



SURGICAL SUTURE

FOR BEGINNERS

A COMPLETE STEP-BY-STEP GUIDE FOR DOCTORS, NURSES, PARAMEDICS ON SURGICAL KNOTS AND SUTURING TECHNIQUES USED IN THE EMERGENCY ROOM AND SURGERY



Surgical Suture for Beginners

A complete step-by-step guide for doctors, nurses, paramedics on surgical knots and suturing techniques used in the emergency room and surgery



© Copyright 2021 by Nurse Academy - All rights reserved.

The following Book is reproduced below with the goal of providing information that is as accurate and reliable as possible. Regardless, purchasing this Book can be seen as consent to the fact that both the publisher and the author of this book are in no way experts on the topics discussed within and that any recommendations or suggestions that are made herein are for entertainment purposes only. Professionals should be consulted as needed prior to undertaking any of the action endorsed herein.

This declaration is deemed fair and valid by both the American Bar Association and the Committee of Publishers Association and is legally binding throughout the United States.

Furthermore, the transmission, duplication, or reproduction of any of the following work including specific information will be considered an illegal act irrespective of if it is done electronically or in print. This extends to creating a secondary or tertiary copy of the work or a recorded copy and is only allowed with the express written consent from the Publisher.

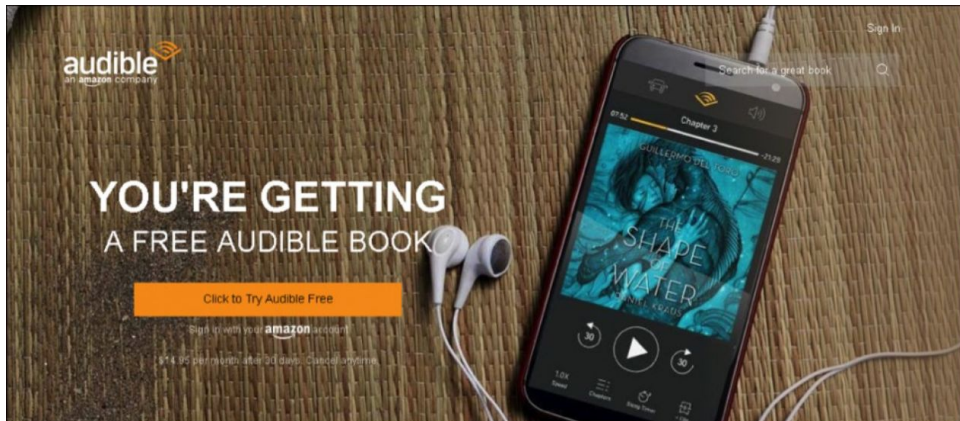All additional right reserved.

The information in the following pages is broadly considered a truthful and accurate account of facts and as such, any inattention, use, or misuse of the information in question by the reader will render any resulting actions solely under their purview. There are no scenarios in which the publisher or the original author of this work can be in any fashion deemed liable for any hardship or damages that may befall them after undertaking information described herein.

Additionally, the information in the following pages is intended only for informational purposes and should thus be thought of as universal. As befitting its nature, it is presented without assurance regarding its prolonged validity or interim quality. Trademarks that are mentioned are done without written consent and can in no way be considered an endorsement from the trademark holder.

Download the Audio Book Version of This Book for FREE

If you love listening to audio books on-the-go, I have great news for you. You can download the audio book version of this book for **FREE** just by signing up for a **FREE** 30-day audible trial! See below for more details!



Audible Trial Benefits

As an audible customer, you will receive the below benefits with your 30-day free trial:

- FREE audible book copy of this book
- After the trial, you will get 1 credit each month to use on any audiobook
- Your credits automatically roll over to the next month if you don't use them
- Choose from Audible's 200,000 + titles
- Listen anywhere with the Audible app across multiple devices
- Make easy, no-hassle exchanges of any audiobook you don't love
- Keep your audiobooks forever, even if you cancel your membership
- And much more

[Click the links below to get started!](#)

For Audible US

For Audible UK

For Audible FR

For Audible DE

TABLE OF CONTENTS

Introduction

Chapter 1: Armamentarium

Suture Material

Classification of Suture Materials

Absorbable vs Non-Absorbable

Synthetic vs Natural

Monofilament vs Multifilament

Suture Size

Suture Needles

Hand Instruments

Needle Holders

Skin Staples

Needle Holder Care

Chapter 2: Surgical Knots

Properties of an Ideal Knot

Principles of Knot Tying

Types of Knots

Square Knot

Surgeon's Knot

Granny Knot

Slip Knot

Reef Knot

Miller's Knot

Aberdeen Knot

Blood Knot

Forwarder Knot

Deep Tie Knot

Constrictor Knot

Chapter 3: Basic Principles of Suturing

Principles of Suturing

Chapter 4: Basic Suturing Techniques

Simple Interrupted Suture

Simple Running Suture

Horizontal Mattress Suture

The Figure Eight Suture

Advantages of Using the Figure-8 Suturing Technique

Disadvantages of Using the Figure-8 Suturing Technique

Interrupted Cruciate Suture

Cruciate Mattress Suture

Chapter 5: Advanced Suture Techniques

Hybrid Suture

Purse-String Suture

Dermal Suture

Subcuticular Sutures

Winch Suture

Cross Suture

Lembert Suture

Lattice Suture

Combined Vertical Mattress Dermal Suture

Kessler's Locking Loop

Cushing Suture

The Running Pleated Suture

Frost Suture

The Bolster Suture


Chapter 6: Postoperative Care of the Sutured Wound and Complications

Topical Surgical Wound Care

Post-Operative Incisional

Conclusion

Introduction



Surgical and severe wounds with sutures and related materials were sealed for decades, but it was only with the advent of local anesthesia 130 years ago that doctors were able to switch from relying on the quickest suture positioning procedure to some of the most effective ones. A paradigm change has occurred from William Halsted's promotion of a buried suture methodology in the late nineteenth century towards contemporary publications on the subtleties of suture placement & tissue handling, with a growing awareness that there are several approaches possible for any suture placement, and that this option may affect performance.

The main theory of suture positioning is to transfer strain as profoundly as possible in the surgical cut, and therefore, adhering to this approach contributes directly to better patient performance, both technically and esthetically. Pressure contributes to higher scarring around the superficial dermis; moving this stress to a deeper dermis or even the fascia, however suturing in a manner that holds the stress deep, helps wounds to heal in the most delicate of scars.

A surgical suture is a medical instrument used during an injury or surgery to tie body tissues together. In general, the application requires the use of a needle with an attached thread length. Over the centuries of its history, a variety of different shapes, sizes, and thread materials have been created. Usually, surgeons, psychiatrists, dentists, podiatrists, eye doctors, professional nurses, and all qualified nursing professionals, physicians, skilled pharmacists, and veterinarians participate in suturing. To protect the sutures, surgical knots are used.

Through flashy titles and multilettered acronyms, surgical history is rife with myriad procedures. Although the titles and acronyms of glamorous and enticing techniques are often desirable, they do nothing to define a strategy or put it within the broader sense of other simple and well-established methods. Besides, this pattern raises the likelihood that described earlier methods may simply be shed off, dressed up, and renamed as apparently new approaches, anything that only helps to raise uncertainty for the beginner and professional alike, because the creation of a shared vocabulary is an essential phase in enhancing strategies and thus performance. *Surgical Suture for Beginners: Solutions to Surgical Wound, Laceration, and Cosmetic Treatments*, where possible, uses descriptive titles for suture techniques, such that the name describes the essence of the procedure, at least somewhat. Also, methods are clarified in the sense of the current literature where appropriate. For instance, the “running looped suture” doesn’t inform the reader of whatever the procedure implies, however referring to it as a “running locking horizontal mattress suture” instantly helps the reader, though in the

absence of a multipage explanation, to grasp the methodological approach.

Independence has been taken in naming methods in the interests of continuity and creating a coherent and translatable nomenclature such that they make intuitive sense. For example, what's been described as the "modified tip stitch" in the literature is thus referred to it as the "modified vertical mattress tip stitch," and what has been originally referred to it as the "vertical mattress tip stitch" is instead referred to as the "hybrid mattress tip stitch." Once the reader understands the methods on which these stitches are centered, the value of the slight shift becomes obvious.

Chapter 1 : *Armamentarium*

Suture Material

Surgical sutures are used for the closing of so many types of wounds. The perfect suture must allow adequate regeneration of the healing tissue to hold the wound closed until it is extracted or absorbed.

Depending on tissue type, the time it takes for a tissue to no longer need assistance from sutures can vary:

- Days: Muscle, tissue, or skin subcutaneous
- Weeks to Months: Tendon or fascia
- Months or Never: Prosthesis of the artery

It is worth mentioning that the body will respond to any suture as a foreign body irrespective of the structure of the suture, creating a foreign body reaction of different degrees.

We will look at the identification of surgical sutures, suture scale, and the features of the surgical needle.

Classification of Suture Materials

Sutures may narrowly be divided into absorbable or non-absorbable materials. They may be further subclassified into sutures that are synthetic or normal and sutures that are monofilament or multifilament.

The perfect suture is the lowest possible pressure to produce uniform tensile strength, holding the wound tightly for the healing time required and then absorbing. It should be predictable, simple to manage, and firmly knotted.

The selected suture type differs considerably depending on the clinical situation. Mass closure of a midline laparotomy may require the use of PDS as a general guideline, a vascular anastomosis may require prolene, a hand-sewn intestinal anastomosis may need vicryl, and a silk suture may be required to protect a surgical drain.

Absorbable vs Non-Absorbable

Absorbable Sutures

Through enzymatic reactions or hydrolysis, absorbable sutures are broken down by the body. The period that this absorption cumulates in changes across the material, suture position, and patient variables.

In skin tissue and materials that recover easily, absorbable sutures are widely used as a result. They can be used in minor intestinal anastomosis, suturing in the urinary or biliary tracts, or tying off small vessels on the surface of the skin.

Total absorption times can vary for the more frequently used absorbable sutures:

- Speedy Vicryl = 42 days
- Vicryl = Sixty days, 60 days
- Monocryl = ~100 days
- PDS= ~200 days, roughly

Non-Absorbable Sutures

To have long-term tissue protection, non-absorbable sutures are used, remaining walled off by the inflammation process in the body (until removed manually if required). Tissues that recover little by little, such as fascia or tendons, abdominal wall closure, or vascular anastomosis, are used.

Synthetic vs Natural

Suture materials can be further categorized by their raw origin:

- Natural - created from natural fibers (e.g., silk or catgut). As they appear to cause a larger tissue response, they are less commonly used. Suturing silk, however, is still widely used in the securing of surgical drains.
- Synthetic - composed of man-made products (e.g., PDS or nylon). They tend to be more predictable, especially in their loss of tensile strength and absorption, than genetic sutures.

Monofilament vs Multifilament

It is also possible to sub-classify suture materials by their structure:

- Monofilament suture (e.g., nylon, PDS*, or prolene)-a single-stranded filament suture. They have a lower risk of contamination, but they still have poor protection and ease of handling of the knot.
- Multifilament suture-composed of many twisted filaments (e.g., braided silk or vicryl). For good knot security, they handle easier and keep their form but can harbor pathogens.

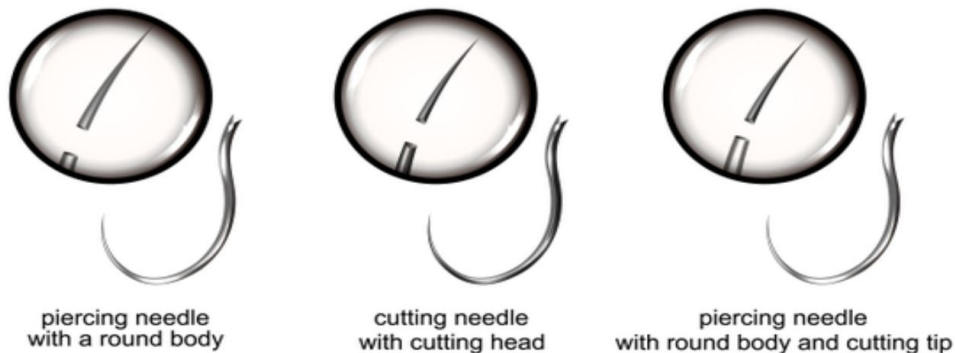
Suture Type	<i>Absorbable</i>	<i>Non-absorbable</i>	<i>Monofilament</i>	<i>Multifilament</i>
Vicryl	✓			✓
PDS*	✓		✓	
Monocryl	✓		✓	
Nylon		✓	✓	
Prolene		✓	✓	
Silk		✓		✓

Suture Size

The suture diameter affects its handling properties and tensile strength. For example, the greater the scale ascribed to the suture, the smaller the thickness, the smaller a 7-0 suture is than a 4-0 suture. The smallest possible size should be used when choosing the suture size, taking into consideration the tissue's inherent strength.

Suture Needles

TYPES OF SURGICAL NEEDLE



The surgical needle enables the suture to be inserted inside the skin, with minimal residual damage bringing the material through. The perfect surgical needle should be rigid enough to survive distortion but versatile enough to bend before splitting, slender enough to mitigate damage, sharp enough to penetrate minimally resistant tissue, and secure within a needle holder to allow precise positioning.

Surgical needles are usually made from stainless steel. They are made up of a number of components.

- The swaged end attaches the suture to the needle.
- The body or shaft of the needle is the area where the needle holder grasps. Needle bodies may be round, sliced, or cut in reverse.
- In friable tissue such as the liver and kidney, round-bodied needles are used.
- Triangular in shape, cutting needles have 3 cutting tips to penetrate rough tissues such as the skin and sternum and have a cutting surface mostly on the concave tip.
- Reverse cutting needles have a convex tip cutting surface and are suitable for hard tissues such as tendons

or subcuticular sutures, and have a decreased chance of tissue cutting.

- The needlepoint, starting at the highest point of the body and running to the end of the needle, serves to pierce the tissue and may be either sharp or blunt.
- Blunt needles are used to close the abdominal wall and friable skin and can theoretically minimize the risk of needlestick infections involving blood-borne virus infection.
- With minimum cutting, sharp needles pierce and scatter fibers and are used in environments where leakage must be avoided.

The structure of the needle varies in its curvature and is defined as the proportions of a complete circle. The most common curvatures used are $1/4$, $3/8$, $1/2$, and $5/8$. Based on the access to the region to be sutured, various curves are required.

Hand Instruments

Suture techniques are used after a surgical operation to ligate, patch, and approximate tissue.

Needle Holders

During a surgical operation, needle holders, also known as needle forceps or needle drivers, are used for suturing. For a safe grip, needle holders usually have a textured tip. They also bring a ratchet (or another mechanism for locking). Any of the tips contain tungsten carbide inserts. Inserts of tungsten carbide are more durable than stainless steel, last longer, and usually have a stronger grip. Compared to stainless steel, tungsten carbide (TC) is stronger. Look for the gold handles

that mark inserts of tungsten carbide. Titanium needle holders are lighter in weight, making them simpler to use for long operations.

Depending on the size of the needle you are using, select your needle holders so that they hold the needle safely. The smaller the instrument, the smaller the holder for the needle.

Skin Staples

Staples are built to be non-crushing as they are placed into the tissue. Our most common instruments used to help in wound closure are included in this list.

Needle Holder Care

If you note any of the above, replace your needle holders if:

- The tip is bent
- There are hairline fissures in the jaws or joints
- There are holes in the TC inserts
- The light shines through when you keep it in its closed state
- The joint is loose
- The ratchet system does not hold firmly
- You are unable to strip rust

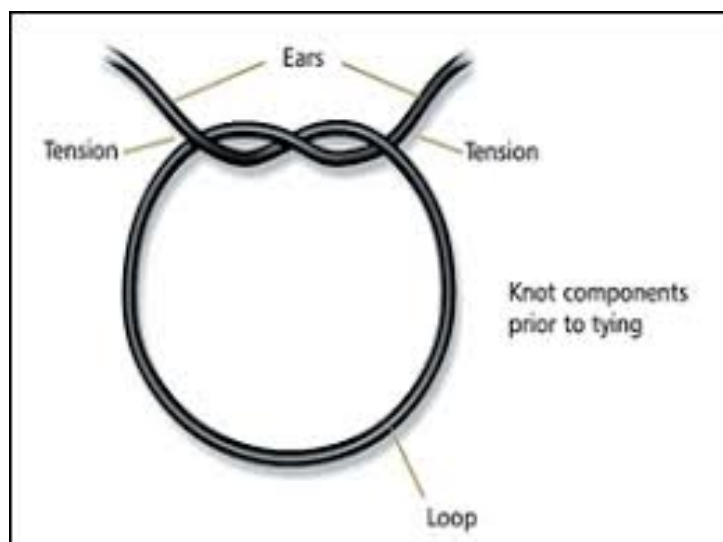
You should be able to hold the hair on your forearm tightly while checking the needle pullers.

Chapter 2 : *Surgical Knots*

Surgical knots have been used in medicine to tie together suture material when binding tissue. They have been used in veterinary and medical environments.

Effective surgical knot binding is a vital skill for doctors, and if the knot doesn't remain intact, the effects can be severe, such as during pulmonary resection, laparoscopic cholecystectomy, and hysterectomy. Primarily, the purpose of surgical knot tying is to cause a knot (or ligature) to be strengthened and keep secure. Ligatures are closed, and several overhand knots have been completed. Slipping, however, often occurs before the final knot is attached, especially during an instrument tie.

Anatomy of the Knot



The knot most often used for binding is perhaps the constrictor knot. The constrictor knot nearly matches the hitch of the clove, except under the dominant turn, both ends form an

overhand knot. There have been new knots mentioned. The surgeon's knot, single-double other side knots, strangle knot, and adapted miller's knot are other widely employed knots.

The surgeon's knot was a normal ligature, but it shows slippage in one study. A knot is used to protect the suture, whereas the suture is being placed in place. Within the body or outside of the body, tying the knot can be finished. Knot binding inside the body takes time to learn about these two choices, so the surgeon is expected to use laparoscopic instrumentation to loop the suture instead of his fingertips.

For certain surgeons, securing the knot outside of the body is easier when the suture is looped by fingertips than in typical tying. To build the knot, each shaped knot must be directed through with a laparoscopic cannula and made close with a knot-pusher.

In laparoscopic surgery, if the knot pusher is used, a better-braided suture is always favored because suture fraying is a symptom of this process. A downside to knot binding outside of the body is that it also creates more strain when suturing fragile tissue, which can trigger tissue breaking.

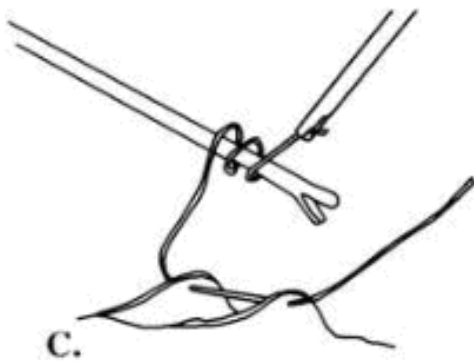
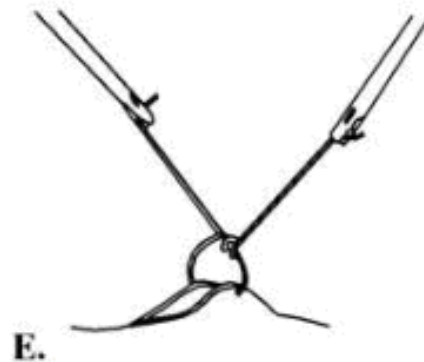
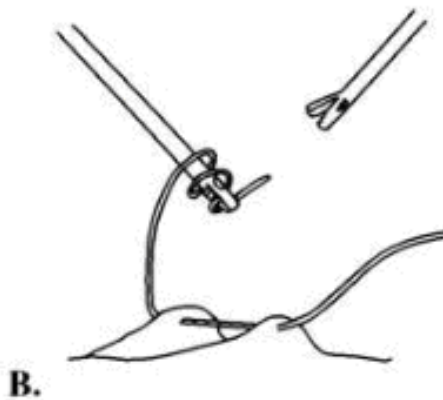
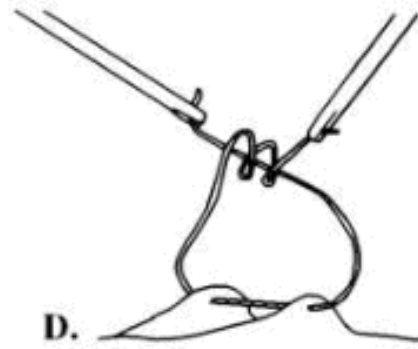

Properties of an Ideal Knot

The main property of an ideal knot is the ratio of its length to diameter, which we term the relative length, which is the principal characteristic of an ideal knot. A fair measurement of the difficulty of a knot is this ratio; the larger the specific length, the more difficult the knot is. Since the relative length of the constituent optimal factor knot does not add up to those

of their ideal composite knot, irrespective of the form of a composite knot, the sum exceeds the relative length of the composite knot by around the same value. If we presume the diameter of the tube containing the composite knots, it should not be too hard to see that each variable knot loses one-half of a quasi-circular arc of 1 cm radius mostly in composite knots produced and receives one straight section of around 1 cm in length.

In particular, the arcs that are removed by the fusion are much longer, as the winding angles are not equal. In sum, the reduction in length is normally much greater than the diameter compounded. The lengths of removed arcs and new linking segments vary because the intersection points of factor knots will have various local configurations for different forms of composite knots. This causes, with a continuous variation, minor variations from subadditivity.

Principles of Knot Tying



Since the beginnings of documented history, the binding of knots has played a significant role in people's everyday lives and grew to a form of art in the sailing culture of the 15th century, where complex knots were clarified under a vow of secrecy. The proper application of the correctly positioned

knot in medical technology is as much a science as it is an art form, which all surgeons must learn painstakingly.

The proper application of a tying procedure in ocular surgery will facilitate difficult operations, facilitate healing, and mitigate the formation of scars. Alternatively, failure to use the right technique, with potentially catastrophic consequences, will lead to knot failure. Wounds may leak, contributing to endophthalmitis and vision loss. Significant bleeding can occur when the suture rope is unnecessarily untied around a vessel.

You will find much in the scientific literature. For individual surgical uses, there are various tying methods. Several microsurgical procedures that can be extended to several conditions, which should be components of any ophthalmic surgeon's armamentarium, are described here.

Underneath the optical microscope, simple surgical knot binding involves the handling of sutures with tying forceps. For good knot tying, correct handling of the forceps is important. It is important to use the tip of the binding platform to grab the suture. If it is not possible to comprehend the suture material, the tying platform should be tested for insufficient completion due to platform injury or foreign matter incarceration. The tying platform can be forced to gape by over-compression or close gripping of the handle. If the suture is longitudinally loaded onto the tying forceps such that the suture is becoming a forceps extension, it is better to tie the suture from around the second tool to prevent the problem. In microsurgery, knowledge of managing the suture material inside the binding forceps is a critical step to effective knot tying.

The suture is placed in a longitudinal direction on the top of the tying forceps such that the suture has become a forceps extension. Via placement, the flexibility with which the surgeon coils the suture around the tying platform improves. The suture in the tying platform is loaded obliquely. The positioning also makes it harder to loop the suture around with other tying forceps and with less leverage.

The wound edges should be added if a suture is tied. The globe should preferably be compressed. To achieve this purpose, multiple different knots can be used. The tension produced by the suture itself will decide which knot form is used to protect the suture. Rough threads create slipknots that are weak. Clean sutures are quickly hooked into slipknots, such as nylon.


In ophthalmic microsurgical knot tying, the fundamental concepts include:

1. For the wound edges to be correctly approximated, the suture must be tied.
2. The real suturing role is done by the first knotting loop, considered the approximation loop. It applies and fixes the wound edges at the desired position. Both extra loops only help to protect the estimated loop.
3. The securing loops must be squeezed at right angles to the suture plane so that the suture tension formed would not be disturbed.
4. As this can lead to tissue distortion or strangulation, the approximate loop must not be bound too closely.
5. To a correctly tied knot, additional throws do not add strength and instead lead to the bulk. It can be hard to bury a bulky knot.

6. A knot's holding strength largely depends on the tension produced inside the tighter loops (hence, the quality of the suture material plays an important role in knot construction).
7. As a result of its high tension, rough suture material prefers square knots.
8. Gentle suture materials prefer slipknots. Even before the approximation loop is tied, the approximating loop begins to loosen.
9. Attention to the technique of knot-tying is very necessary. From the same original loop structure, square knots and slipknots may be connected. Whatever knot is generated can decide only the position of traction on the knots.
10. To prevent injury to the suture material while treating it, caution must be given. Stop improper suture distortion of surgical equipment. Excessive suture management or twisting inside the tool can contribute to premature failure of the suture.
11. Knots left on problem surfaces are a cause of the discomfort, so knots should be as minimal as possible, and they should be buried inside the tissue unless the substance is adequately tissue compliant.

While thousands of knots could be used to cover wounds, only a few satisfy the need to be realistic, powerful, and accurate.

Types of Knots



Square Knot

A square knot, which in itself is a type of final knot, is among the simplest knots. This knot is good for wrapping up parcels and packets. It can also be used for first aid, where it can be used to tie a bandage over a wound to rapidly stop the bleeding. The square knot is also known as the reef knot when it was used by sailors in strong winds to reef sails or tie down half of the sail.

One-Handed Technique

The square knot is tied using the two-hand method whenever possible. For certain times, one hand, either left or right, would need to be used to tie a square knot. In tying single suture strands, the series of throws demonstrated is most widely used. If the surgeon carries a reel of surgical sutures in the right hand and positions a series of ligatures, the order can be reversed. In this case, it should not be stressed so much that the paths that the hands move must be reversed to guarantee

that the knot-shaped lands flat and square through one throw to another. If this measure is not taken, half of the hitches result.

Now one of the hands of the surgeon is busy holding a tool or the needles for the suture. A one-hand technique can be used in certain circumstances. The value is that only one hand is used to tie the knot, and then the other hand never loses the thread touch.

There are two simple steps called “index finger” and “middle finger” techniques in the process. It is possible to pick one of them to execute the first throw of the knot.

Here the index finger approach will be used to execute the first throw.

Procedure:

1. The white strand of rope is stretched over the index finger and kept between the thumb and the index finger of the left hand. A purple strand is held between the thumb and the right-hand index finger.
2. By shifting the right hand further away from the handler, the purple strand is brought over the white strand on the left index finger.
3. A distal phalanx of the left index finger crosses underneath the white strand with a purple strand protected by the right hand, positioning it over the tip of the left index finger. In preparing for applying friction, the white strand is then drawn through the circle.

4. In the horizontal plane, with the left hand drawn towards and the right hand away from the handler, the first half hitch is accomplished by advanced friction.

Two-Hand Technique

In tying most suture materials, the two-hand square knot is the easiest and perhaps most effective. The surgical bowel, virgin linen, surgical cotton, and surgical stainless steel can be tied together.

If suggested by the surgical situation as well as the expertise of the surgeon, the traditional procedure of flat and square ties with external throws must be used to tie Panacryl braided plastic absorbable suture, Monocryl (poliglecaprone 25) suture, Vicryl coated suture (polyglactin 910), Vicryl Rapide coated suture (polyglactin 910), PDS II (polydioxanone) suture, Ethilon nylon suture, Ethibond Excel polyester suture, Permahand silk suture, Pro Nova poly (hexafluoropropyleneVDF) suture, and Prolene polypropylene suture.

Procedure:

1. The white strand is put over the left hand's stretched index finger as a barrier and held in the left hand's palm. It is kept in the right hand with a purple strand.
2. The purple strand is placed between the left thumb and the forefinger of the right hand.
3. Through pronation, the left hand is rotated upward, and the thumbs are twisted beneath a white strand to create the first circle.
4. The purple strand is crossed across the white and placed between the thumbs and the left-hand index

finger.

5. A purple strand is released from the right side. The purple strand is put through the white cord, then the left hand is supinated, with thumb and index finger still gripping the purple strand. The purple strand is then regripped with the right hand.
6. Release the purple strand from the left hand and hold it with the right. With the left hand toward the operator and the right hand away from the horizontal, stress is applied. This makes the first half hitch complete.
7. The left index finger is separated from the white strand and the left hand again supinated over the left thumb to loop the white strand. The purple strand is held in the right hand and pointed slightly to the left.
8. With the right hand, the purple strand is taken towards the operator and put between their left thumb and index finger. The purple thread crosses the white strand.
9. The white strand slips onto the left index finger by the more supinating left hand to form a circle as the purple strand is squeezed between the left index finger and thumb.
10. By pronation, the left hand is turned inward, with the thumb carrying a purple strand around a white strand loop. The purple string is caught between the right thumb and index finger.
11. With the left hand away from the operator and the right hand towards them, horizontal stress is applied. This completes the second hitch of the half.
12. The final stress must be as near to horizontal as possible on the last throw.

Surgeon's Knot

A surgeon's knot or surgical knot is a basic adjustment to the coral knot. While tying the very first throw, it adds a twist, creating that double overhand knot. The extra turn gives more tension which can minimize softening when tying the second half of the knot. This knot is generally used among surgeons in conditions where friction on a suture is necessary to retain, giving it its name.

The surgeon's knot is often used for fly fishing, for binding quilts, and also for tying twine knots; it is especially useful for tying meat with butcher's twine, as wet meat presents equal risks of softening as surgery. Some sources classify the knot of the surgeon as a bend since, as such, it can be successful.

Like the coral knot, if one of the operating ends is taken away from the standing end nearest to it, the surgeon's knot capsizes and collapses.

Procedure:

1. The white strand is put over the extended left-hand index finger and held in the left-hand palm. A purple strand is held between the thumb and the right-hand index finger.
2. By shifting their right hand away from the operator at an angle to the left, the purple strand is crossed over its white strand. The thumb and index finger of the left hand are pinched over the index finger to create a loop in the white strand.
3. Through pronation, the left hand rotates upward, and the white strand loop falls onto the left thumb. The

purple strand is grasped between the thumb and the left hand's index finger. Release the right hand.

4. Rotate the left hand by supination, stretching the left index finger to pass via a loop of the purple strand. Regrasp the purple strand with the right hand.
5. After pronouncing the pinched thumb and index finger of the left hand under the loop, the loop slips onto the thumb of the left hand.
6. The purple strand of the right hand is traced left and again grabbed between the thumb and the left hand's index finger.
7. The left hand is twisted through supination, stretching the left index finger by creating a double loop to move the purple strand again.
8. With the left hand toward the operator and the right hand away from them, horizontal stress is applied. And for the final knot, the double loop must be put in a specific location.
9. The purple strand is gripped between the thumb, and index finger of the left hand, with the thumb, swung under the white strand and held over the white strand with the right hand.
10. Liberated Purple Strand. The left thumb supinates under the chain of a white strand to regrips the purple strand with the index finger.
11. Under the white strand, the purple strand rotated by supinating the squished thumb and left-hand index finger to pull the purple strand around the circle. To full, the right hand grasp the purple strand
12. With the left hand away from and right hand against the user, hands begin to add horizontal friction.

The final stress should be as close to horizontal as possible on the final throw.

Granny Knot

The granny knot is often used to tie a rope or line around an object, is a binding knot. The reef knot (square knot), which it shallowly resembles, is called inferior. By connecting two ropes together, none of these knots should be used as a binding knot.

The granny knot is often referred to as the bogus, lubber's, goat's, and booby knot. In Patterson's Illustrated Nautical Encyclopedia, it is called the "old granny knot." Sir Edwin Arnold calls it the "common or garden knot." In Vocabulary of Sea Phrases, the name granny is given, and Roding portrayed the knot in 1795.

The granny consists of two half-knots that are similar, one tied on top of the other. It has only one functional reason I know of, and that is to serve as the knot of a surgeon. It was commonly used in five-and-ten-cent shops for tying up parcels, but the method was discontinued, and cloth bags were replaced as they were easier.

Procedure:

1. Connect two ends and hold one for each side of the line you choose to join.
2. Like a basic overhand knot, loop the left end over the right.

3. Switch the ends into each other and, as before, loop the left end over the right.
4. Get the knot modified. The ends should be perpendicular to the section of the line that is load-bearing.
5. Know what a granny knot can be used for. Know that this knot is vulnerable to sliding open and should not be used in any condition that needs strength or weight to keep. It is useful for showing children how and when to tie knots, and it is great for loose knots to play a game or keep crafts or other things briefly in place before glue, staples, or nails are placed in place. It may also be used to tie packets together, apply hair ribbons to hair, connect bandages, and tie shoelaces.

Slip Knot

A stopper knot is a slip knot that is quickly removed by removing the tail (working end). The slip knot is connected to the moving knot that releases as the standing end is pulled. All knots are similar, and consist of a slipped overhand knot, where the knot may be freed by pulling on an end by a bight; the working end for a slip knot, and a running knot by the standing end. The slip knot is used for crocheting and knitting as a starting place.

The slip knot is a stopper knot that can be automatically spilled or slipped by pulling to remove a loop on end. There is only one knot entitled to the name.

Procedure:

1. Start by keeping your yarn in the arch. Leave a long enough tail for the initiative on which you are employed.
2. Spin the arch top from right to left.
3. Stretch open the loop using two fingers and stretch the loop with the index finger and thumb open at the tip.
4. Push the loop into the right strand.
5. When you have drawn the strand up into the loop and pulled up through the loop, keep it loose and do not tighten yet.
6. Set your loop on the needle.
7. Around the hook or needle, secure the string and tighten the strands securely, and not too tightly, but enough so that the loop will slide easily onto your needles or hook.

Reef Knot

A reef knot is a traditional and basic binding knot that is used to tie a rope or string around an item is the reef knot or square knot. A left-handed overhand knot and a right-handed overhand knot, or vice versa, are formed by binding the knot. “Right over left; left over right” is a popular short word for this technique, which is sometimes attached with the rhyming suffix “... makes a knot both tidy and tight” A granny knot would be formed by two successive overhands of the same handedness. Whether at the top or the bottom, the functioning ends of the reef knot must appear. Otherwise, a thief knot occurs.

The reef knot comprises of two half knots, one left and one right, one tied on top of another, and one bound first. The reef knot is unusual in that both ends can be tied and twisted. For

boxes, rolls, and bundles, it is commonly used. It is often used at sea to reef and furl sails and to avoid drying fabric. But in no conditions can it ever be wrapped as a bend, for the knot has been almost bound to leak if tied with two ends of different length or if one end is tighter or softer than another. It is a knot to be disowned but for its legitimate function of linking.

Procedure:

1. Bring together two sides of the very same thread right over left in this situation.
2. Wear a half knot and see how spiraling to the right, right to left, the two interwoven knots part.
3. Put the two sides back together, with the left over properly this time.
4. Tie a knot for the second half. Remember that the two twisted pieces to the left and the reverse of the half knot right to left.

Miller's Knot

The miller's knot is a linking knot that is used to close a sack or bag's opening. Big bags, traditionally, frequently held grains, hence the connection of these knots with the exchange of a miller. So many knots are identified by these three names synonymously.

A fiercer binding knot is made by a constrictor, but the miller's knot is ideal for most purposes and is simpler to tie and untie. Like the related ground-line, the miller's knot makes a perfect hitch. Locking use has force uniformly

originating from the internal rope loop, hitch use has pressure input from one hand, then decreases.

Procedure:

1. Hold the bag's collar with the left hand
2. Solve one end of the rope tucked up over its long tips of the finger's hand and double-fold as a bight underneath the index finger to allow a start-side-slip for the last knot.
3. From around the collar of the bag, create two crossing twists.
4. Circle the hand downward and switch its front around like the back collar of the bag underneath the hand at the backside of the hand.
5. Roll the hand upwards, including over the other side.
6. Only at the opening end of the palm require a quick turn around the collar of the bag and overhand.
7. Roll over other ends of a rope, then switch back tucking underneath the crossing point of the other end, and the section between both the two transforms this last strap with a bight as a finished last knot rather than the end.

Aberdeen Knot

The Aberdeen knot has also been found to be tighter and smoother for completing a suture line than that of the surgeon's knot. There is little knowledge as to the optimal layout of the Aberdeen knot. Six throws were suggested by the Royal College of Surgeons of England in its Basic Surgical Skills Course. The goal of this experiment is to explore the optimal balance of twists or changes.

In the O-PDS suture, Aberdeen knots of different configurations are tied in. They tie each setup ten times. To check the knots for failure in a standardized manner, a substance inspection device has been used.

In multiple forms, the knots were shown to act: whether they fell, they unwound, or they split. There were weak knots tied with less than three throws. The best arrangement tends to be knots tied with three throws and two twists. The force of an Aberdeen knot is not improved by incorporating more twists or changes.

The Aberdeen knot looks difficult to tie, however, this surgical knot is one of the simplest and fastest. It is maybe for this purpose that surgeons may not believe it because they do not think it can carry such an easy knot.

Procedure:

1. A needle-attached end of the suture is placed using a right-handed tool at the ends of a straight suture line and moved via the device into the loop from the last suture.
2. The left-handed device, the right-handed mechanism, and the circle into which the suture is placed are moved through the triangle formed by the implanted suture.
3. On the left-handed device, the suture retained by the right-handed method is then pulled, closing the loop and forming a new one.
4. The right-handed device is passed through the loop, and the same procedure is then repeated two or three times.
5. The needle-attached ends are passed via the circle to complete the knot, and the knot is tied.

Blood Knot

A blood knot is by far the most effective bend knot used to join monofilament nylon line sections, thus retaining a large portion of the inherent power of the thread. A major lack of power may be caused by other knots used for this reason. In fly fishing, with castable fly close cooperation at the diameter end as well as the fly or hook at the small surface end, this helped to increase a leader of steadily declining diameter. The only downside to the blood knot is the dexterity needed to tie it. It is also probable to jam, which is not a fishing line problem. This is not a huge loss to cut, but it might be a normal rope concern.

The barrel knot, called Keith Rollo's blood knot, is the greatest bend for both the simple, tight, or slippery line there is. The finishes may be performed immediately, and when taken through the water, the knot provides the least effort possible.

A half-blood knot is a knot that is used to secure a fishing line to a lure, snap or swivel fishing lure. They are perceived to be one knot and called a blood knot when two half-blood knots are being used to participate in two lines. They are one of the greatest nodes for attaching a medium-sized hook to a medium-sized line.

Procedure:

1. The two lines to be connected are intersected for 6–8 cm with the short endpoints of the two lines in different directions when trying to tie the blood knot.
2. At the start of wraps, the short end of one line is wrapped 4-6 times from around two lines, and the

remaining portion of the very first short end is eventually brought and passed between both the lines.

3. The second line's short end is then wrapped around the first line 6 times, and the end of this line is eventually brought and passed through what is now an inverted cone space across each set's first wrap.

Forwarder Knot

Forwarder knots for the beginning of steady operations are more stable than square knots and perform well during fat and fluid media. For creating a stable and solid knot, the forward knot (F) and backward knot (B) are simple knots to learn. They are, happily, super simple knots to make. Typically, this knot is created with sewing floss, but it can also fit with the other string styles.

Procedure:

1. Pick a little from left to right through the tissue.
2. In the left hand, keep the working ends of the suture. In the right hand, hold the needle holder as well as the free ends of the suture.
3. Switch the working end of the suture over both the needle holder as well as the free end. Run the variation two times, making three throws.
4. For the needle holders, grab the working end, pushing the worked end into the looped throws while the needle holder is pushed out.
5. In opposing directions, push the working end and free end, stretching and holding the knot.

Deep Tie Knot

This can be tricky to tie deep into a body cavity. As in other cases, the square knot must be tightly snugged down. The user, however, must prevent upwards strain that may break or avulse a tissue.

Procedure:

1. Strand the loop on the training board with the index finger of the right hand. Cross the hook in the plastic cup while holding the purple strand in the palms of the hand. Keep the white strand in the left palm.
2. The purple strand is placed between both the left thumb and index finger of the right hand. By pronation, the left hand is rotated upward, and the thumb is swung beneath a white strand to create the first circle.
3. Progress the loop into the cavity by putting the left-hand index finger mostly on the white strand.
4. Horizontal tension is exerted by pressing down with the left index finger on the white strand while keeping counter-tension with the right-hand index finger on a purple strand.
5. On the right side, the purple strand is looped over and under the white strand.
6. To shape the second loop, the purple strand is looped from around the white strand. This throw is progressed into the cavity depths.
7. Horizontal stress is introduced by pressing down with the right index finger on the purple strand, thus retaining counter tension with the left index finger on the white strand. The final voltage should be about as horizontal as natural.

Constrictor Knot

The constrictor knot is among the most successful linking. Easy and effective, it is a tough knot that is twisted and can be difficult or even impossible to untangle. Similarly, to a clove hitch, it is created with one end going under another, creating an overhand knot under a riding turn. A far more comprehensive variation featuring two-rider turns is a double constrictor knot.

Procedure:

1. Make a turn across the entity and take the working end out of the standing part.
2. Move the working end, creating an overhand knot underneath a riding turn, over the standing part, then under the riding turn and standing part.
3. Make sure that the ends appear as seen in between two turns. To tighten, tug tightly on the ends.

Chapter 3 : *Basic Principles of Suturing*

Most of the suture selection procedure relies on the preparation and choice of surgeons. With each surgical position and surgical need, a large range of suture materials has increased. Also, the surgeon uses the shortest suture that keeps the edges of the healing process properly. The hardness of the suture can never exceed the tissue's tensile strength. When the wound heals, there may be a slow relative loss of suture strength across time than the increase of tissue tensile strength.

The selection of sutures may be extended to some general concepts. When an injury has achieved full strength, sutures are no longer required. Non-absorbable sutures in the skin, fascia, and tendons (slowly healing tissues) should also be considered, while mucosal wounds (rapidly healing tissues) are closed with surgical sutures.

In areas of the head and neck, including the eyelid, periorbital region, nose, pinna, tongue, and vermilion, esthetic issues are at a premium.

Tensile strength criteria tend to be lower in these regions, and smaller suture sizes are favored. Although a comparatively higher suture tensile strength is required for the flexibility of the lip and vermillion.

Higher tensile strength criteria in suture selection are needed for the action and mobility of the face, anterior and posterior body, scalp, superior trunk, and nasal and oral mucosa. In comparison, major musculocutaneous flaps requiring optimum

long-term tensile strength tend to be closed under substantial stress.

If the surgical operation is completed and the wounds are properly irrigated and debrided, the flap must be restored to its original location by the surgeon or, if necessary, arranged in a different position to keep the flap and sutures in place. Multiple functions are carried out by sutures. The clear and significant role performed by sutures is to grab wound margins, that is, to keep the flap in place and estimate the two wound edges. The finer the incision and the less damage caused on the margin of the bite, the more likely the main intention is to heal. If there is limited space between the two wound ends, wound healing would be swift and complete. If the wound edges are bleeding or there is unnecessary trauma, wound healing would be of secondary intention.

Often, sutures help in hemostasis. If bleeding occurs in the underlying tissue, the mucosa of the surface or skin must not be closed, as bleeding may persist in the surrounding tissue, contributing to the development of a hematoma.

In hemostasis, surface sutures support but only as a tamponade in a typically oozing area, including a tooth socket. To gain hemostasis in a leaking tooth socket, overlying tissue can never be firmly sutured.

Sutures help keep a flap of soft tissue above the bone. This is an exceedingly essential feature since the bone that is not surrounded by soft tissue remains nonvital and takes an unnecessarily long healing time. The depth of the bone must be retrieved with soft tissue flaps once mucoperiosteal flaps are expressed from the alveolar bone. The flap can retract

away from the bone, which reveals it and contributes to delayed healing unless sufficient suture technique is being used

Principles of Suturing

These are some principle of suturing:

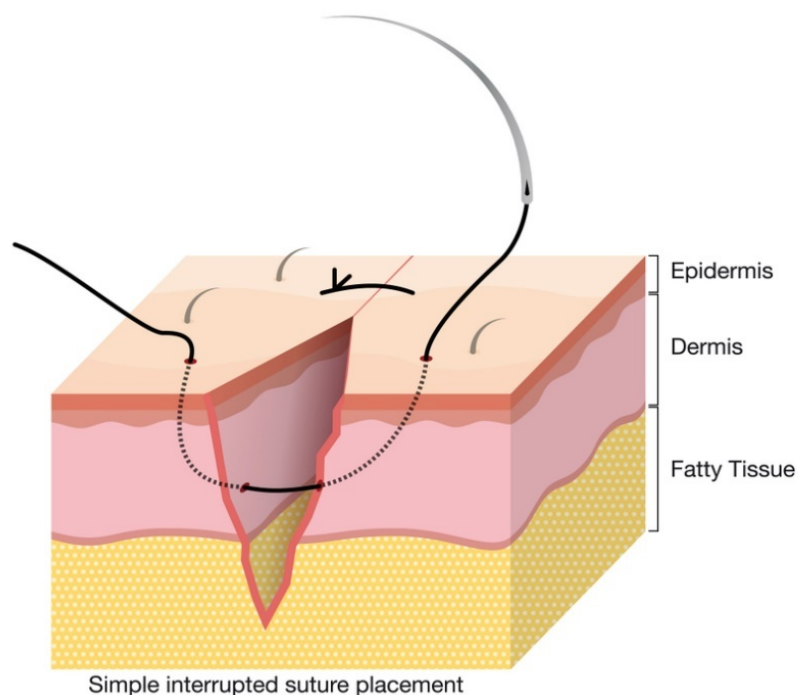
- Needles can be gripped at about $\frac{3}{4}$ of the range from the tip of the needle with the aid of needle holders.
- Because it is the lowest point of the needle, the needle can never be placed at the suture end, and gripping at this point results in either bending or splitting the needle.
- The tissue should be penetrated perpendicular to its surface by the needle.
- Along with the curvature of the needle, curved needles can travel through the tissues to avoid tissue tearing.
- The suture should be equidistant (2-3 mm) from the axis of the incision.
- If one end of the incision line is fixed and the other end is open, it is appropriate to move the needle from free to fixed.
- If one side of the tissue is thinner than the other side, the needle will travel from the thinner side to the thicker side.
- If one side is thicker and the other side is shallow, it can move deeper to the superficial side of the needle.
- The distance between the incision point and the insertion of the needle must be less than the extent of penetration of the needle into the tissues.
- The suture must not be bound so firmly that it contributes to tissue blanching.

- It is important to position each suture between 3 and 4 mm apart.
- It is not appropriate to position the knot over the wound margins.

Chapter 4 : *Basic Suturing Techniques*

A doctor uses sutures to seal cuts on your skin or other tissues. They will use a needle holding a piece of thread to stitch the wounds shut while the doctor sutures a cut. There is indeed a range of tools available that can be used to suture. The doctor will pick a substance that is best for injury or treatment.

Simple Interrupted Suture



This is the most popular and easiest method of suturing. Implanting the needle perpendicular to the epidermis brings the suture in place. Perpendicular insertion tends to be used in the suture in a broader bite of thicker tissue than on the surface, contributing to faster wound healing. This results in a

smaller scar and cosmetically attractive results. At the foot, the stitch must be longer than it was at the top. A knot is eventually connected to protect the suture.

To grip the skin edge throughout suturing, small-toothed forceps, such as the Clayton forceps seen here, should be used. With minimum friction, forceps with teeth have a comfortable grip, thereby they prevent grinding the edge of the flesh. For the first three fingers, the forceps could be held like one might hold a pen.

It is important to place the needle holder in a manner that is relaxed and provides optimum power. By partly slipping the thumbs and ring finger into the coils of the handle, many surgeons grasp the needle holder. Note that there are additional power and stabilization offered by the index finger. This shows the same understanding, but also with the hand being pronated. Supination and pronation are important for the rounded needle used in surgery to be manipulated.

As a guideline, at its middle, the needles must be grasped 50-60 percent back from the pointed part. The needles must be grasped 1-2 mm from the tip of the needle holder. As this can weaken the suture, one must stop gripping the suture material or the outer part of the needles with the needle holder.

The positioning of the 1st suture is initiated by gripping the skin edge and slightly everting it. The right hand is twisted into flexion so that the surface is cut at an angle of 90 degrees by the blade. Remember that to discourage tangling, the trailing suture is placed away from the surgeon. By spinning the needle holder, the needle is pushed into the maximum thickness of the tissue (supinating). By having the needle shaft

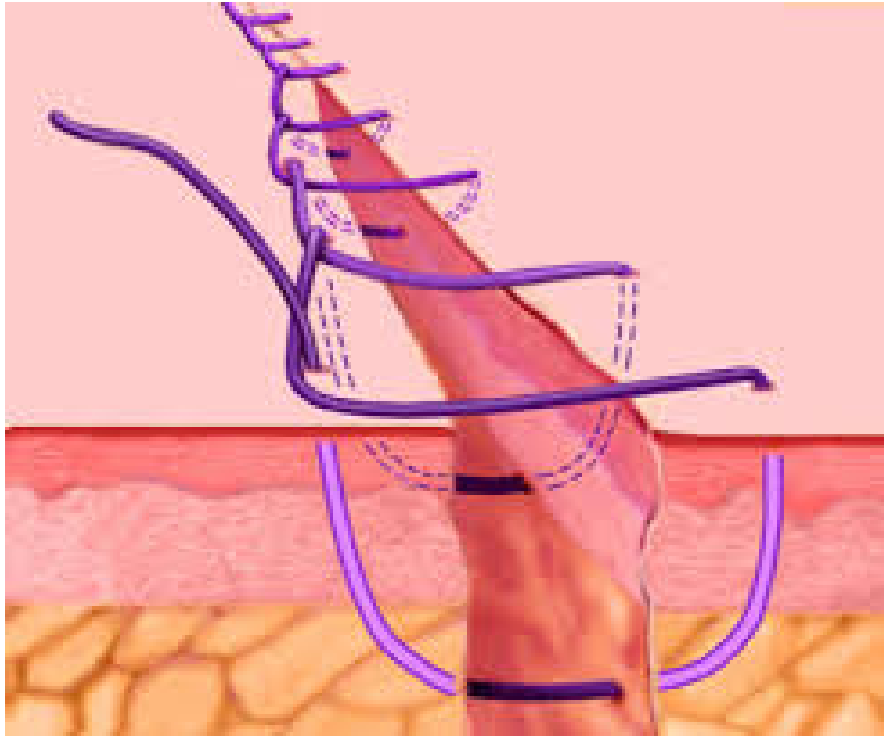
parallel to the surface of the skin at all times, in traversing the skin as tragically as practicable, one takes full advantage of the curve of the needle.

In either dented forceps or a skin hook, the injury edge must be carefully protected. The needle must penetrate perpendicularly to the tissue, 3-5 millimeters from the wound edge. Having entered perpendicular allows the suture to have a larger bite of deeper tissue than on the surface and thereby causes further eversion of the wound and eventually a superior aesthetic effect of a thinner scar. A typical error is penetrating the skin at a softer angle, resulting in the much lower version of the wound tip.

1. The easiest suture to use and sufficient for nearly all cases
2. The needle is inserted into the wound from one hand and out through the wound side.
3. The maximum extent of the dermis can be extended by suture
4. The needle is reinstalled into the contrary direction of the wound at the very same angle and exits from the skin at the very same range from the wound as the injection.
5. Sutures should be positioned between 2-5 mm from the surface of the injury and 5 mm away (this may vary depending on the size of the wound and location)
6. Using forceps or a finger to remove the edges of the wound
7. Aim to bandage the more fixed side from the more mobile edge

8. Knots can be positioned on either side of the surface of the injury and can be used to change the edges slightly to lie close.

Simple Running Suture



A running percutaneous suturing technique is a nice method to help you speed up long wound closures. If you want the most meticulous fix, quick disrupted suturing is always a favorite method, however, when working with fewer cosmetic areas, I like this procedure since it requires less knot tying and gets it done far quicker without losing much in terms of wound appearances.

The percutaneous suturing technique's running benefits provide more even stress distribution from across the entire wound, allowing tissue expansion due to edema and great eversion of tissue.

For long injuries, ones where wound stress has been reduced with correctly arranged deeper sutures and in which estimation of the wound site is fine, running sutures are beneficial. To protect a split or full-thickness skin graft, this sort of suture can also be used. Hypothetically, since fewer knots are created with basic running sutures, less scarring happens with running sutures than receive treatment; nonetheless, the number of needle inserts remains the same. To aid and protect skin grafts, either basting sutures or tie-over bolsters are used. No statistically significant variations in wound cosmesis or problems between running cuticular incisions spaced 2 versus 5 mm apart were found in one study, meaning that the added effort required in inserting very tightly packed sutures might not be necessary, and although the surgeon's interest ultimately dictates the spacing among sutures he or she prefers.

Faster positioning and more efficient approximation of wound site are the benefits of simple moving sutures over simple interrupted sutures. Major disadvantages include potential crosshatching, the possibility of dehiscence if there is a rupture of the suture thread, trouble to make fine changes all along the suture line and then to droop of the suture line when the stitches are inserted in thin tissue.

A modification of the percutaneous suturing method of running requires "locking" each suture loop as you go. This is done by moving the needle into the loop of sutures. This added step allows the suture loop to function more independently throughout the tension-keeping phase.

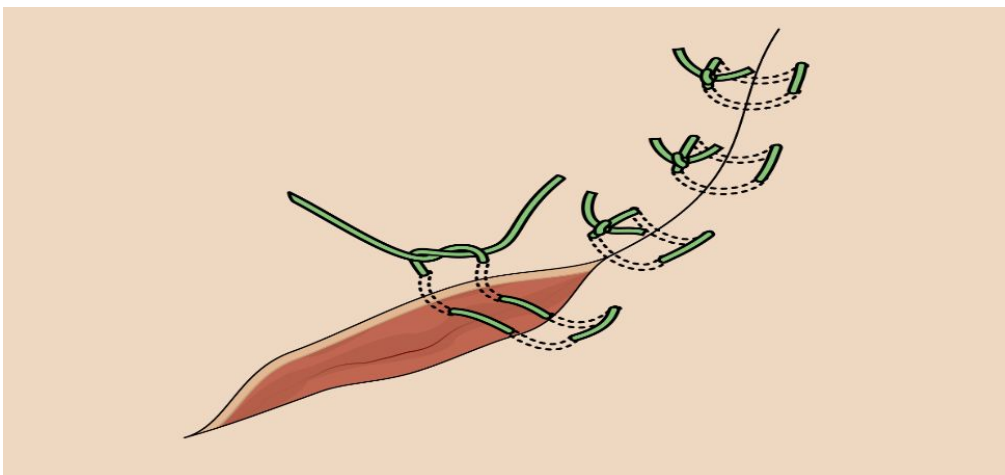
For just a long puncture wound that is mainly straight but might have a little slope to it, this is most effective. Be

recommended to sacrifice the even force distribution that was a benefit of the simple running technique of locking because you have a greater chance of suffocation of tissue.

1. The needle is positioned perpendicular to the epidermis, and roughly half of the needle's radius is positioned at the edge of the bite. It will enable the needle to escape the injury on the contralateral at an average spacing from the wound site by merely following the deformation of the needle.
2. The needle is twisted across the dermis with a smooth motion of the thumb, bringing the bite broader at the deep margins than at the ground, and the needle tip on the contralateral leaves the flesh.
3. Through surgical forceps in the left hand, the needle body is gripped, with received attention to prevent gripping the needle tip, which can be quickly dulled by repeated rubbing against surgical forceps. The surgical forceps are carefully gripped and pushed upwards while the body of the needle is separated from the needle driver. Conversely, the needle from the needle operator can be removed, and the needle operator could be used to catch the needle from the contralateral of the injury to finish the needle via its arc to finish the rotation, eliminating a need for surgical forceps.
4. The advantage of such a suture is that the minimum epidermal fracture point causes the suture to also be left intact longer, avoiding scarring on the suture-track.

5. 10mm distal to one injury end, the needle is inserted and pulled out inside the top of the injury inside the dermis.
6. It is possible to bind the free end of both the suture to itself or lock it with a bead or crimp. Horizontal dermal bites are obtained from the bilateral level of the wounds toward the apex of the injury.
7. As the needle emerges 10 mm from the other end of the injury, the second epidermal puncture is made.
8. In the same fashion as the first, the second free end may be secured. Instead, the absorbable suture thread should be used with the ends tied off under the skin surface.

Horizontal Mattress Suture



A suture technique used during sealing injuries is the horizontal mattress suture. It well captures skin and extends pain around the edge of the injury. This makes it perfect for holding delicate skin together under high stress as well as skin such as the remote edges of a large puncture wound such as the initial suture holding in complex repairs.

The horizontal mattress is so safe that blood flow to the tissue found inside the stitch may be disrupted. This can be effective to avoid bleeding from the wound, but if bound too closely, it can cause suffocation and skin necrosis. It is often possible to put cushioning materials inside the stitch to mitigate this effect. The horizontal mattress will also leave tiny skin wounds called “railroad marks,” like most mattress stitches; for this purpose, it is rarely used on the forehead, and even when used there, it is easily removed. The knot is perpendicular to the side of the wound.

Horizontal suturing of the mattress is a very helpful rear trick to be in your maintenance collection. It is most effective for high-stress wounds where the edges are brittle or frayed in particular. Doctors wouldn't use such sutures much for prime repairs since they wouldn't establish wounds edge attributive as meticulous as basic interrupted sutures or horizontal mattress sutures. This issue can be solved by a minor variation, so if you are just getting familiar with yourself with this method, I will start here.

Throughout the middle of a tough high-stress repair, I consider such sutures most helpful for quick positioning. To allow simple disrupted suturing, wound edges can also be hard to put together. The positioning of horizontal mattress sutures will conquer this obstacle. The very first throw is rendered perpendicular to the wounds, about half of the range between the surface of the wound and the diameter of the needle. For a bigger injury with a bigger needle, this would usually be around 1 cm from the edge of the cut.

In an away manner, the suture needle would then be loaded, and a new throw is made about 1 cm down the wound site on

the very same side, again reaching the wound perpendicularly and leaving on the edge where you began.

Either using an instrument tie or a binding surgical procedure, the suture is then tied. Although “1 cm” is just a rough reference, the range through the wounded or the wounds should usually be identical so that a square box shape is formed.

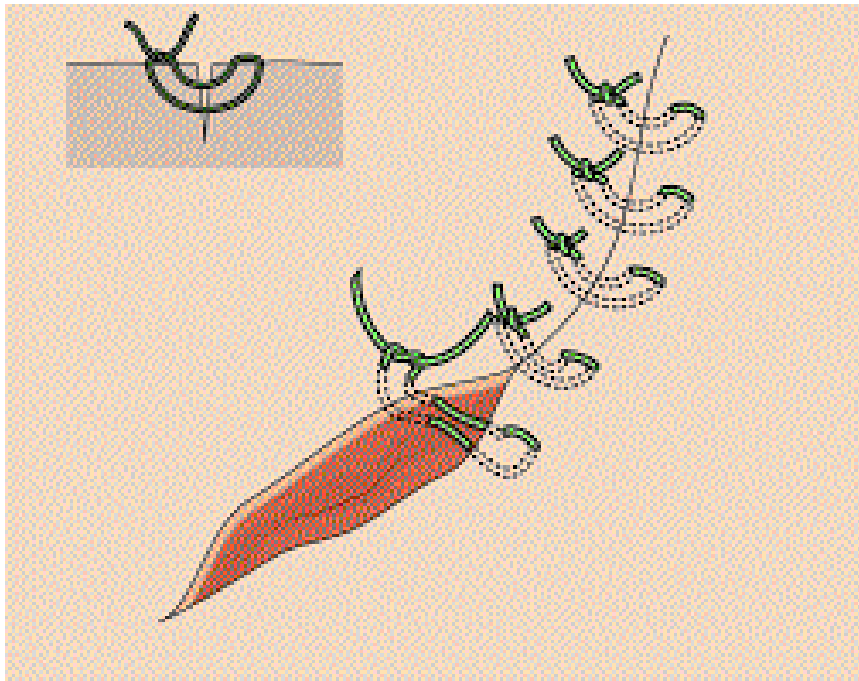
Successful use of this approach is to first position the horizontal mattress to serve as your aid, maintaining the estimated wound edges while doing a more careful closing. In the end, you can also clip this suture—one less foreign body to think about from the wound.

1. Using the forceps, softly raise the skin and impale the facial skin with the needle perpendicular to the surface at around 4 mm from the surface of the cut.
2. Supinate the wrist so that it travels into the dermis through the needle and grows out of the injury core.
3. While you loosen your needle holder, use your forceps to hold the needle.
4. Re-capture the needle with your needle owner in the same position.
5. Using your forceps, softly raise the opposite skin tip.
6. The needle will move from inside to outer perpendicularly across the dermis each time. To pass the needle through the flesh, use the deformation of the needle and supine your wrist. To encourage wound edges to be fairly and neatly opposed, equivalent needle bites of depth and width from the wound must be taken.

7. To grip the needle and pull it through the muscle, use the forceps once. As it passes across the flesh, you can keep following the curves of the needle, dragging the suture across as you go. This should also have a cross-suture perpendicular to the injury, about 4 mm from the side of the scar. You will take a wider 'bite' of skin on either side of the skin under tension, ensuring you reach and leave the skin from 5-8 mm from the edge of the cut.
8. Re-load the needle in the reverse direction now (away from you). The target is to put another 8-10 mm distal suture over the injury perpendicular to your first suture. You need to put a suture back to the other side of the initial entry so you can tie your knot away from or parallel to the cut.
9. Again if you learn this enhances your abilities, you should withdraw your fingertips from the needle holder handle. Use the forceps to softly raise the skin and impale the facial skin with the needle perpendicular to a surface.
10. You will need to breach your wrist so that the needle moves through the dermis and grows out of the wound since your needle is loaded looking backward from you.
11. Use your forceps to keep the needle until your needle holder is released.
12. Re-capture the needle to your needle holder in the same position.
13. Using your forceps, softly raise the opposite skin tip.

14. The needle has to move inside to outside perpendicularly across the dermis this time. To pass, the needle is inserted back to where you stopped; use the curves of the needles and pronate your wrist.
15. To grip the needle and push it through the muscle, use the forceps again. As it moves across the flesh, you can keep watching the curves of the needles. Pull the suture out at last.

Vertical Mattress Suture



The vertical mattress stitch, also called vertical Donati stitch (named after the Italian surgeon Mario Donati), is a suture form that uses closed skin wounds. The benefits of the vertical mattress suture are that it offers deep and superficial surfaces with closure and also enables complete eversion of the scar tissue borders and vertical resistance. A comparatively high ability to dig into the skin and inflict prominent bruises of the stitch mark is its downside.

The vertical mattress stitch is most widely used after extracting a dermoid cyst in anatomical places that appear to invert, including the posterior part of the spine and areas of greater skin laxity, such as the closing of lax skin. It is helpful for shallow puncture wounds, where three sections of deep and shallow sutures may be removed. It will help to pull the outer layer alone again, enabling the remaining surface skin to close with some quick disrupted or flowing stitches. For places including the back of the hand, where major structures were fairly marginal to the skin, vertical mattress sutures aren't suggested.

Another far order with bites is inserted in the vertical mattress stitch. At a 90 ° angle, about 4 mm to 8 mm from the injury margin, a far loop joins and leaves the facial skin. It moves through the dermis fairly deeply. The close loop reaches and leaves the surface of the skin 1 mm to 2 mm from the margin of the cut, overlapping the cut at a depth of 1 mm. Because of the specific level of control offered by the vertical mattress stitch, bites should be curved, particularly the close loop depth, otherwise, the wounded will inevitably misalign and recover on one side with a "shelf." Only before adequate resistance and eversion are reached is the knot strengthened. Over-enthusiastic squeezing increases the probability of the suture substance tearing through the flesh, taking into account the bleeding which will arise and during recovery of the injury. Bolstering stops the suture material from cutting back into the skin (placing thin rolls of gauze underneath the ground loops before strengthening).

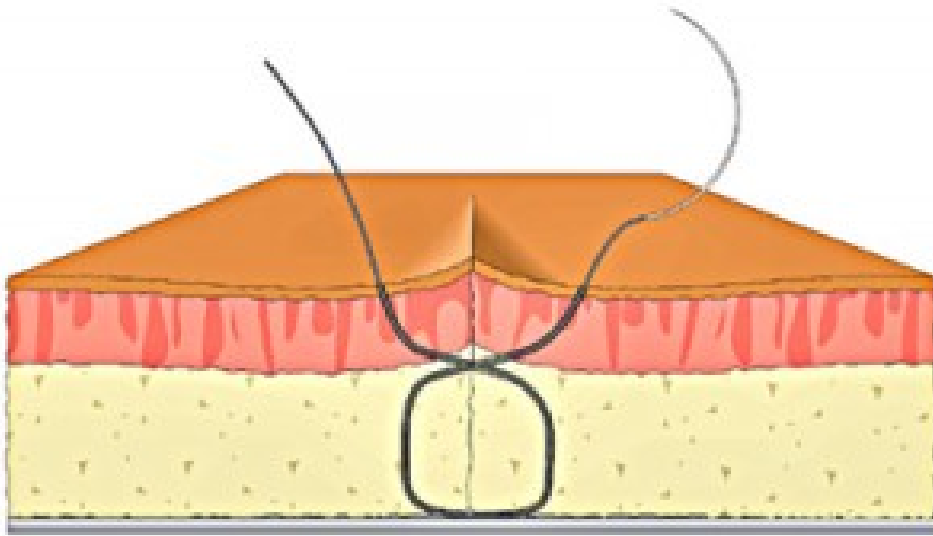
According to its fourfold capacity to attain deep and shallow wound closing, edge eversion, and exact longitudinal

alignment of the shallow wound margins, the vertical mattress stitch has several effects. Many physicians extremely rarely follow such a procedure because of its time-consuming existence. But the benefit of better movements also ensures that the vertical mattress stitch, particularly concerning poor edge detection alignment, is unrewarding of operator error. As mentioned above, like a pizza cutter wire, the vertical mattress stitch is likely to bite into the flesh, and it is more likely than most other suture forms to leave “railroad marks” - small scars around the main injury. Bolstering decreases this issue, but the difficulty of the stitch inevitably rises. All in all, the ability of vertical mattress sutures to develop railway marks prevents the use of vertical mattress sutures in cosmetically sensitive locations, including the ears, and it is still important to remove them as soon as possible.

1. Helps promote the transformation of the wound site
2. Helpful for poorly funded or handheld skin
3. The needle is inserted roughly 5 mm from the wound site as per the basic interrupted suture, and the side opposite is pulled out in that direction.
4. The needle is then reinstalled on the emerging new side closer to the wound (about 1-3 mm), and a superficial bite is taken out from the emerging new side all around the wound, coming out of the surface closer to the wound than that of the original correct depth.
5. On the initial insertion foot, the knot is then attached.
6. This suture offers good wound protection, eliminates void spaces, and allows outstanding eversion of the wound tip.

7. 5-10 mm from the wound site, the needle is inserted, and a hard bite of tissue is extracted before leaving the skin on the opposing wound edge in the same place.
8. In the needle holder, the needle location is then rotated, and the needle is brought back 1-3 mm from the second track of the wound, and a small bite of tissue is extracted until the first side of the injury is extracted. It is then possible to secure a knot.

The Figure Eight Suture



While dealing with one of three common scenarios, the figure-eight suture has been most widely used among health practitioners. Patients are hypersensitive to widely utilized resorbable suture products or are resistant to them. Resorbable products are processed by the body and brain and do not require a medical practitioner to dissolve them. Dehiscence of an injury that was previously sutured happens. Dehiscence is where after the sutures are withdrawn, a wound expands again. It closes a skin wound where it would be likely to have

irregular margins or a dog's ear defect. One example is around or elliptical error.

This methodology was illustrated and portrayed to two and supplementary content. A 0-silk suture was transferred to a 15 Fr sheath insertion site at ~5-10 mm caudal, mostly on a large-curved needle, and progressed through the subcutaneous tissue, despite reaching so far as to ligate the femoral vein. That needle was crossed and over the sheath with the suture. The second run of a needle was achieved at the injection site of the 15 Fr sheath at 5-10 mm cranial or progressed beyond the sheath through the subcutaneous tissue. The blade was slowly pulled out after the initial knot. And over the previous one, a new knot was created, and the suture was strengthened, so the subcutaneous tissue was folding for hemostasis. The location was evaluated after binding the suture, and no stress was exerted and protected by a sterile gauze if there's no blood. The light force was put for 1 min if there was minor bleeding. The injury was treated carefully in the hospital.

1. Just use a needle attached to a needle holder, with suture material connected.
2. Using a ± 7 cm (2.5 inches) cut that depicts a surgical incision or a laceration in the skin to mimic or simulate skin.
3. Throughout the area, from one of the spatial marks on the laceration on the fake skin, from the far side, you begin the suture. You are using the tissue forceps to reverse the far side of a laceration and implant the needle around five and ten millimeters (about a quarter-inch) back from the sides of the wound.

4. Taking a bite on the close side at a depth of the subcutaneous tissue, turning the blade to make the needle-tip appear just under the dermis.
5. Then, duplicate the bite from the far side, causing the needle to show in the subcutaneous tissue depth.
6. Position the last portion of the suture just under the dermis by piercing the tissue on the close side, with the needle facing upward. Enable the needle tip to exit from the edge of the injury on the close side, approximately three millimeters apart.
7. Tie a square instrument knot or a knot for surgeons. Break all ends of a suture, leaving the suture material at least 3 millimeters past the knot.
8. By repeating processes 4 and 5, place the second figure-8 suture roughly three millimeters to the right of the first suture.
9. Till the laceration is healed, follow it up with further figure-8 sutures. That's the direction of the suture after it is said and gone. Top-left bottom-right, bottom-left, and top-right.

Advantages of Using the Figure-8 Suturing Technique

- It's just reversible. It is not necessary to dissolve conventional subcutaneous sutures, and they must be refractory. This would, in many other words, be made of a substance that can be processed by the tissue enzymes of a body.
- It allows two layers to close simultaneously.
- Ischemia at the base of the suture is diminished associated with the disrupted stitch. Ischemia is a drop

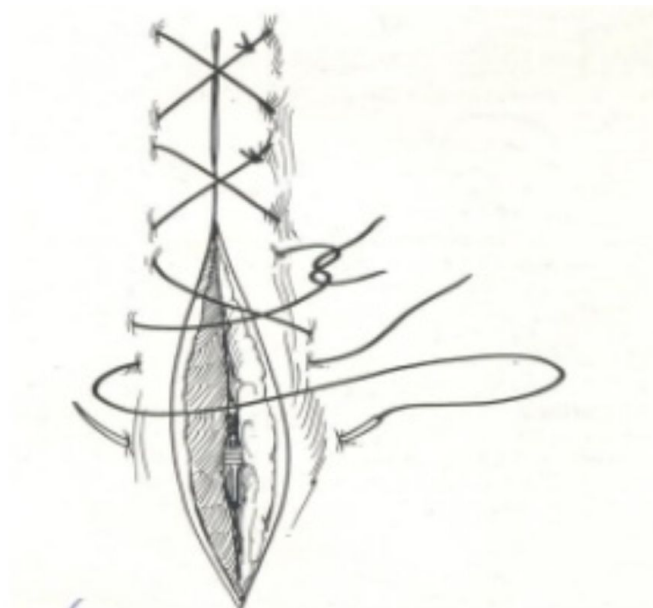
in the flow of blood to body tissue.

- One prevents burying organic substance in the depth of tissue by being temporary, reducing the chances of having a stitch abscess or related disability.
- When sutured, this procedure causes the long gap between both the flaps to be evened out.
- It minimizes flaws in the “dog’s ear.”

Disadvantages of Using the Figure-8 Suturing Technique

- Compared to disrupted sutures, the figure-8 suturing method is more difficult to master and correctly execute.
- Especially in comparison to interrupted sutures, patients feel somewhat more pain after removing stitches.

Interrupted Cruciate Suture



It is a typical type of suture created by two simple joined sutures formed as a figure-of-eight and connected with a single knot. The benefits are that fewer knots are usable, making it easier to position, and the stress is best distributed over a wider area than with a basic suture. Release by cutting all links so that across the tissues, you stop pulling parts of the suture which have been revealed to the surrounding environment.

Types of Equipment:

- Suture pad with silicon or tea towel
- Keepers with needles (mayo or gillies)
- Rat forceps for the tooth
- Scissors mayo
- Throughout the clinical skills laboratory, the suture material is typically used for a nylon suture material reel; packs with such a swaged needle are also accessible.
- Needle-using a triangular skin slashing needle
- Clinical skills lab gloves use non-sterile vinyl gloves
- Stitch scissors elimination

Considerations:

- Swaged needles in a hard jar must be rid of.
- All needles must be re-used except blunt or bent wherein case disposed of in a sharp objects jar
- Needles are sharp and can inflict harm.
- To minimize costs, try using the non-sterile vinyl gloves in the clinical skills lab to practice wearing suturing gloves

Clinical Skills:

1. Just practice cruciate sutures until skilled at conducting simply interrupted and simple continuous sutures. On the other side of an incision, push the needle into the muscle. Only at the end of an incision closest to your dominant side, start suturing (right end if right-handed).
2. Mostly on the close side of the incision, push the needle through the tissue; remember to turn your wrist to track the needle's curve through the tissue, mitigating tissue injury. Push through the suture until it is about 3-4 cm long at the small side.
3. At this point, do not tie a knot or break the suture, but move the needle through the tissue, about 1 cm away from the very first part of a suture.
4. Throughout all stages, the needle and suture fluid should go into the tissue perpendicular to the incision.
5. Push the suture across to the end of the catheter until the suture material lies flat.
6. A basic interrupted suture (silicon skin pad) is used to tie a knot in the same way as with a simple interrupted suture.
7. Position the needle holders over the catheter and twice loop around them with the wide end of the suture material.
8. At the free end, grab the short end of the suture material. Pull it around needle owners into yourself and the circle.
9. To sustain equal pressure, pull equally with both hands. To apply the wound edges, the suture should be close enough but not so tight, or the tissue can cause pain, and the skin may swell. The suture object's short end is on the close sides of the incision.

10. Create a second throw and position the needle holders over the incision.
11. When around the needle holders, wrap up the long side of the suture material.
12. Hold the short stick of the suture material with both the needle holders near the same free end.
13. Pull the short end through the loop. The short stick of the suture material is on the much further side of an incision.
14. Proceed with 2 more throws until a total of 4 is reached.
15. Split the edges down to around 1 cm. While eliminating the sutures, the suture ends must be long enough just to catch and retain.
16. The outlines of the cut should be neatly added after applying a cruciate suture.

Resetting:

- Use the stitch elimination scissors, cut all sutures
- Put excess suture material and some wrapping in the bin
- Needles
- Put in a sharper bin when utilizing a swaged needle
- All needles must be reused (unless they are blunt or twisted in a sharps bin)
- Position tools in the given tray.
- Leave the field tidy.

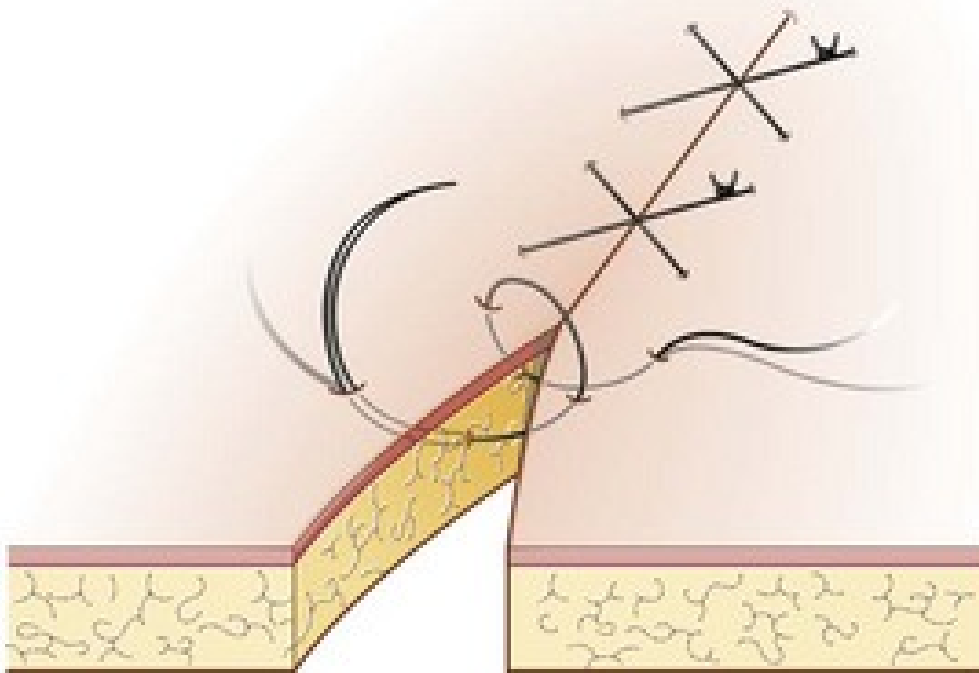
Useful Tips:

1. Skin sutures should not be positioned too firmly, otherwise, the swelling, redness, and pain around the

incision will cause inflammation. It can then seem that the sutures are thicker than originally positioned.

2. Rather than quick interruptions, cruciate sutures may be used with a long incision or cut, for example, and have strong prepositional phrases of wound edges.
3. The sharpened edge of the tools, i.e., the interior of the needle holder jaws, is rough and cannot be used to grab or release the substance of the suture except when applying a knot to hold the short end.
4. The sharpened edge will weaken the suture and may then break down prematurely.
5. Any methodology for suturing is done, the two sides of the injury are applied with no holes at either side and between sutures for the full duration of the incision.
6. Sutures are not too close at the right strain, suggested by cutting in not too open to the skin, leaving holes for dirt and bacteria to join.
7. Sutures are not too near to the incision; each tissue is about 5 mm from the edge of the incision.
8. Sutures from one another can be positioned at equal intervals as well as the length of the suture end is constant.

Cruciate Mattress Suture



A combination of a simple interrupted suture, a mattress suture, and a simple moving suture is an occasionally used procedure. It is helpful if the advantages of interrupted sutures are sought, particularly the frequent knot positioning that leads to a safer closure. If the wound length is slightly too long for a single simple interrupted suture, it can also be used. This technique involves taking in succession two easy interrupted bites but instead tying off the suture, placing over the wound edge an “x” of suture material. It can be used by myself in the sense of minor wounds, including those incurred by a punch biopsy or a traumatic laceration, in minimal to no stress. It may also use it as a secondary layer after the dermis has also been sealed using a dermal or other deep suturing procedure to help in the approximation of an epidermis. For vessel ligation and hemostasis, this procedure may also be used in which it is classically referred to as the figure of eight suture.

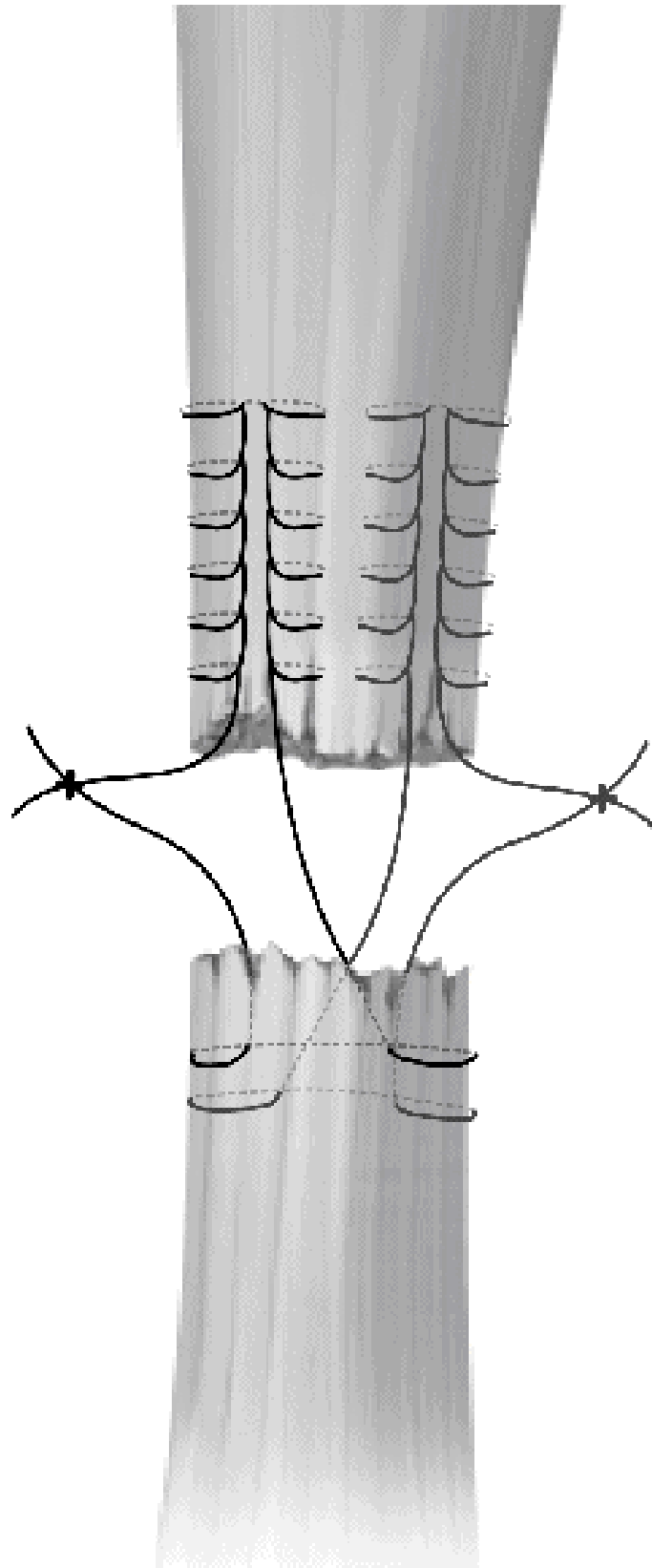
To reduce the possibility of trace marks and international responses, it is safer to use the thinnest suture necessary with both procedures. The collection of sutures would depend primarily on the anatomical position and the purpose of the suture position. This procedure is seldom used on the face, although a 6-0 or 7-0 monofilament suture could be used for an epidermal approximation when it is used there. On the extremities, if there is low stress, a 5-0 monofilament suture can be utilized, and 4-0 monofilament suture can be utilized in places of mild tension where the purpose of suture positioning is to alleviate tension or hemostasis as far as an epidermal approximation. The 3-0 monofilament suture can also be used in selected high-tension regions or used for hemostasis on the interior of a cut, a 4-0 absorbable suture can be used.

1. A needle is positioned perpendicular to the epidermis, and roughly half of a needle's radius is positioned at the surface of the bite. This would enable the needle to escape the wound at an equivalent distance from the center of wounds on the lateral aspect by merely following the deformation of the needle.
2. The needle is twisted across the dermis with a smooth motion of the thumb, bringing the bite broader at the deeper margins than at the ground, and the needle tip mostly on the contralateral side leaves the flesh.
3. Through surgical forceps in the index finger, the needle body is gripped, with received attention to prevent gripping the needle tip, which can be quickly dulled by repeated rubbing against the surgical forceps. The surgical forceps are carefully gripped and pushed upwards while the head of the needle is released.

Chapter 5 : *Advanced Suture*

Techniques

Hybrid Suture



An identical senior surgeon worked on both patients, so the surgical procedure was also consistent.

Similar to the previously reported method, the surgical technique and postoperative recovery were conducted using the hybrid suture technique. After the patient received general anesthesia, the arthroscopic operation was conducted in the beach chair place. Consequently, to assess the path of instability, the senior surgeon conducted a clinical examination. Since sterile preparation of the shoulders and recognition of the bony landmarks, diagnostic arthroscopy was done via a normal posterior portal. 2 cm inferior and 1 cm medial towards the tip of an acromion were formed from the posterior. Another 2 anterior spinal needle portals were developed. In the 2-anterior portal, 2 cannulas are placed. Through the rotator interval, the anterosuperior portal has been created, whereas the second portal is above the subscapularis superior border.

A 30-degree arthroscope was introduced through the posterior portal as well as a periosteal elevator was implemented to test and debride a detached labrum through the anteroinferior portal. For the Bankart fix, the senior surgeon regularly uses 3 bioabsorbable anchor sutures (DePuy Mitek Inc, NJ, USA). For both the right shoulder, the anchors are usually placed at 5:30, 4, and 3 o'clock, whereas for the left shoulder, at 6:30, 8, and 9 o'clock. With both the aid of a drill guide, drill holes were made along with the separation labrum. That hybrid suture technique consisted of two parts. Firstly, the first anchor positioned on the glenoid surface at 5:30/6:30, attempting to create the bumper impact by dragging the IGHL anterior band by horizontal suturing of the mattress and linking it together with the lowest suture. Secondly, at the 4/8 and 3/9 o'clock

position, the second and third anchors were placed and secured with clear vertical sutures.

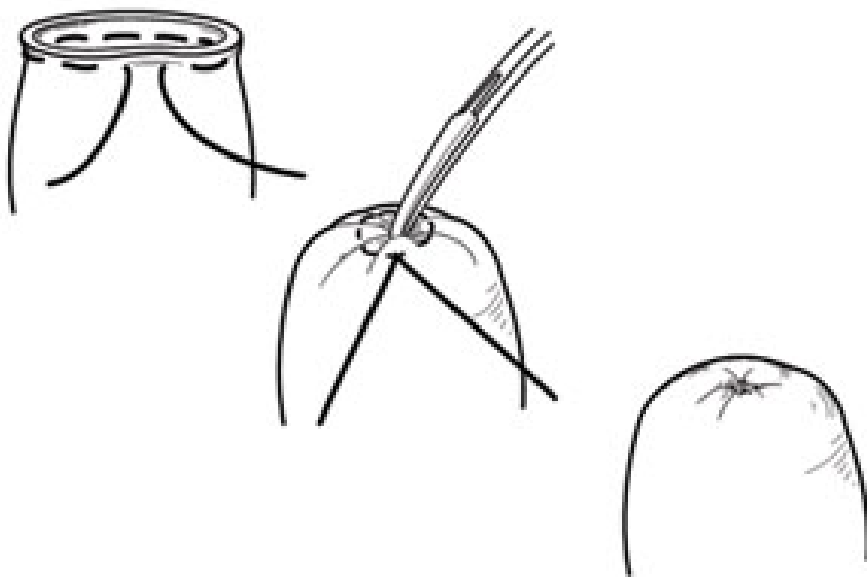
In clarification of depth or obliquity of the suture path, a demonstrative model built from silicon sheets put in phase form is demonstrated. In the long axis of the cut, the needle is placed obliquely. It is implanted 1-2 cm aside from the incision apex from the deep exterior of the flap and 1-2 cm laterally to the cut edge. The needle passes obliquely across the tissue towards the point of the incision, which takes the suture to a lateral cut edge of the cut from the extreme subcutaneous to the superficial dermis and from 1 to 2 cm lateral penetration into the tissue. The needle departs near the wound apex sub-epidermally. The suture exits in a reverse twisted version from the opposite end to withdraw at the very same depth and width on the same edge of the cut as the entrance point. On reversed cutting needles, we use absorbable sutures, with the dimensions determined by tissue thickness.

1. The needle is placed perpendicular to the epidermis, about 6 mm away from the edge of the cut.
2. The needle is twisted across the mucosa with a smooth motion of the thumb, bringing the bite broader at the deep margins than at the ground, and the needle tip mostly on the contralateral side leaves the flesh. A first step can be separated into different, with the needle first ejecting between both the incised wound site and then replayed and put back to exit mostly on the contralateral side if the needle radius is too tiny to complete the whole arc in one motion.
3. Through surgical forceps in the left hand, the needle body is gripped, but care is taken to prevent gripping

the needle tip, which can be quickly dulled by repeated rubbing against the surgical forceps. The surgical forceps are gently grasped and pulled upwards as the body of the needle is set to release from the needle driver.

4. A needle is then loaded up in a backhand manner and placed approximately 3 mm from the wound at 90 degrees right angles to the skin on the same side of an incision line as the exit point, proximal to the doctor comparative to the end destination.
5. The needle rotates through the arc, emerging 3 mm from the engraved wound edge on the contralateral side of a cut.
6. The suture content is then gently tied off, taking measures to reduce tension from across the epidermis and prevent the wound edges from being excessively restricted.

Purse-String Suture



Based on the types of friction and the length of the defect, this strategy is developed to either shrink or completely obviate the length of a defect. It is a niche method because the effect of the purse-string usually leads to a slight puckering throughout the surrounding skin, a function that may be appropriate (and will probably resolve over time) on regions including the forearms and back, and is less desirable in regions such as the face which are aesthetically sensitive. The running nature of a method implies that reconciliation may lead to incision dehiscence at any time in the process of suture placement, although a larger gauge suture material is usually used for this reason.

Suture selection is largely location-specific, although the tiniest gauge suture material suitable for the anatomical location will be used as always. A 2-0 or 3-0 non-absorbable suture material is efficient on the shoulders and back, and a 3-0 or 4-0 absorbable suture material may be used on extremities and scalp. Because the technology provides a simple pull-through with suture material, it is certainly beneficial to monofilament non-absorbable suture.

1. These same edges of the wound were also broadly undermined.
2. A needle is inserted through the epidermis from the far side of a wound with both the snout of the suture material placed between both the surgeon and the far end of the wound, with a trajectory running parallel to the incision. Determines the thickness of the dermis and the expected degree of strain from across closing, the point of entry in the epidermis must be roughly 3-6 mm of set-back from the epidermal edge. At such a uniform

depth, the needle, and thus the suture, should pass through the deep dermis into the undermined orbit.

3. To surgical pickups, the needle would then be grasped and discharged concurrently by the overlay and the needle driver. As the needle is released with the pickup trucks from the tissue, the needle is managed to grasp again with an ideal location by the needle driver to repeat the prior step to the left of the suture attributes.
4. A tiny quantity of suture material is dragged through the needle, to the left of the extent, has been accepted by the suture, is placed into the dermis, and the same movement is reiterated.
5. The very same method is reiterated till the needle exits near the original entry point at the far end of a wound, trying to move stepwise from around the entire wound. When the point nearest to the surgeon is attained, shifting to a backhand method will be much more satisfactory.
6. The suture material is then dragged once the required state of the toss has been positioned, leading to the full or partial closing of the wound, and tied using a device tie or a hand tie.

DermaI Suture

Throughout regions under moderate stress, this method is best used, but it continues to remain the common approach discussed in several textbooks on plastic surgery. Even so, its use in dermatological and plastic surgery has also fallen kind of out of favor, as other technologies are becoming incredibly common, such as the buried vertical mattress and set-back

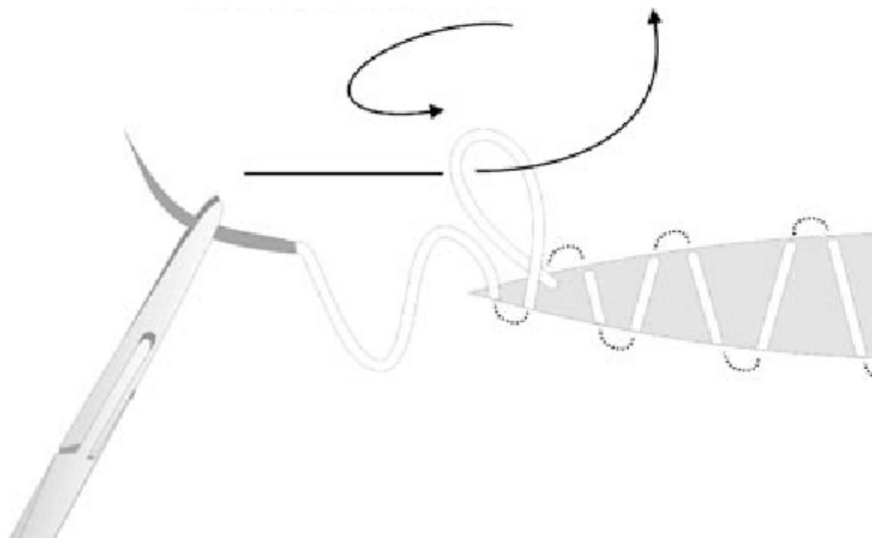
dermal suture. In a wide range of applications, this simple approach is primarily reported when useful that can be used in both facial as well as truncal skin, although it is important in areas where reversal is desired. This includes the folds of the nasolabial and melo labial as well as and choosing regions along the antihelix and umbilicus, where it is beneficial to restore anatomical inversion.

The selection of suture depends primarily on the site, but since this approach retains residual suture material between the engraved brush border and the superficial dermis, caution should be exercised to limit the liberal use of larger-gauge suture material. A 5-0 absorbable suture may be used on the face and neck, and a 4-0 suture on the extremities is normally sufficient. A 3-0 absorbable suture performs well on the rear using this method. To reduce the chance of suture spitting, it may well be best to stop using the 2-0 suture for this procedure.

1. Utilizing operational forceps or chains, the wound's surface is mirrored out.
2. The suture needle is inserted 2 mm away from the incised wound at 90 degrees into the underneath of the dermis as the dermis is reflected.
3. The first bite is performed by following the needle deformation and causing the needle to emerge at the surface of the incised injury. The scale of this bite is dependent on the needle size, the density of the dermis, and the extensor criteria and resistance. The needle's zenith is between the points of an entry concerning the wound.

4. The dermis on the edge of the first bite is released, helping to keep this same free thread of the suture between both the surgeon and the patient. With both the forceps, the tissue on the outer end is then gently managed to grasp.
5. The second and final bite is implemented by implanting the needle only at the level of a simplistic papillary dermis into the contralateral incised wound site. By trying to follow the roundness of the needle and trying to avoid holding the epidermis, focus on this issue, this bite must be finished, which may result in epidermal dimpling. On the underside of the dermis, it then departs approximately 2 mm distal to the wound site. On the first edge of the wound, it should frame the first bite taken.
6. Using a device tie, the suture material would then be tied.

Subcuticular Sutures



This is a method of epidermal approximation acceptable for wounds under minimum or no stress. Mostly in lack of a deep dermal suture, this procedure should seldom be used since its power is in fine-tuning epidermal adjustment, and it is less stable in the control of substantial stress. The existence of a comparatively robust dermis is also premised on its application, as it is a strictly intradermal procedure and thus does not hire any power from the epidermis. Thus in the case of atrophic skin or places of the very thin dermis, such as eyelids, this should be prevented.

As with any procedure, for any given anatomic position, it is better to use the skinniest suture possible. The procedure of the anorexia nervosa suture is not intended to hold stress independent of anatomical position. As its usefulness is limited to fine-tuning epidermal approximation, when adopting such a method, 5-0 or 6-0 suture is always beneficial.

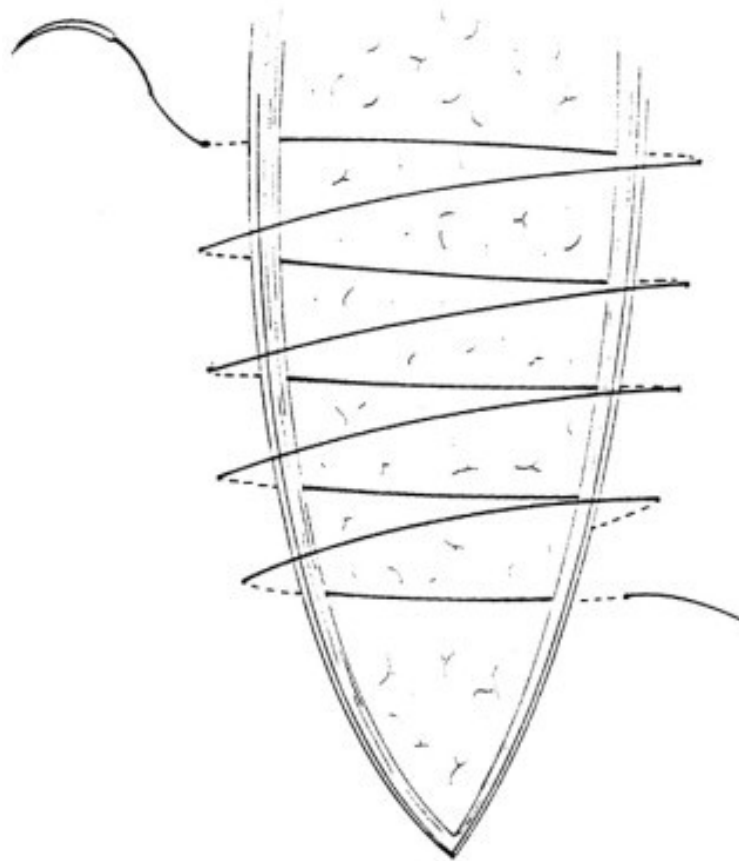
This procedure could be used with either easily absorbed or non-absorbable suture, based on the variation of effective help. When using a non-absorbable suture, it is safer to use a monofilament suture material when extracting the suture to decrease the coefficient of friction. As a reasonably significant volume of suture material would be left in the superficial dermis, it could be safer to use a nonbranded monofilament suture to reduce the chance of contamination and foreign object reaction if easily absorbed material is being used.

1. From the far right corner of the injury, parallel to the incision line, the needle is inserted, starting about 2-5 mm from the apex. From such a point, although it's

lateral to an incision apex, the needle passes straight through the epidermis, emerging just lateral to the apex into the inside of the cut. Notice that this first move can be finessed, as discussed in detail below, depending on the method used to complete the closing.

2. The cut edge is softly mirrored back with the head of the suture material lying lateral to the incision apex and beyond the wound and the needle is threaded into the dermis on the far edge of the injury with a direction running parallel to the incision axis. At a uniform depth, the needle, and thus the suture, should travel through the dermis. The width of the bite is dependent on the size of the needle, although it may be prudent to limit the size within each bite to mitigate the chances of necrosis.
3. At a stage equidistant from the cut edge from which it has reached, the needle must leave the dermis.
4. For surgical pickups, the needle would then be grabbed and released concurrently by the hand while holding the needle driver. The needle is released from the tissue through the pickups as the needle is released from the tissue.

Winch Suture

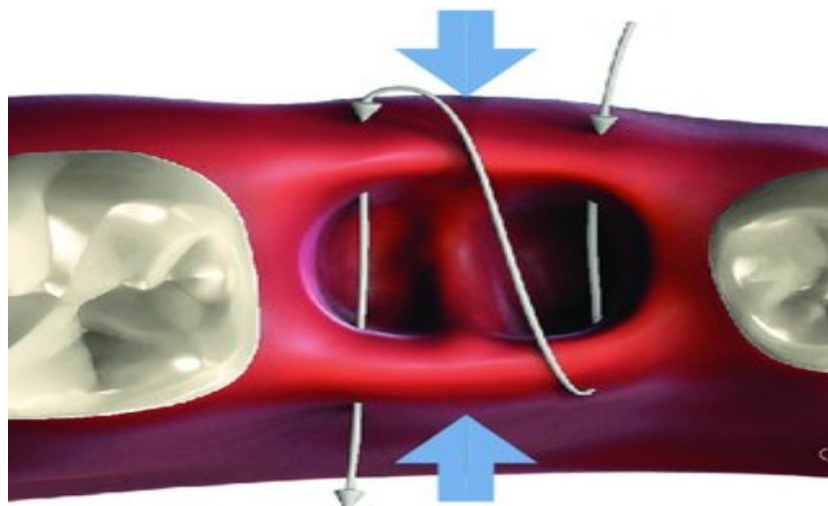


This is an intraoperative tissue growth technique for the niche. Buried or trans epidermal pulley sutures can be inadequate to permit closing while closing injuries under marked stress. In a position to take account of the mechanical tissue creep, inserting a quick winch stitch helps to close these chosen defects. After most tension-relieving sutures have been positioned, the suture is withdrawn intraoperatively.

Because this is a reversible suture, suture material selection is driven more by toughness and breakdown tolerance than with any worry for permanent track lines. Hence in most places where this procedure is used, such as the bark and scalp, a 2-0 or 3-0 monofilament non-absorbable suture is usually acceptable.

1. A needle is positioned perpendicular to the epidermis, and roughly half of a needle's radius is positioned at the surface of the bite. This would enable the needle to escape the injury at an equivalent distance from the center of the wounds on the contralateral by merely following the roundness of the needle.
2. The needle is moved across the dermis with a smooth movement of the thumb, and the needle tip on the contralateral leaves the tissue.
3. Through surgical forceps in the left hand, the needle body is gripped, with received attention to prevent gripping the needle tip, which can be quickly dulled by repeated rubbing against surgical forceps.
4. With the aid of a hemostat, the loose tail of suture material can be fixed in place.
5. Steps (1) through (3) are then replicated consecutively, starting proximal to the previous throw relative to the surgeon, until the appropriate number of throws is put.
6. The suture leading edge is then attached to the loose thread where the hemostat has been mounted.

Cross Suture



This is a niche method used in the closure of select cuts, hemostasis, and epidermal approximate. It can be conceived as a basic running suture done without an attaching knot and traveling in the opposite direction toward the initial wound apex until the terminus is reached. Although it shows an attractive and symmetrical postoperative look, it often requires inserting a larger number of trans epidermal sutures while giving little additional practical value and is thus only used rarely.


As in all procedures, to minimize the possibility of trace marks and foreign-body responses, it is safer to use the thinnest suture possible. The collection of sutures would depend primarily on the anatomical position and the purpose of suture placement. The cross-stitch can be used either to aid the reconstruction of the wound-edge or to assist with hemostasis. Fairly thick suture material can be used in the above example.

A 6-0 or 7-0 monofilament suture for epidermal comparison may be used on the skin. In reality, 5-0 or 6-0 monofilament can also be used on the extremities, while 4-0 monofilament suture could be used in places under moderate stress whereby tension and hemostasis, as well as epidermal similarity, are eased by the objective of suture placement.

1. A needle is positioned perpendicular to the epidermis, and roughly half of the needle's radius is positioned at the surface of the bite. This would enable the needle to escape the wound at an equivalent distance from the center of the wounds on the contralateral side by merely following the curvature of a needle.

2. The needle is twisted across the dermis with a smooth motion of the thumb, bringing the bite broader at the deeper margins than it was at the ground, and the needle tip on the contralateral side leaves the flesh.
3. Through surgical forceps in the left hand, the needle body is gripped and pushed upwards with both the surgical forceps while the needle body is separated from the needle driver.
4. It then leaves a tail of free suture material, but no knot is tied. To eliminate the possibility of pushing it through during the following stages, a hemostat can be used to secure the tail of the suture.
5. Steps (1) to (3) are then replicated consecutively, beginning proximal to the previous knot close to the surgeon, and the needle is passed down the course of the wound before the contralateral apex is hit.
6. After the apex is achieved, steps (1) through (3) are then replicated in the carotid direction, moving again down the injury but now overlapping the previously positioned line of sutures of points of entry, creating an X pattern.

Lembert Suture



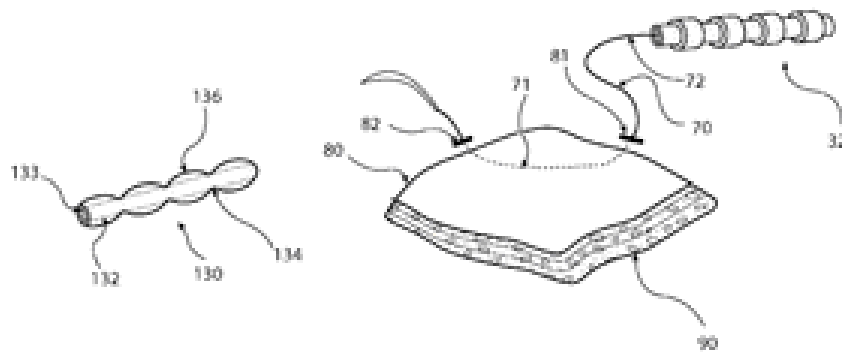
This is a niche procedure intended to promote the inversion of the wound tip, which is mainly useful for recreating a natural crease. As well as to help describe the helical rim, it can be used to replicate the alar wrinkles and can even be helpful when trying to recreate the mental crease.

To reduce the possibility of trace marks and foreign-body responses, it is safer to use the thinnest suture possible with both procedures. This suture is usually used on the face and ears, so a 6-0 or 7-0 monofilament suture might be best, although the need for suture extraction may be prevented by fast-absorbing intestines.

1. A needle is placed perpendicular to the epidermis, about 8 mm away from the edge of the wound.
2. A needle is twisted superficially across the dermis with a smooth rotation of a thumb, as well as the needle tip leaves the skin 2 mm away from the wound site, mostly on the ipsilateral side.
3. Through surgical forceps on the left side, the needle body is gripped and reloaded into the needle driver.

4. Mostly on the contralateral of the wound site, 2 mm apart from the wound edge, the needle is then inserted perpendicular to the tissue.
5. Via its arc, the needle is rotated vaguely again, exiting 8 mm from the incised wound's tip.
6. The suture material is then carefully tied off, taking care to reduce friction around the epidermis to keep the wound edges from being too constrained.

Lattice Suture



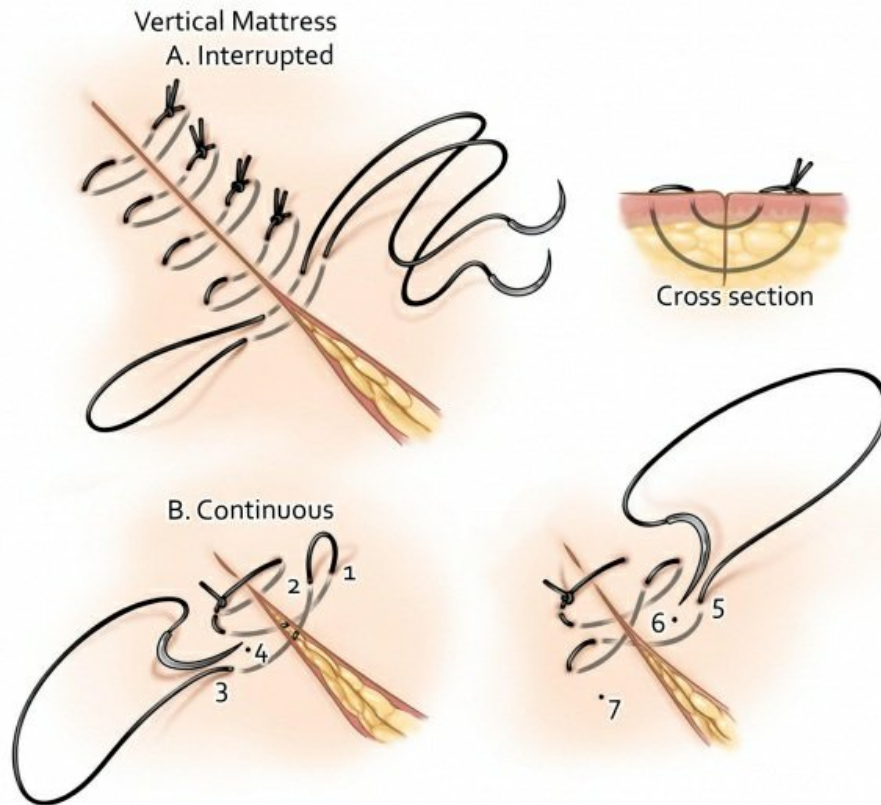
This is a niche technique intended for injuries with or under severe stress with an atrophic dermis where conventional suturing procedures may not allow sufficient tissue mobilization or improved and wound-edge apposition. The basic idea is to position multiple interrupted sutures perpendicular to the edge of wounds but instead connect the interrupted sutures across the edge of the wound by adding the lattice, enhancing the repair's flexibility, and spreading its force widely.

To reduce the possibility of trace marks and international responses, it is safer to use the thinnest suture possible with both procedures. Where there is low stress, a 5-0 monofilament suture material can be used, and a 4-0 monofilament suture in places under high tension. The 3-0

monofilament suture can also be used in selected high-tension regions.

1. Adjacent to the incision line, simple interrupted sutures are positioned to form the anchoring framework: the needle is implanted perpendicular to the epidermis, about 8 mm away from the edge of the wound.
2. The needle is moved through the dermis with a smooth rotation of the wrist, flowing parallel to an incision axis.
3. The material for the suture would then be loosely tied together, leaving a void between both the material for the suture and the flesh.
4. On the contralateral wound edge, steps (1) through (3) are then repeated, forming the system of contralateral anchoring.
5. Then a simple interrupted suture is put, integrating from the anchoring mechanism the suture material. The needle perpendicular to the epidermis from around the anchoring suture at the far side.
6. The needle is twisted across the dermis with a smooth motion of the thumb, bringing the bite broader at the deep margin than it was at the surface, and the needle tip mostly on the contralateral line, around the outside of the anchoring system, escapes the flesh.
7. The suture material would then be carefully tied off, taking care to reduce friction around the epidermis to keep the wound edges from being too constrained.

Combined Vertical Mattress Dermal Suture



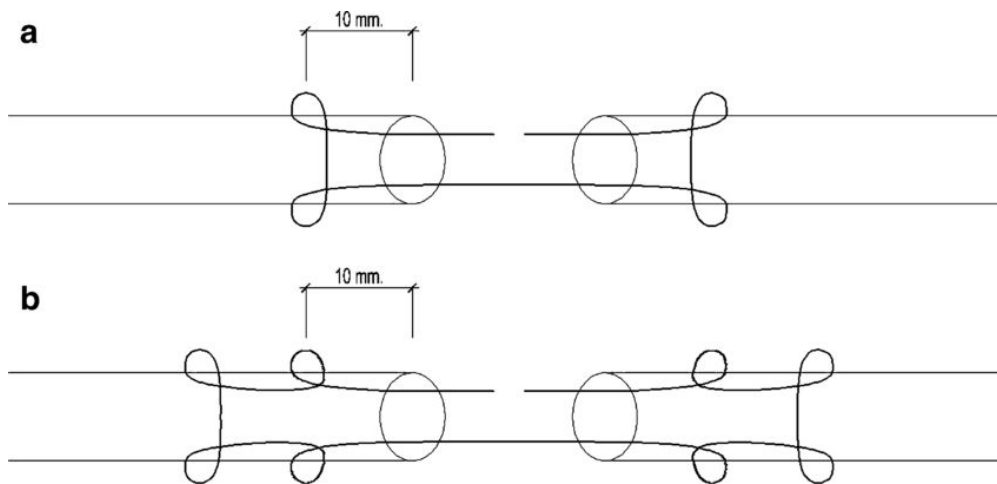
This is a suture type that can be conceived as a cross of a dermal suture and a vertical mattress suture. It was designed to enable the closing of shallow defects and also to allow wound lateral flexion with a single suture, simultaneously avoiding the need for bilayer closure.

To reduce the possibility of trace marks and international responses, it is safer to use the thinnest suture possible with both procedures. The collection of sutures would depend primarily on the anatomical position and the purpose of the suture position.

Usually, if minimal stress is present, 5-0 monofilament non-absorbable suture material is sufficient, and 4-0 monofilament suture may be used in areas of moderate strain. The 3-0 monofilament suture can also be used in high-tension environments.

1. A needle is placed perpendicular to an epidermis, about 6 mm away from the edge of the wound.
2. The needle is twisted through the dermis with a smooth movement of the wrist, bringing the bite broader on the shallow margins than on the top, and the needle tip emerges between both the edges of the incised wound.
3. Mostly on contralateral wounds, the needle would then be loaded up and threaded into the deep dermis.
4. In such a backhand pattern, the needle would then be loaded up again and positioned on the initial wound edge through the deep dermis.
5. The needle is then reloaded, penetrating the contralateral wound edge from below the dermis, leaving the wound edge roughly 6 mm away.
6. A needle would then be loaded up in a backhand manner and inserted roughly 3 mm from the wound site at 90 degrees perpendicular to the epidermis on the same side of an incision line as the end destination.
7. The needle is vaguely rotated through the arc, emerging 3 mm from the incised wound on the contralateral of an injury.
8. The suture material would then be carefully tied off, taking care to reduce friction around the epidermis to keep the wound site from being too constrained.

Kessler's Locking Loop



The bond is locked by tension among the loop sutures and the tendon in the Kessler-loop lock suture technique for the goal of withstanding larger tensile strength and avoiding gap forming. This tactic requires fewer knots than that of the system of MK. In the tendon, the cross-linked collagen fibers produce tension on the suture upwards, eliminating slippage of the tendon and breaking. Better wound recovery may be related to the low stress between both the damaged ends of the tendon, but more study is required to validate this hypothesis.

To use single-strand sutures or suturing in an operating microscope with such magnification of 10, we changed the double-strand Kessler-loop lock suture technique. It is easier for less seasoned surgeons to grasp and embrace this approach. Because no special sutures are needed for this technique, it is reasonably readily involved in medical practice.

Nonetheless, our analysis has many drawbacks. The use of devitalized porcine flexor tendons, which may have specific biomechanical properties than human tissue, was used in this investigation. Even so, our findings could be assessed in animal studies and by clinical trials in the future. Just the

Kessler and interlock suture techniques were related to our method; this contrast may be generalized to other representative 4-strand suture strategies, including the Kessler and Strickland double-strand strategies.

1. Adjusted Kessler, 2 strands, within the repair site with both the knot.
2. Tsuge, 2 strands, with the knot positioned mostly on the tendon's volar surface. A locking loop's diameter was 1/3 the width of the tendon.
3. Method 1, 4 threads of Kessler double modified, including two modified Kessler sutures or two knots at the repair site. On either of the two sutures, on one side, a needle passed through the tendon 6 mm transversely from of the ends of the cut tendon, and on the other side, the needle moved through the tendon about 3 mm transversely from the end of all the other tendon. The two sutures were then overlapping, a variant of the far-near-near-far process.
4. Kessler 2, 4 strands double modified. The updated Kessler repair was carried out with a double-strand looped suture.
5. Modified Kessler-modified Tsuge paired 4 strands. The first modified Kessler suture was put, accompanied by the Tsuge suture, inside the repair site with both the knot.

Cushing Suture



The constant, simple reversing suture pattern that is quick to produce is Cushing Suture. While suturing an intestinal incision, it's being used to make the outer seal. The bites are located perpendicular to the location of the incision. The suture pattern of Cushing doesn't reach the lumen, just the serosa, muscular is, and submucosa reaches it. The Connell suture is close to the Cushing Suture. The key distinction would be that the lumen is pierced by the Connell suture.

The constant, simple inverting suture pattern that is quick to produce is Cushing Suture. While suturing an intestinal incision, it is used to make the outer seal. The bites are located parallel to the location of the incision. The lumen is not penetrated by the Cushing suture pattern, it absorbs only the serosa, muscular, and submucosa.

1. Adjacent to the incision, a laterally opposing passage of the suture is produced.
2. The movement of the suture is rendered in the same direction from the other side of the catheter as the incision opposite to the first movement.
3. The beginning of the line of sutures is fixed by a knot.

4. A suture path is made in the course of the incision, beginning from the rear of the knot.
5. A path similar to the first passage and in the same direction is produced from the other side of the incision. The tissue appears inverted as the suture is removed, as well as the knot is buried beneath the skin.
6. A path through the suture is made in the course of the incision.
7. A path similar to the first passage in the same path is made from the other side of the incision.
8. Steps 6 and 7 in the incision are repeated.
9. By performing the first three steps, the ends of the suture line are set after the incision line has been crossed.

The Running Pleated Suture

As would be commonly found in flap replacements, this procedure is intended to remedy a difference of tissue length on two sides of a wound. Burrow's circles are also drawn at the poles of the flap when conducting development and rotation flaps to allow for the difference in tissue volume between both two sides of the injury. This procedure is intended to take advantage of the formation of several tiny plaques in the tissue that can be thought of as tiny triangles of Burrow all over the width of the wound, eventually leading to a smaller scar.

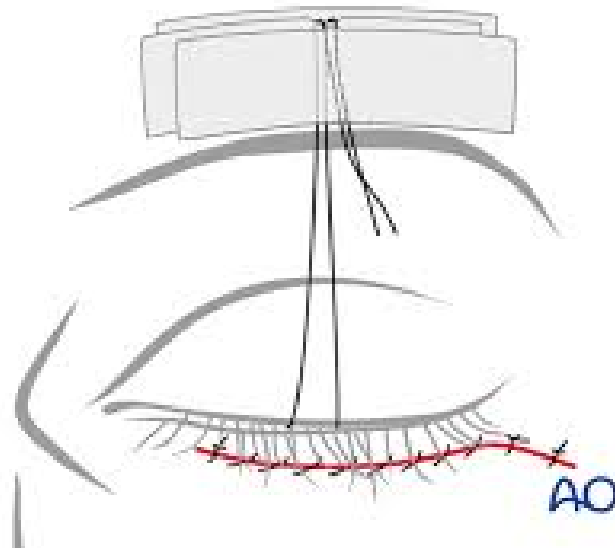
To reduce the possibility of trace marks and international responses, it is safer to use the thinnest suture possible with both procedures. This process is frequently used on the face where it would be acceptable to use 6-0 or 7-0 monofilament

non-absorbable suture. Suture 5-0 can also be suitable for flaps on certain body locations.

1. A needle is positioned perpendicular to the epidermis, and roughly half of the needle's diameter is positioned at the surface of a bite. This would enable the needle to leave the wound at an equivalent distance from the center of the wounds on the contralateral by merely following the roundness of the needle.
2. A needle is twisted across the dermis with a smooth motion of the thumb, bringing the bite broader at the deeper margins than at the ground, and the needle tip on the contralateral leaves the flesh.
3. Therefore the suture material is carefully tied off, taking care to reduce friction around the epidermis to prevent excessively constraining the sides of the cut. For both the running line of pleated sutures, this creates the first attaching knot. The lost tail is clipped and refilled with the needle.
4. That needle is positioned perpendicular to an epidermis mostly on the side with excess fat, starting proximal to the previous knot close to the surgeon, about half the diameter of a needle far from the surface of a cut.
5. A needle is rotated through the dermis with such a smooth motion of a thumb, and the needle tip emerges into an undermined vacuum.
6. Mostly on the contralateral wound line, the needle would then be loaded up and placed into the superficial dermis, allowing a much more superficial bite on this part of the injury.

7. Steps 4 to 6 are then replicated consecutively till the limit of the injury is hit, so there is less excess space among bites on the sides of an injury.
8. A needle is equipped with a backhand procedure for the last throwing at the adverse apex of an injury and placed into the skin at a 90-degree angle in a mirror image of all the other throws, penetrating only proximal to the departure point compared to the surgeon on the very same section of an incision line

Frost Suture



This is a niche technique to help deter postoperative ectropion, used to keep the lower eyelid gap in position. It is helpful where there is fear that throughout the postoperative phase, postoperative edema may lead to a downwards pull on the lower eyelid. This is not, nevertheless, to be used to fix intraoperatively evident ectropion.

Typically, for the frost suture positioning, a 4-0 nonabsorbable monofilament suture is sufficient.

1. A needle is threaded into the tarsus or only inferior to that after closing has also been achieved.
2. A needle is twisted with a smooth movement of the thumb, taking a 3-mm bite.
3. A needle is then loaded up and pushed over the medial eyebrow through the tissue, holding in its anatomical location the orientation and positioning of the lower eyelid.
4. Therefore the suture material is carefully wrapped off, making a sling. Instead, it is possible to protect the location just above the medial eyebrow utilizing adhesive strips.

The Bolster Suture



This is a niche approach that is used to protect bolsters on top of skin grafts. It reflects a running suture technique that has historically been done with several disrupted sutures holding down a bolster dressing to tie on a bolster covering.

To reduce the possibility of trace marks and international responses, it is safer to be using the thinnest suture possible with both procedures. A non-absorbable monofilament suture

of 5-0 or 6-0 is usually acceptable since the suture is not intended to bear substantial stress.

1. The needle at the 3 o'clock mark after locking the graft in place, 5 mm laterally to the graft edge perpendicular to the epidermis and tangentially to the graft angle.
2. The needle is moved through the dermis with a smooth movement of the thumb, as well as the needle tip emerges 2-3 mm from the point of insertion.
3. A hemostat can be used to protect the two ends of a suture.
4. A needle is moved between both the 9 o'clock and 12 o'clock positions along the suture material segment.
5. And by moving them into the roughly 5 o'clock position, nonadherent wrapping or gauze is cut to size and placed over the top of a graft in the appropriate position.
6. To strengthen, the edges of the suture material should be pushed to the 3 and 9 o'clock positions. The suture material would then be carefully tied over the top of the bolster, and the bolster is sealed in position.

Chapter 6 : *Postoperative Care of the Sutured Wound and Complications*

Throughout the postoperative phase, proper surgical wound and incision care are essential to avoid risks, like surgical site infection and wound dehiscence. For mainly sealed incisions and also for subacute and persistent injuries, the concepts of conservative wound care apply.

An essential aspect of a post-operative treatment plan is to avoid incisional infection by adequate washing, skincare, and moisture control. To clarify the logic and significance of post-operative surgical injury and incision treatment, a cursory knowledge of the stages of wound healing or healing by purpose will help.

Topical Surgical Wound Care

To help recovery, all surgical injuries need a moist setting. If a fitting change is post-operatively required during the first 48 hours, the aseptic procedure should be strictly followed. Surgical incision cleaning is done to eliminate debris, bacteria, and exudate; it can be done under sufficient pressure to prevent cytotoxicity (e.g., regular saline) or mechanical trauma while using a sterile agent (do not exceed 15 psi).

Original surgical coatings will usually stay in place for 48-72 hours, though others will remain in place for up to seven days. The superficial epidermis of a primarily sealed incision line

looks “sealed” about post-operation day three. While the tissue layers are not entirely healed and at this point cannot endure external pressures, the epidermis was first to arise, or restrain, and continue to create a barrier to pathogens and contaminants.

Post-Operative Incisional

Opioid medications appear to become the cornerstones of postoperative pain control and will substantially decrease the necessary dose of opioids of sufficient pain relief by replacing these with non-steroidal anti-inflammatory drugs (NSAIDs). This will mitigate the deleterious side effects of the drugs, including altered emotional states, urinary leakage, respiratory distress, and constipation, among others. Thorough initial post-operative pain evaluation should be complete and provide any contraindications with particular pain management strategies (NSAID allergy, aversion to smells, allergy to specific dressings, cleansers, tapes, etc.). Pain-related agitation, post-operative deployment and everyday life tasks, and sometimes insufficient time to heal before returning to work can potentially increase reported pain.

Conclusion

Significant factors in the treatment of post-operative wounds include the foregoing: the experience of tissue regeneration phases; an acknowledgment as to whether primary, secondary, or secondary intent heals a surgical wound; topical wound control; and post-operative incisional pain management. To improve clinical outcomes for post-surgical patients, close exposure to these elements of pain management will benefit.

We hope this book has been informative for you and that you now have a solid grounding in surgical suturing upon which you can build upon. If necessary, go back and review the contents of this book so that you can be sure that you know its contents well. Best of luck to you!

