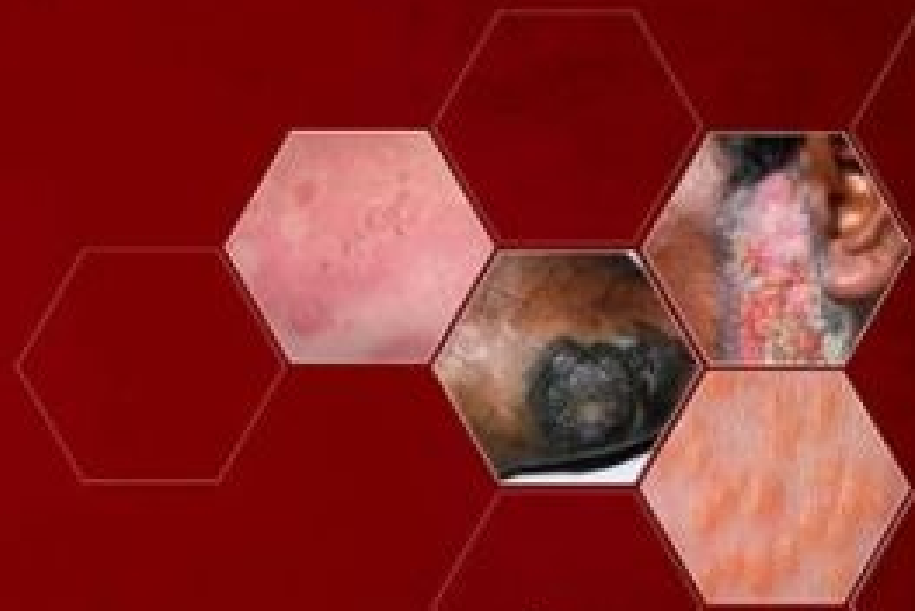

Get Full Access and More at

ExpertConsult.com

William D. James  
Timothy G. Berger  
Dirk M. Elston  
Isaac M. Neuhaus

Twelfth Edition



Andrews'  
Diseases  
of the  
Skin

CLINICAL DERMATOLOGY

ELSEVIER



Andrews'  
Diseases  
of the Skin

CLINICAL DERMATOLOGY

---

*Executive Content Strategist:* Russell Gabbedy

*Senior Content Development Specialist:* Ailsa Laing

*Publishing Services Manager:* Patricia Tannian

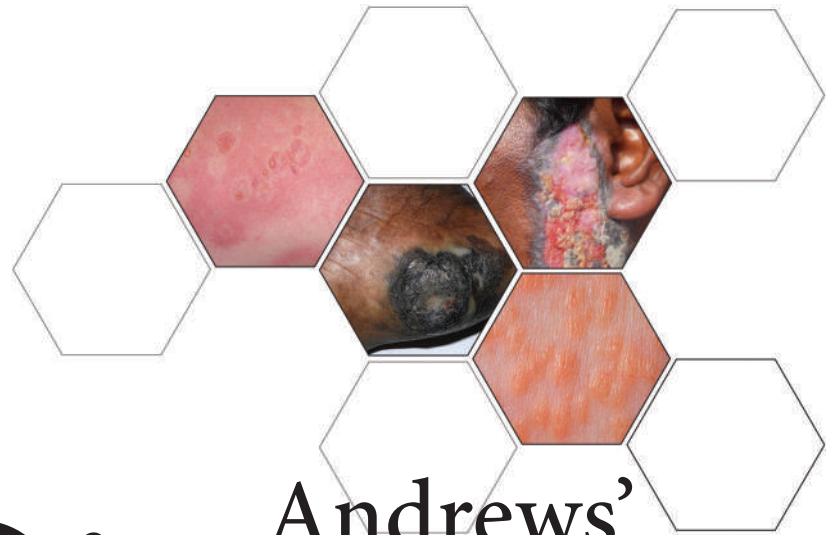*Senior Project Manager:* John Casey

*Designer:* Christian Bilbow

*Original cover images:* Upper left: Dr. Donald Adler (deceased);

Upper right: Dr. Shyam Verma; Center: Dr. Debabrata Bandyopadhyay;

Lower right: Dr. William D. James.



# Andrews' Diseases of the Skin

**CLINICAL DERMATOLOGY**

---

Twelfth Edition

**William D. James, MD**

Paul R Gross Professor of Dermatology  
Department of Dermatology  
University of Pennsylvania School of Medicine  
Philadelphia, Pennsylvania

**Dirk M. Elston, MD**

Professor and Chairman  
Department of Dermatology  
and Dermatologic Surgery  
Medical University of South Carolina  
Charleston, South Carolina;  
Former Director  
Ackerman Academy of Dermatopathology  
New York, New York

**Timothy G. Berger, MD**

Professor of Clinical Dermatology  
Executive Vice Chair and Residency  
Program Director  
Chair in Dermatology Medical Student  
Education  
University of California, San Francisco  
San Francisco, California

# ELSEVIER

1600 John F. Kennedy Blvd.  
Ste. 1800  
Philadelphia, PA 19103-2899

**ANDREWS' DISEASES OF THE SKIN: CLINICAL DERMATOLOGY,  
TWELFTH EDITION  
International Edition**

**ISBN: 978-0-323-31967-6  
ISBN: 978-0-323-31968-3**

**Copyright © 2016 by Elsevier, Inc. All rights reserved.**  
11<sup>th</sup> edition © 2011 by Elsevier, Inc.

No part of this publication may be reproduced or transmitted in any form or by any means, electronic or mechanical, including photocopying, recording, or any information storage and retrieval system, without permission in writing from the publisher. Details on how to seek permission, further information about the Publisher's permissions policies and our arrangements with organizations such as the Copyright Clearance Center and the Copyright Licensing Agency, can be found at our website: [www.elsevier.com/permissions](http://www.elsevier.com/permissions).

This book and the individual contributions contained in it are protected under copyright by the Publisher (other than as may be noted herein).

## Notices

Knowledge and best practice in this field are constantly changing. As new research and experience broaden our understanding, changes in research methods, professional practices, or medical treatment may become necessary.

Practitioners and researchers must always rely on their own experience and knowledge in evaluating and using any information, methods, compounds, or experiments described herein. In using such information or methods they should be mindful of their own safety and the safety of others, including parties for whom they have a professional responsibility.

With respect to any drug or pharmaceutical products identified, readers are advised to check the most current information provided (i) on procedures featured or (ii) by the manufacturer of each product to be administered, to verify the recommended dose or formula, the method and duration of administration, and contraindications. It is the responsibility of practitioners, relying on their own experience and knowledge of their patients, to make diagnoses, to determine dosages and the best treatment for each individual patient, and to take all appropriate safety precautions.

To the fullest extent of the law, neither the Publisher nor the authors, contributors, or editors, assume any liability for any injury and/or damage to persons or property as a matter of products liability, negligence or otherwise, or from any use or operation of any methods, products, instructions, or ideas contained in the material herein.

**International Standard Book Number: ISBN: 978-0-323-31967-6**



Printed in China

Last digit is the print number: 9 8 7 6 5 4 3 2 1

## VIDEO CONTENTS

*Videos available at [expertconsult.inkling.com](http://expertconsult.inkling.com)*

- 37-1 Shave biopsy
- 37-2 Punch biopsy
- 37-3 Narrow hole lipoma excision
- 37-4 Excision
- 37-5 Fusiform excision
- 37-6 Transposition flap
- 37-7 Split thickness skin graft
- 37-8 Mohs surgery
- 38-1 Full face ablative resurfacing
- 39-1 Filler, lips
- 39-2 Botulinum toxin, glabella
- 39-3 Botulinum toxin, frontalis
- 39-4 Starch iodine test for hyperhidrosis
- 39-5 Botulinum toxin, hyperhidrosis axilla
- 39-6 Sclerotherapy
- 39-7 Foam sclerotherapy

# PREFACE AND ACKNOWLEDGMENTS

*Andrews'* remains as it was from the beginning: an authored text whose one volume is filled with clinical signs, symptoms, diagnostic tests, and therapeutic pearls. The authors have remained general clinical dermatologists in an era of subspecialists in academia. They are committed to keeping *Andrews'* as an excellent tool for anyone who needs help in diagnosing a patient with a clinical conundrum or treating a patient with a therapeutically challenging disease.

*Andrews'* is primarily intended for the practicing dermatologist. It is meant to be used on the desktop at his or her clinic, giving consistent, concise advice on the whole spectrum of clinical situations faced in the course of a busy workday. While we have been true to our commitment to a single-volume work, we provide our text in a convenient online format as well. Because of its relative brevity but complete coverage of our field, many find the text ideal for learning dermatology for the first time. It has been a mainstay of the resident yearly curriculum for many programs. We are hopeful that trainees will learn clinical dermatology by studying the clinical descriptions, disease classifications, and treatment insights that define *Andrews'*. We believe that students, interns, internists or other medical specialists, family practitioners, and other health professionals who desire a comprehensive dermatology textbook will find that ours meets their needs. Long-time dermatologists will hopefully discover *Andrews'* to be the needed update that satisfies their lifelong learning desires. On our collective trips around the world, we have been gratified to see our international colleagues studying *Andrews'*. Thousands of books have been purchased by Chinese and Brazilian dermatologists alone.

Many major changes have been made to this edition. Bill James, Tim Berger, and Dirk Elston, three great friends of over three decades, have worked closely to continue to improve the quality of our text. The surgical chapters have been updated and expanded by Isaac Neuhaus. He has added videos of some of the most common procedures, which are available online. We thank him for his continued work to improve this portion of our textbook. Robert Micheletti expertly updated Chapters 29 and 35. He is an internist/dermatologist with superior writing skills whose contributions are most appreciated. We have tried to ensure that each entity is discussed only once, in a complete yet concise manner. In order to do this we have had to make decisions regarding the placement of disease processes in only one site. Clearly, neutrophilic eccrine hidradenitis, for example, could be presented under drug eruptions, neutrophilic reactive conditions, infection or cancer-associated disease, or with eccrine disorders. The final decisions are a team effort and made in the interest of eliminating redundancy. This allows us to present our unified philosophy in treating patients in one dense volume.

Medical science continues to progress at breakneck speed. Our understanding of the etiology of certain conditions has now led us to recategorize well-recognized disease states and dictated the addition of many newly described entities. Molec-

ular investigative techniques, technologic breakthroughs, and designer therapeutics lead the way in providing advances in our specialty. We cover the new understanding following from such innovations by discussing the mechanisms at work in genetic diseases, covering the latest in dermatopathologic staining and analysis, and enlarging the therapeutic recommendations to include our expanded therapeutic options, such as biologic response modifiers and biologically engineered targeted medications. We have attempted to define therapeutics in a fashion that emphasizes those interventions with the highest level of evidence, but also present less critically investigated therapeutic options. To care for our patients we need a large array of options. Not all are fully supported by formal evidence, yet are helpful to individual patients.

Extensive revisions were necessary to add this wealth of new information. We selectively discarded older concepts. By eliminating older, not currently useful information we maintain the brief but complete one-volume presentation that we and all previous authors have emphasized. Additionally, older references have been updated. The classic early works are not cited; instead we have chosen to include only new citations and let the bibliographies of the current work provide the older references as you need them. A major effort in this edition was to reillustrate the text with hundreds of new color images. Many have been added to the printed text; you will also find a number only in the online version. Enjoy! We have looked to our own collections to accomplish this. These are the result of many hours of personal effort, the generosity of our patients, and a large number of residents and faculty of the programs in which we currently work or have worked in the past. Additionally, friends and colleagues from all parts of the globe have allowed us to use their photographs. They have given their permission for use of these wonderful educational photos to enhance your understanding of dermatology and how skin diseases affect our patients. We cannot thank them enough.

All of the authors recognize the importance of our mentors, teachers, colleagues, residents, and patients in forming our collective expertise in dermatology. Dirk, Tim, and Bill were all trained in military programs, and our indebtedness to this fellowship of clinicians is unbounded. The many institutions we have called home, from the East Coast of Walter Reed, the University of Pennsylvania, and Geisinger Medical Center, to the West Coast of the University of California at San Francisco, and many in between, such as Brooke in San Antonio and the Cleveland Clinic, nurtured us and expanded our horizons. Our friendship goes well beyond the limits of our profession; it is wonderful to work with people you not only respect as colleagues, but also enjoy as closely as family. Barbara Lang and Laura Beckerman provided expert assistance throughout the revision process to Bill and Tim, respectively. We are indebted to their hard work. Finally we are proud to be a part of the Elsevier team and have such professionals as Ailsa Laing, John Casey, and Russell Gabbedy supporting us every step of the way.

# DEDICATION



**The authors** (left to right): Tim Berger, Bill James, Dirk Elston

*For my family, whose love and support sustain me and make me happy.*

WDJ

*My wife, Jessica, and my children, Olivia and Mateo, who give me the joy and strength to undertake such a task.*

TGB

*To my wife and best friend, Kathy, and our wonderful children, Carly and Nate.*


DME

# CONTRIBUTORS

**Isaac M. Neuhaus, MD**  
Associate Professor  
Dermatologic Surgery and Laser Center  
University of California, San Francisco  
San Francisco, California



**Robert G. Micheletti, MD**  
Assistant Professor of Dermatology and Medicine  
University of Pennsylvania  
Perelman School of Medicine  
Philadelphia, Pennsylvania







# 1

## Skin: Basic Structure and Function

Skin is composed of three layers: the epidermis, dermis, and subcutaneous fat (panniculus) (Fig. 1-1). The outermost layer, the epidermis, is composed of viable keratinocytes covered by a layer of keratin, the stratum corneum. The principal component of the dermis is the fibrillar structural protein collagen. The dermis lies on the panniculus, which is composed of lobules of lipocytes separated by collagenous septa that contain the neurovascular bundles.

There is considerable regional variation in the relative thickness of these layers. The epidermis is thickest on the palms and soles, measuring approximately 1.5 mm. It is very thin on the eyelid, where it measures less than 0.1 mm. The dermis is thickest on the back, where it is 30–40 times as thick as the overlying epidermis. The amount of subcutaneous fat is generous on the abdomen and buttocks compared with the nose and sternum, where it is meager.

### EPIDERMIS AND ADNEXA

During the first weeks of life, the fetus is covered by a layer of nonkeratinizing cuboidal cells called the periderm (Fig. 1-2). Later, the periderm is replaced by a multilayered epidermis. Adnexal structures, particularly follicles and eccrine sweat units, originate during the third month of fetal life as downgrowths from the developing epidermis. Later, apocrine sweat units develop from the upper portion of the follicular epithelium and sebaceous glands from the midregion of the follicle. Adnexal structures appear first in the cephalic portion of the fetus and later in the caudal portions.

The adult epidermis is composed of three basic cell types: keratinocytes, melanocytes, and Langerhans cells. An additional cell, the Merkel cell, can be found in the basal layer of the palms and soles, oral and genital mucosa, nail bed, and follicular infundibula. Located directly above the basement membrane zone, Merkel cells contain intracytoplasmic dense-core neurosecretory-like granules and, through their association with neurites, act as slow-adapting touch receptors. They have direct connections with adjacent keratinocytes by desmosomes and contain a paranuclear whorl of intermediate keratin filaments. Both polyclonal keratin immunostains and monoclonal immunostaining for keratin 20 stain this whorl of keratin filaments in a characteristic paranuclear dot pattern. Merkel cells also label for neuroendocrine markers such as chromogranin and synaptophysin.

### Keratinocytes

Keratinocytes, or squamous cells, are the principal cells of the epidermis. They are of ectodermal origin and have the specialized function of producing keratin, a complex filamentous protein that not only forms the surface coat (stratum corneum) of the epidermis but also is the structural protein of hair and nails. Multiple distinct keratin genes have been identified and

consist of two subfamilies, acidic and basic. The product of one basic and one acidic keratin gene combines to form the multiple keratins that occur in many tissues. The presence of various keratin types is used as a marker for the type and degree of differentiation of a population of keratinocytes. Keratins are critical for normal functioning of the epidermis, and keratin mutations are recognized causes of skin disease. Mutations in the genes for keratins 5 and 14 are associated with epidermolysis bullosa simplex. Keratin 1 and 10 mutations are associated with epidermolytic hyperkeratosis. Mild forms of this disorder may represent localized or widespread expressions of mosaicism for these gene mutations.

The epidermis can be divided into the innermost basal layer (stratum germinativum), the malpighian or prickle layer (stratum spinosum), the granular layer (stratum granulosum), and the horny layer (stratum corneum). On the palms and soles, a pale clear to pink layer, the stratum lucidum, is noted just above the granular layer. When the skin in other sites is scratched or rubbed, the malpighian and granular layers thicken, a stratum lucidum forms, and the stratum corneum becomes thick and compact. Histones appear to regulate epidermal differentiation, and histone deacetylation suppresses expression of profilaggrin. Slow-cycling stem cells provide a reservoir for regeneration of the epidermis. Sites rich in stem cells include the deepest portions of the rete, especially on palmoplantar skin, as well as the hair bulge. Stem cells divide infrequently in normal skin, but in cell culture they form active, growing colonies. They can be identified by their high expression of  $\beta$ 1-integrins and lack of terminal differentiation markers. Stem cells can also be identified by their low levels of desmosomal proteins, such as desmoglein 3. The basal cells divide, and as their progeny move upward, they flatten and their nucleus disappears. Abnormal keratinization can manifest as parakeratosis (retained nuclei), as corps ronds (round, clear to pink, abnormally keratinized cells), or as grains (elongated, basophilic, abnormally keratinized cells).

During keratinization, the keratinocyte first passes through a synthetic and then a degradative phase on its way to becoming a horn cell. In the synthetic phase, within its cytoplasm the keratinocyte accumulates intermediate filaments composed of a fibrous protein, keratin, arranged in an  $\alpha$ -helical coiled pattern. These tonofilaments are fashioned into bundles, which converge on and terminate at the plasma membrane, where they end in specialized attachment plates called desmosomes. The degradative phase of keratinization is characterized by the disappearance of cell organelles and the consolidation of all contents into a mixture of filaments and amorphous cell envelopes. This programmed process of maturation resulting in death of the cell is called terminal differentiation. Terminal differentiation is also seen in the involuting stage of keratoacanthomas, where the initial phase of proliferation gives way to terminal keratinization and involution.

Premature programmed cell death, or apoptosis, appears in hematoxylin and eosin (H&E)-stained sections as scattered bright-red cells, some of which may contain small, black

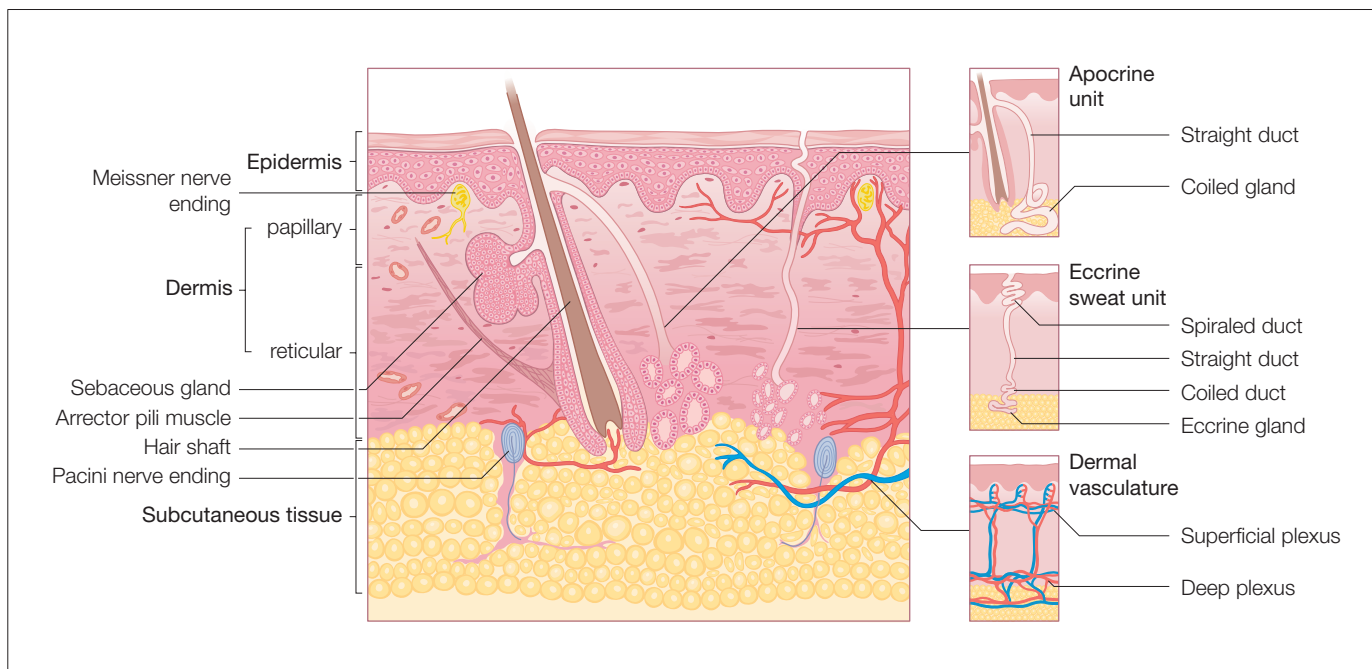


Fig. 1-1 Diagrammatic cross section of the skin and panniculus.

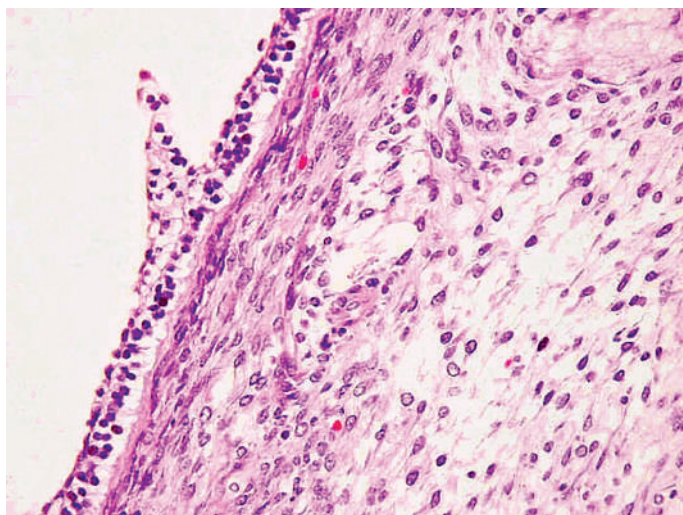


Fig. 1-2 Fetal periderm covering fetal mesenchyme.

pyknotic nuclei. These cells are present at various levels of the epidermis, because this form of cell death does not represent part of the normal process of maturation. Widespread apoptosis is noted in the verrucous phase of incontinentia pigmenti. It is also a prominent finding in catagen hairs, where apoptosis results in the involution of the inferior segment of the hair follicle.

In normal skin, the plasma membranes of adjacent cells are separated by an intercellular space. Electron microscopic histochemical studies have shown that this interspace contains glycoproteins and lipids. Lamellar granules (Odland bodies or membrane-coating granules) appear in this space, primarily at the interface between the granular and cornified cell layers. Lamellar granules contribute to skin cohesion and impermeability. Conditions such as lamellar ichthyosis and Flegel's hyperkeratosis demonstrate abnormal lamellar granules. Glycolipids such as ceramides contribute a water-barrier function to skin and are typically found in topical products meant to restore the epidermal barrier. Lamellar bodies form

abnormally in the absence of critical ceramides such as glucosylceramide, or there is disproportion of critical lipids. Desmosomal adhesion depends on cadherins, including the calcium-dependent desmogleins and desmocollins. Antibodies to these molecules result in immunobullous diseases, but desmogleins function not only in adhesion but also in differentiation. The binding of the desmoglein 1 cytoplasmic tail to the scaffolding protein Erbin downregulates the Ras-Raf pathway to promote stratification and differentiation of keratinocytes in the epidermis.

Keratinocytes of the granular zone contain, in addition to the keratin filament system, keratohyaline granules, composed of amorphous particulate material of high sulfur-protein content. This material, profilaggrin, is a precursor to filaggrin, so named because it is thought to be responsible for keratin filament aggregation. Conversion to filaggrin takes place in the granular layer, and this forms the electron-dense interfilamentous protein matrix of mature epidermal keratin. Kallikrein-related peptidase 5, a serine protease secreted from lamellar granules, appears to function in profilaggrin cleavage.

Keratohyalin is hygroscopic, and repeated cycles of hydration and dehydration contribute to normal desquamation of the stratum corneum. Ichthyosis vulgaris is characterized by a diminished or absent granular layer, contributing to the retention hyperkeratosis noted in this disorder. Keratohyalin results in the formation of soft, flexible keratin. Keratin that forms in the absence of keratohyaline granules is typically hard and rigid. Hair fibers and nails are composed of hard keratin.

Keratinocytes play an active role in the immune function of the skin. In conditions such as allergic contact dermatitis, these cells participate in the induction of the immune response, rather than acting as passive casualties. Keratinocytes secrete a wide array of cytokines and inflammatory mediators, including tumor necrosis factor (TNF)- $\alpha$ . They also can express molecules on their surface, such as intercellular adhesion molecule 1 (ICAM-1) and major histocompatibility complex (MHC) class II molecules, suggesting that keratinocytes actively respond to immune effector signals.

## Melanocytes

Melanocytes are derived from the neural crest and by the eighth week of development can be found within the fetal epidermis. In normal, sun-protected trunk epidermis, melanocytes reside in the basal layer at a frequency of about 1 in every 10 basal keratinocytes. Areas such as the face, shins, and genitalia have a greater density of melanocytes, and in heavily sun-damaged facial skin, Mart-1 immunostaining can demonstrate ratios of melanocytes to basal keratinocytes that approach 1:1. Recognition of the variation in melanocyte/keratinocyte ratio is critical in the interpretation of biopsies of suspected lentigo maligna (malignant melanoma in situ) on sun-damaged skin.

Racial differences in skin color are not caused by differences in the number of melanocytes. It is the number, size, and distribution of the melanosomes or pigment granules within keratinocytes that determine differences in skin color. Pale skin has fewer melanosomes, and these are smaller and packaged within membrane-bound complexes. Dark skin has more melanosomes, and these tend to be larger and singly dispersed. Chronic sun exposure can stimulate melanocytes to produce larger melanosomes, thereby making the distribution of melanosomes within keratinocytes resemble the pattern seen in dark-skinned individuals.

In histologic sections of skin routinely stained by H&E, the melanocyte appears as a cell with ample amphophilic cytoplasm or as a clear cell in the basal layer of the epidermis. The apparent halo is an artifact formed during fixation of the specimen. This occurs because the melanocyte, lacking tonofilaments, cannot form desmosomal attachments with keratinocytes. Keratinocytes also frequently demonstrate clear spaces but can be differentiated from melanocytes because they demonstrate cell-cell junctions and a layer of cytoplasm peripheral to the clear space.

The melanocyte is a dendritic cell. Its dendrites extend for long distances within the epidermis, and any one melanocyte is therefore in contact with a great number of keratinocytes; together they form the so-called epidermal melanin unit. Keratinocytes actively ingest the tips of the melanocytic dendrites, thus imbibing the melanosomes.

Melanosomes are synthesized in the Golgi zone of the cell and pass through a series of stages in which the enzyme tyrosinase acts on melanin precursors to produce the densely pigmented granules. Melanocytes in red-haired individuals tend to be rounder and to produce more pheomelanin. The melanocortin 1 receptor (MC1R) is important in the regulation of melanin production. Loss-of-function mutations in the *MC1R* gene bring about a change from eumelanin to pheomelanin production, whereas activating gene mutations can enhance eumelanin synthesis. Most redheads are compound heterozygotes or homozygotes for a variety of loss-of-function mutations in this gene.

Antimicrobial peptides, including cathelicidin and  $\beta$ -defensins, are key components of the innate immune system. They protect against infection, are implicated in the pathogenesis of atopic dermatitis, and play a role in control of pigmentation. The  $\beta$ -defensins encompass a class of small, cationic proteins important to both the innate and the adaptive immune system.  $\beta$ -Defensin 3 also functions as a melanocortin receptor ligand.

Eumelanin production is optimal at pH 6.8, and changes in cellular pH also result in alterations of melanin production and the eumelanin/pheomelanin ratio. Within keratinocytes, melanin typically forms a cap over the nucleus, where it presumably functions principally in a photoprotective role. Evidence of keratinocyte photodamage in the form of thymidine dimer formation can be assessed using gas

chromatography-mass spectrometry or enzyme-linked immunosorbent assays. Pigment within melanocytes also serves to protect the melanocytes themselves against photodamage, such as ultraviolet A (UVA)-induced membrane damage.

Areas of leukoderma, or whitening of skin, can be caused by very different phenomena. In vitiligo, the affected skin becomes white because of destruction of melanocytes. In albinism, the number of melanocytes is normal, but they are unable to synthesize fully pigmented melanosomes because of defects in the enzymatic formation of melanin. Local areas of increased pigmentation can result from a variety of causes. The typical freckle results from a localized increase in production of pigment by a near-normal number of melanocytes. Black "sunburn" or "ink spot" lentiginos demonstrate basilar hyperpigmentation and prominent melanin within the stratum corneum. Nevi are benign proliferations of melanocytes. Melanomas are their malignant counterpart. Melanocytes and keratinocytes express neurotrophins (ectodermal nerve growth factors). Melanocytes release neurotrophin 4, but the release is downregulated by ultraviolet B (UVB) irradiation, suggesting neurotrophins as possible targets for therapy of disorders of pigmentation. Melanocytes express toll-like receptors (TLRs) and stimulation by bacterial lipopolysaccharides increases pigmentation.

## Langerhans cells

Langerhans cells are normally found scattered among keratinocytes of the stratum spinosum. They constitute 3–5% of the cells in this layer. As with melanocytes, Langerhans cells are not connected to adjacent keratinocytes by the desmosomes. The highest density of Langerhans cells in the oral mucosa occurs in the vestibular region, and the lowest density is in the sublingual region, suggesting the latter is a relatively immunologically "privileged" site.

At the light microscopic level, Langerhans cells are difficult to detect in routinely stained sections. However, they appear as dendritic cells in sections impregnated with gold chloride, a stain specific for Langerhans cells. They can also be stained with CD1 $\alpha$  or S-100 immunostains. Ultrastructurally, they are characterized by a folded nucleus and distinct intracytoplasmic organelles called Birbeck granules. In their fully developed form, the organelles are rod shaped with a vacuole at one end, resembling a tennis racket. The vacuole is an artifact of processing.

Functionally, Langerhans cells are of the monocyte-macrophage lineage and originate in bone marrow. They function primarily in the afferent limb of the immune response by providing for the recognition, uptake, processing, and presentation of antigens to sensitized T lymphocytes and are important in the induction of delayed-type sensitivity. Once an antigen is presented, Langerhans cells migrate to the lymph nodes. Hyaluronan (hyaluronic acid) plays a critical role in Langerhans cell maturation and migration. Langerhans cells express langerin, membrane adenosine triphosphatase (ATPase, CD39), and CCR6, whereas CD1 $\alpha$ + dermal dendritic cells express macrophage mannose receptor, CD36, factor XIIIa, and chemokine receptor 5, suggesting different functions for these two CD1 $\alpha$ + populations. If skin is depleted of Langerhans cells by exposure to UV radiation, it loses the ability to be sensitized until its population of Langerhans cell is replenished. Macrophages that present antigen in Langerhans cell-depleted skin can induce immune tolerance. In contrast to Langerhans cells, which make interleukin-12 (IL-12), the macrophages found in the epidermis 72 h after UVB irradiation produce IL-10, resulting in downregulation of the immune response. At least in mice, viral immunity appears to



require priming by CD8 $\alpha$ + dendritic cells, rather than Langerhans cells, suggesting a complex pattern of antigen presentation in cutaneous immunity.

Vaccine studies suggest the importance of various cutaneous dendritic cells. Microneedle delivery of vaccine into skin can provoke CD8+ T-cell expansion mediated by CD11c(+) CD11b(+) langerin-negative dendritic cells.

**Afshar M, et al:** Innate immune defense system of the skin. *Vet Dermatol* 2013; 24(1):32–38.e8–e9.

**Chen J, et al:** Skin permeation behavior of elastic liposomes: role of formulation ingredients. *Expert Opin Drug Deliv* 2013; 10(6):845–856.

**Chen Y, et al:** Biomaterials as novel penetration enhancers for transdermal and dermal drug delivery systems. *Drug Deliv* 2013; 20(5):199–209.

**Ernfors P:** Cellular origin and developmental mechanisms during the formation of skin melanocytes. *Exp Cell Res* 2010; 316(8):1397–1407.

**Hammers CM, et al:** Desmoglein-1, differentiation, and disease. *J Clin Invest* 2013; 123(4):1419–1422.

**Homborg M, et al:** Beyond expectations: novel insights into epidermal keratin function and regulation. *Int Rev Cell Mol Biol* 2014; 311:265–306.

**Iglesias-Bartolome R, et al:** Control of the epithelial stem cell epigenome: the shaping of epithelial stem cell identity. *Curr Opin Cell Biol* 2013; 25(2):162–169.

**Lee HJ, et al:** Epidermal permeability barrier defects and barrier repair therapy in atopic dermatitis. *Allergy Asthma Immunol Res* 2014; 6:276–287.

**Ortonne JP, et al:** Latest insights into skin hyperpigmentation. *J Invest Dermatol Symp Proc* 2008; 13(1):10–14.

**Roberts N, et al:** Developing stratified epithelia: lessons from the epidermis and thymus. *Wiley Interdiscip Rev Dev Biol* 2014; 3:389–402.

**Sakabe J, et al:** Kallikrein-related peptidase 5 functions in proteolytic processing of profilaggrin in cultured human keratinocytes. *J Biol Chem* 2013; 288(24):17179–17189.

## DERMOEPIDERMAL JUNCTION

The junction of the epidermis and dermis is formed by the basement membrane zone (BMZ). Ultrastructurally, this zone is composed of four components: the plasma membranes of the basal cells with the specialized attachment plates (hemidesmosomes); an electron-lucent zone called the lamina lucida; the lamina densa (basal lamina); and the fibrous components associated with the basal lamina, including anchoring fibrils, dermal microfibrils, and collagen fibers. At the light microscopic level, the periodic acid–Schiff (PAS)–positive basement membrane is composed of the fibrous components. The basal lamina is synthesized by the basal cells of the epidermis. Type IV collagen is the major component of the basal lamina. Type VII collagen is the major component of anchoring fibrils. The two major hemidesmosomal proteins are BP230 (bullous pemphigoid antigen 1) and BP180 (bullous pemphigoid antigen 2, type XVII collagen).

In the upper permanent portion of the anagen follicle, plectin, BP230, BP180,  $\alpha$ 6 $\beta$ 4-integrin, laminin 5, and type VII collagen show essentially the same expression as that found in the interfollicular epidermis. Staining in the lower, transient portion of the hair follicle, however, is different. All BMZ components diminish and may become discontinuous in the inferior segment of the follicle. Hemidesmosomes are also not apparent in the BMZ of the hair bulb. The lack of hemidesmosomes in the deep portions of the follicle may relate to the transient nature of the inferior segment, whereas abundant hemidesmosomes stabilize the upper portion of the follicle.

The BMZ is considered to be a porous semipermeable filter, which permits exchange of cells and fluid between the epidermis and dermis. It further serves as a structural support for the epidermis and holds the epidermis and dermis together. The BMZ also helps to regulate growth, adhesion,

and movement of keratinocytes and fibroblasts, as well as apoptosis. Much of this regulation takes place through activation of integrins and syndecans. Extracellular matrix protein 1 demonstrates loss-of-function mutations in lipid proteinosis, resulting in reduplication of the basement membrane.

**Breitkreutz D, et al:** Skin basement membrane: the foundation of epidermal integrity: BM functions and diverse roles of bridging molecules nidogen and perlecan. *Biomed Res Int* 2013; 2013:179784.

**Masunaga T:** Epidermal basement membrane: its molecular organization and blistering disorders. *Connect Tissue Res* 2006; 47(2):55–66.

## EPIDERMAL APPENDAGES: ADNEXA

Eccrine and apocrine glands, ducts, and pilosebaceous units constitute the skin adnexa. Embryologically, they originate as downgrowths from the epidermis and are therefore ectodermal in origin. Hedgehog signaling by the transducer known as *smoothened* appears critical for hair development. Abnormalities in this pathway contribute to the formation of pilar tumors and basal cell carcinoma. In the absence of hedgehog signaling, embryonic hair germs may develop instead into modified sweat gland or mammary epithelium.

Although the various adnexal structures serve specific functions, all can function as reserve epidermis, in that reepithelialization occurs after injury to the surface epidermis, principally because of the migration of keratinocytes from the adnexal epithelium to the skin surface. It is not surprising, therefore, that skin sites such as the face or scalp, which contain pilosebaceous units in abundance, reepithelialize more rapidly than skin sites such as the back, where adnexa of all types are comparatively scarce. Once a wound has reepithelialized, granulation tissue is no longer produced. Deep, saucerized biopsies in an area with few adnexa will slowly fill with granulation tissue until they are flush with the surrounding skin. In contrast, areas rich in adnexa will quickly be covered with epithelium. No more granulation tissue will form, and the contour defect created by the saucerization will persist.

The pseudoeplitheliomatous hyperplasia noted in infections and inflammatory conditions consists almost exclusively of adnexal epithelium. Areas of thin intervening epidermis are generally evident between areas of massively hypertrophic adnexal epithelium.

## Eccrine sweat units

The intraepidermal spiral duct, which opens directly onto the skin surface, is called the *acrosyringium*. It is derived from dermal duct cells through mitosis and upward migration. The acrosyringium is composed of small polygonal cells with a central round nucleus surrounded by ample pink cytoplasm. In the stratum corneum overlying an actinic keratosis, the lamellar spiral acrosyringial keratin often stands out prominently against the compact red parakeratotic keratin produced by the actinic keratosis.

The straight dermal portion of the duct is composed of a double layer of cuboidal epithelial cells and is lined by an eosinophilic cuticle on its luminal side. The coiled secretory acinar portion of the eccrine sweat gland may be found within the superficial panniculus. In areas of skin such as the back that possess a thick dermis, the eccrine coil is found in the deep dermis, surrounded by an extension of fat from the underlying panniculus. An inner layer of epithelial cells, the secretory portion of the gland, is surrounded by a layer of flattened myoepithelial cells. The secretory cells are of two types: large, pale, glycogen-rich cells and smaller, darker-staining cells. The

pale glycogen-rich cells are thought to initiate the formation of sweat. The darker cells may function similar to cells of the dermal duct, which actively reabsorb sodium, thereby modifying sweat from a basically isotonic to a hypotonic solution by the time it reaches the skin surface. Sweat is similar in composition to plasma, containing the same electrolytes, but in a more dilute concentration. Physical conditioning in a hot environment results in production of larger amounts of extremely hypotonic sweat in response to a thermal stimulus. This adaptive response allows greater cooling with conservation of sodium.

In humans, eccrine sweat units are found at virtually all skin sites. In most other mammals, the apocrine gland is the major sweat gland.

Physiologic secretion of sweat occurs as a result of many factors and is mediated by cholinergic innervation. Heat is a prime stimulus to increased sweating, but other physiologic stimuli, including emotional stress, are important as well. During early development, there is a switch between adrenergic and cholinergic innervation of sweat glands. Some responsiveness to both cholinergic and adrenergic stimuli persists. Cholinergic sweating involves a biphasic response, with initial hyperpolarization and secondary depolarization mediated by the activation of calcium and chloride ion conductance. Adrenergic secretion involves monophasic depolarization and is dependent on cystic fibrosis transmembrane conductance regulator GCl. Cells from patients with cystic fibrosis demonstrate no adrenergic secretion. Vasoactive intestinal polypeptide may also play a role in stimulating eccrine secretion.

## Apocrine units

Apocrine units develop as outgrowths not of the surface epidermis, but of the infundibular or upper portion of the hair follicle. Although immature apocrine units are found covering the entire skin surface of the human fetus, these regress and are absent by the time the fetus reaches term. The straight excretory portion of the duct, which opens into the infundibular portion of the hair follicle, is composed of a double layer of cuboidal epithelial cells.

The coiled secretory gland is located at the junction of the dermis and subcutaneous fat. It is lined by a single layer of cells, which vary in appearance from columnar to cuboidal. This layer of cells is surrounded by a layer of myoepithelial cells. Apocrine coils appear more widely dilated than eccrine coils, and apocrine sweat stains more deeply red in H&E sections, contrasting with the pale pink of eccrine sweat.

The apices of the columnar cells project into the lumen of the gland and in histologic cross section appear as if they are being extruded (decapitation secretion). Controversy surrounds the mode of secretion in apocrine secretory cells, whether merocrine, apocrine, holocrine, or all three. The composition of the product of secretion is only partially understood. Protein, carbohydrate, ammonia, lipid, and iron are all found in apocrine secretion. It appears milky white, although lipofuscin pigment may rarely produce dark shades of brown and gray-blue (apocrine chromhidrosis). Apocrine sweat is odorless until it reaches the skin surface, where it is altered by bacteria, which makes it odoriferous. Apocrine secretion is mediated by adrenergic innervation and by circulating catecholamines of adrenomedullary origin. Vasoactive intestinal polypeptide may also play a role in stimulating apocrine secretion. Apocrine excretion is episodic, although the actual secretion of the gland is continuous. Apocrine gland secretion in humans serves no known function. In other species, it has a protective as well as a sexual function, and in some species, it is important in thermoregulation as well.

Although occasionally found in an ectopic location, apocrine units of the human body are generally confined to the following sites: axillae, areolae, anogenital region, external auditory canal (ceruminous glands), and eyelids (glands of Moll). They are also generally prominent in stroma of the sebaceous nevus of Jadassohn. Apocrine glands do not begin to function until puberty.

## Hair follicles

During embryogenesis, mesenchymal cells in the fetal dermis collect immediately below the basal layer of the epidermis. Epidermal buds grow down into the dermis at these sites. The developing follicle forms at an angle to the skin surface and continues its downward growth. At this base, the column of cells widens, forming the bulb, and surrounds small collections of mesenchymal cells. These papillary mesenchymal bodies contain mesenchymal stem cells with broad functionality. At least in mice, they demonstrate extramedullary hematopoietic stem cell activity, representing a potential therapeutic source of hematopoietic stem cells and a possible source of extramedullary hematopoiesis *in vivo*.

Along one side of the fetal follicle, two buds are formed; an upper bud develops into the sebaceous gland, and a lower bud becomes the attachment for the arrector pili muscle. A third epithelial bud develops from the opposite side of the follicle above the level of the sebaceous gland anlage and gives rise to the apocrine gland. The uppermost portion of the follicle, which extends from its surface opening to the entrance of the sebaceous duct, is called the infundibular segment. It resembles the surface epidermis, and its keratinocytes may be of epidermal origin. The portion of the follicle between the sebaceous duct and the insertion of the arrector pili muscle is the isthmus. The inner root sheath fully keratinizes and sheds within this isthmus portion. The inferior portion includes the lowermost part of the follicle and the hair bulb. Throughout life, the inferior portion undergoes cycles of involution and regeneration.

Hair follicles develop sequentially in rows of three. Primary follicles are surrounded by the appearance of two secondary follicles; other secondary follicles subsequently develop around the principal units. The density of pilosebaceous units decreases throughout life, possibly because of dropout of the secondary follicles. In mouse models, signaling by molecules designated as ectodysplasin A and noggin is essential for the development of primary hair follicles and induction of secondary follicles. Arrector pili muscles contained within the follicular unit interconnect at the level of the isthmus.

The actual hair shaft, as well as an inner and an outer root sheath, is produced by the matrix portion of the hair bulb (Fig. 1-3). The sheaths and contained hair form concentric cylindrical layers. The hair shaft and inner root sheath move together as the hair grows upward until the fully keratinized, inner root sheath sheds at the level of the isthmus. The epidermis of the upper part of the follicular canal is contiguous with the outer root sheath. The upper two portions of the follicle (infundibulum and isthmus) are permanent; the inferior segment is completely replaced with each new cycle of hair growth. On the scalp, anagen, the active growth phase, lasts about 3–5 years. Normally, about 85–90% of all scalp hairs are in the anagen phase, a figure that decreases with age and decreases faster in individuals with male-pattern baldness (as length of anagen decreases dramatically). Scalp anagen hairs grow at a rate of about 0.37 mm/day. Catagen, or involution, lasts about 2 weeks. Telogen, the resting phase, lasts about 3–5 months. Most sites on the body have a much shorter anagen and much longer telogen, resulting in short hairs that

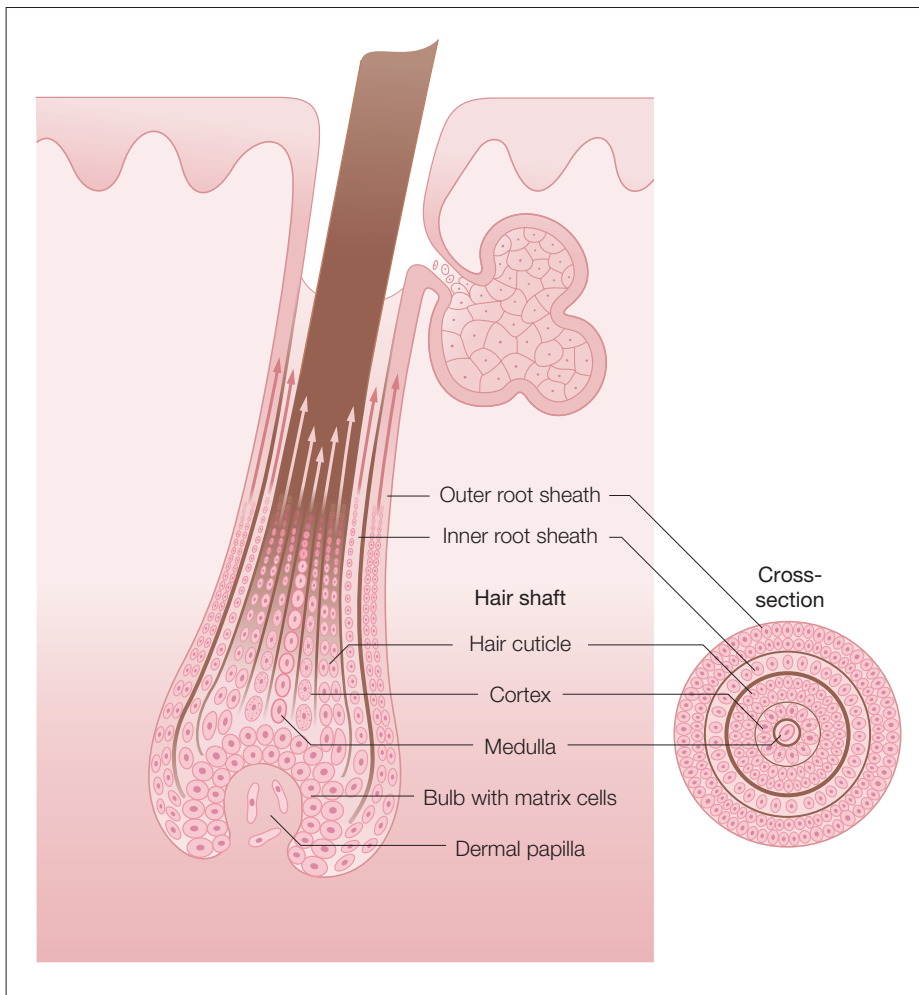


Fig. 1-3 Anatomy of the hair follicle.

stay in place for long periods without growing longer. Prolongation of the anagen phase results in long eyelashes in patients with acquired immunodeficiency syndrome (AIDS).

Human hair growth is cyclic, but each follicle functions as an independent unit (Fig. 1-4). Therefore, humans do not shed hair synchronously, as most animals do. Each hair follicle undergoes intermittent stages of activity and quiescence. Synchronous termination of anagen or telogen results in telogen effluvium. Most commonly, telogen effluvium is the result of early release from anagen, such as that induced by a febrile illness, surgery, or weight loss.

Pregnancy is typically accompanied by retention of an increased number of scalp hairs in anagen, as well as a prolongation of telogen. Soon after delivery, telogen loss can be detected as abnormally prolonged telogen hairs are released. At the same time, abnormally prolonged anagen hairs are converted synchronously to telogen. Between 3 and 5 months later, a more profound effluvium is noted. Patients receiving chemotherapy often have hair loss because the drugs interfere with the mitotic activity of the hair matrix, leading to the formation of a tapered fracture. Only anagen hairs are affected, leaving a sparse coat of telogen hairs on the scalp. As the matrix recovers, anagen hairs resume growth without having to cycle through catagen and telogen.

The growing anagen hair is characterized by a pigmented bulb (Fig. 1-5) and an inner root sheath (Fig. 1-6). Histologically, catagen hairs are best identified by the presence of many apoptotic cells in the outer root sheath (Fig. 1-7). Telogen club

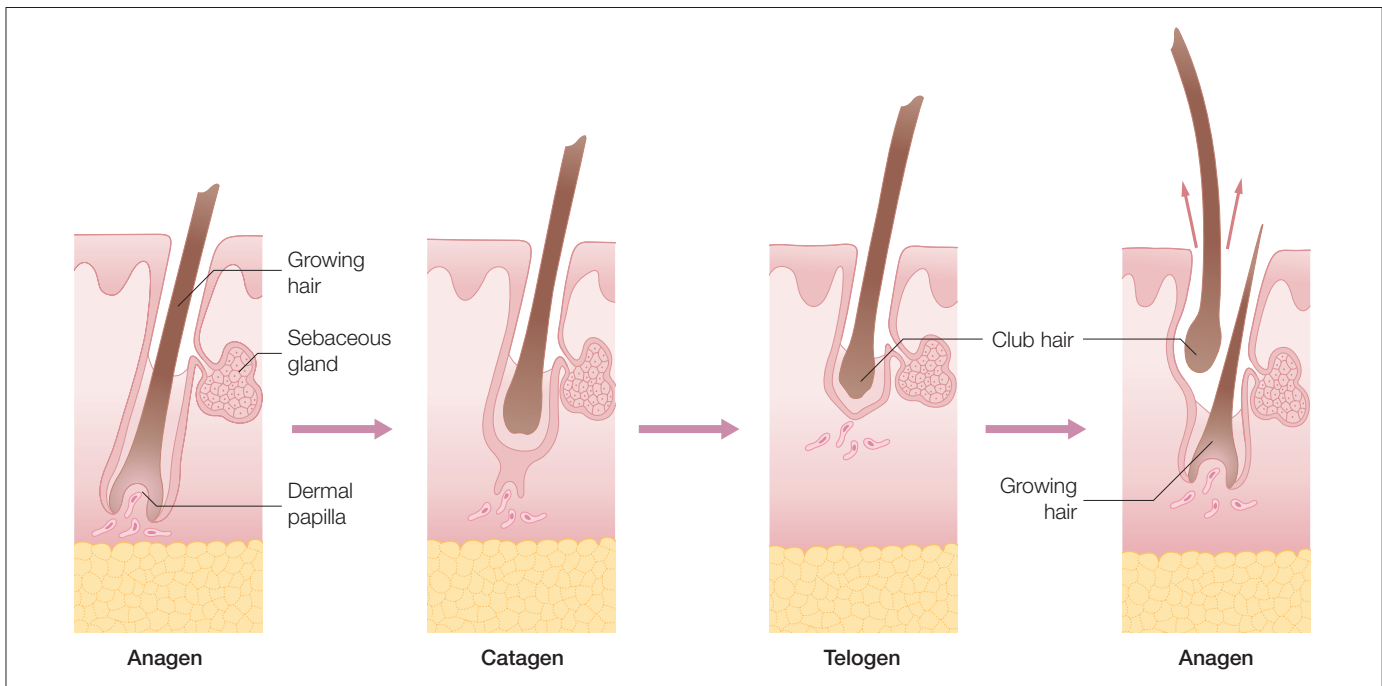
hairs have a nonpigmented bulb with a shaggy lower border. The presence of bright-red trichilemmal keratin bordering the club hair results in a flame thrower-like appearance in vertical H&E sections (Fig. 1-8). As the new anagen hair grows, the old telogen hair is shed.

The scalp hair of white people is round; pubic hair, beard hair, and eyelashes are oval. The scalp hair of black people is also oval, and this, along with curvature of the follicle just above the bulb, causes black hair to be curly. Uncombable hair is triangular with a central canal. Hair shape is at least partially controlled by the trichohyalin gene.

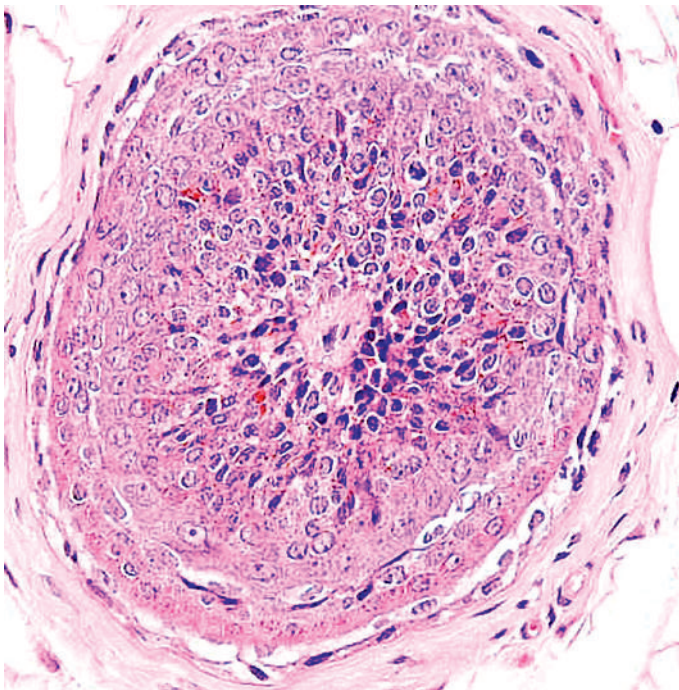
Hair color depends on the degree of melanization and distribution of melanosomes within the hair shaft. Melanocytes of the hair bulb synthesize melanosomes and transfer them to the keratinocytes of the bulb matrix. Larger melanosomes are found in the hair of black persons; smaller melanosomes, which are aggregated within membrane-bound complexes, are found in the hair of white persons. Red hair is characterized by spherical melanosomes. Graying of hair results from a decreased number of melanocytes, which produces fewer melanosomes. Repetitive oxidative stress causes apoptosis of hair follicle melanocytes, resulting in normal hair graying. Premature graying is related to exhaustion of the melanocyte stem cell pool.

Although the genetics of balding is complex, it is known that polymorphisms in the androgen receptor gene are carried on the X chromosome, inherited from the mother. The genetics of female pattern hair loss is less clear, because polymorphisms in the androgen receptor do not appear to be associated with





**Fig. 1-4** Phases of the growth cycle of a hair.

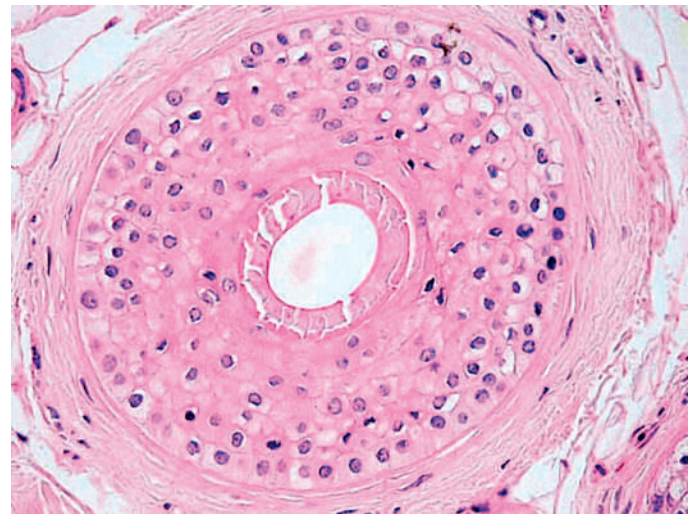


**Fig. 1-5** Cross section of anagen bulb demonstrating pigment within matrix.

female-pattern hair loss, and adrenal androgens may play a larger role.

### Sebaceous glands

Sebaceous glands are formed embryologically as an outgrowth from the upper portion of the hair follicle. They are composed of lobules of pale-staining cells with abundant lipid droplets in their cytoplasm. At the periphery of the lobules, basaloid germinative cells are noted. These cells give rise to the

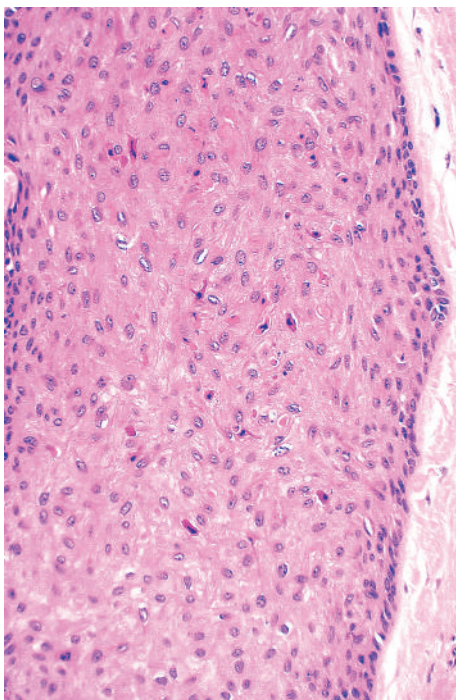


**Fig. 1-6** Cross section of isthmus of anagen follicle demonstrating glycogenated outer root sheath and keratinized inner root sheath.

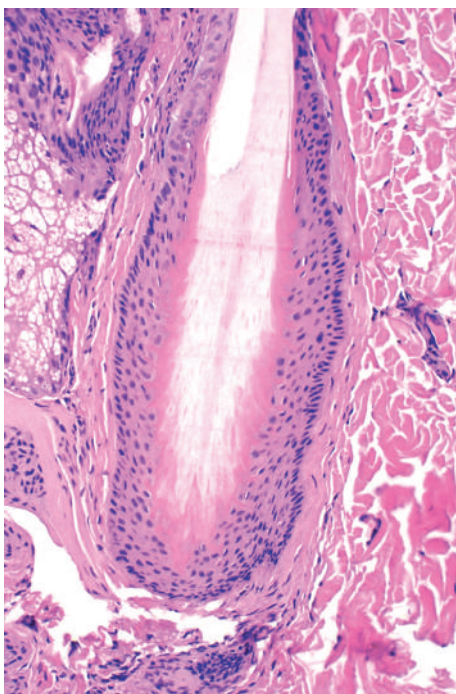
lipid-filled pale cells, which are continuously being extruded through the short sebaceous duct into the infundibular portion of the hair follicle. The sebaceous duct is lined by a red cuticle that undulates sharply in a pattern resembling shark's teeth. This same undulating cuticle is seen in steatocystoma and some dermoid cysts.

Sebaceous glands are found in greatest abundance on the face and scalp, although they are distributed throughout all skin sites except the palms and soles. They are always associated with hair follicles, except at the following sites: tarsal plate of the eyelids (meibomian glands), buccal mucosa and vermilion border of the lip (Fordyce spots), prepuce and mucosa lateral to the penile frenulum (Tyson glands), labia minora, and female areola (Montgomery tubercles).

Although sebaceous glands are independent miniorgans in their own right, they are anatomically and functionally



**Fig. 1-7** Catagen hair with many apoptotic keratinocytes within the outer root sheath.



**Fig. 1-8** Vertical section of telogen hair demonstrating "flame thrower" appearance of club hair.

related to the hair follicle. Cutaneous disorders attributed to sebaceous glands, such as acne vulgaris, are really disorders of the entire pilosebaceous unit. The clinical manifestations of acne, including the comedo, papule, pustule, and cyst, would not form, regardless of increased sebaceous gland activity, as long as the sebaceous duct and infundibular portion of the hair follicle remained patent, and lipid and cell debris (sebum) were able to reach the skin surface.

Most lipids produced by the sebaceous gland are also produced elsewhere in the body. Wax esters and squalene are unique secretory products of sebaceous glands. Sebocytes express histamine receptors, and antihistamines can reduce

squalene levels, suggesting that antihistamines could play a role in modulating sebum production. Skin lipids contribute to the barrier function, and some have antimicrobial properties. Antimicrobial lipids include free sphingoid bases derived from epidermal ceramides and fatty acids (e.g., sapienic acid) derived from sebaceous triglycerides.

**Novotný J, et al:** Synthesis and structure-activity relationships of skin ceramides. *Curr Med Chem* 2010; 17(21):2301–2324.

**Patzelt A, et al:** Drug delivery to hair follicles. *Expert Opin Drug Deliv* 2013; 10(6):787–797.

**Westgate GE, et al:** The biology of hair diversity. *Int J Cosmet Sci* 2013; 35(4):329–336.

**Xu X, et al:** Co-factors of LIM domains (Clims/Ldb/Nli) regulate corneal homeostasis and maintenance of hair follicle stem cells. *Dev Biol* 2007; 312(2):484–500.

## NAILS

Nails act to assist in grasping small objects and in protecting the fingertip from trauma. Matrix keratinization leads to the formation of the nail plate. Fingernails grow an average of 0.1 mm/day, requiring about 4–6 months to replace a complete nail plate. The growth rate is much slower for toenails, with 12–18 months required to replace the great toenail. Abnormalities of the nail may serve as important clues to cutaneous and systemic disease and may provide the astute clinician with information about disease or toxic exposures that occurred several months earlier.

The keratin types found in the nail are a mixture of epidermal and hair types, with the hair types predominating. Nail isthmus keratinization differs from that of the nail bed in that keratin 10 is only present in nail isthmus. Brittle nails demonstrate widening of the intercellular space between nail keratinocytes on electron microscopy.

Whereas most of the skin is characterized by rete pegs that resemble an egg crate, the nail bed has true parallel rete ridges. These ridges result in the formation of splinter hemorrhages when small quantities of extravasated red blood cells mark their path. The nail cuticle is formed by keratinocytes of the proximal nailfold, whereas the nail plate is formed by matrix keratinocytes. Endogenous pigments tend to follow the contour of the lunula (distal portion of matrix), whereas exogenous pigments tend to follow the contour of the cuticle. The dorsal nail plate is formed by the proximal matrix, and the ventral nail plate is formed by the distal matrix with some contribution from the nail bed. The location of a melanocytic lesion within the matrix can be assessed by the presence of pigment within the dorsal or ventral nail plate.

**Fleckman P, et al:** Comparative anatomy of mouse and human nail units. *Anat Rec (Hoboken)* 2013; 296(3):521–532.

## DERMIS

The constituents of the dermis are mesodermal in origin except for nerves, which, as with melanocytes, derive from the neural crest. Until the sixth week of fetal life, the dermis is merely a pool of scattered dendritic-shaped cells containing acid mucopolysaccharide, which are the precursors of fibroblasts. By the 12th week, fibroblasts are actively synthesizing reticulum fibers, elastic fibers, and collagen. A vascular network develops, and by the 24th week, fat cells have appeared beneath the dermis. During fetal development, Wnt/ $\beta$ -catenin signaling is critical for differentiation of ventral versus dorsal dermis, and the dermis then serves as a scaffold for the adnexal structures identified with ventral or dorsal sites.



Infant dermis is composed of small collagen bundles that stain deeply red. Many fibroblasts are present. In adult dermis, few fibroblasts persist; collagen bundles are thick and stain pale red.

Two populations of dermal dendritic cells are noted in the adult dermis. Factor XIIIa–positive dermal dendrocytes appear to give rise to dermatofibromas, angiofibromas, acquired digital fibrokeratomas, pleomorphic fibromas, and fibrous papules. CD34+ dermal dendrocytes are accentuated around hair follicles but exist throughout the dermis. They disappear from the dermis early in the course of morphea. Their loss can be diagnostic in subtle cases. CD34+ dermal dendrocytes reappear in the dermis when morphea responds to UVA1 light treatment.

The principal component of the dermis is collagen, a family of fibrous proteins comprising at least 15 genetically distinct types in human skin. Collagen serves as the major structural protein for the entire body; it is found in tendons, ligaments, and the lining of bones, as well as in the dermis. Collagen represents 70% of the dry weight of skin. The fibroblast synthesizes the procollagen molecule, a helical arrangement of specific polypeptide chains that are subsequently secreted by the cell and assembled into collagen fibrils. Collagen is rich in the amino acids hydroxyproline, hydroxylysine, and glycine. The fibrillar collagens are the major group found in the skin.

Type I collagen is the major component of the dermis. The structure of type I collagen is uniform in width, and each fiber displays characteristic cross-striations with a periodicity of 68 nm. Collagen fibers are loosely arranged in the papillary and adventitial (periadnexal) dermis. Large collagen bundles are noted in the reticular dermis (dermis below level of post-capillary venule). Collagen I messenger RNA and collagen III mRNA are both expressed in the reticular and papillary dermis and are downregulated by UV light, as is the collagen regulatory proteoglycan decorin. This downregulation may play a role in photoaging.

Type IV collagen is found in the BMZ. Type VII collagen is the major structural component of anchoring fibrils and is produced predominately by keratinocytes. Abnormalities in type VII collagen are seen in dystrophic epidermolysis bullosa, and autoantibodies to this collagen type characterize acquired epidermolysis bullosa. Collagen fibers are continuously being degraded by proteolytic enzymes called “spare collagenases” and replaced by newly synthesized fibers. Additional information on collagen types and diseases can be found in Chapter 25.

The fibroblast also synthesizes elastic fibers and the ground substance of the dermis, which is composed of glycosaminoglycans or acid mucopolysaccharides. Elastic fibers differ both structurally and chemically from collagen. They consist of aggregates of two components: protein filaments and elastin, an amorphous protein. The amino acids desmosine and isodesmosine are unique to elastic fibers. Elastic fibers in the papillary dermis are fine, whereas those in the reticular dermis are coarse. The extracellular matrix or ground substance of the dermis is composed of sulfated acid mucopolysaccharide, principally chondroitin sulfate and dermatan sulfate, neutral mucopolysaccharides, and electrolytes. Sulfated acid mucopolysaccharides stain with colloidal iron and with alcian blue at both pH 2.5 and pH 0.5. They stain metachromatically with toluidine blue at both pH 3.0 and pH 1.5. Hyaluronan (hyaluronic acid) is a minor component of normal dermis but is the major mucopolysaccharide that accumulates in pathologic states. It stains with colloidal iron, and with both alcian blue and toluidine blue (metachromatically), but only at the higher pH for each stain.

Collagen is the major stress-resistant material of the skin. Elastic fibers contribute little to resisting deformation and tearing of skin but have a role in maintaining elasticity.

*Connective tissue disease* is a term generally used to refer to a clinically heterogeneous group of autoimmune diseases, including lupus erythematosus, scleroderma, and dermatomyositis. Scleroderma involves the most visible collagen abnormalities, as collagen bundles become hyalinized and the space between collagen bundles diminishes. Both lupus and dermatomyositis produce increased dermal mucin, mostly hyaluronic acid. Bullous lupus has autoantibodies directed against type VII collagen.

Defects in collagen synthesis have been described in a number of inheritable diseases, including Ehlers-Danlos syndrome, X-linked cutis laxa, and osteogenesis imperfecta. Defects in elastic tissue are seen in Marfan syndrome and pseudoxanthoma elasticum.

## Vasculature

The dermal vasculature consists principally of two intercommunicating plexuses. The subpapillary plexus, or upper horizontal network, contains the postcapillary venules and courses at the junction of the papillary and reticular dermis. This plexus furnishes a rich supply of capillaries, end arterioles, and venules to the dermal papillae. The deeper, lower horizontal plexus is found at the dermal-subcutaneous interface and is composed of larger blood vessels than those of the superficial plexus. Nodular lymphoid infiltrates surrounding this lower plexus are typical of early inflammatory morphea. The vasculature of the dermis is particularly well developed at sites of adnexal structures. Associated with the vascular plexus are dermal lymphatics and nerves.

## Muscles

Smooth muscle occurs in the skin as arrectores pilorum (erectors of the hairs), as the tunica dartos (or dartos) of the scrotum, and in the areolas around the nipples. The arrectores pilorum are attached to the hair follicles below the sebaceous glands and, in contracting, pull the hair follicle upward, producing gooseflesh. The presence of scattered smooth muscle throughout the dermis is typical of anogenital skin.

Smooth muscle also comprises the muscularis of dermal and subcutaneous blood vessels. The muscularis of veins is composed of small bundles of smooth muscle that crisscross at right angles. Arterial smooth muscle forms a concentric, wreathlike ring. Specialized aggregates of smooth muscle cells (glomus bodies) are found between arterioles and venules and are especially prominent on the digits and at the lateral margins of the palms and soles. Glomus bodies serve to shunt blood and regulate temperature. Most smooth muscle expresses desmin intermediate filaments, but vascular smooth muscle instead expresses vimentin. Smooth muscle actin is consistently expressed by all types of smooth muscle.

Striated (voluntary) muscle occurs in the skin of the neck as the platysma muscle and in the skin of the face as the muscles of expression. This complex network of striated muscle, fascia, and aponeuroses is known as the superficial muscular aponeurotic system (SMAS).

## Nerves

In the dermis, nerve bundles are found together with arterioles and venules as part of the neurovascular bundle. In the deep dermis, nerves travel parallel to the surface, and the presence of long, sausage-like granulomas following this path is an important clue to the diagnosis of Hansen’s disease.

Touch and pressure are mediated by Meissner corpuscles found in the dermal papillae, particularly on the digits, palms, and soles, and by Vater-Pacini corpuscles located in the deeper portion of the dermis of weight-bearing surfaces and genitalia. Mucocutaneous end organs are found in the papillary dermis of modified hairless skin at the mucocutaneous junctions: the glans, prepuce, clitoris, labia minora, perianal region, and vermilion border of the lips. Temperature, pain, and itch sensation are transmitted by unmyelinated nerve fibers that terminate in the papillary dermis and around hair follicles. Impulses pass to the central nervous system by way of the dorsal root ganglia. Histamine-evoked itch is transmitted by slow-conducting unmyelinated C-polymodal neurons. Signal transduction differs for sensations of heat and cold and in peripheral nerve axons.

Postganglionic adrenergic fibers of the autonomic nervous system regulate vasoconstriction, apocrine gland secretions, and contraction of arrector pili muscles of hair follicles. Cholinergic fibers mediate eccrine sweat secretion.

## Mast cells

Mast cells play an important role in the normal immune response, as well as immediate-type sensitivity, contact allergy, and fibrosis. Measuring 6–12 microns in diameter, with ample amphophilic cytoplasm and a small round central nucleus, normal mast cells resemble fried eggs in histologic sections. In telangiectasia macularis eruptiva perstans (TMEP mastocytosis), they are spindle-shaped and hyperchromatic, resembling large, dark fibroblasts. Mast cells are distinguished by containing up to 1000 granules, each measuring 0.6–0.7 micron in diameter. Coarse particulate granules, crystalline granules, and granules containing scrolls may be seen. On the cell's surface are 100,000–500,000 glycoprotein receptor sites for immunoglobulin E (IgE). There is heterogeneity to mast cells with type I, or connective tissue mast cells found in the dermis and submucosa, and type II, or mucosal mast cells found in the bowel and respiratory tract mucosa.

Mast cell granules stain metachromatically with toluidine blue and methylene blue (in Giemsa stain) because of their high content of heparin. They also contain histamine, neutrophil chemotactic factor, eosinophil chemotactic factor of anaphylaxis, tryptase, kininogenase, and  $\beta$ -glucosaminidase. Slow-reacting substance of anaphylaxis (leukotrienes C4 and D4), leukotriene B4, platelet-activating factor, and prostaglandin D2 are formed only after IgE-mediated release of granules. Mast cells stain reliably with the Leder ASD-chloracetase esterase stain. Because this stain does not rely on the presence of mast cell granules, it is particularly useful in situations when mast cells have degranulated. In forensic medicine, fluorescent labeling of mast cells with antibodies to the mast cell enzymes chymase and tryptase is useful in determining the

timing of skin lesions in regard to death. Lesions sustained while living show an initial increase and then a decline in mast cells. Lesions sustained postmortem demonstrate few mast cells.

Cutaneous mast cells respond to environmental changes. Dry environments result in an increase in mast cell number and cutaneous histamine content. In mastocytosis, mast cells accumulate in skin because of abnormal proliferation, migration, and failure of apoptosis. The terminal deoxynucleotidyl transferase-mediated deoxyuridine triphosphate-biotin nick end labeling (TUNEL) method is used to assess apoptosis and demonstrates decreased staining in mastocytomas. Proliferation usually is only moderately enhanced.

**Abraham SN, et al:** Mast cell-orchestrated immunity to pathogens. *Nat Rev Immunol* 2010; 10(6):440–452.

**Metz M, et al:** Mast cell functions in the innate skin immune system. *Immunobiology* 2008;213(3–4):251–260.

**Mikesh LM, et al:** Proteomic anatomy of human skin. *J Proteomics* 2013; 84:190–200.

## SUBCUTANEOUS TISSUE (FAT)

Beneath the dermis lies the panniculus, with lobules of fat cells or lipocytes separated by fibrous septa composed of collagen and large blood vessels. The collagen in the septa is continuous with the collagen in the dermis. Just as the epidermis and dermis vary in thickness according to skin site, so does the subcutaneous tissue. The panniculus provides buoyancy and functions as a repository of energy and an endocrine organ. It is an important site of hormone conversion, such as that of androstenedione into estrone by aromatase. Leptin, a hormone produced in lipocytes, regulates body weight through the hypothalamus and influences how we react to flavors in food. Various substances can affect lipid accumulation within lipocytes. Obestatin is a polypeptide that reduces feed intake and weight gain in rodents. (-)Ternatin, a highly *N*-methylated cyclic heptapeptide that inhibits fat accumulation, produced by the mushroom *Coriolus versicolor*, has similar effects in mice. Study of these molecules provides insight into the molecular basis of weight gain and obesity. Abnormal fat distribution and insulin resistance are seen in Cushing syndrome and as a result of antiretroviral therapy. In obese children and adolescents developing diabetes, severe peripheral insulin resistance is associated with intramyocellular and intra-abdominal lipocyte lipid accumulation.

Certain inflammatory dermatoses, known as the panniculitides, principally affect this level of the skin, producing subcutaneous nodules. The pattern of the inflammation, specifically whether it primarily affects the septa or the fat lobules, serves to distinguish various conditions that may be clinically similar.

**Khan MH et al:** Treatment of cellulite. Part I. Pathophysiology. *J Am Acad Dermatol* 2010; 62(3):361–370.



# Cutaneous Signs and Diagnosis

# 2

In some patients, the appearance of skin lesions may be so distinctive that the diagnosis is clear at a glance. In others, subjective symptoms and clinical signs alone are inadequate, and a complete history and laboratory examination, including a biopsy, are essential to arrive at a diagnosis.

The same disease may show variations under different conditions and in different individuals. The appearance of the lesions may have been modified by previous treatment or obscured by extraneous influences, such as scratching or secondary infection. Subjective symptoms may be the only evidence of a disease, as in pruritus, and the skin appearance may be generally unremarkable. Although history is important, the diagnosis in dermatology is most frequently made based on the objective physical characteristics and location or distribution of one or more lesions that can be seen or felt. Therefore, careful physical examination of the skin is paramount in dermatologic diagnosis.

## CUTANEOUS SIGNS

Typically, most skin diseases produce or present with lesions that have more or less distinct characteristics. They may be uniform or diverse in size, shape, and color and may be in different stages of evolution or involution. The original lesions are known as the primary lesions, and identification of such lesions is the most important aspect of the dermatologic physical examination. They may continue to full development or be modified by regression, trauma, or other extraneous factors, producing secondary lesions.

### Primary lesions

Primary lesions are of the following forms: macules (or patches), papules (or plaques), nodules, tumors, wheals, vesicles, bullae, and pustules.

### Macules (maculae, spots)

Macules are variously sized, circumscribed changes in skin color, without elevation or depression (nonpalpable) (Fig. 2-1). They may be circular, oval, or irregular and may be distinct in outline or may fade into the surrounding skin. Macules may constitute the whole lesion or part of the eruption or may be merely an early phase. If the lesions become slightly raised, they are then designated papules or, in some cases, morbilliform eruptions.

### Patches

A patch is a large macule, 1 cm or greater in diameter, as may be seen in nevus flammeus or vitiligo.

### Papules

Papules are circumscribed, solid elevations with no visible fluid, varying in size from a pinhead to 1 cm. They may be acuminate, rounded, conical, flat topped, or umbilicated and may appear white (as in milium), red (eczema), yellowish (xanthoma), or black (melanoma).

Papules are generally centered in the dermis and may be concentrated at the orifices of the sweat ducts or at the hair follicles. They may be of soft or firm consistency. The surface may be smooth or rough. If capped by scales, they are known as squamous papules, and the eruption is called papulosquamous.

Some papules are discrete and irregularly distributed, as in papular urticaria, whereas others are grouped, as in lichen nitidus (Fig. 2-2). Some persist as papules, whereas those of the inflammatory type may progress to vesicles and even to pustules, or they may erode or ulcerate before regression takes place.

The term “maculopapular” should not be used. There is no such thing as a “maculopapule,” although there may be both macules and papules in an eruption. Typically, such eruptions are morbilliform.

### Plaques

A plaque is a broad papule (or confluence of papules), 1 cm or more in diameter (Fig. 2-3). It is generally flat but may be centrally depressed. The center of a plaque may be normal skin.

### Nodules

Nodules are morphologically similar to papules but are larger than 1 cm in diameter. Nodules most frequently are centered in the dermis or subcutaneous fat.

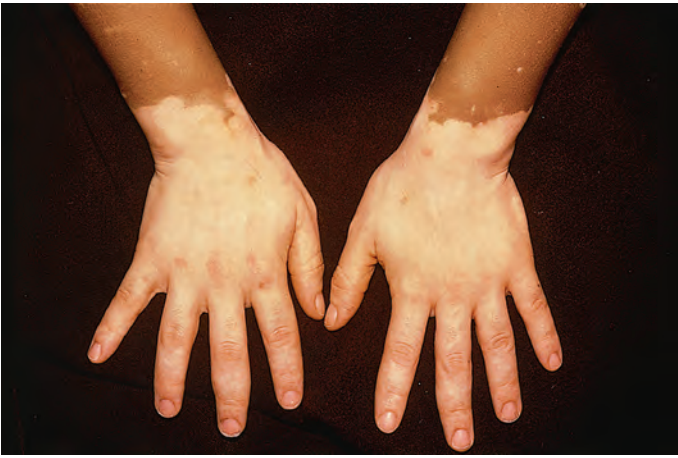### Tumors

Tumors are soft or firm, freely movable or fixed masses of various sizes and shapes, but generally greater than 2 cm in diameter. General usage dictates that the word “tumor” means a neoplasm. They may be elevated or deep seated and in some cases are pedunculated (neurofibromas). Tumors have a tendency to be rounded. Their consistency depends on the constituents of the lesion. Some tumors remain stationary indefinitely, whereas others increase in size or break down.

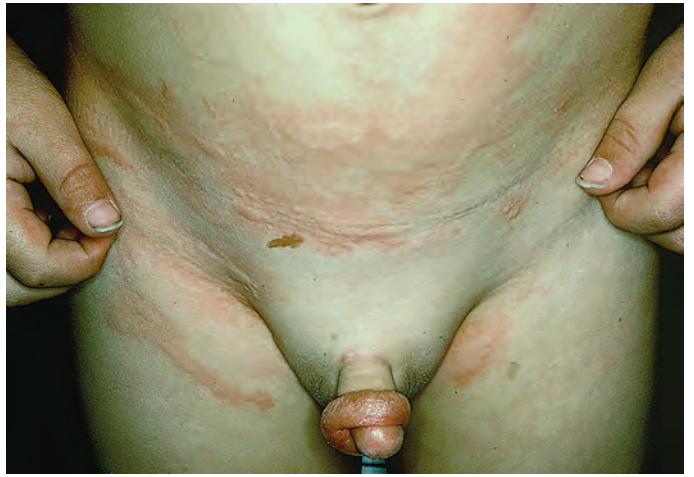### Wheals (hives)

Wheals are evanescent, edematous, plateaulike elevations of various sizes (Fig. 2-4). They are usually oval or of arcuate contours, pink to red, and surrounded by a “flare” of macular

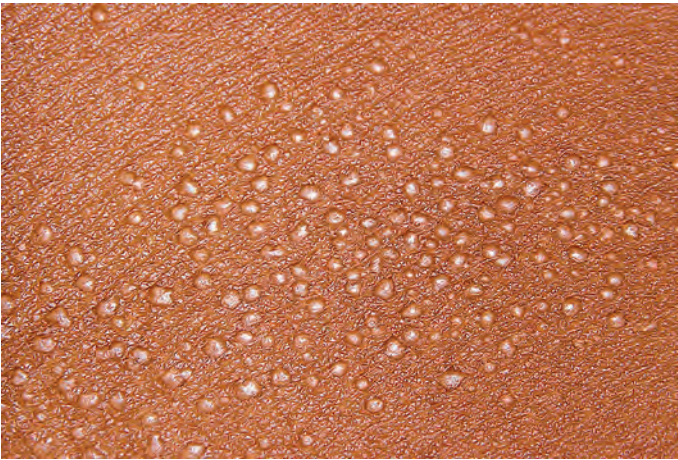



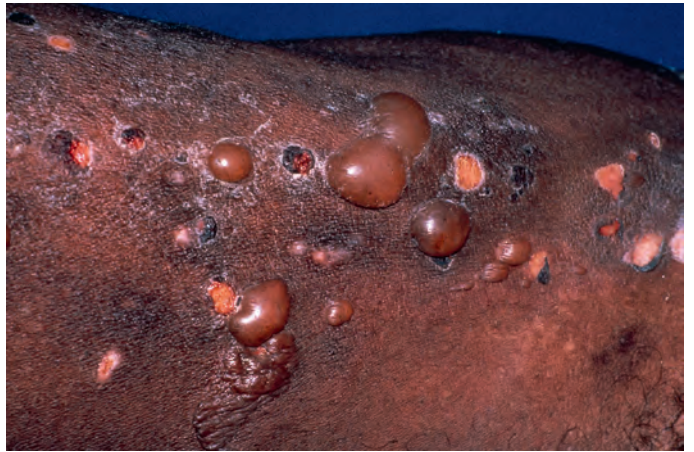**Fig. 2-1** Macular depigmentation, vitiligo.



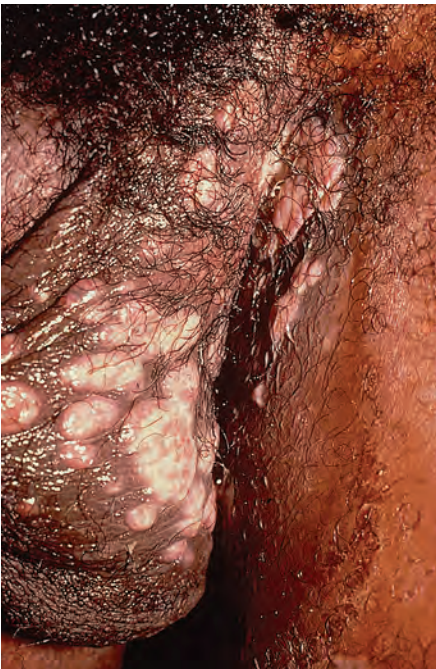**Fig. 2-4** Acute urticaria.



**Fig. 2-2** Whitish grouped papules of lichen nitidus.



**Fig. 2-5** Vesicles, bullae, and erosions; bullous pemphigoid.



**Fig. 2-3** Moist plaques of condyloma lata.

erythema. Whorls may be discrete or may coalesce. These lesions often develop quickly (minutes to hours). Because the wheal is the prototypic lesion of urticaria, diseases in which wheals are prominent are frequently described as “urticarial” (e.g., urticarial vasculitis). Dermatographism, or pressure-induced whealing, may be evident.

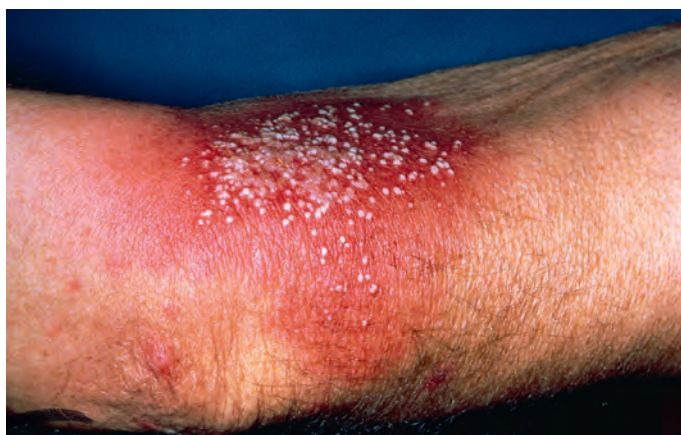### Vesicles (blisters)

Vesicles are circumscribed, fluid-containing elevations 1–10 mm in size. They may be pale or yellow from serous exudate or red from serum mixed with blood. The apex may be rounded, acuminate, or umbilicated, as in eczema herpeticum. Vesicles may be discrete, irregularly scattered, grouped (e.g., herpes zoster), or linear, as in allergic contact dermatitis from urushiol (poison ivy/oak). Vesicles may arise directly or from a macule or papule and generally lose their identity in a short time, breaking spontaneously or developing into bullae through coalescence or enlargement, or developing into pustules (Fig. 2-5). When the contents are of a seropurulent character, the lesions are known as vesicopustules. Vesicles have either a single cavity (unilocular) or several compartments (multilocular).

### Bullae

Bullae are rounded or irregularly shaped blisters containing serous or seropurulent fluid. They differ from vesicles only in size, being larger than 1 cm. They are usually unilocular but





**Fig. 2-6** Erythematous plaques studded with sheets of pustules, pustular psoriasis.

may be multilocular. Bullae may be located superficially in the epidermis, so their walls are flaccid and thin and subject to rupture spontaneously or from slight injury. After rupture, remnants of the thin walls may persist and, together with the exudate, may dry to form a thin crust; or the broken bleb may leave a raw and moist base, which may be covered with seropurulent or purulent exudate. Less frequently, irregular vegetations may appear on the base (as in pemphigus vegetans). When subepidermal, the bullae are tense, do not rupture easily, and are often present when the patient is examined.

Nikolsky's sign refers to the diagnostic maneuver of putting lateral pressure on unblistered skin in a bullous eruption and having the epithelium shear off. Asboe-Hansen's sign refers to the extension of a blister to adjacent, unblistered skin when pressure is put on the top of the blister. Both these signs demonstrate the principle that in some diseases, the extent of microscopic vesiculation is more than what is evident by simple inspection. These findings are useful in evaluating the severity of pemphigus vulgaris and severe bullous drug reactions. Hemorrhagic bullae are common in pemphigus, herpes zoster, severe bullous drug reactions, and lichen sclerosus. The cellular contents of bullae may be useful in cytologically confirming the diagnosis of pemphigus, herpes zoster, and herpes simplex.

## Pustules

Pustules are small elevations of the skin containing purulent material, usually necrotic inflammatory cells (Fig. 2-6). They are similar to vesicles in shape and usually have an inflammatory areola. Pustules are usually white or yellow centrally but may be red if they also contain blood. They may originate as pustules or may develop from papules or vesicles, passing through transitory early stages, during which they are known as papulopustules or vesicopustules.

## Secondary lesions

Secondary lesions are of many types; the most important are scales, crusts, erosions, ulcers, fissures, and scars.

## Scales (exfoliation)

Scales are dry or greasy, laminated masses of keratin. The body ordinarily is constantly shedding imperceptible tiny, thin fragments of stratum corneum. When the formation of epidermal cells is rapid or the process of normal keratinization is disturbed, pathologic exfoliation results, producing scales.

These scales vary in size; some are fine, delicate, and branny, as in tinea versicolor, whereas others are coarser, as in eczema and ichthyosis, and still others are stratified, as in psoriasis. Large sheets of desquamated epidermis are seen in toxic epidermal necrolysis, staphylococcal scalded skin syndrome, and infection-associated (toxin-mediated) desquamations, such as scarlet fever. Scales vary in color from white-gray to yellow or brown from the admixture of dirt or melanin. Occasionally, they have a silvery sheen from trapping of air between their layers; these are micaceous scales, characteristic of psoriasis. When scaling occurs, it usually suggests a pathologic process in the epidermis, and parakeratosis is often present histologically.

## Crusts (scabs)

Crusts are dried serum, pus, or blood, usually mixed with epithelial and sometimes bacterial debris. When crusts become detached, the base may be dry or red and moist.

## Excoriations and abrasions (scratch marks)

An excoriation is a punctate or linear abrasion produced by mechanical means, usually involving only the epidermis but sometimes reaching the papillary layer of the dermis. Excoriations are caused by scratching with the fingernails in an effort to relieve itching. If the skin damage is the result of mechanical trauma or constant friction, the term "abrasion" may be used. Frequently, there is an inflammatory areola around the excoriation or a covering of yellowish dried serum or red dried blood. Excoriations may provide access for pyogenic microorganisms and the formation of crusts, pustules, or cellulitis, occasionally associated with enlargement of the neighboring lymphatic glands. In general, the longer and deeper the excoriations, the more severe is the pruritus that provoked them. Lichen planus is an exception, however, in which pruritus is severe, but excoriations are rare.

## Fissures (cracks, clefts)

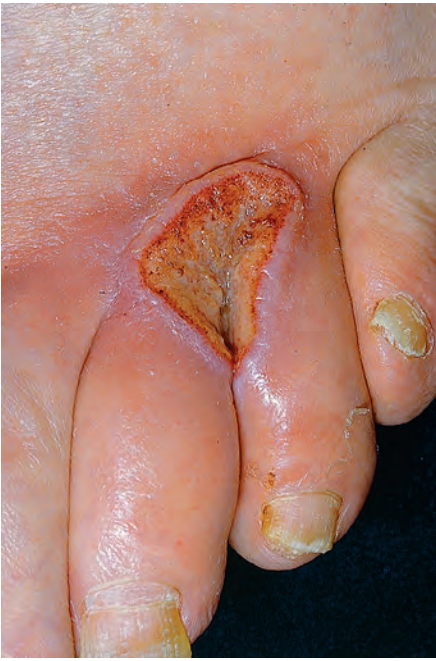A fissure is a linear cleft through the epidermis or into the dermis. These lesions may be single or multiple and vary from microscopic to several centimeters in length with sharply defined margins. Fissures may be dry or moist, red, straight, curved, irregular, or branching. They occur most often when the skin is thickened and inelastic from inflammation and dryness, especially in regions subjected to frequent movement. Such areas are the tips and flexural creases of the thumbs, fingers, and palms; the edges of the heels; the clefts between the fingers and toes; at the angles of the mouth; the lips; and around the nares, auricles, and anus. When the skin is dry, exposure to cold, wind, water, and cleaning products (soap, detergents) may produce a stinging, burning sensation, indicating microscopic fissuring is present. This may be referred to as chapping, as in "chapped lips." When fissuring is present, pain is often produced by movement of the parts, which opens or deepens the fissures or forms new ones.

## Erosions

Loss of all or portions of the epidermis alone, as in impetigo, produces an erosion. It may or may not become crusted, but it heals without a scar.

## Ulcers

Ulcers are rounded or irregularly shaped excavations that result from complete loss of the epidermis plus some portion



**Fig. 2-7** Ulceration secondary to squamous cell carcinoma.

of the dermis. They vary in diameter from a few millimeters to several centimeters (Fig. 2-7). Ulcers may be shallow, involving little beyond the epidermis, as in dystrophic epidermolysis bullosa, the base being formed by the papillary layer, or they may extend deeply into the dermis, subcutaneous tissues, or deeper, as with leg ulcers. Ulcers heal with scarring.

## Scars

Scars are composed of new connective tissue that has replaced lost substance in the dermis or deeper parts resulting from injury or disease, as part of the normal reparative process. Their size and shape are determined by the form of the previous destruction. Scarring is characteristic of certain inflammatory processes and is therefore of diagnostic value. The pattern of scarring may be characteristic of a particular disease. Lichen planus and discoid lupus erythematosus, for example, have inflammation that is in relatively the same area anatomically, yet discoid lupus characteristically causes scarring as it resolves, whereas lichen planus rarely results in scarring of the skin. Both processes, however, cause scarring of the hair follicles when occurring on the scalp. Scars may be thin and atrophic, or the fibrous elements may develop into neoplastic overgrowths, as in hypertrophic scars or keloids. Some individuals and some areas of the body, especially the anterior chest and upper back, are especially prone to hypertrophic scarring. Scars first tend to be pink or violaceous, later becoming white, glistening, and rarely, hyperpigmented. Scars are persistent but usually become softer, less elevated, and less noticeable over years.

## GENERAL DIAGNOSIS

Interpretation of the clinical picture may be difficult because identical clinical lesions may have many different causes. Moreover, the same skin disease may give rise to diverse eruptions. Thus, for each specific type or primary morphologic lesion, there is a differential diagnosis of the conditions that could produce that lesion. Also, there is a parallel list of all the variations that a single skin disease can cause; for example, lichen planus may have hyperpigmented patches, violaceous

plaques, hypertrophic papules, and rarely, minute papules or even cysts.

Being superficial, skin lesions can be easily observed and palpated. Magnification may be easily applied, enhancing visualization of the fine details of the lesions. Smears and cultures may be readily obtained for bacteria and fungi. Biopsy and histologic examination of skin lesions are usually minor procedures, making histopathology an important component of many dermatologic evaluations. The threshold for biopsy should be low. This is especially true of inflammatory dermatoses, potentially infectious conditions, and skin disorders in immunosuppressed and hospitalized patients in whom clinical morphology may be atypical. Once therapy is begun empirically, histologic features may be altered by the treatment, making pathologic diagnosis more difficult.

## History

Knowledge of the patient's age, health, occupation, hobbies, diet, and living conditions is important, as well as the onset, duration, and course of the disease and the response to previous treatment. The family history of similar disorders and other related diseases may be useful.

A complete drug history is one of the most important aspects of a thorough history. This includes prescription and over-the-counter medications, supplements, herbal products, eyedrops, and suppositories. Drug reactions are frequent and may simulate many different skin diseases clinically and histologically. It is equally important to inquire about topical agents that have been applied to the skin and mucous membranes for medicinal or cosmetic purposes, because these agents may cause cutaneous or systemic reactions.

A complete medical history that includes other medical diagnoses of the patient is essential. Certain skin diseases are specific to or associated with other conditions, such as cutaneous Crohn's disease and pyoderma gangrenosum in Crohn's disease. Travel abroad, the patient's environment at home and at work, seasonal occurrences and recurrences of the disease, and the temperature, humidity, and weather exposure of the patient are all important factors in a dermatologic history. Habitation in certain parts of the world predisposes to distinctive diseases for that particular geographic locale, including San Joaquin Valley fever (coccidioidomycosis), Hansen's disease, leishmaniasis, and histoplasmosis. Sexual orientation and practices may be relevant, as in genital ulcer diseases and human immunodeficiency virus (HIV) infection.

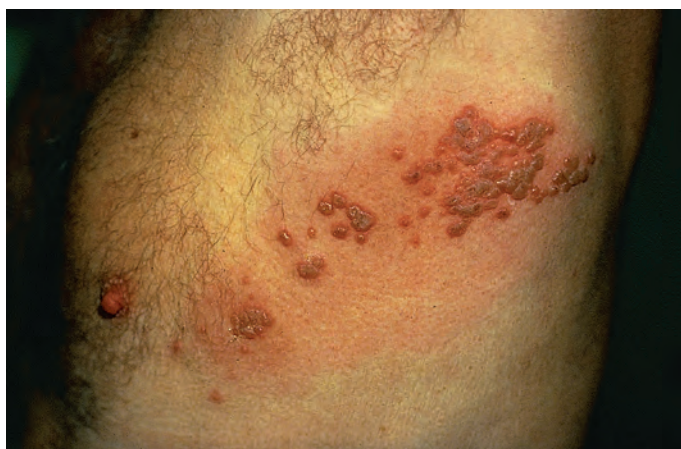## Examination

Examination should be conducted in a well-lit room. Natural sunlight is the ideal illumination. Abnormalities of melanin pigmentation (e.g., vitiligo, melasma) are more clearly visible under ultraviolet (UV) light. A Wood's light (365 nm) is most often used and is also valuable for the diagnosis of some types of tinea capitis, tinea versicolor, and erythrasma.

A magnifying lens is of inestimable value in examining small lesions. It may be necessary to palpate the lesion for firmness and fluctuation; rubbing will elucidate the nature of scales, and scraping will reveal the nature of the lesion's base. Pigmented lesions, especially in infants, should be rubbed in an attempt to elicit Darier's sign (whealing), as seen in urticaria pigmentosa. Dermoscopy is an essential part of the examination of pigmented lesions.

The entire eruption must be seen to evaluate distribution and configuration. This is optimally done by having the patient completely undress and viewing from a distance to take in the





**Fig. 2-8** Grouped vesicles along a dermatome, herpes zoster.

whole eruption at once. “Peek-a-boo” examination, by having the patient expose one anatomic area after another while remaining clothed, is not optimal because the examination of the skin will be incomplete, and the overall distribution is difficult to determine. After the patient is viewed at a distance, individual lesions are examined to identify primary lesions and to determine the evolution of the eruption and the presence of secondary lesions.

## Diagnostic details of lesions

### Distribution

Lesions may be few or numerous, and in arrangement they may be discrete or may coalesce to form patches of peculiar configuration. Lesions may appear over the entire body or may follow the lines of cleavage (pityriasis rosea), dermatomes (herpes zoster) (Fig. 2-8), or lines of Blaschko (epidermal nevi). Lesions may form groups, rings, crescents, or unusual linear patterns. A remarkable degree of bilateral symmetry is characteristic of certain diseases, such as dermatitis herpetiformis, vitiligo, and psoriasis.

### Evolution

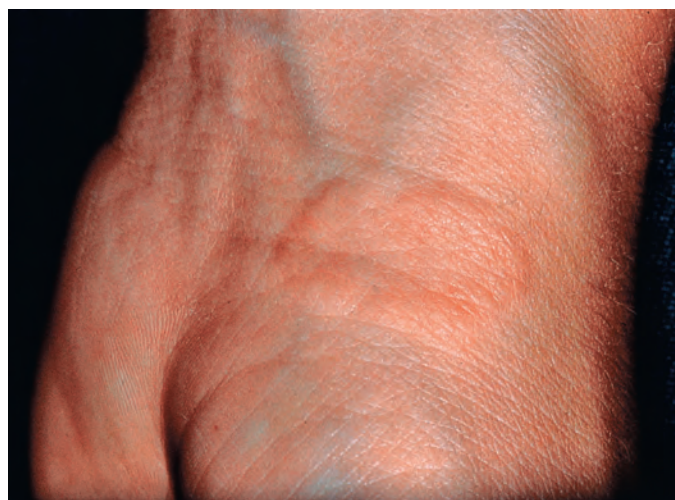
Some lesions appear fully evolved. Others develop from smaller lesions, then remain the same during their entire existence (e.g., warts). When lesions succeed one another in a series of crops, as in varicella and dermatitis herpetiformis, a polymorphous eruption results, with lesions in various stages of development or involution all present at the same time.

### Involution

Certain lesions disappear completely, whereas others leave characteristic residual pigmentation or scarring. Residual dyspigmentation, although a significant cosmetic issue, is not considered a scar. The pattern in which lesions involute may be useful in diagnosis, as with the typical keratotic papule of pityriasis lichenoides varioliformis acuta.

### Grouping

Grouping is a characteristic of dermatitis herpetiformis, herpes simplex, and herpes zoster (see Fig. 2-8). Small lesions arranged around a large one are said to be in a corymbose (corymbiform) arrangement. Concentric annular lesions are typical of borderline Hansen’s disease and erythema multiforme. These



**Fig. 2-9** Papules in an annular configuration, granuloma annulare.

are sometimes said to be in a “cockade” pattern, referring to the tricolor cockade hats worn by French revolutionists. Flea and other arthropod bites are usually grouped and linear (breakfast-lunch-and-dinner sign). Grouped lesions of various sizes may be called agminated.

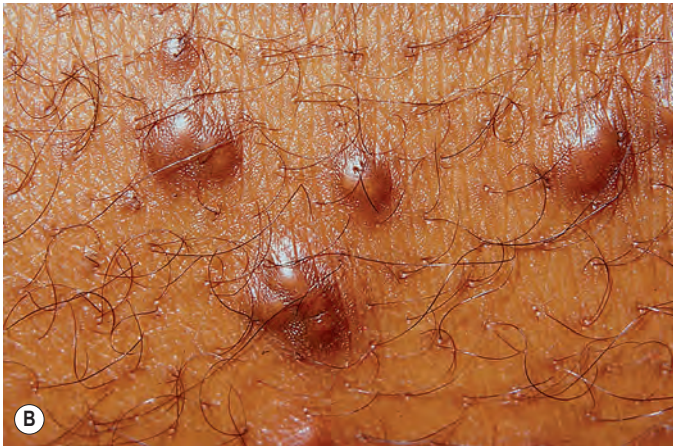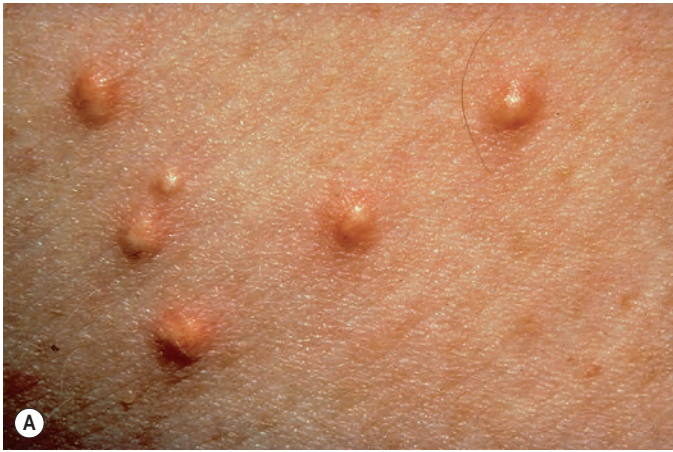## Configuration

Certain terms are used to describe the configuration that an eruption assumes either primarily or by enlargement or coalescence. Lesions in a line are called linear, and they may be confluent or discrete. Lesions may form a complete circle (annular) (Fig. 2-9) or a portion of a circle (arcuate or gyrate), or may be composed of several intersecting portions of circles (polycyclic). If the eruption is not straight but does not form parts of circles, it may be serpiginous. Round lesions may be small, like drops, called guttate; or larger, like a coin, called nummular. Unusual configurations that do not correspond to these patterns or to normal anatomic or embryonic patterns should raise the possibility of an exogenous dermatosis or factitia.

## Color

The color of the skin is determined by melanin, oxyhemoglobin, reduced hemoglobin, lipid, and carotene. Not only do the proportions of these components affect the color, but their depth within the skin, the thickness of the epidermis, and hydration also play a role. The Tyndall effect modifies the color of skin and of lesions by the selective scattering of light waves of different wavelengths. The blue nevus and mongolian spots are examples of this light dispersion effect, in which brown melanin in the dermis appears blue-gray.

The color of lesions may be valuable as a diagnostic factor. Dermatologists should be aware that there are many shades of pink, red, and purple, each of which tends to suggest a diagnosis or disease group. Interface reactions such as lichen planus or lupus erythematosus are described as violaceous. Lipid-containing lesions are yellow, as in xanthomas (Fig. 2-10) or steatocystoma multiplex. The orange-red (salmon) color of pityriasis rubra pilaris is characteristic. The constitutive color of the skin determines the quality of the color one observes with a specific disorder. In dark-skinned persons, erythema is difficult to perceive. Pruritic lesions in African Americans may evolve to be small, shiny, flat-topped papules with a violaceous hue, from the combination of erythema and pigment incontinence. These lichenified lesions would be suspected of being lichenoid by the untrained eye, but are in fact eczematous.



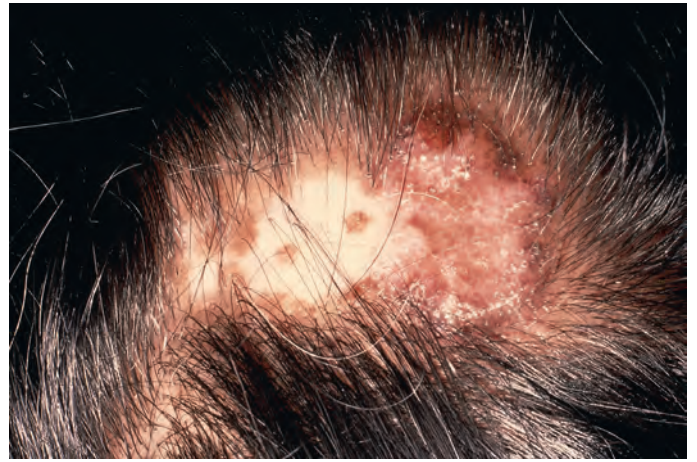
**Fig. 2-10** Eruptive xanthoma. A, Yellow color easily discerned on white skin. B, Yellow color subtler in brown or black skin.

Patches lighter in color than the normal skin may be completely depigmented or may have lost only part of their pigment (hypopigmented). This is an important distinction because certain conditions are or may be hypopigmented, such as tinea versicolor, nevus anemicus, Hansen's disease, hypomelanotic macules of tuberous sclerosis, hypomelanosis of Ito, seborrheic dermatitis, and idiopathic guttate hypomelanosis. True depigmentation should be distinguished from this; it suggests vitiligo, nevus depigmentosus, halo nevus, scleroderma, morphea, or lichen sclerosus.

Hyperpigmentation may result from epidermal or dermal causes. It may be related to either increased melanin or deposition of other substances. Epidermal hyperpigmentation occurs in nevi, melanoma, café au lait spots, melasma, and lentiginos. These lesions are accentuated when examined with a Wood's light. Dermal pigmentation occurs subsequent to many inflammatory conditions (postinflammatory hyperpigmentation) or from deposition of metals, medications, medication-melanin complexes, or degenerated dermal material (ochronosis). These conditions are not enhanced when examined by a Wood's light. The hyperpigmentation following inflammation is most frequently the result of dermal melanin deposition, but in some conditions, such as lichen aureus, is caused by iron. Dermal iron deposition appears more yellow-brown or golden than dermal melanin.

### Texture/consistency

Palpation is an essential part of the physical examination of lesions. Does the lesion blanch on pressure? If not, it may be purpuric. Is it fluctuant? If so, it may have free fluid in it. Is it



**Fig. 2-11** Scalp plaque with scarring alopecia hyperpigmentation and depigmentation, discoid lupus erythematosus.

cold or hot? If there is a nodule or tumor, does it sink through a ring into the panniculus, like a neurofibroma? Is it hard enough for calcification to be suspected, merely very firm, like a keloid or dermatofibroma, or branny, like scleredema?

### Hyperesthesia/anesthesia

Certain conditions may be associated with increased or decreased sensation. For example, the skin lesions of borderline and tuberculoid Hansen's disease typically are anesthetic in their centers. In neuropathic conditions such as neuralgia paresthetica, the patient may perceive both pruritus and hyperesthesia. Neurally mediated itch may be accompanied by other neural sensations, such as heat or burning. The combination of pruritus with other neural symptoms suggests the involvement of nerves in the pathologic process.

### Hair, nails, and oral mucosa

Involvement of hair-bearing areas by certain skin disorders causes characteristic lesions. Discoid lupus, for example, causes scarring alopecia with characteristic dyspigmentation (Fig. 2-11). On the skin, the lesions may be much less characteristic. Diffuse hair loss may be seen in certain conditions, such as acrodermatitis enteropathica, and may be a clue to the diagnosis. In addition, loss of hair within a skin lesion may suggest the diagnosis, such as the alopecia seen in the tumid plaques of follicular mucinosis.

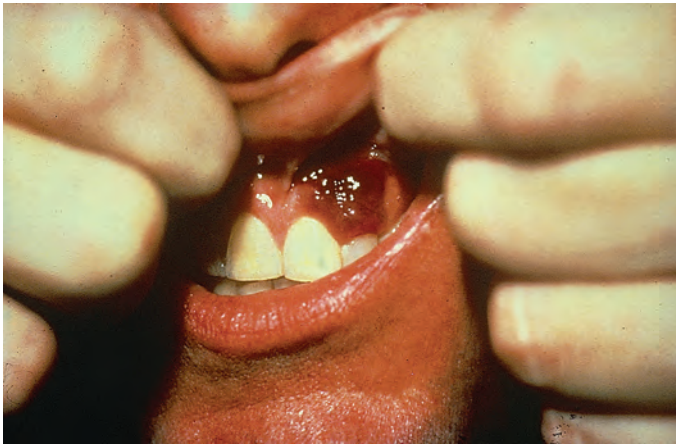Some skin disorders cause characteristic changes of the nails, even when the periungual tissue is not involved. The pitting seen in psoriasis and alopecia areata may be useful in confirming these diagnoses when other findings are not characteristic. In addition, the nails and adjacent structures may be the sole site of pathology, as in candidal paronychia.

The complete skin examination includes examination of the oral mucosa. Oral lesions are characteristically found in viral syndromes (exanthems), lichen planus, HIV-associated Kaposi sarcoma (Fig. 2-12), and autoimmune bullous diseases (pemphigus vulgaris).

### Self-examination

Patients at risk for the development of skin cancer should be taught the correct method of skin self-examination, specifically, the ABCDEs of melanoma detection and the types of lesions that might represent basal cell carcinoma or squamous cell carcinoma.





**Fig. 2-12** Oral Kaposi sarcoma.

[http://www.siumed.edu/medicine/dermatology/student\\_information/skinphysicalexam.pdf](http://www.siumed.edu/medicine/dermatology/student_information/skinphysicalexam.pdf)  
<http://www.aad.org/education/medical-student-core-curriculum>  
<http://www.aad.org/spot-skin-cancer/understanding-skin-cancer/how-do-i-check-my-skin/how-to-perform-a-self-exam>  
<http://missinglink.ucsf.edu/lm/DermatologyGlossary/index.html>



Bonus images for this chapter can be found online at

[expertconsult.inkling.com](http://expertconsult.inkling.com)

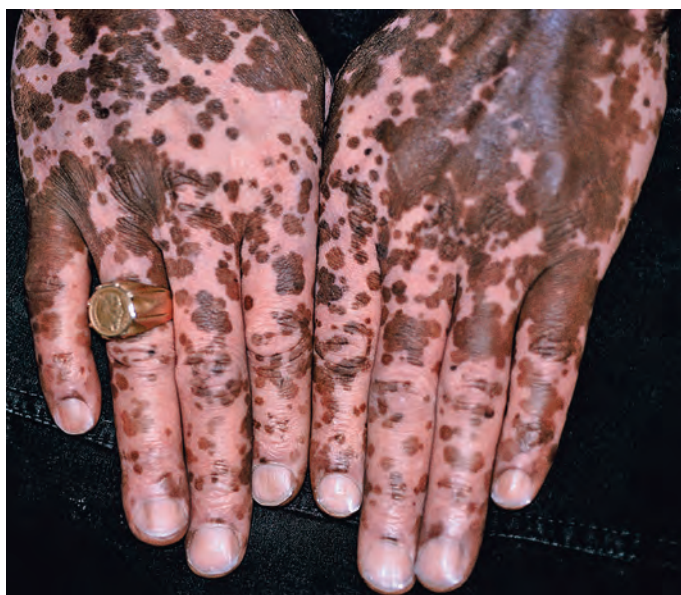**eFig. 2-1** Macular depigmentation, vitiligo.

**eFig. 2-2** Ulcer of the lip, chancre of primary syphilis.

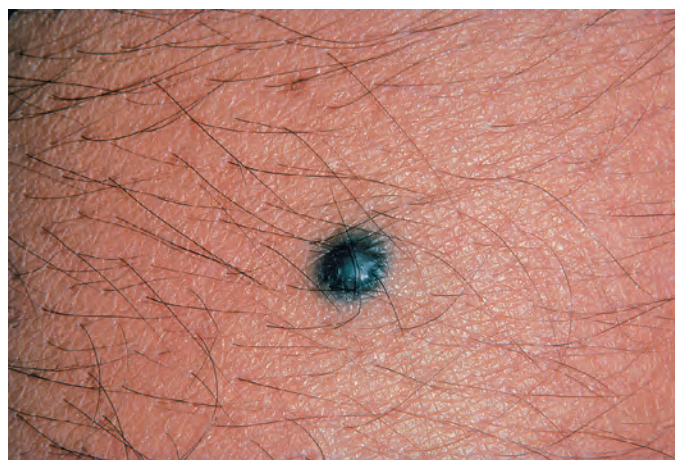**eFig. 2-3** Annular, arcuate, and polycyclic configurations; granuloma annulare.

**eFig. 2-4** Acral small blue papule, blue nevus.

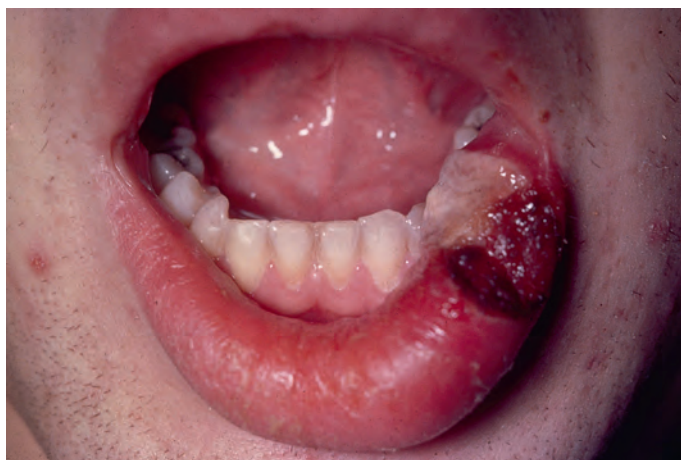**eFig. 2-5** Scalp plaque with scarring alopecia hyperpigmentation and depigmentation, discoid lupus erythematosus.



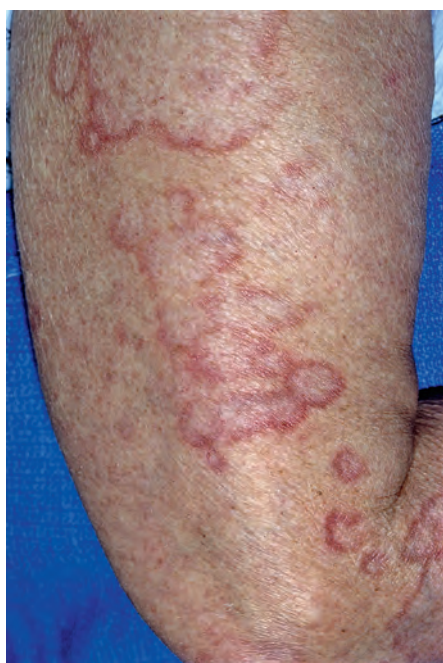**eFig. 2-1** Macular depigmentation, vitiligo.



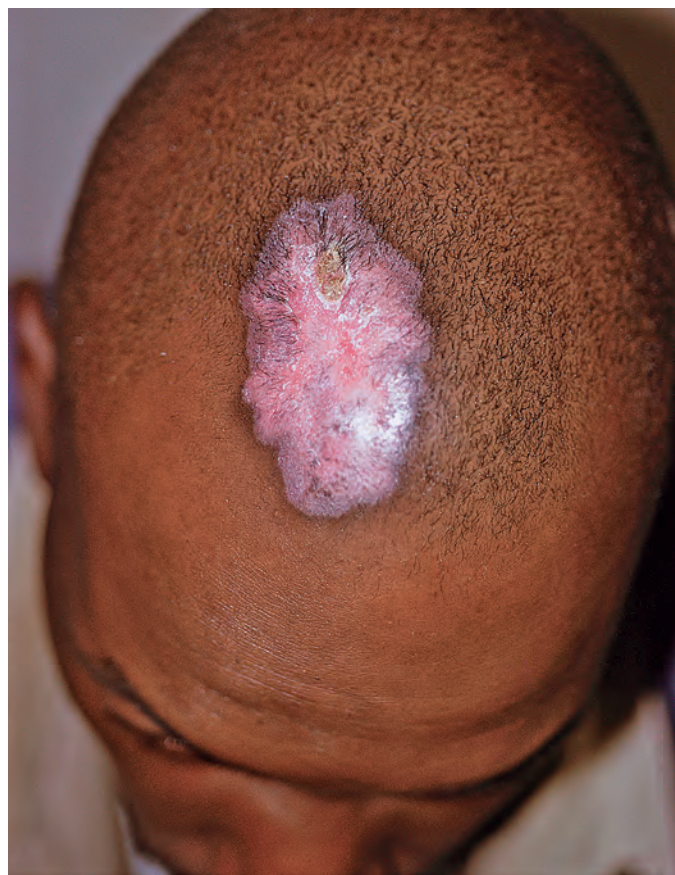**eFig. 2-4** Acral small blue papule, blue nevus.



**eFig. 2-2** Ulcer of the lip, chancre of primary syphilis.



**eFig. 2-3** Annular, arcuate, and polycyclic configurations; granuloma annulare.



**eFig. 2-5** Scalp plaque with scarring alopecia hyperpigmentation and depigmentation, discoid lupus erythematosus.



# 3

## Dermatoses Resulting from Physical Factors

The body requires a certain amount of heat, but beyond definite limits, insufficient or excessive amounts are injurious. The local action of excessive heat causes burns or scalds; undue cold causes chilblains, frostbite, and congelation. Thresholds of tolerance exist in all body structures sensitive to electromagnetic wave radiation of varying frequencies, such as x-rays and ultraviolet (UV) rays. The skin, which is exposed to so many external physical forces, is more subject to injuries caused by this radiation than any other organ.

### HEAT INJURIES

#### Thermal burns

Injury of varying intensity may be caused by the action of excessive heat on the skin. If this heat is extreme, the skin and underlying tissue may be destroyed. The changes in the skin resulting from dry heat or scalding are classified in four degrees, as follows:

- *First-degree burns* of the skin result merely in an active congestion of the superficial blood vessels, causing erythema that may be followed by epidermal desquamation (peeling). Ordinary sunburn is the most common example of a first-degree burn. The pain and increased surface heat may be severe, and some constitutional reaction can occur if the involved area is large.
- *Second-degree burns* are subdivided into superficial and deep forms.

In the superficial second-degree burn, there is a transudation of serum from the capillaries, which causes edema of the superficial tissues. Vesicles and blebs are formed by the serum gathering beneath the outer layers of the epidermis. Complete recovery without scarring is usual in patients with superficial burns.

The deep second-degree burn is pale and anesthetic.

Injury to the reticular dermis compromises blood flow and destroys appendages, so healing takes more than 1 month and results in scarring.

- *Third-degree burns* involve loss of the full thickness of the dermis and often some of the subcutaneous tissues. Because the skin appendages are destroyed, there is no epithelium available for regeneration of the skin. An ulcerating wound is produced, which on healing leaves a scar.
- *Fourth-degree burns* involve the destruction of the entire skin, including the subcutaneous fat, and any underlying tendons.

Both third-degree and fourth-degree burns require grafting for closure. All third- and fourth-degree burns are followed by

constitutional symptoms of varying severity, depending on the size of the involved surface, the depth of the burn, and particularly the location of the burned surface. The more vascular the involved area, the more severe are the symptoms.

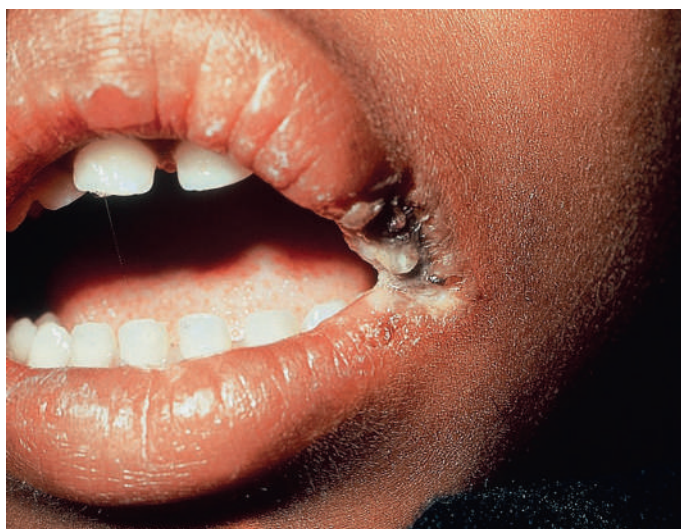The prognosis is poor for any patient in whom a large area of skin surface is involved, particularly if more than two thirds of the body surface has been burned. Women, infants, and toddlers all have a greater risk of death from burns than men. Excessive scarring, with either keloidlike scars or flat scars with contractures, may produce deformities and dysfunction of the joints, as well as chronic ulcerations from impairment of local circulation. Delayed postburn blistering may occur in partial-thickness wounds and skin graft donor sites. It is most common on the lower extremities and is self-limited. Although burn scars may be the site of development of carcinoma, evidence supports only the possibility of a modest excess of squamous cell carcinomas in burn scars. With modern reconstructive surgery, this unfortunate end result can be minimized.

#### Treatment

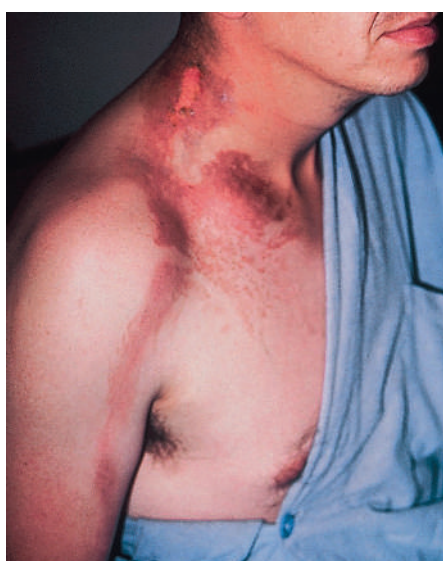Immediate first aid for minor thermal burns consists of prompt cold applications (ice water, or cold tap water if no ice is available), which are continued until pain does not return on stopping them.

The vesicles or blebs of second-degree burns should not be opened but should be protected from injury because they form a natural barrier against contamination by microorganisms. If they become tense and unduly painful, the fluid may be evacuated under strictly aseptic conditions by puncturing the wall with a sterile needle, allowing the blister to collapse onto the underlying wound. Excision of full-thickness and deep dermal wounds that will not reepithelialize within 3 weeks (as soon as hemodynamic stability is achieved, normally 2–3 days) reduces wound infections, shortens hospital stays, and improves survival. Additionally, contractures and functional impairment may be mitigated by such intervention and grafting. The role of early ablative laser treatments to prevent disabling scars and its use in improving fully formed scars is an area of active investigation. The most superficial wounds may be dressed with greasy gauze, whereas silver-containing dressings are used for their antibiotic properties in intermediate wounds.

Fluid resuscitation, treatment of inhalation injury and hypercatabolism, monitoring and early intervention of sepsis, pain control, environmental control, and nutritional support are key components of the critical care of burns. Intensive care management in a burn center is recommended for patients with partial-thickness wounds covering more than 10% of the body surface, if involving the face, hands, feet, genitalia, perineum, or joints; if secondary to electrical, chemical, or inhalation injury; in patients with special needs; and for any full-thickness burn.



**Fig. 3-1** Electrical burn from biting on a cord.



**Fig. 3-2** Lightning strike.

## Electrical burns

Electrical burns may occur from contact or as a flash exposure. A contact burn is small but deep, causing some necrosis of the underlying tissues. Low-voltage injuries usually occur in the home, are treated conservatively, and generally heal well. Oral commissure burns may require reconstructive procedures (Fig. 3-1). High-voltage burns are often occupational; internal damage may be masked by minimal surface skin change and may be complicated by subtle and slowly developing sequelae. Early surgical intervention to improve circulation and repair vital tissues is helpful in limiting loss of the extremity.

Flash burns usually cover a large area and, being similar to any surface burn, are treated as such. Lightning may cause burns after a direct strike, where an entrance and an exit wound are visible (Fig. 3-2). This is the most lethal type of strike, and cardiac arrest or other internal injuries may occur. Other types of lightning strike are indirect and result in the following burns:

- Linear burns in areas on which sweat was present
- Burns in a feathery or arborescent pattern, which is believed to be pathognomonic
- Punctate burns with multiple, deep, circular lesions

- Thermal burns from ignited clothing or heated metal, which may occur if the patient was speaking on a cell phone or listening to an iPod or similar device when struck

## Hot tar burns

Polyoxyethylene sorbitan in bacitracin zinc-neomycin-polymyxin B (e.g., Neosporin) ointment, vitamin E ointment (e.g., Webber), and sunflower oil are excellent dispersing agents that facilitate the removal of hot tar from burns.

**Cancio LC, et al:** Evolving changes in the management of burns and environmental injuries. *Surg Clin North Am* 2012; 92:959.

**Chetty BV, et al:** Blisters in patients with burns. *Arch Dermatol* 1992; 128:181.

**Compton CC:** The delayed postburn blister. *Arch Dermatol* 1992; 128:24.

**Dega S, et al:** Electrical burn injuries. *Burns* 2007; 33:653.

**Glatstein MM, et al:** Pediatric electrical burn injuries. *Pediatr Emerg Care* 2013; 29:737.

**Heffernan EJ, et al:** Thunderstorms and iPods. *N Engl J Med* 2007; 357:198.

**Kerby JD, et al:** Sex differences in mortality after burn injury. *Burn Care Res* 2006; 27:452.

**Ng K, et al:** Management of hot tar burn using vitamin E ointment containing petroleum and polyoxyethylene sorbitan. *CJEM* 2013; 15:1.

**Pham TN, Gibran NS:** Thermal and electrical injuries. *Surg Clin North Am* 2007; 87:185.

**Russell KW, et al:** Lightning burns. *J Burn Care Res* 2013; Jun 24. [Epub ahead of print.]

**Shumaker PR, et al:** Functional improvements in traumatic scars and scar contractures using an ablative fractional laser protocol. *J Trauma Acute Care Surg* 2012; 73(2 Suppl 1):S116.

**Wallingford SC, et al:** Skin cancer arising in scars: a systematic review. *Dermatol Surg* 2011; 37(9):1239.

**Wasaik J, et al:** Minor thermal burns. *Clin Evid* 2005; 14:2388.

## Miliaria

Miliaria, the retention of sweat as a result of occlusion of eccrine sweat ducts, produces an eruption that is common in hot, humid climates, such as in the tropics and during the hot summer months in temperate climates. *Staphylococcus epidermidis*, which produces an extracellular polysaccharide substance, induces miliaria in an experimental setting. This polysaccharide substance may obstruct the delivery of sweat to the skin surface. The occlusion prevents normal secretion from the sweat glands, and eventually pressure causes rupture of the sweat gland or duct at different levels. The escape of sweat into the adjacent tissue produces miliaria. Depending on the level of the injury to the sweat gland or duct, several different forms are recognized.

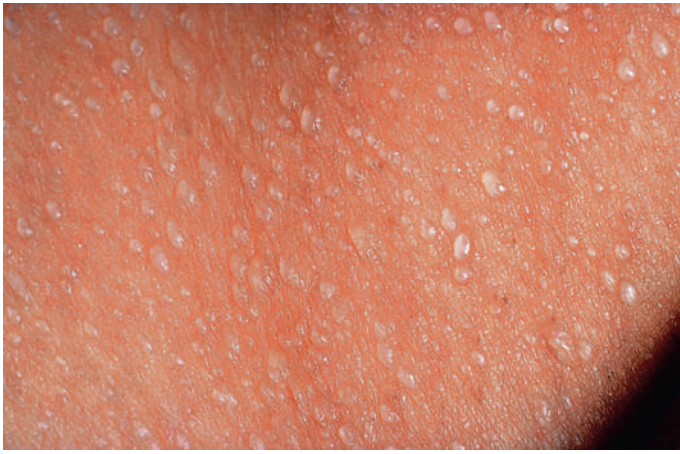### Miliaria crystallina (sudamina)

Miliaria crystallina is characterized by small, clear, superficial vesicles with no inflammatory reaction (Fig. 3-3). It appears in bedridden patients whose fever produces increased perspiration or when clothing prevents dissipation of heat and moisture, as in bundled children. The lesions are generally asymptomatic, and their duration is short-lived because they tend to rupture at the slightest trauma. Drugs such as isotretinoin, bethanechol, and doxorubicin may induce sudamina. The lesions are self-limited; no treatment is required.

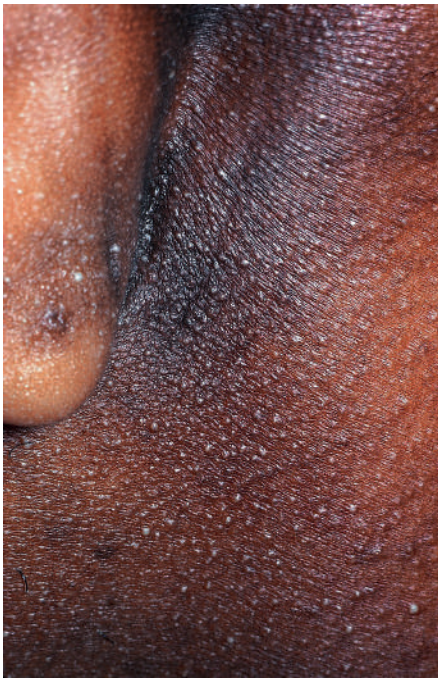
### Miliaria rubra (prickly heat)

The lesions of miliaria rubra appear as discrete, extremely pruritic, erythematous papulovesicles accompanied by a





**Fig. 3-3** Miliaria crystallina.



**Fig. 3-4** Miliaria pustulosa. (Courtesy of Curt Samlaska, MD.)

sensation of prickling, burning, or tingling. They later may become confluent on a bed of erythema. The sites most frequently affected are the antecubital and popliteal fossae, trunk, inframammary areas (especially under pendulous breasts), abdomen (especially at the waistline), and inguinal regions; these sites frequently become macerated because evaporation of moisture has been impeded. Exercise-induced itching or that of atopic dermatitis may also be caused by miliaria rubra. The site of injury and sweat escape is in the prickle cell layer, where spongiosis is produced.

### Miliaria pustulosa

Miliaria pustulosa is preceded by another dermatitis that has produced injury, destruction, or blocking of the sweat duct (Fig. 3-4). The pustules are distinct, superficial, and independent of the hair follicle. The pruritic pustules occur most frequently on the intertriginous areas, flexure surfaces of the extremities, scrotum, and back of bedridden patients. Contact dermatitis, lichen simplex chronicus, and intertrigo are some of the associated diseases, although pustular miliaria may occur several weeks after these diseases have subsided. Recurrent episodes may be a sign of type I pseudohypoaldosteronism,

because salt-losing crises may precipitate miliaria pustulosa or rubra, with resolution after stabilization.

### Miliaria profunda

Nonpruritic, flesh-colored, deep-seated, whitish papules characterize miliaria profunda. It is asymptomatic, usually lasts only 1 h after overheating has ended, and is concentrated on the trunk and extremities. Except for the face, axillae, hands, and feet, where there may be compensatory hyperhidrosis, all the sweat glands are nonfunctional. The occlusion is in the upper dermis. Miliaria profunda is observed only in the tropics and usually follows a severe bout of miliaria rubra.

### Postmiliarial hypohidrosis

Postmiliarial hypohidrosis results from occlusion of sweat ducts and pores, and it may be severe enough to impair an individual's ability to perform sustained work in a hot environment. Affected persons may show decreasing efficiency, irritability, anorexia, drowsiness, vertigo, and headache; they may wander in a daze.

It has been shown that hypohidrosis invariably follows miliaria, and that the duration and severity of the hypohidrosis are related to the severity of the miliaria. Sweating may be depressed to half the normal amount for as long as 3 weeks.

### Tropical anhidrotic asthenia

Tropical anhidrotic asthenia is a rare form of miliaria with long-lasting poral occlusion, which produces anhidrosis and heat retention.

### Treatment

The most effective treatment for miliaria is to place the patient in a cool environment. Even a single night in an air-conditioned room helps to alleviate the discomfort. Circulating air fans can also be used to cool the skin. Anhydrous lanolin resolves the occlusion of pores and may help to restore normal sweat secretions. Hydrophilic ointment also helps to dissolve keratinous plugs and facilitates the normal flow of sweat. Soothing, cooling baths containing colloidal oatmeal or cornstarch are beneficial if used in moderation. Patients with mild cases may respond to dusting powders, such as cornstarch or baby talcum powder.

**Dimon NS, et al:** Goosefleshlike lesions and hypohidrosis. *Arch Dermatol* 2007; 143:1323.

**Godkar D, et al:** Rare skin disorder complicating doxorubicin therapy: miliaria crystallina. *Am J Ther* 2005; 12:275.

**Haas N, et al:** Congenital miliaria crystallina. *J Am Acad Dermatol* 2002; 47:S270.

**Haque MS, et al:** The oldest new finding in atopic dermatitis: subclinical miliaria as an origin. *JAMA Dermatol* 2013; 149:436.

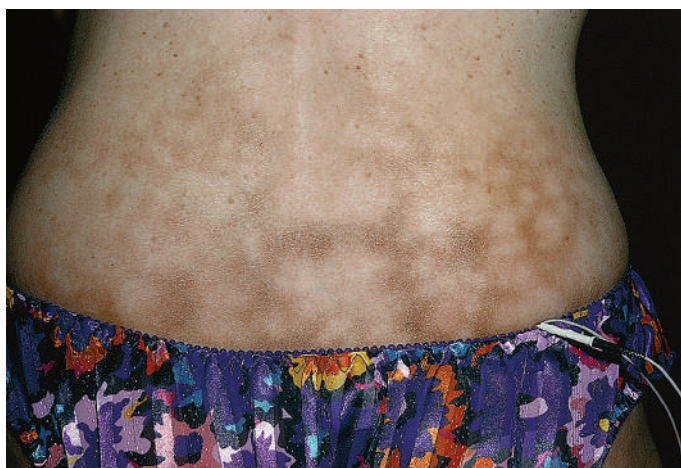**La Shell MS, et al:** Pruritus, papules, and perspiration. *Ann Allergy Immunol* 2007; 98:299.

**Mowad CM, et al:** The role of extracellular polysaccharide substance produced by *Staphylococcus epidermidis* in miliaria. *J Am Acad Dermatol* 1995; 20:713.

**Onal H, et al:** Miliaria rubra and thrombocytosis in pseudohypoaldosteronism. *Platelets* 2012; 23:645.

### Erythema ab igne

Erythema ab igne is a persistent erythema—or the coarsely reticulated residual pigmentation resulting from it—that is usually produced by long exposure to excessive heat without the production of a burn (Fig. 3-5). It begins as a mottling



**Fig. 3-5** Erythema ab igne from transcutaneous electrical nerve stimulation (TENS) unit, with device wire at lower right.

caused by local hemostasis and becomes a reticulated erythema, leaving pigmentation. Multiple colors are simultaneously present in an active patch, varying from pale pink to old rose or dark purplish brown. After the cause is removed, the affection tends to disappear gradually, but sometimes the pigmentation is permanent.

Histologically, an increased amount of elastic tissue in the dermis is noted. The changes in erythema ab igne are similar to those of actinic elastosis. Interface dermatitis and epithelial atypia may be noted.

Erythema ab igne on the legs results from habitually warming them in front of open fireplaces, space heaters, or car heaters. Similar changes may be produced on the lower back or at other sites of an electric heating pad application, on the upper thighs with laptop computers, or on the posterior thighs from heated car seats. The condition occurs also in cooks, silversmiths, and others exposed over long periods to direct moderate heat.

Epithelial atypia, which may lead to Bowen's disease and squamous cell carcinoma, has rarely been reported to occur overlying erythema ab igne. In remote areas of Kashmir, Kangri fire pots can induce erythema ab igne and cancer within the affected area. Treatment with 5-fluorouracil (5-FU), imiquimod, or photodynamic therapy may be effective in reversing this epidermal alteration.

The use of emollients containing  $\alpha$ -hydroxy acids or a cream containing fluocinolone acetonide 0.01%, hydroquinone 4%, and tretinoin 0.05% may help reduce the unsightly pigmentation, as may treatment with the Q-switched neodymium-doped yttrium-aluminum-garnet (Nd:YAG) laser.

**Brodell D, et al:** Automobile seat heater-induced erythema ab igne. *Arch Dermatol* 2012; 148(2):264–265.

**Cho S, et al:** Erythema ab igne successfully treated using 1,064-nm Q-switched neodymium-doped yttrium aluminum garnet laser with low fluence. *Dermatol Surg* 2011; 37(4):551–553.

**Huynh N, et al:** Erythema ab igne. *Cutis* 2011; 88(6):290–292.

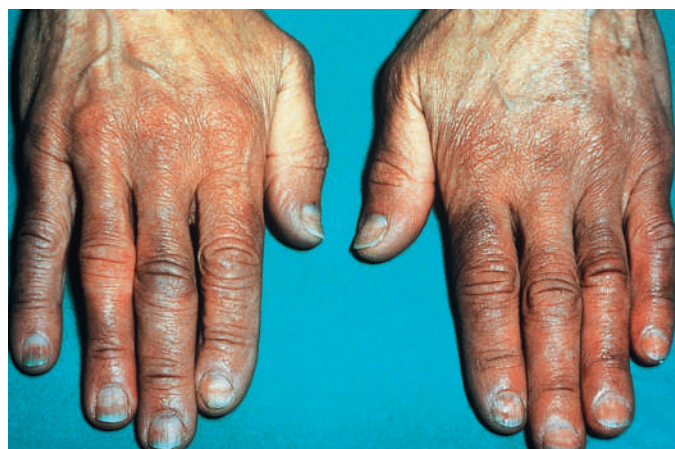**Riahi RR, et al:** Practical solutions to prevent laptop-induced erythema ab igne. *Int J Dermatol* 2014; 53:e395–396.

**Wani I:** Kangri cancer. *Surgery* 2010; 147:586–588.

**Wharton JB, et al:** Squamous cell carcinoma in situ arising in the setting of erythema ab igne. *J Drugs Dermatol* 2008; 7(5):488–489.

## COLD INJURIES

Exposure to cold damages the skin by at least three mechanisms, as follows:



**Fig. 3-6** Acrocyanosis.

- Reduced temperature directly damages the tissue, as in frostbite and cold immersion foot.
- Vasospasm of vessels perfusing the skin prevents adequate perfusion of the tissue and causes vascular injury and consequent tissue injury (pernio, acrocyanosis, and frostbite).
- In unusual circumstances, adipose tissue is predisposed to damage by cold temperatures because of fat composition or location (cold panniculitis; see Chapter 23).

Outdoor workers and recreationalists, military service members, alcoholic persons, and homeless people are particularly likely to sustain cold injuries. Maneuvers to treat orthopedic injuries or heatstroke and cooling devices for other therapeutic use may result in cold injuries ranging from acrocyanosis to frostbite.

**Jurkovich GJ:** Environmental cold-induced injury. *Surg Clin North Am* 2007; 87:247.

## Acrocyanosis

Acrocyanosis is a persistent blue discoloration of the entire hand or foot worsened by cold exposure. The hands and feet may be hyperhidrotic (Fig. 3-6). It occurs chiefly in young women. Cyanosis increases as the temperature decreases and changes to erythema with elevation of the dependent part. The cause is unknown. Smoking should be avoided. Acrocyanosis is distinguished from Raynaud syndrome by its persistent (rather than episodic) nature and lack of tissue damage (ulceration, distal fingertip resorption).

Acrocyanosis with swelling of the nose, ears, and dorsal hands may occur after inhalation of butyl nitrite. Interferon alpha-2a may induce it. Repeated injection of the dorsal hand with narcotic drugs may produce lymphedema and an appearance similar to the edematous phase of scleroderma. This so-called puffy hand syndrome may include erythema or a bluish discoloration of the digits. Patients with anorexia nervosa frequently manifest acrocyanosis as well as pernio, livedo reticularis, and acral coldness. It may improve with weight gain. Approximately one third of patients with skin findings of POEMS syndrome (polyneuropathy, organomegaly, endocrinopathy, M component, skin changes) have acrocyanosis. Also, in patients with a homozygous mutation in *SAMDH1* and cerebrovascular occlusive disease, acrocyanosis was frequent.



Acral vascular syndromes, such as gangrene, Raynaud phenomenon, and acrocyanosis, may be a sign of malignancy. In 47% of 68 reported cases, the diagnosis of cancer coincided with the onset of the acral disease. If such changes appear or worsen in an elderly patient, especially a man, without exposure to vasoconstrictive drugs or prior autoimmune or vascular disorders, a paraneoplastic origin should be suspected.

**Brown PJ, et al:** The purple digit. *Am J Clin Derm* 2010; 11:103.

**Del Giudice P, et al:** Hand edema and acrocyanosis: puffy hand syndrome. *Arch Dermatol* 2006; 142:1084.

**Kurklinsky AK, et al:** Acrocyanosis. *Vasc Med* 2011; 16(4):288–301.

**Miest RY, et al:** Cutaneous manifestations in patients with POEMS syndrome. *Int J Dermatol* 2013; 52(11):1349–1356.

**Poszepczynska-Guigné E, et al:** Paraneoplastic acral vascular syndrome. *J Am Acad Dermatol* 2002; 47(1):47–52.

**Strumia R:** Eating disorders and the skin. *Clin Dermatol* 2013; 31(1):80–85.

**Xin B, et al:** Homozygous mutation in *SAMHD1* gene causes cerebral vasculopathy and early onset stroke. *Proc Natl Acad Sci USA* 2011; 108(13):5372–5377.

### Chilblains (pernio, perniosis)

Chilblains constitute a localized erythema and swelling caused by exposure to cold. Blistering and ulcerations may develop in severe cases. In people predisposed by poor peripheral circulation, even moderate exposure to cold may produce chilblain. Cryoglobulins, cryofibrinogens, antiphospholipid antibodies, or cold agglutinins may be present and pathogenic. Chilblain-like lesions may occur in discoid and systemic lupus erythematosus (chilblain lupus), as a presenting sign of leukemia cutis, or if occurring in infancy may herald the Nakajo-Nishimura syndrome. Chilblain may also be a diagnostic sign of Aicardi-Goutières syndrome. The chronic use of crack cocaine and its attendant peripheral vasoconstriction will lead to perniosis with cold, numb hands and atrophy of the digital fat pads, especially of the thumbs and index fingers, as well as nail curvature.

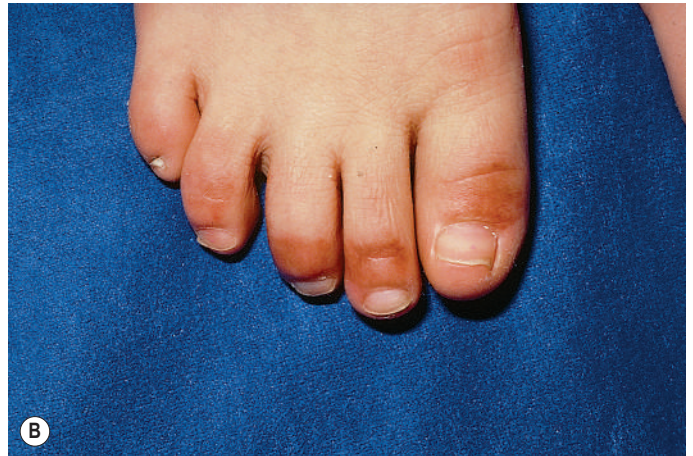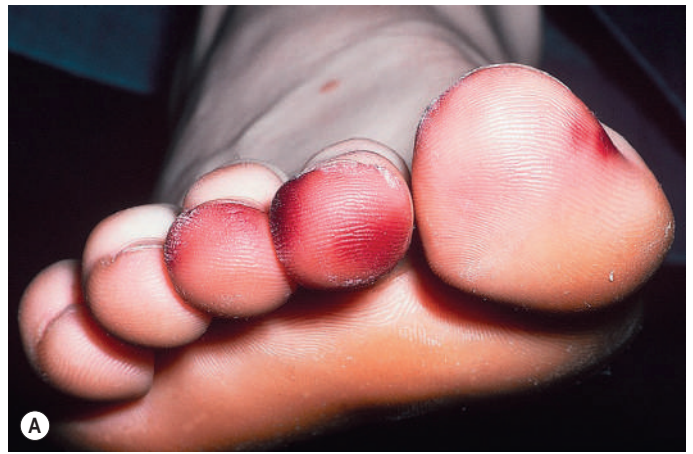Chilblains occur chiefly on the hands, feet, ears, and face, especially in children; onset is enhanced by dampness (Fig. 3-7). In Mohs surgery technicians, the hands are affected if an orthopedic cold therapy system is used; the skin under the device develops the lesions. The lateral thighs are involved in women equestrians who ride on cold, damp days and the hips in those wearing tight-fitting jeans with a low waistband. Wading across cold streams may produce similar lesions. Nondigital lesions of cold injury can be nodular.

Patients with chilblain are often unaware of the cold injury when it is occurring, but later burning, itching, and redness call it to their attention. The affected areas are bluish red, with the color partially or totally disappearing on pressure, and are cool to the touch. Sometimes the extremities are clammy because of excessive sweating. As long as the dampness and cold exposure continues, new lesions will continue to appear. Investigation into an underlying cause should be undertaken in patients with chilblains that are recurrent, chronic, extending into warm seasons, or poorly responsive to treatment.

Pernio histologically demonstrates a lymphocytic vasculitis. There is dermal edema, and a superficial and deep perivascular, tightly cuffed, lymphocytic infiltrate. The infiltrate involves the vessel walls and is accompanied by characteristic “fluffy” edema of the vessel walls.

### Treatment

The affected parts should be protected against further exposure to cold or dampness. If the feet are involved, woolen socks should be worn at all times during the cold months.



**Fig. 3-7** Chilblains (pernio) in adult (A) and child (B).

Because patients are often not conscious of the cold exposure that triggers the lesions, appropriate dress must be stressed, even if patients say they do not sense being cold. Since central cooling triggers peripheral vasoconstriction, keeping the whole body (not just the affected extremity) warm is critical. Heating pads may be used judiciously to warm the parts. Smoking is strongly discouraged.

Nifedipine, 20 mg three times a day, has been effective. Vasodilators such as nicotinamide, 500 mg three times a day, or dipyridamole, 25 mg three times a day, or the phosphodiesterase inhibitor sildenafil, 50 mg twice daily, may be used to improve circulation. Pentoxifylline and hydroxychloroquine may be effective. Spontaneous resolution occurs without treatment in 1–3 weeks. Systemic corticoid therapy is useful in chilblain lupus.

**Abdel-Salam GM, et al:** Chilblains as a diagnostic sign of Aicardi-Goutières syndrome. *Neuropediatrics* 2010; 41:18.

**Boada A, et al:** Perniosis. *Am J Dermatopathol* 2010; 32:19.

**Kanazawa N:** Nakajo-Nishimura syndrome: an antiinflammatory disorder showing pernio-like rashes and progressive partial lipodystrophy. *Allergol Int* 2012; 61:197.

**King JM, et al:** Perniosis induced by a cold-therapy system. *Arch Dermatol* 2012; 148(9):1101.

**Lutz V, et al:** Chilblains and antiphospholipid antibodies. *Br J Dermatol* 2010; 163:641.

**Mireku KA, et al:** Tender macules and papules on the toes. *JAMA Dermatol* 2014; 150:329–330.

**Payne-James JJ, et al:** Pseudosclerodermatous triad of perniosis, pulp atrophy and parrot-beaked clawing of the nails: newly recognized syndrome of chronic crack cocaine use. *J Forensic Leg Med* 2007; 14:65.

**Stewart CL, et al:** Equestrian perniosis. *Am J Dermatopathol* 2013; 35(2):237.

**Viguiet M, et al:** Clinical and histopathologic features and immunologic variables in patients with severe chilblains: a study of the relationship to lupus erythematosus. *Medicine (Baltimore)* 2001; 80:180.

**Weismann K, et al:** Pernio of the hips in young girls wearing tight-fitting jeans with a low waistband. *Acta Derm Venereol* 2006; 86:558.

**Yang X, et al:** Adult pernio and cryoglobulinemia. *J Am Acad Dermatol* 2010; 62(6):e21.

**Yang X, et al:** Successful treatment of pernio with hydroxychloroquine. *J Drugs Dermatol* 2010; 9(10):1242.

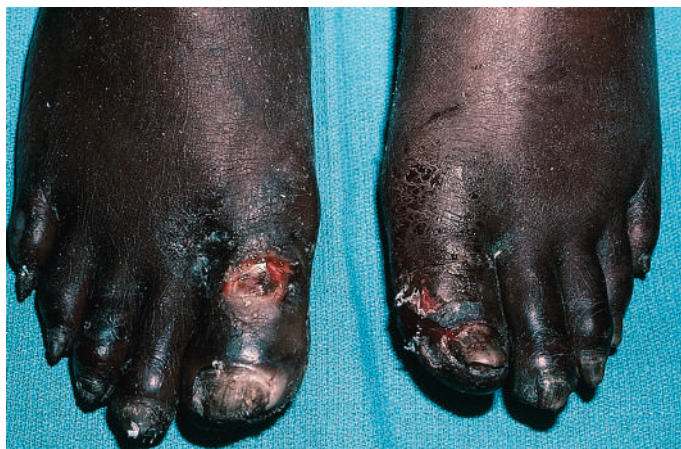## Frostbite

When soft tissue is frozen and locally deprived of blood supply, the damage is called frostbite. The ears, nose, cheeks, fingers, and toes are most often affected. The frozen part painlessly becomes pale and waxy. Various degrees of tissue destruction similar to that caused by burns are encountered. These are erythema and edema, vesicles and bullae, superficial gangrene, deep gangrene, and injury to muscles, tendons, periosteum, and nerves (Fig. 3-8). The degree of injury is directly related to the temperature and duration of freezing. African Americans are at increased risk of frostbite.

## Treatment

Early treatment of frostbite before swelling develops should consist of covering the part with clothing or with a warm hand or other body surface to maintain a slightly warm temperature so that adequate blood circulation can be maintained. Rapid rewarming in a water bath between 37 and 43°C (100–110°F) is the treatment of choice for all forms of frostbite. Rewarming should be delayed until the patient has been removed to an area where there is no risk of refreezing. Slow thawing results in more extensive tissue damage. Analgesics should be administered because of the considerable pain experienced with rapid thawing. When the skin flushes and is pliable, thawing is complete. The use of tissue plasminogen activator to lyse thrombi decreases the need for amputation if given within 24 h of injury. Supportive measures such as bed rest, a high-protein/high-calorie diet, wound care, and avoidance of trauma are imperative. Any rubbing of the affected part should be avoided, but gentle massage of proximal portions of the extremity that are not numb may be helpful.

The use of anticoagulants to prevent thrombosis and gangrene during the recovery period has been advocated. Pentoxifylline, ibuprofen, and aspirin may be useful adjuncts. Antibiotics should be given as a prophylactic measure against



**Fig. 3-8** Frostbite in a homeless person.

infection, and tetanus immunization should be updated. Recovery may take many months. Injuries that affect the proximal phalanx or the carpal or tarsal area, especially when accompanied by a lack of radiotracer uptake on bone scan, have a high likelihood of requiring amputation. Whereas prior cold injury is a major risk factor for recurrent disease, sympathectomy may be preventive against repeated episodes. Arthritis may be a late complication.

**Hallam M-J, et al:** Managing frostbite. *BMJ* 2010; 341:1151.

**Kahn JE, et al:** Frostbite arthritis. *Ann Rheum Dis* 2005; 64:966.

**McIntosh SE, et al:** Wilderness Medical Society Practice Guidelines for the prevention and treatment of frostbite. *Wilderness Environ Med* 2011; 22:156.

**Tropy JM, et al:** Frostbite. *JAMA* 2011; 306:2633.

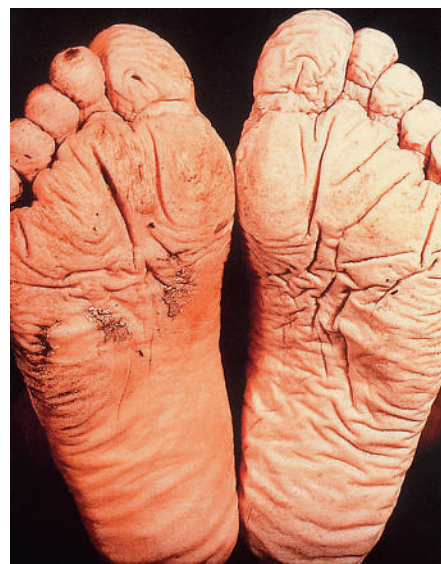
## Immersion foot syndromes

### Trench foot

Trench foot results from prolonged exposure to cold, wet conditions without immersion or actual freezing. The term is derived from trench warfare in World War I, when soldiers stood, sometimes for hours, in trenches with a few inches of cold water in them. Fishermen, sailors, and shipwreck survivors may be seen with this condition. The lack of circulation produces edema, paresthesias, and damage to the blood vessels. Similar findings may complicate the overuse of ice, cold water, and fans by patients trying to relieve the pain associated with erythromelalgia. Gangrene may occur in severe cases. Treatment consists of removal from the causal environment, bed rest, and restoration of the circulation. Other measures, such as those used in the treatment of frostbite, should be employed.

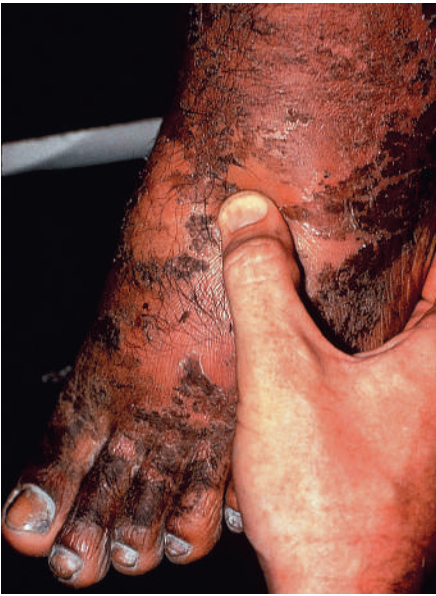### Warm water immersion foot

Exposure of the feet to warm, wet conditions for 48 h or more may produce a syndrome characterized by maceration, blanching, and wrinkling of the soles and sides of the feet (Fig. 3-9). Itching and burning with swelling may persist for a few days after removal of the cause, but disability is temporary. This condition was often seen in military service members in Vietnam but has also been seen in persons wearing insulated boots.



**Fig. 3-9** Warm water immersion foot. (Courtesy of James WD (ed): *Textbook of Military Medicine*, Office of the Surgeon General, United States Army, 1994.)





**Fig. 3-10** Tropical immersion foot. (Courtesy of James WD (ed): Textbook of Military Medicine, Office of the Surgeon General, United States Army, 1994.)

Warm water immersion foot should be differentiated from tropical immersion foot, seen after continuous immersion of the feet in water or mud at temperatures above 22°C (71.6°F) for 2–10 days. This was known as “paddy foot” in Vietnam. It involves erythema, edema, and pain of the dorsal feet, as well as fever and adenopathy (Fig. 3-10). Resolution occurs 3–7 days after the feet have been dried.

Warm water immersion foot can be prevented by allowing the feet to dry for a few hours in every 24 or by greasing the soles with a silicone grease once a day. Recovery is usually rapid if the feet are thoroughly dry for a few hours.

**Adnot J, et al:** Immersion foot syndromes. In: James WD (ed): Military Dermatology. Washington, DC: Office of the Surgeon General, 1994.

**Davis MD:** Immersion foot associated with the overuse of ice, cold water, and fans. *J Am Acad Dermatol* 2013; 69:169.

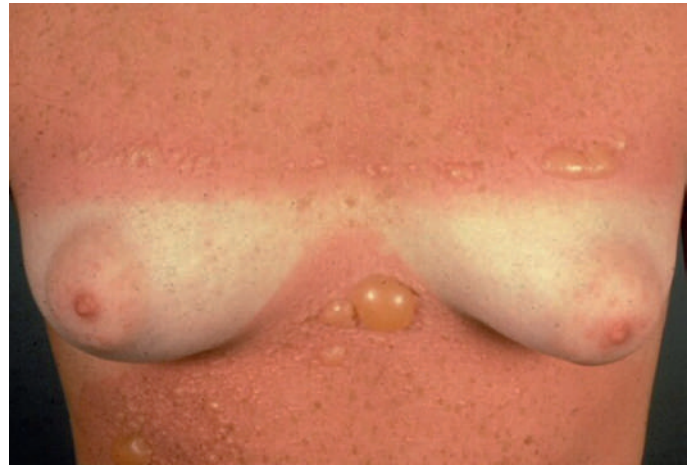**Wrenn K:** Immersion foot. *Arch Intern Med* 1991; 151:785.

## ACTINIC INJURY

### Sunburn and solar erythema

The solar spectrum has been divided into different regions by wavelength. The parts of the solar spectrum important in photomedicine include UV radiation (below 400 nm), visible light (400–760 nm), and infrared radiation (beyond 760 nm). Visible light has limited biologic activity, except for stimulating the retina. Infrared radiation is experienced as radiant heat. Below 400 nm is the UV spectrum, divided into three bands: UVA, 320–400 nm; UVB, 280–320 nm; and UVC, 200–280 nm. UVA is divided into two subcategories: UVA I (340–400 nm) and UVA II (320–340 nm). Virtually no UVC reaches the Earth’s surface because it is absorbed by the ozone layer above the Earth.

The minimal amount of a particular wavelength of light capable of inducing erythema on an individual’s skin is called the minimal erythema dose (MED). Although the amount of UVA radiation is 100 times greater than UVB radiation during midday hours, UVB is up to 1000 times more erythemogenic than UVA, and so essentially all solar erythema is caused by UVB. The most biologically effective wavelength of radiation from the sun for sunburn is 308 nm. Although it does not play a significant role in solar erythema, UVA is of major importance in patients with drug-induced photosensitivity.



**Fig. 3-11** Acute sunburn. (Courtesy of Dr. L. Lieblich.)

The amount of UV exposure increases at higher altitudes, is substantially larger in temperate climates in the summer months, and is greater in tropical regions. UVA may be reflected somewhat more than UVB from sand, snow, and ice. Whereas sand and snow reflect as much as 85% of the UVB, water allows 80% of the UV to penetrate up to 3 feet. Cloud cover, although blocking substantial amounts of visible light, is a poor UV absorber. During the middle 4–6 h of the day, the intensity of UVB is two to four times greater than in the early morning and late afternoon.

### Clinical signs and symptoms

Sunburn is the normal cutaneous reaction to sunlight in excess of an erythema dose. UVB erythema becomes evident at around 6 h after exposure and peaks at 12–24 h, but the onset is sooner and the severity greater with increased exposure. The erythema is followed by tenderness and in severe cases, blistering, which may become confluent (Fig. 3-11). Discomfort may be severe; edema typically occurs in the extremities and face; chills, fever, nausea, tachycardia, and hypotension may be present. In severe cases, such symptoms may last for as long as a week. Desquamation is common about 1 week after sunburn, even in areas that have not blistered.

After UV exposure, skin pigment undergoes two changes: immediate pigment darkening (IPD, Meirowsky phenomenon) and delayed melanogenesis. IPD is maximal within hours after sun exposure and results from metabolic changes and redistribution of the melanin already in the skin. It occurs after exposure to long-wave UVB, UVA, and visible light. With large doses of UVA, the initial darkening is prolonged and may blend into the delayed melanogenesis. IPD is not photoprotective. Delayed tanning is induced by the same wavelengths of UVB that induce erythema, begins 2–3 days after exposure, and lasts 10–14 days. Delayed melanogenesis by UVB is mediated through the production of DNA damage and the formation of cyclobutane pyrimidine dimers (CPD). Therefore, although UVB-induced delayed tanning does provide some protection from further solar injury, it is at the expense of damage to the epidermis and dermis. Tanning is not recommended for sun protection. Commercial tanning bed-induced tanning, while increasing skin pigment, does not increase UVB MED and is therefore not protective for UVB damage. Such tanning devices have been shown to cause melanoma, and their use for tanning purposes should be banned. An individual’s inherent baseline pigmentation, ability to tan, and susceptibility to burns are described as the person’s “skin type.” Skin type is used to determine starting

**Table 3-1** Skin types (phototypes)

Skin type	Baseline skin color	Sunburn and tanning history
I	White	Always burns, never tans
II	White	Always burns, tans minimally
III	White	Burns moderately, tans gradually
IV	Olive	Minimal burning, tans well
V	Brown	Rarely burns, tans darkly
VI	Dark brown	Never burns, tans darkly black

doses of phototherapy and sunscreen recommendations and reflects the risk of development of skin cancer and photoaging (Table 3-1).

Exposure to UVB and UVA causes an increase in the thickness of the epidermis, especially the stratum corneum. This increased epidermal thickness leads to increased tolerance to further solar radiation. Patients with vitiligo may increase their UV exposure without burning by this mechanism.

## Treatment

Once redness and other symptoms are present, treatment of sunburn has limited efficacy. The damage is done, and the inflammatory cascades are triggered. Prostaglandins, especially of the E series, are important mediators. Aspirin (acetylsalicylic acid, ASA) and nonsteroidal anti-inflammatory drugs (NSAIDs), including indomethacin, have been studied, as well as topical and systemic steroids. Medium-potency (class II) topical steroids applied 6 h after the exposure (when erythema first appears) provide a small reduction in signs and symptoms. Oral NSAIDs and systemic steroids have been tested primarily before or immediately after sun exposure, so there is insufficient evidence to recommend their routine use, except immediately after solar overexposure. Therefore, treatment of sunburn should be supportive, with pain management (using acetaminophen, ASA, or NSAIDs), plus soothing topical emollients or corticosteroid lotions. In general, a sunburn victim experiences at least 1 or 2 days of discomfort and even pain before much relief occurs.

## Prophylaxis

Sunburn is best prevented. Use of the UV index facilitates taking adequate precautions to prevent solar injury. Numerous educational programs have been developed to make the public aware of the hazards of sun exposure. Despite this, sunburn and excessive sun exposure continue to occur in the United States and Western Europe, especially in white persons under age 30, more than 50% of whom report at least one sunburn per year. Sun protection programs have the following four main messages:

- Avoid midday sun.
- Seek shade.
- Wear sun-protective clothing.
- Apply a sunscreen.

The period of highest UVB intensity, between 9 AM and 3–4 PM, accounts for the vast majority of potentially hazardous

UV exposure. This is the time when the angle of the sun is less than 45 degrees, or when a person's shadow is shorter than his or her height. In temperate latitudes, it is almost impossible to burn if these hours of sun exposure are avoided. Trees and artificial shade provide substantial protection from UVB. Foliage in trees provides the equivalent of sun protection factor (SPF) 4–50, depending on the density of the greenery. Clothing can be rated by its ability to block UVB radiation. The scale of measure is the UV protection factor (UPF), analogous to SPF in sunscreens. Although it is an *in vitro* measurement, as with SPF, UPF correlates well with the actual protection the product provides *in vivo*. In general, denser weaves, washed older clothing, and loose-fitting clothes screen UVB more effectively. Wetting a fabric may substantially reduce its UPF. Laundering a fabric in a Tinosorb-containing material (SunGuard) will add substantially to the UPF of the fabric. Hats with at least a 4-inch brim all around are recommended.

A sunscreen's efficacy in blocking the UVB (sunburn-inducing) radiation is expressed as an SPF. This is the ratio of the number of MEDs of radiation required to induce erythema through a film of sunscreen (2 mg/cm<sup>2</sup>) compared with unprotected skin. Most persons apply sunscreens in too thin a film, so the actual "applied SPF" is about half that on the label. Sunscreen agents include UV-absorbing chemicals (chemical sunscreens) and UV-scattering or blocking agents (physical sunscreens). Available sunscreens, especially those of high SPFs (>30), usually contain both chemical sunscreens (e.g., *p*-aminobenzoic acid [PABA], PABA esters, cinnamates, salicylates, anthranilates, benzophenones, benzylidene camphors such as ecamsule [Mexoryl], dibenzoylmethanes [Parsol 1789, in some products present as multicomponent technology Helioplex], and Tinosorb [S/M]) and physical agents (zinc oxide or titanium dioxide). Sunscreens are available in numerous formulations, including sprays, gels, emollient creams, and wax sticks. Sunscreens may be water resistant, with some maintaining their SPF after 40 min of water immersion and others maintaining their SPF after 80 min of water immersion.

For skin types I–III (see Table 3-1), daily application of a broad-spectrum sunscreen with an SPF of 30 in a facial moisturizer, foundation, or aftershave is recommended. For outdoor exposure, a sunscreen of SPF 30 or higher is recommended for regular use. In persons with severe photosensitivity and at times of high sun exposure, high-intensity sunscreens of SPF 30+ with inorganic blocking agents may be required. Application of the sunscreen at least 20 min before and 30 min after sun exposure has begun is recommended. This dual-application approach will reduce the amount of skin exposure by twofold to threefold over a single application. Sunscreen should be reapplied after swimming or vigorous activity or toweling. Sunscreen failure occurs mostly in men, from failure to apply it to all the sun-exposed skin or failure to reapply sunscreen after swimming. Sunscreens may be applied to babies (under 6 months) on limited areas. Vitamin D supplementation is recommended with the most stringent sun protection practices. The dose is 600 IU daily for those 70 and younger and 800 IU for older patients.

Photoaging and cutaneous immunosuppression are mediated by UVA as well as UVB. For this reason, sunscreens with improved UVA coverage have been developed. Those containing excellent protection for both UVB and UVA are identified on the label by the words "broad spectrum," and these sunscreens should be sought by patients.

**Bens G:** Sunscreens. *Adv Exp Med Biol* 2014; 810:429–463.

**Butler DB, et al:** Prevalence of sunburn, sun protection, and indoor tanning behaviors among Americans. *J Am Acad Dermatol* 2011; 65:S114.e1–e11.



**Diffey B:** Sunscreens. *Photodermatol Photoimmunol Photomed* 2009; 25:233–236.

**Faurschau A, et al:** Topical corticosteroids in the treatment of acute sunburn. *Arch Dermatol* 2008; 144:620.

**Fisher DE, et al:** Indoor tanning: science, behavior, and policy. *N Engl J Med* 2010; 363(10):901–903.

**Gonzalez S, et al:** Photoprotection. *G Ital Dermatol Venereol* 2010; 145:515–523.

**Lim HW, et al:** Adverse effects of ultraviolet radiation from the use of indoor tanning equipment: time to ban the tan. *J Am Acad Dermatol* 2011; 64(5):893–902.

**Medeiros VL, et al:** Sunscreens in the management of photodermatoses. *Skin Therapy Lett* 2010; 15:1.

**Malbasa C, et al:** Photoprotection with clothing and sunscreens. *G Ital Dermatol Venereol* 2010; 145:509–514.

**Polefka PG, et al:** Effects of solar radiation on the skin. *J Cosmet Dermatol* 2012; 11:134–143.

**Vanchinathan V, et al:** A dermatologist's perspective on vitamin D. *Mayo Clin Proc* 2012; 87:372–380.

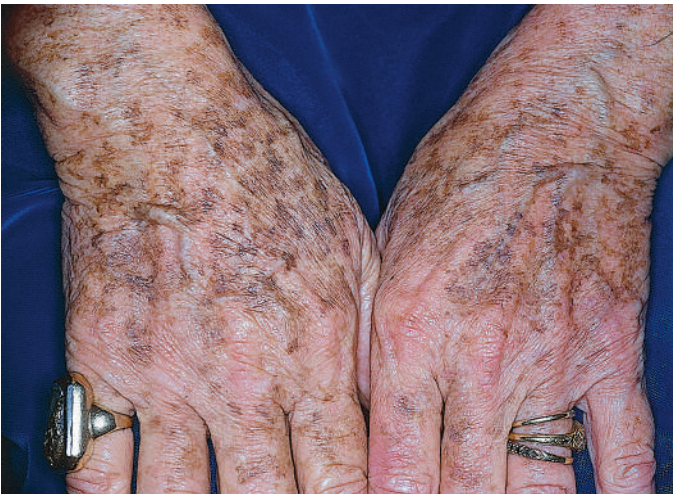### Ephelis (freckle) and lentigo

Freckles are small (<0.5 cm) brown macules that occur in profusion on the sun-exposed skin of the face, neck, shoulders, and backs of the hands. They become prominent during the summer when exposed to sunlight and subside, sometimes completely, during the winter when there is no exposure. Blondes and redheads with blue eyes and of Celtic origin (skin types I or II) are especially susceptible. Ephelides may be genetically determined and may recur in successive generations in similar locations and patterns. They usually appear at about age 5 years.

Ephelis must be differentiated from lentigo simplex. The lentigo is a benign, discrete hyperpigmented macule appearing at any age and on any part of the body, including the mucosa. The intensity of the color is not dependent on sun exposure. The solar lentigo appears at a later age, mostly in persons with long-term sun exposure. The backs of the hands and face (especially the forehead) are favored sites (Fig. 3-12).

Histologically, the ephelis shows increased production of melanin pigment by a normal number of melanocytes. Otherwise, the epidermis is normal, whereas the lentigo has elongated rete ridges that appear to be club shaped.

Freckles and solar lentigines are best prevented by appropriate sun protection. Cryotherapy, topical retinoids, hydroquinone, intense pulse light, undecylenoyl phenylalanine, and lasers are effective in the treatment of solar lentigines.



**Fig. 3-12** Solar lentigines.

**Hafner C, et al:** The absence of *BRAF*, *FGFR3*, and *PIK3CA* mutations differentiates lentigo simplex from melanocytic nevus and solar lentigo. *J Invest Dermatol* 2009; 129(11):2730–2735.

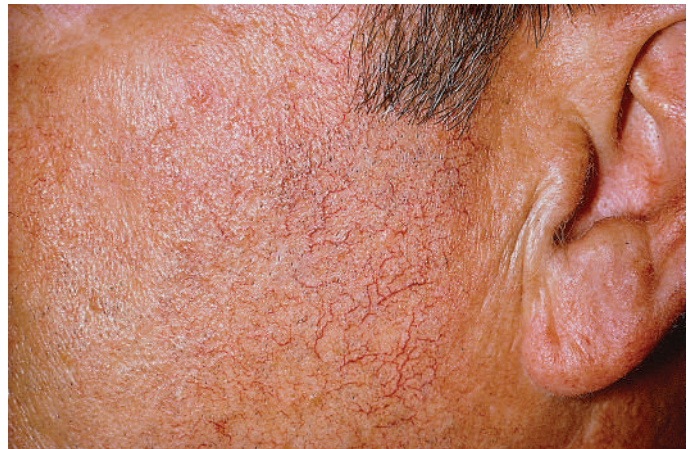**Katoulis AC, et al:** A randomized, double-blind, vehicle-controlled study of a preparation containing undecylenoyl phenylalanine 2% in the treatment of solar lentigines. *Clin Exp Dermatol* 2010; 35(5):473–476.

### Photoaging (dermatoheliosis)

The characteristic changes induced by chronic sun exposure are called photoaging or dermatoheliosis. An individual's risk for developing these changes correlates with the person's skin type (see Table 3-1). Risk for melanoma and nonmelanoma skin cancer is also related to skin type. The persons most susceptible to the deleterious effects of sunlight are those of skin type I: blue-eyed, fair-complexioned persons who do not tan. They are frequently of Irish or other Celtic or Anglo-Saxon descent. Individuals who develop photoaging have the genetic susceptibility and have had sufficient actinic damage to develop skin cancer, and they therefore require more frequent and careful cutaneous examinations.

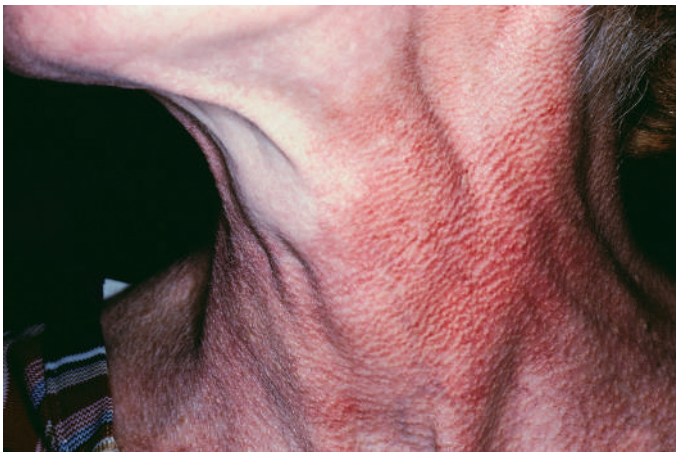
Chronic sun exposure and chronologic aging are additive. Cigarette smoking is also important in the development of wrinkles, resulting in the inability of observers to distinguish solar-induced from smoking-induced skin aging accurately. The areas primarily affected by photoaging are those regularly exposed to the sun: the V area of the neck and chest, back and sides of the neck, face, backs of the hands and extensor arms, and in women the skin between the knees and ankles. The skin becomes atrophic, scaly, wrinkled, inelastic, or leathery with a yellow hue (milian citrine skin). In some persons of Celtic ancestry, dermatoheliosis produces profound epidermal atrophy without wrinkling, resulting in an almost translucent appearance of the skin through which hyperplastic sebaceous glands and prominent telangiectasias are seen (Fig. 3-13). These persons are at high risk for nonmelanoma skin cancer. Pigmentation is uneven, with a mixture of poorly demarcated, hyperpigmented and white atrophic macules observed. The photodamaged skin appears generally darker because of these irregularities of pigmentation; in addition, dermal hemosiderosis occurs from actinic purpura. Solar lentigines occur on the face and dorsa of the hands.

Many of the textural and tinctorial changes in sun-damaged skin are caused by alterations in the upper dermal elastic tissue and collagen. This process is called solar (actinic) elastosis, which imparts a yellow color to the skin. Many clinical variants of solar elastosis have been described, and an affected individual may simultaneously have many of these changes.

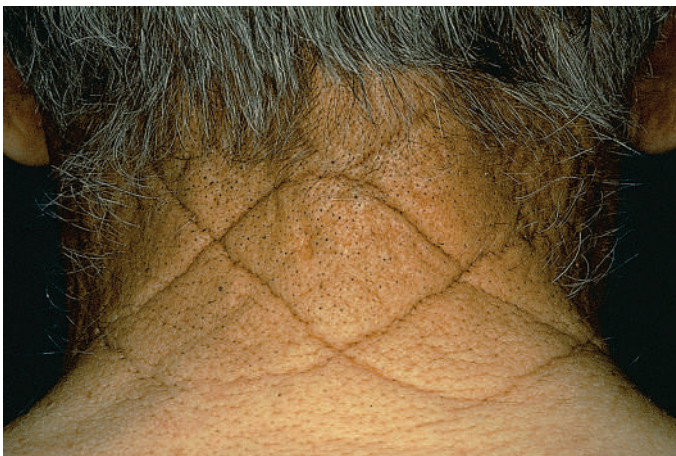

**Fig. 3-13** Dermatoheliosis.





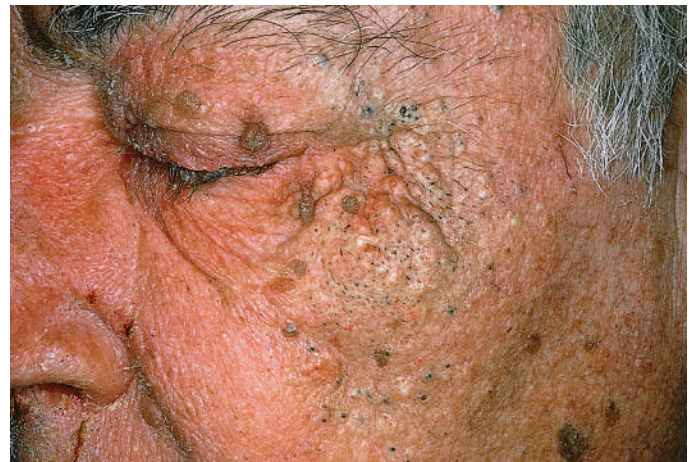**Fig. 3-14** Poikiloderma of Civatte.



**Fig. 3-15** Cutis rhomboidalis nuchae.

Small yellowish papules and plaques may develop along the sides of the neck. They have been variably named “striated beaded lines” (the result of sebaceous hyperplasia) or “fibro-elastic papulosis” of the neck, which is caused by solar elastosis. At times, usually on the face or chest, this elastosis may form a macroscopic, translucent papule with a pearly color that may closely resemble a basal cell carcinoma (actinic elastotic plaque). Similar plaques may occur on the helix or antihelix of the ear (elastotic nodules of the ear). Poikiloderma of Civatte refers to reticulate hyperpigmentation with telangiectasia, and slight atrophy of the sides of the neck, lower anterior neck, and V of the chest. The submental area, shaded by the chin, is spared (Fig. 3-14). Poikiloderma of Civatte frequently presents in fair-skinned men and women in their mid to late thirties or early forties. Cutis rhomboidalis nuchae (sailor’s or farmer’s neck) is characteristic of long-term, chronic sun exposure (Fig. 3-15). The skin on the back of the neck becomes thickened, tough, and leathery, and the normal skin markings are exaggerated. Nodular elastoidosis with cysts and comedones occurs on the inferior periorbital and malar skin (Favre-Racouchot syndrome) (Fig. 3-16) on the forearms (actinic comedonal plaque) or helix of the ear. These lesions appear as thickened yellow plaques studded with comedones and keratinous cysts. The ears may exhibit one or more firm nodules on the helix, known as weathering nodules. Biopsy reveals fibrosis and cartilage metaplasia.

Telangiectasias over the cheeks, ears, and sides of the neck may develop. Because of the damage to the connective tissue of the dermis, skin fragility is prominent, and patients note skin tearing from trivial injuries. This is known as



**Fig. 3-16** Favre-Racouchot syndrome (nodular elastoidosis with cysts and comedones).

dermatoporosis. Most frequently, patients complain that even minimal trauma to their extensor arms leads to an ecchymosis, a phenomenon called actinic purpura. As the ecchymoses resolve, dusky brown macules remain for months, increasing the mottled appearance of the skin. Deep dissecting hematomas may result as well, causing large areas of necrosis. Again, minor trauma may lead to a painful deep bruise or simply erythema, without fever. This severe complication of dermatoporosis occurs primarily on the legs of elderly women, many of whom are taking anticoagulants or systemic steroids. White stellate pseudoscars on the forearms are a frequent complication of this enhanced skin fragility. In some patients, soft, flesh-colored to yellow papules and nodules coalesce on the forearms to form a cordlike band extending from the dorsal to the flexural surfaces (solar elastotic bands).

Both UVB and UVA radiation induce reactive oxygen species (ROS) and hydrogen peroxide. Acting through activator protein 1 (AP-1), transcription of various matrix-degrading enzymes is upregulated, specifically matrix metalloproteinase 1 (MMP-1; collagenase), MMP-3 (stromelysin 1), and MMP-9 (gelatinase). In darkly pigmented persons, UV exposure does not activate MMP-1, in part explaining the protective effect of skin pigmentation against photoaging. In chronologically aged skin, MMP-1 levels are also increased through AP-1. Thus, chronologic aging and photoaging may be mediated through an identical biochemical mechanism.

Histologically, chronically sun-exposed skin demonstrates homogenization and a faint blue color of the connective tissue of the upper reticular dermis, so-called solar elastosis. This “elastotic” material is derived largely from elastic fibers, stains with histochemical stains for elastic fibers, and demonstrates marked increased deposition of fibulin 2 and its breakdown products. Types I and III collagen are decreased. Characteristically, there is a zone of normal connective tissue immediately below the epidermis and above the elastotic material.

### Colloid milium

There are two forms of colloid milium: adult and juvenile. In both the adult and the juvenile form of colloid milium, the primary skin lesion is a translucent, flesh colored or slightly yellow, 1–5 mm papule. Minimal trauma may lead to purpura from vascular fragility. Histologically, the colloid consists of intradermal, amorphous fissured eosinophilic material. In adult colloid milium, lesions appear in the sun-exposed areas of the hands, face, neck, forearms, and ears in middle-age and older adults, usually men. Lesions often coalesce into plaques and may rarely be verrucous. Petrochemical exposures have



been associated with adult colloid milium. Pigmented forms of colloid milium are associated with hydroquinone use. Lesions have been induced by tanning bed exposure, and they can be unilateral, usually in commercial drivers. Adult colloid milium may be considered a papular variant of solar elastosis. The colloid material is derived from elastic fibers, and solar elastosis is found adjacent to the areas of colloid degeneration histologically.

Juvenile colloid milium is much rarer. It develops before puberty, and there may be a family history. The lesions are similar to the adult form but appear initially on the face, later extending to the neck and hands. Sun exposure also appears to be important in inducing lesions of juvenile colloid milium. Juvenile colloid milium, ligenous conjunctivitis, and ligenous periodontitis may appear in the same patient and are probably of similar pathogenesis. Histologically, juvenile colloid milium can be distinguished from adult colloid milium by the finding of keratinocyte apoptosis in the overlying epidermis. The colloid material in juvenile colloid milium is derived from the apoptotic keratinocytes and stains for cytokeratin.

Treatment with fractional photothermolysis or MAL-photodynamic therapy may be effective for colloid milium.

## Prevention and treatment

Because both UVB and UVA are capable of inducing the tissue-destructive biochemical pathways implicated in photoaging, sun protection against both portions of the UV spectrum is the primary prevention required against photoaging. Because photoaging, as with other forms of radiation damage, appears to be cumulative, reducing the total lifetime UV exposure is the goal. The guidelines previously outlined for sunburn prophylaxis should be followed.

The regular use of emollients or moisturizing creams on the areas of sun damage will reduce scaling and may improve fragility by making the skin more pliable.  $\alpha$ -Hydroxy acids may improve skin texture when used in lower, nonirritating concentrations. Topical tretinoin, adapalene, and tazarotene can improve the changes of photoaging. Changes are slow and irritation may occur. Chemical peels, resurfacing techniques, laser and other light technologies (for vascular alterations, pigmented lesions, and dermal alterations), botulinum toxins, and soft tissue augmentation are all used to treat the consequences of photoaging. The surgical and laser treatments of photoaging are discussed in Chapter 38.

**Antoniou C, et al:** Photoaging. *Am J Clin Dermatol* 2010; 11:95–102.

**Balus L, et al:** Fibroelastolytic papulosis of the neck: a report of 20 cases. *Br J Dermatol* 1997; 137:461.

**Calderone DC, Fenske NA:** The clinical spectrum of actinic elastosis. *J Am Acad Dermatol* 1995; 32:1016.

**Chung HT, et al:** Firm papules on the auricular helix. *JAMA Dermatol* 2013; 149(4):475–480.

**Desai C, et al:** Colloid milium. *Arch Dermatol* 2006; 142:784.

**Gambichler T, et al:** Cerebriform elastoma: an unusual presentation of actinic elastosis. *J Am Acad Dermatol* 2005; 52:1106.

**Hughes MC, et al:** Sunscreen and prevention of skin aging. *Ann Intern Med* 2013; 158(11):781–790.

**Katoulis AC, et al:** Poikiloderma of Civatte. *Dermatology* 2007; 214:177.

**Kaya G, et al:** Deep dissecting hematoma: an emerging severe complication of dermatoporosis. *Arch Dermatol* 2008; 144(10):1303–1308.

**Kwitken J:** Papular elastosis. *Cutis* 2000; 66:81.

**Marra DE, et al:** Fractional photothermolysis for the treatment of adult colloid milium. *Arch Dermatol* 2007; 143:572.

**Martorell-Calatayud A, et al:** Familial juvenile colloid milium. *J Am Acad Dermatol* 2011; 64(1):203–206.

**Mehregan D, et al:** Adult colloid milium. *Int J Dermatol* 2011; 50:1531–1534.

**Mukherjee S, et al:** Retinoids in the treatment of skin aging. *Clin Interv Aging* 2006; 1:327.

**Rabe JH, et al:** Photoaging: mechanisms and repair. *J Am Acad Dermatol* 2006; 55:1.

**Tierney E, et al:** Photodynamic therapy for the treatment of cutaneous neoplasia, inflammatory disorders, and photoaging. *Dermatol Surg* 2009; 35(5):725–746.

**Tierney E, et al:** Treatment of poikiloderma of Civatte with ablative fractional laser resurfacing. *J Drugs Dermatol* 2009; 8(6):527–534.

**Tierney E, et al:** Recent advances in combination treatments for photoaging. *Dermatol Surg* 2010; 36:829–840.

**Tierney EP, et al:** Fractionated carbon dioxide laser treatment of photoaging. *Dermatol Surg* 2011; 37(9):1279–90.

**Wang B:** Photoaging. *J Cutan Med Surg* 2012; 15(1):374–377.

## PHOTOSENSITIVITY

Photosensitivity disorders include cutaneous reactions that are chemically induced (from an exogenous source), metabolic (inborn errors such as the porphyrias, resulting in production of endogenous photosensitizers), idiopathic, and light exacerbated (genetic and acquired). Phototoxicity and the idiopathic disorders are discussed here; the other conditions are covered in later chapters.

### Chemically induced photosensitivity

A number of substances known as photosensitizers may induce an abnormal reaction in skin exposed to sunlight or its equivalent. The result may be a greatly increased sunburn response without allergic sensitization called phototoxicity. Phototoxicity may occur from both externally applied (phytophotodermatitis and berloque dermatitis) and internally administered chemicals (phototoxic drug reaction). In contrast, photoallergic reactions are true allergic sensitizations triggered by sunlight, produced either by internal administration (photoallergic drug reaction) or by external contact (photoallergic contact dermatitis). Chemicals capable of inducing phototoxic reactions may also produce photoallergic reactions.

In the case of external contactants, the distinction between phototoxicity and photoallergy is usually straightforward. Phototoxicity occurs on initial exposure, has an onset of less than 48 h, occurs in the vast majority of persons exposed to the phototoxic substance and sunlight, and shows a histologic pattern similar to sunburn. By contrast, photoallergy occurs only in sensitized persons, may have a delayed onset (up to 14 days, the period of initial sensitization), and shows histologic features of allergic contact dermatitis.

### Action spectrum

Chemicals known to cause photosensitivity (photosensitizers) are usually resonating compounds with a molecular weight of less than 500 daltons. Absorption of radiant energy (sunlight) by the photosensitizer produces an excited state; returning to a lower-energy state gives off energy through fluorescence, phosphorescence, charge transfer, heat, or formation of free radicals. Each photosensitizing substance absorbs only specific wavelengths of light, called its absorption spectrum. The specific wavelengths of light that evoke a photosensitive reaction are called the action spectrum. The action spectrum is included in the absorption spectrum of the photosensitizing chemical. The action spectrum that produces phototoxicity is mostly in the long ultraviolet (UVA) region and may extend into the visible light region (320–425 nm).

Photosensitivity reactions occur only when there is sufficient concentration of the photosensitizer in the skin, and when the skin is exposed to a sufficient intensity and duration of light

in the action spectrum of that photosensitizer. The intensity of the photosensitivity reaction is generally dose-dependent and is worse with a greater dose of photosensitizer and greater light exposure.

## Phototoxic reactions

A phototoxic reaction is a nonimmunologic reaction that develops after exposure to a specific wavelength and intensity of light in the presence of a photosensitizing substance. It is a sunburn-type reaction, with erythema, tenderness, and even blistering occurring only on the sun-exposed parts. This type of reaction can be elicited in many persons who have no previous history of exposure or sensitivity to that particular substance, but individual susceptibility varies widely. In general, to elicit a phototoxic reaction, a considerably greater amount of the photosensitizing substance is necessary than that needed to induce a photoallergic reaction. The erythema begins, as with any sunburn, within 2–6 h but worsens for 48–96 h before beginning to subside. Exposure of the nail bed may lead to onycholysis, called photo-onycholysis (Fig. 3-17). Phototoxic reactions, especially from topically applied photosensitizers, may cause marked hyperpigmentation, even without significant preceding erythema.

### Phototoxic tar dermatitis

Coal tar, creosote, crude coal tar, or pitch, in conjunction with sunlight exposure, may induce a sunburn reaction associated with a severe burning sensation. These volatile hydrocarbons may be airborne, so the patient may give no history of touching tar products. The burning and erythema may continue for 1–3 days. Although up to 70% of white persons exposed to such a combination develop this reaction, persons with type V or VI skin are protected by their constitutive skin pigmentation. After the acute reaction, hyperpigmentation occurs, which may persist for years. Coal tar or its derivatives may be found in cosmetics, drugs, dyes, insecticides, and disinfectants.

### Phytophotodermatitis

Furocoumarins in many plants may cause a phototoxic reaction when they come in contact with skin that is exposed to UVA light. This is called phytophotodermatitis. Several hours after exposure, a burning erythema occurs, followed by edema and the development of vesicles or bullae. An intense residual hyperpigmentation results that may persist for weeks or months. The intensity of the initial phototoxic reaction may be mild and may not be recalled by the patient despite significant

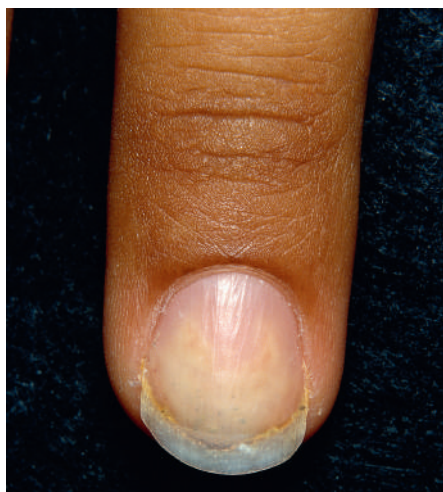hyperpigmentation. Fragrance products containing bergapten, a component of oil of bergamot, will produce this reaction. If a fragrance containing this 5-methoxypsoralen or other furocoumarin is applied to the skin before exposure to the sun or tanning lights, berloque dermatitis may result. This hyperpigmentation, which may be preceded by redness and edema, occurs primarily on the neck and face. Artificial bergapten-free bergamot oil and laws limiting the use of furocoumarins in Europe and the United States have made this a rare condition. However, “Florida Water” and “Kananga Water” colognes, formerly popular in the Hispanic, African American, and Caribbean communities, contain this potent photosensitizer and can still be ordered online, as can other aromatherapy products containing furocoumarins.

Most phototoxic plants are in the families Umbelliferae, Rutaceae (rue), Compositae, and Moraceae. Incriminated plants include agrimony, angelica, atrillal, bavachi, buttercup, common rice, cowslip, dill, fennel, fig, garden and wild carrot, garden and wild parsnip, gas plant, goose foot, zabon, lime and Persian lime, lime bergamot, masterwort, mustard, parsley, St. John’s wort, and yarrow. In Hawaii, the anise-scented moki-hana berry (*Pelea anisata*) was known to natives for its phototoxic properties (moki-hana burn). It is a member of the rue family. Exposure through limes used to flavor gin and tonics and Mexican beer may result in phototoxic reactions in outdoor bartenders and their customers (Fig. 3-18). Home tanning solutions containing fig leaves can produce phytophotodermatitis. These conditions may be widespread and severe enough to require burn unit management (Fig. 3-19).

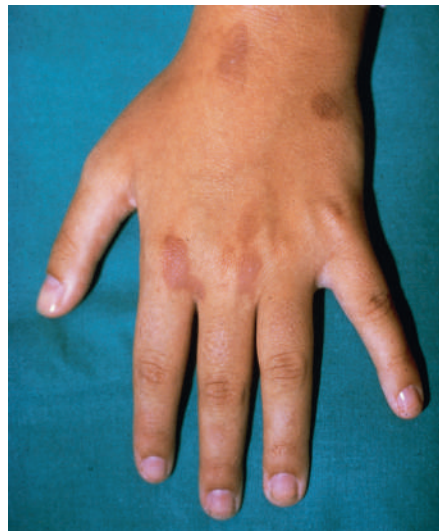Occupational disability from exposure to the pink rot fungus (*Sclerotinia sclerotiorum*), present on celery roots, occurs in celery farmers. In addition, disease-resistant celery contains furocoumarins and may produce phytophotodermatitis in grocery workers. Usually, insufficient sensitizing furocoumarin is absorbed from dietary exposure; however, ingested herbal remedies may cause systemic phototoxicity.

Dermatitis bullosa striata pratensis (grass or meadow dermatitis) is a phytophotodermatitis caused by contact not with grass, but with yellow-flowered meadow parsnip or a wild, yellow-flowered herb of the rose family. The eruption consists of streaks and bizarre configurations with vesicles and bullae that heal with residual hyperpigmentation. The usual cause is sunbathing in fields containing the phototoxic plants. Similarly, tourists in the tropics may rinse their hair with lime juice outdoors, and streaky hyperpigmentation of the arms and back will result where the lime juice runs down (Fig. 3-20).

Blistering phytophotodermatitis must be differentiated from rhus dermatitis. The vesicles and bullae of rhus are not

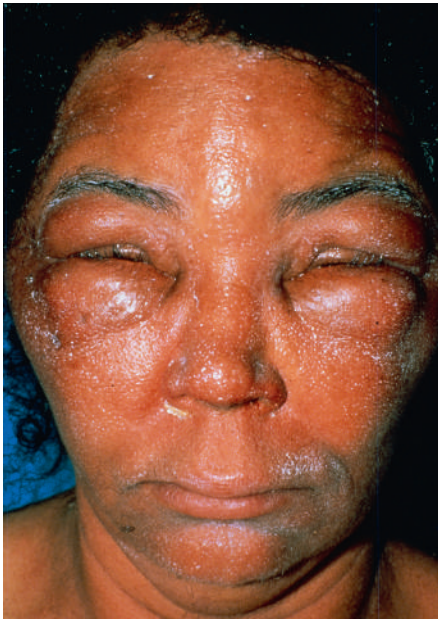

**Fig. 3-17** Photo-onycholysis from minocycline.

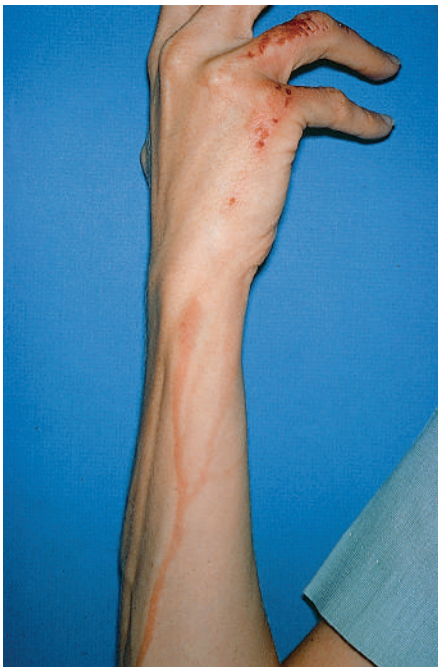

**Fig. 3-18** Phytophotodermatitis to lime in a bartender.





**Fig. 3-19** Severe phytophototoxicity.



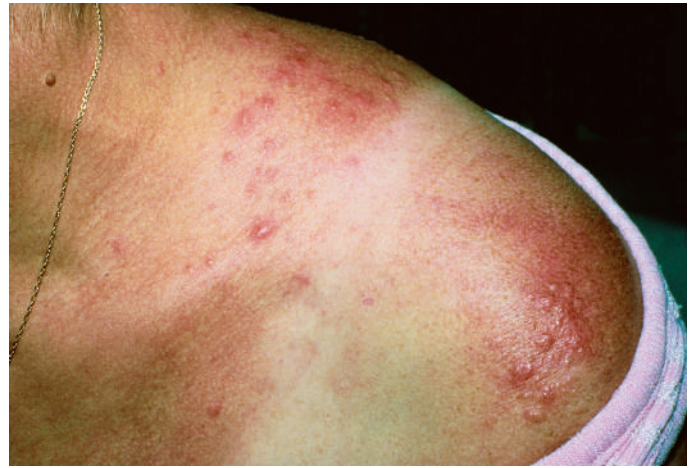**Fig. 3-20** Phytophotodermatitis; the patient had rinsed her hair with lime juice in Mexico.

necessarily limited to the sun-exposed areas, and itching is the most prominent symptom. Lesions continue to occur in rhus dermatitis for a week or more. In phytophotodermatitis, the reaction is limited to sun-exposed sites, a burning pain appears within 48 h, and marked hyperpigmentation results. The asymmetry, atypical shapes, and streaking of the lesions are helpful in establishing the diagnosis. These features may lead to a misdiagnosis of child abuse.

Treatment of a severe, acute reaction is similar to the management of a sunburn, with cool compresses, mild analgesics if required, and topical emollients. Use of topical steroids and strict sun avoidance immediately after the injury may protect against the hyperpigmentation. The hyperpigmentation is best managed by “tincture of time.”

**Abali AE, et al:** Burns or phytophotodermatitis, abuse or neglect. *J Burn Care Res* 2012; 33(6):e309.

**Carlsen K, et al:** Phytophotodermatitis in 19 children admitted to hospital and their differential diagnosis. *J Am Acad Dermatol* 2007; 57:S88.



**Fig. 3-21** Polymorphous light eruption, papulovesicular variant.

**Eickhorst K, et al:** Rue the herb: *Ruta graveolens*-associated phytophotodermatitis. *Dermatitis* 2007; 18:52.

**Flugman SL:** Mexican beer dermatitis. *Arch Dermatol* 2010; 146:1194.

**Maloney FJ, et al:** Iatrogenic phytophotodermatitis resulting from herbal treatment of an allergic contact dermatitis. *Clin Exp Dermatol* 2006; 31:39.

**Pomeranz MK, et al:** Phytophotodermatitis and limes. *N Engl J Med* 2007; 357:e1.

**Rademaker M, et al:** Phytophotodermatitis caused by *Ficus pumila*. *Contact Dermatitis* 2012; 67:53.

**Sasseville D:** Clinical patterns of phyto-dermatitis. *Dermatol Clin* 2009; 27:299.

**Zink A, et al:** Images in clinical medicine. Phototoxic dermatitis. *N Engl J Med* 2014; 371:559.

### Idiopathic photosensitivity disorders

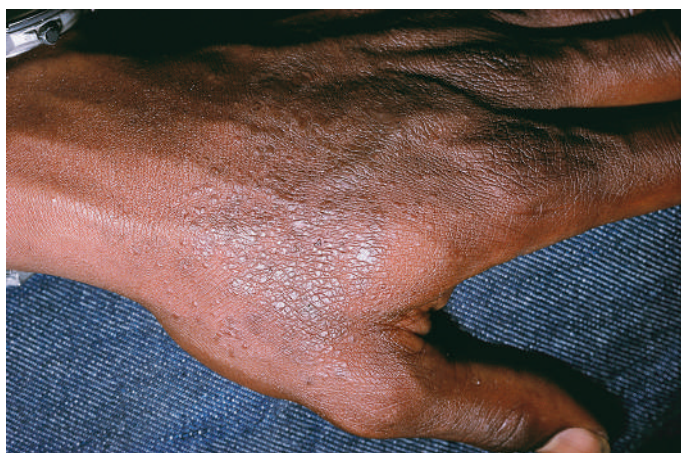This idiopathic group includes the photosensitivity diseases for which no cause is known. These disorders are not associated with external photosensitizers (except for some cases of chronic actinic dermatitis) or inborn errors of metabolism.

### Polymorphous light eruption

Polymorphous light eruption (PLE, PMLE) is the most common form of photosensitivity. In various studies of Northern European white persons, a history of PLE can be elicited in between 5% and 20% of the adult population. It represents about one quarter of all photosensitive patients in referral centers. All races and skin types can be affected. The onset is typically in the first four decades of life, and females outnumber males by 2:1 or 3:1. The pathogenesis is unknown, but a family history may be elicited in 10–50% of patients. Some investigators report that 10–20% of patients with PLE may have positive antinuclear antigens (ANAs) and a family history of lupus erythematosus. Photosensitive systemic lupus erythematosus (SLE) patients may give a history of PLE-like eruptions for years before the diagnosis of SLE is made. PLE patients should be followed for the development of symptoms of SLE.

Clinically, the eruption may have several different morphologies, although in the individual patient, the morphology is usually constant. The papular (or erythematopapular) variant is the most common, but papulovesicular, eczematous, erythematous, and plaquelike lesions also occur (Fig. 3-21). Plaquelike lesions are more common in elderly patients and may closely simulate lupus erythematosus, with indurated, erythematous, fixed lesions. In African Americans, a pinpoint papular variant has been observed, closely simulating lichen





**Fig. 3-22** Polymorphous light eruption, micropapular variant resembling lichen nitidus.

nitidus but showing spongiotic dermatitis histologically (Fig. 3-22). Scarring and atrophy do not occur; in darkly pigmented races, however, marked postinflammatory hyperpigmentation or hypopigmentation may be present. In some patients, pruritus only, without an eruption, may be reported (PLE sine eruptione). Some of these patients will develop typical PLE later in life.

The lesions of PLE appear most often 1–4 days after exposure to sunlight, although patients may report itching and erythema during sun exposure and development of lesions within the first 24 h. A change in the amount of sun exposure appears to be more critical than the absolute amount of radiation. Patients living in tropical climates may be free of eruption, only to develop disease when they move to temperate zones, where there is more marked seasonal variation in UV intensity. Areas of involvement include the face, the V area of the chest, neck, and arms. In general, for each individual, certain areas are predisposed. Typically, however, areas protected during the winter, such as the extensor forearms, are particularly affected, whereas areas exposed all year (face and dorsa of hands) may be relatively spared. The eruption appears most frequently in the spring. The eruption often improves with continued sun exposure (hardening), so patients may be clear of the condition in the summer or autumn.

An unusual variant of PLE is juvenile spring eruption of the ears (see Fig. 3-22). This occurs most frequently in boys age 5–12 years but may also be found in young adult males. It presents in the spring, often after sun exposure on cold but sunny days. The typical lesions are grouped small papules or papulovesicles on the helices. Lesions may form visible vesicles and crusting. Juvenile spring eruption of the ears is self-limited and does not scar. UVA is the inducing spectrum, and some patients also have lesions of PLE elsewhere. The histologic picture is identical to that of PLE. Another localized variant of PLE is spring and summer eruption of the elbows, but this occurs in adults, equally in men and women.

Histologically, a perivascular, predominantly T-cell infiltrate is present in the upper and middle dermis. There is often edema and endothelial swelling, with occasional neutrophils. Epidermal changes are variable, with spongiosis and exocytosis most often observed. Occasionally, a virtual absence of findings microscopically may paradoxically be reported and has been referred to as pauci-inflammatory photodermatitis.

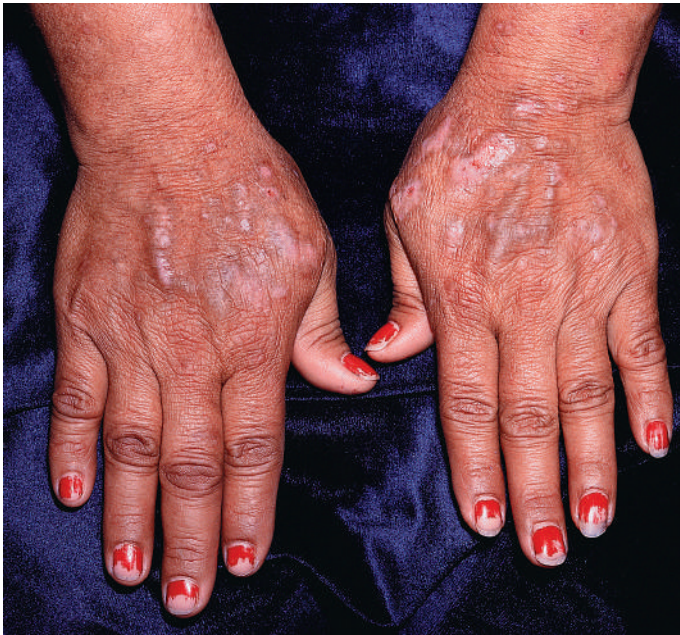The reported action spectrum of PLE varies, possibly depending on the different ethnic backgrounds of reported populations. UVA is most often responsible; however, UVB and both wavelengths in combination are also frequently necessary. Patients often report eruptions following sun exposure through

window glass. Although rare, visible light sensitivity can also occur. Typically, women are more sensitive than men to UVA only, and men are more sensitive to visible light. Men, although the minority of PLE patients, tend to have more severe PLE and broader wavelengths of sensitivity. Most patients react more in affected sites, and in some, lesions can only be induced in affected areas. Phototesting produces variable results. One protocol produced positive results in 83% of tested patients using four exposures of UVB, UVA, or a combination in previously affected sites. However, the light sources are not readily available, and reported protocols vary widely. In clinical practice, the diagnosis is usually made clinically.

The differential diagnosis of PLE includes lupus erythematosus, photosensitive drug eruption, prurigo nodularis, and photoallergic contact dermatitis. Histopathologic examination, ANA testing, and direct immunofluorescence (DIF) are helpful in distinguishing these diseases. Serologic testing alone may not distinguish PLE from SLE because of the possibility of positive ANA tests in PLE patients. Lupus erythematosus may present initially with photosensitivity before other features of lupus occur. A newly described condition, sebaceous neutrophilic adenitis, is characterized by erythematous circinate plaques on the head, neck, and upper chest and has been reported in the first to second month of spring. Histologically, neutrophilic infiltration of the sebaceous glands occurs, sometimes forming microabscesses.

Therapeutically, most patients with mild PLE can be managed by avoiding the sun and using barrier protection and high-SPF, broad-spectrum sunscreens. It is critical that the sunblocks contain specific absorbers or blockers (ecamsule, avobenzone, titanium dioxide, zinc oxide) of long-wave UVA because this is the most common triggering wavelength. Sunblocks containing more than one of these agents are more effective. DermaGard film can be applied to windows at home and in the car to block the transmission of almost all UVB and UVA rays while allowing visible light to be transmitted. Degradation does occur, so the film should be replaced every 5 years. These measures of photoprotection are critical for all patients, since they are free of toxicity and reduce the amount and duration of other therapies required. Patient education is important in the management of PLE. Phototesting may be required to convince patients that they are UV sensitive and will also determine the action spectrum.

The use of topical tacrolimus ointment at night or twice daily, combined with the previous measures for sun avoidance and the use of sunscreens, controls PLE in many patients. At times, topical steroids, frequently of super or high potency and in several daily to weekly pulses, are necessary to control the pruritus and clear the eruption. Antihistamines (hydroxyzine, diphenhydramine, doxepin) may be used for pruritus. Systemic corticosteroids in short courses may be necessary, especially in the spring. In patients whose condition is not controlled by these measures, hardening in the spring with UVB, narrow-band (NB) UVB, or psoralen plus UVA (PUVA) can dramatically decrease the sun sensitivity of patients with PLE, and up to 80% can be controlled with phototherapy. In the most sensitive patients, systemic steroids may be needed at the inception of the phototherapy. Systemic hydroxychloroquine sulfate, 200–400 mg/day, may be used. It has a delayed onset and is best instituted in the late winter to prevent spring outbreaks. Chloroquine or quinacrine may be effective if hydroxychloroquine is not, but in general, antimalarials are inferior to phototherapy. In the most severe cases, management with azathioprine, cyclosporine (cyclosporin A), thalidomide, or mycophenolate mofetil may be considered. If these agents are used in a patient considered to have PLE, an evaluation for chronic actinic dermatitis should be performed because patients with PLE rarely require these agents.



**Fig. 3-23** Actinic prurigo, prurigo nodularis-like lesions.

### Actinic prurigo

Actinic prurigo probably represents a variant of PLE; it is most often seen in Native Americans of North and Central America and Colombia. The incidence in Mexico has been reported at between 1.5% and 3.5%. It has been reported in Europe, Australia, and Japan as well. The female/male ratio is between 2:1 and 6:1. Actinic prurigo in Native Americans in the United States begins before age 10 in 45% of cases and before age 20 in 72%. Up to 75% of patients have a positive family history (hereditary PLE of Native Americans). In Europe, 80% of cases occur before age 10. In the Inuit Canadian population, onset is later and frequently in adulthood.

In childhood, lesions begin as small papules or papulovesicles that crust and become impetiginized. They are intensely pruritic and frequently excoriated. In children, the cheeks, distal nose, ears, and lower lip are typically involved. Cheilitis may be the initial and only feature for years. Conjunctivitis is seen in 10–20% of patients (limbal-type vernal catarrh). Lesions of the arms and legs are also common and usually exhibit a prurigo nodule-like configuration (Fig. 3-23). The eruption may extend to involve sun-protected areas, especially the buttocks, but lesions in these areas are always less severe. In adults, chronic, dry papules and plaques are most typical, and cheilitis and crusting occur less frequently. Skin lesions tend to persist throughout the year in the tropics but are clearly worse during periods of increased sun exposure. In temperate and high-latitude regions, lesions occur from March through the summer and substantially remit in the winter. Hardening, as seen with PLE, does not occur. In up to 60% of patients with actinic prurigo that present before age 20, the condition improves or resolves within 5 years, whereas adults usually have the disease throughout life.

Initial therapy is identical to that for PLE. Thalidomide has been used effectively and safely over many years for this condition. In patients refractory to or intolerant of thalidomide, cyclosporin A can be effective. Topical cyclosporin A 2% may be effective in controlling limbal lesions of actinic prurigo-associated conjunctivitis.

**Akaraphanth R, et al:** Adult-onset actinic prurigo in Thailand. *Photodermatol Photoimmunol Photomed* 2007; 23:234.

**Boonstra HE, et al:** Polymorphous light eruption: a clinical, photobiologic, and follow-up study of 110 patients. *J Am Acad Dermatol* 2000; 42:199.

**Chantorn R, et al:** Photosensitivity disorders in children. Part 1. *J Am Acad Dermatol* 2012; 67:1093.e1–e18.

**Chiam LY, et al:** Pinpoint popular polymorphous light eruption in Asian skin. *Photodermatol Photoimmunol Photomed* 2009; 25:71.

**Gruber-Wackernagel A, et al:** Polymorphous light eruption. *Dermatol Clin* 2014; 32:315.

**Hasan T, et al:** Disease associations in PMLE. *Arch Dermatol* 1998; 134:1081.

**Hatch KL, et al:** Garments as solar ultraviolet radiation screening materials. *Dermatol Clin* 2006; 24:85.

**Honigsmann H:** Polymorphous light eruption. *Photodermatol Photoimmunol Photomed* 2008; 24:155.

**Kerr AC:** Actinic prurigo deterioration due to degradation of DermaGard window film. *Br J Dermatol* 2007; 157:609.

**Kerr HA, et al:** Photodermatoses in African Americans. *J Am Acad Dermatol* 2007; 57:638.

**Millard TP, et al:** Familial clustering of PLE in relatives of patients with lupus erythematosus. *Br J Dermatol* 2001; 144:334.

**Molina-Riu AM, et al:** Spring and summer eruption of the elbows. *J Am Acad Dermatol* 2013; 68: 306-312.

**Patel DC, et al:** Efficacy of short-course oral prednisolone in PLE: a randomized controlled trial. *Br J Dermatol* 2000; 143:828.

**Roelandts R:** The diagnosis of photosensitivity. *Arch Dermatol* 2000; 136:1152.

**Ross G, et al:** Actinic prurigo. *Photodermatol Photoimmunol Photomed* 2008; 24:272.

**Schornagel IJ, et al:** Diagnostic phototesting in PLE. *Br J Dermatol* 2005; 153:1220.

**Stratigos AJ, et al:** Juvenile spring eruption. *J Am Acad Dermatol* 2004; 50:57.

**Su W, et al:** Photodermatitis with minimal inflammatory infiltrate. *Am J Dermatopathol* 2006; 28:482.

**Trelles AS, et al:** A new case of sebaceous neutrophilic adenitis. *J Am Acad Dermatol* 2009; 60:887.

**Van de Pas CB, et al:** An optimal method of photoprovocation of PLE. *Arch Dermatol* 2004; 140:286.

**Wiseman MC, et al:** Actinic prurigo. *J Am Acad Dermatol* 2001; 44:952.

**Yong Gee SA, et al:** Long-term thalidomide for actinic prurigo. *Australas J Dermatol* 2001; 42:281.

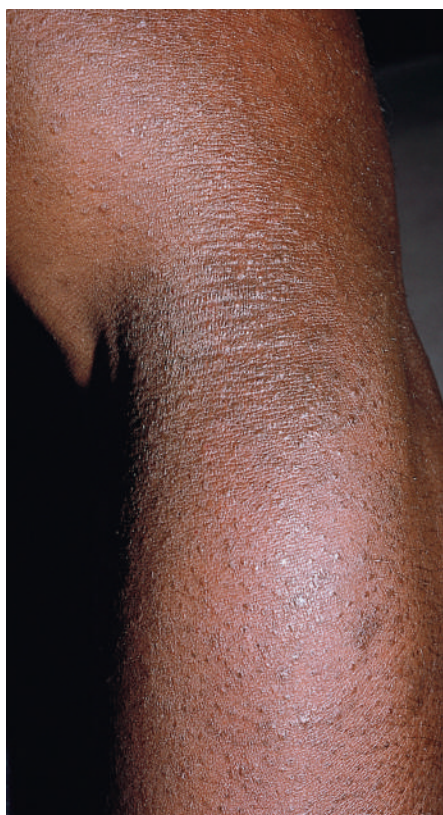### Brachioradial pruritus

Polymorphous light eruption may present initially and only on the brachioradial area. This type of brachioradial eruption was the initial pattern of brachioradial pruritus described and was termed solar pruritus (Fig. 3-24). The majority of cases of brachioradial pruritus, especially those characterized by severe, refractory, intractable pruritus and secondary severe lichenification, are now thought to represent a form of neuropathic pruritus, sometimes related to cervical spine disease (see Chapter 4). Sunlight may be an eliciting factor and cervical spine disease a predisposing factor in patients with brachioradial pruritus. To identify those patients in whom photosensitivity plays a prominent role, a high-SPF (UVA/UVB) sunscreen should be applied to one arm only for several weeks. In patients with PLE, this usually leads to improvement of that one arm compared with the contralateral unprotected arm. In patients with primarily neuropathic disease, sunscreen application leads to minimal improvement.

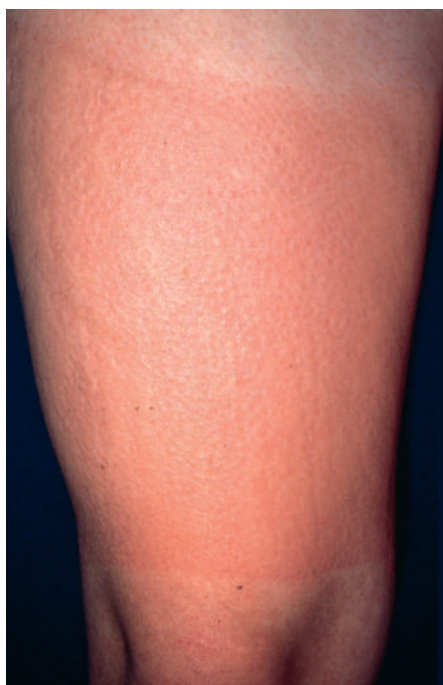### Solar urticaria

Solar urticaria is most common in women age 20–40. Within seconds to minutes after light exposure, typical urticarial lesions appear and resolve in 1–2 h, rarely lasting more than 24 h (Fig. 3-25). Delayed reactions rarely occur. Chronically exposed sites may have some reduced sensitivity. In severe attacks, syncope, bronchospasm, and anaphylaxis may occur.





**Fig. 3-24**  
Polymorphous light eruption, brachioradial distribution.



**Fig. 3-25** Solar urticaria.

Patients with solar urticaria may be sensitive to wavelengths over a broad spectrum. The wavelengths of sensitivity and the minimal urticarial doses (MUDs) may vary with anatomic site and over time within the same patient. UVA sensitivity is the most common, but visible light sensitivity is also frequently reported. The photosensitivity can be passively transferred, and irradiation of the patient's serum with the activating wavelength followed by reinjection will create a wheal in the patient, but not in an unaffected patient. This suggests the presence of a circulating photoinducible allergen to which the

individual patient with solar urticaria is sensitive. In some patients, an inhibition spectrum may be identified that inhibits the binding of the endogenous photoallergen to mast cells.

Solar urticaria is virtually always idiopathic. Rarely, medications such as tetracycline (but not minocycline), chlorpromazine, progestational agents, and repirinast have been reported to induce solar urticaria. Erythropoietic protoporphyria and more rarely porphyria cutanea tarda may present with lesions simulating solar urticaria. There are rare reports of solar urticaria in patients with lupus erythematosus.

The diagnosis of solar urticaria is usually straightforward from the history. Phototesting is useful to determine the wavelengths of sensitivity and to ascertain the MUD if UVA desensitization is being considered.

Because many patients have sensitivity in the UVA or even visible range, broad-spectrum sunscreens should be instituted. Antihistamines, especially the non-sedating H1 agents loratadine, cetirizine HCl, and fexofenadine, may increase the MUD 10-fold or more. Higher doses, twice or more the standard recommendation, may be required (e.g., 180 mg of fexofenadine twice daily). These drugs, plus sun avoidance and broad-spectrum sunscreens, are the first-line therapy. PUVA or increasing UVA exposures are effective in more difficult cases, with PUVA having greater efficacy. Rush hardening may induce UVA tolerance, allowing patients to begin PUVA therapy. PUVA is effective, even if the patient is not sensitive to UVA. Cyclosporin A (4.5 mg/kg/day) and intravenous immune globulin (IVIG; 1 g/kg/day for 2 days) have been anecdotally reported as effective. For the most difficult cases, plasmapheresis may be used to remove the circulating photoallergen, allowing PUVA to be given and leading to remission.

**Aubin F, et al:** Severe and refractory solar urticaria treated with intravenous immunoglobulins. *J Am Acad Dermatol* 2014; 71:948.

**Beattie PE, et al:** Characteristics and prognosis of idiopathic solar urticaria: a cohort of 87 cases. *Arch Dermatol* 2003; 139:1149.

**Botto NC, et al:** Solar urticarial. *J Am Acad Dermatol* 2008; 59:909.

**Fukunaga A, et al:** The inhibition spectrum of solar urticaria suppresses the wheal-flare response following intradermal injection with photoactivated autologous serum but not with compound 48/80. *Photodermatol Photoimmunol Photomed* 2006; 22:129.

**Masuoka E, et al:** Successful and long-lasting treatment of solar urticarial with UVA rush hardening therapy. *Br J Dermatol* 2012; 167:198.

**Ng JCH, et al:** Changes of photosensitivity and action spectrum with time in solar urticaria. *Photodermatol Photoimmunol Photomed* 2002; 18:191.

**Rose RF, et al:** Solar angioedema. *Photodermatol Photoimmunol Photomed* 2005; 21:226.

**Veien NK, et al:** Brachioradial pruritus: a follow-up of 76 patients. *Acta Derm Venereol* 2011; 91:183

**Wessendorf U, et al:** Fixed solar urticarial with delayed onset. *J Am Acad Dermatol* 2009; 60:695-697.

**Yap LM, et al:** Drug-induced solar urticaria due to tetracycline. *Australas J Dermatol* 2000; 41:181.

## Hydroa vacciniforme

Hydroa vacciniforme is a rare, chronic photodermatosis with onset in childhood. Boys and girls are equally represented, but boys present earlier and on average have longer-lasting disease. There is a bimodal onset, between ages 1 and 7 and between 12 and 16. The natural history of the typical disorder is spontaneous remission before age 20, but rare cases in young adults do occur. Within 6 h of exposure, stinging begins. At 24 h or sooner, erythema and edema appear, followed by the characteristic 2–4 mm vesicles. Over the next few days, these lesions rupture, become centrally necrotic, and heal with a smallpoxlike scar. Lesions tend to appear in crops with disease-free intervals. The ears, nose, cheeks, and extensor



arms and hands are affected. Subungual hemorrhage, ocular involvement, or oral ulcerations may occur.

Histologically, early lesions show intraepidermal vesiculation and dermal edema that evolve into a subepidermal blister. Necrotic lesions show reticular degeneration of keratinocytes, with epidermal necrosis flanked by spongiosis with a dense perivascular infiltrate of neutrophils and lymphocytes. Dermal vessels may be thrombosed, simulating vasculitis. Lesions may be reproduced by repetitive UVA, with the action spectrum in the 330–360 nm range.

The differential diagnosis includes PLE, actinic prurigo, and erythropoietic protoporphyria. Porphyrin levels are normal in hydroa vacciniforme. In erythropoietic protoporphyria, the burning typically begins within minutes of sun exposure, and over time patients develop diffuse, thickened, waxlike scarring, rather than the smallpoxlike scars of hydroa vacciniforme. Histologic evaluation is useful in distinguishing these two conditions. Treatment is principally to avoid sunlight exposure and to use broad-spectrum sunscreens that block in the UVA range. Prophylactic NB UVB phototherapy in the early spring may be effective.

A subset of children and less often adults with photosensitive hydroa vacciniforme-like skin lesions manifest facial swelling, indurated nodules or progressive ulcers, fever, and liver damage. Oral, esophageal, or colonic ulcerations may occur. Hypersensitivity to mosquito bites may also be seen. These patients may develop Epstein-Barr virus (EBV)-associated natural killer (NK) cell/T-cell lymphomas and die from this or a hemophagocytic syndrome. The hydroa vacciniforme-like skin lesions may precede the diagnosis of the lymphoma by up to a decade, and initially the patient may appear to have typical hydroa vacciniforme of the self-limited type. This is therefore a disease spectrum, with both typical and severe hydroa vacciniforme being EBV associated. Treatment of the lymphoma may lead to clearing of these lesions.

**Chantorn R, et al:** Photosensitivity disorders in children. Part 1. *J Am Acad Dermatol* 2012; 67:1093.e1–e18.

**Chen HH, et al:** Hydroa vacciniforme-like primary cutaneous CD8-positive T-cell lymphoma. *Br J Dermatol* 2002; 147:587.

**Cho KH, et al:** Epstein-Barr virus-associated peripheral T-cell lymphoma in adults with hydroa vacciniforme-like lesions. *Clin Exp Dermatol* 2001; 26:242.

**Gupta G, et al:** Hydroa vacciniforme: a clinical and follow-up study of 17 cases. *J Am Acad Dermatol* 2000; 42:208.

**Miyake T, et al:** Survival rates and prognostic factors of Epstein-Barr virus-associated hydroa vacciniforme and hypersensitivity to mosquito bites. *Br J Dermatol* 2014; Sep 18.

**Yammamoto T, et al:** Oculomucosal and gastrointestinal involvement in Epstein-Barr virus-associated hydroa vacciniforme. *Eur J Dermatol* 2012; 23:380.

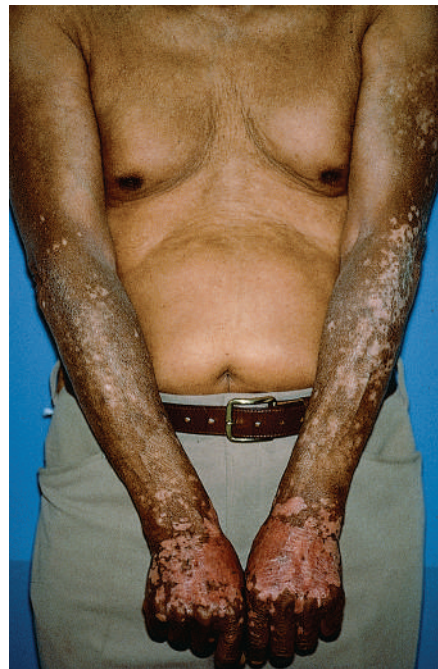**Zeng Y, et al:** Hydroa vacciniforme-like Epstein-Barr virus-associated lymphoproliferative disease. *Pediatr Dermatol* 2012; 29:96.

## Chronic actinic dermatitis

Chronic actinic dermatitis represents the end stage of progressive photosensitivity in some patients. It has replaced the terms persistent light reactivity, actinic reticuloid, photosensitive eczema, and chronic photosensitivity dermatitis. The basic components of this disease are as follows:

- Persistent, chronic, eczematous eruption in the absence of exposure to known photosensitizers
- Usually, broad-spectrum photosensitivity with decreased MED to UVA and/or UVB and at times visible light
- Histology consistent with a chronic dermatitis, with or without features of lymphoma

Clinically, chronic actinic dermatitis predominantly affects middle-age or elderly men. In the United States, patients



**Fig. 3-26** Chronic actinic dermatitis.

with skin types V and VI may be disproportionately affected (Fig. 3-26). Skin lesions consist of edematous, scaling, thickened patches and plaques that tend to be confluent. Lesions occur primarily or most severely on the exposed skin and may spare the upper eyelids, behind the ears, and the bottom of wrinkles. Involvement of unexposed sites often occurs, progressing to erythroderma in the most severe cases. Marked depigmentation resembling vitiligo may result. Patients may not realize their condition is exacerbated by exposure to light. It may persist in all seasons.

The pathogenesis of this syndrome is unknown. In some patients, a preceding topical or oral photosensitizer may be implicated, but chronic actinic dermatitis fails to improve with discontinuation of the inciting agent. In about one third of patients, photopatch testing yields a positive response to previously applied agents, especially musk ambrette, sunscreen ingredients, *p*-phenylenediamine, and hexachlorophene. Patch testing to standard agents may have a positive result in about 30% of patients, but no particular relevance is found. However, in approximately 65% of European patients, sesquiterpene lactone contact sensitivity from Compositae has been identified. In addition, more than 75% of men over age 60 with sesquiterpene lactone sensitivity have abnormal phototesting results. CD8 (suppressor/cytotoxic) T cells are disproportionately represented in the cutaneous infiltrates in the majority of patients and less frequently in the peripheral blood. IgE levels may be elevated.

In this clinical setting, diagnosis of chronic actinic dermatitis is established by histologic evaluation and phototesting. Phototesting often reproduces the lesions. About 65% of patients are sensitive to UVA, UVB, and visible light; 22% to UVA and UVB; and 5% to UVB or UVA only. The finding of photosensitivity to UVA and UVB helps to differentiate chronic actinic dermatitis from drug-induced photosensitivity, in which patients usually exhibit only UVA photosensitivity. PLE, photoallergic contact dermatitis, airborne contact dermatitis, and mycosis fungoides or Sézary syndrome must be excluded. PLE is excluded by the broad-spectrum-reduced MED in chronic actinic dermatitis, although some patients may begin with a PLE like disease that later meets the criteria for chronic actinic dermatitis. Contact dermatitis is excluded by patch and photopatch testing. Mycosis fungoides may be difficult to

differentiate from chronic actinic dermatitis in cases with atypical histology. Phototesting is critical in these patients. Mycosis fungoides will manifest a T-cell receptor rearrangement in lesional skin or peripheral blood and usually shows a CD4 (helper) T-cell predominance.

Therapy for chronic actinic dermatitis includes identifying possible topical photosensitizers by photopatch testing and scrupulously avoiding them. Maximum sun avoidance and broad-spectrum sunscreens are essential. Topical tacrolimus is useful in many patients. Topical and systemic steroids are effective in some patients, but chronic toxicity of systemic steroids limits chronic use. Azathioprine, 50–200 mg/day, is the most reproducibly effective treatment and may be required annually during periods of increased sun intensity. Low-dose PUVA or NB UVB can be effective when used with topical and systemic steroids, but patients may also be intolerant of this approach. Hydroxyurea, 500 mg twice daily, cyclosporin A, thalidomide, and mycophenolate mofetil may also be used. Immunosuppressive agents may allow patients to tolerate PUVA therapy. With careful management, about 1 in 10 patients will lose their photosensitivity within 5 years, 1 in 5 by 10 years, and half of patients by 15 years.

**Beach RA, et al:** Chronic actinic dermatitis. *J Cutan Med Surg* 2009; 13:121.

**Chew AL, et al:** Contact and photocontact sensitization in chronic actinic dermatitis. *Contact Dermatitis* 2010; 62:42.

**Dawe RS, et al:** The natural history of chronic actinic dermatitis. *Arch Dermatol* 2000; 136:1215.

**Khaled A, et al:** Chronic actinic dermatitis: two patients with successful management using narrow band ultraviolet B phototherapy with systemic steroids. *Therapie* 2011; 66:453.

**Ma Y, et al:** Treatment with topical tacrolimus favors chronic actinic dermatitis. *J Dermatol Treat* 2010; 21:171.

**Que SK, et al:** Chronic actinic dermatitis. *Dermatitis* 2011; 22:147.

**Safa G, et al:** Recalcitrant chronic actinic dermatitis treated with low-dose thalidomide. *J Am Acad Dermatol* 2005; 52:E6.

**Thomson MA, et al:** Chronic actinic dermatitis treated with mycophenolate mofetil. *Br J Dermatol* 2005; 152:784.

## Photosensitivity and HIV infection

Photosensitivity resembling PLE, actinic prurigo, or chronic actinic dermatitis is seen in about 5% of patients with human immunodeficiency virus (HIV) infection. In general, photosensitivity is seen when the CD4 count is below 200 (often <50), except in persons with a genetic predisposition (Native Americans). Photosensitivity may be the initial manifestation of HIV disease. African American patients are disproportionately represented among patients with HIV photosensitivity. Photosensitivity may be associated with ingestion of a photosensitizing medication, especially NSAIDs, efavirenz (used in HAART therapy) or trimethoprim-sulfamethoxazole, but the skin eruption often does not improve even when the medication is discontinued. Histologically, the lesions may show subacute or chronic dermatitis, often with a dense dermal infiltrate with many eosinophils. Histology identical to PLE, lichen planus, or lichen nitidus may also occur. When the CD4 count is below 50, especially in black patients, chronic actinic dermatitis with features of actinic prurigo is typical. Widespread vitiliginous lesions may develop. Therapy is difficult, but thalidomide may be beneficial.

**Bilu D, et al:** Clinical and epidemiological characterization of photosensitivity in HIV-positive individuals. *Photodermatol Photoimmunol Photomed* 2004; 20:175.

**Isaacs T, et al:** Annular erythema and photosensitivity as manifestations of efavirenz-induced cutaneous reactions. *J Antimicrob Chemother* 2013; 68:2871.

**Maurer TA, et al:** Thalidomide treatment for prurigo nodularis in HIV-infected subjects: efficacy and risk of neuropathy. *Arch Dermatol* 2004; 140:845.

**Philips RC, et al:** HIV photodermatitis presenting with widespread vitiligo-like depigmentation. *Dermatol Online J* 2012; 18:6.

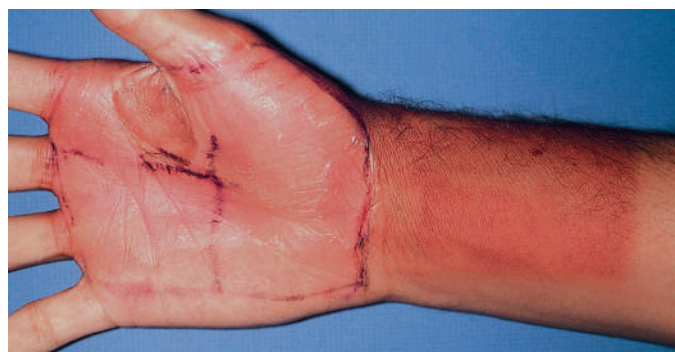## RADIODERMATITIS

The major target within the cell by which radiation damage occurs is the DNA. The effects of ionizing radiation on the cells depend on the amount of radiation, its intensity (exposure rate), and the characteristics of the individual cell. Rapidly dividing cells and anaplastic cells in general have increased radiosensitivity compared with normal tissue. When radiation therapy is delivered, it is frequently fractionated (i.e., divided into small doses). This allows the normal cells to recover between doses.

When the dose is large, cell death results. In small amounts, the effect is insidious and cumulative. Mitosis is arrested temporarily, with consequent retardation of growth. The exposure rate affects the number of chromosome breaks. The more rapid the delivery of a certain amount of radiation, the greater is the number of chromosome breaks. The number of breaks is also increased by the presence of oxygen.

### Acute radiodermatitis

When an “erythema dose” of ionizing radiation is given to the skin, there is a latent period of up to 24 h before visible erythema appears. This initial erythema lasts 2–3 days but may be followed by a second phase beginning up to 1 week after the exposure and lasting up to 1 month. When the skin is exposed to a large amount of ionizing radiation, an acute reaction develops, the extent of which will depend on the amount, quality, and duration of exposure. Such radiation reaction occurs in the treatment of malignancy and in accidental overexposure. The reaction is manifested by initial erythema, followed by a second phase of erythema at 3–6 days (Fig. 3-27). Vesiculation, edema, and erosion or ulceration may occur, accompanied by pain. The skin develops a dark color that may be mistaken for hyperpigmentation but that desquamates. This type of radiation injury may subside in several weeks to several months, again depending on the amount of radiation exposure. Skin that receives a large amount of radiation will never return to normal. It will lack adnexal structures, will be dry, atrophic, and smooth, and will be hypopigmented or depigmented. Cutaneous necrosis may complicate yttrium-90 synovectomy, a treatment given for chronic synovitis.



**Fig. 3-27** Acute radiation burn during treatment of epithelioid sarcoma.



## Eosinophilic, polymorphic, and pruritic eruption associated with radiotherapy

The polymorphic, pruritic eruption arising several days to several months after radiotherapy for cancer tends to favor the extremities. Acral excoriations, erythematous papules, vesicles, and bullae occur. It is not necessarily limited to the areas of radiation treatment. Histologically, a superficial and deep perivascular lymphohistiocytic infiltrate with eosinophils is present. Topical steroids, antihistamines, and UVB are all effective, and spontaneous resolution also occurs.

## Chronic radiodermatitis

Chronic exposure to “suberythema” doses of ionizing radiation over a prolonged period will produce varying degrees of damage to the skin and its underlying parts after a variable latent period ranging from several months to several decades. Radiodermatitis may also occur on the back or flank after fluoroscopy and roentgenography for diagnostic purposes (Fig. 3-28).

Telangiectasia, atrophy, and hypopigmentation with residual focal increased pigment (freckling) may appear (Fig. 3-29). The skin becomes dry, thin, smooth, and shiny. The nails may become striated, brittle, and fragmented. The capacity to repair injury is substantially reduced, resulting in ulceration from minor trauma. The hair becomes brittle and sparse. In more severe cases, these chronic changes may be followed by radia-

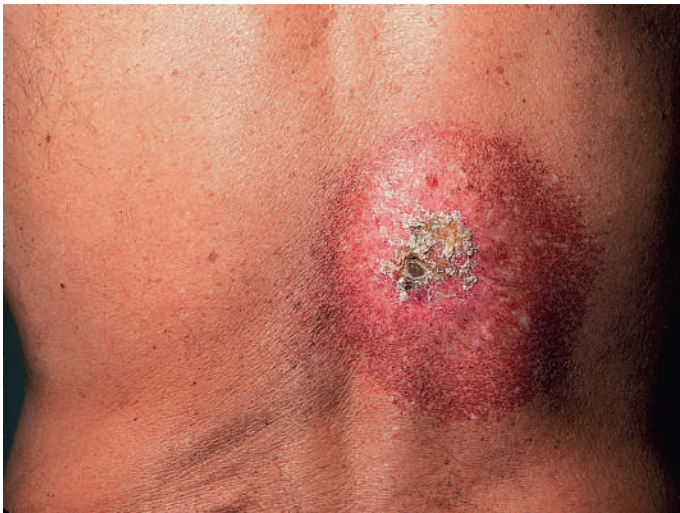

Fig. 3-28 Chronic radiodermatitis after fluoroscopy.

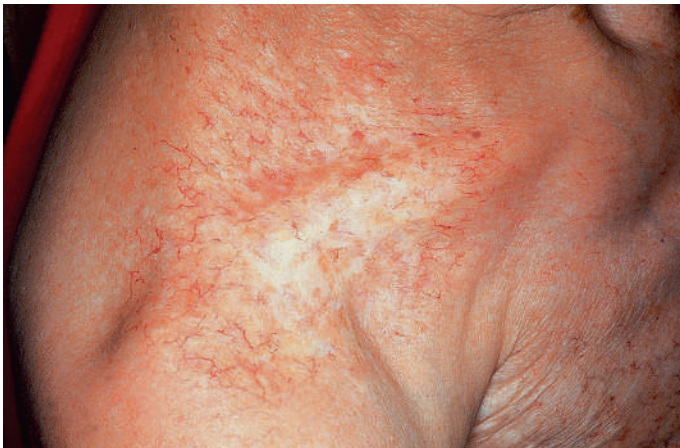

Fig. 3-29 Chronic radiodermatitis.

tion keratoses and carcinoma. Additionally, subcutaneous fibrosis, thickening, and binding of the surface layers to deep tissues may present as tender, erythematous plaques 6–12 months after radiation therapy (Fig. 3-30). It may resemble erysipelas or inflammatory metastases.

## Radiation cancer

After a latent period averaging 20–40 years, various malignancies may develop, most frequently basal cell carcinoma (BCC), followed by squamous cell carcinoma (SCC). These may appear in sites of prior radiation, even if there is no evidence of chronic radiation damage. Sun damage may be additive to radiation therapy, increasing the appearance of nonmelanoma skin cancers. SCCs arising in sites of radiation therapy metastasize more frequently than purely sun-induced SCCs. In some patients, either type of tumor may predominate. Location plays some role; SCCs are more common on the arms and hands, whereas BCCs are seen on the head and neck and lumbosacral area. Other radiation-induced cancers include angiosarcoma (Fig. 3-31), Kaposi sarcoma, malignant fibrous histiocytoma, sarcomas, and thyroid carcinoma. The incidence of malignant neoplasms increases with the passage of time.

## Treatment

Acute radiodermatitis may be reduced with a topical corticosteroid ointment combined with an emollient cream applied twice a day and instituted at the onset of therapeutic radiotherapy. Chronic radiodermatitis without carcinoma requires little or no attention except protection from sunlight and the extremes of heat and cold. Careful cleansing with mild soap and water, the use of emollients, and occasionally hydrocortisone ointment are the only requirements for good care.

The early removal of precancerous keratoses and ulcerations is helpful in preventing the development of cancers. For radiation keratoses treatment with cryosurgery, 5-FU, imiquimod cream, ingenol, or topical 5-aminolevulinic acid (ALA)-photodynamic therapy may be sufficient. If the keratosis feels infiltrated, a biopsy is indicated. Radiation ulcerations should be studied by excisional or incisional biopsy if they have been present for 3 months or longer. Complete removal by excision is frequently required to obtain healing and exclude focal carcinoma in the ulceration. Radiation-induced nonmelanoma skin cancers are managed by standard methods. The higher risk of metastasis from radiation-induced SCCs mandates careful follow-up and regular regional lymph node evaluation.

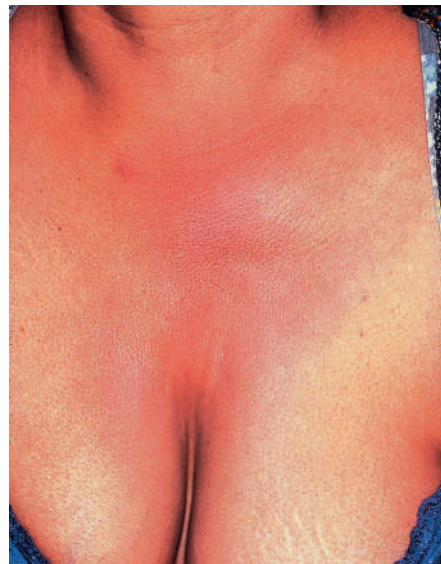

Fig. 3-30 Delayed radiation reaction 8 months after therapy.



**Balter S, et al:** Patient skin reactions from interventional fluoroscopy procedures. *Am J Roentgenol* 2014; 202:335.

**Bolderston A, et al:** The prevention and management of acute skin reactions related to radiation therapy: a systematic review and practice guideline. *Support Care Cancer* 2006; 14:802.

**Cota C, et al:** Localized post-radiation Kaposi sarcoma in a renal transplant immunosuppressed patient. *Am J Dermatopathol* 2014; 36:270-273.

**Davis MM, et al:** Skin cancer in patients with chronic radiation dermatitis. *J Am Acad Dermatol* 1989; 20:608.

**James WD, et al:** Late subcutaneous fibrosis following megavoltage radiotherapy. *J Am Acad Dermatol* 1980; 3:616.

**Lee DJ, et al:** A pustular form of eosinophilic, polymorphous, and pruritic eruption associated with radiotherapy. *J Am Acad Dermatol* 2011; 65:e51-e53.

**Oztürk H, et al:** Treatment of skin necrosis after radiation synovectomy with yttrium-90: a case report. *Rheumatol Int* 2008; 28:1067-1068.

**Ulf E, et al:** A potent steroid cream is superior to emollients in reducing acute radiation dermatitis in breast cancer patients treated with adjuvant radiotherapy. *Radiother Oncol* 2013; 108:287-292.

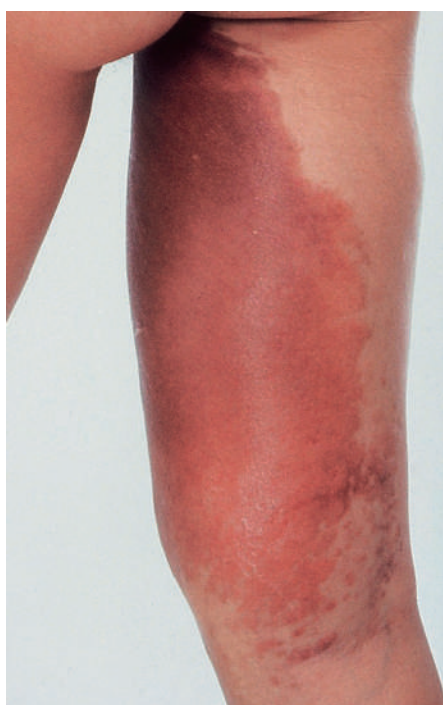**Watt TC, et al:** Radiation-related risk of basal cell carcinoma: a report from the Childhood Cancer Survivor Study. *J Natl Cancer Inst* 2012; 104:1240-1250.

## MECHANICAL INJURIES

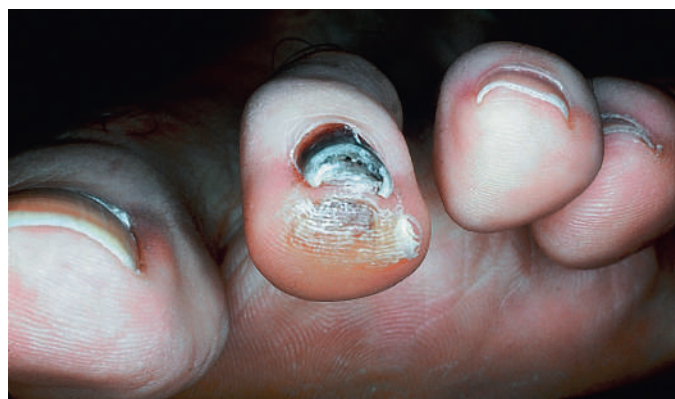Mechanical factors may induce distinctive skin changes. Pressure, friction, and the introduction of foreign substances (as by injection) are some of the means by which skin injuries may occur.

### Callus

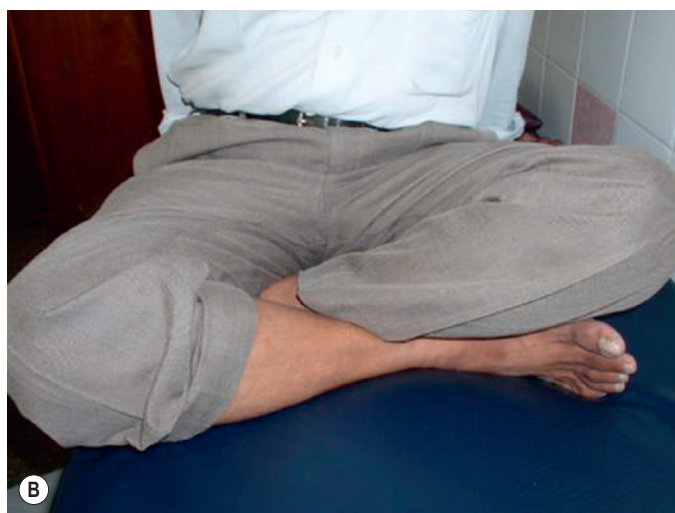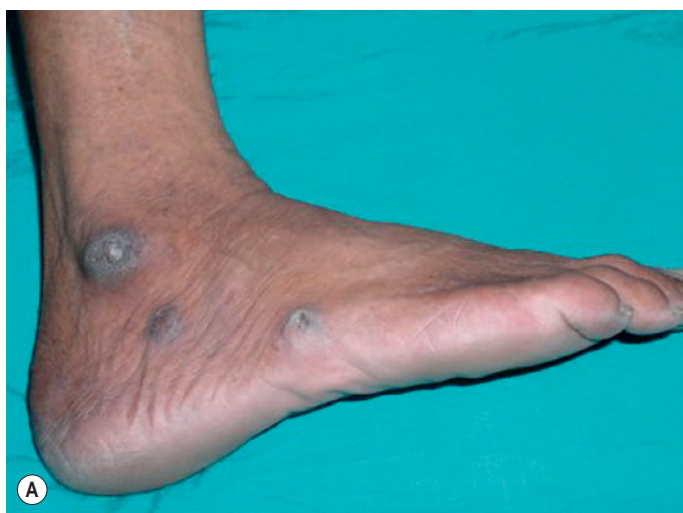Callus is a nonpenetrating, circumscribed hyperkeratosis produced by pressure. It occurs on parts of the body subject to intermittent pressure, particularly the palms and soles, and especially the bony prominences of the joints. Those engaged in various sports, certain occupations, or other repetitive activity develop callosities of distinctive size and location as stigmata. Examples are surfer's nodules, boxer's knuckle pads, jogger's toe, rower's rump, milker's callus, tennis toe (Fig. 3-32), jogger's nipple, prayer callus, the yoga sign (Fig. 3-33), neck callosities of violinists, pillar knocker's knuckles, bowler's hand, and Russell's sign. The latter are calluses, small lacerations, or abrasions on the dorsum of the hand overlying the metacarpophalangeal and interphalangeal joints and are seen as a clue to the diagnosis of bulimia nervosa.



**Fig. 3-31** Angiosarcoma years after radiation therapy.



**Fig. 3-32** Tennis toe.



**Fig. 3-33** A and B, Calluses from sitting in yoga position. (Courtesy of Dr. Shyam Verma.)

The callus differs from the clavus in that it has no penetrating central core and is a more diffuse thickening. Callus tends to disappear spontaneously when the pressure is removed. Most problems are encountered with calluses on the soles. Poorly fitting shoes, orthopedic problems of the foot caused by aging or a deformity of the foot exerting abnormal pressure, and high activity level are some of the etiologic factors to be considered in painful callosities of the feet.

Padding to relieve the pressure, paring of the thickened callus, and use of keratolytics such as 40% salicylic acid plasters are effective means of relieving painful callosities. Use of 12% ammonium lactate lotion or a urea-containing cream is often helpful.

### Clavus (corns)

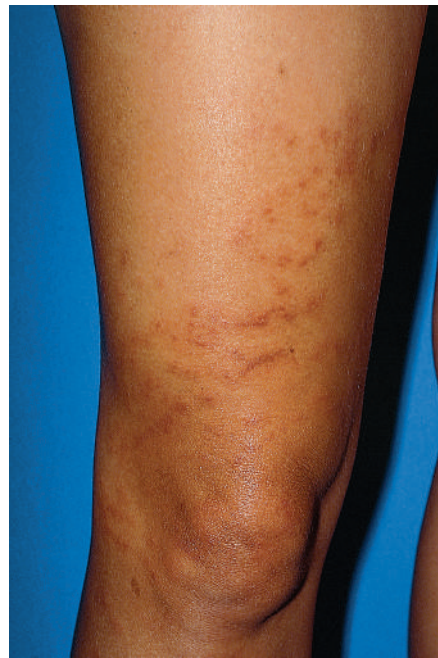Corns are circumscribed, horny, conical thickenings with the base on the surface and the apex pointing inward and pressing on subjacent structures. There are two varieties: the hard corns, which occur on the dorsa of the toes or on the soles, and the soft corns, which occur between the toes and are softened by the macerating action of sweat. In a hard corn, the surface is shiny and polished, and when the upper layers are shaved off, a core is noted in the densest part of the lesion. It is this core that causes a dull/boring or sharp/lancinating pain by pressing on the underlying sensory nerves. Corns arise at sites of friction or pressure, and when these causative factors are removed, they spontaneously disappear. Frequently, a bony spur or exostosis is present beneath both hard and soft corns of long duration, and unless this exostosis is removed, cure is unlikely. The soft interdigital corn usually occurs in the fourth interdigital space of the foot. Frequently, there is an exostosis at the metatarsophalangeal joint that causes pressure on the adjacent toe. These are soft, soggy, and macerated so that they appear white. Treatment by simple excision may be effective.

Plantar corns must be differentiated from plantar warts, and in most cases this can be done with confidence only by paring off the surface keratin until either the pathognomonic elongated dermal papillae of the wart with its blood vessels or the clear horny core of the corn can be clearly seen. Poro-keratosis plantaris discreta is a sharply margined, cone-shaped, rubbery lesion that commonly occurs beneath the metatarsal heads. Multiple lesions may occur. It has a 3:1 female predominance, is painful, and is frequently confused with a plantar wart or corn. Keratosis punctata of the creases may be seen in the creases of the toes, where it may be mistaken for a corn.

The relief of pressure or friction by corrective footwear or the application of a ring of soft felt wadding around the region of the corn will often bring a good result. Soaking the feet in hot water and paring the surface by means of a scalpel blade or pumice stone leads to symptomatic improvement. Salicylic acid is successful when carefully and diligently used. After careful paring of the corn with emphasis on removing the center core, 40% salicylic acid plaster is applied. Soaking the foot for ½ h before reapplying the medication enhances the effect. After 48 h, the plaster is removed, the white macerated skin is rubbed off, and a new plaster is reapplied. This is continued until the corn is gone. It should be stressed that removal of any underlying bony abnormality, if present, is often necessary to effect a cure.

### Pseudoverrucous papules and nodules

These striking 2–8 mm, shiny, smooth, red, moist, flat-topped round lesions in the perianal area of children are considered



**Fig. 3-34** Coral cuts. (Courtesy of Curt Samlaska, MD.)

to be a result of encopresis or urinary incontinence. There is a similarity to lesions affecting urostomy or elderly incontinent patients. Protection of the skin will help eliminate them. Similar lesions have been described in women who repeatedly apply an antifungal (Vagisil) to the groin area.

### Coral cuts

A severe type of skin injury may occur from the cuts of coral skeletons (Fig. 3-34). The abrasions and cuts are painful, and local therapy may provide little or no relief. Healing may take months. As a rule, if secondary infection is guarded against, such cuts heal as well as any others. The possibility of *Mycobacterium marinum* infection must be considered in persistent lesions.

### Pressure ulcers (decubitus)

The bedsore, or decubitus, is a pressure ulcer produced anywhere on the body by prolonged pressure. The pressure sore is caused by ischemia of the underlying structures of the skin, fat, and muscles as a result of sustained and constant pressure. Usually, it occurs in chronically debilitated persons who are unable to change position in bed. The bony prominences of the body are the most frequently affected sites. About 95% of all pressure ulcers develop on the lower body, with 65% in the pelvic area and 30% on the legs. The ulcer usually begins with erythema at the pressure point; in a short time a “punched-out” ulcer develops. Necrosis with a grayish pseudomembrane is seen, especially in the untreated ulcer. Potential complications of pressure ulcers include sepsis, local infection, osteomyelitis, fistulas, and SCC.

More than 100 risk factors have been identified, with diabetes mellitus, peripheral vascular disease, cerebrovascular disease, sepsis, and hypotension being prominent. Pressure ulcers are graded according to a four-stage system, with the earliest being recognized by changes in skin temperature, tissue consistency, and sensation. The lesion first appears as an area of persistent redness. Stage II is a superficial ulcer involving the epidermis and/or dermis. The deeper stage III



ulcers damage the subcutaneous fat and stage IV, the muscle, bone, tendon, or joint capsule.

Prevention relies on redistributing pressure at a minimum interval of 2 h. Treatment consists of relief of the pressure on the affected parts by frequent change of position, meticulous nursing care, and use of air-filled products, liquid-filled flotation devices, or foam products. Other measures include ulcer care, management of bacterial colonization and infection, surgical repair if necessary, continual education, adequate nutrition, management of pain, and provision of psychosocial support.

Ulcer care is critical. Debridement may be accomplished by sharp, mechanical, enzymatic, and autolytic measures, at least once weekly. In some patients, operative care will be required. Stable heel ulcers are an exception; debridement is unnecessary if only a dry eschar is present. Wounds should be cleaned initially and each dressing changed by a nontraumatic technique. Normal saline rather than peroxide or povidone-iodine is best. Selection of a dressing should ensure that the ulcer tissue remains moist and the surrounding skin dry.

Occlusive dressings include more than 300 products, generally classified as films, alginates, foams, hydrogels, hydrofibers, and hydrocolloid dressings. Transparent films are used only for stage II ulcers because they provide light drainage, whereas hydrofibers are used only for full-thickness stage III and IV ulcers. Surgical debridement with reconstructive procedures may be necessary. Adjuvant therapies such as ultrasound, laser, UV radiation, hyperbaric oxygen, electrical stimulation, radiant heat, application of growth factors, cultured keratinocyte grafts, skin substitutes, and miscellaneous topical and oral agents are being investigated to determine their place in the treatment of these ulcers.

At times, anaerobic organisms colonize these ulcers and cause a putrid odor. The topical application of metronidazole eliminates this odor within 36 h.

### Friction blisters

The formation of vesicles or bullae may occur at sites of combined pressure and friction and may be enhanced by heat and moisture. The feet of military recruits in training, the palms of oarsmen who have not yet developed protective calluses, and the fingers of drummers (drummer's digits) are examples of those at risk. The size of the bulla depends on the site of the trauma. If the skin is tense and uncomfortable, the blister should be drained, but the roof should not be completely removed because it may act as its own dressing.

In studies focusing on the prevention of friction blister of the feet in long-distance runners and soldiers, acrylic fiber socks with drying action have been found to be effective. Additionally, pretreatment with a 20% solution of aluminum chloride hexahydrate for at least 3 days has been shown to reduce foot blisters significantly after prolonged hiking, but at the expense of skin irritation. Emollients decrease the irritation but reduce the overall effectiveness of the treatment.

### Fracture blisters

Fracture blisters overlie sites of closed fractures, especially the ankle and lower leg. The blisters appear a few days to 3 weeks after the injury and are thought to be caused by vascular compromise. Fracture blisters may create complications such as infection and scarring, especially if blood filled or in diabetic patients. The blisters generally heal spontaneously in 5–14 days but may cause delay of surgical reduction of the fracture.

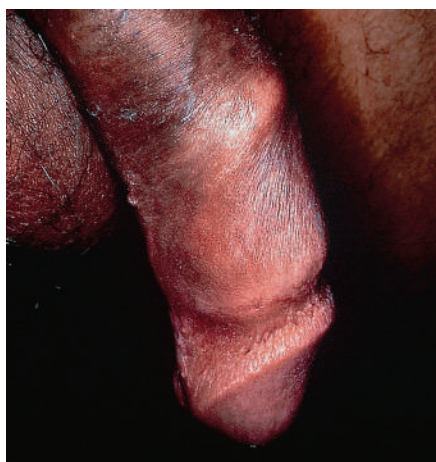

Fig. 3-35 Sclerosing lymphangitis of penis.

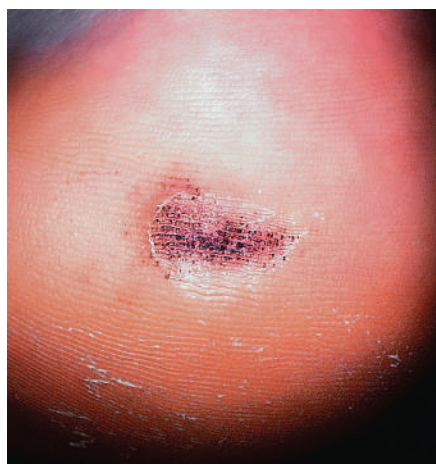


Fig. 3-36 Black heel.

### Sclerosing lymphangitis

This lesion is a cordlike structure encircling the coronal sulcus of the penis or running the length of the shaft and has been attributed to trauma during vigorous sexual play (Fig. 3-35). Most if not all cases result from a superficial thrombophlebitis and thus has been renamed Mondor's disease of the penis. Some early reports favor a lymphatic origin of some cases; CD31 and D240 stains will allow differentiation of future cases. Treatment is not necessary; sclerosing lymphangitis follows a benign, self-limiting course.

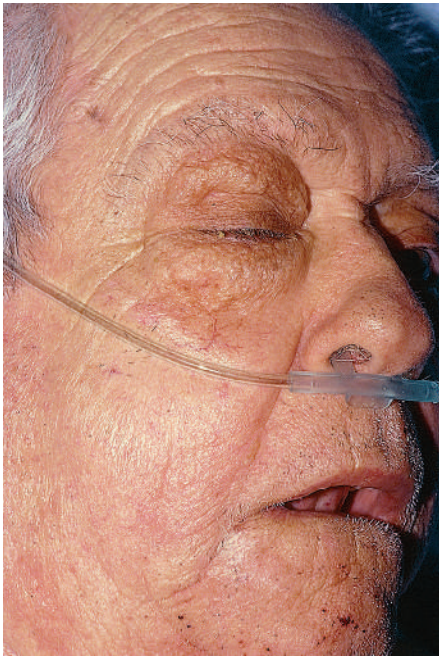### Black heel

Synonyms for black heel include talon noir and calcaneal petechiae. A sudden shower of minute, black, punctate macules occurs most often on the posterior edge of the plantar surface of one or both heels (Fig. 3-36), but sometimes distally on one or more toes. Black heel is often seen in basketball, volleyball, tennis, or lacrosse players. Seeming confluence may lead to mimicry of melanoma. The bleeding is caused by shearing stress of sports activities. Paring with a No. 15 blade and performing a guaiac test will confirm the diagnosis. Treatment is unnecessary.

### Subcutaneous emphysema

Free air occurring in the subcutaneous tissues is detected by the presence of cutaneous crepitations. Gas-producing





**Fig. 3-37**  
Subcutaneous emphysema.  
(Courtesy of Curt Samlaska, MD).

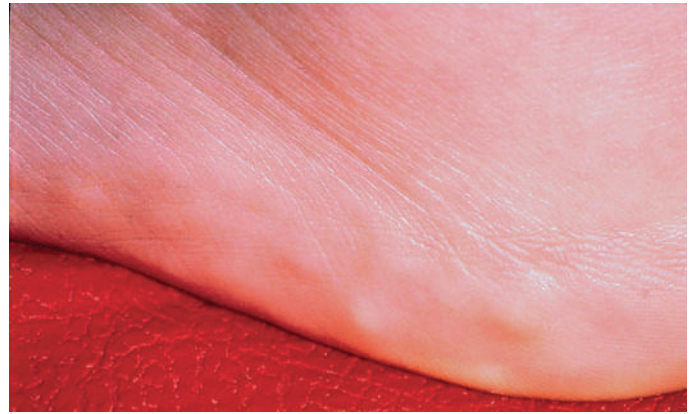
organisms, especially *Clostridia*, and leakage of free air from the lungs or gastrointestinal tract are the most common causes (Fig. 3-37). Samlaska et al. reviewed the wide variety of causes of subcutaneous emphysema, including penetrating and nonpenetrating injuries, iatrogenic causes occurring during various procedures in hospitalized patients, spontaneous pneumomediastinum such as may occur with a violent cough, childbirth, asthma, Boerhaave syndrome (esophageal rupture after vomiting or the Heimlich maneuver), intra-abdominal causes such as inflammatory bowel disease, cancer, perirectal abscess, pancreatitis or cystitis, dental procedures when using air pressure instruments and high-speed drills, and factitial disease.

### Traumatic asphyxia

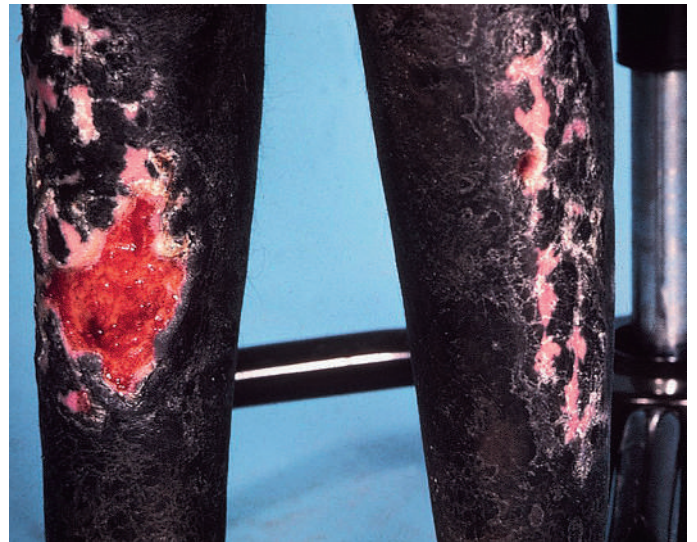Cervicofacial cyanosis and edema; multiple petechiae of the face, neck, and upper chest; and bilateral subconjunctival hemorrhage may occur after prolonged crushing injuries of the thorax or upper abdomen. Such trauma reverses blood flow in the superior vena cava or its tributaries.

### Painful fat herniation

Also called painful piezogenic pedal papules, this rare cause of painful feet represents fat herniations through thin fascial layers of the weight-bearing parts of the heel (Fig. 3-38). These dermatoceles become apparent when weight is placed on the heel and disappear as soon as the pressure is removed. These fat herniations are present in many people, but the majority experience no symptoms. However, extrusion of the fat tissue together with its blood vessels and nerves may initiate pain on prolonged standing. Avoidance of prolonged standing will relieve this pain. Other options include taping of the foot, use of compression stockings, or use of plastic heel cups or padded orthotic devices to restrict the herniations. Laing et al. found 76% of 29 patients had pedal papules, and interestingly, by placing pressure on the wrists, found 86% to have piezogenic wrist papules.



**Fig. 3-38** Piezogenic papules.



**Fig. 3-39** Ulceration secondary to "skin popping."

### Narcotic dermopathy

Heroin (diacetylmorphine) is a narcotic prepared for injection by dissolving the heroin powder in boiling water and then injecting it. The favored route of administration is intravenous. This results in thrombosed, cordlike, thickened veins at the sites of injection. Subcutaneous injection ("skin popping") can result in multiple, scattered ulcerations, which heal with discrete atrophic scars (Fig. 3-39). In addition, amphetamines, cocaine, and other drugs may be injected. Subcutaneous injection may result in infections, complications of bacterial abscess and cellulitis, or sterile nodules, apparently acute foreign body reactions to the injected drug or the adulterants mixed with it. Cocaine-associated vasculitis caused by levamisole is discussed in Chapter 35. These lesions may ulcerate. Chronic persistent firm nodules, a combination of scar and foreign body reaction, may result. If cocaine is being injected, it may cause ulcers because of its direct vasospastic effect. Addicts will continue to inject heroin and cocaine into the chronic ulcer bed.

The cutaneous manifestations of injection of heroin and other drugs also include camptodactyia, edema of the eyelids, persistent nonpitting edema of the hands, urticaria, abscesses, atrophic scars, and hyperpigmentation. Pentazocine abuse leads to a typical clinical picture of tense woody fibrosis, irregular punched-out ulcerations, and a rim of hyperpigmentation at injection sites. Extensive calcification may occur within the thickened sites.

**Alvarez-Garrido H, et al:** Immunohistochemical clues to the diagnosis of Mondor's disease of the penis. *Clin Exp Dermatol* 2009; 34:e663–e665.

**Bae JM, et al:** Differential diagnosis of plantar wart from corn, callus and healed wart with the aid of dermoscopy. *Br J Dermatol* 2009; 160:220–222.

**Berkeley RP, et al:** Rare but serious: recognizing the signs and symptoms of traumatic asphyxia. *JEMS* 2010; 35:30–34.

**Brennan FH Jr, et al:** Blisters on the battlefield. *Mil Med* 2012; 177:157–162.

**Del Giudice P:** Cutaneous complications of intravenous drug abuse. *Br J Dermatol* 2004; 150:1.

**Fleming JD, et al:** Pentazocine-induced cutaneous scarring. *Clin Exp Dermatol* 2013; 39:115–116.

**Garrido-Ruiz MC, et al:** Vulvar pseudoverrucous papules and nodules secondary to a urethral-vaginal fistula. *Am J Dermatopathol* 2011; 33:410–412.

**Grover S:** Pillar knocker's callosities. *Int J Dermatol* 2012; 51:743–744.

**Haitz KA, et al:** Periorbital subcutaneous emphysema mistaken by unilateral angioedema during dental crown preparation. *JAMA Dermatol* 2014; 150:907.

**Hennings C, et al:** Illicit drugs. *J Am Acad Dermatol* 2013; 69:135–142.

**Herring KM, et al:** Friction blisters and sock fiber composition. *J Am Podiatr Med Assoc* 1990; 80:63.

**Knapik JJ, et al:** Influence of an antiperspirant on foot blister incidence during cross-country hiking. *J Am Acad Dermatol* 1998; 39:202.

**Laing VB, et al:** Piezogenic wrist papules. *J Am Acad Dermatol* 1991; 24:415.

**Levine SM, et al:** An evidence-based approach to the surgical management of pressure ulcers. *Ann Plast Surg* 2012; 69:482–484.

**Ma DL, et al:** Piezogenic pedal papules. *CMAJ* 2013; 185:e847.

**Mailler-Savage EA, et al:** Skin manifestations of running. *J Am Acad Dermatol* 2006; 55:290.

**Moore ZE, et al:** Risk assessment tools for the prevention of pressure ulcers. *Cochrane Database Syst Rev* 2008; CDC006471.

**Niederhauser A, et al:** Comprehensive programs for preventing pressure ulcers. *Adv Skin Wound Care* 2012; 25:167–188.

**Reddy M, et al:** Treatment of pressure ulcers: a systematic review. *JAMA* 2008; 300:2647–2662.

**Rudolph RI:** Skin manifestations of cocaine use. *J Am Acad Dermatol* 2009; 60:346–347.

**Samlaska CP, et al:** Subcutaneous emphysema. *Adv Dermatol* 1996; 11:117.

**Strumia R:** Skin signs of anorexia nervosa. *Dermatoendocrinology* 2009; 1:268–270.

**Uebbing CM, et al:** Fracture blisters. *West J Emerg Med* 2011; 12:131–132.

**Urbina F, et al:** Black heel, talon noir or calcaneal petechiae? *Australas J Dermatol* 2008; 49:148–151.

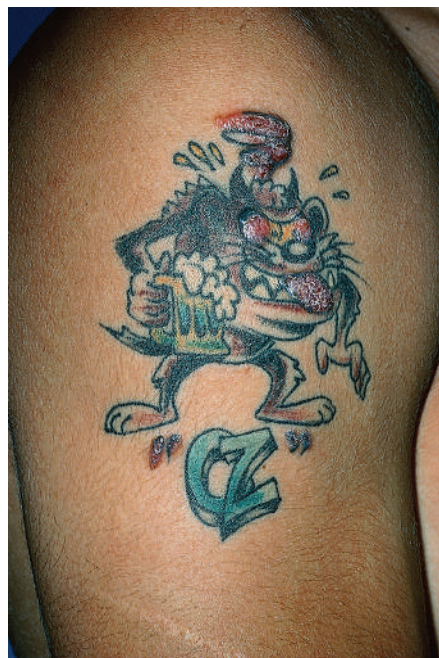**Verma SB, et al:** Callosities of cross legged sitting. *Int J Dermatol* 2008; 47:1212–1214.

**Wilcox JR, et al:** Frequency of debridements and time to heal. *JAMA Dermatol* 2013; 149:1050–1058.

## FOREIGN BODY REACTIONS

### Tattoo

Tattoos result from the introduction of insoluble pigments into the skin. They may be traumatic, cosmetic, or medicinal in nature and may be applied by a professional or an amateur. Pigment is applied to the skin, and then needles pierce the skin to force the material into the dermis. Pigments used include carmine, indigo, vermilion, India ink, chrome green, magnesium (lilac color), Venetian red, aluminum, gold, titanium (white color) or zinc oxide, lead carbonate, copper, iron, logwood, cobalt blue, cinnabar (mercuric sulfide), and cadmium sulfide. Cadmium, cobalt, mercury, and lead are not



**Fig. 3-40** Red tattoo reaction. (Courtesy of Curt Samlaska, MD).

often used; however, occasional photosensitive reactions to cadmium, which was used for yellow color or to brighten the cinnabar red, are still seen. “Invisible tattoos,” seen only under UV light, have ingredients such as polymethylmethacrylate and melamine that may cause granulomatous reactions.

Tattoo-associated dermatopathies may be reactive (allergic, lichenoid, granulomatous, or photosensitive) (Fig. 3-40) or infective (inoculation of syphilis, infectious hepatitis, tuberculosis, HIV, warts, molluscum, Hansen's disease) or may induce a Koebner response in patients with active lichen planus or psoriasis. Discoid lupus erythematosus has been reported to occur in the red-pigmented portion of tattoos. Tattoos over nevi may delay the diagnosis of melanoma. Occasionally, the tattoo marks may become keloidal. Severe allergic reactions to “temporary tattoos” (painting of pigments such as henna on surface of skin) occur when the allergen *p*-phenylenediamine is added to make the color more dramatic.

Red tattoos are the most common cause of delayed reactions, with the histologic findings typically showing a lichenoid process. Occasionally, a pseudolymphomatous reaction may occur in red tattoos. Dermatitis in areas of red (mercury), green (chromium), or blue (cobalt) have been described in patients who are patch test positive to these metals. Sarcoid, foreign body, and allergic granulomatous reactions may also occur within tattoos; aluminum may induce such reactions.

Treatment of such reactions is with topical or intralesional steroids. Excision is also satisfactory when the lesions are small enough and situated so that ellipsoid excisions are feasible. Reactions may also be successfully treated with Q-switched lasers, at times combined with ablative fractional resurfacing. Generalized allergic reactions occasionally occur; prevention by treatment with oral steroids and antihistamines has been suggested. Tattoo darkening can occur, as well as no response to laser treatment. Caution must be used when treating flesh-colored and pink-red tattoos because they may darken after treatment, likely caused by the reduction of ferric oxide to ferrous oxide. White ink, composed mostly of titanium dioxide, is often used to brighten green, blue, yellow, and purple tattoos. Laser irradiation reduces titanium to a blue-colored pigment. Test areas are recommended when treating light-colored facial tattoos. CO<sub>2</sub> resurfacing lasers used conservatively are an alternative to the Q-switched lasers in such patients (see Chapter 38).



## Paraffinoma (sclerosing lipogranuloma)

Injection of oils into the skin for cosmetic purposes, such as the smoothing of wrinkles and the augmentation of breasts, was popular in the past. Paraffin, camphorated oil, cottonseed or sesame oil, mineral oil, and beeswax may produce plaque-like indurations with ulcerations within months and up to 40 years. Several reports document penile paraffinomas caused by self-injection. When petroleum jelly (Vaseline) gauze or a topical ointment is used to dress unsutured wounds, lipogranulomas or inflammatory mild erysipelas-like lesions with marked tenderness may occur. Present treatment methods for sclerosing lipogranuloma are unsatisfactory. Surgical removal must be wide and complete.

## Granulomas

### Silicone granuloma

Liquid silicones, composed of long chains of dimethyl siloxy groups, are biologically inert. Silicones have been used for correcting wrinkles, reducing scars, and building up atrophic depressed areas of the skin. Many case reports detail granulomatous reactions to silicone, some with migration and reactive nodules at points distant from the injection site (Figs. 3-41 and 3-42). Acupuncture needles are coated with silicone, and granulomas may occur at the entry points. The incidence of the

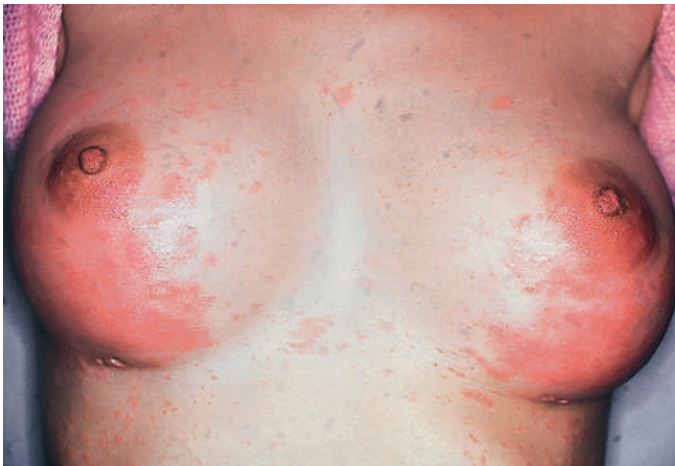

Fig. 3-41 Silicone reaction.

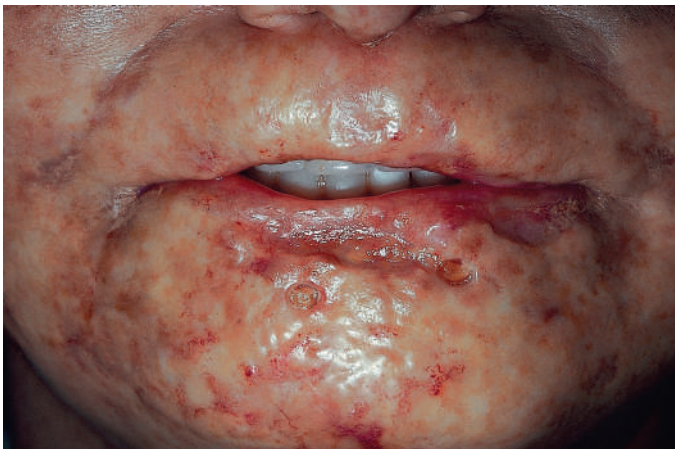

Fig. 3-42 Silicone granuloma.

nodular swellings, which may be quite destructive and treatment resistant, remains unknown. It is clear that, if used off label, medical-grade silicone injected in small volume should be the rule, and it should not be injected into the penis or the glandular tissue of the breast.

For breast augmentation, silicone may be used as Silastic implants. If trauma causes rupture of the bag, subcutaneous fibrotic nodules often develop. Human adjuvant disease and sclerodermatous reactions after such events have been reported; however, large reviews have failed to establish an etiologic link to silicone and connective tissue disease.

Treatment of silicone granulomas is often not successful. Surgical removal may lead to fistulas, abscesses, and marked deformity. Both minocycline, 100 mg twice daily for several months, and imiquimod cream have been anecdotally useful.

Bioplastique consists of polymerized silicone particles dispersed in a gel carrier. When used for lip augmentation, nodules may develop. Histologically, these are foreign body granulomas.

### Mercury granuloma

Mercury may cause foreign body giant cell or sarcoidal-type granulomas (Fig. 3-43), pseudolymphoma, or membranous fat necrosis. It is usually identifiable as egg shaped, extracellular, dark-gray to black, irregular globules. The gold lysis test is positive in tissues. Energy-dispersive radiographic spectroscopy may be done and will identify mercury by the characteristic emission spike. Such testing may be helpful in identifying any foreign substance suspected to have been implanted accidentally or intentionally by the patient. Systemic toxicity or embolus may develop from mercury and may result in death. Therefore, excision is necessary and can be accomplished under x-ray guidance.

### Beryllium granuloma

Beryllium granuloma is seen as a chronic, persistent, granulomatous inflammation of the skin with ulceration that may follow accidental laceration, usually in an occupational setting.

### Zirconium granuloma

A papular eruption involving the axillae is sometimes seen as an allergic reaction in those shaving their armpits and using a deodorant containing zirconium (Fig. 3-44). Although zirconium was eliminated from aerosol-type deodorants in 1978, aluminum-zirconium complex is present in some antiperspirants. Additionally, various poison ivy lotions contain

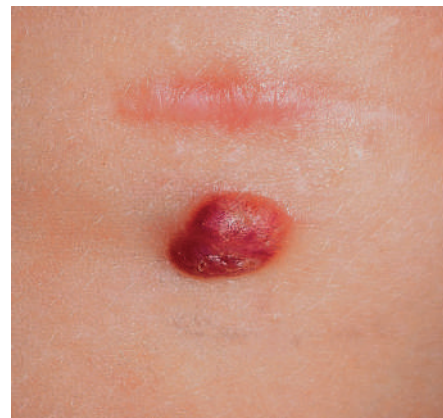
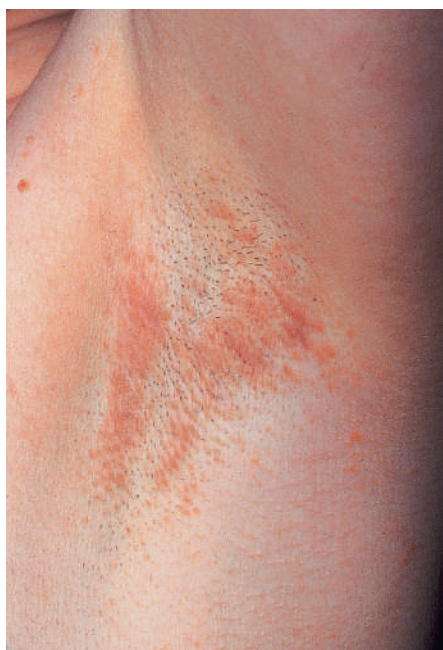
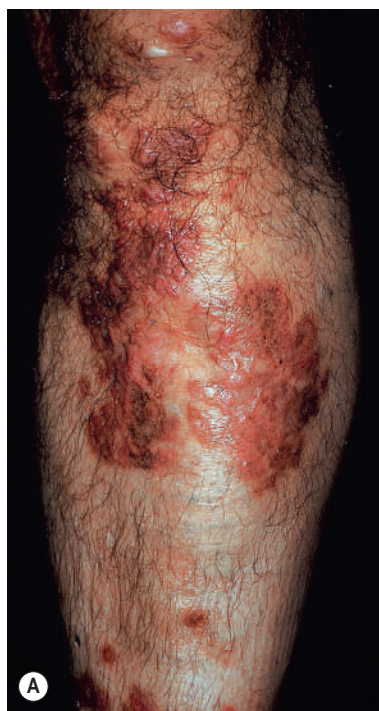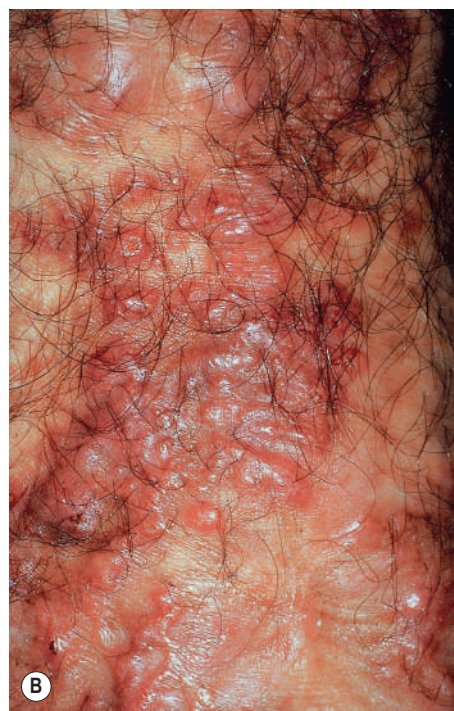Fig. 3-43 Mercury granuloma.



**Fig. 3-44** Aluminum-zirconium granuloma secondary to antiperspirant use.



**Fig. 3-45** A and B, Silica granuloma years after motorcycle crash.



zirconium compounds. The lesions are brownish red, dome-shaped, shiny papules. This is an acquired, delayed-type, allergic reaction resulting in a granuloma of the sarcoidal type. After many months, the lesions involute spontaneously.

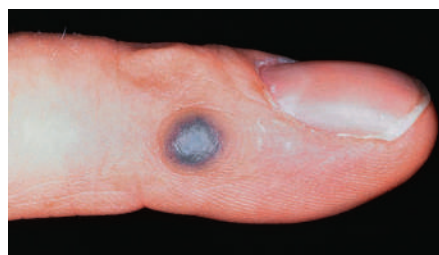
### Silica granuloma

Automobile crashes and other types of trauma may produce tattooing of dirt (silicon dioxide) into the skin, which induces silica granulomas (Fig. 3-45). These typically present as black or blue papules or macules arranged in a linear fashion. At times, the granulomatous reaction to silica may be delayed for many years, with the ensuing reaction being both chronic and disfiguring. The granulomas may be caused by amorphous or crystalline silicon dioxide (quartz), magnesium silicate (talcum), or complex polysilicates (asbestos). Talc granulomas of the skin and peritoneum may develop after surgery from the talcum powder used on surgical gloves. Silica granulomas have a statistical association with systemic sarcoidosis, and silica may act as a stimulus for granuloma formation in patients with latent sarcoidosis.

Removal of these granulomas is fraught with difficulties. The best method of care is immediate and complete removal to prevent these reactions. Excision and systemic steroids have been used, but recurrences are common. Some reactions may subside spontaneously after 1–12 months. Dermabrasion is a satisfactory method for the removal of dirt accidentally embedded into the skin of the face or scalp.

### Carbon stain

Discoloration of the skin from embedded carbon usually occurs in children from improper use of firearms or fireworks or from a puncture wound by a pencil, which may leave a permanent black mark of embedded graphite, easily mistaken for a metastatic melanoma (Fig. 3-46). Narcotic addicts who attempt to clean needles by flaming them with a lighted match may tattoo the carbon formed on the needle as it is inserted



**Fig. 3-46** Graphite granuloma.

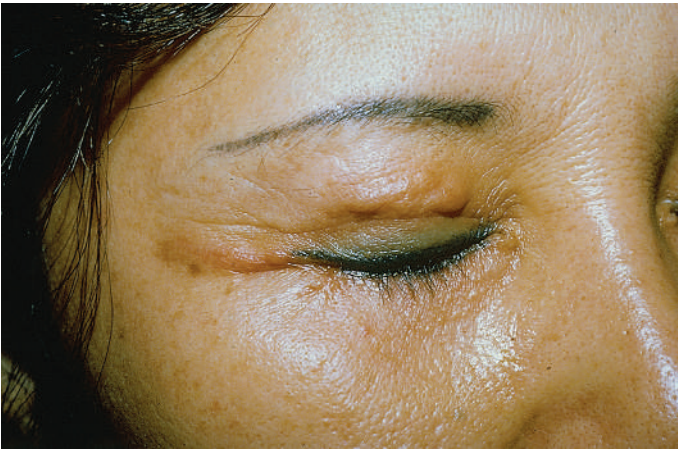
into the skin. The carbon is deposited at various depths, which produces a connective tissue reaction and sometimes even keloids.

Carbon particles may be removed immediately after their deposition using a toothbrush and forceps. This expeditious and meticulous early care results in the best possible cosmetic result. If the particles are left in place long enough, they are best removed using the Q-switched Nd:YAG laser at 1064 nm. In one series success was reported in 50 of 51 treated tattoos with an average of 1.7 treatments. However, microexplosions producing poxlike scars have occurred with each laser pulse. Alternatively, dermabrasion may be used.

### Injected filler substances

Injected or implanted filler substances used for facial rejuvenation may produce foreign body or sarcoidal granulomas. Palpable thickening and nodules (Fig. 3-47), which are occasionally painful, have been reported with collagen, hyaluronic acid and acrylic hydrogels, and polyactic acid, polyalkylimide, and polymethylmethacrylate microspheres. The reaction may be delayed for years; at times, patients are reluctant to admit to these prior cosmetic interventions and frequently cannot name the filler used. Topical, intralesional, or systemic steroids, sometimes augmented by tacrolimus, and minocycline or doxycycline have been reported to be helpful medical interventions.





**Fig. 3-47** Injected filler reaction.

**Alani RM, et al:** Acupuncture granulomas. *J Am Acad Dermatol* 2001; 45:S225.

**Alijotas-Reig J, et al:** Delayed immune-mediated adverse effects of polyalkylimide dermal fillers. *Arch Dermatol* 2008; 144:637.

**Almeida PJ, et al:** Quantification of *p*-phenylenediamine and 2-hydroxy-1,4-naphthoquinone in henna tattoos. *Contact Dermatitis* 2012; 66:33–37.

**Altmyer MD, et al:** Cutaneous mercury granuloma. *Cutis* 2011; 88:189–193.

**Angus JE, et al:** Two cases of delayed granulomatous reactions to the cosmetic filler Dermalive. *Br J Dermatol* 2006; 154:1074.

**Antonovitch DD, et al:** Development of sarcoidosis in cosmetic tattoos. *Arch Dermatol* 2005; 141:869.

**Bachmeyer C, et al:** Penile paraffinoma developing during treatment with pegylated interferon alfa-2a for chronic hepatitis C virus infection. *Arch Dermatol* 2011; 147:1232–1233.

**Bigata X, et al:** Adverse granulomatous reaction after cosmetic dermal silicone injection. *Dermatol Surg* 2001; 27:198.

**Boztepe G, et al:** Cutaneous silica granuloma. *Eur J Dermatol* 2005; 15:194.

**Choudhary S, et al:** Lasers for tattoo removal. *Lasers Med Sci* 2010; 25:619–627.

**Dadzie OE, et al:** Adverse cutaneous reactions to soft tissue fillers: a review of the histological features. *J Cutan Pathol* 2008; 35:536–548.

**England RW, et al:** Immediate cutaneous hypersensitivity after treatment of tattoo with Nd:YAG laser. *Ann Allergy Asthma Immunol* 2002; 89:215.

**Fusade T, et al:** Treatment of gunpowder traumatic tattoo by Q-switched Nd:YAG laser. *Dermatol Surg* 2000; 26:1057.

**Garcovich S, et al:** Lichenoid red tattoo reaction. *Eur J Dermatol* 2010; 22:93–96.

**Gormley RH, et al:** Role for trauma in introducing pencil “lead” granuloma in the skin. *J Am Acad Dermatol* 2010; 62:1074.

**Hou M, et al:** Cutaneous silica granuloma with generalized involvement of lymph nodes. *J Dermatol* 2011; 38:697–701.

**Kazandjieva J, et al:** Tattoos: dermatological complications. *Clin Dermatol* 2007; 25:375.

**Kenmochi A, et al:** Silica granuloma induced by indwelling catheter. *J Am Acad Dermatol* 2007; 57:S54.

**Klontz KL, et al:** Adverse effects of cosmetic tattooing. *Arch Dermatol* 2005; 141:918.

**Lowe NJ, et al:** Adverse reactions to dermal fillers. *Dermatol Surg* 2005; 31:1616.

**Mafong EA, et al:** Removal of cosmetic tattooing with the pulsed carbon dioxide laser. *J Am Acad Dermatol* 2003; 48:271.

**Montemarano AD, et al:** Cutaneous granulomas caused by an aluminum-zirconium complex. *J Am Acad Dermatol* 1997; 37:496.

**Mortimer NJ, et al:** Red tattoo reactions. *Clin Exp Dermatol* 2003; 28:508.

**Ortiz AE, et al:** Rising concern over cosmetic tattoos. *Dermatol Surg* 2012; 38:424–429.

**Ross EV, et al:** Tattoo darkening and nonresponse after laser treatment. *Arch Dermatol* 2001; 137:33.

**Rossmann MD:** Chronic beryllium disease. *Appl Occup Environ Hyg* 2001; 16:615.

**Sclafarni AP, et al:** Treatment of injectable soft tissue filler complications. *Dermatol Surg* 2009; 35(Suppl 2):1672.

**Senet P, et al:** Minocycline for the treatment of cutaneous silicone granulomas. *Br J Dermatol* 1999; 140:963.

**Shimizu I, et al:** Metal-induced granule deposition with pseudochronosis. *J Am Acad Dermatol* 2010; 63:357–359.

**Suwanasuthi S, et al:** *Mycobacterium fortuitum* cutaneous infection from amateur tattoo. *J Med Assoc Thai* 2012; 95:834–847.

**Tamaro A, et al:** Contact allergic dermatitis to gold in a tattoo. *Int J Immunopathol Pharmacol* 2011; 24:1111–1113.

**Timko AL, et al:** In vitro quantitative chemical analysis of tattoo pigments. *Arch Dermatol* 2001; 137:143.

**Tsang M, et al:** A visible response to an invisible tattoo. *J Cutan Pathol* 2012; 39:877–880.

**Uchida Y, et al:** Facial paraffinoma after cosmetic paraffin injection. *J Dermatol* 2007; 34:798.

**Vagefi MR, et al:** Adverse reactions to eyeliner tattoo. *Ophthal Plast Reconstr Surg* 2006; 22:48.

**Vargas-Machuca I, et al:** Facial granulomas secondary to Dermalive microimplants. *Am J Dermatopathol* 2006; 28:173.

**Wolfram D, et al:** Surgery for foreign body reactions to injectable fillers. *Dermatology* 2006; 213:300.



Bonus images for this chapter can be found online at

[expertconsult.inkling.com](http://expertconsult.inkling.com)

**eFig. 3-1** Pernio (chilblain).

**eFig. 3-2** Stellate pseudoscars.

**eFig. 3-3** Colloid milium.

**eFig. 3-4** Berloque dermatitis.

**eFig. 3-5** Chronic actinic dermatitis.

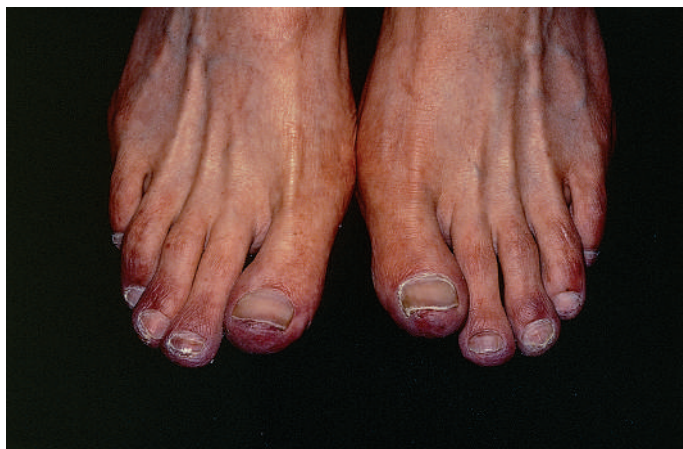**eFig. 3-6** Acute radiation burn during treatment of epithelioid sarcoma.

**eFig. 3-7** Prayer calluses.

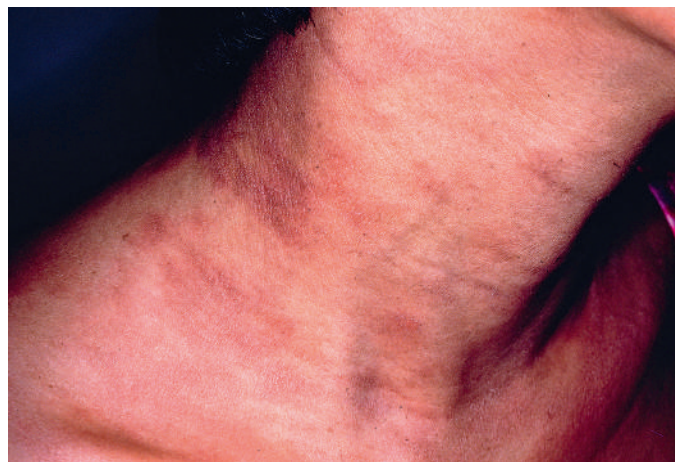
**eFig. 3-8** Scars caused by “skin popping”

**eFig. 3-9** Red tattoo reaction. (Courtesy of Curt Samlaska, MD.)

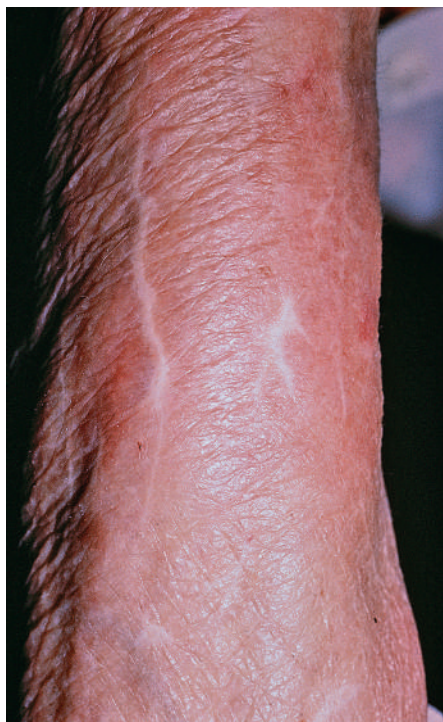



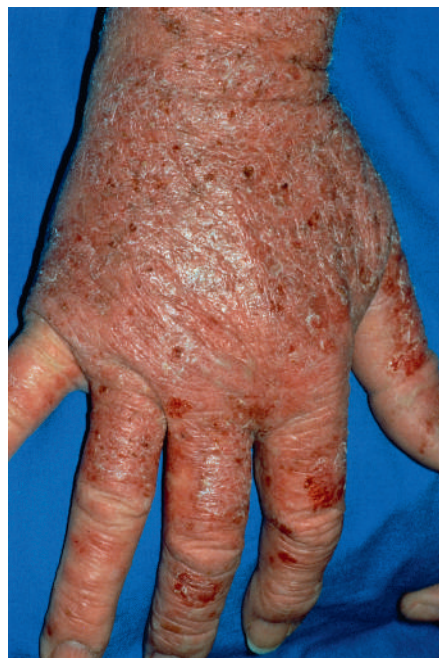eFig. 3-1 Pernio (chilblain).



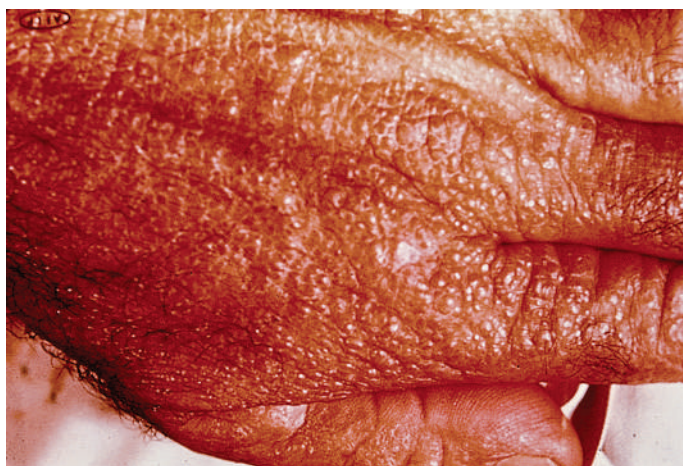eFig. 3-4 Berloque dermatitis.



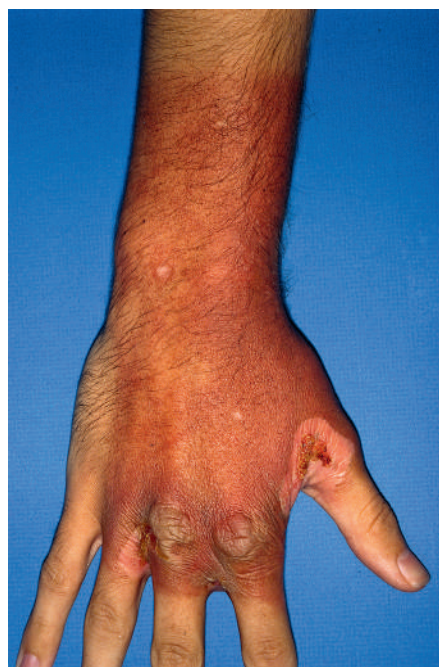eFig. 3-2 Stellate pseudoscars.



eFig. 3-5 Chronic actinic dermatitis.

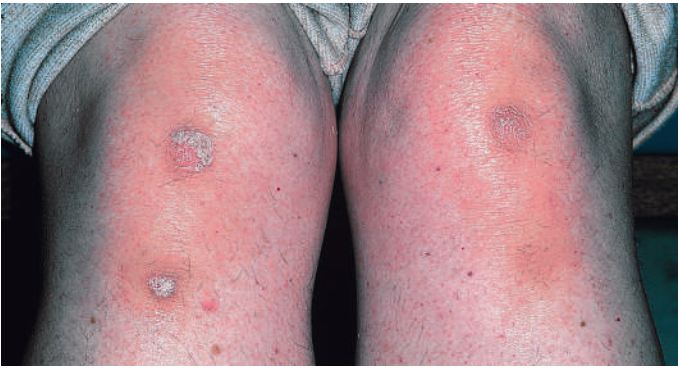


eFig. 3-3 Colloid milium.

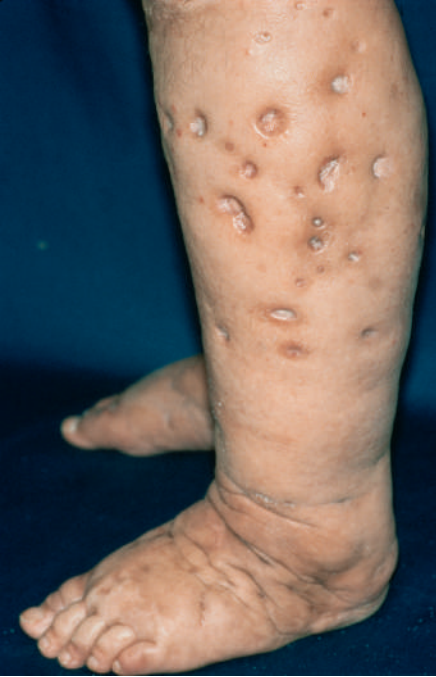

eFig. 3-6 Acute radiation burn during treatment of epithelioid sarcoma.





**eFig. 3-7** Prayer calluses.



**eFig. 3-8** Scars caused by "skin popping"



**eFig. 3-9** Red tattoo reaction. (Courtesy of Curt Samlaska, MD.)



# 4

## Pruritus and Neurocutaneous Dermatoses

### PRURITUS

Pruritus, commonly known as itching, is a sensation exclusive to the skin. It may be defined as the sensation that produces the desire to scratch. Pruritogenic stimuli are first responded to by keratinocytes, which release a variety of mediators, and fine intraepidermal C-neuron filaments. Approximately 5% of the afferent unmyelinated C neurons respond to pruritogenic stimuli. Itch sensations in these nerve fibers are transmitted via the lateral spinothalamic tract to the brain, where a variety of foci generate both stimulatory and inhibitory responses. The sum of this complicated set of interactions appears to determine the quality and intensity of itch.

Itching may be elicited by many normally occurring stimuli, such as light touch, temperature change, and emotional stress. Chemical, mechanical, and electrical stimuli may also elicit itching. The brain may reinterpret such sensations as being painful or causative of burning or stinging sensations. A large group of neuromediators and their receptors have been identified. Some of the most important mediators are histamine and the H4 receptor, tryptase and its proteinase-activated receptor type 2, opioid peptides and the mu ( $\mu$ ) and kappa ( $\kappa$ ) opioid receptors, leukotriene B4, prostaglandins such as PGE, acetylcholine, cytokines such as interleukin-31 (IL-31), and a variety of neuropeptides and vasoactive peptides (e.g., nerve growth factor) and their receptors (e.g., vanilloid). Investigation is ongoing to discover the relative importance of each of these mediators and to determine the clinical circumstances under which therapeutic targeting of these molecules will lead to relief of symptoms.

Itch has been classified into four primary categories, as follows:

- Pruritoceptive itch, initiated by skin disorders
- Neurogenic itch, generated in the central nervous system and caused by systemic disorders
- Neuropathic itch, caused by anatomic lesions of the central or peripheral nervous system
- Psychogenic itch, the type observed in parasitophobia

An overlap or mixture of these types may be causative in any individual patient.

### Patterns of itching

There are wide variations in itching from person to person, and a person may have a variation in reactions to the same stimulus. Heat will usually aggravate preexisting pruritus. Stress, absence of distractions, anxiety, and fear may all enhance itching. Itching tends to be most severe during undressing for bed.

Severe pruritus, with or without prior skin lesions, may be paroxysmal in character with a sudden onset, often severe enough to awaken the patient. It may stop instantly and

completely as soon as pain is induced by scratching. However, the pleasure of scratching is so intense that the patient, despite the realization of damaging the skin, is often unable to stop short of inflicting such damage (Fig. 4-1). Itching of this distinctive type is characteristic of a select group of dermatoses: lichen simplex chronicus, atopic dermatitis, nummular eczema, dermatitis herpetiformis, neurotic excoriations, eosinophilic folliculitis, uremic pruritus, prurigo simplex, paraneoplastic itch (usually secondary to lymphoma), and prurigo nodularis. In general, only these disorders produce such intense pruritus and scratching as to induce bleeding. In individual cases, other diseases may manifest such severe symptoms.

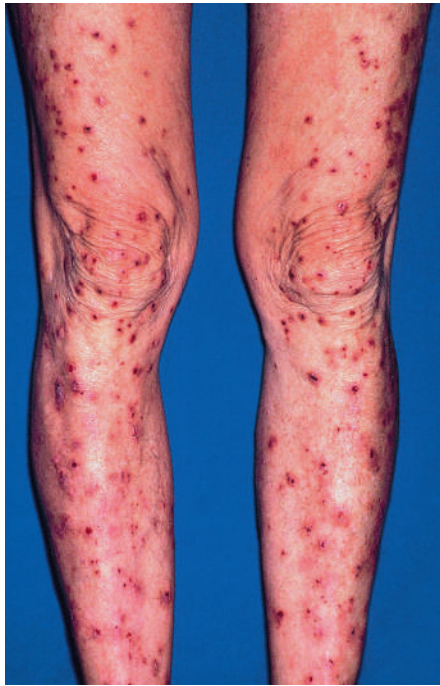### Treatment

General guidelines for therapy of the itchy patient include keeping cool and avoiding hot baths or showers and wool clothing, which is a nonspecific irritant, as is xerosis. Many patients note itching increases after showers, when they wash with soap and then dry roughly. Using soap only in the axilla and inguinal area, patting dry, and applying a moisturizer can often help prevent such exacerbations. Patients often use an ice bag or hot water to ease pruritus; however, hot water can irritate the skin, is effective only for short periods, and over time exacerbates the condition.

Relief of pruritus with topical remedies may be achieved with topical anesthetic preparations. Many contain benzocaine, which may produce contact sensitization. Pramoxine in a variety of vehicles, lidocaine 5% ointment, eutectic mixture of lidocaine and prilocaine (EMLA) ointment, and lidocaine gel are preferred anesthetics that may be beneficial in localized conditions. EMLA and lidocaine may be toxic if applied to large areas. Topical antihistamines are generally not recommended, although doxepin cream may be effective for mild pruritus when used alone. Doxepin cream may cause contact allergy or a burning sensation, and somnolence may occur when doxepin is used over large areas. Topical lotions that contain menthol or camphor feel cool and improve pruritus and may be kept in the refrigerator to enhance this soothing effect. Other lotions have specific ceramide content designed to mimic that of the normal epidermal barrier. Capsaicin, by depleting substance P, can be effective, but the burning sensation present during initial use frequently causes patients to discontinue its use. Topical steroids and calcineurin inhibitors effect a decrease in itching through their anti-inflammatory action and therefore are of limited efficacy in neurogenic, psychogenic, or systemic disease-related pruritus.

Phototherapy with ultraviolet B (UVB), UVA, and psoralen plus UVA (PUVA) may be useful in a variety of dermatoses and pruritic disorders. Many oral agents are available to treat pruritus. Those most frequently used by nondermatologists are the antihistamines. First-generation H1 antihistamines, such as hydroxyzine and diphenhydramine, may be helpful in nocturnal itching, but their efficacy as antipruritics





**Fig. 4-1** Severe pruritus with excoriations.

is disappointing in many disorders, except for urticaria and mastocytosis. Doxepin is an exception in that it can reduce anxiety and depression and is useful in several pruritic disorders. Sedating antihistamines should be prescribed cautiously, especially in elderly patients because of their impaired cognitive ability. The nonsedating antihistamines and H<sub>2</sub> blockers are only effective in urticaria and mast cell disease. Opioids are involved in itch induction. In general, activation of  $\mu$ -opioid receptors stimulates itch, whereas  $\kappa$ -opioid receptor stimulation inhibits itch perception; however, the interaction is complex. Additionally, opioid-altering agents such as naltrexone, naloxone, nalfurafine, and butorphanol have significant side effects and varying modes of delivery (intravenous, intranasal, oral). Initial reports of benefit in one condition are often followed by conflicting reports on further study. Specific recommendations in select pruritic conditions are detailed in those sections. These agents appear most useful for cholestatic pruritus. Central reduction of itch perception may be effected by anticonvulsants, such as gabapentin and pregabalin, and antidepressants, such as mirtazapine and the selective serotonin reuptake inhibitors (SSRIs). Thalidomide, through a variety of direct neural effects, immunomodulatory actions, and hypnotic effects, is also useful in select patients.

**Elmariah SB, et al:** Topical therapies for pruritus. *Semin Cutan Med Surg* 2011; 30:118–126.

**Feramisco JD, et al:** Innovative management of pruritus. *Dermatol Clin* 2010; 28:467–478.

**Greaves MW:** Pathogenesis and treatment of pruritus. *Curr Allergy Asthma Rep* 2010; 10:236–242.

**Ikoma A, et al:** Anatomy and neurophysiology of pruritus. *Semin Cutan Med Surg* 2011; 30:64–70.

**Matterne U, et al:** Prevalence, correlates and characteristics of chronic pruritus. *Acta Derm Venereol* 2011; 91:674–697.

**Metz M, et al:** Chronic pruritus: pathogenesis, clinical aspects and treatment. *J Eur Acad Dermatol Venereol* 2010; 24:1249–1260.

**Patel T, et al:** Therapy of pruritus. *Expert Opin Pharmacother* 2010; 11:1673.

**Siepmann D, et al:** Evaluation of the German guideline for chronic pruritus. *Dermatology* 2011; 223:374–480.

**Steinhoff M, et al:** Pruritus. *Semin Cutan Med Surg* 2011; 30:127–137.

**Tey HL, et al:** Targeted treatment of pruritus. *Br J Dermatol* 2011; 165:5–17.

**Weisshaar I, et al:** European guideline on chronic pruritus. *Acta Derm Venereol* 2012; 92:563–581.

**Yosipovitch G, et al:** Chronic pruritus. *N Engl J Med* 2013; 368:1625–1634.

## Internal causes of pruritus

Itching may be present as a symptom in a number of internal disorders. The intensity and duration of itching vary from one disease to another. The most important internal causes of itching include liver disease, especially obstructive and hepatitis C (with or without evidence of jaundice or liver failure), renal failure, diabetes mellitus, hypothyroidism and hyperthyroidism, hematopoietic diseases (e.g., iron deficiency anemia, polycythemia vera), neoplastic diseases (e.g., lymphoma [especially Hodgkin disease], leukemia, myeloma), internal solid-tissue malignancies, intestinal parasites, carcinoid, multiple sclerosis, acquired immunodeficiency syndrome (AIDS), and neuropsychiatric diseases, especially anorexia nervosa.

The pruritus of Hodgkin disease is usually continuous and at times is accompanied by severe burning. The incidence of pruritus is 10–30% and is the first symptom of this disease in 7% of patients. Its cause is unknown. The pruritus of leukemia, except for chronic lymphocytic leukemia, has a tendency to be less severe than in Hodgkin disease.

Internal organ cancer may be found in patients with generalized pruritus that is unexplained by skin lesions. However, no significant overall increase of malignant neoplasms can be found in patients with idiopathic pruritus. A suggested workup for chronic, generalized pruritus includes a complete history, thorough physical examination, and laboratory tests, including complete blood count (CBC) and differential; thyroid, liver, and renal panels; hepatitis C serology; human immunodeficiency virus (HIV) antibody (if risk factors are present); urinalysis; stool for occult blood; serum protein electrophoresis; and chest x-ray evaluation. Presence of eosinophilia on the CBC is a good screen for parasitic diseases, but if the patient has been receiving systemic corticosteroids, blood eosinophilia may not be a reliable screen for parasitic diseases, and stool samples for ova and parasites should be submitted. Additional radiologic studies or specialized tests are performed as indicated by the patient's age, history, and physical findings. A biopsy for direct immunofluorescence is occasionally helpful to detect dermatitis herpetiformis or pemphigoid.

**Cassano N, et al:** Chronic pruritus in the absence of specific skin disease. *Am J Clin Dermatol* 2010; 11:399–411.

**Greaves MW:** Pathogenesis and treatment of pruritus. *Curr Allergy Asthma Rep* 2010; 10:236–242.

**Ko MJ, et al:** Postprandial blood glucose is associated with generalized pruritus in patients with type 2 diabetes. *Eur J Dermatol* 2013; 23:688–693.

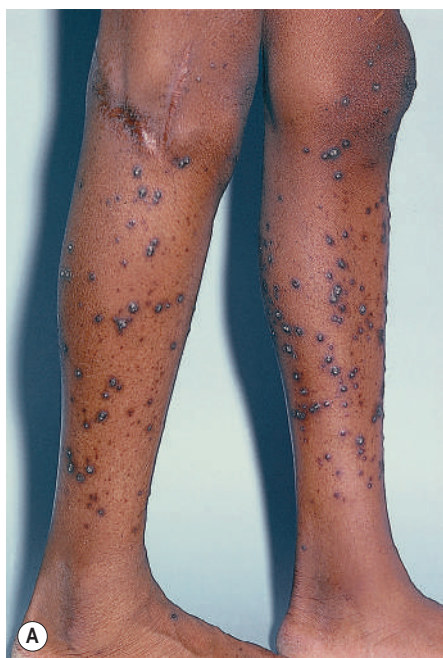**Yosipovitch G:** Chronic pruritus: a paraneoplastic sign. *Dermatol Ther* 2010; 23:590–598.

**Weisshaar I, et al:** European guideline on chronic pruritus. *Acta Derm Venereol* 2012; 92:563–581.

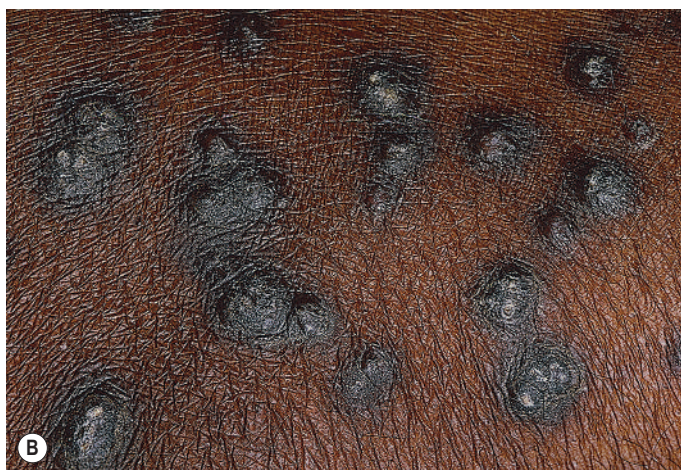## Chronic kidney disease

Chronic kidney disease (CKD) is the most common systemic cause of pruritus; 20–80% of patients with chronic renal failure have itching. The pruritus is often generalized, intractable, and severe; however, dialysis-associated pruritus may be episodic, mild, or localized to the dialysis catheter site, face, or legs.

The mechanism of pruritus associated with CKD is multifactorial. Xerosis, secondary hyperparathyroidism, increased serum histamine levels, hypervitaminosis A, iron deficiency anemia, and neuropathy have been implicated. Complications



**Fig. 4-2** A, Acquired perforating dermatosis of uremia. B, Close-up view of A.



such as acquired perforating disease, lichen simplex chronicus, and prurigo nodularis may develop and contribute to the degree and severity of pruritus (Fig. 4-2).

Many patients have concomitant xerosis, and aggressive use of emollients, including soaking and smearing, may help. A trial of  $\gamma$ -linolenic acid cream twice daily was effective, as was one using baby oil. Gabapentin given three times weekly at the end of hemodialysis sessions can be effective, but its renal excretion is decreased in CKD, so a low initial dose of 100 mg after each session with slow upward titration is recommended. A mainstay of CKD-associated pruritus has been narrow-band (NB) UVB phototherapy, but a randomized controlled trial (RCT) failed to confirm its efficacy. Broad-band UVB may be best in the CKD patient. Naltrexone, topical tacrolimus, and ondansetron also were reported to be useful in initial trials, but subsequent studies indicated these agents are ineffective. Nalfurafine, 5  $\mu$ g once daily after supper, has demonstrated improvement and was relatively well tolerated over a 1-year study. Thalidomide, intranasal butorphanol, and intravenous lidocaine are less practical options. Renal transplantation will eliminate pruritus.

**Berger TG, et al:** Pruritus and renal failure. *Semin Cutan Med Surg* 2011; 30:99–100.

**Ko MJ, et al:** Narrowband ultraviolet B phototherapy for patients with refractory uraemic pruritus. *Br J Dermatol* 2011; 165:633–639.

**Kfoury LW, et al:** Uremic pruritus. *J Nephrol* 2012; 25:644–652.

**Kumagai H, et al:** Efficacy and safety of a novel  $\kappa$ -agonist for managing intractable pruritus in dialysis patients. *Am J Nephrol* 2012; 36: 175–183.

**Lin T-C, et al:** Baby oil therapy for uremic pruritus in haemodialysis patients. *J Clin Nurs* 2011; 21:139–148.

**Yue J, et al:** Comparison of pregabalin with ondansetron in treatment of uraemic pruritus in dialysis patients. *Int Urol Nephrol* 2014; Aug 7.

## Biliary pruritus

Chronic liver disease with obstructive jaundice may cause severe generalized pruritus, and 20–50% of patients with jaundice have pruritus. Intrahepatic cholestasis of pregnancy, primary sclerosing cholangitis, and hereditary cholestatic diseases such as Alagille syndrome all have pruritus in common. Another disease, primary biliary cirrhosis, is discussed separately next because of its many other cutaneous manifestations. Hepatitis C may be associated with pruritus as well.

Itching of biliary disease is probably caused by central mechanisms. The pathophysiology is not well understood, but it appears that lysophosphatidic acid, formed by the action of the enzyme autotaxin on lysophosphatidylcholine, is central. The serum conjugated bile acid levels do not correlate with the severity of pruritus, and the theory invoking endogenous opioids as the main cause has not been upheld by recent studies.

Pruritus of chronic cholestatic liver disease is improved with cholestyramine, 4–16 g daily. Rifampin, 150–300 mg/day, may be effective but should be used with caution because it may cause hepatitis. Naltrexone, up to 50 mg/day, is useful but has significant side effects. If used, naltrexone should be started at  $\frac{1}{4}$  tablet (12.5 mg) and increased by  $\frac{1}{4}$  tablet every 3 to 7 days until pruritus improves. Sertraline, 75–100 mg/day, is another option. UVB phototherapy was effective in a small case series. Ursodeoxycholic acid is effective for the pruritus in intrahepatic cholestasis of pregnancy, but not for the itching of primary biliary cirrhosis from other causes. Liver transplantation is the definitive treatment for end-stage disease and provides dramatic relief from the severe pruritus.

### Primary biliary cirrhosis

Primary biliary cirrhosis occurs almost exclusively in women older than 30. Itching may begin insidiously and may be the presenting symptom in a quarter to half of patients. With time, extreme pruritus develops in almost 80% of patients. This almost intolerable itching is accompanied by jaundice and a striking melanotic hyperpigmentation of the entire skin; the patient may turn almost black, except for a hypopigmented “butterfly” area in the upper back. Eruptive xanthomas, planar xanthomas of the palms (Fig. 4-3), xanthelasma, and tuberous xanthomas over the joints may be seen.

Dark urine, steatorrhea, and osteoporosis occur frequently. Serum bilirubin, alkaline phosphatase, serum ceruloplasmin, serum hyaluronate, and cholesterol values are increased. The antimitochondrial antibody test is positive. The disease is usually relentlessly progressive with the development of hepatic failure. Several cases have been accompanied by scleroderma.

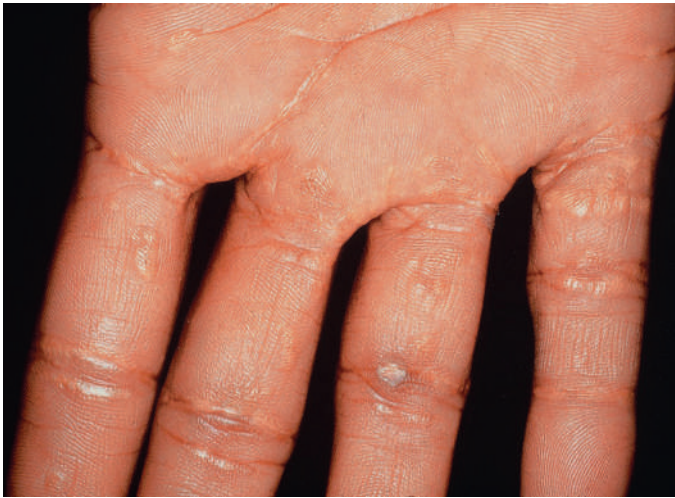**Beuers U, et al:** Pruritus in cholestasis: facts and fiction. *Hepatology* 2014; 1:399–407.

**Bunchornatavakul C, et al:** Pruritus in chronic cholestatic liver disease. *Clin Liver Dis* 2012; 16:331–346.

**Decock S, et al:** Cholestasis-induced pruritus treated with ultraviolet B phototherapy. *J Hepatol* 2012; 57:637–641.

**Imam MH, et al:** Pathogenesis and management of pruritus in cholestatic liver disease. *J Gastroenterol Hepatol* 2012; 27:1150–1158.





**Fig. 4-3** Primary biliary cirrhosis with plane xanthomas.

**Uibo R, et al:** Primary biliary cirrhosis: a multi-faced interactive disease involving genetics, environment and the immune response. *APMIS* 2012; 120:857–871.

### Polycythemia vera

More than one third of patients with polycythemia vera report pruritus; it is usually induced by temperature changes or several minutes after bathing. The cause is unknown.

Aspirin has been shown to provide immediate relief from itching; however, there is a risk of hemorrhagic complications. PUVA and NB UVB are also effective. A marked improvement is noted after an average of six treatments, with complete remission often occurring in 2–10 weeks. Paroxetine, 20 mg/day, produced clearing or near-complete clearing in a series of nine patients. Interferon (IFN) alpha-2 has been shown to be effective for treating the underlying disease and associated pruritus. Two new options are being tested based on the knowledge that polycythemia vera results from a *Jak2*-activating mutation. *Jak2* inhibitors and *mTOR* inhibitors have shown dramatic results in the relief of pruritus in limited early trials.

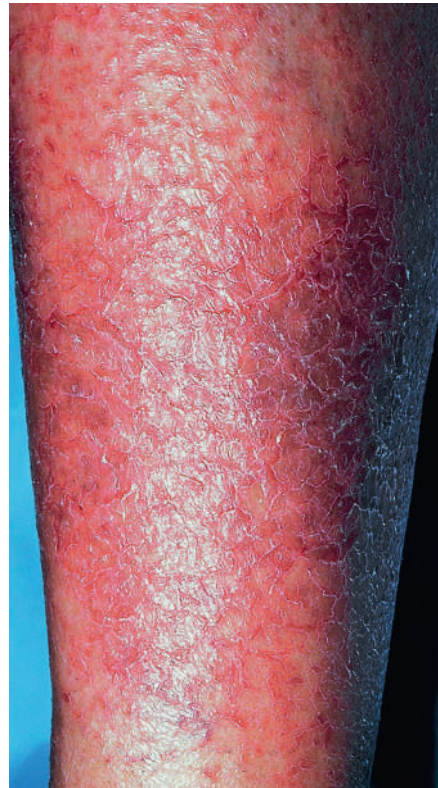**Saini KS, et al:** Polycythemia vera–associated pruritus and its management. *Eur J Clin Invest* 2010; 40:828–834.

## PRURITIC DERMATOSES

### Winter itch

Asteatotic eczema, eczema craquelé, and xerotic eczema are other names for this pruritic condition. Winter itch is characterized by pruritus that usually first manifests and is most severe on the legs and arms. Extension to the body is common; however, the face, scalp, groin, axillae, palms, and soles are spared. The skin is dry with fine flakes (Fig. 4-4). The pretibial regions are particularly susceptible and may develop eczema craquelé, exhibiting fine cracks in the eczematous area that resemble the cracks in old porcelain dishes.

Frequent and lengthy bathing with plenty of soap during the winter is the most frequent cause. This is especially prevalent in elderly persons, whose skin has a decreased rate of repair of the epidermal water barrier and whose sebaceous glands are less productive. Low humidity in overheated rooms during cold weather contributes to this condition. In a study of 584 elderly individuals, the prevalence of asteatosis (28.9%) was second only to seborrheic dermatitis as the most common finding.



**Fig. 4-4** Dry skin of the leg.

Treatment consists of educating the patient on using soap only in the axillae and inguinal area and lubricating the skin with emollients immediately after showering. Preparations containing lactic acid or urea applied after bathing are helpful in some patients but may cause irritation and may worsen itching in patients with erythema and eczema.

For those with more severe symptoms, long-standing disease, or a significant inflammatory component, a regimen referred to as “soaking and smearing” is dramatically effective. The patient soaks in a tub of plain water at a comfortable temperature for 20 min before bedtime. Immediately on exiting the tub, without drying, triamcinolone, 0.025–0.1% ointment, is applied to the wet skin. This will trap the moisture, lubricate the skin, and allow for excellent penetration of the steroid component. An old pair of pajamas is then donned, and the patient will note relief even on the first night. The nighttime soaks are repeated for several nights, after which the ointment alone suffices, with the maintenance therapy of limiting soap use to the axillae and groin, and moisturization after showering. Plain petrolatum may be used as the lubricant after the soaking if simple dryness without inflammation is present.

**Gutman A, et al:** Soak and smear therapy. *Arch Dermatol* 2005; 141:1556.

**Kimura N, et al:** Prevalence of asteatosis and asteatotic eczema among elderly residents in facilities covered by long-term care insurance. *J Dermatol* 2013; 40:770.

### Pruritus ani

Pruritus is often centered on the anal or genital area (less frequently in both), with minimal or no pruritus elsewhere. Anal neurodermatitis is characterized by paroxysms of violent itching, when the patient may tear at the affected area until bleeding is induced. Manifestations are identical to lichen simplex chronicus elsewhere on the body. Specific etiologic

factors should always be sought and generally can be classified as dermatologic disease, local irritants (which may coexist with colorectal and anal causes), and infectious agents.

Allergic contact dermatitis is a common dermatologic cause or secondary complication of pruritus ani. It occurs from various medicaments, fragrance in toilet tissue, or preservatives in moist toilet tissue, with one study reporting 18 of 40 consecutive patients being patch test positive. Seborrheic dermatitis, psoriasis, lichen planus, lichen sclerosis, and atopic dermatitis all may cause perianal itching, and an examination of other classic sites of involvement with these conditions should be carefully undertaken. Extramammary Paget's disease and Bowen's disease, although not often itchy, may be present and will not improve with therapy. Biopsy of resistant dermatitic-appearing skin should be done in nonresponsive pruritus ani.

Irritant contact dermatitis from gastrointestinal contents, such as hot spices or cathartics, or failure to cleanse the area adequately after bowel movements may be causal. Anatomic factors may lead to leakage of rectal mucus on to perianal skin and thus promote irritation. Physical changes such as hemorrhoids, anal tags, fissures, and fistulas may aggravate or produce pruritus.

Mycotic pruritus ani is characterized by fissures and a white, sodden epidermis. Scrapings are examined directly with potassium hydroxide mounts, and cultures will usually reveal *Candida albicans*, *Epidermophyton floccosum*, or *Trichophyton rubrum*. Other sites of fungal infection, such as the groin, toes, and nails, should also be investigated. Erythrasma in the groin and perianal regions may also occasionally produce pruritus. The diagnosis is established by coral red fluorescence under the Wood's light.  $\beta$ -Hemolytic streptococcal infections have also been implicated, especially in young children. The use of tetracyclines may cause pruritus ani, most often in women, by inducing candidiasis. Diabetic patients are susceptible to perianal candidiasis.

Pinworm infestations may cause pruritus ani, especially in children and sometimes in their parents. Nocturnal pruritus is most prevalent. Other intestinal parasites, such as *Taenia solium*, *T. saginata*, amebiasis, and *Strongyloides stercoralis*, may produce pruritus. Pediculosis pubis may cause anal itching; however, attention is focused by the patient on the pubic area, where itching is most severe. Scabies may be causative but often will also involve the finger webs, wrists, axillae, areolae, and genitalia.

Lumbosacral radiculopathy also may be present with pruritus ani, as assessed by radiographs and nerve conduction studies; paravertebral blockade may help these patients.

## Treatment

Meticulous toilet care should be followed, no matter what the cause of the itching. After defecation, the anal area should be cleansed whenever possible, washed with mild soap and water. Cleansing with wet toilet tissue is advisable in all cases. Medicated cleansing pads (Tucks) should be used regularly. A variety of moist toilet tissue products are now available. Contact allergy to preservatives in these products is occasionally a problem. An emollient lotion (Balneol) is helpful for cleansing without producing irritation.

Once the etiologic agent has been identified, a rational and effective treatment regimen may be started. Topical corticosteroids are effective for most noninfectious types of pruritus ani; however, use of topical tacrolimus ointment will frequently suffice and is safer. Pramoxine, a nonsteroidal topical anesthetic, is also often effective, especially in a lotion form combined with hydrocortisone. In pruritus ani, as well as in pruritus scroti and vulvae, it is sometimes best to discontinue

all topical medications and treat with plain water sitz baths at night, followed immediately by plain petrolatum applied over wet skin. This soothes the area, provides a barrier, and eliminates contact with potential allergens and irritants.

**Markell KW, et al:** Pruritus ani. *Surg Clin North Am* 2010; 90:125–135.

**Nasserri YY, et al:** Pruritus ani: diagnosis and treatment. *Gastroenterol Clin North Am* 2013; 42:801–813.

**Silvestri DL, et al:** Pruritus ani as a manifestation of systemic contact dermatitis. *Dermatitis* 2011; 22:50–55.

**Stermer E, et al:** Pruritus ani. *J Pediatr Gastroenterol Nutr* 2009; 48:513–516.

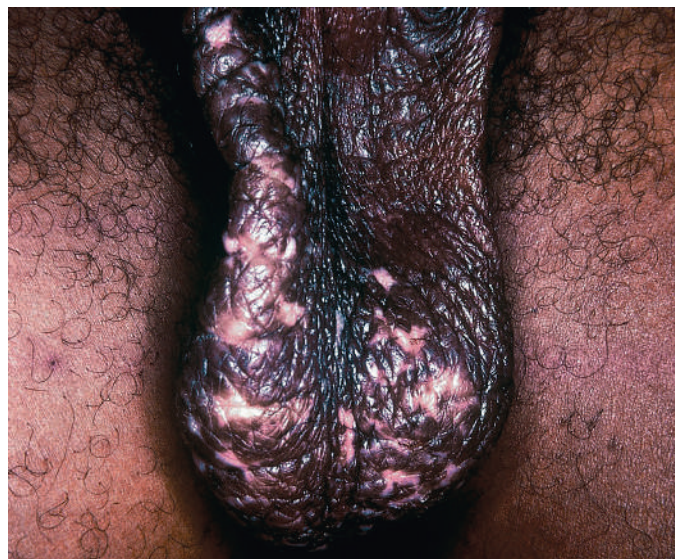
**Suys E, et al:** Randomized study of topical tacrolimus ointment as possible treatment for resistant idiopathic pruritus ani. *J Am Acad Dermatol* 2012; 66:327–328.

## Pruritus scroti

The scrotum of an adult is relatively immune to dermatophyte infection, but it is a susceptible site for circumscribed neurodermatitis (lichen simplex chronicus) (Fig. 4-5). Psychogenic pruritus is probably the most frequent type of itching seen. Why it preferentially affects the scrotum, or in women the vulva (see Pruritus vulvae), is unclear. Lichenification may result, can be extreme, and may persist for many years despite intensive therapy.

Infectious conditions may complicate or cause pruritus on the scrotum but are less common than idiopathic scrotal pruritus. Fungal infections, except candidiasis, usually spare the scrotum. When candidal infection affects the scrotum, burning rather than pruritus is frequently the primary symptom. The scrotum is eroded, weepy, or crusted. The scrotum may be affected to a lesser degree in cases of pruritus ani, but this pruritus usually affects the midline, extending from the anus along the midline to the base of the scrotum, rather than the dependent surfaces of the scrotum, where pruritus scroti usually occurs. Scrotal pruritus may be associated with allergic contact dermatitis from topical medications, including steroidal agents.

Topical corticosteroids are the mainstay of treatment, but caution should be exercised. The “addicted scrotum syndrome” may be caused by the use of high-potency topical steroidal agents. As with facial skin, after attempts to wear patients off the steroid, severe burning and redness may occur.



**Fig. 4-5** Pruritus scroti.



Although usually seen after chronic use, this may occur even with short-term high-potency steroids. The scrotum is frequently in contact with inner thigh skin, producing areas of occlusion, which increases the penetration of topical steroid agents. Topical tacrolimus ointment is useful in overcoming the effects of overuse of potent topical steroids. Another alternative is gradual tapering to less potent corticosteroids. Other useful nonsteroidal alternatives include topical pramoxine, doxepin, and simple petrolatum, which is applied after a sitz bath as described for pruritus ani.

**Cohen AD, et al:** Neuropathic scrotal pruritus. *J Am Acad Dermatol* 2005; 52:61.

## Pruritus vulvae

The vulva is a common site for pruritus of different causes. Pruritus vulvae is the counterpart of pruritus scroti. In a prospective series of 141 women with chronic vulvar symptoms, the most common causes were unspecified dermatitis (54%), lichen sclerosus (13%), chronic vulvovaginal candidiasis (10%), dysesthetic vulvodynia (9%), and psoriasis (5%). In prepubertal children, such itching is most frequently irritant in nature, and girls generally benefit from education about improved hygienic measures.

Vaginal candidiasis is a frequent cause of pruritus vulvae. This is true especially during pregnancy and when oral antibiotics are taken. The inguinal, perineal, and perianal areas may be affected. Microscopic examination for *Candida albicans* and cultures for fungus should be performed. *Trichomonas vaginalis* infection may cause vulvar pruritus. For the detection of *T. vaginalis*, examination of vaginal secretions is often diagnostic. The organism is recognized by its motility, size (sometimes larger than a leukocyte), and piriform shape.

Contact dermatitis from sanitary pads, contraceptives, douche solutions, fragrance, preservatives, colophony, benzocaine, corticosteroids, and a partner's condoms may account for vulvar pruritus. Urinary incontinence should also be considered. Lichen sclerosus is another frequent cause of pruritus in the genital area in middle-age and elderly women. Lichen planus may involve the vulva, resulting in pruritus and mucosal changes, including erosions and ulcerations, resorption of the labia minora, and atrophy.

When burning rather than itching predominates, the patient should be evaluated for signs of sensory neuropathy.

## Treatment

Candidiasis and *Trichomonas* treatments are discussed in Chapters 15 and 20, respectively. Lichen sclerosus responds best to pulsed dosing of high-potency topical steroids or to topical tacrolimus or pimecrolimus. Topical steroid agents and topical tacrolimus may be used to treat psychogenic pruritus or irritant or allergic reactions. Patch testing will assist in identifying the inciting allergen. High-potency topical steroids are effective in treating lichen planus, but other options are also available (see Chapter 12). Topical lidocaine, topical pramoxine, or an oral tricyclic antidepressant may be helpful in select cases. Any chronic skin disease that does not appear to be responding to therapy should prompt a biopsy.

**Bohl TG, et al:** Overview of vulvar pruritus through the life cycle. *Clin Obstet Gynecol* 2005; 48:786.

**Caro-Bruce E, et al:** Vulvar pruritus in a postmenopausal woman. *CMAJ* 2014; 186:688–689.

**Haverhock E, et al:** Prospective study of patch testing in patients with vulvar pruritus. *Australas J Dermatol* 2008; 49:80–85.

**Utas S, et al:** Patients with vulvar pruritus. *Contact Dermatitis* 2008; 58:296–298.

## Puncta prurítica (itchy points)

"Itchy points" consists of one or two intensely itchy spots in clinically normal skin, sometimes followed by the appearance of seborrheic keratoses at exactly the same site. Curettage, cryosurgery, punch biopsy, or likely botulinum toxin A injection of the itchy points may cure the condition.

**Boyd AS, et al:** Puncta prurítica. *Int J Dermatol* 1992; 31:370.

**Salardini A, et al:** Relief of intractable pruritus after administration of botulinum toxin A. *Clin Neuropharmacol* 2008; 31:303–306.

## Aquagenic pruritus and aquadynia

Aquagenic pruritus is itching evoked by contact with water of any temperature. Most patients experience severe, prickling discomfort within minutes of exposure to water or on cessation of exposure to water. There are two groups of patients: about one third consist of an older, primarily male population who have polycythemia vera, hypereosinophilic syndrome, or myelodysplastic syndrome, and two thirds are younger women who develop aquagenic pruritus as young adults and who have no known underlying disease and may have a family history of similar symptoms.

Aquagenic pruritus must be distinguished from xerosis or asteatosis, and an initial trial of "soaking and smearing," as previously described for winter itch, is recommended. Treatment options for aquagenic pruritus include the use of antihistamines, sodium bicarbonate dissolved in bath water, propranolol, SSRIs, acetylsalicylic acid (ASA, aspirin), pregabalin, montelukast, and NB UVB or PUVA phototherapy. One patient found tight-fitting clothing settled the symptoms after only 5 min.

Shelley et al. reported two patients with widespread burning pain that lasted 15–45 min after water exposure, calling this reaction "aquadynia" and considering the disorder a variant of aquagenic pruritus. Clonidine and propranolol seemed to provide some relief.

**Heitkemper T, et al:** Aquagenic pruritus. *J Dtsch Dermatol Ges* 2010; 8:797–804.

**Herman-Kideckel SM et al:** Successful treatment of aquagenic pruritus with montelukast. *J Cut Med Surg* 2012; 16:151–152.

**Koh MJA, et al:** Aquagenic pruritus responding to combine ultraviolet A/narrowband ultraviolet B therapy. *Photodermatol Photoimmunol Photomed* 2009; 25:169–170.

**Nosbaum A, et al:** Treatment with propranolol of 6 patients with idiopathic aquagenic pruritus. *J Allergy Clin Immunol* 2011; 128:1113.

**Shelley WB, et al:** Aquadynia. *J Am Acad Dermatol* 1998; 38:357.

## Scalp pruritus

Pruritus of the scalp, especially in elderly persons, is rather common. Lack of excoriations, scaling, or erythema excludes inflammatory causes of scalp pruritus such as seborrheic dermatitis, psoriasis, dermatomyositis, or lichen simplex chronicus. Most such cases remain idiopathic, but some represent chronic folliculitis. Treatment with topical tar shampoos, salicylic acid shampoos, corticosteroid topical gels, mousse, shampoos, and liquids can be helpful. In patients who have severe scalp pruritus with localized itch, an intralesional injection of corticosteroid suspension may provide relief. Minocycline or oral antihistamines may be helpful. In other patients, low doses of antidepressants, such as doxepin, are useful.

**Bin Saif GA, et al:** The itchy scalp—searching for an explanation. *Exp Dermatol* 2011; 20:959–968.

## Drug-induced pruritus

Medications should be considered a possible cause of pruritus with or without a skin eruption. For example, pruritus is frequently present after opioid use. Also, chloroquine and to a lesser degree other antimalarials produce pruritus in many patients, especially African Americans, treated for malaria. SSRIs and drugs causing cholestatic liver disease are other frequent causes.

Hydroxyethyl starch (HES) is used as a volume expander, a substitute for human plasma. One third of all patients treated will develop severe pruritus with long latency of onset (3–15 weeks) and persistence. Up to 30% of patients have localized symptoms. Antihistamines are ineffective.

**Reich A, et al:** Drug-induced pruritus. *Acta Derm Venereol* 2009; 89:236–244.

## Chronic pruritic dermatoses of unknown cause

Prurigo simplex is the preferred term for the chronic itchy idiopathic dermatosis described here. Papular dermatitis, subacute prurigo, “itchy red bump” disease, and Rosen papular eruption in black men most likely represent variations of prurigo simplex. The term prurigo continues to lack nosologic precision.

Prurigo simplex is characterized by the lesion known as the prurigo papule, which is dome shaped and topped with a small vesicle. The vesicle is usually present only transiently because of its immediate removal by scratching, so that a crusted papule is more frequently seen. Prurigo papules are present in various stages of development and are seen mostly in middle-age or elderly persons of both genders. The trunk and extensor surfaces of the extremities are common sites, symmetrically distributed. Other areas include the face, neck, lower trunk, and buttocks. The lesions usually appear in crops, so that papulovesicles and the late stages of scarring may be seen at the same time.

The histopathology of prurigo simplex is nonspecific but often suggests an arthropod reaction. Spongiosis accompanied by a perivascular mononuclear infiltrate with some eosinophils is often found.

Many conditions may cause pruritic erythematous papules. Scabies, atopic dermatitis, insect bite reactions, papular urticaria, dermatitis herpetiformis, contact dermatitis, pityriasis lichenoides et varioliformis acuta (PLEVA), transient acantholytic dermatosis (TAD), papuloerythroderma of Ofuji, dermatographism, and physical urticarias should be considered. Biopsy may be helpful in differentiating dermatitis herpetiformis, PLEVA, TAD, and on occasion, unsuspected scabies.

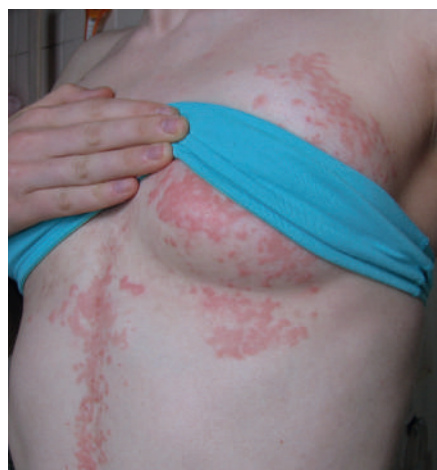## Treatment

The medications for initial treatment of prurigo simplex and its variants should be topical corticosteroids and oral antihistamines. Early in the disease process, moderate-strength steroids should be used; if the condition is found to be unresponsive, a change to high-potency forms is indicated. Rebound may occur. Intralesional injection of triamcinolone will eradicate individual lesions. For more recalcitrant disease, UVB or PUVA therapy may be beneficial.

**Bakker CV, et al:** Bullous pemphigoid as pruritus in the elderly. *JAMA Dermatol* 2013; 149:750–753.

**Clark AR, et al:** Papular dermatitis (subacute prurigo, “itchy red bump” disease). *J Am Acad Dermatol* 1998; 38:929.

**Gambichler T, et al:** Immunophenotyping of inflammatory cells in subacute prurigo. *J Eur Acad Dermatol Venereol* 2011; 25:1221–1226.



**Fig. 4-6** Prurigo pigmentosa.

## Prurigo pigmentosa

Prurigo pigmentosa is a rare dermatosis of unknown cause characterized by the sudden onset of erythematous papules or vesicles that leave reticulated hyperpigmentation when they heal (Fig. 4-6). The condition mainly affects Japanese, although numerous cases have been reported in Caucasians. Women outnumber men 2:1. The mean age of onset is 25. It is associated with weight loss, dieting, anorexia, diabetes, and ketonuria. It is exacerbated by heat, sweating, and friction and thus occurs most often in the winter and spring. The areas most frequently involved are the upper back, nape, clavicular region, and chest. Mucous membranes are spared. Histology of early lesions shows neutrophils in the dermal papillae and epidermis. Following this, a lichenoid dermatitis with variable psoriasiform hyperplasia occurs. Direct immunofluorescence yields negative findings. The cause is unknown. Minocycline, 100–200 mg/day, is the treatment of choice. Dapsone and alteration of the diet are also effective; topical steroids are not effective. Recurrence and exacerbations are common.

**Hijazi M, et al:** Prurigo pigmentosa. *Am J Dermatopathol* 2014; 36:800–806.

**Marín PR, et al:** Pruritic reticular eruption on the chest of a 24-year-old woman—quiz case. Diagnosis: prurigo pigmentosa (PP). *Arch Dermatol* 2010; 146:81–86.

**Oh YJ, et al:** Prurigo pigmentosa. *J Eur Acad Dermatol Venereol* 2012; 26:1149–1153.

## Papuloerythroderma of Ofuji

A rare disorder most often found in Japan, papuloerythroderma of Ofuji (PEO) is characterized by flat-topped, red-to-brown pruritic papules that spare the skinfolds, producing bands of uninvolved cutis, the so-called deck-chair sign. Almost all patients are over age 55, with clear male predominance. Frequently, there is associated blood eosinophilia. Skin biopsies reveal a dense lymphohistiocytic infiltrate, eosinophils in the papillary dermis, and increased Langerhans cells. Malignancies have occurred in 21% of reported cases, but the timing and course do not always often correlate with PEO. Reported malignancies include T-cell lymphomas, B-cell lymphomas, Sézary syndrome, and visceral carcinomas. Drugs (e.g., aspirin, ranitidine, furosemide) and infections (e.g., HIV, hepatitis C) may induce the condition. Severe atopic dermatitis and cutaneous T-cell lymphoma may present with identical morphologic finding of PEO. History will assist in making the diagnosis of atopic dermatitis, whereas biopsy may reveal findings diagnostic of eruptions.



Systemic steroids are the treatment of choice and may result in long-term remission. Topical or systemic steroids, tar derivatives, emollients, systemic retinoids, cyclosporine, UVB, and PUVA may also be therapeutic. UV therapy, with or without steroids, is favored.

**Teraki Y, et al:** High incidence of internal malignancy in papuloerythroderma of Ofuji. *Dermatology* 2013; 224:5–9.

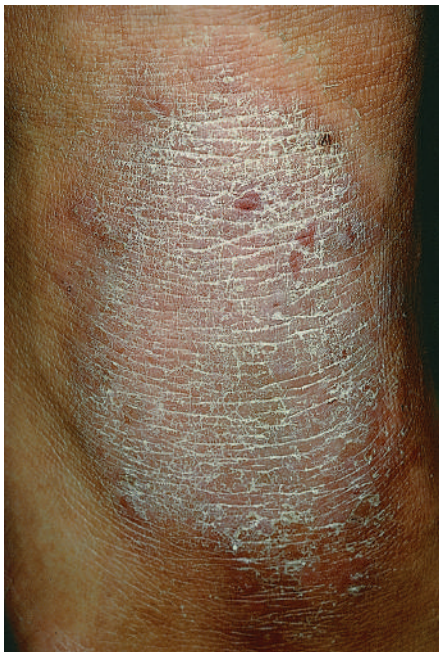**Torchia D, et al:** Papuloerythroderma 2009. *Dermatology* 2010; 220:311–320.

## Lichen simplex chronicus

Also known as circumscribed neurodermatitis, lichen simplex chronicus results from long-term chronic rubbing and scratching, more vigorously than a normal pain threshold would permit, with the skin becoming thickened and leathery. The normal markings of the skin become exaggerated (Fig. 4-7), so that the striae form a crisscross pattern, producing a mosaic in between composed of flat-topped, shiny, smooth quadrilateral facets. This change, known as lichenification, may originate on seemingly normal skin or may develop on skin that is the site of another disease, such as atopic or allergic contact dermatitis or ringworm. Such underlying etiologies should be sought and, if found, treated specifically. Paroxysmal pruritus is the main symptom.

Circumscribed, lichenified pruritic patches may develop on any part of the body; however, lichen simplex chronicus has a predilection for the back and sides of the neck, the scalp, the upper eyelid, the orifice of one or both ears, the palm, soles, or often the wrist and ankle flexures. The vulva, scrotum, and anal areas are common sites, although the genital and anal areas are seldom involved at the same time. The eruption may be papular, resembling lichen planus; and in other cases the patches are excoriated, slightly scaly or moist, and rarely, nodular. Persistent rubbing of the shins or upper back may result in dermal deposits of amyloid and the subsequent development of lichen or macular amyloidosis, respectively.

The onset of this dermatosis is usually gradual and insidious. Chronic scratching of a localized area may be a response to an inciting dermatitis; however, scratching of the localized site continues long after the original insult and becomes a habit.



**Fig. 4-7** Lichen simplex chronicus.

## Treatment

Cessation of pruritus is the goal with lichen simplex chronicus. It is important to stress the need for the patient to avoid scratching the areas involved if the sensation of itch is ameliorated. Recurrences are frequent, even after the most thorough treatment, and in some cases the clearance of one lesion will see the onset of another elsewhere.

A high-potency steroid cream or ointment should be used initially but not indefinitely because of the potential for steroid-induced atrophy. Occlusion of medium-potency steroids may be beneficial. Use of a steroid-containing tape to provide both occlusion and anti-inflammatory effects may have benefit. Treatment can be shifted to the use of medium- to lower-strength topical steroid creams as the lesions resolve. Topical doxepin, capsaicin, or pimecrolimus cream or tacrolimus ointment provides significant antipruritic effects and is a good adjunctive therapy.

Intralesional injections of triamcinolone suspension, using a concentration of 2.5–5 mg/mL, may be required. Too superficial an injection invites the twin risks of epidermal and dermal atrophy and depigmentation, which may last for many months. The suspension should not be injected into infected lesions because it may cause abscess. Botulinum toxin A injection may be curative. In the most severe cases, complete occlusion with an Unna boot may break the cycle.

**Aschoff R, et al:** Topical tacrolimus for the treatment of lichen simplex chronicus. *J Dermatol Treat* 2007; 18:15.

**Feily A, et al:** A succinct review of botulinum toxin in dermatology. *J Cosmet Dermatol* 2011; 10:58–67.

**Rajalakshmi R, et al:** Lichen simplex chronicus of the anogenital region. *Indian J Dermatol Venereol Leprol* 2011; 77:28–36.

**Stewart KMA:** Clinical care of vulvar pruritus, with emphasis on one common cause, lichen simplex chronicus. *Dermatol Clin* 2010; 28:669–680.

## Prurigo nodularis

Prurigo nodularis is a disease with multiple itchy nodules mainly on the extremities (Fig. 4-8), especially on the anterior surfaces of the thighs and legs. A linear arrangement is common. The individual lesions are pea sized or larger, firm, and erythematous or brownish. When fully developed, they become verrucous or fissured. The course of the disease is chronic, and the lesions evolve slowly. Itching is severe but usually confined to the lesions themselves. Bouts of extreme pruritus often occur when these patients are under stress. Prurigo nodularis is one of the disorders in which the pruritus is characteristically paroxysmal: intermittent, unbearably severe, and relieved only by scratching to the point of damaging the skin, usually inducing bleeding and often scarring.

The cause of prurigo nodularis is unknown; multiple factors may contribute, including atopic dermatitis, hepatic diseases (including hepatitis C), HIV disease, pregnancy, renal failure, lymphoproliferative disease, stress, and insect bites. Pemphigoid nodularis may be confused with prurigo nodularis clinically.

The histologic findings are those of compact hyperkeratosis, irregular acanthosis, and a perivascular mononuclear cell infiltrate in the dermis. Dermal collagen may be increased, especially in the dermal papillae, and subepidermal fibrin may be seen, both evidence of excoriation. In cases associated with renal failure, transepidermal elimination of degenerated collagen may be found.

## Treatment

The initial treatment of choice for prurigo nodularis is intralesional or topical administration of steroids. Usually,

superpotent topical products are required, but at times, lower-strength preparations used with occlusion may be beneficial, as when administered as the “soak and smear” regimen. The use of steroids in tape (Cordran) and prolonged occlusion with semipermeable dressings, such as used for treating nonhealing wounds, can be useful in limited areas. Intralesional steroids will usually eradicate individual lesions, but unfortunately, many patients have too extensive disease for these local measures. PUVA, NB UVB, and UVA alone have been shown to be effective in some patients. Vitamin D<sub>3</sub> ointment, calcipotriene ointment, or tacrolimus ointment applied topically twice daily may be therapeutic and steroid sparing. Isotretinoin, 1 mg/kg/day for 2–5 months, may benefit some patients. Managing dry skin with emollients and avoidance of soap, with administration of antihistamines, antidepressants, or anxiolytics, is of moderate benefit in allaying symptoms.

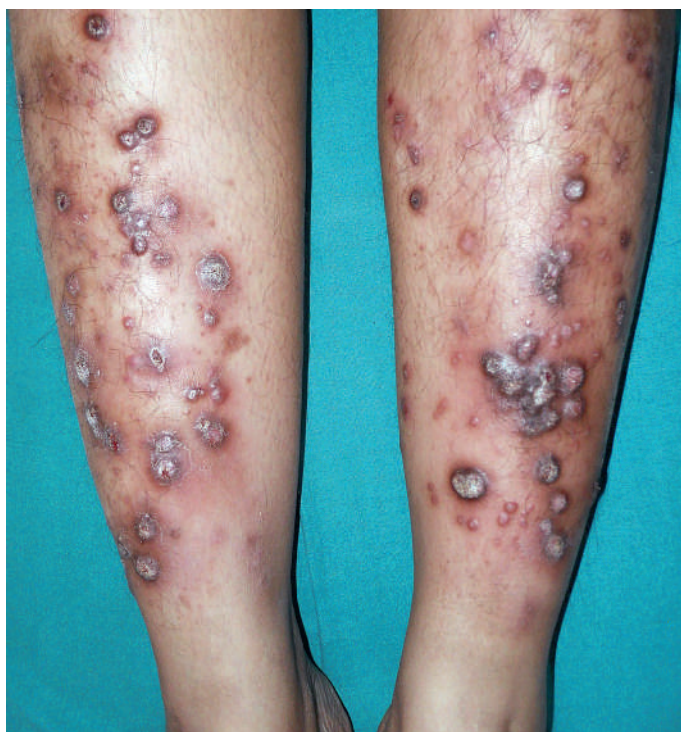Good results have been obtained with thalidomide, lenalidomide, pregabalin, and cyclosporine. With thalidomide, onset may be rapid or slow, and sedation may occur; initial dose is 100 mg/day, titrated to the lowest dose required. Patients treated with thalidomide are at risk of developing a dose-dependent neuropathy at cumulative doses of 40–50 g. Lenalidomide, an analogue of thalidomide, has less problems with neuropathy but may cause myelosuppression, venous thrombosis, and Stevens-Johnson syndrome. Pregabalin, 75 mg/day for 3 months, improved 23 of 30 patients in one study. Cyclosporine at doses of 3–4.5 mg/kg/day has also been shown to be effective in treating recalcitrant disease. Cryotherapy may be used adjunctively.

**Andersen TP, et al:** Thalidomide in 42 patients with prurigo nodularis Hyde. *Dermatology* 2011; 223:107–112.

**Bruni E, et al:** Phototherapy of generalized prurigo nodularis. *Clin Exp Dermatol* 2009; 35:549–550.

**Kanavy H, et al:** Treatment of refractory prurigo nodularis with lenalidomide. *Arch Dermatol* 2012; 148:794–796.

**Mazza M, et al:** Treatment of prurigo nodularis with pregabalin. *J Clin Pharm Ther* 2013; 38:16–18.



**Fig. 4-8** Prurigo nodularis. (Courtesy of Debabrata Bandyopadhyay, MD.)

## PSYCHODERMATOLOGY

Some purely cutaneous disorders are psychiatric in nature, their cause being directly related to psychopathologic causes in the absence of primary dermatologic or other organic causes. Delusions of parasitosis, psychogenic (neurotic) excoriations, factitial dermatitis, and trichotillomania compose the major categories of psychodermatology. The differential diagnosis for these four disorders is twofold, requiring the exclusion of organic causes and the definition of a potential underlying psychological disorder. Bromidrosiphobia is another delusional disorder. Body dysmorphic disorder is a spectrum of disease; some severely affected patients are delusional, whereas others have more insight and are less functionally impaired.

Psychosis is characterized by the presence of delusional ideation, which is defined as a fixed misbelief that is not shared by the patient's subculture. Monosymptomatic hypochondriacal disorder is a form of psychosis characterized by delusions regarding a particular hypochondriacal concern. In contrast to schizophrenia, there are no other mental deficits, such as auditory hallucination, loss of interpersonal skills, or presence of other inappropriate actions. Patients with monosymptomatic hypochondriacal psychosis often function appropriately in social settings, except for a single fixated belief that there is a serious problem with their skin or with other parts of their body.

**Butler DC, et al:** Psychotropic medications in dermatology. *Semin Cutan Med Surg* 2013; 32:126–129.

**Fried RG:** Nonpharmacologic treatments of psychodermatologic conditions. *Semin Cutan Med Surg* 2013; 32:119–125.

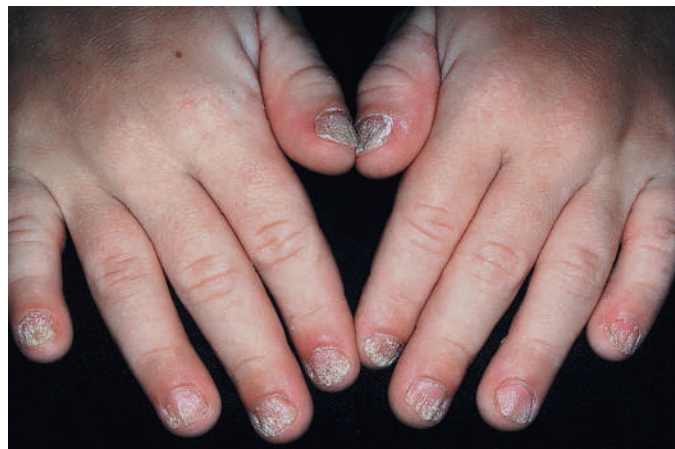**Leon A, et al:** Psychodermatology. *Semin Cutan Med Surg* 2013; 32:64–67.

**Locala JA:** Current concepts in psychodermatology. *Curr Psychiatry Rep* 2009; 11:211–218.

## Skin signs of psychiatric illness

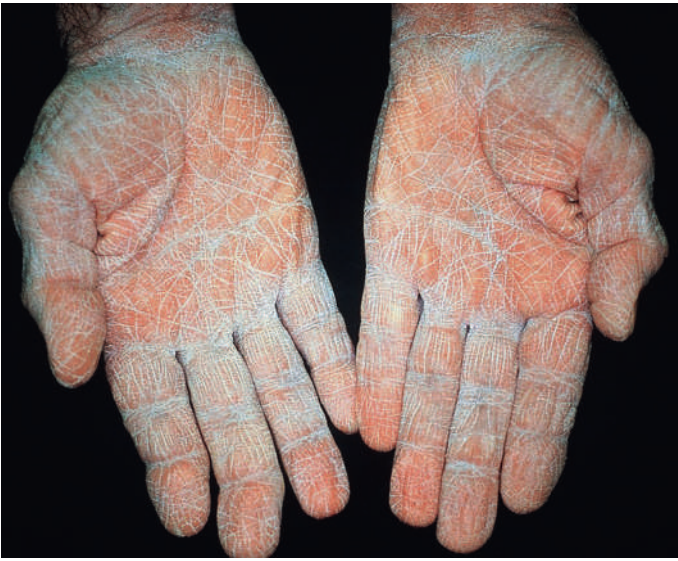The skin is a frequent target for the release of emotional tension. Some of the signs described here may become repetitive compulsions that impair normal life functions and may be manifestations of an obsessive-compulsive disorder. Self-injury by prolonged, compulsive repetitious acts may produce various mutilations, depending on the act and site of injury.

Self-biting may be manifested by biting the nails (onychophagia) (Fig. 4-9), skin (most frequently the forearms, hands,

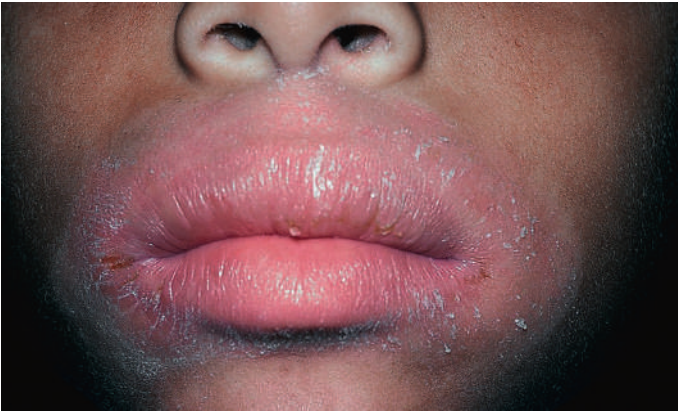

**Fig. 4-9** Onychophagia. (Courtesy of Curt Samlaska, MD.)





**Fig. 4-10** Irritant dermatitis from chronic handwashing.



**Fig. 4-11** Dermatitis caused by lip licking.

and fingers), and lip. Dermatophagia is a habit or compulsion, conscious or subconscious. Bumping of the head produces lacerations and contusions, which may be so severe as to produce cranial defects and life-threatening complications. Compulsive repetitive handwashing may produce an irritant dermatitis of the hands (Fig. 4-10).

Bulimia, with its self-induced vomiting, results in Russell's sign—crusted papules on the dorsum of the dominant hand from cuts by the teeth. Clenching of the hand produces swelling and ecchymosis of the fingertips and subungual hemorrhage. Self-inflicted lacerations may be of suicidal intent. Lip licking produces increased salivation and thickening of the lips. Eventually, the perioral area becomes red and produces a distinctive picture resembling the exaggerated mouth makeup of a clown (Fig. 4-11). Pressure produced by binding the waistline tightly with a cord will eventually lead to atrophy of the subcutaneous tissue.

Psychopharmacologic agents, especially the newer atypical antipsychotic agents, and behavioral therapy alone or in combination with these agents are the treatments of choice.

**Kestenbaum T:** Obsessive-compulsive disorder in dermatology. *Semin Cutan Med Surg* 2013; 32:83–87.

**Shukla R, et al:** Psychopharmacology in psychodermatology. *J Cutan Med Surg* 2008; 12:255–267.

**Strumia R:** Eating disorders and the skin. *Clin Dermatol* 2013; 31:80–85.

## Delusions of parasitosis

Delusions of parasitosis (e.g., delusional parasitosis, Ekbom syndrome, acarophobia, dermatophobia, parasitophobia, entomophobia, pseudoparasitic dysesthesia) are firm fixations in a person's mind that he or she suffers from a parasitic infestation of the skin. At times, close contacts may share the delusion. The belief is so fixed that the patient may pick small pieces of epithelial debris from the skin and bring them to be examined, always insisting that the offending parasite is contained in such material. Samples of alleged parasites enclosed in assorted containers, paper tissue, or sandwiched between adhesive tape are so characteristic that it is referred to as the "matchbox" or "ziplock" sign. Usually, the only symptom is pruritus or a stinging, biting, or crawling sensation. Intranasal formication, or a crawling sensation of the nasal mucosa, is common in this condition. Cutaneous findings may range from none to excoriations, prurigo nodularis, and frank ulcerations.

Frequently, these patients have paranoid tendencies. Women are affected 2:1 over men, often during middle or old age. The condition has been reported to be associated with schizophrenia, bipolar disorders, depression, anxiety disorders, and obsessional states but is usually a monosymptomatic hypochondriacal disorder. A variety of organic conditions may be causative and should be considered. They include cocaine, alcohol, and amphetamine abuse; dementia and other neurologic conditions (e.g., multiple sclerosis, central nervous system tumors, epilepsy, Parkinson's disease); malignancies, particularly lymphoma and leukemia; cerebrovascular disease; endocrine disorders; infectious diseases; pellagra; and vitamin B<sub>12</sub> deficiency. A variety of medications, including gabapentin, antiparkinsonian and antihistaminic drugs, and corticosteroids, may also produce this condition. Some of these agents may produce cutaneous symptoms, particularly pruritus, which may contribute to the delusion.

The differential diagnosis is influenced by the cutaneous findings and history. Initial steps should be directed at excluding a true infestation, such as scabies, or an organic cause. A thorough history, particularly in reference to therapeutic and recreational drug use (e.g., amphetamines, alcohol, cocaine), review of systems, and physical examination should be performed. Many consider Morgellons disease simply to be another name for delusions of parasitosis. Patients complain of crawling, biting, burning, or other sensations that cause them to be intensely anxious. Often, granules or fibers are provided by the patient for analysis. Many patients have associated psychiatric conditions.

A skin biopsy is frequently performed, more to reassure the patient than to uncover occult skin disease. Screening laboratory tests to exclude systemic disorders should be obtained: CBC; urinalysis; liver, renal, and thyroid function tests; iron studies; serum glucose and serum B<sub>12</sub>; folate; and electrolyte levels. Once organic causes have been eliminated, the patient should be evaluated to determine the cause of the delusions. Schizophrenia, monosymptomatic hypochondriacal psychosis, psychotic depression, dementia, and depression with somatization are considerations in the differential diagnosis.

Management of this difficult problem varies. Although referral to a psychiatrist may seem best, most frequently the patient will reject suggestions to seek psychiatric help. The dermatologist is cautioned against confronting the patient with the psychogenic nature of the disease. It is preferable to develop trust, which will usually require several visits. If pharmacologic treatment is undertaken, the patient may accept it if the medication is presented as one that will alter the perception of this bothersome sensation. Pimozide was the long-standing treatment of choice but is associated with a variety of side effects,

including stiffness, restlessness, prolongation of Q-T interval, and extrapyramidal signs. Patients often respond to relatively low dosages, in the 1–4 mg range, which limits these problems. Pimozide is approved for the treatment of Tourette syndrome, and patients should understand the labeling before obtaining the drug. Newer, atypical antipsychotic agents such as risperidone and olanzapine have fewer side effects and are now considered the appropriate first-line agents for the treatment of delusions of parasitosis, although the experience with them is more limited. With appropriate pharmacologic intervention, at least 50% of patients will likely remit.

**Accordino RE, et al:** Morgellons disease? *Dermatol Ther* 2008; 21:8.

**Elliott A, et al:** Cocaine bugs. *Am J Addict* 2012; 21:180–181.

**Friedman AC, et al:** Delusional parasitosis presenting as folie à trois. *Br J Dermatol* 2006; 155:841.

**Huber M, et al:** Delusional infestation. *Gen Hosp Psychiatry* 2011; 33:604–611.

**Hylwa SA, et al:** Delusional infestation, including delusions of parasitosis. *Arch Dermatol* 2011; 147:1041–1045.

**Lepping P, et al:** Antipsychotic treatment of primary delusional parasitosis: systematic review. *Br J Psychiatry* 2007;191:198.

**Lewis EC et al:** Delusions of parasitosis. *Semin Cutan Med Surg* 2013; 32:73–77.

**Lopez PR, et al:** Gabapentin-induced delusions of parasitosis. *South Med J* 2010; 103:711–712.

**Reichenberg JS, et al:** Patients labeled with delusions of parasitosis compose a heterogeneous group. *J Am Acad Dermatol* 2013; 68:41–46.

**Robles DT, et al:** Morgellons disease and delusions of parasitosis. *Am J Clin Dermatol* 2011; 12:1–6.

**Sandoz A, et al:** A clinical paradigm of delusions of parasitosis. *J Am Acad Dermatol* 2008; 59:698–704.

**Schairer D, et al:** Psychology and psychiatry in the dermatologist's office. *J Drug Dermatol* 2012; 11:543–545.

**Walling HW, et al:** Intranasal formication correlates with diagnosis of delusions of parasitosis. *J Am Acad Dermatol* 2008; 58:S35.

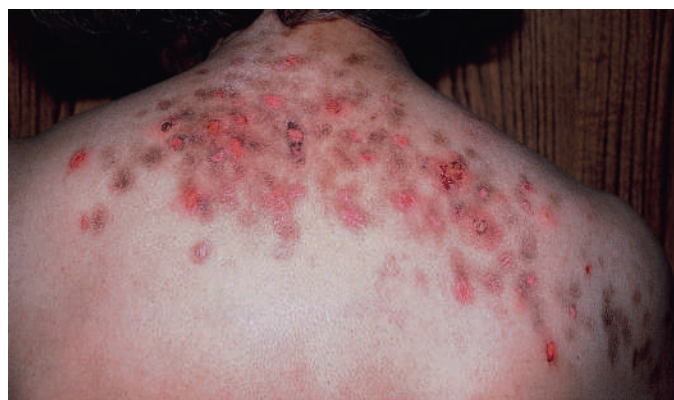## Psychogenic (neurotic) excoriations

Many persons have unconscious compulsive habits of picking at themselves, and at times the tendency is so persistent and pronounced that excoriations of the skin result. The lesions are caused by picking, digging, or scraping and usually occur on parts readily accessible to the hands. These patients admit their actions induce the lesions but cannot control their behavior.

The excavations may be superficial or deep and are often linear. The bases of the ulcers are clean or covered with a scab. Right-handed persons tend to produce lesions on their left side and left-handed persons on their right side. There is evidence of past healed lesions, usually with linear scars, or rounded hyperpigmented or hypopigmented lesions, in the area of the active excoriations. The face, upper arms, and upper back are common sites for these excoriations (Fig. 4-12). Sometimes the focus is on acne lesions, producing acne excoriée.

Most of these patients are otherwise healthy adults. They usually lead normal lives. The organic differential diagnosis is vast and includes any condition that may manifest with excoriations. The most common psychopathologies associated with neurotic excoriations are depression, obsessive-compulsive disorder, and anxiety.

The treatment of choice is doxepin because of its antidepressant and antipruritic effects; doses are slowly increased to 100 mg or higher, if tolerated. Many alternatives to doxepin may be indicated, especially in those affected by an obsessive-compulsive component, including clomipramine, paroxetine, fluoxetine, and sertraline. Other useful drugs are desipramine, buspirone, and rapid-acting benzodiazepines. Treatment is difficult, often requiring a combined psychiatric and pharma-



**Fig. 4-12** Neurotic excoriations. (Courtesy of Lawrence Lieblich, MD.)

cologic intervention. It is important to establish a constructive patient-therapist alliance. Training in diversion strategies during “scratching episodes” may be helpful. An attempt should be made to identify specific conflicts or stressors preceding onset. The therapist should concentrate on systematic training directed at the behavioral reaction pattern. There should be support and advice given with regard to the patient’s social situation and interpersonal relations.

**Kestenbaum T:** Obsessive-compulsive disorder in dermatology. *Semin Cutan Med Surg* 2013; 32:83–87.

**Koblentz CS, et al:** Neurotic excoriations and dermatitis artefacta. *Semin Cutan Med Surg* 2013; 32:95–100.

**Misery L, et al:** Psychogenic skin excoriations. *Acta Derm Venereol* 2012, 92:416–418.

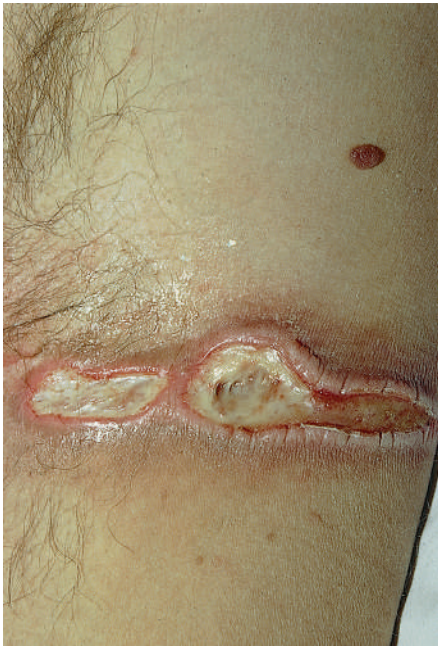**Mustasim DF, et al:** The psychiatric profile of patients with psychogenic excoriation. *J Am Acad Dermatol* 2009; 61:611.

## Factitious dermatitis and dermatitis artefacta

Factitious dermatitis is the term applied to self-inflicted skin lesions with the intent to elicit sympathy, escape responsibility, or collect disability insurance. Malingering applies to the latter two cases, where material gain is the objective. This contrasts with the usual dermatitis artefacta patient, who has an unconscious goal of gaining attention and assuming the sick patient role. Most patients are adults in midlife, with women affected three times more often than men. The vast majority have multiple lesions and are unemployed or on sick leave. These skin lesions are provoked by mechanical means or by the application or injection of chemical irritants and caustics. These patients often have a “hollow” history, unable to detail how the lesions appeared or evolved. The lesions may simulate other dermatoses but usually have a distinctive, geometric, bizarre appearance (Fig. 4-13), often with a shape and arrangement not encountered in other disorders. The lesions are generally distributed on parts easily reached by the hands, tend to be linear and arranged regularly and symmetrically, and are rarely seen on the right hand, right wrist, or right arm, unless the patient is left-handed.

When chemicals are used, red streaks or guttate marks are often seen beneath the principal patch, where drops of the chemical have accidentally run or fallen on the skin. According to the manner of production, the lesions may be erythematous, vesicular, bullous, ulcerative, or gangrenous. The more common agents of destruction used are the fingernails, pointed instruments, hot metal, chemicals (e.g., carbolic, nitric, or acetic acid), caustic potash or soda, turpentine, table salt, urine, and feces. The lesions are likely to appear in crops. At times the only sign may be the indefinitely delayed healing of an operative wound, which is purposely kept open by the





**Fig. 4-13** Factitial ulcers.

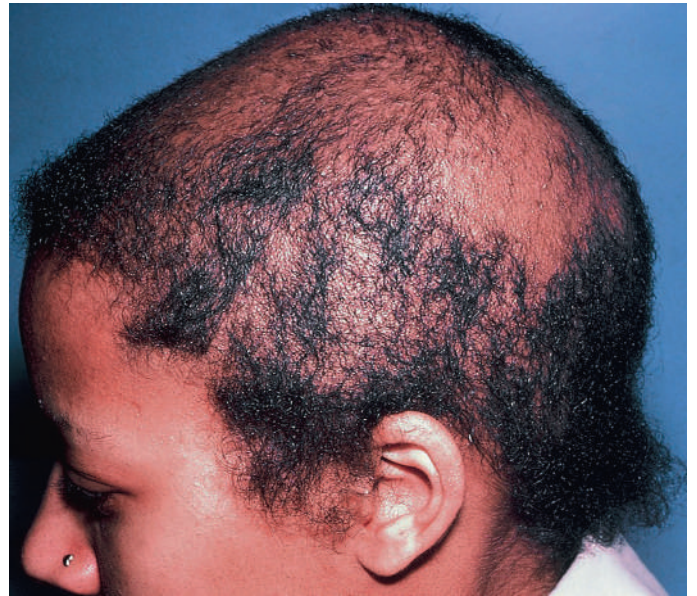patient. Tight cords or clothing tied around an arm or leg may produce factitious lymphedema, which may be mistaken for postphlebotic syndrome or nerve injury, as well as other forms of chronic lymphedema.

Subcutaneous emphysema, manifesting as cutaneous crepitations, may be factitial in origin. Recurrent migratory subcutaneous emphysema involving the extremities, neck, chest, or face can be induced through injections of air into tissue with a needle and syringe. Circular pockets and bilateral involvement without physical findings, indicating contiguous spread from a single source, suggest a factitial origin. Puncturing the buccal mucosa through to facial skin with a needle and puffing out the cheeks can produce alarming results. Neck and shoulder crepitation is also a complication in manic patients that results from hyperventilation and breath holding.

The organic differential diagnosis depends on the cutaneous signs manifested, such as gas gangrene for patients with factitious subcutaneous emphysema and the various forms of lymphedema for factitious lymphedema. A subset of these patients have Munchausen syndrome. They tend to cause lesions that closely simulate known conditions, and they create an intricate, often fantastic story surrounding the problem. Admissions to the hospital with extensive workup often result. Parents may induce lesions on their child to gain attention, so-called Munchausen by proxy, which is really child abuse. Considerations for psychopathology in dermatitis artefacta include borderline personality disorders and psychosis.

Proof of diagnosis is sometimes difficult. Occlusive dressings may be necessary to protect the lesions from ready access by the patient. It is usually best not to reveal any suspicion of the cause to the patient and to establish the diagnosis definitively without the patient's knowledge. If the patient is hospitalized, a resourceful, cooperative nurse may be useful in helping to establish the diagnosis. When injection of foreign material is suspected, examination of biopsy material by spectroscopy may reveal talc or other foreign material.

Treatment should ideally involve psychotherapy, but typically the patient promptly rejects the suggestion and goes to another physician to seek a new round of treatment. It is best for the dermatologist to maintain a close relationship with the patient and provide symptomatic therapy and nonjudgmental support. SSRIs may address associated depression and anxiety. Very-low-dose atypical antipsychotics may also be added, if



**Fig. 4-14** Trichotillomania.

needed. Consultation with an experienced psychiatrist is prudent.

**Koblentz CS, et al:** Neurotic excoriations and dermatitis artefacta. *Semin Cutan Med Surg* 2013; 32:95–100.

**Shah KN, et al:** Factitial dermatoses in children. *Curr Opin Pediatr* 2006; 18:403.

**Ucmak D, et al:** Dermatitis artefacta. *Cutan Ocul Toxicol* 2014; 33:22–27.

## Trichotillomania

Trichotillomania (trichotillois or neuromechanical alopecia) is a neurosis characterized by an abnormal urge to pull out the hair. The sites involved are generally the frontal region of the scalp, eyebrows, eyelashes, and the beard. The classic presentation is the “Friar Tuck” form of vertex and crown alopecia. There are irregular areas of hair loss, which may be linear or bizarrely shaped. Infrequently, adults may pull out pubic hair. Hairs are broken and show differences in length (Fig. 4-14). The pulled hair may be ingested, and occasionally the trichobezoar will cause obstruction. When the tail extends from the main mass in the stomach to the small or large intestine, Rapunzel syndrome is the diagnosis. The nails may show evidence of onychophagy (nail biting), but no pits are present. The disease is seven times more common in children than in adults, and girls are affected 2.5 times more often than boys.

Trichotillomania often develops in the setting of psychosocial stress in the family, which may involve school problems, sibling rivalry, moving to a new house, hospitalization of a parent, or a disturbed parent-child relationship.

Differentiation from alopecia areata is possible because of the varying lengths of broken hairs present, the absence of nail pitting, and the microscopic appearance of the twisted or broken hairs in contrast to the tapered fractures of alopecia areata. Other organic disorders to consider are androgenic alopecia, tinea capitis, monilethrix, pili torti, pseudopelade of Brocq, traction alopecia, syphilis, nutritional deficiencies, and systemic disorders such as lupus and lymphoma. Trichoscopy reveals broken hairs of varying lengths; some may be frayed, longitudinally split, or coiled. If necessary, a biopsy can be performed and is usually quite helpful. It reveals traumatized hair follicles with perifollicular hemorrhage, fragmented hair in the dermis, empty follicles, and deformed hair shafts

(trichomalacia). Multiple catagen hairs are typically seen. An alternative technique to biopsy, particularly for children, is to shave a part of the involved area and observe for regrowth of normal hairs. The differential diagnosis for this impulse control disorder should include underlying comorbid psychopathology, such as an obsessive-compulsive disorder (most common), depression, or anxiety.

In children, the diagnosis should be addressed openly, and referral to a child psychiatrist for cognitive-behavioral therapy (CBT) should be encouraged. Habit-reversal training is often part of the treatment. In adults with the problem, psychiatric impairment may be severe. Pharmacotherapy with clomipramine is the most effective of the studied medications, but SSRIs are most often prescribed and may help any associated depression or anxiety. *N*-acetylcysteine also shows promise; it is available in health food stores and is relatively inexpensive and well tolerated. Trichobezoars require surgical removal.

**Franklin ME, et al:** Trichotillomania and its treatment. *Expert Rev Neurother* 2011; 11:1165–1174.

**Grant JE, et al:** *N*-acetylcysteine, a glutamine inhibitor, in the treatment of trichotillomania. *Arch Gen Psychiatry* 2009; 66:756–763.

**Harrison JP, et al:** Pediatric trichotillomania. *Curr Psychiatry Rep* 2012; 14:188–196.

**Huynh M, et al:** Trichotillomania. *Semin Cutan Med Surg* 2013; 32:88–94.

**Morales-Fuentes B, et al:** Trichotillomania, recurrent trichobezoar and Rapunzel syndrome. *Cir Cir* 2010; 78:265–266.

**Ravindran AV, et al:** Obsessive-compulsive spectrum disorders. *Can J Psychiatry* 2009; 54:331–343.

**Woods DW, et al:** Diagnosis, evaluation, and management of trichotillomania. *Psychiatr Clin North Am* 2014; 37:301–317.

## Dermatothlasia

Dermatothlasia is a cutaneous neurosis characterized by a patient's uncontrollable desire to rub or pinch themselves to form bruised areas on the skin, sometimes as a defense against pain elsewhere.

## Bromidrosiphobia

Bromidrosiphobia (delusions of bromhidrosis) is a mono-symptomatic delusional state in which a person is convinced that his or her sweat has a repugnant odor that keeps other people away. The patient is unable to accept any evidence to the contrary. Three quarters of patients with bromidrosiphobia are male, with an average age of 25. Atypical antipsychotic agents or pimozide may be beneficial. It may be an early symptom of schizophrenia.

## Body dysmorphic disorder (dysmorphic syndrome, dysmorphophobia)

Body dysmorphic disorder is the excessive preoccupation of having an ugly body part. It is most common in young adults of either gender. The concern is frequently centered about the nose, mouth, genitalia, breasts, or hair. Objective evaluation will reveal a normal appearance or slight defect. These patients are usually seen in dermatologic practice, especially among those presenting for cosmetic surgery evaluation. Patients may manifest obsessional features, spending long periods inspecting the area. Associated depression and social isolation along with other comorbidities present a high risk of suicide. The SSRIs accompanied by CBT give the best results for those with this somatoform disorder. More severely affected patients

have delusions that may lead to requests for repeated surgeries of the site and require antipsychotic medications.

**Buhlmann U, et al:** Perceived ugliness. *Curr Psychiatry Rep* 2011; 13:283–288.

**Conrado LA, et al:** Body dysmorphic disorder among dermatologic patients. *J Am Acad Dermatol* 2010; 63:235–243.

**Gupta R, et al:** Body dysmorphic disorder. *Semin Cutan Med Surg* 2013; 32:78–82.

**Ipsier JC, et al:** Pharmacotherapy and psychotherapy for body dysmorphic disorder. *Cochrane Database Syst Rev* 2009; (1):CD005332.

**Sarwer DB, et al:** Body image dysmorphic disorder in persons who undergo aesthetic medical treatments. *Aesthet Surg J* 2012; 32:999–1009.

## CUTANEOUS DYSESTHESIA SYNDROMES

### Scalp dysesthesia

Cutaneous dysesthesia syndromes are characterized by pain and burning sensations without objective findings. Many patients report coexisting pruritus or transient pruritus associated with the dysesthesia. Scalp dysesthesia occurs primarily in middle-age to elderly women. Cervical spine degenerative disk disease was found in 14 of 15 patients. The hypothesis is that chronic tension is placed on the occipitofrontalis muscle and scalp aponeurosis. In one series, gabapentin helped four of the seven patients seen in follow-up. A psychiatric overlay is frequently associated, and treatment with low-dose antidepressants may also be helpful.

**Thornsberry LA, et al:** Scalp dysesthesia related to cervical spine disease. *JAMA Dermatol* 2013; 149:200–203.

### Burning mouth syndrome (glossodynia, burning tongue)

Burning mouth syndrome (BMS) is divided into two forms: a primary type characterized by a burning sensation of the oral mucosa, with no dental or medical cause, and secondary BMS, caused by a number of conditions, including lichen planus, candidiasis, vitamin or nutritional deficiencies (e.g., low B<sub>12</sub>, iron, or folate), hypoestrogenism, parafunctional habits, diabetes, dry mouth, contact allergies, cranial nerve injuries, and medication side effects. Identification of the underlying condition and its treatment will result in relief of secondary BMS.

Primary BMS occurs most frequently in postmenopausal women. They are particularly prone to a feeling of burning of the tongue, mouth, and lips, with no objective findings. Symptoms vary in severity but are more or less constant. Patients with BMS often complain that multiple oral sites are involved. Management with topical applications of clonazepam, capsaicin, doxepin, or lidocaine can help. Oral administration of  $\alpha$ -lipoic acid, SSRIs or tricyclic antidepressants (TCAs), gabapentin, and benzodiazepines has been reported to be effective. The most common, best studied, and most successful therapy is provided by the antidepressant medications, because many patients are depressed as well.

Burning lips syndrome may be a separate entity; it appears to affect both men and women equally and occurs in individuals between ages 50 and 70. The labial mucosa may be smooth and pale, and the minor salivary glands of the lips are frequently dysfunctional. Treatment with  $\alpha$ -lipoic acid showed improvement in 2 months in a double-blind controlled study.

**Crow HC, et al:** Burning mouth syndrome. *Oral Maxillofac Surg Clin North Am* 2013; 25:67–76.



**De Moraes M, et al:** Randomized trials for the treatment of burning mouth syndrome. *J Oral Pathol Med* 2012; 41:281–287.

**Lopez-Jornet P, et al:** Burning mouth syndrome. *Med Oral Patol Oral Cir Bucal* 2010; 15:e562–e568.

**Minguez-Sanz M-P, et al:** Etiology of burning mouth syndrome. *Med Oral Patol Oral Cir Bucal* 2011; 16:e144–e148.

**Spanemberg JC, et al:** Aetiology and therapeutics of burning mouth syndrome. *Gerodontology* 2012; 29:84–89.

**Zakrzewska JM, et al:** Interventions for the treatment of burning mouth syndrome. *Cochrane Database Syst Rev* 2005; 25:CD002779.

## Vulvodynia

Vulvodynia is defined as vulvar discomfort, usually described as burning pain, occurring without medical findings. It is chronic, defined as lasting 3 months or longer. Two subtypes are seen, the localized and generalized subsets. Both may occur only when provoked by physical contact, as a spontaneous pain, or mixed in type. Vulvar pain may be secondary to many specific underlying disorders, but when caused by infections (most often candidal or herpetic), inflammatory conditions (e.g., lichen planus, autoimmune blistering disease), neoplastic disorders (e.g., extramammary Paget's disease, squamous cell carcinoma), neurologic etiologies (e.g., spinal nerve compression, herpetic neuralgia), or previous radiotherapy, these conditions are treated appropriately, and the patient's condition is not categorized as vulvodynia. Thus, the diagnosis of vulvodynia is a diagnosis of exclusion.

The pain experienced may be debilitating. It may be accompanied by pelvic floor abnormalities, headaches, fibromyalgia, irritable bowel syndrome, and interstitial cystitis. Psychosocial problems result and may be exacerbated by stress, depression, or anxiety or may lead to such conditions over time. A male counterpart may be seen and has been called burning genital skin syndrome and dysesthetic penodynia or scrotodynia.

Treatment should always include patient and partner education and psychological support, including sex therapy and counseling, as appropriate. Topical anesthetics and lubricants, such as petrolatum, applied before intercourse may be tried initially. Elimination of irritants, treatment of atopy with topical tacrolimus (allowing for the discontinuance of topical steroids, which have usually been tried without success), and the use of antihistamines for dermatographism may be helpful. Pelvic floor physical therapy and at times CBT may be useful. Vulvodynia is considered among the chronic pain syndromes that can have a psychological impact. Treatment then centers on the use of TCAs, SSRIs, and neuroleptics, chiefly gabapentin or pregabalin. Other interventions, such as botulinum toxin A and surgery, may be considered in individual patients, but the evidence for any of these therapies is limited.

**Andrews JC:** Vulvodynia interventions. *Obstet Gynecol Surv* 2011; 66:299–315.

**Clare CA, et al:** Vulvodynia in adolescence. *J Pediatr Adolesc Gynecol* 2011; 24:110–115.

**Markos AR:** The male genital skin burning syndrome (dysaesthetic peno/scroto-dynia). *Int J STD AIDS* 2002; 13:271–272.

**Nunns D, et al:** Guidelines for the management of vulvodynia. *Br J Dermatol* 2010; 162:1180–1185.

**Shah M, et al:** Vulvodynia. *Obstet Gynecol Clin North Am* 2014; 41:453–464.

## Notalgia paresthetica

Notalgia paresthetica is a unilateral sensory neuropathy characterized by infrascapular pruritus, burning pain, hyperalgesia, and tenderness, often in the distribution of the second to sixth thoracic spinal nerves. A pigmented patch localized to the area of pruritus is often found, caused by postinflamma-

tory change. Macular amyloidosis may be produced by chronic scratching. In most patients, degenerative changes in the corresponding vertebrae are seen, leading to spinal nerve impingement. When this is present, physical therapy, nonsteroidal anti-inflammatory drugs (NSAIDs), gabapentin, oxycarbazepine, and muscle relaxants may be helpful, as may paravertebral blocks.

Topical capsaicin or lidocaine patch has been effective, but relapse occurs in most patients after discontinuing use. Botulinum toxin A injections were reported to be successful, although an RCT failed to show efficacy. Excellent long-term results may occur, and injections may be repeated as necessary. NB UVB is also an option.

**Fleischer AB, et al:** Notalgia paresthetica. *Acta Derm Venereol* 2011; 91:356–357.

**Maari C, et al:** Treatment of notalgia paresthetica with botulinum toxin A. *J Am Acad Dermatol* 2014; 70:1139–1141.

**Perez-Perez L, et al:** Notalgia paresthetica successfully treated with narrow-band UVB. *J Eur Acad Dermatol Venereol* 2010; 24:730–732.

**Savk E, et al:** Investigation of spinal pathology in notalgia paresthetica. *J Am Acad Dermatol* 2005; 52:1085.

**Weinfeld PK, et al:** Successful treatment of notalgia paresthetica with botulinum toxin type A. *Arch Dermatol* 2007; 143:980.

## Brachioradial pruritus

This condition is characterized by itching localized to the brachioradial area of the arm. To relieve the burning, stinging, or even painful quality of the itch, patients will frequently use ice packs. The majority will have the sun-induced variety, a variant of polymorphous light syndrome that usually responds well to broad-spectrum sunscreens (see Chapter 3). In the remaining patients, cervical spine pathology is frequently found on radiographic evaluation. Searching for causes of the abnormality should include discussion of spinal injury, such as trauma, arthritis, or chronic repetitive microtrauma, whiplash injury, or assessment for a tumor in the cervical spinal column.

Gabapentin, botulinum A toxin, topical amitriptyline-ketamine or capsaicin, aprepitant, carbamazepine, cervical spine manipulation, neck traction, anti-inflammatory medications, physical therapy, and surgical resection of a cervical rib have all been successful in individual patients with brachioradial pruritus.

**Ally MS, et al:** The use of aprepitant in brachioradial pruritus. *JAMA Dermatol* 2013; 149:627–628.

**Kavanagh GM, et al:** Botulinum A toxin and brachioradial pruritus. *Br J Dermatol* 2012; 166:1147.

**Marziniak M, et al:** Brachioradial pruritus as a result of cervical spine pathology. *J Am Acad Dermatol* 2011; 65:756–762.

**Poterucha TJ, et al:** Topical amitriptyline-ketamine for the treatment of brachioradial pruritus. *JAMA Dermatol* 2013; 149:148–150.

**Veien NK, et al:** Brachioradial pruritus. *Acta Derm Venereol* 2011; 91:183–185.

## Meralgia paresthetica (Roth-Bernhardt disease)

Persistent numbness and periodic transient episodes of burning or lancinating pain on the anterolateral surface of the thigh characterize Roth-Bernhardt disease. The lateral femoral cutaneous nerve innervates this area and is subject to entrapment and compression along its course. Sensory mono-neuropathies besides notalgia paresthetica and meralgia paresthetica include mental and intercostal neuropathy and cheiralgia, gonyalgia, and digitalgia paresthetica.

Meralgia paresthetica occurs most frequently in middle-age obese men. Additionally, diabetes mellitus is seven times more common in these patients than in the general population. Alopecia localized to the area innervated by the lateral femoral

nerve may be a skin sign of this disease. External compression may occur from tight-fitting clothing, cell phones, or other heavy objects in the pockets or worn on belts, or seat belt injuries from automobile crashes. Internal compression from arthritis of the lumbar vertebrae, a herniated disk, pregnancy, intra-abdominal disease that increases intrapelvic pressure, iliac crest bone graft harvesting, diabetes, neuroma, and rarely a lumbar spine or pelvic tumor have been reported causes in individual patients.

The diagnostic test of choice is somatosensory-evoked potentials of the lateral femoral cutaneous nerve. Local anesthetics (e.g., lidocaine patch), NSAIDs, rest, avoidance of aggravating factors, and weight reduction may lead to improvement; indeed, 70% of patients have spontaneous improvement, aided by conservative measures. Gabapentin is useful in various neuropathic pain disorders. If such interventions fail and a nerve block rapidly relieves symptoms, local infiltration with corticosteroids is indicated. Surgical decompression of the lateral femoral cutaneous nerve can produce good to excellent outcomes but should be reserved for patients with intractable symptoms who responded to nerve blocks but not corticosteroids. If the nerve block does not result in symptom relief, computed tomography (CT) scan of the lumbar spine as well as pelvic and lower abdominal ultrasound examinations to assess for tumors are indicated.

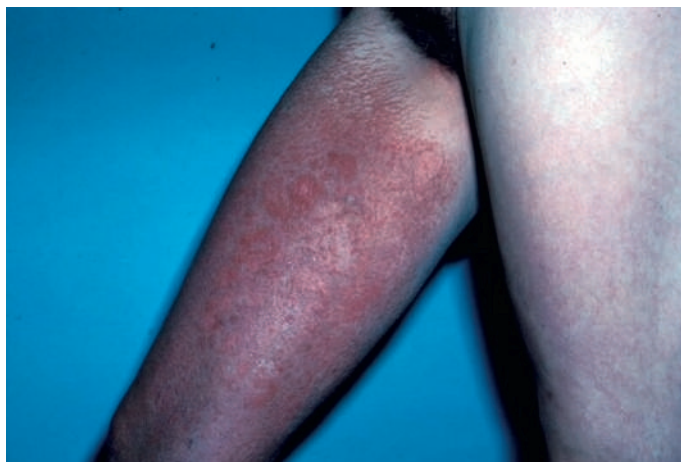**Khalil N, et al:** Treatment for meralgia paresthetica. *Cochrane Database Syst Rev* 2012; 12:CD004159.

**Parisi TJ, et al:** Meralgia paresthetica. *Neurology* 2011; 77:1538–1542.

**Patiñ J, et al:** Meralgia paresthetica. *Pain Prac* 2011; 11:302–308.

## Complex regional pain syndrome

Encompassing the descriptors reflex sympathetic dystrophy, causalgia, neuropathic pain, and Sudek syndrome, complex regional pain syndrome (CRPS) is characterized by burning pain, hyperesthesia, and trophic disturbances resulting from injury to a peripheral nerve. The continuing pain is disproportionate to the injury, which may have been a crush injury, laceration, fracture, hypothermia, sprain, burn, or surgery. It usually occurs in one of the upper extremities, although leg involvement is also common. The characteristic symptom is burning pain aggravated by movement or friction. The skin of the involved extremity becomes shiny, cold, and atrophic and may perspire profusely. Additional cutaneous manifestations include bullae, erosions, edema, telangiectases, hyperpigmentation, ulcerations, and brownish red patches with linear fissures (Fig. 4-15).



**Fig. 4-15** Complex regional pain syndrome.

The intensity of the pain in CRPS patients varies from trivial burning to a state of torture accompanied by extreme hyperesthesia and frequently hyperhidrosis. Not only is the part subject to an intense burning sensation, but a touch of the finger also causes exquisite pain. Exposure to the air is avoided with scrupulous care, and the patient walks carefully, carrying the limb tenderly with the sound hand. Patients are tremulous and apprehensive, and they keep the hand constantly wet, finding relief in the moisture rather than in the temperature of the application. A condition resembling permanent chilblains or even trophic ulcers may be present.

The syndrome usually begins with severe, localized, burning pain, focal edema, muscle spasm, stiffness or restricted mobility, and vasospasm affecting skin color and temperature. These may be followed by a diffusion of the pain and edema, diminished hair growth, brittle nails, joint thickening, and onset of muscle atrophy. Finally, irreversible trophic changes, intractable pain involving the entire limb, flexor contractures, marked atrophy of the muscles, severe limitation in joint and limb mobility, and severe osteoporosis result.

Not all patients will have all the features of CRPS, and an early diagnosis improves the chance of cure. The four major components are categorized as sensory, vasomotor, sudomotor/edema, and motor/trophic. Signs pertaining to at least two of these categories and symptoms relating to three are necessary to meet the Budapest diagnostic criteria. A three-phase technetium bone scan is helpful in confirming the diagnosis of CRPS.

Consultation with a neurologist or an anesthesiologist specializing in pain is advisable. Osteoporosis is a frequent complication, and studies using pamidronate, a powerful inhibitor of bone absorption, have been shown to improve symptoms of pain, tenderness, and swelling significantly. Pain relief, physical and vocational rehabilitation, and psychological intervention are pillars of an integrated interdisciplinary approach to patient care. These patients, their families, and caregivers require ongoing support, education, and counseling.

**Drummond PD, et al:** Sensory disturbances in complex regional pain syndrome. *Pain Med* 2010; 22:1257–1266.

**Goebel A:** Complex regional pain syndrome in adults. *Rheumatology* 2011; 50:1739–1750.

**Marinus J, et al:** Clinical features and pathophysiology of complex regional pain syndrome. *Lancet Neurol* 2011; 10:637–648.

**Slobodin G, et al:** Pamidronate treatment in rheumatology practice. *Clin Rheumatol* 2009; 28:1359–1364.

**Tran DQH, et al:** Treatment of complex regional pain syndrome. *Can J Anesth* 2010; 57:149–166.

**Turner-Stokes L, et al:** Complex regional pain syndrome in adults. *Clin Med* 2011; 11:596–600.

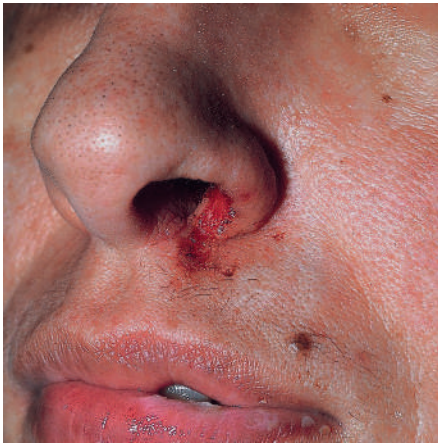**Wasner G:** Vasomotor disturbances in complex regional pain syndrome. *Pain Med* 2010; 11:1267–1273.

**Wertli M et al:** Prognostic factors in complex regional pain syndrome. *J Rehabil Med* 2013; 45:225–231.

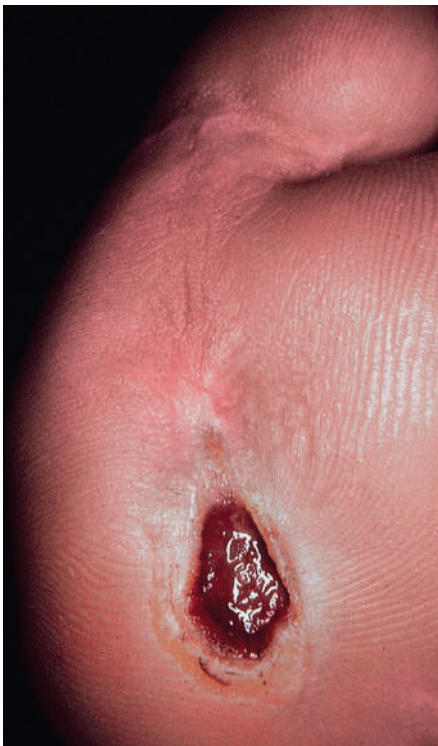
## Trigeminal trophic syndrome

Interruption of the peripheral or central sensory pathways of the trigeminal nerve may result in a slowly enlarging, unilateral, uninfamed ulcer on ala nasi or adjacent cheek skin (Fig. 4-16). The nasal tip is spared. It may infrequently occur elsewhere on the face, scalp, ear, or palate. The neck has been reported to be affected in the so-called cervical trophic syndrome, secondary to herpes zoster-associated nerve injury. Onset of ulceration varies from weeks to several years after nerve injury. Biopsy to exclude tumor or a variety of granulomatous or infectious etiologies is usually indicated. The cause is self-inflicted trauma to the anesthetic skin; the appropriate treatment is to prevent this by occlusion or with psychotropic





**Fig. 4-16** Trigeminal trophic syndrome.



**Fig. 4-17** Mal perforans ulcer.

medication, which is usually successful. Scarring may be severe.

**Collyer S, et al:** Trigeminal trophic syndrome. *Pract Neurol* 2012; 12:341–342.

**Franklin J, et al:** Cervical neuropathic ulceration. *J Otolaryngol Head Neck Surg* 2012; 41:E20–E22.

**Samarin FM, et al:** Cervical trophic syndrome. *J Am Acad Dermatol* 2010; 63:724–725.

### Mal perforans pedis

Also known as neuropathic ulceration or perforating ulcer of the foot, mal perforans is a chronic ulcerative disease seen on the sole in conditions that result in loss of pain sensation at a site of constant trauma (Fig. 4-17). The primary cause lies in the posterolateral tracts of the cord (in arteriosclerosis and tabes dorsalis), lateral tracts (in syringomyelia), or peripheral nerves (in diabetes or Hansen's disease).

In most patients, mal perforans begins as a circumscribed hyperkeratosis, usually on the ball of the foot. This lesion

becomes soft, moist, and malodorous and later exudes a thin, purulent discharge. A slough slowly develops, and an indolent necrotic ulcer is left that lasts indefinitely. Whereas the neuropathy renders the ulceration painless and walking continues, plantar ulcers in this condition have a surrounding thick callus. Deeper perforation and secondary infection often lead to osteomyelitis of the metatarsal or tarsal bones.

Treatment consists of relief of pressure on the ulcer through use of a total-contact cast and debridement of the surrounding callosity. Removable off-loading devices were found to be significantly less effective in a systematic review and meta-analysis. Administration of local and systemic antibiotics is sometimes helpful.

**Morona JK, et al:** Comparison of the clinical effectiveness of different off-loading devices for the treatment of neuropathic foot ulcers in patients with diabetes. *Diabetes Metab Res Rev* 2013; 29:183–193.

### Sciatic nerve injury

Serious sciatic nerve injury can result from improperly performed injections into the buttocks. Older patients are more susceptible to injection-induced sciatic nerve injury because of their decreased muscle mass or the presence of debilitating disease. The most common scenario for nerve damage is improper needle placement. Other common causes of sciatic neuropathy are hip surgery complications, hip fracture and dislocation, and compression by benign and malignant tumors. A paralytic footdrop is the most common finding. There is sensory loss and absence of sweating over the distribution of the sciatic nerve branches. The skin of the affected extremity becomes thin, shiny, and often edematous.

Surgical exploration, guided by nerve action potentials, with repair of the sciatic nerve is worthwhile and is most successful if done soon after injury.

**Topuz K, et al:** Early surgical treatment protocol for sciatic nerve injury due to injection: a retrospective study. *Br J Neurosurg* 2011; 25:509–515.

### Syringomyelia

Syringomyelia results from cystic cavities inside the cervical spinal cord caused by alterations of cerebrospinal fluid flow. Compression of the lateral spinal tracts produces sensory and trophic changes on the upper extremities, particularly in the fingers. The disease begins insidiously and gradually causes muscular weakness, hyperhidrosis, and sensory disturbances, especially in the thumb and index and middle fingers. The skin changes are characterized by dissociated anesthesia with loss of pain and temperature sense but retention of tactile sense. Burns are the most frequent lesions noted. Bullae, warts, and trophic ulcerations occur on the fingers and hands, and eventually contractures and gangrene occur. Other unusual features include hypertrophy of the limbs, hands, or feet and asymmetric scalp hair growth with a sharp midline demarcation. The disease must be differentiated chiefly from Hansen's disease. Unlike Hansen's disease, syringomyelia does not interfere with sweating or block the flare around a histamine wheal.

Early surgical treatment allows for improvement of symptoms and prevents progression of neurologic deficits.

**Stienen MN, et al:** Adult syringomyelia. *Praxis (Bern 1994)* 2011; 100:715–725.

## Hereditary sensory and autonomic neuropathies

A number of inherited conditions are characterized by variable degrees of motor and sensory dysfunctions combined with autonomic alterations. From a dermatologic standpoint, altered pain and temperature sensation, trophic changes, sweating abnormalities, ulcers of the hands and feet, and in some patients, self-mutilating behavior may be present. These five syndromes and their variants are now known to be secondary to disease-producing mutations in 12 genes.

**Rotthier A, et al:** Mechanisms of disease in hereditary sensory and autonomic neuropathies. *Nat Rev Neurol* 2012; 8:73–85.



Bonus images for this chapter can be found online at

[expertconsult.inkling.com](http://expertconsult.inkling.com)

**eFig. 4-1** Eczema craquelé.

**eFig. 4-2** Lichen sclerosis in patient with vitiligo.

**eFig. 4-3** Lichen simplex chronicus.

**eFig. 4-4** Prurigo nodularis. (Courtesy of Lawrence Lieblich, MD.)

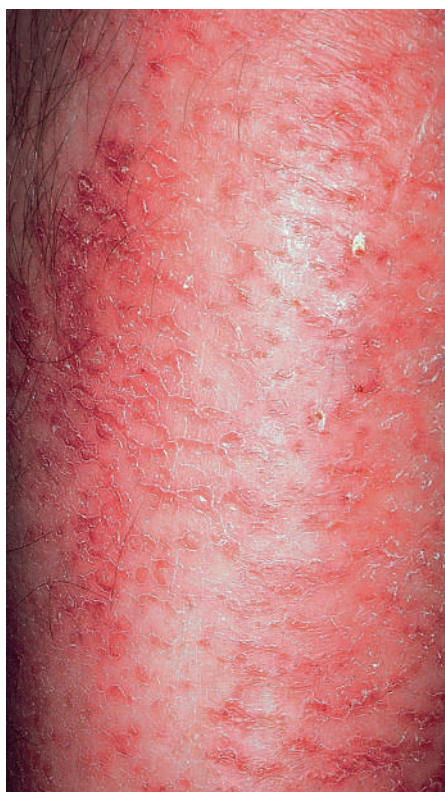**eFig. 4-5** Samples brought in by patient with delusions of parasitosis.

**eFig. 4-6** Factitial ulcer.

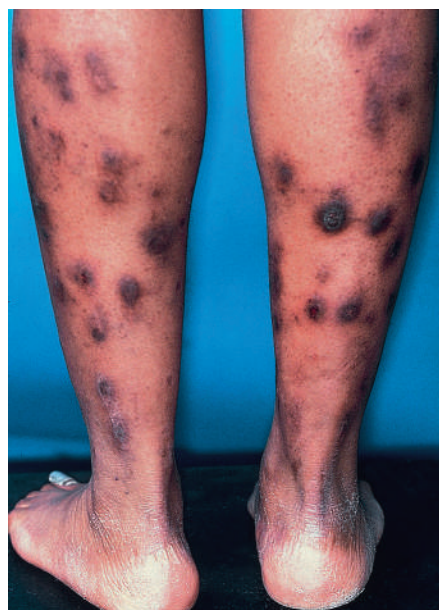
**eFig. 4-7** Complex regional pain syndrome.

**eFig. 4-8** Diabetic foot ulcer.

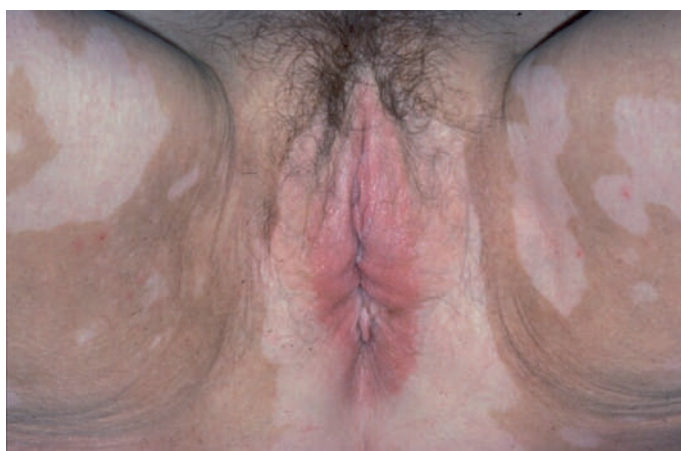



**eFig. 4-1** Eczema craquelé.



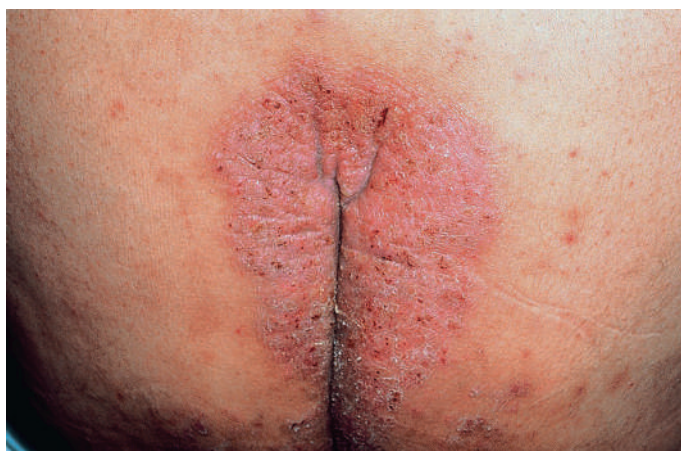**eFig. 4-4** Prurigo nodularis. (Courtesy of Lawrence Lieblich, MD.)



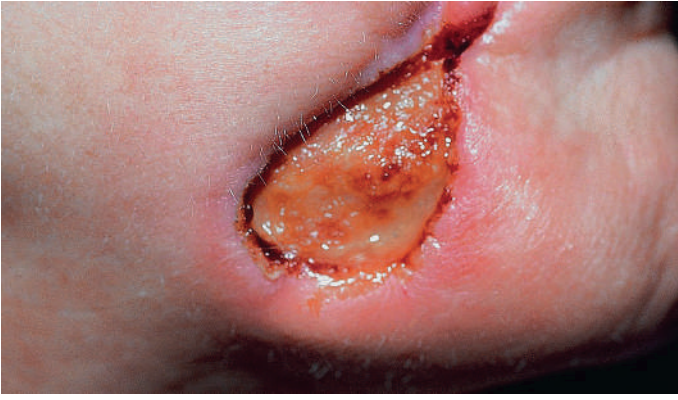
**eFig. 4-2** Lichen sclerosus in patient with vitiligo.



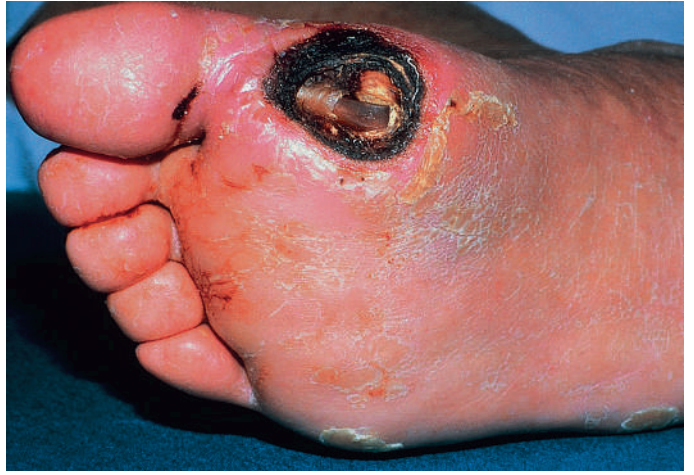**eFig. 4-5** Samples brought in by patient with delusions of parasitosis.



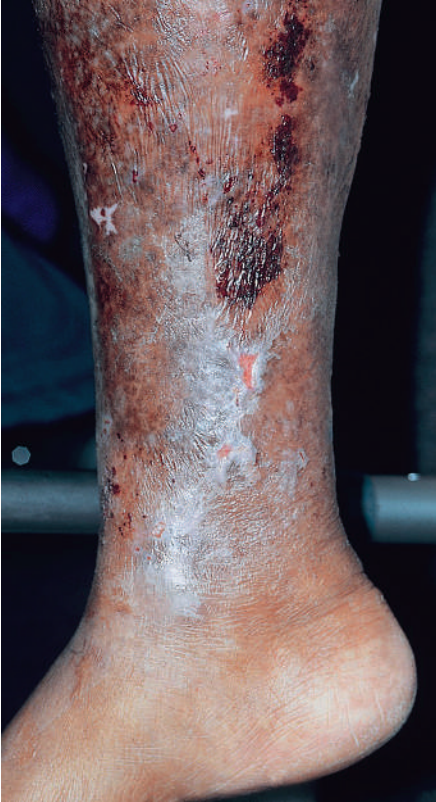**eFig. 4-3** Lichen simplex chronicus.



**eFig. 4-6** Factitial ulcer.



**eFig. 4-8** Diabetic foot ulcer.



**eFig. 4-7** Complex regional pain syndrome.



# 5

## Atopic Dermatitis, Eczema, and Noninfectious Immunodeficiency Disorders

### ATOPIC DERMATITIS

Atopic dermatitis (AD) is a chronic, inflammatory skin disease characterized by pruritus and a chronic course of exacerbations and remissions. It is associated with other allergic conditions, including food allergies, asthma, and allergic rhinoconjunctivitis. Because AD precedes the appearance of these other “atopic” conditions, it has been proposed that AD is the first step in an “atopic march.” Although this sequence of atopic conditions does occur in many children, whether the AD is causal in the development of the other manifestations of atopy is unproved but plausible. For this reason, early and effective treatment of AD is encouraged in an effort to prevent other atopic conditions. The genetic defect(s) predisposing at-risk individuals to the development of AD is the same for asthma and allergic rhinoconjunctivitis, and thus it has been difficult to prove that AD is causal in the development of other atopic conditions.

### Epidemiology

The prevalence of AD, asthma, and allergic rhinoconjunctivitis increased dramatically in the last half of the 20th century, becoming a major health problem in many countries. The increase began first in the most developed nations, and as the standard of living has increased worldwide, so has the prevalence of AD. Rates of AD are about 30% in the most developed nations and exceed 10% in many countries, resulting in a worldwide cumulative prevalence of 20%. In the most developed nations, the rates of AD plateaued in the 1990s, whereas developing nations have rates that continue to increase. Other factors associated with high rates of AD are high latitude (perhaps associated with low levels of annual sun exposure) and lower mean annual temperature. A role for exposure to allergens thought to “trigger” AD is not supported by epidemiologic studies. Iceland has a very high rate of AD (27%) yet has no dust mites, few trees, and low pet ownership. However, children in Iceland often have positive skin prick tests to environmental allergens (24%). This questions the value of such tests in predicting causal environmental allergens in AD. Girls are slightly more likely to develop AD. In the United States, an increased risk of AD during the first 6 months of life is noted in infants with African and Asian race/ethnicity, male gender, greater gestational age at birth, and a family history of atopy, particularly a maternal history of eczema. Other factors that increase the risk for the development of AD early in childhood include consumption of a Western diet, birth order (first children at greater risk), and delivery by cesarean section, all of which alter the intestinal microbiome. Specifically, gut colonization with *Clostridium* cluster I is associated with development of AD. Dog ownership before age 1 year decreases the risk of developing AD by age 4, but cat ownership has no effect.

About 50% of cases of AD appear in the first year of life, the vast majority within the first 5 years of life, and the remaining cases of “adult” AD usually before age 30. Atopy is now so common in the population that most individuals have a family history of atopy. Elevated IgE levels are not diagnostic of atopic disease in the adult. Therefore, elevated IgE and a family history of “atopy” in an adult with new-onset dermatitis should not be used to confirm the diagnosis of adult AD. Rather, a dermatologist should infrequently make the diagnosis of adult “atopic dermatitis” for a dermatitis appearing for the first time after age 30. Adult AD should only be considered when the dermatitis has a characteristic distribution and when other significant diagnoses, such as allergic contact dermatitis, photodermatitis, and cutaneous T-cell lymphoma, have been excluded.

### Genetic basis and pathogenesis

Eighty percent of identical twins show concordance for AD. A child is at increased risk of developing AD if either parent is affected. More than one quarter of offspring of atopic mothers develop AD in the first 3 months of life. If one parent is atopic, more than half the children will develop allergic symptoms by age 2. This rate rises to 79% if both parents are atopic. All these findings strongly suggested a genetic cause for AD. Filaggrin is a protein encoded by the gene *FLG*, which resides in the epidermal differentiation complex (EDC) on chromosome 1q21. Ichthyosis vulgaris is caused by mutations in the *FLG* gene and is frequently associated with AD. Four *FLG* mutations (R501X, 2282del4, S3247X, and R2447X) have an estimated combined allelic frequency of 7–10% in individuals of European descent. Different *FLG* gene mutations are associated with AD in Asians. Filaggrin 2 (*FLG2*), also in the EDC and with similar function to *FLG*, is associated with persistent AD in African Americans (but not with asthma, food allergies, or seasonal allergies). In persons of European descent, inheriting one null *FLG* mutation slightly increases one’s risk of developing AD, and inheriting two mutations, either as a homozygote or a compound heterozygote, dramatically increases one’s risk. Between 42% and 79% of persons with one or more *FLG* null mutations will develop AD. *FLG* mutations account for 11–15% of AD cases in Europe. However, 40% of carriers with *FLG* null mutations never have AD. *FLG* mutations are associated with AD that presents early in life, tends to persist into childhood and adulthood, and is associated with wheezing in infancy and with asthma. *FLG* mutations are also associated with allergic rhinitis and keratosis pilaris, independent of AD. Hyperlinear palms are strongly associated with *FLG* mutations, with a 71% positive predictive value (PPV) for marked palmar hyperlinearity. *LAMA3* gene mutations, encoding the alpha chain of laminin 5, may also predispose to AD.

Not all cases of AD are associated with *FLG* mutations. AD patients often demonstrate immunologic features

consistent with a T-helper 2 (Th2) phenotype, with elevated IgE, eosinophils on skin biopsy, and positive skin tests and radioallergosorbent test (RAST). Thymic stromal lymphopoietin (TSLP) is an important interleukin-7 (IL-7) like cytokine that, through its interaction with mast cells and dendritic cells, promotes the secretion and production of Th2 cytokines and the development of inflammatory Th2 CD4+ T cells (through production of OLA40L). TSLP is produced by keratinocytes and is found in high levels in AD skin lesions. Th2 innate lymphoid cells are also increased in AD skin, as are Th22 cells. In addition, IL-31 is produced by Th2 and Th22 cells, is associated with itching, and downregulates keratinocyte expression of filaggrin. Thus, AD appears to represent a disorder characterized by a barrier defect that engages the production of a specific Th2 immunophenotype through specific cell types and effected by specific cytokines. The cytokines produced worsen the already defective barrier. This leads to a vicious cycle of barrier failure and progressive inflammation, producing a chronic, relapsing, pruritic disorder.

### Prevention in high-risk children

Extensive studies have been undertaken to determine whether it is possible to prevent the development of AD in children at high risk—those with parents or siblings with atopy. Soy formulas do not appear to reduce the risk of developing AD. Prolonged exclusive breastfeeding beyond 3–4 months of age is not protective for the development of AD. Extensively hydrolyzed casein formulas may be used as a supplement or substitute for breast milk during the first 4 months of life. Maternal allergen avoidance during pregnancy does not reduce the risk of AD in the offspring. The use of probiotics and prebiotics is not currently recommended, although some studies suggest these may be effective in reducing AD. House dust mite (HDM) avoidance does not reduce AD, even in sensitized individuals, and high levels of HDM in the environment in early life reduces AD risk. Aggressive emollient therapy early in life is recommended to repair any genetic or acquired epidermal barrier defect.

### Food allergy

The role of food allergy in AD is complicated, and the purported role of foods in AD has changed in recent years. Parents may be misinformed about food allergy by outdated Internet resources. Approximately 35% of children with moderate to severe AD have food allergy. However, 85% of children with AD will have elevated IgE to food or inhalant allergens, making a diagnosis of food allergy with serum or prick tests alone inadvisable. Before food allergy testing is undertaken, treatment of the AD should be optimized. Parents are often seeking a “cause” for the child’s AD, when in fact it could be controlled with appropriate topical measures. Food restriction diets can be difficult and could put the child at risk for malnourishment, and thus food allergy should be pursued only in children under age 5 years with more severe AD in whom standard treatments have failed. These children should also have a history of possible triggering of AD by specific food exposures. Testing, if performed, should only include foods to which the child is likely to be exposed. Double-blind placebo-controlled food challenges are the “gold standard” for diagnosing food allergy. Skin prick tests have a high negative predictive value (NPV >95%) but PPV of only 30–65%. For example, more than 8% of the U.S. population has a positive prick test to peanut, but only 0.4% are actually clinically allergic. Possible food allergy detected by testing should be confirmed by clinical history. A positive RAST or skin prick test for a food that the child rarely or never ingests is probably not

causally relevant to their AD. Higher serum IgE levels and larger wheal sizes (>8–10 mm) are associated with greater likelihood of reacting to these foods when challenged. About 90% of food allergy is caused by a limited number of foods, as follows:

- Infants: cow’s milk, egg, soybean, wheat
- Children (2–10 years): cow’s milk, egg, peanut, tree nuts, fish, crustacean shellfish, sesame, kiwi fruit
- Older children: peanut, tree nuts, fish, shellfish, sesame, pollen-associated foods

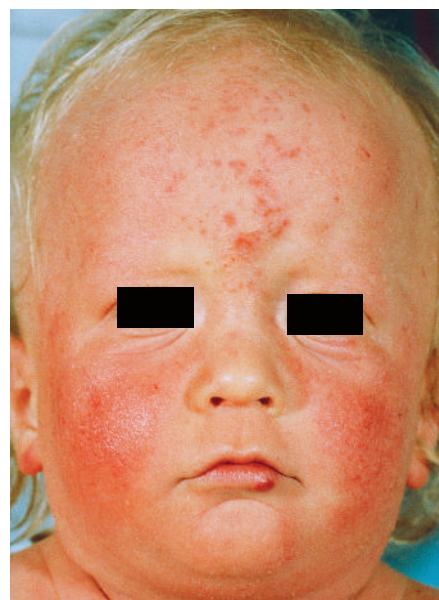Breastfeeding mothers must avoid the incriminated foods if their infant has been diagnosed with a food allergy.

### Clinical manifestations

Atopic dermatitis can be divided into three stages: infantile AD, occurring from 2 months to 2 years of age; childhood AD, from 2–10 years; and adolescent/adult AD. In all stages, pruritus is the hallmark. Itching often precedes the appearance of lesions; thus the concept that AD is “the itch that rashes.” Useful diagnostic criteria include those of Hannifin and Rajka, the UK Working Party, and the American Academy of Dermatology’s Consensus Conference on Pediatric Atopic Dermatitis (Boxes 5-1 and 5-2). These criteria have specificity at or above 90% but have much lower sensitivities (40–100%). Therefore, these criteria are useful for enrolling patients in studies and ensuring that they have AD, but not so useful in diagnosing a specific patient with AD.

### Infantile atopic dermatitis

Fifty percent or more of AD cases present in the first year of life, but usually not until after 2 months. Eczema in infancy usually begins as erythema and scaling of the cheeks (Fig. 5-1). The eruption may extend to the scalp, neck, forehead, wrists, extensor extremities, and buttocks. Children with AD who are *FLG* gene mutants specifically have more cheek and extensor arm/hand involvement. There may be significant exudate; secondary effects from scratching, rubbing, and infection include crusts, infiltration, and pustules, respectively. The infiltrated plaques eventually take on a characteristic lichenified appearance. The infantile pattern of AD usually disappears by the end of the second year of life.



**Fig. 5-1** Involvement of the cheeks in infantile atopic dermatitis.



**Box 5-1** Criteria for atopic dermatitis**Major criteria**

Must have three of the following:

1. Pruritus
2. Typical morphology and distribution
  - Flexural lichenification in adults
  - Facial and extensor involvement in infancy
3. Chronic or chronically relapsing dermatitis
4. Personal or family history of atopic disease (e.g., asthma, allergic rhinitis, atopic dermatitis)

**Minor criteria**

Must also have three of the following:

1. Xerosis
2. Ichthyosis/hyperlinear palms/keratosis pilaris
3. IgE reactivity (immediate skin test reactivity, RAST test positive)
4. Elevated serum IgE
5. Early age of onset
6. Tendency for cutaneous infections (especially *Staphylococcus aureus* and HSV)
7. Tendency to nonspecific hand/foot dermatitis
8. Nipple eczema
9. Cheilitis
10. Recurrent conjunctivitis
11. Dennie-Morgan infraorbital fold
12. Keratoconus
13. Anterior subcapsular cataracts
14. Orbital darkening
15. Facial pallor/facial erythema
16. Pityriasis alba
17. Itch when sweating
18. Intolerance to wool and lipid solvents
19. Perifollicular accentuation
20. Food hypersensitivity
21. Course influenced by environmental and/or emotional factors
22. White dermatographism or delayed blanch to cholinergic agents

RAST, Radioallergosorbent assay; HSV, herpes simplex virus.

Worsening of AD is often observed in infants after immunizations and viral infections. Partial remission may occur during the summer, with relapse in winter. This may relate to the therapeutic effects of ultraviolet (UV) B light and humidity in many atopic patients, as well as the aggravation by wool and dry air in the winter.

**Childhood atopic dermatitis**

During childhood, lesions tend to be less exudative. The classic locations are the antecubital and popliteal fossae (Fig. 5-2), flexor wrists, eyelids, face, and around the neck. Lesions are often lichenified, indurated plaques and in African American patients may have a lichenoid appearance and favor the extensor surfaces. These are intermingled with isolated, excoriated, 2–4 mm papules that are scattered more widely over the uncovered parts. Nummular morphology and involvement of the feet are more common in childhood AD.

Pruritus is a constant feature, and most of the cutaneous changes are secondary to it. Itching is paroxysmal. Scratching induces lichenification and may lead to secondary infection. A vicious cycle may be established, the itch-scratch cycle, as pruritus leads to scratching, and scratching causes secondary

**Box 5-2** Modified criteria for children with atopic dermatitis**Essential features**

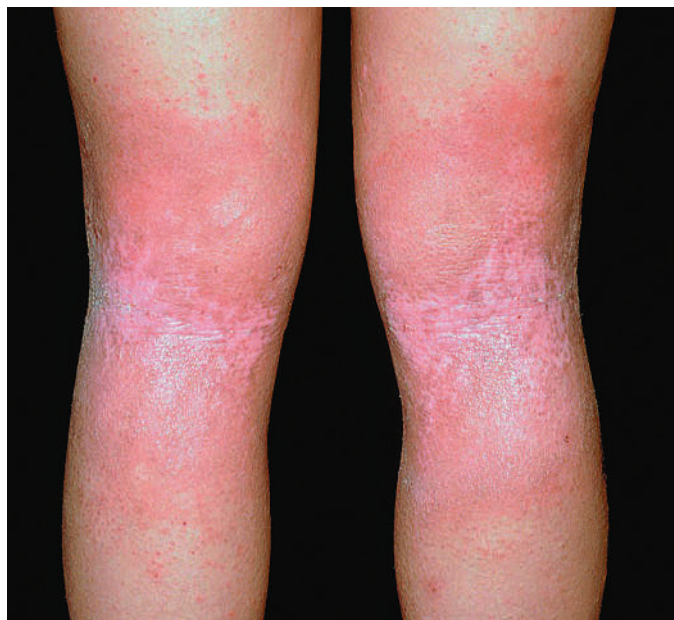1. Pruritus
2. Eczema
  - Typical morphology and age-specific pattern
  - Chronic or relapsing history

**Important features**

1. Early age at onset
2. Atopy
3. Personal and/or family history
4. IgE reactivity
5. Xerosis

**Associated features**

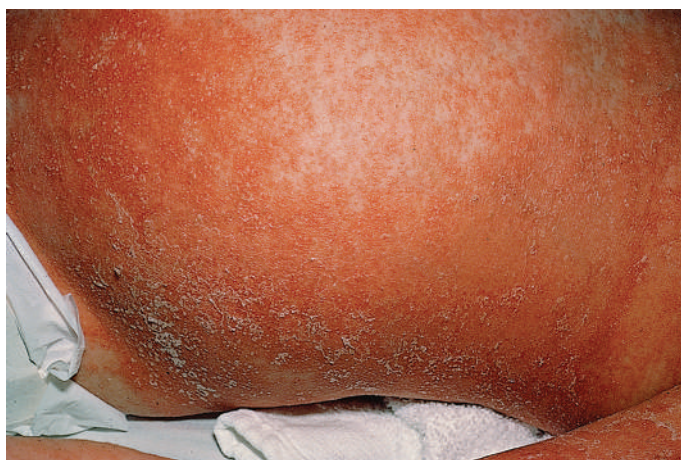1. Atypical vascular responses (e.g., facial pallor, white dermatographism)
2. Keratosis pilaris/ichthyosis/hyperlinear palms
3. Orbital/periorbital changes
4. Other regional findings (e.g., perioral changes/periauricular lesions)
5. Perifollicular accentuation/lichenification/prurigo lesions



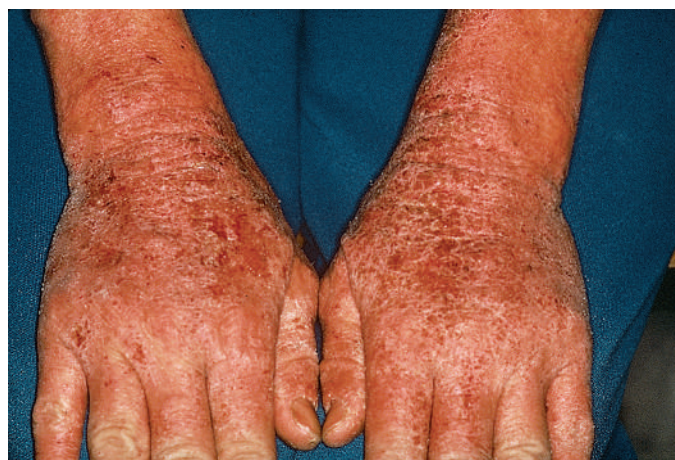**Fig. 5-2** Flexural involvement in childhood atopic dermatitis.

changes that in themselves cause itching. Instead of scratching causing pain, in the atopic patient the “pain” induced by scratching is perceived as itch and induces more scratching. The scratching impulse is beyond the control of the patient. Severe bouts of scratching occur during sleep, leading to poor rest and chronic tiredness in atopic children. This can affect school performance.

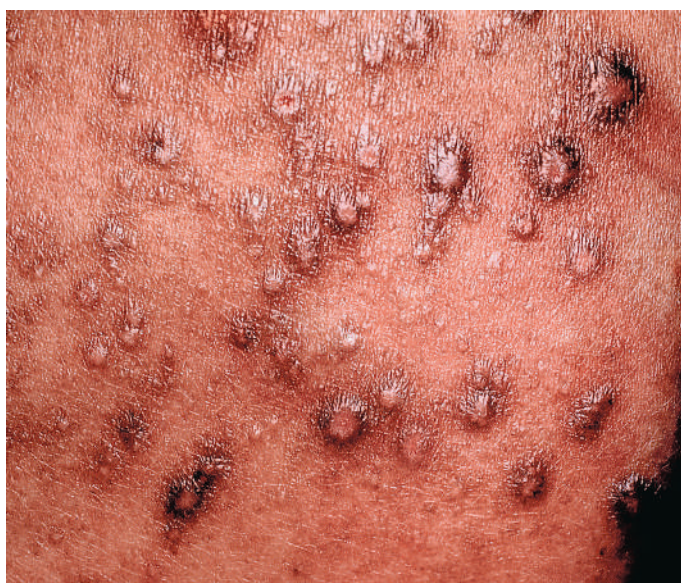Severe AD involving a large percentage of the body surface area can be associated with growth retardation (Fig. 5-3). Restriction diets and steroid use may exacerbate growth impairment. Aggressive management of such children with phototherapy or systemic immunosuppressive agents may allow for rebound growth. Children with severe AD may also have substantial psychological disturbances. Parents should be questioned with regard to school performance and socialization.



**Fig. 5-3** Severe, widespread atopic dermatitis.



**Fig. 5-5** Atopic hand dermatitis.



**Fig. 5-4** Prurigo-like papules in adult atopic dermatitis.

## Atopic dermatitis in adolescents and adults

Most adolescents and adults with AD will give a history of childhood disease. AD will begin after age 18 years in only 6–14% of patients diagnosed with AD. One exception is the patient who moves from a humid, tropical region to a more temperate area of higher latitude. This climatic change is often associated with the appearance of AD. In older patients, AD may occur as localized erythematous, scaly, papular, exudative, or lichenified plaques. In adolescents, the eruption often involves the classic antecubital and popliteal fossae, front and sides of the neck, forehead, and area around the eyes. In older adults, the distribution is generally less characteristic, and localized dermatitis may be the predominant feature, especially hand, nipple, or eyelid eczema. At times, the eruption may generalize, with accentuation in the flexures. The skin generally is dry and somewhat erythematous. Lichenification and prurigo-like papules are common (Fig. 5-4). Papular lesions tend to be dry, slightly elevated, and flat topped. They are almost always excoriated and often coalesce to form plaques. Staphylococcal colonization is almost universal. In darker-skinned patients, the lesions are often dramatically hyperpigmented, frequently with focal hypopigmented areas related to healed excoriations.

Itching usually occurs in crises or paroxysms, often during the evening when the patient is trying to relax or during the night. Adults frequently complain that flares of AD are triggered by acute emotional upsets. Stress, anxiety, and depression reduce the threshold at which itch is perceived and result in damage to the epidermal permeability barrier, further exacerbating AD. Atopic persons may sweat poorly and may complain of severe pruritus related to heat or exercise. Physical conditioning and liberal use of emollients improve this component, and atopic patients can participate in competitive sports.

Even in patients with AD in adolescence or early adulthood, improvement usually occurs over time, and dermatitis is uncommon after middle life. In general, these patients retain mild stigmata of the disease, such as dry skin, easy skin irritation, and itching in response to heat or perspiration. They remain susceptible to a flare of their disease when exposed to the specific allergen or environmental situation. Some will flare in response to aeroallergens, and a few patients will develop flexural dermatitis in response to niacin-induced flushing. Photosensitivity develops in approximately 3% of AD patients and may manifest as either a polymorphous light eruption-type reaction or simply exacerbation of the AD by UV exposure. Most patients (65%) are sensitive to UVA and UVB light, but about 17% are sensitive to only UVA or UVB. The average age for photosensitive AD is the middle to late thirties. Human immunodeficiency virus (HIV) infection can also serve as a trigger, and new-onset AD in an at-risk adult should lead to counseling and testing for HIV if warranted.

The hands, including the wrists, are frequently involved in adults, and hand dermatitis is a common problem for adults with a history of AD. It is extremely common for atopic hand dermatitis to appear in young women after the birth of a child, when increased exposure to soaps and water triggers their disease. Wet work is a major factor in hand eczema in general, including those patients with AD. Atopic hand dermatitis can affect both the dorsal and the palmar surface (Fig. 5-5). Keratosis punctata of the creases, a disorder seen almost exclusively in black persons, is also more common in atopic patients. Patients with AD have frequent exposure to preservatives and other potential allergens in the creams and lotions that are continually applied to their skin. Contact allergy may manifest as chronic hand eczema. Patch testing with clinical correlation is the only certain way to exclude contact allergy in an atopic patient with chronic hand dermatitis.

Eyelids are often involved (Fig. 5-6). In general, the involvement is bilateral and the condition flares with cold weather. As in hand dermatitis, irritants and allergic contact allergens must be excluded by a careful history and patch testing.



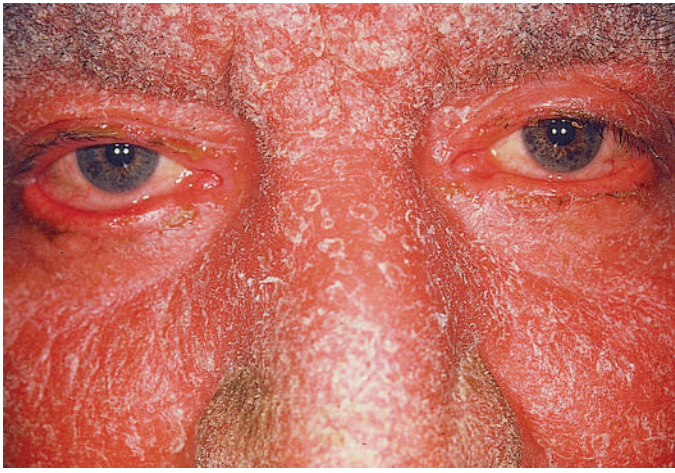

Fig. 5-6 Periorcular atopic dermatitis.

## Associated features and complications

### Cutaneous stigmata

A linear transverse fold just below the edge of the lower eyelids, known as the Dennie-Morgan fold, is widely believed to be indicative of the atopic diathesis, although it may be seen with any chronic dermatitis of the lower lids. In atopic patients with eyelid dermatitis, increased folds and darkening under the eyes is common. When taken together with other clinical findings, these remain helpful clinical signs. A prominent nasal crease may also be noted.

The less involved skin of atopic patients is frequently dry and slightly erythematous and may be scaly. Histologically, the apparently normal skin of atopic patients is frequently inflamed subclinically. The dry, scaling skin of AD may represent low-grade dermatitis. Filaggrin is processed by caspase 14 during terminal keratinocyte differentiation into highly hydroscopic pyrrolidone carboxylic acid and urocanic acid, collectively known as the “natural moisturizing factor” (NMF). Null mutations in *FLG* lead to reduction in NMF, which probably contributes to the xerosis that is almost universal in AD. Transepidermal water loss (TEWL) is increased. This may be caused by subclinical dermatitis, but also by abnormal delivery of lamellar body epidermal lipids (especially ceramide) to the interstices of the terminally differentiated keratinocytes. The resulting defective lipid bilayers retain water poorly, leading to increased TEWL and clinical xerosis. Pityriasis alba is a form of subclinical dermatitis, frequently atopic in origin. It presents as poorly marginated, hypopigmented, slightly scaly patches on the cheeks, upper arms, and trunk, typically in children and young adults. It usually responds to emollients and mild topical steroids, preferably in an ointment base.

Keratosis pilaris (KP) consists of horny follicular lesions of the outer aspects of the upper arms, legs, cheeks, and buttocks and is often associated with AD. The keratotic papules on the face may be on a red background, a variant of KP called keratosis pilaris rubra faciei. KP is often refractory to treatment. Moisturizers alone are only partially beneficial. Some patients will respond to topical lactic acid, urea, or retinoids. Retinoids can easily irritate the skin of atopic patients, and treatment should begin with applications only once or twice a week. KP must be distinguished from follicular eczema because AD and other eczemas are typically folliculocentric, especially in black patients.

Thinning of the lateral eyebrows (Hertoghe’s sign) is sometimes present. This apparently occurs from chronic rubbing caused by pruritus and subclinical dermatitis. Hyperkeratosis

and hyperpigmentation, which produce a “dirty neck” appearance, are also common in AD patients.

### Vascular stigmata

Atopic individuals often exhibit perioral, perinasal, and peri-orbital pallor (“headlight sign”). White dermatographism is blanching of the skin at the site of stroking with a blunt instrument. This reaction differs from the triple response of Lewis, in that it typically lacks a wheal, and the third response (flaring) is replaced by blanching to produce a white line.

Atopic patients are at increased risk of developing various forms of urticaria, including contact urticaria. Episodes of contact urticaria may be followed by typical eczematous lesions at the affected site.

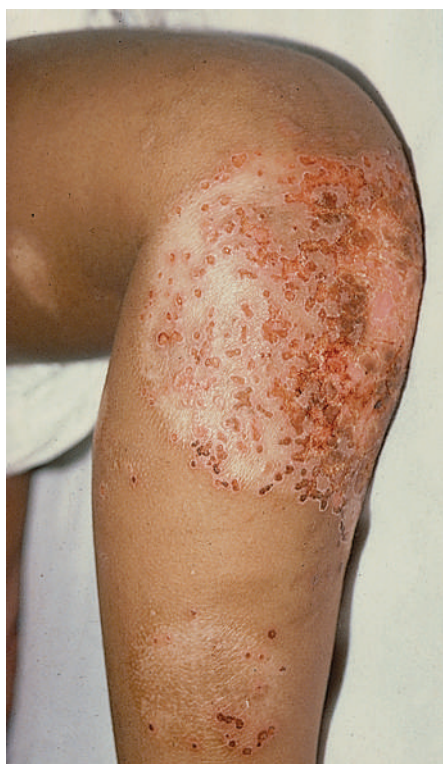### Ophthalmologic abnormalities

Up to 10% of patients with AD develop cataracts, either anterior or posterior subcapsular. Posterior subcapsular cataracts in atopic individuals are indistinguishable from corticosteroid-induced cataracts. Development of cataracts is more common in patients with severe dermatitis. Keratoconus is an uncommon finding, occurring in approximately 1% of atopic patients. Contact lenses, keratoplasty, and intraocular lenses may be required to treat this condition.

### Susceptibility to infection

More than 90% of chronic eczematous lesions contain *Staphylococcus aureus*, often in large numbers. In addition, the apparently normal nonlesional skin of atopic patients is also frequently colonized by *S. aureus*. The finding of increasing numbers of pathogenic staphylococci on the skin of a patient with AD is frequently associated with weeping and crusting of skin lesions, retro- and infra-auricular and perinasal fissures, folliculitis, and adenopathy. In any flaring atopic patient, the possibility of secondary infection must be considered. IgE antibodies directed against *Staphylococcus* and its toxins have been documented in some atopic individuals. Staphylococcal production of superantigens is another possible mechanism for staphylococcal flares of disease. Treatment of lesions of AD with topical steroids is associated with reduced numbers of pathogenic bacteria on the surface, even if antibiotics are not used. Despite the frequent observation that the presence of staphylococcal infection of lesions of AD is associated with worsening of disease, it has been impossible to prove that oral antibiotic therapy makes a long-term difference in the course of the AD. Nonetheless, treatment of the “infected” AD patient with oral antibiotics is a community standard of dermatologists worldwide.

With the widespread presence of antibiotic-resistant *S. aureus*, dermatologists have shifted from the chronic use of oral antibiotics in managing patients with frequent flares of AD associated with staphylococcal infection. Rather, bleach baths and reduction of nasal carriage have become the basis for controlling infection-triggered AD. In an occasional patient with AD and frequent infections, chronic suppressive oral antibiotic therapy may stabilize the disease. Options include cephalosporins, trimethoprim-sulfamethoxazole (TMP-SMX), clindamycin, and (in older patients) doxycycline. Identifying and treating *S. aureus* carriers in the family and pets may also be of benefit. An unusual complication of *S. aureus* infection in patients with AD is subungual infection, with osteomyelitis of the distal phalanx. In atopic patients with fever who appear very toxic, the possibility of streptococcal infection must be considered. These children may require hospital admission and intravenous antibiotics.



**Fig. 5-7** Recurrent herpes simplex in atopic dermatitis.

Patients with AD have increased susceptibility to generalized herpes simplex infection (eczema herpeticum), as well as widespread vaccinia infection (eczema vaccinatum) and complicated varicella. Eczema herpeticum is seen most frequently in young children and is usually associated with herpes simplex virus (HSV) type 1 transmitted from a parent or sibling. Once infected, the atopic may have recurrences of HSV and repeated episodes of eczema herpeticum. Eczema herpeticum presents as the sudden appearance of vesicular, pustular, crusted, or eroded lesions concentrated in the areas of dermatitis (Fig. 5-7). The lesions may continue to spread, and most of the skin surface may become involved. Secondary staphylococcal infection is common, and local edema and regional adenopathy frequently occur. If lesions of eczema herpeticum occur on or around the eyelids, ophthalmologic evaluation is recommended. The severity of eczema herpeticum is quite variable, but most cases require systemic antiviral therapy and an anti-staphylococcal antibiotic. Delayed administration of acyclovir in hospitalized patients is associated with prolonged hospital stay. Genetic variants in TSLP and interferon regulatory factor 2 (IFR-2) are associated with AD and eczema herpeticum.

Vaccination against smallpox is contraindicated in persons with AD, even when the dermatitis is in remission. Widespread and even fatal vaccinia can occur in patients with an atopic diathesis.

Atopic individuals may also develop extensive flat warts or molluscum contagiosum. Because the skin is easily irritated, chemical treatments such as salicylic acid and cantharidin are poorly tolerated. Destruction with curettage (for molluscum), cryosurgery, or electrosurgery may be required to clear the lesions.

### Differential diagnosis

Typical AD in infancy and childhood is not difficult to diagnose because of its characteristic morphology; predilection for symmetric involvement of the face, neck, and antecubital and

popliteal fossae; and association with food allergy, asthma, and allergic rhinoconjunctivitis. Dermatoses that may resemble AD include seborrheic dermatitis (especially in infants), irritant or allergic contact dermatitis, nummular dermatitis, photodermatitis, scabies, and cases of psoriasis with an eczematous morphology. Certain immunodeficiency syndromes (see later discussion) may exhibit a dermatitis remarkably similar or identical to AD.

### Histopathology

The histology of AD varies with the stage of the lesion, with many of the changes induced by scratching. Hyperkeratosis, acanthosis, and excoriation are common. Staphylococcal colonization may be noted histologically. Although eosinophils may not be seen in the dermal infiltrate, staining for eosinophil major basic protein (MBP) reveals deposition in many cases.

### General management

#### Education and support

Parental and patient education is of critical importance in the management of AD. In the busy clinic setting, dermatologists frequently have insufficient time to educate patients adequately regarding the multiple factors that are important in managing AD. Educational formats that have proved effective have been immediate nursing education on the correct use of medications, weekly evening educational sessions, and multidisciplinary day treatment venues. In all cases, “written action plans” outlining a “stepwise approach” have been important for parent/patient education. In addition, patients with chronic disease often become disenchanted with medical therapies or simply “burn out” from having to spend significant amounts of time managing their skin disease. The psychological support that can be incorporated into educational sessions can help motivate parents/patients and keep them engaged in the treatment plan. Having a child with AD is extremely stressful and generates significant stress within the family. Sleep is lost by both the patient and the parents. Supportive educational techniques can help the family cope with this burden. In addition, the dermatologist must consider the complexity and time commitment of any prescribed regimen and ensure that the parents/patient understand and are committed to undertaking the treatments proposed.

#### Barrier repair

Virtually all patients with AD have xerosis and an impaired epidermal barrier. The cornerstone of treatment and prevention of AD lies in addressing this problem. Patients should moisturize daily, especially after bathing. This may be with petrolatum or a petrolatum-based product, an oil-based product, vegetable shortening, or a “barrier repair” moisturizer that contains the essential lipids of the epidermal barrier. These special barrier repair moisturizers have similar benefits in AD to low-potency topical steroids. They are easier to apply and, if available to the patient, may enhance compliance. Petrolatum and petrolatum-based moisturizers are most often recommended and are the least expensive and most effective for most patients. However, men with significant body hair, AD patients triggered by heat, and the rare patient with true allergic contact dermatitis to petrolatum may be unable to tolerate petrolatum-based agents. Patients should



be instructed on the barrier-damaging properties of soaps, hot water, and scrubbing. Synthetic detergents that have a more acidic pH are preferred to harsh soaps. Detergent use should be restricted to the axilla, groin, face, soles, and scalp. Oil-based cleansers can be used to “wash” the skin without water. For flares of AD, the soak and smear technique (soak in tub, then seal in water with a heavy moisturizer or medicated ointments) or wet dressings (wet wraps) with topical steroids can be very effective. In dry climates, AD patients may note some benefit with humidifiers.  $\alpha$ -Hydroxy acid-containing products (lactic acid, glycolic acid) can be irritating and can exacerbate inflamed AD. These products should only be used for the xerosis of AD when there is absolutely no inflammation or pruritus.

### Antimicrobial therapy

When the AD patient has evidence of infection, treatment with topical or systemic antibiotics may be appropriate. Rather than treating once an infection occurs, it appears that the key in AD is to reduce nasal staphylococcal carriage preemptively and to keep the skin decolonized from *Staphylococcus*. Bleach baths have rapidly become a mainstay in AD patients. Twice-weekly bathing in a tepid bath with  $\frac{1}{4}$  cup of standard household bleach (6%) diluted in 20 gallons of water dramatically improves AD on the trunk and extremities, but less so on the face. This treatment combines decolonization of the skin with hydration, addressing two of the major factors in worsening of AD. Adequate moisturizing after bathing is critical. Intranasal application of mupirocin is beneficial in reducing nasal carriage. In 80% of families, at least one parent is carrying the same staphylococcal strain as a colonized AD child. If the AD patient has recurrent infections, other carriers in the family and their pets are sought and treated aggressively. Recurrent infections, especially furunculosis, are a cardinal feature of children and adults with AD who have systemic immunologic abnormalities, especially hyper-IgE syndrome.

### Environmental factors

Stress, heat, sweating, and external irritants may precipitate an attack of itching and flare in the AD patient. Wool garments should be avoided. Addressing these triggers may improve the AD. Itch nerves are more active at higher temperatures, so overheating should be avoided. Irritants and allergens in the numerous products that AD patients may use can lead to flares of AD. Patients should avoid products that contain common allergens and should be evaluated for allergic contact dermatitis if a topical agent is associated with worsening of their AD.

### Antipruritics

The primary treatment for the pruritus of AD is to reduce the severity of the AD. Antihistamines are frequently used for the pruritus of AD but are only beneficial for their sedative properties. If prescribed, sedating antihistamines are optimally used nightly (not “as needed”). Diphenhydramine, hydroxyzine, and doxepin can all be efficacious. Nonsedating antihistamines do not appear to benefit the pruritus of AD in standard doses. In some patients, gabapentin, selective serotonin reuptake inhibitors (SSRIs), mirtazapine, and even opiate antagonists may reduce pruritus. Applying ice during intense bouts of itch may help to “break” an itch paroxysm. Moisturizing lotions containing menthol, phenol, or pramoxine can be used between steroid applications to moisturize and reduce local areas of severe itch. More widespread use of topical doxepin (Sinequan) is limited by systemic absorption and sedation.

## Specific treatment modalities

### Topical corticosteroid therapy

Topical corticosteroids are the most common class of medications, along with moisturizers, used for the treatment of AD. They are effective and economical. In infants, low-potency steroid ointments, such as hydrocortisone 1% or 2.5%, are preferred. Regular application of emollients must be emphasized. Once corticosteroid receptors are saturated, additional applications of a steroid preparation contribute nothing more than an emollient effect. In most body sites, once-daily application of a corticosteroid is almost as effective as more frequent applications, at lower cost and with less systemic absorption. In some areas, twice-daily applications may be beneficial, but more frequent applications are almost never of benefit. Steroid phobia is common in parents and patients with AD. Less frequent applications of lower-concentration agents, with emphasis on moisturizing, address these concerns. Application of topical corticosteroids under wet wraps or vinyl suit occlusion (soak and smear) can increase efficiency. For refractory areas, a stronger corticosteroid, such as desonide, alclometasone, or triamcinolone, may be used. A more potent molecule is more appropriate than escalating concentrations of a weaker molecule because the effect of the latter plateaus rapidly as receptors become saturated. Do not undertreat! This leads to loss of faith on the part of the patient/parents and prolongs the suffering of the patient. For severe disease, use more potent topical steroids in short bursts of a few days to a week to gain control of the disease. In refractory and relapsing AD, twice-weekly steroid application may reduce flares.

In older children and adults, medium-potency steroids such as triamcinolone are often used, except on the face, where milder steroids or calcineurin inhibitors are preferred. For thick plaques and lichen simplex chronicus like lesions, extremely potent steroids may be necessary. Ointments are more effective because of their moisturizing properties and require no preservatives, reducing the likelihood of allergic contact dermatitis. If an atopic patient worsens or fails to improve after the use of topical steroids and moisturizers, the possibility of allergic contact dermatitis to a preservative or the corticosteroid itself must be considered. Contact allergy to the corticosteroid itself can occur. Corticosteroid allergy seldom manifests as acute worsening of the eczema. Instead, it manifests as a flare of eczema whenever the corticosteroid is discontinued, even for a day. This may be difficult to differentiate from stubborn AD.

Although the potential for local and even systemic toxicity from corticosteroids is real, the steroid must be strong enough to control the pruritus and remove the inflammation. Even in small children, strong topical steroids may be necessary in weekly pulses to control severe flares. Monitoring of growth parameters should be carried out in infants and young children.

### Topical calcineurin inhibitors

Topical calcineurin inhibitors (TCIs) such as tacrolimus or pimecrolimus offer an alternative to topical steroids. Systemic absorption is generally not significant with either of these agents. Although a 0.03% tacrolimus ointment is marketed for use in children, it is unclear whether it really offers any safety advantage over the 0.1% formulation. Tolerability is improved if the ointment is applied to “bone-dry” skin. Patients experience less burning if eczematous patches are treated initially with a corticosteroid, with transition to a TCI after partial clearing. Improvement tends to be steady, with progressively

smaller areas requiring treatment. TCIs are particularly useful on the eyelids and face, in areas prone to steroid atrophy, when steroid allergy is a consideration, or when systemic steroid absorption is a concern. Tacrolimus is more effective than pimecrolimus, with tacrolimus 0.1% ointment equivalent to triamcinolone acetonide 0.1%, and pimecrolimus equivalent to a class V or VI topical corticosteroid.

## Tar

Crude coal tar 1–5% in white petrolatum or hydrophilic ointment USP, or liquor carbonis detergens (LCD) 5–20% in hydrophilic ointment USP, is sometimes helpful for an area of refractory AD. Tar preparations are especially beneficial when used for intensive treatment for adults in an inpatient or day care setting, especially in combination with UV phototherapy.

## Phototherapy

If topical modalities fail to control AD, phototherapy is the next option on the therapeutic ladder. Narrow-band (NB) UVB is highly effective and has replaced broadband UV for treating AD. When acutely inflamed, AD patients may tolerate UV poorly. Initial treatment with a systemic immunosuppressive can cool off the skin enough to institute UV treatments. Patients with significant erythema must be introduced to UV at very low doses to avoid nonspecific irritancy and flaring of the AD. Often, the initial dose is much lower and the dose escalation much slower than in patients with psoriasis. In acute flares of AD, UVA I can be used. For patients unresponsive to NB UVB, photochemotherapy with psoralen plus UVA (PUVA) can be effective. It requires less frequent treatments, and can be given either topically (soak/bath PUVA) or systemically (oral PUVA). Goeckerman therapy with tar and UVB in a day treatment setting will lead to improvement in more than 90% of patients with refractory AD, and prolonged remission can be induced.

## Systemic therapy

### Systemic corticosteroids

In general, systemic corticosteroids should be used only to control acute exacerbations. In patients requiring systemic steroid therapy, short courses ( $\leq 3$  weeks) are preferred. If repeated or prolonged courses of systemic corticosteroids are required to control the AD, phototherapy or a steroid-sparing agent should be considered. Chronic corticosteroid therapy for AD frequently results in significant steroid-induced side effects. Osteoporosis in women requires special consideration and should be addressed with a bisphosphonate early in the course of therapy when bone loss is greatest. Preventive strategies, such as calcium supplements, vitamin D supplementation, bisphosphonates, regular exercise, and smoking cessation, should be strongly encouraged. Dual-energy x-ray absorptiometry (DEXA) scans are recommended.

### Cyclosporine

Cyclosporine (cyclosporin A) is highly effective in the treatment of severe AD, but the response is rarely sustained after the drug is discontinued. It is very useful to gain rapid control of severe AD. Cyclosporine has been shown to be safe and effective in both children and adults, although probably tolerated better in children. Potential long-term side effects, especially renal disease, require careful monitoring, with attempts to transition the patient to a potentially less toxic agent if possible. The dose range is 3–5 mg/kg in children and 150–300 mg

in adults, with a better and more rapid response at the higher end of the dose range. Rebound flaring of AD is possible and can be significant after stopping cyclosporin A, and a plan should be in place for this eventuality.

## Other immunosuppressive agents

Several immunosuppressive agents have demonstrated efficacy in patients with AD. These agents do not appear to be as effective or quick to work as cyclosporine. However, over time they may have a better safety profile, so patients requiring long-term immunosuppression may benefit from one of these agents. They include azathioprine (Imuran), mycophenolate mofetil (CellCept), and methotrexate (Rheumatrex). The dosing of azathioprine is guided by the serum thiopurine methyltransferase level. Mycophenolate mofetil (MMF) is generally well tolerated and, as with azathioprine, takes about 6 weeks to begin to reduce the AD. Unfortunately, the response of AD patients to MMF is variable, with 20–40% not responding. Low-dose weekly methotrexate is well tolerated and has demonstrated efficacy in AD in children and adults equivalent to azathioprine. If cyclosporin A is not to be used, the choice of steroid-sparing agent is personalized to the patient's risk factors and tolerance of the medication. Hydroxyurea, as used for psoriasis in the past, can be effective in AD if other steroid-sparing agents fail, as well as in the patient with liver disease.

Intravenous immune globulin (IVIG) has had some limited success in managing AD, but its high cost precludes its use, except when other reasonable therapeutic options have been exhausted. Interferon (IFN)- $\gamma$  given by daily injection has demonstrated efficacy in both children and adults with severe AD. The onset of response can be delayed. IFN- $\gamma$  is well tolerated but can cause flulike symptoms. Omalizumab can be considered in refractory cases, but only 20% of patients achieve a 50% or greater reduction of their AD. Infliximab has not been beneficial in AD. Ustekinumab has been effective in a few reports, since the inflammatory cascade triggering and maintaining AD does involve Th17 cells.

Traditional Chinese herb mixtures have shown efficacy in children and in animal models for AD. The active herbs appear to be ophiopogon tuber and Schisandra fruit. Chinese herbs are usually delivered as a brewed tea to be drunk daily. Their bitter taste makes them unpalatable to most Western patients. However, this option should be considered in patients who might accept this treatment approach.

## Management of acute flare

Initially, the precipitating cause of the flare should be sought. Recent stressful events may be associated with flares. Secondary infection with *S. aureus* should be assumed in most cases. Less frequently, HSV or coxsackievirus may be involved. Pityriasis rosea may also cause AD to flare. The development of contact sensitivity to an applied medication or photosensitivity must be considered.

In the patient with an acute flare, treating triggers may lead to improvement (see earlier discussion). A short course of systemic corticosteroids may be of benefit, but patients should be counseled that prolonged systemic corticosteroid therapy must be avoided. "Home hospitalization" may be useful. The patient goes home to bed, isolated from work and other stressors; large doses of a sedating antihistamine are given at bedtime; and the patient soaks in the tub twice daily, then applies a topical steroid ointment under wet pajamas and a sauna suit (soak and smear). Often, 3–4 days of such intensive home therapy will break a severe flare.



- Agusti-Mejias AM, et al:** Severe refractory atopic dermatitis in an adolescent patient successfully treated with ustekinumab. *Ann Dermatol* 2013; 25:3.
- Allen HB, et al:** Lichenoid and other clinical presentations of atopic dermatitis in an inner city practice. *J Am Acad Dermatol* 2008; 58:503.
- Andreae DA, Wang J:** Immunologic effects of omalizumab in children with severe refractory atopic dermatitis: a randomized, placebo-controlled clinical trial. *Pediatrics* 2014; 134: S160.
- Annesi-Maesano I, et al:** Time trends in prevalence and severity of childhood asthma and allergies from 1995 to 2002 in France. *Allergy* 2009; 64:798.
- Aronson AC, et al:** Delayed acyclovir and outcomes of children hospitalized with eczema herpeticum. *Pediatrics* 2011; 128:6.
- Ashcroft DM, et al:** Efficacy and tolerability of topical pimecrolimus and tacrolimus in the treatment of atopic dermatitis: meta-analysis of randomised controlled trials. *BMJ* 2005; 330:516.
- Boguniewicz M, et al:** A multidisciplinary approach to evaluation and treatment of atopic dermatitis. *Semin Cutan Med Surg* 2008; 27:115.
- Bonness S, et al:** Pulsed-field gel electrophoresis of *Staphylococcus aureus* isolates from atopic patients revealing presence of similar strains in isolates from children and their parents. *J Clin Microbiol* 2008; 46:456.
- Brown SJ, et al:** Atopic eczema and the filaggrin story. *Semin Cutan Med Surg* 2008; 27:128.
- Carson CG, et al:** Clinical presentation of atopic dermatitis by filaggrin gene mutation status during the first 7 years of life in a prospective cohort study. *PLoS One* 2012; 7:e48678.
- Chisolm SS, et al:** Written action plans: potential for improving outcomes in children with atopic dermatitis. *J Am Acad Dermatol* 2008; 59:677.
- Clausen M, et al:** High prevalence of allergic diseases and sensitization in a low allergen country. *Acta Paediatr* 2008; 97:1216.
- Clayton TH, et al:** The treatment of severe atopic dermatitis in childhood with narrowband ultraviolet B phototherapy. *Clin Exp Dermatol* 2007; 32:28.
- Fleischer DM, et al:** Primary prevention of allergic disease through nutritional interventions. *J Allergy Clin Immunol* 2013; 1:29.
- Flohr C, Mann J:** New approaches to the prevention of childhood atopic dermatitis. *Allergy* 2014; 69:56.
- Flohr C, Mann J:** New insights into the epidemiology of childhood atopic dermatitis. *Allergy* 2014; 69:3.
- Eichenfeld LF, et al:** Guidelines of care for the management of atopic dermatitis. Section 1. Diagnosis and assessment of atopic dermatitis. *J Am Acad Dermatol* 2014; 70:2.
- Eichenfeld LF, et al:** Guidelines of care for the management of atopic dermatitis. Section 2. Management and treatment of atopic dermatitis with topical therapies. *J Am Acad Dermatol* 2014; 71:116.
- Epstein TG, et al:** Opposing effects of cat and dog ownership and allergic sensitization on eczema in an atopic birth cohort. *J Pediatr* 2011; 158:2.
- Gao PS, et al:** Genetic variants in interferon regulatory factor 2 (IRF2) are associated with atopic dermatitis and eczema herpeticum. *J Invest Dermatol* 2012; 132:3(Pt 1).
- Gao PS, et al:** Genetic variants in thymic stromal lymphopoietin are associated with atopic dermatitis and eczema herpeticum. *J Allergy Clin Immunol* 2010; 125:6.
- Gittlem JK, et al:** Progressive activation Th2/Th22 cytokines and selective epidermal proteins characterizes acute and chronic atopic dermatitis. *J Allergy Clin Immunol* 2012; 130:6.
- Haeck IM, et al:** Enteric-coated mycophenolate sodium versus cyclosporine as a long-term treatment in adult patients with severe atopic dermatitis: a randomized controlled trial. *J Am Acad Dermatol* 2011; 64:6.
- Hotze M, et al:** Increased efficacy of omalizumab in atopic dermatitis patients with wild-type filaggrin status and higher serum levels of phosphatidylcholines. *Allergy* 2014; 69:132.
- Huang JT, et al:** Treatment of *Staphylococcus aureus* colonization in atopic dermatitis decreases disease severity. *Pediatrics* 2009; 123:e808.
- Isaksson M, et al:** Children with atopic dermatitis should always be patch-tested if they have hand or foot dermatitis. *Acta Derm Venereol* 2014 [Epub ahead of print].
- Jolles S, et al:** Use of IGIV in the treatment of atopic dermatitis, urticaria, scleromyxedema, pyoderma gangrenosum, psoriasis, and pretibial myxedema. *Int Immunopharmacol* 2006; 6:579.
- Julián-González RE, et al:** Less common clinical manifestations of atopic dermatitis: prevalence by age. *Pediatr Dermatol* 2012; 29:580.
- Luca NJ, et al:** Eczema herpeticum in children: clinical features and factors predictive of hospitalization. *J Pediatr* 2012; 161:4.
- Makino T, et al:** Effect of bakumijogan, an herbal formula in traditional Chinese medicine, on atopic dermatitis-like skin lesions induced by mite antigen in *NC/Jic* mice. *Biol Pharm Bull* 2008; 31:2108.
- Margolis DJ, et al:** Filaggrin-2 variation is associated with more persistent atopic dermatitis in African American subjects. *J Allergy Clin Immunol* 2014; 133:784.
- Margolis DJ, et al:** Thymic stromal lymphopoietin variation, filaggrin loss of function, and the persistence of atopic dermatitis. *JAMA Dermatol* 2014; 150:254.
- Meduri NB, et al:** Phototherapy in the management of atopic dermatitis: a systematic review. *Photodermatol Photoimmunol Photomed* 2007; 23:106.
- Moore E, et al:** Nurse-led clinics reduce severity of childhood atopic eczema: a review of the literature. *Br J Dermatol* 2006; 155:1242.
- Osawa R, et al:** Filaggrin gene defects and the risk of developing allergic disorders. *Allergol Int* 2011; 60:1.
- Ozkaya E:** Adult-onset atopic dermatitis. *J Am Acad Dermatol* 2005; 52:579.
- Paller AS, et al:** Tacrolimus ointment is more effective than pimecrolimus cream with a similar safety profile in the treatment of atopic dermatitis: results from 3 randomized, comparative studies. *J Am Acad Dermatol* 2005; 52:810.
- Penders J, et al:** Establishment of the intestinal microbiota and its role for atopic dermatitis in early childhood. *J Allergy Clin Immunol* 2013; 132:601.
- Puya R, et al:** Treatment of severe refractory adult atopic dermatitis with ustekinumab. *Int J Dermatol* 2012; 51:1.
- Rahman SI, et al:** The methotrexate polyglutamate assay supports the efficacy of methotrexate for severe inflammatory skin disease in children. *J Am Acad Dermatol* 2013; 70:252.
- Ricci G, et al:** Three years of Italian experience of an educational program for parents of young children affected by atopic dermatitis: improving knowledge produces lower anxiety levels in parents of children with atopic dermatitis. *Pediatr Dermatol* 2009; 26:1.
- Ring J, et al:** Guidelines for treatment of atopic eczema (atopic dermatitis). Part I. *J Eur Acad Dermatol Venereol* 2012; 26:1176.
- Rupnik H, et al:** Filaggrin loss-of-function mutations are not associated with atopic dermatitis that develops in late childhood or adulthood. *Br J Dermatol* 2014 [Epub ahead of print].
- Salimi M, et al:** A role for IL-25 and IL-33-driven type-2 innate lymphoid cells in atopic dermatitis. *J Exp Med* 2013; 210:13.
- Selnes A, et al:** Diverging prevalence trends of atopic disorders in Norwegian children: results from three cross-sectional studies. *Allergy* 2005; 60:894.
- Sidbury R, et al:** Guidelines of care for the management of atopic dermatitis. Section 3. Management and treatment with phototherapy and systemic agents. *J Am Acad Dermatol* 2014; 71:327.
- Sidbury R, et al:** Guidelines of care for the management of atopic dermatitis: Section 4. Prevention of disease flares and use of adjunctive therapies and approaches. *J Am Acad Dermatol* 2014; [Epub ahead of print].
- Stott B, et al:** Human IL-31 is induced by IL-4 and promotes Th2-driven inflammation. *J Allergy Clin Immunol* 2013; 132:2.
- Stemmler S, et al:** Association of variation in the *LAMA3* gene, encoding the alpha-chain of laminin 5, with atopic dermatitis in a German case-control cohort. *BMC Dermatol* 2014; 14: 17.
- Ten Berge O, et al:** Throwing a light on photosensitivity in atopic dermatitis: a retrospective study. *Am J Clin Dermatol* 2009; 10:119.
- Thomsen SF, et al:** Outcome of treatment with azathioprine in severe atopic dermatitis: a five-year retrospective study of adult outpatients. *Br J Dermatol* 2014 [Epub ahead of print].
- Van Drongelen V, et al:** Reduced filaggrin expression is accompanied by increased *Staphylococcus aureus* colonization of epidermal skin models. *Clin Exp Allergy* 2014 [Epub ahead of print].
- Van Os-Medendorp H, et al:** Costs and cost-effectiveness of the nursing program "Coping with itch" for patients with chronic pruritic skin disease. *Br J Dermatol* 2008; 158:1013.
- Wang WL, et al:** Thymic stromal lymphopoietin: a promising therapeutic target for allergic disease. *Int Arch Allergy Immunol* 2013; 160:18.
- Waxweiler WT, et al:** Systemic treatment of pediatric atopic dermatitis with azathioprine and mycophenolate mofetil. *Pediatr Dermatol* 2011; 28:6.

## ECZEMA

The word eczema seems to have originated in 543 AD and is derived from the Greek work *ekzein*, meaning to “to boil forth” or “to effervesce.” The term encompasses such disorders as dyshidrotic eczema and nummular eczema (NE), but at times is used synonymously for atopic dermatitis (as in “infantile eczema”). The acute stage generally presents as a red edematous plaque that may have grossly visible, small, grouped vesicles. Subacute lesions present as erythematous plaques with scale or crusting. Later, lesions may be covered by a drier scale or may become lichenified. In most eczematous reactions, severe pruritus is a prominent symptom. The degree of irritation at which itching begins (the itch threshold) is lowered by stress. Itching is often prominent at bedtime and usually results in insomnia. Heat and sweating may also provoke episodes of itching.

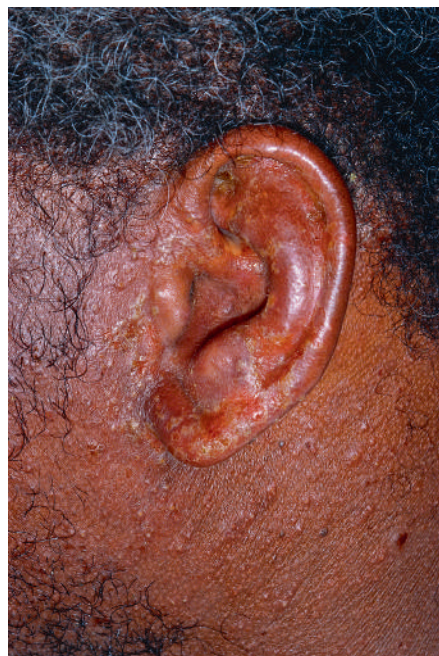Histologically, the hallmark of all eczematous eruptions is a serous exudate between cells of the epidermis (spongiosis), with an underlying dermal perivascular lymphoid infiltrate and exocytosis (lymphocytes present in overlying epidermis singly or in groups). Spongiosis is generally out of proportion to the lymphoid cells in the epidermis. This is in contrast to mycosis fungoides, which demonstrates minimal spongiosis confined to the area immediately surrounding the lymphocytes.

In most eczematous processes, spongiosis is very prominent in the acute stage, where it is accompanied by minimal acanthosis or hyperkeratosis. Subacute spongiotic dermatitis demonstrates epidermal spongiosis with acanthosis and hyperkeratosis. Chronic lesions may have minimal accompanying spongiosis, but acute and chronic stages may overlap because episodes of eczematous dermatitis follow one another. Scale corresponds to foci of parakeratosis produced by the inflamed epidermis. A crust is composed of serous exudate, acute inflammatory cells, and keratin. Eczema, regardless of cause, will manifest similar histologic changes if allowed to persist chronically. These features are related to chronic rubbing or scratching and correspond clinically to lichen simplex chronicus or prurigo nodularis. Histologic features at this stage include compact hyperkeratosis, irregular acanthosis, and thickening of the collagen bundles in the papillary portion of the dermis. The dermal infiltrate at all stages is predominantly lymphoid, but an admixture of eosinophils may be noted. Neutrophils generally appear in secondarily infected lesions. Spongiosis with many intraepidermal eosinophils may be seen in the early spongiotic phase of pemphigoid, pemphigus, and incontinentia pigmenti, as well as some cases of allergic contact dermatitis.

## Regional eczemas

### Ear eczema

Eczema of the ears or otitis externa may involve the helix, postauricular fold, and external auditory canal. By far the most frequently affected site is the external canal, where eczema is often a manifestation of seborrheic dermatitis or allergic contact dermatitis caused by topical medications, especially neomycin (Fig. 5-8). Secretions of the ear canal derive from the specialized apocrine and sebaceous glands, which form cerumen. Rubbing, wiping, scratching, and picking exacerbate the condition. Secondary bacterial colonization or infection is common. Infection is usually caused by staphylococci, streptococci, or *Pseudomonas*. Contact dermatitis from neomycin, benzocaine, and preservatives may be caused by topical



**Fig. 5-8** Ear eczema secondary to allergic contact dermatitis.

remedies. *Pseudomonas aeruginosa* can result in malignant external otitis with ulceration and sepsis. Earlobe dermatitis is virtually pathognomonic of metal contact dermatitis (especially nickel) and occurs most frequently in women who have pierced ears.

Treatment should be directed at removal of causative agents, such as topically applied allergens. First, examine the ear with an otoscope and be sure there is not a perforated tympanic membrane. If there is drainage from a perforated tympanic membrane, management should be in consultation with an otolaryngologist. This purulent fluid can be the cause of an ear eczema—infectious eczematoid dermatitis. If the tympanic membrane is intact, scales and cerumen should be removed by gentle lavage with an ear syringe. A combination of ciprofloxacin plus a topical steroid (e.g., Ciprodex) is preferred to neomycin-containing products. Corticosteroids alone can be effective for noninfected dermatitis. For very weepy lesions, aluminum acetate optic solution (e.g., Domeboro) may be drying and beneficial.

### Eyelid dermatitis

Eyelid dermatitis is most often related to atopic dermatitis or allergic contact dermatitis, or both (see Chapter 6). Allergic conjunctivitis in an atopic patient may lead to rubbing and scratching of the eyelid and result in secondary eyelid dermatitis. Seborrheic dermatitis, psoriasis, and airborne dermatitis are other possible causes. Ninety percent of patients with eyelid dermatitis are female. When an ocular medication contains an allergen, the allergen passes through the nasolacrimal duct, and dermatitis may also be noted below the nares in addition to the eyelids. Some cases of eyelid contact dermatitis are caused by substances transferred by the hands to the eyelids. If eyelid dermatitis occurs without associated AD, an allergen is detected in more than 50% of cases. More than 25% of patients with AD and eyelid dermatitis will also have allergic contact dermatitis contributing to the condition. Fragrances and balsam of Peru, metals (nickel and gold), paraphenylenediamine, quaternium 15, oleamidopropyl dimethylamine, thiuram (in rubber pads used to apply eyelid cosmetics), and tosylamide formaldehyde (in nail polish) are common environmental allergens causing eyelid dermatitis. In medications, preservatives such as cocamidopropyl betaine and active



agents such as phenylephrine hydrochloride, sodium cromoglycate, papain, and idoxuridine have all been implicated.

Eyelid dermatitis requires careful management, often in collaboration with an ophthalmologist. The most important aspect is to identify and eliminate any possible triggering allergens as noted above. Patch testing for standard allergens, as well as the patient's ocular medications, is required. Preservative-free eye medications should be used. The ophthalmologist should monitor the patient for conjunctival complications, measure the intraocular pressure, and monitor for the development of cataracts, especially in patients with AD who have an increased risk for cataracts. Initially, topical corticosteroids and petrolatum-based emollients are recommended. If the dermatitis is persistent, the patient may be transitioned to TCIs to reduce the long-term risk of ocular steroid complications. The TCIs are often not initially tolerated on inflamed eyelids due to the burning. If there is an associated allergic conjunctivitis, or in patients who fail treatment with topical medications applied to the eyelid, ocular instillation of cyclosporine ophthalmic emulsion (Restasis) can be beneficial. Cromolyn sodium ophthalmic drops may be used to stabilize mast cells in the eyelid and reduce pruritus. In balsam of Peru-allergic patients, a balsam elimination diet may benefit.

### Breast eczema (nipple eczema)

Eczema of the breasts usually affects the areolae and may extend on to the surrounding skin (Fig. 5-9). The area around the base of the nipple is usually spared, and the nipple itself is less frequently affected. The condition is rarely seen in men. Usually, eczema of the nipples is of the moist type with oozing and crusting. Painful fissuring is frequently seen, especially in nursing mothers. Atopic dermatitis is a frequent cause, and nipple eczema may be the sole manifestation of AD in adult women. It frequently presents during breastfeeding. The role of secondary infection with bacteria and *Candida* should be considered in breastfeeding women. Other causes of nipple eczema are allergic contact dermatitis and irritant dermatitis. Irritant dermatitis occurs from friction (jogger's nipples), or from poorly fitting brassieres with seams in women with asymmetric and large breasts. In patients in whom eczema of the nipple or areola has persisted for more than 3 months, especially if it is unilateral, a biopsy is mandatory to rule out the possibility of Paget's disease of the breast. Topical

corticosteroids or TCIs are often effective in the treatment of non-Paget eczema of the breast. Nevroid hyperkeratosis of the nipples is a chronic condition that may mimic nipple eczema, but it is not responsive to corticosteroids.

Nipple eczema in the breastfeeding woman is a therapeutic challenge. The dermatitis may appear in an atopic woman when her child begins to ingest solid foods. This may signal contact dermatitis to a food. Allergic contact dermatitis may develop to topical protective creams (containing vitamin A and E, aloe, chamomile, or preservatives). Staphylococcal superinfection may develop and can be identified by culture. Oral antibiotics are the preferred treatment for bacterial secondary infection. Candidal infection of the areola may present as normal skin, erythema, or an acute or chronic eczema. The area of the areola immediately adjacent to the nipple tends to be involved, sometimes with fine hairline cracks. Patients frequently complain of severe pain, especially with nursing. Analgesia may be required, and breastfeeding may need to be suspended for a period. Pumping and the use of a silicone nipple shield may be helpful. Associated conditions include oral thrush in the infant, antibiotic use, and a personal history of vaginal candidiasis. Cultures may or may not be positive from the affected areola/nipple. The child's mouth should also be cultured, even if the examination is completely normal, because candidal colonization of the breastfeeding infant's mouth may be asymptomatic with no findings on clinical examination. A positive culture from the infant in the setting of nipple eczema in the mother would warrant therapy of the mother and infant. Therapy with topical or systemic antifungal agents may be required to determine whether *Candida* is pathogenic. Oral fluconazole can be dramatically effective in these patients. Topical gentian violet 0.5%, applied once daily to the nipple for up to 1 week, or all-purpose nipple ointment (mupirocin 2%, 10 g; nystatin, 100,000 units/mL ointment, 10 g; clotrimazole 10% vaginal cream, 10 g; and betamethasone 0.1% ointment, 10 g) is an effective topical agent. Guaiazulene (Azulon) is a dark-blue hydrocarbon used in Europe for nipple "cracks" with breastfeeding.

The child's thrush should also be treated. A lactation consultant or nurse may be helpful in managing these patients, since poor positioning during breastfeeding is a common cofactor in the development of nipple eczema.

### Hand eczema

Hand eczema is a common and important skin condition. Every year, about 10% of the population has at least one episode of hand dermatitis, and at any time about 4% of the population is affected. The genetic risk factors for the development of hand dermatitis are unknown. Adult female patients with AD may develop hand dermatitis. Atopic patients with the *FLG* null mutation may have a specific form of hand dermatitis characterized by dorsal hand and finger dermatitis, volar wrist involvement, and hyperlinear palms, but limited palmar dermatitis. Hand eczema is the most common occupational skin condition, accounting for more than 80% of all occupational dermatitides. About 1 per 1000 workers are affected annually. Tobacco smoking and alcohol consumption do not appear to be risk factors for the development of hand eczema. Women are at increased risk, most of which is accounted for by a "spike" in the rate of hand eczema in the 20-29 age group, when increased environmental exposures increase women's risk (e.g., child care, housecleaning).

Chronic hand eczema, especially if severe, significantly reduces the patient's quality of life and is associated with symptoms of depression. A significant portion of patients with hand eczema will still be affected 15 years later. The risk for persistence of the hand eczema is doubled if there is associated eczema at other sites at presentation, if there is a childhood

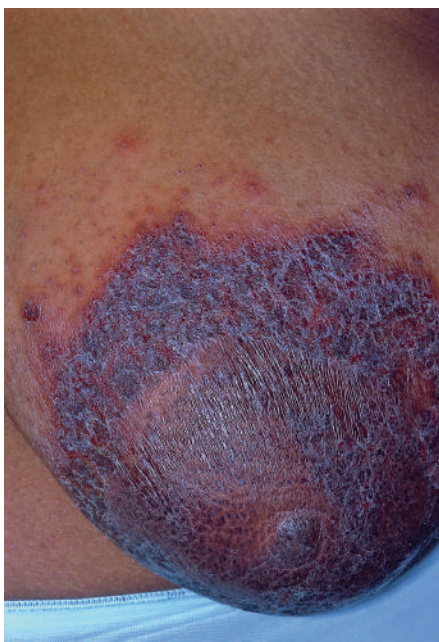

Fig. 5-9 Nummular eczema of the breast.

history of AD, and if the onset of the hand eczema was before age 20. Preventive interventions have been successful on the following two fronts:

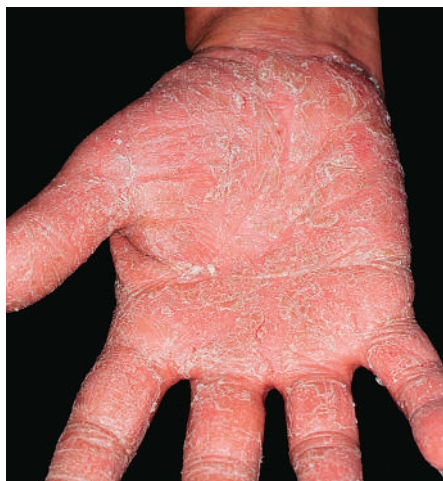1. Persons at high risk for hand eczema can be identified and counseled to avoid high-risk occupations.
2. Once occupational hand eczema develops, some occupation-specific strategies can lead to improvement and prevent recurrence.

The evaluation and management of hand eczema have been hampered by the lack of a uniform classification system and a dearth of controlled therapeutic trials. The diagnostic dilemma in hand dermatitis is in part related to two factors. The clinical appearance of the skin eruption on the palms and soles may be very similar, independent of the etiology. In addition, virtually all chronic hand dermatitis demonstrates a chronic dermatitis histologically, again independent of pathogenic cause. Psoriasis, specifically on the palms and soles, may show spongiosis and closely resemble a dermatitis (Fig. 5-10). As a result, the proposed classification schemes rely on a combination of morphologic features, history of coexistent illnesses, occupational exposure, and results of patch testing. The different types of hand eczema are as follows:

1. Allergic contact dermatitis (with or without an additional irritant component)
2. Irritant hand dermatitis
3. Atopic hand eczema (with or without an additional irritant component)
4. Recurrent vesicular (or vesiculobullous) hand eczema
5. Hyperkeratotic hand eczema
6. Pulpitis (chronic fingertip dermatitis)
7. Nummular dermatitis

A complete history, careful examination of the rest of the body surface, and frequently, patch testing are essential in establishing a diagnosis. Patch testing is recommended in all patients with chronic hand eczema. Allergens in the environment, especially shower gels and shampoos, in the workplace, and in topical medications may be important in any given patient. Patch testing must include broad screens of common allergens or cases of allergic contact dermatitis will be missed.

The role of ingested nickel in the development of hand eczema in nickel-allergic patients is controversial. Some practitioners treat such patients with low-nickel diets and even disulfiram chelation with reported benefit. However, the risk of development of hand eczema in adulthood is independent of nickel allergy. Similarly, the role of low-balsam diets in the management of balsam of Peru-allergic patients with hand eczema is unclear.



**Fig. 5-10** Hand eczema.

Wet work, defined as skin in liquids or gloves for more than 2 hours per day, or handwashing more than 20 times per day, is a strong risk factor for hand eczema. High-risk occupations include those that entail wet work and those with exposure to potential allergens. These nine “high-risk” occupations include bakers, hairdressers, dental surgery assistants, kitchen workers/cooks, butchers, health care workers, cleaners, physicians/dentists/veterinarians, and laboratory technicians. In about 5% of patients with hand eczema, especially if severe, it is associated with prolonged missed work, job change, and job loss. In health care workers, the impaired barrier poses a risk for infection by blood-borne pathogens.

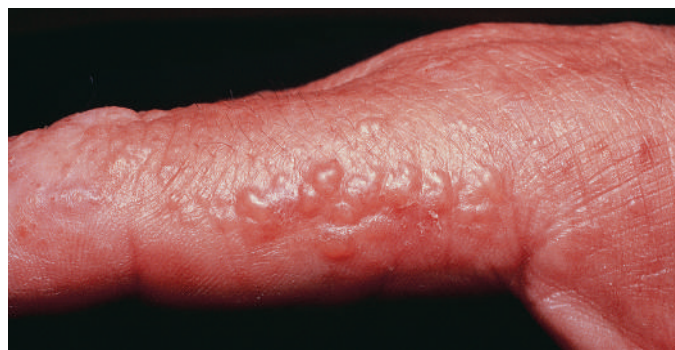Almost one third of baker’s apprentices develop hand dermatitis within 12 months of entering the profession. Among hairdressers, the incidence approaches 50% after several years. Both irritant dermatitis and allergic contact dermatitis are important factors, with glyceryl monoethoxyglycolate and ammonium persulfate being the most common allergens among hairdressers. Cement workers have a high rate of hand dermatitis related to contact allergy, alkalinity, and hygroscopic effects of cement. Dorsal hand dermatitis in a cement worker suggests contact allergy to chromate or cobalt. The addition of ferrous sulfate to cement has no effect on irritant dermatitis, but reduces the incidence of allergic chromate dermatitis by two-thirds.

Among patients with occupational hand dermatitis, atopic patients are disproportionately represented. Hand dermatitis is frequently the initial or only adult manifestation of an atopic diathesis. The likelihood of developing hand eczema is greatest in patients with AD, more common if the AD was severe, but is still increased in incidence in patients with only respiratory atopy. One third to half of patients with hand eczema have atopy. Atopic patients should receive career counseling in adolescence to avoid occupations that are likely to induce hand dermatitis.

Contact urticaria syndrome may present as immediate burning, itching, or swelling of the hands, but a chronic eczematous phase may also occur. Latex is an important cause of the syndrome, but raw meat, lettuce, garlic, onion, carrot, tomato, spinach, grapefruit, orange, radish, fig, parsnip, cheese, or any number of other foods may be implicated.

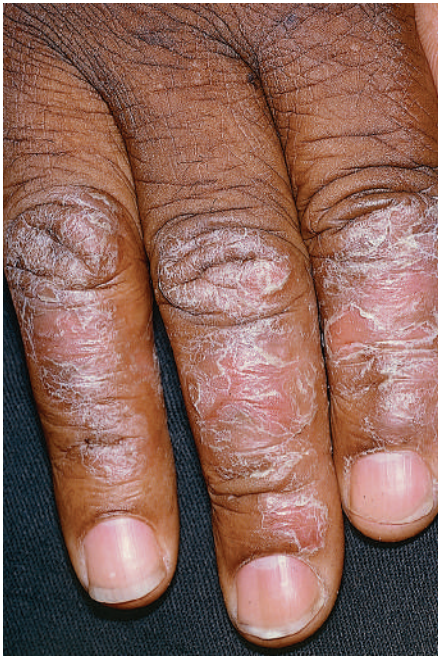### ***Vesiculobullous hand eczema (pompholyx, dyshidrosis)***

Idiopathic acute vesicular hand dermatitis is not related to blockage of sweat ducts, although palmoplantar hyperhidrosis is common in these patients, and control of hyperhidrosis improves the eczema. Acute pompholyx, also known as cheiropompholyx if it affects the hands, presents with severe, sudden outbreaks of intensely pruritic vesicles. Primary lesions are macroscopic, deep-seated multilocular vesicles resembling tapioca on the sides of the fingers (Fig. 5-11), palms, and soles. The eruption is symmetric and pruritic, with pruritus often preceding the eruption. Coalescence of smaller lesions may lead to bulla formation severe enough to prevent



**Fig. 5-11** Acute vesiculobullous hand eczema.





**Fig. 5-12**  
Hyperkeratotic hand dermatitis.

ambulation. Individual outbreaks resolve spontaneously over several weeks. Bullous tinea or an id reaction from a dermatophyte should be excluded, and patch testing should be considered to rule out allergic contact dermatitis.

### **Chronic vesiculobullous hand eczema**

In chronic cases, the lesions may be hyperkeratotic, scaling, and fissured, and the “dyshidrosiform” pattern may be recognized only during exacerbations. The pruritic 1–2 mm vesicles tend to be most pronounced at the sides of the fingers. In longstanding cases, the nails may become dystrophic. The distribution of the lesions is, as a rule, bilateral and roughly symmetric.

### **Hyperkeratotic hand dermatitis**

Males outnumber females by 2:1, and the patients are usually older adults. The eruption presents as hyperkeratotic, fissure-prone, erythematous areas of the middle or proximal palm. Vesicles are not seen. The volar surfaces of the fingers may also be involved (Fig. 5-12). Plantar lesions occur in about 10% of patients. Histologically, the lesions show chronic spongiotic dermatitis. The most important differential diagnosis is psoriasis, and some of the patients with chronic hyperkeratotic hand dermatitis will ultimately prove to be psoriatic. The presence of sharply demarcated plaques, nail pitting, or occasional crops of pustules is an important clue to psoriatic hand involvement.

### **Pulpitis (fingertip hand dermatitis)**

This hyperkeratotic and fissuring eczema affects primarily the fingertips and may extend to merge with eczema of the palm. Vesicles can occur. Involvement of the three fingers of the dominant hand suggests a contact dermatitis (irritant or allergic), whereas similar involvement of the nondominant hand suggests vegetables and other items related to food preparation that are held in this hand for cutting (e.g., garlic).

### **Treatment**

The hands are essential for work both in and out of the home. Treatment regimens must be practical and must allow patients to function as normally as possible. The efficacy of some of the treatments depends on the morphology of the eruption and the diagnostic classification (see previous discussion).

### **Protection**

Vinyl gloves may be worn during wet work, especially when detergents are used. Although vinyl gloves protect against chemicals, they do not prevent exposure to heat through the glove or the macerating effect of sweat, which accumulates under the gloves. They are also much less durable than rubber gloves. Rubber gloves may be used at home if patients do not exhibit allergy to rubber chemicals or latex. Wearing white cotton gloves under the vinyl gloves is beneficial. For rough work, such as gardening, wearing protective cloth or leather gloves is essential.

### **Barrier repair**

Moisturizing is a critical component of the management of hand dermatitis. Application of a protective moisturizing cream or ointment after each handwashing or water exposure is recommended. Creams require a preservative and have a higher risk of contact sensitivity. Ointments tend to have few ingredients and do not generally require a preservative. At night, even during periods of remission, a heavy moisturizing ointment should be applied to the hands after soaking in water. If palmar dryness is present, occlusion of the moisturizer with a plastic bag or vinyl gloves is recommended. White petrolatum is inexpensive and nonsensitizing and remains a valuable agent in the treatment of hand dermatitis. Jars of cream used by patients with hand dermatitis were contaminated with *Staphylococcus aureus* in 20% of cases in one study.

### **Topical agents**

Superpotent and potent topical corticosteroids are first-line pharmacologic therapy. Their efficacy is enhanced by presoaking and occlusion (soak and smear technique or wet dressings). A single application with occlusion at night is often more effective than multiple daytime applications. The treatment is continued until the hands are clear, and then either emollients are substituted or maintenance treatment two or three times weekly is continued to prevent recurrence. In refractory cases, superpotent corticosteroids may be used for 2–3 weeks, then on weekends, with a milder corticosteroid applied during the week.

The TCIs may be of benefit in some mildly affected patients. Soaks with a tar bath oil or applications of 20% LCD or 2% crude coal tar in an ointment base may be of benefit, especially in patients with hyperkeratotic hand eczema. Bexarotene gel can be beneficial in up to 50% of patients with refractory hand eczema.

### **Phototherapy**

Phototherapy in the form of high-dose UVA I, soak or cream PUVA, and oral PUVA can be effective. Given the thickness of the palms, UVA irradiation should be delivered 30 min after soaking, as opposed to bath PUVA, which can be done immediately after bathing. Relatively few phototoxic reactions are seen with regimens that use a 15–20 min soak in a 3 mg/L solution of 8-methoxypsoralen, starting with 0.25–0.5 J/cm<sup>2</sup> and increasing by 0.25–0.5 J/cm<sup>2</sup> three times a week.

Superficial Grenz ray radiotherapy remains a viable modality, but well-maintained machines are few in number. The depth of penetration of these very soft x-rays is limited, so it is best used after acute crusting and vesiculation have been cleared with other treatment.

### **Botulinum toxin A**

In patients with palmoplantar hyperhidrosis and associated hand eczema, treatment of the hyperhidrosis with intradermal injections of botulinum toxin A leads to both dramatic resolution of the sweating and clearing of the hand eczema. The hand eczema returns when the sweating returns.

Iontophoresis, which also reduces sweating, can similarly improve hand dermatitis. This illustrates the importance of wetness in the exacerbation of hand eczema.

### Systemic agents

The systemic agents used to treat severe chronic hand dermatitis are identical to those used for AD. The use of systemic corticosteroids usually results in dramatic improvement. Unfortunately, relapse frequently occurs almost as rapidly, so systemic steroids are recommended only to control acute exacerbations. For example, patients with infrequent but severe outbreaks of pompholyx may benefit from a few weeks of systemic steroids, starting at about 1 mg/kg/day. Patients with persistent, severe hand dermatitis should be considered for alternative, steroid-sparing therapy.

Methotrexate (in psoriatic doses), azathioprine, and MMF (adult dose of 1–1.5 g twice daily) can be considered. Cyclosporine can be effective, but given the chronicity of hand eczema, its use is best reserved for severe outbreaks. Oral retinoids may have a place in the management of hand dermatitis. Alitretinoin, 30 mg/day, will lead to complete or near-complete clearance of chronic refractory hand eczema in about 50% of patients, especially those with hyperkeratotic hand eczema. The onset of response is delayed, with some patients achieving optimal benefit only after more than 6 months of treatment. Acitretin, 30 mg/day, may have similar benefit.

### Workplace modifications

The incidence of hand dermatitis in the workplace can be reduced by identifying major irritants and allergens, preventing exposure through engineering controls, substituting less irritating chemicals when possible, enforcing personal protection and glove use, and instituting organized worker education. Hand eczema classes have been documented to reduce the burden of occupational dermatitis. It is important to note that prevention of exposure to a weak but frequent irritant can have more profound effects than removal of a strong but infrequently contacted irritant.

Proper gloves are essential in industrial settings. Nitrile gloves are generally less permeable than latex gloves. Gloves of ethylene vinyl alcohol copolymer sandwiched with polyethylene are effective against epoxy resin, methyl methacrylate, and many other organic compounds. Latex and vinyl gloves offer little protection against acrylates. The 4H (4 h) glove and nitrile are best in this setting. As hospitals transition to non-latex gloves, it is important to note that even low-protein, powder-free latex gloves reduce self-reported skin problems among health workers.

### Diaper (napkin) dermatitis

Diaper dermatitis has dramatically decreased as a result of highly absorbable disposable diapers. Nonetheless, dermatitis of the diaper area in infants remains a common cutaneous disorder. The highest prevalence occurs between 6 and 12 months of age. Diaper dermatitis is also seen in adults with urinary or fecal incontinence who wear diapers.

Irritant diaper dermatitis is an erythematous dermatitis limited to exposed surfaces. The folds remain unaffected, in contrast to intertrigo, inverse psoriasis, and candidiasis, where the folds are frequently involved. In severe cases of irritant dermatitis, there may be superficial erosion or even ulceration (Jacquet erosive diaper dermatitis), violaceous plaques and nodules (granuloma gluteale infantum), or pseudoverrucous papules and nodules; these three entities are part of a disease spectrum. The tip of the penis may become irritated and crusted, with the baby urinating frequently and spots of blood appearing on the diaper.

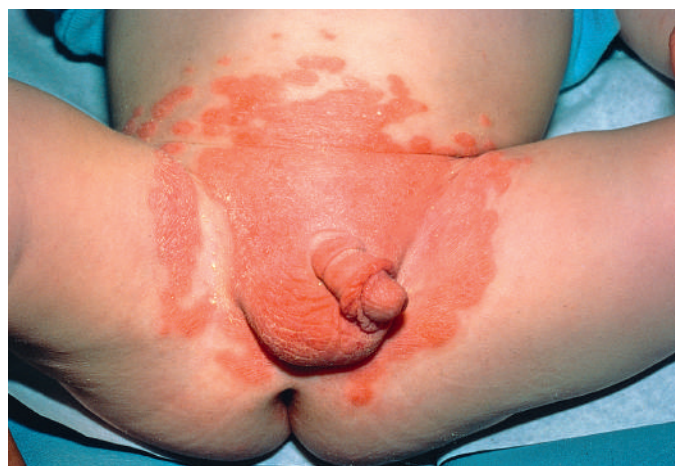

Fig. 5-13 Napkin psoriasis.

Excessive hydration with maceration of the skin is the primary causal factor in diaper dermatitis. The absence of diaper dermatitis in societies where children do not wear diapers clearly implicates the diaper environment as the cause of the eruption. Moist skin is more easily abraded by friction of the diaper as the child moves. Wet skin is more permeable to irritants. Skin wetness also allows the growth of bacteria and yeast. Bacteria raise the local pH, increasing the activity of fecal lipases and proteases. *Candida albicans* is frequently a secondary invader and, when present, produces typical satellite erythematous lesions or pustules at the periphery as the dermatitis spreads. *Staphylococcus aureus* and group A  $\beta$ -hemolytic streptococci can infect diaper dermatitis. Breast-feeding is associated with less frequent diaper dermatitis, and diarrhea is a risk factor.

The differential diagnosis of diaper dermatitis should include napkin psoriasis (Fig. 5-13), seborrheic dermatitis, AD, Langerhans cell histiocytosis, tinea cruris, acrodermatitis enteropathica, aminoacidurias, biotin deficiency, and congenital syphilis. Allergic contact dermatitis is becoming more frequently recognized as a cause of dermatitis in the diaper area. Allergens include sorbitan esequoleate, fragrances, disperse dye, cyclohexylthiophthalimide, and mercaptobenzothiazole (in rubber diaper covers). Given the skill of most pediatricians in the management of diaper dermatitis, dermatologists should think about these conditions in infants who have failed the standard interventions used by pediatricians. Refractory diaper dermatitis may require a biopsy to exclude some of these conditions.

Prevention is the best treatment. Diapers that contain superabsorbent gel have been proved effective in preventing diaper dermatitis in both neonates and infants. They work by absorbing the wetness away from the skin and by buffering the pH. Cloth diapers and regular disposable diapers are equal in their propensity to cause diaper dermatitis and are inferior to the superabsorbent gel diapers. The frequent changing of diapers is also critical: every 2 hours for newborns and every 3–4 hours for older infants. The renewed popularity of cloth and bamboo diapers as more natural and ecologic has led to a reemergence of severe diaper dermatitis in some European countries.

Protecting the skin of the diaper area is the most important treatment for diaper dermatitis. Zinc oxide paste and petrolatum are both effective barriers, preventing the urine and stool from contacting the dermatitis. Zinc oxide paste with 0.25% miconazole may be considered if *Candida* may be present. If simple improved hygiene and barrier therapy are not effective, the application of a mixture of equal parts nystatin ointment and 1% hydrocortisone ointment at each diaper change offers both anticandidal activity and an occlusive protective barrier from urine and stool, and can be very effective.



## Circumostomy eczema

Eczematization of the surrounding skin frequently occurs after an ileostomy or colostomy. It is estimated that 75% of ileostomy patients have some postoperative sensitivity as a result of the leakage of intestinal fluid onto unprotected skin. As the consistency of the intestinal secretion becomes viscous, the sensitization subsides. Proprietary medications containing karaya powder have been helpful; 20% cholestyramine (an ion-exchange resin) in Aquaphor and topical sucralfate as a powder or emollient at 4 g% concentration are effective treatments. Psoriasis may also appear at ostomy sites, especially in patients with inflammatory bowel disease (IBD) being treated with tumor necrosis factor (TNF) inhibitors and developing psoriasis as a complication. Topical treatment may be difficult because the appliance adheres poorly after the topical agents are applied. A topical corticosteroid spray may be used and will not interfere with appliance adherence. Contact dermatitis to the ostomy bag adhesive can be problematic, and even supposedly hypoallergenic ostomy bags may still trigger dermatitis in these patients.

## Autosensitization and conditioned irritability

The presence of a localized, chronic, and usually severe focus of dermatitis may affect distant skin in two ways. Patients with a chronic localized dermatitis may develop dermatitis at distant sites from scratching or irritating the skin. This is called “conditioned irritability.” The most common scenario is distant dermatitis in a patient with a chronic eczematous leg ulcer. Autoeczematization refers to the spontaneous development of widespread dermatitis or dermatitis distant from a local inflammatory focus. The agent causing the local inflammatory focus is not the direct cause of the dermatitis at the distant sites. Autoeczematization most frequently presents as a generalized acute vesicular eruption with a prominent dyshidrosiform component on the hands. The most common associated condition is a chronic eczema of the legs, with or without ulceration. The “angry back” or “excited skin” syndrome observed with strongly positive patch tests, and the local dermatitis seen around infectious foci (infectious eczematoid dermatitis), may represent a limited form of this reaction.

## Id reactions

Patients with a variety of infectious disorders may present with eczematous dermatitis. The classic example is the vesicular id reactions of the hands in response to an inflammatory tinea of the feet. Similarly, inflammatory tinea capitis is often associated with a focal or diffuse dermatitis, primarily of the upper half of the body. Nummular eczematous lesions or pityriasis rosea like lesions may occur in patients with head or pubic louse infestation. Id reactions clear when the focus of infection or infestation is treated, but topical or systemic anti-inflammatory agents may be required until the triggering infection is eradicated.

## Juvenile plantar dermatosis

Juvenile plantar dermatosis is an eczematous disorder of children from age 3 years to puberty. It usually begins as a patchy, symmetric, smooth, red glazed macule on the base or medial surface of the great toes, sometimes with fissuring and desquamation. Lesions evolve into red scaling patches involving the weight-bearing and frictional areas of the feet, usually symmetrically. The forefoot is usually much more involved than the heel. Toe webs and arches are spared. The eruption

is disproportionately more common in atopic children. In some patients, a similar eruption occurs on the fingers.

The disease is caused by the repeated maceration of the feet by occlusive shoes, especially athletic shoes, or by the abrasive effects of pool surfaces or diving boards. The affected soles remain wet in the rubber bottoms of the shoes or are macerated by pool water. Thin, nonabsorbent, synthetic socks contribute to the problem.

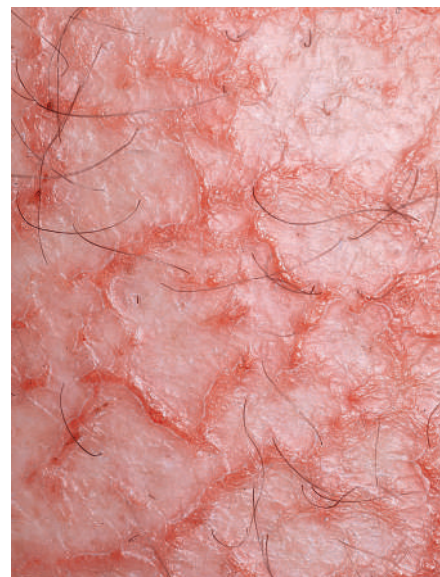Histologically, there is psoriasiform acanthosis and a sparse, largely lymphocytic infiltrate in the upper dermis, most dense around sweat ducts at their point of entry into the epidermis. Spongiosis is often present, and the stratum corneum is thin but compact.

The diagnosis of plantar dermatosis is apparent on inspection, especially if there is a family or personal history of atopy and the toe webs are spared. Treatment involves avoidance of maceration. Foot powders, thick absorbent socks, absorbent insoles, and having alternate pairs of shoes to wear to allow the shoes to dry out are all beneficial. Topical corticosteroid medications are of limited value and often are no more effective than occlusive barrier protection. Petrolatum or urea preparations can sometimes be of benefit. Most cases clear within 4 years of diagnosis.

Allergic contact dermatitis may play a significant role in plantar dermatoses in childhood. In one study from Scotland, 50% of children with “inflammatory dermatitis” of the soles had relevant positive patch tests, and 4 of 14 children with typical juvenile plantar dermatitis also had a relevant contact allergen. Refractory plantar dermatitis in childhood should suggest allergic contact dermatitis.

## Xerotic eczema

Xerotic eczema is also known as winter itch, eczema craquelé, and asteatotic eczema. These vividly descriptive terms are all applied to dehydrated skin showing redness, dry scaling, and fine crackling that may resemble crackled porcelain or the fissures in the bed of a dried lake. The primary lesion is an erythematous patch covered with an adherent scale. As the lesion enlarges, fine cracks in the epidermis occur (Fig. 5-14). Nummular lesions may occur. Xerotic “nummular” eczema is less weepy than classic nummular dermatitis. Favored sites are the anterior shins, extensor arms, and flank. Elderly persons are particularly predisposed, and xerosis is the most



**Fig. 5-14** Eczema craquelé.

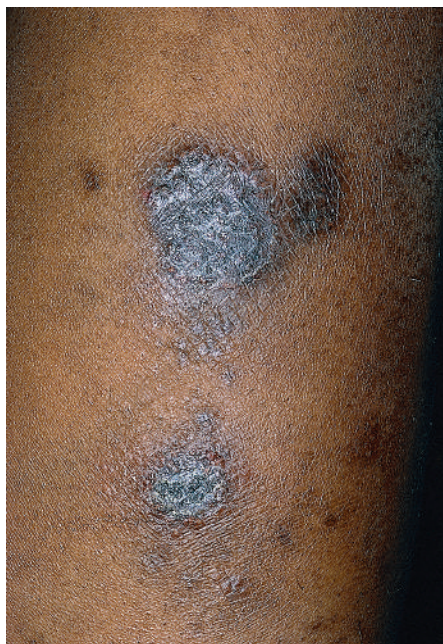common cause of pruritus in older individuals. Xerotic eczema is seen most frequently during the winter, when there is low relative humidity. Bathing with hot water and harsh soaps contributes. The epidermal water barrier is impaired, and TEWL is increased. Epidermal barrier repair begins to decrease after age 55, correlated with an increase in epidermal pH. This is why older patients complain that they have not changed their bathing routine or soaps, yet have developed xerotic dermatitis. The loss of barrier repair ability is improved by acidifying the epidermis, showing the benefit of mild acids in treating xerosis. Heterozygous null mutation of the *FLG* gene is associated with xerosis in young (18–40) and older (60–75) adults.

Taking short tepid showers, limiting use of soap to soiled and apocrine-bearing areas, avoiding harsh soaps and using acid pH synthetic detergents, and promptly applying an emollient after bathing are usually effective. White petrolatum and emollients containing 10% urea or 5% lactic acid are effective. Topical corticosteroids in ointment vehicles are useful for inflamed areas.

### Nummular eczema (discoid eczema)

Nummular eczema (NE) usually begins on the lower legs, dorsa of the hands, or extensor surfaces of the arms. In younger adults, females predominate, but most patients older than 40 are male. Alcohol consumption has been associated with NE in adult males. A single lesion often precedes the eruption and may be present for some time before other lesions appear. The primary lesions are discrete, coin-shaped, erythematous, edematous, vesicular, and crusted patches (Fig. 5-15). Most lesions are 2–4 cm in diameter. Lesions may form after trauma (conditioned hyperirritability). As new lesions appear, the old lesions expand as tiny papulovesicular satellite lesions appear at the periphery and fuse with the main plaque. In severe cases, the condition may spread into palm-sized or larger patches. Pruritus is usually severe and of the same paroxysmal, compulsive quality and nocturnal timing seen in AD and prurigo nodularis.

Atopic dermatitis frequently has nummular morphology in adolescents, but in atopy the lesions tend to be more chronic and lichenified. Histologically, NE is characterized by acute or



**Fig. 5-15** Nummular eczema.

subacute spongiotic dermatitis. The skin lesions of nummular dermatitis are frequently colonized with *Staphylococcus aureus*, in frequency similar to that seen in AD. Relevant positive patch tests are found in one quarter to one third of patients with NE. This may represent the primary cause of the dermatitis or a secondary allergy that developed from products used to treat the NE.

Initial treatment consists of simple soaking and greasing with an occlusive ointment, and once-daily or twice-daily application of a potent or superpotent topical corticosteroid cream or ointment. Ointments are more effective, and occlusion may be necessary. If secondary staphylococcal infection is present, an antibiotic with appropriate coverage can be used. Stopping alcohol consumption may improve response. A sedating antihistamine, doxepin, or gabapentin at bedtime can help with sleep and reduce nighttime scratching. In some cases refractory to topical agents, intralesional or systemic corticosteroid therapy may be required. In patients unresponsive to topical steroids, phototherapy with NB UVB, bath (soak), or oral PUVA can be effective. For refractory plaques, the addition of topical tar as 2% crude coal tar or 20% LCD may be beneficial.

### Pruritic dermatitis in elderly persons

Pruritic skin conditions are common in elderly patients, appearing about age 60 and increasing in severity with age. Males are more often affected, and Asians and Caucasians more frequently have pruritus as seniors than African Americans or Hispanics.

The dermatoses seen in this age group are typically eczematous or papular. The eczematous plaques may resemble nummular dermatitis, a feature recognized by Marion Sulzberger when he coined the phrase “exudative discoid and lichenoid chronic dermatitis,” or “oid-oid disease.” The pathogenic basis of this component of dermatitis in elderly persons may be related to barrier failure due to loss of acidification of the epidermis. In addition, patients often have urticarial papules on the trunk and proximal extremities that resemble insect bites. These lesions are termed “subacute prurigo” and histologically demonstrate features of an arthropod assault, with superficial and deep perivascular lymphohistiocytic infiltrates, dermal edema, and at times interstitial eosinophils. Lesions may also show features of transient acantholytic dermatitis or eosinophilic folliculitis. This component of the eruption may be related to the tendency of elderly individuals to have an immune system that skews toward Th2 because of loss of Th1 function. At times, patients will have both types of eruption, either simultaneously or sequentially. The combination of barrier failure and an immune system skewed toward Th2 is parallel to what occurs in the setting of AD. For this reason, some practitioners consider this “adult atopic dermatitis.” However, it is unknown whether these conditions have a genetic basis, or more likely, given the time of onset, are caused by acquired barrier and immune system abnormalities. In these patients, allergic contact dermatitis and photodermatitis may be present or develop. Patch testing may identify important allergens, avoidance of which leads to improvement.

Calcium channel blockers may be associated with pruritic dermatitis, but stopping them will clear only about one quarter of patients taking that class of medication. Hydrochlorothiazide is also more frequently used by itchy elderly patients. Treatment for these patients is similar to that of AD patients, with oral antipruritics, emollients, and topical corticosteroids (soak and smear) as first-line therapy. In refractory cases, phototherapy (UVB or PUVA), Goeckerman therapy (UVB plus



crude coal tar) in a day treatment setting, and immunosuppressive agents can be effective. Inadvertent use of phototherapy in the patient with coexistent photosensitivity will lead to an exacerbation of pruritic dermatitis.

## HORMONE-INDUCED DERMATOSES

Autoimmune progesterone dermatitis may appear as urticarial papules, deep gyrate lesions, papulovesicular lesions, an eczematous eruption, or targetoid lesions. Urticarial and erythema multiforme like lesions are most characteristic. Lesions typically appear 5–7 days before menses, and improve or resolve a few days following menses. Pruritus is common. Onset is typically in the third and fourth decades of life. Familial cases have been reported. When urticaria is the predominant skin lesion, there is a generalized distribution, and it may be accompanied by laryngospasm. Anaphylactoid reactions may occur. Oral erosions may be present. Many of the reported patients had received artificial progestational agents before the onset of the eruption. In some, it appeared during a normal pregnancy. The eruption may worsen or clear during pregnancy. Rarely, it can occur in males given progesterone and adolescent females. Progesterone luteal-phase support during in vitro fertilization has exacerbated the disease.

In most cases, diagnosis has been confirmed by intradermal testing with progesterone. A positive test may be immediate (30 min) or delayed (24–96 h). Flares may be induced by intramuscular, intravaginal, or oral progesterone. The most common treatment is an oral contraceptive to suppress ovulation, thereby reducing progesterone levels. Topical corticosteroids for mild eczematous cases and antihistamines in urticarial cases can be beneficial. For more refractory cases or in patients with erythema multiforme, fixed drug, or anaphylaxis as the cause, suppression of progesterone production with conjugated estrogen and gonadotropin-releasing antagonists such as leuprolide acetate, danazol, and tamoxifen has been successful. Desensitization protocols may allow for use of progesterone during in vitro fertilization and pregnancy. Menopause and oophorectomy (except in one reported patient) have been curative.

Autoimmune estrogen dermatitis also presents as a cyclic skin disorder that may appear eczematous, papular, bullous, or urticarial. Pruritus is typically present. Skin eruptions may be chronic but are exacerbated premenstrually or occur only immediately before the menses. Characteristically, the dermatosis clears during pregnancy and at menopause. Intracutaneous skin testing with estrone produces a papule lasting longer than 24 h or an immediate urticarial wheal (in patients with urticaria). Injections of progesterone yield negative results, ruling out autoimmune progesterone dermatitis. Tamoxifen is effective in some cases.

**Agner T, et al:** Hand eczema severity and quality of life: a cross-sectional, multicentre study of hand eczema patients. *Contact Dermatitis* 2008; 59:43.

**Alonso C, et al:** Efficacy of petrolatum jelly for the prevention of diaper rash: a randomized clinical trial. *J Spec Pediatr Nurs* 2013; 18:123.

**Asai J, et al:** Case of autoimmune progesterone dermatitis presenting as fixed drug eruption. *J Dermatol* 2009; 36:643.

**Barrett ME, et al:** Dermatoses of the breast in lactation. *Dermatol Ther* 2013; 26:331.

**Bernstein I, et al:** A case of progesterone-induced anaphylaxis, cyclic urticaria/angioedema, and autoimmune dermatitis. *J Womens Health* 2011; 20:643.

**Bonamonte D, et al:** Nummular eczema and contact allergy: a retrospective study. *Dermatitis* 2012; 23:153.

**Chawla SV, et al:** Autoimmune progesterone dermatitis. *Arch Dermatol* 2009; 145:341.

**Coenraads PJ:** Hand eczema. *N Engl J Med* 2012; 367:1829.

**Cvetkovski RS, et al:** Prognosis of occupational hand eczema: a follow-up study. *Arch Dermatol* 2006; 142:305.

**Darling MI, et al:** Sole dermatitis in children: patch testing revisited. *Pediatr Dermatol* 2012; 29:254.

**Delle Sedie A, et al:** Psoriasis, erythema nodosum, and nummular eczema onset in an ankylosing spondylitis patient treated with infliximab. *Scand J Rheumatol* 2007; 36:403.

**Guillet MH, et al:** A 3-year causative study of pompholyx in 120 patients. *Arch Dermatol* 2007; 143:1504.

**Gunes T, et al:** Guaiazulene: a new treatment option for recalcitrant diaper dermatitis in NICU patients. *J Matern Fetal Neonatal Med* 2013; 26:197.

**Heimall LM, et al:** Beginning at the bottom: evidence-based care of diaper dermatitis. *MCN Am J Matern Child Nurs* 2012; 37:10.

**Isaksson M, et al:** Children with atopic dermatitis should always be patch-tested if they have hand or foot dermatitis. *Acta Derm Venereol* 2014 [Epub ahead of print].

**Jacob SE:** Cyclosporin ophthalmic emulsion: a novel therapy for benzyl alcohol-associated eyelid dermatitis. *Contact Dermatitis* 2008; 58:169.

**Jenkins J, et al:** Autoimmune progesterone dermatitis associated with infertility treatment. *J Am Acad Dermatol* 2008; 58:353.

**Kim WJ, et al:** Features of *Staphylococcus aureus* colonization in patients with nummular eczema. *Br J Dermatol* 2013; 168:656.

**Kontochristopoulos G, et al:** Letter: regression of relapsing dyshidrotic eczema after treatment of concomitant hyperhidrosis with botulinum toxin-A. *Dermatol Surg* 2007; 33:1289.

**Krupa Shankar DS, Shrestha S:** Relevance of patch testing in patients with nummular dermatitis. *Indian J Dermatol Venereol Leprol* 2005; 71:406.

**Lakshmi C, Srinivas CR:** Hand eczema: an update. *Indian J Dermatol Venereol Leprol* 2013; 78:569.

**Le K, Wood G:** A case of autoimmune progesterone dermatitis diagnosed by progesterone pessary. *Australas J Dermatol* 2011; 52:139.

**Lee M, et al:** A case of autoimmune progesterone dermatitis misdiagnosed as allergic contact dermatitis. *Allergy Asthma Immunol Res* 2011; 3:141.

**Leubaek A, et al:** Incidence of hand eczema in a population-based twin cohort: genetic and environmental risk factors. *Br J Dermatol* 2007; 157:552.

**Li CH, et al:** Diaper dermatitis: a survey of risk factors for children aged 1–24 months in China. *J Int Med Res* 2012; 40:1752.

**Lundov MD, et al:** Creams used by hand eczema patients are often contaminated with *Staphylococcus aureus*. *Acta Derm Venereol* 2012; 92:441.

**Lynde C, et al:** Extended treatment with oral alitretinoin for patients with chronic hand eczema not fully responding to initial treatment. *Clin Exp Dermatol* 2012; 37:712.

**Mauruani A, et al:** Re-emergence of papulonodular napkin dermatitis with use of reusable diapers: report of 5 cases. *Eur J Dermatol* 2013; 23:246.

**Mutasim DF, et al:** Bullous autoimmune estrogen dermatitis. *J Am Acad Dermatol* 2003; 49:130.

**Nivenius E, et al:** Tacrolimus ointment vs steroid ointment for eyelid dermatitis in patients with atopic keratoconjunctivitis. *Eye* 2007; 21:968.

**Petering H, et al:** Comparison of localized high-dose UVA1 irradiation versus topical cream psoralen-UVA for treatment of chronic vesicular dyshidrotic eczema. *J Am Acad Dermatol* 2004; 50:68.

**Poffet F, et al:** Autoimmune progesterone dermatitis: potential role of cutaneous angiogenin expression? *Dermatol* 2011; 223:32.

**Prieto-Garcia A, et al:** Autoimmune progesterone dermatitis: clinical presentation and management with progesterone desensitization for successful in vitro fertilization. *Fertil Steril* 2011; 95:1121.e9.

**Ravanfar P, et al:** Diaper dermatitis: a review and update. *Curr Opin Pediatr* 2012; 24:472.

**Sergeant A, et al:** Heterozygous null alleles in filaggrin contribute to clinical dry skin in young adults and the elderly. *J Invest Dermatol* 2009; 129:1042.

**Stamatas GN, Tierney NK:** Diaper dermatitis: etiology, manifestations, prevention and management. *Pediatr Dermatol* 2014; 31:1.

**Thyssen JP, et al:** Filaggrin null-mutations may be associated with a distinct subtype of atopic hand eczema. *Acta Derm Venereol* 2010; 90:528.

**Thyssen JP, et al:** Xerosis is associated with atopic dermatitis, hand eczema and contact sensitization independent of filaggrin gene mutations. *Acta Derm Venereol* 2013; 93:406.

**Toms-Whittle LM, et al:** Autoimmune progesterone dermatitis: a diagnosis easily missed. *Clin Dermatol* 2010; 36:378.

**Wollina U:** Pompholyx: a review of clinical features, differential diagnosis, and management. *Am J Clin Dermatol* 2010; 11:305.

## IMMUNODEFICIENCY SYNDROMES

Primary immunodeficiency diseases (PIDs), are important to the dermatologist. PIDs may present with skin manifestations, and the dermatologist may be instrumental in referring appropriate patients for immunodeficiency evaluation. These conditions have also given us tremendous insight into the genetic makeup and functioning of the immune system. The PIDs can be classified as those with predominantly antibody deficiency, impaired cell-mediated immunity (cellular immunodeficiencies, T cells, natural killer [NK] cells), combined B-cell and T-cell deficiencies, defects of phagocytic function, complement deficiencies, and well-characterized syndromes with immunodeficiency. More than 150 PIDs have been identified, as of the 2005 classification. Many of the original paradigms of PIDs have been refuted. PIDs are not rare, can be sporadic (not familial), can have adult onset, can be autosomal dominant, have incomplete penetrance, and may even spontaneously improve over time.

The dermatologist should suspect a PID in certain situations, and the type of immunodeficiency can at times be suggested by the clinical situation. Skin infections, especially chronic and recurrent bacterial skin infections, can be the initial manifestation of a PID with neutropenia, elevated IgE, or T-helper cell immunodeficiency. Fungal (especially *Candida*) and viral infections (warts, molluscum) suggest a PID of helper T cells or a specific monogenetic defect (STAT1, IL-17). Not all immunodeficiencies present with infections, but rather an inflammatory phenotype. Eczematous dermatitis and erythroderma, at times closely resembling severe atopic or seborrheic dermatitis, may affect the skin of PID patients. They may be refractory to standard therapies. Granuloma formation, autoimmune disorders, and vasculitis are other cutaneous manifestations seen in some forms of primary immunodeficiency. The PIDs in which a specific infection or finding is the more common presentation are discussed in other chapters, including chronic mucocutaneous candidiasis (Chapter 15); Hermansky-Pudlak, Chédiak-Higashi, and Griscelli syndromes with pigmentary anomalies (Chapter 36); and cartilage-hair hypoplasia syndrome with disorders of hair (Chapter 33). The conditions described next are the most important PID conditions with which dermatologists should be familiar.

**Abrams M, et al:** Genetic immunodeficiency diseases. *Adv Dermatol* 2007; 23:197.

**Mohiuddin MS, et al:** Diagnosis and evaluation of primary panhypogammaglobulinemia: a molecular and genetic challenge. *J Allergy Clin Immunol* 2013; 131:1717.

**Notarangelo L, et al:** Primary immunodeficiency diseases: an update from the International Union of Immunological Societies Primary Immunodeficiency Diseases Classification Committee Meeting in Budapest, 2005. *J Allergy Clin Immunol* 2006; 117:883.

**Ozcan E, et al:** Primary immune deficiencies with aberrant IgE production. *J Allergy Clin Immunol* 2008; 122:1054.

**Rezaei N, et al:** Primary immunodeficiency diseases associated with increased susceptibility to viral infections and malignancies. *J Allergy Clin Immunol* 2011; 127:1329.

**Schwartzfarb EM, et al:** Pyoderma gangrenosum in a patient with Bruton's X-linked agammaglobulinemia: shared pathogenesis of altered tumor necrosis factor alpha? *J Clin Aesthet Dermatol* 2008; 1:26.

**Sillevis Smitt JH, et al:** The skin in primary immunodeficiency disorders. *Eur J Dermatol* 2005; 15:425.

**Uzzaman A, Fuleihan RL:** Approach to primary immunodeficiency. *Allergy Asthma Proc* 2012; 33:S91.

## Disorders of antibody deficiency

### X-linked agammaglobulinemia

Also known as Bruton syndrome, X-linked agammaglobulinemia (XLA) is caused by mutations in the *BTK* gene (Bruton tyrosine kinase), which is essential for the development of B lymphocytes. XLA typically presents between 4 and 12 months of life, because the neonate obtains adequate immunoglobulin from the mother to protect it from infection in young infancy. The affected boys present with infections of the upper and lower respiratory tracts, gastrointestinal (GI) tract, skin, joints, and central nervous system (CNS). The infections are usually caused by *Streptococcus pneumoniae*, *Staphylococcus aureus*, *Haemophilus influenzae*, *Helicobacter*, and *Pseudomonas*. Recurrent skin staphylococcal infection may be a prominent component of this condition. Atopic-like dermatitis and pyoderma gangrenosum have been described. Hepatitis B, enterovirus, and rotavirus infections are common in XLA patients, and one-third develop a rheumatoid-like arthritis. Enterovirus infection may result in a dermatomyositis-meningoencephalitis syndrome. An absence of palpable lymph nodes is characteristic.

Immunoglobulin A, IgM, IgD, and IgE are virtually absent from the serum, although IgG may be present in small amounts. The spleen and lymph nodes lack germinal centers, and plasma cells are absent from the lymph nodes, spleen, bone marrow, and connective tissues. In XLA, B cells usually only make up 0.1% of circulating peripheral blood lymphocytes (normal 5–20%). More than 500 different mutations have been identified in the *BTK* gene in XLA patients. Some of these mutations only partially compromise the gene, so some patients may have milder phenotype and up to 7% circulating B cells, making differentiation from common variable immunodeficiency difficult. In addition to mutations in the *BTK* gene, mutations in other genes required for immunoglobulin production, such as *IGHM*, *CD79A*, *CD79B*, *IGLLA*, *BLNK*, and *LRRC8A*, can be responsible for panhypogammaglobulinemia.

Treatment with gamma globulin has enabled many patients to live into adulthood. The maintenance dose required can vary considerably from patient to patient. High-dose IVIG may also lead to improvement of pyoderma gangrenosum-like lower extremity ulcerations. Chronic sinusitis and pulmonary infection remain problematic because of the lack of IgA, and chronic sinopulmonary infections require repeated pulmonary function monitoring.

**Dua J, et al:** Pyoderma gangrenosum-like ulcer caused by *Helicobacter cinaedi* in a patient with X-linked agammaglobulinemia. *Clin Exp Dermatol* 2012; 37:642.

**Hunter HL, et al:** Eczema and X-linked agammaglobulinemia. *Clin Exp Dermatol* 2008; 33:148.

**Lin MT, et al:** De novo mutation in the *BTK* gene of atypical X-linked agammaglobulinemia in a patient with recurrent pyoderma. *Ann Allergy Asthma Immunol* 2006; 96:744.

### Isolated IgA deficiency (OMIM 137100)

An absence or marked reduction of serum IgA (<7 mg/dL) is the most common immunodeficiency state. The incidence varies greatly based on ethnic background: about 1:150 in the Arab Peninsula and Spain, 1:225–1:300 in the United States, and 1:14,000–18,000 in Japan. Certain medications appear



to induce selective IgA deficiency, including phenytoin, sulfasalazine, cyclosporine, nonsteroidal anti-inflammatory drugs (NSAIDs), and hydroxychloroquine. The genetic cause in most cases is unknown.

From 10% to 15% of all symptomatic immunodeficiency patients have IgA deficiency. Most IgA-deficient patients, however, are completely well. Of those with symptoms, half have repeated infections of the GI and respiratory tracts, and one-quarter have autoimmune disease. Allergies such as anaphylactic reactions to transfusion or IVIG, asthma, and atopic dermatitis are common in the symptomatic group. There is an increased association of celiac disease, dermatitis herpetiformis, and IBD. Vitiligo, alopecia areata, and other autoimmune diseases (e.g., systemic lupus erythematosus [SLE], dermatomyositis, scleroderma, thyroiditis, rheumatoid arthritis, polyarteritis-like vasculitis, Sjögren syndrome) have all been reported to occur in these patients. Malignancy is increased in adults with IgA deficiency.

**Mellemkjaer L, et al:** Cancer risk among patients with IgA deficiency or common variable immunodeficiency and their relatives: a combined Danish and Swedish study. *Clin Exp Immunol* 2002; 130:495.

**Paradela S, et al:** Necrotizing vasculitis with a polyarteritis nodosa-like pattern and selective immunoglobulin A deficiency: case report and review of the literature. *J Cutan Pathol* 2008; 35:871.

**Samolitis NJ, et al:** Dermatitis herpetiformis and partial IgA deficiency. *J Am Acad Dermatol* 2006; 54:S206.

**Yel L:** Selective IgA Deficiency. *J Clin Immunol* 2010; 30:10.

## Common variable immunodeficiency

Common variable immunodeficiency (CVID) is a heterogeneous disorder and is the most common immunodeficiency syndrome after IgA deficiency. Patients have low levels of IgG and IgA, and 50% also have low levels of IgM. Lymphocyte counts may be normal or low. Multiple genetic defects have been found in CVID, including mutations in *ICOS* (CVID type 1), *TNFRSF13B* (type 2), *CD19* (type 3), *TNFRSF13C* (type 4), *MS4A1* (type 5), *CD81* (type 6), *CR2* (type 7), *LRBA* (type 8), *PRKCD* (type 9), and *NFKB2* (CVID 10). These patients do not form antibodies to bacterial antigens, and have recurrent sinopulmonary infections. They have a predisposition to autoimmune disorders, such as vitiligo and alopecia areata, GI abnormalities, lymphoreticular malignancy (10-fold increase of lymphoma), and gastric carcinoma. Noninfectious granulomas have been reported in as many as 22% of CVID patients. Seven percent of CVID patients with granulomas have cutaneous granulomas, and virtually all patients with cutaneous granulomas also have visceral granulomas. These patients are more often female and have higher risk for lymphoma than other CVID patients. The granulomas can show multiple histologic patterns: granuloma annulare like, sarcoidal, and even caseating. They show a CD4/CD8 ratio of less than 1, distinguishing these granulomas from sarcoidosis. CVID patients who develop granulomas have more severe depletion of isotype-switched memory B cells and naïve T cells, an immunologic profile also seen in ataxia telangiectasia patients with cutaneous granulomas.

Replacement of the reduced immunoglobulins with IVIG may help reduce infections. Topical, systemic, and intralesional corticosteroids may be used for the granulomas, depending on their extent. Infliximab and etanercept have been effective in steroid-refractory cases.

**Artac H, et al:** Sarcoid-like granulomas in common variable immunodeficiency. *Rheumatol Int* 2009; 30:109.

**DeJager M, et al:** Immunohistochemical features of cutaneous granulomas in primary immunodeficiency disorders: comparison with cutaneous sarcoidosis. *J Cutan Pathol* 2008; 35:467.

**Fernandez-Ruiz M, et al:** Fever of unknown origin in a patient with common variable immunodeficiency associated with multisystemic granulomatous disease. *Intern Med* 2007; 46:1197.

**Lin JH, et al:** Etanercept treatment of cutaneous granulomas in common variable immunodeficiency. *J Allergy Clin Immunol* 2006; 117:878.

**Lun KR, et al:** Granulomas in common variable immunodeficiency: a diagnostic dilemma. *Australas J Dermatol* 2004; 45:51.

**Mazzatenta C, et al:** Granulomatous dermatitis in common variable immunodeficiency with functional T-cell defect. *Arch Dermatol* 2006; 142:783.

**Mitra A, et al:** Cutaneous granulomas associated with primary immunodeficiency disorders. *Br J Dermatol* 2005; 153:194.

## Class-switch recombination defects (formerly immunodeficiency with hyper-IgM)

This group of diseases includes defects that are combined T-cell and B-cell abnormalities, such as CD40 deficiency (*CD40*) and CD40 ligand deficiency (*CD40LG*), and disorders of primary B cells, such as cytidine deaminase (*AICDA*) and uracil-DNA glycosylase (*UNG*) deficiencies. Class-switch recombination defects are rare, and the different genetic diseases included in this group appear to have different clinical manifestations. These patients experience recurrent sinopulmonary infections, diarrhea, and oral and anogenital ulcers. Neutropenia may be associated with the ulcers. Recalcitrant human papillomavirus infections (typically flat warts) may occur.

Hypomorphic mutations in *NEMO* or *IKBK* are associated with hypogammaglobulinemia and elevated IgM and may be associated with anhidrotic ectodermal dysplasia with immunodeficiency. *NEMO* mutations cause X-linked recessive disorders with lymphocytosis and elevated CD3 and CD4 cells and low levels of NK cells. The mother may have mild stigmata of incontinentia pigmenti. These male infants present within the first few months of life with hypohidrosis, delayed tooth eruption, and immunodeficiency. Hair may be absent. Frequent infections of the skin and respiratory tract are common. The eruption has been characterized as an “atopic dermatitis-like eruption,” although some patients may have prominent intertriginous lesions resembling seborrheic dermatitis. Treatment is bone marrow transplantation.

**Chang MW, et al:** Mucocutaneous manifestations of the hyper-IgM immunodeficiency syndrome. *J Am Acad Dermatol* 1998; 38:191.

**Mancini AJ, et al:** X-linked ectodermal dysplasia with immunodeficiency caused by *NEMO* mutation: early recognition and diagnosis. *Arch Dermatol* 2008; 144:342.

## Thymoma with immunodeficiency

Thymoma with immunodeficiency, also known as Good syndrome, occurs in adults in whom profound hypogammaglobulinemia and benign thymoma appear almost simultaneously. It is now classified predominantly as an antibody deficiency disorder. There is a striking deficiency of B and pre-B cells. One patient developed vulvovaginal gingival lichen planus. Myelodysplasia and pure red blood cell aplasia may occur. Patients are at risk for fatal opportunistic pulmonary infections with fungi and *Pneumocystis*. Thymectomy does not prevent the development of the infectious or lymphoreticular complications. Supportive therapy with IVIG, granulocyte-macrophage colony-stimulating factor (GM-CSF), and transfusions may be required.

**Moutasim KA, et al:** A case of vulvovaginal gingival lichen planus in association with Good's syndrome. *Oral Surg Oral Med Oral Pathol Oral Radiol Endod* 2008; 105:e57.

**Ohuchi M, et al:** Good syndrome coexisting with leukopenia. *Ann Thorac Surg* 2007; 84:2095.

## Disorders with T-cell deficiency

T-cell deficiency states can result from lack of thymic tissue, enzyme defects toxic to T lymphocytes (purine nucleoside phosphorylase deficiency), failure to express surface molecules required for immune interactions (CD3, major histocompatibility complex [MHC] class I and II), or defects in signaling molecules (ZAP-70).

### DiGeorge syndrome

DiGeorge syndrome is an autosomal dominant disorder that in 50% of cases is caused by hemizygous deletion of 22q11-p11 and rarely by deletions in 10p. Many cases are sporadic. Most DiGeorge syndrome patients have the congenital anomalies and only minor thymic anomalies. They present with hypocalcemia or congenital heart disease. The syndrome includes congenital absence of the parathyroids and an abnormal aorta. Aortic and cardiac defects are the most common cause of death. DiGeorge syndrome is characterized by a distinctive facies: notched, low-set ears, micrognathia, shortened philtrum, and hypertelorism. Patients with these DiGeorge congenital malformations and complete lack of thymus are deemed to have “complete DiGeorge syndrome.” Cell-mediated immunity is absent or depressed, and few T cells with the phenotype of recent thymus emigrants are found in the peripheral blood or tissues. Opportunistic infections are common despite normal immunoglobulin levels. Maternally derived graft-versus-host disease (GVHD) may occur in these patients. A small subset of patients with complete DiGeorge syndrome develop an eczematous dermatitis, lymphadenopathy, and an oligoclonal T-cell proliferation. The condition may present as an atopic-like dermatitis, severe and extensive seborrheic dermatitis, or an erythroderma. This is called “atypical complete DiGeorge syndrome.” Biopsies show features of a spongiotic dermatitis with eosinophils, necrotic keratinocytes with satellite necrosis, and characteristically perieccrine and intraeccrine inflammation. This resembles the histology of grade 1 or 2 GVHD, lichen striatus, and some cases of mycosis fungoides. One African American patient with DiGeorge syndrome developed a granulomatous dermatitis. The treatment for complete DiGeorge syndrome is thymic transplantation.

**Davies EG:** Immunodeficiency in DiGeorge syndrome and options for treating cases with complete athymia. *Front Immunol* 2013; 4:322.

**Jyonouchi H, et al:** SAPHO osteomyelitis and sarcoid dermatitis in a patient with DiGeorge syndrome. *Eur J Pediatr* 2006; 165:370.

**Selim MA, et al:** The cutaneous manifestations of atypical complete DiGeorge syndrome: a histopathologic and immunohistochemical study. *J Cutan Pathol* 2008; 35:380.

## Miscellaneous T-cell deficiencies and severe combined immunodeficiency

### IPEX syndrome

The immune dysregulation, polyendocrinopathy, enteropathy, X-linked (IPEX) syndrome is a rare disorder presenting neonatally with the classic triad of autoimmune enteropathy, endocrinopathy (diabetes, thyroiditis), and eczematous dermatitis. Elevated IgE levels, eosinophilia, and food allergies, plus the eczematous dermatitis, all are manifestations of Th2 skewing of the immune system. Patients present with diffuse and severe erythematous exudative plaques resembling AD. Secondary infection is common, and staphylococcal septicemia can occur. The skin eruption may be follicularly based or may lead to prurigo nodularis. The scalp develops hyperkeratotic psoriasiform plaques. Cheilitis and onychodystrophy can occur. Alopecia areata, chronic urticaria, and bullous

pemphigoid are cutaneous autoimmune manifestations of IPEX syndrome.

The IPEX syndrome is caused by mutations in *FOXP3* (forkhead box P3 protein), the master control gene for regulatory T-cell (Treg) development. IPEX like disease may also be caused by loss-of-function mutations in *CD25*, *STAT5b*, and *ITCH* and gain-of-function mutations in *STAT1* (signal transducer and activator of transcription 1). *FOXP3* is necessary for the development of Tregs, which are required to maintain immune homeostasis and mediate peripheral tolerance to “self” and nonself antigens. The enteropathy may be driven by autoantibodies to villin, and these autoantibodies can be used diagnostically. Treatment is immunomodulator therapy or bone marrow transplantation.

## Severe combined immunodeficiency

Severe combined immunodeficiency (SCID) is a heterogeneous group of genetic disorders characterized by severely impaired cellular and humoral immunity. Severe T-cell deficiency and low lymphocyte count are found in virtually all SCID patients. Candidiasis (moniliasis) of the oropharynx and skin, intractable diarrhea, and pneumonia are the triad of findings that usually lead to the diagnosis of SCID. In addition, severe recurrent infections may occur, caused by *Pseudomonas*, *Staphylococcus*, Enterobacteriaceae, or *Candida*. Overwhelming viral infections are the usual cause of death. Engraftment of maternally transmitted or transfusion-derived lymphocytes can lead to GVHD. The initial seborrheic dermatitis-like eruption may represent maternal engraftment GVHD. This cutaneous eruption may be asymptomatic but tends to generalize. More severe eczematous dermatitis and erythroderma may develop with alopecia. Cutaneous granulomas have been reported.

Deficiency or total absence of circulating T lymphocytes characterizes SCID. Immunoglobulin levels are consistently very low, but B-cell numbers may be reduced, normal, or increased. The thymus is very small; its malformed architecture at autopsy is pathognomonic.

The inheritance is either autosomal recessive or X-linked. Forty percent of SCID cases are X-linked and caused by deficiency of a common  $\gamma$ -chain that is an essential component of the IL-2 receptor. Twenty percent are caused by adenosine deaminase (ADA) deficiency and 6% from *Jak3* mutations.

Prenatal diagnosis and carrier detection are possible for many forms of SCID. The definitive treatment is hematopoietic stem cell transplantation (HSCT, bone marrow transplantation). This should ideally be carried out before age 3½ months for optimal outcome. The success rate approaches 90%. In utero HSCT has been successful in X-linked SCID. SCID patients rarely live longer than 2 years without transplantation. On average, 8 years after successful HSCT, SCID patients may develop severe human papilloma-virus (HPV) infection with common warts, flat warts, or even epidermodysplasia verruciformis. The development of HPV infections in SCID patients following HSCT is only seen in patients with either *Jak3* or  $\gamma$ -chain (gamma c) deficiency, but more than 50% of these patients may develop this complication.

## Miscellaneous Genetic Disorders of Cellular Immunity

The *TAP1* and *TAP2* gene deficiencies are extremely rare autosomal recessive disorders that result in severe reduction of MHC class I expression on the surface of cells. CD8 cells are decreased, but CD4 cells are normal, as are B-cell numbers and



serum immunoglobulins. Three forms of disease occur. The patient with the first phenotype develops severe bacterial, fungal, and parasitic infection and dies by age 3. The patient with the second phenotype is completely asymptomatic. The third group is the most common. Group 3 patients present in childhood with recurrent and chronic bacterial respiratory infections. These lead to bronchiectasis and eventually fatal respiratory failure in adulthood. The skin abnormalities appear in late childhood or more frequently in young adulthood (after age 15). Necrotizing granulomatous lesions appear as plaques or ulcerations on the lower legs and on the midface around the nose. The perinasal lesions are quite destructive and resemble “lethal midline granuloma” or Wegener’s granulomatosis. Nasal polyps with necrotizing granulomatous histology also occur. One patient also developed leukocytoclastic vasculitis.

The ZAP-70 ( $\zeta$ -chain [TCR]-associated protein kinase of 70 kD) deficiency is an autosomal recessive disorder of considerable heterogeneity. This enzyme is required for T-cell receptor (TCR) intracellular signaling. Patients present before age 2 years with recurrent bacterial, viral, and opportunistic infections, diarrhea, and failure to thrive. They have a lymphocytosis with normal CD4, NK, and B cells and decreased CD8 cells. Some patients develop an exfoliative erythroderma, eosinophilia, and elevated IgE levels.

Omenn syndrome (OMIM 603554; histiocytic medullary reticulosis) is a rare disorder that presents at birth or in the neonatal period. Classic Omenn was caused by defects in molecules involved in the variable diversity and joining V(D)J process. It is also caused by hypomorphic mutations in some of the genes that cause SCID. Both antibody production and cell-mediated immune function are impaired. Genetic mutations causing Omenn syndrome occur in *RAG1* and *RAG2* (90% of cases, classic Omenn), *DCLRE1C* (encoding ARTEMIS), *DNA-ligIV*, *IL7R $\alpha$* , *IL2R $\gamma$* , *CHD7*, *ADA*, and *RNRP*. These mutations all result in defective T-cell development and oligoclonal, abnormally activated T cells. Clinical features include severe exfoliative erythroderma, eosinophilia, alopecia, *Pneumocystis jirovecii* and viral pneumonias, colitis, hepatosplenomegaly, lymphadenopathy, hypogammaglobulinemia, and elevated IgE.

**De la Morena MT, Nelson RP Jr:** Recent advances in transplantation for primary immune deficiency diseases: a comprehensive review. *Clin Rev Allergy Immunol* 2014; 46:131.

**D’Hennezel E, et al:** The immunogenetics of immune dysregulation, polyendocrinopathy, enteropathy, X-linked (IPEX) syndrome. *J Med Genet* 2012; 49:291.

**Dvorak CC, et al:** The natural history of children with severe combined immunodeficiency: baseline features of the first fifty patients of the Primary Immune Deficiency Treatment Consortium prospective study 6901. *J Clin Immunol* 2013; 33:1156.

**Gadola SD, et al:** TAP deficiency syndrome. *Clin Exp Immunol* 2000; 121:173.

**Halabi-Tawil M, et al:** Cutaneous manifestations of immune dysregulation, polyendocrinopathy, enteropathy, X-linked (IPEX) syndrome. *Br J Dermatol* 2009; 160:645.

**Horino S, et al:** Selective expansion of donor-derived regulatory T cells after allogeneic bone marrow transplantation in a patient with IPEX syndrome. *Pediatr Transplant* 2014; 18:e25.

**Kelly BT, et al:** Screening for severe combined immunodeficiency in neonates. *Clin Epidemiol* 2013; 5:363.

**Kim VH, et al:** Emergency treatment for  $\zeta$  chain-associated protein of 70 kDa (ZAP70) deficiency. *J Allergy Clin Immunol* 2013; 131:1233.

**Lafort C, et al:** Severe cutaneous papillomavirus disease after haemopoietic stem-cell transplantation in patients with severe combined immune deficiency caused by common gamma c cytokine receptor subunit or JAK-3 deficiency. *Lancet* 2004; 363:2051.

**Lampasona V, et al:** Autoantibodies to harmonin and villin are diagnostic markers in children with IPEX syndrome. *PLoS One* 2013; 8:e78664.

**Lee PP, et al:** The many faces of ARTEMIS-deficient combined immunodeficiency: two patients with *DCLRE1C* mutations and a systematic literature review of genotype-phenotype correlation. *Clin Immunol* 2013; 149:464.

**Marrella V, et al:** Omenn syndrome does not live by V(D)J recombination alone. *Curr Opin Allergy Clin Immunol* 2011; 11:525.

**Moins-Teisserenc HT, et al:** Association of a syndrome resembling Wegener’s granulomatosis with low surface expression of HLA class-I molecules. *Lancet* 1999; 354:1598.

**Plebani A, et al:** Defective expression of HLA class I and CD1a molecules in boy with Marfan-like phenotype and deep skin ulcers. *J Am Acad Dermatol* 1996; 35:814.

**Shearer WT, et al:** Establishing diagnostic criteria for severe combined immunodeficiency disease (SCID), leaky SCID, and Omenn syndrome: the Primary Immune Deficiency Treatment Consortium experience. *J Allergy Clin Immunol* 2013; 133:1092.

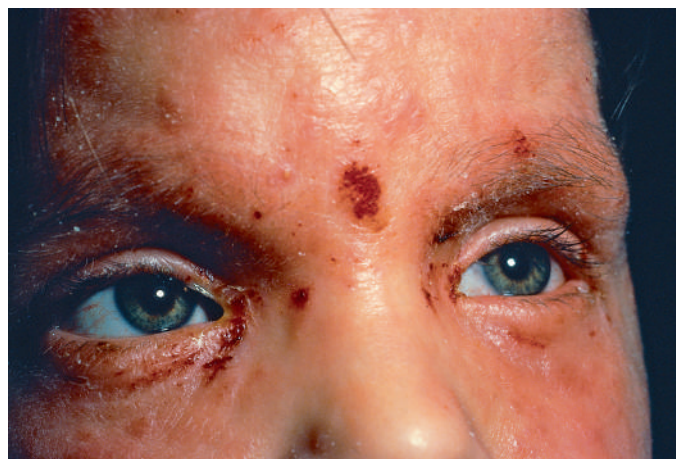
**Uzel G, et al:** Dominant gain-of-function *STAT1* mutations in *FOXp3* wild-type immune dysregulation–polyendocrinopathy–enteropathy–X-linked-like syndrome. *J Allergy Clin Immunol* 2013; 131:161.

**Verbsky JW, Chatila TA:** Immune dysregulation, polyendocrinopathy, enteropathy, X-linked (IPEX) and IPEX-related disorders: an evolving web of heritable autoimmune diseases. *Curr Opin Pediatr* 2013; 25:708.

## Wiskott-Aldrich syndrome

Wiskott-Aldrich syndrome, an X-linked recessive syndrome, consists of a triad of chronic eczematous dermatitis resembling AD (Fig. 5-16); increased susceptibility to bacterial infections, such as pyoderma or otitis media; and thrombocytopenic purpura with small platelets. Levels of IgM are variable, IgA is normal to high, and IgE is elevated, as is IgG. T cells (especially naïve T cells) are low in infancy and progressively decline in number and activity over time. Untreated survival is about 15 years, with death from infection, bleeding, or lymphoma (25% of patients).

The genetic cause of Wiskott-Aldrich syndrome is a mutation in the *WASP* gene. This gene codes for a protein called WASP, which is universally expressed in hematopoietic cells and is critical in the reorganization of the actin cytoskeleton in hematopoietic cells in response to external stimuli. The hematopoietic cells of affected patients cannot polarize or migrate in response to physiologic stimuli, accounting for the protean clinical features of the syndrome. Wiskott-Aldrich syndrome occurs when mutations in *WASP* lead to absence or truncation of the WASP protein (*WASP* – mutations). Mutations that result in normal length but some loss of function in the WASP protein (*WASP* + mutations) result in two different syndromes: X-linked thrombocytopenia (XLT) and intermittent X-linked



**Fig. 5-16** Eczematous eruption with purpura in Wiskott-Aldrich syndrome.

thrombocytopenia. Gain-of-function mutations in WASP cause X-linked neutropenia. Patients with XLT may also have an atopic-like dermatitis, but this is usually milder than the severe and difficult to control eczema affecting patients with the full Wiskott-Aldrich syndrome. WASP/XLT patients may also develop autoimmune disease, especially autoimmune hemolytic anemia, vasculitis, Henoch-Schönlein-like purpura, and IBD. High IgM is associated with the development of autoimmune disease.

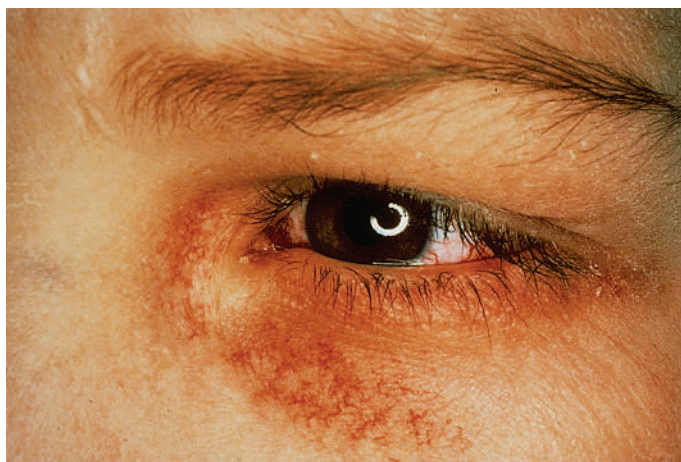Treatment is with platelet transfusions, antibiotics, and IVIG, if required. Often, splenectomy is performed to help control bleeding, but this leads to increased risk of sepsis and is not routinely recommended. Immunosuppressive therapy or rituximab may be used to control autoimmune complications. Bone marrow transplantation from a human leukocyte antigen (HLA)-identical sibling as early as possible in the disease course provides complete reversal of the platelet and immune dysfunction, as well as improvement or clearing of the eczematous dermatitis. Survival at 7 years with a matched sibling donor transplant approaches 90%.

**Massaad MJ, et al:** Wiskott-Aldrich syndrome: a comprehensive review. *Ann NY Acad Sci* 2013; 1285:26.

## Ataxia telangiectasia

Ataxia telangiectasia is an autosomal recessive condition caused by mutations in a single gene on chromosome 11 (*ATM*), which encodes a protein called ATM. This protein is critical in cell cycle control. When ATM is absent, the cell cycle does not stop to repair DNA damage, particularly double-stranded breaks, or for B(D)J recombination of immunoglobulin and TCR genes. This results in immunodeficiency and an increased risk for malignancy. The initial prominent skin feature is progressive ocular and cutaneous telangiectasias starting at age 3–6. These begin on the bulbar conjunctiva but later develop on the eyelids (Fig. 5-17), ears, and flexors of the arms and legs. Premature aging (with loss of subcutaneous fat and graying of hair) and progressive neurodegeneration also occur. The ATM protein seems to be important in maintaining mitochondrial homeostasis, and this defect may be responsible for the premature aging and neurodegeneration.

Cutaneous noninfectious granulomas may occur and can be ulcerative and painful. Other cutaneous features include large, irregular segmental café au lait spots, vitiligo, seborrheic dermatitis, AD, recurrent impetigo, and acanthosis nigricans. Late tightening of the skin can occur and resembles acral sclerosis.



**Fig. 5-17** Ataxia telangiectasia.

Sinopulmonary infections are common, especially otitis media, sinusitis, bronchitis, and pneumonia. Varicella (at times severe), herpes simplex, molluscum contagiosum, and herpes zoster can occur. Refractory warts occur in more than 5% of patients. Aside from candidal esophagitis, unusual opportunistic infections are rare. Childhood immunizations, including live viral vaccines, are well tolerated.

Lymphopenia is common, with reduction of both B and T cells occurring in the majority of patients. Th-cell counts can be below 200. IgA, IgG4, IgG2, and IgE deficiencies can all be present. Paradoxically, IgM, IgA, and IgG can be elevated in some patients, including the presence of monoclonal gammopathy in more than 10%. The immunologic abnormalities are not progressive. Lymphoma risk is increased more than 200-fold (especially B-cell lymphoma), and leukemia (especially T-cell chronic lymphocytic leukemia) is increased 70-fold. Treatment includes high vigilance for infection and malignancy. In patients with low CD4 counts, prophylaxis to prevent *Pneumocystis* pneumonia can be considered. When IgG deficiency is present and infections are frequent, IVIG may be beneficial. IVIG and intralesional corticosteroids may be used for the cutaneous granulomas. Carriers of ataxia telangiectasia have an increased risk for breast cancer. Because of the accumulation of chromosomal breaks after radiation exposure, both the ataxia telangiectasia patients and the carriers should minimize radiation exposure.

**Ambrose M, Gatti RA:** Pathogenesis of ataxia-telangiectasia: the next generation of ATM functions. *Blood* 2013; 121:4036.

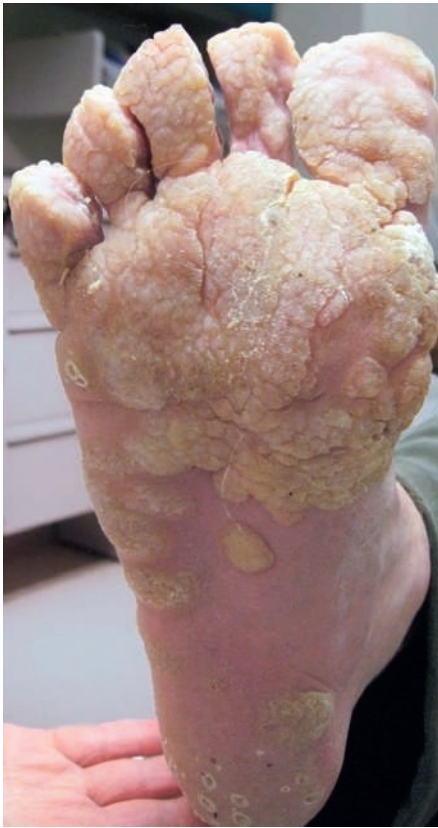## Primary immunodeficiency diseases associated with warts

Depressed T-cell function, either iatrogenic or genetic, is associated with an increased risk of HPV infection. However, a few PIDs are associated with a particular burden of HPV infection, and HPV infection may be an initial or prominent component of the syndrome.

## WHIM syndrome

The warts, hypogammaglobulinemia, infections, and myelokathexis (WHIM) syndrome is an autosomal dominant disorder with hypogammaglobulinemia, reduced B-cell numbers, and neutropenia. The most common genetic cause is a truncation mutation of *CXCR4*, which leads to gain of function in that gene. Additional mutations that are not in the *CXCR4* gene can also cause WHIM, but all of them lead to functional hyperactivity of *CXCR4*. *CXCR4* causes retention of neutrophils in the bone marrow and is the basis of the neutropenia and myelokathexis (increased apoptotic neutrophils in bone marrow). There is profound loss of circulating CD27+ memory B cells, resulting in hypogammaglobulinemia, with the observation that WHIM patients have normal antibody response to certain antigens but fail to maintain this antibody production. However, normal immunoglobulin levels do not exclude the diagnosis of WHIM. Almost 80% of WHIM patients have warts at the time of their diagnosis (Fig. 5-18). These include common and genital wart types. A significant number of female WHIM patients have cervical and vulval dysplasia, which can progress to carcinoma. WHIM patients have disproportionately more HPV infections than SCID patients but have little problem resolving other viral infections. However, they may develop Epstein-Barr virus (EBV)-induced lymphomas. The vast majority of patients in early childhood have recurrent sinopulmonary infections, skin infections, osteomyelitis, and urinary tract infections. Recurrent pneumonias lead to bronchiectasis. Treatment is G-CSF, IVIG, prophylactic antibiotics,





**Fig. 5-18** Warts in WHIM syndrome.

and aggressive treatment of infections. The HPV infections can progress to fatal carcinomas, and therefore male patients must be regularly examined by dermatologists and female patients by gynecologists; a low threshold for biopsy of genital lesions is required.

### DOCK8 deficiency

Deficiency in DOCK8 (dedicator of cytokinesis 8) are associated with hyper-IgE syndrome. However, unlike other genetic causes of hyper-IgE, DOCK8 deficiency is uniquely associated with a susceptibility to cutaneous viral infections, including HSV, molluscum contagiosum, and HPV. Warts can be flat or verrucous and affect about two thirds of patients.

### GATA2 deficiency

GATA2 is an important transcription factor involved in hematopoiesis maintenance of the stem cell compartment. GATA2 deficiency leads to a constellation of syndromes characterized by myelodysplasia, opportunistic infections, and leukemia. Patients have profound monocytopenia, often neutropenia, and NK, B, and dendritic cell lymphocytopenia. T-cell counts are variable. More than 75% of patients have severe or disseminated HPV infection, usually verruca plana or verruca vulgaris, and it is the first manifestation in the majority of patients, usually in adolescence or early adulthood. Severe cervical HPV infection can also occur and may lead to cancer. Thirty percent of patients develop a corticosteroid-responsive panniculitis. Venous thrombosis occurs in 25% and lymphedema in 11% of patients. Allogeneic hematopoietic stem cell transplantation seems to be curative.

### WILD syndrome

The warts, immunodeficiency, lymphedema, and dysplasia (WILD) syndrome is rare and presents at age 6 months with lower extremity lymphedema that is progressive and later

may involve the upper extremities and groin. Warts begin in adolescence and result in anogenital dysplasia and cancer. Patients also have T-cell and B-cell lymphopenia. This may represent a GATA2 mutation syndrome.

**Dotta L, et al:** Clinical and genetic features of warts, hypogammaglobulinemia, infections and myelokathexis (WHIM) syndrome. *Curr Mol Med* 2011; 11:317.

**Kreuter A, et al:** A human papillomavirus-associated disease with disseminated warts, depressed cell-mediated immunity, primary lymphedema, and anogenital dysplasia. *Arch Dermatol* 2008; 144:366.

**Leiding JW, et al:** Warts and all: HPV in primary immunodeficiencies. *J Allergy Clin Immunol* 2012; 130:1030.

**Mansour S, et al:** Emberger syndrome: primary lymphedema with myelodysplasia—report of seven new cases. *Am J Med Genet* 2010; 152A:2287.

**Minegishi Y, Saito M:** Cutaneous manifestations of hyper-IgE syndrome. *Allergol Int* 2012; 61:191.

**Pasquete M, et al:** High frequency of GATA2 mutations in patients with mild chronic neutropenia, evolving to monomac syndrome, myelodysplasia, and acute myeloid leukemia. *Blood* 2013; 121:822.

**Sanal O, et al:** Additional diverse findings expand the clinical presentation of DOCK8 deficiency. *J Clin Immunol* 2012; 32:698.

**Spinner MA, et al:** GATA2 deficiency: a protean disorder of hematopoiesis, lymphatics and immunity. *Blood* 2014; 123:809.

## Defects of phagocyte number, function, or both

### Chronic granulomatous disease

Chronic granulomatous disease (CGD) is a rare disorder caused by mutations in one of the genes that encode the subunits of the superoxide-generating phagocyte NADPH oxidase system responsible for the respiratory burst involved in organism killing. CGD is characterized by repeated and recurrent bacterial and fungal infections of the lungs, skin, lymph nodes, and bones. Gingivostomatitis (aphthouslike ulcerations) and a seborrheic dermatitis of the periauricular, perinasal, and perianal area are characteristic. The dermatitis is frequently infected with *Staphylococcus aureus*, and regional adenopathy and abscesses may complicate the infections. The term “suppurative dermatitis” is used in the immunology literature to describe this seborrheic-like dermatitis with secondary infection, analogous to the “infective dermatitis” seen in human T-cell lymphotropic virus (HTLV)-1 infection. In addition to *S. aureus*, *Serratia* species are often isolated from skin abscesses and osteomyelitis. *Aspergillus* is the most common agent causing pneumonia in CGD patients. In tuberculosis-endemic areas, CGD patients frequently develop active tuberculosis or prolonged scarring, abscesses, or disseminated infection following bacille Calmette-Guérin (BCG) immunization.

There are four types of CGD, one X-linked and three autosomal recessive. The X-linked form is the most common (65–75% of CGD patients) and is caused by a mutation in the *CYBB* gene, which leads to absence of the high-molecular-weight subunit of cytochrome *b* 558 (gp 91-phox) and a total absence of NADPH oxidase activity. In autosomal recessive forms, mutations in the genes encoding for the remaining three oxidase components have been described: p22-phox (*CYBA*), p47-phox (*NCF1*), and p67-phox (*NCF2*). One patient with a mutation in p40-phox (*NCF4*) has been described. The X-linked variant has the most severe phenotype. Compared with the autosomal recessive CGD patients, the X-linked patients present at an earlier age (14 vs. 30 months) and are diagnosed at an earlier age (3–5 vs. 6–13 years). The lack of superoxide generation apparently causes disease, not because the bacteria are not being killed by the superoxide, but because the superoxide is required to activate proteases in phagocytic vacuoles that are needed to kill infectious organisms.

Granuloma formation is characteristic of CGD and can occur in the GI tract, liver, bladder, bone, and lymph nodes. Up to 40% of biopsies from these organs will demonstrate granulomas, at times with identifiable fungal or mycobacterial organisms. These patients are often receiving prophylactic antibiotics, however, so organisms are frequently not found. Subcorneal pustular eruptions can also be seen in CGD patients. In the intestinal tract, an IBD like process occurs, with granulomas in the colon. This can cause significant GI symptoms.

The diagnosis of CGD is made by demonstrating low reduction of yellow nitroblue tetrazolium (NBT) to blue formazan in the "NBT test." Dihydrorhodamine 123 flow cytometry (DHR), chemiluminescence production, and the ferricytochrome *c* reduction assay are also confirmatory. Western blot analysis for NADPH oxidase expression and DNA sequencing can pinpoint the genetic mutation.

Female carriers of the X-linked form of CGD have a mixed population of normal and abnormal phagocytes and therefore show intermediate NBT reduction and two discrete populations with DHR testing. The majority of carriers have skin complaints. Raynaud phenomenon can occur. More than half will report a photosensitive dermatitis, 40% have oral ulcerations, and a third have joint complaints. Skin lesions in carriers have been described as discoid lupus erythematosus (DLE)-like, but histologically, the interface component is often absent, and the lesions resemble tumid lupus. Direct immunofluorescence examination is usually negative, as is common in tumid lupus erythematosus (LE). Less frequently, CGD patients themselves have been described as having similar LE like lesions, or "arcuate dermal erythema." Despite these findings, the vast majority of patients with LE like skin lesions, both carriers and CGD patients, are antinuclear antibody (ANA) negative.

Treatment of infections should be early and aggressive. There should be a low threshold to biopsy skin lesions, as they may reveal important and potentially life-threatening infections. Patients usually receive chronic TMP-SMX prophylaxis, chronic oral itraconazole or another anti-*Aspergillus* agent, and IFN- $\gamma$  injections. Bone marrow or stem cell transplantation has been successful in restoring enzyme function, reducing infections, and improving the associated bowel disease. However, survival is *not* increased with bone marrow transplantation, so this is not routinely undertaken.

**Cale CM, et al:** Cutaneous and other lupus-like symptoms in carriers of X-linked chronic granulomatous disease: incidence and autoimmune serology. *Clin Exp Immunol* 2007; 148:79.

**Gallin JI, et al:** Itraconazole to prevent fungal infections in chronic granulomatous disease. *N Engl J Med* 2003; 348:2416.

**Lee PP, et al:** Susceptibility to mycobacterial infections in children with X-linked chronic granulomatous disease: a review of 17 patients living in a region endemic for tuberculosis. *Pediatr Infect Dis J* 2008; 27:224.

**Leiding JW, Holland SM:** Chronic granulomatous disease. In Pagon RA, et al (eds): *GeneReviews* 2012 [Internet].

**Levine S, et al:** Histopathological features of chronic granulomatous disease (CGD) in childhood. *Histopathology* 2005; 47:508.

**Luis-Montoya P, et al:** Chronic granulomatous disease: two members of a single family with different dermatologic manifestations. *Skinmed* 2005; 4:320.

**Raptaki M, et al:** Chronic granulomatous disease: a 25-year patient registry based on a multistep diagnostic procedure, from the referral center for primary immunodeficiencies in Greece. *J Clin Immunol* 2013; 33:1302.

## Leukocyte adhesion deficiency

This rare autosomal recessive disorder has three types. Leukocyte adhesion deficiency (LAD) type I is caused by a mutation in the common chain (CD18) of the  $\beta$ 2-integrin family (*ITGB2*). It is characterized by recurrent bacterial infections of the skin

and mucosal surfaces, especially gingivitis and periodontitis. Skin ulcerations from infection may continue to expand. Cellulitis and necrotic abscesses, especially in the perirectal area, can occur. Minor injuries may lead to pyoderma gangrenosum-like ulcerations that heal slowly. Infections begin at birth, and omphalitis with delayed separation of the cord is characteristic. Neutrophilia is marked, usually 5–20 times normal, and the count may reach up to 100,000 during infections. Despite this, there is an absence of neutrophils at the sites of infection, demonstrating the defective migration of neutrophils in these patients. LAD type I patients are affected either severely (<1% of normal CD18 expression) or moderately (2.5–10% of normal expression.) Patients with moderate disease have less severe infections and survive into adulthood, whereas patients with severe disease often die in infancy.

LAD type II is caused by a mutation in *SLC35C1*, which results in a general defect in fucose metabolism which results in decreased fucosylation of selectin ligands on leukocytes. This leads to impaired tethering and rolling on activated endothelial cells. Severe mental retardation, short stature, a distinctive facies, and the rare hh blood phenotype are the features. Initially, these patients have recurrent cellulitis with marked neutrophilia, but the infections are not life threatening. After age 3 years, infections become less of a problem and patients develop chronic periodontitis.

LAD type III is caused by a mutation in the gene *FERMT3* and is characterized by severe recurrent infections, bleeding tendency (from impaired platelet function), and marked neutrophilia.

Bone marrow transplantation is required for patients with severe LAD type I and LAD type III.

**Dababneh R, et al:** Periodontal manifestation of leukocyte adhesion deficiency type I. *J Periodontol* 2008; 79:764.

**Etzioni A:** Leukocyte adhesion deficiencies: molecular basis, clinical findings, and therapeutic options. *Adv Exp Med Biol* 2007; 601:51.

**Harris ES et al:** Lessons from rare maladies: leukocyte adhesion deficiency syndromes. *Curr Opin Hematol* 2013; 20:16.

**Mellouli F, et al:** Successful treatment of *Fusarium solani* ecthyma gangrenosum in a patient affected by leukocyte adhesion deficiency type 1 with granulocytes transfusions. *BMC Dermatology* 2010; 10:10.

**Parvaneh N, et al:** Characterization of 11 new cases of leukocyte adhesion deficiency type 1 with seven novel mutations in the *ITGB2* gene. *J Clin Immunol* 2010; 30:756.

**Qasim W, et al:** Allogeneic hematopoietic stem-cell transplantation for leukocyte adhesion deficiency. *Pediatrics* 2009; 123:836.

**Simpson BN, et al:** A new leukocyte hyperadhesion syndrome of delayed cord separation, skin infection, and nephrosis. *Pediatrics* 2014; 133:e257.

**Svensson L, et al:** Leukocyte adhesion deficiency-III is caused by mutations in *KINDLIN3* affecting integrin activation. *Nat Med* 2009; 15:306.

## Hyperimmunoglobulinemia E syndrome

There are at least three defined mutations that cause hyperimmunoglobulinemia E syndrome (HIES; also called hyper-IgE syndrome). The autosomal dominant form is caused by a mutation in *STAT3*, and the autosomal recessive form by mutations in *DOCK8* and rarely in tyrosine kinase 2 (*TYK2*). The two autosomal forms of HIES are clinically somewhat different and are described separately.

Autosomal dominant HIES was first called Job's syndrome or Buckley's syndrome. The classic triad is an AD like eczematous dermatitis, recurrent skin and lung infections, and high serum IgE. The skin disease is the first manifestation of *STAT3* deficiency and begins at birth in 19% of cases, within the first week of life in more than 50%, and in the first month in 80%. The initial eruption is noted first on the face or scalp, but quickly generalizes to affect the face, scalp, and body. The rash



favors the shoulder, arms, chest, and buttocks. The newborn rash begins as pink papules that may initially be diagnosed as “neonatal acne.” The papules develop quickly into pustules, then coalesce into crusted plaques. Histologically, these papules are intraepidermal eosinophilic pustules. The dermatitis evolves to bear a close resemblance to AD, often very severe, and occurs in 100% of autosomal dominant HIES patients. Staphylococcal infection of the dermatitis is common, and treatment of the staphylococcal infection with antibiotics and bleach baths leads to improvement. IgE levels are above 2000 in 95% of patients with autosomal dominant HIES, but since only about 8% of children with IgE levels above 2000 actually have HIES, other features must be used to confirm the diagnosis. Abscesses, sometimes cold, are characteristic. Recurrent pyogenic pneumonia is the rule, starting in childhood. Because of the lack of neutrophilic inflammation in the pneumonia, symptoms may be lacking and lead to a delay in diagnosis. Although antibiotic treatment clears the pneumonia, healing is abnormal, with the formation of bronchiectasis and pneumatoceles, a characteristic feature of HIES. Mucocutaneous candidiasis is common, typically thrush, vaginal candidiasis, and candida onychomycosis. Musculoskeletal abnormalities are common, including scoliosis, osteopenia, minimal trauma fractures (55%), and hyperextensibility, leading to premature degenerative joint disease. Retention of some or all of the primary teeth is a characteristic feature. Other oral manifestations include median rhomboid glossitis, high-arch palate, and abnormally prominent wrinkles on the oral mucosa. Arterial aneurysms are common, including Chiari 1 malformation (40%) and coronary vascular abnormalities (60%). The latter can cause myocardial infarction. Autosomal dominant HIES patients have a characteristic facies, developing during childhood and adolescence. Features include facial asymmetry, broad nose, deep-set eyes, and a prominent forehead. The facial skin is rough, with large pores. There is an increased risk of malignancy, predominantly B-cell non-Hodgkin lymphoma. Laboratory abnormalities are limited to eosinophilia and an elevated IgE. In adults, IgE levels may become normal. Th17 cells are lacking from the peripheral blood of *STAT3* mutation patients. A scoring system developed at the National Institutes of Health (NIH) can accurately identify patients with HIES, selecting those in whom genetic testing could be considered.

Autosomal recessive HIES is much less common. These patients also have severe eczema and recurrent skin and lung infections, although the lung infections resolve without pneumatoceles. Food allergies are often present in autosomal recessive HIES caused by *DOCK8* mutation, as is decreased IgM. These patients are predisposed to cutaneous viral infections, especially warts, molluscum contagiosum, herpes simplex, and varicella-zoster. They also develop mucocutaneous candidiasis. Neurologic disease is much more common in autosomal recessive HIES, ranging from facial paralysis to hemiplegia. Autosomal recessive HIES patients have normal facies, no fractures, and normal shedding of primary dentition, but a dramatic increase in malignancy, especially leukemia.

Treatment for HIES is currently traditional. Infections are suppressed with bleach baths and chronic antibiotic prophylaxis (usually with TMP-SMX); antifungal agents may be used for candidal infections of the skin and nails. Topical anti-inflammatories are used to manage the eczema, and in severe cases, cyclosporine can be considered. Bisphosphonates are used for osteopenia. The role of IVIG, antihistamines, and omalizumab (antibody against IgE) is unknown. In patients with autosomal recessive HIES, hematopoietic cell transplantation (HCT) is recommended because of the high risk of malignancy and CNS infarction. Autosomal dominant HIES patients with malignancy should be considered for HCT, since

it can reverse the HIES, reducing the infectious complications following HCT.

**Eberling CL, et al:** Dermatitis and the newborn rash of hyper-IgE syndrome. *Arch Dermatol* 2004; 140:1119.

**Freeman AF, et al:** Hyper IgE (Job's) syndrome: a primary immune deficiency with oral manifestations. *Oral Dis* 2009; 15:2.

**Ling JC, et al:** Coronary artery aneurysms in patients with hyper IgE recurrent infection syndrome. *Clin Immunol* 2007; 122:255.

**Mogensen TH, et al:** *STAT3* and the hyper-IgE syndrome: clinical presentation, genetic origin, pathogenesis, novel findings and remaining uncertainties. *JAK-STAT* 2013; 2e23435.

**Rael EL, et al:** The hyper-IgE syndromes: lessons in nature, from bench to bedside. *World Allergy Organ J* 2012; 5:79.

**Woellner C, et al:** Mutations in *STAT3* and diagnostic guidelines for hyper-IgE syndrome. *J Allergy Clin Immunol* 2010; 125:424.

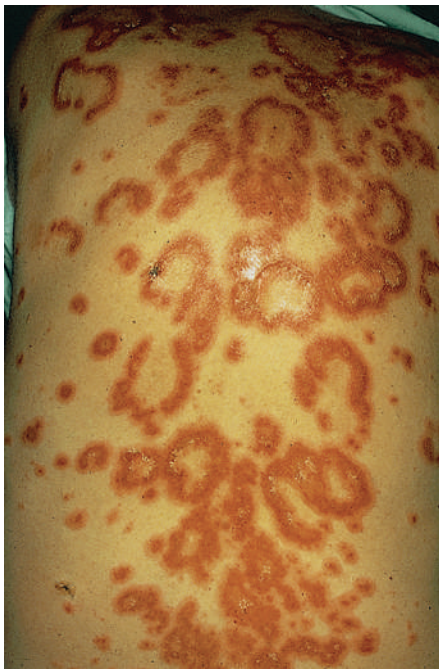**Yong PF, et al:** An update on the hyper-IgE syndromes. *Arthritis Res Ther* 2012; 14:228.

## Complement deficiency

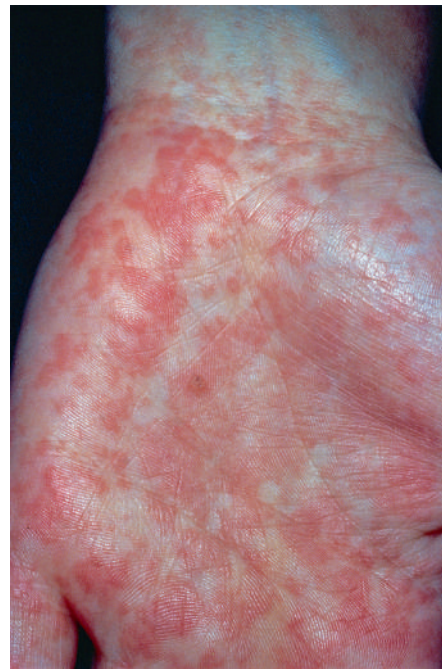The complement system is an effector pathway of proteins that results in membrane damage and chemotactic activity. Four major functions result from complement activation: cell lysis, opsonization/phagocytosis, inflammation, and immune complex removal. In the “classical” complement pathway, complement is activated by an antigen-antibody reaction involving IgG or IgM. Some complement components are directly activated by binding to the surface of infectious organisms; this is called the “alternate” pathway. The central component common to both pathways is C3. In the classical pathway, antigen-antibody complexes sequentially bind and activate three complement proteins, C1, C4, and C2, leading to the formation of C3 convertase, an activator of C3. The alternate pathway starts with direct activation of C3. From activated C3, C5–C9 are sequentially activated. Cytolysis is induced mainly through the membrane attack complex (MAC), which is made up of the terminal components of complement. Opsonization is mainly mediated by a subunit of C3b, and inflammation by subunits of C3, C4, and C5.

Inherited deficiencies of complement are usually autosomal recessive traits. Deficiencies of all 11 components of the classical pathway, as well as inhibitors of this pathway, have been described. Genetic deficiency of the C1 inhibitor is the only autosomal dominant form of complement deficiency and results in hereditary angioedema (see Chapter 7). In general, deficiencies of the early components of the classical pathway result in connective tissue disease states, whereas deficiencies of the late components of complement lead to recurrent neisserial sepsis or meningitis. Overlap exists, and patients with late-component deficiencies may exhibit connective tissue disease, and patients with deficiencies of early components, such as C1q, may manifest infections. Deficiency of C3 results in recurrent infections with encapsulated bacteria such as *Pneumococcus*, *Haemophilus influenzae*, and *Streptococcus pyogenes*. C3 inactivator deficiency, as with C3 deficiency, results in recurrent pyogenic infections. Properdin (component of alternate pathway) dysfunction is inherited as an X-linked trait and predisposes to fulminant meningococcemia. Deficiency of C9 is the most common complement deficiency in Japan but is uncommon in other countries. Most patients appear healthy. MASP2 deficiency, resulting in absent hemolytic activity by the lectin pathway, is considered a complement deficiency and results in a syndrome resembling SLE and increased pyogenic infection. Factor I deficiency results in recurrent infections, including *Neisseria meningitidis*. Partially deficient family members may also have increased infections.

C2 deficiency is the most common complement deficiency in the United States and Europe. Most patients are healthy, but



**Fig. 5-19** Annular subacute cutaneous lupus erythematosus (SACLE) lesions that characterize C2 deficiency.



**Fig. 5-20** Acute graft-versus-host disease.

SLE like syndromes develop in 10%, Frequent infections, anaphylactoid purpura, dermatomyositis, vasculitis, and cold urticaria may be seen. C1q-, C3-, and C4-deficient patients have SLE at rates of 90%, 31%, and 75%, respectively. Complement deficiency-associated SLE typically has early onset, photosensitivity, less renal disease, and Ro/La autoantibodies in two thirds of patients. C2- and C4-deficient patients with LE typically have subacute annular morphology (Fig. 5-19), Sjögren syndrome, arthralgias, and oral ulcerations. Renal disease, anti-dsDNA antibodies, and anticardiolipin antibodies are uncommon. Patients with C4 deficiency may have lupus and involvement of the palms and soles.

Many of the complement component deficiencies can be acquired as an autoimmune phenomenon or a paraneoplastic finding. Examples include acquired angioedema, as when C1 inhibitor is the target, or lipodystrophy and nephritis, when C3 convertase is the target.

When complement deficiency is suspected, a useful screening test is a CH50 (total hemolytic complement) determination, because deficiency of any of the complement components will usually result in CH50 levels that are dramatically reduced or zero.

**Kosaka S, et al:** Cutaneous vasculitic and glomerulonephritis associated with C4 deficiency. *Clin Exp Dermatol* 2013; 38:492.

**Lipsker D, Hauptmann G:** Cutaneous manifestations of complement deficiencies. *Lupus* 2010; 19:1096.

**Sozeri B, et al:** Complement-4 deficiency in a child with systemic lupus erythematosus presenting with standard treatment-resistant severe skin lesion. *ISRN Rheumatol* 2011; 2011:917673.

**Tichaczek-Goska D:** Deficiencies and excessive human complement system activation in disorders of multifarious etiology. *Adv Clin Exp Med* 2012; 21:105.

## Graft-versus-host disease

Graft-versus-host disease (GVHD) occurs most frequently in the setting of HSCT but may also occur following organ transplantation or in the rare situation of transfusion of active lymphoid cells into an immunodeficient child postpartum or even in utero. Blood transfusions with active lymphocytes (nonradiated whole blood) from family members or in populations with minimal genetic variability, given to an immunodeficient

patient, can result in GVHD. HSCT from a monozygotic twin (syngeneic) or even from the patient's own stem cells (autologous) can induce a mild form of GVHD.

Development of GVHD requires three elements. First, the transplanted cells must be immunologically competent. Second, the recipient must express tissue antigens that are not present in the donor and therefore are recognized as foreign. Third, the recipient must be unable to reject the transplanted cells. Immunologic competence of the transplanted cells is important, because ablating them too much may lead to failure of engraftment, or more often, incomplete eradication of the recipient's malignancy (graft vs. tumor effect). Therefore, some degree of immunologic competence of the transplanted cells is desired. For this reason, the prevalence of GVHD still remains about 50% after HSCT. Another important factor in determining the development and severity of the GVHD is the preconditioning regimen. Chemotherapy and radiation cause activation of dendritic cells (antigen-presenting cells, APCs) in tissues with high cell turnover – the skin, gut, and liver. These APCs increase their expression of HLA and other minor cell surface antigens, priming them to interact with transplanted lymphoid cells. Host APCs are important in presenting these antigens to the active lymphoid donor cells. Cytokines, especially IL-2, TNF- $\alpha$ , and IFN- $\gamma$ , are important in enhancing this host-donor immunologic interaction. Reducing this early inflammatory component in GVHD can delay the onset of the GVHD but may not reduce the prevalence. The indications for HSCT, age limits, and allowable degree of HLA incompatibility have resulted in greater use of HSCT, increasing the number of persons at risk for GVHD.

Initially, only reactions that occurred within the first 100 days after transplantation were considered acute GVHD, but it is now recognized that classic acute GVHD can occur up to 1 year or more after HSCT, especially with tapering of anti-GVHD immunosuppressives. Acute GVHD is based on the clinical presentation, *not* the duration following transplantation. In acute GVHD, the cutaneous eruption typically begins between the 14th and 42nd days after transplantation, with a peak at day 30 (Fig. 5-20). Acute GVHD is characterized by an erythematous morbilliform eruption of the face and trunk, which may become confluent and result in exfoliative erythroderma. It often begins with punctate lesions corresponding



to hair follicles and eccrine ducts, resembling keratosis pilaris. Even when morbilliform, darker punctate areas are a helpful clinical sign. In children, the diaper area is often involved. The eruption may appear papular and eczematous, involving web spaces, periumbilical skin, and ears. The appearance bears some resemblance to scabies.

The differential diagnosis for the eruption of acute GVHD includes the eruption of lymphocyte recovery, engraftment syndrome, viral exanthem, and drug eruption. The cutaneous histology in the early phases of acute GVHD may not be able to distinguish these entities. Grade IV GVHD is characterized by full-thickness slough and may resemble toxic epidermal necrolysis. The mucous membranes and the conjunctivae can be involved as well, which can be difficult to distinguish from chemotherapy-induced and infectious mucositis. Often, about the same time, the patient develops the other characteristic features of acute GVHD: cholestatic hepatitis with elevated bilirubin and high-volume diarrhea. Syngeneic/autologous GVHD usually involves only the skin and is self-limited. The preconditioning regimens are thought to result in loss of "self-tolerance."

Engraftment syndrome is a combination of symptoms that occur about the time of engraftment and neutrophil recovery. Patients develop fever (without infectious source), diarrhea, pulmonary infiltrates with hypoxia, and capillary leak syndrome with edema and weight gain. It occurs as soon as 7 days after autologous HSCT and 11–16 days after allogeneic transplants. The associated skin eruption is clinically and histologically identical to acute GVHD, but at presentation it is usually diagnosed as a "drug eruption," and antibiotic therapy is frequently changed. Ocular involvement with keratitis can occur. This syndrome occurs in 7–59% of post-HSCT patients and is a significant cause of morbidity and mortality in autologous peripheral blood progenitor cell transplant patients. In one series, engraftment syndrome accounted for 45% of all transplant-related mortality. It is mediated by cytokine production and neutrophil infiltration of the organs damaged by the conditioning chemotherapy, especially the lungs. Administration of G-CSF and autologous transplantation are risk factors for its development. The relationship of engraftment syndrome to eruption of lymphocyte recovery is unclear. Treatment is high-dose systemic corticosteroids.

With improved support for GVHD patients after HSCT, more are surviving, and 60–70% develop chronic disease (cGVHD). It is the second most common cause of death in HSCT patients. It is unclear whether cGVHD is mediated by the same pathologic mechanisms as acute GVHD. Chronic disease has features more typical of an autoimmune disease. Diagnostic criteria have been adopted, with "diagnostic" and "distinctive" cutaneous manifestations. The most common diagnostic feature, occurring in 80% of patients who develop cGVHD, is a lichen planus like eruption. It typically occurs 3–5 months after grafting, usually beginning on the hands and feet but becoming generalized. It may present with a malar rash resembling LE. The chronic interface dermatitis can leave the skin with a poikilodermatous appearance. Similar lichen planus like lesions may occur on the oral mucosa and can result in pain and poor nutrition. Lichen sclerosus like lesions can also occur. Involvement of the vaginal or esophageal mucosa can result in severe scarring and strictures. About 20% of men with cGVHD have genital skin changes, and 13% have cGVHD of the penis. cGVHD of the skin and oral mucosa is associated with genital involvement. LS-like lesions, phimosis, and inflammatory balanitis are most common; 80% of men with penile cGVHD report erectile dysfunction.

Sclerosis is the other "diagnostic" family of skin lesions. This can include lesions resembling superficial morphea, which can have overlying lichen sclerosus like changes. The morphea-like

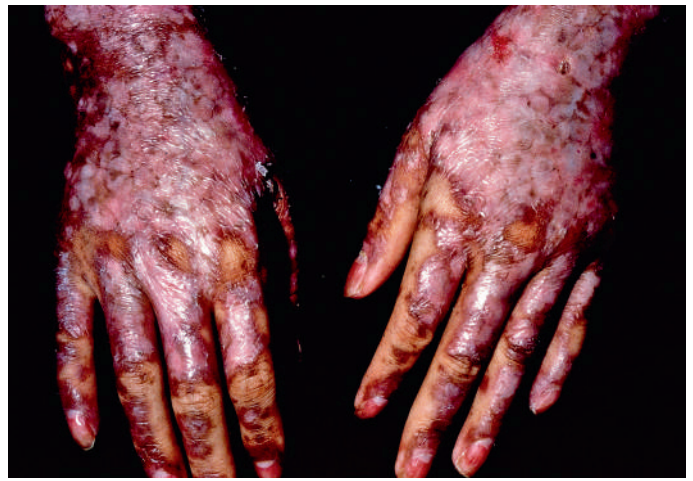

Fig. 5-21 Chronic graft-versus-host disease.

lesions demonstrate an isomorphic response, favoring areas of pressure, especially the waistband and brassiere-band areas. Deeper sclerotic lesions resembling eosinophilic fasciitis (resulting in joint contractures, Fig. 5-21) and restriction of the oral commissure due to sclerosis can occur. These sclerotic plaques may ulcerate, especially during PUVA therapy. The extent of involvement of the deep tissues, such as muscle and fascia, cannot be easily defined by clinical examination and may be aided by magnetic resonance imaging (MRI). Rarely, the myositis of cGVHD may be accompanied by a skin eruption similar to dermatomyositis.

The "distinctive" features of GVHD include depigmentation resembling vitiligo; scarring or nonscarring alopecia; nail dystrophy (e.g., longitudinal ridging, brittle thin nails, pterygium, nail loss); and xerostomia and other, Sjögren like mucosal symptoms.

Histologically, acute GVHD demonstrates vacuolar interface dermatitis. Individual keratinocyte necrosis with adjacent lymphocytes (satellite necrosis) is typically present, suggesting cell-mediated cytotoxicity. The extent of necrosis, bulla formation, and slough is used in grading schemes. In early acute GVHD, the findings may be focal and restricted to hair follicles and sweat ducts. The histologic findings in early disease may be nonspecific, and many treatment protocols do not depend on histologic features to initiate therapy. A background of epidermal disorder and atypia resembling Bowenoid actinic keratosis is almost universally present in later lesions of acute GVHD and is a helpful diagnostic feature. Similar epidermal changes may be seen with cancer chemotherapy, especially in acral erythema or after busulfan. Chronic GVHD demonstrates lichenoid dermatitis or dermal sclerosis with hyalinization of collagen bundles and narrowing of the space between bundles.

Prevention of posttransfusion GVHD is most safely achieved by irradiating the blood before transfusion in high-risk individuals. Acute GVHD is managed on the skin with topical corticosteroids, TCIs, and UV phototherapy. When systemic symptoms appear, a glucocorticoid, cyclosporine, or tacrolimus is instituted. Extracorporeal photopheresis can be considered in patients with acute or chronic GVHD unresponsive to these first-line therapies. Bath PUVA, with or without isotretinoin, can improve sclerotic cGVHD. Blocking the cytokine storm with monoclonal antibodies such as etanercept or infliximab was initially promising but since has been associated with invasive fungal infections. Rituximab, by targeting B cells, has shown some benefit in steroid-refractory cGVHD. Sirolimus and everolimus appear to have activity against fibrosis and may be useful in fibrotic cGVHD. Imatinib may

also be useful in cGVHD with fibrosis by inhibiting platelet-derived growth factor receptor (PDGFR). Mesenchymal stem cells have been reported to be effective in patients with refractory acute or chronic GVHD without discernible adverse effects.

## GVHD in solid-organ transplantation

Transplantation of a solid organ into a partially immunosuppressed host may result in GVHD, because the organ may contain immune cells. The prevalence of GVHD after solid-organ transplantation is extremely low, about 1% at one center over 15 years with more than 2000 transplants. The risk for developing GVHD after solid-organ transplantation is related to the type of organ transplanted and depends on the amount of lymphoid tissue that the organ contains. The risk profile is small intestine > liver/pancreas > kidney > heart. In liver and small intestine transplants, the risk is 1–2%, but when it occurs, mortality is 85%. Close matching increases the risk of GVHD in organ transplantation, because the immunocompetent recipient cells are less likely to recognize the donor lymphocytes as nonself and destroy them. Also, African American race and cytomegalovirus (CMV) infection increase the risk. The onset is usually 1–8 weeks following transplantation but can be delayed for years. Fever, rash, and pancytopenia are the cardinal features. The skin is the first site of involvement, and only cutaneous disease occurs in 15% of cases. Both acute and chronic GVHD skin findings can occur. Skin biopsies tend to show more inflammation than in HSCT-associated GVHD. In GVHD accompanying liver transplantation, the liver is unaffected because it is syngeneic with the donor lymphocytes. In these patients, pancytopenia can occur and is a frequent cause of mortality. The diagnosis of GVHD in patients receiving organ transplantation can be aided by documenting

macrochimerism in the peripheral blood and skin after the first month of transplantation.

**Byun HJ, et al:** Clinical differentiation of acute cutaneous graft-versus-host disease from drug hypersensitivity reactions. *J Am Acad Dermatol* 2011; 65:726.

**Hymes SR, et al:** Graft-versus-host disease. Part I. Pathogenesis and clinical manifestations of graft-versus-host disease. *J Am Acad Dermatol* 2012; 66:515e1.

**Hymes SR, et al:** Graft-versus-host disease. Part II. Management of cutaneous graft-versus-host disease. *J Am Acad Dermatol* 2012; 66:535e1.

**Mueller SM, et al:** Genital chronic GVHD in men after hematopoietic stem cell transplantation: a single-center cross-sectional analysis of 155 patients. *Biol Blood Marrow Transplant* 2013; 19:1574.

**Sharma A, et al:** Graft-versus-host disease after solid organ transplantation: a single center experience and review of literature. *Ann Transplant* 2012; 17:133.

**Zieler M, et al:** Histopathological diagnosis of graft-versus-host disease of the skin: an interobserver comparison. *J Eur Acad Dermatol Venereol* 2014; 28:915.



Bonus images for this chapter can be found online at

[expertconsult.inkling.com](http://expertconsult.inkling.com)

**eFig. 5-1** Dennie-Morgan folds (or Morgan folds).

**eFig. 5-2** Nasal crease.

**eFig. 5-3** Pityriasis alba.

**eFig. 5-4** Hyperkeratotic hand dermatitis.

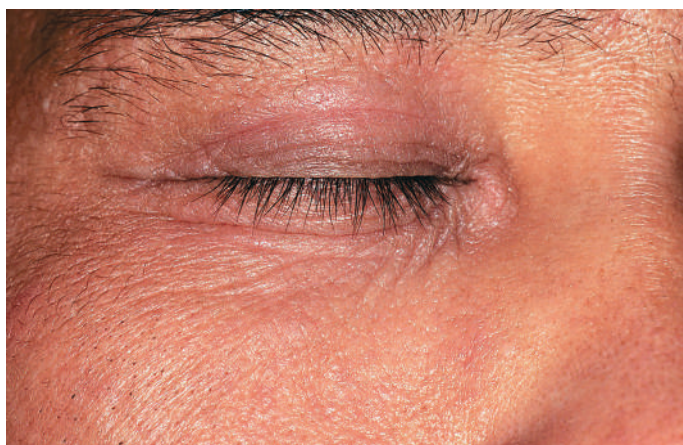
**eFig. 5-5** Napkin psoriasis.

**eFig. 5-6** Juvenile plantar dermatosis.

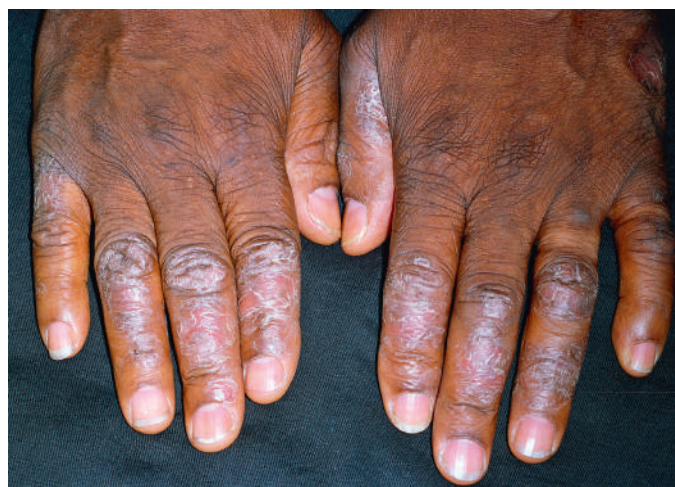**eFig. 5-7** Nummular eczema.

**eFig. 5-8** Eczematous eruption with purpura in Wiskott-Aldrich syndrome.

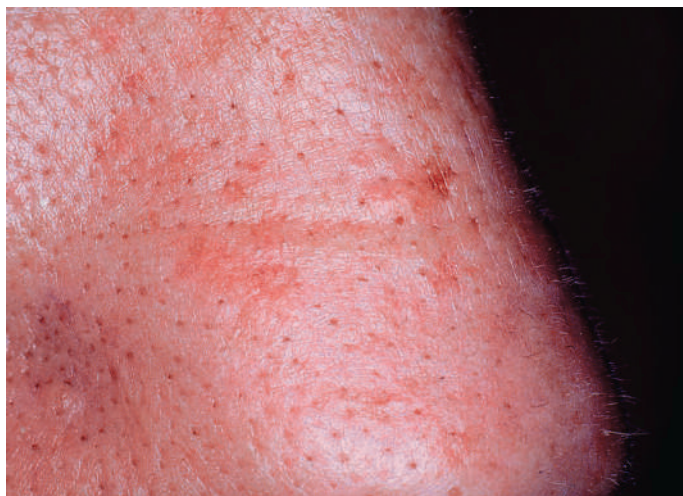



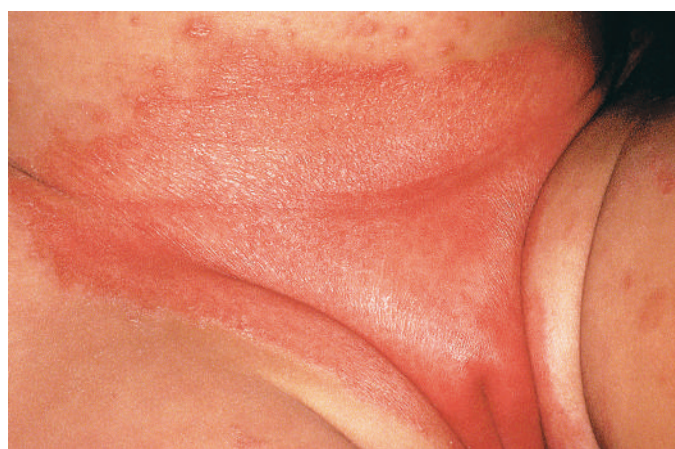**eFig. 5-1** Dennie-Morgan folds (or Morgan folds).



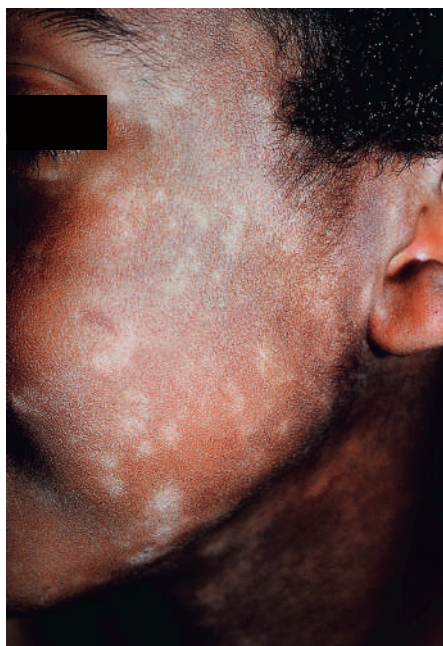**eFig. 5-4** Hyperkeratotic hand dermatitis.



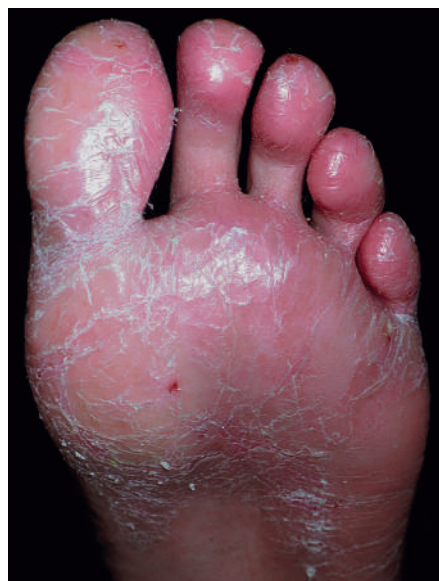**eFig. 5-2** Nasal crease.



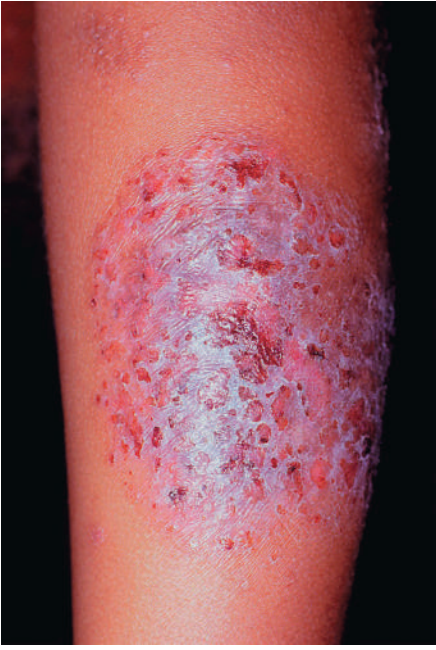**eFig. 5-5** Napkin psoriasis.



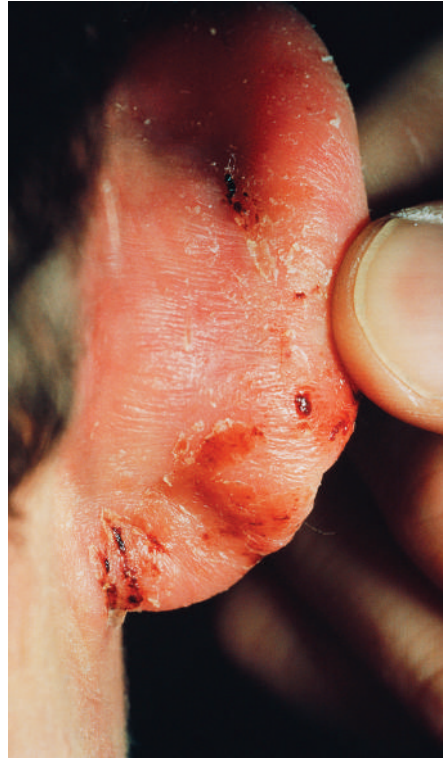**eFig. 5-3** Pityriasis alba.



**eFig. 5-6** Juvenile plantar dermatosis.



**eFig. 5-7** Nummular eczema.



**eFig. 5-8** Eczematous eruption with purpura in Wiskott-Aldrich syndrome.



# 6

## Contact Dermatitis and Drug Eruptions

### CONTACT DERMATITIS

There are two types of dermatitis caused by substances coming in contact with the skin: irritant dermatitis and allergic contact dermatitis. Irritant dermatitis is an inflammatory reaction in the skin resulting from exposure to a substance that causes an eruption in most people who come in contact with it. Allergic contact dermatitis is an acquired sensitivity to various substances that produce inflammatory reactions only in those persons who have been previously sensitized to the allergen.

### Irritant contact dermatitis

Many substances act as irritants that produce a nonspecific inflammatory reaction of the skin. This type of dermatitis may be induced in any person if there is contact with a sufficiently high concentration. No previous exposure is necessary, and the effect is evident within minutes, or a few hours at most. The concentration and type of toxic agent, duration of exposure, and condition of the skin at the time of exposure produce the variation in severity of the dermatitis from person to person, or from time to time in the same person. The skin may be more vulnerable because of maceration from excessive humidity or exposure to water, heat, cold, pressure, or friction. Dry skin, as opposed to wet skin, is less likely to react to contactants, although in chronic xerosis, as seen in elderly patients, increased sensitivity to irritants results. Thick skin is less reactive than thin skin. Atopic patients are predisposed to irritant hand dermatitis. Repeated exposure to some of the milder irritants may produce a hardening effect over time. This process makes the skin more resistant to the irritant effects of a given substance. Symptomatically, pain and burning are more common in irritant dermatitis, contrasting with the usual itch of allergic reactions. Avoidance, substitution of nonirritating agents when possible, and protection, most often by wearing gloves, are the mainstays of treatment.

### Alkalis

Irritant dermatitis is often produced by alkalis such as soaps, detergents, bleaches, ammonia preparations, lye, drain pipe cleaners, and toilet bowl and oven cleansers. Alkalis penetrate and destroy deeply because they dissolve keratin. Strong solutions are corrosive, and immediate application of a weak acid such as vinegar, lemon juice, or 0.5% hydrochloric acid solution will lessen their effects.

The principal compounds are sodium, potassium, ammonium, and calcium hydroxides. Occupational exposure is frequent among workers in soap manufacturing. Sodium silicate (water glass) is a caustic used in soap manufacture and paper sizing and for the preservation of eggs. Alkalis in the form of soaps, bleaching agents, detergents, and most household cleansing agents figure prominently in the causes of hand

eczema. Alkaline sulfides are used as depilatories (Fig. 6-1). Calcium oxide (quicklime) forms slaked lime when water is added. Severe burns may be caused in plasterers.

### Acids

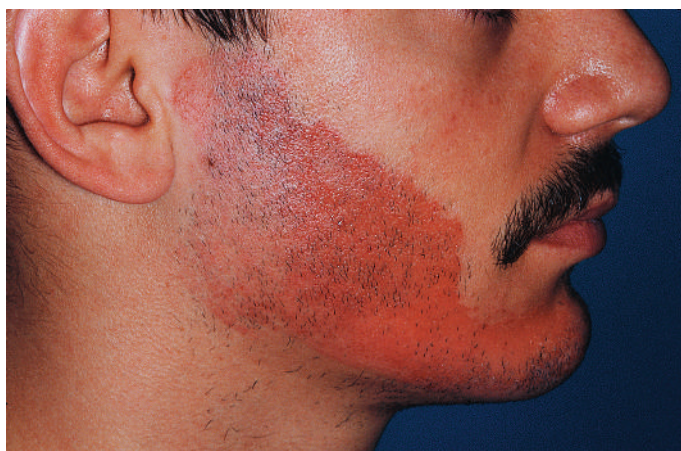The powerful acids are corrosive, whereas the weaker acids are astringent. Hydrochloric acid produces burns that are less deep and more liable to form blisters than injuries from sulfuric and nitric acids (Fig. 6-2). Hydrochloric acid burns are encountered in those who handle or transport the product and in plumbers and those who work in galvanizing or tin-plate factories. Sulfuric acid produces a brownish charring of the skin, beneath which is an ulceration that heals slowly. Sulfuric acid is used more widely than any other acid in industry; it is handled principally by brass and iron workers and by those who work with copper or bronze. Nitric acid is a powerful oxidizing substance that causes deep burns; the tissue is stained yellow. Such injuries are observed in those who manufacture or handle the acid or use it in the making of explosives in laboratories. At times, nitric acid or formic acid is used in assaults secondary to interpersonal conflicts, resulting in scarring most prominently of the face, with the complication of renal failure present in a small number of cases.

Hydrofluoric acid is used widely in rust remover, in the semiconductor industry, and in germicides, dyes, plastics, and glass etching. It may act insidiously at first, starting with erythema and ending with vesiculation, ulceration, and finally necrosis of the tissue. Hydrofluoric acid is one of the strongest inorganic acids, capable of dissolving glass. Hypocalcemia, hypomagnesemia, hyperkalemia, and cardiac dysrhythmias may complicate hydrofluoric acid burns. Fluorine is best neutralized with hexafluorine solution, followed by 10% calcium gluconate solution or magnesium oxide.

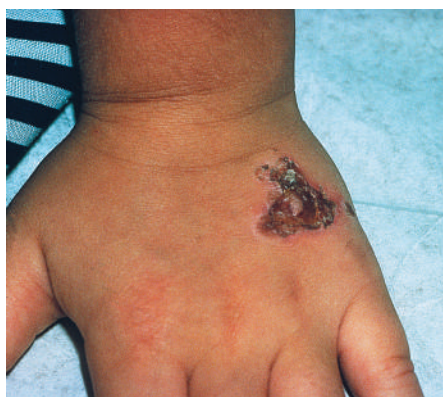Oxalic acid may produce paresthesia of the fingertips, with cyanosis and gangrene. The nails become discolored yellow. Oxalic acid is best neutralized with limewater or milk of magnesia to produce precipitation. Titanium hydrochloride is used in the manufacture of pigments. Application of water to the exposed part will produce severe burns. Therefore, treatment consists only of wiping away the noxious substance.

Phenol (carbolic acid) is a protoplasmic poison that produces a white eschar on the surface of the skin. It can penetrate deep into the tissue. If a large surface of the skin is treated with phenol for cosmetic peeling effects, the absorbed phenol may produce glomerulonephritis and arrhythmias. Locally, temporary anesthesia may also occur. Phenol is readily neutralized with 65% ethyl or isopropyl alcohol.

Chromic acid burns, which may be seen in electroplating and dye production occupations, may result in extensive tissue necrosis and acute renal damage. Excision of affected skin down to the fascia should be accomplished rapidly, and hemodialysis to remove circulating chromium should start in the first 24 h. Other strong acids that are irritants



**Fig. 6-1** Alkali burn caused by depilatory.



**Fig. 6-2** Acid burn.

include acetic, trichloroacetic, arsenious, chlorosulfonic, fluoro-boric, hydriodic, hydrobromic, iodic, perchloric, phosphoric, salicylic, silicofluoric, sulfonic, sulfurous, tannic, and tungstic acids.

Treatment of acid burns consists of immediate rinsing with copious amounts of water and alkalization with sodium bicarbonate, calcium hydroxide (limewater), or soap solutions. Phosphorus burns should be rinsed off with water, followed by application of copper sulfate to produce a precipitate.

### Airbag dermatitis

Airbags are deployed as a safety feature on cars when rapid deceleration occurs. Activation of a sodium azide and cupric oxide propellant cartridge releases nitrogen gas, which expands the bag at speeds exceeding 160 km/h (96 miles/h). Talcum powder, sodium hydroxide, and sodium carbonate are released into the bag. Abrasions, thermal, friction, and chemical burns and an irritant contact dermatitis may result. Superficial erythema may respond well to topical steroids, but full-thickness burns may occur and require debridement and grafting.

### Other irritants

Metal salts that act as irritants include the cyanides of calcium, copper, mercury, nickel, silver, and zinc and the chlorides of calcium and zinc. Bromine, chlorine, fluorine, and iodine are also irritants. Occupational exposure to methyl bromide may produce erythema and vesicles in the axillary and inguinal areas. Insecticides, including 2,2-dichlorovinyl dimethyl phosphate used in roach powder and fly repellents and killers, can act as irritants.

### Fiberglass dermatitis

Fiberglass dermatitis is seen after occupational or inadvertent exposure. The small spicules of glass penetrate the skin and cause severe irritation with tiny erythematous papules, scratch marks, and intense pruritus. Usually, there is no delayed hypersensitivity reaction. Wearing clothes that have been washed together with fiberglass curtains, handling air conditioner filters, or working in the manufacture of fiberglass material may produce severe folliculitis, pruritus, and eruptions that may simulate scabies or insect bites. Fiberglass is also used in thermal and acoustic installation, the wind industry, padding, vibration isolation, curtains, draperies, insulation for automobile bodies, furniture, gasoline tanks, and spacecraft. Talcum powder dusted on the flexure surfaces of the arms before exposure makes the fibers slide off the skin. A thorough washing of the skin after handling fiberglass is helpful. Patch testing to epoxy resins should be done when evaluating workers in fiberglass and reinforced-plastics operations, because an allergic contact dermatitis may be difficult to discern from fiberglass dermatitis.

### Dusts

Some dusts and gases may irritate the skin in the presence of heat and moisture, such as perspiration. The dusts of lime, zinc, and arsenic may produce folliculitis. Dusts from various woods, such as teak, may incite itching and dermatitis. Dusts from cinchona bark, quinine, and pyrethrum produce widespread dermatitis. Tobacco dust in cigar factories, powdered orris root, lycopodium, and dusts of various nutshells may cause swelling of the eyelids and dermatitis of the face, neck, and upper extremities, the distribution of an airborne contact dermatitis. Dusts formed during the manufacture of high explosives may cause erythematous, vesicular, and eczematous dermatitis that may lead to generalized exfoliative dermatitis.

### Capsaicin

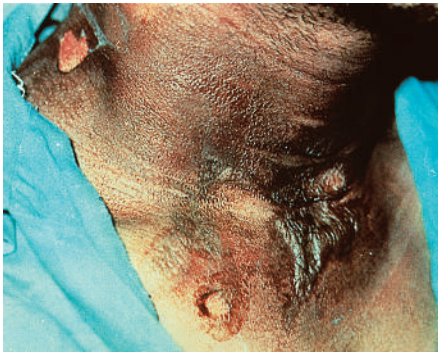
Hand irritation produced by capsaicin in hot peppers used in Korean and North Chinese cuisine (Hunan hand) may be severe and prolonged, sometimes necessitating stellate ganglion blockade and gabapentin. Pepper spray, used by police in high concentrations and by civilians in less concentrated formulas, contains capsaicin and may produce severe burns. Cold water is not much help; capsaicin is insoluble in water. Acetic acid 5% (white vinegar) or antacids (Maalox) may completely relieve the burning, even if applied an hour or more after the contact. Application should be continued until the area can be dried without return of the discomfort.

### Tear gas dermatitis

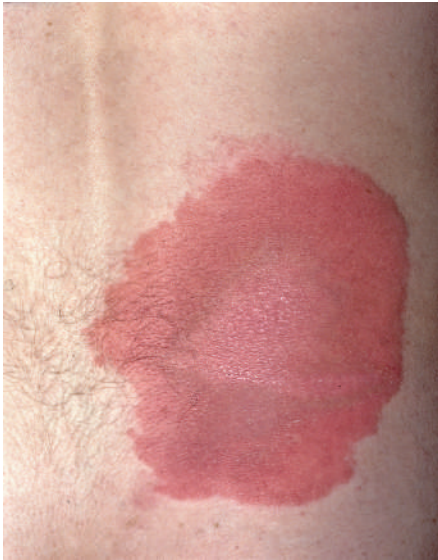Lacrimators such as chloroacetophenone in concentrated form may cause dermatitis, with a delayed appearance about 24–72 h after exposure. Irritation or sensitization, with erythema and severe vesiculation, may result. Treatment consists of lavage of the affected skin with sodium bicarbonate solution and instillation of boric acid solution into the eyes. Contaminated clothing should be removed.

Sulfur mustard gas, also known as yperite (dichlorodiethyl sulfide), has been used in chemical warfare (e.g., Iraq-Iran war in the 1980s). Erythema, vesicles, and bullae result from mild to moderate exposure (Fig. 6-3). Toxic epidermal necrolysis (TEN) like appearance may follow more concentrated contact. The earliest and most frequently affected sites are areas covered by clothing and humidified by sweat, such as the groin, axillae, and genitalia.





**Fig. 6-3** Mustard gas burn. (Courtesy of James WD [ed]: Textbook of Military Medicine. Office of the Surgeon General, United States Army, 1994.)



**Fig. 6-4** Mace-induced reaction.

Mace is a mixture of tear gas (chloroacetophenone) in trichloroethane and various hydrocarbons resembling kerosene. It is available in a variety of self-defense sprays. Mace is a potent irritant and may cause allergic sensitization (Fig. 6-4). Treatment consists of changing clothes, then washing with oil or milk, followed by washing with copious amounts of water.

## Chloracne

Workers in the manufacture of chlorinated compounds may develop chloracne, with small, straw-colored follicular plugs and papules, chiefly on the malar crescent, retroauricular areas, earlobes, neck, shoulders, and scrotum. Histologically, there is a loss of sebaceous glands and the formation of cystic structures. The synthetic waxes chloronaphthalene and chlorodiphenyl, used in the manufacture of electric insulators and in paints, varnishes, and lacquers, predispose workers engaged in the manufacture of these synthetic waxes to chloracne. Exposure to 2,6-dichlorobenzonitrile during the manufacture of a herbicide, and to 3,4,3',4'-tetrachloroazooxybenzene, which is an unwanted intermediate byproduct in the manufacture of a pesticide, may also produce chloracne.

A contaminant in the synthesis of herbicides and hexachlorophene, 2,3,7,8-tetrachlorodibenzo-*p*-dioxin, produces a chemical burn in the acute stage, but chloracne, hyperpigmentation, hirsutism, and skin fragility (with or without criteria for porphyria cutanea tarda) are manifestations of chronic toxicity. Gastrointestinal tract cancer and malignancies of the lymphatic and hematopoietic systems are suspected to result. While direct contact is the usual method of exposure,

inhalation, ingestion, or contact with contaminated clothing may also result in chloracne. Chloracne may persist for long periods because dioxin is stored in the liver and released slowly into the circulation. Treatment is with medications used in acne vulgaris, including isotretinoin.

## Hydrocarbons

Many hydrocarbons produce skin eruptions. Crude petroleum causes generalized itching, folliculitis, or acneiform eruptions. The irritant properties of petroleum derivatives are directly proportional to their fat-solvent properties and inversely proportional to their viscosity. Oils of the naphthalene series are more irritating than those of the paraffin series. Refined fractions from petroleum are less irritating than the unrefined products, although benzene, naphtha, and carbon disulfide may cause a mild dermatitis.

Lubricating and cutting oils are causes of similar cutaneous lesions. They represent a frequent cause of occupational dermatoses in machine tool operators, machinists, layout men, instrument makers, and setup men. Insoluble (neat) cutting oils are responsible for a follicular acneiform eruption on the dorsa of the hands, the forearms, face, thighs, and back of the neck. Hyperpigmentation, keratoses, and scrotal cancer have been found in those exposed to insoluble cutting oils. Soluble oils and synthetic fluids used in metalworking do not result in acne, but rather an eczematous dermatitis, usually of the dorsal forearms and hands. Approximately 50% of the time it is irritant and in the remainder it is allergic. Allergic contact dermatitis arises from various additives, such as biocides, coloring agents, and deodorizers.

Coal briquette makers develop dermatitis as a result of a tarry residue from petroleum used in their trade. Paraffin exposure leads to pustules, keratoses, and ulcerations. Shale oil workers develop an erythematous, follicular eruption that eventually leads to keratoses, which may become the sites of carcinoma. It is estimated that 50% of shale oil workers have skin problems.

Impure and low-grade paraffins and mineral oils cause similar skin eruptions. Initially, the skin changes are similar to those in chloracne. Over time, a diffuse erythema with dappled pigmentation develops. Gradually, keratoses appear, and after many years, some of these are the sites of carcinoma. Melanoderma may occur from exposure to mineral oils and lower-grade petroleum from creosote, asphalt, and other tar products. Photosensitization may play a role. Creosote is a contact irritant, sensitizer, and photosensitizer. Allergy is demonstrated by patch testing with 10% creosote in oil.

Petrolatum dermatitis may appear as a verrucous thickening of the skin caused by prolonged contact with impure petroleum jelly or, occasionally, lubricating oil. A follicular-centered process may occur in which erythematous horny nodules are present, usually on the anterior and inner aspects of the thighs. There are no comedones, and the lesions are separated by apparently normal skin.

Acne corne consists of follicular keratosis and pigmentation resulting from crude petroleum, tar oils, and paraffin. The dorsal aspects of the fingers and hands, the arms, legs, face, and thorax are the areas usually involved. The lesions are follicular horny papules, often black, and are associated at first with a follicular erythema and later with a dirty brownish or purplish spotty pigmentation, which in severe cases becomes widespread and is especially marked around the genitals. This syndrome may simulate pityriasis rubra pilaris or lichen spinulosus.

Coal tar and pitch and many of their derivatives produce photosensitization and an acneiform folliculitis of the forearms, legs, face, and scrotum. Follicular keratoses (pitch warts)

may develop and later turn into carcinoma. Soot, lamp black, and the ash from peat fires produce dermatitis of a dry, scaly character, which over time forms warty outgrowths and cancer. Chimney sweep's cancer occurs under a soot wart and is usually located on the scrotum, where soot, sebum, and dirt collect in the folds of the skin. This form of cancer has virtually disappeared.

Acquired perforating disease may occur in oil field workers who use drilling fluid containing calcium chloride. Patients develop tender, umbilicated papules of the forearms that microscopically show transepidermal elimination of calcium.

## Solvents

The solvents cause approximately 10% of occupational dermatitis. When solvents are applied to the hands to cleanse them, the surface oil is dissolved, and a chronic fissured dermatitis results. Additionally, peripheral neuropathy and chemical lymphangitis may occur after the solvents are absorbed through the fissured skin. Solvent sniffers may develop an eczematous eruption around the mouth and nose; erythema and edema occur. This is a direct irritant dermatitis caused by the inhalation of the solvent placed on a handkerchief.

Trichloroethylene is a chlorinated hydrocarbon solvent and degreasing agent also used in the dry-cleaning and refrigeration industry. Inhalation may produce exfoliative erythroderma, mucous membrane erosions, eosinophilia, and hepatitis.

Allergic contact dermatitis caused by alcohol is rarely encountered with lower-aliphatic alcohols. A severe case of bullous and hemorrhagic dermatitis on the fingertips and deltoid region was caused by isopropyl alcohol. Although rare, ethyl alcohol dermatitis may also be encountered. Cetyl and stearyl alcohols may provoke contact urticaria.

**Ale IS, et al:** Irritant contact dermatitis. *Rev Environ Health* 2014; 29:195–206.

**Bordel-Gomez MT, et al:** Fiberglass dermatitis. *Contact Dermatitis* 2008; 59:120.

**Bourke J, et al:** Guidelines for the management of contact dermatitis. *Br J Dermatol* 2009; 160:946.

**Edlich RF, et al:** Modern concepts of treatment and prevention of chemical injuries. *J Long Term Eff Med Implants* 2005; 15:303.

**Flammiger A, et al:** Sulfuric acid burns. *Cutan Ocul Toxicol* 2006; 25:55.

**Goon AT, et al:** A case of trichloroethylene hypersensitivity syndrome. *Arch Dermatol* 2001; 137:274.

**Herzemans-Boer M, et al:** Skin lesions due to methyl bromide. *Arch Dermatol* 1988; 124:917.

**Jia X, et al:** Adverse effects of gasoline on the skin of gasoline workers. *Contact Dermatitis* 2002; 46:44.

**Karunadasa KP, et al:** Burns due to acid assaults in Sri Lanka. *J Burn Care Res* 2010; 31:781.

**Landeck L, et al:** Clinical course of occupational irritant contact dermatitis of the hands in relation to filaggrin genotype status and atopy. *Br J Dermatol* 2012; 167:1302.

**Momeni AZ, et al:** Skin manifestations of mustard gas. *Arch Dermatol* 1992; 128:775.

**Passarini B, et al:** Chloracne. *Dermatology* 2010; 221:63.

**Salzman M, et al:** Updates on the evaluation and management of caustic exposures. *Emerg Med Clin North Am* 2007; 25:459.

**Saurat JH, et al:** The cutaneous lesions of dioxin exposure: lessons from the poisoning of Victor Yushchenko. *Toxicol Sci* 2012; 125:310.

**Saxena AK, et al:** Multimodal approach for the management of Hunan hand syndrome. *Pain Prac* 2013; 13:227.

**Seyfarth F, et al:** Dry skin, barrier function, and irritant contact dermatitis in the elderly. *Clin Dermatol* 2011; 29:31.

**Stuke LE, et al:** Hydrofluoric acid burns. *J Burn Care Res* 2008; 29:893.

**Wu JJ, et al:** A case of air bag dermatitis. *Arch Dermatol* 2002; 138:1383.

**Yoshimura CA, et al:** Seventy per cent hydrofluoric acid burns. *J Burn Care Res* 2011; 32:e149.

## Allergic contact dermatitis

Allergic contact dermatitis results when an allergen comes into contact with previously sensitized skin. It is caused by a specific acquired hypersensitivity of the delayed type, also known as cell-mediated (type IV) hypersensitivity. These sensitizers do not cause demonstrable skin changes on initial contact. Persons may be exposed to allergens for years before finally developing hypersensitivity. Genetic variability in the immunologic processes leading to sensitization and other factors, such as concentration of the allergen applied, its vehicle, timing and site of the exposure, presence of occlusion, age, gender, and race of the patient, and presence of other skin or systemic disorders, likely determine whether any given exposure will result in sensitization. Once sensitized, however, subsequent outbreaks may result from extremely slight exposure.

Childhood exposures do result in allergy, and the frequency of allergy in this age group is increasing. The most common relevant allergens are nickel, cobalt, and fragrance. Sensitivity is rarely lost over the years; older patients have similar rates of allergy as adults.

Occasionally, dermatitis may be induced when the allergen is taken internally by a patient first sensitized by topical application, as with substances such as cinnamon oil or various medications. The anamnestic response is termed systemic contact dermatitis. It may appear first at the site of the prior sensitization or past positive patch test, but may spread to a generalized morbilliform or eczematous eruption. Additional morphologic patterns include vesicular hand eczema, urticaria, erythema multiforme, vasculitis, or symmetric drug-related intertriginous and flexural exanthema (SDRIFE). Formerly called baboon syndrome, SDRIFE is a deep-red-violet eruption on the buttocks, genital area, inner thighs, and sometimes the axillae.

The most common causes of contact dermatitis in the United States are toxicodendrons (poison ivy, oak, or sumac), nickel, balsam of Peru (*Myroxylon pereirae*), neomycin, fragrance, formaldehyde and the formaldehyde-releasing preservatives, bacitracin, and rubber compounds. Frequent positive reactions to gold and thimerosal do not often correlate with the clinical exposure history. Gold reactions, which may be prolonged, can be correlated in some cases with oral gold exposure or occupational dermatitis, but in most cases, the relevance is questionable. Thimerosal reactions are probably related to its use as a preservative in common vaccines and skin-testing material. It also serves as a marker for piroxicam photosensitivity.

Eczematous delayed-type hypersensitivity reaction, as exemplified by allergic contact dermatitis and the patch test, must be distinguished from immediate-type hypersensitivity reaction. The latter presents within minutes of exposure with urticaria and is proved with a scratch test. It should be kept in mind, however, that persons who develop contact urticaria to a substance may concomitantly have a type IV delayed-type sensitization and eczema from the same allergen.

In some patients, impetigo, pustular folliculitis, and irritation or allergic reactions from applied medications are superimposed on the original dermatitis. A particularly vexing situation is when allergy to topical corticosteroids complicates an eczema, in which case the preexisting dermatitis usually does not flare, but simply does not heal as expected. The cutaneous reaction may also provoke a hypersusceptibility to various other, previously innocuous substances, which continues the eczematous inflammatory response indefinitely.

These eruptions resolve when the cause is identified and avoided. For acute generalized allergic contact dermatitis, treatment with systemic steroidal agents is effective, beginning



with 40–60 mg/day of prednisone in a single oral dose, and tapering slowly to topical steroids. When the eruption is limited in extent and severity, local application of topical corticosteroid creams, lotions, or aerosol sprays is preferred.

## Testing for sensitivity

### Patch test

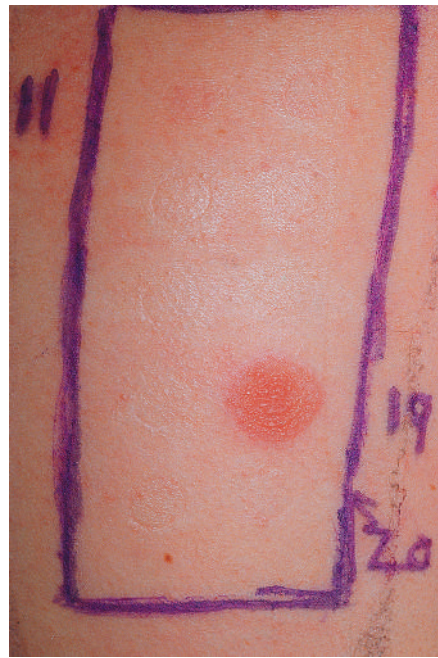
The patch test is used to detect hypersensitivity to a substance that is in contact with the skin so that the allergen may be determined and corrective measures taken. So many allergens can cause allergic contact dermatitis that it is impossible to test a person for all of them. In addition, a good history and observation of the pattern of the dermatitis, its localization on the body, and its state of activity are helpful in determining the cause. The patch test is confirmatory and diagnostic, but only within the framework of the history and physical findings; it is rarely helpful if it must stand alone. Interpretation of the relevance of positive tests and the subsequent education of patients are challenging in some cases. The Contact Allergen Management Program (CAMP) provides names of alternative products that may be used by patients when an allergen is identified. This is available through the American Contact Dermatitis Society.

The patch test consists of application of substances suspected to be the cause of the dermatitis to intact uninfamed skin. Patch testing may be administered by the thin-layer rapid-use epicutaneous (TRUE) test or by individually prepared patches. The TRUE test has resulted in more screening for allergic contact dermatitis than in the past, but if it does not reveal the allergen for a highly suspect dermatitis, testing with an expanded series will on average yield relevant allergens in more than half of these patients. Dermatitis originating in the workplace will almost always require individualized testing.

Test substances are applied usually to the upper back, although if only one or two are applied, the upper outer arm may be used. Each patch should be numbered to avoid confusion. The patches are removed after 48 h (or sooner if severe itching or burning occurs at the site) and read. The patch sites need to be evaluated again at day 4 or 5 because positive reactions may not appear earlier. Some allergens may take up to day 7 to show a reaction, and the patient should be advised to return if such a delayed reaction occurs. Erythematous papules and vesicles with edema are indicative of allergy (Fig. 6-5). Occasionally, patch tests for potassium iodide, nickel, or mercury will produce pustules at the site of the test application. Usually no erythema is produced; therefore, the reaction has no clinical significance.

Strong patch test reactions may induce a state of hyperirritability ("excited skin syndrome") in which adjacent tests that would otherwise be negative appear as weakly positive. Weakly positive tests in the presence of strong tests do not prove sensitivity. The skin and mucous membranes vary widely in the ability to react to antigens. The oral mucosa is more resistant to primary irritants and is less liable to be involved in allergic reactions. This may be because the keratin layer of the skin more readily combines with haptens to form allergens. Also, the oral mucosa is bathed in saliva, which cleanses and buffers the area and dilutes irritants. However, patch testing for various types of oral signs and symptoms, such as swelling, tingling and burning, perioral dermatitis, and the appearance of oral lichen planus, is useful in determining a cause in many cases.

Potent topical corticosteroids, ultraviolet (UV) light, various immunosuppressants (e.g., oral prednisone), and the acquired immunodeficiency syndrome (AIDS) have been reported to



**Fig. 6-5** Positive patch test reaction.

interfere with the number and function of key immunologic processes, leading to sensitization and reactivity to testing. False-negative reactions may result; the value of testing in such circumstances is that if a positive reaction occurs, a diagnosis may be made. Vitiliginous skin is less reactive than normally pigmented adjacent skin.

### Provocative use test

The provocative use test will confirm a positive closed patch test reaction to ingredients of a substance, such as a cosmetic; it is used to test products that are made to stay on the skin once applied. The material is rubbed on to normal skin of the inner aspect of the forearm several times a day for 5 days.

### Photopatch test

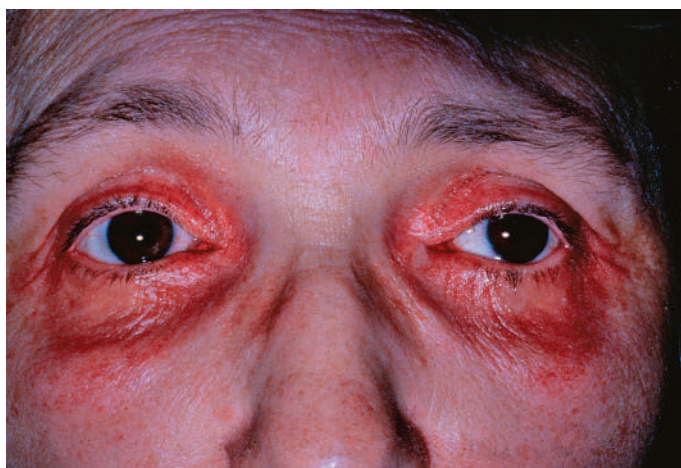The photopatch test is used to evaluate for contact photoallergy to such substances as sulfonamides, phenothiazines, *p*-aminobenzoic acid, oxybenzone, 6-methyl coumarin, musk ambrette, and tetrachlorosalicylanilide. A standard patch test is applied for 48 h; this is then exposed to 5–15 J/m<sup>2</sup> of UVA and read after another 48 h. To test for 6-methyl coumarin sensitivity, the patch is applied in the same manner but for only 30 min before light exposure, rather than for 48 h. A duplicate set of nonirradiated patches is used in testing for the presence of routine delayed hypersensitivity reactions. Also, a site of normal skin is given an identical dose of UVA to test for increased sensitivity to light without prior exposure to chemicals. There is a steady increase in incidence of photoallergy to sunscreens and a decreasing incidence of such reactions to fragrance.

## Regional predilection

Familiarity with certain contactants and the typical dermatitis they elicit on specific parts of the body will assist in diagnosis of the etiologic agent.

### Head and neck

The scalp is relatively resistant to the development of contact allergies; however, involvement may be caused by hair dye, hair spray, shampoo, or permanent wave solutions. The surrounding glabrous skin, including the ear rims and backs of



**Fig. 6-6** Eyelid dermatitis.

the ears, may be much more inflamed and suggestive of the cause. Persistent otitis of the ear canal may be caused by sensitivity to neomycin, an ingredient of most aural medications. The eyelids are the most frequent site for nail polish dermatitis. Volatile gases, false-eyelash adhesive, fragrances, preservatives, mascara, rubber in sponges used to apply cosmetics, and eyeshadow are also frequently implicated (Fig. 6-6). Perioral dermatitis and cheilitis may be caused by flavoring agents in dentifrices and gum, as well as fragrances, shellac, medications, and sunscreens in lipstick and lip balms. Perfume dermatitis may cause redness just under the ears or on the neck. Earlobe dermatitis is indicative of nickel sensitivity. Photocontact dermatitis may involve the entire face and may be sharply cut off at the collar line or extend down on to the sternum in a V shape. There is a typical clear area under the chin where there is little or no exposure to sunlight. The left cheek and left side of the neck (from sun exposure while driving) may be the first areas involved.

### Trunk

The trunk is an infrequent site; however, the dye or finish of clothing may cause dermatitis. The axilla may be the site of deodorant dermatitis and clothing-dye dermatitis; involvement of the axillary vault suggests the former; of the axillary folds, the latter. In women, brassieres cause dermatitis from the material itself, the elastic, or the metal snaps or underwires.

### Arms

The wrists may be involved because of jewelry or the backs of watches and clasps, all of which may contain nickel. Wristbands made of leather are a source of chrome dermatitis.

### Hands

Innumerable substances may cause allergic contact dermatitis of the hands, which typically occurs on the backs of the hands and spares the palms. Florists will often develop fingertip or palmar lesions (see Fig. 6-10). A hand dermatitis that changes from web spaces to fingertips or from palms to dorsal hands should trigger patch testing. Poison ivy and other plant dermatitides frequently occur on the hands and arms. Rubber glove sensitivity must be kept constantly in mind. Usually, irritancy is superimposed on allergic contact dermatitis of the hands, altering both the morphologic and histologic clues to the diagnosis.

### Abdomen

The abdomen, especially the waistline, may be the site of rubber dermatitis from the elastic in pants and undergar-

ments. The metallic rivets in blue jeans may lead to periumbilical dermatitis in nickel-sensitive patients, as may piercings of the umbilicus.

### Groin

The groin is usually spared, but the buttocks and upper thighs may be sites of dermatitis caused by dyes. The penis is frequently involved in poison ivy dermatitis. Condom dermatitis may also occur. The perianal region may be involved from the "caine" medications in suppositories, as well as preservatives and fragrances in cleansing materials. Almost half of women with pruritus vulvae have one or more relevant allergens; often these are medicaments, fragrances, or preservatives.

### Lower extremities

The shins may be the site of rubber dermatitis from elastic stockings. Feet are sites for shoe dermatitis, most often attributable to rubber sensitivity, chrome-tanned leather, dyes, or adhesives. Application of topical antibiotics to stasis ulcers frequently leads to sensitivity and allergic contact dermatitis.

- Bonitsis NG, et al:** Allergens responsible for allergic contact dermatitis among children. *Contact Dermatitis* 2011; 64:245.
- Bourke I, et al:** Guidelines for the management of contact dermatitis. *Br J Dermatol* 2009; 160:946.
- Bryden AM, et al:** Photopatch testing of 1155 patients. *Br J Dermatol* 2006; 155:737.
- Diepgen TL, et al:** Management of chronic hand eczema. *Contact Dermatitis* 2007; 57:203.
- Feser A, et al:** Periorbital dermatitis. *Br J Dermatol* 2008; 159:858.
- Jean SE, et al:** Contact dermatitis in leg ulcer patients. *J Cutan Med Surg* 2009; 13(suppl 1):S38.
- Fonacier LS, et al:** Allergic contact dermatitis. *Ann Allergy Asthma Immunol* 2014; 113:9–12.
- Kockentiet B, et al:** Contact dermatitis in athletes. *J Am Acad Dermatol* 2007; 56:1048.
- Mowad CM:** Patch testing. *Curr Opin Allergy Clin Immunol* 2006; 6:340.
- Prakash AV, et al:** Contact dermatitis in older adults. *Am J Clin Dermatol* 2010; 11:373.
- Rietschel RL, Fowler JF Jr:** *Fisher's Contact Dermatitis*, 6th edn. Hamilton: BC Decker, 2008.
- Schena D, et al:** Contact allergy in chronic eczematous lip dermatitis. *Eur J Dermatol* 2008; 18:688.
- Schlosser BJ:** Contact dermatitis of the vulva. *Dermatol Clin* 2010; 28:697.
- Sheman A, et al:** Contact allergy alternatives. *Dis Mon* 2008; 54:7.
- Simonsen AB, et al:** Contact allergy and allergic contact dermatitis in children. *Contact Dermatitis* 2011; 65:254.
- Spring S, et al:** Contact dermatitis to topical medicaments. *Dermatitis* 2012; 23:210.
- Tan CH, et al:** Contact dermatitis. *Clin Dermatol* 2014; 32:116–124.
- Thyssen JP, et al:** The epidemiology of contact allergy in the general population. *Contact Dermatitis* 2007; 57:287.
- Torgerson RR, et al:** Contact allergy in oral disease. *J Am Acad Dermatol* 2007; 57:315.
- Uter W, et al:** Patch test results with patients' own perfumes, deodorants and shaving lotions. *J Eur Acad Dermatol Venereol* 2007; 21:374.
- Veien NK:** Systemic contact dermatitis. *Int J Dermatol* 2011; 50:1445.
- Warshaw EM, et al:** Positive patch test reactions in older individuals. *J Am Acad Dermatol* 2012; 66:229.
- Winnicki M, et al:** A systematic approach to systemic contact dermatitis and symmetric drug-related intertriginous and flexural exanthema (SDRIFE). *Am J Clin Dermatol* 2011; 12:171.

## Dermatitis resulting from plants

A large number of plants, including trees, grasses, flowers, vegetables, fruits, and weeds, are potential causes of dermatitis. Eruptions from them vary considerably in appearance but are usually vesicular and accompanied by marked edema. After previous exposure and sensitization to the active



substance in the plant, the typical dermatitis results from reexposure. The onset is usually a few hours or days after contact. The characteristic linearly grouped lesions are probably produced by brushing the skin with a leaf edge or a broken twig or by carriage of the allergen under the nails. Contrary to general belief, the contents of vesicles are not capable of producing new lesions.

### Toxicodendron (poison ivy)

*Toxicodendron* dermatitis includes dermatitis from members of the Anacardiaceae family of plants: poison ivy (*T. radicans*, or *Rhus radicans*), poison oak (*T. diversilobum*, *R. diversaloba*), poison sumac (*T. vernix*, *R. vernix*), Japanese lacquer tree, cashew nut tree (allergen in nutshell), mango (allergen in rind, leaves, or sap), Rengas tree, and Indian marking nut tree. The ginkgo (allergen in fruit pulp), spider flower or silver oak, *Gluta* species of trees and shrubs in Southeast Asia, Brazilian pepper tree, also known as Florida holly, and poisonwood tree contain almost identical antigens.

*Toxicodendron* dermatitis appears within 48 h of exposure of a person previously sensitized to the plant. It usually begins on the backs of the fingers, interdigital spaces, wrists, and eyelids, although it may begin on the ankles or other parts that have been exposed. Marked pruritus is the first symptom; inflammation, vesicles, and bullae may then appear. The vesicles are usually grouped and often linear (Fig. 6-7). Large bullae may be present, especially on the forearms and hands. The eyelids are puffy and worst in the morning, improving as the day progresses (Fig. 6-8). Pruritus ani and involvement of the genital areas occur frequently. A black lacquer deposit may occur in which the sap of the plant has been oxidized after being bound to the stratum corneum (Fig. 6-9). Untreated *Toxicodendron* dermatitis usually lasts 2–3 weeks.

The fingers transfer the allergen to other parts, especially the forearms and the male prepuce, which become greatly swollen. However, once the causative oil has been washed off, there is no spreading of the allergen and no further spread of the dermatitis. Some persons are so susceptible that direct contact is

not necessary, the allergen apparently being carried by the fur of their pets or by the wind. It can also be acquired from golf clubs or fishing rods, or even from furniture that a dog or cat might have occupied after exposure to the catechol. Occasionally, eating the allergen, as occurred in a patient who ingested raw cashew nuts in an imported pesto sauce, may result in SDRIFE (see earlier) or a systematized allergic contact dermatitis with the morphology of a generalized erythematous papular eruption.

The cause is an oleoresin known as urushiol, of which the active agent is a mixture of catechols. This and related resorcinol allergens are present in many plants and also in *Philodendron* species, wood from *Persoonia elliptica*, wheat bran, and marine brown algae.

The most striking diagnostic feature is the linearity of the lesions. It is rare to see vesicles arranged linearly except in plant-induced dermatitis. A history of exposure in the country or park to plants that have shiny leaves in groups of three, followed by the appearance of vesicular lesions within 2 days, usually establishes the diagnosis.

Eradication of plants having grouped “leaves of three” growing in frequented places is one easy preventive measure, as is recognition of the plants to avoid. An excellent resource is a pamphlet available from the American Academy of Dermatology. If the individual is exposed, washing with soap and water within 5 min may prevent an eruption. Protective barrier creams are available that are somewhat beneficial. Quaternium-18 bentonite has been shown to prevent or diminish experimentally produced poison ivy dermatitis.

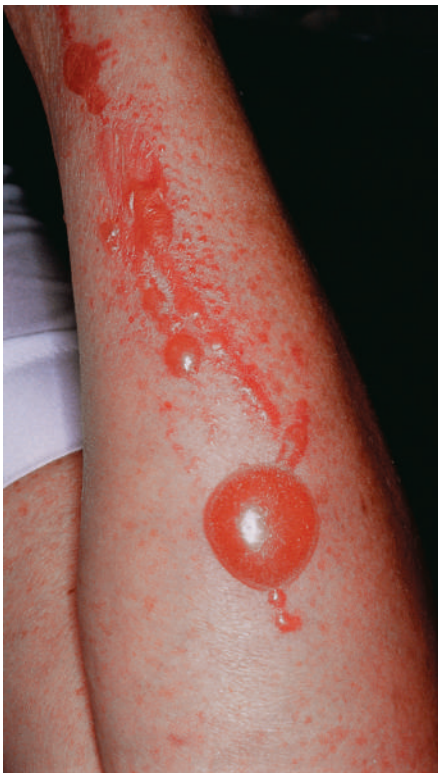

Fig. 6-7 Acute poison ivy reaction.

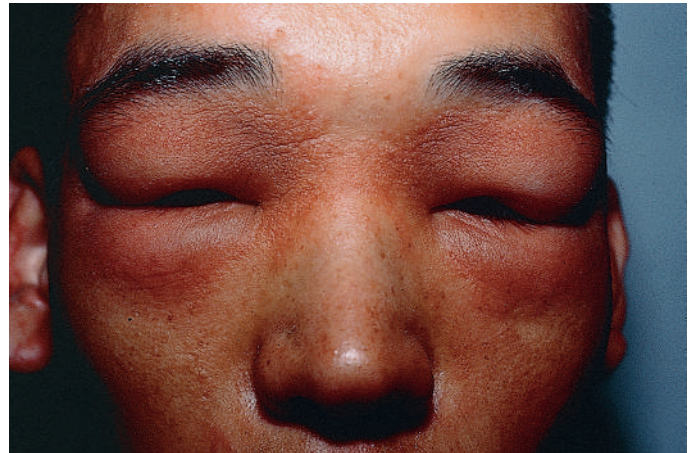

Fig. 6-8 Acute poison ivy reaction.

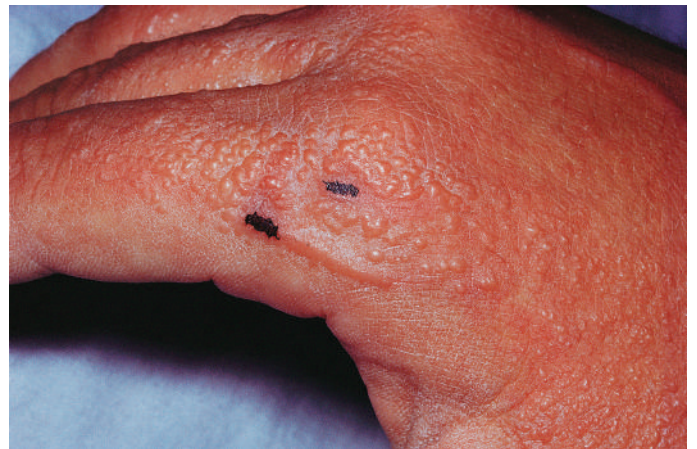

Fig. 6-9 Black dot sign in poison ivy reaction.

Innumerable attempts have been made to immunize against poison ivy dermatitis by oral administration of the allergen or subcutaneous injections of oily extracts. To date, no accepted method of immunization is available. Repeated attacks do not confer immunity, although a single severe attack may achieve this by what has been called massive-dose desensitization.

When the diagnosis is clear and the eruption severe or extensive, systemic steroidal agents are effective, beginning with 40–60 mg of prednisone in a single oral dose daily, tapered off over a 3-week period. When the eruption is limited in extent and severity, local application of topical corticosteroid creams, lotions, or aerosol sprays is preferred. Time-honored calamine lotion without phenol is helpful and does no harm. Antihistaminic ointments should be avoided because of their sensitization potential. This also applies to the local application of the “caine” topical anesthetics.

### Other Toxicodendron-related dermatitides

Lacquer dermatitis is caused by a furniture lacquer made from the Japanese lacquer tree, used on furniture, jewelry, or bric-a-brac. Antique lacquer is harmless, but lacquer less than 1 or 2 years old is highly antigenic. Cashew nutshell oil is extracted from the nutshells of the cashew tree (*Anacardium occidentale*). This vesicant oil contains cardol, a phenol similar to urushiol in poison ivy. The liquid has many commercial applications, such as the manufacture of brake linings, varnish, synthetic glue, paint, and sealer for concrete.

Mango dermatitis is uncommon in natives of mango-growing countries (e.g., Philippines, Guam, Hawaii, Cuba) who have never been exposed to contact with *Toxicodendron* species. Many persons who have been so exposed, however, whether or not they had dermatitis from it, are sensitized by one or a few episodes of contact with the peel of the mango fruit. The palms carry the allergen, so the eyelids and the male prepuce are often early sites of involvement.

Ginkgo tree dermatitis simulates *Toxicodendron* dermatitis with its severe vesiculation, erythematous papules, and edema. The causative substances are ginkgolic acids from the fruit pulp of the ginkgo tree. Ingestion of the ginkgo fruit may result in perianal dermatitis. Ginkgo biloba given orally for cerebral disturbances is made from a leaf extract so it does not elicit a systemic contact allergy when ingested.

### Flowers and houseplants

Among the more common houseplants, the velvety-leaved philodendron, *Philodendron crystallinum* (and its several variants), known in India as the “money plant,” is a frequent cause of contact dermatitis. The eruption is often seen on the face, especially the eyelids, carried there by hands that have watered or cared for the plant. English ivy follows philodendron in frequency of cases of occult contact dermatitis. Primrose dermatitis affects the fingers, eyelids, and neck with a punctate or diffuse erythema and edema. Formerly found most frequently in Europe, the primrose is now a common U.S. houseplant. Primin, a quinone, is the causative oleoresin abounding in the glandular hairs of the plant *Primula obconica*.

The popular cut flower, the Peruvian lily, is the most common cause of allergic contact dermatitis in florists. When handling flowers of the genus *Alstroemeria*, the florist uses the thumb and second and third digits of the dominant hand. Because it is chronic, fissured hyperkeratotic dermatitis results, identical to the “tulip fingers” seen among sensitized tulip workers (Fig. 6-10). Testing is done with the allergen tuliposide A. It does not penetrate nitrile gloves.

Chrysanthemums frequently cause dermatitis, with the hands and eyelids of florists most often affected. The  $\alpha$ -methylene portion of the sesquiterpene lactone molecule is

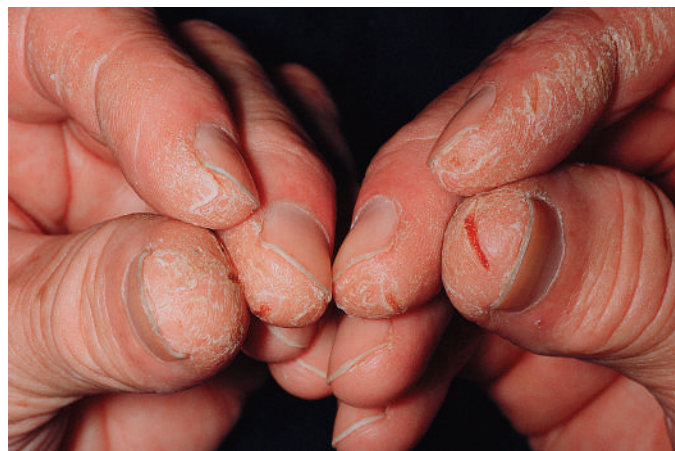

Fig. 6-10 Chronic fissured fingertip dermatitis in a florist.

the antigenic site, as it is in the other genera of the Compositae family.

A severe inflammatory reaction with bulla formation may be caused by the prairie crocus (*Anemone patens* L.), the floral emblem of the province of Manitoba. Several species of ornamental “bottle brush” from Queensland (*Grevillea banksii*, *G. Robyn Gordon*, *G. robusta*), may cause allergic contact dermatitis. It is exported to the United States and other Western countries. The allergen is a long-chain alkyl resorcinol. Cross-sensitivity to *Toxicodendron* has been demonstrated.

Contact dermatitis may be caused by handling many other flowers, such as the geranium, scorpion flower (*Phacelia crenulata* or *P. campanularia*), hydrangea, creosote bush (*Larvia tridentata*), *Heracula*, daffodil, foxglove, lilac, lady slipper, magnolia, and tulip and narcissus bulbs. The poinsettia and oleander almost never cause dermatitis, despite their reputation for it, although they are toxic if ingested. Treatment of all these plant dermatitides is the same as that recommended for toxicodendron dermatitis.

*Parthenium hysterophorus*, a photosensitizing weed, was accidentally introduced into India in 1956 and has spread over most of the country; it is also spreading in Australia, parts of Africa, China, and Argentina. The well-deserved reputation for harmfulness of dieffenbachia, a common, glossy-leaved house plant, rests on the high content of calcium oxalate crystals in its sap, which burn the mouth and throat severely if any part of the plant is chewed or swallowed. Severe edema of the oral tissues may result in complete loss of voice, thus its common nickname, “dumb cane.” It does not appear to sensitize. The castor bean, the seed of *Ricinus communis*, contains ricin, a poisonous substance (phytotoxin). Its sap contains an antigen that may cause anaphylactic hypersensitivity and also dermatitis.

### Fruit and vegetables

Many vegetables may cause contact dermatitis, including asparagus, carrot, celery, cow-parsnip, cucumber, garlic, Indian bean, mushroom, onion, parsley, tomato, and turnip. Onion and celery, among other vegetables, have been incriminated in the production of contact urticaria and even anaphylaxis. Several plants, including celery, fig, lime, and parsley, can cause a phototoxic dermatitis because of the presence of psoralens.

### Trees

Trees with timber and sawdust that may produce contact dermatitis include ash, birch, cedar, cocobolo, elm, Kentucky coffee tree, koa, mahogany, mango, maple, mesquite, milo, myrtle, pine, and teak. The latex of fig and rubber trees may



also cause dermatitis, usually of the phototoxic type. Melaleuca oil (tea tree oil), which may be applied to the skin to treat a variety of maladies, can cause allergic contact dermatitis, primarily through the allergen D-limonene. The exotic woods, especially cocobolo and rosewood, and tea tree oil are prominent among allergens that may produce erythema multiforme after cutaneous exposure. *Toxicodendron*, various medicaments, and a variety of other allergens may induce this reaction.

### Tree-associated plants

Foresters and lumber workers can be exposed to allergenic plants other than trees. Lichens are a group of plants composed of symbiotic algae and fungi. Foresters and wood choppers exposed to these lichens growing on trees may develop severe allergic contact dermatitis. Exposure to the lichens may also occur from firewood, funeral wreaths, and also fragrances added to aftershave lotions (oak moss and tree moss). Sensitization is produced by D-usnic acid and other lichen acids contained in lichens. The leafy liverwort (*Frullania nisquallensis*), a forest epiphyte growing on tree trunks, has produced allergic dermatitis in forest workers. The eruption is commonly called "cedar poisoning." It resembles *Toxicodendron* dermatitis; its attacks are more severe during wet weather. The allergen is sesquiterpene lactone.

### Pollens and seeds

The pollens in ragweed are composed of two antigens. The protein fraction causes the respiratory symptoms of asthma and hay fever, and the oil-soluble portion causes contact dermatitis. Ragweed oil dermatitis is a seasonal disturbance seen mainly during the ragweed growing season from spring to fall. Contact with the plant or with wind-blown fragments of the dried plant produces the typical dermatitis. The oil causes swelling and redness of the lids and entire face, and a red blotchy eruption on the forearms that, after several attacks, may become generalized, with lichenification. It closely resembles chronic atopic dermatitis, with lichenification of the face, neck, and major flexures, and severe pruritus. The distribution also mimics that of photodermatitis, with ragweed dermatitis differentiated by its involvement of the upper eyelids and the retroauricular and submental areas. Chronic cases may continue into the winter, although signs and symptoms are most severe at the height of the season. Sesquiterpene lactones are the cause. Coexistent sensitization to pyrethrum may account for prolongation of ragweed dermatitis. Men outnumber women in hypersensitivity reactions; farmers outnumber patients of all other occupations.

### Marine plants

Numerous aquatic plants are toxic or produce contact dermatitis. Algae are the worse offenders. Freshwater plants are rarely of concern. Seaweed dermatitis is a type of swimmer's eruption produced by contact with a marine blue-green alga, which has been identified as *Lyngbya majuscula* Gomont. The onset is within a few minutes of leaving the ocean, with severe itching and burning, followed by dermatitis, blisters, and deep, painful desquamation that affects the areas covered by the bathing suit, especially the scrotum, perineum, and perianal areas and occasionally the breasts in women). Patch tests with the alga are neither necessary nor helpful because it is a potent irritant. Bathing in fresh water within 10 or 15 min of leaving the ocean may prevent the dermatitis. The Bermuda fire sponge may produce contact erythema multiforme. Trawler fishermen in the Dogger Bank area of the North Sea develop allergic dermatitis after contact with *Alcyonidium hirsutum*. This seaweedlike animal colony becomes caught in nets and produces erythema, edema, and lichenification on the fishermen's hands and wrists.

### Plant-associated dermatitis

Phototoxic contact dermatitis from plants is discussed in Chapter 3.

The residua of various insecticides on plants may also produce dermatitis. This is especially true of sprays containing arsenic and malathion. Radox (2-chloro-*N,N*-diallyl-acetamide) has been reported as the cause of hemorrhagic bullae on the feet of farmers. Lawn care companies spray herbicides and fungicides throughout the spring, summer, and fall. Dryene, thiuram, carbamates, and chlorothalonil are potential sensitizers in these workers, whose clothing frequently becomes wetted while spraying.

Barbs, bristles, spines, thorns, spicules, and cactus needles are some of the mechanical accessories of plants that may produce dermatitis. Sabra dermatitis is an occupational dermatitis resembling scabies. It is seen among pickers of the prickly pear cactus plant. It also occurs in persons handling Indian figs in Israel, where the condition is seen from July to November. The penetration of minute, invisible thorns into the skin is the cause. *Agave americana* is a low-growing plant used for ornamental purposes in many southwestern U.S. communities. Trimming during landscaping can induce an irritant dermatitis caused by calcium oxalate crystals. The stinging nettle is a common weed that bears tiny spines with biologically active substances such as histamine that produce itching and urticaria within minutes of contact.

### Plant derivatives

Sensitizing substances derived from plants are found in the oleoresin fractions that contain camphors, essential oils, phenols, resins, and terpenes. The chief sensitizers are the essential oils. These may be localized in certain parts of the plant, such as in the peel of citrus fruits, leaves of the eucalyptus tree, and bark of the cinnamon tree. Aromatherapy, an increasingly popular treatment for relief of stress, involves either inhaling or massaging with essential oils; this may cause allergic contact dermatitis in therapists or clients. Exposure to botanical extracts through many cosmetics and homeopathic remedies has resulted in an increasing number of reports of allergic contact sensitivity to individual ingredients, especially tea tree oil.

Cinnamon oil (*Cassia* oil) is a common flavoring agent, especially in pastries. Hand dermatitis in pastry bakers is often caused by cinnamon. It is also used as a flavor for lipstick, bitters, alcoholic and nonalcoholic beverages, toothpaste, and chewing gum. Perioral dermatitis may be caused by cinnamon in chewing gum. A 5% cinnamon solution in olive oil is used for patch testing. Eugenol, clove oil, and eucalyptus oil are used by dentists, who may acquire contact dermatitis from them. Anise, peppermint, and spearmint oils may cause sensitization.

Nutmeg, paprika, and cloves are causes of spice allergy. Fragrance mix is a useful indicator allergen. Lemon oil from lemon peel or lemon wood may cause sensitization in the various handlers of these substances. Citric acid may cause dermatitis in bakers. Lime oil in lime-scented shaving cream or lotion may cause photoallergy. *Myroxylon pereirae* contains numerous substances, including essential oils similar to the oil of lemon peel. It is known to cross-react with vanilla, cinnamon, and many other substances. Vanillin is derived from the vanilla plant and frequently produces contact dermatitis, vanillism, in those connected with its production and use.

Turpentine frequently acts as an irritant and as an allergic sensitizer (carene). It is contained in paints, paint thinners, varnishes, and waxes.

**Arberer W:** Contact allergy and medicinal plants. *J Dtsch Dermatol Ges* 2008; 6:15.

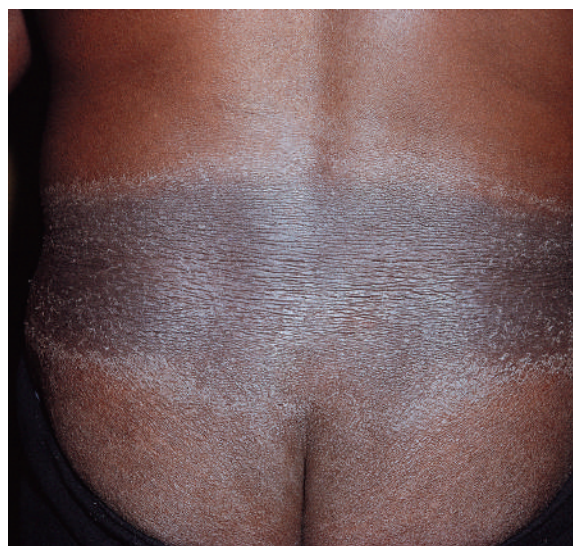- Crawford GH, et al:** Use of aromatherapy products and increased risk of hand dermatitis in massage therapists. *Arch Dermatol* 2004; 140:991.
- Dos Reis VM:** Dermatitis due to plants (phytodermatitis). *An Bras Dermatol* 2010; 85:479.
- Ferreira O, et al:** Erythema multiforme-like lesions revealing allergic contact dermatitis to exotic woods. *Cutan Ocul Toxicol* 2012; 31:61.
- Ghorpade A:** Tense bullae after *Toxicodendron* treatment for a twisted ankle. *Clin Exp Dermatol* 2010; 35:e24.
- Ghorpade A:** Contact dermatitis caused by Indian marking nut juice used to relieve ankle pain. *Int J Dermatol* 2014; 53:117.
- Gladman AC:** *Toxicodendron* dermatitis. *Wilderness Environ Med* 2006; 17:120.
- Goon AT, et al:** Plant dermatitis. *Indian J Dermatol* 2011; 56:707.
- Hershko K, et al:** Exploring the mango-poison ivy connection. *Contact Dermatitis* 2005; 52:3.
- Jack AR, et al:** Allergic contact dermatitis to plant extracts in cosmetics. *Semin Cutan Med Surg* 2013; 32:140.
- Koo B, et al:** Five-year-old boy with a diffuse erythematous rash with black crusts. *Pediatr Dermatol* 2010; 27:395.
- Linares T, et al:** Phytodermatitis caused by *Agave americana*. *Allergol Immunopathol (Madr)* 2011; 39:184.
- McGovern TW, et al:** Is it, or isn't it? Poison ivy look-a-likes. *Am J Contact Dermat* 2000; 11:104.
- Modi GM, et al:** Irritant contact dermatitis from plants. *Dermatitis* 2009; 20:63.
- Paulsen E, et al:** Systemic allergic dermatitis caused by Apiaceae root vegetables. *Contact Dermatitis* 2014; 70:98.
- Rutherford T, et al:** Allergy to tea tree oil. *Australas J Dermatol* 2007; 48:83.
- Sharma VK, et al:** *Parthenium* dermatitis. *Photochem Photobiol Sci* 2013; 12:85.
- Swinnen I, et al:** An update on airborne contact dermatitis: 2007–2011. *Contact Dermatitis* 2013; 68:232.
- Trehan I, et al:** Mango contact allergy. *J Travel Med* 2010; 17:284.
- Veien NK:** Systemic contact dermatitis. *Int J Dermatol* 2011; 50:1445.
- Verma P, et al:** Severe marking-nut dermatitis. *Dermatitis* 2012; 23:293.

## Dermatitis from clothing

A predisposition to contact dermatitis from clothing occurs in persons who perspire freely or who are obese and wear clothing that tends to be tight. Depending on the offending substance, various regions of the body will be affected. Regional location is helpful in identifying the sensitizing substance. The axillary folds are often involved; the vaults of the axillae are usually spared. Sites of increased perspiration and sites where evaporation is impeded, such as the intertriginous areas, will tend to leach dyes from fabrics to produce dermatitis. Areas where the material is tight against the skin, such as the waistband or neck, are frequently involved (Fig. 6-11). The thighs are affected when pants contain the offending allergen. The hands, face, and undergarment sites are usually spared, but otherwise these reactions may be scattered and generalized. Secondary changes of lichenification and infection occur frequently because of the chronicity of exposure.

Cotton, wool, linen, and silk fabrics were used exclusively before the advent of synthetic fabrics. Most materials are now blended in definite proportions with synthetics to produce superior lasting and esthetic properties. Dermatitis from cotton is virtually nonexistent. In most cases, there is no true sensitization to wool. Wool acts as an irritant because of the barbs on its fibers. These barbs may produce severe pruritus at points of contact with the skin, especially in the intertriginous areas. In persons with sensitive skin, such as those with atopic dermatitis, the wearing of wool is not advisable because of its mechanical irritative properties. Silk is a sensitizer, but rarely; the nature of the allergen is not known. Many patients believe their detergent is the source of a dermatitis, but this is rarely the case.

Numerous synthetic fibers are available for clothing and accessory manufacture, all of which again are remarkably free



**Fig. 6-11** Waistband clothing dermatitis.

of sensitizing properties. Polyvinyl resins are the plastics used in such apparel as raincoats, rainhoods, wristbands, suspenders, plastic mittens, and gloves. These also are only infrequently found to be causes of contact dermatitis.

The most common causes of clothing dermatitis are the fabric finishers, dyes, and rubber additives. Fabric finishers are used to improve the durability, appearance, and feel of a material. Antiwrinkling and crease-holding chemicals are mostly resins, which are incorporated into the fibers as they are being manufactured or applied to the finished fabric. Fabrics are treated to make them less vulnerable to the effects of perspiration and ironing. Clothing may be treated with these substances to make it dry rapidly after washing. They are used to make clothing fabrics shrink resistant and water and stain repellent. When all these uses are taken into consideration, the low incidence of dermatitis from these formaldehyde resin materials is remarkable.

Ethylene urea melamine formaldehyde resin and dimethylol dihydroxyethylene urea formaldehyde resin are the best screening agents. Many persons also react to formaldehyde and the formaldehyde-releasing preservatives such as quaternium 15. Avoidance of exposure of the skin to formaldehyde resin is most difficult. New clothes should be thoroughly washed twice before wearing the first time. Even with this precaution, however, allergens may still be present in sufficient quantities to continue the dermatitis. Jeans, Spandex, silk, 100% linen, 100% nylon, and 100% cotton that is not wrinkle resistant or colorfast are best tolerated. T-shirts, sweat-shirts and pants, white underclothes suitable for bleaching, and garments of mixed synthetic fibers with cotton fibers added to make them drip-dry are most likely to cause problems in these patients.

An increasing number of patients allergic to clothing dye are being reported. Synthetic fabrics such as polyester and acetate liners in women's clothing are prime causes, and women are more affected than men. Even infants may be affected, however, with dyes in diapers accounting for some cases. Many patients do not react to paraphenylene diamine, but only to the disperse dye allergens. The best screening agents are disperse blue 106 and 124. Suspected fabrics may be soaked in water for 15 min and applied under a patch for 72–96 h. Lymphomatoid contact allergy may result from clothing dye reactivity.

Spandex is a nonrubber (but elastic) polyurethane fiber. It is widely used for garments such as girdles, brassieres, and



socks, but is generally safe in the United States because it is free of rubber additives.

**Carlson RM, et al:** Diagnosis and treatment of dermatitis due to formaldehyde resin in clothing. *Dermatitis* 2004; 15:169.

**Donovan J, et al:** Allergic contact dermatitis from formaldehyde textile resins in surgical uniforms and nonwoven textile masks. *Dermatitis* 2007; 18:40.

**Malinauskiene L, et al:** Contact allergy from disperse dyes in textiles: a review. *Contact Dermatitis* 2013; 68:65.

**Narganes LM, et al:** Lymphomatoid dermatitis caused by contact with textile dyes. *Contact Dermatitis* 2013; 68:62.

**Nedorost S, et al:** Allergens retained in clothing. *Dermatitis* 2007; 18:212.

**Reich HC, et al:** Allergic contact dermatitis from formaldehyde textile resins. *Dermatitis* 2010; 21:65.

**Slodownik D, et al:** Textile allergy. *Contact Dermatitis* 2011; 65:38.

**Wentworth AB, et al:** Patch testing with textile allergens. *Dermatitis* 2012; 23:269.

**Zug KA, et al:** The value of patch testing patients with a scattered generalized distribution of dermatitis. *J Am Acad Dermatol* 2008; 59:426.

## Shoe dermatitis

Footwear dermatitis may begin on the dorsal surfaces of the toes and may remain localized to that area indefinitely (Fig. 6-12). There is erythema, lichenification, and, in severe cases, weeping and crusting. Secondary infection is frequent. In severe cases, an id reaction may be produced on the hands, similar to the reaction from fungal infection of the feet. A diagnostic point is the normal appearance of the skin between the toes, which has no contact with the offending substance. In fungal infections, the toe webs are usually involved. Another pattern seen is involvement of the sole with sparing of the instep and flexural creases of the toes. Also, purpuric reactions

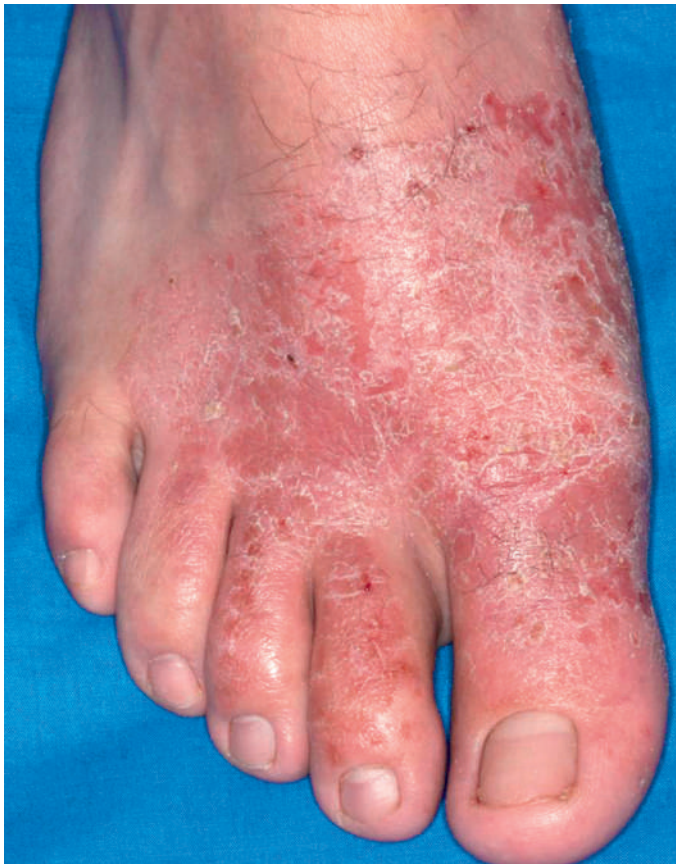

Fig. 6-12 Shoe dermatitis.

may occur to components of black rubber mix. Hyperhidrosis and atopy predispose to development of shoe allergy.

Shoe dermatitis is most frequently caused by the rubber accelerators mercaptobenzothiazole, carbamates, and tetramethylthiuram disulfide. Potassium dichromate in leather and the adhesives used in synthetic materials (especially *p*-tert-butylphenol formaldehyde resin) are also common shoe allergens. Diisocyanates are used in making foam rubber padding for athletic shoes and may cause allergy. Dimethyl fumarate is a preservative used in antihumidity sachets. It is a volatile substance and may deposit on shoes during its transport. Dimethyl fumarate is highly allergenic, and several outbreaks of shoe dermatitis in Europe have occurred secondary to this allergen. Other causative agents are felt, cork liners, formaldehyde, dyes, asphalt, and tar. Patch testing with pieces of various shoe parts may be done by soaking them for 15 min in water and applying them to the back for 72–96 h. Once the allergen has been identified, selection of shoes without the offending substance will lead to resolution. Unfortunately, this is a difficult process, because most shoes are made in areas without mandatory labeling requirements, and plastic, wooden, or fabric shoes that contain fewer allergens are often impractical.

**Castando-Tardan MP, et al:** Allergic contact dermatitis to Crocs. *Contact Dermatitis* 2008; 58:248.

**Matthys E, et al:** Shoe allergic contact dermatitis. *Dermatitis* 2014; 25:163–171.

**Munk R, et al:** Thiurams in shoe contact dermatitis. *Contact Dermatitis* 2013; 68:185.

**Švecová D, et al:** Footwear contact dermatitis from dimethyl fumarate. *Int J Dermatol* 2013; 52:803.

**Washaw EM, et al:** Shoe allergens. *Dermatitis* 2007; 18:191.

## Dermatitis from metals and metal salts

Metal dermatitis is most frequently caused by nickel and chromates. Usually, with the exception of nickel, the pure metals generally do not cause hypersensitivity; only when they are incorporated into salts do they cause reactions. Most objects containing metal or metal salts are combinations of several metals, some of which may have been used to plate the surface, thereby enhancing its attractiveness, durability, or tensile strength. For this reason, suspected metal-caused dermatitis should be investigated by doing patch tests to several of the metal salts.

Patients have developed a variety of dermatoses, most often eczematous in type, after placement of an orthopedic, gynecologic, or dental implant or a pacemaker/defibrillator or endovascular device. In general, patch testing in patients with known metal hypersensitivity before placement may help guide the specific type of device to be used. When patients are symptomatic with an eczematous process after implantation, patch testing will allow evaluation of allergy by testing with an extended tray, metals, a test disk of the metal used in the implant, and bone cement. A positive diagnosis of allergy at a minimum requires the appearance of a chronic dermatitis after placement, no other cause, a positive patch test for the suspected metal (or with drug-eluting stents, the drug), and healing after removal. This scenario is exceedingly uncommon; the removal of the foreign material needs to be judged as necessary, reasonable, and safe, and no objective criteria exist to determine the necessity. Dental and gynecologic implants are more frequently replaced; some patients do improve.

### Black dermatographism

Black or greenish staining under rings, metal wristbands, bracelets, and clasps is caused by the abrasive effect of



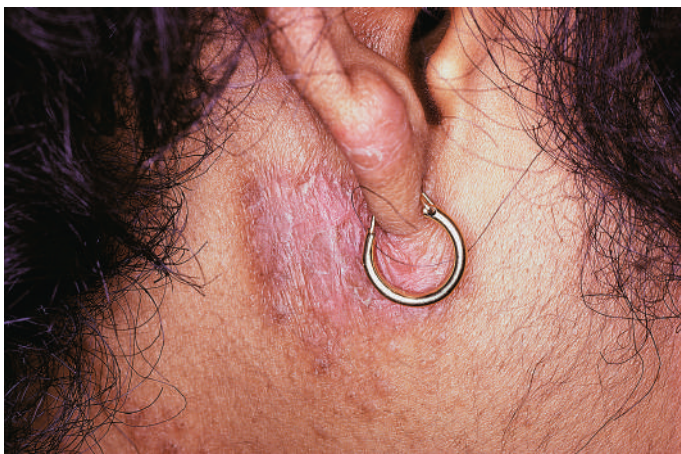

Fig. 6-13 Nickel dermatitis caused by earring.

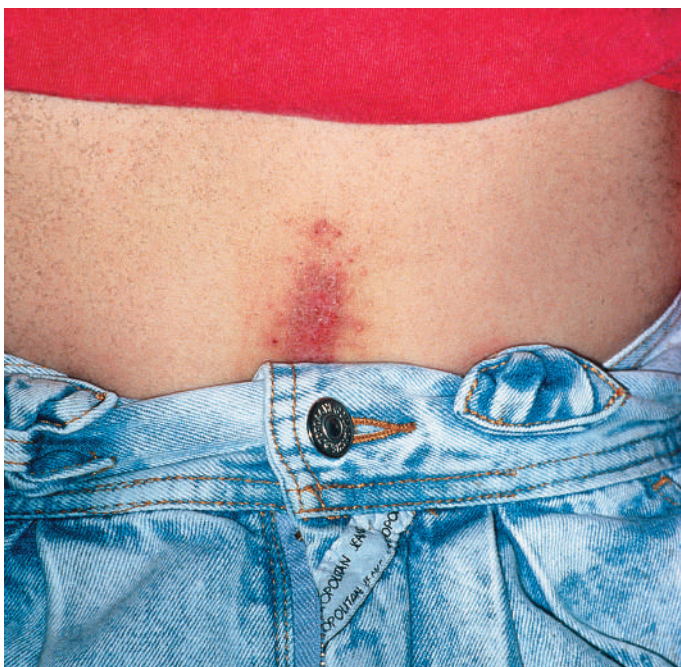

Fig. 6-14 Jeans button nickel-induced dermatitis.

cosmetics or other powders containing zinc or titanium oxide on gold jewelry. This skin discoloration is black because of the deposit of metal particles on skin that has been powdered and that has metal, such as gold, silver, or platinum, rubbing on it. Abrasion of the metal results because some powders are hard (zinc oxide) and can abrade the metal.

### Nickel

Because we are all constantly exposed to nickel, nickel dermatitis is a frequent occurrence. Although still most common among women, sensitization is increasing among men. A direct relationship between prevalence of nickel allergy and number of pierced sites has been documented. Nickel produces more cases of allergic contact dermatitis than all other metals combined. Erythematous and eczematous eruptions, sometimes with lichenification, appear beneath earrings (Fig. 6-13), bracelets, rings, wrist watches, clasps, and jeans buttons (Fig. 6-14). The snaps on clothing have been implicated in producing allergy in children; nickel is the most common cause of allergic contact dermatitis in children as well as adults. Patients with dermatitis on one ear or the preauricular area were reported to be allergic to their cell phone. The metal

portion often contains nickel, the implicated allergen. Nickel ranks highly on lists of occupationally induced allergic contact dermatitis.

Nickel dermatitis is seen most frequently on the earlobes. Piercing the earlobes with nickel-plated instruments or wearing nickel-plated jewelry readily induces nickel sensitivity. Earlobes should be pierced only with stainless steel instruments, and only stainless steel earrings should be worn until the ears have healed. Exposure to the metal may not be readily apparent most of the time. Even with gold jewelry, the clasps and solder may contain nickel. Nickel objects may be plated with chrome but may still cause nickel dermatitis through the leaching of some of the nickel through the small pores of the chromium plating.

Nickel oxides in green paints may produce nickel dermatitis. Homeopathic and complementary medicaments may also contain enough nickel to produce a contact allergy. Sweat containing sodium chloride may combine with nickel to form nickel chloride. This affects the degree of nickel dermatitis, being more severe in persons who perspire profusely.

The diagnosis is established by a positive patch test reaction to nickel sulfate. Nickel may be detected by applying a freshly prepared 1% alcohol solution of dimethylglyoxime and a 10% aqueous solution of ammonia separately in equal amounts to the test object. In the presence of nickel, the cotton swab used to apply the solution will turn orange-pink. A positive test always means that nickel is present, but a negative test does not rule out its presence. Sweat, blood, or saline may leach nickel from stainless steel.

Prophylactic measures should include the reduction of perspiration in those sensitive to nickel. Topical corticosteroids applied before exposure to nickel, such as before putting on a wristband, may be successful. Clasps and other objects are available in plastic material so that some of the exposure to nickel may be decreased. Polyurethane varathane 91 (Flecto) applied in three coats will give protection for several months. Treatment of nickel dermatitis consists of the application of topical corticosteroids. In Europe, laws regulating the maximum content of nickel in jewelry have led to a marked decrease in sensitization.

Hand eczema and pompholyx in nickel-sensitive or cobalt-sensitive patients have rarely been aggravated by ingested metals in the diet. In severe, treatment-resistant dermatitis, a specific diet low in nickel and cobalt may be tried.

### Chromium

The chromates are strongly corrosive and irritating to the skin and may act as primary irritants or as sensitizers to produce allergic contact dermatitis. Besides affecting employees in chromate works, chrome dermatitis is encountered among tanners, painters, dyers, photographers, polishers, welders, aircraft workers, diesel engine workers, and those involved with the bleaching of crude oils, tallows, and fats. Traces of dichromates in shoe leather and gloves may cause eczema of the feet and hands. Many zippers are chromium plated, and the nickel underneath may be the causative agent. Chromium metal and stainless steel do not produce contact dermatitis.

Zinc chromate paint is a source of dermatitis. Matches, hide glues, chrome alloys, cigarette lighters, and leather hatbands, sandals, or camera cases may cause chrome dermatitis. Anti-corrosion solutions used for refrigeration and other recirculation systems often contain chromates that produce dermatitis. Most workers in the cement industry who have cement eczema show positive patch tests to dichromates. Cement eczema is often a primary irritant dermatitis complicated by allergic contact dermatitis to the hexavalent chromates. The incidence of cement dermatitis has decreased significantly over the years, believed to be the result of the addition of ferrous



sulfate, delivery of premixed cement to the job site, and improved education.

The skin changes are multiform, ranging from a mild follicular dermatitis to widespread nodular and crusted eruptions, all being worse on exposed parts. Often the eruptions are slow to clear up, lasting from a few weeks to 6 months after contact has ceased. Heavy exposure of industrial workers to chromates may produce chrome ulcers on the backs of the hands and forearms, usually beginning around a hair follicle, or in the creases of the knuckles or finger webs. The hole begins as a small abrasion that deepens and widens as its edges grow thick, eventually forming a conical, indolent ulceration. Chrome ulcers may also arise on—and perforate—the nasal septum. Arsenic exposure may result in similar ulcers.

Diagnosis of chrome sensitivity is made by a positive patch test to potassium dichromate in petrolatum. The hexavalent chrome compounds are the most frequent cause of chrome dermatitis because these penetrate the skin more easily than the trivalent form. Both forms are sensitizers. Even with avoidance of chromate-containing materials, chromate-induced dermatitis is often persistent.

### Mercury

The mercurials may act not only as irritants but also as sensitizers. Thimerosal is a mercuric-containing preservative; it is an allergen that is rarely relevant. Allergy to this compound is likely to have been caused by exposure during childhood vaccinations and to tincture of merthiolate antiseptic. In general, these patients tolerate repeated vaccinations well. Most individuals are sensitized to the ethyl mercuric component of thimerosal; however, those who react to the thiosalicylic acid portion develop photodermatitis to piroxicam. Mercury in amalgam dental fillings has been shown in multiple large studies to cause oral lichenoid eruptions. The relationship is especially strong when the oral lesion, often with a painful erosion present, is apposed to a gold or amalgam filling. In many cases, when sensitivity is proved by patch testing and fillings are replaced, involution of the oral findings occurs.

### Cobalt

Cobalt is frequently combined with nickel as a contaminant, and patients allergic to cobalt typically are also allergic to nickel. The metals have similar properties but do not produce cross-reactions. Cobalt dermatitis may occur in those involved in the manufacture of polyester resins and paints, hard metals used for cutting and drilling tools, and cement. Cobalt dermatitis may also occur in producers of pottery, ceramics, metal alloys, glass, carbides, and pigments. Individuals may be exposed to cobalt in hair dye, flypaper, and vitamin B<sub>12</sub>. Blue tattoo pigment contains cobalt oxide. Rarely, cobalt chloride may cause nonimmunologic local release of vasoreactive materials, with a local urticarial response.

### Gold

Gold dermatitis may rarely occur from the wearing of gold jewelry. A predisposing factor in such patients is the presence of dental gold. Oral lichenoid eruptions have also been reported with gold, similar to the situation with mercury-containing amalgams. It is not uncommon to see positive reactions to gold when patch-testing patients with facial, eyelid, or widespread dermatitis of unknown cause. Although it is difficult to make a direct clinical correlation with any one piece of jewelry, occasionally patients will clear if they stop wearing all gold jewelry. In most patients, however, there is a lack of relevance.

A number of cases of dermatitis resulting from gold jewelry, especially gold rings, contaminated with radon and its decay

products have been reported. This may result in radiation dermatitis and squamous cell carcinoma of the finger. Apparently, the source of contaminated gold for the rings had been reclaimed, decayed-radon gold seeds.

### Other metals

Most other common metals are not important in causing contact dermatitis. Platinum dermatitis may occur from exposure to platinum salts and sprays in industry. Platinum rings, earrings, white gold spectacles, clasps, and other jewelry cause eruptions resembling those caused by nickel. Zinc, aluminum, copper sulfate, titanium, and antimony dermatitis rarely occur, although these metals may act as irritants.

**Atanaskova Mesinkovska N, et al:** The effect of patch testing on surgical practices and outcomes in orthopedic patients with metal implants. *Arch Dermatol* 2012; 148:687.

**De Medeiros LM, et al:** Complementary and alternative remedies: an additional source of potential systemic nickel exposure. *Contact Dermatitis* 2008; 58:97.

**Giorgini S, et al:** Occupational airborne allergic contact dermatitis caused by gold. *Dermatitis* 2010; 21:284.

**Heim KE, et al:** Children's clothing fasteners as a potential source of exposure to releasable nickel ions. *Contact Dermatitis* 2009; 60:100.

**Honari G, et al:** Hypersensitivity reactions associated with endovascular devices. *Contact Dermatitis* 2008; 59:7.

**Kornick R, et al:** Nickel. *Dermatitis* 2008; 19:3.

**Mahta V, et al:** Persistent nodular contact dermatitis to gold. *Indian J Dermatol Venerol Leprol* 2010; 76:397.

**Malinauskiene L, et al:** Systemic contact dermatitis in a gold-allergic patient after treatment with an oral homeopathic drug. *J Am Acad Dermatol* 2013; 68:e58.

**Mislankar M, et al:** Low nickel diet scoring system for systemic nickel allergy. *Dermatitis* 2013; 24:190.

**Reed KB, et al:** Retrospective evaluation of patch testing before or after metal device implantation. *Arch Dermatol* 2008; 144:999.

**Roberts H, et al:** Nickel allergy presenting as mobile phone contact dermatitis. *Australas J Dermatol* 2010; 51:23.

**Schalock PC, et al:** Hypersensitivity reactions to metallic implants: diagnostic algorithm and suggested patch test series for clinical use. *Contact Dermatitis* 2012; 66:4.

**Stuckert J, et al:** Low cobalt diet for dyshidrotic eczema. *Contact Dermatitis* 2008; 59:361.

**Suneja T, et al:** Blue-jean button nickel. *Dermatitis* 2007; 18:208.

**Thyssen JP:** Cobalt sensitization and dermatitis. *Dermatitis* 2012; 23:203.

**Thyssen JP, et al:** Patch test reactivity to metal allergens following regulatory intervention. *Contact Dermatitis* 2010; 63:102.

**Torgerson RR, et al:** Contact allergy in oral disease. *J Am Acad Dermatol* 2007; 57:315.

### Contact stomatitis

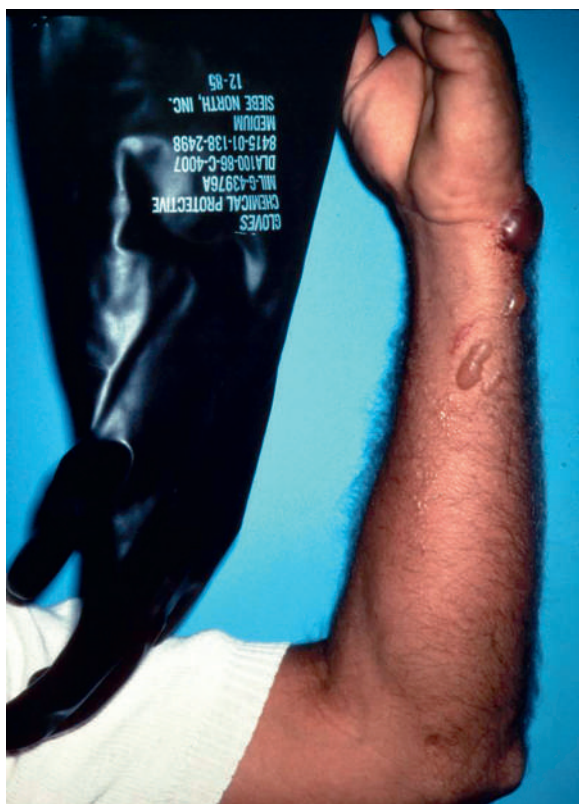The role of contact allergy in oral symptomatology is significant. Approximately 30% of patients with oral symptoms will have relevant allergens, most frequently metals used in dental fillings, food additives (flavorings and antioxidants), and dental products (acrylic monomers, epoxy resins, hardeners used in prosthodontics and dental impression materials). Chewing gums and dentifrices may also produce contact stomatitis. Ingredients responsible for this are hexylresorcinol, thymol, dichlorophen, oil of cinnamon, and mint.

Clinical signs may be bright erythema of the tongue and buccal mucosa with scattered erosions. Angular cheilitis may also develop. Oral lichenoid lesions may be caused by sensitization to metals in dental fillings and gold caps or crowns.

**Batchelor JM, et al:** Allergic contact stomatitis caused by a polyether dental impression material. *Contact Dermatitis* 2010; 63:296.

**Biron JF, et al:** Cinnamon-induced oral contact stomatitis. *Dent Today* 2013; 82:82.

**Krishen C, et al:** Dental allergic contact dermatitis. *Dermatitis* 2012; 23:222.



**Fig. 6-15** Occupational dermatitis from rubber glove allergy.

**Torgerson RR, et al:** Contact allergy in oral disease. *J Am Acad Dermatol* 2007; 57:315.

**Zug KA, et al:** Patch-testing North American lip dermatitis patients. *Dermatitis* 2008; 19:202.

## Rubber dermatitis

Rubber dermatitis generally occurs on the hands from wearing rubber gloves, as by surgeons, nurses, and homemakers (Fig. 6-15). The eruption is usually sharply limited to the gloved area but may spread up the forearms. Rubber dermatitis also develops from exposure to condoms, diaphragms, swim goggles, caps and scuba masks, wet suits, bandages for chronic leg ulcers, respirators, gas masks, rubber sheets, and cosmetic sponges. Shoe dermatitis may be caused by rubber allergy to insoles or sneakers (see earlier).

Natural and synthetic rubbers are used separately or in combination to make the final rubber product. The chemicals added in the rubber manufacturing process, most importantly the accelerators and antioxidants, are the common causes of allergic contact dermatitis. A similar list of additives is present in neoprene, a synthetic rubber. One particular class of additive in neoprene is causing an increasing number of reactions: the dialkyl thioureas. These are not in the standard patch trays and thus may escape detection unless applied as a supplemental allergen. Elastic in underwear is chemically transformed by laundry bleach into a potent sensitizing substance. The allergen is permanent and cannot be removed by washing. The offending garments must be thrown out and the use of bleaches interdicted.

## Accelerators

During the manufacturing process, chemicals are used to hasten the vulcanization of rubber. Among the numerous chemicals available, tetramethylthiuram disulfide, mercaptobenzothiazole, and diphenylguanidine are frequently used.

Tetramethylthiuram disulfide and its analogs, known as disulfiram and thiuram, may produce contact dermatitis when moist skin is exposed to the finished rubber product. In a 10-year study of 636 cases of allergy to rubber additives, thiuram mix was by far the most common sensitizer. Mercaptobenzothiazole is most often the cause in shoe allergy and thiuram in glove allergy.

## Antioxidants

Antioxidants are used to preserve rubber. Amine antioxidants, such as phenyl- $\alpha$ -naphthylamine, are most effective. Hydroquinone antioxidants may cause depigmentation of the skin, as well as allergic contact dermatitis. A frequent antioxidant sensitizer, propyl *p*-phenylenediamine, is used in tires, heavy-duty rubber goods, boots, and elastic underwear.

**Bendewald MJ, et al:** An 8-year retrospective review of patch testing with rubber allergens. *Dermatitis* 2010; 21:33.

**Cao LY, et al:** Allergic contact dermatitis to synthetic rubber gloves. *Arch Dermatol* 2010; 146:1001.

**Cravo M, et al:** Allergic contact dermatitis to rubber-containing bandages in patients with leg ulcers. *Contact Dermatitis* 2008; 58:371.

**Dall AB-H, et al:** Targeted testing with diethyothiurea often reveals clinically relevant allergic contact dermatitis caused by neoprene rubber. *Contact Dermatitis* 2012; 67:89.

**Nedorost S:** Clinical patterns of hand and foot dermatitis. *Dermatol Clin* 2009; 27:281.

**Warshaw EM, et al:** Positive patch-test reactions to mixed dialkyl thioureas. *Dermatitis* 2008; 19:190.

## Adhesive dermatitis

Cements, glues, and gums may cause adhesive dermatitis. Formaldehyde resin adhesives contain free formaldehyde, naphtha, glue, and disinfectants. Synthetic resin adhesives contain plasticizers; hide glues may contain chromates from the tanned leather, and other glues incorporate preservatives such as formaldehyde. Dental bonding adhesives may contain acrylic monomers and epoxy resins and hardeners. Pressure-sensitive adhesives contain rubber and acrylates, and anaerobic adhesives have primarily acrylates.

Vegetable gums, such as gum tragacanth, gum arabic, and karaya, may be used in denture adhesives, hair wave lotions, topical medications, toothpastes, and depilatories, and many cause contact dermatitis. Resins are used in adhesive tapes and in various adhesives such as tincture of benzoin. Turpentine is frequently found in rosin; abietic acid in the rosin is the causative sensitizer.

Adhesive tape reactions are frequently irritant in nature. Allergic reactions to adhesive tape itself are caused by the rubber components, accelerators, antioxidants, and various resins or turpentine. Some adhesive tapes contain acrylate polymers rather than rubber adhesives. These acrylates may cause allergic contact dermatitis. Pressure-sensitive adhesives are in widespread use in the tape and label industries. Allergens present in these adhesives include rosin, rubber accelerators, antioxidants, acrylates, hydroquinones, lanolin, thiourea compounds, and *N*-dodecylmaleamic compounds.

**Bhargava K, et al:** Eyelid allergic contact dermatitis caused by ethyl cyanoacrylate-containing eyelash adhesive. *Contact Dermatitis* 2012; 67:306.

**Corazza M, et al:** Allergic contact dermatitis in a volleyball player due to protective adhesive taping. *Eur J Dermatol* 2011; 21:430.

**Howard BK, et al:** Contact dermatitis from Dermabond. *Contact Dermatitis* 2010; 62:314.

**Meikle A, et al:** Allergic contact dermatitis at the epidural catheter site due to Mastisol liquid skin adhesive. *Can J Anaesth* 2012; 59:515.

**Ruhlemann D, et al:** Contact dermatitis to self-adhesive ECG electrodes. *Contact Dermatitis* 2010; 62:314.



## Synthetic resin dermatitis

The many varieties of synthetic resins preclude adequate discussion of each. The reactions during the manufacture of these substances are more common than those in their finished state.

### Epoxy resins

The epoxy resins in their liquid (noncured, monomer) form may produce severe dermatitis, especially during the manufacturing process. The fully polymerized or cured product is nonsensitizing. Nonindustrial exposure is usually to epoxy resin glues, nail lacquers, and artificial nails. Epoxy resins are used in the home as glues and paints (bathtub and refrigerator). Artists and sculptors frequently use epoxy resins.

Epoxy resins consist of two or more components, the resin and the curing agent. Approximately 90% of allergic reactions are to the resin and 10% to the hardener. The numerous curing agents include the amines, phenolic compounds, peroxides, and polyamides. These may be irritants and/or allergens. The resin, based on an acetone and phenol compound known as bisphenol A, in its raw state may cause allergic contact dermatitis. BIS-GMA, a combination of bisphenol A and glycidyl methacrylate, is the main allergen in dental bonding agents. Epoxy resins are used also as stabilizers and plasticizers. Their use in the manufacture of polyvinyl chloride (plastic) film has caused dermatitis from plastic handbags, beads, gloves, and panties.

### Polyester resins

Ordinarily, completely cured or polymerized resins are not sensitizers. The unsaturated polyester resins are dissolved and later copolymerized with vinyl monomers. Such polyester resins are used for polyester plasticizers, polyester fibers (Dacron), and polyester film (Mylar). The unsaturated polyester resins, on the other hand, will produce primary irritation in their fabrication or among sculptors. The dermatitis occurs typically as an eczematous eruption on the back of the hands, wrists, and forearms. Polyester resins are incorporated into other plastic material as laminates to give them strength; applications include boat hulls, automobile body putty, safety helmets, fuel tanks, lampshades, and skylights.

### Acrylic monomers

Cyanoacrylates are used widely as adhesives in a variety of home and commercial products. They are generally a rare cause of contact dermatitis. With the advent of skin-bonding agents, reports of allergy may increase. Multifunctional acrylic monomers may produce allergic or irritant contact dermatitis. Pentaerythritol triacrylate, trimethylolpropane triacrylate, and hexanediol diacrylate are widely used acrylic monomers. Printers handling multifunctional acrylic monomers in printing inks and acrylic printing plates may present with an erythematous, pruritic eruption, mainly of the hands and arms, swelling of the face, and involvement of the eyelids.

Orthopedic surgeons experience contact dermatitis from the use of acrylic bone cement (methyl methacrylate monomer) used in mending hip joints. Dentists and dental technicians are exposed when applying this to teeth. The sensitizer passes through rubber and polyvinyl gloves and may additionally cause paresthesias. In patients who are allergic to their acrylate dental prosthesis, coating this with UV light-cured acrylate lacquer may allow it to be worn without adverse effects.

Benzoyl peroxide is a popular acne remedy. It is also used for bleaching flour and edible oils and for curing plastics, such as acrylic dentures. Infrequently, an allergic contact dermatitis may result.

**Aalto-Korte K, et al:** Methacrylate and acrylate allergy in dental personnel. *Contact Dermatitis* 2007; 57:324.

**Bangsgaard N, et al:** Contact allergy to epoxy resin. *Contact Dermatitis* 2012; 67:73.

**Ozkaya E:** Neighborial allergy: a hidden cause of nonoccupational airborne contact dermatitis in a housewife from epoxy resin. *Dermatitis* 2012; 23:124.

**Shmidt E, et al:** Patch-testing with plastics and glues series allergens. *Dermatitis* 2010; 21:269.

**Strazzula L, et al:** Fingertip purpura in a dental student. *JAMA Dermatol* 2014; 150:784–785.

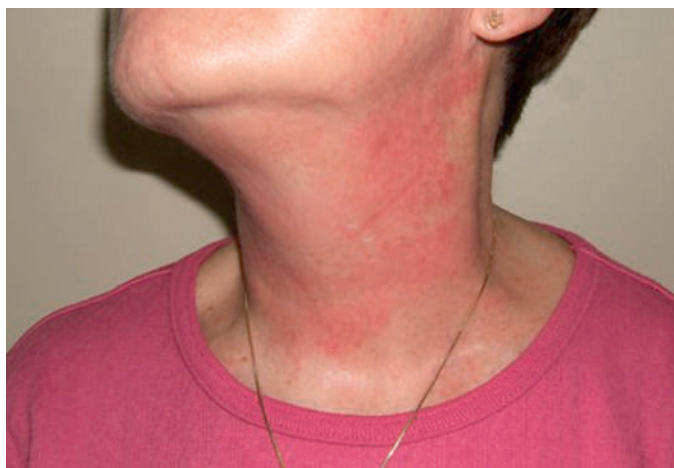## Cosmetic dermatitis

Cutaneous reactions to cosmetics may be divided into irritant, allergic hypersensitivity, and photosensitivity reactions. More than half the reactions occur on the face and are caused primarily by skin care products, nail cosmetics, shaving preparations, and deodorants. The leading cause of allergic contact dermatitis associated with cosmetics is from fragrance. A close second is preservatives, such as Bronopol (2-bromo-2-nitropropane-1,3-diol), Kathon CG, quaternium 15, Euxyl K 400, and imidazolidinyl urea. The third leading cause is *p*-phenylenediamine in hair dye. It is recommended that patch testing with the patient's own product, as long as it is applied to the skin as a leave-on product, be part of the evaluation.

### Fragrances

Almost all cosmetic preparations, skin care products, and many medications contain fragrance; even those labeled "non-scented" often contain a masking fragrance that may be a sensitizer. Even "fragrance-free" products have been documented to contain the raw fragrance ingredients, such as rose oil in "all-natural" products. Again, fragrances are the most common cosmetic ingredient causing allergic contact dermatitis. Photodermatitis, irritation, contact urticaria, and dyspigmentation are other types of reactions that fragrances may produce.

The most common individual allergens identified are cinnamic alcohol, oak moss, cinnamic aldehyde, hydroxy citronellal, musk ambrette, isoeugenol, geraniol, coumarin, lylal (Fig. 6-16), and eugenol. Frequently, unspecified allergens are the cause, because they are not listed on labels, and fragrances are combinations of many different ingredients. *Myroxylon pereirae* (balsam of Peru) will identify approximately half of those often unsuspected cases of allergic dermatitis, and additional testing with the fragrance mixes will identify over 90%. Additionally, a natural fragrance mixture of jasmine absolute, ylang-ylang oil, narcissus absolute, spearmint oil, and sandalwood oil is recommended. New products should be tested for tolerance in patients with a history of fragrance sensitivity.



**Fig. 6-16** Fragrance allergy, lylal.

About 1% of the population have fragrance sensitivity. Women still outnumber men, but as the frequency of fragrance contact reactions has increased over the years, men have shown a steeper increase in sensitivity. Fragrance is one allergen that may be transferred by skin-to-skin contact to a sensitive person, causing conjugal contact dermatitis. Ingestion of balsam-related foods, such as tomatoes, citrus fruits, and spices, may cause a flare in some sensitive patients. In particularly difficult-to-treat patients, balsam-restricted diets may be beneficial but are not easy to follow.

### Hair dyes

Permanent hair dyes incorporate *p*-phenylenediamine (PPDA), a popular but potent sensitizer that may cross-react with many chemicals. In rinses and tints, the azo dyes, acid violet 6B, water-soluble nigrosine, and ammonium carbonate may sensitize and cross-react with PPDA. Workers in the manufacture of PPDA, furriers, hairdressers, and those in the photographic and rubber vulcanization industries develop eruptions first on the back of the hands, wrists, forearms, eyelids, and nose, consisting of an eczematous, erythematous, oozing dermatitis. Lichenification and scaling are seen in the chronic type. In those with dyed hair, sensitivity is manifested by itching, redness, and puffiness of the upper eyelids, tops of the ears, temples, and back of the neck (Fig. 6-17). Beard dermatitis may be caused by coloring of the facial hair and eyelid dermatitis by dyeing eyelashes. PPDA added to temporary henna tattoos to make them darker has resulted in acute vesicular allergic reactions, some with scarring and hyperpigmentation. Kumkum is a common cosmetic in India, primarily smeared on the forehead of women to denote their marital status; one of many reported allergens in the product is PPDA.

For those sensitive to this type of hair dye, use of semipermanent or temporary dyes might be the solution. In the case of sensitivity to the latter, vegetable dyes such as henna may be tried. Metallic dyes are usually not favored by women but are frequently used by men as "hair color restorers." The metallic hair dyes may contain nickel, cobalt, chromium, or lead. Hair dyes containing FD&C and D&C dyes often do not cross-react with PPDA.

### Other hair products

Hair bleach products incorporate peroxides, persulfates, and ammonia, which may act as primary irritants. Hair bleaches

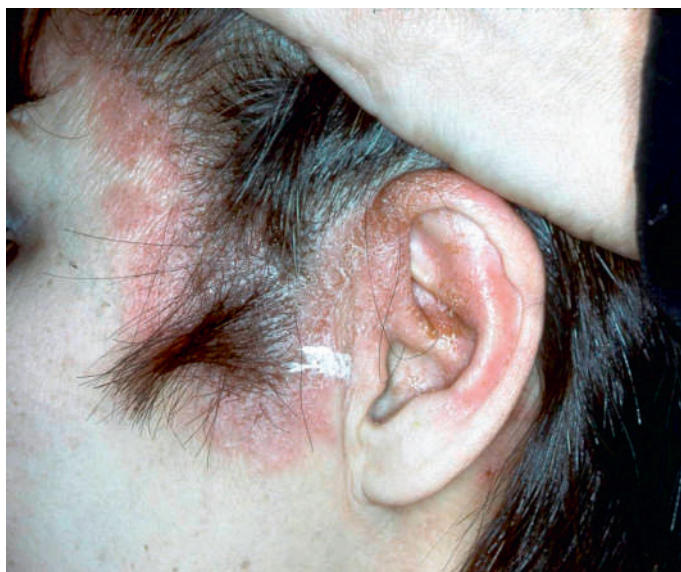

Fig. 6-17 Hair dye allergy.

that contain ammonium persulfate, a primary irritant, may produce a local urticarial and a generalized histamine reaction.

Several types of permanent wave preparations exist. The alkaline permanent wave preparations, which use ammonium thioglycolate, are rarely if ever sensitizers and usually cause only hair breakage and irritant reactions. The hot type, or acid perm, is a common sensitizer, the allergen being glyceryl monothioglycolate. Cosmetologists are at risk for development of hand dermatitis. The glyceryl monothioglycolate persists in the hair for at least 3 months after application and may cause a long-lasting dermatitis. It readily penetrates rubber and vinyl gloves. A more neutral pH permanent wave solution is less allergenic than the acid perms; however, allergy to cysteamine hydrochloride found in neutral permanent wave products may occur. This allergen does not penetrate household-weight latex gloves, and hair waved with it does not produce allergic reactions in sensitized individuals. Also, it is an amine salt, not a thioglycolate, so cross-reactivity is unlikely.

Hair straighteners using greases and gums are not sensitizers; however, the perfume incorporated in these preparations can be sensitizing. Thioglycolates are also used, and hair breakage may occur with these products.

Hair sprays may contain shellac, gum arabic, sunscreens, and synthetic resins as sensitizers, and allergic reactions occur infrequently. Lanolin is frequently incorporated into aerosol sprays.

Chemical depilatories containing calcium thioglycolate and the sulfides and sulfhydrates may cause primary irritant dermatitis. Mechanical hair removers include the mercaptans, waxes, and resins; resins may produce allergic dermatitis.

Hair tonics and lotions with tincture of cinchona produce allergic sensitization; tincture of cantharidin and salicylic acid cause primary irritation. Resorcin, quinine sulfate, and perfumes such as bay rum are also sensitizers.

### Nail products

Nail lacquers may contain tosylamide/formaldehyde resin and are a frequent cause of eyelid and neck dermatitis. Polishes free of this resin are available. Nail polish removers are solvents such as acetone, which can cause nail brittleness. The acrylic monomers in artificial nails, as well as the ethyl cyanoacrylate glue required to attach the prosthetic nail, may produce allergic sensitivity. Photoinitiating agents, such as benzophenone, used in photobonded acrylic sculptured nails are other potential allergens.

### Lipsticks

Various R and C dyes, sunscreens, shellac, flavoring agents, preservative, and lipstick perfumes may cause sensitization reactions. Lipsticks are tested as is. Lip plumpers may cause contact urticaria in those being kissed. Propolis is found in many so-called natural products, including lip balms, toothpastes, lotions, shampoos, and other cosmetics. Its main allergens are two types of caffeates.

### Eye makeup

In mascara, eye shadow, and eyeliners, the preservative, shellac, metals, base wax, and perfumes are the components that may produce sensitization, but this occurs rarely. False-positive reactions to some mascaras occur when a closed patch test is used. This is caused by the irritative qualities of the solvents. An open or nonocclusive patch test is recommended. A provocative use test in the antecubital fossae may ultimately be necessary. The rubber sponges used to apply eye makeup or cocamidopropylbetaine in eye makeup remover also cause eyelid dermatitis.



## Sunscreens

*p*-Aminobenzoic acid (PABA) and its derivatives (e.g., padimate O, padimate A, glycerol PABA), dibenzoylmethanes, salicylates, cinnamates, and benzophenones are photosensitizers as well as sensitizers. If allergy to PABA exists, its derivatives should be avoided, and the patient should be aware that thiazides, sulfonylurea antidiabetic medication, azo dyes, *p*-aminosalicylic acid, benzocaine, and PPDA all may cause dermatitis from cross-reactions. Oxybenzone is the most common sunscreen allergen.

## Bleaching creams

Hydroquinones are occasional sensitizers. Ammoniated mercury is a sensitizing agent formerly used in bleaching creams.

## Lanolin

The fatty alcohol lanolin is rarely a sensitizer on normal skin, and most cosmetic and skin care products do not cause dermatitis. It provokes allergic reactions more frequently in therapeutic agents used by atopic patients and in emollient products that may be used postsurgically.

## Dentifrices and mouthwashes

Dentifrices and mouthwashes contain sensitizers, such as the essential oils used as flavoring agents, preservatives, formalin, antibiotics, and antiseptics. Circumoral dermatitis and cheilitis may be caused by tartar-control types of dentifrice.

## Axillary antiperspirants

Aluminum salts, such as aluminum chloride and chlorhydroxide, and zinc salts, such as zinc chloride, act as primary irritants and may rarely produce a folliculitis. Aluminum chlorhydrate is considered to be the least irritating antiperspirant. Zirconium salt preparations, now removed from all antiperspirants, produced a granulomatous reaction. Zirconium-aluminum complexes, however, are often used as the active ingredient in topical antiperspirants and may produce granulomas. Quaternary ammonium compounds in some roll-on deodorants may produce allergic contact dermatitis.

## Axillary deodorants and feminine hygiene sprays

Fragrances, bacteriostats, and propellants cause the majority of the reactions seen with these products. Deodorants that contain cinnamic aldehyde can induce irritation on axillary skin even when tolerated on healthy skin in other sites.

## Cosmetic intolerance syndrome

Occasionally, a patient will complain of intense burning or stinging after applying any cosmetic. The patient usually has only subjective symptoms, but objective inflammation may also be present. The underlying cause may be difficult to document, even after thorough patch, photopatch, and contact urticaria testing. Endogenous disease, such as seborrheic dermatitis, rosacea, or atopic dermatitis, may complicate the assessment. Avoidance of all cosmetics, with only glycerin being allowed, for 6–12 months is often necessary to calm the reactive state. Adding back cosmetics one at a time, no more frequently than one a week, may then be tolerated.

**Alani JI, et al:** Allergy to cosmetics. *Dermatitis* 2013; 24:283–290.

**Alrowaishdi F, et al:** Allergic contact cheilitis caused by carnauba wax in a lip balm. *Contact Dermatitis* 2013; 69:318–319.

**Broides A, et al:** Contact dermatitis with severe scalp swelling and upper airway compromise due to black henna hair dye. *Pediatr Emerg Care* 2011; 27:745–746.

**Das S, et al:** Shellac. *Dermatitis* 2011; 22:220–222.

**De Groot AC:** Propolis. *Dermatitis* 2013; 24:263–282.

**Esdaile B, et al:** Allergic contact dermatitis caused by polyester-8 in a sunscreen moisturizer. *Contact Dermatitis* 2012; 67:105–106.

**Firoz EF, et al:** Lip plumper contact urticaria. *J Am Acad Dermatol* 2009; 60:861–863.

**Ghazavi MK, et al:** Photo-allergic contact dermatitis caused by isoamyl P-methoxycinnamate in an “organic” sunscreen. *Contact Dermatitis* 2011; 64:115–116.

**Hamilton T, et al:** Allergic contact dermatitis to preservatives and fragrances in cosmetics. *Skin Therapy Lett* 2011; 16:1–4.

**Handa S, et al:** Contact dermatitis to hair dye. *Indian J Dermatol Venereol Leprol* 2012; 78:683–690.

**Heisterberg M, et al:** Deodorants are the leading cause of allergic contact dermatitis to fragrance ingredients. *Contact Dermatitis* 2011; 64:258–264.

**Jacob SE, et al:** Benzyl alcohol: a covert fragrance. *Dermatitis* 2007; 18:232–233.

**Jefferson J, et al:** Update on nail cosmetics. *Dermatol Ther* 2012; 25:481–490.

**Jensen, P, et al:** Connubial allergic contact dermatitis caused by fragrance ingredients. *Dermatitis* 2012; 25:481–490.

**Kind F, et al:** Contact dermatitis to para-phenylenediamine in hair dye following sensitization to black henna tattoos. *J Dtsch Dermatol Ges* 2012; 10:572–578.

**Kumar P, et al:** Patch testing in suspected allergic contact dermatitis to cosmetics. *Dermatol Res Pract* 2014; 2014:695387.

**Landers MC, et al:** Permanent wave dermatitis. *Am J Contact Dermat* 2003; 14:157–160.

**Lee SS, et al:** Multicenter study of preservative sensitivity in patients with suspected cosmetic contact dermatitis in Korea. *J Dermatol* 2012; 39:677–681.

**Leventhal JS, et al:** Crystal deodorant-induced axillary granulomatous dermatitis. *Int J Dermatol* 2014; 53:e59–e60.

**Lev-Tov H, et al:** The sensitive skin syndrome. *Indian J Dermatol* 2012; 57:419–423.

**Miest RY, et al:** Diagnosis and prevalence of lanolin allergy. *Dermatitis* 2013; 24:119–123.

**Nardelli A, et al:** Results of patch testing with fragrance mix 1, fragrance mix 2, and their ingredients, and *Myroxylon pereirae* and *colophonium*, over a 21-year period. *Contact Dermatitis* 2013; 68:307–313.

**Nguyen JC, et al:** Allergic contact dermatitis caused by lanolin (wool) alcohol contained in an emollient in three postsurgical patients. *J Am Acad Dermatol* 2010; 62:1064–1065.

**Scheman A, et al:** Balsam of Peru. *Dermatitis* 2013; 24:153–160.

**Warshaw EM, et al:** Positive patch test reactions to lanolin. *Dermatitis* 2009; 20:79–88.

**Washaw EM, et al:** Patch test reactions associated with sunscreen products and the importance of testing to an expanded series. *Dermatitis* 2013; 24:176–182.

**Waters AJ, et al:** Photocontact allergy to PABA in sunscreens: the need for continued vigilance. *Contact Dermatitis* 2009; 60:172–173.

**Wetter DA, et al:** Results of patch testing to personal care product allergens in a standard series and a supplemental cosmetic series. *J Am Acad Dermatol* 2010; 63:789–798.

## Preservatives

Preservatives are added to any preparation that contains water to kill microorganisms and prevent spoilage. Such products include moist materials such as baby wipes, which when used in either infants or adults can produce reactions caused by preservatives. The most important class is formaldehyde and the formaldehyde-releasing compounds, including quaternium 15 (the leading preservative sensitizer in the United States), imidazolidinyl urea, diazolidinyl urea, DMDM hydantoin, and 2-bromo-2-nitropropane-1,3-diol.

Kathon CG, or methylchloroisothiazolinone/methylisothiazolinone (MCI/MI), and Euxyl K 400 (methyl-dibromoglutaronitrile and phenoxyethanol in 1:4 ratio) are other important preservative allergens. In Euxyl K 400, the methyl-dibromoglutaronitrile component produces the allergic response. This preservative may produce false-negative results on testing, so repeat open testing is indicated if a specific leave-on product is suspected of causing allergy. European regulations limit

exposure to methylidibromoglutaronitrile. As with similar laws regulating nickel in Europe, allergy to this preservative is also lowering in incidence over time.

Tea tree oil is an additive to some natural products that may serve as an antimicrobial. It is becoming a more frequent sensitizer as more products include this oil as a “natural” antimicrobial agent. Sorbic acid is a rare sensitizer among the preservatives; however, it is a cause of facial flushing and stinging through its action as an inducer of nonimmunologic contact urticaria. Benzalkonium chloride is widely used but a rare sensitizer. Triclosan and benzyl alcohol are weak sensitizers. Thimerosal is discussed earlier.

### Formaldehyde and formaldehyde-releasing agents

Formaldehyde is used rarely, primarily in shampoos. Because it is quickly diluted and washed away, sensitization through this exposure is rare. Formaldehyde releasers are polymers of formaldehyde that may release small amounts of formaldehyde under certain conditions. Allergy may be to the formaldehyde-releasing preservatives (which act as antibacterial and antifungal agents in their own right) or to the released formaldehyde. Cross-reactivity among them is common, so when allergy is proved to one compound and avoidance does not clear the eruption, screening for clinically relevant reactions to the others is indicated. This may be done by repetitive open application testing to the leave-on product or by extended patch testing.

### Parabens

Allergic contact dermatitis may develop from parabens, which are used in cosmetics, foods, drugs, dentifrices, and suppositories. The paraben esters (methyl, ethyl, propyl, and butyl *p*-hydroxybenzoates) are used in low concentrations in cosmetics and rarely cause dermatitis. They are found in higher concentration in topical medicaments and may be the cause of allergic reactions. Perpetuation of a dermatitis, despite effective topical medication, suggests the possibility of paraben or corticosteroid sensitivity or the presence of another sensitizer. Parabens, which are frequently used as bacteriostatic agents, are capable of producing immunologically mediated, immediate systemic hypersensitivity reactions. Cross-reactivity to *p*-phenylenediamine and benzocaine occurs in some individuals.

### *p*-Chloro-metaxyleneol (PCMX)

This chlorinated phenol antiseptic is used in many over-the-counter products with the disinfectant properties of *p*-chloro-metacresol. Sensitization occurs primarily through exposure to betamethasone-containing cream. PCMX is cross-reactive with *p*-chloro-metacresol.

**Aakhus AE, et al:** Allergy to methylidibromoglutaronitrile/phenoxylethanol (Euxyl K 400): regulatory issues, epidemiology, clinical characteristics, and management. *Dermatitis* 2011; 22:127–140.

**Boyapati A, et al:** Allergic contact dermatitis to methylisothiazolinone: exposure from baby wipes causing hand dermatitis. *Australas J Dermatol* 2013; 54:264–267.

**Chow ET, et al:** Frequency of positive patch test reactions to preservatives. *Australas J Dermatol* 2013; 54:31–35.

**Curry EJ, et al:** Benzyl alcohol allergy. *Dermatitis* 2005; 16:203.

**Maier LE, et al:** Hand dermatitis. *Dermatol Clin* 2001; 27:251–264.

**Maio P, et al:** Contact allergy to methylchloroisothiazolinone/methylisothiazolinone (MCI/MI). *Cutan Ocul Toxicol* 2012; 31:151–153.

**Schnuch A, et al:** Risk of sensitization to preservatives estimated on the basis of patch test data and exposure, according to a sample of 3541 leave-on products. *Contact Dermatitis* 2011; 65:167–174.

**Wilson M, et al:** Chloroxylenol. *Dermatitis* 2007; 18:120.

**Yim E, et al:** Contact dermatitis caused by preservatives. *Dermatitis* 2014; 25:215–231.

## Vehicles

Formulation of topically applied products is complex, and additives are blended to make a pleasant base for carriage of the active ingredient to the skin. Various emulsifiers, humectants, stabilizers, surfactants, and surface active agents are used to make esthetically pleasing preparations. These may cause irritation, erythema, and allergy. The surfactant cocamidopropyl betaine produces dermatitis of the head and neck in consumers and the hands in hairdressers, often from its presence in shampoos. Propolis and lanolin are discussed previously under “Cosmetic dermatitis.”

### Propylene glycol

Propylene glycol is widely used as a vehicle for topical medications, cosmetics (especially antiperspirants), and various emollient lotions. It is used in the manufacture of automobile brake fluid and alkyd resins, as a lubricant for food machinery, and as an additive for food colors and flavoring agents. Propylene glycol must be considered as a sensitizer able to produce contact dermatitis, and it can cause a flare of the contact dermatitis when ingested. It is tested as a 4% aqueous solution, but irritant reactions or false-negative results are common. A use test of the implicated propylene glycol-containing products may be required.

### Ethylenediamine

Ethylenediamine is used as a stabilizer in medicated creams. It may cause contact dermatitis and cross-react with internally taken aminophylline, which consists of theophylline and ethylenediamine. Hydroxyzine is a piperazine derivative that is structurally based on a dimer of ethylenediamine, to which patients sensitive to the stabilizer may develop a generalized itchy, red eruption that recurs each time hydroxyzine is taken orally.

**Al Jasser M, et al:** Propylene glycol. *Skin Therapy Lett* 2011; 16:5–7.

**Jacob SE, et al:** Cocamidopropyl betaine. *Dermatitis* 2008; 19:157–160.

**Lowther A, et al:** Systemic contact dermatitis from propylene glycol. *Dermatitis* 2008; 19:105–108.

**Reid N, et al:** Worsening of contact dermatitis by oral hydroxyzine: a case report. *Dermatol Online J* 2013; 19:4.

**Suuronen K, et al:** Occupational contact allergy to cocamidopropyl betaine and its impurities. *Contact Dermatitis* 2012; 66:286–292.

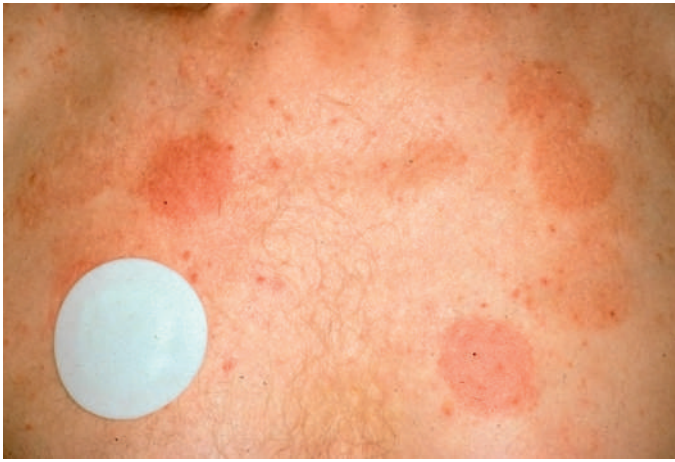**Warshaw EM, et al:** Positive patch-test reactions to propylene glycol. *Dermatitis* 2009; 20:14–20.

## Topical drug contact dermatitis

Drugs, in addition to their pharmacologic and possible toxic action, also possess sensitizing properties. Sensitization may occur not only from topical application but also from ingestion, injection, or inhalation. Some drugs, such as the antihistamines, including topical doxepin, sensitize much more frequently when applied topically than when taken orally. With the advent of transdermal patches for delivery of medications such as nitroglycerin, hormones, nicotine, clonidine, fentanyl, lidocaine, and scopolamine, reports of sensitization have been increasing (Fig. 6-18). Clonidine induces the highest rate of allergic reactions. At times, erythema multiforme like reactions may occur with transdermally applied drugs.

Some drugs may produce sensitization of the skin when applied topically; if the medication is taken later internally, an acute flare at the site of the contact dermatitis may result. This anamnestic (recalled) eruption or systemic contact dermatitis can occur with antihistamines, sulfonamides, and penicillin. The same is true of the local anesthetic ointments containing “caine” medications. Usually, if sensitization occurs when using transdermal patches, the drugs do not cause systemic





**Fig. 6-18** Nitroglycerin patch allergy.

contact dermatitis when taken orally. The important topical medications that cause irritation or allergic contact dermatitis are discussed next.

### Local anesthetics

Physicians and dentists may develop allergic contact dermatitis from local anesthetics. In addition, the continued use of these local anesthetics as antipruritic ointments and lotions causes sensitization of the skin. Benzocaine is a frequently used topical antipruritic and is the most common topical sensitizer of this group. Itchy dermatitis of the anogenital area may be caused by a topical anesthetic.

Local anesthetics may be divided into two groups. The first group includes the *p*-aminobenzoic acid esters, such as benzocaine, butethamine, chlorprocaine, procaine (Novacaine), and tetracaine. The second group, which sensitizes much less frequently, includes the amides, such as dibucaine (Nupercainal), lidocaine (Lido-Mantle, EMLA, Lidoderm patch, LMX, Xylocaine), mepivacaine (Carbocaine), and prilocaine. In addition, the preservative methylparaben, frequently found in these prepared solutions, may cause hypersensitivity reactions that can easily be misattributed to the local anesthetics. It should be kept in mind that numerous cross-reactions are seen in benzocaine-sensitive individuals. These are discussed earlier in the sections on sunscreens and preservatives. Lidocaine can induce contact urticaria as well.

### Antimicrobials

Physicians, dentists, nurses, and other medical personnel, as well as patients, especially those with chronic leg ulcers, may develop contact dermatitis from various antibiotics. Neomycin and bacitracin are only behind nickel, fragrances (and the related *Myroxylon perei*), and quaternium 15 as the most common sensitizers in the United States. As a topical antibiotic, neomycin sulfate has been incorporated into innumerable ointments, creams, and lotions. It is present in such preparations as underarm deodorants, otic and ophthalmologic preparations, and antibiotic creams and ointments available without prescription. The signs of neomycin sensitivity may be those of a typical contact dermatitis but are often signs of a recalcitrant skin eruption that has become lichenified and even hyperkeratotic. This may result because many topical agents contain several types of antibiotic but also often have corticosteroids present. This picture may be seen in persistent external otitis, lichen simplex chronicus of the nuchal area, or dermatophytosis between the toes. A late-appearing reaction on patch testing can occur, so an assessment at day 7 is recommended.

Allergy to bacitracin increased dramatically because of its use after minor surgical procedures. After clean surgical procedures, white petrolatum is as effective in wound healing as antibiotic ointment, and it prevents more infection and does not carry the allergenic potential. Petrolatum should be used after clean cutaneous surgery; antibiotic ointments are not necessary. With evidence indicating that use of topical antibiotics after clean cutaneous surgery is waning, the frequency of bacitracin allergy should decrease as well. There is a high rate of co-reaction (not cross-reaction) with neomycin because of simultaneous exposures. Contact urticaria and anaphylaxis are reported more often with bacitracin than with other antibiotics.

Mafenide acetate, the topical antimicrobial found in Sulfamylon, a burn remedy, may cause allergic contact dermatitis, as can metronidazole.

### Antifungal agents

Allergic contact dermatitis to imidazole and other antifungal agents may occur. There is a high cross-reactivity rate among miconazole, isoconazole, clotrimazole, and oxiconazole because of their common chemical structure.

### Phenothiazine drugs

Handling injectable solutions and tablets may produce dermatitis in patients sensitized to chlorpromazine and other phenothiazine derivatives. The reactions may be photoallergic or nonphotoallergic.

### Corticosteroids

Numerous reports of large series of patients who have developed allergy to common corticosteroid preparations emphasize the need for a high index of suspicion when treating patients with chronic dermatitis who fail to improve, or who worsen, when topical steroidal agents are used. Once sensitized to one type of corticosteroid, cross-sensitization may occur. The corticosteroids have been separated into the following four structural classes:

- Class A is the hydrocortisone, tixocortol pivalate group.
- Class B is the triamcinolone acetonide, budesonide group.
- Class C is the betamethasone group.
- Class D is the hydrocortisone-17-butyrate group.

There are frequent cross-reactions between classes B and D. Tixocortol pivalate and budesonide have been found to be the best screening agents, finding 93% of steroid allergies. Patch testing to the implicated leave-on product may be useful. An empiric trial of desoximetasone (Topicort) or mometasone (Elocon) in the absence of patch testing will give the best chance of selecting a topical steroid with an extremely low risk of sensitization.

**Cronin H, et al:** Anaphylactic reaction to bacitracin ointment. *Cutis* 2009; 83:127.

**Isaksson M:** Systemic contact allergy to corticosteroids revisited. *Contact Dermatitis* 2007; 57:368.

**Javanovic M, et al:** Contact urticaria and allergic contact dermatitis to lidocaine in a patient sensitive to benzocaine and propolis. *Contact Dermatitis* 2006; 54:124.

**Jean SE, et al:** Contact dermatitis in leg ulcer patients. *J Cutan Med Surg* 2009; 13:S38.

**Musel AL, et al:** Cutaneous reactions to transdermal therapeutic systems. *Dermatitis* 2006; 17:109.

**Nihawan RI, et al:** Systemic contact dermatitis. *Dermatol Clin* 2009; 27:355.

**Ramirez P, et al:** Allergic contact dermatitis from antihemorrhoidal ointments. *Dermatitis* 2010; 21:176.

**Sasseville K:** Contact dermatitis from topical antibiotics. *Eur J Dermatol* 2011; 3:311.

- Timmermans MW, et al:** Allergic contact dermatitis from EMLA cream. *J Dtsch Dermatol Ges* 2009; 7:237.
- Torres MJ, et al:** Hypersensitivity reactions to corticosteroids. *Curr Opin Allergy Clin Immunol* 2010; 10:273.
- Veien NK:** Systemic contact dermatitis. *Int J Dermatol* 2011; 50:1445.
- Warshaw EM, et al:** Patch-test reactions to topical anesthetics. *Dermatitis* 2008; 19:81.
- Wu PA, et al:** Topical antibiotic use following dermatologic procedures. *J Am Acad Dermatol* 2013; 68:516.

## Occupational contact dermatitis

Workers in various occupations are prone to contact dermatitis from primary irritants and allergic contactants. In certain occupations, it is a common occurrence. Irritant contact dermatitis occurs more frequently in the workplace, but it tends to be less severe and less chronic than allergic contact dermatitis (see Fig. 6-15). Occupational skin disease has declined over the past 30 years but still constitutes approximately 10% of all occupational disease cases. Agriculture, forestry, and fishing have the highest incidence of occupational skin disease, with the manufacturing and health care sectors contributing many cases as well.

Irritant contact dermatitis is often present in wet-work jobs, and allergy occurs in hairdressers, machinists, and many others with unique exposures to multiple sensitizing chemicals. The hands are the parts most affected and are involved in 60% of allergic reactions and 80% of irritant dermatitis. Epoxy resin is an allergen overrepresented when evaluating occupational patients. The allergens most frequently encountered in occupational cases are carba mix, thiuram mix, epoxy resin, formaldehyde, and nickel.

## Management

Occupational contact dermatitis is managed by eliminating contact of the skin with irritating and sensitizing substances. The work environment should be carefully controlled, with use of all available protective devices to prevent accidental and even planned exposures. Personal protective measures, such as frequent clothing changes, cleansing showers, protective clothing, and protective barrier creams should be used as appropriate. Hand-cleansing procedures should be thoroughly surveyed, with particular attention to the soaps available and the solvents used.

Treatment of the dermatitis follows closely that recommended for *Toxicodendron* dermatitis. Topical corticosteroid preparations are especially helpful in the acute phase. For dry, fissured hands, soaking them in water for 20 min at night followed immediately on removing (without drying them) with triamcinolone 0.1% ointment will help hydrate and heal. Topical tacrolimus ointment and pimecrolimus cream may assist in maintenance therapy, along with high-lipid content moisturizing creams. When rubber and polyvinyl gloves cannot be used against irritant and allergenic substances, protective skin creams may offer a solution but are often impractical. A wide variety is available, but two main types are used: for "wet work," to protect against acids, alkalis, water-based paints, coolants, and cutting oils with water, and for "dry work," to protect against oils, greases, cutting oils, adhesive, resins, glues, and wood preservatives.

Unfortunately, despite the best efforts at treatment and prevention, the prognosis for occupational skin disease is guarded. One-third to one-quarter heal, and another one-third to one-half improve, with the remainder the same or worse. A change or discontinuance of the job does not guarantee relief; many individuals continue to have persistent postoccupational dermatitis. The importance of thorough patient education cannot

be overemphasized. Atopic patients, males with chromate allergy, females with nickel allergy, those with a delay in diagnosis before institution of treatment, and construction industry workers fare the worst, whereas irritation from metalworking fluids, reactions to urushols in foresters, and allergic contact dermatitis to acrylic monomers or amine curing agents is usually short-lived.

- Bauer A, et al:** Intervention for preventing occupational irritant hand dermatitis. *Cochrane Database Syst Rev* 2010; 6:CD004414.
- Bourrain JL:** Occupational contact urticaria. *Clin Rev Allergy Immunol* 2006; 30:39.
- Diepgen TL, et al:** Management of chronic hand eczema. *Contact Dermatitis* 2007; 57:203.
- Friis UF, et al:** Occupational irritant contact dermatitis diagnosed by analysis of contact irritants and allergens in the work environment. *Contact Dermatitis* 2014; Oct 10.
- Holness DL, et al:** Workers with occupational contact dermatitis. *Occup Med* 2012; 62:455.
- Keegel T, et al:** The epidemiology of occupational contact dermatitis (1997–2007). *Int J Dermatol* 2009; 48:571.
- Mai Konen T, et al:** Long-term follow-up study of occupational hand eczema. *Br J Dermatol* 2010 [Epub].
- Nicholson PJ:** Occupational contact dermatitis. *Clin Dermatol* 2011; 29:325.
- Nicholson PJ, et al:** Evidence-based guidelines for the prevention, identification and management of occupational contact dermatitis and urticaria. *Contact Dermatitis* 2010; 63:177.
- Patruno C, et al:** Occupational allergic contact dermatitis to acrylic nails in beauticians. *Occup Environ Med* 2012; 69:772.
- Ponten A, et al:** Occupational allergic contact dermatitis caused by sterile non-latex protective gloves. *Contact Dermatitis* 2012; 68:103.
- Rietschel RL, Fowler JF Jr:** *Fisher's Contact Dermatitis*, 6th edn. Hamilton: Lippincott, BC Decker, 2008.
- Shalock PC, et al:** Protection from occupational allergens. *Curr Probl Dermatol* 2007; 34:58.
- Slodownik D, et al:** Occupational factors in skin diseases. *Curr Probl Dermatol* 2007; 35:173.
- Smedley J:** Concise guidance: diagnosis, management and prevention of occupational contact dermatitis. *Clin Med* 2010; 10:487.
- Sohrabian S, et al:** Contact dermatitis in agriculture. *J Agromed* 2007; 12:3.
- Suneja T, et al:** Occupational dermatoses in health care workers evaluated for suspected allergic contact dermatitis. *Contact Dermatitis* 2008; 58:285.
- Warshaw EM, et al:** Occupational contact dermatitis in hairdressers/cosmetologists. *Dermatitis* 2012; 23:258.
- Zhai H, et al:** Protection from irritants. *Curr Probl Dermatol* 2007; 34:47.

## Contact urticaria

Contact urticaria may be defined as a wheal and flare reaction occurring when a substance is applied to the intact skin. Urticaria is only one of a broad spectrum of immediate reactions, including pruritus, dermatitis, local or general urticaria, bronchial asthma, orolaryngeal edema, rhinoconjunctivitis, gastrointestinal distress, headache, or anaphylactic reaction. Any combination of these is subsumed under the expression "syndrome of immediate reactions."

Contact urticaria may be nonimmunologic (no prior sensitization), immunologic, or of unknown mechanism. The nonimmunologic type is the most common and may be caused by direct release of vasoactive substances from mast cells. The allergic type tends to be the most severe, because anaphylaxis is possible. The third type has features of both other types.

### Nonimmunologic mechanism

The nonimmunologic type of reaction occurs most frequently and may produce contact urticaria in almost all exposed individuals. Examples of this type of reaction are seen with nettle rash (plants), dimethyl sulfoxide (DMSO), sorbic acid, benzoic acid, cinnamic aldehyde, cobalt chloride, and Trafuril.



### Immunologic mechanism

The immunologic reaction is of the immediate (IgE-mediated) type of hypersensitivity. Latex, potatoes, phenylmercuric propionate, and many other allergens have been reported to cause this type.

### Uncertain mechanism

The uncertain type of reaction occurs with agents that produce contact urticaria and a generalized histamine type of reaction but lack a direct or immunologic basis for the reaction.

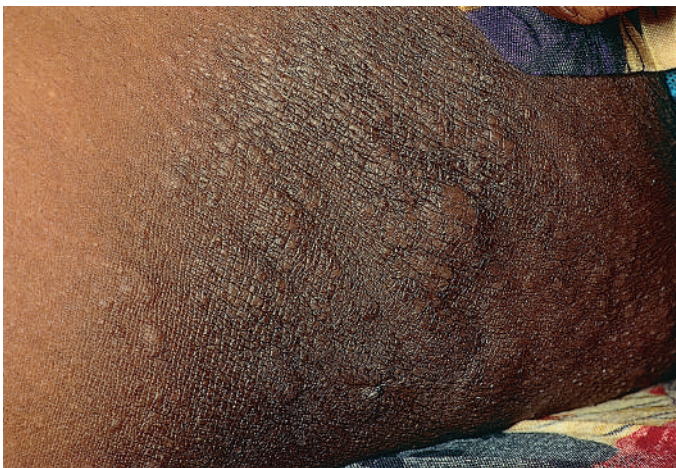### Substances causing contact urticaria

Many different substances can elicit such a reaction. Contact urticaria is seen in homemakers and food workers who handle raw vegetables, raw meats and fish, shellfish, and other foods. Raw potatoes have been shown to cause not only contact urticaria but also asthma at the same time. It has been seen in hairdressers who handle bleaches and hair dyes containing ammonium persulfate, in whom the contact urticaria is accompanied by swelling and erythema of the face, followed by unconsciousness. Caterpillars, moths, and hedgehogs may cause contact urticaria just by touching the skin.

Additional substances inducing this reaction are oatmeal, flour, meat, turkey skin, calf liver, banana, lemon, monoamine, benzophenone, nail polish, tetanus antitoxin, streptomycin, cetyl alcohol, stearyl alcohol, estrogenic cream, cinnamic aldehyde, sorbic acid, benzoic acid, castor bean, lindane, carrots, spices, wool, silk, dog and cat saliva, dog hairs, horse serum, ammonia, sulfur dioxide, formaldehyde, acrylic monomers, exotic woods, wheat, cod liver oil, and aspirin.

Bacitracin ointment may cause anaphylactic reactions when applied topically, especially to chronic leg ulcers; however, it may rarely occur after application to acute wounds (Fig. 6-19).

Universal precautions not only led to a marked increase in delayed-type hypersensitivity reaction to rubber additives, but also to many reports of contact urticaria and anaphylaxis to latex. Most of these reactions occur in health professionals. Reactions are characterized by itching and swelling of the hands within a few minutes of donning the gloves, usually resolving within an hour after removing them. In patients with continued exposure, the eruption may eventually appear as chronic eczema. Glove powder may aerosolize the allergen and produce more generalized reactions. Although these reactions may occur on the job, many cases present as death or near-death events when sensitized individuals undergo surgery or other procedures, especially when there is mucosal exposure (e.g., dental care, rectal examination, childbirth).



**Fig. 6-19** Contact urticaria caused by bacitracin applied to punch biopsy site.

In addition to health care workers, who have a reported incidence of 3–10%, atopic persons and spina bifida patients are other risk groups for the development of type I allergy to latex protein. The sensitized individual should also be aware that up to 50% of patients have a concomitant fruit allergy to foods such as banana, avocado, kiwi, chestnut, and passion fruit.

### Testing

The usual closed patch tests do not show sensitivity reactions. Instead, open patch tests are performed for eliciting immediate-type hypersensitivity. The substance is applied to a 1-cm<sup>2</sup> area on the forearm and observed for 20–30 min for erythema that evolves into a wheal and flare response. When foods are tested, a small piece of the actual food is placed on the skin. Rubber glove testing can be done by applying one finger of a latex glove to a moistened hand for 15 min. If no reaction is observed, the entire glove is worn for another 15–20 min. The radioallergosorbent test (RAST) detects 75% of latex-allergic individuals. There is no standard allergen available for prick testing. Prick, scratch, or intradermal testing is undertaken only when there are problems of interpretation of the open patch tests. These tests have produced anaphylactic reactions and should only be attempted when support for this complication is available.

### Management

Avoidance of the offending substance is best, but if this is not possible, antihistamines are of benefit. If generalized urticaria or asthmatic reactions occur, systemic glucocorticoids are best. For anaphylaxis, epinephrine and supportive measures are needed.

**Alikhan A, et al:** Produce-induced contact urticarial and dermatitis. *Contact Dermatitis* 2009; 60:174.

**Bourrain JL:** Occupational contact urticaria. *Clin Rev Allergy Immunol* 2006; 30:39.

**Bousquet J, et al:** Natural rubber latex allergy among health care workers. *J Allergy Clin Immunol* 2006; 118:447.

**Cronin H, et al:** Anaphylactic reaction to bacitracin ointment. *Cutis* 2009; 83:127.

**Doutre MS:** Occupational contact urticaria and protein contact dermatitis. *Eur J Dermatol* 2005; 15:419.

**Firoz EF, et al:** Lip plumper contact urticaria. *J Am Acad Dermatol* 2009; 60:861.

**Gimenez-Arnau A, et al:** Immediate contact skin reactions, an update of contact urticaria, contact urticarial syndrome and protein contact dermatitis. *Eur J Dermatol* 2010; 20:552.

**Konstantinou GN, et al:** Food contact hypersensitivity syndrome. *Clin Exp Dermatol* 2008; 33:383.

**Stutz N, et al:** Anaphylaxis caused by contact urticaria because of epoxy resins. *Contact Dermatitis* 2008; 58:307.

**Williams JD, et al:** Occupational contact urticaria. *Br J Dermatol* 2008; 159:125.

## DRUG REACTIONS

### Epidemiology

Adverse drug reactions (ADRs) are a common cause of dermatologic consultation. In a large French study, about 1 in 200 inpatients on medical services developed a drug eruption, compared with 1 in 10,000 on surgical services. In the United States, similar studies have shown a reaction rate of 2–3 in 100 for medical inpatients. In only about 55% of patients who were carefully evaluated was it possible to attribute a specific medication definitely as the cause of the eruption. Simple exanthems (75–95%) and urticaria (5–6%) account for the vast majority of drug eruptions. Females are 1.3–1.5 times more likely to develop drug eruptions, except in children under age

3 years, with boys more likely to be affected than girls. Aminopenicillins cause drug eruptions in 1.2–8% of exposures and trimethoprim-sulfamethoxazole (TMP-SMX) in 2.8–3.7%. About 20% of emergency department visits for adverse events caused by medications are related to antibiotics, mainly penicillins and cephalosporins. Nonsteroidal anti-inflammatory drugs (NSAIDs) have a reaction rate of about 1 in 200. In contrast, reaction rates for digoxin, lidocaine, prednisone, codeine, and acetaminophen are less than 1 in 1000.

Patients with human immunodeficiency virus (HIV) or Epstein-Barr virus (EBV) infection have dramatically increased rates of exanthematous reactions to certain antibiotics. Hypersensitivity syndromes from multiple drug classes have been associated with reactivation of latent viral infections, primarily human herpesvirus (HHV) 6 and HHV-7, but also EBV and cytomegalovirus (CMV). Human leukocyte antigen (HLA) type, in a race-specific manner, may increase risk for drug reactions for specific medications.

## Evaluation

Four basic rules should always be applied in evaluating the patient with a suspected ADR, as follows:

1. The patient is probably on unnecessary medications, and all of these should be stopped. Pare down the medication list to the bare essentials.
2. The patient must be asked about nonprescription medications and pharmaceuticals delivered by other means (e.g., eyedrops, suppositories, implants, injections, patches, recreational drugs).
3. Regardless of how atypical the patient's cutaneous reaction, always consider medication as a possible cause. In patients with unusual reactions, searching the medical literature and calling the manufacturer for prior reports may be useful.
4. The timing of drug administration must correlate with the appearance of the eruption. A drug chart lists all the drugs given to the patient in the left column, with the dates along the lower axis, and the course of the drug eruption at the top. Lines extend from left to right for the dates of administration of each medication. These are directly below the course of the eruption. This graphic representation of the timing of medication administration and eruption is a very handy tool in assigning plausibility to a certain medication causing an eruption. The nurses' notes and patient history are most useful in determining exactly when the eruption first appeared.

An important step in evaluating a patient with a potential ADR is to diagnose the cutaneous eruption by clinical pattern (e.g., urticaria, exanthem, vasculitis, hypersensitivity syndrome). Regularly updated manuals (e.g., Litt) or similar Internet databases are strongly recommended as ready reference sources for this information. The following questions provide a framework for evaluation:

- Has the suspected medication been reported to cause the reaction the patient is experiencing? How frequently? Has the patient had a previous reaction to any medications?
- What are other possible causes of the patient's eruption? For example, an exanthem could be related to an associated viral illness, not the medication.
- When did the eruption appear relative to the administration of the suspected medication?
- Certain reactions are known to be related to rate of administration (vancomycin red man syndrome) or

cumulative dose (lichenoid reactions to gold). Could the rate or dose be causing this patient's reaction?

- Does the eruption clear when the suspected medication is stopped? Because certain eruptions may clear with continuation of the drug, however, this is a useful, but not irrefutable, criterion to ascribe a specific reaction to a medication.
- Does the reaction recur with rechallenge?

Skin testing may be useful in evaluating type I (immediate) hypersensitivity reactions. It is most frequently used in evaluating adverse reactions to penicillin, local anesthetics, insulin, and vaccines. RAST has demonstrated a 20% false-negative rate in penicillin type I allergy; thus, in their current form, RASTs cannot replace skin testing. Intradermal, skin prick, and patch testing are also reported to be beneficial in some patients with morbilliform reactions or fixed-drug reaction. Lymphocytotoxicity assays, which are available commercially, may be predictive of an adverse reaction and have been used in patients with anticonvulsant or sulfonamide hypersensitivity reaction.

The patient should be given concrete advice about the reaction. What was the probability that the patient's reaction was caused by the medication? Can the patient take the medication again, and if so, what may occur? What cross-reactions are known? What other medications must the patient avoid? Unusual reactions should be reported to regulatory agencies and the manufacturer, whereas routine reporting of exanthems is strongly discouraged because this practice dilutes important safety signals related to unusual reactions.

## Pathogenesis

T cells, specifically T-helper 1 (Th1) cells, are thought to be important inducers of ADRs. T cells in the dermis in acute generalized exanthematous pustulosis (AGEP) secrete interleukin-8 (IL-8), a neutrophil-attracting chemokine. In drug rash (reaction) with eosinophilia and systemic symptoms (DRESS), they secrete IL-5 and eotaxin, recruiting eosinophils. As a consequence of T-helper cell activation, memory T cells are produced, resulting in recurrence of the eruption on rechallenge. Since Th1 cells are mediators of these eruptions, interferon (IFN)- $\gamma$  release assays using peripheral blood lymphocytes are being evaluated for confirming the inciting medication in ADRs. The sensitivity appears to be drug class dependent, with low sensitivity for ADRs induced by anticonvulsants, antibiotics, and cardiovascular medications.

Large molecules, such as rat- or mouse-derived antibodies, can be immunogenic. Most medications, however, are too small to be recognized as antigens by immunologically active cells. They must bind to a larger molecule, usually a protein, to form an immunogenic product. The medication is the hapten, and the immunologically active molecule is a medication-protein complex or hapten-carrier complex. Some medications, such as penicillin, are active enough to bind directly to proteins. Most, however, need to be metabolized to more active or more immunogenic forms to bind to proteins and cause an immunologic reaction. The drug metabolites can also be toxic to cells, causing direct cell damage. Drug metabolism often occurs in the cytochrome P450 system in the liver.

There has also been a proposed model for ADRs in which the drug or a metabolite binds directly to T cells or Langerhans cells in close opposition to sentinel T cells in the skin. This direct binding could activate the T cell-Langerhans cell interactive unit, resulting in the production of biologically active molecules. This would explain how some drug eruptions occur soon after exposure or with the first exposure to a medication. It could also explain a dose-dependent effect in drug



eruptions. Also, a systemic viral infection may have already activated the immune cells in the skin, reducing their threshold for activation by drug binding. Once the T cell is activated, it may produce a variety of reactions, as follows:

1. T cells stimulate IFN- $\gamma$  production and a Th1 response, simulating contact dermatitis. This type of reaction could be “bullous” but without extensive epidermal necrosis.
2. T cells could be activated to function in a Th2 manner and stimulate eosinophil ingress through Th2 cytokines (morbilliform and urticarial drug eruptions).
3. T cells could activate cytotoxic (CD8+) T cells, which would secrete perforin/granzyme B and Fas ligand, resulting in keratinocyte apoptosis. This could explain bullous reaction, the observation that occasional necrotic keratinocytes are seen in patients with exanthems, and the rare eruption that begins as an exanthem and progresses to a bullous eruption. Drug eruptions containing activated CD8+ T cells are more dangerous, since CD8+ cells attack all major histocompatibility complex (MHC) class I-expressing cells (including keratinocytes), resulting in more severe reactions.
4. T cells, through cytokine production, recruit neutrophils, resulting in pustular exanthems and AGEF.

Th17 cells are implicated in many drug eruptions, and sulfamethoxazole induces a T-cell switch mechanism based on the TCRV $\beta$ 20-1 domain altering peptide-HLA recognition. Dermal CD4+/CD25+/Foxp3 regulatory T cells (Tregs) are reduced in severe bullous drug eruptions such as toxic epidermal necrolysis (TEN). Circulating Tregs expressing skin-homing molecules are increased in early drug-induced hypersensitivity syndrome (DIHS, DHS). The cells are immunologically active early in the course of the eruption, enter the skin, and can effectively suppress the immune response. However, they become functionally deficient later, perhaps explaining the occasional development of autoimmune phenomena months after DIHS, as well as the tendency of DIHS reactions to relapse, recur, or fail to resolve. Peripheral blood mononuclear cells are stimulated by the incriminated drug, in a lymphocyte transformation test (LTT), for only the first week in TEN and exanthems. In DIHS, however, the LTT test is negative until 5–6 weeks following the eruption and remains positive for 1 year or more. This supports the observation that DIHS reactions are long-lived. In addition, the LTT is essentially only useful in diagnosing DIHS, because it is rarely performed during the first week of an ADR. In severe drug reactions, micro-RNA-18a-5p downregulates the expression of the antiapoptotic B-cell lymphoma/leukemia-2-like protein 10 (BCL2L10), promoting apoptosis.

### Clinical morphology

Cutaneous drug reactions are initially discussed here by morphologic pattern. In addition to the cutaneous eruption, some reactions may be associated with other systemic symptoms or findings. The modifier “simple” is used to describe reactions without systemic symptoms or internal organ involvement. “Complex” reactions are those with systemic findings. Complex reactions are also called DIHS because the ancillary features of complex reactions are often a characteristic syndrome of findings (e.g., infectious mononucleosis-like picture with anticonvulsant hypersensitivity reactions). DIHS or complex reaction is synonymous with DRESS.

Drug reactions may cause cutaneous lesions and findings identical to a known disease or disorder. These may be of similar or disparate pathogenesis. For example, true serum sickness caused by the injection of foreign proteins, such as

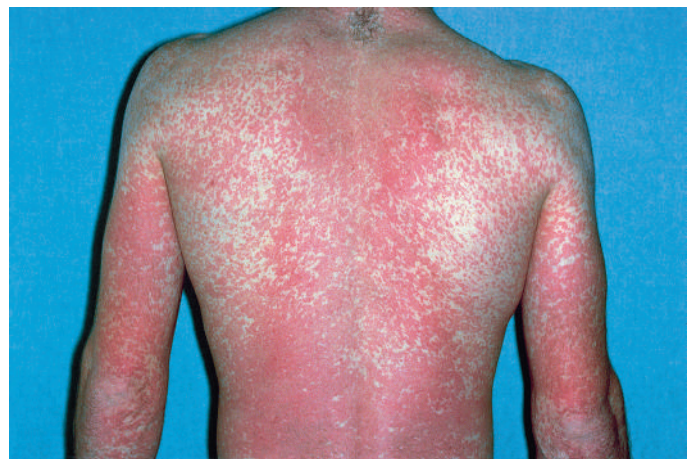antithymocyte globulin, is associated with circulating immune complexes. Medications, notably cefaclor, induce a serum sickness-like illness not associated with circulating immune complexes. Both calcium channel blockers and interferon are strongly associated with eczematous eruptions.

### Exanthems (morbilliform or maculopapular reactions)

Exanthems are the most common form of adverse cutaneous drug eruption. They are characterized by erythema, often with small papules throughout. Exanthems tend to occur within the first 2 weeks of treatment but may appear later, or even up to 10 days after the medication has been stopped. Lesions tend to appear first proximally, especially in the groin and axilla, generalizing within 1 or 2 days. The face may be spared. Pruritus is usually prominent, helping to distinguish a drug eruption from a viral exanthem. Antibiotics, especially semisynthetic penicillins and TMP-SMX, are the most common causes of this reaction pattern (Fig. 6-20). Ampicillin-amoxicillin given during EBV infection causes an exanthem in 29–69% of adults and 100% of children. TMP-SMX given to AIDS patients causes exanthems in about 40%. Certain quinolones (e.g., gemifloxacin) cause exanthems at a high rate: 4% overall and 30% in young women.

Morbilliform eruptions may rarely be restricted to a previously sunburned site, the so-called “UV recall-like” phenomenon. It occurs with various antibiotics. The sunburn may have occurred 1–7 months before the drug eruption. This pattern of eruption must be distinguished from a true UV recall caused by antimetabolites (see later section, “Adverse reactions to chemotherapeutic agents”).

In the case of simple exanthems, treatment is supportive. The eruption will clear within 2 weeks of stopping the offending medication, and it may clear even if the drug is continued. Topical corticosteroids and antipruritics may be of benefit and allow the course of therapy to be completed. Rechallenge usually results in the reappearance of the eruption, except in the setting of HIV. In many HIV-infected patients with simple reactions to TMP-SMX, reexposure by slow introduction or full-dose reexposure may be tolerated. Infrequently in HIV patients, however, and rarely in persons with normal immune function, rechallenge may result in a more severe blistering reaction. The use of patch and intradermal testing for the confirmation of the incriminated drug in morbilliform exanthems is not standardized. Only 2–10% of patients who experience



**Fig. 6-20** Morbilliform (exanthematous) drug eruption caused by exposure to an antibiotic.

the eruption on rechallenge will have a positive patch or intra-dermal test.

Cutaneous findings identical to simple exanthems may occur as part of DIHS or DRESS. In contrast to simple exanthems, in complex exanthems the inciting agent must be stopped immediately, and rechallenge should rarely be undertaken. Even outside the setting of DIHS/DRESS, higher eosinophil counts correlate with more severe ADRs.

**Aquino MR, et al:** Patch testing for drugs. *Dermatitis* 2013; 24:205–214.

**Chen CJ, et al:** A comprehensive 4-year survey of adverse drug reactions using a network-based hospital system. *J Clin Pharm Ther* 2012; 37:647–651.

**De la Torre C, et al:** Advances in the diagnosis of drug eruptions. *Actas Dermosifiliogr* 2013; 104:782–788.

**Dodiuk-Gad RP, et al:** Epidemiology of severe drug hypersensitivity. *Semin Cutan Med Surg* 2014; 33:2–9.

**Harp JL, et al:** Severe cutaneous adverse reactions: impact of immunology, genetics, and pharmacology. *Semin Cutan Med Surg* 2014; 33:17–27.

**Heelan K, et al:** Cutaneous drug reactions in children: an update. *Paediatr Drugs* 2013; 15:493–503.

**Raison-Peyron N:** “Cutaneous adverse drug reactions” are not always drug-induced. *Eur J Dermatol* 2013; 23:439–442.

**Seitz CS, et al:** Drug-induced exanthems: correlation of allergy testing with histologic diagnosis. *J Am Acad Dermatol* 2013; 69:721–728.

**Summers EM, et al:** Chronic eczematous eruptions in the aging: further support for an association with exposure to calcium channel blockers. *JAMA Dermatol* 2013; 149:814–818.

**Turk BG, et al:** Adverse cutaneous drug reactions among hospitalized patients: five year surveillance. *Cutan Ocul Toxicol* 2013; 32:41–45.

**Walsh S, et al:** Drug reaction with eosinophilia and systemic symptoms: is cutaneous phenotype a prognostic marker for outcome? A review of clinicopathological features of 27 cases. *Br J Dermatol* 2013; 168:391–401.

**Yang J, et al:** Peripheral blood eosinophil counts predict the prognosis of drug eruptions. *J Investig Allergol Clin Immunol* 2013;23:248–255.

### Drug-induced hypersensitivity syndrome or drug reaction with eosinophilia and systemic symptoms

All patients with DIHS share the characteristic features of fever, rash, and internal organ involvement. Characteristic features include the following:

- Rash developing late (>3 weeks) after the inciting medication is started; often occurs with the first exposure to the medication
- Long-lasting symptoms (>2 weeks) after discontinuation of the causative drug
- Fever (>38°C)
- Multiorgan involvement
- Eosinophilia (>1500 absolute eosinophilia); less common with dapsone (criteria vary, with some groups citing counts greater than 1500/μl and others more than 700/μl or above 10% if the leukocyte count is lower than 4000/μl)
- Lymphocyte activation (lymphocytosis, atypical lymphocytosis, lymphadenopathy)
- Frequent reactivation of HHV-6, HHV-7, EBV, and CMV

Seven major medications/classes of medication are implicated, as follows:

1. Anticonvulsants: phenobarbital, lamotrigine, and phenytoin
2. Long-acting sulfonamides: sulfamethoxazole, sulfadiazine, and sulfasalazine (but *not* related medications – sulfonyleureas, thiazine diuretics, furosemide, and acetazolamide)

3. Allopurinol
4. Nevirapine
5. Abacavir
6. Dapsone
7. Minocycline

Vancomycin has also recently been recognized as a cause, as has trichloroethylene, an industrial solvent that causes DRESS with reactivation of latent HHV-6.

The skin eruption accompanying DRESS/DIHS is typically morbilliform, often with follicular accentuation, and can vary from faint and mild to severe with exfoliative erythroderma. Facial edema often accompanies the skin eruption, and the eruption may evolve to demonstrate superficial pustules, especially on the face. Some patients with Stevens-Johnson syndrome or toxic epidermal necrolysis may have some of the features of DRESS, specifically fever, eosinophilia, and internal organ involvement, but these patients differ in that they may require corticosteroids. Adverse prognostic indicators include tachycardia, leukocytosis, tachypnea, coagulopathy, thrombocytopenia, and gastrointestinal bleeding. Dysphagia can be severe. The internal organ involvement described in DRESS can be divided into two types: (1) organ dysfunction occurring during or immediately associated with the acute episode and (2) late sequelae, possibly with an autoimmune basis. The first category includes colitis/intestinal bleeding, encephalitis/aseptic meningitis, hepatitis, interstitial nephritis, interstitial pneumonitis/respiratory distress syndrome, sialadenitis, and myocarditis. Late sequelae include syndrome of inappropriate secretion of antidiuretic hormone (SIADH), thyroiditis/Graves' disease, and diabetes mellitus. Systemic lupus erythematosus (SLE) can rarely occur. In one series, 5% of patients with DRESS died, usually from complications of liver or renal involvement. It is important to note that the manifestations of the syndrome vary by drug; dapsone hypersensitivity has a weaker association with eosinophilia, and allopurinol hypersensitivity has more renal involvement. A erythema multiforme-like eruption in patients with DIHS/DRESS may be predictive of more severe hepatic involvement.

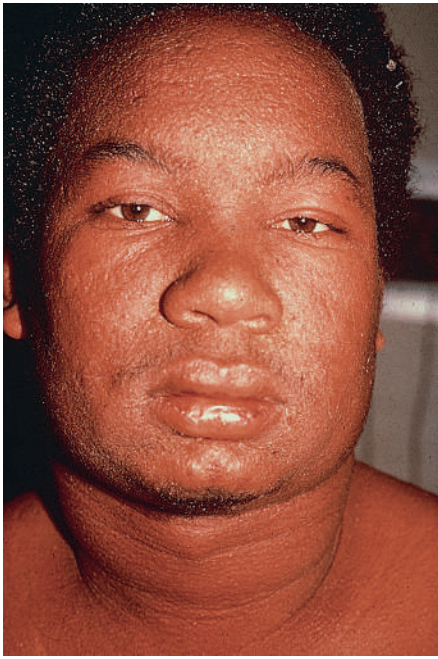In patients with severe DRESS, HHV-6 can be found in the liver and cerebrospinal fluid associated with hepatitis and encephalitis, and in one series, all fatal cases of DRESS were associated with HHV-6 reactivation.

### Anticonvulsant hypersensitivity syndrome

Anticonvulsant hypersensitivity syndrome can be seen with phenytoin, phenobarbital, carbamazepine, lamotrigine, zonisamide, and other anticonvulsants. The estimated incidence of this condition is 1:1000 to 1:10,000 patients treated with these medications, but is 10 times that rate for lamotrigine. Carbamazepine is currently the most common anticonvulsant causing DRESS, because it is also used to treat neuropathic pain, bipolar disorder, and schizophrenia. Medication dosage does not determine risk for anticonvulsant hypersensitivity syndrome. HHV-6 and HHV-7 reactivation are observed in about 30% of these patients, and much more often in carbamazepine-induced cases.

The DRESS begins on average 30–40 days after starting the anticonvulsant. Low-grade fever and pharyngitis may precede the eruption by a few days. The skin eruption is typically morbilliform initially, associated with marked facial and neck edema (Fig. 6-21). The eruption begins on the trunk and face, spreading centrifugally. As the eruption becomes more severe, it may evolve to confluent plaques with purpura. The associated intense dermal edema may lead to bulla formation. Other common findings include fever (>50% of patients), adenopathy (20%), and elevated liver function tests (66–75%). Atypical





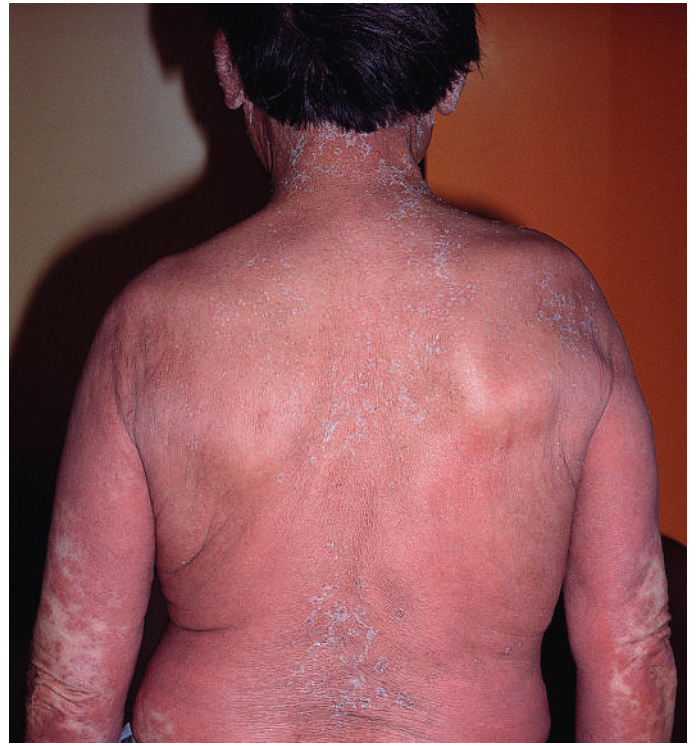**Fig. 6-21**  
Erythroderma with papulopustules and lymphadenopathy, phenytoin (Dilantin)-induced hypersensitivity syndrome. (Courtesy of Dr. L. Lieblich.)

lymphocytosis can occur, completing a mononucleosis-like picture. Lung and renal involvement is uncommon. Lamotrigine-induced DRESS demonstrates eosinophilia in only 19% of patients, lymphadenopathy in only 12%, and multiorgan involvement in 45%. The syndrome occurs within 4 weeks of starting the drug in most patients, although a delay of up to 6 months has been noted in 10% of cases. Coadministration of valproate increases the risk of lamotrigine DRESS, whereas slow introduction reduces the risk.

In anticonvulsant hypersensitivity syndrome, as the eruption evolves, widespread pinpoint pustules typically appear on the face, trunk, and extremities, especially in dark-skinned patients. The syndrome may continue to progress, even after the inciting medication has been stopped. The associated hepatitis can be life threatening.

Because many of the anticonvulsants are metabolized through the same pathway, cross-reactions are frequent, making selection of an alternative agent quite difficult. The rate of cross-reactivity among phenytoin, phenobarbital, and carbamazepine is 70%. In vitro tests are commercially available and may aid in selecting an agent to which the patient will not cross-react. Valproate is generally considered a safe alternative for patients sensitive to aromatic anticonvulsants.

The management of anticonvulsant hypersensitivity syndrome requires immediate discontinuation of the offending medication. Because cross-reactivity among these drugs is high, the therapeutic benefit of a medication from this class must be carefully reconsidered. If the treatment is for depression, prophylaxis after closed head injury, or atypical pain syndromes, medication from another class can often be substituted. Treatment is initially supportive until the extent and severity of the syndrome are assessed. Some patients clear if the medication is simply discontinued. Indications for systemic corticosteroid treatment include severe systemic toxicity, with pulmonary, cardiac, liver, or renal involvement. The usually starting dose is 1.0–1.5 mg/kg/day. *N*-acetylcysteine may be added if hepatitis is present. Steroid therapy is continued at whatever dose is required for control, then gradually tapered. It may require weeks to wean the patient off corticosteroids successfully. Intravenous immune globulin (IVIG) and other immunosuppressives (e.g., azathioprine, cyclosporine) have been successfully used in steroid-refractory cases.



**Fig. 6-22** Allopurinol hypersensitivity syndrome.

### Allopurinol hypersensitivity syndrome

Allopurinol hypersensitivity syndrome typically occurs in patients with preexisting renal failure. Often, affected patients are treated unnecessarily for asymptomatic hyperuricemia, with clear indications for therapy present in only about one third of these patients. They are often given a dose not adjusted for their coexisting renal disease and are frequently taking a thiazide diuretic. Weeks to many months (average 7 weeks) after the allopurinol is begun, the patient develops a morbiliform eruption (50% of cases) that often evolves to an exfoliative erythroderma (20%) (Fig. 6-22). Bullae may occur, especially on the palms and soles, and oral ulcers may be present. Associated with the dermatitis are fever, eosinophilia, sometimes hepatitis (70% of cases), and typically worsening of renal function (40–80%, the higher percentage in those with preexisting renal disease). Lung involvement and adenopathy occur infrequently. About 25% of patients die as a result of this syndrome, often from cardiovascular complications. Pancreatitis and subsequent insulin-dependent diabetes may occur as a complication. Dialysis does not appear to accelerate the resolution of the eruption, suggesting that if a drug metabolite is responsible, it is not dialyzable. There is a strong association between HLA-B-5801 and the development of allopurinol hypersensitivity syndrome in the Han Chinese, but not in other races. HHV-6 reactivation may be associated. This syndrome may be steroid responsive but is extremely slow to resolve, frequently lasting for months after allopurinol has been stopped. Very gradual tapering of systemic corticosteroids with monitoring of eosinophil count and renal function is essential. Too rapid tapering may lead to relapse of the syndrome.

### Sulfonamide hypersensitivity syndrome

Fewer than 0.1% of treatment courses with sulfonamides are complicated by a hypersensitivity syndrome. Sulfonamide hypersensitivity syndrome is similar to that seen with

the anticonvulsants, including the characteristic facial and periorbital edema. It typically begins 3 weeks after starting the medication but may occur as soon as 1 week. The skin eruption is usually morbilliform or an erythroderma. Patients are often slow acetylators, unable to detoxify the toxic and immunogenic metabolites generated during the metabolism of the sulfonamides. Patients with sulfonamide hypersensitivity syndrome may develop antibodies that recognize microsomal proteins to which the reactive metabolite of the sulfonamides binds. Hepatitis, nephropathy, pneumonitis, pericarditis, myocarditis, pancreatitis, and pleural effusion can all occur as a part of the syndrome. The hepatitis can be life threatening. Treatment is with topical agents appropriate for the skin eruption and systemic corticosteroids for systemic complications. Zonisamide, a sulfonamide anticonvulsant, cross-reacts with sulfonamides but not other anticonvulsants.

### Minocycline hypersensitivity syndrome

Minocycline hypersensitivity syndrome occurs in young adults, usually in the context of acne therapy. Deficiency of glutathione *S*-transferases is common in affected individuals and is more common in persons of African Caribbean descent. Females are more often affected. Minocycline may be detected in the blood of these patients up to 17 months after its discontinuation, suggesting that slow metabolism and persistent levels of medication may play a role. Minocycline hypersensitivity syndrome usually begins 2–4 weeks after starting the minocycline. Fever, a skin eruption, and adenopathy occur in more than 80% of patients. Headache and cough are common complaints. The eruption can be morbilliform, erythrodermic, or pustular. Facial edema is common. Liver involvement occurs in 75% of patients and renal disease in 17%. Minocycline hypersensitivity is particularly associated with interstitial pneumonia with eosinophilia. This may progress to respiratory distress syndrome. It can be life threatening, but most patients survive. Myocarditis has also been reported.

### Dapsone hypersensitivity syndrome

Dapsone hypersensitivity syndrome occurs in less than 1% of patients given this medication. It usually begins 4 weeks or more after starting dapsone. Hemolytic anemia and methemoglobinemia may be present. A morbilliform eruption that heals with desquamation is most characteristic. Icterus and lymphadenopathy occur in 80% of patients. Eosinophilia is typically *not* present. Liver involvement is a mixture of hepatocellular and cholestatic. The bilirubin is elevated in 85%, partly attributable to the hemolysis, and hypoalbuminemia is characteristic. Liver involvement is often severe and may be fatal. As with the hypersensitivity syndromes previously discussed, corticosteroids are the mainstay of treatment.

**Atzori L, et al:** Cutaneous adverse drug reactions to allopurinol: 10-year observational survey of the Dermatology Department–Cagliari University (Italy). *J Eur Acad Dermatol Venereol* 2012; 26:1424–1430.

**Bansal S, et al:** Eosinophilia in pre-anesthetic assessment: a guide to diagnosis of DRESS syndrome. *J Anaesthesiol Clin Pharmacol* 2013; 29:270–271.

**Gill S, et al:** Nevirapine-induced rash with eosinophilia and systemic symptoms (DRESS). *Indian J Pharmacol* 2013; 45:401–402.

**Husain Z, et al:** DRESS syndrome. Part I. Clinical perspectives. *J Am Acad Dermatol* 2013; 68:693.e1–e14.

**Husain Z, et al:** DRESS syndrome. Part II. Management and therapeutics. *J Am Acad Dermatol* 2013; 68:709.e1–e9.

**Kamijima M, et al:** Occupational trichloroethylene hypersensitivity syndrome: human herpesvirus 6 reactivation and rash phenotypes. *J Dermatol Sci* 2013; 72:218–224.

**Lee T, et al:** Characteristics of liver injury in drug-induced systemic hypersensitivity reactions. *J Am Acad Dermatol* 2013; 69:407–415.

**Karlin E, et al:** Genotyping for severe drug hypersensitivity. *Curr Allergy Asthma Rep* 2014; 14:418.

**Perkins JR, et al:** The study of severe cutaneous drug hypersensitivity reactions from a systems biology perspective. *Curr Opin Allergy Clin Immunol* 2014; 14:301–306.

**Wei CH, et al:** Identifying prognostic factors for drug rash with eosinophilia and systemic symptoms (DRESS). *Eur J Dermatol* 2011; 21:930–937.

**Yang MS, et al:** Clinical features and prognostic factors in severe cutaneous drug reactions. *Int Arch Allergy Immunol* 2013; 162:346–354.

## Bullous drug reactions: Stevens-Johnson syndrome and toxic epidermal necrolysis

Skin blistering may complicate drug reactions in many ways. Medications may induce known autoimmune bullous diseases such as pemphigus (penicillamine) or linear IgA disease (vancomycin). AGEP may be so extensive as to cause a positive Nikolsky's sign, and have a background of purpura and targetoid lesions, simulating Stevens-Johnson syndrome (SJS, erythema multiforme *majus/major*) and toxic epidermal necrolysis (TEN, Lyell syndrome, nonstaphylococcal scalded skin syndrome). Pseudoporphyria and other photodermatoses from drugs may form bullae. Cytokines may produce widespread bullous eruptions, perhaps through physiologic mechanisms. The term bullous drug reaction, however, usually refers to a drug reaction in the erythema multiforme (EM) group (Fig. 6-23). (For a complete discussion of other forms of erythema multiforme, see Chapter 7.)

Fortunately, these are uncommon reactions to medications, with an incidence of 0.4–1.2 per million person-years for TEN and 1.2–6.0 per million person-years for SJS. These drug-induced forms of EM are usually more extensive than herpes-associated EM or mycoplasma-associated EM *major*, but at times the distinction may be difficult. The more severe the reaction, the more likely it is to be drug-induced (50% of cases of SJS and 80% of TEN). The exact definitions of SJS and TEN remain arbitrary, and some consider these syndromes to be parts of a disease spectrum, based on the following:

- Both SJS and TEN are most frequently induced by the same medications.
- Patients initially presenting with SJS may progress to extensive skin loss resembling TEN.
- The histologic findings of TEN and SJS are indistinguishable.
- Both are increased by the same magnitude in HIV infection.

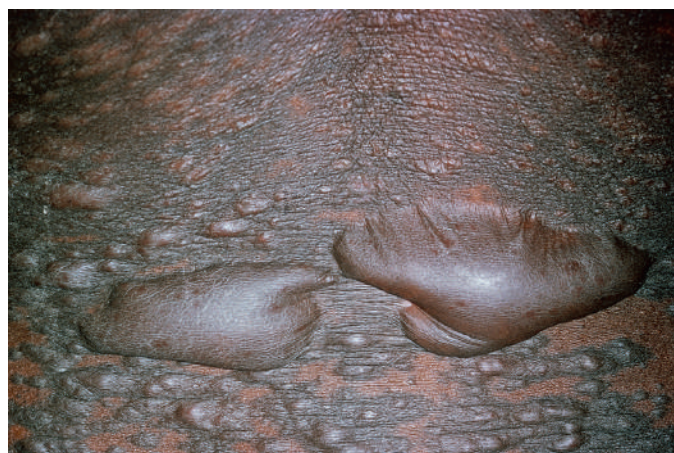

Fig. 6-23 Bullous drug reaction.



However, genetic evaluations of Caucasians with SJS and TEN showed distinct genetic predispositions for these conditions.

In Taiwan, carbamazepine causes up to one third of cases, but only 5% in Europe. In Han Chinese, the HLA haplotype HLA-B\*1502 is present in the vast majority of carbamazepine-induced SJS/TEN patients and is present in about 10% of the Han Chinese population in general. This HLA association is *not* usually found in patients of other ethnicities with carbamazepine-induced SJS/TEN. HLA typing should be performed in all Asians before starting carbamazepine, since the prevalence of HLA-B\*1502 is 5–10% in Asians in the United States and Asia. HHV-6 reactivation may also be seen in SJS/TEN patients.

More than 100 medications have been reported to cause SJS and TEN. In adults, common inciting medications are TMP-SMX (1–3:100,000), sulfadoxine plus pyrimethamine (Fansidar-R) (10:100,000), nevirapine, lamotrigine (1:1000 adults and 3:1000 children), and carbamazepine (14:100,000). Antibiotics (especially long-acting sulfa drugs and penicillins), other anticonvulsants, anti-inflammatories (NSAIDs), and allopurinol are also frequent causes. Currently, in Europe, allopurinol is the most common cause of SJS and TEN. In children SJS/TEN is most often caused by sulfonamides and other antibiotics, antiepileptics, and acetaminophen. SJS/TEN from TMP-SMX is significantly more common in the spring. If the inciting drug has a short half-life, and it is promptly stopped, mortality is reduced from 26% to 5%. Establishing causality of a drug can sometimes be difficult. Rechallenge can be dangerous, so *in vitro* methods have been developed. Lymphocyte granulysin expression, Granzyme B-ELISpot, and IFN- $\gamma$  production assays together provided a sensitivity of 80% and specificity of 95%.

Fever and influenza-like symptoms often precede the eruption by a few days. Skin lesions appear on the face and trunk and rapidly spread, usually within 4 days, to their maximum extent. Initial lesions are macular and may remain so, followed by desquamation, or may form atypical targets with purpuric centers that coalesce, form bullae, then slough. Patients with purpuric atypical targets may evolve more slowly, and usually the skin lesions are clinically inflammatory. In SJS, virtually always, two or more mucosal surfaces are also eroded, with the oral mucosa and conjunctiva most frequently affected. The patient may have photophobia, difficulty with swallowing, rectal erosions, painful urination, and cough, indicative of ocular, alimentary, urinary, and respiratory tract involvement, respectively. Over time, more than 10% of the skin surface may be sloughed, leading to SJS/TEN overlap; if more than 30% of the skin is lost, a case is classified as TEN. In other patients, macular erythema is present in a local or widespread distribution over the trunk. Mucosal involvement may not be found. The epidermis in the areas of macular erythema rapidly becomes detached from the dermis, leading to extensive skin loss, often much more rapidly than occurs in the patients with atypical targets and extensive mucosal involvement. “Pure TEN” is a conceptual way of thinking of such patients. Rarely, SJS/TEN patients may present with lesions predominantly in sun-exposed areas, with a clear history of a recent significant sun exposure. This suggests that, in rare cases, SJS/TEN may be photo induced or photo exacerbated. Patients with SJS/TEN may have internal involvement similar to patients with DRESS/DIHS caused by the same medication. These most frequently include eosinophilia, hepatitis, and worsening renal function.

A skin biopsy is usually performed. Frozen-section analysis may lead to a rapid diagnosis. The histology of TEN and SJS is similar. There is a lymphocytic infiltrate at the dermoepidermal junction (DEJ) with necrosis of keratinocytes that at times may be full thickness. There is typically cellular necrosis out

of proportion to the infiltrate. Paraneoplastic pemphigus also shows changes of EM and may be excluded with direct immunofluorescence (DIF). Patients with graft-versus-host disease (GVHD) may also demonstrate a TEN-like picture with identical histology.

Management of SJS/TEN patients is similar to those with an extensive burn. They have fluid and electrolyte imbalances, bacteremia from loss of the protective skin barrier, hypercatabolism, and sometimes acute respiratory distress syndrome (ARDS). Their metabolic and fluid requirements are less than in burn victims, but nutritional support and monitoring for sepsis are critical. Burn units are typically skilled in managing SJS/TEN patients. In addition to extent of skin loss, age, known malignancy, tachycardia, renal failure, hyperglycemia, and low bicarbonate are all risk factors for having a higher mortality with SJS/TEN. SCORTEN, the most common model used to predict mortality, gives 1 point for each of these findings, with a 3.2% mortality for 0–1 points, and a 90% mortality for 5 or more points. However, respiratory tract involvement, not included in the SCORTEN, is also a poor prognostic sign. About one quarter of TEN patients have bronchial involvement. In TEN, epithelial detachment of the respiratory mucosae and associated ARDS are associated with a mortality of 70%. Preexisting diabetes mellitus and concurrent tuberculosis may also increase mortality.

The use of systemic agents to treat SJS/TEN is controversial because of the increased risk of septic death. IVIG has been used at a dose of 1 g/kg/day for the first 4 days following admission, but data supporting its efficacy are mixed.

Keratinocyte death in SJS and TEN is proposed to occur through more than one potential mechanism, and the relative importance of each of these mechanisms in SJS and TEN is not known. Activated cytotoxic T cells and natural killer (NK) cells produce granulysin, perforin, and granzyme B, all of which can induce keratinocyte necrosis. Th17 cells appear to play a role in mediating the disease. In addition, keratinocyte necrosis can be induced by the binding of soluble Fas ligand (sFasL) to Fas (also known as the death receptor or CD95). Soluble Fas ligand is elevated in the blood of patients with TEN, and its level correlates with body surface area (BSA) involvement. In addition, the peripheral blood mononuclear cells of patients with TEN secrete Fas ligand on exposure to the incriminated drug. The sera of patients with TEN induce necrosis of cultured keratinocytes, and a monoclonal antibody to Fas ligand in a dose-dependent manner inhibits keratinocyte necrosis exposed to TEN patient sera. This strongly supports Fas expression by keratinocytes and Fas ligand production by immune cells as the mechanisms by which TEN is mediated. The proposed mechanism of action of IVIG in TEN is by IVIG blocking the binding of sFasL to Fas, stopping keratinocyte apoptosis.

The presence of cytotoxic T lymphocytes and NK cells within the dermis subjacent to the necrotic epidermis suggests that immunosuppressive agents that block immune function could also be effective in SJS or TEN. Cyclosporine is the most promising agent, with some *in vitro* and *in vivo* data supporting its use, whereas *in vitro* data suggest that sirolimus could promote keratinocyte necrosis. If considered, immunosuppressive treatment should be used as soon as possible, given as a short trial to see if the process may be arrested, and then tapered rapidly to avoid the risk of continued immunosuppression in a patient with substantial loss of skin. Anecdotally, both etanercept, 25 mg twice, and infliximab, 5 mg/kg intravenously once, have led to rapid termination of skin sloughing, but a prospective trial of thalidomide (another anti-TNF agent) was discontinued because of excessive mortality in the active treatment arm. Data are mixed regarding systemic corticosteroid therapy for skin disease, and there is a clear risk of

sepsis. Systemic and topical steroid therapy for ocular involvement may improve outcomes, as may topical cyclosporine. In patients with SJS/TEN who also have systemic involvement, as seen in DIHS (considered by some as SJS/TEN representing the cutaneous eruption of DIHS), systemic corticosteroids should be given early and tapered as rapidly as possible.

For patients who survive, the average time for epidermal regrowth is 3 weeks. The most common sequelae are ocular scarring and vision loss. The only predictor of eventual visual complications is the severity of ocular involvement during the acute phase. A siccalike syndrome with dry eyes may also result, even in patients who never had clinical ocular involvement during the acute episode. Other complications include cutaneous scarring, eruptive melanocytic lesions, and nail abnormalities. Transient, widespread verrucous hyperplasia resembling confluent seborrheic keratoses has also been reported.

**Bouvesse S, et al:** Toxic epidermal necrolysis, DRESS, AGEP: do overlap cases exist? *Orphanet J Rare Dis* 2012; 7:72.

**Butt TF, et al:** Internet accounts of serious adverse drug reactions: a study of experiences of Stevens-Johnson syndrome and toxic epidermal necrolysis. *Drug Saf* 2012; 35:1159–1170.

**Castelain F, et al:** Toxic epidermal necrolysis. *Curr Drug Saf* 2012; 7:332–338.

**Ellender RP, et al:** Clinical considerations for epidermal necrolysis. *Ochsner J* 2014; 14:413–417.

**Ferrandiz-Pulido C, et al:** A review of causes of Stevens-Johnson syndrome and toxic epidermal necrolysis in children. *Arch Dis Child* 2013; 98:998–1003.

**Fu M, et al:** Recovered patients with Stevens-Johnson syndrome and toxic epidermal necrolysis maintain long-lived IFN- $\gamma$  and sFasL memory response. *PLoS One* 2012; 7:e45516.

**Jalilian C, Jevtic A:** The management of toxic epidermal necrolysis. *Australas J Dermatol* 2013; 54:75–76.

**Kapoor S:** Emerging new markers of toxic epidermal necrolysis. *J Intensive Care Med* 2013; 28:72.

**Kirchhof MG, et al:** Retrospective review of Stevens-Johnson syndrome/toxic epidermal necrolysis treatment comparing intravenous immunoglobulin with cyclosporine. *J Am Acad Dermatol* 2014 Jul 30 [Epub ahead of print].

**Mockenhaupt M:** Stevens-Johnson syndrome and toxic epidermal necrolysis: clinical patterns, diagnostic considerations, etiology, and therapeutic management. *Semin Cutan Med Surg* 2014; 33:10–16.

**Porebski G, et al:** In vitro drug causality assessment in Stevens-Johnson syndrome: alternatives for lymphocyte transformation test. *Clin Exp Allergy* 2013; 43:1027–1037.

**Schwartz RA, et al:** Toxic epidermal necrolysis. Part I. Introduction, history, classification, clinical features, systemic manifestations, etiology, and immunopathogenesis. *J Am Acad Dermatol* 2013; 69:173.e1–e13.

**Schwartz RA, et al:** Toxic epidermal necrolysis. Part II. Prognosis, sequelae, diagnosis, differential diagnosis, prevention, and treatment. *J Am Acad Dermatol* 2013; 69:187.e1–e16.

**Sekula P, et al:** Comprehensive survival analysis of a cohort of patients with Stevens-Johnson syndrome and toxic epidermal necrolysis. *J Invest Dermatol* 2013; 133:1197–1204.

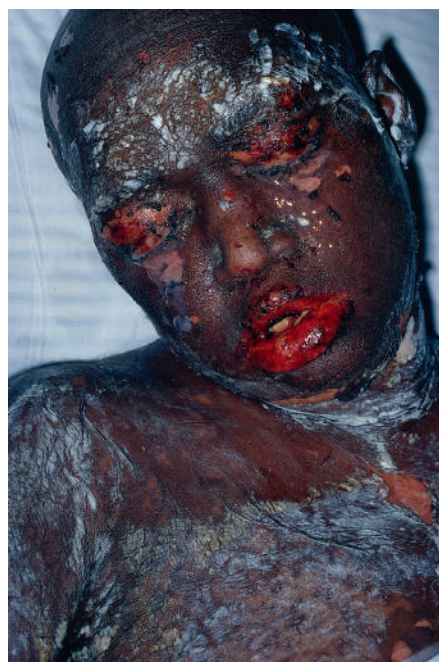**Teraki Y, et al:** Possible role of TH17 cells in the pathogenesis of Stevens-Johnson syndrome and toxic epidermal necrolysis. *J Allergy Clin Immunol* 2013; 131:907–909.

**Thammakumpee J, et al:** Characteristics of toxic epidermal necrolysis and Stevens-Johnson syndrome: a 5-year retrospective study. *J Med Assoc Thai* 2013; 96:399–406.

**Weinand C, et al:** 27 years of a single burn centre experience with Stevens-Johnson syndrome and toxic epidermal necrolysis: analysis of mortality risk for causative agents. *Burns* 2013; 39:1449–1455.

**Yip VL, et al:** HLA genotype and carbamazepine-induced cutaneous adverse drug reactions: a systematic review. *Clin Pharmacol Ther* 2012; 92:757–765.

**Zhu QY, et al:** Toxic epidermal necrolysis: performance of SCORTEN and the score-based comparison of the efficacy of corticosteroid therapy and intravenous immunoglobulin combined therapy in China. *J Burn Care Res* 2012; 33:e295–e308.



**Fig. 6-24** Radiation-induced reaction.

### Radiation-induced erythema multiforme

If phenytoin is given prophylactically in neurosurgical patients who are receiving whole-brain radiation therapy and systemic steroids, an unusual reaction occurs. As the dose of steroids is being reduced, erythema and edema initially appear on the head in the radiation ports. This evolves over 1 or 2 days to lesions with the clinical appearance and histology of SJS or even TEN. The eruption spreads caudad, and mucosal involvement may occur (Fig. 6-24). A similar syndrome has been reported with the use of amifostine, phenobarbital, or levetiracetam during radiation for head and neck cancers. This EM syndrome can rarely be seen with radiation therapy alone. If amifostine is used to reduce acute and chronic, radiation-associated head and neck xerostomia, there is a significant risk of SJS/TEN.

**Barbosa LA, Teixeira CB:** Erythema multiforme associated with prophylactic use of phenytoin during cranial radiation therapy. *Am J Health-Syst Pharm* 2008; 65:1048.

**Chodkiewicz HM, et al:** Radiation port erythema multiforme: erythema multiforme localized to the radiation port in a patient with non-small cell lung cancer. *Skinmed* 2012; 10:390.

**Elazzazy S, et al:** Toxic epidermal necrolysis associated with antiepileptic drugs and cranial radiation therapy. *Case Rep Oncol Med* 2013; 2013:415031.

**Vern Gross TZ, et al:** Erythema multiforme, Stevens Johnson syndrome, and toxic epidermal necrolysis syndrome in patients undergoing radiation therapy: a literature review. *Am J Clin Oncol* 2012; Aug 13. PMID: 22892429.

### Human immunodeficiency virus disease and drug reactions

Patients infected with HIV, especially those with Th-cell counts between 25 and 200, are at increased risk for the development of adverse reactions to medications. Morbilliform reactions to TMP-SMX occur in 45% or more of AIDS patients being treated for *Pneumocystis jirovecii* (formerly *P. carinii*) pneumonia. In two thirds of patients without life-threatening reactions, TMP-SMX treatment can be continued with simple conservative support, and the eruption may



resolve. Associated hepatitis or neutropenia may require discontinuation of the drug. A similar increased rate of reaction to amoxicillin-clavulanate is also seen, and patients have been described with sensitivity to multiple antituberculosis agents, especially streptomycin and ofloxacin. If the dermatitis is treatment limiting but the eruption is not life threatening, low-dose rechallenge/desensitization may be attempted. It is successful in 65–85% of patients in the short term and in more than 50% in the long term. In fact, initial introduction of TMP-SMX for prophylaxis by dose escalation reduces the rate of adverse reactions as well. However, rechallenge at full dose may have the same rate of recurrent eruptions as does introduction by dose escalation. Low-dose rechallenge is usually safe, but severe acute reactions may occur, including marked hypotension. Although most ADRs occur in the first few days of rechallenge, reactions may appear months after restarting TMP-SMX and may be atypical in appearance. The mechanism of this increased adverse reaction to TMP-SMX is unknown.

Severe bullous reactions, SJS, and TEN are 100–1000 times more common per drug exposure in patients with AIDS. These reactions are usually caused by sulfa drugs, especially long-acting ones, but may be caused by many agents. Nevirapine, a nonnucleoside reverse transcriptase inhibitor, has been associated with a high rate of severe drug eruptions, including SJS/TEN. Most of these ADRs are cutaneous and occur in the first 6 weeks of treatment. This high rate of reaction can be reduced by starting with a lower lead-in dose and by concomitant treatment with prednisone during the induction period. Nevirapine hypersensitivity syndrome presents with fever, hepatitis, or rash. More than 1% of patients will develop SJS/TEN. HLA-DRB1\*0101 patients are at increased risk for cutaneous reactions to nevirapine if not associated with hepatotoxicity. Hepatitis, but not cutaneous reactions, is seen more often in patients with CD4 counts above 200–250. Fixed drug eruptions (FDEs) are also frequently seen in patients with HIV infection. Abacavir is associated with a potentially life-threatening ADR in 8% of patients. The syndrome includes fever, rash, and gastrointestinal or respiratory symptoms. It usually occurs in the first 6 weeks of treatment but can occur within hours of the first dose. Rechallenge in these patients may lead to life-threatening hypotension and death. Abacavir hypersensitivity is increased in patients who are HLA-B\*5701 positive, and screening of patients for this HLA type and not exposing patients with this HLA type to abacavir have decreased the number of cases of abacavir hypersensitivity syndrome. ADRs to abacavir can also occur in HLA-B\*5701-negative patients.

Aciclovir, nucleoside and nonnucleoside reverse transcriptase inhibitors (except nevirapine), and protease inhibitors are uncommon causes of ADRs. Many reactions attributed to these agents may actually be coexistent HIV-associated pruritic disorders, especially folliculitis, which are common in patients with AIDS.

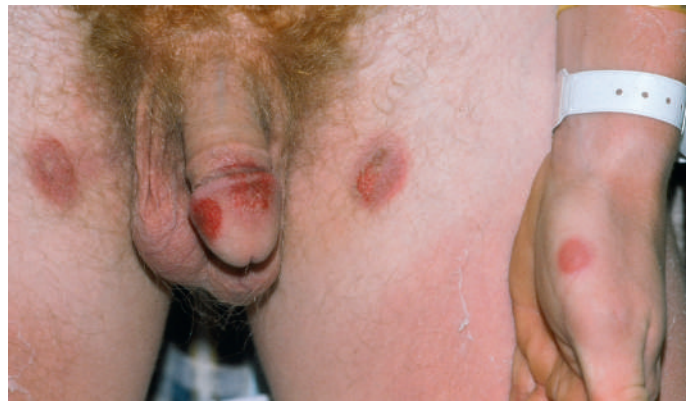**Isaacs T, et al:** Annular erythema and photosensitivity as manifestations of efavirenz-induced cutaneous reactions: a review of five consecutive cases. *J Antimicrob Chemother* 2013; 68:2871–2874.

**Lehloeny R, et al:** Multiple drug hypersensitivity reactions to anti-tuberculosis drugs: five cases in HIV-infected patients. *Int J Tuberc Lung Dis* 2012; 16:1260–1264.

**Mittmann N, et al:** Incidence of toxic epidermal necrolysis and Stevens-Johnson syndrome in an HIV cohort: an observational, retrospective case series study. *Am J Clin Dermatol* 2012; 13:49–54.

**Punyaratabandhu P, et al:** Skin manifestation of Thai HIV infected patients in HAART era. *J Med Assoc Thai* 2012; 95:497–504.

**Scherer K, et al:** Desensitization in delayed drug hypersensitivity reactions: an EAACI position paper of the Drug Allergy Interest Group. *Allergy* 2013; 68:844–852.



**Fig. 6-25** Fixed drug reactions caused by aspirin.

### Fixed drug reactions (eruptions)

Fixed drug reactions are common. Fixed drug eruptions (FDEs) are so named because they recur at the same site with each exposure to the medication. The time from ingestion of the offending agent to the appearance of symptoms is between 30 min and 8 hours, averaging 2 hours. In most patients, six or fewer lesions occur, and often only one. Infrequently, FDEs may be multifocal with numerous lesions (Fig. 6-25). They may present anywhere on the body, but half occur on the oral and genital mucosa. FDEs represent 2% of all genital ulcers evaluated at clinics for sexually transmitted diseases and can occur in young boys. In males, lesions are usually unifocal and can affect the glans or shaft of the penis. FDE of the vulva is often symmetric, presenting as an erosive vulvitis, with lesions on the labia minora and majora and extending to the perineum. Other unusual variants of FDE include eczematous, urticarial, papular, purpuric, linear, giant, and psoriasiform. At times, some lesions of FDE will not reactivate with exposure because of a presumed “refractory period” that may last from weeks to months.

Clinically, an FDE begins as a red patch that soon evolves to an iris or target lesion similar to erythema multiforme and that may eventually blister and erode. Lesions of the genital and oral mucosae usually present as erosions. Most lesions are 1 to several cm in diameter, but larger plaques may occur, resembling cellulitis. Characteristically, prolonged or permanent postinflammatory hyperpigmentation results, although a nonpigmenting variant of an FDE is recognized. With repeated or continued ingestion of the offending medication, new lesions may be added, sometimes eventuating in a clinical picture similar to SJS with similar morbidity and mortality. Histologically, an interface dermatitis occurs with subepidermal vesicle formation, necrosis of keratinocytes, and a mixed superficial and deep infiltrate of neutrophils, eosinophils, and mononuclear cells. Pigment incontinence is usually marked, correlating with the pigmentation resulting from FDEs. Because biopsies are generally performed during the acute stage of a recurrence, the stratum corneum is normal. Papillary dermal fibrosis and deep perivascular pigment incontinence are often present from prior episodes. This contrast between a normal stratum corneum (suggesting an acute process) and chronic dermal changes is virtually pathognomonic of FDE.

Medications inducing FDEs are usually those taken intermittently. Many of the NSAIDs, especially pyrazolone derivatives, paracetamol, naproxen, oxicams, and mefenamic acid, cause FDE, with a special predilection for the lips. Sulfonamides, trimethoprim, and TMP-SMX are now responsible for the majority of genital FDEs. Barbiturates, tetracyclines, fluconazole, fluoroquinolones, phenolphthalein, acetaminophen,

cetirizine, celecoxib, dextromethorphan, hydroxyzine, quinine, lamotrigine, phenylpropranolamine, erythromycin, and Chinese and Japanese herbs are also among the long list of possible causes. The risk of developing a FDE has been linked to HLA-B22. Patch tests with various concentrations of the offending medication can reproduce the lesion on affected but not unaffected skin. Tape-stripping the skin before applying the suspected medication in various vehicles may increase the likelihood of a positive patch test. This technique appears to be most useful in pyrazolone derivative-related reactions that are reproduced in 85% or more of cases.

Occasionally, FDEs do not result in long-lasting hyperpigmentation. The so-called nonpigmenting FDE is distinctive and has two variants. The pseudocellulitis or scarlatiniform type is characterized by large, tender, erythematous plaques that resolve completely within weeks, only to recur on reingestion of the offending drug. Pseudoephedrine hydrochloride is by far the most common culprit. The second variant is symmetric drug-related intertriginous and flexural exanthema (SDRIFE, formerly baboon syndrome; see “Allergic contact dermatitis,” earlier). SDRIFE preferentially affects the buttocks, groin, and axillae with erythematous, fixed plaques. Histologically, a giant cell lichenoid dermatitis can be seen in this setting.

The diagnosis of FDE is often straightforward and is elucidated by the history. Antibiotics manufactured overseas are readily available in many ethnic markets, and the formulations may not be carefully regulated. In some patients, the reaction may be to a dye in a medication rather than the active ingredient. Fixed drug reaction may rarely be related to foods, including residual antibiotics in meat products and quinine contained in tonic water. Confirmation with provocation tests can be performed. Because of the “refractory period,” provocation tests need to be delayed at least 2 weeks from the last eruption. If an oral provocation test is considered, the initial challenge should be 10% of the standard dose, and patients with widespread lesions (SJS/TEN like) should not be challenged. Patch testing using a drug concentration of 10–20% in petrolatum or water applied to a previously reacted site is the recommended approach. In most patients, the treatment is simply to stop the medication. Desensitization can be successful.

Lesions of an FDE contain intraepidermal CD8+ T cells with the phenotypic markers of effector memory T cells. These epidermal resident T cells produce IFN- $\gamma$ . Such cells are found in resolved lesions of herpes simplex virus (HSV), suggesting they are a defense mechanism preventing viral reactivation in the epidermis. Once the medication is stopped, the abundant CD4+/FoxP3 T cells (Tregs) in lesions of FDE are believed to downregulate the eruption. In SJS/TEN patients, such Tregs are found in much fewer numbers than in FDE, explaining the progression of SJS/TEN despite stopping of the medication. Resident mast cells in lesions of FDE may be the cells initially activated with drug exposure, explaining the rapid onset of the lesion.

**Centers for Disease Control and Prevention:** Fixed drug eruption associated with sulfonamides sold in Latino grocery stores—Greater Washington, DC, Area, 2012–2013. *MMWR* 2013; 62(46):914–916.

**Hiware S, et al:** Evaluation of cutaneous drug reactions in patients visiting outpatient departments of Indira Gandhi Government Medical College and Hospital (IGGMC and H), Nagpur. *Indian J Dermatol* 2013; 58:18–21.

**Leleu C, et al:** Quinoline yellow dye-induced fixed food-and-drug eruption. *Contact Dermatitis* 2013; 68:187–188.

**Lim WS, et al:** A case of fixed drug eruption due to doxycycline and erythromycin present in food. *Allergy Asthma Immunol Res* 2013; 5:337–339.

**Lipowicz S, et al:** Prognosis of generalized bullous fixed drug eruption: comparison with Stevens-Johnson syndrome and toxic epidermal necrolysis. *Br J Dermatol* 2013; 168:726–732.

**Ognongo-Ibiaho AN, et al:** Epidemiological study of fixed drug eruption in Pointe-Noire. *Int J Dermatol* 2012; 51(Suppl 1):30–31, 33–35.

**Ohira A, et al:** Fixed eruption due to quinine in tonic water: a case report with high-performance liquid chromatography and ultraviolet A analyses. *J Dermatol* 2013; 40:629–631.

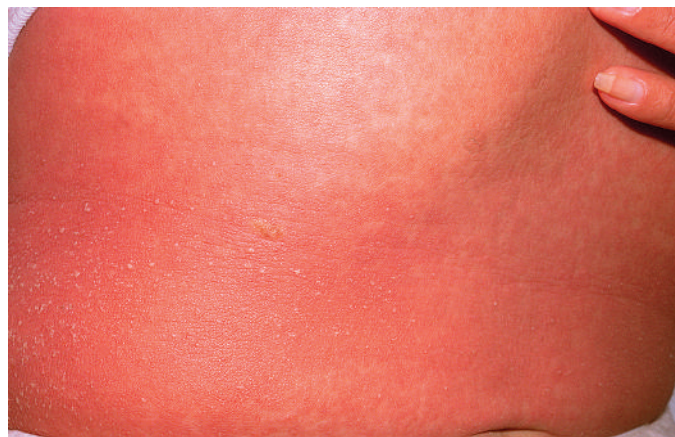**Özkaya E:** Oral mucosal fixed drug eruption: characteristics and differential diagnosis. *J Am Acad Dermatol* 2013; 69:e51–e58.

## Acute generalized exanthematous pustulosis

Also known as toxic pustuloderma and pustular drug eruption, AGEP is an uncommon reaction with an incidence of 1–5 cases per million per year. The average age in Europe is in the fifties and about one decade younger in Israel and Taiwan. Children can be affected. Women have been affected slightly more than men until recently, when a strong female predominance has been identified. Drugs are the most common cause of this reaction pattern, although AGEP has also been reported after mercury exposure. AGEP following viral and bacterial infections has been reported, but a causal association has not been validated. Similarly, *Loxosceles* spider (e.g., brown recluse) bites have been followed by AGEP, but some of these patients have also received antibiotics. Recent reports of “acute localized exanthematous pustulosis” (ALEP) appear to be acneiform eruptions that occur acutely after antibiotic exposure. The relationship to AGEP is unclear.

The eruption is of sudden onset, within 1 day in many cases associated with antibiotics, and averaging 11 days in other cases. The rash is accompanied by fever in most patients. Facial edema may be present. Initially, there is a scarlatiniform erythema. The eruption evolves and disseminates rapidly, consisting usually of more than 100 nonfollicular pustules less than 5 mm in diameter (Fig. 6-26). Nikolsky’s sign may be positive. Mucous membrane involvement is common but usually affects only one surface and is nonerosive. Laboratory abnormalities typically include a leukocytosis with neutrophilia (90%) and at times an eosinophilia (30%). Typically, the entire self-limited episode lasts up to 15 days. Characteristically, widespread superficial desquamation occurs as the eruption clears. AGEP can recur with a second exposure to the medication.

In more than 90% of patients, drugs are the cause of AGEP. Frequently implicated medications include ampicillin/amoxicillin, pristinamycin, quinolones, hydroxychloroquine, sulfonamide antibiotics, terbinafine, imatinib, and diltiazem. Corticosteroids, macrolides, oxycam, NSAIDs, pseudoephedrine, terazosin, omeprazole, sennoside, and antiepileptics have also caused AGEP. In some patients, contact sensitivity has been implicated as a cause, with a variety of triggering agents.



**Fig. 6-26** Acute generalized exanthematous pustulosis.



Recently, radiocontrast material has been shown to cause AGEP. In 5% of patients, no trigger can be identified.

In the classic case, the diagnosis is straightforward, with the characteristic sudden and rapid onset, widespread pustulation, and self-limited course. The facial edema and pustulation can simulate DRESS/DIHS from anticonvulsants. In anticonvulsant hypersensitivity syndrome, eosinophilia, lymphadenopathy, atypical lymphocytosis, and liver dysfunction are often found. Recently, cases of AGEP have been reported with a prolonged course, widespread erosive mucosal lesions, and systemic involvement identical to DRESS/DIHS, suggesting that AGEP may coexist with the anticonvulsant hypersensitivity syndrome. About 17% of patients with AGEP have systemic involvement, with respiratory involvement most common, and in about 1% or less, skin lesions similar to SJS/TEN are seen. These include purpuric atypical targets and widespread skin loss. Pustular psoriasis, especially pustular psoriasis of pregnancy, can be difficult to differentiate from AGEP. If there are no characteristic lesions of psoriasis elsewhere and no prior personal or family history of psoriasis, distinguishing these two entities may be impossible, and the patient may need to be followed for a final diagnosis to be made. A microbial pustulosis in the setting of a connective tissue disease can also resemble AGEP, but lesions are usually localized to the flexors, and the course is more chronic.

Histologically, early lesions show marked papillary edema, neutrophil clusters in the dermal papillae, and perivascular eosinophils. There may be an associated leukocytoclastic vasculitis. Well-developed lesions show intraepidermal or subcorneal spongiform pustules. If there is a background of erythema multiforme clinically, the histologic features of EM may be superimposed. The presence of eosinophils and the marked papillary edema help to distinguish this eruption from pustular psoriasis. However, pustular psoriasis of pregnancy is often associated with tissue eosinophilia.

Patch testing with the suspected agent may reproduce a pustular eruption on an erythematous base at 48 h in about 50% of patients. Patch testing rarely will result in a recrudescence of AGEP. AGEP is mediated by T cells, which produce high levels of IL-8, IFN- $\gamma$ , IL-4/IL-5, and granulocyte-macrophage colony-stimulating factor (GM-CSF). IL-8 is also produced by keratinocytes in lesions of AGEP.

Most patients with AGEP can be managed with topical corticosteroids and antihistamines. In many cases, systemic corticosteroids are also given. In severe cases, infliximab and etanercept have rapidly stopped the pustulation and appeared to have hastened the resolution of the eruption. This approach has also been used in AGEP/TEN patients with success. Cyclosporine, as used for pustular psoriasis, has been used effectively in an AGEP patient who relapsed as systemic corticosteroids were tapered.

**Bailey K, et al:** Acute generalized exanthematous pustulosis induced by hydroxychloroquine: first case report in Canada and review of the literature. *J Cutan Med Surg* 2013; 17:414–418.

**Bommarito L, et al:** A case of acute generalized exanthematous pustulosis due to amoxicillin-clavulanate with multiple positivity to beta-lactam patch testing. *Eur Ann Allergy Clin Immunol* 2013; 45:178–180.

**Eyler JT, et al:** Two cases of acute generalized exanthematous pustulosis related to oral terbinafine and an analysis of the clinical reaction pattern. *Dermatol Online J* 2012; 18(11):5.

**Hotz C, et al:** Systemic involvement of acute generalized exanthematous pustulosis: a retrospective study on 58 patients. *Br J Dermatol* 2013; 169:1223–1232.

**Mohyuddin GR, et al:** Acute generalized exanthematous pustulosis with multiple organ dysfunction syndrome. *Am J Crit Care* 2013; 22:270–273.

**Otero Rivas MM, et al:** Acute generalized exanthematous pustulosis due to dextromethorphan. *Dermatol Online J* 2013; 19(10):20030.

## Drug-induced pseudolymphoma

At times, exposure to medication may result in cutaneous inflammatory patterns that resemble lymphoma. These pseudolymphomatous drug eruptions may resemble either T-cell or B-cell lymphomas. The most common drug-induced pseudolymphoma is one resembling cutaneous T-cell lymphoma (CTCL) clinically and histologically. The most common setting in which these pseudolymphomas occur is a drug-induced hypersensitivity syndrome (DRESS/DIHS), as described earlier, in which infrequently the histology may resemble CTCL. More rarely, medications may induce plaques or nodules, usually in elderly white men after many months of treatment. Lymphadenopathy and circulating Sézary cells may also be present. CD30+ cells may be present in the infiltrate. Usually, other features (e.g., keratinocyte necrosis, dermal edema) help to distinguish these reactions from true lymphoma. Importantly, T-cell receptor gene rearrangements in the skin and blood may be positive (or show pseudoclones) in these drug-induced cases, representing a potential pitfall for the unwary physician. Pseudolymphoma resolves with discontinuation of the medication. The medication groups primarily responsible are anticonvulsants, sulfa drugs (including thiazide diuretics), dapsone, and antidepressants. Vaccinations and herbal supplements can also induce pseudolymphoma.

**Keri K:** Histopathological patterns indicative of distinct adverse drug reactions. *Chem Immunol Allergy* 2012; 97:61–78.

**Macisaac JL, et al:** Cutaneous T-cell lymphoma–like drug eruption in an HIV-positive patient taking vancomycin and rifampin. *J Cutan Med Surg* 2013; 17:433–436.

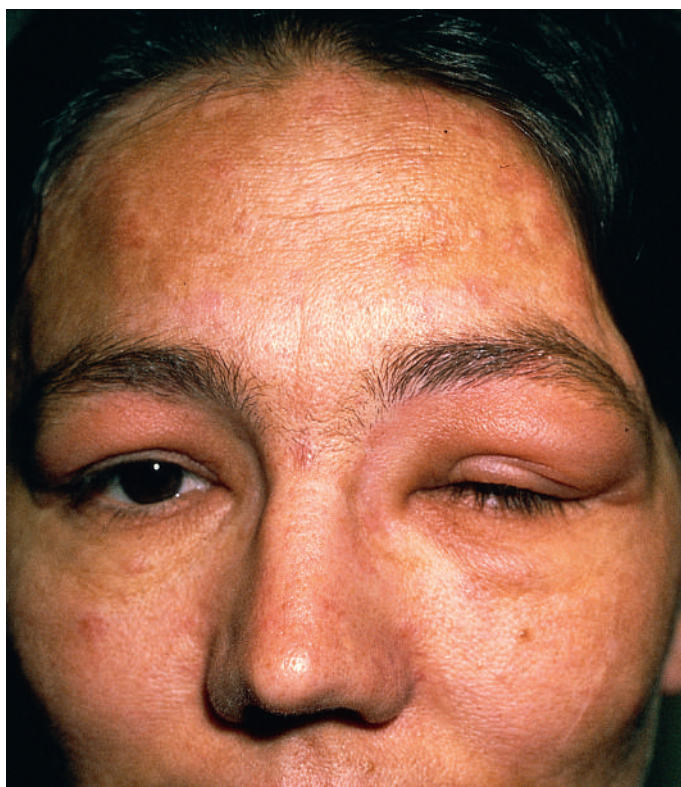**Pulitzer MP, et al:** CD30+ lymphomatoid drug reactions. *Am J Dermatopathol* 2013; 35:343–350.

## Urticaria/angioedema

Medications may induce urticaria by immunologic and non-immunologic mechanisms. In either case, clinically the lesions are pruritic wheals or angioedema (Fig. 6-27). Urticaria may be part of a more severe anaphylactic reaction with bronchospasm, laryngospasm, or hypotension. Immediate hypersensitivity skin testing and sometimes RAST is useful in evaluating risk for these patterns of reaction.

Aspirin and NSAIDs are the most common causes of nonimmunologic urticarial reactions. They alter prostaglandin metabolism, enhancing degranulation of mast cells. They may therefore also exacerbate chronic urticaria of other causes. The nonacetylated salicylates (trilisate and salsalate) do not cross-react with aspirin in patients experiencing bronchospasm and may be safe alternatives. Some patients have urticaria to only one medication in this family, without cross-reaction with other NSAIDs, suggesting that specific IgE-mediated mechanisms may also be possible in NSAID-induced urticaria. Other agents causing nonimmunologic urticaria include radiocontrast material, opiates, tubocurarine, and polymyxin B. Pretesting does not exclude the possibility of anaphylactoid reaction to radiocontrast material. The use of low-osmolarity radiocontrast material and pretreatment with antihistamines, systemic steroids, and in those with a history of asthma, theophylline, may reduce the likelihood of reaction to radiocontrast material.

Immunologic urticaria is most often associated with penicillin and related  $\beta$ -lactam antibiotics and relates to the minor determinants rather than the  $\beta$ -lactam ring. It is associated with IgE antibodies to penicillin or its metabolites. Skin testing with major and minor determinants is useful in evaluating patients with a history of urticaria associated with penicillin exposure. Patients with penicillin allergy have an increased



**Fig. 6-27** Angioedema and urticaria.

rate of reaction to cephalosporins. In the case of cefaclor, half of anaphylactic reactions occur in patients with a history of penicillin allergy. Third-generation cephalosporins, especially cefdinir, are much less likely to induce a reaction in a penicillin-allergic patient than are first- or second-generation agents.

Bupropion is often used for depression and smoking cessation. It can induce urticaria, which may be associated with hepatitis and a serum sickness like syndrome. Two antihistamines, cetirizine and hydroxyzine, may induce urticaria, an apparent paradox which may lead to confusion in the clinical setting.

Angioedema is a known complication of the use of angiotensin-converting enzyme (ACE) inhibitors and angiotensin II antagonists. Blacks are at almost five times greater risk than whites. Lisinopril and enalapril produce angioedema more frequently than captopril. Angioedema typically occurs within a week of starting therapy but may begin after months of treatment. The episodes may be severe, requiring hospitalization in up to 45% of patients, intensive care in up to 27%, and intubation in up to 18%. One quarter of patients affected give a history of previous angioedema. Captopril enhances the flare reaction around wheals. The angioedema appears to be dose dependent, because it may resolve with decreased dose. All these factors suggest that the angioedema may represent a consequence of a normal pharmacologic effect of the ACE inhibitors. The blocking of kininase II by ACE inhibitors may increase tissue kinin levels, enhancing urticarial reactions and angioedema. Although this is dose dependent, ACE inhibitor users with one episode of angioedema have a 10-fold risk of a second episode, and the recurrent episodes may be more severe. The treatment of urticaria is discussed in Chapter 7.

### Red man syndrome

The intravenous infusion of vancomycin, especially if rapid, is frequently complicated by a characteristic reaction called “red

man syndrome.” At any time during the infusion, a macular eruption appears initially on the back of the neck, sometimes spreading to the upper trunk, face, and arms. Angioedema has been described. There is associated pruritus and “heat,” as well as hypotension that may be severe enough to cause cardiac arrest. Oral vancomycin has caused a similar reaction in a child. Children with systemic juvenile idiopathic arthritis (JIA) may have potentially fatal macrophage activation syndrome during or after a “red man reaction” from vancomycin. The red man reaction is caused by elevated blood histamine. Red man syndrome can be prevented in most patients by reducing the rate of infusion of the antibiotic, or by pretreatment with H1 and H2 antihistamines. Although typically reported with vancomycin, similar “anaphylactoid” reactions have been seen with ciprofloxacin, cefepime, amphotericin B, rifampin, infliximab, and teicoplanin.

**Bauters T, et al:** Vancomycin-induced red man syndrome in pediatric oncology: still an issue? *Int J Clin Pharm* 2012; 34:13–16.

**Myers AL, et al:** Defining risk factors for red man syndrome in children and adults. *Pediatr Infect Dis J* 2012; 31:464–468.

**Panos G, et al:** Red man syndrome adverse reaction following intravenous infusion of cefepime. *Antimicrob Agents Chemother* 2012; 56:6387–6388.

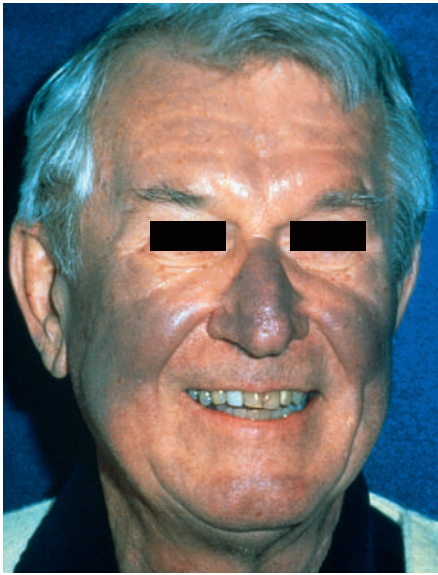
### Photosensitivity reactions (photosensitive drug reactions)

Medications may cause phototoxic, photoallergic, and lichenoid reactions and photodistributed telangiectasias, as well as pseudoporphyria. The mechanisms of photosensitivity are discussed in Chapter 3. In many cases, the mechanism for drug-induced photosensitivity is unknown. Most medication-related photosensitivity is triggered by radiation in the UVA range, partly because (1) most photosensitizing drugs have absorption spectra in the UVA and short-visible range (315–430 nm), and (2) UVA penetrates into the dermis where the photosensitizing drug is present. The most common causes of photosensitivity are NSAIDs, TMP-SMX, thiazide diuretics and related sulfonyleureas, quinine and quinidine, phenothiazines, and certain tetracyclines; numerous other medications in many classes induce photosensitivity less frequently.

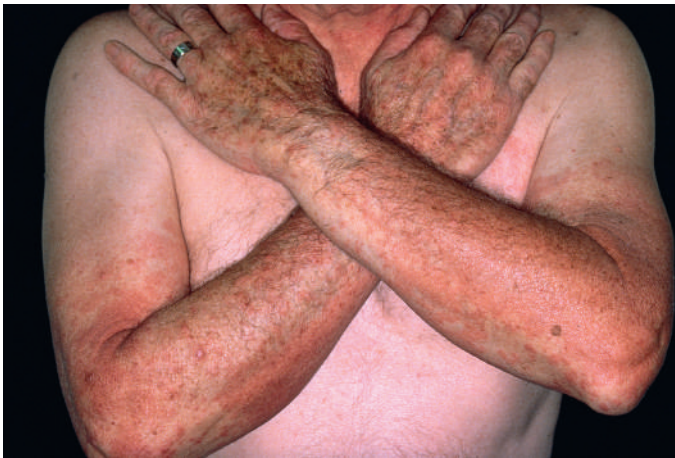Phototoxic reactions are related to the dose of both the medication and the UV irradiation. Reactions can occur in anyone if sufficient thresholds are reached and do not require prior exposure or participation by the immune system. Persons of higher skin types are at lower risk of developing phototoxic eruptions in some studies. There is individual variation in the amount of photosensitivity created by a standard dose of medication, independent of serum concentration. This remains unexplained but reflects the clinical setting, where interindividual variability in development of phototoxic eruptions is seen. Reactions can appear from hours to days after exposure. Tetracyclines, amiodarone, and NSAIDs are common culprits. The reaction may present as immediate burning with sun exposure (amiodarone, chlorpromazine) or exaggerated sunburn (fluoroquinolone antibiotics, chlorpromazine, amiodarone, thiazide diuretics, quinine, tetracyclines). Hyperpigmentation may complicate phototoxic reactions and may last for many months. Treatment may include dose reduction and photoprotection by a sunblock with strong coverage through the whole UVA spectrum.

Photoallergic reactions are typically eczematous and pruritic, may first appear weeks to months after drug exposure, and involve the immune system. Unfortunately, in the patient with photoallergy to systemic medications, photopatch testing is infrequently positive and of limited clinical value. In general, photoallergic reactions are not as dependent on drug dose as





**Fig. 6-28** Amiodarone-induced pigmentation.



**Fig. 6-29** Piroxicam photosensitivity.

phototoxic reactions. Photosensitivity of both the phototoxic and the photoallergic type may persist for months to years after the medication has been stopped. Photosensitivity reactions to various drugs are discussed individually next, emphasizing the characteristic patterns seen with each medication group.

Amiodarone photosensitivity develops in up to 75% of treated patients and occurs after a cumulative dose of 40 g. A reduced minimal erythema dose (MED) to UVA, but not UVB, occurs, and gradually returns to normal between 12 and 24 months after stopping the medication. Stinging and burning may occur as soon as 30 min after sun exposure. Less frequently, a dusky, blue-red erythema of the face and dorsa of the hands occurs (Fig. 6-28). At times, papular reactions are also seen. Desquamation, as seen after sunburn, is not observed following amiodarone photosensitivity reactions. This reaction may be dose dependent, and acute burning may be relieved by dose reduction. Narrow-band UVB may desensitize patients with persistent phototoxicity after stopping amiodarone.

The NSAIDs, especially piroxicam, are frequently associated with photosensitivity (Fig. 6-29). The characteristic reaction is a vesicular eruption of the dorsa of the hands, sometimes associated with a dyshidrosiform pattern on the lateral aspects of the hands and fingers. In severe cases, even the palms may be

involved. Histologically, this reaction pattern shows intraepidermal spongiosis, exocytosis, and perivascular inflammatory cells—a pattern typical of photoallergy. However, this reaction may occur on the initial exposure to the medication, but phototoxicity tests in animals and humans have been negative. Patients with photosensitivity to piroxicam may also react to thiosalicylic acid, a common sensitizer in thimerosal. Half of patients having a positive patch test to thimerosal with no prior exposure to piroxicam test positive to piroxicam. This suggests that piroxicam reactions seen on initial exposure to the medication may be related to sensitization during prior thimerosal exposure.

Sulfonamide antibiotics, related hypoglycemic agents, and the sulfonyleurea diuretics may all be associated with photosensitivity reactions. In addition, patients may tolerate one of the medications from this group, but when additional members of the group are added, clinical photosensitivity occurs. The typical pattern is erythema, scale, and in chronic cases, lichenification and hyperpigmentation.

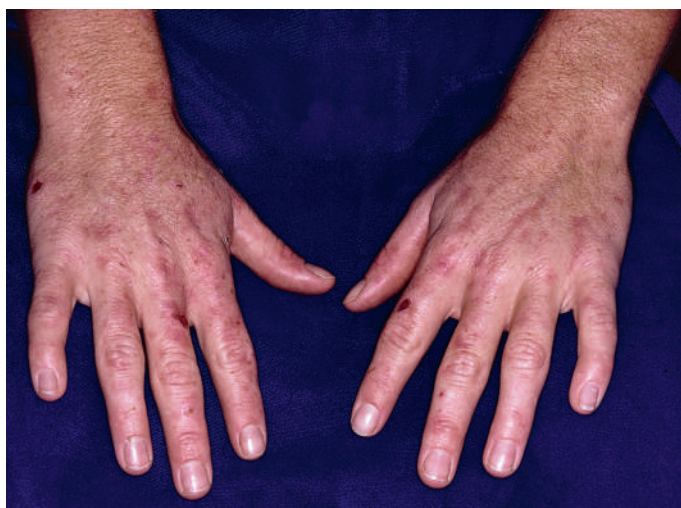Fluoroquinolone antibiotics are frequently associated with photosensitivity reactions. Sparfloxacin is highly photosensitizing; enoxacin, ciprofloxacin, and sitafloxacin are mildly photosensitizing; and levofloxacin rarely, if ever, causes photosensitivity.

Photodistributed lichenoid reactions have been reported most often from thiazide diuretics, quinidine, and NSAIDs, but also occur from diltiazem and clopidogrel bisulfate. They present as erythematous patches and plaques. Sometimes, typical Wickham's striae are observed in the lesions. Histologically, photodistributed lichenoid reactions are often indistinguishable from idiopathic lichen planus. Marked hyperpigmentation may occur, especially in persons of higher skin types (IV–VI) and diltiazem-induced cases. The lichenoid nature of the eruption may not be clinically obvious, and histology is required to confirm the diagnosis. This hyperpigmentation may persist for months. UVA-associated phototoxicity is also common with vemurafenib, with reduced UVA MED in 94% of those tested.

Voriconazole, a second-generation triazole, has been associated with an unusual combination of photosensitive phenomena. Photosensitivity occurs in 1–2% or more of patients taking voriconazole for more than 12 weeks. It appears to be UVA induced, and is not dose dependent. Usually, the photosensitivity is mild, and with the use of sun protection and topical treatment, voriconazole can be continued. Cheilitis and facial erythema are typical initial manifestations. In a few patients, however, significant complications occur. Pseudoporphyria (with foot erosions as well), eruptive lentiginos and atypical nevi, premature aging, and even the development of highly aggressive and potentially fatal squamous cell carcinomas in sun-exposed sites have been reported. Affected patients can closely resemble patients with xeroderma pigmentosa. Photodistributed granuloma annulare has also been seen. This severe form of photosensitivity rapidly resolves on stopping voriconazole. Posaconazole can be an effective alternative.

Photodistributed telangiectasia is a rare complication of calcium channel blockers (nifedipine, felodipine, amlodipine). UVA appears to be the action spectrum. Cefotaxime has also been reported to produce this reaction. Corticosteroids, oral contraceptives, isotretinoin, IFNs, lithium, thiothixene, lithium, methotrexate, and other medications may induce telangiectasia, but not through photosensitivity.

Pseudoporphyria is a photodistributed bullous reaction clinically and histologically resembling porphyria cutanea tarda (Fig. 6-30). Patients present with blistering on sun-exposed skin of the face and hands and skin fragility. Varioliform scarring occurs in 70% of patients. Facial scarring is especially common in children with pseudoporphyria. Hypertrichosis is rarely



**Fig. 6-30** Sixteen-year-old with scarring from pseudo-porphyrria cutanea tarda reaction to tetracycline.

found; dyspigmentation and sclerodermoid changes are not reported. Porphyrin studies are normal. The blistering usually resolves gradually once the offending medication is stopped. However, skin fragility may persist for years. Naproxen is the most frequently reported cause. Up to 12% of children with JIA treated with NSAIDs may develop pseudoporphyria. Pseudoporphyria has also been reported to other NSAIDs (oxaprozin, nabumetone, ketoprofen, mefenamic acid; but not piroxicam), tetracycline, furosemide, nalidixic acid, isotretinoin, acitretin, 5-fluorouracil, bumetanide, dapsone, oral contraceptives, rofecoxib, celecoxib, cyclosporine, voriconazole, and pyridoxine. Tanning booth (sunbed) exposure and even excessive sun exposure can produce pseudoporphyria. Cases in women outnumber men by 24:1. Some women with sunbed-induced pseudoporphyria are taking oral contraceptives. Patients on dialysis may develop pseudoporphyria, and *N*-acetylcysteine in doses up to 600 mg twice daily may lead to improvement in these cases. Histologically, a pauci-inflammatory subepidermal vesicle is seen. DIF may show immunoglobulin and complement deposition at the DEJ and perivascularly, as seen in porphyria cutanea tarda.

**Boussemart L, et al:** Prospective study of cutaneous side-effects associated with the BRAF inhibitor vemurafenib: a study of 42 patients. *Ann Oncol* 2013; 24:1691–1697.

**Elkeeb D, et al:** Photosensitivity: a current biological overview. *Cutan Ocul Toxicol* 2012; 31:263–272.

**Gelot P, et al:** Vemurafenib: an unusual UVA-induced photosensitivity. *Exp Dermatol* 2013; 22:297–298.

**Hansford JR, et al:** Idiosyncratic nature of voriconazole photosensitivity in children undergoing cancer therapy. *J Antimicrob Chemother* 2012; 67:1807–1809.

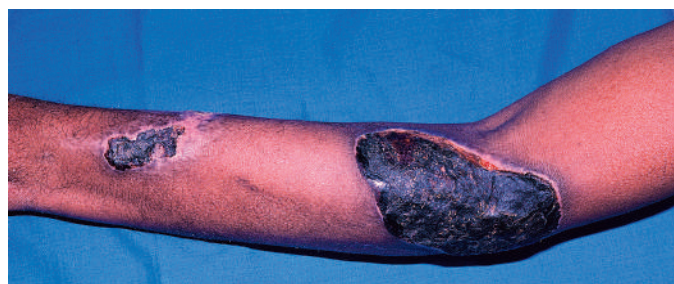
**Haylett AK, et al:** Voriconazole-induced photosensitivity: photobiological assessment of a case series of 12 patients. *Br J Dermatol* 2013; 168:179–185.

**Lacouture ME, et al:** Analysis of dermatologic events in vemurafenib-treated patients with melanoma. *Oncologist* 2013; 18:314–322.

**Srinivas CR, et al:** Photodermatoses in India. *Indian J Dermatol Venereol Leprol* 2012; 78(Suppl 1):1–8.

### Anticoagulant-induced skin necrosis

Both warfarin and heparin induce lesions of cutaneous necrosis, although by different mechanisms. Obese, postmenopausal women are predisposed, and lesions tend to occur in areas with abundant subcutaneous fat, such as the breast, abdomen, thigh, or buttocks. The clinical appearance overlaps with



**Fig. 6-31** Warfarin-induced necrosis.

calciphylaxis, and patients with warfarin-induced calciphylaxis have been described.

Warfarin-induced skin necrosis (WISN) usually occurs 3–5 days after therapy is begun, and a high initial dose increases the risk. Patients with a much more delayed onset (up to 15 years) are ascribed to noncompliance, drug-drug interactions, or liver dysfunction. WISN occurs in 1:1000 to 1:10,000 patients treated with warfarin. Lesions begin as red, painful plaques that develop petechiae, then form a large bulla. Necrosis follows (Fig. 6-31). Priapism can complicate warfarin necrosis. Hereditary or acquired deficiency of protein C, and less often protein S, antithrombin III, or factor V Leiden, and lupus anticoagulant syndrome are associated with warfarin necrosis. A less common variant seen in patients with a deep venous thrombosis (DVT) of an extremity is necrosis of a distal extremity, usually the one with the DVT. Warfarin-induced venous limb necrosis is most often seen in cancer patients, but also in the setting of heparin-induced thrombocytopenia and antiphospholipid syndrome.

Early in warfarin treatment, the serum levels of the vitamin K-dependent antithrombotic protein C fall. Since the half-life of antithrombotic protein C is shorter than that of the vitamin K-dependent prothrombotic factors II, X, and IX, an acquired state of reduced protein C level occurs before the clotting factors are reduced. This creates a temporary prothrombotic state. This is more likely to occur if the levels of protein C are already low, if other antithrombotic proteins are deficient, or if the patient has an associated hypercoagulable state. This explains why the syndrome does not always recur with gradual reinstitution of warfarin, and why it has been reported to resolve with continued warfarin treatment. Histologically, noninflammatory thrombosis with fibrin in the subcutaneous and dermal vessels is seen. Treatment is to stop the warfarin, administer vitamin K to reverse the warfarin, and begin heparin or low-molecular-weight (LMW) heparin. Administration of purified protein C can rapidly reverse the syndrome, as well as associated priapism. Rivaroxaban, a direct inhibitor of activated factor X that does not inhibit other vitamin K-dependent proteins, may be considered an alternative anticoagulant. Dabigatran etexilate has been suggested for prevention of warfarin-induced skin necrosis in the patient with protein C deficiency.

Heparin induces necrosis both at the sites of local injections and in a widespread pattern when infused intravenously or given by local injection. Local reactions are the most common. Heparin can also induce local allergic reactions at injection sites, which are distinct from the necrosis syndrome. Independent of its method of delivery, heparin-induced skin necrosis lesions present as tender red plaques that undergo necrosis, usually 6–12 days after the heparin treatments are started. Intraepidermal hemorrhagic bullae have also been described. Unfractionated heparin is more likely to cause this complication than fractionated LMW heparin, and postsurgical patients are at greater risk than medical patients. Even the heparin



used for dialysis or to flush arterial catheters may be associated with cutaneous necrosis, simulating calciphylaxis.

Some necrotic reactions to local injections, and most disseminated reactions occurring with intravenous heparin, are associated with heparin-induced thrombocytopenia (HIT). Patients with underlying prothrombotic conditions, such as factor V Leiden and prothrombin mutations or elevated levels of factor VIII, may develop severe skin lesions if they develop HIT and heparin necrosis. A heparin-dependent antiplatelet antibody is the pathogenic basis of HIT and apparently of heparin-induced skin necrosis. This antibody causes both the thrombocytopenia and the aggregation of platelets in vessels, leading to thrombosis (white clot syndrome). The antibody may appear up to 3 weeks after the heparin has been discontinued, so the onset of the syndrome may be delayed. Histologically, fibrin thrombi are less reproducibly found in affected tissues, because the vascular thrombosis is the result of platelet aggregation, not protein deposition. The process may not only produce infarcts in the skin, but also cause arterial thrombosis of the limbs, heart, lung, and brain, resulting in significant morbidity or mortality. Bilateral adrenal necrosis caused by hemorrhagic infarction can occur and, if not detected early, may lead to death from acute Addisonian crisis. The syndrome must be recognized immediately in any patient receiving heparin with late-developing thrombocytopenia. The treatment is to stop the heparin and give a direct thrombin inhibitor and vitamin K. After the platelet count has returned to normal, warfarin therapy is typically given for 3–6 months. Patients with HIT cannot be treated with warfarin immediately, as the warfarin would be ineffective in stopping the thrombosis (it is *not* antithrombotic) and may worsen the thrombosis by enhancing coagulation. The diagnosis of HIT can be delayed because the antiplatelet antibody may not be present while the platelet count is falling. Adding warfarin at this time can lead to disastrous widespread acral thrombosis resembling disseminated intravascular coagulation (DIC).

Skin necrosis has also been associated with enoxaparin. Patients with cancer, an acquired prothrombotic state, are at increased risk for DVT. If they are treated with heparin and develop HIT, patients are at extreme risk for development of a prothrombotic state if treated with warfarin. In this setting, digital and limb gangrene has occurred in the face of normal peripheral pulses and supertherapeutic anticoagulation by standard measures (international normalized ratio, INR). The consumptive coagulopathy induced by the cancer is the underlying trigger.

**Choudhry S, et al:** Heparin-induced bullous hemorrhagic dermatosis. *Cutis* 2013; 91:93–98.

**Gucalp A, et al:** Skin necrosis induced by generic enoxaparin. *Am J Hematol* 2013; 88:339.

**Hafiji J, et al:** Warfarin-induced calciphylaxis successfully treated with sodium thiosulphate. *Australas J Dermatol* 2013; 54:133–135.

**Hermans C, et al:** Dabigatran etexilate (Pradaxa) for preventing warfarin-induced skin necrosis in a patient with severe protein C deficiency. *Thromb Haemost* 2012; 107:1189–1191.

**Martinelli I, et al:** Anticoagulant treatment with rivaroxaban in severe protein S deficiency. *Pediatrics* 2013; 132:e1435–e1439.

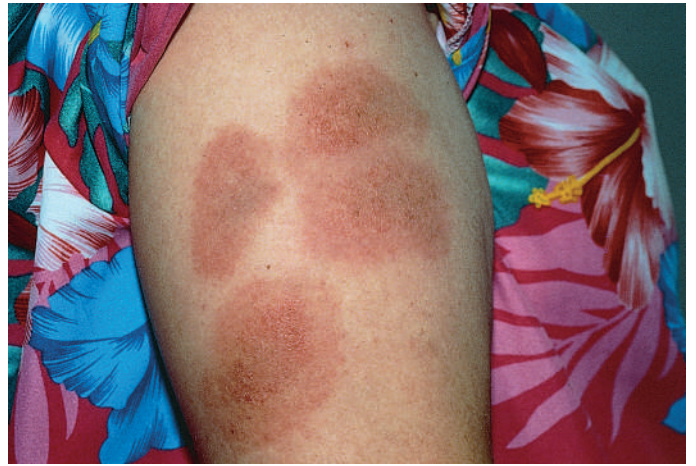**Mungalsingh CR, et al:** Warfarin-induced skin necrosis. *Clin Med* 2012; 12:90–91.

**Saifan C, et al:** Warfarin-induced calciphylaxis: a case report and review of literature. *Int J Gen Med* 2013; 6:665–669.

**Stelfox HT, et al:** Skin necrosis in patients with arterial catheters flushed with a solution containing heparin. *Intensive Care Med* 2012; 38:918–919.

## Vitamin K reactions

Several days to 2 weeks after injection of vitamin K, an allergic reaction at the injection site may occur (Fig. 6-32). Most affected



**Fig. 6-32** Vitamin K allergy.

patients have liver disease and are being treated for elevated prothrombin time. The lesions are pruritic red patches or plaques that can be deep seated, involving the dermis and subcutaneous tissue. There may be superficial vesiculation. Lesions occur most often on the posterior arm and over the hip or buttocks. Plaques on the hip tend to progress around the waist and down the thigh, forming a “cowboy gunbelt and holster” pattern. Small, generalized eczematous papules may occur on other skin sites in severe reactions. These reactions usually persist for 1–3 weeks, but may persist much longer, or resolve only to recur spontaneously. On testing, patients with this pattern of reaction are positive on intradermal testing to the pure vitamin K<sub>1</sub>.

In Europe, a second pattern of vitamin K reaction has been reported. Subcutaneous sclerosis with or without fasciitis appears at the injection site many months after vitamin K treatment. There may have been a preceding acute reaction as previously described. Peripheral eosinophilia may be found. These pseudosclerodermatous reactions have been termed Texier’s disease and last several years.

The addition of vitamin K<sub>1</sub> to cosmetics has led to allergic contact dermatitis from the vitamin K, confirmed by patch testing.

## Injection site reactions

In addition to allergic reactions, as described with vitamin K, cutaneous necrosis may occur at sites of medication injections. These are of two typical forms: those associated with intravenous (IV) infusions and those related to intramuscular (IM) injections. Pharmacologic agents that extravasate into tissue during IV infusion may cause local tissue necrosis, resulting from inherent tissue-toxic properties. These include chemotherapeutic agents, calcium salts, radiocontrast material, and nafcillin. IM injections may produce a syndrome called embolia cutis medicamentosa, livedoid dermatitis, or Nicolau syndrome. Immediately after injection, local intense pain occurs and the overlying skin blanches (ischemic pallor). Within minutes to hours, the site develops an erythematous macule that evolves into a livedoid violaceous patch with dendrites. This becomes hemorrhagic, then ulcerates, often forming a deep ulcer many centimeters in diameter. Eventually, over weeks to months, the ulcer heals with an atrophic scar. Muscle and liver enzymes may be elevated, and neurologic symptoms and sequelae occur in one third of patients. The circulation of the limb may be affected, rarely leading to amputation. Nicolau syndrome has been seen with injection of many unrelated agents, including NSAIDs, local anesthetics, corticosteroids,

antibiotics, IFN alpha, sedatives, vaccines, and medroxyprogesterone acetate (Depo-Provera). It appears to be caused by periarterial injection leading to arterial thrombosis. IFN- $\beta$  injections into subcutaneous tissue of the abdomen, buttocks, or thighs of patients with multiple sclerosis has resulted in similar lesions. Patient education and auto-injectors can prevent this complication. Biopsy of the interferon injection site reactions resembles lupus panniculitis. Vitamin B<sub>12</sub> also produces localized sclerodermoid reactions. Treatment of Nicolau syndrome is conservative: dressing changes, debridement, bed rest, and pain control. Surgical intervention is rarely required.

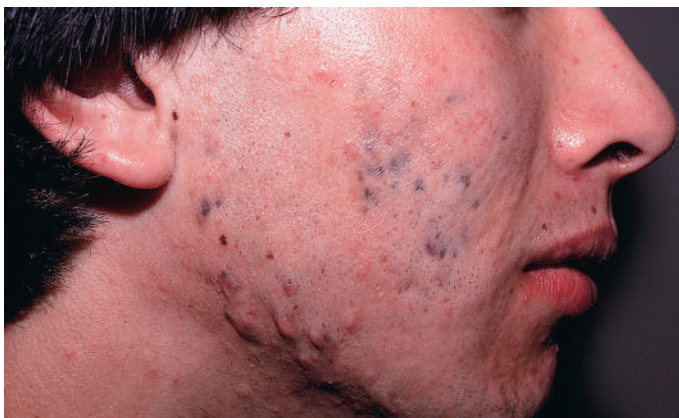**Pereira SP, et al:** Adverse events associated with vitamin K1: results of a worldwide postmarketing surveillance programme. *Pharmacoepidemiol Drug Saf* 1998; 7:173–182.

**Sousa T, et al:** Localized cutaneous reaction to intramuscular vitamin K in a patient with acute fatty liver of pregnancy. *Dermatol Online J* 2010; 16(12):16.

## Drug-induced pigmentation

Pigmentation of the skin may result from drug administration. The mechanism may be postinflammatory hyperpigmentation in some patients but frequently is related to actual deposition of the drug in the skin.

Minocycline induces many types of hyperpigmentation, which may occur in various combinations in the affected patient. Classically, three types of pigmentation are described. Type I is a blue-black discoloration appearing in areas of prior inflammation, often acne or surgical scars (Fig. 6-33). This may be the most common type seen by dermatologists. It does not appear to be related to the total or daily dose of exposure. In all other types of pigmentation resulting from minocycline, the incidence increases with total dose, with up to 40% of treated patients experiencing hyperpigmentation with more than 1 year of therapy. The second type (type II) is the appearance of a similar-colored pigmentation on the normal skin of the anterior shins, analogous to that seen in antimalarial-induced hyperpigmentation. It is initially mistaken for ecchymoses but does not fade quickly. In most cases, types I and II minocycline pigmentation occur after 3 months to several years of treatment. Generalized black hyperpigmentation has occurred after several days or a few weeks of treatment in Japanese patients. In type I and type II minocycline hyperpigmentation, histologic evaluation reveals pigment granules within macrophages in the dermis and at times in the fat, resembling a tattoo. These granules usually stain positively for both iron and melanin, the usual method for confirming the diagnosis. At times, the macrophages containing minocycline are found only in the



**Fig. 6-33** Minocycline-induced hyperpigmentation.

subcutaneous fat. Stains for iron may be negative in some cases. Calcium stains may also be positive because minocycline binds calcium. In unusual cases, electron microscopy or sophisticated chemical analysis can confirm the presence of minocycline in the granules. The least common type (type III) is generalized, muddy-brown hyperpigmentation, accentuated in sun-exposed areas. Tigecycline may produce similar hyperpigmentation. Histologic examination reveals only increased epidermal and dermal melanin. This may represent the consequence of a low-grade photosensitivity reaction.

In addition to the skin, minocycline types I and II pigmentation may also involve the sclera, conjunctiva, bone, thyroid, ear cartilage (simulating alkaptonuria), nail bed, oral mucosa, and permanent teeth. Tetracycline staining of the teeth is usually related to childhood or fetal exposure, is brown, and is accentuated on the gingival third of the teeth. Dental hyperpigmentation caused by minocycline, in contrast, occurs in adults, is gray or gray-green, and is most marked in the mid-portion of the tooth. Some patients with affected teeth do not have hyperpigmentation elsewhere. Cutaneous hyperpigmentation from minocycline fades slowly, and the teeth may remain pigmented for years. The blue-gray pigmentation of the skin may be improved with the Q-switched ruby laser or fractional photothermolysis.

Chloroquine, hydroxychloroquine, and quinacrine all may cause a blue-black pigmentation of the face, extremities, ear cartilage, oral mucosa, and nails. Pretibial hyperpigmentation is the most common pattern and is similar to that induced by minocycline. The gingiva or hard palate may also be discolored. Quinidine may also rarely cause such a pattern of hyperpigmentation. Quinacrine is yellow and concentrated in the epidermis. Generalized yellow discoloration of the skin and sclera (mimicking jaundice) occurs reproducibly in patients but fades within 4 months of stopping the drug. In dark-skinned patients, this color is masked and less significant cosmetically. Histologically, in both forms of pigmentation, pigment granules are present within macrophages in the dermis.

Amiodarone after 3–6 months causes photosensitivity in 30–57% of treated patients. In 1–10% of patients, a slate-gray hyperpigmentation develops in the areas of photosensitivity. The pigmentation gradually fades after the medication is discontinued. Histologically, periodic acid–Schiff (PAS)-positive, yellow-brown granules are seen within the cytoplasm of macrophages in the dermis. Electron microscopy reveals membrane-bound structures resembling lipid-containing lysosomes. It responds to treatment with the Q-switched ruby laser.

Clofazimine treatment is reproducibly complicated by the appearance of a pink discoloration that gradually becomes reddish blue or brown and is concentrated in the lesions of patients with Hansen's disease. This pigmentation may be disfiguring and is a major cause of noncompliance with this drug in the treatment of Hansen's disease. Histologically, a PAS-positive, brown, granular pigment is variably seen within foamy macrophages in the dermis. This has been called "drug-induced lipofuscinosis."

Zidovudine causes a blue or brown hyperpigmentation that is most frequently observed in the nails. The lunula may be blue, or the whole nail plate may become dark brown. Diffuse hyperpigmentation of the skin, pigmentation of the lateral tongue, and increased tanning are less common. It occurs in darkly pigmented persons, is dose dependent, and clears after zidovudine is discontinued. Hydroxyurea causes a similar pattern of hyperpigmentation (Fig. 6-34).

Chlorpromazine, thioridazine, imipramine, and clomipramine may cause a slate-gray hyperpigmentation in sun-exposed areas after long periods of ingestion. Frequently,



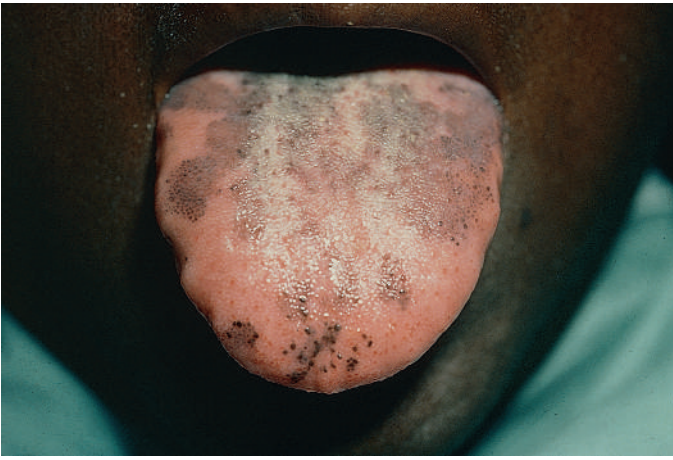

Fig. 6-34 Hydroxyurea-induced pigmentation, tongue.

corneal and lens opacities are also present, so all patients with hyperpigmentation from these medications should have an ophthalmologic evaluation. The pigmentation from the phenothiazines fades gradually over years, even if the patient is treated with another phenothiazine. The corneal, but not the lenticular, changes also resolve. Imipramine hyperpigmentation has been reported to disappear within 1 year. Histologically, in sun-exposed but not sun-protected skin, numerous refractile golden-brown granules are present within macrophages in the dermis, along with increased dermal melanin. The slate-gray color comes from a mixture of the golden-brown pigment of the drug and the black color of the melanin viewed in the dermis.

The heavy metals gold, silver, and bismuth produce blue to slate-gray hyperpigmentation. Pigmentation occurs after years of exposure, predominantly in sun-exposed areas, and is permanent. Silver is by far the most common form of heavy metal-induced pigmentation seen by dermatologists. It occurs in two forms, local or systemic. Local argyria typically follows the topical use of silver sulfadiazine or silver-containing dressings (Acticoat). Blue-gray pigmentation occurs at the site of application. Implantation into the skin by needles or pierced jewelry may lead to focal areas of argyria. Systemic argyria can also arise from topical application to the skin (in burn and epidermolysis bullosa patients), by inhalation, by mucosal application (nose drops or eyedrops), or by ingestion. Patients may purchase or build devices that allow them to make colloidal silver solutions, which they then ingest in the belief that it will improve their health. After several months of such exposure, the skin becomes slate-gray or blue-gray, primarily in areas of sun exposure. Histologically, granules of silver are found in basement membranes around adnexal (especially eccrine) and vascular structures. Sun exposure leads to the silver binding to either sulfur or selenium in the skin, increasing deposition. The deposited silver activates tyrosinase, increasing pigmentation. Most patients with argyria have no systemic symptoms or consequences of the increased silver in their body. In one patient, the use of a Q-switched 1064-nm neodymium-doped yttrium-aluminum-garnet (Nd:YAG) laser improved the condition. Gold deposition was more common when gold was used as a treatment for rheumatoid arthritis. Cutaneous chrysiasis also presents as blue-gray pigmentation, usually after a cumulative dose of 8 g. Chrysiasis is also more prominent in sun-exposed sites. Dermatologists should remain aware of this condition, since patients treated with gold, even decades earlier, may develop disfiguring hyperpigmentation after Q-switched laser therapy for hair removal or lentiginos lightening. Chrysiasis has been treated

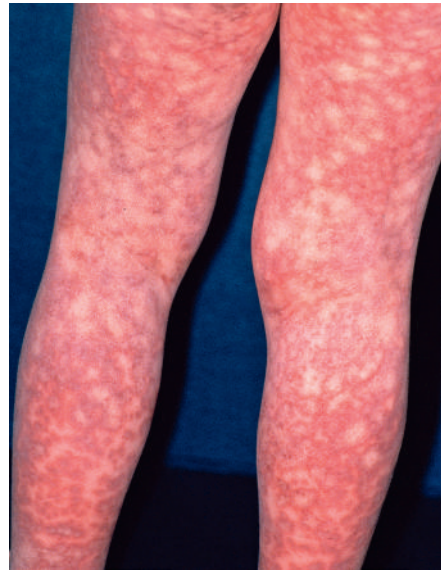


Fig. 6-35 Cefaclor-induced reaction.

effectively in one patient using repeated 595-nm pulsed dye laser therapy. Bismuth also pigments the gingival margin. Histologically, granules of the metals are seen in the dermis and around blood vessels. Arsenical melanosis is characterized by black, generalized pigmentation or by a pronounced truncal hyperpigmentation that spares the face, with scattered depigmented macules that resemble raindrops.

The calcium channel blocker (CCB) diltiazem can cause a severe photodistributed hyperpigmentation. This is most common in African American or Hispanic women and occurs about 1 year after starting therapy. The lesions are slate-gray or gray-blue macules and patches on the face, neck, and forearms. Perifollicular accentuation is noted. Histology shows a sparse lichenoid dermatitis with prominent dermal melanophages. The action spectrum of the drug appears to be in the UVB range, but hyperpigmentation is induced by UVA irradiation. The mechanism appears to be postinflammatory hyperpigmentation from a photosensitive lichenoid eruption rather than drug or drug metabolite deposition. Treatment is broad-spectrum sunscreens, stopping the diltiazem, and bleaching creams if needed. Other CCBs can be substituted without the reappearance of the hyperpigmentation.

Periocular hyperpigmentation occurs in patients treated with prostaglandin analogs for glaucoma. These agents also cause pigmentation of the iris. Eyelash length increases. The periocular hyperpigmentation may gradually resolve when the medications are discontinued.

### Vasculitis and serum sickness-like reactions

True leukocytoclastic vasculitis can be induced by many medications, but these events are rare, except in the case of propylthiouracil. True serum sickness is caused by foreign proteins such as antithymocyte globulin, with resulting circulating immune complexes. In the patient with true serum sickness, purpuric lesions tend to be accentuated along the junction between palmoplantar and glabrous skin (Wallace line).

Serum sickness like reactions refer to adverse reactions that have similar symptoms to serum sickness, but in which immune complexes are not found. This reaction was particularly common with cefaclor. Patients present with fever, an urticarial rash, and arthralgias 1–3 weeks after starting the medication (Fig. 6-35). Minocycline, bupropion, and rituximab have been reported to cause serum sickness like reactions.

## Lichenoid reactions

Lichenoid reactions can be seen with many medications, including gold, hydrochlorothiazide, furosemide, NSAIDs, aspirin, antihypertensives (ACE inhibitors,  $\beta$ -blockers, CCBs), terazosin, quinidine, proton pump inhibitors, pravastatin, phenothiazines, anticonvulsants, antituberculous drugs, ketoconazole, sildenafil, imatinib, and antimalarials. Hepatitis B immunization may trigger a lichenoid eruption. Reactions may be photodistributed (lichenoid photoeruption) or generalized, and drugs causing lichenoid photoeruptions may also induce more generalized ones. In either case, the lesions may be plaques (occasionally with Wickham striae), small papules, or exfoliative erythema. Photolichenoid reactions favor the extensor extremities, including the dorsa of the hands. Oral involvement is less common in lichenoid drug reactions than in idiopathic lichen planus but can occur (and with imatinib may be severe). It appears as either plaques or erosions. The lower lip is frequently involved in photolichenoid reactions. The nails may also be affected and can be the only site of involvement. Lichenoid drug eruptions can occur within months to years of starting the offending medication and may take months to years to resolve once the medication has been stopped. Histologically, inflammation occurs along the DEJ, with necrosis of keratinocytes and a dermal infiltrate composed primarily of lymphocytes. Eosinophils are useful, if present, but are not common in photolichenoid reactions. The histology is often similar to idiopathic lichen planus, and a clinical correlation is required to determine if the lichenoid eruption is drug induced. If the drug is essential, the course of treatment may be tolerated with corticosteroid therapy.

Lichenoid reactions may be restricted to the oral mucosa, especially if induced by dental amalgam. In these patients, the lesions are topographically related to the dental fillings or to metal prostheses. Patients may be patch test positive to mercury, or less often gold, cobalt, or nickel, in up to two thirds of cases. Amalgam replacement will result in resolution of the oral lesions in these cases. Patients with cutaneous lesions of lichen planus and oral lesions do not improve with amalgam removal. An unusual form of eruption is the "drug-induced ulceration of the lower lip." Patients present with a persistent erosion of the lower lip that is tender but not indurated. It is induced by diuretics and resolves slowly once they are discontinued.

**Fessa C, et al:** Lichen planus-like drug eruptions due to  $\beta$ -blockers: a case report and literature review. *Am J Clin Dermatol* 2012; 13:417-421.

**Ghosh SK:** Generalized lichenoid drug eruption associated with imatinib mesylate therapy. *Indian J Dermatol* 2013; 58:388-392.

**Lage D, et al:** Lichen planus and lichenoid drug-induced eruption: a histological and immunohistochemical study. *Int J Dermatol* 2012; 51:1199-1205.

**Lehloanya RJ, et al:** Lichenoid drug reaction to antituberculosis drugs treated through with topical steroids and phototherapy. *J Antimicrob Chemother* 2012; 67:2535-2537.

## Adverse reactions to chemotherapeutic agents

Chemotherapeutic agents can cause adverse reactions by multiple potential mechanisms. Adverse reactions may be related to toxicity either directly to the mucocutaneous surfaces (stomatitis, alopecia), or to some other organ system, and reflected in the skin, such as purpura resulting from thrombocytopenia. As organic molecules or monoclonal antibodies, chemotherapeutic agents can act as antigens inducing classic immunologic reactions. In addition, since they are inherently immunosuppressive, they can cause skin reactions associated with alterations of immune function. Some of these patterns may be

overlapping and clinically difficult to distinguish. For example, oral erosions may occur as a toxic effect of chemotherapy and also by immunosuppression-associated activation of HSV.

Dermatologists are rarely confronted with the relatively common acute hypersensitivity reactions seen during infusion of chemotherapeutic agents. These reactions resemble type I allergic reactions, with urticaria and hypotension, and can be prevented by premedication with systemic corticosteroids and antihistamines in most cases.

Numerous macular and papular eruptions have been described with chemotherapeutic agents as well. Many occur at the earliest recovery of the bone marrow, as lymphocytes return to the peripheral circulation. They are associated with fever. This phenomenon has been called "cutaneous eruptions of lymphocyte recovery." Histologically, these reactions demonstrate a nonspecific, superficial perivascular mononuclear cell infiltrate, composed primarily of T lymphocytes. Treatment is not required, and the eruption spontaneously resolves.

## Radiation enhancement and recall reactions

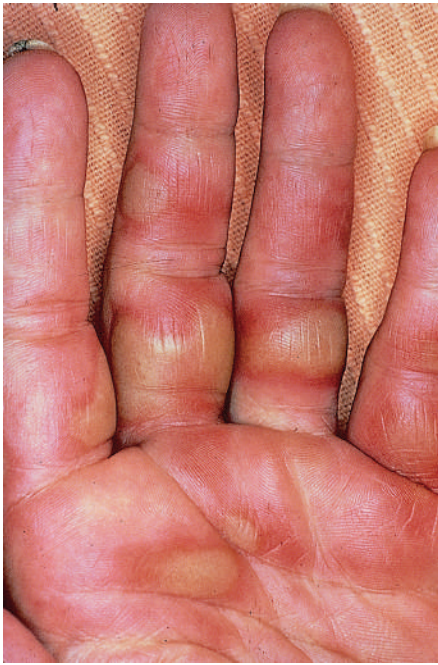Radiation dermatitis, in the form of intense erythema and vesiculation of the skin, may be observed in radiation ports. Administration of many chemotherapeutic agents, during or about the time of radiation therapy, may induce an enhanced radiation reaction. In some patients, however, months to years after radiation treatment, the administration of a chemotherapeutic agent may induce a reaction within the prior radiation port, with features of radiation dermatitis. This phenomenon has been termed "radiation recall," reported with numerous chemotherapeutic agents, high-dose IFN- $\alpha$ , and simvastatin. Besides the skin, internal structures such as the gut may also be affected. A similar reaction of reactivation of a sunburn after methotrexate therapy also occurs. Exanthems restricted to prior areas of sunburn are not true radiation recall.

## Chemotherapy-induced acral erythema (palmoplantar erythrodysesthesia syndrome, hand-foot syndrome)

Chemotherapy-induced acral erythema is a relatively common syndrome most frequently caused by 5-fluorouracil (5-FU), doxorubicin, and cytosine arabinoside, but also seen with docetaxel, capecitabine, and high-dose liposomal doxorubicin and daunorubicin. A localized plaque of fixed erythrodysesthesia has been described proximal to the infusion site of docetaxel. The reaction may occur in as many as 40% or more of treated patients. The reaction is dose dependent and may appear with bolus short-term infusions or low-dose, long-term infusions. It may present days to months after the treatments are started. It is probably a direct toxic effect of the chemotherapeutic agents on the skin. The large number of sweat glands on the palms and soles that may concentrate the chemotherapeutic agents may explain the localization of the toxicity. In the case of pegylated liposomal doxorubicin, localization of the chemotherapeutic agent to the sweat glands has been demonstrated, and the sweat glands appear to be the organ by which the chemotherapy is delivered onto the surface of normal skin. A flexural eruption in the groin and axilla may accompany acral erythema, again from sweat gland accumulation of the drug in these regions. Cases of neutrophilic eccrine hidradenitis and syringometaplasia, all induced by the same agents, suggest that the eccrine glands are unique targets for adverse reactions to antineoplastic agents.

The initial manifestation is often dysesthesia or tingling of the palms and soles. This is followed in a few days by painful, symmetric erythema and edema most pronounced over the





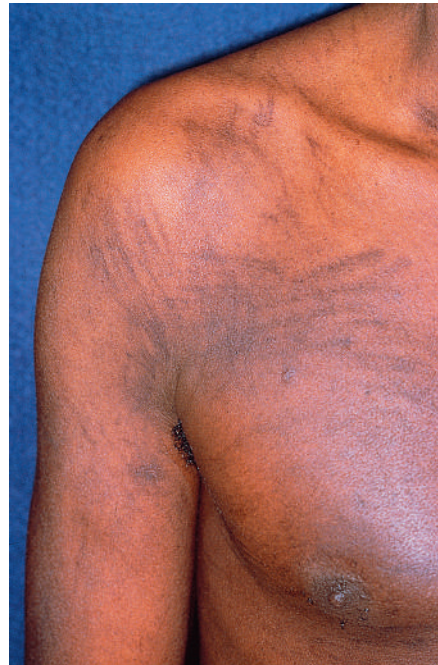**Fig. 6-36** Hand-foot syndrome.

distal pads of the digits. The reaction may spread to the dorsal hands and feet and may be accompanied by a morbilliform eruption of the trunk, neck, scalp, and extremities. Over the next several days, the erythema becomes dusky, develops areas of pallor, blisters, desquamates, and then reepithelializes. The desquamation is often the most prominent part of the syndrome. Blisters developing over pressure areas of the hands, elbows, and feet are a variant of hand-foot syndrome (Fig. 6-36). The patient usually recovers without complication, although rarely full-thickness ischemic necrosis occurs in the areas of blistering.

The histopathology is nonspecific, with necrotic keratinocytes and vacuolar changes along the basal cell layer. Acute GVHD is in the differential diagnosis. Histologic evaluation may not be useful in the acute setting to distinguish these syndromes. Most helpful are gastrointestinal or liver findings of GVHD.

Most patients require only local supportive care. Cold compresses and elevation are helpful, and cooling the hands during treatment may reduce the severity of the reaction. Modification of the dose schedule can be beneficial. Pyridoxine, 100–150 mg daily, decreases the pain of 5-FU-induced acral erythema. IVIG has been reported to be beneficial in a methotrexate-induced case of acral erythema. Cyclosporine has been reported to result in worsening of the condition.

Sorafenib and sunitinib are small, multikinase-inhibiting molecules with blocking activity for numerous tyrosine kinases, including vascular endothelial growth factor (VEGF), platelet-derived growth factor (PDGFR $\beta$ ), and c-kit ligand (stem cell factor). Both agents induce a condition similar to acral erythema, also referred to as hand-foot skin reaction (HFSR). Patients also present with acral pain and dysesthesia, but usually less severe and with less edema than with classic chemotherapeutic agents. In contrast to classic acral erythema, multikinase inhibitor-induced HFSR causes marked, patchy hyperkeratotic plaques over areas of friction. The HFSR is dose dependent, high grade in 9% of cases (with blisters, ulceration, and functional loss) and results in the sorafenib being stopped in about 1% of patients. The addition of another VEGF inhibitor, bevacizumab, leads to worse HFSR. Painful distal subungual splinter hemorrhages can also occur 2–4 weeks after onset of treatment. It has been suggested that the blocking of VEGF



**Fig. 6-37** Bleomycin-induced flagellate hyperpigmentation.

may be pathogenically important in causing HFSR splinter hemorrhages. The development of hand-foot syndrome in patients receiving sorafenib for metastatic renal cell carcinoma is associated with better tumor response and improved progression-free survival.

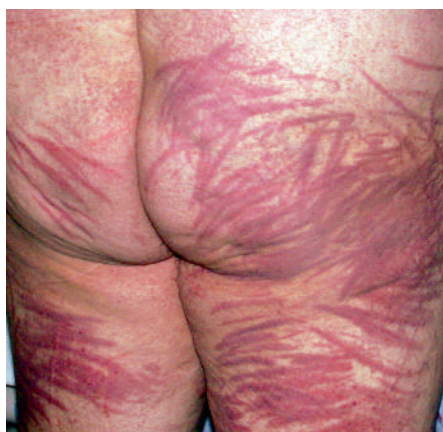Histologically, there are horizontal layers of necrotic keratinocytes within the epidermis (if biopsy is taken in first 30 days) or in the stratum corneum (later biopsies). Topical tazarotene, 40% urea, heparin ointment, and fluorouracil cream have been used to treat HFSR from multikinase inhibitors.

Neutrophilic eccrine hidradenitis is discussed in Chapter 33.

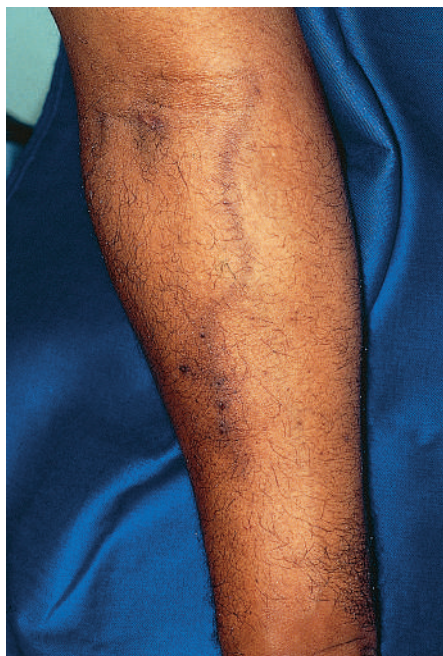## Chemotherapy-induced dyspigmentation

Many chemotherapeutic agents (especially the antibiotics bleomycin, doxorubicin, and daunorubicin) and the alkylating agents (cyclophosphamide and busulfan) cause various patterns of cutaneous hyperpigmentation. Adriamycin (doxorubicin) causes marked hyperpigmentation of the nails, skin, and tongue. This is most common in black patients and appears in locations where constitutional hyperpigmentation is sometimes seen. Hydroxyurea can also cause this pattern of hyperpigmentation. It is similar to zidovudine-associated pigmentation seen in pigmented persons. Cyclophosphamide causes transverse banding of the nails or diffuse nail hyperpigmentation beginning proximally. Bleomycin and 5-FU cause similar transverse bands. Busulfan and 5-FU induce diffuse hyperpigmentation that may be photoaccentuated. Paradoxical hyperpigmentation of the skin, nails, and hair caused by imatinib has been reported. Eruptive melanocytic nevi and lentigines with an acral predisposition have been seen with sorafenib therapy.

Bleomycin induces characteristic flagellate erythematous urticarial wheals associated with pruritus within hours or days of infusion (Fig. 6-37). Lesions continue to appear for days to weeks. Although investigators have not always been able to induce lesions, the pattern strongly suggests scratching is the cause of the erythematous lesions. A similar characteristic pattern of flagellate hyperpigmentation occurs after bleomycin treatment, possibly preceded by the erythematous reaction or simply pruritus. Bleomycin hyperpigmentation may be accentuated at areas of pressure, strongly supporting trauma as the cause of the peculiar pattern.



**Fig. 6-38** Shiitake mushroom-induced dermatitis. (Courtesy of Don Adler, DO.)



**Fig. 6-39** 5-Fluorouracil (5-FU)-induced serpentine hyperpigmentation.

Patients may present with linear erythematous wheals 1–2 days after eating raw or cooked shiitake mushrooms (Fig. 6-38). This so-called toxicodermia, or shiitake flagellate dermatitis, is thought to be caused by a toxic reaction to lentinan, a polysaccharide component of the mushrooms. It is self-limited and resolves within days to weeks of its appearance, but can be treated with topical corticosteroids to relieve the associated pruritus some patients experience. Other associations with flagellate eruptions include adult-onset Still's disease, dermatomyositis, and docetaxel therapy.

5-Fluorouracil, and less frequently other chemotherapeutic agents, may produce a serpentine hyperpigmentation overlying the veins proximal to an infusion site (Fig. 6-39). This represents postinflammatory hyperpigmentation from a direct cytotoxic effect of the chemotherapeutic agent.

Imatinib in doses of 400–600 mg daily leads to generalized or localized depigmentation in 40% or more of pigmented persons. It starts an average of 4 weeks after treatment and progresses over time if treatment with imatinib is continued. Patients also complain of an inability to tan and “photosensitivity.” One patient with vitiligo had significant progression with imatinib therapy. The proposed mechanism is inhibition of stem cell factor,<sup>1</sup> which is implicated in melanogenesis. By a similar mechanism, sunitinib leads to depigmentation of the hair after 5–6 weeks of treatment. Sunitinib may lead to yellow

pigmentation of the skin from the drug or its metabolites being deposited.

### Exudative hyponychial dermatitis

Nail toxicity is common (26–40%) during chemotherapy for breast cancer, especially if docetaxel is in the chemotherapeutic regimen. Subungual hemorrhage, subungual abscesses, paronychia, subungual hyperkeratosis, and onychomadesis all occur. In its most severe form, severe exudation and onycholysis may result. All these reactions probably represent various degrees of toxicity to the nail bed. Capecitabine has caused a similar reaction.

### Palifermin-associated papular eruption

Palifermin is a recombinant human keratinocyte growth factor used to reduce the severity and duration of mucositis in patients undergoing preparative regimens for hematopoietic stem cell transplantation. An intertriginous erythema accompanied by oral white confluent plaques and small lichenoid papules developed in one patient receiving palifermin therapy. The papules resembled flat warts clinically and histologically but were human papillomavirus (HPV) negative by in situ hybridization studies. A direct hyperproliferative effect of the keratinocyte growth factor is the proposed mechanism.

### Scleroderma-like reactions to taxanes

Patients treated with docetaxel or paclitaxel may develop an acute, diffuse, infiltrated edema of the extremities and head. This occurs after one to several courses of the taxane. The affected areas, specifically the lower extremities, evolve over months to become sclerotic and at times painful. Flexion contractures of the palm, digits, and large joints may occur. Biopsies of the initial lesion show lymphangiectasia and a diffuse infiltration with mononuclear cells in the superficial dermis. Late fibrotic lesions demonstrate marked dermal fibrosis. Discontinuation of the taxane therapy leads to resolution in most cases. Lupuslike reactions, including subacute cutaneous lupus, have also been reported with the taxanes.

### Adverse reactions to immunosuppressants used in dermatology

Azathioprine is used as a steroid-sparing agent for dermatologic conditions and can cause a hypersensitivity syndrome. In addition, neutrophilic dermatoses resembling Sweet syndrome appear with azathioprine therapy and resolve with its discontinuation. Patients with inflammatory bowel disease appear to be at particular risk. Photosensitivity can also occur with azathioprine, despite its frequent use in severe photodermatoses.

Methotrexate can cause erosive skin lesions in two patterns. Ulceration or erosion of psoriatic plaques may be a sign that the patient is taking a midweek dose of methotrexate. This can be associated with severe methotrexate marrow toxicity. If renal failure is present or occurs during low-dose methotrexate therapy, a severe bullous eruption resembling TEN can occur. This apparently represents severe cutaneous toxicity from the prolonged blood and skin levels of methotrexate that result from reduced excretion because of coexistent renal disease and drug-drug interactions. If this scenario is recognized, leucovorin rescue should be given immediately.

**Baldo BA, et al:** Adverse reactions to targeted and non-targeted chemotherapeutic drugs with emphasis on hypersensitivity responses and the invasive metastatic switch. *Cancer Metastasis Rev* 2013; 32:723–761.



**Boussemart L, et al:** Prospective study of cutaneous side-effects associated with the BRAF inhibitor vemurafenib: a study of 42 patients. *Ann Oncol* 2013; 24:1691–1697.

**Chan MP, et al:** Subcutaneous Sweet syndrome in the setting of myeloid disorders: a case series and review of the literature. *J Am Acad Dermatol* 2013; 68:1006–1015.

**Maldonado Cid P, et al:** Acral erythema worsened by intravenous infusions of cyclosporin. *Dermatol Online J* 2013; 19(3):16.

**Nakano K, et al:** Hand-foot skin reaction is associated with the clinical outcome in patients with metastatic renal cell carcinoma treated with sorafenib. *Jpn J Clin Oncol* 2013; 43:1023–1029.

**Nardone B, et al:** The effect of hand-foot skin reaction associated with the multikinase inhibitors sorafenib and sunitinib on health-related quality of life. *J Drugs Dermatol* 2012; 11:e61–e65.

**Rehan HS, et al:** Adverse drug reactions: trends in a tertiary care hospital. *Curr Drug Saf* 2012; 7:384–388.

**Reyes-Habito CM, et al:** Cutaneous reactions to chemotherapeutic drugs and targeted therapy for cancer. Part II. Targeted therapy. *J Am Acad Dermatol* 2014; 71:217.e1–217.e11.

**Rinderknecht JD, et al:** RASopathy skin eruptions during vemurafenib therapy. *PLoS One* 2013; 8(3):e58721.

**Shabaruddin FH, et al:** A systematic review of utility values for chemotherapy-related adverse events. *Pharmacoeconomics* 2013; 31:277–288.

**Zhu SY, et al:** Radiation recall reaction: two case studies illustrating an uncommon phenomenon secondary to anti-cancer agents. *Cancer Biol Med* 2012; 9:202–204.

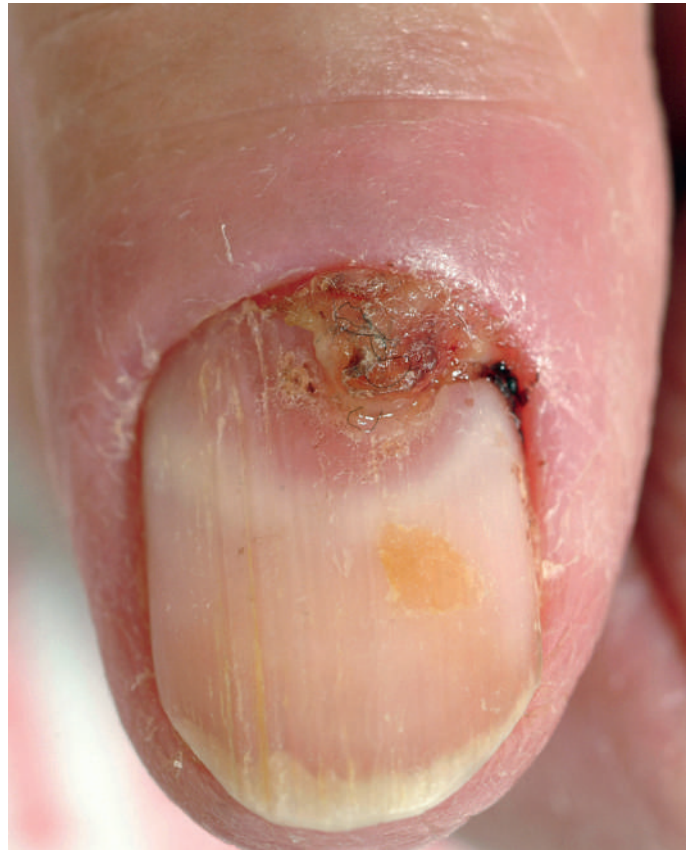### Cutaneous side effects of epidermal growth factor receptor inhibitors

Epidermal growth factor receptor (EGFR) is expressed by basal keratinocytes, sebocytes, and the outer root sheath, explaining why up to 90% of patients treated with EGFR inhibitors may develop cutaneous side effects. Xerosis is often seen. Painful periungual or finger pulp fissures and paronychia (with or without periungual pyogenic granulomas) may develop (Fig. 6-40). The most common and characteristic adverse skin reaction is a dose-dependent papulopustular eruption. The eruption begins 7–10 days after initiation of therapy, attaining maximum severity in the second week. The seborrheic areas of the scalp, central face, upper back, and retroauricular regions are mainly affected. The primary lesion is a follicular papule or pustule with few or no comedones. Hemorrhagic crusting and confluence can occur, resembling rosacea fulminans (pyoderma faciale) in the most severely affected patients. Cultures should be performed to rule out secondary infection in patients with severe or unusual manifestations. Telangiectasia may be prominent, and long eyelashes and curlier scalp hair may also be seen.

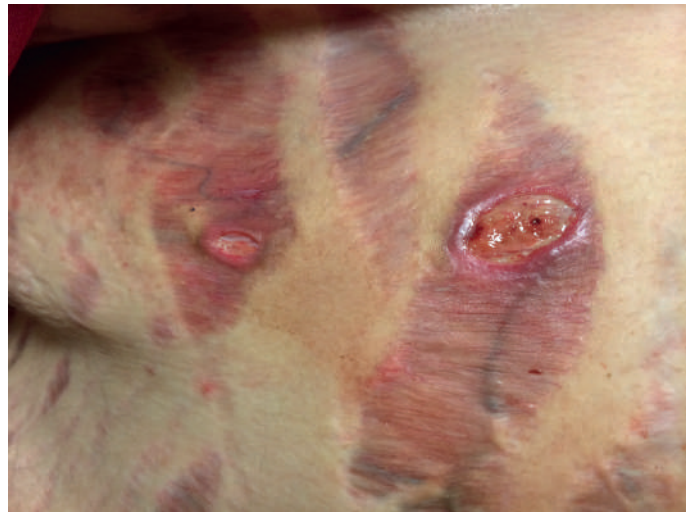
The eruption may itch. The presence and severity of this skin eruption are correlated with survival, so some oncologists will increase the dose to induce the eruption. Radiation therapy during EGFR inhibitor therapy will enhance the skin toxicity, but previously radiated skin is often spared from inhibitor toxicity. Effective topical therapies have included metronidazole, clindamycin, hydrocortisone, pimecrolimus, and tretinoin. Oral tetracyclines can treat or prevent the eruption. In the most severe cases, isotretinoin or acitretin can be used. Tumor necrosis factor (TNF)- $\alpha$  and IL-1 are involved in the pathogenesis of EGFR inhibitor toxicity. Etanercept and anakinra, therefore, can also be therapeutically useful.

### Cutaneous side effects of multikinase inhibitors

In addition to the reactions previously listed, multikinase inhibitors may cause other skin reactions. Psoriasis exacerbation, acral psoriasiform hyperkeratosis, and pityriasis rosea like eruptions have been described with imatinib. Both imatinib and sunitinib cause facial edema, with a periorcular



**Fig. 6-40** Epidermal growth factor receptor (EGFR) inhibitor-induced paronychia.



**Fig. 6-41** Bevacizumab-induced ulceration of striae.

predilection. Increased vascular permeability caused by PDGFR inhibition has been the proposed mechanism. Dasatinib has caused a lobular panniculitis. Bevacizumab, a VEGF inhibitor, causes bleeding and wound healing complications. Extensive cutaneous surgery should probably be delayed for 60 days after bevacizumab therapy, and 28 days should elapse after surgery before initiation of bevacizumab therapy. Bevacizumab has also been associated with ulceration of striae distensae (Fig. 6-41). Sorafenib has been associated with the rapid development of multiple squamoproliferative lesions called keratoacanthomas or squamous cell carcinomas, as well as eruptive melanocytic lesions. Bexarotene was reported as

therapeutic in a patient with sorafenib-induced squamoproliferative lesions. Multiple monomorphous, follicular, keratotic skin-colored papules resembling keratosis pilaris can develop during sorafenib treatment. Histologically, these papules show hyperplasia of the follicular isthmus or follicular hyperkeratosis with plugging. Facial and scalp erythema and dysesthesia occur in about 60% of sorafenib-treated patients.

## Adverse reactions to cytokines

Cytokines, which are normal mediators of inflammation or cell growth, are increasingly used in the management of malignancies and to ameliorate the hematologic complications of disease or its treatment. Skin toxicity is a common complication of the use of these agents. Many cause local inflammation and ulceration at the injection site in a large number of the patients treated. More widespread papular eruptions are also frequently reported, but these have been poorly studied in most cases and are of unclear pathogenesis.

Granulocyte colony-stimulating factor (G-CSF) has been associated with the induction of several neutrophil-mediated disorders, most often Sweet syndrome or bullous pyoderma gangrenosum. These occur about 1 week after cytokine therapy is initiated and are present despite persistent neutropenia in peripheral blood. A rare complication of G-CSF is a thrombotic and necrotizing panniculitis. Both G-CSF and GM-CSF may exacerbate leukocytoclastic vasculitis. IFN- $\alpha$ , IFN- $\gamma$ , and G-CSF have been associated with the exacerbation of psoriasis. G-CSF can also cause cutaneous eruptions containing histiocytes. Anakinra and rarely erythropoietin can cause similar granulomatous skin reactions.

IL-2 frequently causes diffuse erythema, followed by desquamation, pruritus, mucositis (resembling aphthosis), glossitis, and flushing. The majority of erythema reactions with IL-2 treatment are mild to moderate, but some may be severe. Erythroderma with blistering or TEN like reactions can occur and may be dose limiting. Administration of iodinated contrast material within 2 weeks of IL-2 therapy is associated with a hypersensitivity reaction in 30% of patients. Fever, chills, angioedema, urticaria, and hypotension may occur. Subcutaneous injections of IL-2 can lead to injection site nodules or necrosis. Histologically, a diffuse panniculitis with noninflammatory necrosis of the involved tissue is present. Rarely, linear IgA disease can be induced by IFN- $\alpha$ .

**Dosal J, et al:** Ulceration of abdominal striae distensae (stretch marks) in a cancer patient. *Arch Dermatol* 2012; 148:385–390.

**Giacchero D, et al:** A new spectrum of skin toxic effects associated with the multikinase inhibitor vandetanib. *Arch Dermatol* 2012; 148:1418–1420.

**Habl G, et al:** Differentiation of irradiation and cetuximab induced skin reactions in patients with locally advanced head and neck cancer undergoing radioimmunotherapy: the HICARE protocol (head and neck cancer: immunochemo and radiotherapy with Erbitux)—a multicenter Phase IV trial. *BMC Cancer* 2013; 13:345.

**Li JR, et al:** Efficacy of a protocol including heparin ointment for treatment of multikinase inhibitor-induced hand-foot skin reactions. *Support Care Cancer* 2013; 21:907–911.

**Liu HB, et al:** Skin rash could predict the response to EGFR tyrosine kinase inhibitor and the prognosis for patients with non-small cell lung cancer: a systematic review and meta-analysis. *PLoS One* 2013; 8:e55128.

**Moreno Garcia V, et al:** Association of creatine kinase and skin toxicity in Phase I trials of anticancer agents. *Br J Cancer* 2012; 107:1797–1800.

**Peters KB, et al:** Ulceration of striae distensae in high-grade glioma patients on concurrent systemic corticosteroid and bevacizumab therapy. *J Neurooncol* 2011; 101:155–159.

**Uhlenhake EE, et al:** Sorafenib induced eruptive melanocytic lesions. *Dermatol Online J* 2013; 19(5):18184.

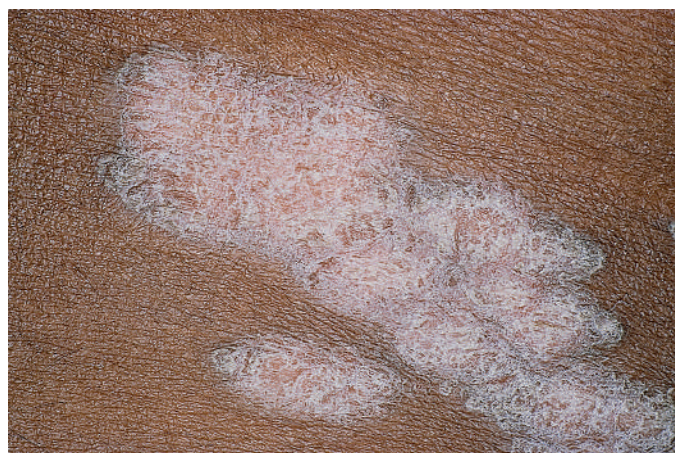**Wiznia LE, et al:** Unique presentations of epidermal growth factor receptor inhibitor-induced papulopustular eruption related to bacterial superinfection. *Dermatol Online J* 2013; 19(3):8.

## Adverse reactions to biologic agents

### Tumor necrosis factor inhibitors

The TNF inhibitors are associated with palmoplantar pustulosis, pustular folliculitis, worsening of psoriasis, interface dermatitis, neutrophilic eccrine hidradenitis, Sweet syndrome, systemic lupus, and vasculitis. Injection site reactions (ISRs) are common with etanercept therapy for rheumatologic disease, with 20–40% of patients developing ISR. ISRs present as erythematous, mildly swollen plaques, appearing 1–2 days after the injection. Pruritus occurs in 20% of patients. ISR is most common early in the treatment course (median number of injections, four) and stops appearing with continued treatment. Individual lesions resolve over 2–3 days. Recall ISR (reappearance of eruption at previous ISR site) occurs in 40% of patients. This adverse reaction appears to be mediated by CD8+ T cells. Cytokine therapy with TNF and IFN- $\alpha$ , IFN- $\beta$ , and IFN- $\gamma$  also causes ISRs.

The paradoxical appearance of psoriasis or a psoriasiform dermatitis is now a well-recognized complication of TNF inhibitor therapy. It occurs with all three of the common TNF inhibitors: infliximab, etanercept, and adalimumab. The risk may be slightly higher for adalimumab. The psoriasis can appear from days to years after anti-TNF therapy. There is no age or gender predisposition. Several clinical patterns have been described. Palmoplantar pustulosis represents about 40% of cases. Generalized pustular disease may accompany the palmoplantar lesions. Plaque-type psoriasis occurs in about one third of TNF inhibitor-induced psoriasis (Fig. 6-42). New-onset guttate psoriasis occurs in 10% of cases. Stopping the TNF inhibitor led to improvement or resolution in the vast majority of patients. In some cases, therapy was continued and the eruption resolved. Experts disagree as to whether switching to a different anti-TNF agent may be tolerated in these patients. Many patients have been rechallenged with other TNF inhibitors. In severe cases, this is probably not prudent, but in milder or localized cases, this could be considered. The psoriasis caused by anti-TNF agents can be treated with topical corticosteroids, UV phototherapy, topical vitamin D analogs, methotrexate, acitretin, or cyclosporine. The proposed mechanism for the appearance with psoriasis with anti-TNF therapy is either overactivity of Th1 cells or increased IFN- $\alpha$  production by skin-resident plasmacytoid dendritic cells. Systemic IFN- $\alpha$



**Fig. 6-42** Plaque-type psoriasis.



and topical imiquimod (an interferon inducer) have been reported to exacerbate psoriasis, supporting this hypothesis. Sarcoidosis induced by anti-TNF agents could also be related to increased Th1 function.

About 11% of patients treated for rheumatoid arthritis with etanercept develop new antinuclear antibodies (ANAs) and 15%, anti-double-stranded DNA (dsDNA) antibodies. Anti-Sm antibodies can also occur. Similarly, patients treated with infliximab may develop new ANAs, anti-dsDNA (14%), and anticardiolipin antibodies. All three common TNF inhibitors have caused drug-induced lupus (DIL) with features of SLE. It begins on average after 41 weeks of treatment. Compared with DIL from other medications, the TNF inhibitors cause more skin disease with malar rash, discoid lesions, and photosensitivity. Many of the patients fulfill the American Rheumatology Association (ARA) criteria for SLE, and significant internal organ involvement can occur, including renal and central nervous system (CNS) involvement. Etanercept, specifically, seems to cause skin lesions more frequently. Etanercept patients also developed vasculitis more often. The vast majority of patients improve about 10 months after therapy has been discontinued. Switching from one TNF inhibitor to another has been reported to be successful. Dermatomyositis has also been caused by TNF inhibitor treatment.

Vasculitis is also a well-recognized complication of treatment with TNF inhibitors. Etanercept is the most common agent to induce vasculitis. The lesions of vasculitis may begin around the injection sites in some etanercept-induced vasculitis cases. More than 85% of patients present with skin lesions, usually a leukocytoclastic vasculitis. Ulcerations, nodules, digital lesions, chilblains, livedo, and other morphologies have also been described. Visceral vasculitis occurs in about one quarter of patients. They may be ANA positive or antineutrophil cytoplasmic antibody (ANCA) positive (usually p-ANCA) or may have cryoglobulins. Drug-induced antiphospholipid syndrome with TNF inhibitors can be associated with DIL or vasculitis and presents with thrombosis as well as cutaneous lesions. Some patients with TNF inhibitor-induced vasculitis have died. Stopping the TNF inhibitor leads to resolution of the vasculitis in more than 90% of cases. Rechallenge leads to new vasculitic lesions in 75% of cases. Other neutrophilic disorders induced by TNF inhibitors include Sweet syndrome-like reactions and neutrophilic eccrine hidradenitis.

Lichenoid drug eruptions have been reported from all three commonly used anti-TNF agents. They are typically pruritic and affect areas typically involved by lichen planus: the flexor wrists. However, gluteal cleft lesions are also common. In some cases, the lichenoid eruption superimposes itself on psoriatic lesions, presenting as an exacerbation of the "psoriasis." Biopsies show features of both lichen planus and psoriasis, and stopping the anti-TNF therapy leads to improvement of the "psoriasis." Despite these agents' immunosuppressive properties, patients can still develop allergic contact dermatitis while taking them, and patch testing during anti-TNF treatment may identify relevant allergens. It appears that patients receiving anti-TNF agents are at slightly increased risk for development of nonmelanoma skin cancers, especially if they also have used methotrexate.

**Hawryluk EB, et al:** Broad range of adverse cutaneous eruptions in patients on TNF- $\alpha$  antagonists. *J Cutan Pathol* 2012; 39:481–492.

**Peluso R, et al:** Side effects of TNF- $\alpha$  blockers in patients with psoriatic arthritis: evidences from literature studies. *Clin Rheumatol* 2013; 32:743–753.

**Wright LN, et al:** Modeling the transcriptional consequences of epidermal growth factor receptor ablation in Ras-initiated squamous cancer. *Clin Cancer Res* 2012; 18:170–183.

## Mercury

Mercury may induce multiple cutaneous syndromes. The classic syndrome is acrodynia, also known as calomel disease, pink disease, and erythrodermic polyneuropathy. Acrodynia is caused by mercury poisoning, usually in infancy. The skin changes are characteristic and almost pathognomonic: painful swelling of the hands and feet, sometimes associated with considerable itching of these parts. The hands and feet are also cold, clammy, and pink or dusky red. The erythema is usually blotchy but may be diffuse. Hemorrhagic puncta are frequently evident. Over the trunk, a blotchy macular or papular erythema is usually present. Stomatitis and loss of teeth may occur. Constitutional symptoms consist of moderate fever, irritability, marked photophobia, increased perspiration, and a tendency to cry most of the time. There is always moderate upper respiratory inflammation with throat soreness. The infant may have hypertension, hypotonia, muscle weakness, anorexia, and insomnia. Albuminuria and hematuria are usually present. The diagnosis is made by finding mercury in the urine.

An exanthem may occur from inhalation of mercury vapors or absorption by direct contact. A diffuse, symmetric, erythematous morbilliform eruption in the flexors and proximal extremities begins within a few days of exposure. Accentuation in the groin and medial thighs produces a "baboon syndrome" appearance. The eruption burns or itches, and small follicular pustules appear. Extensive desquamation occurs with resolution. Old broken thermometers or the application of mercury-containing skin-lightening creams and herbal medications are potential sources. In Haiti, elemental mercury is applied to surfaces for religious purposes and may result in contamination of those coming in contact.

Mercury is also a possible cause of foreign body granulomas and hyperpigmentation at sites of application. An eruption of 1–2 mm, minimally pruritic papules and papulovesicles on the palms (all patients) and soles, arms, and trunk has also been ascribed to levels of mercury in the blood at near the upper limits considered to be safe. Treatment with a seafood-free diet and chelation with succimer led to resolution of the eruption in some patients. Nummular dermatitis improved in two mercury patch test-positive patients when their dental amalgam was removed.

**Adawe A, et al:** Skin-lightening practices and mercury exposure in the Somali community. *Minn Med* 2013; 96:48–49.

**Centers for Disease Control and Prevention:** Mercury exposure among household users and nonusers of skin-lightening creams produced in Mexico, California and Virginia, 2010. *MMWR* 2012; 61:33–36.

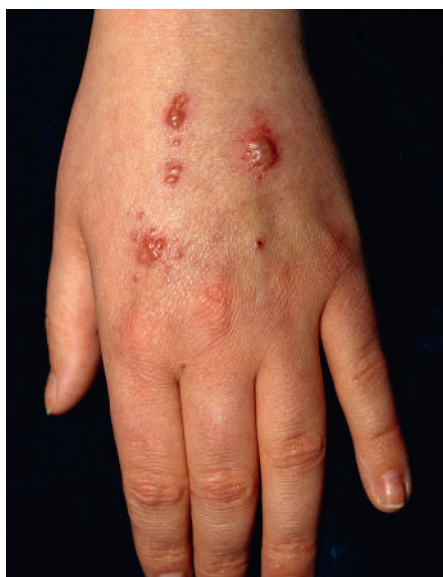**Cristaudo A, et al:** Use of potentially harmful skin-lightening products among immigrant women in Rome, Italy: a pilot study. *Dermatology* 2013; 226:200–206.

**Park JD, et al:** Human exposure and health effects of inorganic and elemental mercury. *J Prev Med Public Health* 2012; 45:344–352.

## Halogenoderma

### Bromoderma and fluoroderma

Bromides and fluorides produce distinctive follicular eruptions: acneiform, papular, or pustular. Vegetative, exudative plaques studded with pustules may develop, resembling Sweet syndrome, pyoderma gangrenosum, or an orthopoxvirus infection. Any area of skin may be affected, but bromoderma and especially fluoroderma tend to affect the lower extremities more than iododerma. Histologically, the lesions show epidermal hyperplasia with intraepidermal and dermal neutrophilic abscesses. There is rapid involution of the lesions on cessation of bromide ingestion. Excessive cola or soft-drink



**Fig. 6-43** Iododerma.

consumption or ingestion of bromine-containing medications (ipratropium bromide, dextromethorphan hydrobromide, potassium bromide, pipobroman, Medecital) may be the cause of a bromoderma. Serum bromide level is elevated and confirms the diagnosis. Fluoroderma has been associated with intensive use of dental fluoride treatments.

## Iododerma

Iodides may cause a wide variety of skin eruptions. The most common sources of exposure are oral and IV contrast materials and when iodides are used to treat thyroid disease. Application of povidone-iodine to the skin, mucosa, or as a tub soak has produced iododerma. The most common type is the acneiform eruption with numerous acutely inflamed follicular pustules, each surrounded by a ring of hyperemia (Fig. 6-43). Dermal bullous lesions are also common and may become ulcerated and crusted, resembling pyoderma gangrenosum or Sweet syndrome. The eruption may involve the face, upper extremities, trunk, and even the buccal mucosa. Acne vulgaris and rosacea are unfavorably affected by iodides. Acute iododerma may follow IV radiocontrast studies in patients with renal failure. The lesions may be associated with severe leukocytoclastic vasculitis, intraepidermal spongiform pustules, and suppurative folliculitis. The lesions respond to prednisone.

**Aliagaoglu C, et al:** Iododerma following topical povidone-iodine application. *Cutan Ocul Toxicol* 2013; 32:339–4340.

**Guerrero AF, et al:** Thyroid protection gone awry: iododerma following potassium iodide administration prior to metaiodobenzylguanidine scintigraphy. *Thyroid* 2011; 21:93–94.

**Ogretmen Z, et al:** Use of topical povidone-iodine resulting in iododerma. *Indian J Dermatol* 2011; 56:346–347.

**Rothman LR, et al:** Iododerma following serial computed tomography scans in a lung cancer patient. *J Drugs Dermatol* 2013; 12:574–576.

**Saurat JH, et al:** The cutaneous lesions of dioxin exposure: lessons from the poisoning of Victor Yushchenko. *Toxicol Sci* 2012; 125:310–317.

**Vandergriff TW, et al:** Iododerma following radioactive iodine ablation of the thyroid for Graves disease. *J Drugs Dermatol* 2011; 10:1070–1071.

## Drug-induced autoimmune diseases

### Lupus erythematosus

Drug-induced SLE is rarely associated with skin lesions. It occurs in older patients and affects men as frequently as

women. The symptoms are generally mild and include fever, myalgias/artralgias, and serositis. This form of DIL is associated with a positive ANA, homogeneous pattern, and antihistone antibodies, but a negative anti-dsDNA antibody and normal complement levels. Procainamide, hydralazine, quinidine, captopril, isoniazid, minocycline, carbamazepine, propylthiouracil, sulfasalazine, and the statins are among the reported agents triggering this form of DIL. The TNF inhibitors, especially etanercept, may also cause an SLE like syndrome but with prominent skin lesions. Women are favored, and nephropathy and CNS involvement can occur. Again, the affected patients are ANA positive, but also anti-dsDNA antibody positive, and more than half are hypocomplementemic. Methimazole has been implicated in bullous SLE.

Numerous medications have been reported to produce cutaneous lesions characteristic of subacute cutaneous lupus erythematosus (SCLE). The eruption begins days to years after starting the medications. Hydrochlorothiazide, diltiazem (and other calcium channel blockers), and terbinafine are the most common causative agents, but ACE inhibitors, proton pump inhibitors, statins, TNF inhibitors, anticonvulsants, NSAIDs, paclitaxel, doxycycline, and even agents used to treat lupus (e.g., hydroxychloroquine, leflunomide) can induce SCLE. These patients may also be ANA positive and may have antihistone antibodies, but in addition have positive anti-SSA antibodies. Cutaneous lesions are photosensitive, but not photodistributed, annular or papulosquamous plaques. Chilblain-like lesions are rarely seen. Treatment is as for SCLE, with sun avoidance, and topical and systemic corticosteroids as required. Drug withdrawal results in resolution over weeks to months. The positive serologies may decrease as the eruption improves. The pathogenesis of drug-induced SCLE is unknown, but most causative agents also cause both photosensitive and lichenoid drug eruptions. Etanercept can produce both classic drug-induced SLE and drug-induced SCLE.

### Hydroxyurea dermatopathy

Chronic use of hydroxyurea for chronic myelogenous leukemia, thrombocytopenia, or psoriasis may be associated with the development of cutaneous lesions characteristic of dermatomyositis. Scaly, linear erythema of the dorsal hands, accentuated over the knuckles, is noted. There may be marked acral atrophy and telangiectasia. Elbow and eyelid involvement characteristic of dermatomyositis may also be seen. Biopsy shows vacuolar degeneration of the basal cells and an interface lymphocytic infiltrate. The skin lesions tend to improve over months, although the atrophy may not improve.

**Grönhagen CM, et al:** Subacute cutaneous lupus erythematosus and its association with drugs: a population-based matched case-control study of 234 patients in Sweden. *Br J Dermatol* 2012; 167:296–305.

**Lamond NW, et al:** Drug-induced subacute cutaneous lupus erythematosus associated with nab-paclitaxel therapy. *Curr Oncol* 2013; 20:e484–e487.

**Miller KK, et al:** Drug-induced subacute cutaneous lupus erythematosus related to doxycycline. *Dermatol Online J* 2011; 17(10):3.

**Seo JY, et al:** Methimazole-induced bullous systemic lupus erythematosus: a case report. *J Korean Med Sci* 2012; 27:818–821.

### Linear IgA bullous dermatosis

Linear IgA disease is frequently associated with medication exposure, especially vancomycin. Men and women are equally affected, and the eruption usually begins within 2 weeks of vancomycin therapy. Clinical morphology is variable and can include flaccid or tense bullae, vesicles, erythematous papules or plaques, exanthematous morbilliform eruptions typical of



a drug exanthem, and targetoid papules. TEN or severe SJS may be simulated, but mucosal involvement is only 30–45% and conjunctival involvement, 10%. Histology will show subepidermal blistering with neutrophils and eosinophils in biopsies taken from bullous lesions. In nonbullous and TEN/SJS like lesions, there is a vacuolar/lichenoid dermatitis with eosinophils. Unless DIF is performed, this would be interpreted as erythema multiforme or a drug eruption, and the diagnosis of linear IgA disease would be missed. Treatment is to stop the offending drug and to give dapsone at 100–200 mg daily, if needed.

### Leukotriene receptor antagonist–associated Churg–Strauss syndrome

Asthma patients being treated with leukotriene receptor antagonists may develop a syndrome resembling Churg–Strauss vasculitis. It occurs 2 days to 10 months after the leukotriene receptor antagonist has been started. Inhaled fluticasone has also been reported to produce this syndrome. Involvement may be limited to the skin. Features of the syndrome include peripheral eosinophilia, pulmonary infiltrates, and, less often, neuropathy, sinusitis, pericardial effusion, and cardiomyopathy. Skin lesions occur in about half the patients and are usually purpuric and favor the lower legs. Histologically, the skin lesions show leukocytoclastic vasculitis with significant tissue eosinophilia. In one patient, cutaneous perivascular granulomas with eosinophils were found in the skin with surrounding necrobiotic collagen. Perinuclear ANCA (p-ANCA) may be positive. Withdrawal of leukotriene receptor antagonist therapy may lead to improvement, but systemic therapy with prednisone and cyclophosphamide may be required. The neuropathy may be permanent. The pathogenesis of this drug-induced syndrome is unknown. Some cases occur as corticosteroids are tapered, but others have occurred in steroid-naïve asthmatic patients. Unopposed leukotriene B<sub>4</sub> activity, a potent chemoattractant for eosinophils and neutrophils, may explain the clinical findings.

**Carlesimo M, et al:** Churg–Strauss and montelukast. *Int J Immunopathol Pharmacol* 2011; 24:1079–1082.

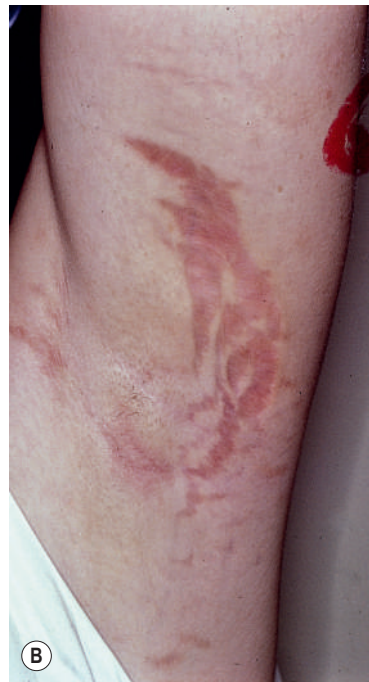**Man MA, et al:** Churg–Strauss syndrome associated with montelukast: case report. *Pneumologia* 2012; 61:113–116.

### Adverse reactions to corticosteroids

Cutaneous reactions may result from topical, intralesional, subcutaneous, or systemic delivery of corticosteroids.

#### Topical application

The prolonged topical use of corticosteroid preparations may produce distinctive changes in the skin. The appearance of these side effects depends on four factors: strength of the steroid, area to which it is applied, amount of coexistent sun damage at the site of application, and patient's predisposition to certain side effects. Atrophy, striae, telangiectasia, skin fragility, and purpura are the changes most frequently seen (Fig. 6-44). The most striking changes of telangiectasia are seen in fair-skinned individuals who use fluorinated corticosteroids on the face. The changes in the skin are enhanced by occlusion. When these side effects occur, the strength of the steroid should be reduced or substituted with pimecrolimus or tacrolimus. Weekly pulse dosing of a potent topical corticosteroid can also reduce the incidence of side effects. Adjunctive measures to reduce steroid requirement could include addition of topical doxepin, pramoxine, or menthol and camphor to the



**Fig. 6-44** Steroid-induced striae.

regimen. Usually, the telangiectases disappear a few months after corticosteroid applications are stopped.

When corticosteroid preparations are applied to the face over weeks or months, persistent erythema with telangiectases, and often small pustules, may occur. Perioral dermatitis and rosacea may be caused by topical corticosteroids. Steroid rosacea has been reported from long-term use of 1% hydrocortisone cream. For this reason, the authors do not recommend chronic topical corticosteroid preparations of any strength in the adjunctive treatment of rosacea. A topical calcineurin inhibitor may be used instead as an anti-inflammatory, although it can also induce a rosacea-like eruption. When a rosacea-like eruption appears in the setting of a topical anti-inflammatory, a pustule should be opened and the contents examined for overgrowth of *Demodex* mites.

Repeated application of corticosteroids to the face, scrotum, or vulva may lead to marked atrophy of these tissues, including the red scrotum syndrome. The tissues become “addicted” to the topical steroid, so that withdrawing treatment results in severe itching or burning and intense erythema. Topical application of corticosteroids can produce epidermal atrophy with hypopigmentation. If used over large areas, sufficient topical steroids may be absorbed to suppress the hypothalamic-pituitary axis. This may affect the growth of children with atopic dermatitis and has led to Addisonian steroid dependency and also Cushing syndrome. Atopic children with more than 50% BSA involvement have short stature. This may be related to their increased use of potent topical corticosteroids. In addition, bone mineral density is reduced in adults with chronic atopic dermatitis severe enough to require corticosteroid preparations stronger than hydrocortisone.

#### Injected corticosteroids

Intralesional injection of corticosteroids is valuable in the management of many dermatoses. The injection of corticosteroids may produce subcutaneous atrophy at the site of injection. The injected corticosteroid may also migrate along lymphatic channels, causing not only local side effects but also linear, atrophic, hypopigmented hairless streaks. These may take years to resolve. These complications are best avoided by injecting directly into the lesion, not into the fat, and using

only the minimal concentration and volume required. Triamcinolone acetonide, not hexacetonide, should be used for injecting cutaneous lesions.

Intramuscular steroid injections should always be given into the buttocks with a long needle (at least 1½ inches in adults). Injection of corticosteroids into the deltoid muscle sometimes causes subcutaneous atrophy. The patient becomes aware of the reaction by noticing depression and depigmentation at the site of injection. There is no pain, but it is bothersome cosmetically. The patient may be assured that this will fill in eventually but may take several years.

## Systemic corticosteroids

Prolonged use of corticosteroids may produce numerous changes of the skin. In addition, steroids have a profound effect on the metabolism of many tissues, leading to predictable, and sometimes preventable, complications. IM injections are not a safer delivery method than oral administration.

### Purpura and ecchymosis

The skin may become thin and fragile. Spontaneous tearing may occur from trivial trauma. Purpura and ecchymoses are especially seen over the dorsal forearms in many patients over age 50, caused by aggravation of actinic purpura.

### Cushingoid changes

The most common change is probably the alteration in fat distribution. Buffalo hump, facial and neck fullness, increased supraclavicular and suprasternal fat, gynecomastia, protuberant or pendulous abdomen, and flattening of the buttocks may occur. Aggressive dietary management with reduction in carbohydrate and caloric intake may ameliorate these changes.

### Steroid acne

Small, firm follicular papules on the forehead, cheeks, and chest may occur. Even inhaled corticosteroids for pulmonary disease can cause acne. Steroid acne can persist as long as the corticosteroids are continued. The management is similar to acne vulgaris with topical preparations and oral antibiotics. Acne from androgen use closely resembles steroid acne.

### Striae

Striae may be widely distributed, especially over the abdomen, buttocks, and thighs.

### Other skin changes

There may be generalized skin dryness (xerosis). The skin may become thin and fragile; keratosis pilaris may develop; persistent erythema of the skin in sun-exposed areas may occur, and erythromelanosis may rarely occur.

## Hair changes

Hair loss occurs in about half of patients receiving long-term corticosteroids in large doses. There may be thinning and brittle fracturing along the hair shaft. Hair growth may be increased on the bearded area and on the arms and back with fine, vellus hairs.

## Systemic complications

Hypertension, cataracts, aseptic necrosis of the hip, and osteoporosis are potential consequences of prolonged therapy with systemic steroids. Bone loss can occur early in the course of corticosteroid therapy, so it should be managed preemptively. Effective management can reduce steroid-induced osteoporosis. All patients with anticipated treatment courses longer than 1 month should be supplemented with calcium and vitamin D (1.0–1.5 g calcium and 400–800 U cholecalciferol daily) and a bisphosphonate, such as alendronate or risedronate. Smoking should be stopped and alcohol consumption minimized. Bone mineral density can be accurately measured at baseline with dual-energy x-ray absorptiometry (DEXA) scan and followed during corticosteroid therapy. Hypogonadism, which contributes to osteoporosis, can be treated in men and women with testosterone or estrogen, respectively. Implementation of bone loss prevention strategies by dermatologists is unacceptably low.

**Torres MJ, et al:** Hypersensitivity reactions to corticosteroids. *Curr Opin Allergy Clin Immunol* 2010; 10:273–279.



Bonus images for this chapter can be found online at

[expertconsult.inkling.com](http://expertconsult.inkling.com)

**eFig. 6-1** *Toxicodendron radicans* subspecies *radicans*, a common poison ivy species found in the eastern United States. (Courtesy of James WD [ed]: *Textbook of Military Medicine*. Office of the Surgeon General, United States Army, 1994.)

**eFig. 6-2** Acute poison ivy reaction.

**eFig. 6-3** Shoe dermatitis.

**eFig. 6-4** Fixed drug reactions. (Courtesy of Dr. L. Liebllich.)

**eFig. 6-5** Nonpigmenting fixed dry eruption caused by pseudoephedrine.

**eFig. 6-6** Argyria.

**eFig. 6-7** Lichenoid drug eruption caused by gold.

**eFig. 6-8** Acneiform eruption caused by epidermal growth factor receptor (EGFR) inhibitor therapy.

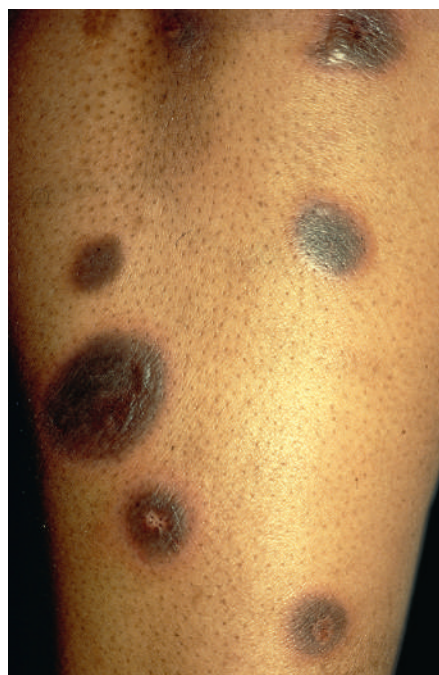**eFig. 6-9** Topical steroid atrophy.

**eFig. 6-10** Fat atrophy caused by superficial steroid injection.

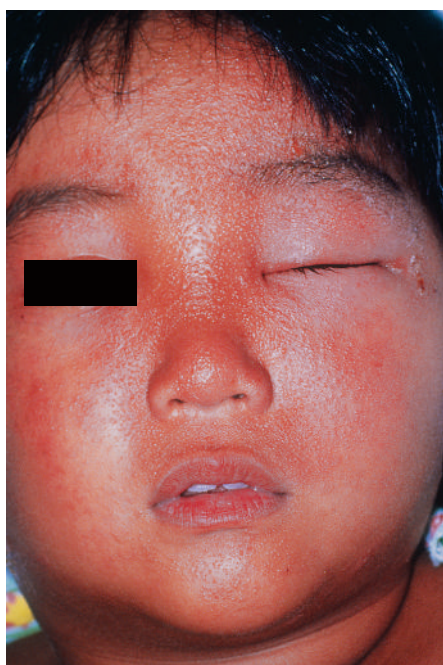



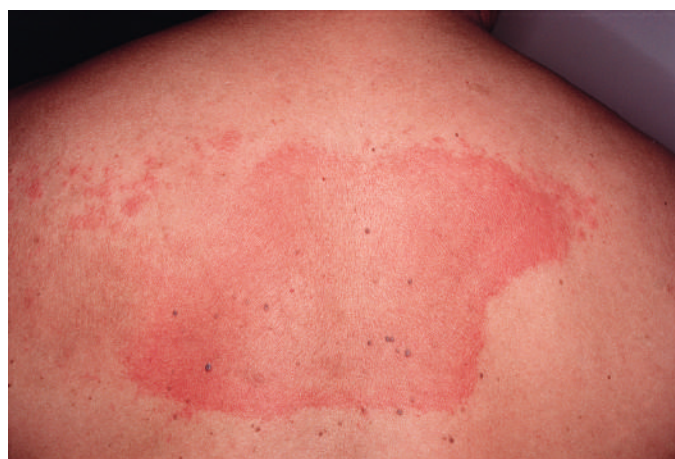**eFig. 6-1** *Toxicodendron radicans* subspecies *radicans*, a common poison ivy species found in the eastern United States. (Courtesy of James WD [ed]: Textbook of Military Medicine. Office of the Surgeon General, United States Army, 1994.)



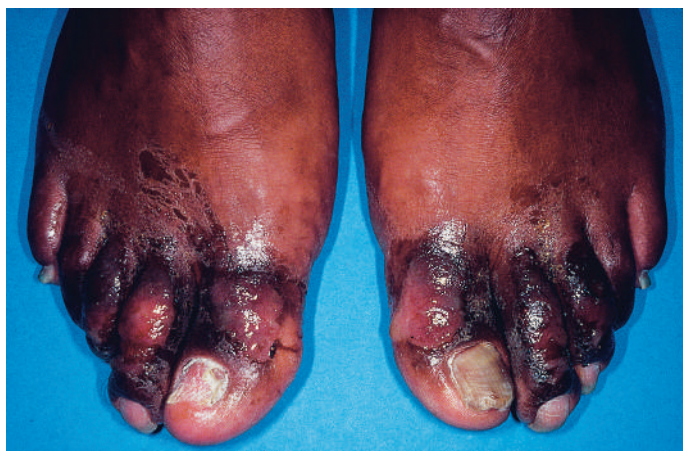**eFig. 6-4** Fixed drug reactions. (Courtesy of Dr. L. Liebllich.)



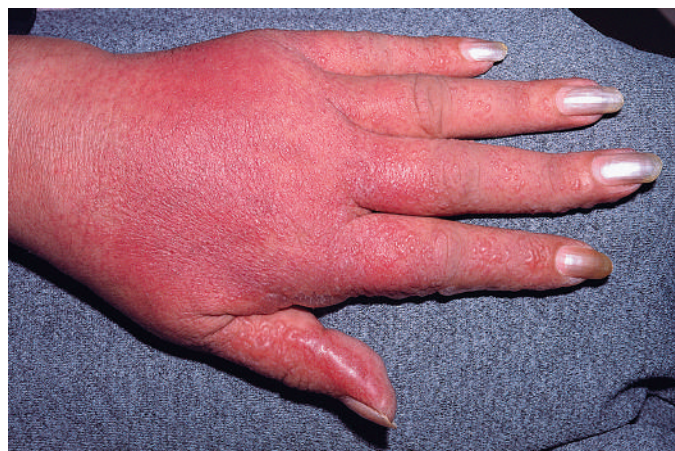**eFig. 6-2** Acute poison ivy reaction.



**eFig. 6-5** Nonpigmenting fixed dry eruption caused by pseudoephedrine.

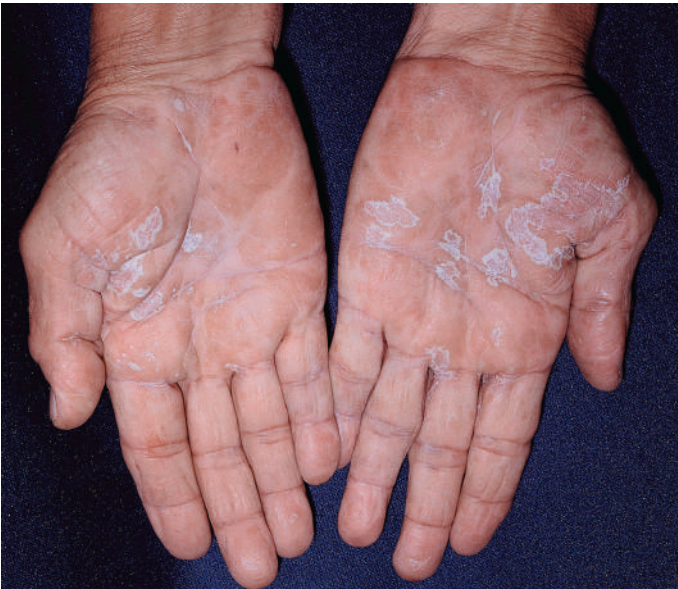

**eFig. 6-3** Shoe dermatitis.

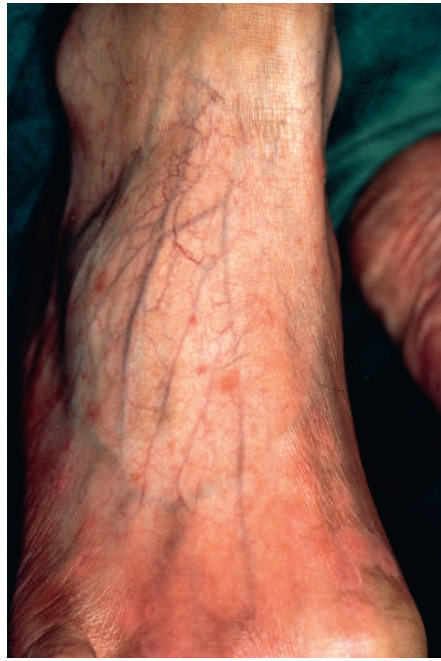

**eFig. 6-6** Argyria.

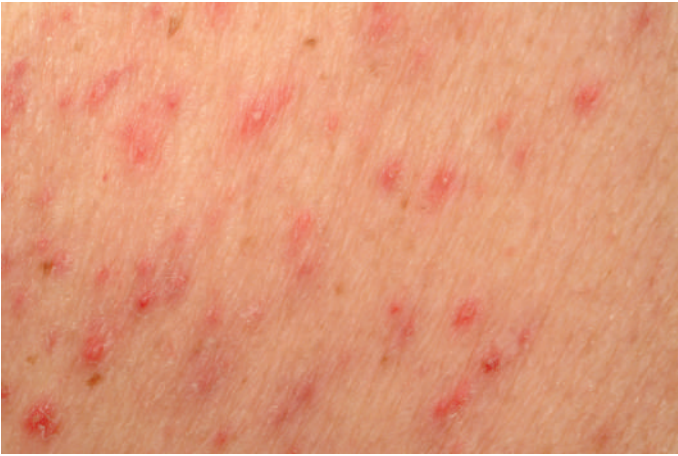



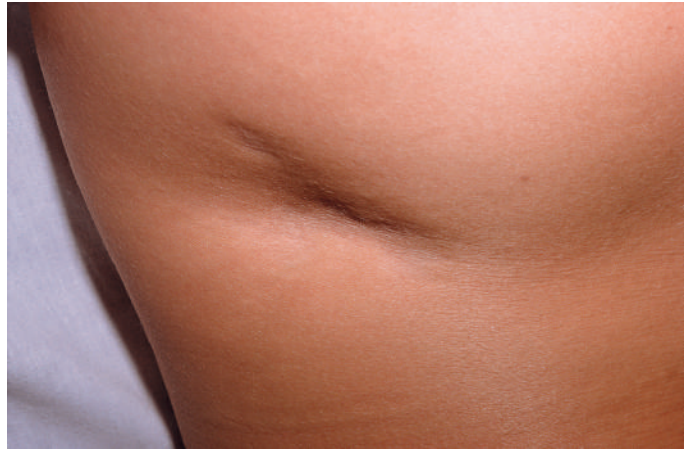**eFig. 6-7** Lichenoid drug eruption caused by gold.



**eFig. 6-9** Topical steroid atrophy.



**eFig. 6-8** Acneiform eruption caused by epidermal growth factor receptor (EGFR) inhibitor therapy.



**eFig. 6-10** Fat atrophy caused by superficial steroid injection.



# 7

## Erythema and Urticaria

### FLUSHING

Flushing presents with transient erythema, usually localized to the face, neck, and upper trunk. Menopausal flushing may be associated with perspiration, as is flushing induced by high ambient temperature, fever, or consumption of hot or spicy foods and beverages. Flushing associated with medications, histamine, or serotonin is generally dry.

Menopausal flushing may be age related, may be induced by oophorectomy or medication (tamoxifen, leuprolide acetate), and may begin long before menses cease. Men may also experience climacteric flushing after surgery or antiandrogen therapy (flutamide).

Blushing, or emotional flushing, may be either emotionally or physiologically induced. Simple facial redness may occur in individuals with translucent skin and is called anatomically predisposed blushing. Intense flushing may be associated with rosacea. In patients with rosacea, exercise, ambient heat or cold, spicy foods, alcohol, and hot beverages are common triggers for flushing. Drugs associated with flushing include niacin, calcium channel blockers, cyclosporine, chemotherapeutic agents, vancomycin, bromocriptine, intravenous contrast material, sildenafil and related drugs for erectile dysfunction, and high-dose methylprednisolone. Severe serotonin toxicity with flushing can be precipitated by the combination of a monoamine oxidase inhibitor and a selective serotonin reuptake inhibitor (SSRI). Reduced or absent methylnicotinate-induced flushing has been noted in patients with schizophrenia. This lack of flushing in response to methylnicotinate has been used for diagnostic psychiatric testing. Flushing after induction of general anesthesia with agents such as thiopental and muscle relaxants is more common in patients prone to blushing. It appears to be neuronally mediated rather than related to histamine release. Endogenous vasoactive substances are associated with flushing in carcinoid syndrome, mastocytosis, medullary thyroid carcinoma, and pheochromocytoma.

Food-associated flushing may be caused by capsaicin (red pepper), sodium nitrate, or alcohol. Alcohol may produce flushing in patients using topical calcineurin inhibitors. Sulfites are found in wine, dried fruit, prepared foods, and fresh grapes and potatoes. Ciguatera or scombroid fish poisoning is a form of histamine-related food poisoning, caused by histamine within the flesh of the fish. Dietary histamine is normally detoxified by amine oxidases, and those with low amine oxidase activity are at greater risk for histamine toxicity. Individuals who flush without an identifiable cause should be investigated for dietary triggers and subtle manifestations of rosacea. Urinary catecholamines and serotonin and histamine metabolites should be measured if an endogenous cause is suspected. Many cases of flushing remain idiopathic. These patients may be managed with avoidance of dietary triggers and by sipping iced water to break the flush. Menopausal flushing responds to low-dose oral or transdermal estrogen.

The Women's Health Initiative studies concerning hormone replacement therapy (HRT) suggested that breast cancer risk is increased by combinations of estrogen and progestogen taken for longer than 5 years. Unopposed estrogen can increase the risk of endometrial carcinoma in premenopausal women. HRT does not appear to lower the risk of cardiac events, and the risks of long-term therapy often outweigh the benefits. Short-term HRT may still be very helpful in the management of perimenopausal flushing, because alternatives, including SSRIs, adrenergic agents, gabapentin, and phytoestrogens, have generally been disappointing. Flushing can be reduced by avoidance of alcohol, caffeine, and spicy foods. Niacin-induced flushing is mediated by prostaglandin D<sub>2</sub>. PGD<sub>2</sub> shows some response to aspirin, as well as the PGD<sub>2</sub> receptor-1 antagonist laropiprant.

**Demoncheaux JP, et al:** A large outbreak of scombroid fish poisoning associated with eating yellowfin tuna (*Thunnus albacares*) at a military mass catering in Dakar, Senegal. *Epidemiol Infect* 2012; 140:1008–1012.

**Hsu CC, et al:** Pronounced facial flushing and persistent erythema of rosacea effectively treated by carvedilol, a nonselective  $\beta$ -adrenergic blocker. *J Am Acad Dermatol* 2012; 67:491–493.

**Maintz L, et al:** Histamine and histamine intolerance. *Am J Clin Nutr* 2007; 85:1185–1196.

**Ogunleye T, et al:** Ethanol-induced flushing with topical pimecrolimus use. *Dermatitis* 2008; 19:E1–E2.

**Paolini JF, et al:** Effects of laropiprant on nicotinic acid-induced flushing in patients with dyslipidemia. *Am J Cardiol* 2008; 101:625–630.

**Sassarini J, et al:** Hot flushes: are there effective alternatives to estrogen? *Menopause Int* 2010; 16:81–88.

### ERYTHEMAS

The term erythema means blanchable redness (hyperemia) of the skin. A number of reactive skin conditions are referred to as erythema. These include toxic erythemas related to viral and bacterial infections, erythema multiforme, erythema nodosum, and the gyrate (figurate) erythemas.

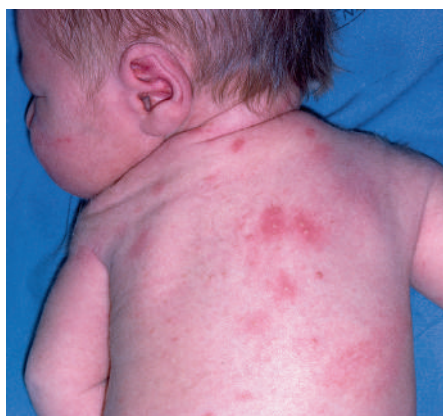#### Erythema palmare

Erythema palmare, or persistent palmar erythema, is usually most marked on the hypothenar areas and is associated with an elevated level of circulating estrogen. Cirrhosis, hepatic metastases, and pregnancy are common causes.

**Serrao R, et al:** Palmar erythema. *Am J Clin Dermatol* 2007; 8:347–356.

#### Generalized erythema

Generalized erythema may be caused by medications, bacterial toxins, or viral infection. It is often uneven in distribution, being most noticeable on the chest, proximal extremities, and face. In general, these reactions are self-limited and resolve



**Fig. 7-1** Erythema toxicum neonatorum.

when the offending medication is stopped or the associated infection is treated or resolves. Specific exanthems associated with bacterial or viral infections are discussed in Chapters 14 and 19.

### Erythema toxicum neonatorum

Erythema toxicum neonatorum occurs in just under half of healthy full-term newborns, usually on the second or third day of life (Fig. 7-1). Because it is so common, dermatologists are usually consulted only for the most florid or atypical cases. Characteristically, the broad erythematous flare is much more prominent than the small follicular papule or pustule it surrounds. Lesions involve the face, trunk, and proximal extremities and appear rarely on the soles or palms. There may be confluent erythema on the face. Fever is absent, and the eruption generally disappears by the 10th day. Erythema toxicum must be distinguished from miliaria, bacterial folliculitis, neonatal herpes, and scabies. When the rash is atypical, smears of the pustules demonstrating eosinophils are adequate to confirm the diagnosis. Rarely, a biopsy is required and demonstrates folliculitis containing eosinophils and neutrophils.

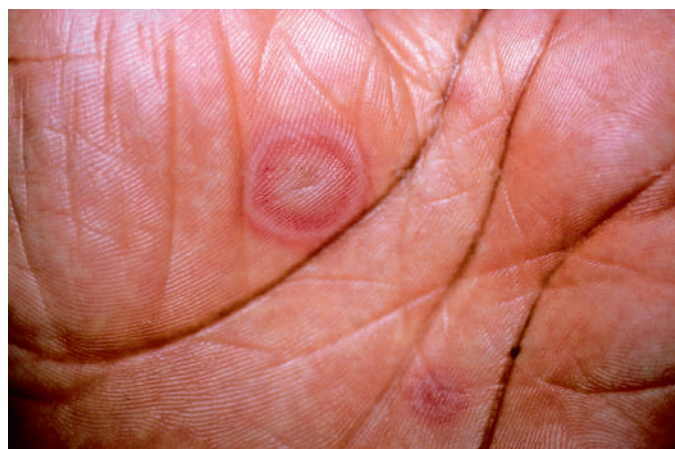**Monteagudo B, et al:** Prospective study of erythema toxicum neonatorum. *Pediatr Dermatol* 2012; 29:166–168.

**Morgan AJ, et al:** Erythema toxicum neonatorum revisited. *Cutis* 2009; 83:13–16.

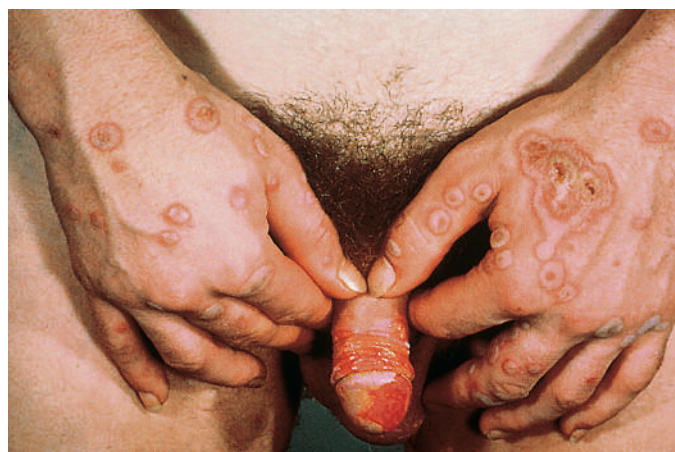### Erythema multiforme

In 1860, von Hebra first described erythema exudativum multiforme. The original disease described by von Hebra is now called erythema multiforme minor (minus) or herpes simplex-associated erythema multiforme. It is strongly associated with a preceding herpetic infection. When multiple mucous membranes are involved, the lesions are more intense, and fever or arthralgias accompany the eruption, erythema multiforme major (majus) is diagnosed. This is most often caused by *Mycoplasma* infection. In contrast, Stevens-Johnson syndrome (SJS) and toxic epidermal necrolysis (TEN) usually represent adverse reactions to medications (see Chapter 6). As treatment and prognosis are related in part to the inciting agent, it is useful to classify erythema multiforme (EM) as follows:

- Herpes simplex-associated EM (HAEM)
- Erythema multiforme major (most often caused by *Mycoplasma*)
- Chronic oral EM
- Contact dermatitis-induced EM (see Chapter 6)
- Radiation-induced EM (see Chapter 6)
- Idiopathic



**Fig. 7-2** Erythema multiforme, target lesions.



**Fig. 7-3** Erythema multiforme involving dorsal hands and penis.

### Clinical features

Erythema multiforme minor (HAEM) is a recurrent self-limited disease, usually of young adults, occurring seasonally in the spring and fall, with each episode lasting 1–4 weeks. The individual clinical lesions begin as sharply margined, erythematous macules, which become raised, edematous papules over 24–48 h. The lesions may reach several centimeters in diameter. Typically, a ring of erythema forms around the periphery, and centrally the lesions become flatter, more purpuric, and dusky. This lesion is the classic “target” or “iris” lesion with three zones: central dusky purpura; an elevated, edematous, pale ring; and surrounding macular erythema (Figs. 7-2 and 7-3). The central area may be bullous. Typical targets are best observed on the palms and soles. Lesions generally appear symmetrically and acrally, with initial involvement most frequently on the dorsal hands. The dorsal feet, extensor limbs, elbows, knees, palms, and soles typically become involved. In about 10% of patients, more widespread lesions occur on the trunk. The Koebner phenomenon or photoaccentuation may be observed. Mucosal involvement occurs in 25% of cases and is usually limited to the oral mucosa. Oral lesions may appear as indurated plaques, target lesions, or erosions (Fig. 7-4).

An atypical variant of HAEM has been described in women. It consists of outbreaks of unilateral or segmental papules and plaques that may be few in number or solitary. Lesions may be up to 20 cm in diameter. The plaques are erythematous and evolve to have a dusky center, which desquamates. Subcutaneous nodules resembling erythema nodosum may be



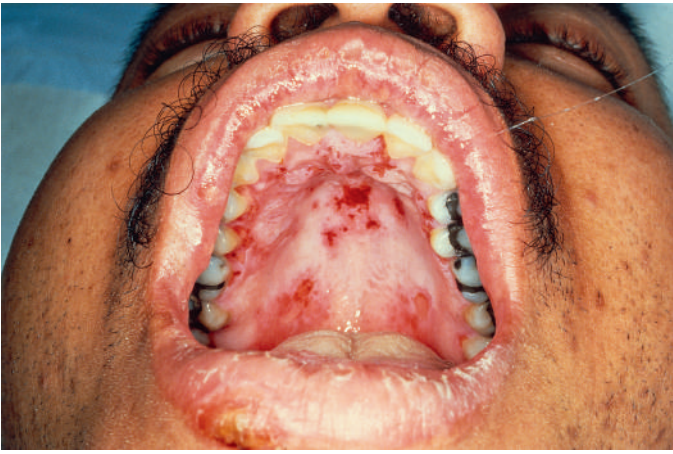

Fig. 7-4 Mucosal lesions of erythema multiforme.

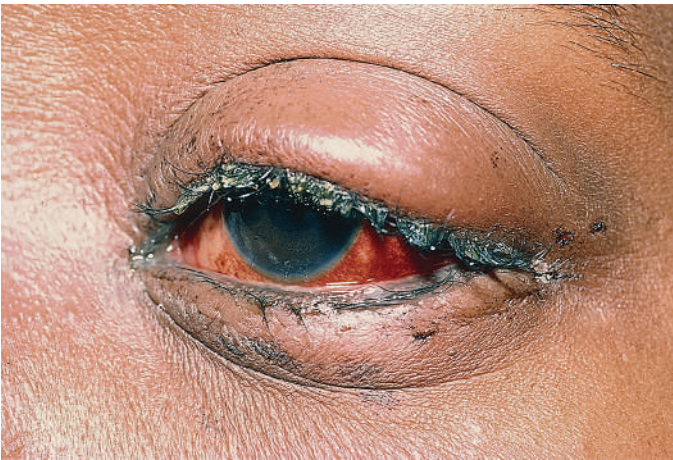

Fig. 7-5 Ocular erythema multiforme.

simultaneously present. Histologic examination shows features of EM, and herpes simplex virus (HSV) DNA is identified in the lesions by polymerase chain reaction (PCR). Acyclovir suppression prevents the lesions, and prednisone therapy seems to increase the frequency of attacks.

Erythema multiforme major is frequently accompanied by a febrile prodrome and sometimes arthralgias. It occurs in all ages, is centered on the extremities and face, but more often than EM minor may include truncal lesions, which are papular and erythematous to dusky in color. Mucous membrane disease is prominent and often involves not only the oral mucosa and lips, but the genital and ocular mucosa as well (Fig. 7-5). SJS is distinguished morphologically by the presence of purpura or bullae in macular lesions of the trunk (Fig. 7-6). In children, polycyclic urticarial lesions often become dusky centrally and are frequently misdiagnosed as EM. This presentation of urticaria has been dubbed “urticaria multiforme.” It represents urticaria, and histologic changes of EM are never present.

### Etiologic factors

Typical EM minor is usually associated with a preceding orolabial HSV infection. HAEM lesions appear 1–3 weeks (average 10 days) after the herpes outbreak. Episodes of EM minor may not follow every episode of herpes, and some EM outbreaks will not be preceded by a clinically recognizable herpetic lesion. Using PCR and in situ hybridization techniques, HSV DNA and antigens have been found in the lesions of EM minor. The majority of “idiopathic” cases of EM minor are

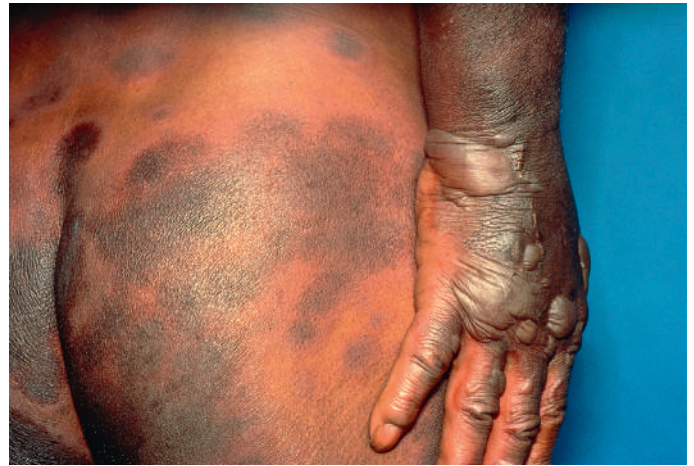

Fig. 7-6 Atypical target lesion in Stevens-Johnson syndrome.

associated with recurrent HSV infection, and patients may be successfully treated with suppressive antiviral regimens. EM major is associated with *Mycoplasma* infections, although a minority may result from herpes simplex and a reaction to medications.

### Histopathology

The histologic features are similar in HAEM and EM major and are not predictive of etiology. The extent of epidermal involvement depends on the duration of the lesion and where in the lesion the biopsy is taken. All lesions are characterized by cellular necrosis. Biopsies of EM demonstrate a normal basket-weave stratum corneum and a vacuolar interface reaction. Vacuoles and foci of individual cell necrosis are present and out of proportion to the number of lymphocytes. The dermal infiltrate is largely mononuclear and tends to be primarily around the upper dermal vessels and along the dermo-epidermal junction. Activated T lymphocytes are present in lesions of EM, with cytotoxic or suppressor cells more prominent in the epidermis and helper T cells in the dermis. Leukocytoclastic vasculitis is not observed. Eosinophils may be present but are rarely prominent. The presence of eosinophils is not predictive of the etiology. Histologically, EM must be distinguished from the following:

- Fixed drug eruption, which often has a deeper infiltrate, eosinophils and neutrophils, papillary dermal fibrosis, and melanophages around postcapillary venules
- Graft-versus-host disease (GVHD), which typically has a more compact stratum corneum and epithelial disorder resembling Bowen’s disease
- Pityriasis lichenoides, which characteristically has a lymphocyte in every vacuole, erythrocyte extravasation, and neutrophil margination within dermal vessels
- Lupus erythematosus, which has compact hyperkeratosis, a deeper periadnexal infiltrate, dermal mucin, and basement membrane zone thickening

### Differential diagnosis

When characteristic target lesions are present, the diagnosis of EM is established clinically. When bullae are present, EM major must be distinguished from bullous arthropod reactions and autoimmune bullous diseases: pemphigus if mucous membrane involvement is prominent, and bullous pemphigoid if lesions are small and erythema is prominent at the periphery of the bulla. Paraneoplastic pemphigus may produce atypical target lesions, mucosal involvement, and a vacuolar



interface dermatitis and may appear similar to *Mycoplasma*-induced EM major. Use of direct immunofluorescence may be necessary to exclude this possibility.

## Treatment

Treatment of EM is determined by its cause and extent. EM minor is generally related to HSV, and prevention of herpetic outbreaks is central to control of the subsequent episodes of EM. A sunscreen lotion and sunscreen-containing lip balm should be used daily on the face and lips to prevent ultraviolet B (UVB)-induced outbreaks of HSV. If this does not prevent recurrence or if genital HSV is the cause, chronic suppressive doses of an oral antiviral drug (valacyclovir, 1 g/day, or famciclovir, 250 mg/day) may be used. If this dose is ineffective, it may be doubled. This will prevent recurrences in up to 90% of HSV-related cases. Intermittent treatment with systemic antivirals or the use of topical antivirals is of minimal benefit in preventing HAEM. In patients whose condition fails to respond adequately to antiviral suppression, dapsone, cyclosporine, or thalidomide may occasionally be helpful. It should be noted that most cases of EM minor (HAEM) are self-limited, and symptomatic treatment may be all that is required. Symptoms related to oral lesions often respond to topical “swish and spit” mixtures containing lidocaine, diphenhydramine (Benadryl), and kaolin. In extensive cases of EM minor, systemic corticosteroids have been used, but because these theoretically may reactivate HSV, steroids are best given concurrently with an antiviral drug. For patients with widespread EM unresponsive to the previous therapies, management is as for severe drug-induced SJS (see Chapter 6).

**Bakis S, et al:** Intermittent oral cyclosporin for recurrent herpes simplex-associated erythema multiforme. *Australas J Dermatol* 2005; 14:18.

**Chen CW, et al:** Persistent erythema multiforme treated with thalidomide. *Am J Clin Dermatol* 2008; 9:123–127.

**Emer JJ, et al:** Urticaria multiforme. *J Clin Aesth Dermatol* 2013; 6:34–39.

**Majorana A, et al:** Oral mucosal lesions in children from 0 to 12 years old: ten years' experience. *Oral Surg Oral Med Oral Pathol Oral Radiol Endod* 2010; 110:e13–e18.

**Samim F, et al:** Erythema multiforme. *Dent Clin North Am* 2013; 57:583–596.

**Sokumbi O, et al:** Clinical features, diagnosis, and treatment of erythema multiforme. *Int J Dermatol* 2012; 51:889–902.

**Wetler DA, et al:** Recurrent erythema multiforme. *J Am Acad Dermatol* 2010; 62:45.

## Oral erythema multiforme

A unique subset of EM is limited to or most prominent in the oral cavity. Clinically, patients are otherwise well; 60% are female, with a mean age of 43 years. The minority, about 25%, have recurrent, self-limited, cyclic disease. The oral cavity is the only site of involvement in 45%, in 30% there is oral and lip involvement, and in 25% the skin is also involved. All portions of the oral cavity may be involved, but the tongue, gingiva, and buccal mucosa are usually most severely affected. Lesions are almost universally eroded, with or without a pseudomembrane. There are no well-designed trials of treatment for oral EM, but the treatments previously listed for EM minor are typically used. “Swish and spit” mixtures containing lidocaine, diphenhydramine, and kaolin are helpful for symptomatic relief. Patients should be warned to chew carefully because the anesthetic effect may dampen their gag reflex.

**Joseph TI, et al:** Drug-induced oral erythema multiforme. *J Oral Maxillofac Pathol* 2012; 16:145–148.

**Scully C, Bagan J:** Oral mucosal diseases: erythema multiforme. *Br J Oral Maxillofac Surg* 2008; 46:90–95.

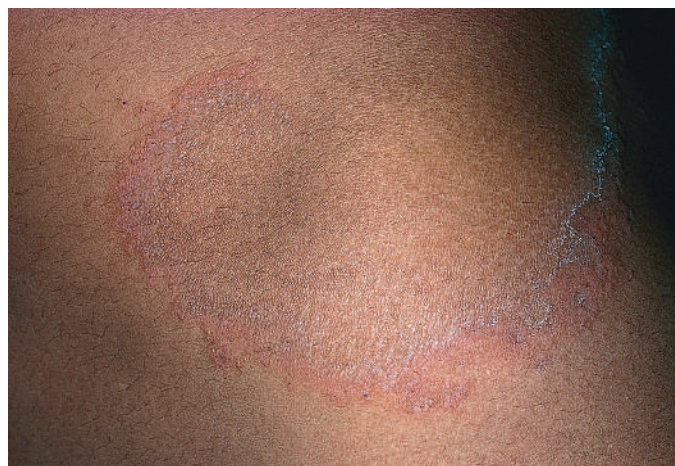

Fig. 7-7 Erythema annulare centrifugum.

## Gyrate erythemas (figurate erythemas)

The gyrate erythemas are characterized by clinical lesions that are round (circinate), ringlike (annular), polycyclic (figurate), or arcuate. The primary lesions are erythematous and slightly elevated. There may be a trailing scale, as in erythema annulare centrifugum. In some of these diseases, the lesions are transient and migratory, and in some they are fixed. Gyrate erythemas often represent the cutaneous manifestations of an infection, malignancy, or drug reaction. Certain diseases in this group have specific causes (erythema marginatum of rheumatic fever, carrier state of chronic granulomatous disease, erythema migrans of Lyme borreliosis) and are discussed in the relevant chapters.

## Erythema annulare centrifugum

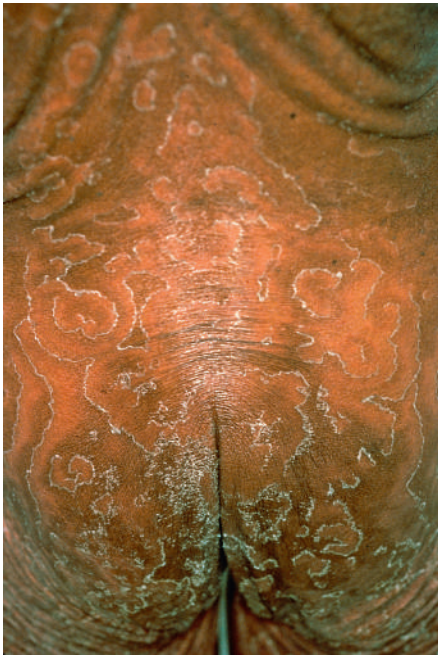Erythema annulare centrifugum (EAC) is the most common gyrate erythema. It is characterized by asymptomatic annular or polycyclic lesions that grow slowly (2–3 mm/day), rarely reaching more than 10 cm in diameter. Characteristically, there is a trailing scale at the inner border of the annular erythema (Fig. 7-7). The surface is typically devoid of crusts or vesicles, although atypical cases with telangiectasia and purpura have been described. Lesions usually occur on the trunk and proximal extremities. Mucosal lesions are absent.

Histologically, the epidermis will show mild focal spongiosis and parakeratosis. Within the superficial dermis and at times the deep dermis, lymphocytes are organized tightly around the blood vessels in a pattern described as a “coat sleeve” arrangement. The gyrate erythemas are divided into the superficial and deep types, but these histologic types do not correlate with etiology.

Waxing and waning in severity, EAC tends to be recurrent over months to years. Most cases eventually subside spontaneously. While active, the eruption is often responsive to topical steroids. Topical calcipotriol has also been reported to be successful.

The majority of EAC cases are idiopathic. Some cases are clearly associated with dermatophytosis or the ingestion of molds, such as those in blue cheese. Other foods, such as tomatoes, are sometimes implicated, and a dietary journal may be helpful. Medications are implicated in some cases, and internal cancer has been found. Laboratory tests should be dictated by the physical examination and associated signs and symptoms. In one study of 66 patients, 48% had an associated cutaneous fungal infection such as tinea pedis, and 13% had internal malignancies.





**Fig. 7-8** Erythematous gyratum repens.

The differential diagnosis of EAC includes conditions that can have annular configuration, including granuloma annulare, secondary syphilis, tinea, subacute cutaneous lupus erythematosus, sarcoidosis, Hansen's disease, erythema marginatum, erythema migrans, annular urticaria, and mycosis fungoides. Histologic examination, clinical features, and basic laboratory examinations will usually allow these diseases to be excluded.

### Erythema gyratum repens

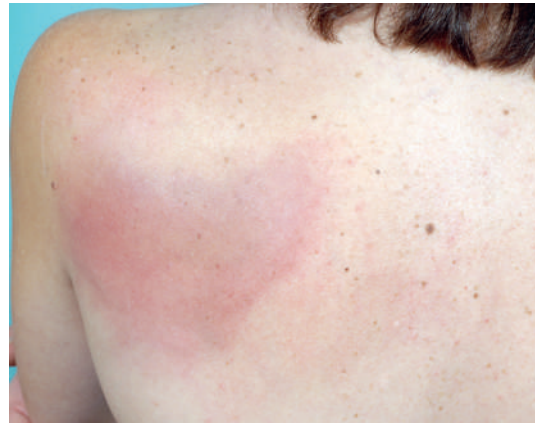Erythema gyratum repens (EGR) is a rare disease that is striking and unique in appearance. Lesions consist of undulating wavy bands of slightly elevated erythema with trailing scale over the entire body. Lesions migrate rapidly (up to 1 cm/day) and are characteristically concentric, giving the skin a "wood grain" appearance (Fig. 7-8).

Pruritus may be severe, and blood eosinophilia is often found. In more than 70% of patients, an underlying malignancy is found. Lung cancer is the most common associated malignancy, although a wide range of neoplasms has been described. The skin eruption precedes the detection of the malignancy by an average of 9 months. Given the high frequency of malignant disease, patients with EGR should have extensive evaluations to exclude internal malignancy. If the carcinoma is removed, the lesions clear. Otherwise, the eruption is generally resistant to treatment, although cetirizine and topical corticosteroids have been reported to improve individual cases. EGR may be a drug-induced eruption or rarely, secondary to pulmonary tuberculosis. These patients respond to discontinuation of the implicated medication or to treatment of the underlying condition.

### Eosinophilic annular erythema

Adults or children may develop bilateral annular erythema, usually presenting on the trunk and often symmetrical. Females are the favored sex. Histologically a dense perivascular and interstitial lymphocytic infiltrate with many eosinophils is seen but without flame figures. Spontaneous resolution may occur. Hydroxychloroquine and/or prednisone are favored treatments when needed. No associated conditions are present.

Neutrophilic figurate erythema of infancy is a variant with a dermal neutrophilic infiltrate and karyorrhexis on biopsy.



**Fig. 7-9** Wells syndrome (eosinophilic cellulitis).

**Campbell L, et al:** Erythema gyratum repens without associated malignancy. *J Am Acad Dermatol* 2011; 65:e22–e23.

**Chodkiewicz HM, et al:** Paraneoplastic erythema annulare centrifugum eruption. *Am J Clin Dermatol* 2012; 13:239–246.

**De La Torre-Lugo EM, et al:** Erythema gyratum repens. *J Am Acad Dermatol* 2011; 64:e89–e90.

**El-Khalawany M, et al:** Eosinophilic annular erythema is a peculiar subtype in the spectrum of Wells syndrome. *J Eur Acad Dermatol Venereo* 2013; 27:973–979.

**Honma M, et al:** Erythema annulare centrifugum simulating erythema gyratum repens. *J Dermatol* 2011; 38:192–193.

**Kim KJ, et al:** Clinicopathologic analysis of 66 cases of erythema annulare centrifugum. *J Dermatol* 2002; 29:61.

**Patrizi A, et al:** Neutrophilic figurate erythema of infancy. *Pediatr Dermatol* 2008; 25:255–260.

**Rao NG, et al:** Erythema responding to tacrolimus ointment. *J Drugs Dermatol* 2003; 2:421.

**Rongioletti F, et al:** Erythema gyratum repens is not an obligate paraneoplastic disease. *J Eur Acad Dermatol Venereo* 2014; 28:112–115.

## EOSINOPHILIC CELLULITIS (WELLS SYNDROME)

In 1971, Wells described four patients with acute onset of plaques resembling cellulitis that persisted for many weeks (Fig. 7-9). Wells syndrome occurs at all ages, and pruritus is common. The condition is typically recurrent, and individual episodes may be prolonged. Degranulation of dermal eosinophils produces the flame figures seen in histologic sections. These consist of dermal collagen with adherent eosinophil granules. Eosinophilic panniculitis may also be present.

It is unclear whether Wells syndrome is a distinct disorder sui generis or a reaction pattern to many possible allergic stimuli. Many (perhaps most) cases represent arthropod reactions. It has also been associated with onchocerciasis, intestinal parasites, varicella, mumps, immunization, drug reactions that include the anti-tumor necrosis factor (TNF)- $\alpha$  biologic agents, myeloproliferative diseases, angioimmunoblastic lymphadenopathy, atopic diathesis, inflammatory bowel disease (IBD), hypereosinophilic syndrome, Churg-Strauss syndrome, and fungal infection. Treatment includes topical and intralesional corticosteroids, oral antihistamines, tacrolimus ointment, minocycline, UVB, psoralen plus ultraviolet A (PUVA), dapsone, and low-dose prednisone. Despite that some cases may be caused by exposure to TNF inhibitors, one patient whose condition responded well to adalimumab has been documented. Any triggering factor, such as arthropod bites, should be eliminated.

**Boura P, et al:** Eosinophilic cellulitis (Wells' syndrome) as a cutaneous reaction to the administration of adalimumab. *Ann Rheum Dis* 2006; 65:839–840.

**Powell JG, et al:** Eosinophilic cellulitis (Wells syndrome) in a pediatric patient: a case report and review of the literature. *Cutis* 2012; 89:191–194.

**Sarin KY, et al:** Treatment of recalcitrant eosinophilic cellulitis with adalimumab. *Arch Dermatol* 2012; 148:990–992.

**Tugnet N, et al:** Wells syndrome (eosinophilic cellulitis) secondary to infliximab. *Rheumatology* 2012; 51:195–196.

**Verma P, et al:** Idiopathic bullous eosinophilic cellulitis (Wells syndrome) responsive to topical tacrolimus and antihistamine combination. *Indian J Dermatol Venereol Leprol* 2012; 78:378–380.

**Winfield H, et al:** Eosinophilic cellulitis–like reaction to subcutaneous etanercept injection. *Arch Dermatol* 2006; 142:218–220.

## REACTIVE NEUTROPHILIC DERMATOSES

As with the gyrate erythemas, the reactive neutrophilic dermatoses tend to follow certain stimuli, such as acute upper respiratory tract infections (URIs), or are associated with underlying diseases, such as IBD and hematologic malignancy. Some of the neutrophilic dermatoses share common triggers, and clinical features may overlap. Patients may exhibit the simultaneous or sequential appearance of two or more of the conditions. Most often is the combination of typical lesions of Sweet syndrome on the upper body and erythema nodosum (EN)-like lesions on the legs. In these patients, histology often enables the diagnosis of subcutaneous Sweet syndrome for the EN-type lesions, allowing one diagnosis to be made. In occasional cases, however, it may be difficult to establish the diagnosis firmly as one of the neutrophilic reactive dermatoses. For these reasons, it is clinically useful to think of these diseases as forming a spectrum of conditions expressed in certain individuals by a group of stimuli with various overlapping morphologies.

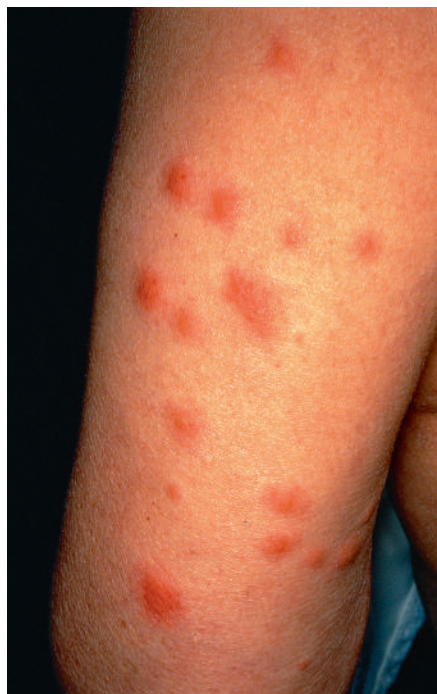### Erythema nodosum

Erythema nodosum is discussed in Chapter 23.

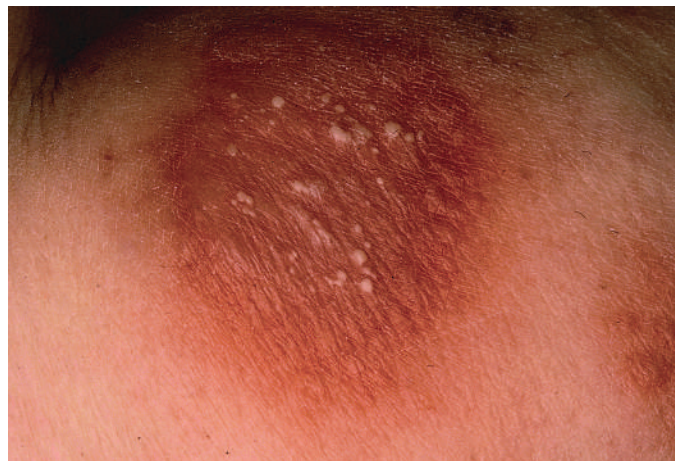### Sweet syndrome (acute febrile neutrophilic dermatosis)

Since its first description in 1964 by Dr. Robert Sweet, as a recurrent febrile dermatosis in women, the spectrum of this syndrome has expanded. Sweet syndrome primarily affects adults, and females outnumber males by about 3:1. In younger adults, female predominance is marked, but in persons older than 50, the gender ratio is more equal, and cases associated with malignancy have a 1:1 ratio. In children, boys and girls are equally affected. In Europe, cases are more common in the spring and fall. Four subtypes of Sweet syndrome have been described, based on their pathogenesis: the classic type (71%), cases associated with neoplasia (11%), cases associated with inflammatory disease (16%), and cases associated with pregnancy (2%).

The clinical features of all four subtypes are similar, although dusky bullous and necrotic lesions that overlap with pyoderma gangrenosum are more common in patients with associated leukemia. The primary skin lesion is a sharply marginated, rapidly extending, tender, erythematous or violaceous, painful, elevated plaque, 2–10 cm in diameter. Lesions may appear intensely edematous or merely indurated (Fig. 7-10). They typically involve the face, neck, upper trunk, and extremities. Some patients have lesions localized to the cheeks. Lesions may burn but do not itch. The surface of the plaques may develop vesiculation or postulation as a result of an intense dermal inflammatory infiltrate and accompanying



**Fig. 7-10** Sweet syndrome, erythematous lesions.



**Fig. 7-11** Sweet syndrome; note superficial pustules.

dermal edema (Fig. 7-11). Clinical morphologic variants recently described include three immunocompromised patients with deep necrosis simulating necrotizing fasciitis and a second report of three patients whose lesions were extremely large and described as giant cellulitis–like in appearance. Pathergy and koebnerization after trauma or UVB occur infrequently.

More than three quarters of Sweet syndrome patients have systemic findings. The most common is fever, present in 50–80% of patients. Arthritis, arthralgias, or myalgias occur in one third to two thirds of cases. About 30% of patients have conjunctivitis or episcleritis. Other ocular manifestations include periorbital inflammation, dacryoadenitis, limbal nodules, peripheral ulcerative keratitis, glaucoma, iritis, and choroiditis. Oral lesions resembling aphthae occur in 2% or 3% of classic cases, but in 10% or more of those associated with hematologic malignancy. Cough, dyspnea, and pleuritis may represent pulmonary involvement. Pulmonary infiltrates and effusions are often seen on chest radiographs of such patients. Rarely, there may be cardiac, renal, hepatic, intestinal, and neurologic involvement. Multifocal sterile osteomyelitis may occur.



Laboratory findings include an elevated sedimentation rate (90%), neutrophilia (70%), leukocytosis (60%), and a left shift (increased bands; 50%). Antineutrophilic cytoplasmic antibodies (ANCA) have been reported. In most cases, an attack lasts 3–6 weeks and then resolves. Recurrences may be seen with the same precipitating cause, such as URI. Persistent cases, with new lesions erupting before the old lesions resolve, may continue for many years.

The histologic hallmark of Sweet syndrome is a nodular and diffuse dermal infiltrate of neutrophils with karyorrhexis and massive papillary dermal edema. Leukocytoclastic vasculitis may be present focally, and this does not exclude a diagnosis of Sweet syndrome. Upper dermal edema may be so intense as to form subepidermal bullae. Leukemic cells may be present in the infiltrate, and clonal restriction of neutrophils has even been seen in Sweet syndrome not associated with malignancy.

Histologic variants described as histiocytic or lymphocytic Sweet syndrome have been reported. Occasionally, the main infiltrating cell resembles these cell types, but on immunohistochemical stains, they are found to be of myelogenous origin. Special investigations such as myeloperoxidase stains are positive and confirm Sweet syndrome as the diagnosis. Usually, myelodysplasia or frank leukemia is present or will manifest in the not-so-distant future.

The majority of cases of Sweet syndrome follow a URI and are therefore acute and self-limited. Other associated conditions include infections with *Yersinia*, toxoplasmosis, histoplasmosis, salmonellosis, tuberculosis, tonsillitis, and vulvovaginal infections. Sweet syndrome has been reported in association with IBD and overlaps with the bowel bypass or “blind loop” syndrome. Cases have also been associated with peripheral ulcerative keratitis and Behçet syndrome.

Hematologic malignancies or solid tumors are present in about 10% of reported cases. Sweet syndrome often presents early in the course of the cancer, when therapy is more efficacious. Associated malignancies are usually hemoproliferative and include leukemias (usually acute myelogenous), lymphomas, anemias, myelodysplastic syndrome, and polycythemia vera. Solid tumors are of any type but are most often genitourinary, breast (in women), or gastrointestinal (in men). Anemia is found in 93% of men and 71% of women with malignancy-associated Sweet syndrome. Thrombocytopenia is seen in half. Solitary, bullous or ulcerative lesions are more frequently associated with malignancy.

Pregnancy-associated Sweet syndrome typically presents in the first or second trimester with lesions on the head, neck, trunk, and less often on the upper extremities. Lower-extremity lesions resembling EN may occur. The condition may resolve spontaneously or clear with topical or systemic corticosteroids. It may recur with subsequent pregnancies, but there seems to be no risk to the fetus.

Many drug therapies have been associated with Sweet-like reactions in the skin, although the strongest association exists for granulocyte colony-stimulating factor and all-*trans*-retinoic acid. Oral contraceptives, radiation therapy fields, vaccines, bortezomib, gemcitabine, trimethoprim-sulfamethoxazole, and minocycline have been implicated. All-*trans*-retinoic acid causes terminal differentiation of some leukemic clones and is used to treat promyelocytic leukemia. After about 2 weeks of treatment, Sweet-like lesions may appear. Initially, these skin lesions may contain immature blasts, making it difficult to distinguish them from leukemia cutis. Later, the lesions contain more mature neutrophils. Induction of the skin lesions appears to be related to the desired pharmacologic effect of the medication.

The two major criteria for the diagnosis of Sweet syndrome are the presence of red edematous plaques and a biopsy dem-

### Box 7-1 Revised diagnostic criteria for diagnosis of Sweet syndrome\*

#### Major criteria

1. Abrupt onset of erythematous plaques or nodules, occasionally with vesicles, pustules, or bullae
2. Nodular and diffuse neutrophilic infiltration in the dermis with karyorrhexis and massive papillary dermal edema

#### Minor criteria

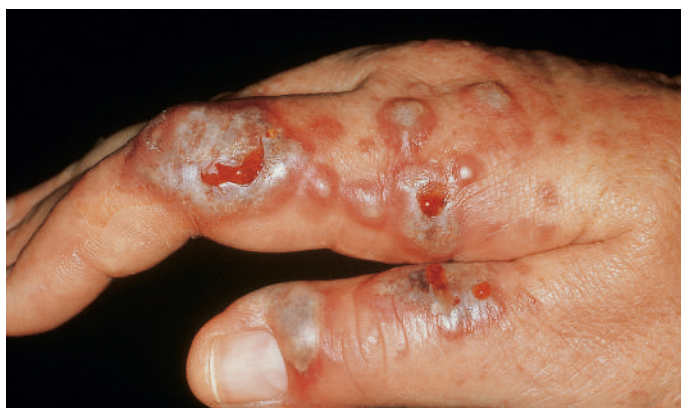1. Preceded by a respiratory infection, gastrointestinal tract infection or vaccination, or associated with:
  - Inflammatory disease or infection
  - Myeloproliferative disorders or other malignancy
  - Pregnancy
2. Malaise and fever (>38°C [100.4°F])
3. Abnormal laboratory findings  $\geq 3$  of the following:
  - Erythrocyte sedimentation rate >20 mm/hr
  - C-reactive protein elevated
  - Leukocytosis >8000/mm<sup>3</sup>
  - Left shift with >70% neutrophils
4. Excellent response to treatment with systemic corticosteroids

\*Both major criteria and two minor criteria are needed for diagnosis.

onstrating neutrophils, karyorrhexis, and marked papillary dermal edema. Minor criteria include associated symptoms or conditions, laboratory findings, and response to therapy. Patients should have both major criteria and two of the four minor criteria for diagnosis (Box 7-1). EM can be distinguished by its typical morphology and histologic features. Clinically, both diseases can have red plaques, and central vesiculation can occur. True target lesions are not seen in Sweet syndrome. Bowel bypass syndrome has skin lesions that, on histologic examination, are identical to those of Sweet syndrome; fever and arthritis also accompany bowel bypass syndrome. Although it is easy to distinguish classic EN from Sweet syndrome, these two conditions share many features. Both occur most often in young adult women and frequently follow URIs. Both may be associated with pregnancy, underlying malignancy, and IBD. In both, fever and arthritis may occur, along with leukocytosis with neutrophilia. There are many reports of simultaneous or sequential EN and Sweet syndrome in the same patient. Leukemia-associated Sweet syndrome may overlap with pyoderma gangrenosum. A search for an underlying cause should be undertaken, especially in persons over age 50 and those with anemia, thrombocytopenia, or lesions that are bullous or necrotic. The standard treatment is systemic corticosteroids, with approximately 1 mg/kg/day of oral prednisone. This will result in resolution of fever and skin lesions within days. Sulfapyridine, potassium iodide, colchicine, dapsone, doxycycline, clofazimine, cyclosporine, and nonsteroidal anti-inflammatory drugs (NSAIDs) may be helpful in chronic or refractory disease. Medication should be continued for several weeks to prevent relapse.

### Neutrophilic dermatosis of the dorsal hands

Lesions of neutrophilic dermatosis of the dorsal hands present as edematous, pustular, or ulcerative nodules or plaques localized to the dorsal hands (Fig. 7-12). Histologically, papillary dermal edema and a nodular and diffuse neutrophilic infiltrate with karyorrhexis are noted. As in Sweet syndrome, leukocytoclastic vasculitis may be present focally. Individual flares



**Fig. 7-12** Neutrophilic dermatosis of the dorsal hands.

respond to prednisone and dapsone, but recurrences are common. As the clinical appearance, tendency to relapse, response to treatment, and histologic features overlap with those of Sweet syndrome and pyoderma gangrenosum, this condition illustrates the close relationship of the various neutrophilic dermatoses. Neutrophilic dermatosis of the dorsal hands is best considered a localized variant of Sweet syndrome.

### Neutrophilic eccrine hidradenitis

Neutrophilic eccrine hidradenitis is discussed in Chapter 33.

### Marshall syndrome

The rare Marshall syndrome is characterized by skin lesions resembling Sweet syndrome, which are followed by acquired cutis laxa. Cases occur primarily in children. Small red papules expand to urticarial, targetoid plaques with hypopigmented centers. Histologic evaluation of the skin lesions usually shows a neutrophilic dermatosis virtually identical to Sweet syndrome. Occasionally, an eosinophilic infiltrate will be found. The lesions resolve with destruction of the elastic tissue at the site, producing soft, wrinkled, skin-colored protuberant plaques that can be pushed into the dermis. Elastic tissue in other organs may also be affected, especially the heart and lungs. Some cases may be associated with  $\alpha$ 1-antitrypsin deficiency.

**Chan MP, et al:** Subcutaneous Sweet syndrome in the setting of myeloid disorders. *J Am Acad Dermatol* 2013; 68:1006–1015.

**Cohen PR:** Sweet's syndrome—a comprehensive review of an acute febrile neutrophilic dermatosis. *Orphanet J Rare Dis* 2007; 2:34.

**Cook-Norris RH, et al:** Neutrophilic dermatosis of the hands: an under-recognized hematological condition that may result in unnecessary surgery. *Am J Hematol* 2009; 84:60.

**Del Pozo J, et al:** Neutrophilic dermatosis of the hands: presentation of eight cases and review of the literature. *J Dermatol* 2007; 34:243–247.

**Gottlieb CC, et al:** Ocular involvement in acute febrile neutrophilic dermatosis (Sweet syndrome): new cases and review of the literature. *Surv Ophthalmol* 2008; 53:219–226.

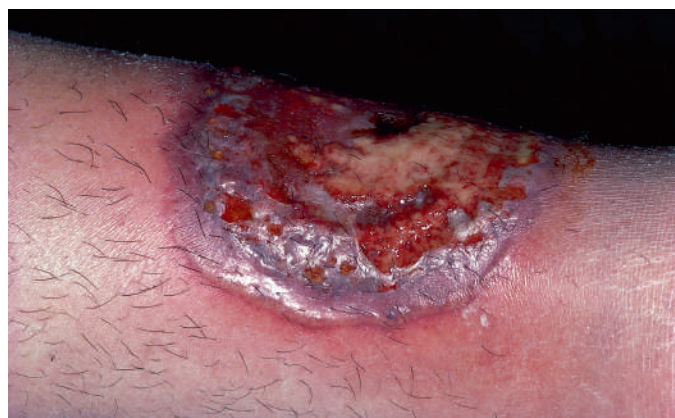**Gray PEA, et al:** Neonatal Sweet syndrome. *Pediatrics* 2012; 129:e1353–e1359.

**Haider M, et al:** Acquired cutis laxa type II (Marshall syndrome) in and 18-month-old child. *Pediatr Dermatol* 2010; 27:89–91.

**Kaminska EC, et al:** Giant cellulitis-like Sweet syndrome in the setting of autoimmune disease. *J Am Acad Dermatol* 2014; 71:e94–95.

**Kroshinsky D, et al:** Necrotizing Sweet syndrome. *J Am Acad Dermatol* 2012; 67:945–954.

**Neoh CY, et al:** Sweet's syndrome: a spectrum of unusual clinical presentations and associations. *Br J Dermatol* 2007; 156:480–485.



**Fig. 7-13** Enlarging ulcer of pyoderma gangrenosum.

**Ratzinger G, et al:** Acute febrile neutrophilic dermatosis: a histopathologic study of 31 cases with review of literature. *Am J Dermatopathol* 2007; 29:125–133.

**Requena L, et al:** Histiocytoid Sweet syndrome: a dermal infiltration of immature neutrophilic granulocytes. *Arch Dermatol* 2005; 141:837.

**Surovy AM, et al:** Giant cellulitis-like Sweet syndrome. *JAMA Dermatol* 2013; 149:79–83.

**Tabanlıoğlu D, et al:** Sweet's syndrome and erythema nodosum: a companionship or a spectrum? A case report with review of the literature. *Int J Dermatol* 2010; 49:62–66.

**Thompson DF, et al:** Drug-induced Sweet's syndrome. *Ann Pharmacother* 2007; 41:802–811.

**Uihlein LC, et al:** Sweet's syndrome in children. *Pediatr Dermatol* 2012; 29:38–44.

**Vignon-Pennamen MD, et al:** Chronic recurrent lymphocytic Sweet syndrome as a predictive marker of myelodysplasia. *Arch Dermatol* 2006; 142:1170–1176.

**Wallach D, et al:** From acute febrile neutrophilic dermatosis to neutrophilic disease: forty years of clinical research. *J Am Acad Dermatol* 2006; 55:1066–1071.

### Pyoderma gangrenosum

Brunsting is credited with the initial clinical description of pyoderma gangrenosum (PG) in 1930. Classic PG begins as an inflammatory pustule with a surrounding halo that enlarges and begins to ulcerate. A primary lesion may not always be seen, and a substantial proportion of lesions appear at sites of trauma (pathergy). Satellite violaceous papules may appear just peripheral to the border of the ulcer and break down to fuse with the central ulcer. Fully developed lesions are painful ulcers with sharply marginated, undermined, blue to purple borders (Fig. 7-13). PG most typically occurs in adults age 40–60 and presents on the lower extremities and trunk. Lesions heal with characteristic thin, atrophic scars. Pustular PG consists of pustules that generally do not progress to ulcerative lesions. This form of PG is most often seen in IBD patients. Pyostomatitis vegetans and subcorneal pustular dermatosis are two other pustular neutrophilic diseases reported in association with PG, sometimes in patients with IgA gammopathy.

Bullous PG is more superficial and less destructive than the ulcerative type. These lesions have considerable overlap with what has been called “bullous Sweet syndrome” and are usually seen in patients with leukemia or polycythemia vera. These red plaques become dusky and develop superficial erosions. They are not deep, usually are not undermined, and are less painful than ulcerative PG.

Vegetative PG is the least aggressive form of PG. Lesions present as chronic, superficial, cribriform ulcerations, usually of the trunk, that enlarge slowly and have elevated borders



and clean bases. The lesions are rarely painful, generally respond to relatively conservative treatments, and are usually not associated with underlying systemic disease. PG is rare in children. More than 40% of these patients have underlying IBD, and another 18% have leukemia. An association of childhood acquired immunodeficiency syndrome (AIDS) and PG has been documented. About one quarter of children with PG have no underlying disease. Genital and head/neck lesions can occur in children.

Overall, approximately 50% of patients with PG have an associated disease, most often IBD—both Crohn's disease and ulcerative colitis. Between 1.5% and 5% of patients with IBD develop PG. The two diseases may flare together or run an independent course. Surgical removal of the diseased intestine may lead to complete remission of PG, or lesions may persist or first appear after removal of the affected bowel. Most patients with PG and IBD have colon involvement. The ulcerative and pustular types of PG are most frequently seen in patients with associated IBD. A peristomal variant occurs near such sites as painful erosions with violaceous, undermined borders.

Many other associated conditions have been reported. Leukemia (chiefly acute or chronic myelogenous leukemia), myeloma, monoclonal gammopathy (chiefly IgA), polycythemia vera, myeloid metaplasia, chronic active hepatitis, hepatitis C, human immunodeficiency virus (HIV) infection, systemic lupus erythematosus, pregnancy, PAPA syndrome (see Autoinflammatory syndromes next), and Takayasu arteritis are among the many diseases seen in conjunction with PG. More than one third of PG patients have arthritis, usually an asymmetric, seronegative, monoarticular arthritis of the large joints. Monoclonal gammopathy, usually IgA, is found in 10% of PG patients. Children with congenital deficiency of leukocyte adhesion glycoproteins (LAD) develop PG-like lesions. There are increasing reports of PG occurring in hidradenitis suppurativa patients.

Early biopsies of PG show a suppurative folliculitis. The affected follicle is often ruptured. As the lesions evolve, they demonstrate suppurative inflammation in the dermis and subcutaneous fat. Massive dermal edema and epidermal neutrophilic abscesses are present at the violaceous, undermined border. These features are not diagnostic, and infectious causes must be excluded.

The clinical picture of PG, in the classic ulcerative form, is characteristic. Because no diagnostic serologic or histologic features exist, however, PG remains a diagnosis of exclusion. Multiple infections, including mycobacteria, deep fungi, gummatous syphilis, synergistic gangrene, and amebiasis, must be excluded with cultures and special studies. Other disorders frequently misdiagnosed as PG include vascular occlusive or chronic venous disease, vasculitis, cancer, and exogenous tissue injury, including factitial disease.

Pyoderma gangrenosum may be misdiagnosed as a spider bite if there is only a solitary lesion on an extremity. Spider bites tend to evolve more rapidly and may be associated with other systemic symptoms or findings, such as disseminated intravascular coagulation. Various forms of cutaneous large-vessel vasculitis may produce similar clinical lesions and are excluded by histologic evaluation and ancillary studies, such as ANCA and antiphospholipid antibody tests. Thus, the initial workup of the patient includes studies necessary to ensure that the proper diagnosis is made, as well as to investigate possible associated diseases.

The most difficult diagnosis to exclude is factitial disease. The clinical lesions may be strikingly similar, evolving from small papulopustules to form ulcerations that do not heal. Histologic evaluation will often simply show suppurative dermatitis, since the injected or applied caustic substance may not

be identifiable (urine, disinfectants, drain cleaner). Even the most experienced clinician may misdiagnose factitial disease as PG.

Management of PG is challenging. The initial step is to classify the lesion by type. Underlying conditions should be sought, even if no symptoms are found. Treatment of underlying IBD may lead to improvement. In general, the vegetative type will respond to topical or local measures. The treatment is determined by the severity of disease and rate of progression. In rapidly progressive cases, aggressive early management may reduce morbidity.

Local treatment includes both proper wound care and medication to reduce inflammation; compresses or whirlpool baths are followed by the use of ointment or hydrophilic occlusive dressings. In solitary lesions or slowly progressive cases, application of potent topical corticosteroids, intralesional steroid injections, or tacrolimus may be beneficial, although pathergy may be seen at sites of injection. The absorption of tacrolimus in large or multiple wounds may lead to systemic blood levels. Systemic corticosteroids can be extremely effective, with initial doses in the range of 1 mg/kg. If control is achieved, the dose may be rapidly tapered. If corticosteroid reduction is not possible, a steroid-sparing agent may be added. Patients unresponsive to oral corticosteroids may benefit from pulse methylprednisolone, 1 mg/kg for 3–5 days, followed by 40–60 mg of prednisone tapering as the lesions heal.

In general, when the disease is aggressive and corticosteroid therapy does not lead to rapid resolution, an immunosuppressive agent is added. Cyclosporine and infliximab result in a rapid response and are the immunosuppressives of choice for PG in such situations. The lesions often respond dramatically to these agents, including many that have not responded adequately to corticosteroids. Initial doses of cyclosporine of approximately 5 mg/kg/day are effective in most cases. In treatment failures, the dose can be raised to 10 mg/kg/day. The response is independent of any underlying cause. Infliximab is given as intravenous infusions in doses of about 5 mg/kg at weeks 0, 2, and 6 and then every 8 weeks. In very aggressive, rapidly progressive cases, consideration should be given to starting cyclosporine or infliximab treatment early to gain control of the disease. Other useful systemic agents include etanercept, adalimumab, alefacept, ustekinumab, mycophenolate mofetil (MMF), granulocyte apheresis intravenous immune globulin (IVIg), alkylating agents, and thalidomide.

Sulfapyridine, sulfasalazine, salicylazosulfapyridine, dapsone, methotrexate, azathioprine, and minocycline generally are less helpful and may be useful adjuncts.

Once the inflammatory component is controlled, the ulceration(s) will need to heal, so proper wound care is essential. Epidermal allografts or autografts may be applied soon after PG is controlled. Pathergy is rarely noted at the donor site when patients are receiving adequate immunosuppressive therapy.

**Ahronowitz I, et al:** Etiology and management of pyoderma gangrenosum. *Am J Clin Dermatol* 2012; 13:191–211.

**Binus AM, et al:** Pyoderma gangrenosum. *Br J Dermatol* 2011; 165:1244–1250.

**Cozzani E, et al:** Pyoderma gangrenosum. *G Ital Dermatol Venereol* 2014; 149:587–600.

**Callen JP, et al:** Pyoderma gangrenosum: an update. *Rheum Dis Clin North Am* 2007; 33:787–802.

**Hsiao JL, et al:** Hidradenitis suppurativa and concomitant pyoderma gangrenosum. *Arch Dermatol* 2010; 146:1265–1270.

**Li J, et al:** Treatment of pyoderma gangrenosum with mycophenolate mofetil as a steroid-sparing agent. *J Am Acad Dermatol* 2013; 69:565–569.

**Kikuchi N, et al:** Pyoderma gangrenosum following surgical procedures. *Int J Dermatol* 2010; 49:346–348.

**Miller J, et al:** Pyoderma gangrenosum: a review and update on new therapies. *J Am Acad Dermatol* 2010; 62:646–654.

**Rudocco E, et al:** Pyoderma gangrenosum. *J Eur Acad Dermatol Venereol* 2009; 23:1008–1017.

**Turner RB, et al:** Rapid resolution of pyoderma gangrenosum after treatment with intravenous cyclosporine. *J Am Acad Dermatol* 2010; 63:e72–e74.

## AUTOINFLAMMATORY SYNDROMES

The autoinflammatory syndromes are a group of disorders characterized by bouts of systemic inflammation related to dysregulation of the innate immune system. These conditions present most often in children with episodes that often include fever and symptoms related to the skin, gastrointestinal (GI) tract, eyes, chest, musculoskeletal system, and central nervous system (CNS). Inflammatory skin lesions are often prominent manifestations, especially acne, PG, and erysipelas-like and urticaria-like lesions. Although more than half of these are autosomal dominant disorders inherited in patients with a family history of these syndromes or of deafness, amyloidosis or renal failure should be sought. In addition, many acquired syndromes have features of autoinflammatory disease, such as Schnitzler syndrome (see under Urticaria later) as well as Behçet syndrome and periodic fever, aphthous stomatitis, pharyngitis, and adenitis (PFAPA) syndrome (see Chapter 34).

Familial Mediterranean fever (FMF) is the most common inherited autoinflammatory syndrome and was the first recognized. FMF is an autosomal recessive syndrome characterized by recurrent attacks of 12–72 h of fever and a monoarthritis with overlying erysipelas-like erythema. Peritonitis, pleuritis, and vasculitis, including Henoch-Schönlein purpura, may also occur in these patients, who usually present before the teenage years. FMF is caused by mutation in the *MEFV* gene, which produces pyrin, but approximately 30% of patients with a similar phenotype lack a detectable gene defect. Colchicine is the mainstay of treatment for FMF patients and can reduce the risk of associated amyloidosis. Riloncept, an interleukin-1 (IL-1)-soluble fusion protein receptor, may help those resistant to colchicine.

The PAPA syndrome is an autosomal dominant disorder characterized by pyogenic sterile arthritis, PG, and acne and is caused by proline-serine-threonine-phosphatase-interacting protein 1 (*PSTPIP1*) or CD2-binding protein 1 (*CD2BP1*) gene mutations. *PSTPIP1/CD2BP1*, a tyrosine-phosphorylated protein involved in cytoskeletal organization, interacts with pyrin, the gene product important in the pathogenesis of FMF.

The TNF receptor-associated periodic syndrome (TRAPS) is similar to FMF but shows autosomal dominant inheritance, longer attacks, and a lack of response to colchicine. TRAPS is associated with mutations in the *TNFRSF1A* gene, resulting in decreased serum-soluble TNF receptor. TRAPS and deficiency of the IL-36 receptor antagonist (DITRA) are the most common autoinflammatory syndromes with onset in adulthood. Febrile episodes of 1–3 weeks are accompanied by periorbital edema and a painful, distally migrating erythematous or urticarial-like plaques. NSAIDs or prednisone can treat the acute episodes; anti-TNF receptor antagonists or anakinra may prevent bouts. An autosomal recessive DITRA leads to episodes of generalized pustular psoriasis, nail dystrophy, and geographic tongue. Treatment is as for pustular psoriasis. Deficiency of the IL-1 receptor antagonist (DIRA) also manifests as a pustular eruption, although onset is in the neonatal period. Bone lesions, oral ulcers, and other findings are all reversed dramatically by anakinra.

The recessively inherited hyper-IgD syndrome (HIDS), associated with mutations in the mevalonate kinase (*MVK*) gene, leading to *MVK* deficiency, also presents with hereditary periodic fever. Two thirds of patients manifest various

morbilliform, urticarial eruptions. Oral and genital ulcerations may occur.

There are three autosomal dominant cryopyrin-associated periodic syndromes. Familial cold autoinflammatory syndrome is characterized by fever, cold urticaria, conjunctivitis, and arthralgia elicited by generalized exposure to cold. Patients with Muckle-Wells syndrome manifest most often in adolescence with acute febrile inflammatory episodes comprising abdominal pain, arthritis, urticaria, hearing loss, and multiorgan amyloidosis. Neonatal-onset multisystem inflammatory disease is characterized by fever, chronic meningitis, uveitis, sensorineural hearing loss, urticarial rash, and a deforming arthritis. Patients may also have dysmorphic facial appearance, clubbing of the fingers, mild mental retardation, and papilledema. All three of these conditions have mutations in the *NLRP3* gene. A second familial cold autoinflammatory syndrome is similar in its clinical findings but is related to mutations in the *NALP12* gene.

A newly described autoinflammatory disease, CANDLE is characterized by chronic, atypical, neutrophilic dermatosis with lipodystrophy and elevated temperature. Patients present in the newborn period with fever, swollen purplish red eyelids, red and purplish papules and plaques of the trunk, neck, and extremities, and lipodystrophy of the face, along with other systemic findings. The skin biopsy reveals atypical cells of the myelocytic lineage in the dermis. It is caused by a mutation in the *PSMB8* gene.

Blau syndrome is an autosomal dominant disease with arthritis, uveitis, granulomatous inflammation, and camptodactyly. It is associated with mutations in the *NOD2* gene, which also predisposes to Crohn's disease and early-onset sarcoidosis. Another acquired syndrome, consisting of dermatitis, fever, arthritis, and serositis, without autoantibody formation and with the occurrence of a *NOD2* mutation, has been described in 22 patients. The dermatitis was polymorphic, but many patients had papules and plaques on the face, trunk, and extremities. Biopsies were also variable. The authors named it NAID; the only effective therapy was prednisone or topical corticosteroids. Lastly, two patients with urticarial lesions that burned rather than itched had accompanying fever, or arthralgias, and/or laboratory markers of systemic inflammation, such as a high erythrocyte sedimentation rate (ESR) or C-reactive protein (CRP). They did not respond to antihistamines but did respond to anakinra, suggesting their urticarial lesions were mediated by IL-1 and fit into this acquired autoinflammatory disease spectrum. This disease was dubbed "neutrophilic urticaria with systemic inflammation," which is differentiated from prior reports of neutrophilic urticaria.

**Belani H, et al:** Neutrophilic urticaria with systemic inflammation. *JAMA Dermatol* 2013; 149:453–458.

**Braun-Falco M, et al:** Skin manifestations in autoinflammatory syndromes. *J Dtsch Dermatol Ges* 2011; 9:232–245.

**Farasat S, et al:** Autoinflammatory diseases: clinical and genetic advances. *Arch Dermatol* 2008; 144:392–402.

**Gattorno M et al:** Treatment of autoinflammatory syndromes. *Curr Opin Pediatr* 2010; 22:771–778.

**Hashkes PH, et al:** Autoinflammatory syndromes. *Pediatr Clin North Am* 2012; 59:447–470.

**Kluk J, et al:** Chronic atypical neutrophilic dermatosis with lipodystrophy and elevated temperature syndrome. *Br J Dermatol* 2014; 170:215–217.

**Rigant D, et al:** Monogenic autoinflammatory syndromes at a dermatological level. *Arch Dermatol Res* 2011; 303:375–380.

**Ross JB, et al:** Use of anakinra (Kineret) in the treatment of familial cold autoinflammatory syndrome with a 16-month follow-up. *J Cutan Med Surg* 2008; 12:8–16.

**Shinkai K, et al:** Cryopyrin-associated periodic syndromes and autoinflammation. *Clin Exp Dermatol* 2008; 33:1–9.



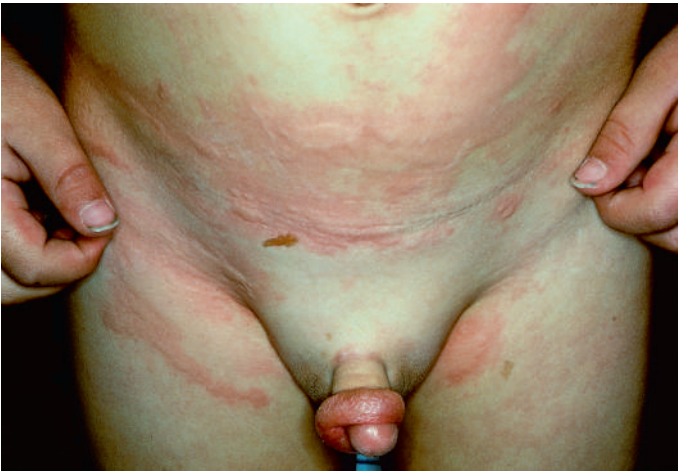

Fig. 7-14 Acute urticaria.

Tufekci O, et al: CANDLE syndrome. *J Pediatr Hematol Oncol* 2014; July 17.

Yao Q, et al: Dermatitis as a characteristic phenotype of a new autoinflammatory disease associated with *NOD2* mutations. *J Am Acad Dermatol* 2013; 68:624–631.

## URTICARIA (HIVES)

Urticaria is a vascular reaction of the skin characterized by the appearance of wheals (Fig. 7-14), generally surrounded by a red halo or flare and associated with severe itching, stinging, or pricking sensations. These wheals are caused by localized edema. Clearing of the central region may occur, and lesions may coalesce, producing an annular or polycyclic pattern. Subcutaneous swellings (angioedema) may or may not accompany the wheals. When angioedema is not present, and fever, malaise, and joint/bone pain coexist, diagnostic consideration of an autoinflammatory condition is necessary, including many inherited syndromes, as previously described.

Schnitzler syndrome is another diagnosis to consider. This rare acquired disorder is a combination of chronic nonpruritic urticaria, fever of unknown origin, disabling bone pain, hyperostosis, increased ESR, and monoclonal IgM gammopathy. Pruritus is not generally a feature. The age of onset ranges from 29–77 years, without gender predilection. The skin biopsy most often reveals a predominant neutrophilic perivascular and interstitial infiltrate, although about one third of cases are mononuclear. In some patients, the IgM gammopathy progresses to neoplasia, especially Waldenström macroglobulinemia. Effective therapy for patients with Schnitzler syndrome has included anakinra, rituximab, tocilizumab, rilonacept, and canakinumab.

## Classification

Acute urticaria evolves over days to weeks, producing evanescent wheals that individually, rarely last more than 12 hours, with complete resolution of the urticaria within 6 weeks of onset. Daily episodes of urticaria and/or angioedema lasting more than 6 weeks are designated chronic urticaria. Chronic urticaria predominantly affects adults and is twice as common in women as in men.

More than 50% of cases of chronic urticaria are of unknown causation and are called chronic spontaneous urticaria. Physical stimuli may produce urticarial reactions and represent up to 35% of cases of chronic urticaria. The physical

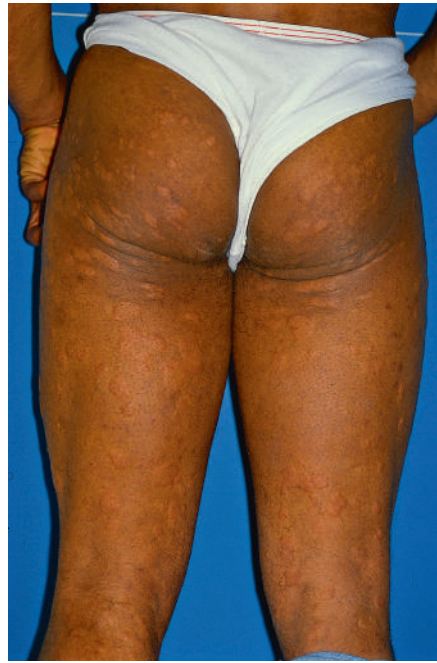

Fig. 7-15 Urticaria secondary to hepatitis B.

urticarias include dermatographic, cold, heat, cholinergic, aquagenic, solar, vibratory, galvanic, and exercise-induced cases. Physical urticaria usually coexists with chronic spontaneous urticaria.

## Etiologic factors

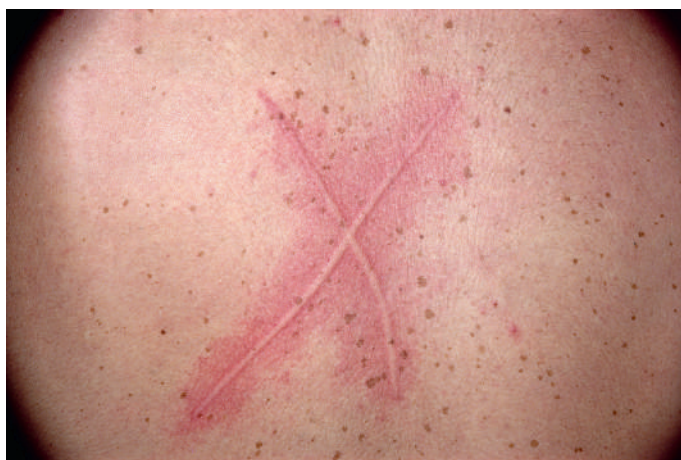In general, infections, ingestants, inhalants, and injections should be considered as possible underlying causes of urticaria. In acute spontaneous cases, URIs and viral infections are the most common etiologies in children. Drugs (e.g., NSAIDs, antibiotics) and foods are other common causes in both adults and children. Clues suggesting physical urticaria as both a primary cause and as a coexistent second etiology should be sought historically.

In addition to streptococcal and viral URIs, the possibility of localized infection in the tonsils, a tooth, sinuses, gallbladder, prostate, bladder, or kidney should be considered. Treatment with antibiotics for *Helicobacter pylori* has led to resolution of the urticaria. Chronic viral infections, such as hepatitis B and C, may cause urticaria (Fig. 7-15). Acute infectious mononucleosis and psittacosis may also be triggering conditions. Helminths may cause urticaria and include *Ascaris*, *Ankylostoma*, *Strongyloides*, *Filaria*, *Echinococcus*, *Schistosoma*, *Trichinella*, *Toxocara*, and liver fluke.

The most allergenic foods are chocolate, shellfish, nuts, peanuts, tomatoes, strawberries, melons, pork, cheese, garlic, onions, eggs, milk, and spices. Food allergens that may cross-react with latex include chestnuts, bananas, passion fruit, avocado, and kiwi. Food additives and preservatives are also implicated in some cases. Natural food additives that may be implicated in urticaria include yeasts, salicylates, citric acid, egg, and fish albumin. Synthetic additives include azo dyes, benzoic acid derivatives, sulfite, and penicillin.

Inhalants that have caused urticaria include grass pollens, house dust mites, feathers, formaldehyde, acrolein (produced when frying with lard or by smoking cigarettes containing glycerin), castor bean or soybean dust, cooked lentils, cottonseed, animal dander, cosmetics, aerosols, pyrethrum, and molds.

Injections of both prescribed and recreational drugs, as well as vaccinations, should be considered in the historical data obtained.



**Fig. 7-16** Dermatographism.

Nonimmunologic mechanisms can produce mast cell degranulation. Common triggers include opiates, polymyxin B, tubocurarine, radiocontrast dye, aspirin, other NSAIDs, tartrazine, and benzoate.

### Physical (inducible) urticarias

Specific physical stimuli cause up to 35% of all urticarias and occur most frequently in persons age 17–40. The most common form is dermatographism, followed by cholinergic urticaria and cold urticaria. Several forms of physical urticaria may occur in the same patient. Physical urticarias, particularly dermatographic, delayed pressure, cholinergic, and cold urticarias, are frequently found in patients with chronic idiopathic urticaria. Provocative testing off of all treatment at sites not recently affected by urticaria is a useful diagnostic maneuver, and repeated testing with treatment may help gauge therapeutic response. Treatment may be avoidance of the provocative stimulus and often, antihistamines, as discussed later for chronic urticaria.

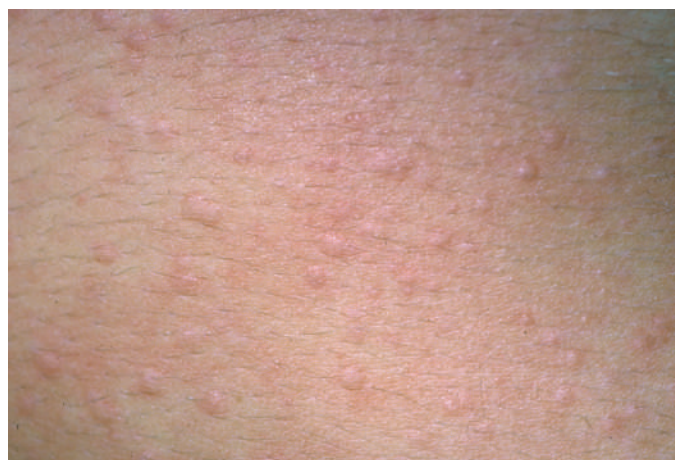#### Dermatographism

Dermatographism is a sharply localized edema or wheal, with a surrounding erythematous flare occurring in seconds to minutes after the skin has been stroked (Fig. 7-16). It affects 2–5% of the population. Dermatographism may arise spontaneously after drug-induced urticaria and persist for months. It has also been reported to be associated with the use of the H<sub>2</sub> blocker famotidine. It may occur in hypothyroidism and hyperthyroidism, infectious diseases, diabetes mellitus, and during onset of menopause. It may be a cause of localized or generalized pruritus. Antihistamines suppress this reaction. The addition of an H<sub>2</sub> antihistamine may be of benefit.

#### Cholinergic urticaria

Cholinergic urticaria, produced by the action of acetylcholine on the mast cell, is characterized by minute, highly pruritic, punctate wheals or papules 1–3 mm in diameter and surrounded by a distinct erythematous flare (Fig. 7-17). These lesions occur primarily on the trunk and face. The condition spares the palms and soles. Lesions persist for 30–90 min and are followed by a refractory period of up to 24 h. Bronchospasm may occur. Familial cases have been reported.

The lesions may be induced in the susceptible patient by increasing the core body temperature with either exercise or a warm bath to raise core temperature by 0.7–1.0°C (1.2–1.8°F). In some cases, an attack may be aborted by rapid cooling of the body, as by taking a cold shower. Cholinergic dermatographism is noted in some patients.



**Fig. 7-17** Cholinergic urticaria, small papules with surrounding large, erythematous flare.

Antihistamines suppress this reaction. The addition of an H<sub>2</sub> antihistamine may be of benefit. Antihistamines have been combined with other agents, such as montelukast and propranolol. Attenuated androgens, such as danazol, may be of benefit in patients with refractory cholinergic urticaria.

#### Adrenergic urticaria

Adrenergic urticaria may occur alone or may coexist with cholinergic urticaria. Bouts of urticaria are mediated by norepinephrine. The eruption consists of small (1–5 mm) red macules and papules with a pale halo, appearing within 10–15 min of emotional upset, coffee, or chocolate. Serum catecholamines, norepinephrine, dopamine, and epinephrine may rise greatly during attacks, whereas histamine and serotonin levels remain normal. Propranolol, 10 mg four times daily, is effective; atenolol has been ineffective. A provocative test consists of intradermal administration of 3–10 ng of norepinephrine.

#### Cold urticaria

Exposure to cold may result in edema and whealing on the exposed areas, usually the face and hands. The urticaria does not develop during chilling, but on rewarming. This heterogeneous group of disorders is classified into primary (essential), secondary, and familial cold urticaria.

Primary (essential) cold urticaria is not associated with underlying systemic diseases or cold-reactive proteins. Symptoms are usually localized to the areas of cold exposure, although respiratory and cardiovascular compromise may develop. Fatal shock may occur when these persons go swimming in cold water or take cold showers. This type of cold urticaria usually begins in adulthood. It usually yields a positive ice cube test result. Antihistamines suppress this reaction. The addition of an H<sub>2</sub> antihistamine may be of benefit. Desensitization by repeated, increased exposures to cold has been effective in some cases. In many patients, cold urticaria will resolve after months, although about 50% of patients have symptomatic disease for years. As a provocative test, a plastic-wrapped ice cube is applied to the skin for 5–20 min. If no wheal develops, the area should be fanned for an additional 10 min. The use of a combination of cold and moving air is, in some cases, more effective in reproducing lesions than cold alone. The provocative test is not performed if secondary cold urticaria is being considered.

Secondary cold urticaria is associated with an underlying systemic disease, such as cryoglobulinemia. Other associations include cryofibrinogenemia, multiple myeloma, secondary



syphilis, hepatitis, and infectious mononucleosis. Patients may have headache, hypotension, laryngeal edema, and syncope. An ice cube test is not recommended because it can precipitate vascular occlusion and tissue ischemia.

Familial cold autoinflammatory syndrome is grouped with the other autoinflammatory syndromes discussed earlier. The lesions produce a burning sensation rather than itching. They may have cyanotic centers and surrounding white halos and last for 24–48 h. They may be accompanied by fever, chills, headache, arthralgia, myalgia, and abdominal pain. A prominent feature is leukocytosis, which is the first observable response to cold. Familial cold urticaria will yield a negative ice cube test result.

### Heat urticaria

Within 5 min of the skin being exposed to heat above 43°C (109.4°F), the exposed area begins to burn and sting, then becomes red, swollen, and indurated. This rare type of urticaria may also be generalized and is accompanied by cramps, weakness, flushing, salivation, and collapse. Heat desensitization may be effective. As a provocative test, apply a heated cylinder, 45°C (113°F), to a small area of skin on the upper body for 5 min.

### Solar urticaria

Solar urticaria appears soon after unshielded skin is exposed to sunlight. It is classified by the wavelengths of light that precipitate the reaction. Visible light can trigger solar urticaria, and sunscreens may not prevent it. Angioedema may occasionally occur. Solar urticaria may be a manifestation of porphyria, leukocytoclastic vasculitis, and Churg-Strauss syndrome. Treatment is sun avoidance, sunscreens, antihistamines, repetitive phototherapy, and PUVA. (Solar urticaria is reviewed more extensively in Chapter 3.)

### Pressure urticaria (delayed pressure urticaria)

Pressure urticaria is characterized by the development of swelling with pain that usually occurs 3–12 h after local pressure has been applied. It occurs most frequently on the feet after walking and on the buttocks after sitting. It is unique in that there may be a latent period of as long as 24 h before lesions develop. Arthralgias, fever, chills, and leukocytosis can occur. The pain and swelling last for 8–24 h. Pressure urticaria may be seen in combination with other physical urticarias. As a provocative test, a 15-lb weight is suspended from the shoulder by a 3-cm strap for 20 min and the area inspected after 4–8 h. Antihistamines may suppress this reaction. The addition of an H<sub>2</sub> antihistamine or montelukast may be of benefit. Systemic corticosteroids are often therapeutic but are generally unsuitable for long-term use. Tranexamic acid, high-dose IVIG, or an anti-TNF biologic may be effective in patients refractory to other treatment.

### Exercise-induced urticaria

Although both cholinergic urticaria and exercise urticaria are precipitated by exercise, they are distinct entities. Raising the body temperature passively will not induce exercise urticaria, and the lesions of exercise urticaria are larger than the tiny wheals of cholinergic urticaria (Fig. 7-18). Urticarial lesions appear 5–30 min after the start of exercise. Anaphylaxis may be associated. Atopy is common in these patients, and some have documented food allergy. Some patients only have such a reaction after eating celery before exercise. Avoiding these allergens may improve symptoms.

Antihistamines suppress the exercise-induced reaction. The addition of an H<sub>2</sub> antihistamine may be of benefit. Self-injectable epinephrine kits are recommended for rare patients with episodes of anaphylaxis manifesting with respiratory

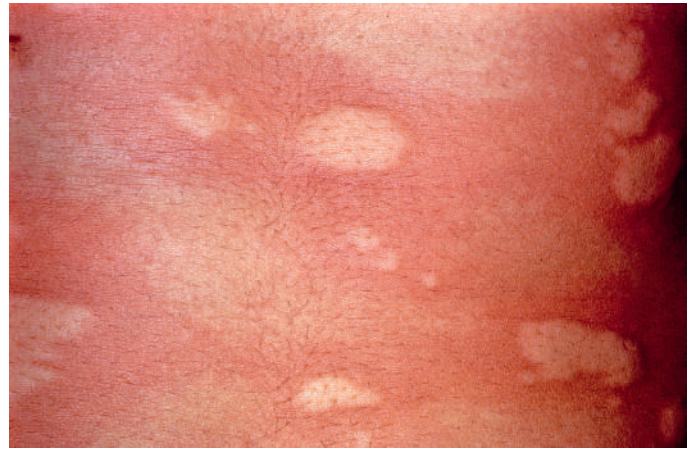

Fig. 7-18 Exercise-induced urticaria.

symptoms. Exercise is a provocative test but may require priming with the identified food allergens.

### Vibratory angioedema

Vibratory angioedema, a form of physical urticaria, may be an inherited autosomal dominant trait or may be acquired after prolonged occupational vibration exposure. Dermatographism, pressure urticaria, and cholinergic urticaria may occur in affected patients. Plasma histamine levels are elevated during attacks. The appearance of the angioedema is usually not delayed. The treatment is antihistamines. As a provocative test, laboratory vortex vibration is applied to the forearm for 5 min.

### Aquagenic urticaria

The rare aquagenic urticaria is elicited by water or seawater at any temperature. Pruritic wheals develop immediately or within minutes at the sites of contact of the skin with water, irrespective of temperature or source, and clear within 30–60 min. Sweat, saliva, and even tears can precipitate a reaction. Aquagenic urticaria may be familial in some cases or associated with atopy or cholinergic urticaria. Systemic symptoms have been reported, including wheezing, dysphagia, and respiratory distress. The pathogenesis is unknown but may be associated with water-soluble antigens that diffuse into the dermis and cause histamine release from sensitized mast cells.

Whealing may be prevented by pretreatment of the skin with petrolatum. Antihistamines suppress this reaction. The addition of an H<sub>2</sub> antihistamine may be of benefit. PUVA appears to prevent skin lesions but may not prevent the symptoms of pruritus. The provocative test is to apply water compresses, 35°C (95°F), to the skin of the upper body for 30 min.

### Galvanic urticaria

Galvanic urticaria has been described after exposure to a galvanic device used to treat hyperhidrosis. The relationship of this condition to other forms of physical urticaria remains to be established.

## Pathogenesis/histopathology

Capillary permeability results from the increased release of histamine from the mast cells situated around the capillaries. The mast cell is the primary effector cell in urticarial reactions. Other mediators include IL-1 in the autoinflammatory conditions discussed earlier and bradykinin in angioedema associated with angiotensin-converting enzyme (ACE) inhibitors and in the hereditary and acquired angioedema syndromes discussed shortly.

About one third of patients with chronic idiopathic urticaria have circulating functional histamine-releasing IgG autoantibodies that bind to the high-affinity IgE receptor. Some patients have IgG that does not bind the IgE receptor, but rather causes mast cell degranulation. Thyroid autoantibodies are often present in women with chronic idiopathic urticaria, but clinically relevant thyroid disease is seldom present. Even in those with thyroid disease, treatment of the thyroid disorder generally does not affect the course of the urticaria.

The histopathologic changes in acute urticaria include mild dermal edema and margination of neutrophils within postcapillary venules. Later, neutrophils migrate through the vessel wall into the interstitium, and eosinophils and lymphocytes are also noted in the infiltrate. Karyorrhexis and fibrin deposition within vessel walls are absent, helping to differentiate urticaria from vasculitis.

A subset of patients have urticarial lesions with biopsies that show a preponderance of neutrophils; this has been called neutrophilic urticaria. Patients with such histology may present with acute urticaria, chronic urticaria, or physical urticaria. Because neutrophils are typically present in urticaria in general, it is likely that cases of neutrophilic urticaria simply represent urticaria with upregulation of some mast cell-derived cytokines.

## Diagnosis

Diagnosis of urticaria and angioedema is usually made on clinical grounds. Lesions in a fixed location for more than 24 h suggest urticarial vasculitis, the urticarial phase of an immunobullous eruption, EM, granuloma annulare, sarcoidosis, or cutaneous T-cell lymphoma. If individual wheals last for longer than 24 h, a skin biopsy should be performed.

## Clinical evaluation

Laboratory evaluation should be driven by associated signs and symptoms. Random tests in the absence of a suggestive history or physical findings are rarely cost-effective and are not recommended. A practical evaluation is limited to a detailed history and a thorough physical examination. Questions to ask include a history of the timing, duration, and frequency of wheals and any associated angioedema; possible association with foods, drugs, febrile illness, occupation, travel, or hobbies; and a family or personal history of atopy, or potential physical causes. A history of aspirin or NSAID ingestion should trigger their avoidance because these drugs may not only cause urticaria, but also aggravate preexisting disease.

If the urticaria is acute and recurrent, food allergy may be suggested by a food diary. Serum radioallergen sorbent tests (RASTs) can be used to detect specific IgE, and elimination diets can occasionally be beneficial in some patients. One such diet permits inclusion of lamb, beef, rice, potatoes, carrots, string beans, peas, squash, applesauce, tapioca, preserves (pear, peach, cherry), rye crackers, butter, sugar, tea without milk or lemon, and coffee without cream. This diet is followed for 3 weeks. If urticaria does not occur, suspected foods are added one by one and reactions observed. This diet is best tried only after a careful history.

Angioedema in the absence of urticaria may be related to hereditary angioedema or an ACE inhibitor. C1 esterase deficiency does not cause hives, only angioedema, and measurement of C4 is indicated. If C4 is low, an evaluation of C1 esterase inhibitor is appropriate.

In patients with chronic spontaneous urticaria, a directed history and physical examination should elicit signs or

symptoms of thyroid disease, connective tissue disease, changes in bowel or bladder habits, vaginal or urethral discharge, other localized infection, jaundice, or risk factors for hepatitis or Lyme disease. Positive findings should prompt appropriate screening tests. Although sinus x-ray films, a panoramic dental film, streptococcal throat culture, abdominal ultrasonography, and urinalysis with urine culture (with prostate massage in men) may reveal the most common occult infections triggering urticaria, positive cases are almost always associated with some signs or symptoms suggestive of the diagnosis. For example, if the patient has a history of sinus difficulties, particularly if there is palpable tenderness over the maxillary or ethmoid sinuses, radiologic sinus evaluation is recommended. Lastly, a routine complete blood count (CBC) with differential, liver function testing, and ESR or CRP level may be done to help decide if infection may be an causal factor. In areas where parasitic disease is common, eosinophilia is an inexpensive screening test with a fair yield.

If the history suggests a physical urticaria, the appropriate challenge test should be used to confirm the diagnosis. Lesions that burn rather than itch, resolve with purpura, or last longer than 24 h should prompt a biopsy to exclude urticarial vasculitis. If lesions burn rather than itch, and if patients have associated fever, arthralgias, or other evidence of systemic inflammation and antihistamines are not effective, an acquired autoinflammatory syndrome should be considered, and a trial of anakinra may be useful.

## Treatment

### Acute urticaria

The mainstay of treatment of acute urticaria is administration of antihistamines. In adults, nonsedating antihistamines pose a lower risk of psychomotor impairment. If the cause of the acute episode can be identified, avoiding that trigger should be stressed. In patients with acute urticaria that does not respond to antihistamines, systemic corticosteroids are generally effective. Less rebound is seen with a 3-week tapered course of systemic corticosteroid therapy than with shorter courses.

For severe reactions, including anaphylaxis, respiratory and cardiovascular support is essential. A 0.3-mL dose of a 1:1000 dilution of epinephrine is administered every 10–20 min as needed. In young children, a half-strength dilution is used. In rapidly progressive cases, intubation or tracheotomy may be required. Adjunctive therapy includes intramuscular antihistamines (25–50 mg hydroxyzine or diphenhydramine every 6 h as needed) and systemic corticosteroids (250 mg hydrocortisone or 50 mg methylprednisolone intravenously every 6 h for 2–4 doses).

### Chronic urticaria

In chronic spontaneous urticaria, the goal of therapy is to alleviate symptoms. The mainstay of treatment is administration of antihistamines. These should be taken on a daily basis; antihistamines should *not* be prescribed to be taken only as needed. Second-generation H1 antihistamines (cetirizine, desloratadine, fexofenadine, acrivastine, ebastine, mizolastine) are large, lipophilic molecules with charged side chains that bind extensively to proteins, preventing the drugs from crossing the blood-brain barrier; thus they produce less sedation in most patients than the third-generation antihistamine levocetirizine. Long-acting forms are available, and the long half-life of these antihistamines and reduced sedation result in improved compliance and efficacy. First-line treatment is the



use of a second- or third-generation nonsedating antihistamine such as cetirizine, in standard dosage. If after 2 weeks the symptoms persist, the dosage should be increased up to four times the standard dosage, usually adding a second pill in the evening, then a third in the AM and a fourth in the AM to a maximum of 4 pills per day, two in the morning and two in the evening. If this is ineffective, another nonsedating antihistamine may be tried. Some experience indicates that fexofenadine is less likely to work at higher-than-standard dosages, so this is not escalated if there is no response at standard dosage. Cetirizine and some of the other second-generation antihistamines can cause drowsiness in some individuals, particularly in higher doses or when combined with other antihistamines.

Although some add an H<sub>2</sub> blocker such as ranitidine as well, evidence is conflicting on whether this is an effective strategy. Ranitidine should not be used alone for treatment of urticaria because it may interfere with feedback inhibition of histamine release. Also, doxepin, a tricyclic antidepressant with potent H<sub>1</sub> antihistaminic activity, may be useful, but evidence is weak. Doxepin is frequently dosed at bedtime, so much of the drowsiness and dry mouth are gone by morning. The same is true for first-generation antihistamines; if any is added to the previous second-generation strategy, it should only be used at night.

If it is necessary to consider other therapies, the following guidance is offered. Cyclosporine and prednisone are often effective but the potential for side effects limit their clinical utility. Also, because the prognosis is that at least 20% of patients, and up to 50% in some studies, will continue to have chronic spontaneous urticaria after 5 years, the role of these two agents is limited. Dapsone, colchicine, and sulfasalazine may be most useful if the biopsy shows a preponderance of neutrophils, and they may be added to antihistamine treatment if some response to the latter has been obtained. Hydroxychloroquine, leukotriene receptor antagonists such as montelukast, and even phototherapy may have some benefit in individual patients. Also, their more satisfactory safety profile makes these therapies worth considering as alternatives to medications such as MMF, omalizumab, and methotrexate, which show more evidence of efficacy. Data are accumulating that omalizumab, a recombinant humanized monoclonal antibody that binds to free IgE, is effective in many patients with chronic spontaneous urticaria in doses of 150–300 mg every 4 weeks.

Topical corticosteroids, topical antihistamines, and topical anesthetics have no role in the management of chronic urticaria. For local treatment, tepid or cold tub baths or showers may be freely advocated if cold is not a trigger. Topical camphor and menthol can provide symptomatic relief. Sarna lotion contains menthol, phenol, and camphor.

In about one third of patients with chronic idiopathic urticaria, autoantibodies bind to high-affinity IgE receptors. Unfortunately, testing for this condition is not well standardized, has false-positive results, and is impractical. If chronic spontaneous urticaria is nonresponsive to the previous approach, patients may require more aggressive management, including chronic immunosuppressive therapy, plasmapheresis, or IVIG.

## Angioedema

Angioedema is an acute, evanescent, circumscribed edema that usually affects the most distensible tissues, such as the eyelids, lips (Fig. 7-19), earlobes, and external genitalia, or the mucous membranes of the mouth, tongue, or larynx. The swelling occurs in the deep dermis or in the subcutaneous

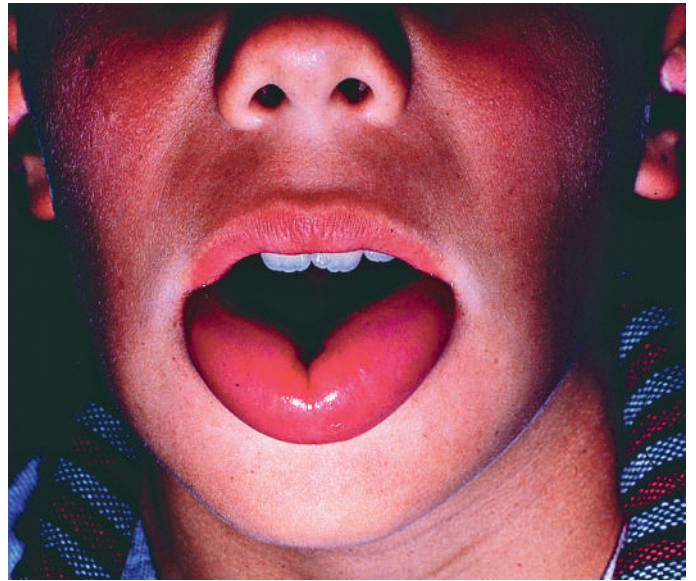


Fig. 7-19 Angioedema of the lips.

tissues and as a rule is only slightly tender, with the overlying skin unaltered, edematous, or rarely ecchymotic. There may be a diffuse swelling on the hands, forearms, feet, and ankles. Frequently, the condition begins during the night and is found on awakening. Angioedema may target the GI and respiratory tracts, resulting in abdominal pain, coryza, asthma, and respiratory problems. Respiratory tract involvement can produce airway obstruction. Anaphylaxis and hypotension may also occur.

There are two distinct subsets of angioedema. The first is considered a deep form of urticaria and may be observed as solitary or multiple sites of angioedema alone or in combination with urticaria. The action of histamine creates vasomotor lability, and pruritus may be a significant feature. The second subgroup, angioedema associated with C1 esterase inhibitor deficiency, or that related to ACE inhibitors, is not associated with hives, or pruritus. Symptoms of pain predominate, and this deficiency is mediated by bradykinin.

## Hereditary angioedema

Also known as Quincke edema, hereditary angioedema (HAE) was originally described and named by Osler in 1888. HAE characteristically appears before age 20. Sudden attacks of angioedema occur as frequently as every 2 weeks throughout the patient's life, lasting for 2–5 days. Swelling is typically asymmetric, and urticaria or itching does not occur. The presentation may overlap with that of the autoinflammatory syndromes.

Patients may experience local swelling in subcutaneous tissues (face, hands, arms, legs, genitals, buttocks); abdominal organs (stomach, intestines, bladder), mimicking surgical emergencies; and the upper airway (larynx), which can be life threatening. There is minimal response to antihistamines, epinephrine, or corticosteroids. Mortality is high, often caused by laryngeal edema. GI edema is manifested by nausea, vomiting, and severe colic, and it may simulate appendicitis so closely that appendectomy is mistakenly performed. The factors that trigger attacks are minor trauma, surgery, sudden changes of temperature, or sudden emotional stress.

Inherited in an autosomal dominant fashion, HAE is estimated to occur in 1 in 50,000–150,000 persons. There are three phenotypic forms of the disease. Type I is characterized by low antigenic and functional plasma levels of a normal C1 esterase

inhibitor protein (C1-EI). Type II is characterized by the presence of normal or elevated antigenic levels of a dysfunctional protein. Type III demonstrates normal C1-EI function and normal complement. The majority of patients are women. Criteria for type III include a long history of recurrent attacks of skin swelling, abdominal pain, or upper airway obstruction; absence of urticaria; familial occurrence; normal C1-EI and C4 concentrations; and failure of treatment with antihistamines, corticosteroids, and C1-EI concentrate.

The screening test of choice for types I and II is a C4 level. C4 will be low (<40% of normal) as a result of continuous activation and consumption. In addition to depressed C4 levels, patients with types I and II also have low C1, C1q, and C2 levels. If the clinical picture and screening tests are positive, a titer of C1-EI should be ordered. C1-EI is a labile protein, and sample decay is common. A low C1-EI in the presence of normal C4 levels should raise the suspicion of sample decay, rather than true HAE.

The treatment of choice for acute HAE types I and II is plasma-derived or recombinant C1 inhibitor or contact system modulators such as ecallantide or icatibant. Short-term prophylaxis (e.g., for patients undergoing dental care, endoscopy, or intubation for surgery) can be obtained from C1 inhibitors or danazol, an attenuated androgen. Estrogens in oral contraceptives, in contrast, may precipitate attacks. Attenuated androgens, C1 inhibitors, and in some cases antifibrinolytics are useful for long-term prophylaxis. Patients with type III do not respond to C1-EI replacement but may respond to danazol.

### Acquired C1 esterase inhibitor deficiency

Some patients present with symptoms indistinguishable from HAE, but with onset after the fourth decade of life and lacking a family history. As in HAE, there is no associated pruritus or urticaria. This condition is subdivided into acquired angioedema I and II and an idiopathic form. Acquired angioedema I is a rare disorder associated with lymphoproliferative disease. These associations include lymphomas (usually B cell), chronic lymphocytic leukemia, monoclonal gammopathy, myeloma, myelofibrosis, Waldenström macroglobulinemia, and breast carcinoma. Some patients have detectable autoantibodies to C1-EI. Worsening of stable HAE has been the presenting sign of lymphoma. Part of the management of this condition is to treat the causative associated condition.

Acquired angioedema II is an extremely rare disease defined by the presence of autoantibodies to C1-EI. It is important to realize that autoantibodies directed against C1-EI may also be found in acquired angioedema I, particularly in patients with B-cell lymphomas, so the diagnosis of acquired angioedema II is made only when no such underlying condition exists.

The pathophysiology of acquired angioedema I is unknown but may be related to increased catabolism of C1-EI; many patients with the disorder have been shown to produce normal amounts of C1-EI. In acquired angioedema II, hepatocytes and monocytes are able to synthesize normal C1-EI; however, a subpopulation of B cells secretes autoantibodies to the functional region of the C1-EI molecule.

Management of acute attacks in acquired angioedema I is directed toward replacement of C1-EI with plasma-derived or recombinant C1 inhibitor. Some patients develop progressive resistance to the infusions. Antifibrinolytic agents, such as aminocaproic acid or tranexamic acid, may be beneficial and are more effective than antiandrogen therapy. Synthetic androgens, such as danazol, may be helpful in angioedema I. However, androgens are ineffective in treating patients with acquired angioedema II, stressing the importance of identifying these patients. Immunosuppressive therapy has been shown to be effective in the treatment of acquired angioedema

II by decreasing autoantibody production. Systemic corticosteroids may be temporarily effective.

### Episodic angioedema with eosinophilia

Episodic angioedema or isolated facial edema may occur with fever, weight gain, eosinophilia, and elevated eosinophil major basic protein (Gleich syndrome). The disorder is not uncommon, and there is no underlying disease. Increased levels of IL-5 have been documented during periods of attack. Treatment options include administration of systemic steroidal medications, imatinib, antihistamines, and IVIG.

### Anaphylaxis

Anaphylaxis is an acute and often life-threatening immunologic reaction, frequently heralded by scalp pruritus, diffuse erythema, urticaria, or angioedema. Bronchospasm, laryngeal edema, hyperperistalsis, hypotension, and cardiac arrhythmia may occur. Antibiotics (especially penicillins), other drugs, and radiographic contrast agents are the most common causes of serious anaphylactic reactions. Hymenoptera stings are the next most frequent cause, followed by ingestion of crustaceans and other food allergens. Atopic dermatitis is frequently associated with anaphylaxis, regardless of origin. Causative agents can be identified in up to two thirds of cases, and recurrent attacks are the rule. Exercise-induced anaphylaxis often depends on priming by prior ingestion of a specific food, or food in general, and aspirin may be an additional exacerbating factor.

**Bernstein JA, et al:** The diagnosis and management of acute and chronic urticaria. *J Allergy Clin Immunol* 2014; 133:1270–1277.

**Bianca-Lopez N, et al:** Value of the clinical history in the diagnosis of urticaria/angioedema induced by NSAIDs with cross-intolerance. *Clin Exp Allergy* 2012; 43:85–91.

**Hogan SR, et al:** Adrenergic urticaria. *J Am Acad Dermatol* 2014; 70:763–766.

**Kaplan AP:** Biologic agents in the treatment of urticaria. *Curr Allergy Asthma Rep* 2012; 12:288–291.

**Khakoo G, et al:** Clinical features and natural history of physical urticaria in children. *Pediatr Allergy Immunol* 2008; 19:363–366.

**Konstantinou GN, et al:** EAACI taskforce position paper: evidence for autoimmune urticaria and proposal for defining diagnostic criteria. *Allergy* 2013; 68:27–36.

**Lacy KE, et al:** Galvanic urticaria. *Clin Exp Dermatol* 2006; 31:739–740.

**Magerl M, et al:** The definition and diagnostic testing of physical and cholinergic urticarias: EAACI/GA2/EDF/UNEV consensus panel recommendations. *Allergy* 2009; 64:1715–1721.

**Marrouche N, et al:** Childhood urticaria. *Curr Opin Allergy Clin Immunol* 2012; 12:485–490.

**Maurer M, et al:** Revisions to the international guideline on the diagnosis and therapy of chronic urticaria. *J Dtsch Dermatol Ges* 2013; Aug 19. [Epub ahead of print.]

**Metz M, et al:** Omalizumab in chronic urticaria. *Curr Opin Allergy Clin Immunol* 2012; 12:406–411.

**Morita E, et al:** Food-dependent exercise-induced anaphylaxis. *J Dermatol Sci* 2007; 47:109–117.

**Parish LC:** Hereditary angioedema. *J Am Acad Dermatol* 2011; 65:843–850.

**Patruno C, et al:** Vibratory angioedema in a saxophonist. *Dermatitis* 2009; 20:346–347.

**Pressler A, et al:** Failure of omalizumab and successful control with ketotifen in a patient with vibratory angio-oedema. *Clin Exp Dermatol* 2013; 38:151–153.

**Sanchez-Borges M, et al:** Diagnosis and treatment of urticaria and angioedema. *WAO J* 2012; 5:125–147.

**Scranton SE, et al:** Episodic angioedema with eosinophilia: successful treatment with imatinib. *Ann Allergy Asthma Immunol* 2008; 100:172–174.



**Sokumbi O, et al:** Clinical and histopathologic review of Schnitzler syndrome. *J Am Acad Dermatol* 2012; 67:1289–1295.

**Tarbox JA, et al:** Utility of routine laboratory testing in management of chronic urticaria/angioedema. *Ann Allergy Asthma Immunol* 2011; 107:239–243.

**Tinazzi E, et al:** Schnitzler syndrome, and autoimmune autoinflammatory syndrome. *Autoimmunity Rev* 2011; 10:404–409.

**Trojan TD, et al:** Calcineurin inhibitors in chronic urticaria. *Curr Opin Allergy Clin Immunol* 2012; 12:412–420.

**Vanderschueren S, et al:** Canakinumab in Schnitzler syndrome. *Semin Arthritis Rheum* 2013; 42:413–416.

**Xu Y-Y, et al:** Update on treatment of hereditary angioedema. *Clin Exp All* 2013; 43:395–406.

**Yao Q, et al:** Dermatitis as a characteristic phenotype of a new autoinflammatory disease associated with *NOD2* mutations. *J Am Acad Dermatol* 2013; 68:624–631.

**Zuberbier T, et al:** EAACI/GA2LEN/EDF/WAQ guideline: definition, classification and diagnosis of urticaria. *Allergy* 2009; 64:1417–1426.

**Zuberbier T, et al:** EAACI/GA2LEN/EDF/WAQ guideline: management of urticaria. *Allergy* 2009; 64:1427–1443.



Bonus images for this chapter can be found online at

[expertconsult.inkling.com](http://expertconsult.inkling.com)

**eFig. 7-1** Erythema multiforme, target lesions.

**eFig. 7-2** Erythema multiforme, target lesions.

**eFig. 7-3** Erythema multiforme involving the lips.

**eFig. 7-4** Mucosal lesions of erythema multiforme.

**eFig. 7-5** Erythema annulare centrifugum.

**eFig. 7-6** Sweet syndrome, intensely edematous lesion.

**eFig. 7-7** Sweet syndrome, erythema lesions.

**eFig. 7-8** Enlarging ulcer of pyoderma gangrenosum.

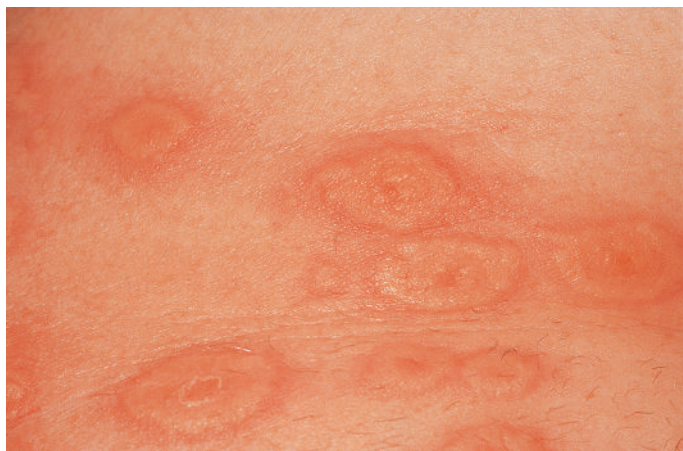**eFig. 7-9** Cold urticaria after ice cube applied to site for 3 min.

**eFig. 7-10** Annular and polycyclic urticaria.

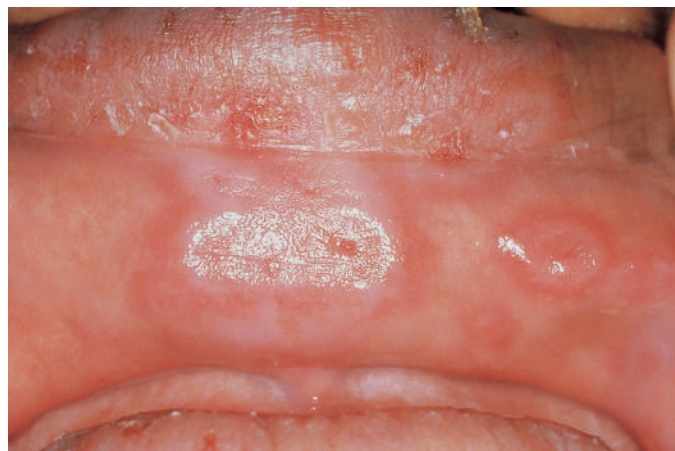**eFig. 7-11** Dermatographism.

**eFig. 7-12** Cholinergic urticaria, small papules with surrounding large, erythematous flare.

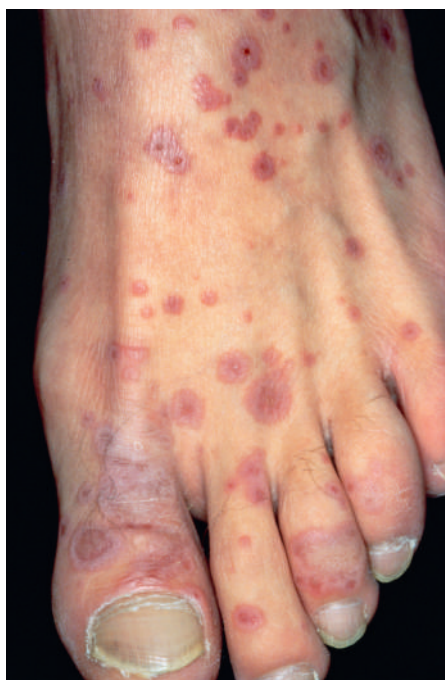**eFig. 7-13** Cold urticaria after ice cube applied to site for 3 min.



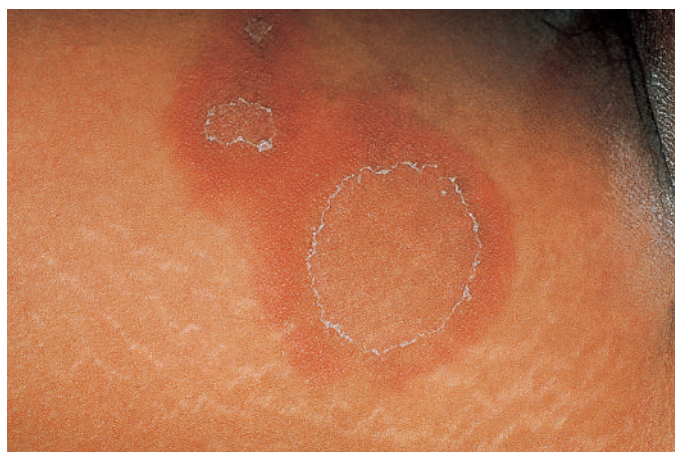**eFig. 7-1** Erythema multiforme, target lesions.



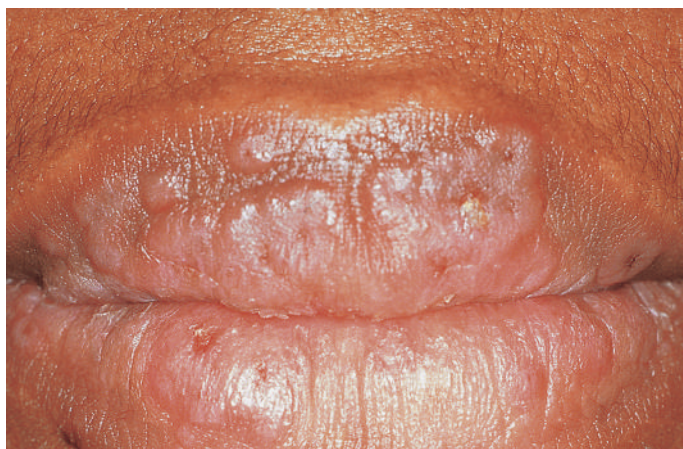**eFig. 7-4** Mucosal lesions of erythema multiforme.



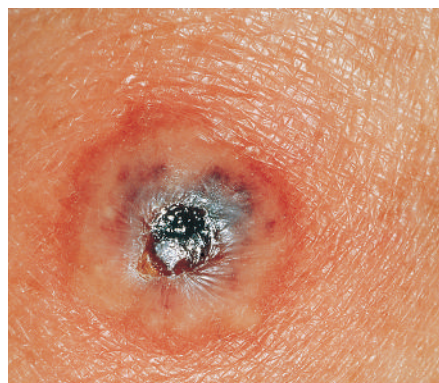
**eFig. 7-2** Erythema multiforme, target lesions.



**eFig. 7-5** Erythema annulare centrifugum.

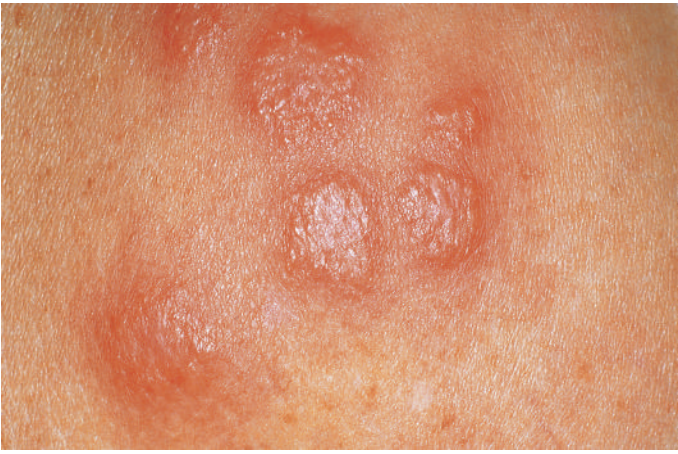

**eFig. 7-3** Erythema multiforme involving the lips.

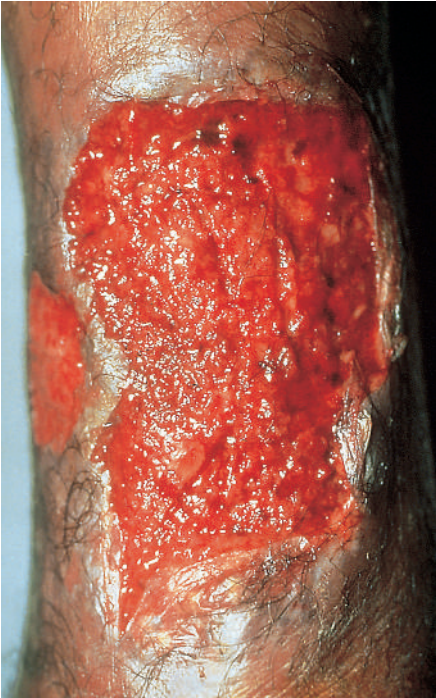

**eFig. 7-6** Sweet syndrome, intensely edematous lesion.

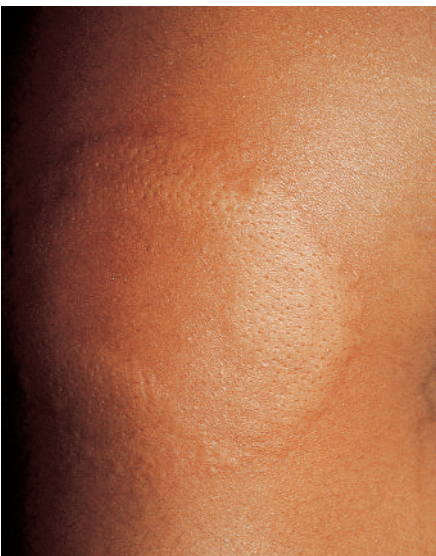



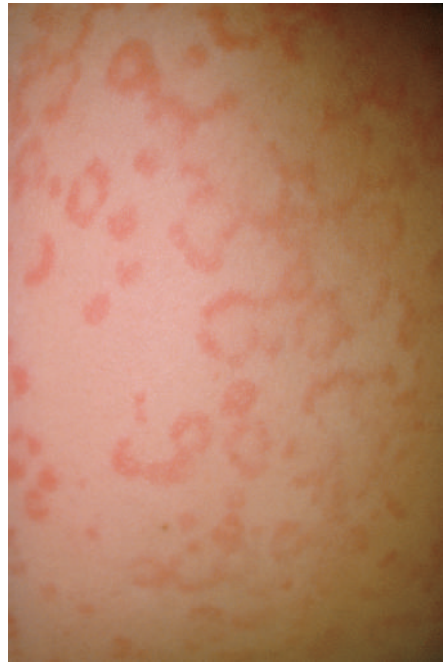
**eFig. 7-7** Sweet syndrome, erythema lesions.



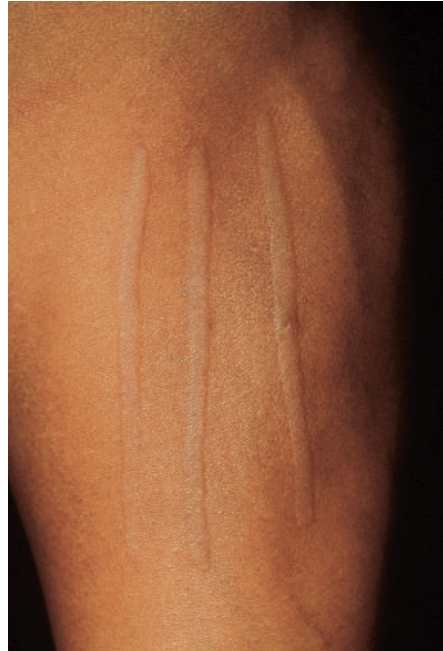**eFig. 7-8** Enlarging ulcer of pyoderma gangrenosum.



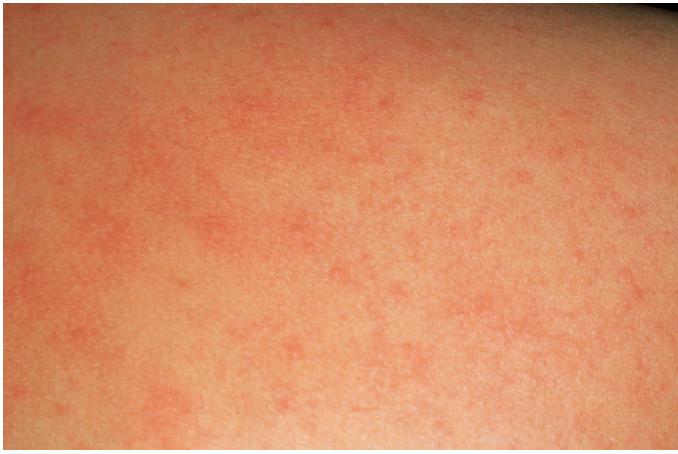**eFig. 7-9** Cold urticaria after ice cube applied to site for 3 min.



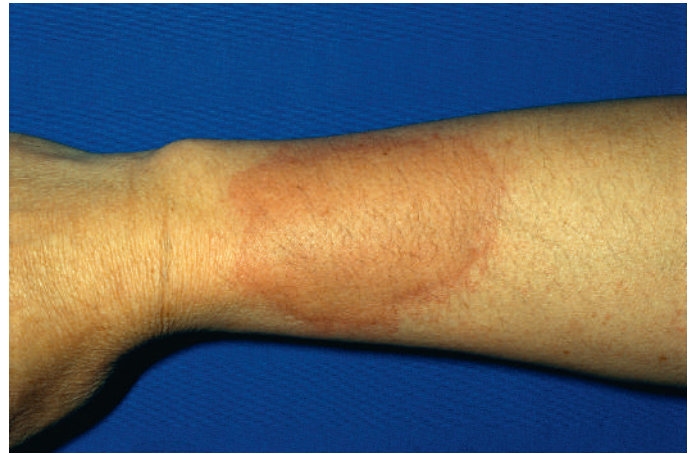**eFig. 7-10** Annular and polycyclic urticaria.



**eFig. 7-11** Dermatographism.



**eFig. 7-12** Cholinergic urticaria, small papules with surrounding large, erythematous flare.



**eFig. 7-13** Cold urticaria after ice cube applied to site for 3 min.





## Connective Tissue Diseases

Lupus erythematosus (LE), dermatomyositis, scleroderma, rheumatoid arthritis, Sjögren syndrome, eosinophilic fasciitis, relapsing polychondritis, and related disorders are classified as connective tissue diseases. Basic to all these is a complex array of autoimmune responses that target or affect collagen or ground substance.

### LUPUS ERYTHEMATOSUS

Lupus may manifest as a systemic disease or in purely cutaneous forms. Cutaneous manifestations of LE are classified as in [Box 8-1](#).

#### Chronic cutaneous lupus erythematosus

##### Discoid lupus erythematosus

Discoid lupus erythematosus (DLE) generally occurs in young adults, with women outnumbering men 2:1. Lesions begin as dull-red macules or indurated plaques that develop an adherent scale, then evolve with atrophy, scarring, and pigment changes ([Fig. 8-1](#)). In darker-skinned individuals, lesions typically demonstrate areas of both hyperpigmentation and depigmentation. In lighter-skinned patients, the plaques may appear gray or have minimal pigment alteration. The hyperkeratosis characteristically extends into patulous follicles, producing carpet tack like spines on the undersurface of the scale.

Very small lesions of DLE may be mistaken for actinic keratoses. Some early discoid lesions are superficial, resembling seborrheic dermatitis. Others may be brightly erythematous or even urticarial.

##### Localized discoid lupus erythematosus

Discoid lesions are usually localized above the neck. Favored sites are the scalp, bridge of the nose, malar areas, lower lip, and ears ([Fig. 8-2](#)). The concha of the ear and external canal are frequently involved. Some patients present with periorbital edema and erythema. On the scalp, most lesions begin as erythematous patches or plaques that evolve into white, often depressed, hairless patches. Perifollicular erythema and the presence of easily extractable anagen hairs are signs of active disease and are helpful in monitoring the response to therapy. Scarred areas may appear completely smooth or may demonstrate dilated follicular openings in the few remaining follicles. Itching and tenderness are common and may rarely be severe. On the lips, lesions may be gray or red and hyperkeratotic. They may be eroded and are usually surrounded by a narrow, red inflammatory zone ([Fig. 8-3](#)). In one study, 24% of DLE patients had mucosal involvement of the mouth, nose, eye, or vulva. Rarely, aggressive squamous cell carcinoma arises in long-standing lesions of DLE.

##### Generalized discoid lupus erythematosus

Generalized DLE is less common than localized DLE. All degrees of severity are encountered. Most often, the thorax and upper extremities are affected as well as the head and neck ([Fig. 8-4](#)). The scalp may become quite bald with striking patterns of hyperpigmentation and depigmentation. Diffuse scarring may involve the face and upper extremities. Laboratory abnormalities, such as an elevated erythrocyte sedimentation rate (ESR), elevated antinuclear antibodies (ANAs), single-stranded (ss) DNA antibodies, and leukopenia, are more common with this form of LE than with localized DLE.

The course of DLE is variable, but 95% of cases confined to the skin at the outset will remain so. Progression from purely cutaneous DLE to systemic lupus erythematosus (SLE) occurs infrequently. However, patients with SLE frequently have discoid lesions. These patients generally have systemic involvement early in the course of their disease, rather than evolving from chronic cutaneous LE to SLE. Fever and arthralgia are common in patients with SLE and discoid lesions. In patients with systemic symptoms, abnormal laboratory tests, such as elevation of ANAs, antibodies to double-stranded (ds) DNA and C1q, leukopenia, hematuria, and proteinuria, help to identify patients with SLE and suggest a prognosis.

##### Childhood discoid lupus erythematosus

Among children with DLE, a low frequency of photosensitivity and a higher rate of association with SLE have been noted. In most other respects, the clinical presentation and course are similar to those in adults.

##### Histology

The epidermis may demonstrate effacement of the rete ridge pattern or irregular acanthosis. Compact hyperkeratosis without parakeratosis is characteristic, and follicular plugging is typically prominent. Hydropic degeneration of the basal layer of the epidermis and follicular epithelium results in pigmentary incontinence. A patchy perivascular and periadnexal lymphoid inflammatory infiltrate occurs in the superficial and deep dermis. The infiltrate characteristically surrounds vessels, follicles, and the eccrine coil. Increased mucin is often present and may be visible as deposition of a blue to amphophilic substance between collagen bundles, or merely as a widening of the space between the bundles. Thickening of the basement membrane zone (BMZ) may be prominent.

The histology varies with the stage of the lesion. Acute lesions show only patchy lymphoid inflammation and vacuolar interface dermatitis. Lesions established for several months begin to show hyperkeratosis, BMZ thickening, and dermal mucin. Chronic, inactive lesions show atrophy, with postinflammatory pigmentation and scarring throughout the dermis. At this stage, the inflammatory infiltrate is sparse to

### Box 8-1 Classification of cutaneous manifestations of lupus erythematosus (LE)

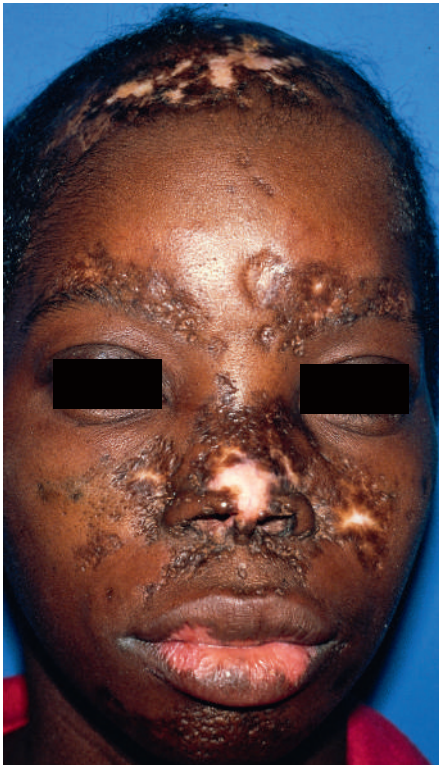#### I. Chronic cutaneous LE

- A. Discoid LE
  1. Localized
  2. Disseminated
- B. Verrucous (hypertrophic) LE (Behçet): usually acral and often lichenoid
- C. Lupus erythematosus–lichen planus overlap
- D. Chilblain LE
- E. Tumid lupus
- F. Lupus panniculitis (LE profundus)
  1. With no other involvement
  2. With overlying discoid LE
  3. With systemic LE

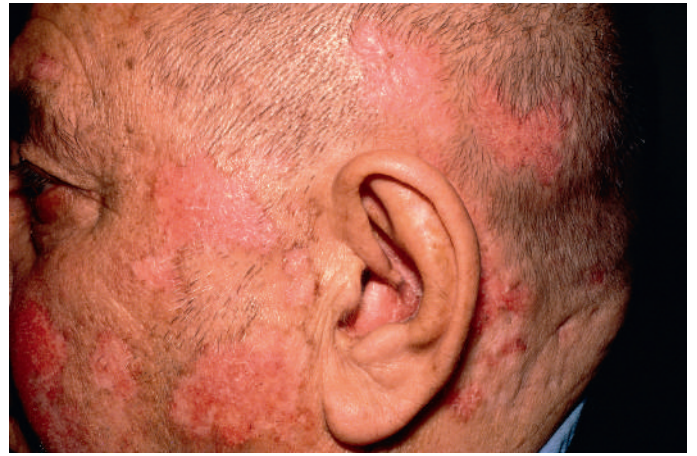#### II. Subacute cutaneous LE

- A. Papulosquamous
- B. Annular
- C. Syndromes commonly exhibiting similar morphology
  1. Neonatal LE
  2. Complement deficiency syndromes
  3. Drug-induced

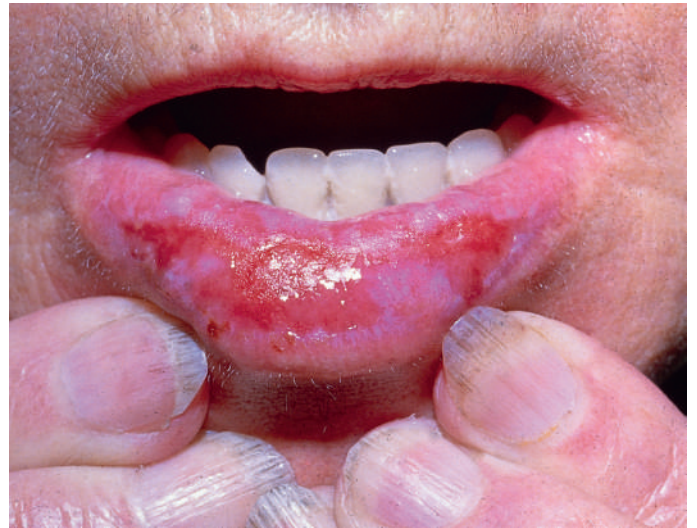#### III. Acute cutaneous LE: localized or generalized erythema or bullae, generally associated with SLE



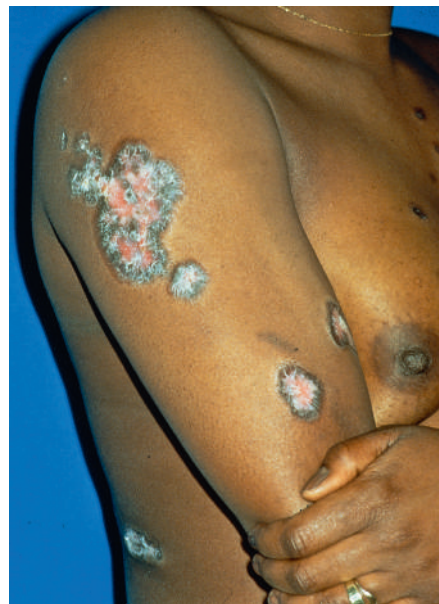**Fig. 8-1** Extensive scarring from discoid lupus erythematosus.



**Fig. 8-2** Discoid lupus erythematosus.



**Fig. 8-3** Lupus of the lip.



**Fig. 8-4** Generalized discoid lupus erythematosus.

absent. Pilosebaceous units, except for “orphaned” arrector muscles, are destroyed. At this stage, the dermis appears fibrotic, but an elastic tissue stain can still distinguish the diffuse dermal scar of lupus from the focal, wedge-shaped, superficial scars of lichen planopilaris (LPP) or folliculitis decalvans. Direct immunofluorescence (DIF) testing of lesional skin is positive in more than 75% of cases, provided the lesions have been active for at least several months and usually demonstrate strong, continuous granular deposition

of immunoglobulin and complement located at the dermo-epidermal junction (DEJ). Transporting specimens in normal saline may result in a higher yield than freezing or Michel’s transport medium, if the specimen can reach the laboratory within 24 hours.



### Differential diagnosis

Discoid LE must often be differentiated from seborrheic dermatitis, rosacea, lupus vulgaris, sarcoidosis, drug eruptions, actinic keratosis, Bowen's disease, lichen planus (LP), tertiary syphilis, and polymorphous light eruption (PMLE). Seborrheic dermatitis does not show atrophy, alopecia, or dilated follicles and has greasy, yellowish scale without follicular plugs. Acral, lip, and scalp lesions of chronic cutaneous LE may demonstrate lichenoid dermatitis histologically. In these cases, the presence of continuous granular immunoglobulin in addition to cytooid bodies is a helpful distinguishing feature.

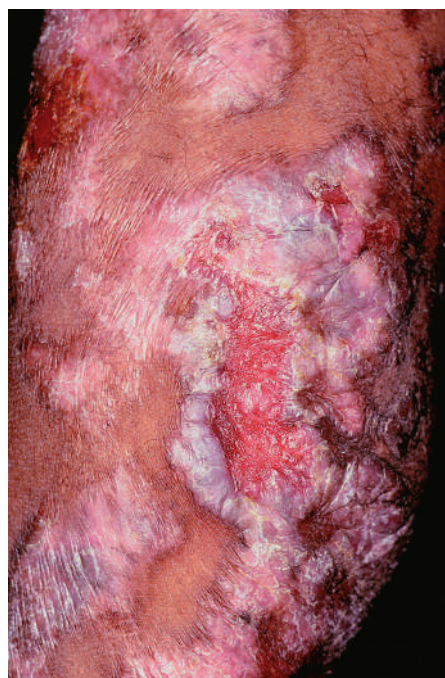In rosacea, atrophy does not occur, and pustules are almost always found. Apple-jelly nodules (granulomas) are seen with diascopy in lupus vulgaris. Sunlight-sensitizing agents, such as sulfonamides, may produce lesions similar to LE, because phototoxic reactions demonstrate vacuolar interface dermatitis. It may be necessary to differentiate syphilis and sarcoid by biopsy and serologic testing. PMLE is distinguished by the absence of scarring and the presence of intensely edematous plaques and papules. DIF is generally negative or nonspecific in PMLE.

### Hypertrophic lupus erythematosus

Nonpruritic papulonodular lesions may occur on the arms and hands, resembling keratoacanthoma or hypertrophic LP (Fig. 8-5). The lips and scalp may also demonstrate lesions that resemble LP or LPP. Histologic sections of these lesions typically demonstrate lichenoid dermatitis, and a careful examination for other characteristic skin lesions of LE or LP, as well as DIF testing, may be critical in establishing a diagnosis. BMZ thickening, dermal mucin, eccrine coil involvement, and subcutaneous nodular lymphoid infiltrates are features of LE that are not found in LP.

### Lupus erythematosus–lichen planus overlap syndrome

In addition to the cases of hypertrophic LE with lichenoid histology previously discussed, there are patients with a true



**Fig. 8-5** Hypertrophic lupus erythematosus.

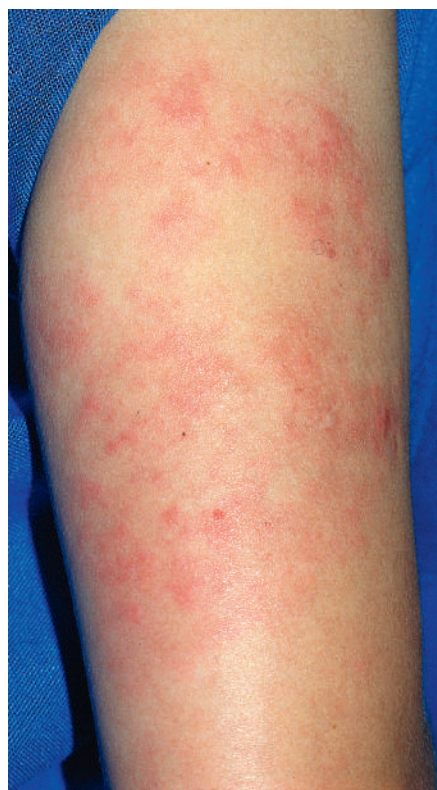overlap syndrome with features of both LE and LP. The lesions are usually large, atrophic, hypopigmented, red or pink patches and plaques. Pigment abnormalities become prominent over time, and fine telangiectasia and scaling are usually present. The extensor aspects of the extremities and midline back are typically affected. Prominent palmoplantar involvement is characteristic and tends to be the most troublesome feature for these patients. Nail dystrophy and anonychia may occur. Scarring alopecia and oral involvement have been noted in some patients. The histology of individual lesions has features of LP and/or LE. DIF usually suggests the former, but immunofluorescence may demonstrate a continuous granular deposition of immunoglobulin. Response to treatment is poor, although potent topical corticosteroids, dapsone, thalidomide, or isotretinoin may be effective. Some patients require immunosuppressive therapy with agents such as mycophenolate mofetil (MMF) or azathioprine. It should also be noted that antimalarials can occasionally produce a lichenoid drug eruption in patients with LE.

### Chilblain lupus erythematosus

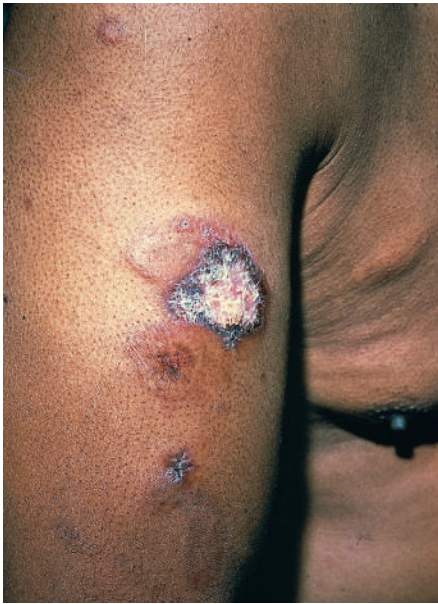Chilblain LE (Hutchinson) is a chronic, unremitting form of LE affecting the fingertips, rims of ears, calves, and heels, especially in women. It is usually preceded by DLE on the face. Systemic involvement is sometimes seen. Mimicry of sarcoidosis may be striking. Cryoglobulins and antiphospholipid antibody (APLA) should also be sought.

### Tumid lupus erythematosus

Tumid LE is a rare but distinctive entity. Patients present with edematous erythematous plaques, usually on the trunk (Fig. 8-6). Histologically, the lesions demonstrate a patchy superficial and deep perivascular and periadnexal lymphoid infiltrate that frequently affects the eccrine coil. Dermal mucin deposition is typical and may be striking. The lesions generally respond readily to antimalarials. Tumid LE shares many



**Fig. 8-6** Tumid lupus.



**Fig. 8-7** Lupus panniculitis with overlying discoid lupus erythematosus.

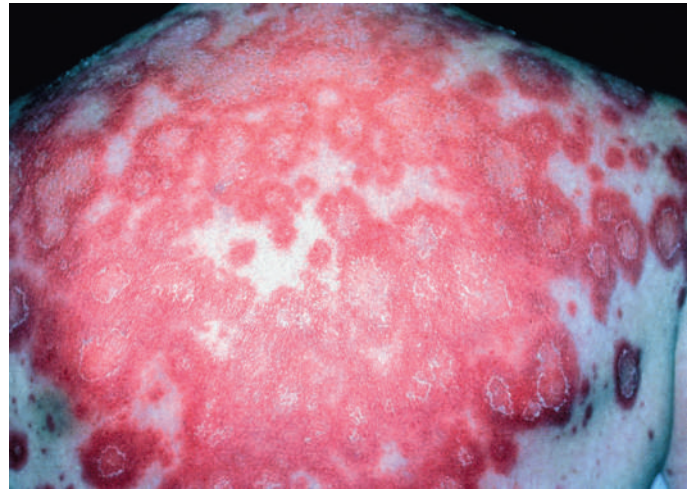
features with reticular erythematosus mucinosis, and some authorities consider them to be closely related entities.

### Lupus erythematosus panniculitis (lupus erythematosus profundus)

Patients with the panniculitis type of LE develop subcutaneous nodules that are usually firm, sharply defined, and nontender. The proximal extremities are typically involved. Usually, the overlying skin is normal, but overlying discoid or tumid lesions may occur (Fig. 8-7). Some cases are discovered incidentally when an unrelated lesion is biopsied. The lesions may heal with deep depressions from loss of the panniculus. LE panniculitis is characteristically chronic and occurs most often in women between ages 20 and 45. Many patients have DLE at other sites or less typically, in the overlying skin.

Histologic sections demonstrate lymphoid nodules in the subcutaneous septa, necrosis of the fat lobule, and fibrinoid or hyaline degeneration of the remaining lipocytes. Lipomembranous change, resembling frost on a windowpane, is more typical of stasis panniculitis (lipodermatosclerosis), but it may be noted focally in LE panniculitis. The overlying epidermis may show basal liquefaction and follicular plugging or may be normal. Dermal lymphoid nodules or vertical columns of lymphoid cells may be seen in fibrous tract remnants. Dermal mucin may be prominent, and dermal collagen hyalinization (resembling that seen in morphea) may be present. Continuous granular deposition of immunoglobulin and C3 may be seen at the DEJ. In active cases, abundant fibrin is usually noted in the panniculus.

The most important entity to consider in the differential diagnosis is subcutaneous panniculitis-like lymphoma. Important clues include the presence of lipocytes, rimmed by atypical lymphocytes with nuclear molding, and the presence of constitutional symptoms. Erythrophagocytosis may be present focally, and T-cell clonality can usually be demonstrated. The infiltrate may be CD8 dominant or may label strongly for CD56, as in natural killer cell lymphoma, or CD30, as in anaplastic lymphoma. CD5 and CD7 expression may be reduced (aberrant loss of pan-T markers). Unfortunately, T-cell clonality, erythrophagocytosis, CD8 predominance, and loss of CD5 or CD7 may also be seen in patients with LE panniculitis who respond to antimalarials or corticosteroids and do not



**Fig. 8-8** Subacute cutaneous lupus erythematosus.

progress to clinical lymphoma. Taken together, these data suggest that some cases of lymphoma may be virtually indistinguishable from LE panniculitis, or that some cases of LE panniculitis represent an abortive lymphoid dyscrasia.

### Subacute cutaneous lupus erythematosus

In 1979, Sontheimer, Thomas, and Gilliam described a clinically distinct subset of cases of LE to which they gave the name subacute cutaneous lupus erythematosus (SCLE). Patients are most often white women age 15–40. SCLE patients make up approximately 10–15% of the LE population. Lesions are scaly and evolve as polycyclic annular lesions or psoriasiform plaques. The lesions vary from red to pink with faint violet tones. The scale is thin and easily detached, and telangiectasia or dyspigmentation may be present. Follicles are not involved; the lesions tend to be transient or migratory, and there is no scarring. Lesions tend to occur on sun-exposed surfaces of the face and neck, the V portion of the chest and back (Fig. 8-8), and the sun-exposed areas of the arms. Photosensitivity is prominent in about half of patients. Concomitant DLE is present in 20% of cases.

About three quarters of patients have arthralgia or arthritis, 20% have leukopenia, and 80% have a positive ANA test (usually in a particulate pattern). About one third of patients meet the American Rheumatology Association (ARA) criteria for a diagnosis of SLE. The majority of cases have antibodies to Ro/SSA antigen, and most are positive for human leukocyte antigen (HLA) DR3. La/SSB may also be present, and many patients have overlap features with Sjögren syndrome. The disease generally runs a mild course, and renal, central nervous system (CNS), or vascular complications are unusual. An association with autoimmune thyroid disease has been noted. Most patients respond to sun protection and antimalarial agents. Drug-induced SCLE is most often related to hydrochlorothiazide but may also be seen with angiotensin-converting enzyme (ACE) inhibitors, calcium channel blockers (CCBs), interferons (IFNs), anticonvulsants, griseofulvin, glyburide, piroxicam, penicillamine, spironolactone, terbinafine, and statins.

### Histopathology

Vacuolar interface dermatitis is a universal finding in active SCLE lesions. Mild hyperkeratosis and parakeratosis may be present. Chronic changes of DLE, such as follicular plugging, BMZ thickening, and heavy lymphoid aggregates, are usually



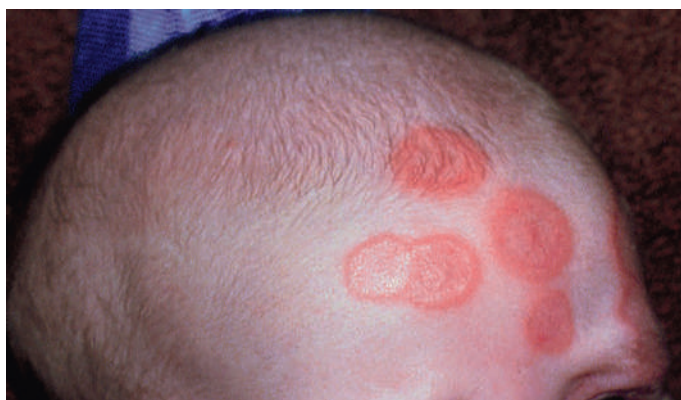

Fig. 8-9 Neonatal lupus erythematosus.

lacking. Dermal mucin is variable. DIF is positive in lesional skin in only about one third of cases. A dustlike particulate deposition of IgG in epidermal nuclei of Ro-positive patients may be present and is a helpful diagnostic finding.

### Neonatal lupus erythematosus

Most infants with neonatal lupus are girls, born to mothers who carry the Ro/SSA antibody. These infants have no skin lesions at birth, but develop them during the first few weeks of life. Annular erythematous macules and plaques may appear on the head and extremities (Fig. 8-9). Periocular involvement (raccoon eyes) may be prominent. With time, the lesions fade and become atrophic. Telangiectasia or dermal mucinosis in an acral papular pattern may be the predominant findings in some cases. Telangiectatic macules or angiomatous papules may be found in sun-protected sites such as the diaper area, and may occur independently of active lupus skin lesions, and may be persistent. The skin lesions usually resolve spontaneously by 6 months of age, and usually heal without significant scarring, although atrophy and telangiectatic mats may persist. Dyspigmentation and persistent telangiectasias may remain for months to years. Half the mothers are asymptomatic at delivery, although many will subsequently develop arthralgia, Sjögren syndrome, or other mild systemic findings.

Although the skin lesions are transient, half the patients have an associated isolated congenital heart block, usually third degree, which is permanent. Some infants have only this manifestation of LE, and for cardiac lesions alone, there is no female predominance. In children with cutaneous involvement, thrombocytopenia and hepatic disease may occur as frequently as cardiac disease.

There is a strong association with Ro/SSA autoantibody. Almost all mothers, and thus almost all infants, are positive for this antibody, although some mothers are also positive for La/SSB, and some with only U1RNP antibodies have been described. Infants with only U1RNP antibodies have not developed heart block. There is linkage to HLA-DR3 in the mother. The risk that a second child will have neonatal LE is approximately 25%. Japanese infants apparently differ in that they may express anti-dsDNA antibodies, and 8% progress to SLE. In unselected women with anti-Ro antibodies, only 1–2% will have an infant with neonatal LE.

### Complement deficiency syndromes

Although deficiency of many complement components may be associated with LE-like conditions, deficiencies of the early

components, especially C2 and C4, are most characteristic. Many such cases are found to have photosensitive annular SCLÉ lesions and Ro/SSA antibody formation. Patients with C4 deficiency often have hyperkeratosis of the palms and soles. Heterozygous deficiency of either complement component C4A or C4B has a frequency of approximately 20% in white populations. Homozygous deficiency of both is rare, and affected patients may present with SLE with mesangial glomerulonephritis, membranous nephropathy, and severe skin lesions. Although frequently asymptomatic, homozygous C2 deficiency can cause severe infections, SLE, and atherosclerosis.

### Systemic lupus erythematosus

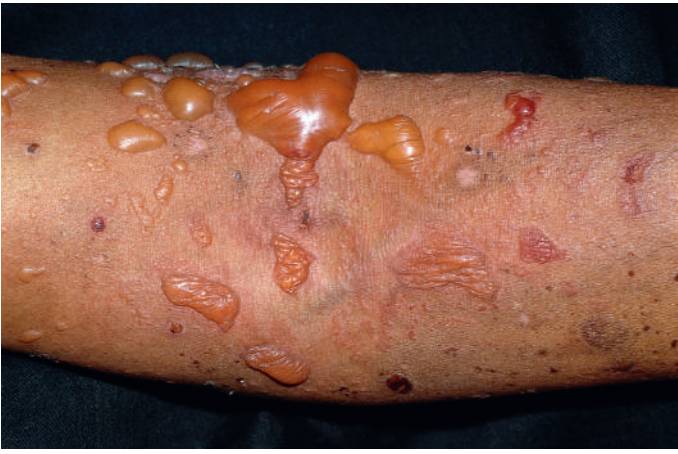Young to middle-aged women are predominantly affected by SLE, manifesting a wide range of symptoms and signs. Skin involvement occurs in 80% of cases and is often helpful in arriving at a diagnosis. Its importance is suggested by the fact that 4 of the 11 American College of Rheumatology (ACR) criteria for the diagnosis of SLE are mucocutaneous findings. The diagnostic criteria are as follows:

1. Malar rash
2. Discoid rash
3. Photosensitivity
4. Oral ulcers (21%)
5. Arthritis
6. Proteinuria >0.5 g/day or casts
7. Neurologic disorders (seizures or psychosis in the absence of other known causes)
8. Pleuritis/pericarditis
9. Blood abnormalities (e.g., hemolytic anemia, leukopenia, thrombocytopenia)
10. Immunologic disorders, including anti-dsDNA antibody, anti-Sm, APLAs (based on IgG or IgM anticardiolipin antibodies, lupus anticoagulant (LA), or false-positive serologic test for syphilis known for at least 6 months)
11. Positive ANA blood test

For identification of patients in clinical studies, a patient may be said to have SLE if four or more of these criteria are satisfied, serially or simultaneously. It is important to note that many patients present with autoantibodies, arthralgia, and constitutional signs, but do not meet ACR criteria for SLE. With time, patients may evolve to meet all criteria. The Systemic Lupus International Collaborating Clinics (SLICC) group revision of the ACR criteria results in greater sensitivity with equal specificity. According to the SLICC rule, the patient must manifest at least four criteria (including at least one clinical criterion and one immunologic criterion) *or* must have biopsy-proven lupus nephritis in the presence of either ANAs or anti-dsDNA antibodies.

### Cutaneous manifestations

The characteristic butterfly facial erythema seen in patients with SLE is a common manifestation of acute cutaneous LE. The eruption usually begins on the malar area and the bridge of the nose. There may be associated edema. The ears and chest may also be the sites of early lesions. Biopsies at all sites show interface dermatitis and a scant perivascular lymphoid infiltrate. The eruption may last a day to several weeks and resolves without scarring. There may be more widespread erythema in some cases.



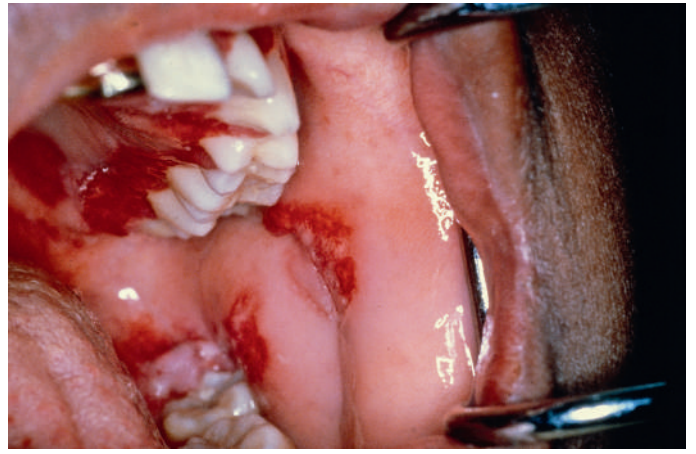
**Fig. 8-10** Bullous lupus erythematosus.

Bullous lesions of lupus erythematosus (BLE) occur as single or grouped vesicles or bullae, often widespread, with a predilection for sun-exposed areas (Fig. 8-10). Rarely, the lesions may itch. Most sets of published criteria require that patients with BLE meet ACR criteria for SLE, but some patients have identical bullous lesions and less than four ACR criteria. ACR criteria are critical to ensure that patients with similar severity are enrolled in clinical trials, but these sometimes fall short in the evaluation of a given patient. Histologically, neutrophils accumulate at the DEJ and within dermal papillae. In bullous lesions, there is a subepidermal bulla or superficial dermal edema containing neutrophils. Fluorescence with IgG, IgM, IgA, or C3 is typically present in a continuous, granular pattern at the BMZ on DIF testing. Neutrophils are found in or below the lamina densa on immunofluorescent electron microscopy. Most of these patients are HLA-DR2 positive. The recognition of this subset as distinct is made clear by its often dramatic therapeutic response to dapsone. Epidermolysis bullosa acquisita is histopathologically and immunopathologically identical, since both diseases are mediated by circulating antibodies against type VII collagen. Dapsone is usually ineffective in epidermolysis bullosa acquisita. Bullous lesions also occasionally arise as a result of liquefactive degeneration of the basal cell layer or full-thickness epidermal necrosis resembling toxic epidermal necrolysis (TEN).

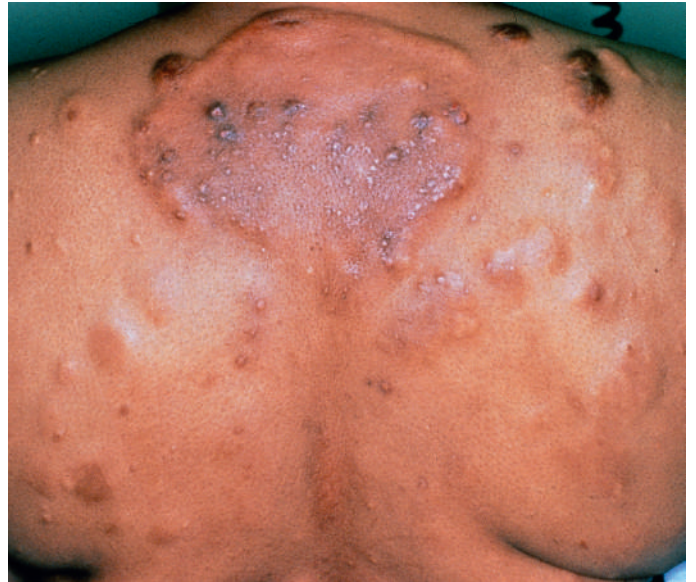
A variety of vascular lesions occur in 50% of SLE patients. Often, fingertips or toes show edema, erythema, or telangiectasia. Nailfold capillary loops in LE are more likely to show wandering glomeruloid loops, whereas dermatomyositis and scleroderma capillary loops demonstrate symmetric dilation and dropout of vessels. Capillary loops in the Osler-Weber-Rendu syndrome demonstrate ectasia of half the capillary loop. Erythema multiforme (EM)-like lesions may predominate, termed Rowell syndrome. Rarely, TEN may be associated with lupus.

In addition to periungual telangiectasia, red or spotted lunulae may be present in patients with SLE, as in RA. The palms, soles, elbows, knees, or buttocks may become persistently erythematous or purplish, sometimes with overlying scale. Diffuse, nonscarring hair loss is common. Short hairs in the frontal region are called "lupus hairs." These hairs result from a combination of chronic telogen effluvium and increased hair fragility.

Mucous membrane lesions are seen in 20-30% of SLE patients, and chronic cutaneous lupus may be localized to the eyelid or oral mucosa. Conjunctivitis, episcleritis, and nasal and vaginal ulcerations may occur. Oral mucosal hem-



**Fig. 8-11** Oral lesions of systemic lupus erythematosus.



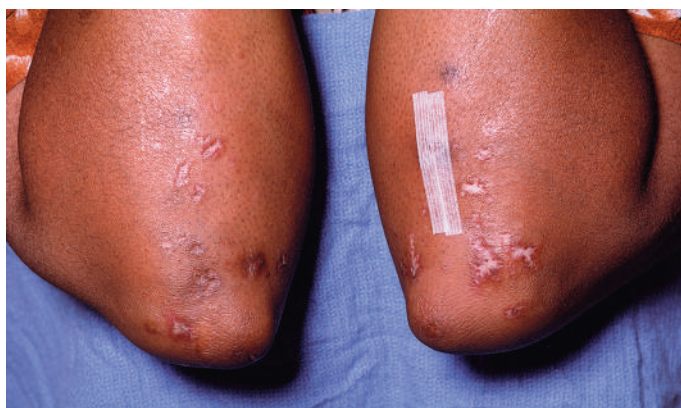
**Fig. 8-12** Papulonodular mucinosis.

orrhages, erosions, shallow angular ulcerations with surrounding erythema, and gingivitis are common (Fig. 8-11). Erythema, petechiae, and ulcerations may occur on the hard palate.

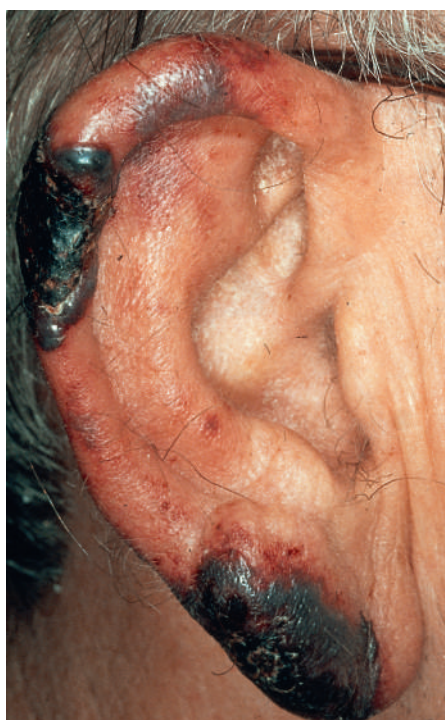Multiple eruptive dermatofibromas have been described in SLE. Leg ulcers, typically deeply punched out and with very little inflammation, may be seen on the pretibial or malleolar areas. Many of these patients present with a livedoid pattern, and many have an antiphospholipid antibody. Sneddon syndrome is composed of livedo reticularis and strokes related to a hyalinizing vasculopathy. Both EM like and TEN like presentations have been described.

Calcinosis cutis is uncommon but may be dramatic. Also seen infrequently are plaquelike or papulonodular depositions of mucin. These reddish purple to skin-colored lesions are often present on the trunk and arms or head and neck (Fig. 8-12). Lastly, a symmetric papular eruption of the extremities may occur (Fig. 8-13). These skin-colored to erythematous lesions with a smooth, ulcerated or umbilicated surface may show vasculitis or, in older lesions, a palisaded granulomatous inflammation. These occur in patients with SLE, RA, or other immune complex-mediated disease. This eruption has been referred to as palisaded neutrophilic and granulomatous dermatitis of immune complex disease.





**Fig. 8-13** Palisaded neutrophilic granulomatous dermatitis.



**Fig. 8-14** Cutaneous thrombosis in antiphospholipid antibody syndrome.

## Systemic manifestations

Most organs can be involved in SLE; the symptoms and findings are often caused by immune complex disease, especially vasculitis. The earliest changes noted may be transitory or migratory arthralgia, often with periarticular inflammation. Fever, weight loss, pleuritis, adenopathy, or acute abdominal pain may occur. Arthralgia is often the earliest abnormality and may remain the sole symptom for some time. About 95% of SLE patients will manifest this symptom. Arthralgia, deforming arthropathy, and acute migratory polyarthritis resembling RA may all occur as manifestations of SLE. Avascular necrosis of the femoral head has been observed. Although this is a known complication of systemic corticosteroid therapy, it has also occurred in patients with SLE who have never taken corticosteroids.

Patients with SLE have a higher rate of peripheral arterial disease compared with controls. Thrombosis in vessels of various sizes and thromboembolism may be a recurring event (Fig. 8-14). It may be attributed to a plasma constituent, paradoxically called “lupus anticoagulant” (LA) because it causes

prolonged coagulation studies in vitro but thrombosis in vivo. The finding of an LA is usually associated with APLAs. These may be anticardiolipin antibodies, but other APLA types—antiphosphatidylserine, antiphosphatidylinositol, and antiphosphatidylethanolamine—may occur. APLAs and elevated homocysteine may each increase the risk of thrombosis. APLAs are associated with early-onset organ damage. Many, but not all, patients have a false-positive blood test for syphilis. In one study, inflammatory lesions of SLE and infections were the most common causes of death during the initial 5 years of disease, while thromboses were the most common cause of death after the first 5 years.

Renal involvement may be of either nephritic or nephrotic type, leading in either case to chronic renal insufficiency with proteinuria and azotemia. Active nephritis is unlikely in the absence of anti-dsDNA. Both anti-dsDNA antibody and anti-C1q antibody are of relatively high specificity for active nephritis. Hypercholesterolemia and hypoalbuminemia may occur. Immunoglobulin and complement components have been found localized to the BMZ of glomeruli, where vasculitis produces the characteristic “wire-loop” lesion.

Myocarditis is indicated by cardiomegaly and gallop rhythm, but the electrocardiographic (ECG) changes are usually not specific. Pericarditis, the most frequent cardiac manifestation, and endocarditis also occur. Raynaud phenomenon occurs in about 15% of patients, who have less renal disease and consequently lower mortality.

The CNS may be involved with vasculitis, manifested by hemiparesis, convulsions, epilepsy, diplopia, retinitis, choroiditis, psychosis, and other personality disorders. Livedo reticularis is a marker for patients at risk for CNS lesions (Sneddon syndrome; see earlier).

Idiopathic thrombocytopenic purpura is occasionally the forerunner of SLE. Coombs-positive hemolytic anemia, neutropenia, and lymphopenia are other hematologic findings. Gastrointestinal (GI) involvement may produce symptoms of nausea, vomiting, and diarrhea. Frequently, the intestinal wall and the mesenteric vessels show vasculitis. Pulmonary involvement with pleural effusions, interstitial lung disease, and acute lupus pneumonitis may be present. Sjögren syndrome (keratoconjunctivitis sicca) and Hashimoto thyroiditis are associated with SLE. Overlap with any of the connective tissue diseases may be seen, occurring in approximately 25% of patients. Muscular atrophy may accompany extreme weakness so that dermatomyositis may be suspected. Myopathy of the vacuolar type may produce muscular weakness, myocardial disease, dysphagia, and achalasia of the esophagus. Steroid myopathy may also occur. The serum aldolase level may be elevated with a normal creatine phosphokinase. Type B insulin resistance syndrome with insulin receptor antibodies accompanied by pancytopenia has been reported in the setting of chronic discoid LE evolving to SLE.

A history of exposure to excessive sunlight before the onset of the disease or before an exacerbation is sometimes obtained. Some patients may have only mild constitutional symptoms for weeks or months, but immediately after exposure to strong sunlight, they may develop the facial eruption and severe disease complications.

Hydralazine, procainamide, sulfonamides, penicillin, anti-convulsants, minocycline, and isoniazid have been implicated as causes of drug-induced LE. Most drug-induced lupus is associated with a positive ANA test, antihistone antibodies, and sometimes serositis. Penicillamine induces (or unmasks) true SLE, and etanercept has produced a range of findings, including SLE. Anti-tumor necrosis factor (TNF) agents have produced a shift to a lupus profile of autoantibodies in patients with RA.

## Childhood systemic lupus erythematosus

The onset of childhood SLE occurs between ages 3 and 15, with girls outnumbering boys 4:1. The skin manifestations may be the typical butterfly eruption on the face and photosensitivity. In addition, there may be morbilliform, bullous, purpuric, ulcerating, or nodose lesions. The oral mucosa is frequently involved. Skin eruptions may be associated with joint, renal, neurologic, and GI disease. Weight loss, fatigue, hepatosplenomegaly, lymphadenopathy, and fever are other manifestations. Pediatric patients with SLE and APLAs, specifically lupus anticoagulants, are at high risk of developing thromboembolic events.

### Pregnancy

Women with LE may have successful pregnancies, but they might have difficulty conceiving, and miscarriages occur with greater frequency, especially among those with APLAs. The course of pregnancy may be entirely normal, with remission of the LE, or the symptoms of LE may become worse. Risk of fetal death is increased in women with a previous history of fetal loss and anticardiolipin or anti-Ro antibodies. Low-dose aspirin is often used in the former situation. For the patient with these antibodies but without a history of previous fetal loss, the risk of fetal loss or neonatal lupus is low. In most cases, the pregnancy itself is well tolerated, although a flare of SLE may occur during the postpartum period. Several studies have failed to demonstrate a clinically significant association between oral contraceptive (OC) use and flares of SLE. There is a high incidence of thromboses in women with APLAs, and OCs containing second- or third-generation progestogens may induce a higher risk.

### Etiology

A family history of connective tissue disease is a strong risk factor for all forms of LE. HLA and gene linkage studies suggest a strongly heritable component, and some skin lesions of LE follow lines of Blaschko, suggesting postzygotic mutation or loss of heterozygosity for a genetic locus. The C-reactive protein (CRP) response is defective in patients with flares of SLE, and the gene locus for CRP maps to 1q23.2 within an interval linked with SLE. Gene polymorphisms in *APRIL*, a member of the TNF family, have also been linked with SLE. Increased expression of TNF- $\alpha$  and IFN-inducible protein myxovirus protein A is noted in cutaneous LE. Polymorphisms of the *C1qA* gene are associated with both systemic and cutaneous LE. Strong linkage has been found with SLE at 5p15.3, 1q23, 1q31, 11q14, 12q24, and 16q12, as well as other candidate sites. Linkage varies in different ethnic groups and different clinical subsets of lupus. Taken together, these data suggest polygenetic susceptibility to LE.

Both ultraviolet (UV) B and UVA can upregulate antigen expression and cytokines, causing release of sequestered antigens and free radical damage. All these mechanisms may contribute to photosensitivity and UV-induced flares of systemic disease.

Several aspects of the altered immune response are worth particular attention. T-suppressor cell function is reduced in patients with LE. Overproduction of  $\gamma$ -globulins by B cells and reduced clearance of immune complexes by the reticuloendothelial system may contribute to complement-mediated damage. Externalization of cellular antigens, such as Ro/SSA in response to sunlight, may lead to cell injury by way of antibody-dependent cellular cytotoxicity. Abnormal apoptosis or reduced clearance of apoptotic cells may lead to increased exposure of nucleosome antigens and antinucleosome anti-

bodies. HLA-DR4 individuals, who are slow acetylators, are predisposed to develop hydralazine-induced LE. Antibody to the histone complex H2A-H2B is closely associated with disease. In most drug-induced LE, antibodies are directed against histones. Exceptions include penicillamine and etanercept, which may induce or unmask native disease with anti-dsDNA antibodies. Pegylated IFN- $\alpha$  and ribavirin have also produced systemic LE during treatment for chronic hepatitis C. Drugs implicated in SLE are listed earlier in this chapter. L-Canavanine, an amino acid found in alfalfa sprouts and tablets, can also induce or worsen SLE. Minimal credible data exist regarding other possible aggravating dietary factors, but some reports have implicated excess calories, excess protein, high fat (especially saturated and  $\omega$ -6 polyunsaturated fatty acids), excess zinc, and excess iron. Well-designed studies are needed. Cigarette smoking is associated with increased disease activity in SLE, and can interfere with the effects of antimalarial drugs.

### Laboratory findings

There may be hemolytic anemia, thrombocytopenia, lymphopenia, or leukopenia; ESR usually is greatly elevated during active disease, Coombs test may be positive, there is a biologic false-positive test for syphilis, and a rheumatoid factor (RF) may be present. IgG levels may be high, the albumin/globulin ratio is reversed, and serum globulin is increased, especially the  $\gamma$ -globulin or  $\alpha$ 2 fraction. Albumin, red blood cells, and casts are the most frequent findings in the urine.

### Immunologic findings

1. *ANA test*. This is positive in 95% of cases of SLE. Human substrates, such as Hep-2 or KB tumor cell lines, are far more sensitive than mouse substrates. ANA pattern has some correlation with clinical subsets, such as a shrunken peripheral pattern in SLE with renal disease, a fine particulate pattern in subacute cutaneous LE, and a homogeneous pattern with antihistone antibodies.
2. *Lupus erythematosus cell test*. This is specific but not very sensitive and has been deleted from the ACR criteria.
3. *Double-stranded DNA. Anti-dsDNA, anti-native DNA*. This is specific, but not very sensitive. It indicates a high risk of renal disease, and correlates with a shrunken peripheral ANA pattern and positive DIF in sun-protected skin.
4. *Anti-Sm antibody*. Sensitivity is less than 10%, but specificity is very high.
5. *Antinuclear ribonucleic acid protein (anti-nRNP)*. Very high titers are present in mixed connective tissue disease (MCTD). Lower titers may be seen in SLE.
6. *Anti-La antibodies*. These are common in SLE and Sjögren syndrome, and occasionally found in SLE.
7. *Anti-Ro antibodies*. These are found in about 25% of SLE and 40% of Sjögren patients. They are more common in patients with SLE (70%), neonatal LE (95%), C2- and C4-deficient LE (50–75%), late-onset LE (75%), and Asian patients with LE (50–60%). Photosensitivity may be striking, and externalization of the antigen is seen after UV exposure.
8. *Serum complement*. Low levels indicate active disease, often with renal involvement.
9. *Lupus band test. Direct cutaneous immunofluorescence*. Continuous granular deposits of immunoglobulins and complement along the DEJ occur in more than 75% of well-established lesions of DLE. In SLE, it usually is



positive in sun-exposed skin. A positive test in normal, protected skin correlates with the presence of anti-dsDNA antibodies and renal disease. The lupus band test is seldom performed, because the same population of patients can be detected with anti-dsDNA antibodies.

10. *Anti-ssDNA antibody.* This test is sensitive but not specific. Many patients are photosensitive. An IgM isotope seen in DLE may identify a subset of patients at risk for developing systemic symptoms.
11. *Antiphospholipid antibodies.* Both the anticardiolipin antibody and the lupus anticoagulant are subtypes of APLAs. These are associated with a syndrome that includes venous thrombosis, arterial thrombosis, spontaneous abortions, and thrombocytopenia. Livedo reticularis is a frequent skin finding, and nonfading acral microlivedo, with small, pink cyanotic lesions on the hands and feet, is a subtle clue to the presence of APLAs. These antibodies may occur in association with lupus and other connective tissue disease, or as a solitary event. In the latter case, it is referred to as the primary antiphospholipid syndrome.

## Differential diagnosis

Diagnostically, SLE must be differentiated from dermatomyositis, EM, polyarteritis nodosa, acute rheumatic fever, RA, pellagra, pemphigus erythematosus (Seneur-Usher syndrome), drug eruptions, hyperglobulinemic purpura, Sjögren syndrome, necrotizing angitis, and myasthenia gravis. The SLE patient may have fever, arthralgia, weakness, lassitude, diagnostic skin lesions, increased ESR, cytopenias, proteinuria, immunoglobulin deposition at DEJ, and positive ANA test. Biopsies of skin lesions and involved kidney may also be diagnostic.

## Treatment

Some general measures are important for all patients with LE. Exposure to sunlight must be avoided, and a high sun protection factor (SPF) sunscreen should be used daily. Photosensitivity is frequently present even if the patient denies it, and all patients must be educated about sun avoidance and sunscreen use. The patient should also avoid exposure to excessive cold, to heat, and to localized trauma. Biopsies and scar revision will often provoke a flare of the disease. Women with SLE have an increased risk of osteoporosis, independent of corticosteroid use, and rituximab may increase the risk. Bone density should be monitored and calcium and vitamin D supplementation considered. Some women will benefit from bisphosphonate therapy, especially if corticosteroids are used. The most rapid bone loss with corticosteroid therapy occurs at the onset of treatment, so bisphosphonate therapy should not be delayed. Patients who will be treated with immunosuppressive agents should receive a tuberculin skin test as well as a thorough physical examination. Aggressive treatment is often necessary for discoid lesions and scarring alopecia. The slowly progressive nature of these lesions, and the lack of systemic involvement, may lead to inappropriate therapeutic complacency. The result is slow, progressive disfigurement.

### Local treatment

The application of potent or superpotent topical corticosteroids is beneficial in LE patients. Occlusion may be necessary and may be enhanced by customized vinyl appliances (especially for oral lesions) or surgical dressings. Tape containing corticosteroid (Cordran) is sometimes helpful. The single most effective local treatment is the injection of corticosteroids into

the lesions. Triamcinolone acetonide, 2.5–10 mg/mL, is infiltrated into the lesion through a 30-gauge needle at intervals of 4–6 weeks. No more than 40 mg of triamcinolone should be used at one time. Steroid atrophy is a valid concern, but so are the atrophy and scar produced by the disease. The minimal intralesional dose needed to control the disease should be used; when the response is poor, however, it is generally better to err on the slightly more aggressive side of treatment than to undertreat. Topical calcineurin inhibitors (topical macrolactams) may also be useful as second-line topical therapy. Photodynamic therapy has been reported as effective.

### Systemic treatment

The safest class of systemic agent for LE is the antimalarials. Retinoids are second-line agents and are particularly helpful in treating hypertrophic LE. Systemic immunosuppressive agents are often required to manage the systemic manifestations of LE, and these are third-line systemic agents for cutaneous LE. Thalidomide can be effective, but its use is limited by the risk of teratogenicity and neuropathy. Dapsone is the drug of choice for bullous systemic LE and may be effective in some cases of SCLE and DLE. Oral prednisone is generally reserved for acute flares of disease. Biologic agents are now used for refractory disease, as described later.

### Antimalarials

Hydroxychloroquine (Plaquenil), at a dose of 6.5 mg/kg/day or less, has an excellent safety profile and is generally used as first-line systemic therapy in most forms of cutaneous LE. If no response occurs after 3 months, another agent should be considered. Chloroquine (Aralen) is effective at 250 mg/day for an average adult but is difficult to procure. Quinacrine (Atabrine), 100 mg/day, may be added to hydroxychloroquine because it adds no increased risk of retinal toxicity. Quinacrine is also difficult to procure and carries a higher risk of disfiguring pigmentation than the other antimalarials. Systemic treatment can sometimes be reduced or stopped during the winter months. A Cochrane group review of randomized controlled trials (RCTs) concluded that hydroxychloroquine and acitretin appear to be of similar efficacy, although adverse effects are more severe and occur more often with acitretin.

Ocular toxicity is rare with doses of hydroxychloroquine of 6.5 mg/kg/day or less. Ophthalmologic consultation should be obtained before, and at 4-month to 6-month intervals during, treatment. Constriction of visual fields to a red object and paracentral scotomas are rare at the recommended dose, but even a small risk of loss of vision must be taken seriously. The finding of any visual field defect or pigmentary abnormality is an indication to stop antimalarial therapy.

Other reported side effects with antimalarials include erythroderma, EM, purpura, urticaria, nervousness, tinnitus, abducens nerve paralysis, toxic psychoses, leukopenia, and thrombocytopenia. Antimalarials, except in very small doses, will exacerbate skin disease or cause hepatic necrosis in patients with porphyria cutanea tarda. They may also worsen or induce psoriasis. Quinacrine produces a yellow discoloration of the skin and conjunctivae. Quinacrine has also been known to produce blue-black pigmentation of the hard palate, nail beds, cartilage of the ears, alae nasi, and sclerae. Other antimalarials may also rarely produce a blue-black pigmentation of skin. Bullous EM, lichenoid drug eruption, nausea, vomiting, anorexia, and diarrhea may develop. Aplastic anemia has rarely been noted in long-term therapy. A patient's brown or red hair may turn light blond.

### Corticosteroids

Systemic corticosteroids are highly effective for widespread or disfiguring lesions, but disease activity often rebounds

quickly when the drug is discontinued. Because of long-term side effects, corticosteroid treatment should be limited to short (generally  $\leq 3$  weeks) courses to treat flares of disease or to obtain initial control while antimalarial therapy is being initiated. In patients with renal or neurologic involvement, corticosteroids should be administered in doses adequate to control the disease while treatment with a steroid-sparing regimen is initiated. Treatment with 1000 mg/day intravenous methylprednisolone for 3 days, followed by oral prednisone, 0.5–1 mg/kg/day, is effective in quickly reversing most clinical and serologic signs of activity of lupus nephritis. In general, the corticosteroid dose should be optimized to the lowest possible that controls symptoms and laboratory abnormalities.

### Immunosuppressive therapy

Aggressive treatment protocols with agents such as pulse cyclophosphamide (with hydration and mesna to prevent bladder toxicity) have greatly improved the outcome of renal LE. Other immunosuppressive agents (e.g., azathioprine, methotrexate, MMF), are often employed as steroid-sparing agents for refractory cutaneous disease. Some authorities have suggested that azathioprine is inferior to MMF in the treatment of cutaneous lesions. Interleukin (IL)-6 receptor inhibition with tocilizumab appears promising but may cause neutropenia.

### Other therapy

Isotretinoin therapy, 1 mg/kg/day, may be effective, especially in patients with hypertrophic or lichenoid lesions of LE. Rapid relapse may be noted when the drug is discontinued. Dapsone, clofazimine, acitretin, IFN alpha-2a, auranofin (oral gold), high-dose intravenous gamma globulin (IVIG), efalizumab, and thalidomide have all been reported as effective in anecdotal use or limited trials. Pulsed dye laser has been shown to be effective for some erythematous lesions of cutaneous LE but should be used cautiously, because it may also cause flares of disease. Flares are also common with surgical modalities used to improve scarring or alopecia. Anti-CD20 monoclonal antibody (rituximab) has been used successfully to treat life-threatening refractory SLE with renal and CNS involvement, as well as for hypocomplementemic urticarial vasculitis and refractory cutaneous lesions. Although lupus is a photosensitive disorder, UVA-I therapy appears to be a useful adjuvant treatment modality in some patients, and photodynamic therapy has been effective in some patients. Fluvastatin appears promising in patients with antiphospholipid syndrome, based on its ability to suppress prothrombotic markers. Clinical validation is needed, along with novel agents, because aspirin resistance is common among patients with the syndrome. Tolerogenic dendritic cells show some promise for the treatment of autoimmune diseases, including lupus.

**Akdogan A, et al:** Aspirin resistance in systemic lupus erythematosus. a pilot study. *Lupus* 2013; 22(8):835–838.

**Albrecht J, et al:** Dermatology position paper on the revision of the 1982 ACR criteria for systemic lupus erythematosus. *Lupus* 2004; 13:839.

**Barsalou J, et al:** An update on childhood-onset systemic lupus erythematosus. *Curr Opin Rheumatol* 2013; 25(5):616–622.

**Boackle SA:** Advances in lupus genetics. *Curr Opin Rheumatol* 2013; 25(5):561–568.

**Calvo-Alén J, et al:** SER consensus statement on the use of biologic therapy for systemic lupus erythematosus. *Rheumatol Clin* 2013; 9(5):281–296.

**Cavazzana I, et al:** Treatment of lupus skin involvement with quinacrine and hydroxychloroquine. *Lupus* 2009; 18(8):735–739.

**Condon MB, et al:** Prospective observational single-centre cohort study to evaluate the effectiveness of treating lupus nephritis with rituximab

and mycophenolate mofetil but no oral steroids. *Ann Rheum Dis* 2013; 72(8):1280–1286.

**Erkan D, et al:** A prospective open-label pilot study of fluvastatin on proinflammatory and prothrombotic biomarkers in antiphospholipid antibody positive patients. *Ann Rheum Dis* 2014; 73(6):1176–1180.

**Grech P, et al:** Targeted therapies in systemic lupus erythematosus. *Lupus* 2013; 22(10):978–986.

**Hassan AA, et al:** Peripheral arterial disease in patients with systemic lupus erythematosus: a prospective controlled study. *Int J Rheum Dis* 2013; 16(3):319–324.

**Hofmann S, et al:** Effects of rituximab-based B-cell depletion therapy on skin manifestations of lupus erythematosus: report of 17 cases and review of the literature. *Lupus* 2013; 22(9):932–939.

**Jessop S, et al:** Drugs for discoid lupus erythematosus. *Cochrane Database Syst Rev* 2009; (4):CD002954.

**Kuhn A, et al:** Treatment of cutaneous lupus erythematosus. *Lupus* 2010; 19(9):1125–1136.

**Liu CC, et al:** Biomarkers in systemic lupus erythematosus: challenges and prospects for the future. *Ther Adv Musculoskelet Dis* 2013; 5(4):210–233.

**Llanos C, et al:** Tolerogenic dendritic cells as a therapy for treating lupus. *Clin Immunol* 2013; 148(2):237–245.

**Luo YJ, et al:** Correlation of cutaneous immunoreactants in lesional skin with the serological disorders and disease activity of systemic lupus erythematosus. *PLoS One* 2013; 8(8):e70983.

**Marzano AV, et al:** Drug-induced lupus: an update on its dermatologic aspects. *Lupus* 2009; 18(11):935–940.

**Md Yusof MY, et al:** B-cell-targeted therapies in systemic lupus erythematosus and ANCA-associated vasculitis: current progress. *Expert Rev Clin Immunol* 2013; 9(8):761–772.

**Ostensen M, et al:** Pathogenesis of pregnancy complications in systemic lupus erythematosus. *Curr Opin Rheumatol* 2013; 25(5):591–596.

**Petri M, et al:** Derivation and validation of the Systemic Lupus International Collaborating Clinics classification criteria for systemic lupus erythematosus. *Arthritis Rheum* 2012; 64(8):2677–2686.

**Pinto CM, et al:** Bone mineral density in systemic lupus erythematosus women one year after rituximab therapy. *Lupus* 2013; Aug 29. [Epub ahead of print.] PMID: 23989736.

**Rao V, et al:** Latest advances in connective tissue disorders. *Ther Adv Musculoskelet Dis* 2013; 5(4):234–249.

**Sticherling M, et al:** Diagnostic approach and treatment of cutaneous lupus erythematosus. *J Dtsch Dermatol Ges* 2008; 6(1):48–59.

**Sui W, et al:** Hematopoietic and mesenchymal stem cell transplantation for severe and refractory systemic lupus erythematosus. *Clin Immunol* 2013; 148(2):186–197.

**Van Vollenhoven RF:** Challenges and opportunities in SLE clinical trials. *Curr Opin Rheumatol* 2013; 25(5):606–615.

**Walling HW, et al:** Cutaneous lupus erythematosus: issues in diagnosis and treatment. *Am J Clin Dermatol* 2009; 10(6):365–381.

**Zattra E, et al:** TNF blockade and cutaneous lupus erythematosus: where do we stand and where are we going? *Immunotherapy* 2013; 5(8):791–794.

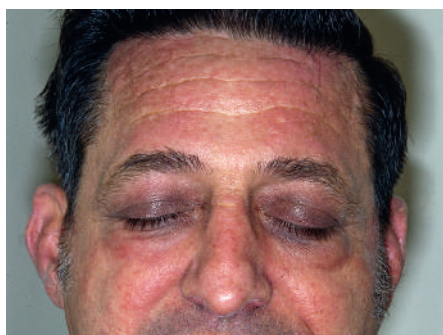
## DERMATOMYOSITIS

Dermatomyositis (DM) is typically characterized by inflammatory myositis and skin disease, although the hypomyopathic type (DM with subclinical or absent myopathy) also occurs. Muscle involvement without skin changes is called polymyositis (PM). With or without skin lesions, weakness of proximal muscle groups is characteristic.

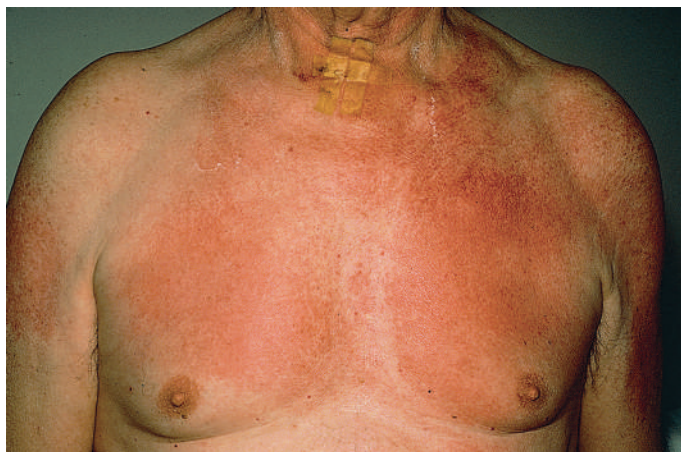### Skin findings

Usually, the disease begins with erythema and edema of the face and eyelids. Eyelid involvement may be characterized by pruritic and scaly pink patches, edema, and pinkish violet (heliotrope) discoloration or bullae (Fig. 8-15). Pruritic scaly pink patches are often seen in amyopathic DM. Edema and pinkish violet discoloration are often signs of inflammation in





**Fig. 8-15** Heliotrope rash in patient with dermatomyositis.

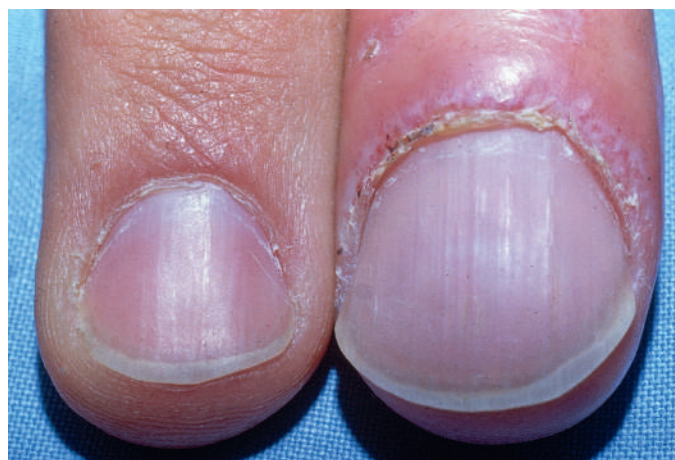

**Fig. 8-16** Chest erythema in dermatomyositis.

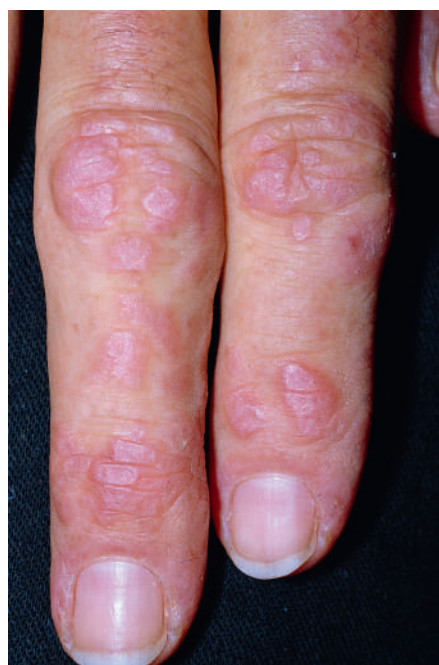the underlying striated orbicularis oculi muscle, rather than the skin itself; the patient's eyelids may be tender to the touch. Bullous DM may portend a poor prognosis, and patients often have severe inflammatory myopathy or lung disease.

Other skin changes include erythema, scaling, and swelling of the upper face, often with involvement of the scalp and eyebrows. Over time, the lesions tend to develop a reticulated pattern of white scarring. Extensor surfaces of the extremities are often pink, red, or violaceous with an atrophic appearance or overlying scale. The similarity to psoriasis can be striking, and patients may suffer severe flares of DM if they are inappropriately treated with phototherapy for presumed psoriasis. Photosensitivity to natural sunlight is common as well. Firm, slightly pitting edema may be seen over the shoulder girdle, arms, and neck (Fig. 8-16). Associated erythema and scale (with or without poikiloderma) over the shoulder regions is known as the "shawl sign." Similar changes on the hip are called the "holster sign." Pruritus may be severe, especially on the scalp, and is much more common in DM than in psoriasis or LE. Occasionally, a flagellate pattern mimicking bleomycin-induced linear edematous streaks or erythroderma may be seen.

On the hands, telangiectatic vessels often become prominent in the proximal nailfolds. Enlarged capillaries of the nailfold appear as dilated, sausage-shaped loops with adjacent avascular regions, similar to those changes observed in scleroderma but without the associated sclerodactyly. There may be cuticular overgrowth with an irregular, frayed appearance (Fig. 8-17). A pink to reddish purple atrophic or scaling eruption often occurs over the knuckles, knees, and elbows (Gottron's sign). Flat-topped, polygonal, violaceous papules over the knuckles (Gottron's papules) are less common but highly characteristic of DM (Fig. 8-18). Hyperkeratosis, scaling, fissuring, and hyperpigmentation over the fingertips, sides of the thumb, and fingers, with occasional involvement of the palms,



**Fig. 8-17** Cuticular fraying of proximal nailfold.



**Fig. 8-18** Gottron's papules of dermatomyositis involving the knuckles.

is referred to as "mechanic's hands" and has been reported in 70% of patients with antisynthetase antibodies (Fig. 8-19). Intermittent fever, malaise, anorexia, arthralgia, and marked weight loss are typically present at this stage.

In some patients with disease remission, the residual hyperpigmentation simulates the bronze discoloration of Addison's disease. Rarely, large, persistent ulcerations in flexural areas or over pressure points may develop. Ulceration in the early stages of DM has been reported to be associated with a higher incidence of cancer and a poor prognosis, but the authors have seen many patients with ulcerative DM without associated cancer. In later stages, ulceration may merely be a manifestation of pressure or trauma to atrophic areas. Rarely, DM may be associated with clinical findings of pityriasis rubra pilaris (Wong variant of DM) or generalized subcutaneous edema.

Calcium deposits in the skin and muscles occur in more than half of children with DM and are found infrequently in adults. Calcification is related to duration of disease activity and its severity. Calcinosis of the dermis, subcutaneous tissue, and muscle occurs mostly on the upper half of the body around the shoulder girdle, elbows, and hands. Ulcerations and cellulitis are frequently associated with this debilitating and disabling complication of DM.

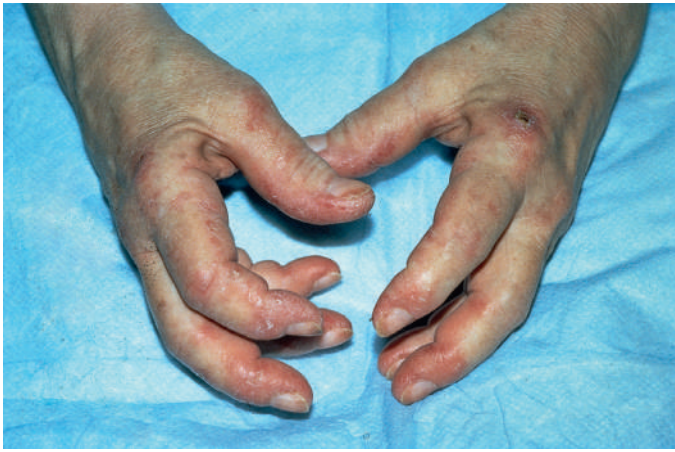

Fig. 8-19 "Mechanic's hands" in dermatomyositis.

### Muscle changes

In patients with severe DM, early and extensive muscular weakness occurs, with acute swelling and pain. The muscle weakness is seen symmetrically, most frequently involving the shoulder girdle and sometimes the pelvic region, as well as the hands. The patients may notice difficulty in lifting even the lightest objects. They may be unable to raise their arms to comb their hair, and rising from a chair may be impossible without "pushing off" with the arms. Patients often complain of pain in the legs when standing barefoot or of being unable to climb stairs. Difficulty in swallowing, talking, and breathing, caused by weakness of the involved muscles, may be noted early in the disease. Some patients with severe diaphragmatic disease require mechanical ventilation. Cardiac failure may be present in the terminal phase of the disease.

Skin involvement frequently precedes muscle involvement, but some patients have typical skin findings of DM but never develop clinically apparent muscle involvement. These cases have been termed amyopathic DM or DM sine myositis. However, muscle inflammation often is present but not symptomatic, and the term hypomyopathic is preferred. Muscle enzymes (to include both creatine kinase [CK] and aldolase), electromyography (EMG), and magnetic resonance imaging (MRI) may be required to detect subtle involvement.

### Diagnostic criteria

The following criteria are used to define DM/PM:

- Skin lesions
- Heliotrope rash (red-purple edematous erythema on upper palpebra)
- Gottron's papules or sign (red-purple flat-topped papules, atrophy, or erythema on extensor surfaces and finger joints)
- Proximal muscle weakness (upper or lower extremity and trunk)
- Elevated serum CK or aldolase level
- Muscle pain on grasping or spontaneous pain
- Myogenic changes on EMG (short-duration, polyphasic motor unit potentials with spontaneous fibrillation potentials)
- Positive anti-Jo-1 (histidyl tRNA synthetase) antibody
- Nondestructive arthritis or arthralgias
- Systemic inflammatory signs (fever  $>37^{\circ}\text{C}$  at axilla, elevated serum CRP level or accelerated ESR of  $>20$  mm/h by Westergren method)

- Pathologic findings compatible with inflammatory myositis

Patients with the first criterion, skin lesions, and four of the remaining criteria have DM. Patients lacking the first criterion but with at least four of the remaining criteria have PM. Some patients with DM have little evidence of myopathy, and drug eruptions may mimic the characteristic rash. In particular, hydroxyurea has been associated with a DM like eruption. Antisynthetase antibody syndrome presents with variable systemic manifestations, mainly PM, interstitial lung disease, cutaneous lesions, and Raynaud phenomenon.

### Associated diseases

Dermatomyositis may overlap with other connective tissue diseases. Sclerodermatous changes are the most frequently observed; this is called sclerodermatomyositis. Antibodies such as anti-Ku and anti-PM/scl may be present in this subgroup. Mixed connective tissue disease associated with high anti-ribonucleoprotein (RNP), RA, LE, and Sjögren syndrome may occur concomitantly. DM may be associated with interstitial lung disease, which is frequently the cause of death. The presence of anti-Jo-1 antibody, as well as other antisynthetase antibodies, such as anti-PL-7, anti-PL-12, anti-DJ, and anti-EJ, correlates well with the development of pulmonary disease. Even patients without anti-Jo-1 should routinely be screened for interstitial lung disease (ILD) because up to 69% of ILD patients are seronegative for the anti-Jo-1 antibody in published reports.

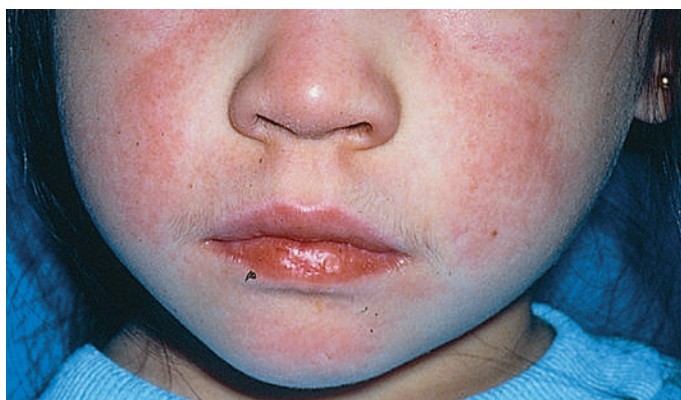### Neoplasia with dermatomyositis

In adults, malignancy is frequently associated with DM. The malignancy is discovered before, simultaneously, or after the DM at near-equal rates. The highest probability of finding an associated tumor occurs within 2 years of the diagnosis. Factors associated with malignancy include age, constitutional symptoms, rapid onset of DM, lack of Raynaud phenomenon, and a grossly elevated ESR or CK level. Malignancy is most frequently seen in patients in the fifth and sixth decades of life. Routine "age-appropriate screening" may be inadequate to uncover a significant number of malignancies. In addition to history and physical examination, a stool guaiac test for occult blood (Hemoccult), mammography, pelvic examination, chest radiography, and computed tomography (CT) scans of the abdominal, pelvic, and thoracic areas may be indicated. Periodic rescreening may be of value, but the appropriate interval for screening has not been established. The presence of leukocytoclastic vasculitis might indicate a higher potential for malignancy.

### Childhood dermatomyositis

Several features of childhood dermatomyositis differ from the adult form. Two childhood variants exist. The more common Brunsting type has a slow course, progressive weakness, calcinosis, and steroid responsiveness (Fig. 8-20). Calcinosis may involve intermuscular fascial planes or may be subcutaneous. The second type, the Banker type, is characterized by a vasculitis of the muscles and GI tract, rapid onset of severe weakness, steroid unresponsiveness, and high mortality. Internal malignancy is seldom seen in children with either type, but insulin resistance may be present. Calcinosis cutis is more common in children with severe disease.





**Fig. 8-20** Childhood dermatomyositis.

## Etiology

Evidence indicates that muscle findings in DM are related to humoral immunity, a vasculopathy mediated by complement deposition, lysis of endomysial capillaries, and resulting muscle ischemia. In contrast, PM and inclusion-body myositis are related to clonally expanded CD8+ cytotoxic T cells invading muscle fibers and causing necrosis through the perforin pathway. The initial immune response in DM is an IFN- $\alpha$ / $\beta$ -induced cascade with secondary stimulation of IFN- $\gamma$ . Many autoantibodies may be present in DM, some of which are disease specific and can identify specific subgroups. In addition to the antisynthetase antibodies previously discussed, the anti-Mi-2 antibody is present in some patients with acute onset of classic DM and a good prognosis.

Both healthy individuals and children with juvenile DM may demonstrate persistence of maternal microchimerism, but the incidence is higher in children with juvenile DM. This has also been demonstrated in patients with other connective tissue diseases, such as scleroderma. The finding may be an epiphenomenon or may be part of a pathogenic alloimmune response. An inherited predisposition has been demonstrated, and studies of juvenile DM gene expression have shown DQA1\*0501 in 85% of patients.

Viral or bacterial infections may produce an abnormal immune response, and human herpesvirus 6 reactivation has been reported. Fulminant disease may be related to an endotheliotropic viral infection. Epitopes of group A  $\beta$ -hemolytic streptococcal M protein have sequence homology with myosin and can elicit both cell-mediated cytotoxicity and TNF- $\alpha$  production when incubated with mononuclear cells from children with active juvenile DM. The TNF- $\alpha$ -308A allele is associated with increased TNF- $\alpha$  synthesis in juvenile DM patients and with increased thrombospondin 1 and small-vessel occlusion. Interestingly, as with LE, DM can be induced by anti-TNF biologic agents. In adults with PM and DM, endothelial damage occurs early. Pathogenic factors in adults include IL-1 $\alpha$ , transforming growth factor (TGF)- $\beta$ , and myoblast production of IL-15. Cases associated with terbinafine may be related to apoptosis induced by the drug.

## Incidence

The disease is twice as prevalent in women as in men and four times as common in black as in white patients. There is a bimodal peak, the smaller one seen in children and the larger peak in adults age 40–65.

## Histopathology

The histologic changes in DM are similar to those of LE. The two may be indistinguishable, although lesions of DM tend to become atrophic more often. Lesions typically demonstrate thinning of the epidermis, hydropic degeneration of the basal layer, BMZ thickening, papillary dermal edema, and a perivascular and periadnexal lymphocytic infiltrate in the superficial and deep dermis with increased dermal mucin. Scattered melanophages are present in the superficial dermis. Compared with LE, DM shows less eccrine coil involvement and fewer vertical columns of lymphocytes in fibrous tract remnants. Subcutaneous lymphoid nodules and panniculitis are rarely seen in DM. Characteristic changes are found in the muscles. The deltoid, trapezius, and quadriceps muscles seem to be almost always involved and are good biopsy sites. Muscle bundles demonstrate lymphoid inflammation and atrophy, which preferentially affects the periphery of the muscle bundle. Muscle biopsy is directed to those areas found to be most tender or in which EMG demonstrates myopathy. MRI is a useful aid in identifying active sites for muscle biopsy and may obviate the need for biopsy in some cases. The short T1 inversion recovery (STIR) MR images are best and can be used to localize disease and longitudinally assess results of treatment.

## Laboratory findings

The serum CK levels are elevated in most patients. Aldolase, lactic dehydrogenase (LDH), and transaminases (ALT, AST) are other indicators of active muscle disease. There may be leukocytosis, anemia with low serum iron, and an increased ESR. Positive ANA tests are seen in 60–80% of patients if a human diploid substrate is used; 35–40% have myositis-specific antibodies.

Cutaneous DIF is positive in at least one third of cases, with a higher yield in well-established lesion (at least 3–6 months old). Cytooid bodies are often seen, although continuous granular staining with IgG, IgM, and IgA may be seen.

X-ray studies with barium swallow may show weak pharyngeal muscles and a collection of barium in the piriform sinuses and valleculae. MRI of the muscles is an excellent way to assess activity of disease noninvasively.

The EMG studies for diagnosis show spontaneous fibrillation, polyphasic potential with voluntary contraction, short duration potential with decreased amplitude, and salvos of muscle stimulation.

## Differential diagnosis

Dermatomyositis must be differentiated from erysipelas, SLE, angioedema, drug eruptions, trichinosis, and EM. Aldosteronism, with adenoma of adrenal glands and hypokalemia, may also cause puffy heliotrope eyelids and face. Hydroxyurea may produce an eruption resembling DM.

## Treatment

Prednisone is the mainstay of acute treatment for DM patients, at doses beginning with 1 mg/kg/day, until severity decreases and muscle enzymes are almost normal. The dosage is reduced with clinical response. The aspartate transaminase (AST, SGOT)/alanine transaminase (ALA/SGOT) and CK return to normal levels as remission occurs. Methotrexate and MMF are used as steroid-sparing agents and should be started early in

the course of treatment to reduce steroid side effects. Because of the increased risk of ILD with methotrexate, some avoid this agent in patients with pulmonary disease or anti-Jo-1 antibodies. Azathioprine is less expensive than MMF, but skin disease may not respond as well. If patients do not respond adequately to methotrexate, MMF, or azathioprine, a trial of IVIG (1 g/kg/day for 2 days each month), cyclosporine, or tacrolimus may be beneficial. IVIG has been associated with thromboembolic events, including deep venous thrombosis, pulmonary embolism, myocardial infarction, and cerebrovascular accident (stroke), and this risk must be weighed against the benefits of the drug. Anti-TNF- $\alpha$  treatment with infliximab has proved a rapidly effective therapy for some patients with myositis. Etanercept has also been used, but some studies have found little improvement or flares of muscle disease. Because anti-TNF therapy has been shown to induce DM in the setting of RA, patients should be monitored carefully. Cyclophosphamide is generally reserved for refractory cases. Leflunomide, an immunomodulatory drug used to treat RA, has been effective as adjuvant therapy.

In severe juvenile DM, pulse IV methylprednisone (30 mg/kg/day) or oral prednisone are effective for acute management, but some data suggest that corticosteroids may not be necessary in many children treated with methotrexate or IVIG. Rituximab appears promising in the treatment of refractory disease. Onset of calcinosis is associated with delays in diagnosis and treatment, as well as longer disease duration. Calcinosis related to DM has been treated with aluminum hydroxide, diphosphonates, diltiazem, probenecid, colchicine, low doses of warfarin, and surgery with variable, but usually poor, results. Autologous stem cell transplantation has been reported as successful, and polymyxin B-immobilized fiber column treatment has been reported as successful for rapidly progressive ILD.

The skin lesions may respond to systemic therapy; however, response is unpredictable, and skin disease may persist despite involution of the myositis. Because DM is photosensitive, sunscreens with high SPF (>30) should be used daily, and patients should be counseled about sun avoidance. Topical corticosteroids may be helpful in some patients. Antimalarials such as hydroxychloroquine at 200–400 mg/day (2–5 mg/kg/day in children) have been shown to be useful in abating the eruption of DM, although adverse cutaneous reactions are common. Non-life-threatening cutaneous reactions occur in approximately one third of patients, and up to one half of those who react to hydroxychloroquine will also react to chloroquine. In pregnant patients who require treatment, evidence supports the use of topical corticosteroids and topical calcineurin inhibitors. Published evidence also suggests that systemic corticosteroids, hydroxychloroquine, and azathioprine may be used in pregnancy when necessary. Evidence supporting the use of rituximab, IVIG, dapsone, phototherapy, and plasmapheresis consists only of case reports or clinical experience.

## Prognosis

Major causes of death in DM patients are cancer, ischemic heart disease, and lung disease. Independent risk factors include failure to induce clinical remission, white blood cell count above 10000/mm<sup>3</sup>, temperature greater than 38°C (100.4°F) at diagnosis, older age, shorter disease history, and dysphagia. Early aggressive therapy in juvenile cases is associated with a lower incidence of disabling calcinosis cutis. Anti-Ro-52 and anti-melanoma differentiation-associated gene 5 antibody (anti-MDA5) are markers for ILD. Anti-Jo-1 may correlate more strongly with pulmonary alterations in PM.

- Broccolo F, et al:** Selective reactivation of human herpesvirus 6 in patients with autoimmune connective tissue diseases. *J Med Virol* 2013; 85(11):1925–1934.
- Callen JP:** Cutaneous manifestations of dermatomyositis and their management. *Curr Rheumatol Rep* 2010; 12(3):192–197.
- Chen Z, et al:** Utility of anti-melanoma differentiation-associated gene 5 antibody measurement in identifying patients with dermatomyositis and a high risk for developing rapidly progressive interstitial lung disease: a review of the literature and a meta-analysis. *Arthritis Care Res (Hoboken)* 2013; 65(8):1316–1324.
- Choy E, et al:** Immunosuppressant and immunomodulatory treatment for dermatomyositis and polymyositis. *Cochrane Database Syst Rev* 2005; (3):CD003643.
- Femia AN, et al:** Cutaneous dermatomyositis: an updated review of treatment options and internal associations. *Am J Clin Dermatol* 2013; 14(4):291–313.
- Ghirardello A, et al:** Autoantibodies in polymyositis and dermatomyositis. *Curr Rheumatol Rep* 2013; 15(6):335.
- Holzer U, et al:** Successful autologous stem cell transplantation in two patients with juvenile dermatomyositis. *Scand J Rheumatol* 2010; 39(1):88–92.
- Mira-Avendano IC, et al:** A retrospective review of clinical features and treatment outcomes in steroid-resistant interstitial lung disease from polymyositis/dermatomyositis. *Respir Med* 2013; 107(6):890–896.
- Nagappa M, et al:** Efficacy and limitations of pulse cyclophosphamide therapy in polymyositis and dermatomyositis. *J Clin Neuromuscul Dis* 2013; 14(4):161–168.
- Nakashima R, et al:** Anti-MDA5 (melanoma differentiation-associated gene 5) antibody and dermatomyositis with rapidly progressive interstitial pneumonia. *Nihon Rinsho Meneki Gakkai Kaishi* 2013; 36(2):71–76.
- Nalotto L, et al:** Rituximab in refractory idiopathic inflammatory myopathies and antisynthetase syndrome: personal experience and review of the literature. *Immunol Res* 2013; 56(2/3):362–370.
- Sasaki O, et al:** A case of polymyxin B-immobilized fiber column treatment for rapidly progressive interstitial pneumonia associated with clinically amyopathic dermatomyositis. *Case Rep Med* 2013; 2013:750275.
- Shimizu M, et al:** Cutaneous calcinosis in juvenile dermatomyositis. *J Pediatr* 2013; 163(3):921.
- Uribe L, et al:** Antisynthetase antibody syndrome: case report and review of the literature. *Clin Rheumatol* 2013; 32(5):715–719.

## SCLERODERMA

Scleroderma is characterized by the appearance of circumscribed or diffuse, hard, smooth, ivory-colored areas that are immobile and give the appearance of hidebound skin. It occurs in both localized and systemic forms. Cutaneous types may be categorized as morphea (localized, generalized, profunda, atrophic, and pansclerotic types) or linear scleroderma (with or without melorheostosis or hemiatrophy). Progressive systemic sclerosis (PSS) and the Thibierge-Weissenbach syndrome (usually called CREST syndrome) are the two types of systemic scleroderma.

### Cutaneous types

#### Localized morphea

The morphea form of scleroderma is twice as common in women as men and occurs in childhood as well as adult life. It presents most often as macules or plaques a few centimeters in diameter, but also may occur as bands or in guttate lesions or nodules. Rose or violaceous macules may appear first, followed by smooth, hard, somewhat depressed, yellowish white



or ivory lesions. The lesions are most common on the trunk but also occur on the extremities.

The margins of the areas are generally surrounded by a lilac border or by telangiectases. Within the patch, skin elasticity is lost, and when it is picked up between the thumb and index finger, it feels rigid. The follicular orifices may be unusually prominent, leading to a condition that resembles pigskin.

In guttate morphea, multiple small, chalk-white, flat or slightly depressed macules occur over the chest, neck, shoulders, or upper back. The lesions are not very firm and may be difficult to separate clinically from guttate lichen sclerosus et atrophicus (LSA).

### Morphea–lichen sclerosus et atrophicus overlap

Some patients present with lesions of both morphea and LSA, typically women with widespread morphea who have LSA lesions separated from morphea or overlying morphea. When the changes are seen above dermal changes of morphea, the characteristic inflammatory lymphoid band of LSA is lacking, suggesting that the superficial homogenization is actually a manifestation of morphea rather than a separate disease process.

### Generalized morphea

Widespread involvement by indurated plaques with pigmentary change characterizes generalized morphea. Muscle atrophy may be present, but no visceral involvement (Fig. 8-21). Patients may lose their wrinkles as a result of the firmness and contraction of skin. Spontaneous involution is less common with generalized morphea than with localized lesions.

### Atrophoderma of Pasini and Pierini

In 1923, Pasini described a peculiar form of atrophoderma now thought to be in the spectrum of morphea. The disease consists of brownish gray, oval, round or irregular, smooth atrophic lesions depressed below the level of the skin, with a well-demarcated, sharply sloping border. Some of the appearance of depression is an optical illusion related to the color change. Atrophoderma occurs mainly on the trunk of young, predominantly female, patients (Fig. 8-22). The lesions are usually asymptomatic and may measure 20 cm or more in diameter. Linear atrophoderma of Moulin is a related condition that follows lines of Blaschko.

Biopsies of atrophoderma demonstrate a reduction in the thickness of the dermal connective tissue. Some widening and hyalinization of collagen bundles may be noted. Because the changes may be subtle, a biopsy should include normal-appearing skin so that a comparison may be made.

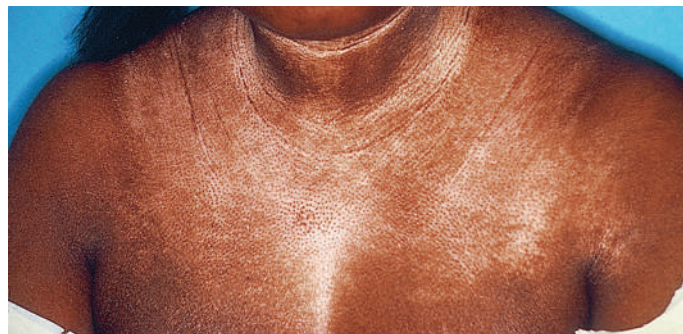

Fig. 8-21 Generalized morphea.

### Pansclerotic morphea

Pansclerotic morphea manifests as sclerosis of the dermis, panniculus, fascia, muscle, and at times the bone. The patient has disabling limitation of joint motion.

### Morphea profunda

Morphea profunda involves deep subcutaneous tissue, including fascia. There is clinical overlap with eosinophilic fasciitis, eosinophilia myalgia syndrome, and the Spanish toxic oil syndrome. The latter two conditions were related to contaminants found in batches of tryptophan or cooking oil. Unlike eosinophilic fasciitis, morphea profunda shows little response to corticosteroids and tends to run a more chronic debilitating course.

### Linear scleroderma

These linear lesions may extend the length of the arm or leg and may follow lines of Blaschko. The condition often begins during the first decade of life. Lesions may also occur parasagittally on the frontal scalp and extend partly down the forehead (en coup de sabre; Fig. 8-23). The Parry-Romberg syndrome, which manifests as progressive hemifacial atrophy, epilepsy, exophthalmos, and alopecia, may be a form of linear scleroderma. When the lower extremity is involved, there may be associated spina bifida, faulty limb development, hemiatrophy, or flexion contractures. Melorheostosis, seen on radiographs as a dense, linear cortical hyperostosis, may occur. At times, linear lesions of the trunk merge into more generalized involvement. Physical therapy of the involved limb is of paramount importance to prevent contractures and frozen joints.

### Systemic types

#### CREST syndrome

This variant of systemic scleroderma has the most favorable prognosis because of the usually limited systemic involvement. Patients with CREST syndrome develop calcinosis cutis,

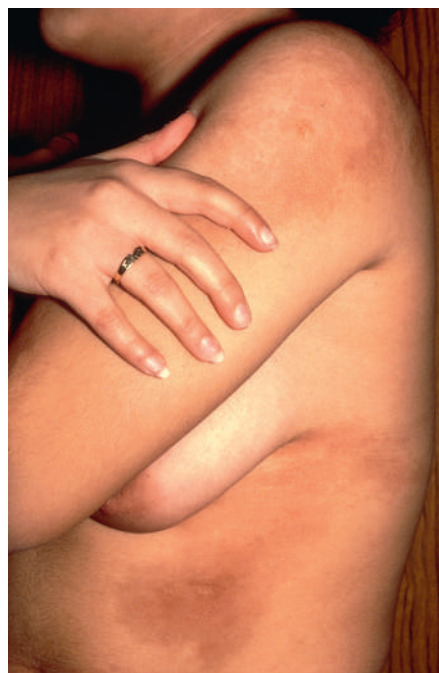
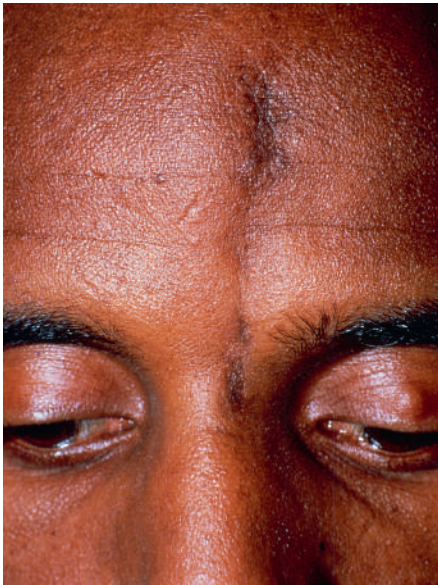
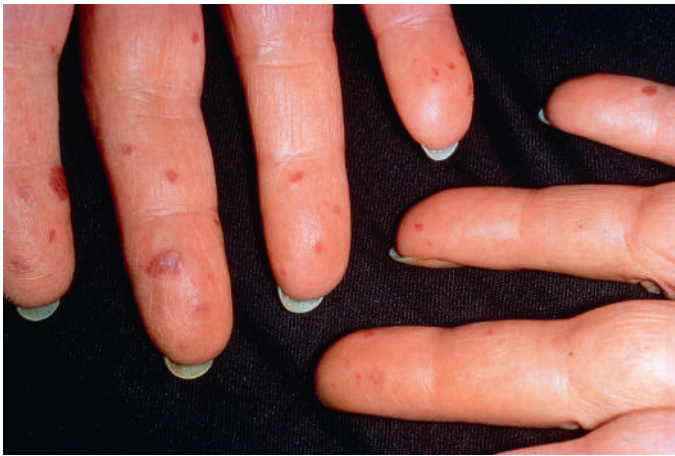Fig. 8-22 Atrophoderma of Pasini and Pierini.



**Fig. 8-23** En coup de sabre.



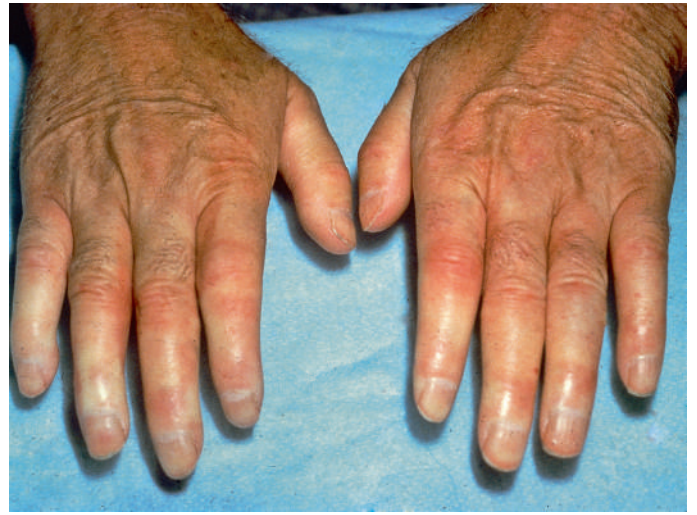**Fig. 8-24** Calcinosis in CREST syndrome.

Raynaud phenomenon, esophageal dysmotility, sclerodactyly, and telangiectasia (Fig. 8-24). Patients may present with sclerodactyly, severe heartburn, or telangiectatic mats. The mats tend to have a smooth outline, in contrast to the mats of the Osler-Weber-Rendu syndrome, which tend to exhibit an irregular outline with more radiating vessels. This form of scleroderma generally lacks serious renal or pulmonary involvement. Anticentromere antibodies are highly specific for the CREST syndrome, being positive in 50–90% of cases and only 2–10% of patients with progressive sclerosis.

### Progressive systemic sclerosis

Progressive systemic sclerosis (PSS) is a generalized disorder of connective tissue in which there is thickening of dermal collagen bundles, as well as fibrosis and vascular abnormalities in internal organs. Raynaud phenomenon is the first manifestation of PSS in more than half the cases. Other patients present with “woody edema” of the hands. The heart, lungs, GI tract, kidney, and other organs are frequently involved. Women are affected three times more often than men, with peak age of onset between the third and fifth decades.

Classic criteria include either proximal sclerosis or two or all of the following:



**Fig. 8-25** Sclerodactyly.

1. Sclerodactyly (Fig. 8-25)
2. Digital pitting scars of the fingertips or loss of substance of the distal finger pad
3. Bilateral basilar pulmonary fibrosis

Localized forms of scleroderma must be excluded. These criteria have been shown to be 97% sensitive and 98% specific for the diagnosis. The ACR has proposed an expanded list of criteria for PSS, as follows:

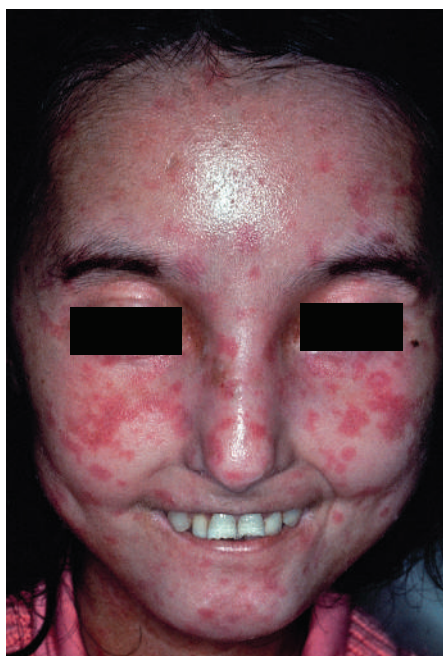1. *Skin changes*: tightness, thickening, and nonpitting induration, sclerodactyly, proximal scleroderma; changes proximal to the metacarpophalangeal or metatarsophalangeal joints and affecting other parts of the extremities, face, neck, or trunk (thorax or abdomen), digital pitting, loss of substance from the finger pad, bilateral firm but pitting finger or hand edema, abnormal skin pigmentation (often “pepper and salt”). The changes are usually bilateral and symmetric and almost always include sclerodactyly.
2. *Raynaud phenomenon*: at least two-phase color change in fingers and often toes consisting of pallor, cyanosis, and reactive hyperemia
3. *Visceral manifestations*: bibasilar pulmonary fibrosis not attributable to primary lung disease, lower (distal) esophageal dysphagia, lower (distal) esophageal dysmotility, colonic sacculations

### Skin findings

In the earlier phases of scleroderma, affected areas are erythematous and swollen. Patients are frequently misdiagnosed as having carpal tunnel syndrome and may even have positive EMG results. Raynaud phenomenon is often present and suggests the correct diagnosis. Over time, sclerosis supervenes. The skin becomes smooth, yellowish, and firm and shrinks so that the underlying structures are bound down. The earliest changes often occur insidiously on the face and hands, and in more advanced stages, these parts become “hidebound,” so the face is expressionless, the mouth is constricted (Fig. 8-26), and the hands are clawlike. The facial skin appears drawn, stretched, and taut, with loss of lines of expression. The lips are thin, contracted, and radially furrowed; the nose appears sharp and pinched; and the chin may be puckered. The “neck sign” is described as a ridging and tightening of the neck on extension, occurring in 90% of patients with scleroderma.

The disease may remain localized to the hands and feet for long periods (acrosclerosis). The fingers become semiflexed,





**Fig. 8-26** Facial involvement in scleroderma.

immobile, and useless, the overlying skin hard, inelastic, incompressible, and pallid. The terminal phalanges are board-like and indurated. In the “round finger-pad sign,” the fingers lose their normal peaked contour and appear as rounded hemispheres when viewed from the side. This process may lead to loss of pulp on the distal digit. Trophic ulcerations and gangrene may occur on the tips of the fingers and knuckles, which may be painful or insensitive. In pterygium inversum unguis, the distal part of the nail bed remains adherent to the ventral surface of the nail plate; it may be seen in scleroderma and LE or may be idiopathic. Dilated nailfold capillary loops are present in 75% of systemic scleroderma patients. Symmetrically dilated capillaries are seen adjacent to avascular areas. Nailfold capillary hemorrhage in two or more fingers is highly specific for scleroderma and correlates with the anti-centromere antibody.

Keloidlike nodules may develop on the extremities or the chest, and there may be a widespread diffuse calcification of the skin, as shown by radiographs. A diffuse involvement of the chest may lead to a cuirasslike restraint of respiration. Late in the course of the disorder, hyperpigmented or depigmented spots or a diffuse bronzing may be present. The most characteristic pigmentary change is a loss of pigment in a large patch with perifollicular pigment retention within it. Perifollicular pigmentation may appear in response to UV light exposure. Pigment may also be retained over superficial blood vessels. The affected areas become hairless, and atrophy is often associated with telangiectasia. Bullae and ulcerations may develop, especially on the distal parts of the extremities.

### **Internal involvement**

Sclerosis may involve most of the internal organs. Esophageal involvement is seen in more than 90% of PSS patients; the distal two thirds of the esophagus is affected, leading to dysphagia and reflux esophagitis. Small intestinal atonia may lead to constipation, malabsorption, or diarrhea. Pulmonary fibrosis with arterial hypoxia, dyspnea, and productive cough may be present. Progressive nonspecific interstitial fibrosis, with bronchiectasis and cyst formation, is the most frequent pathologic change. Pulmonary hypertension and right-sided heart failure are ominous signs, occurring in 5–10% of patients. The cardiac involvement produces dyspnea and other symptoms of congestive heart failure. Sclerosis of the myocardium also

produces conduction changes and may result in arrhythmia. Pericarditis, hypertension, and retinopathy may be present.

The skeletal manifestations include articular pain, swelling, and inflammation. Polyarthritis may be the first symptom in PSS. There is limitation of motion as a result of skin tautness, followed by ankylosis and severe contractual deformities. The hand joints are involved most frequently. There may be resorption and shortening of the phalanges and narrowing of the joint spaces. Osteoporosis and sclerosis of the bones of the hands and feet may occur, as well as decalcification of the vault of the skull.

Childhood PSS has identical cutaneous manifestations. Raynaud phenomenon occurs less often, whereas cardiac wall involvement is more common and is responsible for half of deaths. Renal disease is unusual. Familial scleroderma rarely occurs.

### **Prognosis**

The course of PSS is variable. Renal disease accounts for some early mortality, but pulmonary disease remains the major cause of death. The patient's age at disease onset is a significant risk factor for pulmonary arterial hypertension. Cardiac disease also correlates with a poor prognosis, whereas GI involvement contributes mainly to morbidity. ANA patterns predict different subsets of disease with varying prognosis. Anticentromere antibodies correlate with CREST syndrome and a good prognosis, whereas Scl-70 and ANA correlate with a poorer prognosis. Malignancy may be associated with PSS in up to 10% of patients, with lung and breast cancer the most frequent associated malignancies. The presence of many telangiectases is strongly associated with the presence of pulmonary vascular disease.

### **Laboratory findings**

In PSS, ANA testing is positive in more than 90% of patients. As noted, several of these antibodies identify specific clinical subsets of patients. The antinucleolar pattern is considered most specific for scleroderma, and when present as the only pattern, it is highly specific for scleroderma. When antibodies to such nucleolar antigens as RNA polymerase *t* and fibrillarin are present, diffuse sclerosis, generalized telangiectasia, and internal organ involvement are often seen. The homogeneous ANA pattern is seen in patients with PM-Scl antibodies, the marker for PM-scleroderma overlap. The true speckled or anti-centromere pattern is sensitive and specific for the CREST variant. Patients with antibodies to Scl-70 tend to have diffuse truncal involvement, pulmonary fibrosis, and digital pitted scars, but a lower incidence of renal disease. Antibodies to nuclear RNP are found in patients with Raynaud phenomenon, polyarthralgia, arthritis, and swollen hands. Very high RNP titers define mixed connective tissue disease. These patients are fairly homogeneous and the term is not synonymous with connective tissue overlap. Anti-ssDNA antibodies are common in linear scleroderma. Anti-Rpp25 chemiluminescence and anti-Th/To by immunoprecipitation correlate with limited cutaneous and internal involvement. Cryoglobulins are only found in about 3% of patients with PSS, but the presence of cryoglobulinemic vasculitis is associated with a poor prognosis.

### **Radiographic findings**

The GI tract is usually involved. The esophagus may have decreased peristalsis and dilation. Esophagography and esophageal manometry may be helpful. In early esophageal involvement, a barium swallow in the usual upright position may be reported as normal. If the patient is supine, however, barium will often be seen to pool in the flaccid esophagus. The stomach may be dilated and atonic, resulting in delayed

emptying time. Involvement of the small intestine may cause extreme dilation of the duodenum and jejunum, producing a characteristic radiographic picture of persistently dilated intestinal loops long after the barium has passed through. Colonic or small intestinal sacculations may be present.

## Histology

Systemic and localized forms of scleroderma show similar histologic changes, although lymphoid infiltrates tend to be heavier in the acute phase of morphea. In the acute phase, there is a perivascular lymphocytic infiltrate with plasma cells that is heaviest at the junction of the dermis and subcutaneous fat. Collagen bundles become hyalinized, and the space between adjacent bundles is lost. Loss of CD34+ dermal dendritic cells is an early finding.

Dermal sclerosis typically results in a rectangular punch biopsy specimen. As the dermis replaces the subcutaneous tissue, eccrine glands appear to be in the midportion of the thickened dermis. The subcutaneous fat is quantitatively reduced, and adventitial fat (fat that normally surrounds adnexal structures on trunk) is lost. Collagen abuts directly on the adnexal structures. Elastic fibers in the reticular dermis may be prominent and stain bright red, and the papillary dermis may appear pale and edematous. In advanced lesions, the inflammatory infiltrate may be minimal. Pilosebaceous units are absent, and eccrine glands and ducts are compressed by surrounding collagen.

On DIF testing of skin, the nucleolus may be stained in the keratinocytes if antinucleolar circulating antibodies are present. A “pepper-dot” epidermal nuclear reaction pattern may be seen in CREST patients who have anticentromere antibodies in their serum.

## Differential diagnosis

Myxedema is softer and associated with other signs of hypothyroidism. Diabetic scleredema tends to be erythematous and affects the central back in a pebbly pattern. Scleromyxedema begins with discrete papules but may assume an appearance similar to PSS. A paraprotein is typically present. Sclerodactyly may be confused with digital changes of Hansen’s disease and syringomyelia. Eosinophilic fasciitis is more steroid responsive. The skin is thickened, edematous, and erythematous and has a coarse, peau d’orange appearance, unlike its sclerotic, taut appearance in scleroderma. The hands and face are usually spared in eosinophilic fasciitis, and when the arms are involved, the blood vessels draw inward when the arms are raised, producing a “dry riverbed” appearance.

In vitiligo, the depigmentation is the sole change in the skin, and sclerosis is absent. Scleroderma in the atrophic stage may closely resemble acrodermatitis chronica atrophicans (ACA), but ACA shows more attenuation of collagen fibers and a diffuse lymphohistiocytic infiltrate. Lyme titers may be positive.

Dermal fibrosis is a major feature of chronic, sclerodermoid graft-versus-host disease (GVHD), porphyria cutanea tarda, phenylketonuria, carcinoid syndrome, juvenile-onset diabetes, progeria, and the Werner, Huriez, and Crow-Fukase (POEMS) syndromes. Occupational exposure to silica, epoxy resins, polyvinyl chloride (PVC), and vibratory stimuli (jackhammer or chainsaw) may produce sclerodermoid conditions. Chemicals (e.g., PVC), bleomycin, isoniazid, pentazocine, valproate sodium, epoxy resin vapor, vitamin K (after injection), contaminated Spanish rapeseed oil (toxic oil syndrome), contaminated tryptophan (eosinophilia-myalgia syndrome),

nitrofurantoin, and hydantoin may also induce various patterns of fibrosis. The “stiff skin syndrome,” also known as congenital fascial dystrophy, is characterized by stony-hard induration of the skin and deeper tissues of the buttocks, thighs, and legs, with joint limitation and limb contractures. The disease begins in infancy. Scleroderma-like symptoms may be the presenting features of multiple myeloma and amyloidosis. IgG4-related disease presents with soft tissue sclerosis, elevated serum IgG4, and increased IgG4-positive plasma cells in a variety of tissues.

## Pathogenesis

The pathogenesis of scleroderma and morphea involves vascular damage, autoimmune mechanisms, and possibly microchimerism resulting in alloimmune graft-versus-host reactions. Both anticardiolipin and anti- $\beta$ 2-glycoprotein I antibodies appear to play roles in pathogenesis. The plasma D-dimer concentration correlates with macrovascular complications. *Borrelia afzelii* and *Borrelia garinii* are related to the development of morphealike lesions in some cases. Other environmental agents may be involved. Epidemiologic studies support the role of organic solvents and certain chemicals. In women, there is an association with teaching and working in the textile industry.

The immune mechanisms involved are complex. Upregulated proteins and messenger RNAs include monocyte chemoattractant protein 1 (MCP-1), pulmonary and activation-regulated chemokine, macrophage inflammatory protein 1 (MIP-1), IL-4, IL-6, IL-8, CRP, platelet-derived growth factor receptor  $\beta$  (PDGFR- $\beta$ ), and TGF- $\beta$ , although TGF- $\beta$  has not correlated well in some studies. These factors may stimulate extracellular matrix production, TGF- $\beta$  production and activation, and chemoattraction of T cells. Various target antigens have been proposed, including a protein termed “protein highly expressed in testis” (PHET), which is ectopically overexpressed in scleroderma dermal fibroblasts. Serum antibodies to a recombinant PHET fragment have been detected in 9 (8.4%) of 107 scleroderma patients, but in none of 50 SLE patients or 77 healthy controls. The presence of anti-PHET antibodies was associated with diffuse cutaneous scleroderma and lung involvement.

The macrophage receptor protein CD163 is upregulated in scleroderma, and increased levels of soluble CD163 correlate with disease progression. Expression of CD40 is increased on fibroblasts in lesional skin, and ligation of CD40 by recombinant human CD154 results in increased production of IL-6, IL-8, and MCP-1 in a dose-dependent manner. These phenomena are not shown in normal fibroblasts with the addition of CD154. Lesion skin of early-stage scleroderma contains T cells preferentially producing high levels of IL-4. CD4+ T-helper 2 (Th2)-like cells can inhibit collagen production by normal fibroblasts and the inhibition is mediated by TNF- $\alpha$ . The inhibition is dominant over the enhancement induced by IL-4 and TGF- $\beta$ . To be inhibitory, Th2 cells require activation by CD3 ligation. Th2 cells are less potent than T-helper 1 (Th1) cells in inhibiting collagen production by normal fibroblasts, and fibroblasts from involved skin are resistant to inhibition. Etanercept has been shown to decrease serum TGF- $\beta$ 1, tissue hydroxyproline, dermal fibrosis, and the number of  $\alpha$ -SMA-positive cells. However, because Th2 cells reduce type I collagen synthesis through the effect of TNF- $\alpha$ , TNF- $\alpha$  blockade by new biologics should be approached with caution. Drug-induced morphea has been related to the cathepsin K inhibitor balicatib, used for osteoporosis. Capecitabine, an oral prodrug of 5-fluorouracil used in the treatment of metastatic colon and breast carcinoma, has been associated with a hand-foot



syndrome with sclerodactyly. Onset of systemic sclerosis with digital ulcers has been reported during IFN- $\beta$  therapy for multiple sclerosis.

## Treatment

Although effective treatment is available for many of the visceral complications of scleroderma, treatment for the skin disease remains unsatisfactory. Spontaneous improvement may be seen in some children and in some cases of localized scleroderma. Physical therapy emphasizing range of motion for all joints as well as the mouth is important. Exposure to cold is to be avoided, and smoking is forbidden. Among patients with scleroderma, smokers are three to four times more likely than never-smokers to incur digital vascular complications.

Vasodilating drugs—CCBs, angiotensin II receptor antagonists, topical nitrates, and prostanoids—remain the mainstay of medical therapy for Raynaud phenomenon. Antioxidants such as vitamin C have been used, but data are mixed. Both sildenafil (Viagra) and IV or inhaled iloprost are useful in the treatment of both pulmonary hypertension and Raynaud phenomenon. Ginkgo biloba has been shown to have some efficacy in a double-blind trial. Oral L-arginine has reversed digital necrosis in some patients with Raynaud phenomenon and improved symptoms in others. CCBs such as nifedipine (Procardia XL), 30–60 mg/day, are often used as first-line therapy. Some patients who experience worsening of esophageal reflux with nifedipine do better with diltiazem (Cardizem CD), 120–180 mg/day. Botulinum toxin, topical nitroglycerin, and simple hand warming on a regular basis may also be effective. Bosentan, an oral, dual endothelin receptor antagonist, has been effective in preventing and treating scleroderma-related ulcers, and oral treprostinil diethanolamine has been shown to improve skin perfusion in an open label trial.

Systemic corticosteroids have been used, but evidence of benefit is limited and patients must be monitored closely for scleroderma renal crisis. TNF blockade has shown some benefit in reducing fibrosis, but has also triggered onset of disease. Rituximab has resulted in resolution of limited disease associated with anti-TNF therapy. Cyclophosphamide has shown some promising results in the treatment of cutaneous disease, improving skin scores, maximal oral opening, flexion index, forced vital capacity (FVC), and carbon monoxide diffusing capacity (DLCO). Results with cyclophosphamide have been superior to those obtained with D-penicillamine. Oral methotrexate or cyclophosphamide has been used with prednisolone in some trials. Oral cyclophosphamide must be given in the morning with vigorous hydration. Many rheumatologists prefer intravenous pulse cyclophosphamide with the sulfhydryl compound mesna and hydration to reduce bladder toxicity. Cyclophosphamide has been used together with anti-thymocyte globulin and hematopoietic stem cell infusion. Other evolving therapies include agents that target TGF- $\beta$ 1 signaling, tyrosine kinase inhibitors (e.g., imatinib), and inhibitors of histone deacetylase.

Phototherapy and photochemotherapy, especially with UVA I, have also shown some efficacy. Widespread morphea has been treated with oral calcitriol, and calcipotriene may have some efficacy as a topical agent. Halofuginone, an inhibitor of collagen type I synthesis, can decrease collagen synthesis in the tight-skin mouse and murine GVHD. Application of halofuginone caused a reduction in skin scores in a pilot study with scleroderma patients. Carbon dioxide (CO<sub>2</sub>) laser vaporization has produced remission of symptoms in cutaneous calcinosis of CREST syndrome. Some data suggest that

minocycline may be effective in the control of calcinosis in systemic sclerosis. Oral type I collagen has been disappointing overall, but may be of some limited benefit for skin findings in late-phase disease.

Although there is strong evidence that the ACE inhibitors are disease-modifying for scleroderma renal crisis, better randomized controlled trials are still needed. Epoprostenol is used to treat pulmonary hypertension in scleroderma, based largely on evidence that it can be life-saving in the treatment of primary pulmonary hypertension. Other promising drugs for visceral involvement include bosentan (for pulmonary hypertension and ischemic ulcers), cyclophosphamide (for alveolitis), IFN- $\gamma$  (for interstitial pulmonary fibrosis), IV prostaglandins (for vascular disease), and sildenafil (for pulmonary hypertension and Raynaud phenomenon).

The future lies with early aggressive intervention before the development of fibrosis and organ damage. Bone marrow and nonmyeloablative allogeneic hematopoietic stem cell transplantation has shown dramatic and sustained benefits in some patients. It should be noted that increased renal and pulmonary toxicity, as well as parenchymal fibrosis, has been reported in some patients with scleroderma, and this treatment should still be considered experimental. Objective measures of improvement of skin sclerosis can be obtained by means of durometer measurements and high-resolution ultrasound. The course of microangiopathic changes can be evaluated with serial nailfold videocapillaroscopy.

**Arkachaisri T, et al:** Development and initial validation of the localized scleroderma skin damage index and physician global assessment of disease damage: a proof-of-concept study. *Rheumatology (Oxford)* 2010; 49(2):373–381.

**Bielecki M, et al:** Increased release of soluble CD163 by the peripheral blood mononuclear cells is associated with worse prognosis in patients with systemic sclerosis. *Adv Med Sci* 2013; 58(1):126–133.

**Brenner M, et al:** Phototherapy and photochemotherapy of sclerosing skin diseases. *Photodermatol Photoimmunol Photomed* 2005; 21:157.

**Chimenti MS, et al:** Resolution with rituximab of localized scleroderma occurring during etanercept treatment in a patient with rheumatoid arthritis. *Eur J Dermatol* 2013; 23(2):273–274.

**Fett N:** Scleroderma: nomenclature, etiology, pathogenesis, prognosis, and treatments: facts and controversies. *Clin Dermatol* 2013; 31(4):432–437.

**Giuggioli D, et al:** Systemic sclerosis and cryoglobulinemia: our experience with overlapping syndrome of scleroderma and severe cryoglobulinemic vasculitis and review of the literature. *Autoimmun Rev* 2013; 12(11):1058–1063.

**Ingegnoli F, et al:** Nailfold capillaroscopy in systemic sclerosis: data from the EULAR Scleroderma Trials and Research (EUSTAR) database. *Microvasc Res* 2013; 89:122–128.

**Iudici M, et al:** Glucocorticoids in systemic sclerosis: weighing the benefits and risks—a systematic review. *Clin Exp Rheumatol* 2013; 31(2 Suppl 76):157–165.

**Markatseli TE, et al:** Subcutaneous calcifications in a patient with diffuse scleroderma. *Clin Exp Rheumatol* 2013; 31(2 Suppl 76):180.

**Muangchant C, et al:** The significance of interleukin-6 and C-reactive protein in systemic sclerosis: a systematic literature review. *Clin Exp Rheumatol* 2013; 31(2 Suppl 76):122–134.

**Muro Y, et al:** What autoantibody tests should become widely available to help scleroderma diagnosis and management? *Arthritis Res Ther* 2013; 15(4):116.

**Naert A, et al:** Successful treatment with bosentan of lower extremity ulcers in a scleroderma patient. *Case Rep Med* 2013; 2013:690591.

**Reddi DM, et al:** Scleroderma and IgG4-related disease. *Am J Dermatopathol* 2013; 35(4):458–462.

**Shah AA, et al:** Telangiectases in scleroderma: a potential clinical marker of pulmonary arterial hypertension. *J Rheumatol* 2010; 37(1):98–104.

**Shah AA, et al:** My approach to the treatment of scleroderma. *Mayo Clin Proc* 2013; 88(4):377–393.

**Shah AA, et al:** Open label study of escalating doses of oral treprostinil diethanolamine in patients with systemic sclerosis and digital ischemia:

pharmacokinetics and correlation with digital perfusion. *Arthritis Res Ther* 2013; 15(2):R54.

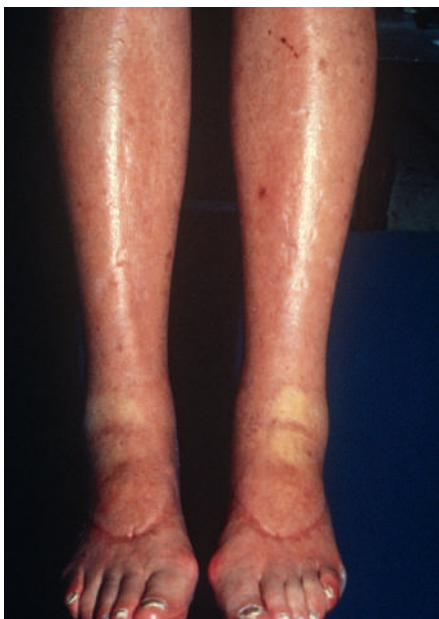**Yaqub A, et al:** Localized cutaneous fibrosing disorders. *Rheum Dis Clin North Am* 2013; 39(2):347–364.

**Zulian F, et al:** Scleroderma in children: an update. *Curr Opin Rheumatol*. 2013; 25(5):643–650.

## EOSINOPHILIC FASCIITIS

In 1974, Lawrence Shulman described a disorder that he called diffuse eosinophilic fasciitis. Classically, patients had engaged in strenuous muscular activity for a few days or weeks before the acute onset of weakness, fatigability, and pain and swelling of the extremities. The prodrome was followed by severe induration of the skin and subcutaneous tissues of the forearms and legs. A favorable response to corticosteroids was noted. Since the initial description, environmental exposures have been reported as possible triggers for the syndrome, including L-tryptophan contaminated with 1,1'-ethylidenebis, *Borrelia*, and exposure to trichloroethylene. Alterations in L-tryptophan metabolism have been described with elevated levels of L-kynurenine and quinolinic acid. Some consider this disease to be a variant of scleroderma. Polycythemia vera, metastatic colorectal carcinoma, and multiple myeloma have been associated in a limited number of patients, suggesting that some cases may represent a paraneoplastic phenomenon.

The skin is usually edematous and erythematous, with a coarse peau d'orange appearance, most noticeable inside the upper arms, thighs, or flanks. The hands and face are usually spared. When the patient holds the arms laterally or vertically, linear depressions occur within the thickened skin. This "groove sign" or "dry riverbed sign" follows the course of underlying vessels (Fig. 8-27). This contrasts with scleroderma, in which the skin remains smooth and taut. Limitation of flexion and extension of the limbs and contracture may develop, and patients are often unable to stand fully erect. In contrast to scleroderma, Raynaud phenomenon is usually absent. Associated systemic abnormalities have included carpal tunnel syndrome, peripheral neuropathy, seizures, posterior ischemic optic neuropathy, pleuropericardial effusion, pancytopenia, anemia, antibody-mediated hemolytic anemia,



**Fig. 8-27** Eosinophilic fasciitis.

thrombocytopenia, Sjögren syndrome, lymphadenopathy, pernicious anemia, and IgA nephropathy. Detected cytokine abnormalities are similar to those in atopic patients, but with a striking elevation of TGF- $\beta$ 1. Considerable evidence supports a Th17-mediated pathway. ESR is generally increased, and hypergammaglobulinemia is common. Increased production of IL-5 and clonal populations of circulating T cells have been reported.

Biopsy shows a patchy lymphohistiocytic and plasma cell infiltrate in the fascia and subfascial muscle, with massive thickening of the fascia and deep subcutaneous septa. Peripheral blood eosinophilia of 10–40% is the rule, but eosinophils may or may not be present in the affected fascia. The inflammatory infiltrate is mainly composed of macrophages and lymphocytes, often with a CD8+ T lymphocyte predominance. Few eosinophils are typically present in tissue, although they may be numerous in some cases. Cytotoxic CD8+ T lymphocytes may be demonstrated by granzyme B staining. Major histocompatibility complex (MHC) class I antigens are upregulated in muscle fibers, but MHC class II antigens are not usually expressed by muscle fibers. C5b9 membrane attack complex (MAC) deposits are generally not detected. CT and MRI have both been used to demonstrate fascial thickening and may obviate the need for biopsy in some cases.

The response to systemic corticosteroids is generally excellent. In responders, complete recovery is usual within 1–3 years. Some patients have also demonstrated a response to histamine blockers, including hydroxyzine and cimetidine. Patients with a prolonged course unresponsive to systemic corticosteroids are being recognized with increasing frequency. Many of these poorly responsive cases overlap with morphea profunda. In refractory cases, Plaquenil, cyclosporine, methotrexate, azathioprine, psoralen plus UVA (PUVA), bath PUVA, extracorporeal photochemotherapy, IVIG, rituximab, and other immunosuppressive regimens have been used with variable success. The increased synthesis of IL-5 may be blocked by IFN- $\alpha$ , suggesting a possible role for IFN in the treatment of this disorder. Both infliximab and IV cyclophosphamide used with moderate- to high-dose prednisolone have been reported as effective in refractory cases.

**Khanna D, et al:** Infliximab may be effective in the treatment of steroid-resistant eosinophilic fasciitis: report of three cases. *Rheumatology (Oxford)* 2010; 49(6):1184–1188.

**Kissin EY, et al:** Ultrasound assessment of subcutaneous compressibility: a potential adjunctive diagnostic tool in eosinophilic fasciitis. *J Clin Rheumatol* 2013; 19(7):382–385.

**Lebeaux D, et al:** Eosinophilic fasciitis (Shulman disease). *Best Pract Res Clin Rheumatol* 2012; 26(4):449–458.

**Tyndall A, et al:** The differential diagnosis of systemic sclerosis. *Curr Opin Rheumatol* 2013; 25(6):692–699.

## MIXED CONNECTIVE TISSUE DISEASE

Mixed connective tissue disease (MCTD) is defined by the presence of Raynaud phenomenon, arthralgias, swollen joints, esophageal dysfunction, muscle weakness, and sausage-like appearance of the fingers, together with the presence of high titer anti-RNP antibodies in the absence of anti-Sm antibodies. The term is not synonymous with "overlap syndrome," a combination of diseases in which each disease complies with the diagnostic criteria for that disorder. Also, MCTD is not synonymous with undifferentiated connective tissue disease (UCTD)—patients with connective tissue disease who have not yet developed a defined disease. Only about 4% of patients with UCTD go on to develop MCTD.

The ANA test typically demonstrates a particulate pattern in MCTD, reflecting the high titers of nuclear RNP antibodies



(anti-RNP antibodies). This ANA pattern generally persists through periods of remission and is a valuable diagnostic test. In addition, particulate epidermal nuclear IgG deposition on DIF study of skin is a distinctive finding in MCTD. Anti-TS1-RNA antibodies appear to define a subpopulation with predominance of lupuslike clinical features. Patients with a younger age of onset and those with pulmonary hypertension, Raynaud phenomenon, and livedo reticularis have a higher risk of mortality. Causes of death include pulmonary fibrosis and pulmonary arterial hypertension, cardiovascular events, renal disease, CNS disease, thrombotic thrombocytopenic purpura, and infection.

For acute treatment, corticosteroids such as prednisone (1 mg/kg/day) are effective for inflammatory features such as arthritis and myositis. As with LE, MCTD may be associated with an independent risk of osteoporosis, and the long-term morbidity associated with corticosteroid treatment can be significant. Bisphosphonate therapy and therapy with a steroid-sparing agent should be considered early. In general, the LE features of MCTD are the most likely to improve with therapy, and the scleroderma features are the least likely to improve. Generally, the prognosis is better than that of scleroderma, largely related to the lower incidence of renal disease. Small-molecule tyrosine kinase inhibitors such as imatinib, dasatinib, and nilotinib target TGF- $\beta$  and PDGF signaling and are being investigated as therapeutic options. Life-threatening complications refractory to other treatment often respond to rituximab. In the setting of thrombocytopenia, the response rate is 80%.

**Braun-Moscovici Y, et al:** Rituximab: rescue therapy in life-threatening complications or refractory autoimmune diseases: a single center experience. *Rheumatol Int* 2013; 33(6):1495–1504.

**Hajas A, et al:** Clinical course, prognosis, and causes of death in mixed connective tissue disease. *J Rheumatol* 2013; 40(7):1134–1142.

**Jovancevic B, et al:** Anti B-cell therapy against refractory thrombocytopenia in SLE and MCTD patients: long-term follow-up and review of the literature. *Lupus* 2013; 22(7):664–674.

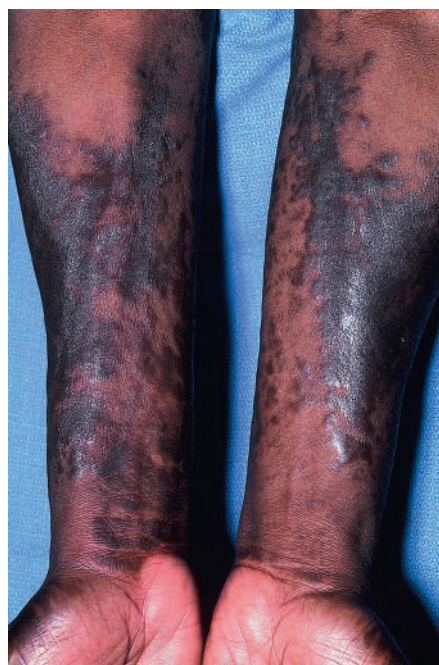**Ortega-Hernandez OD, et al:** Mixed connective tissue disease: an overview of clinical manifestations, diagnosis and treatment. *Best Pract Res Clin Rheumatol* 2012; 26(1):61–72.

**Szodoray P, et al:** Distinct phenotypes in mixed connective tissue disease: subgroups and survival. *Lupus* 2012; 21(13):1412–1422.

## NEPHROGENIC SYSTEMIC FIBROSIS

Nephrogenic systemic fibrosis (NSF) is a recently recognized fibrosing skin condition that resembles scleromyxedema histologically. It usually develops in patients with renal insufficiency on hemodialysis, although it has been noted in patients with acute renal failure who had never undergone dialysis. Epidemiologic and x-ray emission spectroscopic studies have implicated gadolinium-containing MRI contrast agents, and incidence of NSF has decreased since their use has been limited in patients with renal failure. Concurrent infection, increased serum phosphate and calcium concentrations, and acidosis may play important roles in pathogenesis. Clinical findings of NSF include thickened sclerotic or edematous papules and plaques involving the extremities and trunk (Fig. 8-28). Yellow scleral plaques and scleral telangiectasia resembling conjunctivitis have been described. Soft tissue calcification is rare but may be extensive when it occurs. Clinically, NSF differs from scleromyxedema by the lack of involvement of the face, absence of plasma cells, and lack of paraproteinemia. Systemic involvement is generally absent but may occur with fibrosis and calcification of the diaphragm, psoas muscle, renal tubules, and rete testes.

Circulating antiphospholipid antibodies have been noted in some patients. Histologic sections demonstrate plump bipolar



**Fig. 8-28**  
Hyperpigmented sclerotic plaques of nephrogenic fibrosing dermopathy.

CD34+ spindle cells with dendrites extending along both sides of elastic fibers (tram track sign), many new collagen bundles, and increased mucin. With time, thickened collagen bundles become prominent in the reticular dermis. Ossification with trapped elastic fibers appears to be fairly specific for gadolinium exposure. Myofibroblasts have been noted in lesional skin. Immunohistochemical staining for CD34 and procollagen I in the spindle cells of NFD suggests that many of the dermal cells of NFD may represent circulating fibrocytes recruited to the dermis. The CD34 positivity in NFD contrasts with the loss of CD34+ cells in morphea.

Effective therapy remains elusive. Topical retinoids, steroids, and vitamin D analogs are not effective. Immunosuppressive therapy appears to be of little benefit. In three cases evolving after liver transplantation, treatment with basiliximab, MMF, calcineurin inhibitor, and prednisone did not stop the development of “woody” skin induration of the distal extremities, erythematous papules, and contractures. The most effective treatment strategy appears to be optimization of renal function through medical therapy or transplantation. Some data support a beneficial effect from phototherapy, extracorporeal photopheresis, or IV sodium thiosulfate, tyrosine kinase inhibitors, and rapamycin. The proliferating fibrocytes of NSF express phospho-70-S6 kinase, a protein downstream from the mammalian target of rapamycin. All patients should be referred for physical therapy.

**Bhawan J, et al:** Sclerotic bodies beyond nephrogenic systemic fibrosis. *J Cutan Pathol* 2013; 40(9):812–817.

**Chen AY, et al:** Nephrogenic systemic fibrosis: a review. *J Drugs Dermatol* 2010; 9(7):829–834.

**Elmholdt TR, et al:** Antifibrotic effect after low-dose imatinib mesylate treatment in patients with nephrogenic systemic fibrosis: an open-label non-randomized, uncontrolled clinical trial. *J Eur Acad Dermatol Venereol* 2013; 27(6):779–784.

**Girardi M, et al:** Nephrogenic systemic fibrosis: clinicopathological definition and workup recommendations. *J Am Acad Dermatol* 2011; 65(6):1095–1106.

**Martin DR, et al:** Decreased incidence of NSF in patients on dialysis after changing gadolinium contrast-enhanced MRI protocols. *J Magn Reson Imaging* 2010; 31(2):440–446.

**Swaminathan S, et al:** Rapid improvement of nephrogenic systemic fibrosis with rapamycin therapy: possible role of phospho-70-ribosomal-S6 kinase. *J Am Acad Dermatol* 2010; 62(2):343–345.

Swaminathan S, et al: Gadolinium contrast agent-induced CD163(+) ferroportin(+) osteogenic cells in nephrogenic systemic fibrosis. *Am J Pathol* 2013; 183(3):796–807.

## SJÖGREN SYNDROME (SICCA SYNDROME)

Sjögren syndrome is a chronic autoimmune disorder characterized by lymphocytic infiltration of the exocrine glands, particularly the salivary and lacrimal glands. One third of patients present with extraglandular manifestations, such as vasculitis. Most patients are age 50 or older, and more than 90% are women. Secondary Sjögren syndrome is defined as xerostomia and keratoconjunctivitis sicca in patients with other connective tissue diseases. The presence of arthritis, leukopenia, proteinuria, or low complement levels suggests secondary Sjögren syndrome. These patients have lower incidences of xerostomia and ILD compared with patients who have primary Sjögren syndrome.

Xerostomia may produce difficulty in speech and eating, increased tooth decay, thrush, and decreased taste (hypogeusia). Patients frequently suck on sour candies to stimulate what little salivary secretions remain, and those unfamiliar with the condition may blame the habit of sucking lemon drops for the ensuing tooth decay. Sjögren syndrome alters the composition of saliva, producing a decrease in salivary amylase and carbonic anhydrase, along with an increase in lactoferrin,  $\beta$ 2-microglobulin, cystatin C, sodium, and lysozyme C.

Rhinitis sicca (dryness of nasal mucous membranes) may induce nasal crusting and decreased olfactory acuity (hyposmia). Vaginal dryness and dyspareunia may develop. Dry eyes are painful, feel gritty or scratchy, and produce discharge and blurry vision. Fatigue is a prominent symptom. In addition, there may be laryngitis, gastric achlorhydria, thyroid enlargement resembling Hashimoto thyroiditis, malignant lymphoma, thrombotic thrombocytopenic purpura, painful distal sensory axonal neuropathy, and splenomegaly.

Skin manifestations of Sjögren syndrome include vasculitis, xerosis, pruritus, and annular erythema. Decreased sweating occurs. Asian patients have been described who develop erythematous, indurated, annular dermal plaques, primarily on the face. This is different from the annular lesions of SCLE, which show epidermal change and histologic changes of lupus. Patients may also present with an overlap of Sjögren syndrome and LE. A common finding in these patients is Ro/SSA antibody positivity. SCLE patients with Sjögren syndrome have a worse prognosis than patients with SCLE not associated with Sjögren syndrome.

Patients with Sjögren syndrome and cutaneous vasculitis also have a significant incidence of peripheral, renal, or CNS vasculitis. Cutaneous vasculitis may present as purpura of the legs, which may be palpable or nonpalpable. Sjögren vasculitis accounts for most patients with Waldenström benign hypergammaglobulinemic purpura; about 30% of these patients will have or will develop Sjögren syndrome, and a high percentage have SSA and SSB antibodies. Other cutaneous vascular manifestations are urticarial vasculitis, digital ulcers, and petechiae. Histologically, a leukocytoclastic vasculitis is found at the level of the postcapillary venule, with expansion of the vascular wall, fibrin deposition, and karyorrhexis, but no necrosis of the endothelium.

Labial salivary gland biopsy from inside the lower lip is usually regarded as the most definitive test for Sjögren syndrome. Typically, there is a dense lymphocytic infiltrate with many plasma cells and fewer histiocytes in aggregates within minor salivary glands. More than one focus of 50 or more lymphocytes is typically present per 4 mm<sup>2</sup> of the tissue biopsy. Lymphoepithelial islands predominate early, whereas

glandular atrophy predominates in the late stages. At this stage, few lymphoid aggregates are present. Xerostomia is diagnosed by the Schirmer test and reflects diminished glandular secretion from the lacrimal glands. Imaging studies are also helpful.

Classically, the diagnosis is made when there is objective evidence for two of three major criteria: (1) xerophthalmia, (2) xerostomia, and (3) an associated autoimmune, rheumatic, or lymphoproliferative disorder. These criteria may be too restrictive, however, because patients are increasingly being identified with predominantly extraglandular disease. The lack of sicca symptoms or anti-SSA or anti-SSB antibodies does not exclude Sjögren syndrome. Numerous serologic abnormalities are associated with Sjögren syndrome or its associated conditions. Antibodies to fodrin, a major component of the membrane cytoskeleton of most eukaryotic cells, are present in some populations with primary and secondary Sjögren syndrome. IgA and IgG antibodies against  $\alpha$ -fodrin are detected in 88% and 64%, respectively, in some studies. In other populations, fodrin antibodies are less helpful. About 80% of patients have anti-Ro/SSA antibodies; half as many have anti-La/SSB antibodies. The rheumatoid factor is usually positive, and elevated ESR, serum globulin, and CRP and high titers of IgG, IgA, and IgM are common. Cryoglobulins may be demonstrated. Dendritic cells are increased in tissue during the early phases of the disease.

The aquaporin family of water channels (proteins freely permeated by water but not protons) appears to be an important target in the pathogenesis of Sjögren syndrome. Both duct and secretory cells are targets for the activation of CD4+ T cells. IL-12 and IFN- $\gamma$  are upregulated. It appears that Th1 cytokines mediate the functional interactions between antigen-presenting cells (APCs) and CD4+ T cells in early lesions.

Patients with Sjögren syndrome are predisposed to the development of lymphoreticular malignancies, especially non-Hodgkin B-cell lymphoma. Both malignant and nonmalignant extraglandular lymphoproliferative processes occur. Cases of pseudolymphoma have the potential for regression or for progression to overt B-cell lymphoma. Patients with palpable purpura, low C4, and mixed monoclonal cryoglobulinemia are at higher risk for lymphoma.

The differential diagnosis of Sjögren syndrome includes sarcoidosis, lymphoma, amyloidosis, and human immunodeficiency virus (HIV) disease. HIV produces diffuse infiltrative lymphocytosis syndrome (DILS), which is characterized by massive parotid enlargement; prominent renal, lung, and GI manifestations; and a low frequency of autoantibodies.

Treatment for Sjögren syndrome has largely been symptomatic, but disease-modifying therapy is also becoming a reality. Artificial lubricants are helpful for eye symptoms as well as oral, nasal, and vaginal dryness. Topical lubricants are useful for xerosis. In hot climates, patients with impaired sweating must be counseled to avoid heatstroke. Pharmacologic agents, such as pilocarpine and cevimeline, are helpful to stimulate salivation. These agents may also have a role in the treatment of dry eyes. Topical cyclosporine looks promising for local treatment of Sjögren syndrome, as does topical human IFN therapy for oral lesions. In all trials, mechanical stimulation by the lozenge may play a significant role in improvement of symptoms, as reflected in a high placebo response. Acid maltose lozenges are less expensive and remain useful for symptomatic relief. For patients with systemic disease, biologic TNF inhibitors such as infliximab show some promise. Pilocarpine, in doses of 10 mg/day, has been shown to have a beneficial effect on subjective eye symptoms, as well as improvement of rose bengal staining. An increase in tear production, as measured by the Schirmer-I test, was not substantiated. Gene therapy also looks promising, at least in animal



models. IL-10 genes can be transferred by adenovirus vectors and can have disease-modifying effects in the salivary glands of a mouse model. Severe systemic vasculitis causing renal disease has responded to corticosteroids with or without cyclophosphamide. Mycophenolate sodium and rituximab have both been used to treat severe manifestations associated with Sjögren syndrome. Rituximab has proved effective in double-blind RCTs, and rituximab plus cyclophosphamide, vincristine, and prednisone have been used to treat Sjögren syndrome-associated B-cell non-Hodgkin lymphoma.

**Dong L, et al:** Possible mechanisms of lymphoma development in Sjögren's syndrome. *Curr Immunol Rev* 2013; 9(1):13–22.

**Huang YF, et al:** The immune factors involved in the pathogenesis, diagnosis, and treatment of Sjögren's syndrome. *Clin Dev Immunol* 2013; 2013:160491.

**Lieberman SM:** Childhood Sjögren syndrome: insights from adults and animal models. *Curr Opin Rheumatol* 2013; 25(5):651–657.

**Mavragani CP, et al:** New advances in the classification, pathogenesis and treatment of Sjögren's syndrome. *Curr Opin Rheumatol* 2013; 25(5):623–629.

**Nocturne G, et al:** Advances in understanding the pathogenesis of primary Sjögren's syndrome. *Nat Rev Rheumatol* 2013; 9(9):544–556.

**Yang Y, et al:** The clinical and laboratory characteristics of Sjögren's syndrome that progresses to systemic lupus erythematosus: a retrospective case-control study. *Int J Rheum Dis* 2013; 16(2):173–177.

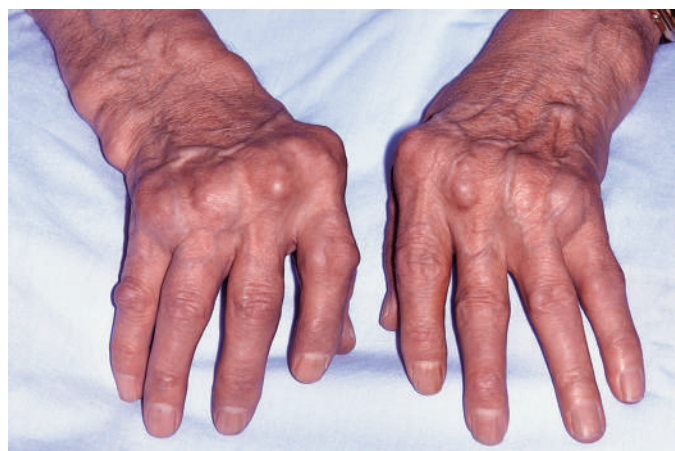## RHEUMATOID ARTHRITIS

The majority of skin manifestations of rheumatoid arthritis are the result of neutrophil-mediated injury. There may be annular erythemas, purpura, bullae, shallow ulcers, and gangrene of the extremities. Many diseases have been reported to occur in association with RA, such as erythema elevatum diutinum, pyoderma gangrenosum, Felty syndrome, IgA vasculitis, linear IgA disease, Sjögren syndrome, bullous pemphigoid, and yellow nail syndrome. Treatment of RA with disease-modifying drugs has reduced the burden of destructive disease for patients. Biologic agents are being used with increasing frequency, although traditional drugs such as methotrexate still have a role. In patients with RA, tuberculin skin testing and INF- $\gamma$  release assay testing are less sensitive compared with controls. Both may be advisable before initiating therapy with anti-TNF agents.

Methotrexate-treated RA patients have an increased incidence of melanoma, as well as non-Hodgkin lymphoma, and lung cancer. The disease itself predisposes to infections (e.g., papillomavirus), which should be followed for development of cutaneous lesions. Of interest to dermatologists, extracts from the *Rhus* family of plants have shown some benefit in limited studies. Ofatumumab, a new anti-CD20 human monoclonal antibody, has shown promise in early clinical trials.

### Rheumatoid nodules

Subcutaneous nodules are seen in 20–30% of patients (Fig. 8-29). They may arise anywhere on the body but most frequently are found over the bony prominences, especially on the extensor surface of the forearm just below the elbow and the dorsal hands. The lesions are nontender, firm, skin-colored, round nodules, which may or may not be attached to the underlying tissue. Frequently, they are attached to the fibrous portions of the periarticular capsule, or they may be free in the subcutaneous tissue. Rheumatoid nodules can easily be mistaken for xanthomas because of a yellow color (pseudoxanthomatous variant). They also occur in 5–7% of patients with SLE, especially around small joints of the hands. Rheumatoid factor (RF) may or may not be present. Histologic examination of the



**Fig. 8-29** Rheumatoid nodules.

rheumatoid nodule shows intensely staining foci of fibrin surrounded by histiocytes in palisade arrangement. Neutrophils and neutrophilic debris may be noted in association with the fibrin, and over time, the surrounding histiocytes are replaced by fibrosis.

Rheumatoid nodules are differentiated from Heberden nodes, which are tender, hard, bony exostoses on the dorso-lateral aspects of the distal interphalangeal joints of patients with degenerative joint disease. Nodules or tophi of gout are characterized by masses of feathery urate crystals surrounded by a chronic inflammatory infiltrate often containing foreign body giant cells.

Rarely, RA patients present with multiple ulcerated nodules and high RF, but no active joint disease. This variant of rheumatoid disease without destructive joint disease is designated “rheumatoid nodulosis.”

### Rheumatoid vasculitis

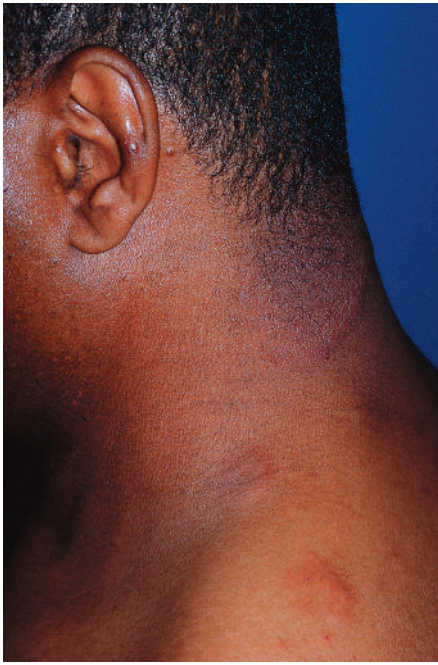Peripheral vascular lesions appear as typical features of RA. These are localized purpura, cutaneous ulceration, and gangrene of the distal parts of the extremities. Additionally, papular lesions located primarily on the hands have been described as rheumatoid papules. These show a combination of vasculitis and palisading granuloma formation. An RF is typically present. Peripheral neuropathy is frequently associated with the vasculitis. The presence of rheumatoid nodules may help to distinguish these lesions of vasculitis from SLE, polyarteritis nodosa, Buerger's disease (thromboangiitis obliterans), and the dysproteinemias. Prednisone and cytotoxic agents are frequently used, as in other forms of vasculitis. Rituximab has also been used successfully.

### Rheumatoid neutrophilic dermatosis

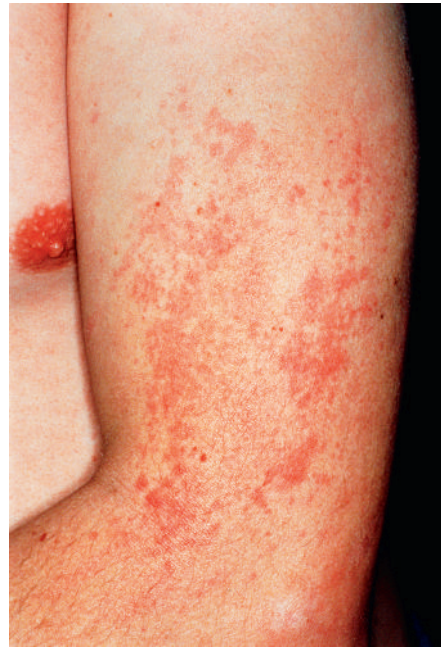Chronic urticaria-like plaques characterized histologically by a dense neutrophilic infiltrate have been described in patients with debilitating RA (Fig. 8-30). The differential diagnosis includes erythema elevatum diutinum and Sweet syndrome.

### Related palisading granulomas

Interstitial granulomatous dermatitis with arthritis is a condition with a range of clinical presentations. It can present with round to oval erythematous or violaceous plaques on the flanks, axillae, inner thighs, and lower abdomen. Linear,



**Fig. 8-30** Rheumatoid neutrophilic dermatosis presents with urticarial plaques.



**Fig. 8-31** Evanescent eruption of Still's disease.

slightly red or skin-colored cords extending from the upper back to the axilla may occur. The presence of these linear bands has been called the “rope sign.” When the lesions resolve, they may leave behind hyperpigmentation and a slightly wrinkled appearance. Arthritis may occur before, during, or after the eruption and tends to affect multiple joints of the upper extremities. Although patients do not have a well-defined associated connective tissue disease, some cases are associated with LE or other autoimmune diseases. Some presentations are paraneoplastic, associated with a range of solid and hematopoietic tumors.

Histologically, a moderate to dense inflammatory infiltrate is seen through the reticular dermis, composed mostly of histiocytes distributed interstitially around discrete bundles of sclerotic collagen. Variable numbers of neutrophils and eosinophils are seen. Mucin, necrobiosis, vasculitis, and vacuolar change are usually absent or mild. The eruption is typically asymptomatic and may spontaneously involute after many months or years. If therapy is required, intralesional corticosteroids, methotrexate, etanercept, ustekinumab, tocilizumab, and cyclosporine have been used.

Palisaded neutrophilic and granulomatous dermatitis is usually associated with a well-defined connective tissue disease, usually LE or RA. It often presents with eroded or ulcerated, symmetrically distributed umbilicated papules or nodules on the elbows, knuckles, and knees. The biopsy may reveal leukocytoclastic vasculitis and collagen degeneration in early lesions or palisaded granulomatous infiltrates with dermatofibrosis and scant neutrophilic debris in older lesions.

Methotrexate-induced papular eruption appears in patients with rheumatic diseases during methotrexate therapy. They present with erythematous indurated papules, usually located on the proximal extremities. Histopathologic examination reveals an inflammatory infiltrate composed of histiocytes interstitially arranged between collagen bundles of the dermis, intermingled with few neutrophils. At times, small rosettes composed of clusters of histiocytes surrounding a thick, central collagen bundle are present in the deep reticular dermis.

**Leloup P, et al:** Ustekinumab therapy for severe interstitial granulomatous dermatitis with arthritis. *JAMA Dermatol* 2013; 149(5):626–627.

**Marmor S, et al:** Lupus-erythematosus-associated interstitial granulomatous dermatitis. *Dermatol Online J* 2012; 18(12):31.

**Martínez-Martínez M, et al:** Cutaneous papillomavirus infection in patients with rheumatoid arthritis or systemic lupus erythematosus: a case-control study. *Lupus* 2013; 22(9):948–952.

**Moyano Almagro B, et al:** Interstitial granulomatous dermatitis and arthritis revealing oesophageal carcinoma. *Clin Exp Dermatol* 2013; 38(5):501–503.

**O'Shea JJ, et al:** Janus kinase inhibitors in autoimmune diseases. *Ann Rheum Dis* 2013; 72(Suppl 2):111–115.

**Peroni A, et al:** Interstitial granulomatous dermatitis: a distinct entity with characteristic histological and clinical pattern. *Br J Dermatol* 2012; 166(4):775–783.

**Schanz S, et al:** Interstitial granulomatous dermatitis with arthritis responding to tocilizumab. *Arch Dermatol* 2012; 148(1):17–20.

**Song GG, et al:** Interferon-gamma release assays versus tuberculin skin testing in patients with rheumatoid arthritis. *Int J Rheum Dis* 2013; 16(3):279–283.

**Walling HW:** Interstitial granulomatous dermatitis associated with chronic inflammatory demyelinating polyneuropathy. *Cutis* 2012; 90(1):30–32.

### Juvenile rheumatoid arthritis (juvenile idiopathic arthritis)

Juvenile rheumatoid arthritis (JRA) is not a single disease but a group of disorders characterized by arthritis and young age of onset. The subset called Still's disease accounts for only 20% of the patients. It shows skin manifestations in about 40% of young patients age 7–25 years. An eruption consisting of evanescent, nonpruritic, salmon-pink, macular, or papular lesions on the trunk and extremities may precede the onset of joint manifestations by many months (Fig. 8-31). Neutrophilic panniculitis has been described. The systemic symptoms of fever and serositis usually recur over weeks each afternoon. Most patients remit permanently by adulthood. IL-1 $\beta$ , IL-6, and IL-18 are implicated in the pathogenesis of JRA, as are phagocyte-specific S100-proteins, such as S100A8, S100A9, and S100A12. Steroid-sparing agents are useful to decrease steroid-associated toxicity. The dose-response curve for methotrexate plateaus with parenteral administration of 15 mg/m<sup>2</sup>/week. The full therapeutic effect may not be evident for 12 months. Refractory disease has been treated with pulse methylprednisolone, tocilizumab, and cyclophosphamide. Anakinra has shown modest efficacy.



**Lequerré T, et al:** Interleukin-1 receptor antagonist (anakinra) treatment in patients with systemic-onset juvenile idiopathic arthritis or adult onset Still disease: preliminary experience in France. *Ann Rheum Dis* 2008; 67(3):302–308.

**Zhang X, et al:** Clinical pharmacology of tocilizumab for the treatment of systemic juvenile idiopathic arthritis. *Expert Rev Clin Pharmacol* 2013;6(2):123–137.

## Fibroblastic rheumatism

Fibroblastic rheumatism is characterized by bilateral distal polyarthritis, flexion contractures, cutaneous nodules, sclerodactylitis, thickened palmar fascia, and Raynaud phenomenon. Biopsy demonstrates a fibroblastic proliferation with a collagenous stroma varying from smooth muscle actin-positive cellular fascicles to paucicellular areas with randomly arranged spindle or stellate cells. Elastic fibers are typically absent. Standard therapy includes immunosuppressive agents, typically methotrexate and oral corticosteroids, although some patients have responded to physical therapy without immunosuppressive treatment. Interferon has also been used.

**Jurado SA, et al:** Fibroblastic rheumatism: a report of 4 cases with potential therapeutic implications. *J Am Acad Dermatol* 2012; 66(6):959–965.

**Parida JR, et al:** An unusual case of polyarthritis, skin nodules and patchy skin thickening: fibroblastic rheumatism. *Int J Rheum Dis* 2012; 15(1):e12–e14.

**Trotta F, et al:** Multicentric reticulohistiocytosis and fibroblastic rheumatism. *Best Pract Res Clin Rheumatol* 2012; 26(4):543–557.

## Paraneoplastic rheumatism

Paraneoplastic syndromes resembling adult Still's disease have been associated with a variety of neoplasms, including gastric carcinoma, lung carcinoma, and lymphoma. Patients with new onset of rheumatologic disease should be screened for signs and symptoms suggesting neoplasm.

## Symmetric synovitis

Symmetric seronegative synovitis is an idiopathic form of arthritis sometimes associated with idiopathic edema. Symmetric synovitis may also be a manifestation of Blau syndrome, an early-onset granulomatous disease with symmetric arthritis and recurrent uveitis, related to the caspase recruitment domain gene *CARD15/NOD2* and considered by some to be a form of early-onset sarcoidosis.

**Alias A, et al:** Rheumatology and oncology: an updated review of rheumatic manifestations of malignancy and anti-neoplastic therapy. *Bull NYU Hosp Joint Dis* 2012; 70(2):109–114.

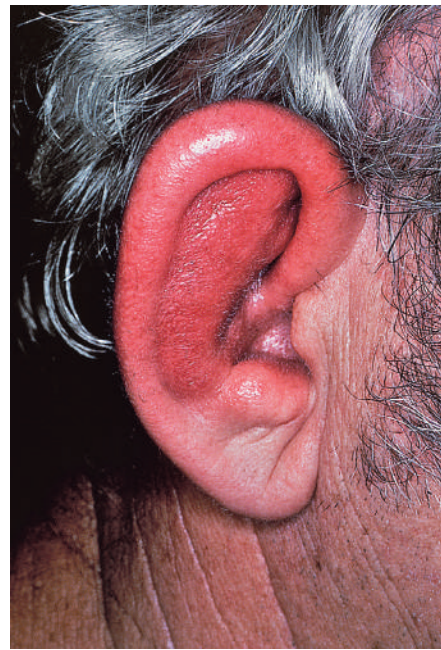**Okamoto M, et al:** A case of paraneoplastic syndrome mimicking adult Still's disease caused by rectal cancer. *J Am Geriatr Soc* 2013; 61(7):1243–1245.

**Punzi L, et al:** Miscellaneous non-inflammatory musculoskeletal conditions: Blau syndrome. *Best Pract Res Clin Rheumatol* 2011; 25(5):703–714.

**Serrano Ostoa B, et al:** Remitting symmetric seronegative synovitis with pitting edema (RS3PE). *Rheumatol Clin* 2012; 8(3):156–157.

## RELAPSING POLYCHONDritis

Relapsing polychondritis is characterized by intermittent episodes of inflammation of the articular and nonarticular cartilage resulting in chondrolysis and collapse of the involved



**Fig. 8-32** Relapsing polychondritis characteristically involves cartilaginous portions of the ear but spares the lobe.

cartilage. The course of the disease is chronic and variable, with episodic flares. Both genders are equally affected, with age at onset usually in the fourth to fifth decade. Dissolution of the cartilage involves the ears, nose, and respiratory tract. During bouts of inflammation, the bright-red involvement of the ears is confined to the cartilaginous portion while the earlobes remain conspicuously normal (Fig. 8-32). The affected areas are swollen and tender. There may be conductive deafness as a result of the obstruction produced by the swollen cartilage. The nasal septal cartilage is similarly involved to produce rhinitis, with crusting and bleeding and eventually saddle nose. Involvement of the bronchi, larynx, and epiglottis produces hoarseness, coughing, and dyspnea. Migratory arthralgia and atypical chest pain are often present. Patients evaluated for chest pain are often released without treatment and with a diagnosis of costochondritis. Ocular disease most often presents as conjunctivitis, scleritis, or iritis. Perforation of the globe may occur. Complete heart block has been reported as a presenting sign. The MAGIC syndrome is a combination of Behçet's disease and relapsing polychondritis (mouth and genital ulcers with inflamed cartilage).

Cell-mediated immunity to cartilage has been demonstrated in vitro, with a degree of response correlated with disease activity. IgG anti-type II collagen antibodies have been documented, again in titers corresponding with disease activity. Elevations in ESR, CRP levels, and urinary type II collagen neoepitope levels correlate with disease activity. A second connective tissue disease or other autoimmune disease is present in about one third of patients with relapsing polychondritis, and some cases appear to be paraneoplastic, occurring in association with hematopoietic malignancies. Limited data suggest that serum levels of Th1 cytokines (IFN- $\gamma$ , IL-12, IL-2) may correlate better with disease activity than those of Th2 cytokines (IL-4, IL-5, IL-6, IL-10).

Histologically, a predominantly neutrophilic infiltrate is noted in the perichondrium. Varying degrees of chondrolysis may be present. DIF often demonstrates a lupuslike, continuous granular band of immunoglobulin and complement in the perichondrium.

Dapsone, 100 mg once or twice daily for an adult, reduces the frequency of flares but is usually inadequate to control relapsing polychondritis. Colchicine, leflunomide, or hydroxychloroquine may also be helpful. Systemic corticosteroids

should be used to treat acute flares, but most patients require a steroid-sparing immunosuppressive drug. Azathioprine, methotrexate, MMF, cyclophosphamide, TNF- $\alpha$  inhibitors, IVIG, anakinra, tocilizumab, and rituximab have been used, but only about half of the patients experienced a good response. Sustained response to etanercept has been reported, even after failure to respond to infliximab. Endobronchial ultrasonography has been used to facilitate the diagnosis of relapsing polychondritis and estimate the size of the involved airway for placement of stents.

**Arnaud L, et al:** The Relapsing Polychondritis Disease Activity Index: development of a disease activity score for relapsing polychondritis. *Autoimmun Rev* 2012; 12(2):204–209.

**Chopra R, et al:** Relapsing polychondritis. *Rheum Dis Clin North Am* 2013; 39(2):263–276.

**Kemta Lekpa F, et al:** Biologics in relapsing polychondritis: a literature review. *Semin Arthritis Rheum* 2012; 41(5):712–719.

**McCarthy EM, et al:** Treatment of relapsing polychondritis in the era of biological agents. *Rheumatol Int* 2010; 30(6):827–828.



Bonus images for this chapter can be found online at [expertconsult.inkling.com](http://expertconsult.inkling.com)

**eFig. 8-1** Discoid lupus erythematosus.

**eFig. 8-2** Ear involvement with discoid lupus erythematosus.

**eFig. 8-3** Lower eyelid lesion of discoid lupus erythematosus.

**eFig. 8-4** Discoid lupus erythematosus.

**eFig. 8-5** Dyspigmentation and scarring of discoid lupus erythematosus.

**eFig. 8-6** Hypertrophic lupus erythematosus of the lip.

**eFig. 8-7** Characteristic palmar involvement in lupus-lichen planus overlap syndrome.

**eFig. 8-8** Annular lesions of subacute cutaneous lupus erythematosus.

**eFig. 8-9** Psoriasiform subacute cutaneous lupus erythematosus.

**eFig. 8-10** Annular erythematous lesions of neonatal lupus erythematosus.

**eFig. 8-11** Periocular neonatal lupus erythematosus.

**eFig. 8-12** Palmar erythema in systemic lupus erythematosus.

**eFig. 8-13** Lupus hair; short, miniaturized hairs affecting the anterior hairline.

**eFig. 8-14** Bullous lupus erythematosus.

**eFig. 8-15** Scalp erythema in dermatomyositis.

**eFig. 8-16** Poikiloderma on the trunk in dermatomyositis.

**eFig. 8-17** Dilated vessels and avascular regions in dermatomyositis.

**eFig. 8-18** Gottron's sign.

**eFig. 8-19** Calcinosis cutis in long-standing dermatomyositis.

**eFig. 8-20** Vasculitis in childhood dermatomyositis.

**eFig. 8-21** Atrophic lesions of dermatomyositis involving the knuckles.

**eFig. 8-22** Morphea.

**eFig. 8-23** Linear scleroderma presents with induration and pigmentary change.

**eFig. 8-24** Scleroderma.

**eFig. 8-25** Calcinosis in CREST syndrome.

**eFig. 8-26** Scarring, loss of finger pad substance, and pterygium inversum unguis.

**eFig. 8-27** Pterygium inversum unguis in progressive systemic sclerosis.

**eFig. 8-28** Ulceration of the fingertip.

**eFig. 8-29** Eosinophilic fasciitis, "dry riverbed sign."

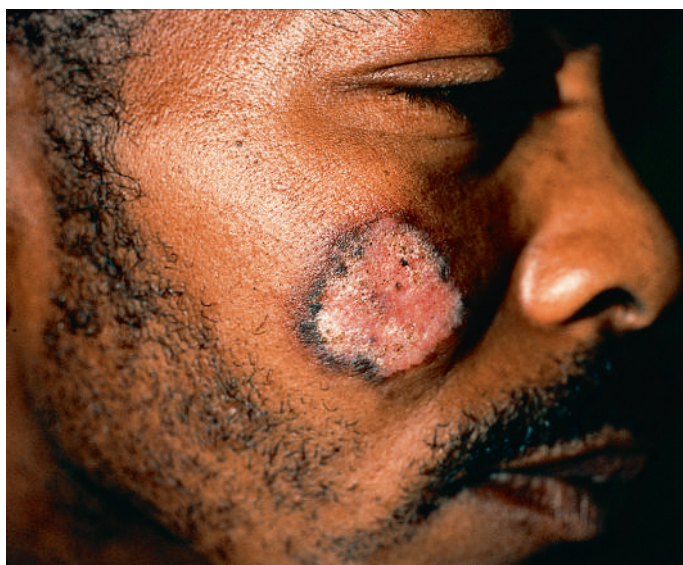**eFig. 8-30** Mucosal ulcerations in mixed connective tissue disease.

**eFig. 8-31** Rheumatoid vasculitis, frequently results in ulceration.

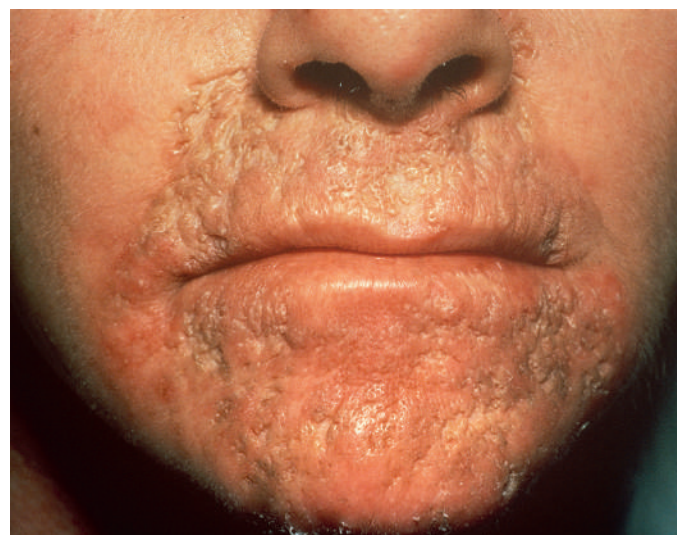**eFig. 8-32** Palisaded neutrophilic and granulomatous dermatitis.

**eFig. 8-33** Rheumatoid neutrophilic dermatosis presents with urticarial plaques.

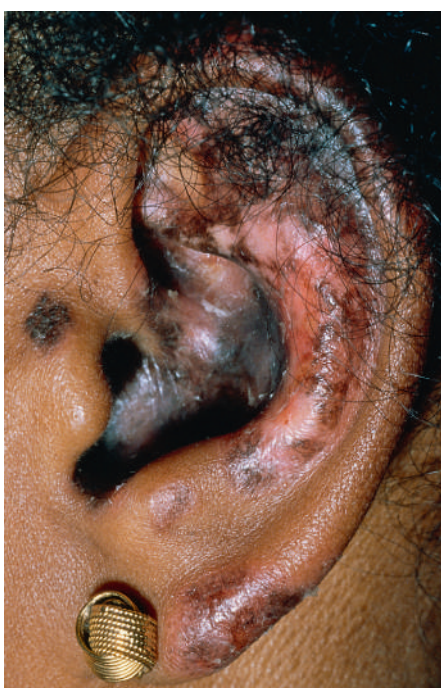



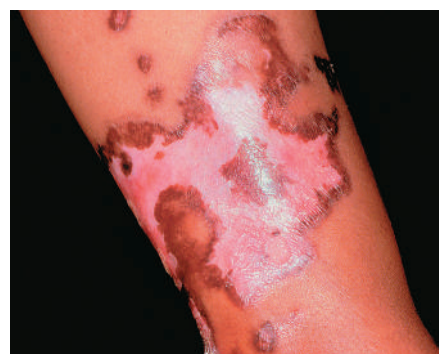
**eFig. 8-1** Discoid lupus erythematosus.



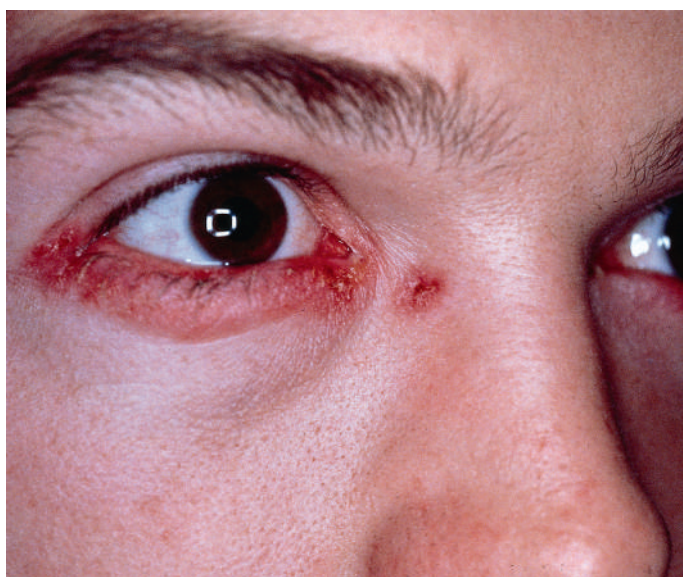**eFig. 8-4** Discoid lupus erythematosus.



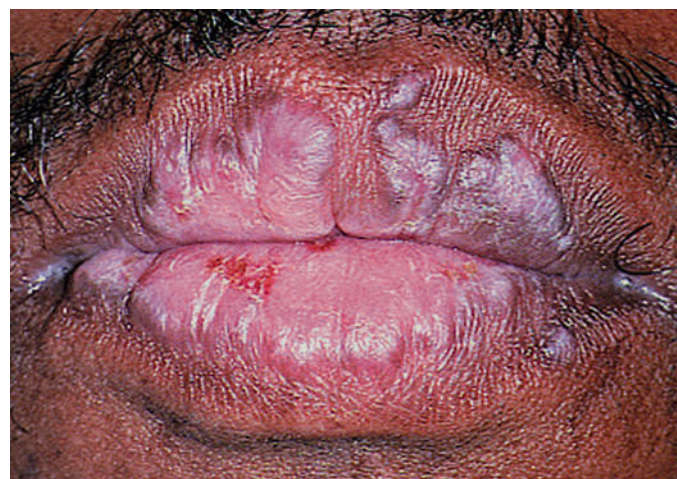**eFig. 8-2** Ear involvement with discoid lupus erythematosus.



**eFig. 8-5** Dyspigmentation and scarring of discoid lupus erythematosus.

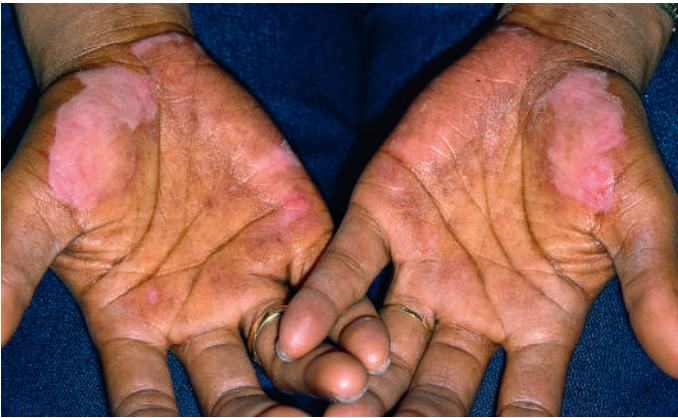

**eFig. 8-3** Lower eyelid lesion of discoid lupus erythematosus.

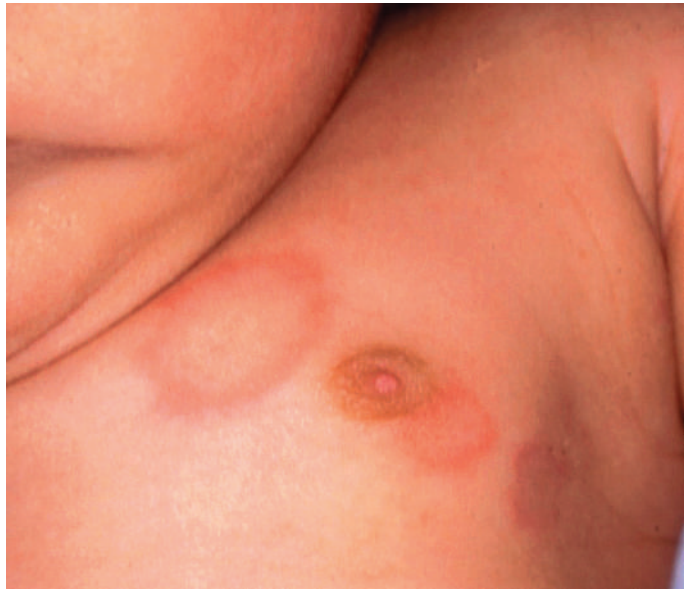

**eFig. 8-6** Hypertrophic lupus erythematosus of the lip.

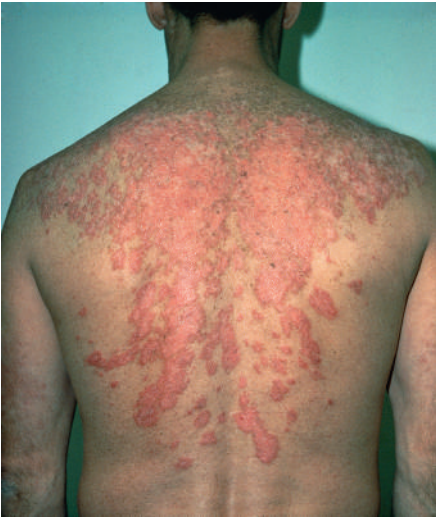



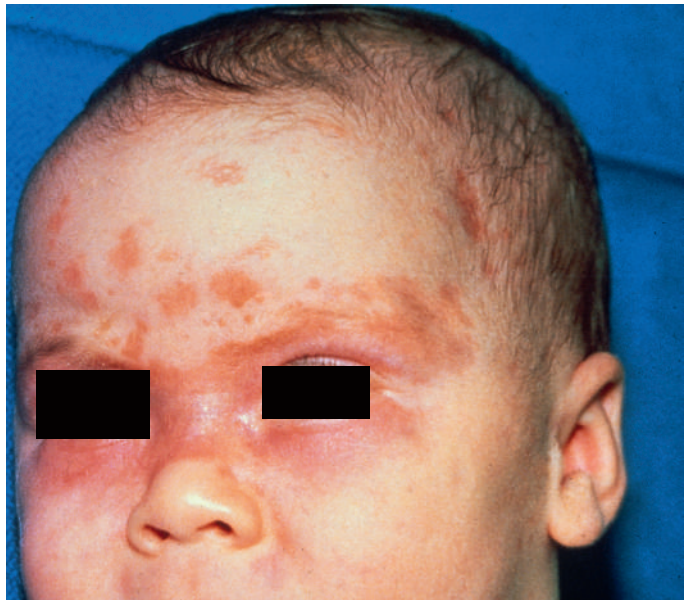**eFig. 8-7** Characteristic palmar involvement in lupus-lichen planus overlap syndrome.



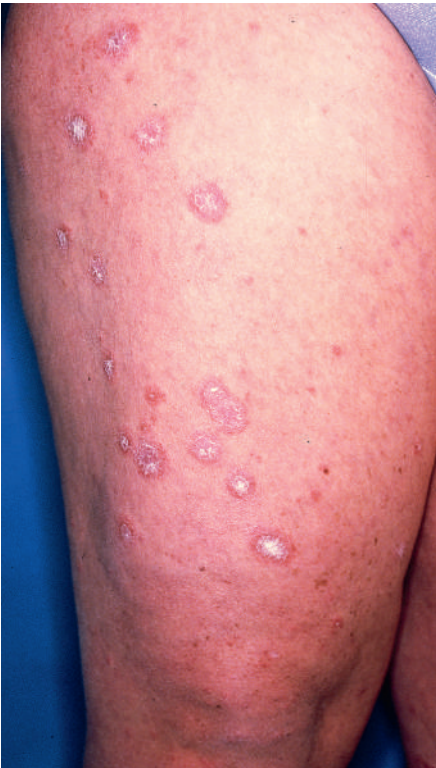**eFig. 8-10** Annular erythematous lesions of neonatal lupus erythematosus.



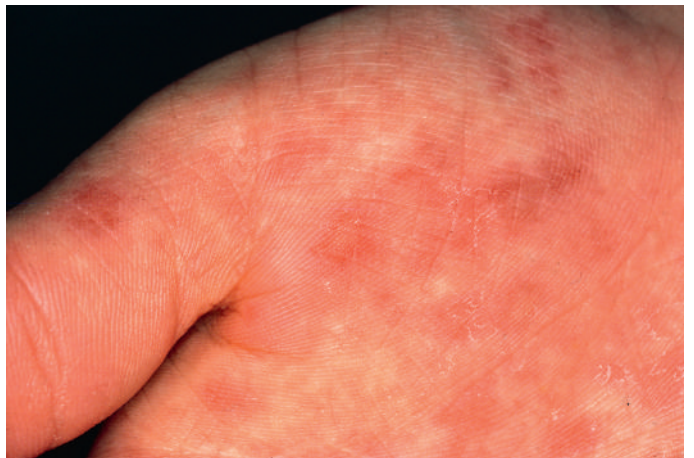
**eFig. 8-8** Annular lesions of subacute cutaneous lupus erythematosus.



**eFig. 8-11** Periocular neonatal lupus erythematosus.

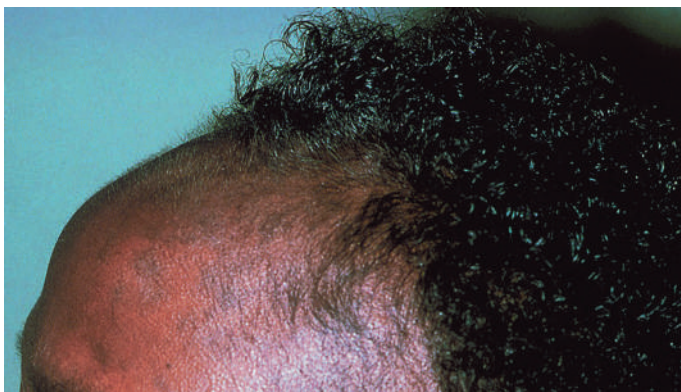

**eFig. 8-9** Psoriasiform subacute cutaneous lupus erythematosus.

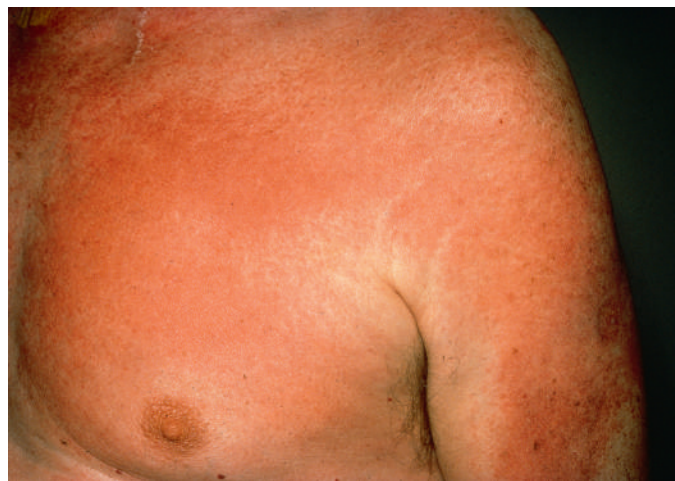

**eFig. 8-12** Palmar erythema in systemic lupus erythematosus.

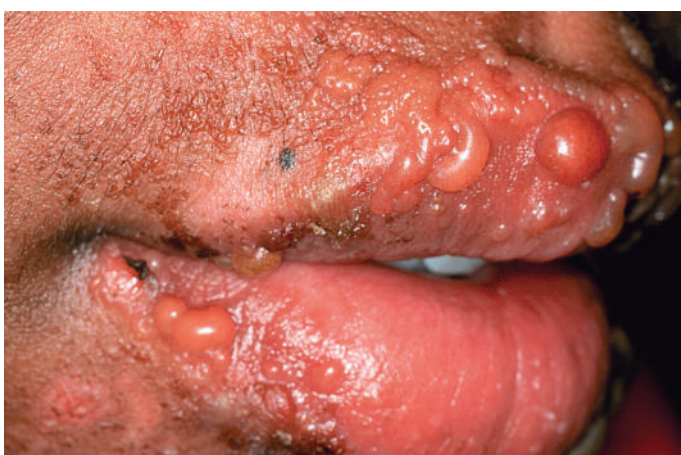



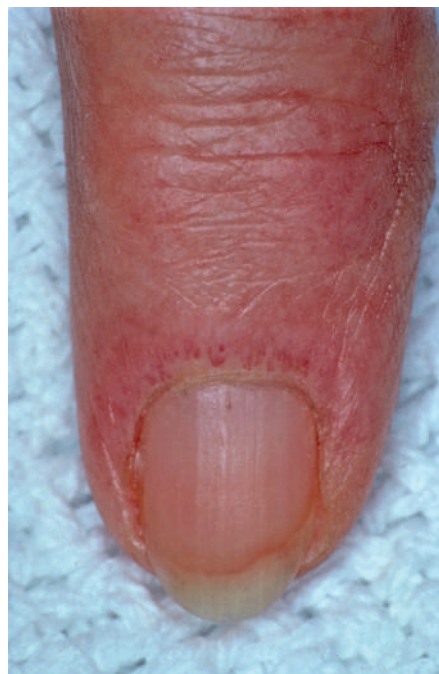**eFig. 8-13** Lupus hair; short, miniaturized hairs affecting the anterior hairline.



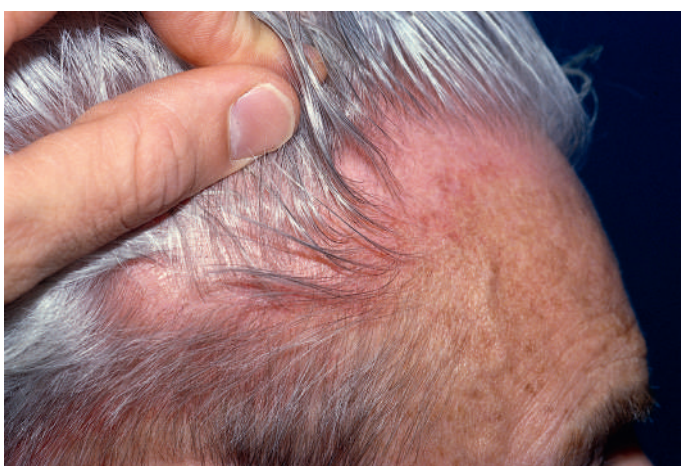
**eFig. 8-16** Poikiloderma on the trunk in dermatomyositis.



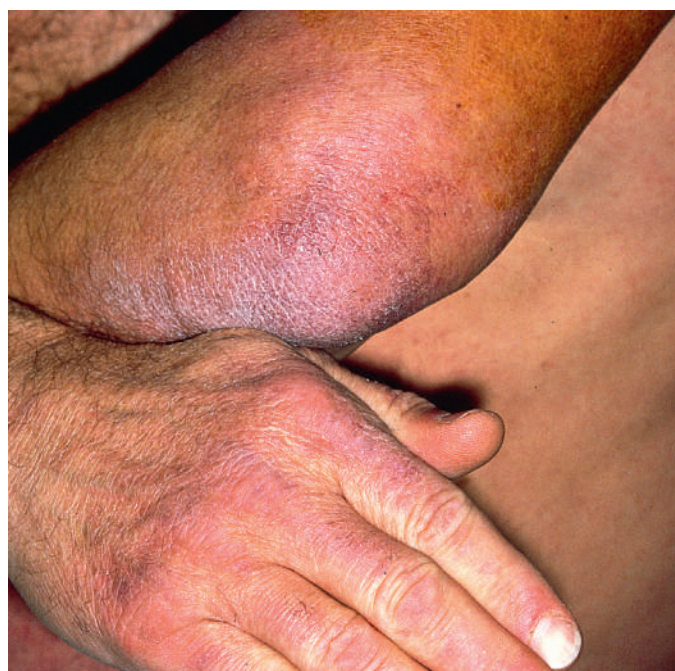**eFig. 8-14** Bullous lupus erythematosus.



**eFig. 8-17** Dilated vessels and avascular regions in dermatomyositis.

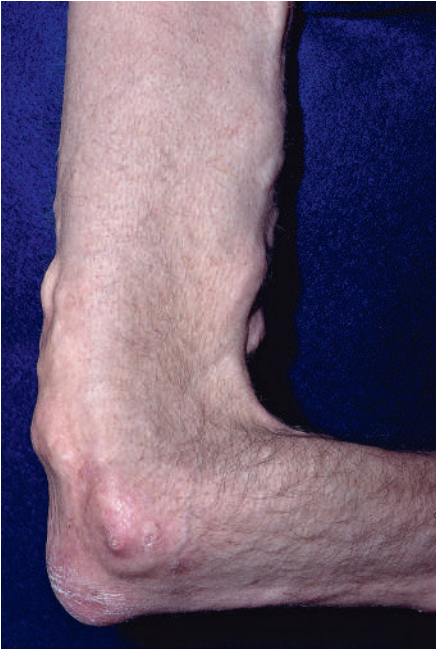


**eFig. 8-15** Scalp erythema in dermatomyositis.

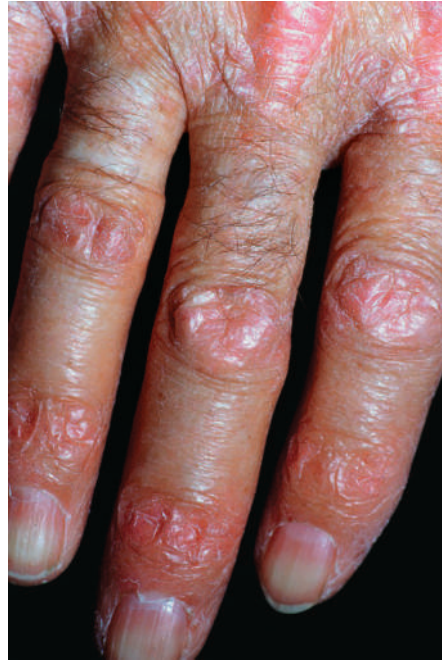

**eFig. 8-18** Gottron's sign.

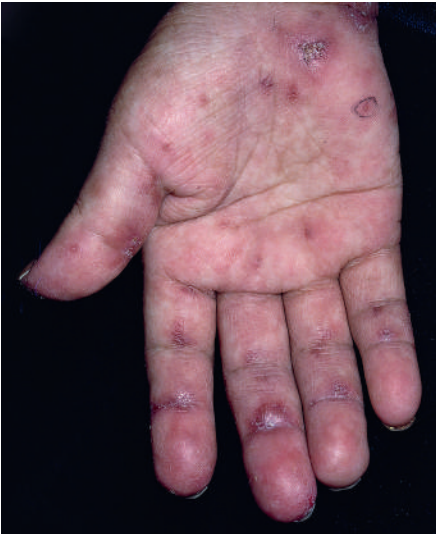



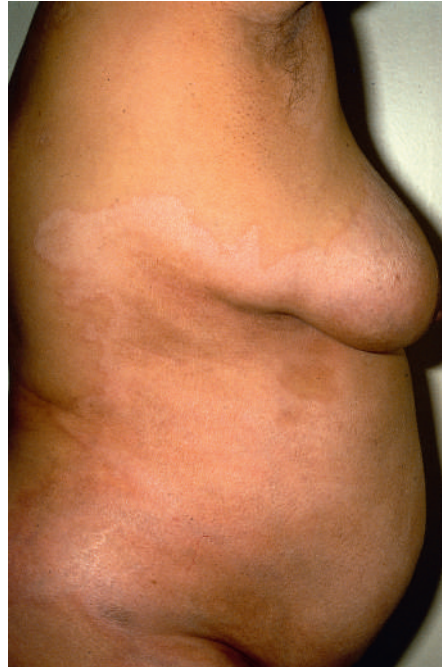**eFig. 8-19** Calcinosi cutis in long-standing dermatomyositis.



**eFig. 8-21** Atrophic lesions of dermatomyositis involving the knuckles.

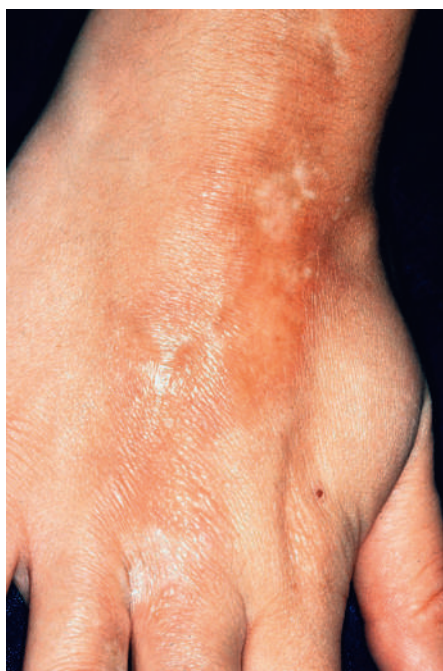

**eFig. 8-20** Vasculitis in childhood dermatomyositis.

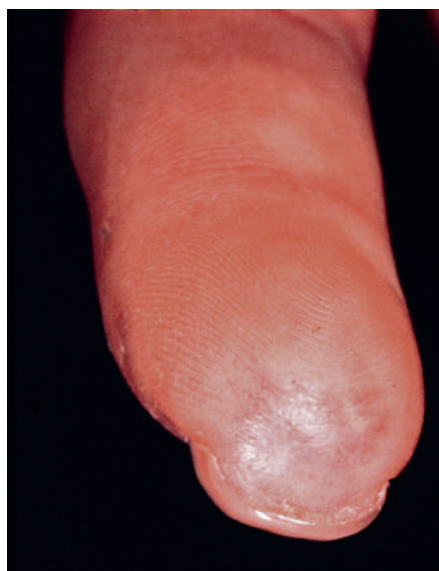


**eFig. 8-22** Morphea.

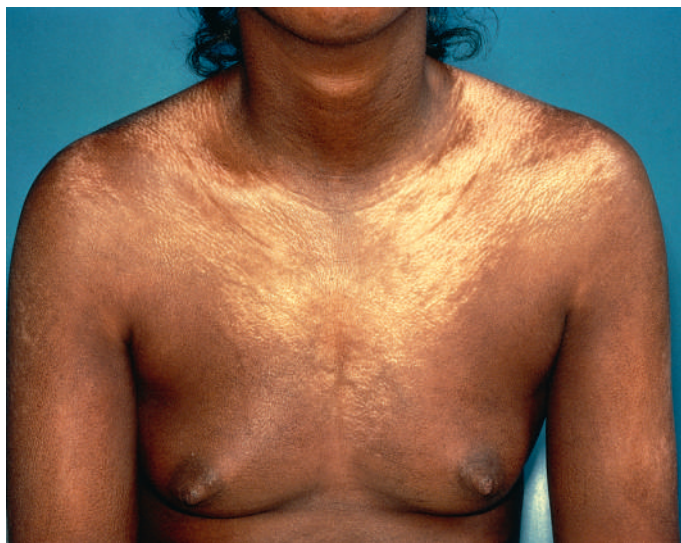



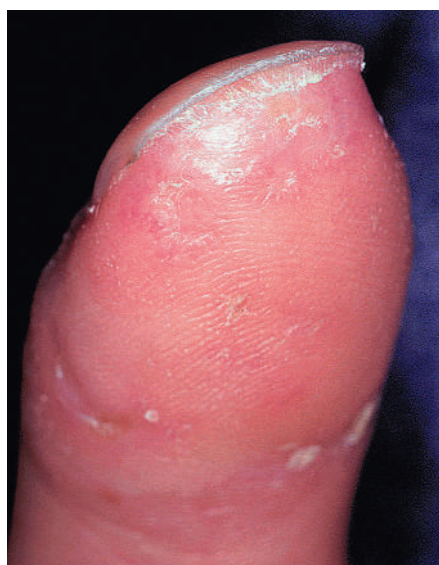**eFig. 8-23** Linear scleroderma presents with induration and pigmentary change.



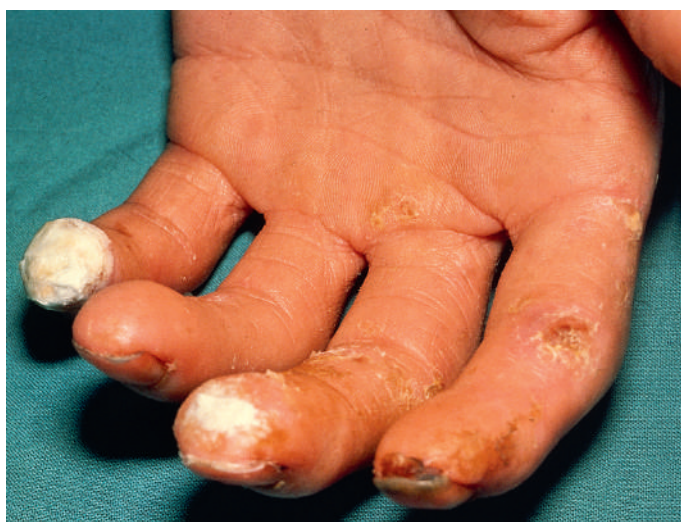**eFig. 8-26** Scarring, loss of finger pad substance, and pterygium inversum unguis.



**eFig. 8-24** Scleroderma.

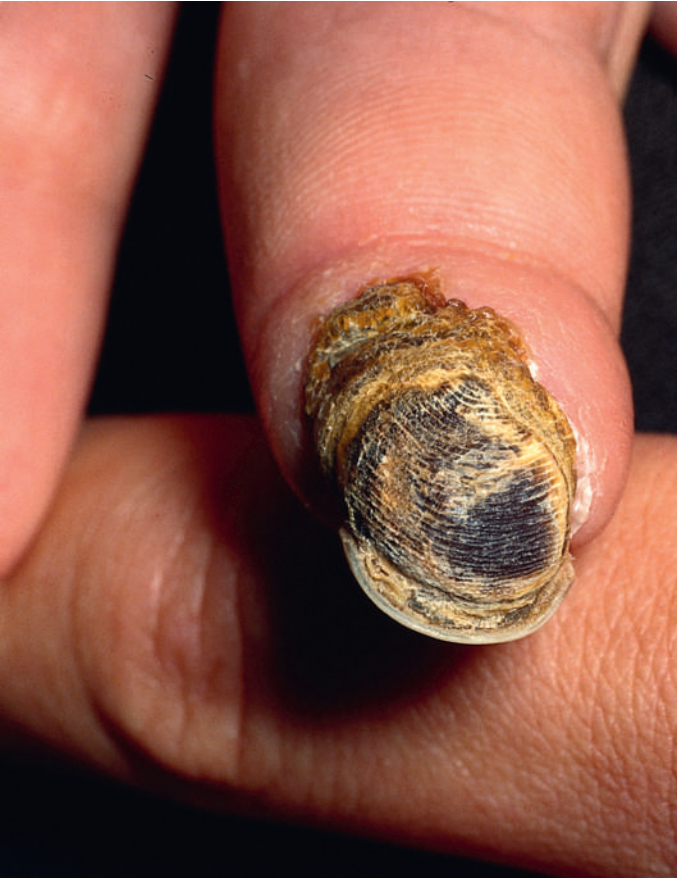

**eFig. 8-27** Pterygium inversum unguis in progressive systemic sclerosis.

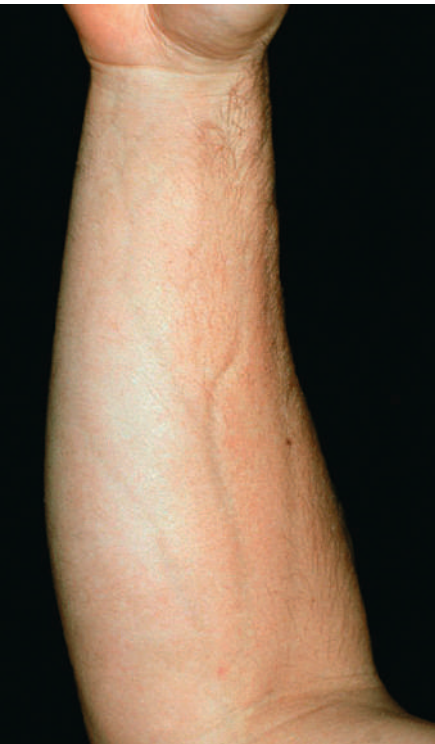

**eFig. 8-25** Calcinosis in CREST syndrome.

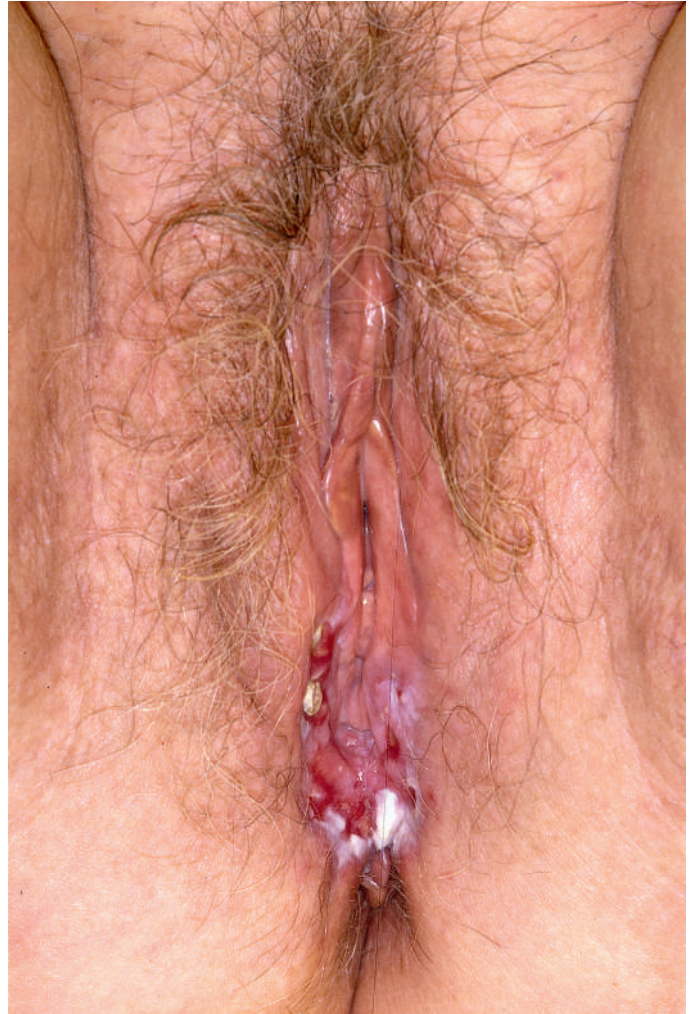




**eFig. 8-28** Ulceration of the fingertip.

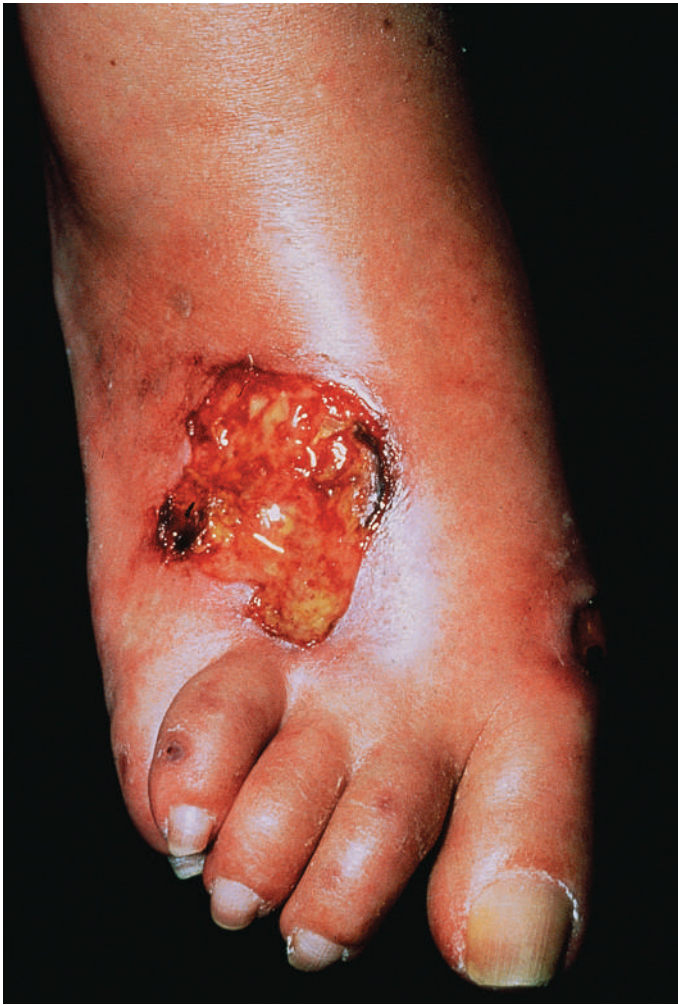

**eFig. 8-29** Eosinophilic fasciitis, "dry riverbed sign."

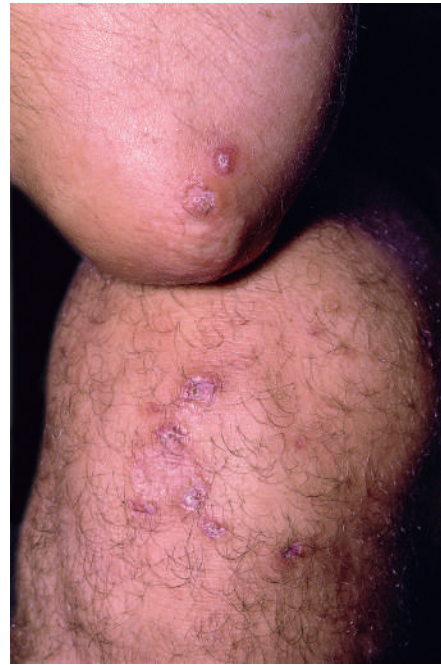

**eFig. 8-30** Mucosal ulcerations in mixed connective tissue disease.

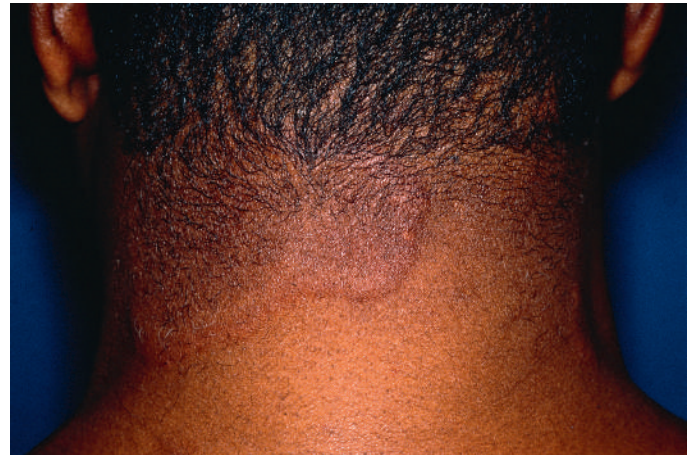



**eFig. 8-31** Rheumatoid vasculitis, frequently results in ulceration.



**eFig. 8-32** Palisaded neutrophilic and granulomatous dermatitis.



**eFig. 8-33** Rheumatoid neutrophilic dermatosis presents with urticarial plaques.

Within the dermis is a fibrillar matrix, termed ground substance, composed of proteoglycans and glycosaminoglycans. These acid mucopolysaccharides, produced by fibroblasts, are highly hygroscopic, binding about 1000 times their own volume in water. They are critical in holding water in the dermis and are responsible for dermal volume and texture. Normally, the sulfated acid mucopolysaccharide chondroitin sulfate and heparin are the primary dermal mucins. In certain diseases, fibroblasts produce abnormally large amounts of acid mucopolysaccharides, usually hyaluronic acid. These acid mucopolysaccharides (mucin) accumulate in large amounts in the dermis and may be visible as pale-blue, granular or amorphous material between collagen bundles. They are often not visualized with hematoxylin and eosin stains because the water they bind is removed in processing, so the presence of increased mucin is suspected by the presence of large, empty spaces between the collagen bundles. Acid mucopolysaccharides can be detected by special stains, such as colloidal iron, alcian blue, and toluidine blue. Incubation of the tissue with hyaluronidase eliminates the staining, confirming the presence of hyaluronic acid.

Increased dermal mucin may result from many diseases and is a normal component of wound healing. The mucinoses are diseases in which production of increased amounts of mucin is the primary process. Mucin may also accumulate in the skin as a secondary phenomenon, as when it is present in lupus erythematosus, dermatomyositis, Degos' disease, granuloma annulare, and cutaneous tumors, or after therapies such as psoralen plus ultraviolet A (PUVA) or retinoids. The genetic diseases in which mucin accumulates as a result of inherited metabolic abnormalities are termed the mucopolysaccharidoses (see Chapter 26). Myxedema and pretibial myxedema are reviewed in Chapter 24.

**Rongioletti F, et al:** Cutaneous mucinoses: microscopic criteria for diagnosis. *Am J Dermatopathol* 2001; 23:257.

**Yaqub A, et al:** Localized cutaneous fibrosing disorders. *Rheum Dis Clin North Am* 2013; 39:347–364.

## LICHEN MYXEDEMATOSUS

The terminology used to describe disorders in the lichen myxedematosus group has varied widely over the years; the 2001 classification of Rongioletti and Reborna is used here. A generalized form, scleromyxedema, is accompanied by a monoclonal gammopathy and may have systemic organ involvement. Five localized forms are recognized, characterized by a lack of a monoclonal antibody and systemic disease. Also, patients may have disease that does not fit into these subsets, and their condition is termed atypical or intermediate in type. Thyroid disease should not account for the findings in any category.

## Generalized lichen myxedematosus

Scleromyxedema affects both men and women and generally appears between ages 30 and 80. It is chronic and progressive. The primary lesions are multiple, waxy, 2–4 mm, dome-shaped or flat-topped papules (Fig. 9-1). They may coalesce into plaques (Fig. 9-2) or may be arranged in linear arrays. Less often, urticarial, nodular, or even annular lesions are seen. The dorsal hands, face, elbows, and extensor extremities are most frequently affected (Fig. 9-3). Mucosal lesions are absent.

A diffuse infiltration develops, leading to “woody” sclerosis of the skin. A reduced range of motion of the mouth, hands, and extremities may follow (Fig. 9-4). On the glabella and forehead, coalescence of lesions leads to the prominent furrowing of a “leonine facies.” At the proximal interphalangeal joint, induration surrounding a centrally depressed area has been called the “doughnut sign.” Pruritus may occur.

Scleromyxedema is often associated with visceral disease. Gastrointestinal findings are most common. Dysphagia from esophageal involvement often occurs, and the stomach or intestine may also be affected. Pulmonary complications with dyspnea caused by restrictive or obstructive disease are also common. Proximal muscle weakness with an inflammatory myopathy or a nonspecific vacuolar change may occur. Carpal tunnel syndrome occurs in 10% of patients. Arthralgia or inflammatory arthritis frequently develop. Disease-specific adenopathy and renal impairment may be present.

The most serious systemic findings are cardiac, hematologic, and neurologic manifestations. Peripheral neuropathies and central nervous system (CNS) disturbances can occur, including confusion, dizziness, dysarthria, ascending paralysis, seizures, syncope, and coma. The latter conditions have been called “dermatoneuro syndrome.” Middle-age men are most frequently affected, and one third of these patients demonstrate recurrent symptoms. Plasmapheresis and intravenous immune globulin (IVIg) may result in dramatic recovery from this life-threatening emergency. Visceral disease can be fatal.

Criteria for inclusion in the scleromyxedema category include mucin deposition, fibroblast proliferation and fibrosis, normal thyroid function tests, and presence of a monoclonal gammopathy. Approximately 10% of patients do not have this latter finding on initial evaluation. The gammopathy is usually an IgG- $\lambda$  type, suggesting an underlying plasma cell dyscrasia. Bone marrow examination may be normal or may reveal increased numbers of plasma cells or frank myeloma.

Clinical and histologic features are usually diagnostic. Skin biopsies of early papular lesions demonstrate a proliferation of fibroblasts with mucin and many small collagen fibers. The papules generally appear more fibrotic than mucinous. Over time, fibroblast nuclei become less numerous, and collagen fibers become thickened.

Many clinical findings in scleromyxedema are also found in systemic scleroderma, including cutaneous sclerosis, Raynaud



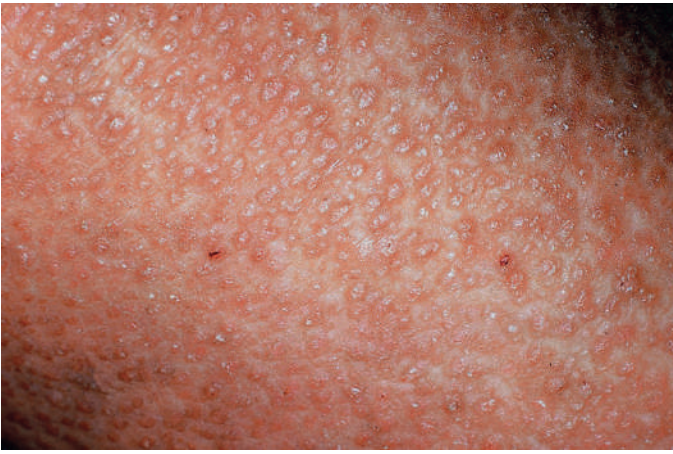

Fig. 9-1 Shiny papules of early scleromyxedema.

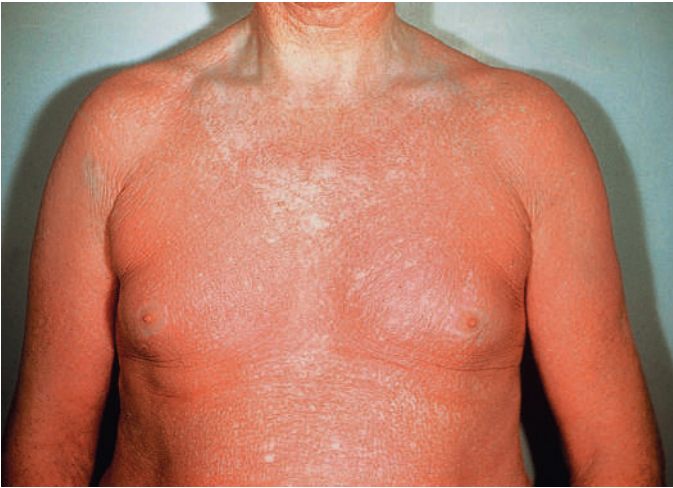


Fig. 9-2 Scleromyxedema.

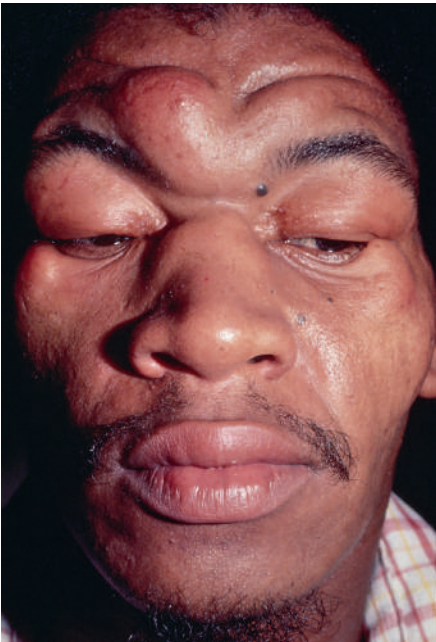

Fig. 9-3  
Scleromyxedema.  
(Courtesy of Marshall  
Guill, MD.)

phenomenon, dysphagia, and carpal tunnel syndrome. This distinction in some cases may be difficult without a biopsy. Other infiltrative disorders, such as amyloidosis, must be excluded. Association with hepatitis C has been reported frequently. Nephrogenic systemic fibrosis presents with skin

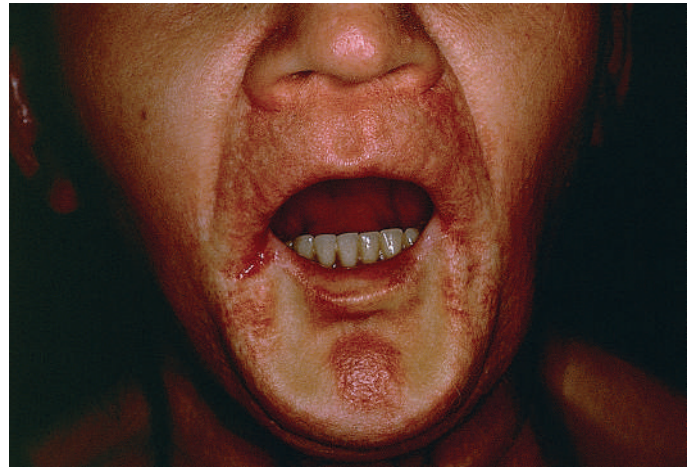

Fig. 9-4 Scleromyxedema, tightness of lower face and mouth.

thickening in the setting of renal failure. In its earliest form, it includes mucin along with collagen deposition with a proliferation of CD34+ cells in the dermis. The histologic findings are identical to those of scleromyxedema, and a first report referred to a scleromyxedema-like disease associated with renal failure. The clinical findings are dominated by fibrosis (see Chapter 8).

Treatment of scleromyxedema is difficult and usually undertaken in concert with an oncologist. Many patients are treated with immunosuppressive agents, especially melphalan, bortezomib, or cyclophosphamide, with or without plasma exchange and high-dose prednisone. Temporary remission of progressive visceral disease may occur. These short-term benefits must be weighed against the increase in malignancies and sepsis complicating such therapy. Chances of remission are enhanced by the use of autologous stem cell transplantation with high-dose melphalan. IVIG is relatively effective and safe. Maintenance infusions are necessary.

Skin-directed therapy may also be used. Physical therapy is indicated. Retinoids, plasmapheresis, extracorporeal photopheresis, grenz ray and electron beam therapy, PUVA, thalidomide, interferon (IFN)- $\alpha$ , cyclosporine, topical dimethyl sulfoxide, and topical and intralesional hyaluronidase and corticosteroids have all produced improvement in the skin of select patients. Many others, however, have not benefited, and visceral disease is usually not affected. Ultraviolet B (UVB) light and IFN- $\alpha$  have exacerbated scleromyxedema.

Occasional patients are reported who spontaneously remit even after many years of disease; however, scleromyxedema remains a therapeutic challenge, and the overall prognosis is poor.

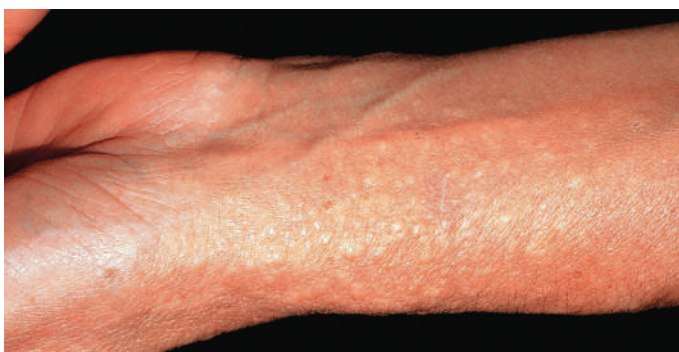### Localized lichen myxedematosus

The localized variants of lichen myxedematosus lack visceral involvement or an associated gammopathy. As a group, they are benign but often persistent. No therapy is reliably effective in any of the localized forms of lichen myxedematosus. Since there is no gammopathy, visceral involvement, or associated thyroid disease in any of the variants, often no treatment is needed. Shave excision or carbon dioxide (CO<sub>2</sub>) ablation are other options for individual lesions. Spontaneous resolution may occur in all varieties.

### Discrete papular lichen myxedematosus

Discrete papular lichen myxedematosus is characterized by the occurrence of waxy, 2–5 mm, firm, flesh-colored papules,





**Fig. 9-5** Acral persistent papular mucinosis.

usually confined to the limbs or trunk. The papules may have an erythematous or yellowish hue, may coalesce into nodules or plaques, and may number into the hundreds. Nodules may occasionally be the predominant lesion present, with few or absent papules. The underlying skin is not indurated, and there is no associated gammopathy or internal involvement. Biopsy reveals the presence of mucin in the upper and middle dermis. Fibroblast proliferation is variable, but collagen deposition is minimal. The slow accumulation of papules is the usual course, without the development of a gammopathy or internal manifestations. Occasional cases may spontaneously involute.

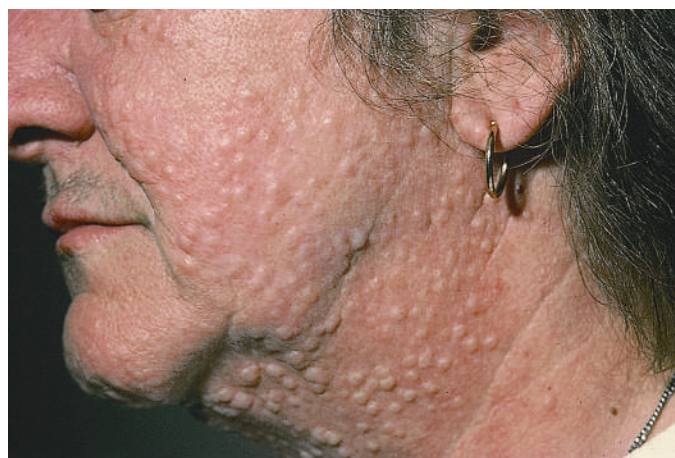Many patients with acquired immunodeficiency syndrome (AIDS) have been reported to develop mucinous papules, usually widespread, unassociated with a paraprotein. It is usually seen in advanced human immunodeficiency virus (HIV) disease, in patients with multiple infectious complications. These lesions may occur in association with an eczematous dermatitis or on normal skin. If associated with an eczematous dermatitis, the lesions often clear if the eczema is controlled. Lesions on normal skin may respond to systemic retinoid therapy. At times, spontaneous remission occurs. The authors have also seen a patient with AIDS and true scleromyxedema with visceral involvement, and two patients have been reported with acral persistent papular mucinosis.

### Acral persistent papular mucinosis

Patients with acral persistent papular mucinosis have a few to more than 100 bilaterally symmetric, 2–5 mm, flesh-colored papules localized to the hands and wrists (Fig. 9-5). The knees, calves, or elbows may also be involved in a minority of patients. The face and trunk are spared. Women outnumber men by 5:1. The course is one of persistence and slow progression. Two involved sisters have been reported. Histologically, there is a collection of upper dermal mucin with minimal or no increase in fibroblasts. Electrocoagulation of these lesions was reported to result in no recurrence in 6 months.

### Self-healing papular mucinosis

Self-healing papular mucinosis occurs in a juvenile and an adult form. The juvenile variant, also called self-healing juvenile cutaneous mucinosis, is a rare but distinct disorder characterized by the sudden onset of skin lesions and polyarthritides. Children, usually between ages 5 and 15, are affected. Familial cases are reported. Skin lesions are ivory-white papules of the head, neck, trunk, and typically the periarticular regions; deep nodules on the face and periarticular sites; and hard edema of the periorbital area and face. An acute arthritis affects the knees, elbows, and hand joints. In the adult form, papular lesions occur, usually without the associated joint symptoms (Fig. 9-6). Histology of the skin lesions reveals dermal mucin



**Fig. 9-6** Self-healing papular mucinosis.

with minimal fibroblastic proliferation or collagen deposition. Although the initial presentation is worrisome, the prognosis is excellent. Spontaneous resolution without sequelae occurs over several months.

### Papular mucinosis of infancy

Also referred to as cutaneous mucinosis of infancy, this rare syndrome occurs at birth or within the first few months of life. Skin-colored or translucent, grouped or discrete, 2–8 mm papules develop on the trunk or upper extremities, especially the back of the hands. Biopsies show very superficial upper dermal mucin without proliferation of fibroblasts. Existing lesions remain static; new lesions continue to accumulate gradually. Similar lesions may sometimes be noted in association with neonatal lupus erythematosus.

### Nodular lichen myxedematosus

Patients may have multiple nodules on the trunk or extremities.

### Atypical or intermediate lichen myxedematosus

The cutaneous mucinoses are all relatively uncommon. In a literature dominated by case reports, individual patients have been found who do not fit well into the above scheme. For example, some patients with acral persistent papular mucinosis have a paraprotein, with localized papular mucinosis and IgA nephropathy, whereas others with apparently classic scleromyxedema with visceral lesions may not have a detectable circulating paraprotein.

**Abbot RA, et al:** Widespread papules in a patient with HIV. *Clin Exp Dermatol* 2010; 35:801–802.

**Andre Jorge F, et al:** Treatment of acral persistent papular mucinosis with electrocoagulation. *J Cutan Med Surg* 2011; 15:227–229.

**Blum M, et al:** Scleromyxedema: a case series highlighting long-term outcomes of treatment with IVIG. *Medicine (Baltimore)* 2008; 87:10.

**Brunet-Possenti F, et al:** Combination of intravenous immunoglobulins and lenalidomide in the treatment of scleromyxedema. *J Am Acad Dermatol* 2013; 69:319–320.

**Canueto J, et al:** The combination of bortezomib and dexamethasone is an efficient therapy for relapsed/refractory scleromyxedema. *Eur J Haematol* 2012; 88:450–454.

**Concheiro J, et al:** Discrete papular lichen myxedematosus. *Clin Exp Dermatol* 2009; 34:e608–e610.

**Donato ML, et al:** Scleromyxedema: role of high-dose melphalan with autologous stem cell transplantation. *Blood* 2006; 107:463.



**Feliciani C, et al:** Adult self-healing papular mucinosis on genital skin. *Clin Exp Dermatol* 2009; 34:e760–e762.

**Fleming KE, et al:** Scleromyxedema and the dermato-neuro syndrome. *J Cutan Pathol* 2012; 39:508–517.

**Hummers LK:** Scleromyxedema. *Curr Opin Rheumatol* 2014; 26:658.

**Lee WS, et al:** Cutaneous focal mucinosis arising from the chin. *J Craniofac Surg* 2010; 21:1639–1641.

**Luo DQ, et al:** Acral persistent papular mucinosis. *J Dtsch Dermatol Ges* 2011; 9:354–359.

**Rampino M, et al:** Scleromyxedema: treatment of widespread cutaneous involvement by total skin electron beam therapy. *Int J Dermatol* 2007; 46:864.

**Rongioletti F, et al:** Scleromyxedema. *J Am Acad Dermatol* 2013; 69:66–72.

**Rongioletti F, et al:** Treatment of localized lichen myxedematosus of discrete type with tacrolimus ointment. *J Am Acad Dermatol* 2008; 58:530.

**Wang P, et al:** Localized papular mucinosis with IgA nephropathy. *Arch Dermatol* 2011; 147:599–602.

**Yamamoto M, et al:** Plaque-type focal mucinosis. *Int J Dermatol* 2011; 50:893–900.

**Zeng R, et al:** Nodular lichen myxedematosus during childhood: a case report. *Pediatr Dermatol* 2014; Sep 22.

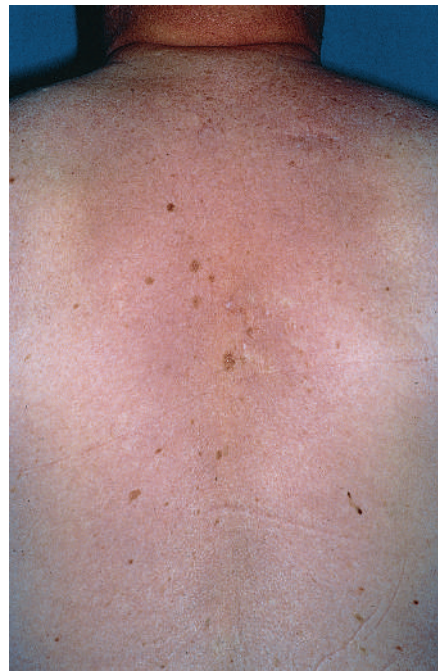## SCLEREDEMA

Scleredema is a skin disease characterized by a stiffening and hardening of the subcutaneous tissues, as if infiltrated with paraffin. It occurs in two forms: with and without diabetes mellitus. In the more generalized, nondiabetic condition, a sudden onset after an infection, typically streptococcal, may occur. This reactive variant may also present as a drug eruption. In other cases, onset is insidious and chronic and has no preceding infection. In the more common diabetes-associated disease, a long-lasting induration of the upper back is characteristic.

In cases not associated with diabetes, females outnumber males by 2:1. The age at onset is from childhood through adulthood. Skin tightness and induration begin on the neck and/or face, spreading symmetrically to involve the arms, shoulders, back, and chest. The distal extremities are spared. The patient may have difficulty opening the mouth or eyes and a masklike expression as a result of the infiltration. The involved skin, which is waxy and of woodlike consistency, gradually transitions into normal skin with no clear demarcation. Associated findings occur in variable numbers of patients and can include dysphagia caused by tongue and upper esophageal involvement, cardiac arrhythmias, and an associated paraproteinemia, usually an IgG type. Myeloma may be present. There may be pleural, pericardial, or peritoneal effusion.

In about half the patients in whom scleredema follows an infection, spontaneous resolution will occur in months to a few years. In one patient whose disease had a sudden onset after beginning infliximab treatment for rheumatoid arthritis, the condition resolved quickly after discontinuation of the medicine and did not recur after etanercept was initiated. The remaining patients with nondiabetic scleredema have a prolonged course. Therapy is generally of no benefit, but patients may live with the disease for many years. Cyclosporine, UVA I, pulsed dexamethasone, tamoxifen, IVIG, and extracorporeal photopheresis have reportedly been beneficial in individual patients. Bortezomib induced remission in one patient with myeloma-associated scleredema.

In the second group, which in most dermatologists' experience is the more common type, there is an association with late-onset, insulin-dependent diabetes. Men outnumber women by 10:1. Affected men tend to be obese. The lesions are of insidious onset and long duration, presenting as woody induration and thickening of the skin of the mid-upper back,



**Fig. 9-7** Scleredema.

neck, and shoulders (Fig. 9-7). There is a sharp step-off from the involved to the normal skin. Persistent erythema and folliculitis may involve the affected areas. The associated diabetes is of long duration and is difficult to control. Further, patients often have complications of their diabetes, such as nephropathy, atherosclerotic disease, retinopathy, and neuropathy. Control of the diabetes does not affect the course of the scleredema. No paraprotein is detected, and no visceral involvement is seen. Lesions are persistent and usually unresponsive to treatment. Intravenous penicillin, electron beam alone or in combination with photon irradiation, narrow-band UVB, and both bath and systemic PUVA, in one case combined with colchicine, have each been effective in individual patients. Although low-dose methotrexate was successful in one patient, it was ineffective in a case series of seven patients.

The histology of both forms is identical. The skin is dramatically thickened, with the dermis often expanded twofold to threefold. There is no hyalinization, such as that seen in scleroderma, but rather the thick, dermal collagen bundles are separated by clear spaces that may contain visible mucin (hyaluronic acid). The amount of mucin is variable and usually only prominent in early lesions. In late lesions, slightly widened spaces between thick collagen bundles are the sole finding, because the amount of mucin is scant.

**Aichelburg MC, et al:** Successful treatment of poststreptococcal scleredema adutorum Buschke with intravenous immunoglobulins. *Arch Dermatol* 2012; 148:1126–1128.

**Alsaedi SH, et al:** Treatment of scleredema diabetorum with tamoxifen. *J Rheumatol* 2010; 37:2636–2637.

**Beers WH, et al:** Scleredema adutorum of Buschke: a case report and review of the literature. *Semin Arthritis Rheum* 2006; 35:355.

**Ioannidou DI, et al:** Scleredema adutorum of Buschke presenting as periorbital edema. *J Am Acad Dermatol* 2005; 52:41.

**Kokpol C, et al:** Successful treatment of scleredema diabetorum by combining local PUVA and colchicine. *Case Rep Dermatol* 2012; 4:265–268.

**Kroft EB, et al:** Ultraviolet A phototherapy for sclerotic skin diseases. *J Am Acad Dermatol* 2008; 59:1017–1030.

**Kurihara Y, et al:** Case of diabetic scleredema: diagnostic value of magnetic resonance imaging. *J Dermatol* 2011; 38:693–696.

**Morais P, et al:** Scleredema of Buschke following *Mycoplasma pneumoniae* respiratory infection. *Int J Dermatol* 2011; 50:454–457.

**Ranganathan P:** Infliximab-induced scleredema in a patient with rheumatoid arthritis. *J Clin Rheumatol* 2005; 11:319.

**Szturz P, et al:** Complete remission of multiple myeloma associated scleredema after bortezomib-based treatment. *Leuk Lymphoma* 2013; 54:1324–1326.

**Yachoui R, et al:** Scleredema in a patient with AIDS-related lipodystrophy syndrome. *Case Rep Endocrinol* 2013; Jan 10. [Epub ahead of print.]

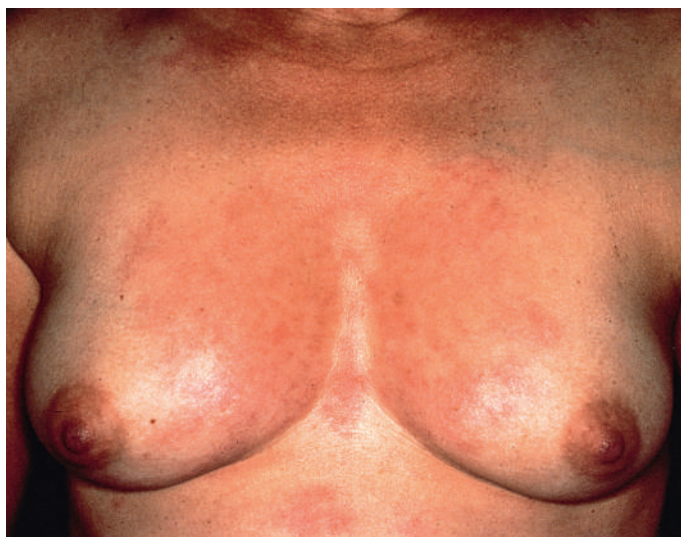## RETICULAR ERYTHEMATOUS MUCINOSIS (REM SYNDROME, PLAQUELIKE CUTANEOUS MUCINOSIS)

Reticular erythematous mucinosis (REM) favors women in the third and fourth decades of life. The eruption frequently appears after intense sun exposure. Clinical lesions are erythematous plaques or reticulated patches that are several centimeters in diameter and usually in the midline of the chest and back (Fig. 9-8). Evolution is gradual, photosensitivity may be present, and lesions induced with UVB. Onset or exacerbation with oral contraceptives, menses, and pregnancy is another feature. Serologic tests for lupus erythematosus (LE) are negative.

Histologically, there are varying degrees of lymphocytic infiltration around dermal vessels, with deposits of mucin in the dermis. Direct immunofluorescence is negative, but focal vacuolar interface dermatitis is sometimes seen. Treatment with antimalarials is successful in most cases. The pulsed dye laser has led to resolution in two patients.

Lesions of REM have also been reported to occur on the face, arms, abdomen, and groin. When evaluating patients with mucinous smooth-surfaced erythematous lesions it is important to consider the possibility of connective tissue disease. Plaque-like or papulonodular lesions in sites away from the central chest and back may infrequently herald the development of systemic LE, discoid LE, dermatomyositis, or scleroderma.

Tumid lupus erythematosus is a subset of chronic cutaneous lupus characterized by erythematous papules, nodules, and plaques that most often involve the face, extensor aspects of the arms, shoulders, V of the neck, and upper back. Histology more often has a deep perivascular and perifollicular location and commonly reveals direct immunofluorescence activity than REM. Tumid LE is photoinducible and responsive to



**Fig. 9-8** Reticulated erythematous mucinosis.

antimalarials. Although serologic abnormalities occur in a small percentage of patients, this is usually a skin-limited condition.

**Cinotti E, et al:** Reticular erythematous mucinosis. *J Eur Acad Dermatol Venerol* 2014; Aug 4.

**Clarke JT:** Recognizing and managing reticular erythematous mucinosis. *Arch Dermatol* 2011; 147:715–716.

**Kreuter A, et al:** Clinical features and efficacy of antimalarial treatment for reticulated erythematous mucinosis. *Arch Dermatol* 2011; 147:710–715.

**Susok L, et al:** Complete clearance of reticular erythematous mucinosis with quinacrine monotherapy. *Arch Dermatol* 2012; 148:768–769.

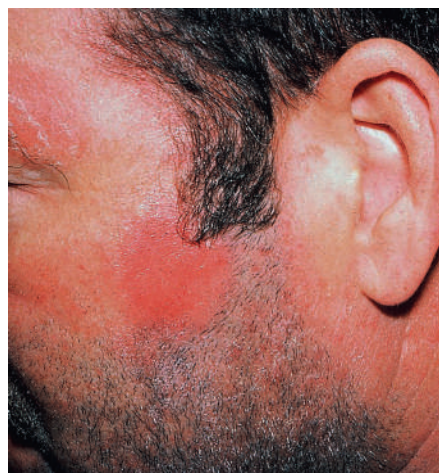**Thareja S, et al:** Reticulated erythematous mucinosis. *Int J Dermatol* 2012; 51:903–909.

**Wristen CC, et al:** Plaque-like cutaneous mucinosis. *Am J Dermatopathol* 2012; 34:e50–e54.

## FOLLICULAR MUCINOSIS (ALOPECIA MUCINOSA)

In 1957, Pinkus used the name alopecia mucinosa to describe a series of patients who had inflammatory plaques with alopecia, characterized histologically by mucinous deposits in the outer root sheaths of the hair follicles. The plaques may be simply hypopigmented or erythematous and scaly, eczematous, or composed of flesh-colored, follicular papules (Fig. 9-9). There may be only one lesion, especially on the head and neck, or multiple sites may be present. The plaques are firm and coarsely rough to the palpating finger. They are distributed mostly on the face, neck, and scalp but may appear on any part of the body. Itching may or may not be present. Alopecia occurs regularly in lesions on the scalp and frequently in lesions located elsewhere. Some papules show a comedolike black central dot that corresponds to a broken hair or the mucin itself. These may cause the surface of a patch to resemble keratosis pilaris. Sensory dissociation, with hot-cold perception alterations or anesthesia to light touch, has been reported in some lesions, with a resultant misdiagnosis of Hansen's disease.

The term alopecia mucinosa may be used to describe the disease process, and follicular mucinosis to describe the histologic features. The disease may be limited to skin and benign (primary follicular mucinosis) or may be associated with follicular mycosis fungoides. When lesions are solitary or few in number and cluster on the head and neck of individuals younger than 40, the condition usually follows a benign, chronic course, even when the infiltrate is found to be clonal in nature. Widespread lesions in an older patient, however, will usually be found to be cutaneous T-cell lymphoma (CTCL)



**Fig. 9-9** Alopecia mucinosa.



at initial presentation or will progress to lymphoma within 5 years. These two subsets are not exclusive, however, and no clinical or histologic criteria absolutely distinguish them in the absence of diagnostic findings of CTCL.

Histologically, follicular mucinosis demonstrates large collections of mucin within the sebaceous gland and outer root sheath. The mucin typically stains as hyaluronic acid. A mixed dermal infiltrate is present. When the condition occurs in association with CTCL, the perifollicular infiltrate is atypical but not generally epidermotropic, and considerable admixture of eosinophils and plasma cells is present. The additional finding of the presence of syringolymphoid hyperplasia should raise concern that lymphoma is or will become evident. T-cell receptor gene rearrangement studies that indicate clonality are also supportive but do not alone predict an aggressive course.

Spontaneous involution of primary follicular mucinosis may occur, especially in young children. Topical corticosteroids produce improvement. Hydroxychloroquine is an excellent first-line systemic therapy. Dapsone, PUVA, radiation therapy, IFN alpha-2b, minocycline, isotretinoin, photodynamic therapy, and indomethacin have been effective in individual cases. Follicular mycosis fungoides, with or without associated mucin, is more refractory to treatment and has a worse prognosis than classic CTCL.

**Alikhan A, et al:** Pediatric follicular mucinosis. *Pediatr Dermatol* 2013; 30:192–198.

**Lehman JS, et al:** Folliculotropic mycosis fungoides. *Arch Dermatol* 2010; 146:662.

**Schneider SW, et al:** Treatment of so-called idiopathic follicular mucinosis with hydroxychloroquine. *Br J Dermatol* 2010; 163:420.

**White FN, et al:** Acneiform follicular mucinosis responding to hydroxychloroquine. *Arch Dermatol* 2011; 147:130–131.

**Zvulunov A, et al:** Clinical and histopathologic spectrum of alopecia mucinosa/follicular mucinosis and its natural history in children. *J Am Acad Dermatol* 2012; 67:1174–1181.

## CUTANEOUS FOCAL MUCINOSIS

Focal mucinosis is characterized by a solitary nodule or papule. Lesions are asymptomatic and usually occur on the face, neck, trunk, or extremities. They appear in adulthood. Histologically, the lesion is characterized by a loose dermal stroma containing large quantities of mucin together with numerous dendritic-shaped fibroblasts. The clinical appearance is not distinctive and at times may suggest a cyst, basal cell carcinoma, or neurofibroma. Treatment is surgical excision.

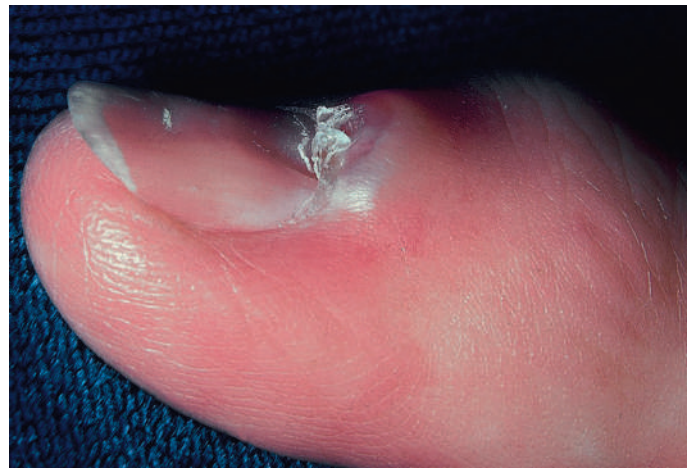**Lee WS, et al:** Cutaneous focal mucinosis arising from the chin. *J Craniofac Surg* 2010; 21:1639.

**Takemura N, et al:** Cutaneous focal mucinosis. *J Dermatol* 2005; 32:1051.

## MYXOID CYSTS

Myxoid cysts, also called synovial and digital mucous cysts, occur most frequently on the dorsal or lateral terminal digits of the hands but may also occur on the toes. These lesions present as solitary, 5–7 mm, opalescent or skin-colored cysts. They may occur as asymptomatic swellings of the proximal nailfold, as subungual growths, or over the distal interphalangeal joint. Women are more frequently affected, and osteoarthritis is often present in the adjacent distal interphalangeal joint. Myxoid cysts that can be reduced with pressure communicate directly with the joint space.

Multiple myxoid cysts are associated with connective tissue disease. Young children, even infants, may present with mul-



**Fig. 9-10** Distortion of nail distal to myxoid cyst.

multiple digital mucous cysts as the initial manifestation of juvenile rheumatoid arthritis.

When a synovial cyst is present beneath the proximal nailfold, a characteristic groove may be formed in the nail plate by pressure of the lesion on the nail matrix (**Fig. 9-10**). Those located beneath the nail cause a transverse nail curvature and a red or blue discoloration of the lunula. Nail integrity typically is compromised, leading to distal or longitudinal splitting or onycholysis. The diagnosis can be confirmed by magnetic resonance imaging (MRI) or surgical exploration. Myxoid cysts contain a clear, viscous, sticky fluid that may spontaneously drain. These cysts do not have an epithelial lining, but rather a compacted fibrous wall.

Treatment depends on the site of the myxoid cyst. The repeated puncture technique for cysts located beneath the proximal nailfold may achieve a cure rate of up to 70%, but multiple punctures (>40) may be required. This technique may be complicated by local tissue or joint infection. Steroids may be injected into the tissue after draining the cyst. Intralesional injection of sodium tetradecyl sulfate has an 80% response rate. Destruction by cryotherapy, CO<sub>2</sub> laser ablation, curettage, and fulguration are alternatives with similar cure rates, but these therapies result in scarring.

Surgical approaches that reflect the skin overlying the cyst and either excise or tie off the communication to the joint, which may be visualized by injecting the myxoid cyst with methylene blue, have a cure rate greater than 90%.

**Li K, et al:** Digital mucous cysts. *Cutan Med Surg* 2010; 14:199–206.

**Park SE, et al:** Treatment of digital mucous cysts with intralesional sodium tetradecyl sulfate injection. *Dermatol Surg* 2014; 40:1249.



Bonus images for this chapter can be found online at

[expertconsult.inkling.com](http://expertconsult.inkling.com)

**eFig. 9-1** Scleromyxedema. (Courtesy of Marshall Guill, MD.)

**eFig. 9-2** Scleromyxedema. (Courtesy of Marshall Guill, MD.)

**eFig. 9-3** Scleromyxedema. (Courtesy of Marshall Guill, MD.)

**eFig. 9-4** Nephrogenic systemic fibrosis.

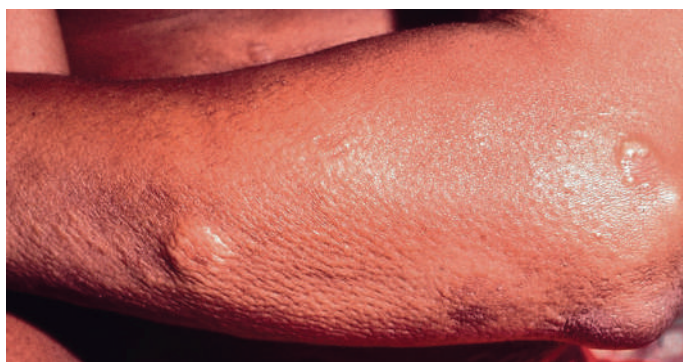**eFig. 9-5** Scleredema.

**eFig. 9-6** Reticulated erythematous mucinosis.

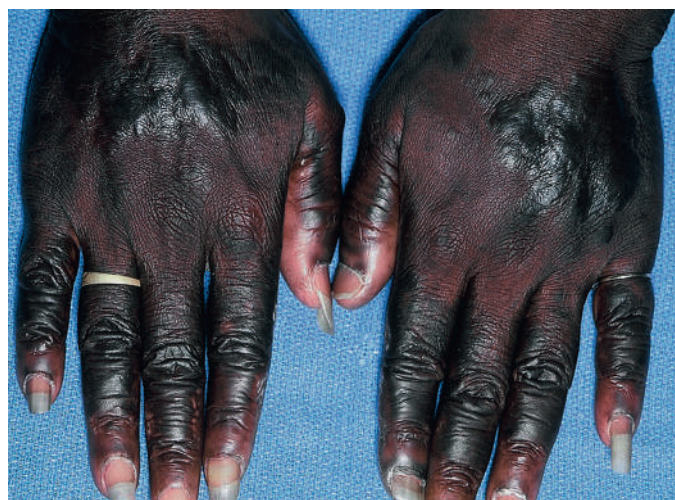**eFig. 9-7** Alopecia mucinosa.

**eFig. 9-8** Myxoid (digital mucous) cyst.

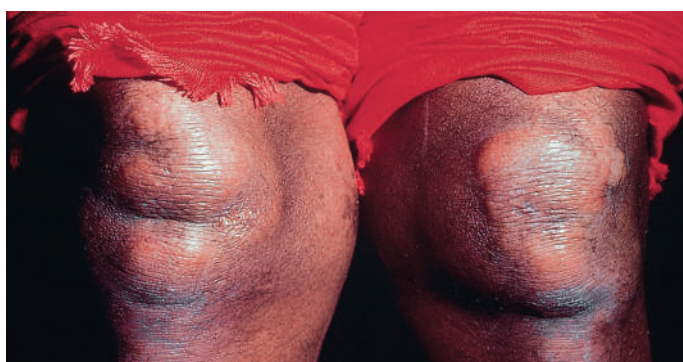



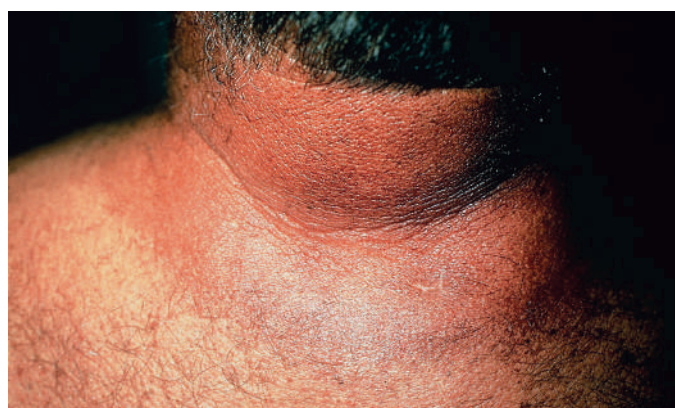eFig. 9-1 Scleromyxedema. (Courtesy of Marshall Guill, MD.)



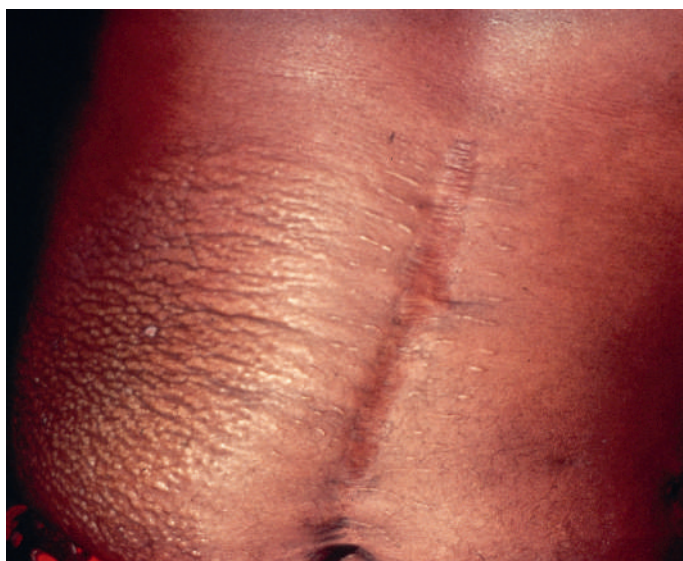
eFig. 9-4 Nephrogenic systemic fibrosis.



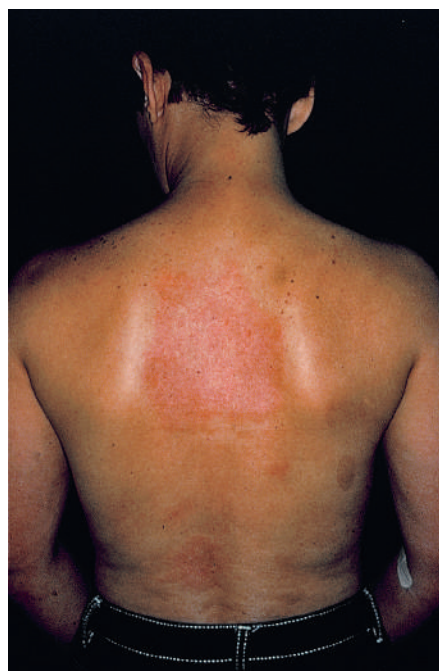eFig. 9-2 Scleromyxedema. (Courtesy of Marshall Guill, MD.)



eFig. 9-5 Scleredema.

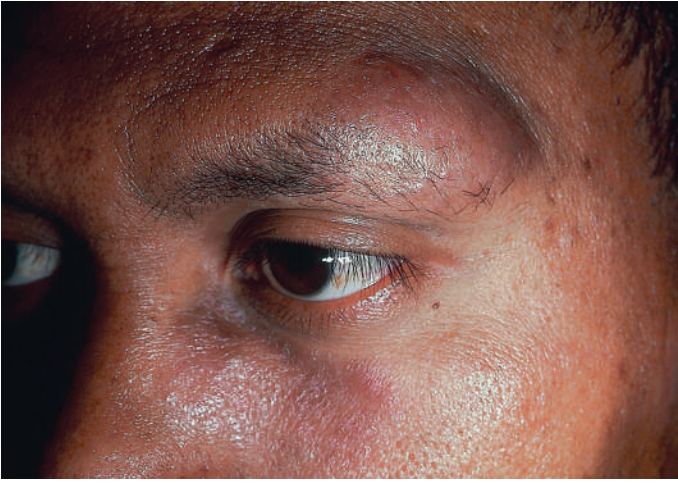


eFig. 9-3 Scleromyxedema. (Courtesy of Marshall Guill, MD.)

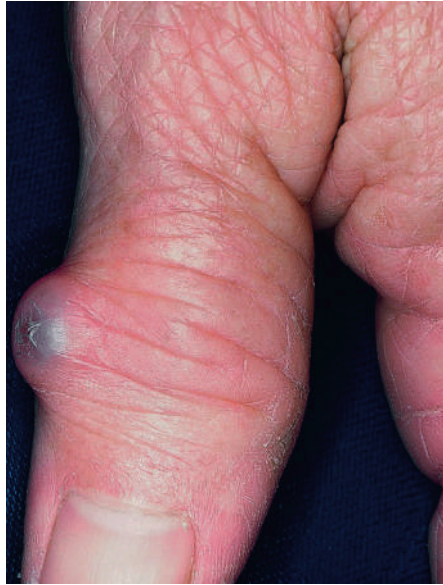

eFig. 9-6 Reticulated erythematous mucinosis.





**eFig. 9-7** Alopecia mucinosa.



**eFig. 9-8** Myxoid (digital mucous) cyst.



# Seborrheic Dermatitis, Psoriasis, Recalcitrant Palmoplantar Eruptions, Pustular Dermatitis, and Erythroderma

# 10

## SEBORRHEIC DERMATITIS

### Clinical features

Seborrheic dermatitis is common, occurring in 2–5% of the population. It is a chronic, superficial, inflammatory disease with a predilection for the scalp, eyebrows, eyelids, nasolabial creases, lips, ears (Fig. 10-1), sternal area, axillae, submammary folds, umbilicus, groins, and gluteal crease. The disease is characterized by scaling on an erythematous base. The scale often has a yellow, greasy appearance. Itching may be severe. Dandruff (pityriasis sicca) represents a mild form of seborrheic dermatitis. An oily type, pityriasis steatoides, is accompanied by erythema and an accumulation of thick crusts.

Other types of seborrheic dermatitis on the scalp include arcuate, polycyclic, or petaloid patches and psoriasiform, exudative, or crusted plaques. The disease frequently spreads beyond the hairy scalp to the forehead, ears, postauricular regions, and neck. On these areas, the patches have convex borders and are reddish yellow or yellowish. In dark-skinned individuals, arcuate and petaloid lesions typically involve the hairline. In extreme cases, the entire scalp is covered by a greasy, dirty crust with an offensive odor. In infants, yellow or brown scaling lesions on the scalp, with accumulated adherent epithelial debris, are called “cradle cap.”

Erythema and scaling are often seen in the eyebrows. The lids may show fine, yellowish white scales and faint erythema. The edges of the lids may be erythematous and granular (marginal blepharitis), and the conjunctivae may be injected. If the glabella is involved, fissures in the wrinkles at the inner end of the eyebrow may accompany the fine scaling. In the nasolabial creases and on the alae nasi, there may be yellowish or reddish yellow scaling macules, sometimes with fissures. In men, folliculitis of the beard area is common.

In the ears, seborrheic dermatitis may be mistaken for an infectious otitis externa. There is scaling in the aural canals, around the auditory meatus, usually with marked pruritus. The postauricular region and skin under the lobe may be involved. In these areas, the skin often becomes red, fissured, and swollen. In the axillae, the eruption begins in the apices, bilaterally, and later progresses to neighboring skin. This pattern resembles that of allergic contact dermatitis to deodorant, but differs from that of clothing dermatitis (which involves periphery of axillae but spares the vault). The involvement may vary from simple erythema and scaling to more pronounced petaloid patches with fissures. The inframammary folds and the umbilicus may be involved. The presternal area is a favored site on the trunk.

Seborrheic dermatitis is common in the groin and gluteal crease, where its appearance may closely simulate tinea cruris or candidiasis. In these areas, the appearance often overlaps with that of inverse psoriasis. In fact, many of these patients have an overlap of the two conditions (seborrheic dermatitis or

seborrheic dermatitis) in the groin, as well as the scalp. The lesions may also become generalized and progress to an exfoliative erythroderma (erythroderma desquamatum), especially in infants. A minority of these infants will have evidence of immunosuppression. In adults, generalized eruptions may be accompanied by adenopathy and may simulate mycosis fungoides or psoriatic erythroderma.

Seborrheic dermatitis may be associated with several internal diseases. Parkinson’s disease is often accompanied by severe refractory seborrheic dermatitis involving the scalp and face, with waxy, profuse scaling. A unilateral injury to the innervation of the face, or a stroke, may lead to unilateral localized seborrheic dermatitis. Patients with acquired immunodeficiency syndrome (AIDS) have an increased incidence of seborrheic dermatitis. An increased incidence has also been noted in patients who are seropositive for human immunodeficiency virus (HIV) but have not developed other signs of clinical disease. Diabetes mellitus (especially in obese persons), sprue, malabsorption disorders, epilepsy, neuroleptic drugs (e.g., haloperidol), and reactions to arsenic and gold have all produced seborrheic dermatitis-like eruptions.

### Etiology and pathogenesis

The etiology of this common disorder is complex but may be related to the presence of the lipophilic yeast *Malassezia ovalis* (*Pityrosporum ovale*), which produces bioactive indoles, oleic acid, malseszin, and indole-3-carbaldehyde. The density of yeast has been correlated with the severity of the disease, and reduction of the yeast occurs with response to therapy. *M. ovalis* may also be abundant on the scalps of patients who have no clinical signs of the disease, and the yeast may only be pathogenic in predisposed individuals.

Patients with seborrheic dermatitis may show upregulation of interferon (IFN)- $\gamma$ , expressed interleukin-6 (IL-6), expressed IL-1 $\beta$ , and IL-4. Expression of cytotoxicity-activating ligands and recruitment of natural killer (NK) cells have also been noted.

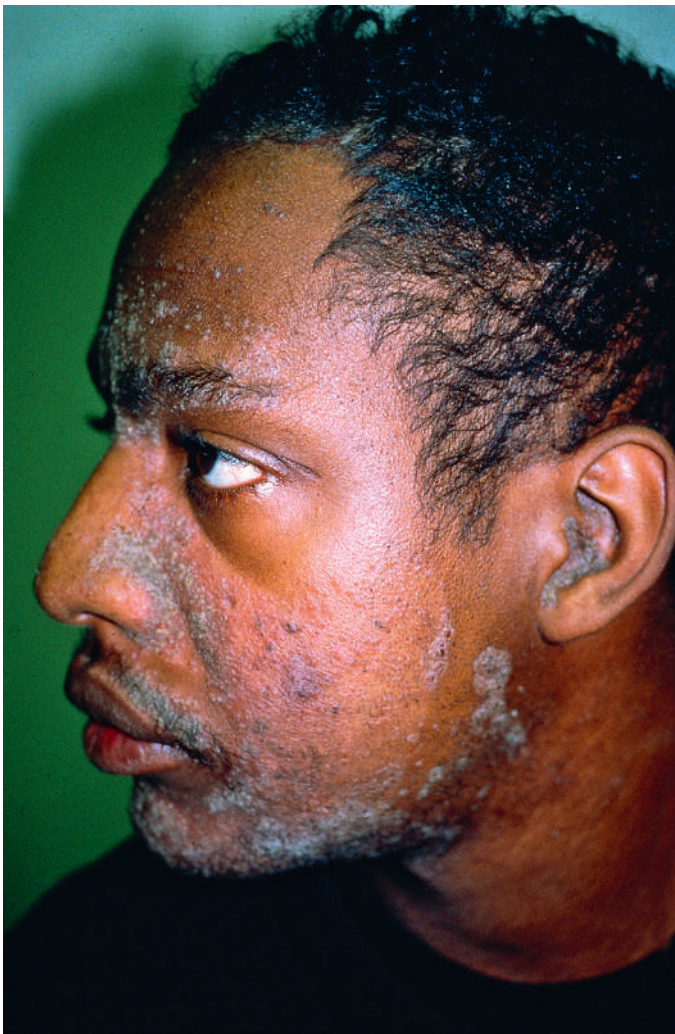### Histology

The epidermis demonstrates regular acanthosis with some thinning of the suprapapillary plates. Varying degrees of spongiosis and lymphocyte exocytosis are noted. A characteristic finding is the presence of a focal scale crust adjacent to the follicular ostia.

### Differential diagnosis

Some cases of seborrheic dermatitis bear a close clinical resemblance to psoriasis, and the two conditions may overlap.





**Fig. 10-1** Seborrheic dermatitis.

Patients with psoriasis tend to have more pronounced erythema and heavier silvery scales that peel in layers. Removal of scales in psoriasis may disclose bleeding points (Auspitz sign). This sign is common but lacks great specificity. Severe itching favors seborrheic dermatitis. Characteristic psoriasis elsewhere (nail pitting, balanitis) may resolve the question. Impetigo of the scalp, especially when associated with pediculosis, may cause difficulty in differentiation. Scalp impetigo can be an indolent crusted dermatosis associated with failure to thrive. Langerhans cell histiocytosis may also resemble seborrheic dermatitis, but typically demonstrates yellow-brown perifollicular papules and groin fissuring. Crusted scabies of the scalp can also be confused with seborrheic dermatitis, and *Trichophyton tonsurans* often produces a subtle seborrheic scale. In subtle cases of tinea, a moist gauze pad rubbed vigorously on the scalp will typically dislodge short, broken potassium hydroxide (KOH)-positive hairs. This can be the fastest way to make the diagnosis.

## Treatment

Agents suitable for use on glabrous skin include corticosteroid creams, gels, sprays, and foams. Corticosteroids tend to produce a rapid effect, but on the face, even midpotency corticosteroids can produce steroid rosacea. For this reason, antifungal agents and topical calcineurin inhibitors (CNIs) are often preferred. Ketoconazole, ciclopirox, sertaconazole,

tacrolimus, pimecrolimus, zinc pyrithione, and *Quassia amara* extract preparations are all effective alone and in combination. The antifungals are now available in a wide range of vehicles to include foams, gels, and liquids. Bifonazole shampoo has been effective in treating infants and small children. Topical CNIs may be associated with a burning sensation, especially on moist skin, and may produce flushing if patients consume alcohol. Patients generally tolerate these agents better after initial treatment with a corticosteroid. An open, randomized, prospective, comparative study of topical pimecrolimus 1% cream versus topical ketoconazole 2% cream found the two to be equally effective, but side effects were somewhat more common with pimecrolimus. Preliminary studies suggest oral itraconazole and oral terbinafine may show some efficacy. Oral fluconazole showed marginal benefit. Study results with topical metronidazole have been mixed.

When secondary bacterial infection is present, a topical or oral antibiotic may be required. In patients infected with HIV, lithium succinate ointment (Efalith) has been used for facial disease. Lithium gluconate 8% ointment has compared favorably with ketoconazole 2% emulsion in healthy adults and was more effective in terms of control of scaling and symptoms. Sodium sulfacetamide products, with or without sulfur, are effective in some refractory patients.

For scalp disease, selenium sulfide, ketoconazole, tar, zinc pyrithione, fluocinolone, and resorcin shampoos are effective. In many patients, these agents may be used two to three times a week, with a regular shampoo used in between as required. White patients often prefer antifungal foams and gels, as well as corticosteroid solutions, foams, gels, and sprays, whereas some black patients prefer ointment or oil preparations.

Itching of the external ear canal usually responds to a topical corticosteroid, CNIs, or antifungals (e.g., ketoconazole, ciclopirox). Some patients require the use of a class 1 corticosteroid on weekends to control refractory pruritus. Cortisporin otic suspension (neomycin, polymyxin B, hydrocortisone) can bring about prompt clearing, but contact dermatitis to neomycin may complicate the use of some Cortisporin products. Desonide otic lotion (0.05% desonide, 2% acetic acid) is also effective and may be better tolerated than Domeboro otic solution (aluminum acetate).

Sodium sulfacetamide drops or ointment may be effective for seborrheic blepharitis. Oral tetracyclines can also be effective and have been shown to decrease the density of microorganisms in the affected follicles. Steroid preparations are suitable for short-term use but may induce glaucoma and cataracts. Daily gentle cleansing with a cotton-tipped applicator and baby shampoo in water can reduce symptoms. In severe cases, oral antibiotics or oral antifungals may be combined with topical agents.

**Alizadeh N, et al:** Comparison the efficacy of fluconazole and terbinafine in patients with moderate to severe seborrheic dermatitis. *Dermatol Res Pract* 2014; 2014:705402.

**Dessinioti C, et al:** Seborrheic dermatitis: etiology, risk factors, and treatments: facts and controversies. *Clin Dermatol* 2013; 31(4):343–351.

**Diehl C, et al:** Efficacy of topical 4% *Quassia amara* gel in facial seborrheic dermatitis: a randomized, double-blind, comparative study. *J Drugs Dermatol* 2013; 12(3):312–315.

**Gary G:** Optimizing treatment approaches in seborrheic dermatitis. *J Clin Aesthet Dermatol* 2013; 6(2):44–49.

**Kastarinen H, et al:** Topical anti-inflammatory agents for seborrheic dermatitis of the face or scalp. *Cochrane Database Syst Rev* 2014 May 19; 5:CD009446.

**Kim TW, et al:** Proactive treatment of adult facial seborrheic dermatitis with 0.1% tacrolimus ointment: randomized, double-blind, vehicle-controlled, multi-centre trial. *Acta Derm Venereol* 2013; 93(5):557–561.



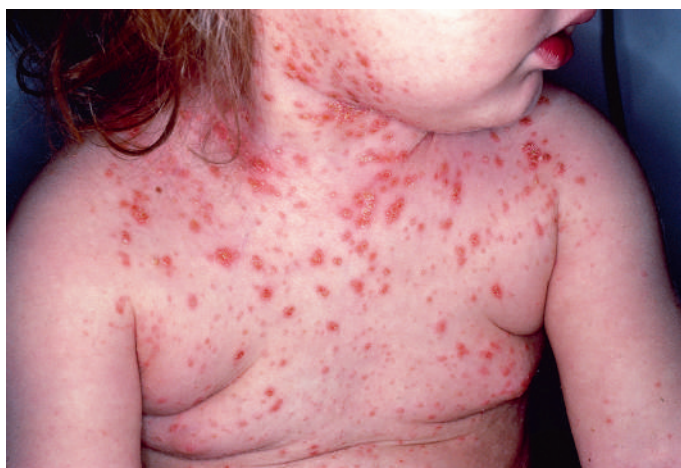

Fig. 10-2 Psoriasis.

Lee YW, et al: Evaluation of expression of lipases and phospholipases of *Malassezia restricta* in patients with seborrheic dermatitis. *Ann Dermatol* 2013; 25(3):310-314.

## PSORIASIS

### Clinical features

Psoriasis is a common, chronic, and recurrent inflammatory disease of the skin characterized by circumscribed, erythematous, dry, scaling plaques of various sizes, usually covered by silvery white lamellar scales. The lesions are usually symmetrically distributed and have a predilection for the scalp, nails, extensor surfaces of the limbs, umbilical region, and sacrum. It usually develops slowly but may be exanthematous, with the sudden onset of numerous guttate (droplike) lesions (Fig. 10-2). Subjective symptoms, such as itching or burning, may be present and may cause extreme discomfort.

The early lesions are small, erythematous macules covered with dry, silvery scales from the onset. The lesions increase in size by peripheral extension and coalescence. The scales are micaceous, meaning they peel in layers, and are looser toward the periphery and adherent centrally. When removed, bleeding points appear (Auspitz sign). Although plaques typically predominate, lesions may be annular or polycyclic. Old patches may be thick and covered with tough lamellar scales like the outside of an oyster shell (psoriasis ostracea). Descriptive terms applied to the diverse appearance of the lesions include psoriasis *guttata*, in which the lesions are the size of water drops; psoriasis *follicularis*, in which tiny, scaly lesions are located at the orifices of hair follicles; psoriasis *figurata*, *annulata*, or *gyrata*, in which curved linear patterns are produced by central involution; psoriasis *discoidea*, in which central involution does not occur and solid patches persist; and psoriasis *rupioides*, in which crusted lesions occur, resembling syphilitic rupia. The term *chronic plaque psoriasis* is often applied to stable lesions of the trunk and extremities. Inverse psoriasis predominates in intertriginous areas. Pustular variants of psoriasis may be chronic on the palms and soles (Fig. 10-3), or these may be eruptive and accompanied by severe toxicity and hypocalcemia.

Involved nails can demonstrate distal onycholysis, random pitting caused by parakeratosis from the proximal matrix (Fig. 10-4), oil spots (yellow areas of subungual parakeratosis from the distal matrix; Fig. 10-5), or salmon patches (nail bed psoriasis). Thick, subungual hyperkeratosis may resemble onychomycosis.

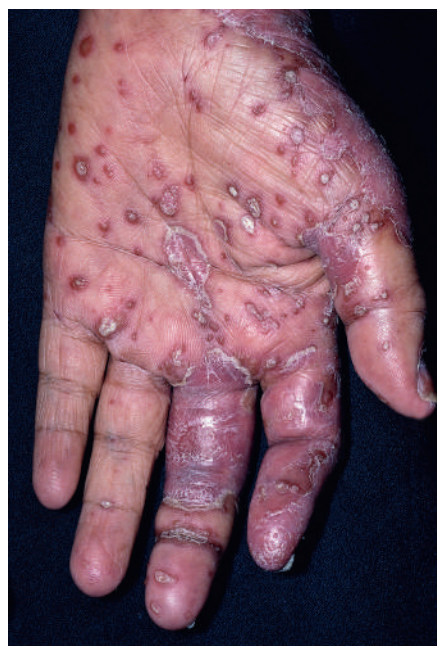

Fig. 10-3 Pustular psoriasis of the hand.

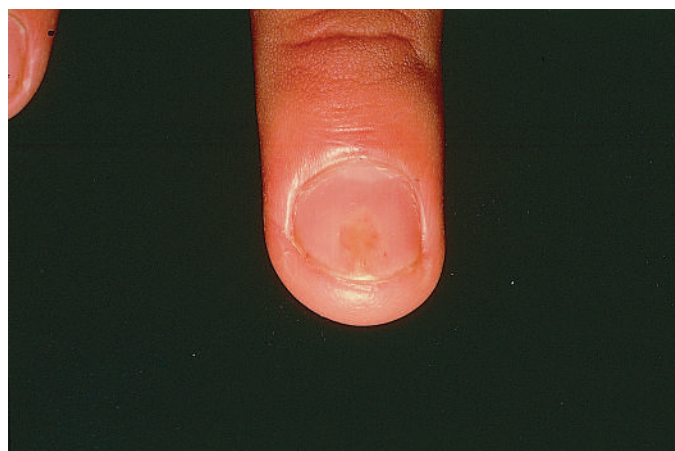


Fig. 10-4 Nail with oil spot of psoriasis.

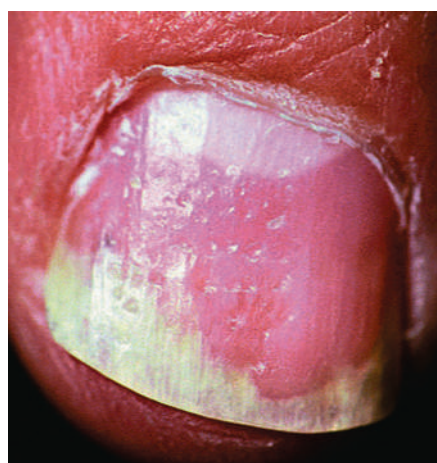


Fig. 10-5 Nail pitting and distal onycholysis in psoriasis.

### Types

#### Seborrheic-like psoriasis

Some cases of psoriasis overlap with seborrheic dermatitis. Seborrheic lesions may predominate on the face, under the breasts, and in the scalp, flexures, and axillae. Lesions in these



areas are moist and erythematous, with yellow, greasy, soft scales, rather than dry and micaceous scales. Terms such as seborrheic dermatitis and seborrheic dermatitis may be used to describe the condition of such patients.

### Inverse psoriasis

Inverse psoriasis selectively and often exclusively involves folds, recesses, and flexor surfaces, such as the ears, axillae, groin, inframammary folds, navel, intergluteal crease, penis, lips, and web spaces. Other areas, such as the scalp and nails, may be involved.

### “Napkin” psoriasis

Napkin psoriasis, or psoriasis in the diaper area, is characteristically seen in infants between 2 and 8 months of age. Lesions appear as brightly erythematous, sharply demarcated patches of skin involving much of the diaper area. The lesions typically clear with topical therapy, but psoriasis may reappear in adulthood.

### Psoriatic arthritis

Five clinical patterns of psoriatic arthritis occur, as follows:

1. Asymmetric distal interphalangeal joint involvement with nail damage (16%)
2. Arthritis mutilans with osteolysis of phalanges and metacarpals (5%) (Fig. 10-6)
3. Symmetric polyarthritis-like rheumatoid arthritis (RA), with clawhand (15%)
4. Oligoarthritis with swelling and tenosynovitis of one or a few hand joints (70%)
5. Ankylosing spondylitis alone or with peripheral arthritis (5%).

Most radiographic findings resemble those in RA, but certain findings are highly suggestive of psoriasis. These include erosion of terminal phalangeal tufts (acrosteolysis), tapering or “whittling” of phalanges or metacarpals with “cupping” of proximal ends of phalanges (“pencil in a cup deformity”), bony ankylosis, osteolysis of metatarsals, predilection for distal interphalangeal and proximal interphalangeal joints, relative sparing of metacarpophalangeal and metatarsophalangeal joints, paravertebral ossification, asymmetric sacroiliitis, and rarity of “bamboo spine” when the spine is involved.

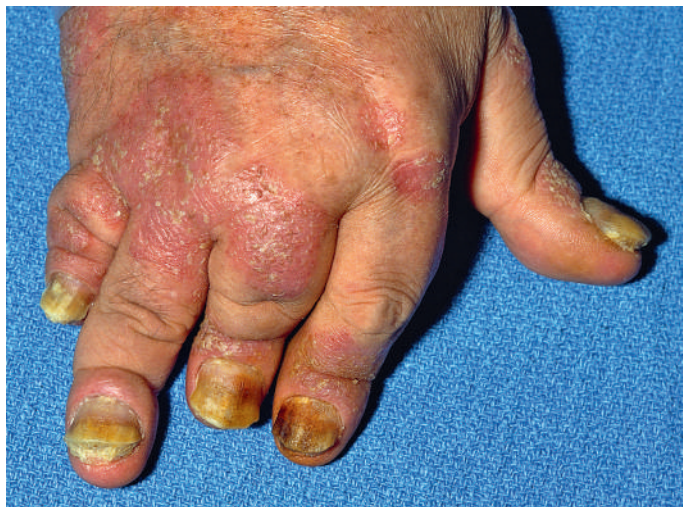

Fig. 10-6 Psoriatic arthritis.

Almost half the patients with psoriatic arthritis have type human leukocyte antigen (HLA)-B27.

Rest, splinting, passive motion, and nonsteroidal anti-inflammatory drugs (NSAIDs) may provide symptomatic relief but do not prevent deformity. Methotrexate, cyclosporine, tacrolimus, and biologic agents are disease-modifying drugs that prevent deformity.

### Guttate psoriasis

In the distinctive guttate form of psoriasis, typical lesions are the size of water drops, 2–5 mm in diameter. Lesions typically occur as an abrupt eruption after acute infection, such as a streptococcal pharyngitis. Guttate psoriasis occurs mostly in patients under age 30. This type of psoriasis usually responds rapidly to broad-band ultraviolet B (UVB) at erythemogenic doses. Suberythemogenic doses often have little impact on the lesions. This is one of the few forms of psoriasis where broad-band UVB may have an advantage over narrow-band UVB. Minimal erythemogenic (erythema) dose (MED) testing is recommended to allow for appropriately aggressive treatment. Recurrent episodes may be related to pharyngeal carriage of the responsible streptococcus by the patient or a close contact. A course of a semisynthetic penicillin (e.g., dicloxacillin, 250 mg four times daily for 10 days) with rifampin (600 mg/day for adult) may be required to clear chronic streptococcal carriage.

### Generalized pustular psoriasis (von Zumbusch psoriasis)

Typical patients with generalized pustular psoriasis have plaque psoriasis and often psoriatic arthritis. The onset is sudden, with formation of lakes of pus periungually, on the palms, and at the edge of psoriatic plaques. Erythema occurs in the flexures before the generalized eruption appears. This is followed by a generalized erythema and more pustules (Fig. 10-7). Pruritus and intense burning are often present. Mucous membrane lesions are common. The lips may be red and scaly, and superficial ulcerations of the tongue and mouth occur. Geographic or fissured tongue frequently occurs (Fig. 10-8).

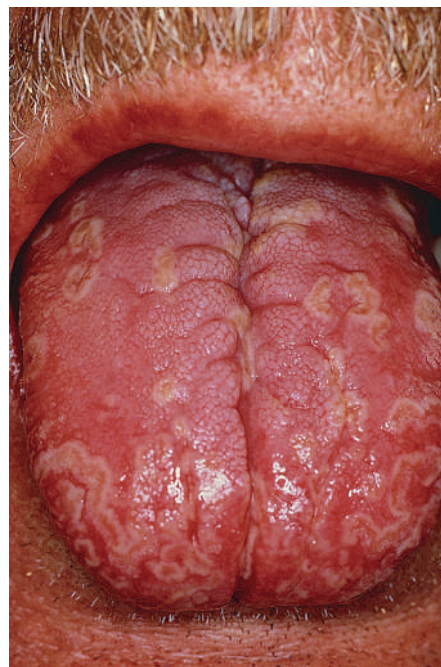
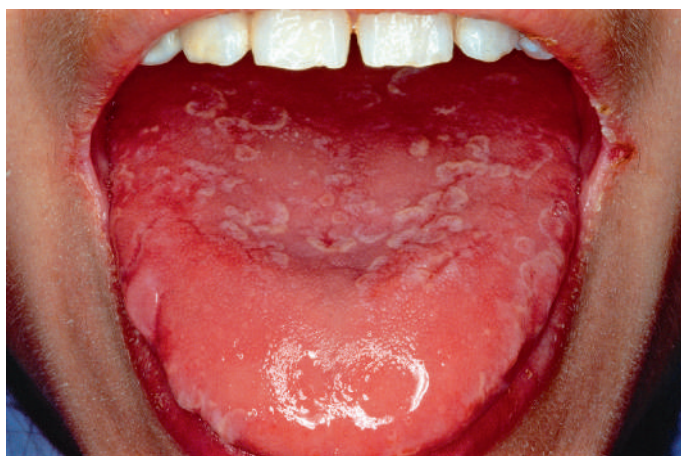
Fig. 10-7 Fissured and geographic tongue in patient with generalized pustular psoriasis.





**Fig. 10-8** Geographic tongue in pustular psoriasis.

The patient is frequently ill with fever, erythroderma, hypocalcemia, and cachexia. A number of cases of acute respiratory distress syndrome associated with pustular and erythrodermic psoriasis have been reported. Other systemic complications include pneumonia, congestive heart failure, and hepatitis.

Episodes are often provoked by withdrawal of systemic corticosteroids. The authors have also observed generalized pustular psoriasis as the presenting sign of Cushing's disease. Other implicated drugs include iodides, coal tar, terbinafine, minocycline, hydroxychloroquine, acetazolamide, and salicylates. There is usually a strong familial history of psoriasis. Generalized pustular psoriasis may occur in infants and children with no implicated drug. It may also occur as an episodic event punctuating the course of localized acral pustular psoriasis.

Acitretin is the drug of choice in this severe disease. The response is generally rapid. Isotretinoin is also effective. Cyclosporine, methotrexate, and biologic agents are alternatives. In some cases, dapsone is effective in doses of 50–100 mg/day.

### Acrodermatitis continua (of Hallopeau)

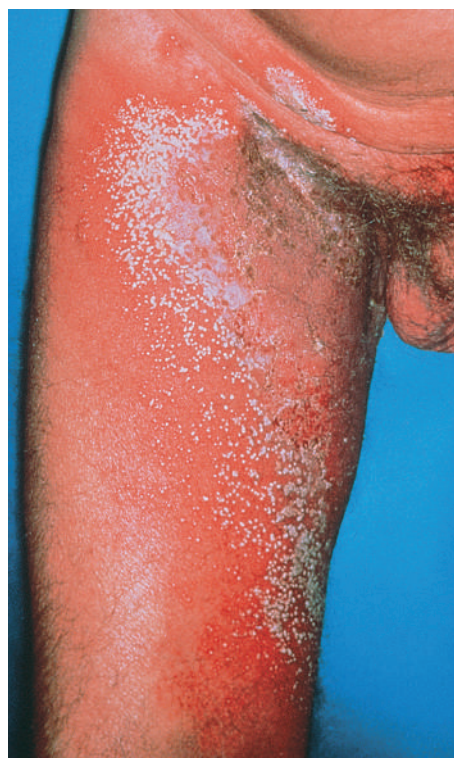Typical patients develop acral erythematous plaques studded with pustules. The nail beds are heavily involved, and the fingernails float away on lakes of pus, resulting in anonychia. Hyperkeratosis often ensues, and the fingertips become increasingly painful, tapering to long, keratotic points. Occasionally, patients may develop generalized pustular flares (Fig. 10-9). Acrodermatitis continua is discussed in more detail later (see Dermatitis repens under Recalcitrant palmoplantar eruptions).

### Impetigo herpetiformis

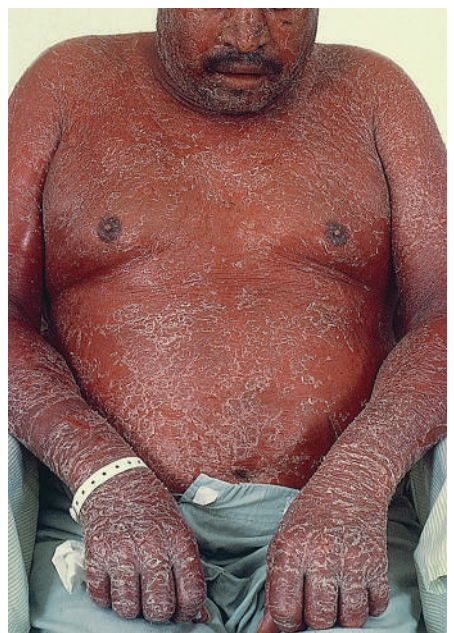The term impetigo herpetiformis has been applied to pustular psoriasis of pregnancy. Flexural erythema, studded with pustules, often occurs initially, followed by a generalized pustular flare and increasing toxicity. These patients are pregnant, so systemic retinoids are not appropriate. Many patients only respond to delivery, and early delivery should be strongly considered as soon as it is safe for the infant. Alternatively, patients may respond to prednisone, 1 mg/kg/day. The corticosteroid can also contribute to neonatal lung maturity.

### Keratoderma blennorrhagicum (Reiter syndrome)

Keratoderma blennorrhagicum resembles psoriasis both histologically and clinically, except for its tendency for thicker



**Fig. 10-9** Generalized pustular flare in a patient with acrodermatitis continua.



**Fig. 10-10** Erythrodermic psoriasis.

keratotic lesions. Patients are often positive for HLA-B27 and develop reactive arthritis and skin disease after a bout of urethritis or enteritis.

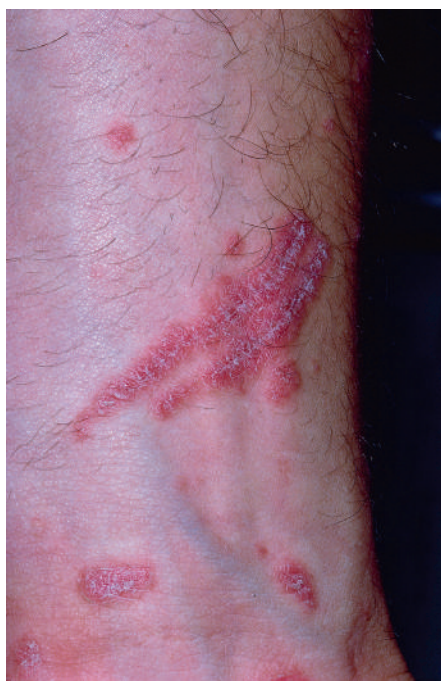### Erythrodermic psoriasis

Patients with psoriasis may develop a generalized erythroderma (Fig. 10-10). Erythrodermic psoriasis is covered in greater detail in Chapter 11 under Exfoliative dermatitis.

### Course

The course of psoriasis is unpredictable. It usually begins on the scalp or elbows and may remain localized in the original





**Fig. 10-11** Koebner phenomenon in psoriasis.

region for years. Chronic disease may also be almost entirely limited to the fingernails. Involvement over the sacrum may easily be confused with candidiasis or tinea. Onset may also be sudden and widespread.

Two of the chief features of psoriasis are its tendency to recur and its persistence. The isomorphic response (Koebner phenomenon) is the appearance of typical lesions of psoriasis at sites of even trivial injury (Fig. 10-11). Lesions may occur at sites of scratches, incisions, and burns. Lesions may first appear after viral exanthema or pityriasis rosea. The isomorphic response may occur if psoriatic lesions are severely burned during phototherapy. With a reduction in light dosage, the erythema and burning resolve, and the plaques begin to clear. Woronoff's ring is concentric blanching of the erythematous skin at or near the periphery of a healing psoriatic plaque. It is often the first sign that the patient's psoriasis is responding to phototherapy.

The palms and soles are sometimes exclusively affected, showing discrete, dry, erythematous scaling patches, circumscribed verrucous thickenings, or pustules on an erythematous base. The patches usually begin in the midportion of the palms or on the soles and gradually expand. Psoriasis of the palms and soles is typically chronic and extremely resistant to treatment.

Many studies report an association between hepatitis C and psoriasis, and hepatitis C virus (HCV) has also been implicated in psoriatic arthritis. If treatment of psoriasis is to include a potentially hepatotoxic drug, such as methotrexate, HCV serology should be obtained. Also, interferon (IFN) treatment of the hepatitis can further exacerbate or induce psoriasis. Anti-tumor necrosis factor (TNF)- $\alpha$  therapy shows promise in the treatment of psoriasis, even in the setting of chronic HCV infection.

### Inheritance

In a large study of psoriasis in monozygotic twins, heritability was high and environmental influence low. Patients with psoriasis often have relatives with the disease, and the incidence typically increases in successive generations. Multifactorial inheritance is likely. Analysis of population-specific

HLA haplotypes has provided evidence that susceptibility to psoriasis is linked to major histocompatibility complex (MHC) classes I and II on human chromosome 6. A number of genetic loci are linked to psoriasis, including *PSORS1* on chromosome 6 and within the MHC, and *PSORS2* on chromosome 17q. Also, there are two subsets that differ in age of onset and frequency of HLA associations. Early onset is type I psoriasis and is associated mostly with Cw6, B57, and DR7. Late onset is type II and predominantly features Cw2. *PSORS9* has also been confirmed as a susceptibility locus for psoriasis.

A variety of other HLA associations have been reported. It is believed that any individual who has B13 or B17 carries a fivefold risk of developing psoriasis. In pustular psoriasis, HLA-B27 may be seen, whereas B13 and B17 are increased in guttate and erythrodermic psoriasis. In palmoplantar pustulosis, there is an association with HLA-B8, Bw35, Cw7, and DR3. HLA typing is a research tool for population-based studies, but of limited value in assessing an individual patient.

### Epidemiology

Psoriasis occurs with equal frequency in both genders. Between 1% and 2% of the U.S. population has psoriasis. It occurs less frequently in the tropics. It is less common in North American and West African black persons. Native (Indian) Americans and native Fijians rarely have psoriasis. The onset of psoriasis is at a mean age of 27 years, but the range is wide, from the neonatal period to the seventies. Severe emotional stress tends to aggravate psoriasis in almost half of those studied.

In pregnancy, there is a distinct tendency for improvement or even temporary disappearance of lesions in the majority of women studied. After childbirth, there is a tendency for exacerbation of lesions. Paradoxically, pregnancy is also the milieu for impetigo herpetiformis, and psoriasis may behave differently from one pregnancy to another in the same patient.

A high prevalence of celiac disease has been noted in patients with psoriasis. Lymphoma also has an increased incidence in these patients, and psoriasis has been linked to the metabolic syndrome and a higher risk of cardiovascular disease, although early age of onset does not appear to correlate with greater risk.

### Pathogenesis

Psoriasis is a hyperproliferative disorder, but the proliferation is driven by a complex cascade of inflammatory mediators. Psoriasis appears to represent a mixed T-helper 1 (Th1) and Th17 inflammatory disease. Th17 cells appear to be more proximal in the inflammatory cascade. T cells and cytokines play pivotal roles in the pathophysiology of psoriasis. Overexpression of type 1 cytokines, such as IL-2, IL-6, IL-8, IL-12, IFN- $\gamma$  and TNF- $\alpha$ , has been demonstrated, and overexpression of IL-8 leads to the accumulation of neutrophils. The main signal for Th1 development is IL-12, which promotes intracellular IFN- $\gamma$  production. In animal models, shifting from Th1 to Th2 responses improves psoriasis. IL-4 is capable of inducing Th2 responses and improving psoriasis. Reduced expression of the anti-inflammatory cytokines IL-1RA and IL-10 has been found, and polymorphisms for IL-10 genes correlate with psoriasis. IL-10 is a type 2 cytokine with major influence on immunoregulation, inhibiting type 1 proinflammatory cytokine production. Patients receiving established traditional therapies show rising levels of IL-10 messenger RNA expression, suggesting that IL-10 may have antipsoriatic capacity.

The response to biologic agents has demonstrated that Th17, T-regulatory cells, CD2<sup>+</sup> lymphocytes, CD-11a, and TNF- $\alpha$  are important in the pathogenesis of psoriasis. IL-15 triggers

inflammatory cell recruitment, angiogenesis, and production of inflammatory cytokines, including IFN- $\gamma$ , TNF- $\alpha$ , and IL-17, all of which are upregulated in psoriatic lesions. The interplay is complex, but IL-17 appears to be proinflammatory, while IL-22 may serve to retard keratinocyte differentiation. IL-23 stimulates survival, as well as proliferation of Th17 cells. Circulating NK cells are reduced in psoriasis. Other cytokines that may play an important pathogenetic role in psoriasis include IL-17A and Th22 cells.

## Streptococci

Streptococci play a role in some patients. Patients with psoriasis report sore throat more often than controls.  $\beta$ -Hemolytic streptococci of Lancefield groups A, C, and G can cause exacerbation of chronic plaque psoriasis. Th1 cells recognize cell wall extract isolated from group A streptococci. HLA variation has a significant effect on the immune response to group A streptococci.

## Stress

Various studies have shown a positive correlation between stress and severity of disease. In almost half of patients studied, stress appears to play a significant role.

## Drug-induced psoriasis

Psoriasis may be induced by  $\beta$ -blockers, lithium, antimalarials, terbinafine, calcium channel blockers, captopril, glyburide, granulocyte colony-stimulating factor, interleukins, interferons, and lipid-lowering drugs. Systemic steroids may cause rebound or pustular flares. Antimalarials are associated with erythrodermic flares, but patients traveling to malaria-endemic regions should take appropriate prophylaxis. Often, drugs such as doxycycline or mefloquine are appropriate for the geographic area, but when a quinine derivative offers the best protection, it is generally better to take the prophylactic doses of a quinine derivative than to risk disease and full-dose treatment.

## Pathology

Histologically, all psoriasis is pustular. The microscopic pustules include spongiform intraepidermal pustules, and Munro microabscesses within the stratum corneum. In early guttate lesions, focal parakeratosis is noted within the stratum corneum. The parakeratotic focus typically has an outline resembling a seagull. Neutrophils are generally noted immediately above the focus of parakeratosis, but in some sections the neutrophils will not be visible as a result of sampling error. In plaque psoriasis, neutrophilic foci are so numerous that they are rarely missed. Neutrophilic microabscesses are generally present at multiple levels in the stratum corneum, usually on top of small foci of parakeratosis. These foci generally alternate with areas of orthokeratotic stratum corneum, suggesting that the underlying spongiform pustules arise in a rhythmic fashion. The granular layer is absent focally, corresponding to areas producing foci of parakeratosis. In well-developed plaques, there is regular epidermal acanthosis with long, bulbous rete ridges, thinning over the dermal papillae, and dilated capillaries within the dermal papillae. The last two findings correlate with the Auspitz sign. The stratum corneum may be entirely parakeratotic but still shows multiple small, neutrophilic microabscesses at varying levels. Spongiosis is typically scant, except in the area immediately surrounding collections of neutrophils.

In pustular psoriasis, geographic tongue, and Reiter syndrome, intraepidermal spongiform pustules tend to be much larger. Grossly pustular lesions often have little associated acanthosis. In Reiter syndrome, the stratum corneum is often massively thickened, with prominent foci of neutrophils above parakeratosis, alternating with orthokeratosis.

Acral lesions often demonstrate nondiagnostic features histologically. Spongiosis is typically prominent in these lesions and often leads to a differential diagnosis of psoriasis or chronic psoriasiform spongiotic dermatitis. Foci of neutrophils often contain serum and may be interpreted as impetiginized crusting.

On direct immunofluorescence testing, the stratum corneum demonstrates intense fluorescence with all antibodies, complement, and fibrin. This fluorescence may be partially independent of the fluorescent label, as it has been noted in hematoxylin and eosin-stained sections and frozen unstained sections. The same phenomenon of stratum corneum autofluorescence has been noted in some cases of candidiasis that demonstrate a psoriasiform histology.

Psoriasis can generally be distinguished from dermatitis by the paucity of edema, relative absence of spongiosis, tortuosity of the capillary loops, and presence of neutrophils above foci of parakeratosis. Neutrophils in the stratum corneum are often seen in tinea, impetigo, candidiasis, and syphilis, but they rarely are found atop parakeratosis alternating with orthokeratosis rhythmically. In psoriasiform syphilis, the rete ridges are typically long and slender; a vacuolar interface dermatitis is usually present; dermal blood vessels appear to have no lumen because of endothelial swelling; and plasma cells are present in the dermal infiltrate. About one third of biopsies of syphilis lack plasma cells, but the remaining characteristics still suggest the correct diagnosis. Psoriasiform lesions of mycosis fungoides exhibit epidermotropism of large lymphocytes with little spongiosis. The lymphocytes are typically larger, darker, and more angulated than the lymphocytes in the dermis. There is associated papillary dermal fibrosis, and the superficial perivascular infiltrate is asymmetrically distributed around the postcapillary venules, favoring the epidermal side ("bare underbelly sign").

## Clinical differential diagnosis

Psoriasis must be differentiated from dermatomyositis (DM), lupus erythematosus (LE), seborrheic dermatitis, pityriasis rosea, lichen planus, eczema, and psoriasiform syphilid. The distribution in psoriasis is on the extensor surfaces, especially of the elbows and knees, and on the scalp; DM shares this distribution, whereas LE generally lacks involvement of the extensor surfaces. Patients with DM may exhibit a heliotrope sign, atrophy, poikiloderma, and nailfold changes. Advanced lesions of discoid LE often demonstrate follicular hyperkeratosis (carpet tack sign). Seborrheic dermatitis has a predilection for the eyebrows, nasolabial angle, ears, sternal region, and flexures. The scales in psoriasis are dry, white, and shiny, whereas those in seborrheic dermatitis are greasy and yellowish. On removal of the scales in psoriasis, blood oozes from the capillaries (Auspitz sign), whereas this does not occur in seborrheic dermatitis.

In pityriasis rosea, the eruption is located on the upper arms, trunk, and thighs, and the duration is over weeks. Lesions are typically oval and follow skin tension lines. Individual lesions show a crinkling of the epidermis and collarette scaling. A herald patch is frequently noted. Lichen planus chiefly affects the flexor surfaces of the wrists and ankles. Often the violaceous color is pronounced. In darker-skinned individuals, the lesions have a tendency to pronounced hyperpigmentation.



The nails are not pitted as in psoriasis, but longitudinally ridged, rough, and thickened. Pterygium formation is characteristic of lichen planus.

Hand eczema may resemble psoriasis. In general, psoriatic lesions tend to be more sharply margined, but at times the lesions are indistinguishable. Psoriasiform syphilid has infiltrated copper-colored papules, often arranged in a figurate pattern. Serologic tests for syphilis are generally positive, but prozone reactions may occur, and the serum may have to be diluted to obtain a positive test. Generalized lymphadenopathy and mucous patches may be present.

## Treatment

Topical therapy, intralesional triamcinolone, excimer laser, or other forms of intense pulsed light may be suitable for limited plaques. Phototherapy remains highly cost-effective for widespread psoriasis. Cyclosporine has a rapid onset of action but is generally not suitable for sustained therapy. Methotrexate remains the systemic agent against which others are compared. Biologic agents can produce dramatic responses at dramatic expense.

## Topical treatment

### Corticosteroids

Topical application of corticosteroids in creams, ointments, lotions, foams, and sprays is the most frequently prescribed therapy for localized psoriasis. Class I steroids are suitable for 2-week courses of therapy on most body areas. Therapy can be continued with pulse applications on weekends to reduce the incidence of local adverse effects. On the scalp, corticosteroids in propylene glycol, gel, foam, and spray bases are preferred by most white patients. Black patients may find them drying and may prefer oil and ointment preparations. Low- to mid-strength creams are preferred in the intertriginous areas and on the face. To augment effectiveness of topical corticosteroids in areas with thick keratotic scale, the area should be hydrated before application and covered with an occlusive dressing of polyethylene film (plastic wrap) or a sauna suit. Side effects include epidermal atrophy, steroid acne, miliaria, and pyoderma.

Intralesional injections of triamcinolone are helpful for refractory plaques. Triamcinolone acetonide (Kenalog) suspension, 10 mg/mL, may be diluted with sterile saline to make a concentration of 2.5–5 mg/mL. Good results are also obtained in the treatment of psoriatic nails by injecting triamcinolone into the region of the matrix and the lateral nailfold. A digital block can be performed before injection to provide anesthesia. Injections are given once a month until the desired effect is achieved.

### Tars

Crude coal tar and tar extracts such as liquor carbonis detergens (LCD) can be compounded into agents for topical use. Tar bath oils and shampoos are readily available. Oil of cade (pine tar) or birch tar in concentrations of 5–10% may also be incorporated into ointments. The odor of all tars may be offensive, and relapse is more rapid than with topical agents such as calcipotriene.

### Anthralin

Anthralin is effective but is irritating and stains skin, clothing, and bedding. To avoid these drawbacks, short-contact anthralin treatment (SCAT) can be helpful, with anthralin washed off after 15–30 min. Anthralin exerts a direct effect on keratino-

cytes and leukocytes by suppressing neutrophil superoxide generation and inhibiting monocyte-derived IL-6, IL-8, and TNF- $\alpha$ .

### Tazarotene

Tazarotene is a nonisomerizable retinoic acid receptor-specific retinoid. It appears to treat psoriasis by modulating keratinocyte differentiation and hyperproliferation, as well as by suppressing inflammation. Combining its use with a topical corticosteroid and weekend pulse therapy can decrease irritation.

### Calcipotriene

Vitamin D<sub>3</sub> affects keratinocyte differentiation partly through its regulation of epidermal responsiveness to calcium. Treatment with the vitamin D analog calcipotriene (Dovonex) in ointment, cream, or solution form has been effective in the treatment of plaque-type and scalp psoriasis. Combination therapy with calcipotriene and high-potency steroids may provide greater response rates, fewer side effects, and steroid sparing. Calcipotriene is unstable in the presence of many other topical agents and degrades in the presence of UV light. Monitoring of serum calcium levels in adults is not required. Calcipotriene plus betamethasone dipropionate (Taclonex) is more effective than either agent alone.

### Macrolactams (calcineurin inhibitors)

Topical macrolactams such as tacrolimus and pimecrolimus are especially helpful for thin lesions in areas prone to atrophy or steroid acne. The burning associated with these agents can be problematic but may be avoided by prior corticosteroid treatment and application to dry skin rather than after bathing.

### Salicylic acid

Salicylic acid is used as a keratolytic agent in shampoos, creams, and gels. It can promote the absorption of other topical agents. Widespread application may lead to salicylate toxicity, manifesting with tinnitus, acute confusion, and refractory hypoglycemia, especially in patients with diabetes and those with compromised renal function.

### Ultraviolet light

Phototherapy is a cost-effective and underused modality for psoriasis. In most cases, sunlight improves psoriasis. However, severe burning of the skin may cause the Koebner phenomenon and an exacerbation. Artificial UVB light is produced by fluorescent bulbs in broad-band or narrow-band (NB) spectrum. Maximal effect is usually achieved at MEDs. Although suberythemogenic doses can be effective, the response is slower than with erythemogenic regimens. With treatment, a tanning response occurs, and the dose must be increased to maintain efficacy. Maintenance UVB phototherapy after clearing contributes to the duration of remission and is justified for many patients.

Using a monochromator, it has been shown that wavelengths of 254, 280, and 290 nm are ineffective; at 296, 300, 304, and 313 nm, however, there is clearing. NB UVB (peak emission about 311 nm) has been more effective in treating psoriasis than broad-band UVB. Erythemogenic doses are not required to achieve a response. The response rates are better than 70% and close to those achievable with psoralen plus ultraviolet A (PUVA) therapy.

### Goekerman technique

Goekerman therapy remains an effective and cost-effective method of treatment even in patients with poor responses to biologic agents. In its modern form, a 2–5% tar preparation is applied to the skin, and a tar bath is taken at least once a day.

The excess tar is removed with mineral or vegetable oil, and UV light is given. In psoriasis day care centers, patients clear in an average of 18 days, and 75% remain free of disease for extended periods. The addition of a topical corticosteroid to the Goeckerman regimen shortens the time required for remission. Phototoxic reactions (tar smarts) may result from UVA generated by the predominantly UVB bulbs.

### **Ingram technique**

Ingram therapy consists of a daily coal tar bath in a solution such as 120 mL LCD to 80 L of warm water. This is followed by daily exposure to UV light for increasing periods. An anthralin paste is then applied to each psoriatic plaque. Talcum powder is sprinkled over the lesions, and stockinette dressings are applied. Modern versions of the technique employ SCAT.

### **PUVA therapy**

High-intensity longwave UV radiation (UVA) given 2 h after ingestion of 8-methoxypsoralen (Oxsoralen-Ultra), twice a week, is highly effective, even in severe psoriasis. Most patients clear in 20–25 treatments, but maintenance treatment is needed.

Although PUVA therapy is highly effective, in patients with less than 50% of the skin surface affected, UVB may be as effective. Polyethylene sheet bath PUVA is another therapeutic alternative to oral psoralen-UVA. The patient is immersed in a psoralen solution contained in plastic sheeting that conforms to the patient's body.

Oral psoralen can produce cataracts, and protective eyewear must be used. PUVA therapy is a risk factor for skin cancer, including squamous cell carcinoma (SCC) and melanoma. Arsenic exposure is a more significant cofactor than prior exposure to methotrexate, UVB, or concomitant use of topical tar. Men treated without genital protection are at an increased risk of developing SCC of the penis and scrotum. Although the risk of cancer is dose related, there is no definitive threshold dose of cumulative PUVA exposure above which carcinogenicity can be predicted.

### **Surgical treatment**

In patients with pharyngeal colonization by streptococci, an excellent response has been reported after tonsillectomy. More effective antibiotic regimens, such as a 10-day course of dicloxacillin combined with rifampin (600 mg/day for adult), have largely replaced tonsillectomy.

### **Hyperthermia**

Local hyperthermia can clear psoriatic plaques, but relapse is usually rapid. Microwave hyperthermia may produce significant complications, such as pain over bony prominences and tissue destruction.

### **Occlusive treatment**

Occlusion with surgical tape or dressings can be effective as monotherapy or when combined with topical drugs.

### **Systemic treatment**

#### **Corticosteroids**

The hazards of the injudicious use of systemic corticosteroids must be emphasized. There is great risk of "rebound" or induction of pustular psoriasis when therapy is stopped. Corticosteroid use is generally restricted to unique circumstances, such as impetigo herpeticiformis when expeditious delivery is not possible.

#### **Methotrexate**

This folic acid antagonist remains the standard against which other systemic treatments are measured. Methotrexate has a greater affinity for dihydrofolic acid reductase than does folic acid. The indications for methotrexate include psoriatic erythroderma, psoriatic arthritis, acute pustular psoriasis (von Zumbusch type), or widespread body surface area (BSA) involvement. Localized pustular psoriasis or palmoplantar psoriasis that impairs normal function and employment may also require systemic treatment.

It is important to ensure the patient has no history of liver or kidney disease. Methotrexate can be toxic to the liver, and decreased renal clearance can enhance toxicity. Other important factors to consider are alcohol abuse, cryptogenic cirrhosis, severe illness, debility, pregnancy, leukopenia, thrombocytopenia, active infectious disease, immunodeficiency, anemia, colitis, and ability to comply with directions. Hepatic enzymes, bilirubin, serum albumin, creatinine, alkaline phosphatase, complete blood count, platelet count, hepatitis serology (B and C), HIV antibody, and urinalysis should all be evaluated before starting treatment. Patients with hypoalbuminemia have a higher risk of developing pulmonary complications.

The need for liver biopsy remains controversial. Biopsy is not without risks and is not usually performed in the setting of methotrexate therapy for rheumatic disease. However, patients with psoriasis have a greater risk of liver disease than other patient populations. In most patients with no risk factors for liver disease, the first liver biopsy is obtained at approximately 1.0–1.5 g of cumulative methotrexate and repeated every subsequent 1.5–2.0 g until a total of 4.0 g is reached. The frequency then changes to every 1.0–1.5 g cumulative intervals. These recommendations are likely to change as more data are evaluated. Weekly blood counts and monthly liver enzyme assessment are recommended at the onset of therapy or when the dosage is changed. Monitoring of aminoterminal procollagen III peptide may reduce the need for liver biopsy.

Numerous treatment schedules have evolved. The authors recommend either three divided oral doses (12 h apart) weekly, weekly single doses orally, or single weekly subcutaneous injections. The weekly dose varies from 5 mg to more than 50 mg, with most patients requiring 15–30 mg a week. Once a single dose exceeds 25 mg, oral absorption is unpredictable, and subcutaneous injections are recommended. Midweek doses can result in severe toxicity and must be avoided. Oral or cutaneous ulceration may be a sign that the patient has taken a midweek dose. Oral folic acid has been reported to decrease side effects, especially nausea, and doses of 1–4 mg/day are used. Oral folic acid is not adequate for the treatment of overdosage, and leukovorin must be used in such cases.

#### **Cyclosporine**

The therapeutic benefit of cyclosporine in psoriatic disease may be related to downmodulation of proinflammatory epidermal cytokines. The microemulsion formulation Neoral has greater bioavailability and is now standard. Doses of 2–5 mg/kg/day generally produce rapid clearing of psoriasis, with both efficacy and risk being dose related. Unfortunately, the lesions recur rapidly as well, and transition to another form of therapy is required. Treatment durations of up to 6 months are associated with a low incidence of renal complications, but blood pressure and serum creatinine must be monitored and doses adjusted accordingly. Usually, the dose is reduced if the baseline creatinine increases by one-third. Some data support the feasibility of pulse dosing for a few days each week for both the induction and the maintenance of response in psoriasis patients.



## Diet

The anti-inflammatory effects of fish oils rich in n-3 polyunsaturated fatty acids (PUFAs) have been demonstrated in RA, inflammatory bowel disease, psoriasis, and asthma. n-3 and n-6 PUFAs affect a variety of cytokines, including IL-1, IL-6, and TNF. Herbal remedies have also been used with variable effects. Many of these products are unpalatable, and their efficacy does not compare favorably to pharmacologic agents.

## Oral antimicrobial therapy

The association of streptococcal pharyngitis with guttate psoriasis is well established. *Staphylococcus aureus* and streptococci secrete exotoxins that act as superantigens, producing massive T-cell activation, and pharyngeal colonization should be addressed as previously noted. Oral bile acid supplementation has been shown to improve psoriasis, presumably by affecting the microflora and endotoxins in the gut. Oral ketoconazole, itraconazole, and other antibiotics have shown efficacy in a limited number of patients with psoriasis.

## Retinoids

Oral treatment with the aromatic retinoid ethylester etretinate has been effective in many patients with psoriasis, especially in pustular disease. Because of its long half-life, etretinate has been replaced by acitretin. Alcohol ingestion can convert acitretin to etretinate and is discouraged. 13-*Cis*-retinoic acid can also produce good results in some patients with pustular psoriasis. All these drugs are potent teratogens, and elevated triglyceride levels may complicate therapy. Combinations of retinoic acids with photochemotherapy can be effective in chronic plaque psoriasis, resulting in lowered cumulative doses of light.

## Dapsone

Dapsone use is limited largely to palmoplantar pustulosis or other variants of pustular psoriasis. Even in this setting, it is a second-line or third-line agent with limited efficacy.

## Biologic agents

A number of biologic agents are available that can produce dramatic responses in some patients with psoriasis; all are expensive. Retrospective analysis using BSA multiplied by physician's global assessment as an endpoint suggests that outcomes with biologic agents are superior to those with other systemic agents, despite the patients taking biologics having a higher baseline severity and a greater number of previous treatments.

Several agents block TNF- $\alpha$ . Infliximab is a chimeric monoclonal antibody (mAb) to TNF- $\alpha$  and requires intravenous infusion; etanercept is a fusion protein of human TNF type II receptor and the Fc region of IgG1; and adalimumab is a recombinant, fully human IgG1 mAb to TNF- $\alpha$ . Alefacept is a fusion protein of the external domain of LFA-3 and the Fc region of IgG1; it blocks T-cell activation and triggers apoptosis of pathogenic T cells. Golimumab is an anti-TNF agent with less frequent dosing used in patients with psoriatic arthritis, and certolizumab has also demonstrated efficacy. Ustekinumab, a human mAb against IL-12 and IL-23, is the first of a new class of agents that appear highly effective. They block the inflammatory pathway at a more proximal point than anti-TNF agents.

## Percentage of patients clearing with each drug

Published data allow for some comparisons of biologic agents, but the endpoints of some trials differ. A meta-analysis of

published trials suggests that of the agents studied at the end of the induction phase (week 24), ustekinumab has the greatest probability of achieving at least 75% improvement from baseline in the psoriasis area and severity index (PASI 75), followed by infliximab, adalimumab, and etanercept. Newer anti-IL-17 agents can achieve PASI 100, a dramatic improvement over previous biologic agents. The anti-IL-17 agents include secukinumab, ixekizumab, and brodalumab. For comparison, in controlled trials of infliximab, the percentage of patients reaching PASI 75 at week 10 is about 70% with infliximab at 3 mg/kg and 90% at 5 mg/kg, compared with 6% for placebo. About 35% of patients receiving etanercept, 25 mg subcutaneously twice weekly, achieve PASI 75 at 12 weeks and 45% at 24 weeks. With the 50-mg induction dose administered twice a week, about 46% of patients achieve PASI 75 at 12 weeks and 50% at 24 weeks. The data available suggest that about 53% of patients taking 40 mg of adalimumab every other week achieve PASI 75 by week 12, and about 80% of those taking 40 mg a week achieve PASI 75.

## Risks

The anti-TNF agents may induce flares of psoriasis through upregulation of plasmacytoid dendritic cells. This may be a class effect. The biologic agents all suppress the normal immune response. Infliximab has been associated with reactivation of tuberculosis, demyelinating disease, and serious systemic opportunistic infection. Infliximab may also lose its effect because of neutralizing antibodies. Methotrexate or azathioprine may be needed as concomitant therapy to reduce the incidence of neutralizing antibodies and infusion reactions. Even though adalimumab is a fully human antibody, it may also induce an antibody response. Serious infections have been reported in RA patients treated with this agent. Etanercept has been associated with infection, onset, or exacerbation of multiple sclerosis, vasculitis, and LE-like manifestations. All these effects are rare and may not be statistically increased from the general population. Many of the reported complications, such as lymphoma, demyelinating disease, progressive multifocal leukoencephalopathy and infection, are not unique to any one immunosuppressive agent.

The National Psoriasis Foundation has endorsed a recommendation that all patients be screened for latent tuberculosis infection before any immunologic therapy. The Foundation recommends delaying immunologic therapy until prophylaxis for latent tuberculosis infection is completed, although noting that patients with severe disease may be treated after 1–2 months of prophylaxis. IFN- $\gamma$  assays have greater specificity than tuberculin skin tests and are being used along with imaging studies to confirm tuberculosis in patients with positive skin tests.

## Combination therapy

In more severe forms of psoriasis, a combination of treatment modalities may be employed. In treating patients with methotrexate, for example, concomitant topical agents may be used to minimize the dose. Methotrexate has been combined with infliximab to reduce the incidence of neutralizing antibodies, and also has been used with acitretin in managing patients with severe, generalized pustular psoriasis. The use of PUVA and retinoids is called Re-PUVA and has been studied extensively. Acitretin has been combined with biologic agents to treat refractory psoriasis. Combination systemic therapy has the potential to reduce overall toxicity if the toxicities of each agent are different. However, new regimens should be used with caution because of the potential for cumulative toxicity or drug interaction.

## Evolving therapies

Alternative therapies for psoriasis include mycophenolate mofetil, sulfasalazine, paclitaxel, azathioprine, fumaric acid esters, climatotherapy, and grenz ray therapy. Nail disease can respond to systemic agents, topical retinoids, local triamcinolone injections, and topical 5-fluorouracil. The latter agent can cause onycholysis if applied to the free edge of the nail. Apremilast, a small molecule specific inhibitor of phosphodiesterase 4, has demonstrated efficacy in recalcitrant plaque psoriasis. Janus kinase (JAK) inhibitors such as tofacitinib have demonstrated efficacy in the treatment of psoriasis. The side effect profile of tofacitinib includes dose-dependent decreases in red blood cell counts, along with transient or reversible dose-dependent decreases in neutrophil counts. Tofacitinib has also demonstrated transient increases in lymphocyte counts, primarily attributable to increases in B-cell counts.

**Akaraphanth R, et al:** Efficacy of a far erythemogenic dose of narrow-band ultraviolet B phototherapy in chronic plaque-type psoriasis. *J Dermatol* 2010; 37(2):140–145.

**Au SC, et al:** Comparison of the efficacy of biologics versus conventional systemic therapies in the treatment of psoriasis at a comprehensive psoriasis care center. *J Drugs Dermatol* 2013; 12(8):861–866.

**Bhatia BK, et al:** Diet and psoriasis. Part II. Celiac disease and role of a gluten-free diet. *J Am Acad Dermatol* 2014; 71:350–358.

**Berends MA, et al:** Reliability of the Roenigk classification of liver damage after methotrexate treatment for psoriasis: a clinicopathologic study of 160 liver biopsy specimens. *Arch Dermatol* 2007; 143(12):1515–1519.

**Chirch LM, et al:** Proactive infectious disease approach to dermatologic patients who are taking tumor necrosis factor- $\alpha$  antagonists. Part I. Risks associated with tumor necrosis factor- $\alpha$  antagonists. *J Am Acad Dermatol* 2014; 71:1.e1–8.

**Chirch LM, et al:** Proactive infectious disease approach to dermatologic patients who are taking tumor necrosis factor- $\alpha$  antagonists. Part II. Screening for patients on tumor necrosis factor- $\alpha$  antagonists. *J Am Acad Dermatol* 2014; 71:11.e1–7.

**Colombo MD, et al:** Cyclosporine regimens in plaque psoriasis: an overview with special emphasis on dose, duration, and old and new treatment approaches. *SciWorldJ* 2013 Jul 25; 2013:805705.

**Debbaneh M, et al:** Diet and psoriasis. Part I. Impact of weight loss interventions. *J Am Acad Dermatol* 2014; 71:133–140.

**Demirsoy EO, et al:** Effectiveness of systemic treatment agents on psoriatic nails: a comparative study. *J Drugs Dermatol* 2013; 12(9):1039–1043.

**Filkor K, et al:** Genome wide transcriptome analysis of dendritic cells identifies genes with altered expression in psoriasis. *PLoS One* 2013; 8(9):e73435.

**Fitzmaurice S, et al:** Goeckerman regimen for management of psoriasis refractory to biologic therapy: the University of California San Francisco experience. *J Am Acad Dermatol* 2013; 69(4):648–649.

**Gan EY, et al:** Therapeutic strategies in psoriasis patients with psoriatic arthritis: focus on new agents. *BioDrugs* 2013; 27(4):359–373.

**Gottlieb AB, et al:** Efficacy, tolerability, and pharmacodynamics of apremilast in recalcitrant plaque psoriasis: a Phase II open-label study. *J Drugs Dermatol* 2013; 12(8):888–897.

**Kwatra SG, et al:** JAK inhibitors in psoriasis: a promising new treatment modality. *J Drugs Dermatol* 2012; 11(8):913–918.

**Millsop JW, et al:** Diet and psoriasis. Part III. Role of nutritional supplements. *J Am Acad Dermatol* 2014; 71:561–569.

**Puig L, et al:** Efficacy of biologics in the treatment of moderate-to-severe plaque psoriasis: a systematic review and meta-analysis of randomized controlled trials with different time points. *J Eur Acad Dermatol Venereol* 2013; Aug 19. doi: 10.1111/jdv.12238. [Epub ahead of print.] PMID: 24033851.

**Punwani N, et al:** Preliminary clinical activity of a topical JAK1/2 inhibitor in the treatment of psoriasis. *J Am Acad Dermatol* 2012; 67(4):658–664.

**Singh P, et al:** Comparative evaluation of topical calcipotriol versus coal tar and salicylic acid ointment in chronic plaque psoriasis. *J Drugs Dermatol* 2013; 12(8):868–873.

**Skroza N, et al:** Correlations between psoriasis and inflammatory bowel diseases. *Biomed Res Int* 2013; 2013:983902.

**Villacorta R, et al:** Cost-effectiveness of moderate to severe psoriasis therapy with etanercept and ustekinumab in the United States. *Pharmacoeconomics* 2013; 31(9):823–839.

**Wu JJ, et al:** Association of gender, tumor necrosis factor inhibitor therapy, and myocardial infarction risk in patients with psoriasis. *J Am Acad Dermatol* 2013; 69(4):650–651.

## REACTIVE ARTHRITIS WITH CONJUNCTIVITIS/URETHRITIS/DIARRHEA (REITER SYNDROME)

Reiter syndrome is a characteristic clinical triad of urethritis, conjunctivitis, and arthritis. The disease occurs chiefly in young men of HLA-B27 genotype, generally following a bout of urethritis or diarrheal illness. Systemic involvement can include the gastrointestinal tract, kidneys, central nervous system, and cardiovascular system. Because few patients present with the classic triad, the American College of Rheumatology recognizes criteria for limited manifestations of the syndrome, including peripheral arthritis of more than 1-month duration in association with urethritis, cervicitis, or bilateral conjunctivitis.

Hans Reiter was a Nazi war criminal, involved with or having knowledge of involuntary sterilization as well as a study of an experimental typhus vaccine that resulted in hundreds of deaths of concentration camp internees. Some believe that he should no longer be afforded the name recognition to designate the syndrome.

## Clinical features

Any part of the triad may occur first, often accompanied by fever, weakness, and weight loss. Although the inciting urethritis may be bacterial, later manifestations include a nonbacterial urethritis with painful urination and pyuria. Cystitis, prostatitis, and seminal vesiculitis may be accompaniments. Vulvar ulceration has been reported. About one third of patients develop conjunctivitis, which may be bulbar, tarsal, or angular. Keratitis is usually superficial and extremely painful. Iritis is common, especially in recurrent cases. Infrequently, optic neuritis may occur. Uveitis correlates with axial joint disease and HLA-B27 positivity. An asymmetric arthritis may affect peripheral joints, especially weight-bearing joints. Its onset is usually sudden. Pain in one or both heels is a frequent symptom. Sacroiliitis may develop in up to two thirds of patients, most of whom are of HLA-B27 type.

The skin involvement usually begins with small, guttate, hyperkeratotic, crusted or pustular lesions of the genitals (Fig. 10-12), palms, or soles. Involvement of the glans penis (balanitis circinata) occurs in 25% of patients. Lesions on the soles and trunk often become thickly crusted or hyperkeratotic. The eruption on the soles is known as keratoderma blennorrhagicum and occurs in 10% of patients (Fig. 10-13). The buccal, palatal, and lingual mucosa may show painless, shallow, red erosions. The nails become thick and brittle, with heavy subungual keratosis. Children are much more likely to have the postdysenteric form, often with conjunctivitis and arthritis as the most prominent complaints.

The syndrome generally follows an infectious urethritis or diarrheal illness. Implicated organisms include *Chlamydia*, *Shigella*, *Salmonella*, *Yersinia*, *Campylobacter*, *Ureaplasma*, *Borrelia*, *Cryptosporidium*, gonococci, and bacille Calmette-Guérin (BCG). *Chlamydia trachomatis* and *Ureaplasma urealyticum* have been isolated from the synovial fluid of affected joints, and some patients respond to antibiotic therapy. Chlamydial antigens demonstrate high homology with human sequences containing the binding motif of HLA-B27. Reiter syndrome has



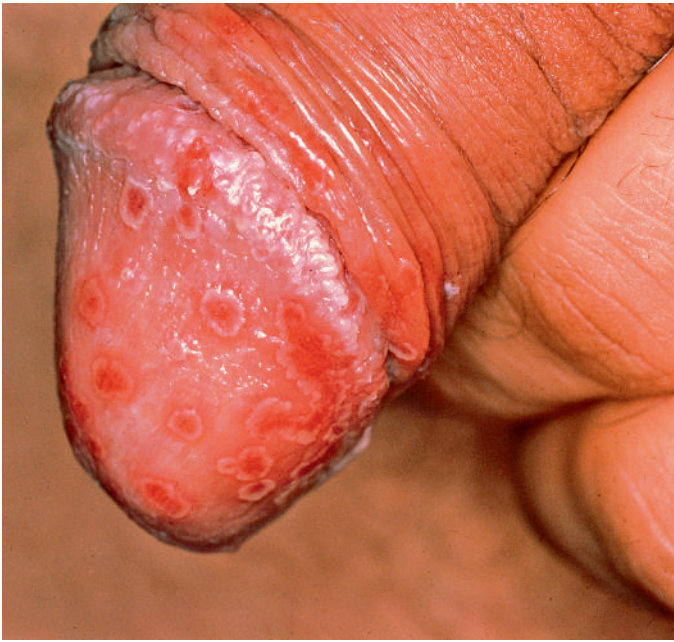

Fig. 10-12 Genital involvement in reactive arthritis.

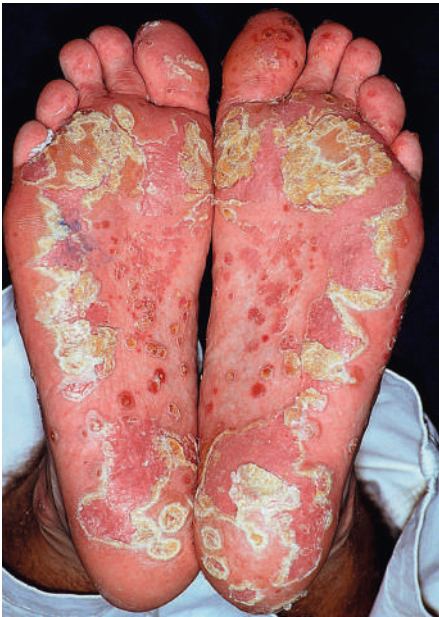

Fig. 10-13  
Keratoderma  
blennorrhagicum.

also been observed in HIV disease but may not be directly related to the virus, because it frequently occurs during treatment as the immune response improves. The disease has also been triggered by adalimumab and leflunomide in the setting of ankylosing spondyloarthritis and Crohn's disease.

Peripheral leukocytosis of 10000–20000/mm<sup>3</sup> and elevated erythrocyte sedimentation rate are the most consistent findings. There is no specific test for Reiter syndrome. The differential diagnosis includes RA, ankylosing spondylitis, gout, psoriatic arthritis, gonococcal arthritis, acute rheumatic fever, chronic mucocutaneous candidiasis, and serum sickness. The presence of associated mucocutaneous lesions establishes the diagnosis. Some cases of Lyme disease overlap with Reiter syndrome. Individual skin lesions may be indistinguishable from those in psoriasis. Hyperkeratotic lesions generally have a thicker scale crust than most psoriatic plaques, but are otherwise identical.

Mucocutaneous lesions are generally self-limited and clear with topical corticosteroids. Joint disease is managed with rest and NSAIDs. Antibiotics, such as doxycycline, have been effective in some cases. Immunosuppressive agents, such as methotrexate, are used for refractory joint disease. Infliximab has been successful in treating severe disease. Refractory skin lesions are treated similar to refractory psoriasis, and severely affected patients have responded to acitretin or cyclosporine.

**Alvarez-Navarro C, et al:** Novel HLA-B27-restricted epitopes from *Chlamydia trachomatis* generated upon endogenous processing of bacterial proteins suggest a role of molecular mimicry in reactive arthritis. *J Biol Chem* 2013; 288(36):25810–25825.

**Connor BA, et al:** Post-infectious sequelae of travelers' diarrhea. *J Travel Med* 2013; 20(5):303–312.

**Sampaio-Barros PD, et al:** An analysis of 372 patients with anterior uveitis in a large Ibero-American cohort of spondyloarthritis: the RESPONDIA Group. *Clin Exp Rheumatol* 2013; 31(4):484–489.

**Vasala M, et al:** High frequency of reactive arthritis in adults after *Yersinia pseudotuberculosis* O:1 outbreak caused by contaminated grated carrots. *Ann Rheum Dis* 2014; 73(10):1793–1796.

### SUBCORNEAL PUSTULAR DERMATOSIS (SNEDDON-WILKINSON DISEASE)

In 1956, Sneddon and Wilkinson described a chronic pustular disease that occurred chiefly in middle-age women. The pustules are superficial and arranged in annular and serpiginous patterns, especially on the abdomen, axillae, and groins. Cultures from the pustules are sterile. Oral lesions are rare. The condition is chronic, with remissions of variable duration.

Histologically, the pustules form below the stratum corneum, as in impetigo. Acantholysis is absent, but spongiform pustules may be noted in the upper epidermis. The histologic differential diagnosis includes pustular psoriasis and superficial fungal and bacterial infections.

IgA pemphigus shows significant overlap with subcorneal pustular dermatosis. Presentations of IgA pemphigus include subcorneal pustular dermatosis and intraepidermal neutrophilic IgA dermatosis types. Immunoblotting techniques have shown that human desmocollin 1 is an autoantigen for the subcorneal pustular dermatosis type of IgA pemphigus.

Localized cases may respond well to topical corticosteroids. Dapsone, 50–200 mg/day (adult), is effective for most of the remaining cases. Some patients have responded better to sulfapyridine therapy. Acitretin, NB UVB phototherapy, colchicine, azithromycin, biologic agents, and tetracycline with niacinamide may also be effective in subcorneal pustular dermatosis.

**Bedi MKL:** Successful treatment of long-standing, recalcitrant subcorneal pustular dermatosis with etanercept. *Skinmed* 2007; 6(5):245–247.

**Bliziotis I, et al:** Regression of subcorneal pustular dermatosis type of IgA pemphigus lesions with azithromycin. *J Infect* 2005; 51:E31.

### EOSINOPHILIC PUSTULAR FOLLICULITIS

Eosinophilic pustular folliculitis (EPF) was first described in 1970 by Ofuji, although it is also referred to as sterile eosinophilic pustulosis. It occurs more often in males and is mostly reported in Asia. The mean age of onset is 35. It is characterized by pruritic, follicular papulopustules that measure 1–2 mm. The lesions tend to be grouped, and plaques usually form. New lesions may form at the edges of the plaques, leading to peripheral extension, while central clearing takes place. The most frequent site is the face, particularly over the cheeks. The trunk and upper extremities frequently are

affected, and 20% have palmoplantar pustules. The distribution is usually asymmetric, and the typical course is one of spontaneous remissions and exacerbations lasting several years. The condition must be distinguished from HIV-associated eosinophilic folliculitis (see Chapter 19). A similar condition has occurred in association with HCV infection, with allopurinol, and during pregnancy.

Histologically, there is spongiosis and vesiculation of the follicular infundibulum and heavy infiltration with eosinophils. Follicular mucinosis may be present. There is a peripheral eosinophilia in half the cases, and pulmonary eosinophilia has been described. The cause is unknown; but numerous studies have implicated chemotactic substances, intercellular adhesion molecule 1 (ICAM-1), and cyclooxygenase-generated metabolites. Tryptase-positive and chymase-negative mast cells have also been implicated.

Indomethacin is effective in the vast majority of patients with eosinophilic pustular folliculitis. Topical and intralesional corticosteroids, clofazimine, minocycline, isotretinoin, UVB therapy, dapsone, colchicine, cyclosporine, topical tacrolimus, nicotine patches, infliximab, and cetirizine have also been reported as effective.

Childhood cases have been described. This subset differs from the typical cases in Asian males. Pediatric patients develop sterile pustules and papules preferentially over the scalp, although scattered clusters of pustules may occur over the trunk and extremities. Leukocytosis and eosinophilia are often present. Recurrent exacerbations and remissions usually occur, with eventual spontaneous resolution. High-potency topical steroids are the treatment of choice in pediatric patients.

**Hasegawa A, et al:** A case of eosinophilic pustular folliculitis with response to infliximab. *J Am Acad Dermatol* 2012; 67(4):e136–e137.

**Hernández-Martín Á, et al:** Eosinophilic pustular folliculitis of infancy: a series of 15 cases and review of the literature. *J Am Acad Dermatol* 2013; 68(1):150–155.

**Lim HL, et al:** Recalcitrant eosinophilic pustular folliculitis of Ofuji with palmoplantar pustulosis: dramatic response to narrowband UVB phototherapy. *Photodermatol Photoimmunol Photomed* 2012; 28(4):219–221.

**Oka D, et al:** Refractory eosinophilic pustular folliculitis resistant to oral indomethacin successfully treated with adjuvant topical indomethacin. *J Dermatol* 2014; 41:860–861.

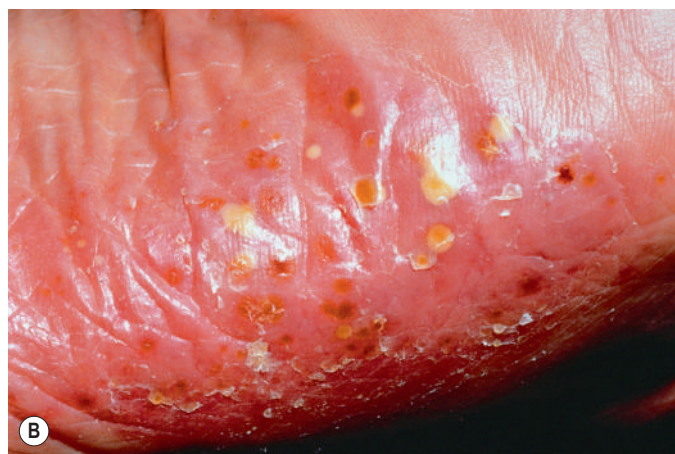
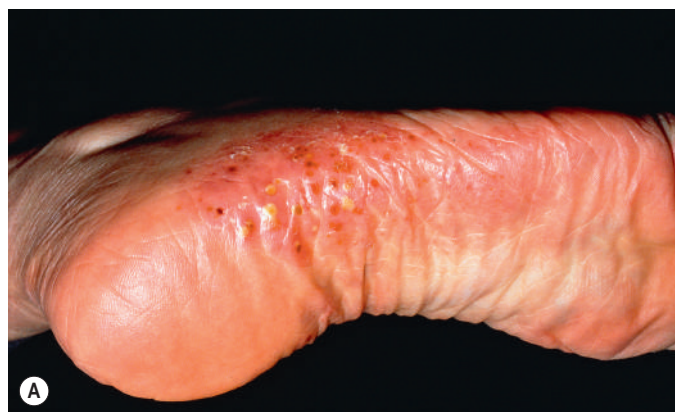**Yoshifuku A, et al:** Transdermal nicotine patches for eosinophilic pustular folliculitis. *J Dermatol* 2013; 40(9):711–714.

## RECALCITRANT PALMOPLANTAR ERUPTIONS

### Dermatitis repens

Dermatitis repens, also known as acrodermatitis continua (see earlier) and acrodermatitis perstans, is a chronic inflammatory disease of the hands and feet. It usually remains stable on the extremities, but in rare cases, generalized pustular flares may occur. The disease usually begins distally on a digit, either as a pustule in the nail bed or as a paronychia. Extension takes place by eruption of fresh pustules with subsequent hyperkeratosis and crusting. The disease is usually unilateral at first and asymmetric throughout its entire course. As the disease progresses, one or more of the nails may become dystrophic or float away on pus. Anonychia is common in chronic cases. Some have used the term dermatitis repens to refer to more indolent involvement of the distal fingers.

Involvement of the mucous membranes may occur, even when the eruption of the skin is localized. Painful, circular, white plaques surrounded by inflammatory areolae are found on the tongue and may form a fibrinous membrane. Fissured or geographic tongue may occur.



**Fig. 10-14** A, Plantar pustulosis. B, Pustules and hyperkeratosis are typical.

Histologically, intraepithelial spongiform pustules identical to those of psoriasis are seen in the acute stage. Later stages show hyperkeratosis with parakeratosis or atrophy.

Numerous treatment options have been used, including topical corticosteroids, calcipotriene, dapsone, sulfapyridine, methotrexate, PUVA, acitretin, cyclosporine, and topical mechlorethamine, anti-TNF agents, and anakinra. The choice of agent to use should consider the severity of disease and the patient's age and functional impairment.

### Palmoplantar pustulosis (pustular psoriasis of extremities)

Chronic palmoplantar pustulosis is essentially a bilateral and symmetric dermatosis (Fig. 10-14). The favorite locations are the thenar or hypothenar eminences or the central portion of the palms and soles. The patches begin as erythematous areas in which minute intraepidermal pustules form. At the beginning, these are pinhead sized; then they may enlarge and coalesce to form small lakes of pus. As the lesions resolve, denuded areas, crusts, or hyperkeratosis may persist. Palmoplantar pustulosis is strongly associated with thyroid disorders and cigarette smoking. Medications such as lithium, which aggravate psoriasis, have also been reported to induce palmoplantar pustular psoriasis.

In 1968, Kato described the first case of bilateral clavicular osteomyelitis with palmar and plantar pustulosis. In 1974, Sonozaki described persistent palmoplantar pustulosis and sternoclavicular hyperostosis. These conditions belong to the spectrum of skin and joint involvement designated by Kahn



as the SAPHO syndrome (synovitis, acne, pustulosis, hyperostosis, and osteitis). Common features include palmoplantar pustulosis, acneiform eruption, and pain and swelling of a sternoclavicular joint or at sternomanubrial or costochondral junctions. There is shoulder, neck, and back pain, and limitation of motion of the shoulders and neck is common. Brachial plexus neuropathy and subclavian vein occlusion may occur. The lumbar spine and sacroiliac joints are usually spared. Chronic multifocal osteomyelitis in children may be a pediatric variant. Others have described an association between palmoplantar pustulosis and arthritis or osteitis. SAPHO syndrome may coexist with features of Behçet's disease. The knees, spine, and ankles may be involved. Ivory vertebrae have been described.

The disease typically is resistant to treatment. Topical corticosteroids, retinoids, calcipotriene, and macrolactams are of some benefit. Acitretin is generally extremely effective at 1 mg/kg/day, although rebound occurs more quickly than with etretinate. Low-dose cyclosporine, 1.25–5 mg/kg/day, has also been effective, but it is not suitable for long-term treatment. Dapsone, colchicine, leflunomide, and mycophenolate mofetil may be effective. Oral 8-methoxypsoralen and high-intensity UVA irradiation or soak PUVA can both be helpful, and grenz ray therapy can induce prolonged remissions in some patients. Chronic osteomyelitis in SAPHO syndrome has been reported to respond to bisphosphonates.

### Pustular bacterid

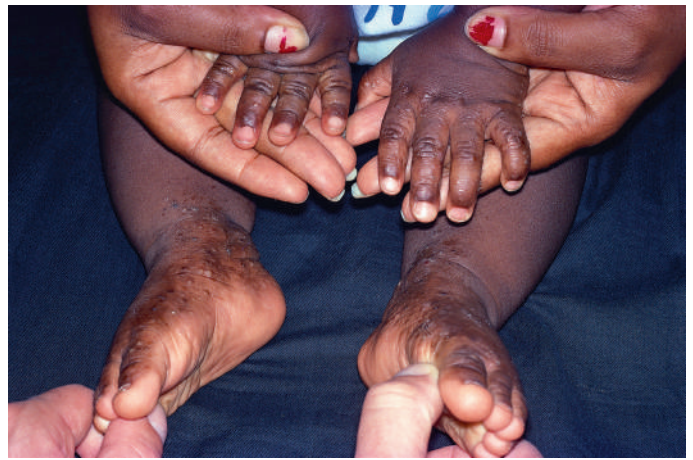Pustular bacterid was first described by George Andrews. It is characterized by a symmetric, grouped, vesicular, or pustular eruption on the palms and soles, marked by exacerbations and remissions over long periods. Andrews regarded the discovery of a remote focus of infection, and cure on its elimination, as crucial to the diagnosis.

The primary lesions are pustules. Tiny hemorrhagic puncta intermingled with the pustules are frequently seen. When lesions are so numerous as to coalesce, they form a honey-comblike structure in the epidermis. The disease usually begins on the midportions of the palms or soles, from which it spreads outwardly until it may eventually cover the entire flexor aspects of the hands and feet. There is no involvement of the webs of the fingers or toes, as in tinea pedis.

When the eruption is fully developed, both palms and soles are completely covered, and the symmetry is pronounced. During fresh outbreaks, the white blood count may show a leukocytosis that ranges from 12,000 to 19,000 cells/mm<sup>3</sup> with 65–80% neutrophils. As a rule, scaling is present in fully evolved lesions, and the scales are adherent, tough, and dry. During exacerbations, crops of pustules or vesicles make their appearance, and there is often severe itching of the areas. Tenderness may be present. Many regard this condition as a variant of psoriasis, triggered by infection.

### Infantile acropustulosis

Infantile acropustulosis is an intensely itchy vesicopustular eruption of the hands and feet (Fig. 10-15). Most cases begin



**Fig. 10-15** Acropustulosis of infancy. (Courtesy of Curt Samlaska, MD).

by 10 months of age. Lesions often predominate at the edges of the palms and soles. Individual crops of lesions clear in a few weeks, but recurrences may continue for months or years. Most cases are postscabetic, and active scabies can produce similar lesions.

Histologically, a subcorneal pustule with neutrophils is noted. Eosinophils may be numerous. The lesions are easily punctured to produce smears of the inflammatory cells, so biopsies are seldom employed.

Lesions often respond to topical corticosteroids. Refractory lesions may respond to dapsone at doses of 1–2 mg/kg/day.

**Abbas O, et al:** Acrodermatitis continua of Hallopeau is a clinical phenotype of DITRA: evidence that it is a variant of pustular psoriasis. *Dermatology* 2013; 226(1):28–31.

**Lutz V, et al:** Acitretin- and tumor necrosis factor inhibitor-resistant acrodermatitis continua of Hallopeau responsive to the interleukin 1 receptor antagonist anakinra. *Arch Dermatol* 2012; 148(3):297–299.

**Sehgal VN, et al:** Acrodermatitis continua of Hallopeau: evolution of treatment options. *Int J Dermatol* 2011; 50(10):1195–1211.

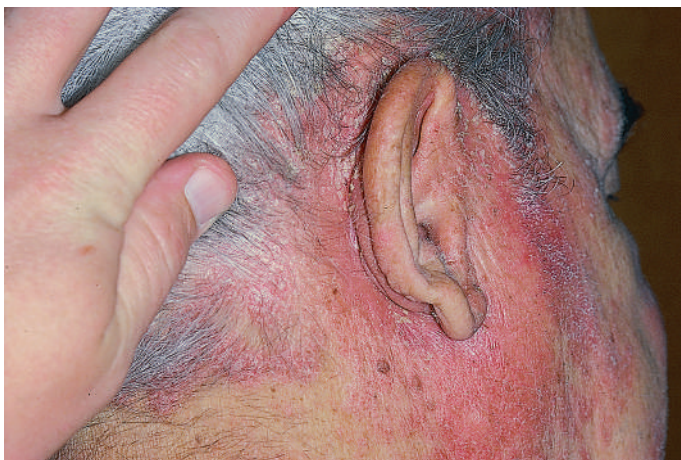

Bonus images for this chapter can be found online at

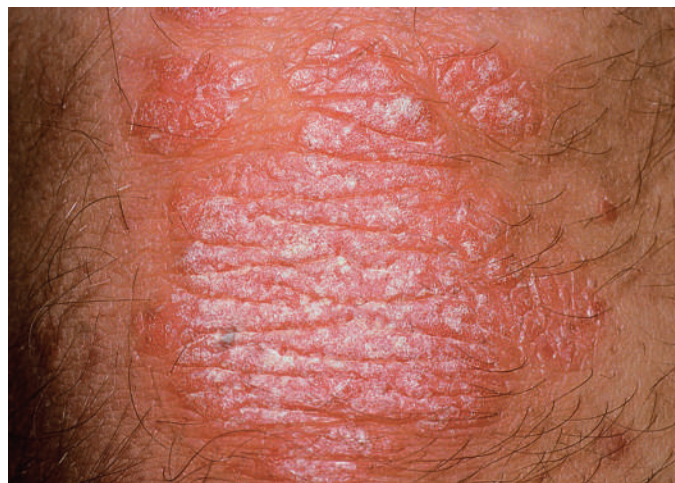[expertconsult.inkling.com](http://expertconsult.inkling.com)

- eFig. 10-1 Seborrheic dermatitis.
- eFig. 10-2 Seborrheic dermatitis involving the chest.
- eFig. 10-3 Psoriasis.
- eFig. 10-4 Psoriasis plaque, red plaque with silver scale on the knee.
- eFig. 10-5 Inverse psoriasis.
- eFig. 10-6 Nail pitting.
- eFig. 10-7 Nail bed involvement in acrodermatitis continua.
- eFig. 10-8 Guttate psoriasis.
- eFig. 10-9 Erythrodermic psoriasis.
- eFig. 10-10 Plantar pustulosis.
- eFig. 10-11 Psoriasis.

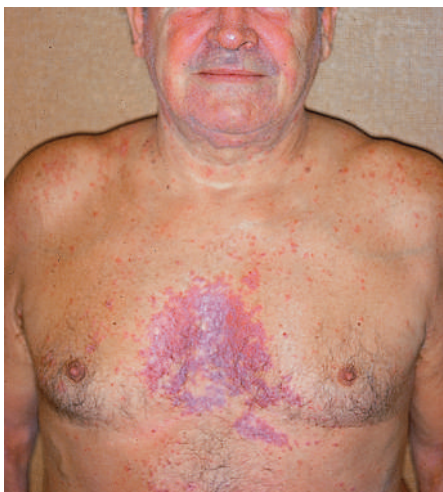



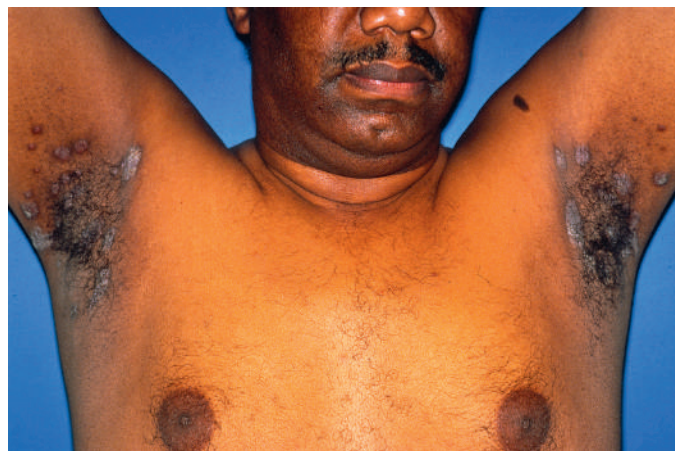**eFig. 10-1** Seborrheic dermatitis.



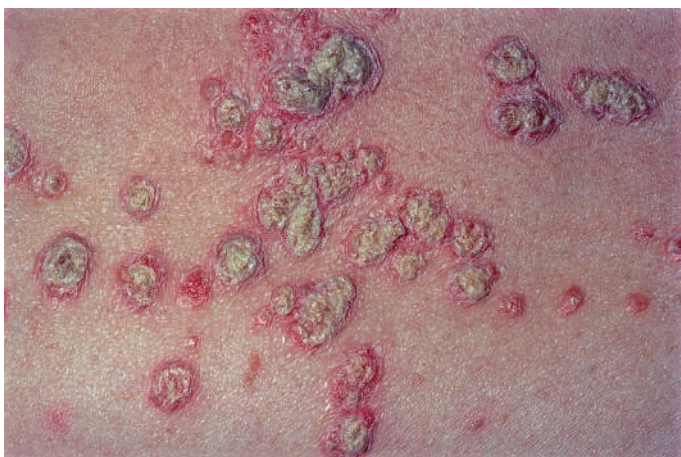**eFig. 10-4** Psoriasis plaque, red plaque with silver scale on the knee.



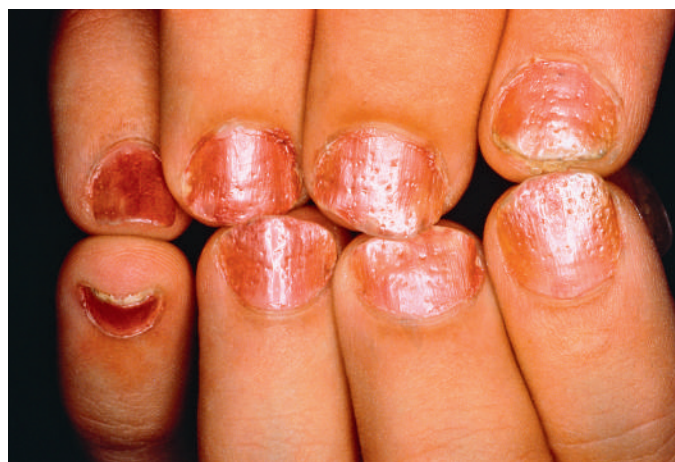**eFig. 10-2** Seborrheic dermatitis involving the chest.



**eFig. 10-5** Inverse psoriasis.

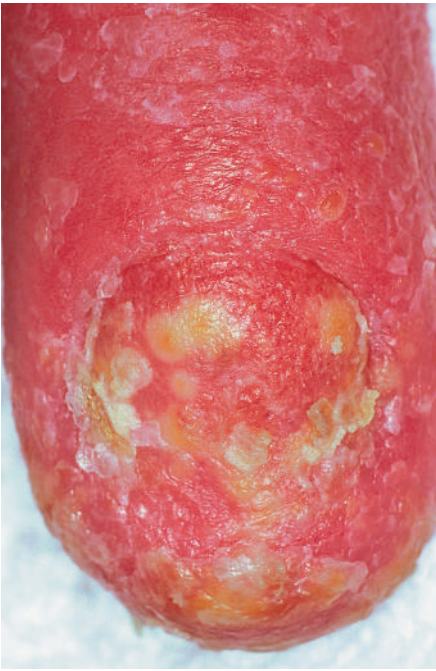

**eFig. 10-3** Psoriasis.

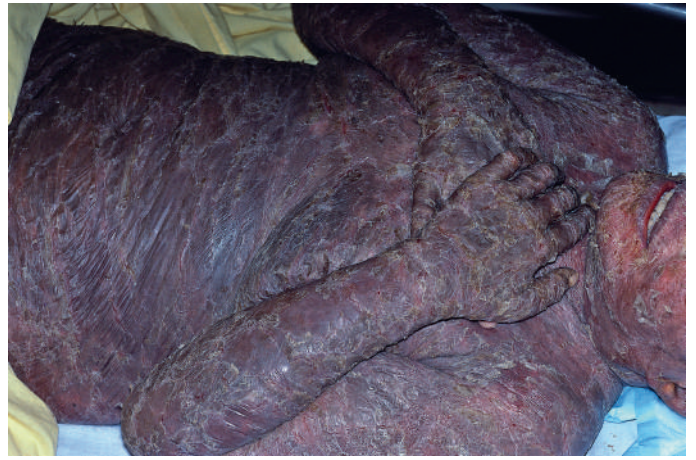

**eFig. 10-6** Nail pitting.

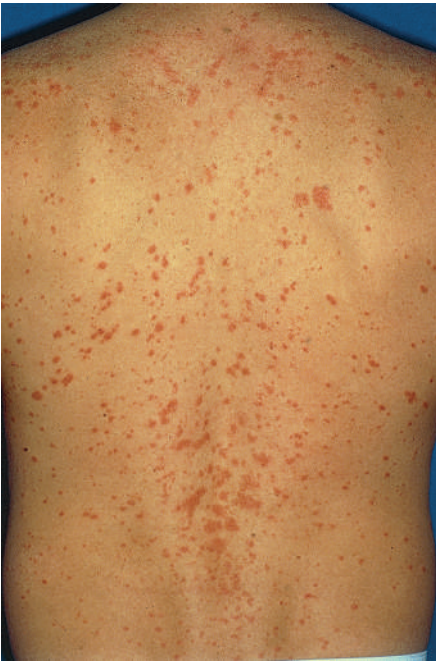



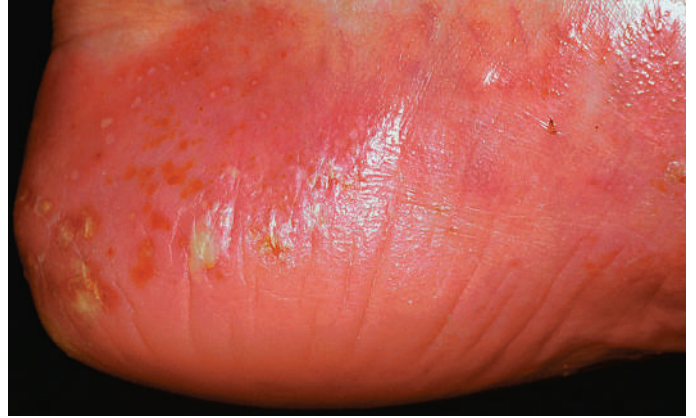
**eFig. 10-7** Nail bed involvement in acrodermatitis continua.



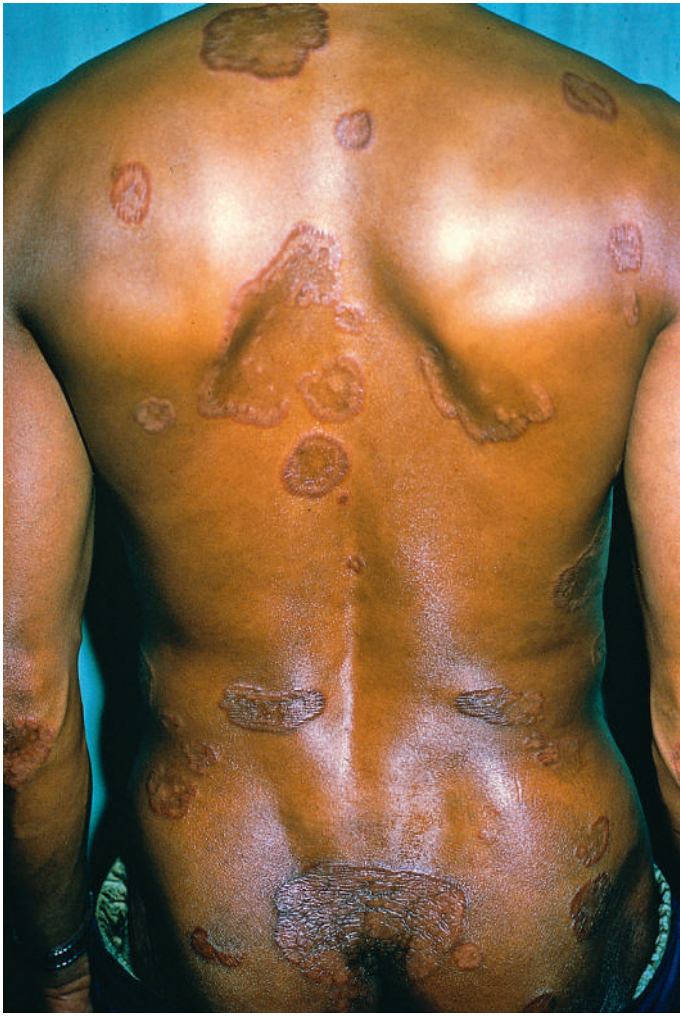**eFig. 10-9** Erythrodermic psoriasis.



**eFig. 10-8** Guttate psoriasis.



**eFig. 10-10** Plantar pustulosis.



**eFig. 10-11** Psoriasis.



## Pityriasis Rosea, Pityriasis Rubra Pilaris, and Other Papulosquamous and Hyperkeratotic Diseases

### SMALL PLAQUE PARAPSORIASIS

Small plaque parapsoriasis (SPP) is characterized by hyperpigmented or yellowish red scaling patches, round to oval in configuration, with sharply defined, regular borders. Most lesions occur on the trunk, and all are 1–5 cm in diameter. In the digitate variant, yellowish tan, elongated, fingerprintlike lesions are oriented along the cleavage lines, predominantly on the flank (Fig. 11-1). These lesions may at times be longer than 5 cm. There is an absence of the induration, the large, erythematous to purplish red lesions, and poikiloderma that characterize small patches of cutaneous T-cell lymphoma in its early stages. The eruption may be mildly itchy or asymptomatic and has a definite male preponderance. Typical SPP rarely progresses to mycosis fungoides, although the histologic changes can overlap, and clonality may be demonstrated. Debate continues on this issue. A hypopigmented variant may have a somewhat higher rate of progression to hypopigmented mycosis fungoides. SPP has been reported in the setting of liposarcoma, with resolution of the eruption after resection of the tumor.

The histologic findings of SPP are characterized by an infiltrate in the superficial dermis composed predominantly of lymphocytes. The overlying epidermis demonstrates mild acanthosis, spongiosis, and focal overlying parakeratosis. SPP is considered to be a type of chronic spongiotic dermatitis. Lesional skin also demonstrates an increase in CD1a(+), Langerhans cells, CD1a-positive dermal dendritic cells, and CD68(+) macrophages.

Although SPP may be refractory to topical steroids alone, patients usually respond to phototherapy. Treatment with ultraviolet B (UVB), narrow-band (NB) UVB, or natural sunlight, alone or in combination with a low-strength topical corticosteroid or simple lubricant, will usually clear SPP. Without treatment, the patches of SPP may persist for years to decades but rarely progress to lymphoma.

**Arai R, et al:** Retrospective study of 24 patients with large or small plaque parapsoriasis treated with ultraviolet B therapy. *J Dermatol* 2012; 39(7):674–676.

**Duarte IA, et al:** An evaluation of the treatment of parapsoriasis with phototherapy. *An Bras Dermatol* 2013; 88(2):306–308.

**El-Darouti MA, et al:** Hypopigmented parapsoriasis en plaque, a new, overlooked member of the parapsoriasis family: a report of 34 patients and a 7-year experience. *J Am Acad Dermatol* 2012; 67(6):1182–1188.

**Lewin J, et al:** Digitate dermatosis (small-plaque parapsoriasis). *Dermatol Online J* 2012; 18(12):3.

**Takahashi H, et al:** Digitate dermatosis successfully treated by narrowband ultraviolet B irradiation. *J Dermatol* 2011; 38(9):923–924.

### CONFLUENT AND RETICULATED PAPILOMATOSIS (GOUGEROT AND CARTEAUD)

The eruption of confluent and reticulated papillomatosis typically begins on the intermammary and upper lateral trunk as

slightly scaly macules that slowly spread to involve the remainder of the trunk (Fig. 11-2). In white patients, the lesions vary from skin-colored or faintly erythematous to hyperpigmented; in pigmented persons, lesions usually show hyperpigmentation, although a nonpigmenting form with fine, white scale has been described. There may be severe itching, or the lesions may be entirely asymptomatic. Familial cases have been reported. An actinomycete, dubbed *Dietzia papillomatosis*, has been isolated from lesional skin. Isolated cases have been associated with hypothyroidism and 15q tetrasomy syndrome.

Histologically, hyperkeratosis, acanthosis, and papillomatosis are generally seen and *Pityrosporum (Malassezia)* yeast are frequently present. The histologic changes resemble those seen in acanthosis nigricans, and the two conditions may occur together.

A variety of antibiotics have been successful in treating this papillomatosis. Minocycline, 100 mg twice daily for 6 weeks, is used most often. Successful treatment has also been reported with oral fusidic acid, clarithromycin, amoxicillin, erythromycin, azithromycin, and topical mupirocin. Topical and oral retinoids have also been used successfully, either alone or in combination with topical lactic acid, urea, or alcohol. Confluent and reticulated papillomatosis associated with polycystic ovarian syndrome has responded to contraceptive therapy.

Pseudo-atrophoderma colli may be a related condition that occurs on the neck. It manifests as papillomatous, pigmented, and atrophic glossy lesions with delicate wrinkling, which tend to have a vertical orientation and may respond to minocycline.

**Berk DR:** Confluent and reticulated papillomatosis response to 70% alcohol swabbing. *Arch Dermatol* 2011; 147(2):247–248.

**Hudacek KD, et al:** An unusual variant of confluent and reticulated papillomatosis masquerading as tinea versicolor. *Arch Dermatol* 2012; 148(4):505–508.

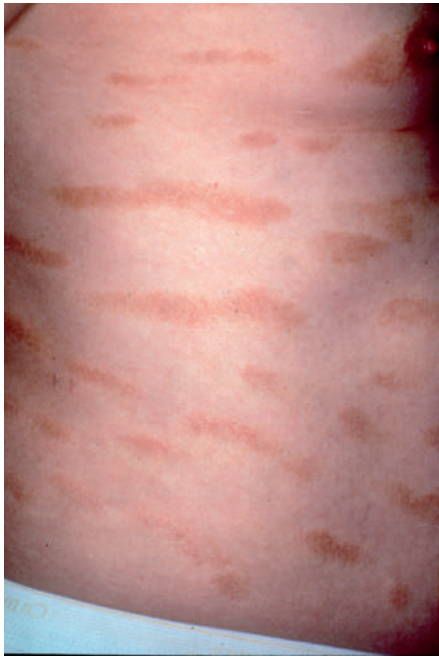**Koguchi H, et al:** Confluent and reticulated papillomatosis associated with 15q tetrasomy syndrome. *Acta Derm Venereol* 2013; 93(2):202–203.

**Tamraz H, et al:** Confluent and reticulated papillomatosis: clinical and histopathological study of 10 cases from Lebanon. *J Eur Acad Dermatol Venereol* 2013; 27(1):e119–e123.

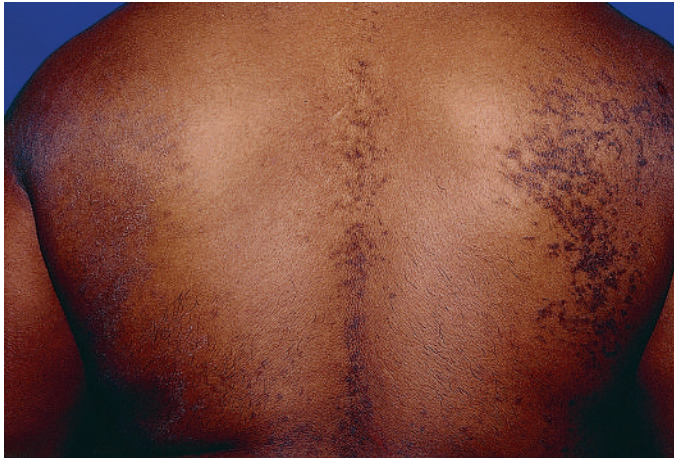### PITYRIASIS ROSEA

#### Clinical features

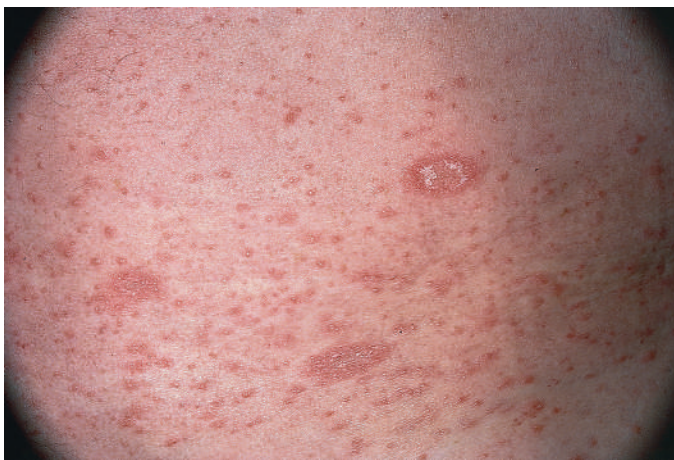Pityriasis rosea is a mild inflammatory exanthem characterized by salmon-colored papular and macular lesions that are at first discrete but may become confluent (Fig. 11-3). The individual patches are oval or circinate and covered with finely crinkled, dry epidermis, which often desquamates, leaving a collarette of scaling. When stretched across the long axis, the scales tend to fold across the lines of stretch, the so-called “hanging curtain sign.” The disease most frequently begins with a single herald or mother patch (Fig. 11-4), usually



**Fig. 11-1** Digitate parapsoriasis. (Courtesy of Thomas Nicotori, MD.)

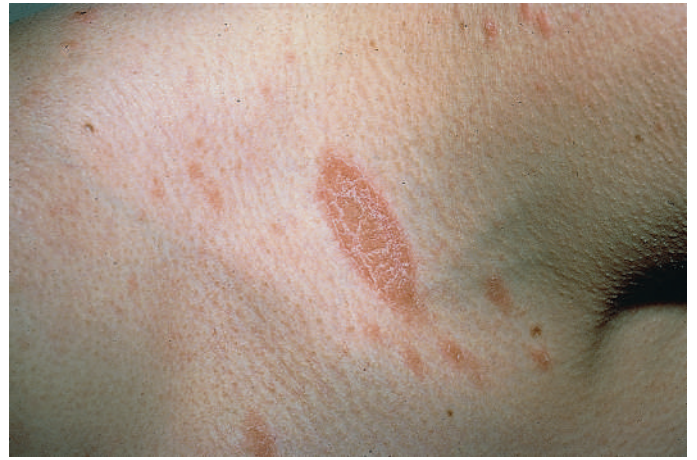

**Fig. 11-2** Confluent and reticulated papillomatosis.

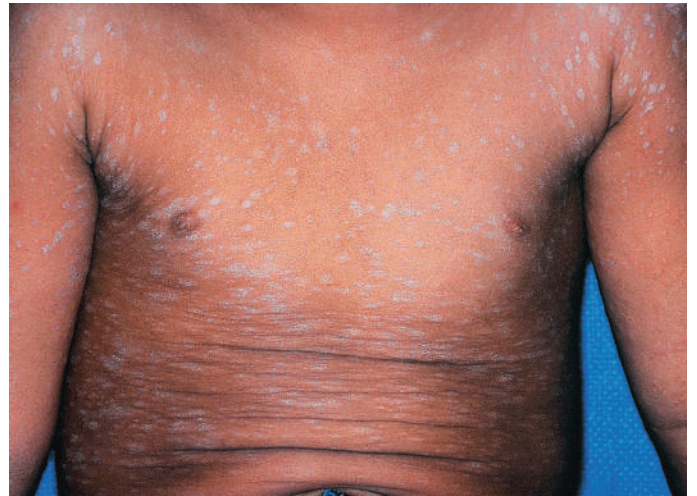

**Fig. 11-3** Pityriasis rosea.

larger than succeeding lesions, which may persist 1 week or longer before others appear. By the time involution of the herald patch has begun, the efflorescence of new lesions spreads rapidly (Fig. 11-5), and after 3-8 weeks, they usually disappear spontaneously. Relapses and recurrences are



**Fig. 11-4** Herald patch of pityriasis rosea.



**Fig. 11-5** Pityriasis rosea.

observed infrequently. The incidence is highest between ages 15 and 40, and the disease is most prevalent in the spring and autumn. Women are more frequently affected than men.

The fully developed eruption has a striking appearance because of the distribution and definite characteristics of the individual lesions. These are arranged so that the long axis of the macules runs parallel to the lines of cleavage. The eruption is usually generalized, affecting chiefly the trunk and sparing sun-exposed surfaces. At times it is localized to a certain area, such as the neck, thighs, groins, or axillae. In these regions, confluent circinate patches with gyrate borders may form and may strongly resemble tinea corporis. Rarely, the eyelids, palms and soles, scalp, or penis may be involved. Unilateral and segmental forms have been described. Oral lesions are relatively uncommon; they are asymptomatic, erythematous macules with raised borders and clearing centers or aphthous ulcer-like lesions. They involute simultaneously with the skin lesions. Moderate pruritus may be present, particularly during the outbreak, and mild constitutional symptoms may occur before the onset.

Black children are particularly predisposed to the papular variant and are also more prone to facial and scalp involvement. The lesions often heal, leaving hypopigmented macules. An inverse distribution, sparing covered areas, can occur and is common in papular cases. A vesicular variant has also been described, and erythema multiforme-like lesions may occur. Purpuric pityriasis rosea may manifest with petechiae and ecchymoses along Langer lines of the neck, trunk, and proximal extremities, and may occasionally be a sign of an



underlying acute myeloid leukemia. Pityriasis rosea occurring during pregnancy may be associated with premature delivery, neonatal hypotonia, and fetal loss, especially if the eruption occurs within the first 15 weeks of gestation.

## Etiology

Watanabe et al. have provided evidence for the long-held belief that pityriasis rosea is a viral exanthem. They demonstrated active replication of human herpesvirus (HHV) 6 and HHV-7 in mononuclear cells of lesional skin, as well as identifying the viruses in serum samples of patients including women who experienced miscarriage in association with pityriasis rosea. Although these viruses are almost universally acquired in early childhood and remain in a latent phase as mononuclear cells, the eruption is likely secondary to reactivation leading to viremia. HHV-2 and hepatitis C virus (HCV) have also been implicated in individual cases.

A pityriasis rosea-like eruption may occur as a reaction to captopril, imatinib mesylate, interferon, ketotifen, arsenicals, gold, bismuth, clonidine, methoxypropazine, tripeleminamine hydrochloride, ergotamine, lisinopril, acyclovir, lithium, adalimumab, nortriptyline, lamotrigine, rituximab, imatinib, asepamine, barbiturates, or bacille Calmette-Guérin (BCG) vaccine.

## Histology

The histologic features of pityriasis rosea include mild acanthosis, focal parakeratosis, and extravasation of erythrocytes into the epidermis. Spongiosis may be present in acute cases. A mild perivascular infiltrate of lymphocytes is found in the dermis. Histologic evaluation is especially helpful in excluding the conditions with which pityriasis rosea may be confused.

## Differential diagnosis

Pityriasis rosea may closely mimic seborrheic dermatitis, tinea corporis, macular syphilid, drug eruption, other viral exanthems, and psoriasis. In seborrheic dermatitis, the scalp and eyebrows are usually scaly; there is a predilection for the sternal and interscapular regions, as well as the flexor surfaces of the articulations, where the patches are covered with greasy scales. Tinea corporis is rarely so widespread. Tinea versicolor may also closely simulate pityriasis rosea. A positive potassium hydroxide (KOH) examination serves well to differentiate these last two. In macular syphilid, the lesions are of a uniform size and assume a brownish tint. Scaling and itching are absent or slight, and there is generalized adenopathy with mucous membrane lesions, palmoplantar lesions, positive nontreponemal and treponemal tests, and often the remains of a chancre. Scabies and lichen planus may be confused with the papular type.

## Treatment

Most patients with pityriasis rosea require no therapy because they are asymptomatic; however, the duration of the eruption may be notably reduced by several interventions. A Cochrane review cited inadequate evidence for efficacy for most published treatments; however, lack of evidence does not equate to lack of efficacy. Some evidence indicated that oral erythromycin may be effective for both the rash and the itch, although this is based on only one small, randomized controlled trial (RCT; see next).

Use of UVB light in erythema exposures expedites the involution of the lesions after the acute inflammatory stage has passed. The erythema produced by UV treatment is followed by superficial exfoliation. In a comparison study using a "placebo" of 1-J UVA light on the untreated side compared with the UVB-treated side, there was significant improvement in disease severity on the treated side. However, there was no difference in itchiness or disease course. Corticosteroid lotions or creams provide some relief from itching. A randomized controlled trial suggested that high dose acyclovir may be effective. One RCT found that erythromycin, 250 mg four times daily for adults and 25–40 mg/kg in four divided doses daily for children over 2 weeks, resulted in complete clearance of all lesions. This response in 33 of 45 patients contrasted with none of the 45 placebo patients having the same response. Other studies have challenged the effectiveness of erythromycin, and more research is needed. For dryness and irritation, simple emollients are recommended.

**Bangash HK, et al:** Pityriasis rosea-like drug eruption due to nortriptyline in a patient with vulvodynia. *J Low Genit Tract Dis* 2013; 17(2):226–229.

**Drago F, et al:** Recurrence of hepatitis C virus infection during pityriasis rosea. *Acta Derm Venereol* 2013; 93(4):483.

**Drago F, et al:** Evidence of human herpesvirus-6 and -7 reactivation in miscarrying women with pityriasis rosea. *J Am Acad Dermatol* 2014; 71:198–199.

**Ganguly S:** A Randomized, double-blind, placebo-controlled study of efficacy of oral acyclovir in the treatment of pityriasis rosea. *J Clin Diagn Res* 2014; 8:YC01–4.

**Oh CW, et al:** Pityriasis rosea-like rash secondary to intravesical bacillus Calmette-Guérin immunotherapy. *Ann Dermatol* 2012; 24(3):360–362.

**Relhan V, et al:** Pityriasis rosea with erythema multiforme-like lesions: an observational analysis. *Indian J Dermatol* 2013; 58(3):242.

**Sezer E, et al:** Pityriasis rosea-like drug eruption related to rituximab treatment. *J Dermatol* 2013; 40(6):495–496.

## PITYRIASIS RUBRA PILARIS

### Clinical features

Pityriasis rubra pilaris (PRP) is a chronic skin disease characterized by small follicular papules, disseminated yellowish pink scaling patches, and often, solid confluent palmoplantar hyperkeratosis. The papules are the most important diagnostic feature, being more or less acuminate, reddish brown, about pinhead sized, and topped by a central horny plug (Fig. 11-6). A hair, or part of one, is usually embedded in the horny center. The highest incidence of onset is during the first 5 years of life or between ages 51 and 55. The classic disease generally

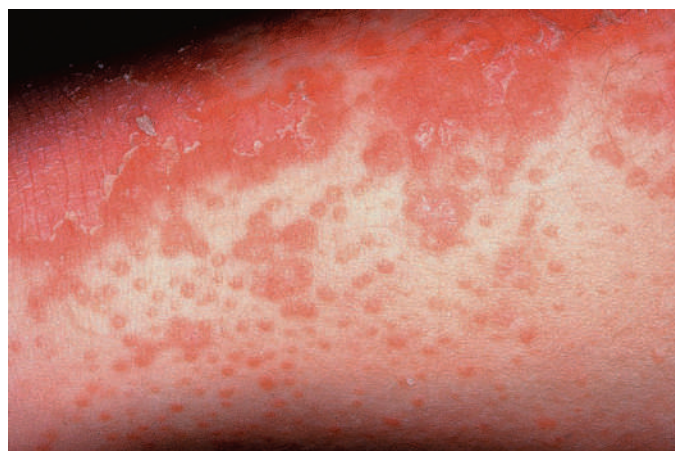
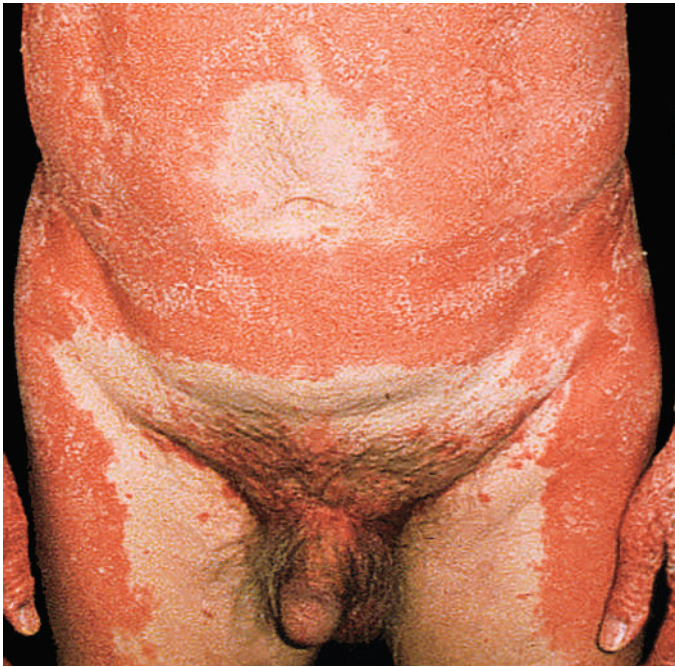
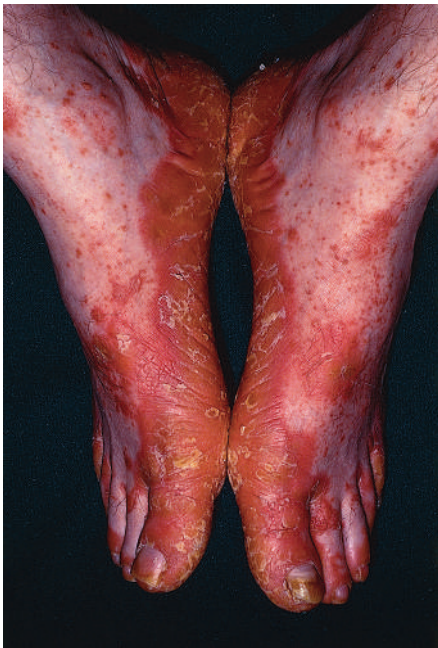Fig. 11-6 Pityriasis rubra pilaris.



**Fig. 11-7** Islands of sparing in pityriasis rubra pilaris.



**Fig. 11-8** Palmar hyperkeratosis in pityriasis rubra pilaris.

manifests first by scaliness and erythema of the scalp. The eruption is limited in the beginning, having a predilection for the sides of the neck and trunk and the extensor surfaces of the extremities, especially the backs of the first and second phalanges. Then, as new lesions occur, extensive areas are converted into sharply margined patches of various sizes, which look like exaggerated gooseflesh and feel like a nutmeg grater. Any part or the entire skin surface may be affected.

The involvement is generally symmetric and diffuse, with characteristic small islands of normal skin within the affected areas (Fig. 11-7). There is a hyperkeratosis of the palms and soles, with a tendency to fissures (Fig. 11-8). On the soles especially, the hyperkeratosis typically extends up the sides, the so-called sandal. The nails may be dull, rough, thickened, brittle, and striated, and are apt to crack and break. They are

rarely, if ever, pitted. The exfoliation may become generalized and the follicular lesions less noticeable, finally disappearing and leaving a widespread dry, scaly erythroderma. The skin becomes dull red, glazed, atrophic, sensitive to slight changes in temperature, and over the bony prominences, subject to ulcerations. In the classic juvenile type, limited plaques occur on extensor surfaces, with adjacent “nutmeg-grater” papules.

There are no subjective symptoms except itching in some cases. The Koebner phenomenon may be present. The general health of most patients is not affected, although occasionally arthritis may accompany the eruption. A number of cases of associated malignancy have recently been reported. It remains to be established whether these are true associations or chance findings. Protein-losing enteropathy may occur. Both hypothyroidism and hypoparathyroidism have been reported, as has the combination of sacroiliitis and autoimmune thyroiditis.

Pityriasis rubra pilaris may be classified according to familial (typically autosomal dominant) or acquired types and to the onset of disease in childhood or adulthood. Griffith’s classification is useful in this regard. Type I, the classic adult type, is seen most often and carries a good prognosis, with 80% involuting over a 3-year period. Likewise, most patients with the classic juvenile type (type III) have clearing of the disease in 1 year, although it may recur, even into adulthood. The atypical adult and juvenile variants and the circumscribed juvenile-onset form account for up to 35% of cases and carry a poorer prognosis for spontaneous recovery. Human immunodeficiency virus (HIV) patients may develop PRP and have associated acne conglobata, hidradenitis suppurativa, or lichen spinulosus.

## Etiology

The etiology of PRP is unknown. Familial cases are uncommon. Either gender may be affected, with equal frequency. Both clinically and histologically, the disease has many features that suggest it is a vitamin deficiency disorder, particularly of vitamin A. Some reports of patients with low serum levels of retinol-binding protein have appeared, but this is not a reproducible finding. A similar eruption has been described secondary to imatinib, sorafenib, and telaprevir.

## Histology

There is hyperkeratosis, follicular plugging, and focal parakeratosis at the follicular orifice. Parakeratosis may alternate both vertically and horizontally, producing a checkerboard pattern. Acantholysis may be present, especially within adnexal structures. The inflammatory infiltrate in the dermis is composed of mononuclear cells and is generally mild. Although making an unequivocal histologic diagnosis of PRP may be difficult, the findings of psoriasis, which is the most common clinical entity in the differential diagnosis, are not present.

## Diagnosis

The diagnosis of fully developed PRP is rarely difficult because of its distinctive features, such as the peculiar orange or salmon-yellow color of the follicular papules, containing a horny center, on the backs of the fingers, sides of the neck, and extensor surfaces of the limbs; the thickened, rough, and slightly or moderately scaly, harsh skin; the sandal-like palmo-plantar hyperkeratosis; and the islands of normal skin in



the midst of the eruption. It is distinguished from psoriasis by the scales, which in the latter are silvery and light, and overlap like shingles, and by the papules, which extend peripherally to form patches. Phrynoderma (follicular hyperkeratosis) caused by vitamin A deficiency gives a somewhat similar appearance to the skin, as may eczematous eruptions caused by vitamin B deficiency. Rheumatologic disorders, such as subacute cutaneous lupus erythematosus and dermatomyositis, may present with similar cutaneous findings.

## Treatment

The management of PRP is generally with systemic retinoids, although topical tazarotene has also been reported to be of benefit. Isotretinoin, in doses of 0.5–1 mg/kg/day, may induce prolonged remissions or cures. It may take 6–9 months for full involution to occur, and tapering of the drug may prevent recurrence. Acitretin, in doses of 10–75 mg, is also effective over several months. Methotrexate has been used with good results in doses of 2.5–30 mg, either alone or in combination with oral retinoids. Resolution by way of an erythema gyratum repens–like pattern has been described during methotrexate therapy. UV light may flare some patients, but in others, psoralen plus ultraviolet A (PUVA), UVA I, or NB UVB, alone or in combination with retinoids, may be effective. Phototesting before initiating light therapy is recommended. Extracorporeal photochemotherapy, cyclosporine, anti-tumor necrosis factor (TNF) agents, ustekinumab, and azathioprine have been reported to be effective in resistant and severe cases.

Topical applications of calcineurin inhibitors, lactic acid, or urea-containing preparations may be helpful. Responses to topical corticosteroids are not very effective as a rule. Systemic corticosteroids are beneficial only for acute, short-term management, but are not recommended for chronic use. In HIV-related disease, multiagent antiviral therapy may be useful alone or in combination with retinoids.

**Adnot-Desanlis L, et al:** Effectiveness of infliximab in pityriasis rubra pilaris is associated with pro-inflammatory cytokine inhibition. *Dermatology* 2013; 226(1):41–46.

**Eastham AB, et al:** Treatment options for pityriasis rubra pilaris including biologic agents: a retrospective analysis from an academic medical center. *JAMA Dermatol* 2014; 150:92–94.

**Ko CJ, et al:** Pityriasis rubra pilaris: the clinical context of acantholysis and other histologic features. *Int J Dermatol* 2011; 50(12):1480–1485.

**Marchetti MA, et al:** Pityriasis rubra pilaris treated with methotrexate evolving with an erythema gyratum repens–like appearance. *J Am Acad Dermatol* 2013; 69(1):e32–e33.

**Mercer JM, et al:** Familial pityriasis rubra pilaris: case report and review. *J Cutan Med Surg* 2013; 17(4):226–232.

**Pampin A, et al:** Successful treatment of atypical adult pityriasis rubra pilaris with oral acitretin. *J Am Acad Dermatol* 2013; 69(2):e105–e106.

**Paz C, et al:** Sorafenib-induced eruption resembling pityriasis rubra pilaris. *J Am Acad Dermatol* 2011; 65(2):452–453.

**Petrof G, et al:** A systematic review of the literature on the treatment of pityriasis rubra pilaris type 1 with TNF-antagonists. *J Eur Acad Dermatol Venereol* 2013; 27(1):e131–e135.

**Plana A, et al:** Pityriasis rubra pilaris–like reaction induced by imatinib. *Clin Exp Dermatol* 2013; 38(5):520–522.

**Stalling SS, et al:** Telaprevir-induced pityriasis rubra pilaris–like drug eruption. *Arch Dermatol* 2012; 148(10):1215–1217.

## PALMOPANTAR KERATODERMA

The term keratoderma is frequently used synonymously with keratosis palmaris et plantaris (KPP) and tylosis. This group of conditions is characterized by excessive formation of keratin

on the palms and soles. Some varieties exist as part of a syndrome. Acquired types include keratoderma climactericum, arsenical keratoses, corns, calluses, porokeratosis plantaris discreta, porokeratotic eccrine ostial and dermal duct nevus, glucan-induced keratoderma in acquired immunodeficiency syndrome (AIDS), keratosis punctata of the palmar creases, and many skin disorders associated with palmoplantar keratoderma, such as psoriasis, paraneoplastic syndromes, PRP, lichen planus, and syphilis. A high incidence of melanoma has been noted in Japanese patients with palmoplantar keratoderma. Palmoplantar keratoderma has been described with sorafenib, an oral multikinase inhibitor used in the treatment of renal cell carcinoma. Arsenical keratoses can occur from tainted water supplies, intentional poisoning, and medications containing arsenic. Arsenical keratoses have been treated with a combination of keratolytics and low-dose acitretin.

The hereditary types include hereditary palmoplantar keratoderma (Unna-Thost), punctate palmoplantar keratosis, Papillon-Lefèvre syndrome, mal de Meleda, familial keratoderma with carcinoma of the esophagus (Howell-Evans), autosomal dominant hereditary punctate keratoderma associated with malignancy (Buschke-Fisher-Brauer), KPP of Sybert (palmoplantar hyperkeratosis with transgrediens, autosomal dominant inheritance, and a lack of associated systemic features), acrokeratoelastoidosis, focal acral hyperkeratosis, and several inherited disorders that have palmoplantar keratoderma as an associated finding, such as pachyonychia congenita, tyrosinemia II (Richner-Hanhart), Darier's disease, Naxos syndrome (keratoderma, wooly hair, and cardiomyopathy), and dyskeratosis congenita. Many disorders that have palmoplantar keratoderma as a feature are discussed in other chapters.

A number of mutations in keratin genes have been found. American patients with nonepidermolytic palmoplantar keratoderma associated with malignancy are linked to aquaporin 5 (AQP5), encoding a water-channel protein.

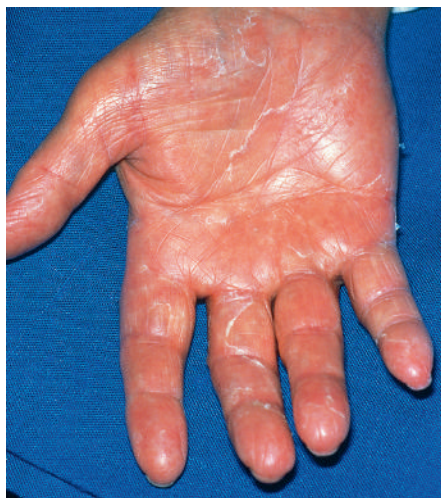Pachyonychia congenita is associated with mutations in the helical initiation peptide of K6a, K16, or K17. Epidermolytic palmoplantar keratoderma (EPPK) is an autosomal dominant disease caused by mutations of the gene for keratin 9. The mutations localize to sequences encoding the highly conserved 1 A rod domain. Acantholysis of epidermal keratinocytes suggests the presence of desmoglein 1 gene mutations. Punctate keratoderma has been linked to AAGAB as well as COL14A1 mutations. Aquagenic wrinkling is associated with cystic fibrosis.

## Keratolysis exfoliativa (lamellar dyshidrosis, recurrent palmar peeling)

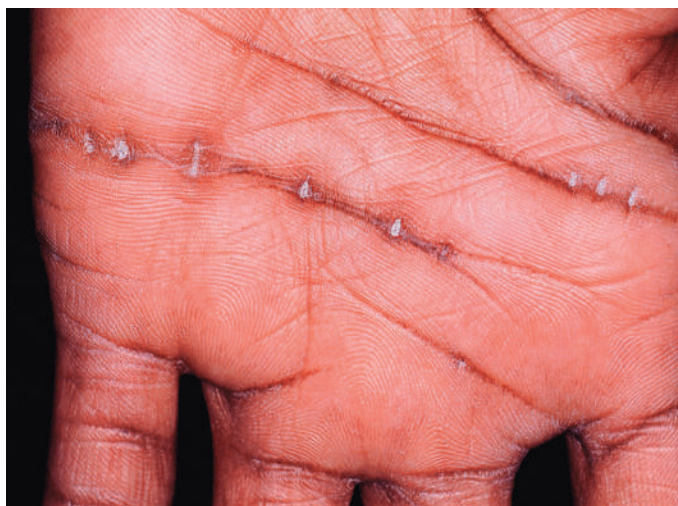Keratolysis exfoliativa is a superficial exfoliative dermatosis of the palms and sometimes soles. Clinically, inflammation is minimal to absent, although white spots appear and gradually extend peripherally. The lesions rupture to produce an annular adherent collarette (Fig. 11-9), but remain largely asymptomatic. The eruption is often exacerbated by environmental factors. Many patients have an atopic background, and some have lesions of dyshidrotic eczema. Although some suggest it is a cohesion disorder of the stratum corneum, keratolysis exfoliativa more likely represents subclinical eczema. The condition must be differentiated from dermatophytosis, and a KOH examination is recommended.

Because keratolysis exfoliativa is generally asymptomatic, no treatment may be necessary. In some patients, spontaneous involution occurs in a few weeks. For patients who require treatment, emollients, corticosteroid preparations, tar, urea, and lactic acid or ammonium lactate may be effective.





**Fig. 11-9** Keratolysis exfoliativa.



**Fig. 11-10** Keratosis punctata of the palmar creases.

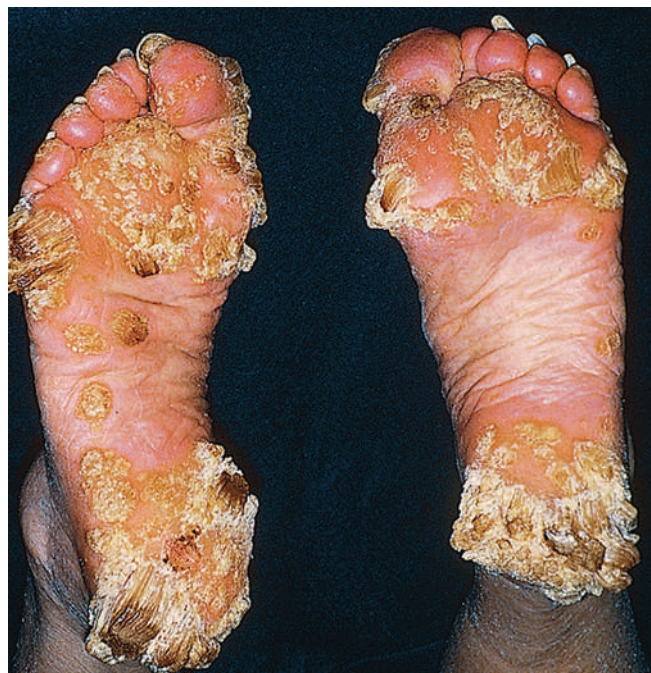### Keratosis punctata of the palmar creases

Keratosis punctata of the palmar creases has also been referred to as keratotic pits of the palmar creases, punctate keratosis of the palmar creases, keratosis punctata, keratoderma punctata, hyperkeratosis penetrans, lenticular atrophia of the palmar creases, and hyperkeratosis punctata of the palmar creases. This common disorder occurs most often in black patients. The primary lesion is a 1–5 mm depression filled with a comedo-like keratinous plug. The lesions localize to the creases of the palms or fingers (Fig. 11-10). The soles may be involved. An autosomal dominant inheritance pattern has been suggested, but onset is often delayed until adulthood.

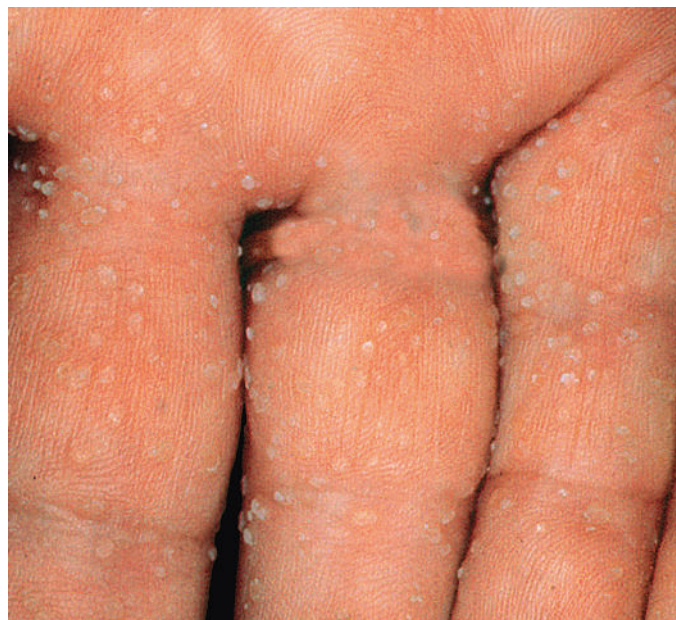Keratosis punctata of the palmar creases has been associated with atopic dermatitis, Dupuytren contractures, pterygium inversum unguis, dermatitis herpetiformis, knuckle pads, striate keratoderma, and psoriasis. Keratolytic agents and topical retinoids have provided temporary relief. Extremely painful lesions respond to punch excision.

### Punctate keratoses of the palms and soles

Punctate keratoses of the palms and soles has also been referred to as punctate keratoderma, keratoderma punctata, keratosis punctata palmaris et plantaris, keratoma hereditarium dissipatum palmare et plantare, keratoderma dissemina-



**Fig. 11-11** Punctate keratoderma.



**Fig. 11-12** "Music box" spiny keratoderma.

tum palmaris et plantaris, palmar keratoses, and palmar and plantar seed dermatoses. Spiny keratoderma of the palms and soles, known as "music box spines," is a distinct variant (Fig. 11-11).

There may be from 1 to over 40 papules, with an average in one series of 8.3 (Fig. 11-12). The main symptom is pruritus. The onset is between ages 15 and 68. Black individuals predominate, and it more frequently affects men. There have been reports of autosomal dominant inheritance. The histology demonstrates hyperkeratosis and parakeratosis, pyknotic, vacuolated epithelium, basal layer spongiosis, and dilated, occluded sweat ducts, blood vessels, and lymph vessels. Only mechanical debridement and excision have achieved any permanent results.

Circumscribed palmar hypokeratosis is a delayed manifestation of friction and repetitive-use trauma that presents



as a sharply circumscribed, erythematous patch on the palm. Histologically, thickness of the stratum corneum decreases abruptly.

### Porokeratosis plantaris discreta

Porokeratosis plantaris discreta occurs in adults, with a 4:1 female preponderance. It is characterized by a sharply marginated, rubbery, wide-based papule that on blunt dissection reveals an opaque plug without bleeding on removal. Lesions are multiple, painful, and usually 7–10 mm in diameter. They are usually confined to the weight-bearing area of the sole, beneath the metatarsal heads. Treatment may begin with fitted foot pads to redistribute the weight. Surgical excision, blunt dissection, and cryotherapy have been successful.

### Keratoderma climactericum

Keratoderma climactericum is characterized by hyperkeratosis of the palms and soles (especially the heels) beginning at about the time of menopause. The discrete, thickened, hyperkeratotic patches are most pronounced at sites of pressure such as around the rim of the sole. Fissuring of the thickened patches may be present. There is a striking resemblance to plantar psoriasis, and indeed, keratoderma climactericum may represent a form of psoriasis. Therapy consists of keratolytics such as 10% salicylic acid ointment, lactic acid creams, or 20–30% urea mixtures. The response to topical corticosteroids is often disappointing. Acitretin is more effective than isotretinoin.

### Hereditary palmoplantar keratoderma

Hereditary palmoplantar keratoderma (Unna-Thost) is characterized by a dominantly inherited, marked congenital thickening of the epidermal horny layer of the palms and soles, usually symmetrically and affecting all parts equally (Fig. 11-13). At times the thickening extends to the lateral or dorsal surfaces, especially over the knuckles. The arches of the feet

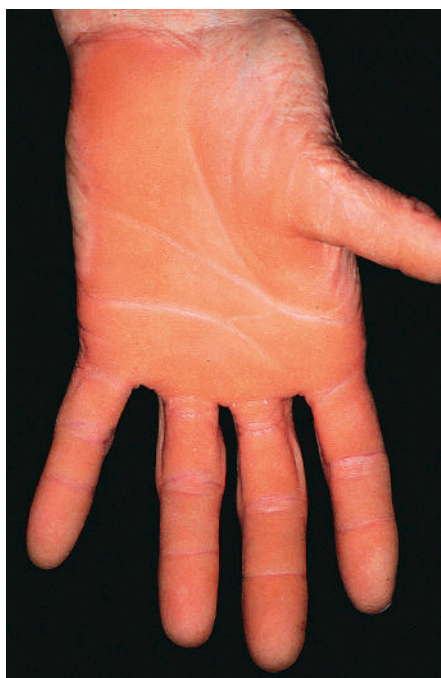

Fig. 11-13 Unna-Thost keratoderma.

are generally spared. The epidermis is thick, yellowish, and horny. The uniform thickening forms a rigid plate, which ends with characteristic abruptness at the periphery of the palm. Hyperhidrosis may cause a sodden appearance.

Hereditary palmoplantar keratoderma is poorly responsive to therapy; 5% salicylic acid, 12% ammonium lactate, and 40% urea have been used. Systemic retinoid therapy is impractical because of bone toxicity, and topical retinoids are generally not effective.

### Palmoplantar keratodermas and malignancy

Howell-Evans reported a diffuse, waxy keratoderma of the palms and soles occurring as an autosomal dominant trait associated with esophageal carcinoma. Other related features are oral leukoplakia, esophageal strictures, squamous cell carcinoma of tyrotic skin, and carcinoma of the larynx and stomach. The tylosis esophageal cancer gene has been localized to chromosome 17q25. Acquired forms of palmoplantar keratoderma have also been associated with cancers of the esophagus, lung, breast, urinary bladder, and stomach.

### Mutilating keratoderma of Vohwinkel

Vohwinkel described honeycomb palmoplantar hyperkeratosis associated with starfishlike keratoses on the backs of the hands and feet, linear keratoses of the elbows and knees, and annular constriction (pseudo-ainhum) of the digits (Fig. 11-14), which may progress to autoamputation. Inheritance is mostly autosomal dominant, although a recessive type exists. The disease is more common in women and in whites, with onset in infancy or early childhood. Reported associations include deafness, deaf-mutism, high-tone acoustic impairment, congenital alopecia universalis, pseudopelade-type alopecia, acanthosis nigricans, ichthyosiform dermatoses, spastic paraplegia, myopathy, nail changes, mental retardation, and bullous lesions on the soles. Vohwinkel keratoderma maps to chromosome 1q21 and represents a mutation of *loricrin*. There have been some reports of a response to acitretin (or etretinate) therapy. Mutations in the gene for connexin 26 produce a similar phenotype.

Other forms of mutilating keratoderma also occur. They lack the constricting bands, honeycomb palmoplantar hyperkeratosis, and starfishlike keratoses of Vohwinkel syndrome. The affected digits are often shortened, narrow, rigid, and tapered.

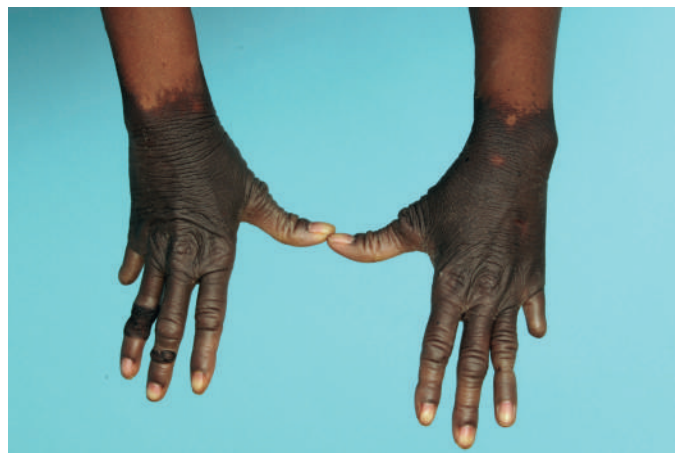

Fig. 11-14 Vohwinkel keratoderma.

## Olmsted syndrome

Olmsted syndrome is characterized by mutilating palmoplantar keratoderma and periorificial keratotic plaques. The distinctive features of this syndrome include a congenital, sharply marginated, palmoplantar keratoderma; constriction of the digits; linear keratotic streaks on the flexural aspects of the wrists; onychodystrophy; and periorificial keratoses. Constriction of digits may result in spontaneous amputations. Extensive grafting has sometimes been necessary. Most cases of Olmsted syndrome are sporadic. Associated abnormalities have included hyperhidrosis of the palms and soles and congenital deafness. Histologically, there is acanthosis, papillomatosis, and orthokeratotic hyperkeratosis. The finding of Ki-67 staining of suprabasal keratinocytes suggests that Olmsted syndrome is a hyperproliferative disorder of the epidermis.

## Acrokeratoelastoidosis

Acrokeratoelastoidosis presents with translucent to erythematous papules at the margins of the palms. Both sporadic and autosomal dominant forms have been reported. Small, round, firm papules occur over the dorsal hands, knuckles, and lateral margins of the palms and soles. The lesions appear in early childhood or adolescence in the inherited form and progress slowly. They are most often asymptomatic. The characteristic histologic feature is dermal elastorrhexis.

The differential diagnosis includes focal acral hyperkeratosis, which occurs as a familial trait in African American patients. The lesions are marginal hyperkeratotic papules, often with a central dell and usually on both the hands and the fingers. No alteration of the collagen or elastin is present on biopsy.

## Collagenous and elastotic marginal plaques of the hands

Collagenous and elastotic marginal plaques of the hands are slowly progressive lesions at the margins of the palms that demonstrate thickened collagen bundles admixed with elastic fibers and amorphous basophilic elastotic material.

## Focal acral hyperkeratosis

Focal acral hyperkeratosis occurs in autosomal dominant and sporadic forms. Clinically, it is characterized by crateriform keratotic papules and plaques along the borders of the hands and feet. It differs from acrokeratoelastoidosis and collagenous and elastotic marginal bands by the lack of underlying dermal changes.

## Mal de Meleda

Mal de Meleda is a rare, autosomal recessive form of palmoplantar keratoderma seen in individuals from the island of Meleda. The hyperkeratosis does not remain confined to the palms, and the extensor surfaces of the arms are frequently affected. The disease has been mapped to chromosome 8q, and mutations in the *ARS* (component B) gene have been identified in families with this disorder. Mutations in the gene encoding secreted lymphocyte antigen-6/urokinase-type plasminogen activator receptor-related protein 1 (*SLURP-1*) have been found.

“Nagashima-type” keratosis is a nonprogressive, autosomal recessive palmoplantar keratoderma that resembles a mild form of mal de Meleda.

## Papillon-Lefèvre syndrome

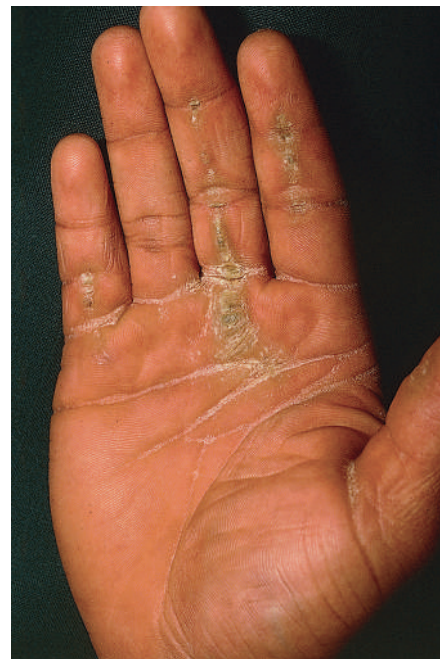The Papillon-Lefèvre syndrome is inherited in an autosomal recessive fashion and presents with palmoplantar keratoderma and destructive periodontitis, usually beginning in young childhood. Well-demarcated, erythematous, hyperkeratotic lesions on the palms and soles may extend to the dorsal hands and feet. Hyperkeratosis may also be present on the elbows, knees, and Achilles tendon areas. Transverse grooves of the fingernails may occur. Severe gingival inflammation with loss of alveolar bone is typical. Histology reveals a psoriasisiform pattern. Mutations in the gene for cathepsin C have been detected. The condition usually has an early age of onset, although a late-onset variant has been reported. Some patients with late-onset disease have not shown mutations in the cathepsin C gene.

The early onset of periodontal disease has been attributed to alterations in polymorphonuclear leukocyte function caused by *Actinomyces actinomycetemcomitans*, although a variety of other bacteria have also been implicated. Acro-osteolysis and pyogenic liver abscesses may occur. There are asymptomatic ectopic calcifications in the choroid plexus and tentorium. Some patients have responded to acitretin, etretinate, or isotretinoin.

The stocking-glove distribution of the hyperkeratosis is similar to that seen in mal de Meleda. Haim-Munk syndrome is autosomal recessive with periodontal disease, keratoderma, and onychogryphosis, linked to cathepsin C gene mutations.

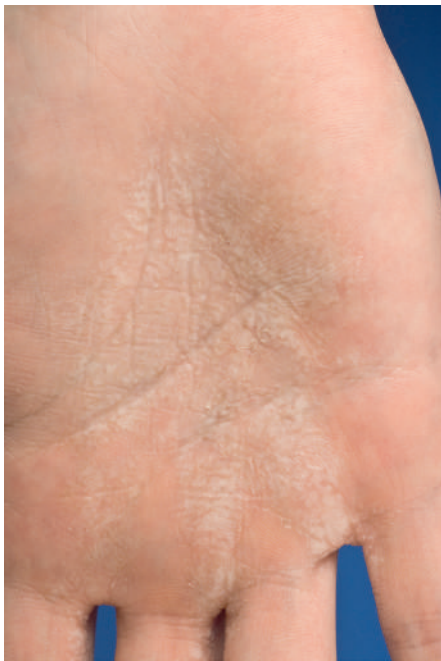## Striate keratodermas

The striate keratodermas are a group of autosomal dominant palmoplantar keratodermas with streaking hyperkeratosis involving the fingers and extending onto the palm (Fig. 11-15). In some patients, a heterozygous C to A transversion involving



**Fig. 11-15** Striate keratoderma.





**Fig. 11-16**  
Transient reactive papulotranslucent acrokeratoderma.

the gene for desmoglein 1 has been found. Mutations in the gene for desmoplakin have also been described. Brunauer-Foehs-Siemens syndrome is one form with diminished desmosomes, clumping of keratin filaments, and enlarged keratohyalin granules. Mutations in genes for desmoglein 1, desmoplakin, and keratin 1 have been described in these patients. In other patients, desmosome numbers are normal, but their inner plaques are attenuated. Striate keratoderma has also been reported in association with Rubinstein-Taybi syndrome.

### Richner-Hanhart syndrome

Richner-Hanhart syndrome (tyrosinemia type 2) is characterized by corneal opacities and keratosis palmoplantaris. The skin manifestations usually develop after the first year of life and relate to defects in tyrosine aminotransferase. Newborn screening can allow early intervention with dietary restriction.

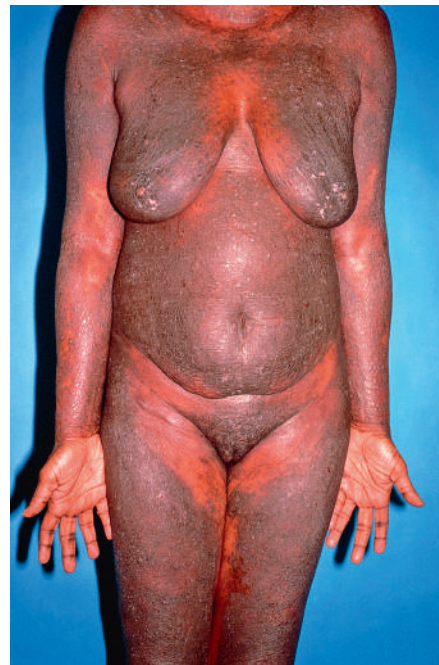### Acquired aquagenic syringal acrokeratoderma (aquagenic wrinkling of the palms)

Patients with papulotranslucent acrokeratoderma, sometimes referred to as aquagenic wrinkling, develop white papules on the palms after water exposure. The lesions are sharply demarcated from the surrounding skin and appear white. There may be a central prominent pore within each white lesion (Fig. 11-16). The lesions appear 3–5 min after exposure to water and resolve within a short time of drying. Sometimes the white skin can be peeled off. It may be a marker for cystic fibrosis and has also been reported in patients taking aspirin or rofecoxib. Autosomal dominant inheritance has been suggested in some cases, and abnormal AQP5 has been described in sweat glands.

**Baquerizo K, et al:** Atypical form of transient reactive papulotranslucent acrokeratoderma in a cystic fibrosis carrier. *J Cutan Pathol* 2013; 40(4):413–418.

**Chang YY, et al:** Keratolysis exfoliativa (dyshidrosis lamellosa sicca): a distinct peeling entity. *Br J Dermatol* 2012; 167(5):1076–1084.

**Fuchs-Telem D, et al:** Epidermolytic palmoplantar keratoderma caused by activation of a cryptic splice site in *KRT9*. *Clin Exp Dermatol* 2013; 38(2):189–192.



**Fig. 11-17**  
Erythroderma.

**Giehl KA, et al:** Nonsense mutations in *AAGAB* cause punctate palmoplantar keratoderma type Buschke-Fischer-Brauer. *Am J Hum Genet* 2012; 91(4):754–759.

**Guo BR, et al:** Exome sequencing identifies a *COL14A1* mutation in a large Chinese pedigree with punctate palmoplantar keratoderma. *J Med Genet* 2012; 49(9):563–568.

**Kosem R, et al:** Cathepsin C gene 5'-untranslated region mutation in Papillon-Lefèvre syndrome. *Dermatology* 2012; 225(3):193–203.

**Pohler E, et al:** Haploinsufficiency for *AAGAB* causes clinically heterogeneous forms of punctate palmoplantar keratoderma. *Nat Genet* 2012; 44(11):1272–1276.

**Tieu KD, et al:** Thickened plaques on the hands: collagenous and elastotic marginal plaques of the hands (CEMPH). *Arch Dermatol* 2011; 147(4):499–504.

## EXFOLIATIVE DERMATITIS (ERYTHRODERMA)

Exfoliative dermatitis is also known as dermatitis exfoliativa, pityriasis rubra (Hebra), and erythroderma (Wilson-Brocq). Patients present with extensive erythema and scaling (Fig. 11-17). Ultimately, the entire body surface is dull scarlet and covered by small, laminated scales that exfoliate profusely. Vesiculation and pustulation are usually absent. An extensive telogen effluvium is often noted. In both PRP and mycosis fungoides, distinctly spared islands of skin are frequently noted. Patients with PRP also have thickened, orange palms and “nutmeg grater” follicular papules on the dorsa of the fingers (see earlier).

Itching of the erythrodermic skin may be severe, and the onset is often accompanied by symptoms of general toxicity, including fever and chills. Transepidermal water loss is high, and secondary infections by pyogenic organisms often complicate the disease course in the absence of treatment. Severe complications include sepsis, high-output cardiac failure, acute respiratory distress syndrome, and capillary leak syndrome. The mortality rate attributable to the erythroderma approaches 7% in some series.

### Etiology

Erythroderma is frequently the result of generalization of a preexisting chronic dermatosis such as psoriasis or atopic

dermatitis. Many other cases are related to a medication, and some occur as a manifestation of an internal malignancy, erythrodermic mycosis fungoides, or the Sézary syndrome. Internal malignancies, pemphigus foliaceus, generalized dermatophytosis, and even Norwegian scabies may show the picture of generalized exfoliative dermatitis. Inadequate intake of branched-chain amino acids in infants with maple syrup urine disease reportedly produces exfoliative erythroderma. In a significant number of patients, however, the cause remains idiopathic, even after extensive evaluation.

In several reported series, the largest group of patients had preexisting dermatoses, including atopic dermatitis, chronic actinic dermatitis, psoriasis, seborrheic dermatitis, PRP, and allergic or irritant contact dermatitis. Drug eruptions are generally the next most common group, followed by idiopathic cases, cutaneous T-cell lymphoma (CTCL), paraneoplastic erythroderma, and leukemia cutis. Common implicated drugs include allopurinol, sulfa drugs, gold, phenytoin, phenobarbital, isoniazid, carbamazepine, cisplatin, dapsone, mefloquine, tobramycin, minocycline, nifedipine, and iodine. Anti-TNF therapy has produced the combination of erythroderma and keratoderma.

In a study of erythrodermic patients managed in the community, exacerbation of preexisting dermatoses accounted for 61%, compared with 51% of those evaluated at a university medical center; idiopathic cases for 14% and 31%, respectively; and CTCL for 1% and 6%, respectively. In a study of 51 children with erythroderma, immunodeficiency was diagnosed in 30%, ichthyosis in 24%, Netherton syndrome in 18%, and eczematous or papulosquamous dermatitis in 20%. Five of the 51 patients remained idiopathic. A biopsy established the diagnosis in only 19 (45%) of 42 cases. Mortality was 16%, usually related to an immunodeficiency disorder. Neonatal erythroderma is frequently a manifestation of a genodermatosis or immunodeficiency syndrome. Other causes include psoriasis, metabolic disease, and infection. Atopic dermatitis presenting as erythroderma is usually observed later, after the neonatal period.

In a comparison of patients with and without HIV infection, erythroderma in the HIV-positive group was most often related to drug reactions (40.6%), with ethambutol accounting for 30.8%. In the non-HIV group, drug reactions accounted for only 22.5%. HIV-positive patients did not have an overall increase in the number of episodes of erythroderma.

Mycosis fungoides can be erythrodermic without meeting the criteria for the Sézary syndrome. Sézary syndrome consists of generalized exfoliative dermatitis with intense pruritus, leonine facies, alopecia, palmoplantar hyperkeratosis, and onychodystrophy. The criteria for a diagnosis of Sézary syndrome include an absolute Sézary cell count of at least 1000 cells/mm<sup>3</sup>; a CD4/CD8 ratio of 10 or higher by flow cytometry, caused by an increase in circulating T cells or loss of expression of pan-T-cell markers; increased lymphocyte counts with evidence of a T-cell clone by Southern blot or polymerase chain reaction; or a chromosomally abnormal T-cell clone. Prognosis is poor and similar to that of patients with nodal involvement.

Hodgkin disease may show generalized exfoliative dermatitis. Fever, lymphadenopathy, splenomegaly, and hepatomegaly are frequently present. The erythrocyte sedimentation rate is elevated in most of these patients.

## Histopathology

Exfoliative dermatitis may retain the histologic features of the original disease process. This is particularly true in patients with psoriasis and mycosis fungoides. Often, however, the histology is nonspecific, with hyperkeratosis, mild acanthosis, and focal parakeratosis.

## Treatment

In drug-induced erythroderma, the offending drug must be stopped. Application of a midstrength corticosteroid after soaking and occlusion under a sauna suit are often helpful, regardless of the cause of the erythroderma. Moist pajamas can be added under the sauna suit. Acitretin, cyclosporine, and methotrexate are useful in psoriatic erythroderma. Isotretinoin, acitretin, and methotrexate are useful in erythroderma caused by PRP. Immunosuppressive agents, such as azathioprine and methotrexate, are occasionally necessary in idiopathic erythroderma patients not responding to therapy.

**Carter JB, et al:** Case records of the Massachusetts General Hospital: Case 24-2013—a 53-year-old woman with erythroderma, pruritus, and lymphadenopathy. *N Engl J Med* 2013; 369(6):559–569.

**Dhar S, et al:** Neonatal erythroderma: diagnostic and therapeutic challenges. *Indian J Dermatol* 2012; 57(6):475–478.

**Dunst-Huemer KM, et al:** Generalized erythroderma and palmoplantar hyperkeratosis in a patient receiving TNF- $\alpha$  antagonist therapy. *J Cutan Pathol* 2013; 40(9):855–856.

**Hulmani M, et al:** Clinico-etiological study of 30 erythroderma cases from tertiary center in South India. *Indian Dermatol Online J* 2014; 5:25–29.

**Mohd Noor N, et al:** Transepidermal water loss in erythrodermic patients of various aetiologies. *Skin Res Technol* 2013; 19(3):320–323.

**Rice SA, et al:** Erythroderma in the emergency department. *BMJ* 2013; 346:f3613.

**Yang JH, et al:** Paraneoplastic erythroderma: an unusual manifestation of diffuse large B-cell lymphoma. *Int J Dermatol* 2013; 52(9):1149–1151.



Bonus images for this chapter can be found online at

[expertconsult.inkling.com](http://expertconsult.inkling.com)

**eFig. 11-1** Confluent and reticulated papillomatosis.

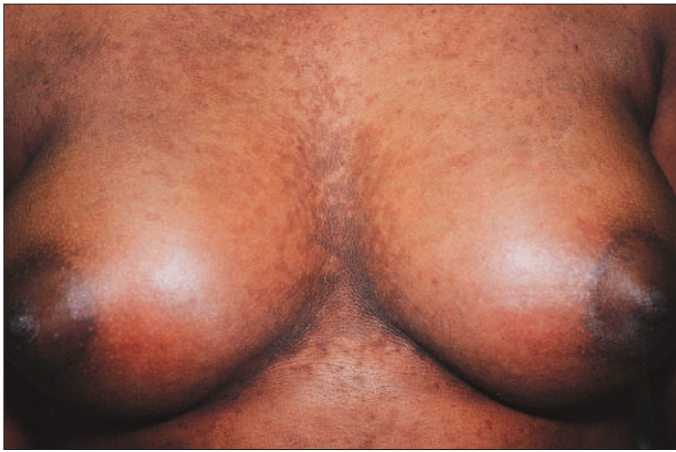**eFig. 11-2** Pityriasis rubra pilaris.

**eFig. 11-3** Palmar hyperkeratosis in pityriasis rubra pilaris.

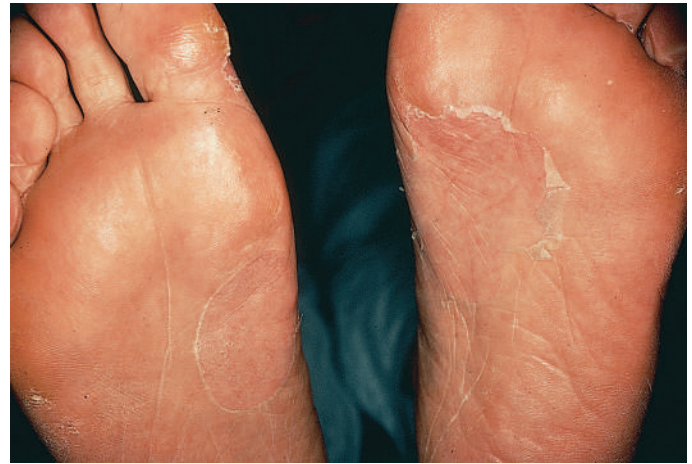**eFig. 11-4** Keratolysis exfoliativa.

**eFig. 11-5** Transient reactive papulotranslucent acrokeratoderma.

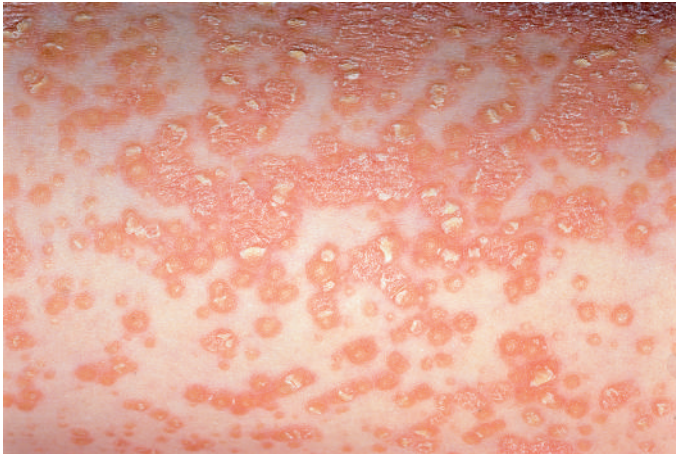




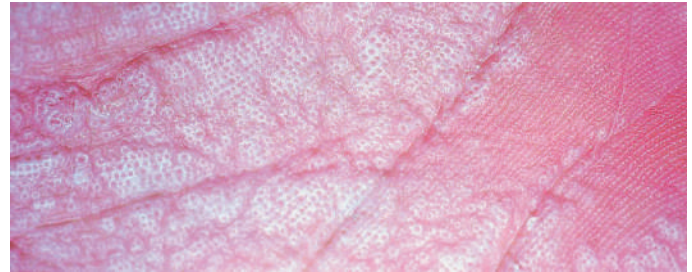
**eFig. 11-1** Confluent and reticulated papillomatosis.



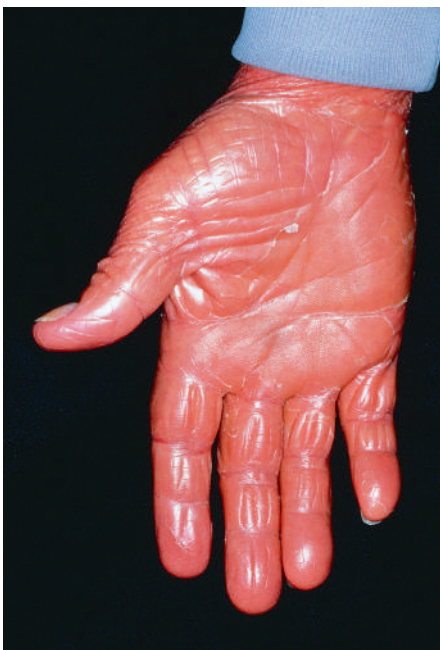**eFig. 11-4** Keratolysis exfoliativa.



**eFig. 11-2** Pityriasis rubra pilaris.



**eFig. 11-5** Transient reactive papulotranslucent acrokeratoderma.



**eFig. 11-3** Palmar hyperkeratosis in pityriasis rubra pilaris.

## Lichen Planus and Related Conditions

### LICHEN PLANUS

Lichen planus (LP) is a common, pruritic, inflammatory disease of the skin, mucous membranes, and hair follicles. It occurs throughout the world, in all races. Cutaneous lichen planus affects 0.3% of men and 0.1% of women. Oral LP affects 1.5% of men and 2.3% of women. It may be familial in rare cases. The pattern of LP detected and the age distribution vary among various genetic and geographic groups. In persons of European descent, it appears primarily after age 20, and peaks between 40 and 70. Very few cases appear after age 80. Childhood LP typically accounts for 5% or less of LP cases, although in some regions, including the Indian subcontinent, Arab countries, and Mexico, it represents 10–20%. Race appears to be the critical factor; in the United Kingdom, for example, Indians account for 80% of childhood LP.

The primary lesions of LP are characteristic, almost pathognomonic: small, flat-topped, polygonal papules (Fig. 12-1). The color of the lesions initially is erythematous. Well-developed lesions are violaceous, and resolving lesions are often hyperpigmented, especially in persons of color. The surface is glistening and dry, with scant, adherent scales. On the surface, gray or white puncta or streaks (Wickham striae) cross the lesions—a feature seen more easily with dermoscopy. Lesions begin as pinpoint papules and expand to 0.5–1.5 cm plaques. Infrequently, larger lesions are seen. There is a predilection for the flexor wrists, trunk, medial thighs, shins, dorsal hands, and glans penis (Fig. 12-2). The face is only rarely involved, with lesions usually confined to the eyelids and lips. The palms and soles may be affected with small papules or hyperkeratotic plaques (Fig. 12-3). Certain morphologic patterns favor certain locations (e.g., annular lesions favoring penis; keratotic lesions favoring anterior shins). The Koebner phenomenon occurs in LP (Fig. 12-4).

Pruritus is often prominent in LP. The pruritus may precede the appearance of the skin lesions, and as with scabies, the intensity of the itch may seem out of proportion to the amount of skin disease. It may be almost intolerable in acute cases. Most patients react to the itching of LP by rubbing rather than scratching, and thus scratch marks are usually not present.

The natural history of LP is highly variable and dependent on the site of involvement and the clinical pattern. Two thirds of patients with skin lesions will have LP for less than 1 year, and many patients spontaneously clear in the second year. Mucous membrane disease is much more chronic. Recurrences are common.

Nail changes are present in approximately 5–10% of patients. Involvement of the nail can occur as an initial manifestation, especially in children. Longitudinal ridging and splitting are most common, seen in 90% of patients. Onycholysis and subungual debris may be present, indicating involvement of the nail bed. The lunulae are red in 30% of patients with nail LP. Involvement of the entire matrix may lead to obliteration of the whole nail plate (anonychia). Pterygium formation is

characteristic of LP of the nails (Fig. 12-5), but seen in only about 20% of patients. The nail matrix is destroyed by the inflammation and replaced by fibrosis. The proximal nailfold fuses with the proximal portion of the nail bed. LP may be a cause of some cases of 20-nail dystrophy of childhood. In the absence of periungual lesions or pterygium formation, 20-nail dystrophy usually resolves spontaneously, and frequently in these children, no other stigmata of cutaneous or mucosal LP are found. Rarely, nail bed LP can result in onychopapilloma, a localized distal subungual hyperkeratosis.

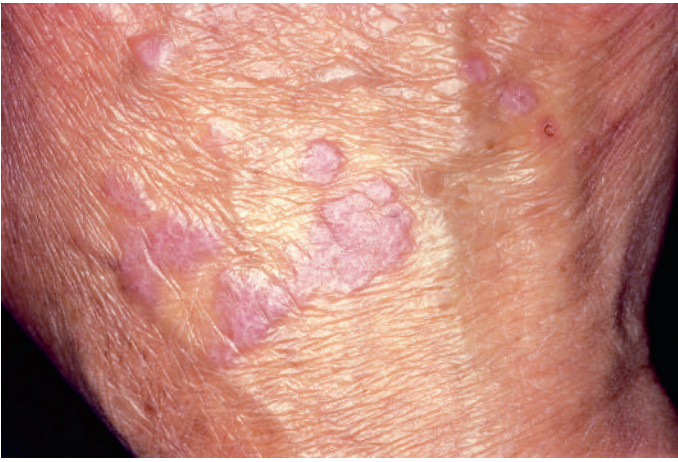
Involvement of the genitalia, with or without lesions at other sites, is common. On the glans or shaft of the penis, the lesions may consist of flat, polygonal papules, or these may be annular. Erosive LP can occur on the glans. Simultaneous involvement of the gingival and penile mucosa may occur. On the labia and anus, similar lesions are observed, generally whitish because of maceration. Half of women with oral LP also have vulval LP, but in only half of these patients is the genital LP symptomatic. Vulval LP occurs in three main forms. The *classic* type presents with polygonal papules resembling cutaneous LP and affects the clitoral hood and labia minora. Pruritus is the usual symptom. Although only about 20% of women with vulval LP have *erosive* or *ulcerative* LP, this type represents the vast majority of patients seen for vulval LP, since it is usually very symptomatic. Soreness, pain, and dyspareunia are frequent complaints. Vaginal involvement with a bloody discharge can occur. Involvement is symmetric from the fourchette to the anterior vestibule. The erosions have a lacy white periphery, a good area to biopsy to confirm the diagnosis of vulval LP. The third, and least common, form of vulval LP is the *hypertrophic* type. It involves the perineum and perianal skin (but not the vagina) with warty plaques with a violaceous edge. Pruritus is severe. Vulval splitting, vaginal stenosis, and sealing of the clitoral hood may be caused by LP, which should not be confused with lichen sclerosus.

Conjunctival involvement is a rarely recognized complication of LP but was seen in 0.5% of patients with vulval LP in one series. It most frequently occurs in patients with involvement of other mucosal surfaces. Cicatrization, lacrimal canalicular duct scarring, and keratitis can occur. It may closely simulate mucous membrane pemphigoid. Routine histology and direct immunofluorescence (DIF) may be required to confirm the diagnosis.

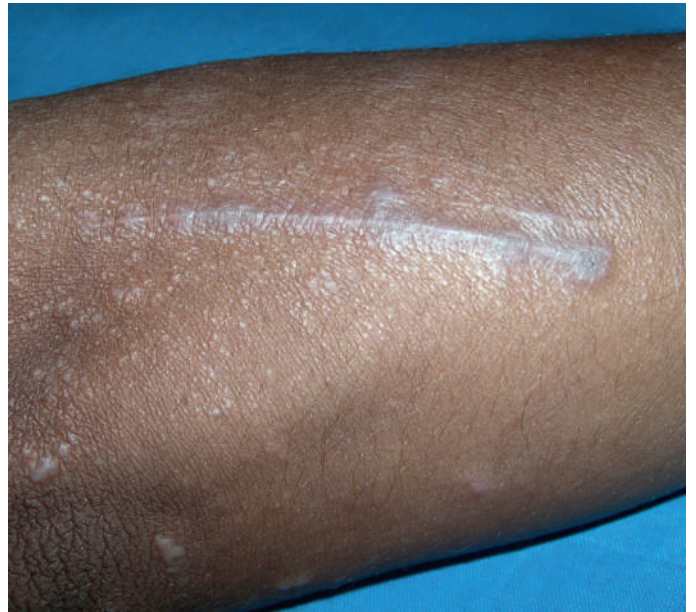Otic involvement by LP is rarely reported. It affects primarily females (80% of patients) and is associated with oral and vulval LP in more than 50% of cases. Hearing loss and external auditory canal stenosis are the most common otic complaints and complications. Four of 19 (21%) patients with otic LP also had esophageal involvement.

Lichen planus of the esophagus is increasingly being recognized, but occurs in only 1% of patients with LP. The diagnosis is frequently delayed. Dysphagia, odynophagia, and weight loss are typical manifestations. The midesophagus is primarily affected. Virtually all the patients have coexistent oral disease.

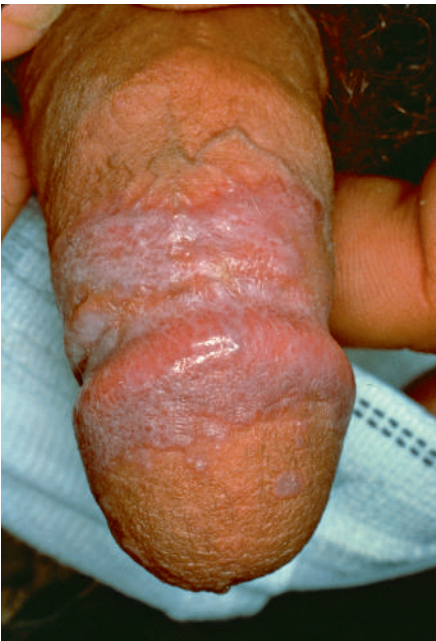



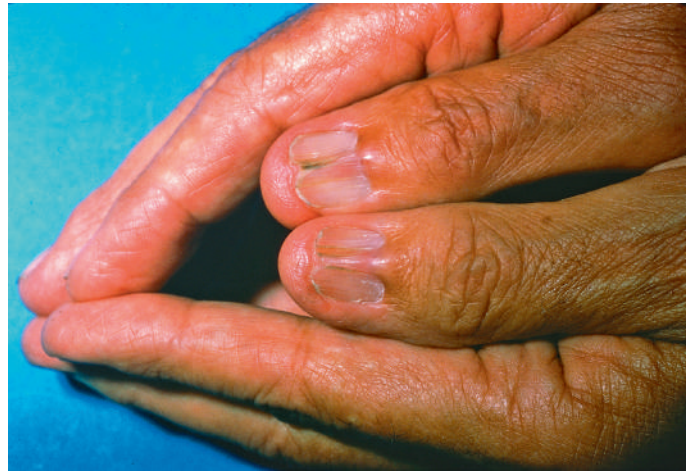**Fig. 12-1** Lichen planus, violaceous, flat-topped papules with minimal scale.



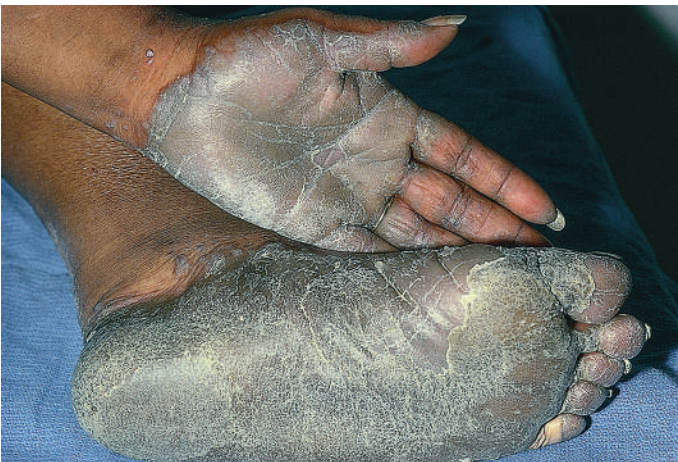**Fig. 12-4** Koebnerized lichen planus. (Courtesy of Dr. Debabrata Bandyopadhyay.)



**Fig. 12-2** Lichen planus of the penis.



**Fig. 12-5** Lichen planus, nail involvement with pterygium. (Courtesy of Lawrence Lieblich, MD.)



**Fig. 12-3** Lichen planus of the palm and sole.

Esophageal involvement is much more common in women with vulvovaginal and oral disease, in whom 15% develop esophageal lesions. Stricture formation occurs in 80% of esophageal LP and may require frequent dilations. Esophageal squamous cell carcinoma may complicate esophageal LP, suggesting that, once this diagnosis is made, routine gastrointestinal evaluation is required.

Whether the many clinical variants of LP represent separate diseases or part of the LP spectrum is unknown. They all demonstrate typical LP histologically. The variants are described separately because their clinical features are distinct from classic LP. Some patients with these clinical variants may have typical cutaneous, follicular, or mucosal LP. The more common or better-known variants are described here.

### Linear lichen planus

Small, linear lesions caused by the Koebner phenomenon often occur in classic LP. Limitation of LP to one band or streak has also been described in less than 1% of patients of European descent. In Japan, however, up to 10% of cases are linear, and



in India, 7% of childhood cases of LP are linear. Although originally described as following dermatomes (zosteriform), the lesions actually follow lines of Blaschko. It is more common in children but also occurs in adults. Papules with varying degrees of overlying hyperkeratosis or simple hyperpigmentation may be the presenting manifestations. There are often “skip areas” of normal skin between the individual lesions.

### Annular and annular atrophic lichen planus

Men represent 90% of patients with annular LP. Lesions with this configuration favor the axilla, penis/scrotum, and groin. LP lesions of the mucosa, scalp, and nails are rare in patients with annular LP. Patients usually have fewer than 10 lesions. Most patients with annular LP are asymptomatic. The ringed lesions are composed of small papules and measure about 1 cm in diameter. Central hyperpigmentation may be the dominant feature. They may coalesce to form polycyclic figures. Annular lesions may also result from central involution of flat papules or plaques, forming lesions with violaceous, elevated borders and central hyperpigmented macules.

### Hypertrophic lichen planus

Hypertrophic LP usually occurs on the shins but may occur anywhere. The typical lesions are verrucous plaques with variable amounts of scale (Fig. 12-6). At the edges of the plaques, small, flat-topped, polygonal papules may at times be discovered. Superficial inspection of the lesion often suggests psoriasis or a keratinocytic neoplasm rather than LP, but the typical appearance resembling rapidly cooled igneous rock (igneous rock sign) may be useful in suggesting LP over keratinocytic neoplasms. The lesions are of variable size but are frequently several centimeters in diameter and larger than the lesions of classic LP. The anterior lower leg below the knee is the sole area of involvement in most patients. Clinical diagnosis may be difficult, and biopsy is often required. Histologically, the pseudoepitheliomatous keratinocyte hyperplasia may be marked, leading to the erroneous diagnosis of squamous cell carcinoma (SCC). Eosinophils are much more often present in the dermal infiltrate of hypertrophic LP than classic LP. True SCC may also evolve from long-standing hypertrophic LP, and over 50% of cutaneous SCC arising in LP occurs below the knee in lesions of hypertrophic LP. In addition, keratoacanthoma-like proliferations may occur in lesions of hypertrophic LP. This has also been called “hypertrophic

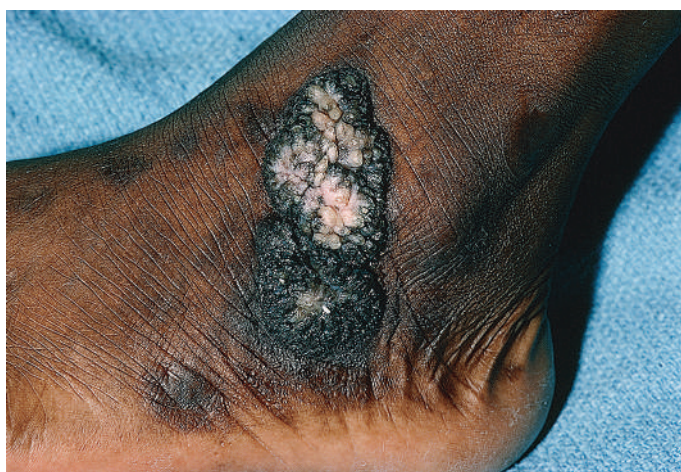

Fig. 12-6 Hypertrophic lichen planus.

lichen planus–like reactions combined with infundibulocystic hyperplasia.” Hypertrophic LP is chronic and often refractory to topical therapy. Hypertrophic lupus erythematosus (LE) resembles hypertrophic LP both clinically and histologically. Hypertrophic LE tends to affect the distal extremities, face, and scalp. The finding of continuous granular immunoglobulin on DIF strongly suggests a diagnosis of hypertrophic LE rather than LP.

### Erosive/ulcerative/mucosal lichen planus

Ulcerative LP is rare on the skin but common on the mucous membranes. A rare ulcerative variant of cutaneous LP, or LE/LP overlap syndrome, affects the feet and toes, causing bullae, ulcerations, and permanent loss of the toenails. These chronic ulcerations on the feet are painful and disabling. Cicatricial alopecia may be present on the scalp, and the buccal mucosa may also be affected. These cases are a therapeutic challenge, and aggressive oral retinoid or immunomodulatory treatment is indicated if there is a poor response to standard topical and systemic agents. Skin grafting of the soles has produced successful results.

Oral mucosal LP is the most common form of mucosal LP, and it is usually chronic. Between 10% and 15% of patients with oral LP will also have skin lesions. Women represent 75% of patients with oral LP. Oral LP in women begins 10 years later than in men (age 57 vs. 47). Oral lesions may be reticulate (reticular) (Fig. 12-7), erythematous (atrophic), or ulcerative (erosive). The most common pattern in oral LP is the ulcerative form (40% of patients). Usually, reticulate and erythematous lesions are found adjacent to the ulcerative areas. The erythematous pattern is the predominant pattern in 37% of patients, but almost always, reticulate lesions are also seen in these patients. In oral LP, the “classic” reticulate lesions are most prominent in 23% of patients. Symptoms are least common in patients with reticulate lesions; 23% are symptomatic, and then only when the tongue is involved. All patients with erosive lesions are symptomatic, usually with burning or pain. Patients may simultaneously have several patterns, so patients are characterized by the primary form they exhibit. Lesions appear on any portion of the mouth, and multisite involvement is common. The buccal mucosa is involved in 90%, the gingiva in more than 50%, and the tongue in about 40%.

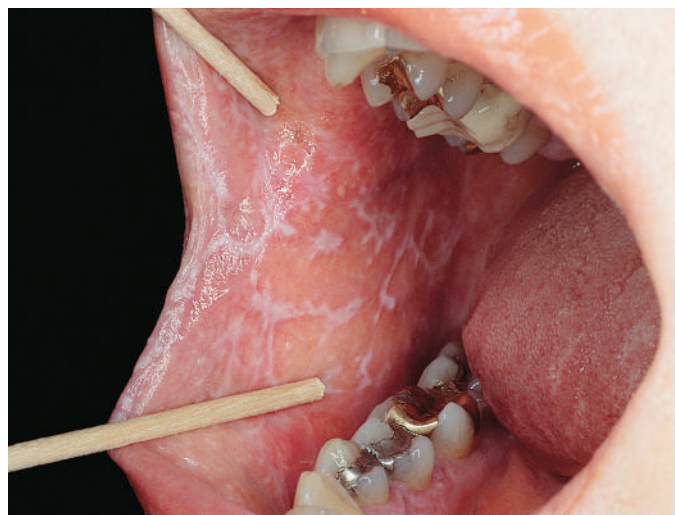
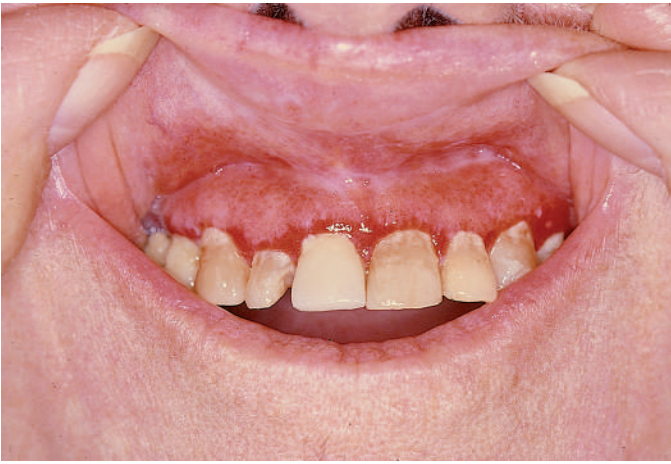
Fig. 12-7 Lichen planus, reticulate white lesions of the buccal mucosa.



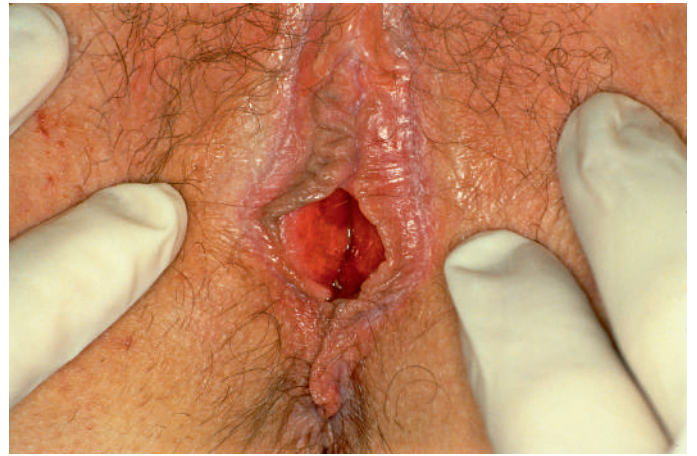

**Fig. 12-8** Desquamative gingivitis secondary to lichen planus.

On the gingiva, LP may produce desquamative gingivitis (Fig. 12-8). Gingival involvement is particularly difficult to diagnose and often requires biopsy for both histology and DIF to confirm the diagnosis and exclude other autoimmune causes of desquamative gingivitis. Gingival involvement is associated with accelerated gingival recession. Mechanical injury from dental procedures and poorly fitting appliances may trigger or exacerbate gingival LP. On the tongue and palate, lesions are often mistaken for leukoplakia. The lower lip is involved in 15% of oral LP patients, but the upper lip in only 2%. Lower lip LP is frequently mistaken for actinic cheilitis. Imiquimod treatment can lead to exacerbation of the labial LP, with extensive erosion and crusting. Oral LP is stable but chronic, with less than 3% of patients having a spontaneous remission in an average 5-year follow-up. Periodontitis appears to exacerbate oral LP, especially gingival disease. Plaque control either by the patient after training or by a dental professional improves the clinical appearance and pain.

Oral lichenoid lesion (OLL) refers to an oral lesion histologically identical to oral LP (OLP) but from a different cause, such as graft-versus-host disease (GVHD), medications, and local or systemic exposures. Gold, cobalt, indium, manganese, chrome, nickel, palladium, cinnamate, and spearmint sensitivity may induce OLLs. The most common causes, however, are the metals in dental amalgams, including mercury, copper, zinc, and tin. If the lesions in the oral mucosa are physically close to the amalgam, removal of the amalgam will lead to resolution of the OLL in 36%. In patients patch test positive to a metal in the amalgam, 44% and 47% of OLLs healed with removal of the amalgam in two studies. In patients with the OLL in strict contact with the amalgam, and there is a relevant positive patch test to a component of the amalgam, 80% or more of OLLs will heal. Patch testing, however, may not identify all patients whose OLLs improve with removal of the oral metal. Rarely, patients with metal sensitivity will also have skin and nail lesions that improve with removal of the oral metal. In one study, 6 of 10 patients with nail LP who were patch test positive to a metal in their amalgam improved with removal of the dental material or with oral disodium chromoglycate treatment.

Involvement of the vulva and vagina with LP, along with the gingiva, has been called the vulvovaginal-gingival (VVG) syndrome. Although all three of these mucous membranes may be involved, only one or two sites may be involved at any one time. The prevalence of erosive vulvar LP had been underappreciated simply because many women with oral LP did not volunteer their vulvovaginal complaints and were not asked about them. The vaginal lesions of VVG are erythematous, friable erosions that are very painful. Untreated scarring is



**Fig. 12-9** Scarring and erosions in the vulvovaginal-gingival syndrome.

severe and can lead to adhesions, vestibular bands, and even vaginal stenosis (Fig. 12-9). In one third of patients, typical reticulate buccal LP is seen, and in up to 80% the oral mucosa is also involved. Cutaneous lesions occur in 20–40% of VVG patients. The course of the vulvovaginal syndrome is protracted, and patients frequently have sequelae, including chronic pain, dyspareunia, and even scarring of the conjunctiva, urethra, and oral, laryngeal, pharyngeal, and esophageal mucosae. Nails are involved in about 15% of patients with VVG, compared with only 2% of patients with oral LP. The VVG syndrome is now considered to be a separate subgroup of mucosal LP that is particularly disabling, scarring, and refractory to therapy.

Although the pathogenesis of LP is unknown, evidence shows that erosive LP of the vulva (and lichen sclerosus) may have an autoimmune basis. A personal and family history of autoimmune disorders (usually thyroid disease) is present in up to 30% of patients with vulvar LP, and up to 40% have circulating autoantibodies. The prevalence of autoimmune phenomena is *not* increased in patients with classic cutaneous LP. The autoantibodies do not appear to be pathogenic, because the disease seems to be caused by cytotoxic T cells. Erosive LP has significant impact on quality of life, and patients with erosive LP have high levels of depression, anxiety, and stress.

### Cancer risk and lichen planus

Rare cases of squamous cell carcinoma of the skin occurring on the lower leg in lesions of hypertrophic LP have been reported. There is no statistical increase in cutaneous or visceral carcinoma in patients with cutaneous LP, and cutaneous LP alone is not considered to be a condition with increased cancer risk. Oral LP and vulvovaginal LP, however, do appear to increase the risk of developing SCC. About 1% of patients with oral LP will develop oral SCC. SCC occurs only in patients with erythematous or ulcerative LP, not in those with only the reticulate pattern. Of the oral LP patients who develop oral SCC, about 45% have only one cancer. The majority develop multiple cancers, and close vigilance is recommended in these patients. LP patients with erosive penile and vaginal disease also have developed SCC. The number of penile cases is too low to determine the frequency, but in patients with vulvar LP, development of SCC may be as high as 3%. Clinicians should have a low threshold to biopsy fixed erosive or leukokeratotic lesions in patients with mucosal LP. The use of oral and topical calcineurin inhibitors (CNIs) for LP has been

associated with the appearance of SCC on the genitalia. There is no evidence that the medications caused the neoplasia, but if these agents are used, regular follow-up and careful examination are required.

### Hepatitis-associated lichen planus

Three liver conditions have been associated with LP: hepatitis C virus (HCV), hepatitis B immunization, and primary biliary cirrhosis. HCV infection has been found in proportionately more patients with LP than in controls in numerous studies. The prevalence of HCV infection in patients with LP varies from 1.6% to 20%. There is an association with the human leukocyte antigen (HLA) DR6 allele. The association of HCV infection and LP has been questioned. In a large series of patients with oral LP from the United States, none of the 195 patients was infected with HCV, whereas 29% of patients with oral LP from Italy had HCV. In Scotland, 20% of patients infected with HCV had oral LP, compared with 1% of seronegative patients. Although the data are conflicting, screening for HCV appears appropriate in persons from a geographic region where or a population in whom HCV infection is frequently associated with LP. These areas include East and Southeast Asia, South America, the Middle East, and Europe. In North America, South Asia, and Africa, such screening may not be cost-effective but can still be recommended. The clinical features of LP in patients with hepatitis C are identical to classic LP, but LP patients with HCV infection are reported as being more likely to have erosive mucous membrane disease. The existence of underlying hepatitis cannot be predicted by clinical pattern or the results of liver function tests. Treatment of hepatitis C with interferon (IFN) alpha may be associated with the initial appearance of LP or exacerbation of preexisting LP. LP may occur at IFN injection sites, and skin testing may reproduce LP-like lesions. LP may improve or may not change with IFN and ribavirin treatment for hepatitis C. Improvement is usually seen toward the end of the treatment course. Most patients do not completely clear their LP. The HCV genome is not found in lesions of LP associated with HCV infection.

Hepatitis B virus (HBV) immunization may be associated with the appearance of LP in both children and adults. Lesions are typical of LP, and the oral mucosa may be affected. Typically, the first lesions of LP appear about 1 month after the second dose of vaccine. Lesions usually resolve after some time.

Primary biliary cirrhosis and LP may coexist. Patients with this liver abnormality also have a marked propensity to develop a lichenoid eruption while receiving D-penicillamine therapy. Xanthomas in patients with primary biliary cirrhosis may appear initially in lesions of LP, and the infiltrate, although lichenoid, may contain xanthomatous cells. Primary sclerosing cholangitis has been associated with oral LP.

### Bullous lichen planus

Two forms of LP may be accompanied by bullae. In classic LP, usually on the lower extremities, individual lesions will vesiculate centrally (Fig. 12.10). This represents macroscopic exaggeration of the subepidermal space formed by the lichenoid interface reaction destroying the basal keratinocytes. These lesions often spontaneously resolve.

Lichen planus pemphigoides describes a rare subset of patients who usually have typical LP, then an average of 8 months later, develop blistering on their LP lesions and on normal skin. Less often, the blister and the LP lesions occur simultaneously. Clinically, these patients appear to be a

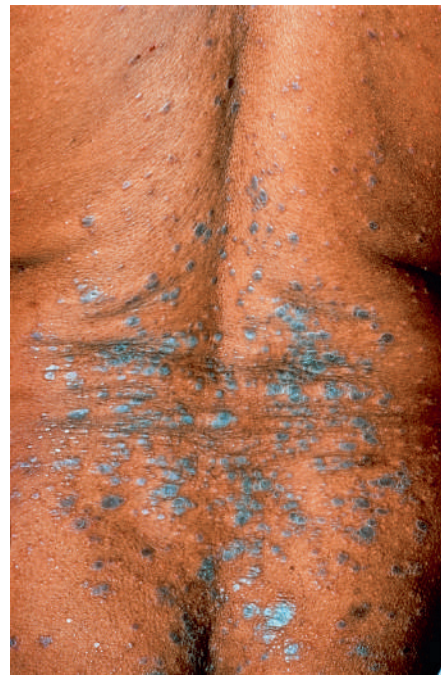

Fig. 12-10 Generalized lichen planus.

combination of LP and bullous pemphigoid. Oral disease may occur and resemble either LP or mucous membrane pemphigoid. Lichen planus pemphigoides has been triggered by medications, especially angiotensin-converting enzyme (ACE) inhibitors, as well as interferon, HBV, and psoralen plus ultraviolet A (PUVA). Pruritus may be severe, and lesions may evolve to resemble pemphigoid nodularis. Bullous pemphigoid affects an older age group than LP pemphigoides; typical onset for lichen planus pemphigoides is 30–50. Histologically, the LP lesions show LP, and the bullous lesions show the features of bullous pemphigoid. DIF is positive in a linear pattern, with IgG and C3 along the basement membrane zone (BMZ), at the roof of saline split skin. The antigen targeted by the autoantibody in lichen planus pemphigoides is located in the same region as the bullous pemphigoid antigen, at the basal hemidesmosome. Antibodies from patients with lichen planus pemphigoides typically bind the 180-kD bullous pemphigoid antigen, but in a different region from bullous pemphigoid sera. Lichen planus pemphigoides tends to follow a benign and chronic course, even compared with bullous pemphigoid. Treatment of lichen planus pemphigoides is similar to bullous pemphigoid, with potent topical steroids, systemic steroids, tetracycline, nicotinamide, intravenous immune globulin (IVIG), and immunosuppressives all being variably effective.

### Pathogenesis and histology

Lichen planus is characterized by an immunologic reaction mediated by CD8+ T cells. These cells induce keratinocytes to undergo apoptosis. Although this inflammatory reaction is thought to be autoimmune, the antigen targeted by these effector T lymphocytes is unknown. Patients with LP and OLP have a high rate of dyslipidemia, with elevated triglycerides, elevated low-density lipoprotein (LDL) cholesterol and reduced high-density lipoprotein (HDL) cholesterol. Inflammatory markers also are elevated in the blood of LP patients, potentially contributing to this dyslipidemia. In addition, both insulin resistance and frank type 2 diabetes mellitus are increased in patients with LP compared with controls. Both insulin resistance and dyslipidemia are cardiovascular risk factors. Adult LP patients should be evaluated appropriately.



Lichen planus pemphigoides is hypothesized to result from exposure to the immune system of epitopes in the BP180 antigen as keratinocytes are destroyed by the lichenoid inflammation. Epitope spreading can occur, and LP pemphigoides patients may also have autoantibodies to the same epitopes as bullous pemphigoid patients.

The histologic features of LP are distinctive and vary with the stage of the lesion. In early lesions, there is an interface dermatitis along the dermoepidermal junction. As the lesion evolves, the epidermis takes on a characteristic appearance. There is destruction of the basal layer with a “sawtooth” pattern of epidermal hyperplasia, orthokeratosis, and beaded hypergranulosis. The basal cells are lost, so the basal layer is described as “squamatized.” In the superficial dermis, there is a dense, bandlike infiltrate composed of lymphocytes and melanophages. “Civatte bodies” (cytoid bodies, colloid bodies) represent necrotic keratinocytes in the superficial dermis. Hypertrophic LP shows marked epidermal hyperplasia (pseudoepitheliomatous hyperplasia). Old lesions of LP show effacement of the rete ridge pattern, melanophages in the upper dermis, and occasional Civatte bodies. LP rarely demonstrates parakeratosis or eosinophils, except in hypertrophic LP. The presence of either of these suggests a different cause of lichenoid tissue reaction, such as lichenoid drug eruption. Lichen planopilaris, frontal fibrosing alopecia, and Graham-Little-Piccardi-Lasseur syndrome show the findings of LP, centered on the superficial follicular epithelium.

Lesions of LP of the skin or mucosae can demonstrate clumps of IgM on DIF, and less frequently IgA, IgG, and C3, subepidermally, corresponding to the colloid bodies. Dense, shaggy staining for fibrinogen along the BMZ is characteristic of LP. A lichenoid drug eruption may be difficult to differentiate from LP. The presence of eosinophils or parakeratosis supports the diagnosis of lichenoid drug eruption. GVHD tends to have a sparser infiltrate. Hypertrophic LE may be histologically identical to LP, and the diagnosis is best made by clinical correlation and DIF. In most other forms of LE, there is a greater tendency for epidermal atrophy with parakeratosis, dermal mucin is found, and follicular plugging is more prominent. The infiltrate in lupus tends to surround and involve deep portions of the appendageal structures, such as the follicular isthmus and eccrine coil. Deep, nodular, perivascular lymphoplasmacytic infiltrates and necrosis of the fat lobule with fibrin or hyalin rings are also findings characteristic of LE.

### Differential diagnosis

Classic LP displays lesions that are so characteristic that clinical examination is often adequate to lead to suspicion of the diagnosis. Lichenoid drug eruptions may be difficult to distinguish. A lichenoid drug reaction should be suspected if the eruption is photodistributed, scaly but not hypertrophic, and confluent or widespread—clinical features that are unusual for idiopathic LP. The presence of oral mucosa involvement may prompt suspicion of LP, but oral lesions may occasionally occur in lichenoid drug eruptions as well. Pityriasis rosea, guttate psoriasis, the small papular or lichenoid syphilid, and pityriasis lichenoides et varioliformis acuta are dermatoses that may resemble generalized LP. Mucous membrane lesions may be confused with leukoplakia, LE, mucous patches of syphilis, candidiasis, cancer, and oral lesions of autoimmune bullous diseases, such as pemphigus or cicatricial pemphigoid. On the scalp, the atrophic lesions may be mistaken for other cicatricial alopecias, such as LE, folliculitis decalvans, and pseudopelade of Brocq. Hypertrophic LP type may simulate psoriasis and SCC in situ. Isolated patches of LP may resemble lichen simplex chronicus.

### Treatment

There is virtually no high-quality evidence for treatment of lichen planus of the skin, scalp, or mucosae. Limited lesions may be treated with superpotent topical corticosteroids or intralesional steroid injections. In patients with widespread disease, these treatments are usually unsatisfactory. Widespread lesions respond well to systemic corticosteroids but tend to relapse as the dose is reduced. Monthly pulse dosing has been championed by dermatologists in India. Phototherapy may be effective for cutaneous LP, including narrow-band (NB) ultraviolet B (UVB), UVA I, and PUVA. NB UVB was superior to systemic corticosteroids in one study. Topical cream PUVA has been used effectively in genital LP. The oral retinoids: isotretinoin, alitretinoin, and acitretin, in doses similar to or slightly lower than those used for other skin conditions, may also be useful and avoid the long-term complications of systemic steroids. They are especially beneficial in patients with hypertrophic LP and palmoplantar LP. Retinoid therapy may be combined with phototherapy in refractory cases. Photodynamic therapy with topical 5-aminolevulinic acid can be effective in penile LP. Low-molecular-weight heparin (enoxaparin), 3 mg injected subcutaneously once a week, led to remission of cutaneous and reticulate oral LP in 61% of patients and improvement in 11%. Enoxaparin is less effective than systemic steroids; erosive oral LP responded variably and lichen planopilaris not at all. For erosive skin lesions, topical tacrolimus or pimecrolimus can be effective. Hydroxychloroquine in standard doses can be effective for cutaneous, oral, genital and follicular LP. Adding quinacrine, 100 mg daily, may be considered in patients with only a partial response to hydroxychloroquine. Thalidomide, 50–150 mg daily, can improve refractory oral and cutaneous LP. Apremilast, a phosphodiesterase type IV inhibitor, at a dose of 20 mg twice daily, showed modest efficacy in pooled data, but pruritus was dramatically decreased, and 3 of 10 treated patients cleared completely. Medication-related headache occurred in 3 of 10 patients.

In the most severe cases, immunosuppressive agents may be indicated. Cyclosporine, methotrexate, and mycophenolate mofetil are all options and can induce remission in severe cases of cutaneous and oral LP. The tumor necrosis factor (TNF) inhibitors, adalimumab and etanercept, as well as alefacept have been effective in anecdotal cases. Similarly, extracorporeal photophoresis, anakinra, rituximab, and IVIG have been successful in extremely refractory cases.

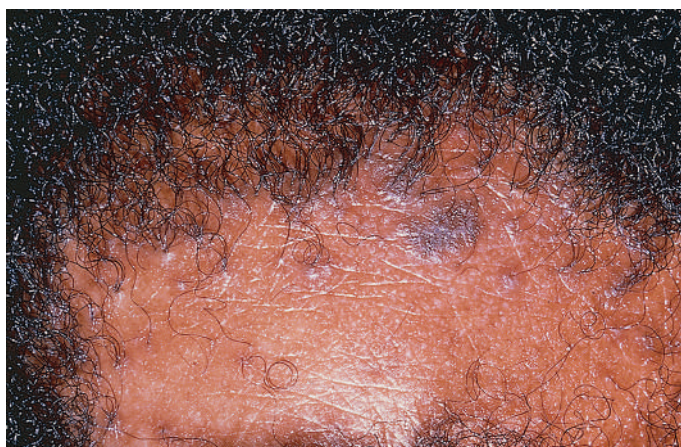For oral lesions, superpotent steroids in Orabase or gel form are useful. Vinyl dental trays may be used to apply steroid ointments to the gingiva. Begin with 30-min applications three times a day and reduce to maintenance of 20 min every evening. Addition of nystatin to clobetasol in Orabase may be especially effective. Overall, more than 70% of patients with vulvar LP have relief of symptoms with topical clobetasol. Intralesional injections may be used for focal unresponsive lesions. Topical tacrolimus 0.1% ointment has become standard treatment in erosive LP of the oral and genital mucosa. Burning may occur initially but can be reduced by concomitant use of topical steroids or initial use of a lower strength of tacrolimus ointment. Higher concentrations, up to 0.3%, also may be used. Most patients have a partial but significant response, with increased ability to eat with much less pain. Blood levels can be detected, independent of area of involvement, but tend to decrease over time as the oral erosions heal. Pimecrolimus can be used successfully in patients intolerant of topical tacrolimus. Sustained remissions are rare, and chronic use is usually required to maintain remission. Topical cyclosporine is ineffective. PUVA, photodynamic therapy, and 308-nm excimer laser have been effective in oral LP. The

systemic agents recommended earlier to treat cutaneous LP may also improve mucosal disease. For VVG syndrome, corticosteroids topically and systemically are beneficial. Topical therapy with corticosteroids may be enhanced by mixing the steroid in vaginal bioadhesive moisturizer (Replens). Iontophoresis may improve delivery.

- Ahlgren C, et al:** Contact allergy to gold in patients with oral lichen lesions. *Acta Derm Venereol* 2012; 92:138.
- Al-Khenaizan S:** Lichen planus occurring after hepatitis B vaccination: a new case. *J Am Acad Dermatol* 2001; 45:614.
- Al-Khenaizan S, et al:** Ulcerative lichen planus of the sole: excellent response to topical tacrolimus. *Int J Dermatol* 2008; 47:626.
- Alomari A, McNiff JM:** The significance of eosinophils in hypertrophic lichen planus. *J Cutan Pathol* 2014; 41:347.
- Arias-Santiago S, et al:** Cardiovascular risk factors in patients with lichen planus. *Am J Med* 2010; 124:543.
- Atefi N, et al:** Prevalence of diabetes mellitus and impaired fasting blood glucose in patients with lichen planus. *Med J Islam Repub Iran* 2012; 26:22.
- Balasubramaniam P, et al:** Lichen planus in children: review of 26 cases. *Clin Exp Dermatol* 2008; 33:457.
- Belfiore P, et al:** Prevalence of vulval lichen planus in a cohort of women with oral lichen planus: an interdisciplinary study. *Br J Dermatol* 2006; 155:994.
- Bermejo-Fenoll A, et al:** Familiar oral lichen planus: presentation of six families. *Oral Surg Oral Med Oral Pathol Oral Radiol Endod* 2006; 102:e12.
- Brauns B, et al:** Intralesional steroid injection alleviates nail lichen planus. *Int J Dermatol* 2011; 50:626.
- Brehmer F, et al:** Response of recalcitrant lichen planus to alitretinoin in 3 patients. *J Am Acad Dermatol* 2011; 65:e58.
- Camisa C, Popovsky JL:** Effective treatment of oral erosive lichen planus with thalidomide. *Arch Dermatol* 2000; 136:1442.
- Chandan V, et al:** Esophageal lichen planus. *Arch Pathol Lab Med* 2008; 132:1026.
- Chave TA, Graham-Brown RAC:** Keratoacanthoma developing in hypertrophic lichen planus. *Br J Dermatol* 2003; 148:592.
- Chryssostalis A, et al:** Esophageal lichen planus: a series of eight cases including a patient with esophageal verrucous carcinoma—a case series. *Endoscopy* 2008; 40:764.
- Cohen PR, Kurzrock R:** Anakinra-responsive lichen planus in a woman with Erdheim-Chester disease: a therapeutic enigma. *Dermatol Online J* 2014; 20:21241.
- Cooper S, et al:** The association of lichen sclerosus and erosive lichen planus of the vulva with autoimmune disease. *Arch Dermatol* 2008; 144:1432.
- Copper S, Wojnarowska F:** Influence of treatment of erosive lichen planus of the vulva on its prognosis. *Arch Dermatol* 2006; 142:289.
- Di Fede O, et al:** Unexpectedly high frequency of genital involvement in women with clinical and histological features of oral lichen planus. *Acta Derm Venereol* 2006; 86:433.
- Domingues E, et al:** Imiquimod reactivation of lichen planus. *Cutis* 2012; 89:276.
- Dreijer J, et al:** Lichen planus and dyslipidaemia: a case-control study. *Br J Dermatol* 2009; 111:626.
- Elewa R, et al:** Recalcitrant severe erosive cutaneous lichen planus treated with extracorporeal photopheresis monotherapy. *Br J Dermatol* 2011; 165:441.
- Fiveson D, et al:** Treatment of generalized lichen planus with alefacept. *Arch Dermatol* 2006; 142:151.
- Ganguly S, Jaykar KC:** Twenty-nail dystrophy in association with zosteriform lichen planus. *Indian J Dermatol* 2012; 57:329.
- Goettmann S, et al:** Nail lichen planus: epidemiological, clinical, pathological, therapeutic and prognosis study of 67 cases. *J Eur Acad Dermatol Venereol* 2012; 26:1304.
- Goñi Esarte S, et al:** Rituximab as rescue therapy in refractory esophageal lichen planus. *Gastroenterol Hepatol* 2013; 36:264.
- Gonzalez-Moles MA, et al:** Treatment of severe erosive gingival lesions by topical application of clobetasol propionate in custom trays. *Oral Surg Oral Med Oral Pathol Oral Radiol Endod* 2003; 95:688.
- Guyot AD, et al:** Treatment of refractory erosive oral lichen planus with extracorporeal photochemotherapy: 12 cases. *Br J Dermatol* 2007; 156:553.
- Halawani M, et al:** Hepatitis C virus genotypes among patients with lichen planus in the Kingdom of Saudi Arabia. *Int J Dermatol* 2014; 53:171.
- Hamada T, et al:** Lichen planus pemphigoides and multiple keratoacanthomas associated with colon adenocarcinoma. *Br J Dermatol* 2004; 151:232.
- Harden D, et al:** Lichen planus associated with hepatitis C virus: no viral transcripts are found in the lichen planus, and effective therapy for hepatitis C virus does not clear lichen planus. *J Am Acad Dermatol* 2003; 49:847.
- Holló P, et al:** Successful treatment of lichen planus with adalimumab. *Acta Derm Venereol* 2012; 92:339.
- Hoskyn J, Guin J:** Contact allergy to cinnamyl in a patient with oral lichen planus. *Contact Dermatitis* 2005; 52:161.
- Hoshi A, et al:** Penile carcinoma originating from lichen planus on glans penis. *J Urol* 2008; 71:816.
- Iorizzo M:** Nail lichen planus—a possible new indication for oral alitretinoin. *J Eur Acad Dermatol Venereol* 2014. [EPub ahead of print.]
- Iraji F, et al:** Comparison the narrow band UVB versus systemic corticosteroids in the treatment of lichen planus: a randomized clinical trial. *J Res Med Sci* 2011; 16:1578.
- Iraji F, et al:** Comparison of the therapeutic effect of low-dose low-molecular-weight heparin (enoxaparin) vs. oral prednisone in treatment of patients with lichen planus: clinical trial. *Adv Biomed Res* 2013; 2:76.
- Irla N, et al:** Nail lichen planus: successful treatment with etanercept. *Case Rep Dermatol* 2010; 2:173.
- Ito Y, et al:** Disseminated lichen planus due to a zinc allergy. *J Dermatol* 2012; 39:948.
- Jang N, Fischer G:** Treatment of erosive vulvovaginal lichen planus with methotrexate. *Australas J Dermatol* 2008; 49:219.
- Kanwar AJ, De D:** Methotrexate for treatment of lichen planus: old drug, new indication. *J Eur Acad Dermatol Venereol* 2013; 27:e410.
- Keenan AV, Ferraiolo D:** Insufficient evidence for effectiveness of any treatment for oral lichen planus. *Evid Based Dent* 2011; 12:85.
- Kirby B, et al:** Treatment of lichen planus of the penis with photodynamic therapy. *Br J Dermatol* 1999; 141:765.
- Kirtschig G, et al:** Successful treatment of erosive vulvovaginal lichen planus with topical tacrolimus. *Br J Dermatol* 2002; 147:625.
- Köksal AS, et al:** Treatment of esophageal stricture due to lichen planus with intralesional corticosteroid injection. *Surg Laparosc Endosc Percutan Tech* 2014; 24:e32.
- Kolios AG, et al:** Oral, esophageal and cutaneous lichen ruber planus controlled with alitretinoin: case report and review of the literature. *Dermatology* 2013; 226:302.
- Kollner K, et al:** Treatment of oral lichen planus with the 308-nm UVB excimer laser—early preliminary results in eight patients. *Lasers Surg Med* 2003; 33:158.
- Kortekangas-Savolainen O, Kiilholma P:** Treatment of vulvovaginal erosive and stenosing lichen planus by surgical dilatation and methotrexate. *Acta Obstet Gynecol Scand* 2007; 86:339.
- Kossard S, et al:** Hypertrophic lichen planus—like reactions combined with infundibulocystic hyperplasia. *Arch Dermatol* 2004; 140:1262.
- Krasowska D, et al:** Development of squamous cell carcinoma with lesions of cutaneous lichen planus. *Eur J Dermatol* 2007; 17:447.
- Kyriakis KP, et al:** Sex and age distribution of patients with lichen planus. *Eur Acad Dermatol Venereol* 2006; 18:625.
- Lade NR, et al:** Blaschkoid lichen planus: not a Koebner phenomenon. *Dermatol Online J* 2013; 19:17.
- Laeijendecker R, et al:** Oral lichen planus and allergy to dental amalgam restorations. *Arch Dermatol* 2004; 140:1434.
- Laeijendecker R, et al:** Oral lichen planus and hepatitis C virus infection. *Arch Dermatol* 2005; 141:906.
- Le Cleach L, Chosidow O:** Lichen planus. *N Engl J Med* 2012; 366:723.
- Level NJ:** No evidence for therapeutic effect of topical cyclosporin in oral lichen planus. *Br J Dermatol* 2006; 155:477.
- Lewis FM, Bogliatto F:** Erosive vulval lichen planus: a diagnosis not to be missed—a clinical review. *Eur J Obstet Gynecol Reprod Biol* 2013; 171:214.
- Limas C, Limas CJ:** Lichen planus in children: a possible complication of hepatitis B vaccines. *Pediatr Dermatol* 2002; 19:204.



- Lonsdale-Eccles AA, Velangi S:** Topical pimecrolimus in the treatment of genital lichen planus: a prospective case series. *Br J Dermatol* 2005; 153:390.
- Lora V, et al:** Zosteriform lichen planus after herpes zoster: report of a new case of Wolf's isotopic phenomenon and literature review. *Dermatol Online J* 2014;20.
- Lospinoso DJ, et al:** Lupus erythematosus/lichen planus overlap syndrome: successful treatment with acitretin. *Lupus* 2013; 22:851.
- Lozada-Nur F, Sroussi H:** Tacrolimus powder in Orabase 0.1% for the treatment of oral lichen planus and oral lichenoid lesions: an open clinical trial. *Oral Surg Oral Med Oral Pathol Oral Endod* 2006; 102:744.
- Luis-Montaya P, et al:** Lichen planus in 24 children with review of the literature. *Pediatr Dermatol* 2005; 22:295.
- Lundqvist EN, et al:** Psychological health in patients with genital and oral erosive lichen planus. *Eur Acad Dermatol Venereol* 2006; 20:661.
- Maender J, et al:** Complete resolution of generalized lichen planus after treatment with thalidomide. *J Drugs Dermatol* 2005; 4:86.
- Maluf R, et al:** Bilateral lower eyelid margin erosion associated with lichen planus. *Ophthalm Plast Reconstr Surg* 2006; 22:310.
- Mansura A, et al:** Ultraviolet A-1 as a treatment for ulcerative lichen planus of the feet. *Photodermatol Photoimmunol Photomed* 2006; 22:164.
- Montebugnoli L, et al:** Clinical and histologic healing of lichenoid oral lesions following amalgam removal: a prospective study. *Oral Surg Oral Med Oral Pathol Oral Radiol* 2012; 113:766.
- Morales-Callaghan A Jr, et al:** Annular atrophic lichen planus. *J Am Acad Dermatol* 2005; 52:906.
- Muñoz ER, et al:** Isolated conjunctival lichen planus: a diagnostic challenge. *Arch Dermatol* 2011; 147:465.
- Nagao Y, et al:** Exacerbation of oral erosive lichen planus by combination of interferon and ribavirin therapy for chronic hepatitis C. *Int J Mol Med* 2005; 15:237.
- Nakashima C, et al:** Treatment of intractable oral lichen planus with intravenous immunoglobulin therapy. *Eur J Dermatol* 2012; 22:693.
- Nishizawa A, et al:** Close association between metal allergy and nail lichen planus: detection of causative metals in nail lesions. *J Eur Acad Dermatol* 2013; 27:e231.
- Noda S, et al:** Lichen planus in a patient with long-term exposure to chrome. *Eur J Dermatol* 2011; 21:417.
- Okiyama N, et al:** Squamous cell carcinoma arising from lichen planus of nail matrix and nail bed. *J Am Acad Dermatol* 2005; 53:908.
- Pandhi D et al:** Lichen planus in childhood: a series of 316 patients. *Pediatr Dermatol* 2014, 31:59.
- Parodi A, et al:** Prevalence of stratified epithelium-specific antinuclear antibodies in 138 patients with lichen planus. *J Am Acad Dermatol* 2007; 56:974.
- Passeron T, et al:** Treatment of erosive oral lichen planus by the 308 nm excimer laser. *Lasers Surg Med* 2004; 34:205.
- Passeron T, et al:** Treatment of oral erosive lichen planus with 1% pimecrolimus cream. *Arch Dermatol* 2007; 143:472.
- Paul J, et al:** An open-label pilot study of apremilast for the treatment of moderate to severe lichen planus: a case series. *J Am Acad Dermatol* 2013; 68:255.
- Petropoulou H, et al:** Effective treatment of erosive lichen planus with thalidomide and topical tacrolimus. *Int J Dermatol* 2006; 45:1244.
- Polderman MC, et al:** Ultraviolet A1 in the treatment of generalized lichen planus: a report of 4 cases. *J Am Acad Dermatol* 2004; 50:646.
- Quispel R, et al:** High prevalence of esophageal involvement in lichen planus: a study using magnification chromoendoscopy. *Endoscopy* 2009; 41:187.
- Radfar L, et al:** A comparative treatment study of topical tacrolimus and clobetasol in oral lichen planus. *Oral Surg Oral Med Oral Pathol Oral Radiol Endod* 2008; 105:187.
- Reich HL, et al:** Annular lichen planus: a case series of 20 patients. *J Am Acad Dermatol* 2004; 50:595.
- Reichrath J, et al:** Treatment of genito-anal lesions in inflammatory skin diseases with PUVA cream photochemotherapy: an open pilot study in 12 patients. *Dermatology* 2002; 205:245.
- Richert B, et al:** Nail bed lichen planus associated with onychopapilloma. *Br J Dermatol* 2007; 156:1071.
- Rogers RS, Bruce AJ:** Lichenoid contact stomatitis. *Arch Dermatol* 2004; 140:1524.
- Sakuma-Oyama Y, et al:** Lichen planus pemphigoides evolving into pemphigoid nodularis. *Clin Exp Dermatol* 2003; 28:613.
- Salem CB, et al:** Captopril-induced lichen planus pemphigoides. *Pharmacoepidemiol Drug Safety* 2008; 17:722.
- Salgado DS, et al:** Plaque control improves the painful symptoms of oral lichen planus gingival lesions: a short-term study. *J Oral Pathol Med* 2013; 42:728.
- Sanchez-Perez J, et al:** Lichen planus with lesions on the palms and/or soles: prevalence and clinicopathological study of 36 patients. *Br J Dermatol* 2000; 142:310.
- Saricaoglu H, et al:** Narrowband UVB therapy in the treatment of lichen planus. *Photodermatol Photoimmunol Photomed* 2003; 19:265.
- Sartori-Valinotti JC, et al:** A 10-year review of otic lichen planus: the Mayo Clinic experience. *JAMA Dermatol* 2013; 149:1082.
- Schwartz M, et al:** Two siblings with lichen planus and squamous cell carcinoma of the esophagus. *Eur J Gastroenterol Hepatol* 2006; 10:1111.
- Setterfield JF, et al:** The vulvovaginal gingival syndrome: a severe subgroup of lichen planus with characteristic clinical features and a novel association with the class II HLA DQB1\* 0201 allele. *J Am Acad Dermatol* 2006; 55:98.
- Seyhan M, et al:** High prevalence of glucose metabolism disturbance in patients with lichen planus. *Diabetes Research Clin Pract* 2007; 77:198.
- Shah KM, et al:** Oral lichenoid reaction due to nickel alloy contact hypersensitivity. *BMJ Case Rep* 2013; 2013.
- Simpson RC, et al:** Real-life experience of managing vulval erosive lichen planus: a case-based review and UK multicenter case note audit. *Br J Dermatol* 2012; 167:85.
- Sing SK, et al:** Squamous cell carcinoma arising from hypertrophic lichen planus. *Eur Acad Dermatol Venereol* 2006; 20:745.
- Singal A:** Familial mucosal lichen planus in three successive generations. *Int J Dermatol* 2005; 44:81.
- Singh S, et al:** Lichen planus causing severe vulval stenosis: rare presentation of a common dermatosis. *Int J Dermatol* 2013; 52:1398.
- Stone SJ, et al:** Cost-effectiveness of personalized plaque control for managing the gingival manifestations of oral lichen planus: a randomized control study. *J Clin Periodontol* 2013; 40:859.
- Thorne JE, et al:** Lichen planus and cicatricial conjunctivitis: characterization of five cases. *Am J Ophthalmol* 2003; 136:239.
- Thornhill M, et al:** The role of histopathological characteristic in distinguishing amalgam-associated oral lichenoid reactions and oral lichen planus. *J Oral Pathol Med* 2006; 35:233.
- Tong DC, Ferguson MM:** Concurrent oral lichen planus and primary sclerosing cholangitis. *Br J Dermatol* 2002; 147:356.
- Torti D, et al:** Oral lichen planus. *Arch Dermatol* 2007; 143:511.
- Tosti A, et al:** Nail changes in lichen planus may resemble those of yellow nail syndrome. *Br J Dermatol* 2000; 142:848.
- Tosti A, et al:** Nail lichen planus in children: clinical features, response to treatment, and long-term follow-up. *Arch Dermatol* 2001; 137:1027.
- Turan H, et al:** Methotrexate for the treatment of generalized lichen planus. *J Am Acad Dermatol* 2009; 60:164.
- Verma S:** Lichen planus affecting eyelid alone: a rare entity. *Indian J Dermatol Venereol Leprol* 2006; 72:398.
- Walsh DS, et al:** A vaginal prosthetic device as an aid in treating ulcerative lichen planus of the mucous membrane. *Arch Dermatol* 1995; 131:265.
- Webber NK, et al:** Lacrimal canalicular duct scarring in patients with lichen planus. *Arch Dermatol* 2012; 148:224.
- Wee JS, et al:** Efficacy of mycophenolate mofetil in severe mucocutaneous lichen planus: a retrospective review of 10 patients. *Br J Dermatol* 2012; 167:36.
- Welsh JP, et al:** A novel visual clue for the diagnosis of hypertrophic lichen planus. *Arch Dermatol* 2006; 142:954.
- Wong CS, et al:** Isolated vulval splitting—is this normal or pathological? *J Obstet Gynaecol* 2004; 24:899.
- Xia J, et al:** Short-term clinical evaluation of intralesional triamcinolone acetonide injection for ulcerative oral lichen planus. *J Oral Pathol Med* 2006; 35:327.
- Yokozeki H, et al:** Twenty-nail dystrophy (trachyonychia) caused by lichen planus in a patient with gold allergy. *Br J Dermatol* 2005; 152:1089.
- Zaraa I, et al:** Lichen planus pemphigoides: four new cases and a review of the literature. *Int J Dermatol* 2013; 52:406.



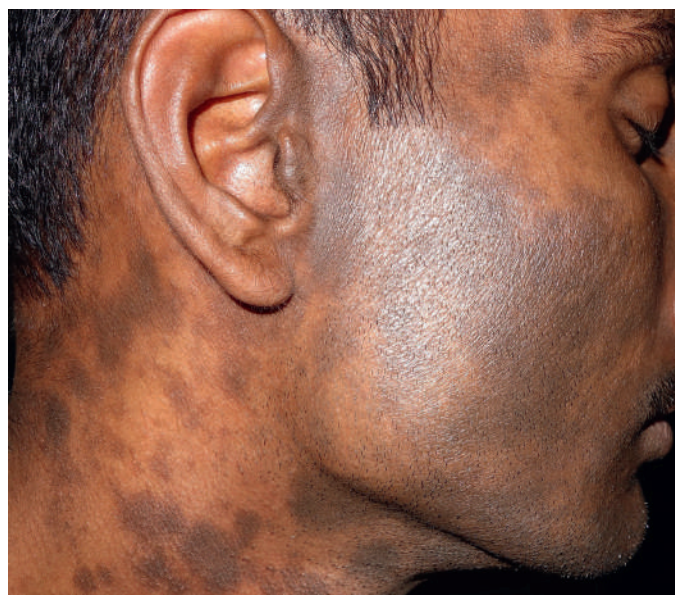**Fig. 12-11** Cicatricial alopecia caused by lichen planus.

### Adnexal lichen planus: follicular lichen planus (lichen planopilaris) and acrosyringal lichen planus

Lichen planopilaris (LPP) is lichen planus involving the follicular apparatus. Most cases involve the scalp, and LPP is an important cause of cicatricial alopecia (Fig. 12-11; see Chapter 33). From 70–80% of affected patients are women, usually about age 50. The oral mucosa is involved, with reticulate LP in 7–27% of patients, and 20–40% of patients have cutaneous involvement. Graham-Little-Piccardi-Lasseur syndrome describes patients with LPP of the scalp with coexistent keratosis pilaris-like LPP lesions on the skin. In addition to this classic variant of lichen planopilaris, a newly recognized variant of cutaneous LPP presents with numerous, small (1–2 mm) skin-colored papules on the upper half of the face, often lateral to the eye. These are seen in association with alopecia of the eyebrows and frontal fibrosing alopecia (LPP variant of scalp). The rarest variant of LPP is lichen planus follicularis tumidus, formerly called agminate lichen follicularis with cysts and comedones. This presents in the retroauricular area and on the cheeks of middle-age women, where the lesions appear as tumid, red-violet plaques covered with numerous small, white-yellow cysts and comedones. The lesions resemble the plaques seen in Favre-Racouchot syndrome and some cases of phymatous and cystic rosacea. The ears, chin, and scalp can be similarly involved. Other variants of LP of the skin and nails can occur in the same patient, and these may appear at about the same time. Histologically, a dense lichenoid infiltrate surrounds the follicles and cysts of the affected skin. The cysts are considered secondary to the lichenoid inflammation. Similar lesions have been seen in follicular mycosis fungoides, probably forming by a similar mechanism. Favre-Racouchot syndrome, follicular mucinosis, and LE must be distinguished histologically from LPP.

Lichen planus can involve the soles and at times the palms. Lesions are typically scaly plaques that look very psoriasiform and are usually only diagnosed by the coexistence of typical LP elsewhere or by biopsy. Less often, the lesions of LP of the palms and soles may present as petechial-like lesions, or diffuse keratoderma. When palmoplantar LP affects primarily the acrosyringium, the lesions appear as umbilicated papules or punctate keratoses. A biopsy is usually required to confirm the diagnosis, unless typical LP is present elsewhere. Palmoplantar LP can respond well to oral retinoids.

**Andrews ID, et al:** A papular eruption on the face: a distinct subtype of lichen planopilaris. *J Dermatol Case Rep* 2013; 1:23.



**Fig. 12-12** Lichen planus pigmentosa. (Courtesy of Dr. Debabrata Bandyopadhyay.)

**Donati A, et al:** Facial papules in frontal fibrosing alopecia. *Arch Dermatol* 2011; 147:1424.

**Guttee RM:** Acrosyringal lichen planus of palm. *Indian J Dermatol Venereol Leprol* 2012; 78:521.

**Guttee RM:** Unilateral acrosyringal lichen planus of palm. *Indian Dermatol Online J* 2013; 4:350.

**Jiménez-Gallo D, et al:** Facial follicular cysts: a case of lichen planus follicularis tumidus. *J Cutan Pathol* 2013; 40:818.

**Kim MJ, et al:** Two cases of palmoplantar lichen planus with various clinical features. *J Dermatol* 2010; 37:985.

**Zeng YP, et al:** Lichen planus with palmoplantar involvement: rapid therapeutic response to acitretin. *Eur J Dermatol* 2011; 21:632.

### Lichen planus pigmentosus/actinicus

Lichen planus pigmentosus is seen primarily in Central America, the Indian subcontinent, the Middle East, and Japan. It appears to be a form of LP restricted to certain racial groups. The persons from these genetic groups can develop the condition when they move to North America and Europe, but Caucasians from Europe and North America do not develop lichen planus pigmentosus when they move to tropical areas where the disease is common. Lichen planus pigmentosus patients are young, usually 20–45, and men and women are equally affected. Men present a decade earlier (mean age 26 vs. 34). The face and neck are primarily involved (Fig. 12-12), but the axilla, inframammary region, and groin may also be affected. Lesions may be unilateral. The condition is usually mild (<10% body surface area), and although patients may have associated pruritus, it is usually much milder than in patients with classic LP. Sometimes, classic LP papules occur at other sites or at the periphery of the lesions. In the United States, persons of color may demonstrate this pattern of LP. Individual lesions are typically several millimeters to several centimeters in size, are oval in shape, and may follow lines of Blaschko.

Some patients with lichen planus pigmentosus may have lesions predominantly in sun-exposed areas, and the diagnosis of lichen planus actinicus can be used in these cases. Lichen planus actinicus is reported most frequently in Africa, the Middle East, and the Indian subcontinent and represents a substantial proportion of LP diagnosed in these geographic areas (36% of all LP patients in an Egyptian series). Most cases



reported as lichen planus actinicus occur in childhood through young adulthood, with 20–30 the primary decade of presentation. The disease presents in the spring or summer and is frequently quiescent in winter. Lesions favor the sun-exposed parts of the body, especially the face, which is almost always the most severely affected site. Most lesions occur on the forehead, cheeks, eyelids, and lips. Outside the face, the V area of the chest, the neck, the backs of the hands, and the lower extensor forearms are involved. Associated pruritus, the hallmark of LP, is usually described as mild or absent. Lesions are usually annular but may be reticulate or diffuse. Individual lesions are often macular but may be plaques with peripheral violaceous papules. Characteristically, lesions are hyperpigmented, sometimes with the blue-gray tinge of dermal melanin. They may resemble melasma.

Because cases of lichen planus pigmentosus and lichen planus actinicus overlap, it is best to think of these conditions as a single disorder that may or may not be photoexacerbated. It is important to recognize the lichen planus actinicus variant of lichen planus pigmentosus because the actinicus patients do respond to sun protection, with gradual fading of their hyperpigmentation. Mucous membrane disease is significantly less common in patients with lichen planus pigmentosus/actinicus. Histologically, any papular element will usually show features of LP. Even macular areas may show subtle evidence of an interface dermatitis, with prominent dermal melanophages.

Lichen planus pigmentosus-inversus is described in the literature as a unique, separate, and rare disorder. Lesions can be seen in patients with classic lichen planus pigmentosus; however, this inverse pattern has a different racial distribution and has been reported in Caucasian patients as well as Asians and Hispanics. The axillae are the primary region of involvement in most patients (90%), although the groin, inframammary, neck, retroauricular, and flexural areas can also be involved. As with other types of lichen planus pigmentosus, pruritus is uncommon in the inversus type, and oral, nail, and hair involvement usually does not occur.

The treatment of lichen planus pigmentosus of all types is similar to other forms of LP. Topical corticosteroids and CNIs, antimalarials, and even immunomodulators can be used. The lesions may fade slowly because they are primarily caused by melanin incontinence, and even if the active agent has stopped the interface reaction, the pigment will persist.

### Erythema dyschromicum perstans

Erythema dyschromicum perstans is also known as “ashy dermatosis” or dermatosis cenicienta. The age of onset is virtually always before 40, but it is a chronic disease, so patients of all ages have been described. Prepubertal children have been reported. Lesions are typically several centimeters in size and affect primarily the trunk. A characteristic very fine (several millimeters), erythematous, palpable, nonscaling border is seen at the periphery of the lesions. This is described as feeling like a small cord. Unfortunately, this leading edge (and diagnostic feature) of the disorder is only present early in the disease course (a few months). Pruritus is not reported, and typical lichenoid papules are said not to occur. Nail and mucosal involvement is not found. An association with HLA-DR4 has been suggested for Mexican patients. Unfortunately, erythema dyschromicum perstans became a catchall term for the panoply of dermatologic disorders that heal with prominent postinflammatory change in pigmented persons. It is now believed that most cases previously called erythema dyschromicum perstans are actually cases of lichen planus pigmentosus. Childhood cases may represent idiopathic eruptive macular pigmentation. True erythema dyschromicum

perstans, if it exists, is quite rare and largely restricted to certain geographic regions.

At the active border, the characteristic histologic features of erythema dyschromicum perstans are those of a lichenoid dermatitis. In the centers of the lesions, the histologic changes are those of postinflammatory pigmentation. Therapeutic agents used for LP may benefit the acute inflammatory stage but have limited effect on the pigmented lesions. Spontaneous improvement has occurred, leading some to suggest that no treatment is reasonable.

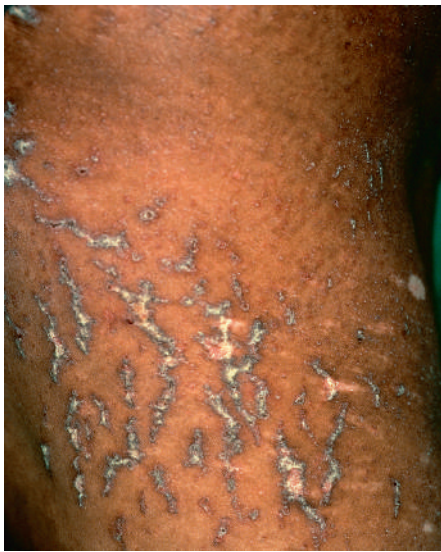### Idiopathic eruptive macular pigmentation

Although rarely reported, idiopathic eruptive macular pigmentation (IEMP) is not rare. Young persons (mean age 11 years in one study) presented with asymptomatic widespread brown to gray macules of up to several centimeters in diameter on the neck, trunk, and proximal extremities. Lesions are not confluent, and there is no history of preceding inflammation. At times, there is slight papillomatosis histologically, identical to that seen in confluent and reticulate papillomatosis (CARP). Unlike CARP, however, IEMP does not respond to oral minocycline. Lesions may spontaneously involute. Some cases reported as erythema dyschromicum perstans in childhood may actually represent IEMP.

- Anbar T, et al:** A clinical and epidemiological study of lichen planus among Egyptians of Al-Minya province. *Dermatol Online* 2005; 11:4.
- Barros HR, et al:** Lichen planus pigmentosus inversus. *An Bras Dermatol* 2013; 88:146.
- Chiu MW, et al:** Multiple brown patches on the trunk: idiopathic eruptive macular pigmentation with papillomatosis (IEMP). *Arch Dermatol* 2010; 146:1301.
- Correa M, et al:** HLA-DR association with the genetic susceptibility to develop ashy dermatosis in Mexican mestizo patients. *J Am Acad Dermatol* 2007; 56:617.
- Gaertner E, Elstein W:** Lichen planus pigmentosus-inversus: case report and review of an unusual entity. *Dermatol Online J* 2012; 18:11.
- Jang KA, et al:** Idiopathic eruptive macular pigmentation: report of 10 cases. *J Am Acad Dermatol* 2001; 44:351.
- Jansen T, et al:** Lichen planus actinicus treated with acitretin and topical corticosteroids. *J Eur Acad Dermatol Venereol* 2002; 16:171.
- Kanwar AJ, et al:** A study of 124 Indian patients with lichen planus pigmentosus. *Clin Exp Dermatol* 2003; 28:481.
- Kim G, Mikkilineni R:** Lichen planus actinicus. *Dermatol Online J* 2007; 13:13.
- Najhawan RI, et al:** Lichen planus pigmentosus-inversus involving the post-auricular sulci. *Dermatol Online J* 2013; 19: 18571.
- Ohshima N, et al:** Lichen planus pigmentosus-inversus occurring extensively in multiple intertriginous areas. *J Dermatol* 2012; 39:412.
- Ramirez P, et al:** Childhood actinic lichen planus: successful treatment with antimalarials. *Australas J Dermatol* 2012; 53:e10.
- Rieder E et al:** Lichen planus pigmentosus. *Dermatol Online J* 2013; 19:20713.
- Shgal VN, et al:** Lichen planus pigmentosus. *Skinmed* 2013; 11:96.
- Verma S, Thakur BK:** Idiopathic eruptive macular pigmentation with papillomatosis. *Indian Dermatol Online J* 2011; 2:101.
- Yokozeki H, et al:** Multiple linear erythema dyschromicum perstans (ashy dermatosis) in the lines of Blaschko. *Dermatology* 2005; 210:356.

### KERATOSIS LICHENOIDES CHRONICA

Keratosis lichenoides chronica is a rare dermatosis characterized by its chronicity. In adults, the disease begins in the late twenties. Typical lesions are papulonodular and hyperkeratotic and covered with gray scales. These lesions favor the extremities and buttocks. Although initially discrete,



**Fig. 12-13** Keratosis lichenoides chronica.

the lesions frequently coalesce to form linear and reticulate arrays of warty lichenoid lesions (Fig. 12-13). Lesions are infundibulocentric and acrosyringocentric. Keratotic plugs and prominent telangiectasia may be present. The palms and soles have discrete hyperkeratotic papules. There is an associated sharply marginated erythema, scaling, and telangiectasia of the face, superficially resembling seborrheic dermatitis or rosacea. Nail changes described include thickening of the nail plate, yellowing, longitudinal ridging, onycholysis, hyperkeratosis of the nail bed, paronychia, and warty lesions of the periungual areas. In addition, painful oral ulcerations occur in 25% of cases, and oral or genital involvement occurs in 50% of adult patients. Other findings include hoarseness from vocal cord edema and involvement of the eyelids (one third of patients), conjunctiva, iris, or anterior chamber.

Topical calcipotriol, PUVA, retinoids with PUVA, bath PUVA, photodynamic therapy, and oral retinoids (isotretinoin and acitretin) may all prove beneficial. Keratosis lichenoides chronica rarely responds to topical or systemic steroids. Childhood cases are rare and differ from adult cases. Infants are affected in the first year of life and have prominent facial purpura and erythema, especially on the cheeks. More than half of childhood cases are familial, suggesting autosomal recessive inheritance.

Histologically, there is irregular acanthosis or epidermal atrophy with hyperkeratosis and zones of parakeratosis. A lichenoid infiltrate, consisting primarily of lymphocytes, and vacuolar alteration at the basal cell layer, but concentrated around the infundibula or acrosyringia. Marked follicular plugging and plugging of the acrosyringia are characteristic.

**Boer A:** Keratosis lichenoides chronica: proposal of a concept. *Am J Dermatopathol* 2006; 28:260.

**Grammatikopoulou E, et al:** Keratosis lichenoides chronica: a case report. *Cutis* 2010; 86:245.

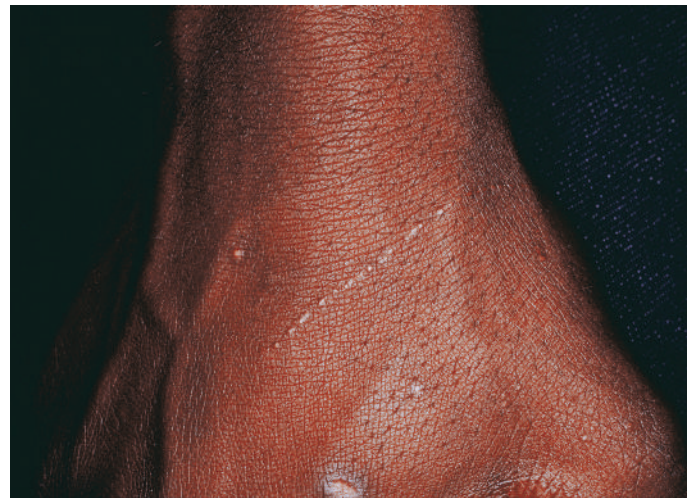**Kunte C, et al:** Keratosis lichenoides chronica: treatment with bath-PUVA. *Acta Derm Venereol* 2007; 87:182.

**Oyama N, et al:** Juvenile-onset lichenoides chronica treated successfully with topical tacrolimus: a safe and favourable outcome. *Eur J Dermatol* 2011; 21:595.

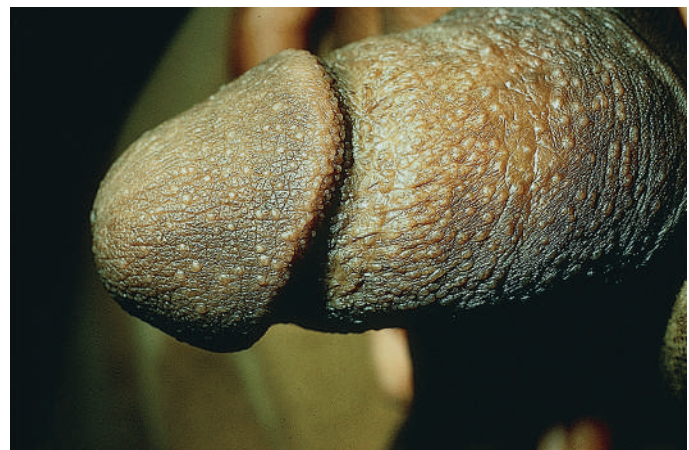
**Ruis-Maldonado R, et al:** Keratosis lichenoides chronica in pediatric patients: a different disease. *J Am Acad Dermatol* 2007; 56:S1.

**Singh BE, et al:** Pediatric onset keratosis lichenoides chronica: a case report. *Pediatr Dermatol* 2012; 29:511.

**Zhou P, et al:** Keratosis lichenoides chronica in association with primary cutaneous anaplastic large cell lymphoma. *Int J Dermatol* 2014; 53:e80.



**Fig. 12-14** Lichen nitidus, linear lesion from trauma.



**Fig. 12-15** Lichen nitidus, characteristic lesions of the penile shaft.

## LICHEN NITIDUS

### Clinical features

Lichen nitidus (LN) is a chronic inflammatory disease characterized by minute, shiny, flat-topped, pale, exquisitely discrete, uniform papules, rarely larger than 1–2 mm. Children and young adults are primarily affected. Pruritus is usually minimal or absent but may be more prominent in more generalized cases. Linear arrays of papules (Koebner phenomenon) are common, especially on the penis, forearms, and dorsal hands (Fig. 12-14). Initially, lesions are localized and often remain limited to a few areas, chiefly the penis and lower abdomen, the inner surface of the thighs, and the flexor aspects of the wrists and dorsal hands/forearms (Fig. 12-15). In other cases, the disease assumes a more widespread distribution, and the papules fuse into erythematous, finely scaly plaques. The reddish color varies with tints of yellow, brown, or violet. Unusual variants of LN include vesicular, hemorrhagic, linear, purpuric (resembling a pigmented purpuric dermatosis), and spinous follicular (resembling lichen spinulosus).

Palm and sole involvement may occur in LN, and the disease may be restricted to these areas. It presents with multiple tiny, hyperkeratotic papules. The papules may coalesce to form diffuse hyperkeratotic plaques that fissure. The differentiation of LN from hyperkeratotic hand eczema and LP of the palms is aided by the presence of a keratotic plug in the center of



lesions of palmoplantar LN. Nail involvement with pitting, beaded, longitudinal ridging, and nailfold inflammation has been reported. Oral involvement, with gray-yellow papules or petechiae of the hard palate, is rare.

A variant of LN, termed actinic lichen nitidus, has been reported in dark-skinned patients from the Middle East and Indian subcontinent. Cases seen in African Americans have also been termed “pinpoint, papular polymorphous light eruption” (PMLE), or known by the older term “summer actinic lichenoid eruption.” These cases all have lesions clinically and histologically identical to LN, which are limited to the sun-exposed areas of the dorsal hands, brachioradial area, and posterior neck. The LN histology may represent subacute or chronic lesions of pinpoint PMLE. Actinic LN/pinpoint papular PMLE usually responds to sun protection, with or without topical corticosteroids. Hydroxychloroquine has been used successfully in one Moroccan case.

The cause of LN is unknown. Rare familial cases do occur. The course of LN is slowly progressive, with a tendency for remission. The lesions may remain stationary for years but often eventually disappear spontaneously and entirely. Treatment is not required because it is usually asymptomatic and self-healing. However, topical corticosteroids or CNIs can be used for localized disease. NB UVB and PUVA can be effective in generalized cases, but care must be taken to be sure that the LN is not of the actinic variety. Anecdotal reports suggest therapeutic benefit from oral retinoids (acitretin). As in LP, refractory LN cases requiring aggressive therapy may respond to cyclosporin A.

Lichen nitidus is clinically and histologically distinct from lichen planus, and immunohistochemical studies also suggest they are distinct disorders. However, patients have had both disorders, suggesting some common pathogenic basis. Both LP and LN have been reported secondary to hepatitis B immunization and during treatment of hepatitis with IFN alpha. There are also reports of patients with both LN and Crohn’s disease, another condition with granulomatous inflammation.

Lichen nitidus has a characteristic histologic appearance. Dermal papillae are widened and contain a dense infiltrate composed of lymphocytes, histiocytes, and melanophages. There is an accumulation of both CD68+ histiocytes and S-100+, CD1a+ Langerhans cells in the dermal collections. Multinucleate giant cells are often present, imparting a granulomatous appearance to the infiltrate. The epidermal rete ridges on either side of the papilla form a clawlike collarette. The overlying epidermis is attenuated, and there is usually vacuolar alteration of its basal layer. At times, the infiltrate may extend down adjacent hair follicles and eccrine ducts, making distinction of LN from lichen scrofulosorum and lichen striatus difficult.

**Bilgili SG, et al:** A case of generalized lichen nitidus successfully treated with narrow-band ultraviolet B treatment. *Photodermatol Photoimmunol Photomed* 2013; 29:215.

**Bouras M, et al:** Facial actinic lichen nitidus successfully treated with hydroxychloroquine: a case report. *Dermatol Online J* 2013; 19:20406.

**Çakmak SK, et al:** Lichen nitidus with involvement of the palms. *Pediatr Dermatol* 2013; 30:e100.

**Dar NR, Rao SU:** Facial lichen nitidus actinicus. *Australas J Dermatol* 2012; 53:e16.

**Fetil E, et al:** Lichen nitidus after hepatitis B vaccine. *Int Soc Dermatol* 2004; 43:956.

**Ikenberg K, et al:** Thirty-year history of palmar eruptions: a quiz. *Acta Derm Venereol* 2011; 91:108.

**Lee MW, et al:** Penile lichen nitidus successfully treated with topical pimecrolimus 1% cream. *J Dermatol* 2013; 40:499.

**Lernia V, et al:** Lichen planus appearing subsequent to generalized lichen nitidus in a child. *Pediatr Dermatol* 2007; 24:453.

**Leung AK, Ng J:** Generalized lichen nitidus in identical twins. *Case Rep Dermatol Med* 2012; 2012:982084.

**MacDonald AJ, et al:** Lichen nitidus and lichen spinulosus or spinous follicular lichen nitidus. *Clin Exp Dermatol* 2005; 30:435.

**Nakamizo S, et al:** Accumulation of S-100+ CD1a+ Langerhans cells as a characteristic of lichen nitidus. *Clin Exp Dermatol* 2011; 36:811.

**Park J, et al:** Persistent generalized lichen nitidus successfully treated with 0.03% tacrolimus ointment. *Eur J Dermatol* 2013; 23:918.

**Park JH, et al:** Treatment of generalized lichen nitidus with narrowband ultraviolet B. *J Am Acad Dermatol* 2006; 54:545.

**Park JS:** Lichen nitidus and lichen spinulosus or spinous follicular lichen nitidus? A second case. *Clin Exp Dermatol* 2011; 36:557.

**Park SH, et al:** A case of palmar lichen nitidus presenting as a clinical feature of pompholyx. *Ann Dermatol* 2010; 22:235.

**Schelar M, et al:** Generalized lichen nitidus with involvement of the palms following interferon alpha treatment. *Dermatol* 2007; 215:236.

**Solano-López G, et al:** Actinic lichen nitidus in a Caucasian European patient. *J Eur Acad Dermatol Venereol* 2014. [Epub ahead of print.]

**Srivastava M, et al:** Lasseur-Graham-Little-Piccardi syndrome. *Dermatol Online J* 2007; 13:12.

**Summe HS, et al:** Generalized spinous follicular lichen nitidus with perifollicular granulomas. *Pediatr Dermatol* 2013; 30:e20.

**Tay EY, et al:** Lichen nitidus presenting with nail changes: case report and review of the literature. *Pediatr Dermatol* 2014. [Epub ahead of print.]

**Summey B, et al:** Actinic lichen nitidus. *Cutis* 2008; 81:266.

**Wanat KA, et al:** Extensive lichen nitidus as a clue to underlying Crohn’s disease. *J Am Acad Dermatol* 2012; 67:5.

**Yanez S, Val-Bernal F:** Purpuric generalized lichen nitidus: an unusual eruption simulating pigmented purpuric dermatosis. *Dermatology* 2004; 208:167.

**Yoon TY, et al:** Two cases of perforating lichen nitidus. *J Dermatol* 2006; 33:278.

## LICHEN STRIATUS

Lichen striatus is a fairly common, self-limited eruption seen primarily in young children (mean age 3 years). Girls are affected two to three times more frequently than boys. Lesions begin as small papules that are erythematous and slightly scaly (Fig. 12-16). In more darkly pigmented persons, hypopigmentation is prominent and may be purely macular. The 1–3 mm papules coalesce to form a band 1–3 cm wide, either continuous or interrupted, which over a few weeks progresses down the extremity or around the trunk, following lines of Blaschko. An extremity is more often involved, but trunk lesions or lesions extending from the trunk onto an extremity can also occur. About 10% of cases occur on the head. Multiple bands infrequently occur. Lesions are usually asymptomatic, but pruritus may occur, especially in patients who are also atopic.

Nail involvement can occur if the process extends down the digit to the nail. Typically, the lichen striatus appears first on the skin, but the skin and nail abnormality may appear

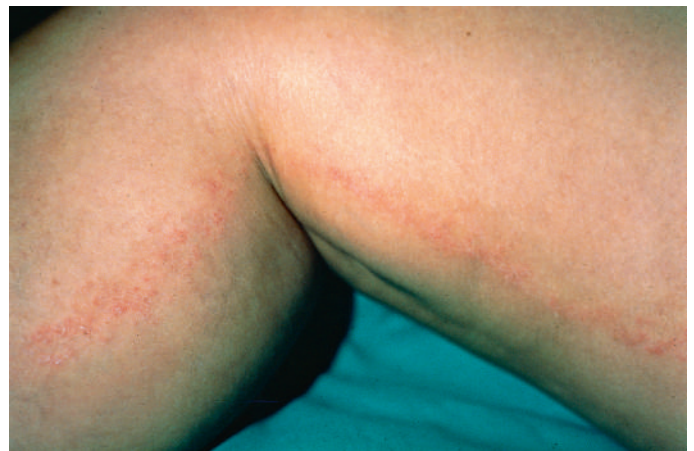

Fig. 12-16 Lichen striatus.

simultaneously. Infrequently, only the nail may be involved for months, with later appearance of the band on the skin, or the nail may remain the sole area of involvement throughout the course of the disease. Unilateral lichen striatus may be associated with bilateral nail involvement. Nail plate thinning, longitudinal ridging, splitting, and nail bed hyperkeratosis may be seen. Often, only a part of the nail is involved. The histology of involved nails is identical to that of the skin lesions.

The active lesions of lichen striatus last for an average of 1 year but may persist for up to 4 years. Eventually, all the lesions, including dystrophic nails, spontaneously resolve without scarring. Hypopigmentation may persist for several years. Hyperpigmentation is uncommon (<5%) and should suggest a diagnosis of linear LP instead. Relapses can occur in up to 5% of cases, either in the same distribution or in a different anatomic region.

The histologic features of lichen striatus vary, partly reflecting the stage of evolution of the lesion. There may be a spongiotic dermatitis, but most frequently a lichenoid component is present. There is a bandlike infiltrate with necrotic keratinocytes at the dermoepidermal junction. Granulomatous inflammation is occasionally present. Typically, there is a dense lymphoid infiltrate around the eccrine sweat glands and ducts. This helps to distinguish lichen striatus from lichen planus.

Multiple reports exist of simultaneous cases in siblings. There is also a seasonal variation, with most cases occurring in the spring and summer. Epidemic outbreaks have been reported, suggesting a viral etiology or trigger. Trauma has also been reported to precipitate an outbreak of lichen striatus.

Adult cases of lichen striatus differ from those in childhood and are rarer and more papulovesicular, affecting multiple regions, resolving more rapidly (<2 months), and relapsing more frequently (up to one third of patients). Histologically, the lesions show more spongiotic and less lichenoid features, leading some authors to call these cases "adult blaschkitis" or "Grosshans-Marot disease." This splitting of terms probably has no clinical utility.

Usually, the diagnosis of lichen striatus is straightforward, in a young child with sudden onset of an eruption following the lines of Blaschko. The differential diagnosis could include linear LP, linear psoriasis, inflammatory linear verrucous epidermal nevus, epidermal nevus, linear cutaneous LE, and verruca plana. Histologic evaluation will usually distinguish these entities, but this is rarely required.

Treatment is usually not necessary. Parents may be reassured of the uniformly excellent prognosis. Topical corticosteroids and topical CNIs may accelerate the resolution of lesions. The combination of tazarotene and topical steroid treatment has led to rapid resolution in one series. In children with an acquired nail dystrophy of one or two digits, lichen striatus must be considered, and watchful waiting might be considered before biopsying the nail.

**Al-Niami FA, Cox NJ:** Unilateral lichen striatus with bilateral onychodystrophy. *Eur J Dermatol* 2009; 19:511.

**Feely MA, Silverberg NB:** Two cases of lichen striatus with prolonged active phase. *Pediatr Dermatol* 2014; 31:e67.

**Jo JH, et al:** Early treatment of multiple and spreading lichen striatus with topical tacrolimus. *J Am Acad Dermatol* 2007; 57:904.

**Karakas M, et al:** Lichen striatus following HBV vaccination. *J Dermatol* 2005; 32:506.

**Karempelis PS, et al:** Lichen striatus in a mother and son. *Int J Dermatol* 2014; 53:e366.

**Lee DY, et al:** Lichen striatus in an adult treated by a short course of low-dose systemic corticosteroid. *J Dermatol* 2010; 38:298.

**Litvinov IV, Jafarian F:** Images in clinical medicine: lichen striatus and lines of Blaschko. *N Engl J Med* 2012; 367:2427.

**Lora V, et al:** Lichen striatus associated with etanercept treatment of rheumatoid arthritis. *J Am Acad Dermatol* 2014; 70:e90.

**Mu EW, et al:** Facial lichen striatus in children: retracting the lines of Blaschko. *Pediatr Dermatol* 2013; 30:364.

**Müller CS, et al:** Lichen striatus and blaschkitis: reappraisal of the concept of blaschkolinear dermatoses. *Br J Dermatol* 2011; 164:257.

**Palleschi GM, et al:** Lichen striatus and nail involvement: truly rare or question of time? *Int J Dermatol* 2012 51:749.

**Park JY, Kim YC:** Lichen striatus successfully treated with photodynamic therapy. *Clin Exp Dermatol* 2012; 37:562.

**Patrizi A, et al:** Lichen striatus: clinical and laboratory features of 115 children. *Pediatr Dermatol* 2004; 21:197.

**Sato H, et al:** Case of lichen striatus presenting with multiple lesions along Blaschko's lines. *J Dermatol* 2012; 39:802.

**Taniguchi K, et al:** Lichen striatus: description of 89 cases in children. *Pediatr Dermatol* 2004; 21:440.

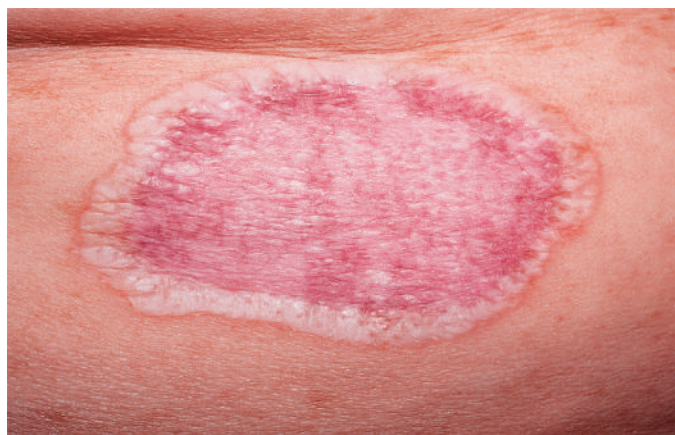**Youssef SM, Teng JM:** Effective topical combination therapy for treatment of lichen striatus in children: a case series and review. *J Drugs Dermatol* 2002; 11:872.

## LICHEN SCLEROSUS (LICHEN SCLEROSUS ET ATROPHICUS)

Lichen sclerosus is a chronic disease of the skin and mucosa. The terms lichen sclerosus et atrophicus, kraurosis vulvae, and balanitis xerotica obliterans are synonymous but have been replaced by the single term lichen sclerosus (LS). LS can present from childhood to old age. Although it occurs in all races, whites and Hispanics are more frequently affected, and it is rare in African Americans. Both genders develop LS both before and after puberty, with females predominating at all ages. The prevalence is about 1.7% in the general adult female population, and about one-tenth as frequent in premenarchal girls.

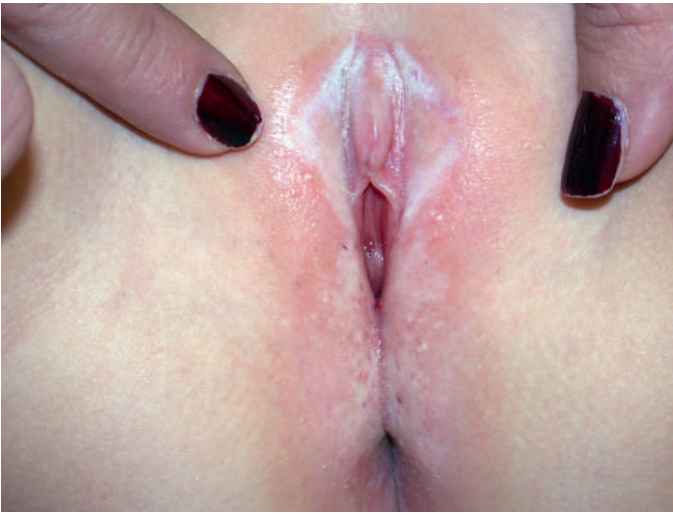The pathogenesis of LS is poorly understood. Autoimmune diseases (thyroid disease, vitiligo, morphea, alopecia areata, pernicious anemia) occur in one fifth to one third of women with LS but are much less common in men. Psoriasis is increased in women with LS, reported to occur in 7.5–17% of patients. Autoantibodies to extracellular matrix protein 1 (ECM-1) are found in 80% of LS patients, compared with 4% of controls and 7–10% of patients with other autoimmune diseases. The titer of the ECM-1 autoantibody correlates with the disease severity. The importance of this humoral autoimmunity in the pathogenesis of LS is currently unclear.

In females, there is a bimodal age distribution—prepubertal and postmenopausal. The initial lesions of LS are white, polygonal, flat-topped papules, plaques, or atrophic patches (Fig. 12-17). Lesions may be surrounded by an erythematous to



**Fig. 12-17** Lichen sclerosus of the glabrous skin.





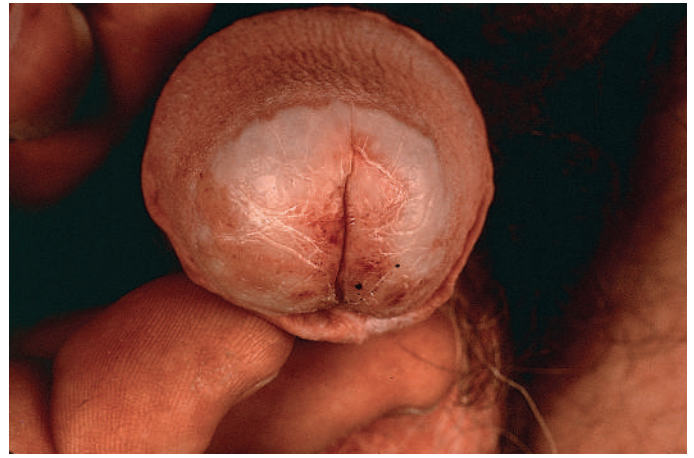**Fig. 12-18** Lichen sclerosus, white atrophic lesions with loss of normal tissue markings.

violaceous halo. In atrophic lesions, the skin is smooth, slightly wrinkled, soft, and white. Bullae, often hemorrhagic, telangiectasias, and fixed areas of purpura may occur on the patches. About 40% of women with LS are asymptomatic. However, when women referred to specialists are questioned, virtually 100% are symptomatic. Itching is frequently severe, especially in the anogenital area. In the genital area, fissuring and erosion may occur. This may result in dysuria, urethral and vaginal discharge, dyspareunia, and burning pain. Normal anatomic structures may be obliterated, with loss of the labia minora, clitoral hood, and urethral meatus. In women, this perineal involvement typically affects the vulvar and perianal areas, giving a figure-8 or hourglass appearance. Introital stenosis or fusion may occur. The vaginal and cervical mucosae are not involved by LS, in contrast to LP. Prepubertal girls may also be affected and usually have vulvar and perianal lesions (Fig. 12-18).

Vulvar disease is associated with similar skin changes to those in adult women, and pruritus may be a prominent symptom. Perianal involvement may produce significant symptomatology of constipation, stool holding, and rectorrhagia caused by rectal fissures. Infantile perineal protrusion refers to a pyramidal soft tissue swelling covered by red or rose-colored skin along the median perineal raphe (skin between posterior fourchette and anus). This occurs only in girls and appears to be a manifestation of LS in some prepubertal girls. Two thirds of girls with LS have been evaluated for sexual abuse, largely because of the ecchymoses that accompany the lesions. If risk of sexual abuse is suspected, appropriate investigations must be performed.

There is clearly a relationship between the hormonal milieu and LS. Postmenopausal women are preferentially affected. Pregnancy leads to improvement and often complete resolution. Oral contraceptive (OC) use is common in premenopausal women with LS. These OCs are often antiandrogenic. Stopping OCs and treating with standard topical agents lead to significant improvement, suggesting that the antiandrogen OCs may have accelerated the appearance of the LS. However, treatment of postmenopausal women with estrogen supplementation does not alter the incidence or course of their LS.

In males, lesions are atrophic and may be greatly hypopigmented or depigmented, resembling vitiligo. Lesions usually involve only the glans penis and the inner foreskin of the uncircumcised male. Infrequently, LS may extend on to the penile shaft and scrotum. If the glans is involved, hemorrhage is common, and shallow erosions may occur. LS of the glans



**Fig. 12-19** Lichen sclerosus, phimosis; note the hemorrhagic macule.

does not usually lead to nonhealing erosions of the glans, but rather simply skin fragility. Phimosis and paraphimosis are common complications of LS in men (Fig. 12-19). Between 15% and 100% of circumcision specimens from prepubertal boys show features of LS. Sixty percent of acquired phimosis in boys and at least 10% in adult men are associated with LS. Most men with LS are uncircumcised, and exposure to urine appears to be an important trigger for LS in males. Circumcision is effective treatment for penile LS, with cure rates of 75–100%. Urethral meatal stenosis may occur and requires surgical correction. Perianal involvement by LS is rare in men and boys with penile LS.

Extragenital lesions are most frequent on the upper back, chest, and breasts and are usually asymptomatic. The tongue and oral mucosa may also be involved, either alone or with lesions elsewhere. Peristomal involvement around colostomy sites may occur. Patients having only extragenital lesions with histologic features of both LS and morphea have been reported. About one quarter of these patients have LS-like changes overlying the morphea lesions (a recognized histopathologic variant of morphea), and in three quarters the extragenital LS lesions are distinct from the morphea lesions. Genital LS is much more common in patients (usually women) with localized plaque or generalized morphea. In one study, up to 40% of patients with morphea also had genital LS. The genital area of patients with morphea should be examined for the presence of LS. Rarely, in Europe, *Borrelia* has been reported to cause extragenital LS, and treatment with antibiotics has arrested the progression of the lesions.

### Lichen sclerosus and cancer

Although the risk is not as high as was proposed early in this century, LS of the genitalia is a condition with increased risk for genital squamous cell carcinoma in both women and men. The lifetime risk for women who are carefully followed appears to be 5% or less but is clearly higher than for the general population. About one third of vulvar SCCs in women arise on a background of LS. Human papillomavirus (HPV) appears to be associated with only about 15% of SCCs arising in women with LS. Hypertrophic vulvar lesions and age beyond 60 are risk factors for the development of SCC in women with LS. Such lesions and patients should be evaluated carefully. In men with LS, the risk for genital SCC is less than in women with LS. However, about 25% of cases of penile SCC are associated with LS. Oncogenic HPV types do not appear to be associated with LS-related penile cancer.

## Histopathology

Early lesions of LS are characterized by an interface dermatitis with vacuolar alteration of keratinocytes. With evolution, the epidermis is thinned and the rete ridges are effaced. Compact orthokeratosis and follicular and eccrine plugging are present. The upper dermis is edematous, with the upper dermal collagen homogenized. Immediately beneath the altered papillary dermis, there is a sparse, bandlike and perivascular lymphoid infiltrate. In pruritic lesions, coexistent changes of lichen simplex chronicus may be seen, with acanthosis rather than atrophy of the epidermis.

## Differential diagnosis

Extragenital LS must be differentiated from guttate morphea and LP, especially of the atrophic type. Anogenital LS must be distinguished from genital LP, lichen simplex chronicus, vulvar intraepithelial neoplasia (SCC in situ), and extramammary Paget's disease. The white color and atrophic surface are characteristic, and such areas are most fruitful if biopsied to confirm the diagnosis.

## Treatment

The use of superpotent topical corticosteroids has dramatically changed the management of anogenital LS. These are universally accepted as the treatment of choice for all forms of genital LS. Most patients will respond to once-daily application of these agents and can subsequently be tapered to less frequent applications (once or twice a week) or to lower-strength corticosteroids. Most women can achieve a symptom-free state with 30 g of clobetasol ointment used over 3 months, and they will require 60 g or less per year to maintain control of the LS. Generally, the untreated lesions are atrophic, and pulsed weekend applications of a potent topical steroid are associated with clinicohistologic reversal of the epidermal atrophy as the inflammatory process is controlled. Coexistent candidiasis may be present, or may appear with this treatment, and can be managed with topical or oral agents. Penile, vulvar, and prepubertal LS in girls have all been documented to respond to this form of treatment. Phimosis in young boys should be treated initially with potent topical steroids. The degree of symptomatic improvement far exceeds the objective improvement. The majority of patients have dramatic reduction in their itching and burning with topical clobetasol. However, the visible white, atrophic, scarred vulvar skin is often only minimally improved. In one study, 95% of compliant patients achieved complete symptom control; none had disease progression. In partially compliant patients, only 75% achieved complete symptom control, and 35% experienced progression. None of the fully compliant women developed vulvar SCC, but 5 of 45 (11%) of the partially compliant women did. This adds limited evidence to the impression that good control of LS is associated with better outcomes—symptomatically, functionally, and with respect to cancer development. Vulvar pain associated with LS may have a neuropathic component (as in vulvodinia), and treatment with tricyclic antidepressants (e.g., amitriptyline), gabapentin, and duloxetine hydrochloride may be tried.

Topical tacrolimus 0.1% and 0.03% ointments and pimecrolimus 1% cream have also been demonstrated to be effective in genital LS. However, since superpotent corticosteroids have proven so effective in genital LS, topical CNIs should be reserved for patients in whom topical corticosteroids are ineffective or not tolerated. Close clinical follow-up is

recommended because the long-term risk of applying topical CNIs to skin predisposed to malignant degeneration is not known. Topical calcipotriol may also be of benefit. Topical testosterone was no more effective than emollient and in one trial was worse than emollients as maintenance therapy. It is no longer recommended. Hydroxychloroquine, calcitriol, topical 8% progesterone cream, topical calcipotriol, topical tretinoin, cyclosporine, and hydroxyurea can be considered in refractory cases. In one patient, intralesional adalimumab cleared LS of the glans penis. UVA-I phototherapy led to moderate improvement in some patients unresponsive to topical steroids. Patients who initially failed topical steroid treatment may respond to topical corticosteroids following the UV treatment. Intralesional steroid/anesthetic injections can be helpful for persistently symptomatic areas. Surgical treatment can be effective, starting with cryotherapy, which has been reported as helpful in three quarters of patients with severe vulvar itch. Photodynamic therapy has brought significant improvement in multiple reports and can be considered in refractory cases. Extragenital LS is very difficult to treat. If superpotent topical steroids are ineffective, PUVA, UVA I, NB UVB, calcipotriol, or antimalarials may be tried. Given the appearance of LS-like lesions in chronic GVHD and the success of extracorporeal photophoresis (ECP) in cGVHD, ECP has been tried in a few severe cases of extragenital LS with success.

- Ayhan A, et al:** Topical testosterone versus clobetasol for vulvar lichen sclerosus. *Int J Gynecol Obstet* 2007; 96:117.
- Barbara E, et al:** High prevalence of concomitant anogenital lichen sclerosus and extragenital psoriasis in adult women. *Obstet Gynecol* 2008; 111:1143.
- Baskan EB, et al:** Open label trial of cyclosporine for vulvar lichen sclerosus. *J Am Acad Dermatol* 2007; 57:276.
- Beattie PE, et al:** UVA1 phototherapy for genital lichen sclerosus. *Clin Exp Dermatol* 2006; 31:343.
- Becker K, et al:** Lichen sclerosus and atopy in boys: coincidence or correlation? *Br J Dermatol* 2013; 168:362.
- Bradford J, Fischer G:** Long-term management of vulvar lichen sclerosus in adult women. *Aus N Z J Obstet Gynaecol* 2010; 50:148.
- Brouillard C, et al:** A case of cutaneous lichen sclerosus et atrophicus effectively treated by extracorporeal photochemotherapy. *Photodermatol Photoimmunol Photomed* 2013; 29:160.
- Celis S, et al:** Balanitis xerotica obliterans in children and adolescents: a literature review and clinical series. *J Pediatr Urol* 2014; 10:34.
- Chi CC, et al:** Systematic review and meta-analysis of randomized controlled trials on topical interventions of genital lichen sclerosus. *J Am Acad Dermatol* 2012; 67:305.
- Colbert R, et al:** Progressive extragenital lichen sclerosus successfully treated with narrowband UV-B phototherapy. *Arch Dermatol* 2007; 143:19.
- Cusini M:** Lichen sclerosus et atrophicus in males: how to diagnose, how to manage. *Acta Derm Venereol* 2014; 94:499.
- Dalmaj J, et al:** Psoralen UVA treatment for generalized prepubertal extragenital lichen sclerosus et atrophicus. *J Am Acad Dermatol* 2006; 55:S56.
- D'Hauwers KW, et al:** Human papillomavirus, lichen sclerosus and penile cancer: a study in Belgium. *Vaccine* 2012; 30:6573.
- Doulaveri G, et al:** Genital vulvar lichen sclerosus in monozygotic twin women: a case report and review of the literature. *Case Rep Dermatol* 2013; 5:321.
- Edmonds EV, et al:** Extracellular matrix protein 1 autoantibodies in male genital lichen sclerosus. *Br J Dermatol* 2011; 165:218.
- Edmonds EV, et al:** Clinical parameters in male genital lichen sclerosus: a case series of 329 patients. *J Eur Acad Dermatol Venereol* 2012; 26:730.
- Eisendle K, et al:** Possible role of *Borrelia burgdorferi sensu lato* infection in lichen sclerosus. *Arch Dermatol* 2008; 144:591.
- Fistarol SK, Iiin PH:** Diagnosis and treatment of lichen sclerosus: an update. *Am J Clin Dermatol* 2013; 14:27.
- Gambichler T, et al:** Differential expression of connective tissue growth factor and extracellular matrix proteins in lichen sclerosus. *J Eur Acad Dermatol Venereol* 2012; 26:207.



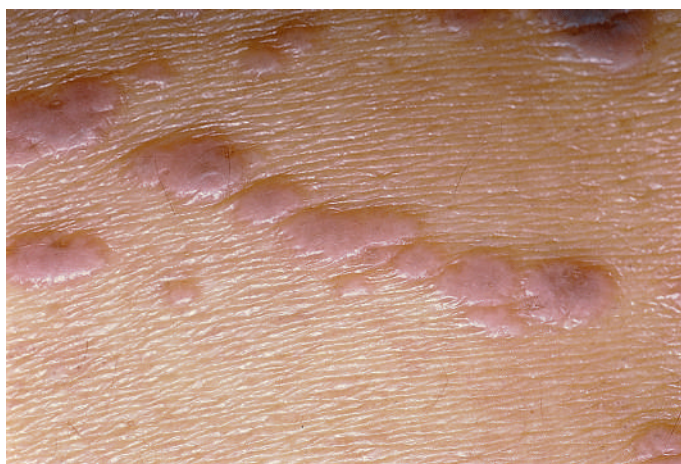
- Goldstein AT, et al:** A double-blind, randomized controlled trial of clobetasol versus pimecrolimus in patients with vulvar lichen sclerosis. *J Am Acad Dermatol* 2011; 64:e99.
- Gunther A, et al:** Early onset vulvar lichen sclerosis in premenopausal women and oral contraceptives. *Euro J Obstet Gynecol* 2008; 137:56.
- Gupta S, et al:** Treatment of genital lichen sclerosis with topical calcipotriol. *Int J STD AIDS* 2005; 16:772.
- Hernandez-Machin B, et al:** Infantile pyramidal protrusion localized at the vulva as a manifestation of lichen sclerosis et atrophicus. *J Am Acad Dermatol* 2007; 56:S49.
- Homer L, et al:** Meatal stenosis in boys following circumcision for lichen sclerosis (balanitis xerotica obliterans). *J Urol* 2014; 192:1784.
- Kim GW, et al:** Topical tacrolimus ointment for the treatment of lichen sclerosis, comparing genital and extragenital involvement. *J Dermatol* 2012; 39:145.
- Kreuter A, et al:** Low-dose ultraviolet A1 phototherapy for extragenital lichen sclerosis: results of a preliminary study. *J Am Acad Dermatol* 2002; 46:251.
- Kreuter A, et al:** Coexistence of lichen sclerosis and morphea: a retrospective analysis of 472 patients with localized scleroderma from a German tertiary referral center. *J Am Acad Dermatol* 2012; 67:1157.
- Kreuter A, et al:** Association of autoimmune diseases with lichen sclerosis in 532 male and female patients. *Acta Derm Venereol* 2013; 93:238.
- Kulkarni S, et al:** Lichen sclerosis of the male genitalia and urethra: Surgical options and results in a multicenter international experience with 215 patients. *Eur Urol* 2009; 55:945.
- Lansdorp CA, et al:** Quality of life in Dutch women with lichen sclerosis. *Br J Dermatol* 2013; 168:787.
- LeFevre C, et al:** Management of lichen sclerosis with triamcinolone ointment: effectiveness in reduction of patient symptom scores. *J Low Genit Tract Dis* 2011; 15:205.
- Lowenstein EB, Zeichner JA:** Intralesional adalimumab for the treatment of refractory balanitis xerotica obliterans. *JAMA Dermatol* 2013; 149:23.
- Lutz V, et al:** High frequency of genital lichen sclerosis in a prospective series of 76 patients with morphea: toward a better understanding of the spectrum of morphea. *Arch Dermatol* 2012; 148:24.
- Mannweiler S, et al:** Penile carcinogenesis in a low-incidence area: a clinicopathologic and molecular analysis of 115 invasive carcinomas with special emphasis on chronic inflammatory skin disease. *Am J Surg Pathol* 2011; 35:998.
- Marchs-Braun N, et al:** Acute urinary retention in an adolescent as the presenting symptom of lichen sclerosis et atrophicus. *J Pediatr Adolesc Gynecol* 2013; 26:e117.
- Maronn M, et al:** Constipation as a feature of anogenital lichen sclerosis in children. *Pediatr* 2005; 115:e230.
- Mentrikoski MJ, et al:** Histologic and immunohistochemical assessment of penile carcinomas in a North American population. *Am J Surg Pathol* 2014; 38:1340.
- Neill SM, et al:** British Association of Dermatologists' guidelines for the management of lichen sclerosis 2010. *Br J Dermatol* 2010; 163:672.
- Nelson DM, Peterson AC:** Lichen sclerosis: epidemiological distribution in an equal access health care system. *J Urol* 2011; 185:522.
- Ozalp SS, et al:** Vulval pruritus: the experience of gynaecologists revealed by biopsy. *J Obstet Gynaecol* 2014; 10:1.
- Philippou P, et al:** Genital lichen sclerosis/balanitis xerotica obliterans in men with penile carcinoma: a critical analysis. *Br J Urol* 2013; 111:970.
- Poindexter G, Morrell D:** Anogenital pruritus: lichen sclerosis in children. *Pediatr Ann* 2007; 36:785.
- Renaud Vilmer C:** Effect of long term topical application of a potent steroid on the course of the disease. *Arch Dermatol* 2004; 140:709.
- Romero A, et al:** Treatment of recalcitrant erosive vulvar lichen sclerosis with photodynamic therapy. *J Am Acad Dermatol* 2007; 57:S46.
- Schlosser BJ:** Practice gaps. Missing genital lichen sclerosis in patients with morphea: Don't ask? Don't tell? Comment on "High frequency of genital lichen sclerosis in a prospective series of 76 patients with morphea." *Arch Dermatol* 2012; 148:28.
- Simpkin S, et al:** Clinical review of 202 patients with vulval lichen sclerosis: a possible association with psoriasis. *Aus J Dermatol* 2007; 48:28.
- Stuckert M, et al:** The outcome after cryosurgery and intralesional steroid injection in vulvar lichen sclerosis corresponds to preoperative histopathological findings. *Dermatology* 2005; 210:218.
- Tausch TJ, Peterson AC:** Early aggressive treatment of lichen sclerosis may prevent disease progression. *J Urol* 2012; 187:2101.
- Thami GP, Kaur S:** Genital lichen sclerosis, squamous cell carcinoma and circumcision. *Br J Dermatol* 2003; 148:1058.
- Toberer F, Näher H:** Lichen sclerosis et atrophicus leading to joint contractures: restoring of joint mobility by extracorporeal photopheresis. *J Am Acad Dermatol* 2012; 167:e269.
- Ventolini G, et al:** Lichen sclerosis: a 5-year follow-up after topical, subdermal, or combined therapy. *J Low Genit Tract Dis* 2012; 16:271.
- Vincent MV, Mackinnon E:** The response of clinical balanitis xerotica obliterans to the application of topical steroid-based creams. *J Pediatr Surg* 2005; 40:709.
- Wehbe-Alamah H, et al:** Silent no more! The lived experiences of women with lichen sclerosis. *J Am Acad Nurs Pract* 2012; 24:499.
- West DS, et al:** Dermatopathology of the foreskin: an institutional experience of over 400 cases. *J Cutan Pathol* 2013; 40:11.
- Weyers W:** Hypertrophic lichen sclerosis sine sclerosis: clues to histopathologic diagnosis when presenting as psoriasiform lichenoid dermatitis. *J Cutan Pathol* 2014. [Epub ahead of print.]
- Zavras N, et al:** Infantile perianal pyramidal protrusion: a report of 8 new cases and a review of the literature. *Case Rep Dermatol* 2012; 4:202.



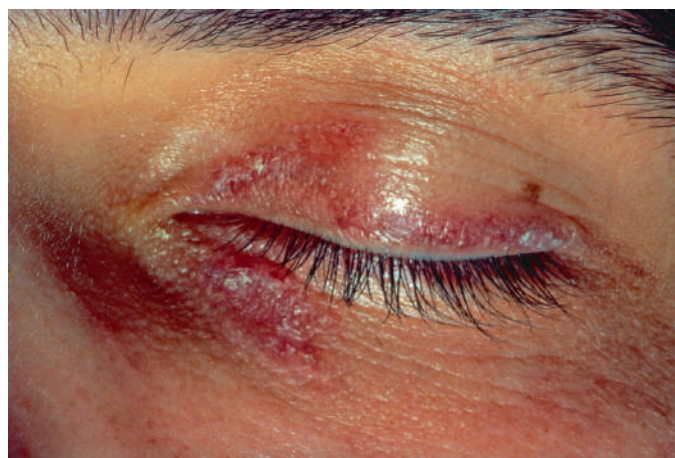
Bonus images for this chapter can be found online at

[expertconsult.inkling.com](http://expertconsult.inkling.com)

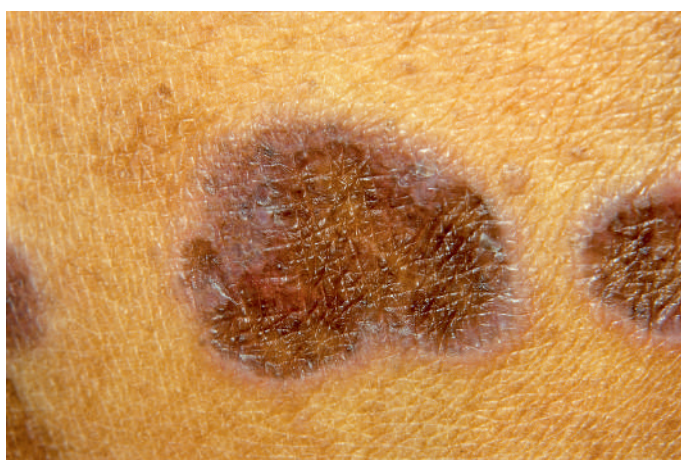
- eFig. 12-1** Lichen planus, violaceous, flat-topped papules with minimal scale.
- eFig. 12-2** Annular lichen planus.
- eFig. 12-3** Lichen planus, penile papules.
- eFig. 12-4** Lichen planus of the eyelids.
- eFig. 12-5** Lichen planus of the lips.
- eFig. 12-6** Lichen planus, hyperpigmented lesions.
- eFig. 12-7** Lichen planus, annular type.
- eFig. 12-8** Lichen planus of the sole.
- eFig. 12-9** Lichen planus of the tongue.
- eFig. 12-10** Lichen planus, nail involvement with pterygium.
- eFig. 12-11** Koebnerization of lichen planus after *Toxicodendron* dermatitis.
- eFig. 12-12** Annular lichen planus.
- eFig. 12-13** Follicular lichen planus.
- eFig. 12-14** Lichen nitidus, pinhead-sized hypopigmented papules.
- eFig. 12-15** Lichen nitidus.
- eFig. 12-16** Lichen striatus.
- eFig. 12-17** Lichen striatus, lesion following lines of Blaschko.
- eFig. 12-18** Lichen sclerosis, early lesion of the glans penis.
- eFig. 12-19** Lichen sclerosis of the vulva.
- eFig. 12-20** Lichen sclerosis and phimosis.



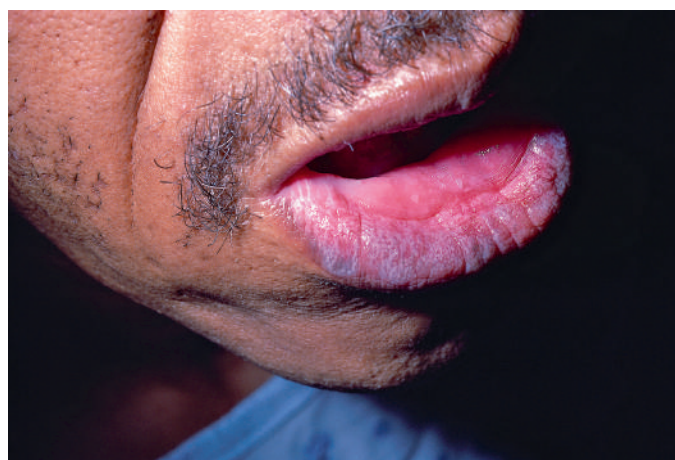**eFig. 12-1** Lichen planus, violaceous, flat-topped papules with minimal scale.



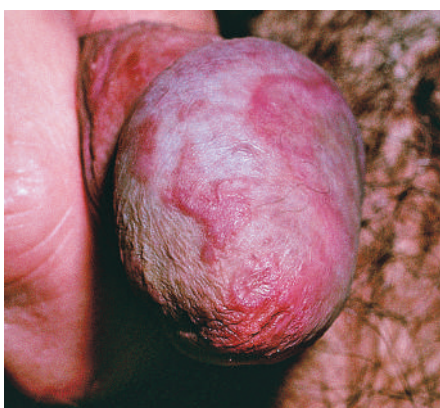**eFig. 12-4** Lichen planus of the eyelids.



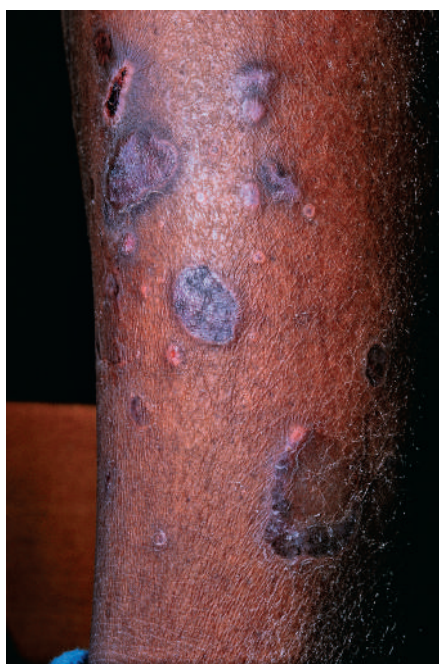**eFig. 12-2** Annular lichen planus.



**eFig. 12-5** Lichen planus of the lips.

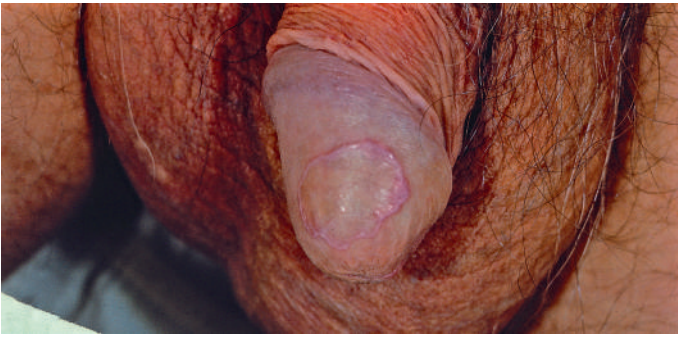

**eFig. 12-3** Lichen planus, penile papules.

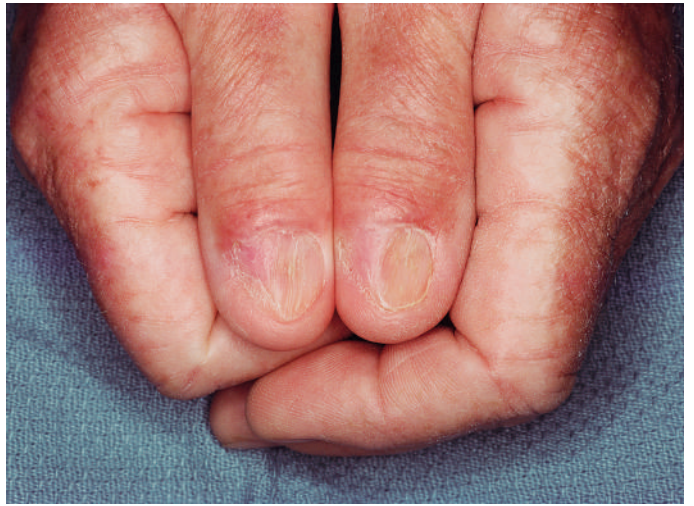

**eFig. 12-6** Lichen planus, hyperpigmented lesions.

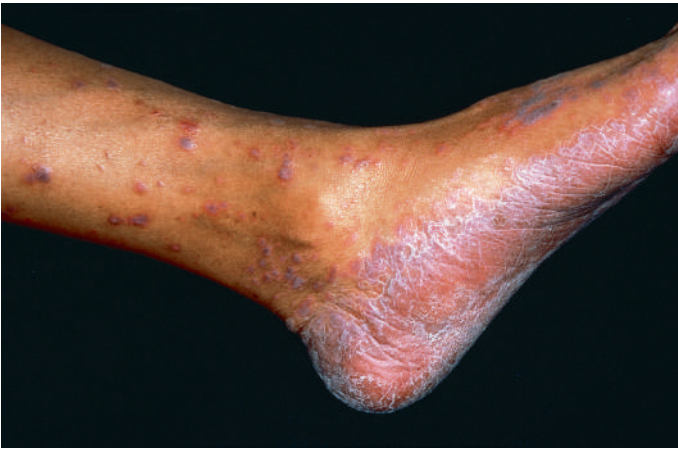



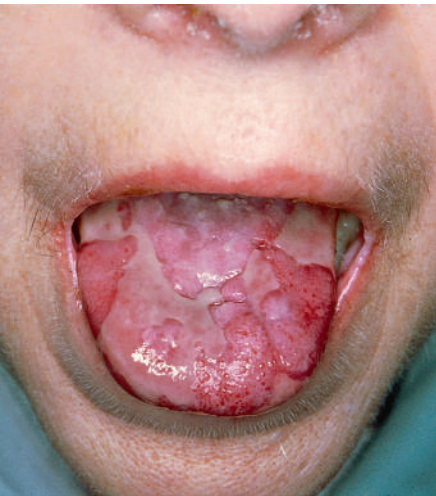**eFig. 12-7** Lichen planus, annular type.



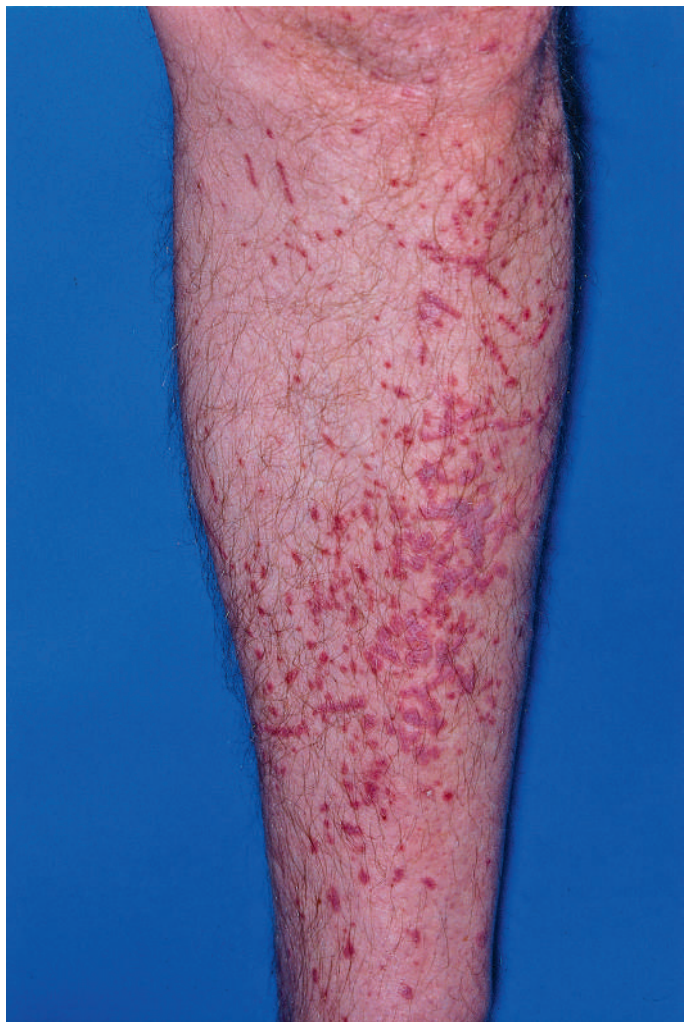**eFig. 12-10** Lichen planus, nail involvement with pterygium.



**eFig. 12-8** Lichen planus of the sole.

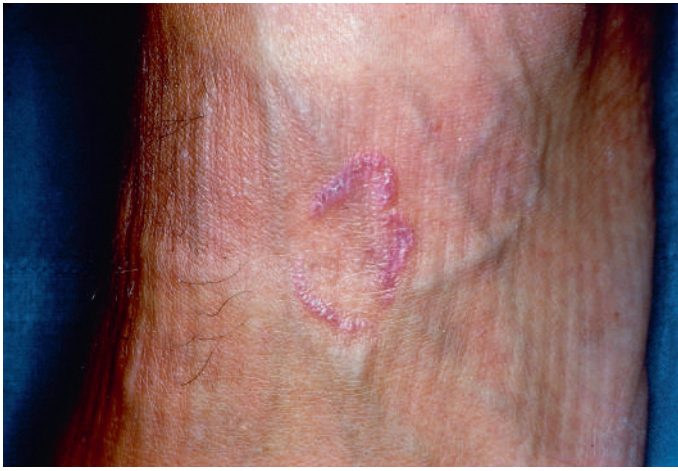

**eFig. 12-9** Lichen planus of the tongue.

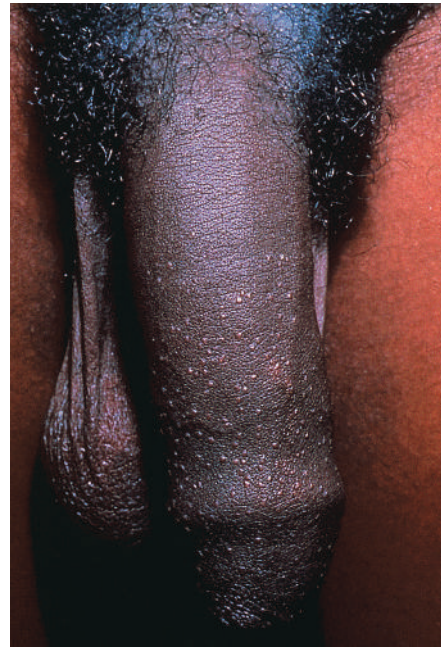

**eFig. 12-11** Kobnerization of lichen planus after *Toxicodendron* dermatitis.

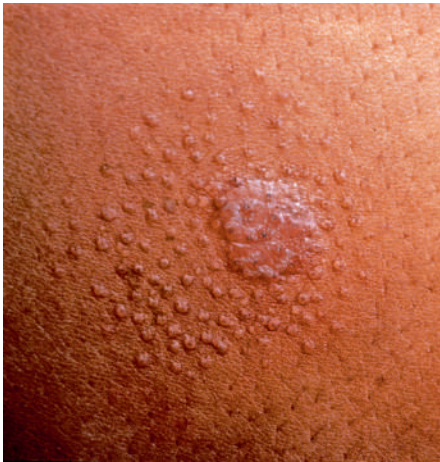



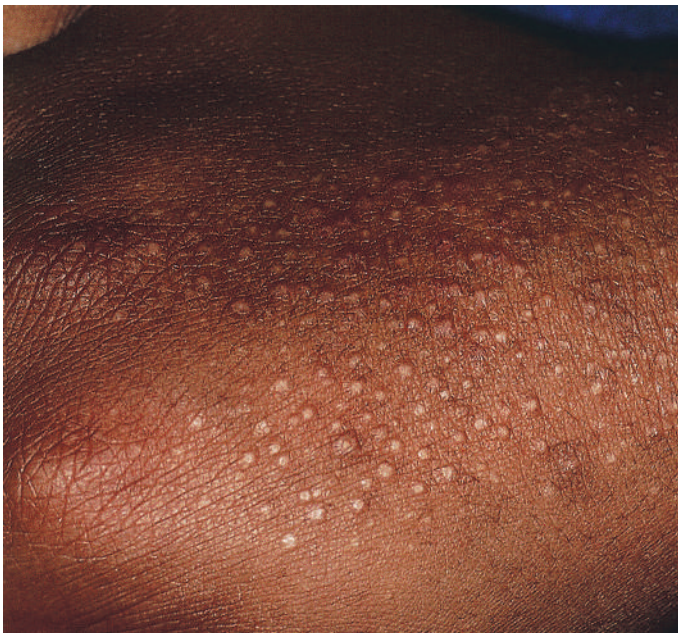**eFig. 12-12** Annular lichen planus.



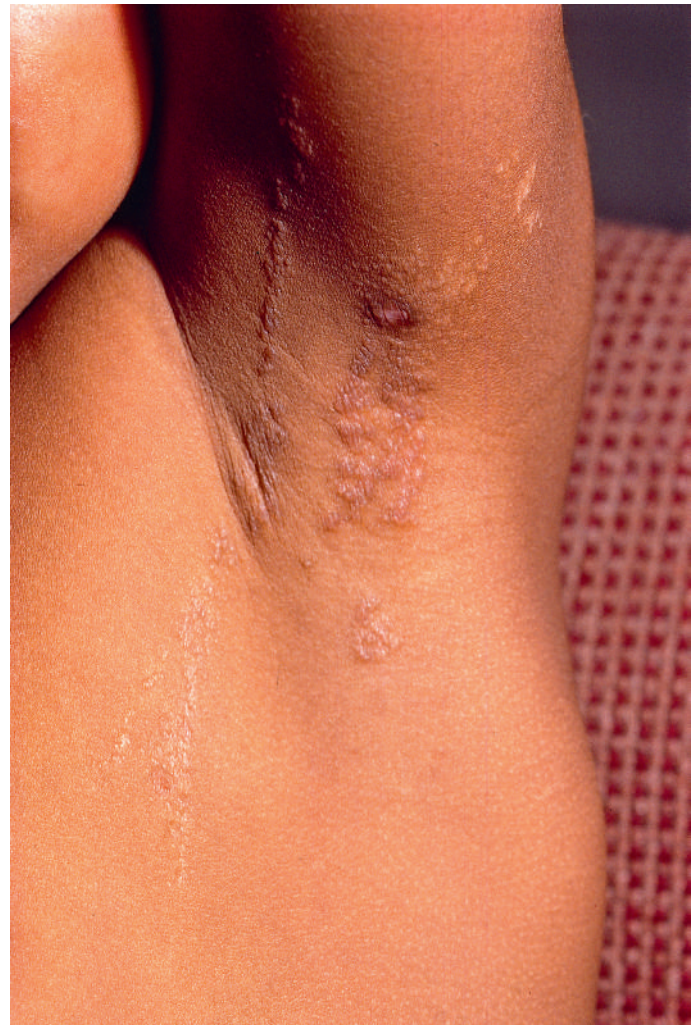**eFig. 12-15** Lichen nitidus.



**eFig. 12-13** Follicular lichen planus.

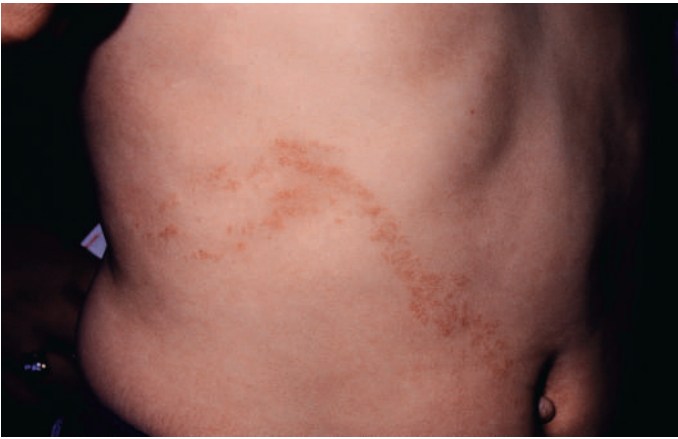

**eFig. 12-14** Lichen nitidus, pinhead-sized hypopigmented papules.

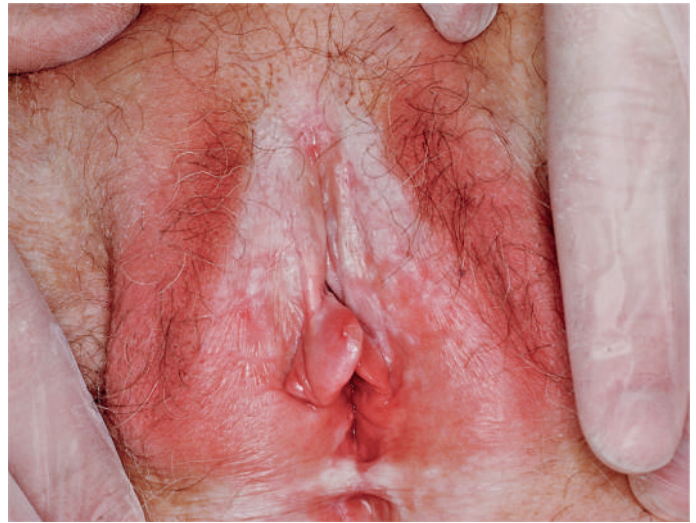

**eFig. 12-16** Lichen striatus.

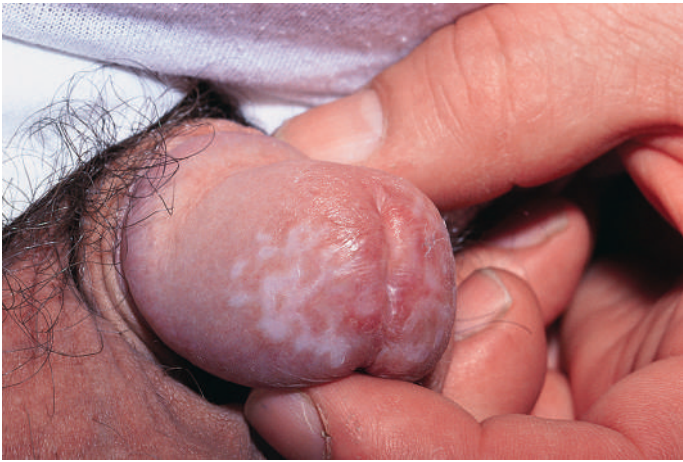



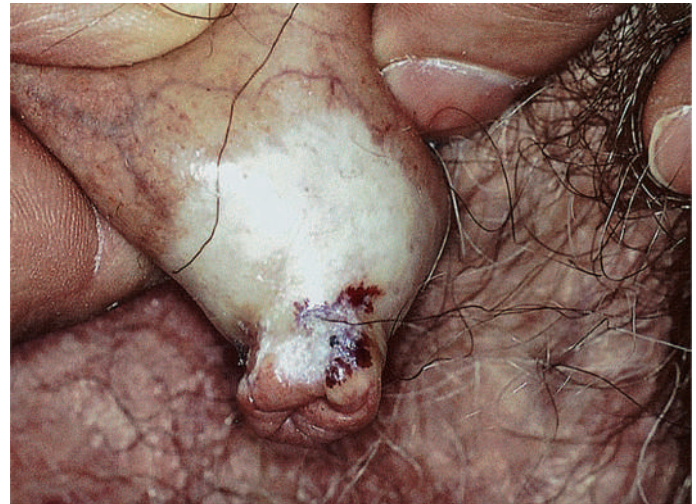
**eFig. 12-17** Lichen striatus, lesion following lines of Blaschko.



**eFig. 12-19** Lichen sclerosus of the vulva.



**eFig. 12-18** Lichen sclerosus, early lesion of the glans penis.



**eFig. 12-20** Lichen sclerosus and phimosis.

## ACNE VULGARIS

### Clinical features

Acne vulgaris is a chronic inflammatory disease of the pilosebaceous follicles, characterized by comedones, papules, pustules, nodules, and often scars. The comedo is the primary lesion of acne. It may be seen as a flat or slightly elevated papule with a dilated central opening filled with blackened keratin (open comedo or blackhead) (Fig. 13-1). Closed comedones (whiteheads) are usually 1-mm yellowish papules that may require stretching of the skin to visualize. Macrocomedones, which are uncommon, may reach 3–4 mm in size. The papules and pustules are 1–5 mm in size and are caused by inflammation, so erythema and edema occur (Fig. 13-2). They may enlarge, become more nodular, and coalesce into plaques of several centimeters that are indurated or fluctuant, contain sinus tracts, and discharge serosanguineous or yellowish pus (Fig. 13-3).

Patients typically have a variety of lesions in various states of formation and resolution. In light-skinned patients, lesions often resolve with a reddish purple macule that is short-lived. In dark-skinned individuals, macular hyperpigmentation results and may last several months (Fig. 13-4). Acne scars are heterogeneous in appearance. Morphologies include deep, narrow, ice pick scars seen most often on the temples and cheeks; canyon-type atrophic lesions on the face (Fig. 13-5); whitish yellow papular scars on the trunk and chin; anetoderma-type scars on the trunk; and hypertrophic and keloidal elevated scars on the neck and trunk.

Acne affects primarily the face, neck, upper trunk (Fig. 13-6), and upper arms. On the face, acne occurs most frequently on the cheeks and to a lesser degree on the nose, forehead, and chin. The ears may be involved, with large comedones in the concha, cysts in the lobes, and sometimes preauricular and retroauricular comedones and cysts. On the neck, especially in the nuchal area, large cystic lesions may predominate.

Acne typically begins at puberty and is often the first sign of increased sex hormone production. When acne begins at age 8–12 years, it is frequently comedonal in character, affecting primarily the forehead and cheeks. It may remain mild in its expression, with only an occasional inflammatory papule. However, as hormone levels rise into the middle teenage years, more severe inflammatory pustules and nodules occur, with spread to other sites. Young men tend to have an oilier complexion and more severe widespread disease than young women. Women may experience a flare of their papulopustular lesions about 1 week before menstruation. Acne may also begin in 20–35-year-old women who have not experienced teenage acne. This acne frequently manifests as papules, pustules, and deep, painful, persistent nodules on the jawline, chin, and upper neck.

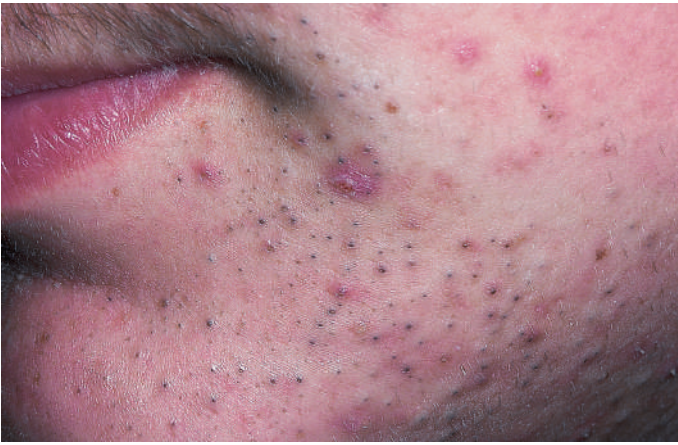Acne is primarily a disease of the adolescent, with 85% of all teenagers being affected to some degree. It occurs with greatest frequency between ages 15 and 18 in both genders. Generally, involution of the disease occurs before age 25; however, great variability in age at onset and of resolution occurs. About 12% of women and 3% of men will continue to have clinical acne until age 44. A few will have inflammatory papules and nodules into late adulthood.

Neonatal acne is a common condition that develops a few days after birth, has male preponderance, and is characterized by transient facial papules or pustules that usually clear spontaneously in a few days or weeks (Fig. 13-7). Infantile acne includes cases that persist beyond the neonatal period or that have an onset after the first 6 weeks of life. Most neonatal acne patients remit by age 1 year, although occasionally cases extend into childhood and through puberty. In prolonged cases, topical benzoyl peroxide, erythromycin, or the retinoids may be effective. With more inflammatory disease, oral erythromycin, 125 mg twice daily, or trimethoprim, 100 mg twice daily, may be added to topical medications. Oral isotretinoin has been used in the infantile period and is effective. Midchildhood acne may evolve from persistent infantile acne or begin after age 1 year. It is uncommon and has a male predominance. Grouped comedones, papules, pustules, and nodules can occur alone or in any combination, usually limited to the face (Fig. 13-8). The duration is variable, from a few weeks to several years, and occasionally extends into more severe pubertal acne. Often, there is a strong family history of moderately severe acne. A pediatric endocrinology workup is indicated for midchildhood acne and for earlier-onset patients with physical findings suggestive of a hormonal disorder, such as sexual precocity, virilization, or growth abnormality. Acne onset from age 7 to 12 is categorized as preadolescent acne. This is the time of adrenarche, and unless there are signs of androgen excess, no workup is needed.

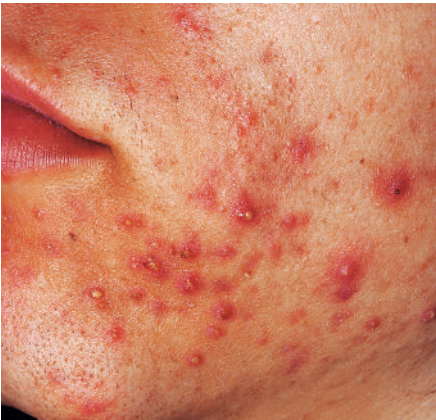### Pathogenesis

Acne vulgaris is exclusively a follicular disease, with the principal abnormality being comedo formation. It is produced by the impaction and distention of the follicles with a keratinous plug in the lower infundibulum. The keratinous plug is caused by hyperproliferation and abnormal differentiation of keratinocytes of unknown causes. Androgens, alterations in lipid composition, and an abnormal response to local cytokines are all hypothesized to be important. Androgen stimulation of the sebaceous glands is critical. Acne begins after sebum secretion increases, and women with hyperandrogenic states often manifest acne, along with hirsutism and menstrual abnormalities. Treatment directed at reducing sebaceous secretion, such as isotretinoin, estrogens, or antiandrogens, is effective in clearing acne.

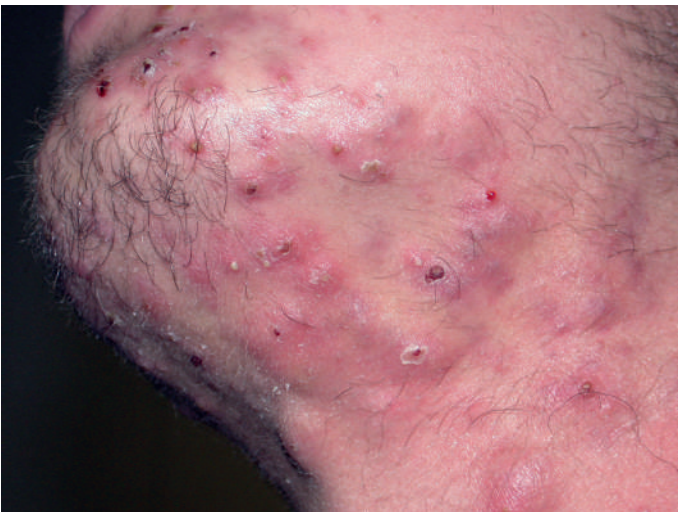



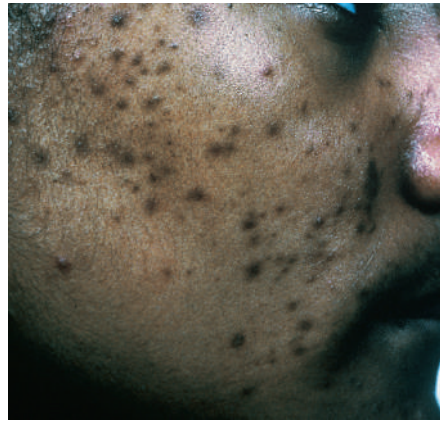**Fig. 13-1** Acne vulgaris, with comedones, on the chin.



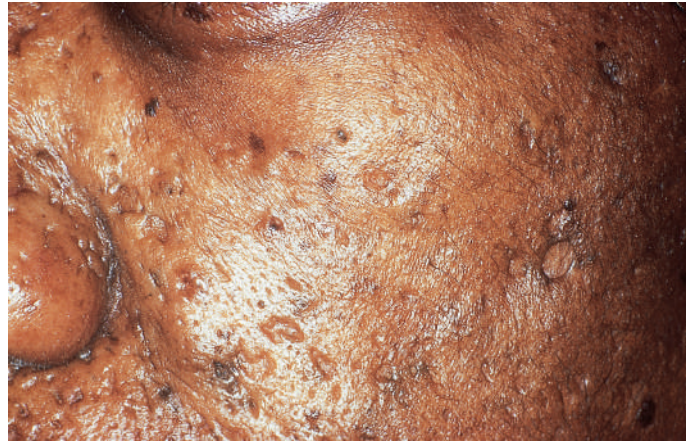
**Fig. 13-2** Acne vulgaris, with papules and pustules, on the cheek.



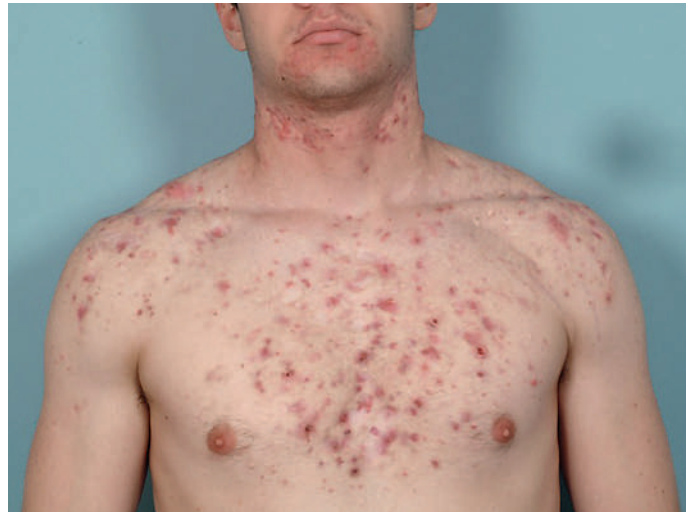**Fig. 13-3** Inflammatory acne with papules and nodules. (Courtesy of Dr. Don Adler.)



**Fig. 13-4** Postinflammatory hyperpigmentation at sites of acne lesions.



**Fig. 13-5** Acne scarring on the cheek.



**Fig. 13-6** Upper chest involvement with acne. (Courtesy of Dr. Don Adler.)

As the retained cells block the follicular opening, the lower portion of the follicle is dilated by entrapped sebum. Disruption of the follicular epithelium permits discharge of the follicular contents into the dermis. The combination of keratin, sebum, and microorganisms, particularly *Propionibacterium acnes*, leads to the release of proinflammatory mediators and the accumulation of lymphocytes, neutrophils, and foreign body giant cells. This in turn causes the formation of inflammatory papules, pustules, and nodulocystic lesions.

Additional factors may exacerbate acne or, in a predisposed patient, cause the onset of acne. Comedogenic greasy or occlusive products such as hair pomades may induce closed comedones and at times inflammatory lesions. Other types of cosmetics may initiate or worsen acne, but acne cosmetica is uncommon because most cosmetics are tested for comedogenicity.

Many types of mechanical or frictional forces can aggravate existing acne. A common problem is the overexuberant



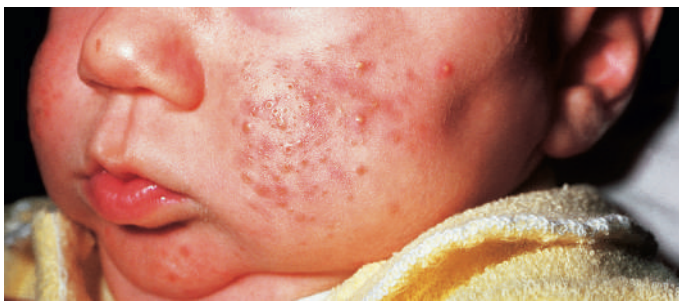

Fig. 13-7 Infantile acne.

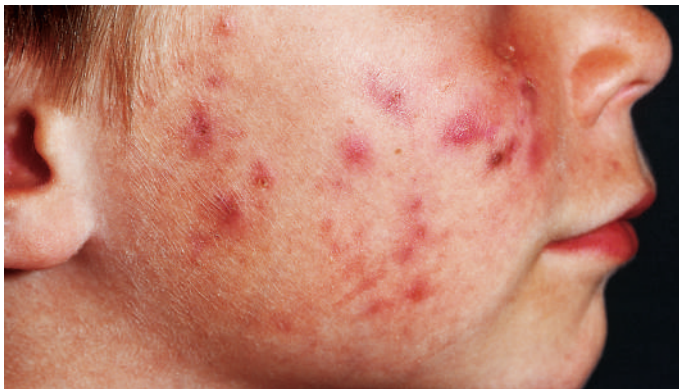

Fig. 13-8 Childhood acne.

washing some patients think may help rid them of their blackheads or oiliness. A key feature of mechanical or frictional acne is an unusual distribution of the acne lesions. Provocative factors include chin straps, violins, hats, collars, surgical tape, orthopedic casts, chairs, and seats. One acne patient who had laser hair removal developed flares of inflammatory lesions localized to the acne-prone sites after each laser session; the legs and abdomen were spared. All these factors are likely to irritate the follicular epithelium and exacerbate the changes that lead to comedogenesis and follicular rupture. Prophylactic measures designed to interdict these various mechanical forces are beneficial.

In all women or children with acne, the possibility of a hyperandrogenic state should be considered. In women, the presence of irregular menses, hirsutism, seborrhea, acanthosis nigricans, or androgenic alopecia increases the likelihood of finding clinically significant hyperandrogenism. Additionally, gynecologic endocrine evaluation may be indicated in women who have acne resistant to conventional therapy, who relapse quickly after a course of isotretinoin, or who experience sudden onset of severe acne. Screening tests to exclude a virilizing tumor include serum dehydroepiandrosterone sulfate (DHEAS) and testosterone, obtained 2 weeks before the onset of menses. DHEAS levels may be very high in adrenal tumors ( $>800 \mu\text{g}/\text{dL}$ ) or less dramatic in congenital adrenal hyperplasia ( $400\text{--}800 \mu\text{g}/\text{dL}$ ). Ovarian tumor is suggested by testosterone levels greater than  $200 \text{ng}/\text{dL}$ . Many patients with late-onset congenital adrenal hyperplasia will have normal levels of DHEAS. Although 17-hydroxyprogesterone and adrenocorticotropic hormone (ACTH) stimulation tests have been used in this setting, the baseline 17-hydroxyprogesterone may be normal in some women with adult 21-hydroxylase deficiency, and ACTH stimulation may result in overdiagnosis of the syndrome. It is not clear that screening for adult-onset 21-hydroxylase deficiency improves patient outcome. Patients with polycystic ovarian syndrome (PCOS) may have a high serum testosterone level ( $150\text{--}200 \text{ng}/\text{dL}$ ) or an increase in the luteinizing hormone/follicle-stimulating hormone (LH/FSH)

ratio ( $>2\text{--}3$ ), but American College of Obstetricians and Gynecologists (ACOG) guidelines suggest that laboratory and imaging studies are best used to exclude a virilizing tumor. The diagnosis of PCOS may be made clinically by the presence of anovulation ( $<9$  periods per year or periods  $>40$  days apart) and signs of hyperandrogenism, such as acne and hirsutism.

Acne neonatorum is explained by infantile production of androgens, which wanes at 6 to 12 months. Occasional patients have persistent acne, although acne developing after age 1 and before age 7 (with onset of adrenarche) may be a form of acne cosmetica, acne venenata, or drug-induced acne or part of an endocrinologic disorder. A workup should be initiated if acne develops between ages 1 and 7 and no obvious external factor is present. In the absence of any discovered abnormalities, the qualitative or quantitative alteration of cutaneous androgen, metabolism, and increased end-organ sensitivity could be postulated as pathogenic mechanisms for preadolescent acne.

### Pathology

Comedones reveal a thinned epithelium and a dilated follicular canal filled with lamellar lipid-impregnated keratinous material. In pustular cases, there are folliculocentric abscesses surrounded by a dense inflammatory exudate of lymphocytes and polymorphonuclear leukocytes. In addition to these findings, indolent nodular lesions frequently show plasma cells, foreign body giant cells, and proliferation of fibroblasts. Epithelial-lined sinus tracts may form.

### Treatment

#### General principles

It is important to take a complete historical record of prior therapies, including all over-the-counter (OTC) products. The dose, timing, combinations, side effects, and response to interventions should be obtained. Corticosteroids, anabolic steroids, neuroleptics, lithium, and cyclosporine may worsen acne. A family history of acne and, if present, its tendency to scarring should be noted. Women should be queried regularly about menstrual irregularities and hair growth in a male pattern, as well as use of cosmetics.

Treatment may fail because of drug interactions, coexisting conditions, or antibiotic resistance, but the most common and important cause is lack of adherence to the treatment plan. Utilizing medications that are well tolerated, have convenient dosing regimens, and are cosmetically acceptable will help. However, thorough patient education is essential: explaining how lesions form, defining the expected response to and the duration and side effects of treatment, and giving clear, unambiguous instructions. Patients should know the difference between active inflammatory lesions and the purplish red or hyperpigmented macules of inactive resolved lesions. Topical application should be to the entire affected area rather than to specific lesions, and oral and topical medications should be used daily as preventive treatment.

A high-glycemic diet may worsen acne, although the strength of its influence is unknown. The authors in general do not counsel patients to alter their diet unless large quantities of skim milk are being ingested or obesity is present. A trial lessening skim milk intake is worthwhile, with appropriate calcium and vitamin D supplementation given. In obese patients, dietary counseling is recommended, especially if PCOS, ovarian seborrhea, acne, hirsutism and androgenetic alopecia syndrome, or other syndromes known to be associated with insulin resistance and metabolic syndrome (e.g.,



**Box 13-1 Acne treatment****Mild****1. Comedonal**

- Topical retinoid ± physical extraction (first line)
- Alternate retinoid, salicylic acid, azelaic acid (second line)

**2. Papular/pustular**

- Topical antimicrobial combination + topical retinoid, benzoyl peroxide wash if mild truncal lesions (first line)
- Alternate antimicrobials + alternate topical retinoids, azelaic acid, sodium sulfacetamide–sulfur, salicylic acid (second line)

**Moderate****1. Papular/pustular**

- Oral antibiotic + topical retinoid + benzoyl peroxide (first line)
- Alternate antibiotic, alternate topical retinoid, alternate benzoyl peroxide (second line)
- In women, spironolactone + oral contraceptive + topical retinoids ± topical antibiotic and/or benzoyl peroxide
- Isotretinoin if relapses quickly off oral antibiotics, does not clear, or scars

**Severe****1. Nodular/conglobate**

- Isotretinoin
- Oral antibiotic + topical retinoid + benzoyl peroxide
- In women, spironolactone + oral contraceptive + topical retinoid ± topical or oral antibiotics and/or benzoyl peroxide

HAIR-AN syndrome) are present. For some patients who want a more “natural” approach to therapy and a change in diet, a low-glycemic diet may be recommended. Scrubbing of the face increases irritation and may worsen acne. Use of only prescribed medications and avoidance of potentially drying OTC products, such as astringents, harsh cleansers, and antibacterial soaps, should be emphasized. Noncomedogenic cosmetics are recommended, and pressed powders and oil-based products should be avoided.

**Medical therapy**

Systemic and topical retinoids, systemic and topical antimicrobials, and systemic hormonal therapy are the main therapeutic classes of treatment available. Treatment guidelines are outlined in [Box 13-1](#).

**Topical treatment**

All topical treatments are preventive, and use for 6–8 weeks is required to judge their efficacy. The entire acne-affected area is treated, not just the lesions, and long-term use is the rule. In many patients, topical therapy may be effective as maintenance therapy after initial control is achieved with a combination of oral and topical treatment.

**Topical retinoids**

It has long been appreciated that topical retinoids are especially effective in promoting normal desquamation of the follicular epithelium, reducing comedones and inhibiting the development of new lesions. Additionally, they have a marked anti-inflammatory effect, inhibiting the activity of leukocytes, the release of proinflammatory cytokines and other mediators, and the expression of transcription factors and toll-like receptors involved in immunomodulation. These agents also help

penetration of other active agents. Thus, the topical retinoids should be used in most patients with acne and are the preferred agents in maintenance therapy.

Tretinoin was the first of this group of agents to be used for acne. Popular forms of tretinoin are 0.025% and 0.05% in a cream base and the micronized gels because these are less irritating than standard gels and liquids. Its incorporation into microspheres and a polyolprepolymer also helps to limit irritation and make the product more stable in the presence of light and oxidizers. Tretinoin treatment may take 8–12 weeks before improvement occurs. When patients are tolerating the medication and are slow to respond, retinoic acid gel or solution may be used. Tretinoin should be applied at night and is in pregnancy category C.

Adapalene is a well-tolerated retinoidlike compound that has efficacy equivalent to the lower concentrations of tretinoin. Because it is light stable, adapalene may be applied in either the morning or the evening. It is in pregnancy category C.

Tazarotene is comparatively strong in its action, but also relatively irritating. It should be applied once at night or every other night, and as it is in pregnancy category X, contraceptive counseling should be provided.

Initially using retinoids every other night or adding a moisturizer with their use may lessen their irritant effects. They are also particularly useful in patients of color because retinoids may lighten postinflammatory hyperpigmentation.

**Benzoyl peroxide**

Benzoyl peroxide has a potent antibacterial effect. *Propionibacterium acnes* resistance does not develop during use. Its concomitant use during treatment with antibiotics will limit the development of resistance, even if only given for short 2- to 7-day pulses. Although benzoyl peroxide is most effective in inflammatory acne, some studies have shown it to be comedolytic as well. The wash formulations may be used for mild truncal acne when systemic therapies are not required, and these need to be in place 2 min to be effective.

Treatment is usually once or twice daily. Benzoyl peroxide may irritate the skin and produce peeling. Water-based formulations of lowest strength are least irritating and do not compromise efficacy. Application limited to once a day or every other day will also help. Allergic contact dermatitis will rarely develop, suggested by the complaint of itch rather than stinging or burning. Benzoyl peroxide is in pregnancy category C.

**Topical antibacterials**

Topical clindamycin and erythromycin are available in a number of formulations. In general, they are well tolerated and are effective in mild inflammatory acne. These topical products are in pregnancy category B. Use of these topical antibiotics alone, however, is not recommended because of increasing antibiotic resistance. As mentioned, concurrent therapy with benzoyl peroxide will limit this problem. Concomitant use with a topical retinoid will hasten the response and allow for more rapid discontinuance of the antibiotic.

Dapsone is available topically in a gel formulation. Hemolytic anemia may occur, and skin discoloration is possible when benzoyl peroxide is applied after topical dapsone. Additionally, concomitant oral use of trimethoprim-sulfamethoxazole will increase the systemic absorption of topical dapsone. Dapsone is in pregnancy category C.

**Sulfur, sodium sulfacetamide, resorcin, and salicylic acid**

Although benzoyl peroxide, retinoids, and topical antibiotics have largely supplanted these older medications, sulfur, resorcin, and salicylic acid preparations are still useful and moderately helpful if the newer medications are not tolerated. They

are frequently found in OTC preparations. Sulfacetamide-sulfur combination products are mildly effective in both acne and rosacea, but should be avoided in patients with known hypersensitivity to sulfonamides.

### Azelaic acid

This dicarboxylic acid is usually well tolerated and has mild efficacy in both inflammatory and comedonal acne. Azelaic acid may help to lighten postinflammatory hyperpigmentation and is in pregnancy category B.

### Combination topical therapy

Several products are available that combine antibiotics such as clindamycin and benzoyl peroxide or combine retinoids and either antibiotics or benzoyl peroxide. In general, these medications increase adherence because they require less frequent application, and they may also limit irritation compared with the cumulative topical application of each product separately. However, combination topical therapy limits flexibility and may cause more irritation than a single product used alone.

### Oral antibiotics

Oral antibiotics are indicated for moderate to severe acne; in patients with inflammatory disease who do not tolerate or respond to topical combinations; for the treatment of chest, back, or shoulder acne; and in patients for whom absolute control is deemed essential, such as those who scar with each lesion or who develop inflammatory hyperpigmentation. It generally takes 6–8 weeks to judge efficacy. Starting at a high dose and reducing it after achieving control is preferred. Working to maintain control eventually with topical retinoids or retinoid–benzoyl peroxide combination therapy is ideal; however, keeping patients free of disease for 1–2 months before each decrease in dosage is best to prevent flaring. Most courses of oral therapy are of at least 3–6 months' duration.

There is concern that oral antibiotics may reduce the effectiveness of oral contraceptives (OCs). It is appropriate for this as-yet unproved (except with rifampin, which is not used for acne) association to be discussed with patients and a second form of birth control offered.

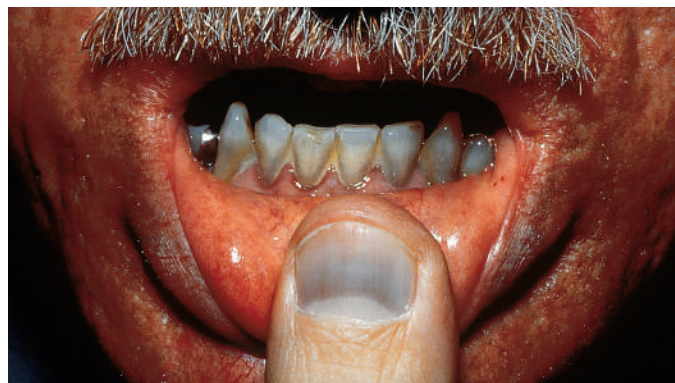### Tetracycline derivatives

Tetracycline's availability and utility are limited.

**Doxycycline.** The usual dose of doxycycline is 50–100 mg once or twice a day, depending on the disease severity. Photosensitivity reactions can occur with this form of tetracycline and can be dramatic. Vaginitis or perianal itching may result from tetracycline and its derivatives (e.g., doxycycline) and occurs in about 5% of patients, with *Candida albicans* usually present in the involved site. The only other common side effects are gastrointestinal (GI) symptoms such as nausea. To reduce the incidence of esophagitis, tetracyclines should not be taken at bedtime. An enteric-coated formulation is available and limits the GI side effects. Staining of growing teeth occurs, precluding use of tetracyclines in pregnant women and in children under age 9 or 10. The tetracyclines should also be avoided when renal function is impaired.

Subantimicrobial-dose doxycycline (doxycycline hyclate, 20 mg) may be given twice daily. The advantage of this is that the anti-inflammatory activity is being utilized, but no antibiotic resistance results because of the low dose. A sustained-release 40-mg formulation is also available. However, these low-dose preparations appear to be of low efficacy.

**Minocycline.** Minocycline is effective in treating acne vulgaris. In patients whose *P. acnes* infection develops tetracycline resistance, minocycline is an alternative. The usual dose is 50–100 mg once or twice daily, depending on the severity of disease. Its absorption is less affected by milk and food than



**Fig. 13-9** Minocycline-induced blue pigmentation of the teeth and nails.

is tetracycline. Vertigo may occur, and beginning minocycline therapy with a single dose in the evening may be prudent. An extended-release preparation is also available, which limits the vestibular side effects. Pigmentation in areas of inflammation, of oral tissues, in postacne osteoma or scars, in a photodistributed pattern, on the shins, or in the sclera, nail bed, ear cartilage, or teeth or in a generalized pattern may also be seen (Fig. 13-9). Additionally, lupuslike syndromes, a hypersensitivity syndrome (fever, hepatitis, and eosinophilia), serum sickness, pneumonitis, and hepatitis are uncommon but potentially serious adverse effects of minocycline.

### Amoxicillin

For those who cannot take tetracyclines because of side effects, or in pregnant women requiring oral antibiotic therapy, amoxicillin may be useful. Amoxicillin and the much less effective erythromycin are in pregnancy category B. Amoxicillin can be given in doses ranging from 250 mg daily to 500 mg three times daily. Side effects are allergic reactions, which may be serious, and GI upset. Many patients of acne age have taken amoxicillin in the past and are aware of their ability to tolerate the medicine without allergic reactions.

### Clindamycin

Past experience has shown that clindamycin provides an excellent response in the treatment of acne. However, the potential for the development of pseudomembranous colitis and the availability of isotretinoin have limited its use. The initial dose of clindamycin is 150 mg three times daily, reduced gradually as control is achieved.

### Other antibiotics

Sulfonamides may be effective in many cases unresponsive to other antibiotics; however, the potential for severe drug eruptions limits their use by dermatologists. Trimethoprim-sulfamethoxazole (TMP-SMX; Bactrim, Septra), in double-strength dose twice daily, is recommended initially when given to moderately to severely affected patients who have failed other oral medication. Trimethoprim alone, 300 mg twice daily, is also useful. Oral dapsone has been used in severe acne conglobata but is rarely used today. Isotretinoin is favored.

### Bacterial resistance

*Propionibacterium acnes* antimicrobial resistance has been a clinically relevant problem. However, with the limited use of erythromycin, clindamycin, and tetracycline, this consideration is less problematic. Doxycycline resistance may occur, and minocycline is a suitable alternative if this problem is suspected. Although concomitant use of benzoyl peroxide will



help limit cutaneous drug resistance problems, it is now appreciated that *Staphylococcus aureus* in the nares, streptococci in the oral cavity, and enterobacteria in the gut may also become resistant. Also, close contacts, including treating dermatologists, may harbor such drug-resistant bacteria. Strategies to prevent antibiotic resistance include limiting the duration of treatment, stressing the importance of adherence to the treatment plan, restricting the use of antibiotics to inflammatory acne, encouraging repeat treatment with the same antibiotic unless it has lost its efficacy, avoiding the use of dissimilar oral and topical antibiotics at the same time, and using isotretinoin if unable to maintain clearance without oral antibacterial therapy.

### Hormonal therapy

Hormonal interventions in women may be beneficial even in the absence of abnormal laboratory tests. The workup for the woman with signs of hyperandrogenism, such as acne, menstrual irregularities, hirsutism, or androgenic alopecia, is presented earlier. Women with normal laboratory values often respond to hormonal therapy. Results take longer to be seen with these agents, with first evidence of improvement often not apparent for 3 months and continued improved response seen for at least 6 months. Good candidates for hormonal treatment include women with PCOS, late-onset adrenal hyperplasia, or another identifiable endocrinologic condition and women with late-onset acne, severe acne, acne unresponsive to other oral and topical therapies, or acne that has relapsed quickly after isotretinoin treatment. Women with acne primarily located on the lower face and neck and with deep-seated nodules that are painful and long-lasting are often quite responsive to hormonal intervention, which may be considered a first-line therapy in some women (Fig. 13-10).

### Oral contraceptives

The OCs block both adrenal and ovarian androgens. Ortho Tri-Cyclen, Estrostep, Alesse, Yasmin, and Yaz are examples of OCs that have beneficial effects on acne. The progestins that these contain have either low androgenic activity or antiandrogenic activity. Both the physician and the patient should be familiar with the adverse reactions associated with OCs, such as nausea, vomiting, abnormal menses, melasma, weight gain, breast tenderness, and rarely thrombophlebitis, pulmonary embolism, and hypertension.

### Spironolactone

Antiandrogen treatment during pregnancy will result in feminization of a male fetus, and thus spironolactone is usually prescribed in combination with OCs. It may be effective in doses from 25–200 mg/day. Most women will tolerate a starting dose of 100 mg at night. Most also tolerate 150 mg/day (50 in the AM, 100 at night), but many will have side effects at

200 mg/day (100 twice daily). Side effects include breast tenderness, headache, dizziness, lightheadedness, fatigue, irregular menstrual periods, and diuresis; the non-central nervous system (CNS) effects are dose dependent. In a study of 85 women treated with spironolactone at 50–100 mg/day, hyperkalemia was measurable, but in the absence of renal or cardiac disease, was clinically insignificant. One third of patients cleared, one third had marked improvement, one quarter showed partial improvement, and 7% had no response. In the author's experience, clearance or marked improvement may be expected in a high percentage of women if doses up to 200 mg/day are given. Spironolactone may be combined with other topical or oral acne therapy. Several months of treatment are usually required to see benefit.

### Dexamethasone

Dexamethasone, 0.125–0.5 mg given once at night, reduces androgen excess and may alleviate cystic acne. Corticosteroids are effective in the treatment of adult-onset adrenal hyperplasia, but antiandrogens are often used in this setting.

### Prednisone

Although corticosteroids may produce steroid acne, they are also effective anti-inflammatory agents in severe and intractable acne vulgaris. In severe cystic acne and acne conglobata, corticosteroid treatment is effective; however, side effects restrict its use. Prednisone is generally only given to patients with severe inflammatory acne during the first 1 or 2 months of treatment with isotretinoin, for initial reduction of inflammation, and to reduce isotretinoin-induced flares.

### Other hormonal agents

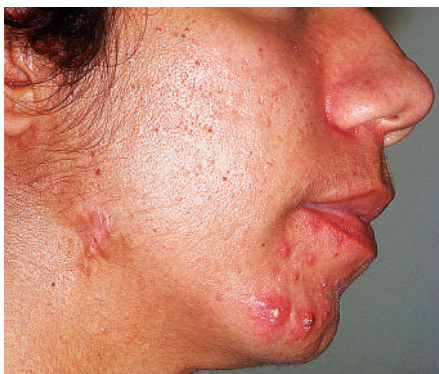Finasteride, flutamide, estrogen, gonadotropin-releasing agonists, and metformin (by decreasing testosterone levels) have all showed a beneficial effect on acne. Because of side effects, expense, and other considerations, however, these agents are not typically used.

### Oral retinoid therapy

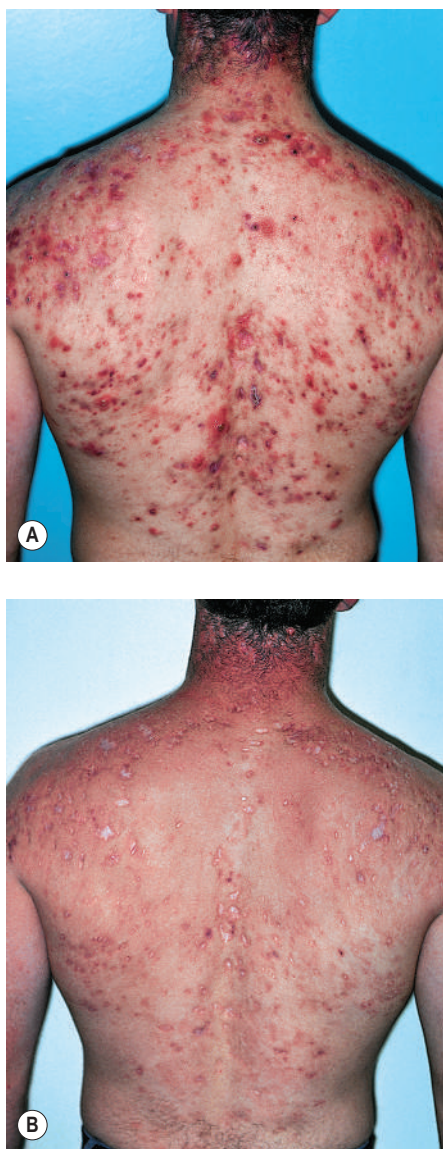#### Isotretinoin

Isotretinoin is approved only for severe cystic acne. However, it is useful in less severe forms of acne to prevent the need for continuous treatment and the repeated office visits often required. A consensus of experts found that oral isotretinoin is warranted for severe acne, poorly responsive acne that improves by less than 50% after 6 months of therapy with combined oral and topical antibiotics, acne that relapses after oral treatment, scars, and acne that induces psychological distress. Other indications are gram-negative folliculitis, inflammatory rosacea, pyoderma faciale, acne fulminans, and acne conglobata.

This retinoid is a reliable remedy in almost all acne patients (Fig. 13-11). The dose of isotretinoin is 0.5–1 mg/kg/day in one or two daily doses. For severe truncal acne in patients who tolerate higher doses, up to 2 mg/kg/day may be given. In practice, most patients are started at 20–40 mg to avoid an early flare, then increased to 40–80 mg/day to limit side effects, which generally are dose related. Doses as low as 0.1 mg/kg/day are almost as effective as the higher doses in clearing acne; the disadvantage is that lower doses are less likely to produce a prolonged remission, even after 20 weeks of treatment. To achieve potentially prolonged remission, patients should receive 120–150 mg/kg over the treatment course. An easy way to calculate the total isotretinoin dose needed is to multiply the patient's weight in kilograms by 3. The product is the total number of 40-mg capsules needed to reach the low end of the dosage spectrum. Two groups recently



**Fig. 13-10** Jawline lesions in adult woman.



**Fig. 13-11** A, Severe back acne before isotretinoin. B, Response to treatment.

reported treating patients with 1.5–2 mg/kg for a total dose of approximately 300 mg/kg. These patients had a lower relapse rate, although side effects may limit tolerance of such dosages.

The major advantage of isotretinoin is that it is the only acne therapy that is not open ended (i.e., leads to a remission that may last many months or years). Approximately 40–60% of patients remain acne free after a single course of isotretinoin. Approximately one third of the relapsing patients will need only topical therapy, with the others requiring oral treatments. Many patients in the latter category prefer to be re-treated with isotretinoin because of its reliable efficacy and predictable side effects, which will be similar to those experienced in the first course. Many treated patients will require at least a second course of isotretinoin in 2 years.

Some subsets of patients tend to relapse more often. In patients under age 16 years, 40% need a second course of isotretinoin within 1 year and 73% within 2 years. Adult women and patients with mild acne tend to relapse more often and more quickly than severely affected 17–22-year-olds. Although patients' tolerance and response to repeated courses are similar to their experience with the first course, adult women who relapse may be better managed with hormonal therapies and mild acne treated with standard therapy.

In adult acne patients, who frequently tolerate the side effects of isotretinoin less well, lower doses and intermittent

therapy are possible. In 80 adult acne patients treated with 0.5 mg/kg/day for 1 week in every 4 weeks over 6 months, acne resolved in 88%, and 39% relapsed after 1 year. In nine patients age 56–75 treated with 0.25 mg/kg/day for 6 months, all cleared and all except one remained clear 36 months later.

Patient education is critical in isotretinoin therapy. Its most serious adverse effect is the risk of severe damage to the fetus if given during pregnancy. Retinoid embryopathy is a well-defined syndrome characterized by craniofacial, cardiovascular, CNS, and thymus abnormalities. It is crucial that a woman of childbearing potential follow closely the manufacturer's recommendations. The use of consent forms, contraception education, and unequivocal documentation of the absence of pregnancy through monthly laboratory testing are important components of a U.S. Food and Drug Administration (FDA)-mandated verification program designed to prevent pregnancy during treatment. Women should not become pregnant until stopping medication for at least 1 month. Isotretinoin is not mutagenic, and there is no risk to a fetus while the male partner is taking the drug.

A second major area of educational emphasis concerns the psychological effects of the medication. Reports of depression, psychosis, suicidal ideation, suicide, and attempted suicide have prompted numerous studies of the mental health of patients taking isotretinoin. Although the usual outcome is improved mood because the disease clears, and only a fraction of the many large-scale population-based studies has found evidence of an elevated incidence of depression, a small number of patients have developed depression and have positive dechallenge and rechallenge tests. Close monitoring for depression, fully educating the patient, and enlisting the help of a roommate or family member to look for changes in mood are methods used to assess the psychological status of the patient taking isotretinoin.

Inflammatory bowel disease (IBD) is a third concern. Patients with IBD have been successfully treated with isotretinoin without flaring, but new-onset IBD in patients exposed to isotretinoin is a concern. The age of onset of IBD overlaps with the age when acne will frequently be treated with isotretinoin and antibiotics. A meta-analysis of five studies concluded that there was no increased risk of IBD or the subtypes. In the highest-risk study, one extra case of IBD would be predicted if more than 5000 patients were treated. Long-term use of tetracycline medications and severe acne itself may be predisposing factors for IBD. Patients should be educated about this potential problem and monitored appropriately.

Other side effects of isotretinoin are dose dependent and generally not serious. Dry lips, skin, eyes, and oronasal mucosa occur in up to 90% of patients. These effects can be treated with moisturization. Dryness of the nasal mucosa leads to colonization by *S. aureus* in 80–90% of treated patients. Skin abscesses, staphylococcal conjunctivitis, impetigo, facial cellulitis, and folliculitis may result. Such colonization can be avoided by the use of bacitracin ointment applied to the anterior nares twice daily during isotretinoin therapy. Arthralgias may occur but, as with other side effects, do not require interruption of therapy unless severe. Monitoring of serum lipids is done because some patients will develop hypertriglyceridemia. This may be controlled by avoiding smoking and alcohol and following a low-fat diet. It should be emphasized that patients who develop this complication, as well as their family, are at risk for the development of the metabolic syndrome.

Liver function tests should be checked at regular intervals, depending on patient risk factors and the dose used. Isotretinoin should be taken with a high-fat meal to ensure excellent absorption. A new formulation not requiring this type of meal is available.



## Tumor necrosis factor inhibitors

Adalimumab, etanercept, and infliximab have been reported in individual patients to improve or clear severe resistant acne. Some cases have been part of an inflammatory syndrome (e.g., SAPHO, PAPA, PASS) or found in patients with IBD. Paradoxically, acne has also been reported as an adverse reaction to these medications.

## Intralesional corticosteroids

Intralesional corticosteroids are especially effective in reducing inflammatory nodules. Triamcinolone acetonide at 10 mg/mL (Kenalog-10) is best diluted with sterile normal saline solution to 2.5 mg/mL. Injecting less than 0.1 mL directly into the center of the nodule will help safeguard against atrophy and hypopigmentation.

## Physical modalities

Local surgical treatment is helpful in quickly resolving the comedones, although many clinicians wait until after 2 or more months of topical retinoid therapy to extract the remaining comedones. The edge of the follicle is nicked with a No. 11 scalpel blade, and the contents are expressed with a comedo extractor. Scarring is not produced by this procedure. Light electrode desiccation is an alternative. In isotretinoin-treated patients, macrocomedones present at weeks 10–15 may be expressed, since they tend to persist throughout therapy.

The use of photodynamic therapy and various forms of light, laser, or radiofrequency energy is under investigation. Such interventions clearly are capable of destroying sebaceous glands and killing *P. acnes*, but the methods to deliver such treatment in an efficient, cost-effective, safe, relatively pain free, and practical manner are still evolving. These treatments will be a welcome addition with the potential to provide care without the concerns associated with systemic drugs. More studies of larger patient populations with appropriate controls are needed to evaluate the role of light and related energy in the spectrum of acne therapy.

## Complications

Even with the excellent treatment options available, scarring may occur. This may be quite prominent and often results from the cystic type of acne, although smaller lesions may produce scarring in some individuals. Pitted scars, wide-mouthed depressions, and keloids, primarily seen along the jawline and chest, are common types of scarring (Fig. 13-12).

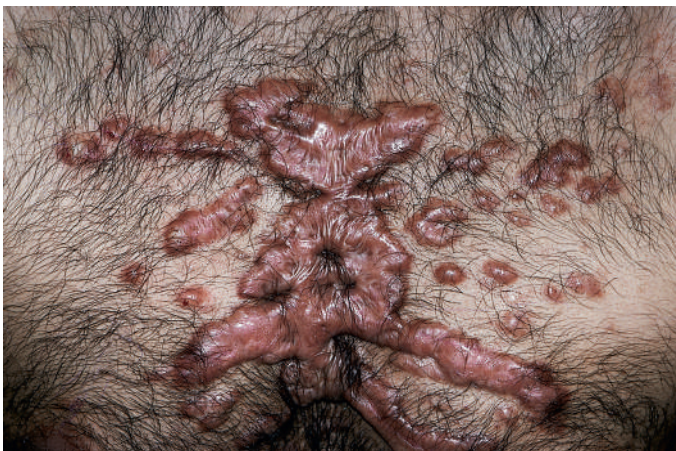

Fig. 13-12 Keloid of the chest secondary to acne.

These may improve spontaneously over 1 year or longer. Many treatment options are available. Procedures reported to be effective in improving appearance include chemical peeling; ablative, nonablative, and vascular laser therapy; skin needling or rolling; dermabrasion; scar excision; subcision; punch grafts alone or followed by dermabrasion or laser smoothing; intralesional corticosteroids or fluorouracil; fractionated laser resurfacing; fat transfer; and use of filler substances.

Other complications from acne are prominent residual hyperpigmentation, especially in darker-skinned patients; pyogenic granuloma formation, which is more common in acne fulminans and in patients treated with high-dose isotretinoin; osteoma cutis, which consists of small, firm papules resulting from long-standing acne vulgaris; and solid facial edema. The latter is a persistent, firm facial swelling that is an uncommon but distressing result of acne vulgaris or acne rosacea. Both corticosteroids and isotretinoin have been reported to be effective treatments.

- Arora MK, et al:** Role of hormones in acne vulgaris. *Clin Biochem* 2011; 44:m1035–m1040.
- Arowojolu AO, et al:** Combined oral contraceptive pills for treatment of acne. *Cochrane Database Syst Rev* 2007; 1:CD004425.
- Arrington EA, et al:** Combined oral contraceptives for the treatment of acne. *Cutis* 2012; 90:83–90.
- Azoulay L, et al:** Isotretinoin therapy and the incidence of acne relapse. *Br J Dermatol* 2007; 157:1240.
- Berard A, et al:** Isotretinoin, pregnancies, abortions and birth defects. *Br J Clin Pharmacol* 2007; 63:196.
- Blasiak RC, et al:** High-dose isotretinoin treatment and the rate of retreatment, relapse, and adverse effects in patients with acne vulgaris. *JAMA Dermatol* 2013; 149:1392–1398.
- Bowe WP, et al:** Diet and acne. *J Am Acad Dermatol* 2010; 63:124.
- Brown RJ, et al:** Minocycline-induced drug hypersensitivity syndrome followed by multiple autoimmune sequelae. *Arch Dermatol* 2009; 145:63.
- Bruzzese V:** Pyoderma gangrenosum, acne conglobata, suppurative hidradenitis, and axial spondyloarthritis. *J Clin Rheumatol* 2012; 18:413–415.
- Chen W, et al:** Acne-associated syndromes. *J Eur Acad Dermatol Venereol* 2011; 25:637–646.
- Costello M, et al:** Insulin-sensitising drugs versus the combined oral contraceptive pill for hirsutism, acne and risk of diabetes, cardiovascular disease, and endometrial cancer in polycystic ovary syndrome. *Cochrane Database Syst Rev* 2007; 1:CD005552.
- Cyrułnik AA, et al:** High-dose isotretinoin in acne vulgaris. *Int J Dermatol* 2012; 51:1123–1130.
- Dalamaga M, et al:** Ovarian SAHA syndrome is associated with a more insulin-resistant profile and represents an independent risk factor for glucose abnormalities in women with polycystic ovary syndrome. *J Am Acad Dermatol* 2013; 69:922–930.
- Dreno B, et al:** Large-scale international study enhances understanding of an emerging acne population. *J Eur Acad Dermatol Venereol* 2014; Oct 8.
- Eichenfield LF, et al:** Evidence-based recommendations for the diagnosis and treatment of pediatric acne. *Pediatrics* 2013; 131:mS163.
- Frangos JE, et al:** Acne and oral contraceptives. *J Am Acad Dermatol* 2008; 58:781.
- Gamble R, et al:** Topical antimicrobial treatment of acne vulgaris. *Am J Clin Dermatol* 2012; 13:141–152.
- Garner SE, et al:** Minocycline for acne vulgaris. *Cochrane Database Syst Rev* 2012; 8:CD002086.
- Goodman GJ, et al:** The management of postacne scarring. *Dermatol Surg* 2007; 33:1175.
- Hahn BJ, et al:** Changes of psychiatric parameters and their relationships by oral isotretinoin in acne patients. *J Dermatol* 2009; 36:255.
- Hu S, et al:** Fractional resurfacing for the treatment of atopic facial acne scars in Asian skin. *Dermatol Surg* 2009; 35:826.
- Ismail NH, et al:** High glycemic load diet, milk, and ice cream consumption are related to acne vulgaris in Malaysian young adults. *BMC Dermatol* 2012; 12:13.
- Jacobs A, et al:** Systemic review of the rapidity of the onset of action of topical treatments in the therapy of mild-to-moderate acne vulgaris. *Br J Dermatol* 2014; 170:557.

- James WD:** Clinical practice: acne. *N Engl J Med* 2005; 352:1463.
- Kwon HH, et al:** Clinical and histological effect of a low glycaemic load diet in treatment of acne vulgaris in Korean patients. *Acta Derm Venereol* 2012; 92:241–246.
- Lee AT, et al:** Dermatologic manifestations of polycystic ovary syndrome. *Am J Clin Dermatol* 2007; 8:201.
- Leyden JJ, et al:** The use of isotretinoin in the treatment of acne vulgaris. *J Clin Aesthet Dermatol* 2014; 7:S3–S21.
- Manolache L, et al:** A case of solid facial oedema successfully treated with isotretinoin. *J Eur Acad Dermatol Venereol* 2009; 23:965.
- Margolis D, et al:** Potential association between the oral tetracycline class of antimicrobials used to treat acne and inflammatory bowel disease. *Am J Gastroenterol* 2010; 105:2610–2616.
- Mays RM, et al:** New antibiotic therapies for acne and rosacea. *Dermatol Ther* 2012; 25:23–37.
- Morrone A, et al:** Clinical features of acne vulgaris in 444 patients with ethnic skin. *J Dermatol* 2011; 38:405–408.
- Nast A, et al:** European evidence-based guidelines for the treatment of acne. *J Eur Acad Dermatol Venereol* 2012; 26:S1–S29.
- Perkins AC, et al:** Acne vulgaris in women. *J Womens Health (Larchmt)* 2012; 21:223–230.
- Rowe C, et al:** Isotretinoin and mental health in adolescents. *Australas J Dermatol* 2014; 55:162–167.
- Sakamoto FH, et al:** Photodynamic therapy for acne vulgaris. *J Am Acad Dermatol* 2010; 63:183–193, 195–211.
- Sand FL, et al:** Adalimumab for the treatment of refractory acne conglobata. *JAMA Dermatol* 2013; 149:1306–1307.
- Strahan JE, et al:** Cyclosporine-induced infantile nodulocystic acne. *Arch Dermatol* 2009; 145:797.
- Strauss JS, et al:** Guidelines of care for acne vulgaris management. *J Am Acad Dermatol* 2007; 56:651.
- Taub AF:** Procedural treatments for acne vulgaris. *Dermatol Surg* 2007; 33:1005.

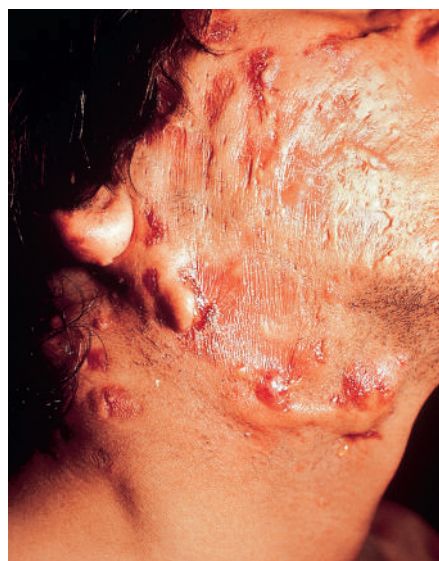## ACNE CONGLOBATA

Cystic acne is the mildest form of acne conglobata (conglobate means shaped in a rounded mass), an unusually severe type of acne. This form is characterized by numerous comedones (many of which are double or triple) and large abscesses with interconnecting sinuses, cysts, and grouped inflammatory nodules (Fig. 13-13). Suppuration is characteristic of acne conglobata. Pronounced scars remain after healing.

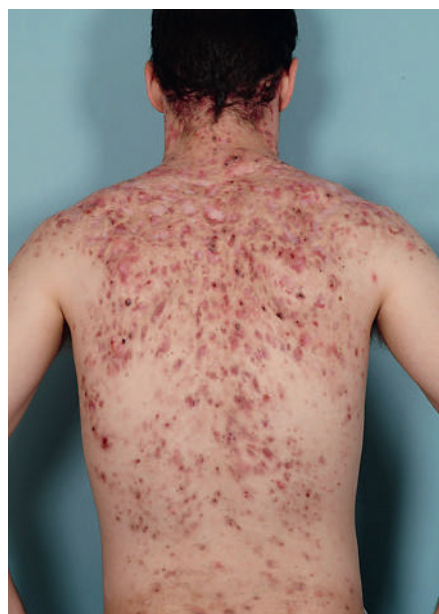The cysts occur on the back, buttocks, chest, forehead, cheeks, anterior neck, and shoulders (Fig. 13-14). They contain a thick, yellowish, viscid, stringy, blood-tinged fluid. After incision and drainage, there is frequently a prompt refilling with the same type of material. These cysts are suggestive of the type found in hidradenitis suppurativa. Hidradenitis suppurativa and dissecting cellulitis of the scalp may be seen with acne conglobata, an association known as the “follicular occlusion triad.”

This severe and painful disease occurs most frequently in young men about 16 years old; it may extend and persist into adulthood and even into the fifth decade of life, especially over the posterior neck and back. Women are less frequently affected. Athletes and bodybuilders should be questioned about the use of anabolic steroids, which may induce such aggressive acne.

The therapy of choice in all but the earliest lesions is isotretinoin, 0.5–1 mg/kg/day to a total dose of 150 mg/kg, with a second course if resolution does not occur after a rest period of 2 months. Pretreatment with prednisone and low initial doses of isotretinoin, as described for acne fulminans, are recommended to avoid flaring of disease. Carbon dioxide (CO<sub>2</sub>) fractional laser abrasion of cysts, external beam radiation, and infliximab are other reported therapies. Infliximab cleared a patient in whom pyoderma gangrenosum, acne conglobata, suppurative hidradenitis (PASH) alone or with coexisting axial spondyloarthritis (PASS syndrome).



**Fig. 13-13** Acne conglobata with fistula formation.



**Fig. 13-14** Acne conglobata of the back. (Courtesy of Dr. Don Adler.)

**Bruzzese V:** Pyoderma gangrenosum, acne conglobata, suppurative hidradenitis, and axial spondyloarthritis. *J Clin Rheumatol* 2012; 18:413–415.

**Gerber PA, et al:** The dire consequences of doping. *Lancet* 2008; 372:656.

**Hasegawa T, et al:** Acne conglobata successfully treated by fractional laser after CO<sub>2</sub> laser abrasion of cysts combined with topical tretinoin. *J Dermatol* 2009; 36:118.

**Myers JN, et al:** Treatment of acne conglobata with modern external beam radiation. *J Am Acad Dermatol* 2010; 62:861–863.

## ACNE FULMINANS

Acne fulminans is a rare form of extremely severe cystic acne that occurs primarily in teenage boys. It is characterized by highly inflammatory nodules and plaques that undergo swift suppurative degeneration, leaving ragged ulcerations, mostly on the chest and back. The face is usually less severely involved. Fever and leukocytosis are common. Polyarthralgia and polymyalgia, destructive arthritis, and myopathy have



been reported in association with acne fulminans. Focal lytic bone lesions may be seen. As in acne conglobata, anabolic steroids taken by bodybuilders may induce this condition.

Prednisone, 40–60 mg, is necessary during the initial 4–8 weeks to calm the dramatic inflammatory response of acne fulminans. After 4 weeks 10–20 mg of isotretinoin is added. This should be slowly increased to standard doses and continued for a full 120–150 mg/kg cumulative course. Large cysts may be opened and the contents expressed. Intralesional corticosteroids will aid their resolution. Infliximab and dapsone are alternatives if isotretinoin is contraindicated.

**Iqbal M, et al:** Acne fulminans with SAPHO syndrome treated with infliximab. *J Am Acad Dermatol* 2005; 52:S118.

**Krause SL, et al:** The dark side of beauty. *Arch Dermatol* 2012; 148:1210–1212.

**Lages RB, et al:** Acne fulminans successfully treated with prednisone and dapsone. *An Bras Dermatol* 2012; 87:612–614.

**Zaba R, et al:** Acne fulminans. *J Eur Acad Dermatol Venereol* 2011; 25:501–507.

## SAPHO SYNDROME

The SAPHO syndrome is characterized by synovitis, acne, pustulosis, hyperostosis, and osteitis. Skin findings may include acne fulminans, acne conglobata, pustular psoriasis, hidradenitis suppurativa, dissecting cellulitis of the scalp, Sweet syndrome, Sneddon-Wilkinson disease, and palmo-plantar pustulosis. These may be present at the outset of the skeletal changes, but most often precede bone findings, or in 15% of adult cases and 70% of childhood cases, do not occur at all. The chest wall and mandible are the most common sites for musculoskeletal complaints in adults; the long bones, particularly the tibia, predominate in children. Bone changes of the anterior chest wall on nuclear scans are the most specific diagnostic findings. Acquired hyperostosis syndrome (AHYS) and, in a familial setting of a dominantly inherited disorder, pyogenic sterile arthritis, pyoderma gangrenosum, and acne (PAPA syndrome) both present with similar clinical scenarios. PAPA syndrome is caused by mutations in the gene for proline-serine-threonine-phosphatase interacting protein 1. Systemic retinoids and tumor necrosis factor (TNF) antagonists, particularly infliximab, have been successful in treating these patients. Interestingly, Crohn's disease may be associated with SAPHO syndrome or may occur during treatment with TNF antagonists. If isotretinoin is used, it should be initiated at a low dosage, such as 10 mg/day, in combination with prednisone for the first month to prevent flaring of the disease. Anakinra, methotrexate, sulfasalazine, and cyclosporine are other, less well-documented but likely effective choices. Pamidronate and other bisphosphonates such as ibandronate, alendronate, and zoledronic acid, are effective in treating the osteoarticular manifestations.

**Chen W, et al:** Acne-associated syndromes. *J Eur Acad Dermatol Venereol* 2011; 25:637–646.

**Colina M, et al:** Clinical and radiologic evolution of synovitis, acne, pustulosis, hyperostosis, and osteitis syndrome. *Arthritis Rheum* 2009; 61:813.

**Firinu D, et al:** Biological treatments for SAPHO syndrome. *Inflamm Allergy Drug Targets* 2014; 13:199.

**Galadari H, et al:** Synovitis, acne, pustulosis, hyperostosis, and osteitis syndrome treated with a combination of isotretinoin and pamidronate. *J Am Acad Dermatol* 2009; 61:123.

**Garcovich S, et al:** Long-term treatment of severe SAPHO syndrome with adalimumab. *Am J Clin Dermatol* 2012; 13:55–59.

**Naves JE, et al:** A systematic review of SAPHO syndrome and inflammatory bowel disease association. *Dig Dis Sci* 2013; 58:2138–2147.

**Nguyen MT, et al:** The SAPHO syndrome. *Semin Arthritis Rheum* 2012; 42:254–265.

**Soyfoo MS, et al:** Successful treatment of SAPHO syndrome with ibandronate. *J Clin Rheumatol* 2010; 16:253.

## OTHER ACNE VARIANTS

### Tropical acne

Tropical acne is unusually severe acne occurring in the tropics during the seasons when the weather is hot and humid. Nodular, cystic, and pustular lesions occur chiefly on the back, buttocks, and thighs (Fig. 13-15). Characteristically, the face is spared. Conglobate abscesses occur often, especially on the back. Comedones are sparse. Acne tropicalis usually occurs in young adults who may have had acne vulgaris at an earlier age. This is especially true of those in the armed forces stationed in the tropics and carrying backpacks. Treatment is that for cystic acne, but acne tropicalis may persist until the patient moves to a cooler, less humid climate.

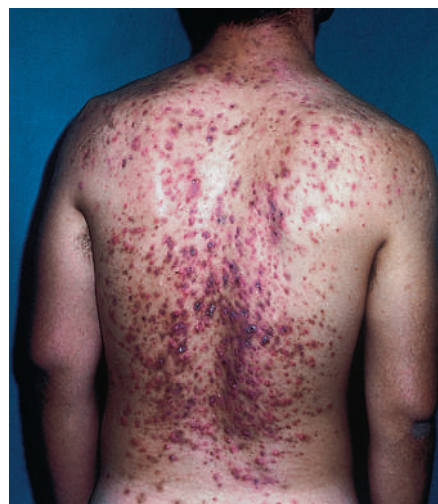### Acne estivalis

Also known as Mallorca acne, this rare form of acne starts in the spring, progresses during the summer, and resolves completely in the fall. Acne estivalis affects almost exclusively women age 25–40. Dull-red, dome-shaped, hard, small papules, usually not larger than 3–4 mm, develop on the cheeks and usually extend on to the sides of the neck, chest, shoulders, and characteristically the upper arms. Comedones and pustules are notably absent or sparse. Acne estivalis does not respond to antibiotics but benefits from application of retinoic acid.

### Excoriated acne

Also known as picker's acne and acne excoriée des jeunes filles, excoriated acne is seen primarily in young women with a superficial type of acne. The primary lesions are trivial or even nonexistent, but the compulsive neurotic habit of picking the face and squeezing minute comedones produces secondary lesions that crust and may leave scars. Often, the lesion that is excoriated is minute, seen only in a magnifying mirror.

Excoriated acne may be a sign of depression or anxiety. It is an obsessive-compulsive symptom. If the patient admits to picking but being unable to stop this habit, improvement may



**Fig. 13-15** Tropical acne.

follow support and acne therapy. However, most patients will require interventions with selective serotonin reuptake inhibitors, behavior modification, or psychotherapy. Other pharmacologic treatments that have been successful in case reports include doxepin, clomipramine, naltrexone, pimozide, and olanzapine.

**Gieler U, et al:** Self-inflicted lesions in dermatology. *Acta Derm Venereol* 2013; 93:4–12.

**Hjorth N, et al:** Acne aestivalis: Mallorca acne. *Acta Dermatol Venereol* 1972; 2:61.

**Wells JM:** Tropical acne—one hundred cases. *J R Army Med Corps* 1981; 127:55.

## ACNEIFORM ERUPTIONS

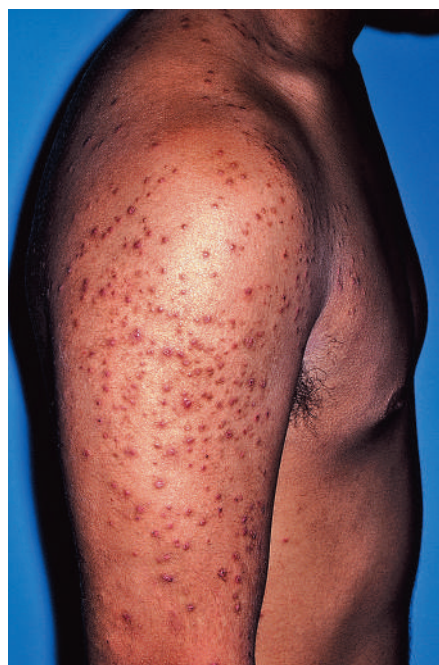Acneiform eruptions are follicular eruptions characterized by papules and pustules resembling acne. Breaks in the epithelium and spillage of follicular contents into the dermis lead to the lesions. Eruptions are not necessarily confined to the usual sites of acne vulgaris, often have a sudden onset, are monomorphic, and usually appear in a patient well past adolescence. If secondary to a drug, an eruption begins within days of initiation of the medication, may be accompanied by fever and malaise, and resolves when the drug is stopped.

Acneiform eruptions may originate from skin exposure to various industrial chemicals, such as fumes generated in the manufacture of chlorine and its byproducts. These chlorinated hydrocarbons may cause chloracne, consisting of cysts, pustules, folliculitis, and comedones. The most potent acneiform-inducing agents are the polyhalogenated hydrocarbons, notably dioxin (2,3,7,8-tetrachlorodibenzo-*p*-dioxin). Cutting and lubricating oils, pomades, crude coal tar applied to the skin for medicinal purposes, heavy tar distillates, coal tar pitch, and asbestos are known to cause acneiform eruptions. Acne venenata or contact acne is another term applied to this process.

Acneiform eruptions are induced by medications such as iodides from radiopaque contrast media or potassium iodide, bromides in drugs such as propantheline bromide, testosterone, cyclosporine, antiepileptic medications, lithium, and systemic corticosteroids. When medium or high doses of corticosteroids are taken for as briefly as 3–5 days, a distinctive eruption may occur, known as steroid acne. It is a sudden outcropping of inflamed papules, most numerous on the upper trunk and arms (Fig. 13-16) but also seen on the face. The lesions typically present as papules rather than comedones; however, a histologic study confirmed they begin follicularly with microcomedone formation. Tretinoin (Retin-A), 0.05% cream applied once or twice daily, may clear the lesions within 1–3 months despite the continuation of high doses of corticosteroid. Oral antibiotics and other typical acne medications are also effective. Topical steroids, especially the fluorinated types or when applied under occlusion, may also induce an acneiform eruption. Topical tacrolimus and pimecrolimus may both induce a papulopustular eruption. Epidermal growth factor inhibitors, including monoclonal antibodies and tyrosine and multikinase inhibitors used in cancer therapy, produce a folliculitis in the majority of treated patients. Often, oral minocycline and topical benzoyl peroxide are given prophylactically at the outset of the cancer therapy to prevent what may be a dose-limiting reaction. Radiation therapy for malignancy also can induce acne in the radiation port.

Comedonal lesions may be limited to the nasal crease, in the flexural areas in children and on the temple and malar skin in Favre-Racouchot syndrome.

**Cho SB, et al:** A new case of childhood flexural comedones. *J Eur Acad Dermatol Venereol* 2009; 23:366–367.



**Fig. 13-16** Steroid acne. (Courtesy of Curt Samlaska, MD.)

**Dessinioti C, et al:** Acneiform eruptions. *Clin Dermatol* 2014; 32:24–34.

**Hameed AF:** Steroid dermatitis resembling rosacea. *ISRN Dermatol* 2013; 49:1376.

**Kraus SL, et al:** The dark side of beauty: acne fulminans induced by anabolic steroids in a male bodybuilder. *Arch Dermatol* 2012; 148:1210–1212.

**Li JC, et al:** Facial acne during topical pimecrolimus therapy for vitiligo. *Clin Exp Dermatol* 2009; 34:e489–e490.

**Li T, et al:** Skin toxicities associated with epidermal growth factor receptor inhibitors. *Target Oncol* 2009; 4:107.

**Melnik B, et al:** Abuse of anabolic-androgenic steroids and bodybuilding acne. *J Dtsch Dermatol Ges* 2007; 5:110.

**Momin SB, et al:** A status report on drug-associated acne and acneiform eruptions. *J Drugs Dermatol* 2010; 9:627–636.

**Pelclova D, et al:** Adverse health effects in humans exposed to 2,3,7,8-tetrachlorodibenzo-*p*-dioxin (TCDD). *Rev Environ Health* 2006; 21:119.

**Petukhova TA, et al:** Acneiform eruptions associated with vemurafenib. *J Am Acad Dermatol* 2013; 68:e97–e99.

**Saurat JH, et al:** The cutaneous lesions of dioxin exposure. *Toxicol Sci* 2012; 125:310–317.

**Waller B, et al:** Transverse nasal crease and transverse nasal milia. *Arch Dermatol* 2012; 148:1037–1039.

## GRAM-NEGATIVE FOLLICULITIS

Gram-negative folliculitis occurs in patients who have had moderately inflammatory acne for long periods and have been treated with long-term antibiotics, mainly tetracyclines. During antibiotic treatment, patients develop either superficial pustules 3–6 mm in diameter, flaring out from the anterior nares, or fluctuant, deep-seated nodules (Fig. 13-17). Culture of these lesions usually reveals a species of *Klebsiella*, *Escherichia coli*, *Enterobacter*, or from the deep cystic lesions, *Proteus*.

With long-term, broad-spectrum antibiotic therapy, the anterior nares may become colonized with these gram-negative organisms. As the use of long-term antibiotic therapy declines, this disease has become less common.

Isotretinoin is very effective and is the treatment of choice in gram-negative folliculitis. This treatment not only clears the acne component of the disease but also eliminates the colonization of the anterior nares with gram-negative organisms. If isotretinoin cannot be tolerated or is contraindicated,



amoxicillin or TMP-SMX may be effective in suppressing the disease.

**Boni R, et al:** Treatment of gram-negative folliculitis in patients with acne. *Am J Clin Dermatol* 2003; 4:273.

**Lehrhoff S, et al:** *Serratia marcescens* folliculitis and concomitant acne vulgaris. *Dermatol Online J* 2012; 18:19.

## ACNE KELOIDALIS

Acne keloidalis is most frequently encountered in young adult black, Hispanic, or Asian men who otherwise are in excellent health. It is not associated with acne vulgaris and is a primary cicatricial alopecia variant. Keloid acne is a persistent folliculitis and perifolliculitis of the back of the neck that presents as inflammatory papules and pustules. Over time, fibrosis ensues with coalescence of firm papules into keloidal plaques, as on the neck (acne keloidalis nuchae, [Fig. 13-18](#)). At times, sinus tract formation results.

Histologically, acne keloidalis is characterized by perifollicular, chronic lymphocytic and plasmacytic inflammation, most intense at the level of the isthmus and lower infundibulum of terminal hairs. There is lamellar fibroplasia, most marked at the level of the isthmus and, eventually, in the keloidal masses; the connective tissue becomes sclerotic, forming hypertrophic scars or keloids. Persistent free hairs in the dermis may be responsible for the prolonged inflammation and eventual scarring.

Topical therapy with potent steroid ointments or foams alone, or following twice-daily tretinoin gel, is useful for the follicular papules. Oral antibiotics of the tetracycline group may be added and are helpful in suppressing the inflamma-

tory response. Triamcinolone acetonide by intralesional injection, using 10 mg/mL into the inflammatory follicular lesions and 40 mg/mL into the hypertrophic scars and keloids, is useful in reducing inflammation and fibrosis. Smaller lesions may be excised to a level below the hair follicle and closed. This may be followed by 40 mg/mL triamcinolone by intralesional injection every 3 weeks. For larger lesions, deep excision or CO<sub>2</sub> laser ablation left to heal by primary intention may be necessary. Laser hair removal with the neodymium:yttrium-aluminum-garnet (Nd:YAG) laser may be used as a preventive measure against acne keloidalis.

**Bajaj V, et al:** Surgical excision of acne keloidalis nuchae with secondary intention healing. *Clin Exp Dermatol* 2008; 33:53.

**Dragoni F, et al:** Successful treatment of acne keloidalis nuchae resistant to conventional therapy with 1064-nm ND:YAG laser. *G Ital Dermatol Venereol* 2013; 148:231–232.

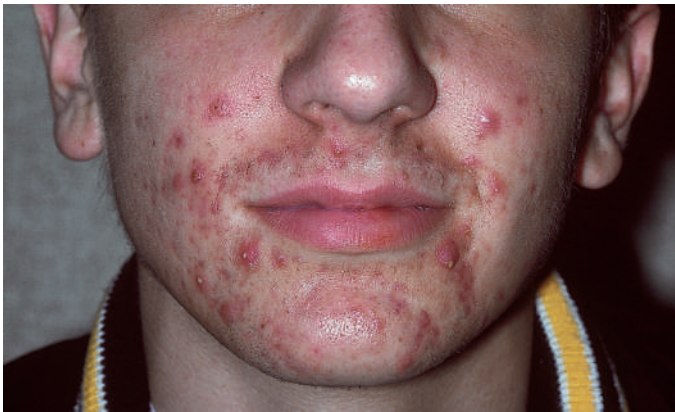**Esmat SM, et al:** The efficacy of laser-assisted hair removal in the treatment of acne keloidalis nuchae. *Eur J Dermatol* 2012; 22:645–650.

## HIDRADENITIS SUPPURATIVA

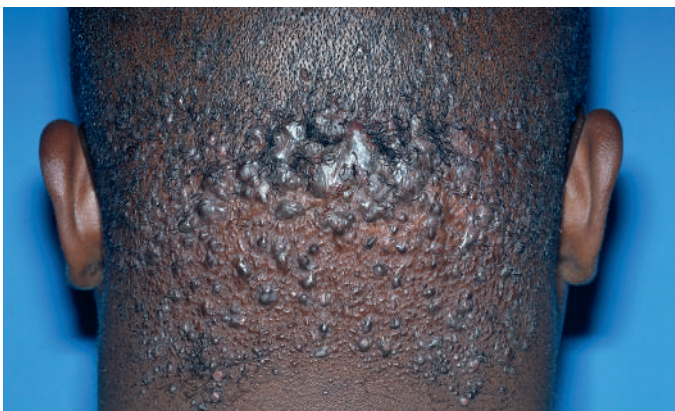### Clinical features

Hidradenitis suppurativa is a chronic disease characterized by recurrent abscess formation, primarily within the folded areas of skin that contain both terminal hairs and apocrine glands. The primary site of inflammation is not the gland but the terminal hair. Plewig uses the term “dissecting terminal folliculitis” to unify diseases primarily affecting the terminal hair follicle, such as hidradenitis suppurativa, acne keloidalis nuchae, pilonidal sinus, and dissecting cellulitis of the scalp. The axilla is the most frequently affected site. The inguinal and submammary areas are favored in women ([Figs. 13-19 and 13-20](#)), with the buttock, perianal area, and atypical areas (e.g., retroauricular, trunk) more often affected in men, although any and all areas may be affected in either gender. This post-pubertal process affects women about four times more often than men.

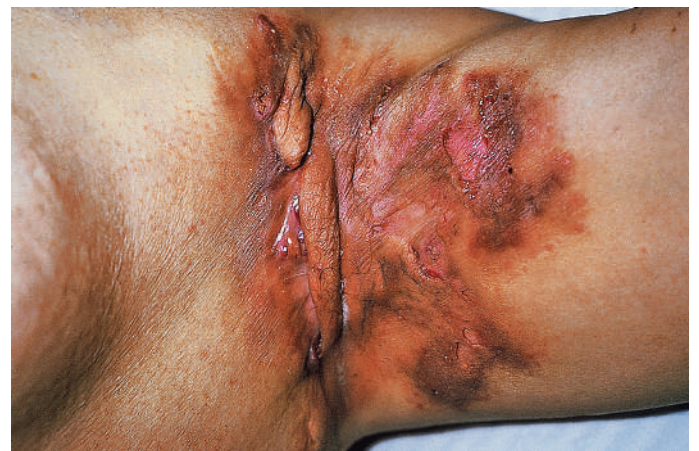The disease is characterized by the development of tender, red nodules, which at first are firm but soon become fluctuant and painful. Rupture of the lesion, suppuration, formation of sinus tracts, and extensive scarring are distinctive. As one area heals, recurrent lesions form, so that the course of the disease is protracted. It may eventually lead to the formation of honeycombed, fistulous tracts with chronic infection. The individual lesions contain a thick, viscous, mucoid, suppurative material. When a probe is used to explore the suppurating



**Fig. 13-17** Gram-negative folliculitis.



**Fig. 13-18** Acne keloidalis nuchae.



**Fig. 13-19** Hidradenitis of the axilla.

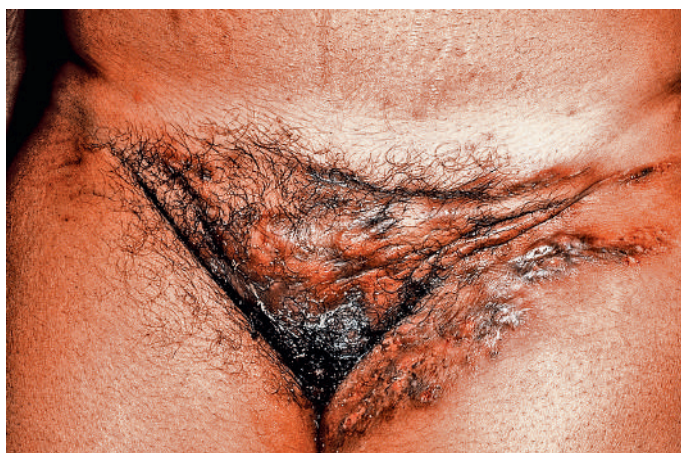

Fig. 13-20 Hidradenitis of the groin.

nodule, a burrowing sinus tract is usually detected that may extend for many centimeters, running horizontally just underneath the skin surface.

Disease severity varies, as does the impact on quality of life from this chronic, recurrent, painful, odiferous, messy condition. The majority of the approximately 1% of the population affected by hidradenitis suppurativa are mildly affected. Severe debilitation occurs more often in men than in women. Men also more often have a history of acne and pilonidal cysts. Squamous cell carcinoma (SCC, after an average 19 years of active disease), interstitial keratitis, spondyloarthropathy, urethral vesical and rectal fistulas, anemia, hypoproteinemia, and amyloidosis have been reported to complicate hidradenitis suppurativa, but are rare. Pyoderma gangrenosum lesions complicate this condition at times, with the diagnosis dependent on the clinical signs of a rapidly expanding, painful ulcer with undermined edges. These lesions occur a median of 19 years after the onset of hidradenitis and may be at sites distant from or within the area of the hidradenitis lesions. Some of these patients may have associated conglobate acne (PASH) or PASS syndrome. Significant lymphedema of the penis and groin, along with alteration of the anatomy because of surgical intervention, often makes physical examination of these sites difficult. The risk of SCC occurring as an ulceration or thickening in a skin crease, which can metastasize and cause death, requires attention to detail in this regard.

## Etiology

Detailed histologic studies of hidradenitis suppurativa reveal that terminal follicle hyperkeratosis is followed by rupture of the follicular epithelium and release of keratin, sebum, bacteria, and hairs into the dermis. The resulting inflammatory process engulfs the apocrine gland and leads to rupture of the overlying skin, fibrosis, and sinus tract formation. Secondary bacterial infection with *Staphylococcus aureus*, *Streptococcus pyogenes*, and various gram-negative organisms may occur. The initiating event is unknown. Comorbidities include obesity, metabolic syndrome, inflammatory bowel disease, and polycystic ovarian syndrome. Mechanical friction, often worsened by obesity, is an exacerbating factor, as is bacterial infection. There is an autosomal dominant inherited form of this disease. Mutations in the gamma-secretase genes *NCSTN*, *PSENEN*, and *PSEN1* have been identified. Mutation-positive patients have severe and extensive disease, and may have onset before age 13.

## Differential diagnosis

Hidradenitis is to be differentiated from common furuncles, which are typically unilateral. Hidradenitis must also be differentiated from Bartholin abscess, scrofuloderma, actinomycosis, granuloma inguinale, and lymphogranuloma venereum.

## Treatment

The earliest lesions often heal quickly with intralesional steroid therapy, which may be used initially in combination with topical Cleocin or oral doxycycline or minocycline. Topical daily cleansing with chlorhexidine gluconate (Hibiclens) solution or benzoyl peroxide wash is an important preventive measure. Additionally, laser hair removal, if performed, should be done in unaffected sites as a preventive therapy. Other general preventive strategies include reduction of friction by wearing loose-fitting clothing and weight loss, if needed, and avoidance of excessive sweating through the use of topical aluminum chloride or botulinum toxin A injections, smoking cessation, and heat avoidance. The disease itself causes sterile abscesses, but culture of the pus may reveal *S. aureus* or gram-negative organisms. The latter are usually cultured in patients with chronic disease given long-term antibiotic therapy; antibiotics should be selected based on sensitivities of the cultured organism. Antibiotics that may be useful in suppressing the disease long term include the tetracyclines amoxicillin, TMP-SMX DS, or dapsone. The combination of clindamycin and rifampin, both given in doses of 300 mg twice daily, has been extensively studied in Europe and found to be quite effective. In severely affected patients, admission and treatment with intravenous ertapenem was reported to calm the disease so outpatient oral management might be effective. Incision and drainage is strongly discouraged.

Isotretinoin and acitretin are effective in some cases, but a remission seldom follows their use. Secondary infection with *S. aureus* often occurs. The TNF antagonists have all been used; infliximab is most effective and may clear the condition during use. In women, spironolactone and OCs and finasteride in men or postmenopausal women may be a helpful adjuvant. Cyclosporine or ustekinumab may work well in select cases.

Photodynamic therapy and lasers have also been investigated to various degrees in hidradenitis. Methyl-aminolevulinic acid or 5-aminolevulinic acid given before blue or red light activation (photodynamic therapy) has had reports of success in some cases, but also anecdotal reports of lack of efficacy. It is inconvenient, costly, and often painful and does not produce remission, so further studies are required before such treatment can be recommended. Nd:YAG laser treatment has been reported to be effective in a prospective, randomized controlled trial of 22 severely affected patients. After a series of three monthly sessions, significant improvement was seen.

Chances of permanent cure are best when excision of the affected areas is done. Wide surgical excision, using intraoperative color marking of sinus tracts, is most effective at limiting recurrence; however, it has moderate morbidity, especially in the groin and perianal areas. The recurrence rate is low in the axillary and perianal areas; however, the inguinal folds and especially the submammary sites more often recur so that excision of the latter site is uncommonly recommended. CO<sub>2</sub> laser may also destroy lesions and sinus tracts. The open areas may be closed or left to heal secondarily.

Most patients with severe recalcitrant hidradenitis suppurativa responded to the approach reported by van Rappard: combination clindamycin and rifampin, each 300 mg twice daily for 2 to 4 months. If patients do not respond and a clear

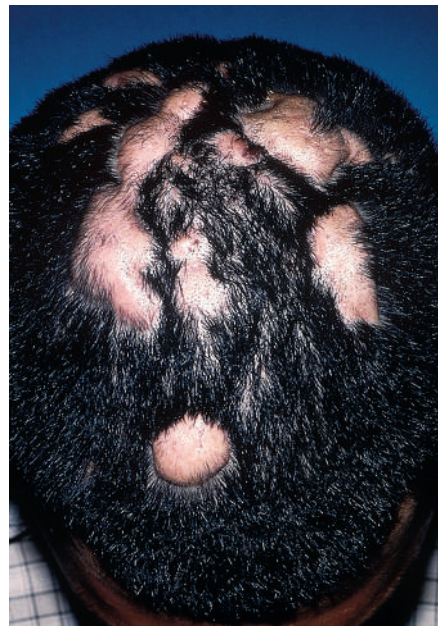

inflammatory component is present, infliximab is added, with infusions given at weeks 0, 2, 6, and subsequently every 8 weeks. After 3–6 months, any remaining sinuses and fistulas not responding to treatment are removed surgically.

- Alhusayen R, et al:** Pharmacologic interventions for hidradenitis suppurativa. *Am J Clin Dermatol* 2012; 13:283–291.
- Alikhan A, et al:** Hidradenitis suppurativa. *J Am Acad Dermatol* 2009; 60:539.
- Blok JL, et al:** Systemic therapy with immunosuppressive agents and retinoids in hidradenitis suppurativa. *Br J Dermatol* 2012; 168:243–252.
- Bruzzese V:** Pyoderma gangrenosum, acne conglobata, suppurative hidradenitis, and axial spondyloarthritis. *J Clin Rheumatol* 2012; 18:413–415.
- Deckers IE, et al:** Correlation of early-onset hidradenitis suppurativa with stronger genetic susceptibility and more widespread involvement. *J Am Acad Dermatol* 2015; S0190-9622(14)02202-6.
- Howland N, et al:** Approach to the severe hidradenitis suppurativa patient. *Plast Reconstr Surg* 2014; 134:148.
- Hsiao JL, et al:** Hidradenitis suppurativa and concomitant pyoderma gangrenosum. *Arch Dermatol* 2010; 146:1265–1270.
- Kimball AB, et al:** Adalimumab for the treatment of moderate to severe hidradenitis suppurativa. *Ann Intern Med* 2012; 157:846–855.
- Kirby JS, et al:** Health care utilization patterns and costs for patients with hidradenitis suppurativa. *JAMA Dermatol* 2014; 150:937.
- Kraft JN, et al:** Hidradenitis suppurativa in 64 female patients: retrospective study comparing oral antibiotics and antiandrogen therapy. *J Cutan Med Surg* 2007; 11:125.
- Levogiez C, et al:** Clinicopathological study of 13 cases of squamous cell carcinoma complicating hidradenitis suppurativa. *Dermatology* 2010; 220:147–153.
- Mendoca CO, et al:** Clindamycin and rifampicin combination therapy for hidradenitis suppurativa. *Br J Dermatol* 2006; 154:977.
- Micheletti RG:** Natural history, presentation, and diagnosis of hidradenitis suppurativa. *Semin Cutan Med Surg* 2014; 33:S51.
- Mikkelsen PR, et al:** Hidradenitis suppurativa in children and adolescents. *Paediatr Drugs* 2014; Sep 19.
- Miller IM, et al:** Association of metabolic syndrome and hidradenitis suppurativa. *JAMA Dermatol* 2014; 150:1273–1280.
- Nassif A, et al:** Complete remission of severe hidradenitis suppurativa obtained in 4 patients using wide-spectrum antimicrobial treatment. *J Am Acad Dermatol* 2012; 66 (poster abstract).
- Pink AE, et al:** Gamma-secretase mutations in hidradenitis suppurativa. *J Invest Dermatol* 2013; 133:601–607.
- Rambhatla PV, et al:** A systematic review of treatments for hidradenitis suppurativa. *Arch Dermatol* 2012; 148:439–446.
- Randhawa HK, et al:** Finasteride for the treatment of hidradenitis suppurativa in children and adolescents. *JAMA Dermatol* 2013; 149:732–735.
- Saraceno R, et al:** Methyl aminolevulinic photodynamic therapy for the treatment of hidradenitis suppurativa and pilonidal cysts. *Photodermatol Photoimmunol Photomed* 2009; 25:164.
- Schrader AM, et al:** Hidradenitis suppurativa. *J Am Acad Dermatol* 2014; 71:460.
- Shlyankevich J, et al:** Hidradenitis suppurativa is a systemic disease with substantial comorbidity burden. *J Am Acad Dermatol* 2014; 71:1144.
- Tierney E, et al:** Randomized control trial for the treatment of hidradenitis suppurativa with a neodymium-doped yttrium-aluminum-garnet laser. *Dermatol Surg* 2009; 35:1.
- Van Rappard DC, et al:** Treatment of severe hidradenitis suppurativa with infliximab in combination with surgical intervention. *Br J Dermatol* 2012; 167:202–208.

## DISSECTING CELLULITIS OF THE SCALP

Also known as perifolliculitis capitis abscedens et suffodiens, this is an uncommon chronic suppurative disease of the scalp characterized by numerous follicular and perifollicular inflammatory nodules. These nodules suppurate and undermine to form intercommunicating sinuses as long as 5 cm (Fig. 13-21).



**Fig. 13-21** Dissecting folliculitis. (Courtesy of Curt Samlaska, MD.)

Scarring and alopecia ensue, although seropurulent drainage may last indefinitely. Adult black men are most often affected, and the vertex and occiput of the scalp are the favored sites.

The primary lesions are follicular and perifollicular erythematous papules that progress to abscesses. This disease is a variant of dissecting terminal hair folliculitis, along with hidradenitis suppurativa, acne keloidalis nuchae, and pilonidal sinus. Coagulase-positive *S. aureus* may be found in the lesions.

Treatment with oral antibiotics such as the tetracyclines, TMP-SMX, or the quinolones may produce good results. If *S. aureus* is cultured, the combination of oral rifampin and clindamycin has produced excellent results. The combination of intralesional steroid injections and isotretinoin at a dose of 0.5–1.5 mg/kg/day for 6–12 months may be successful. Starting at a lower dose, such as 10 mg/day, for the first month or two may prevent a flare of the condition. The length of remission with isotretinoin is variable, but treatment may be repeated with similar results expected. The anti-TNF medications infliximab and adalimumab and the retinoid alitretinoin have been helpful in individual cases.

A surgical approach is sometimes necessary. Marsupialization or excision of sinus tracts may help limit inflammation. The Nd:YAG laser used to remove hair has led to long-term improvement. Excision of the entire scalp has been necessary in select patients.

- Georgala S, et al:** Dissecting cellulitis of the scalp treated with rifampicin and isotretinoin. *Cutis* 2008; 82:195.
- Greenblatt DT, et al:** Dissecting cellulitis of the scalp responding to oral quinolones. *Clin Exp Dermatol* 2008; 33:99.
- Housewright CD, et al:** Excisional surgery (scalpectomy) for dissecting cellulitis of the scalp. *Dermatol Surg* 2011; 37:1189–1191.
- Krasner BD, et al:** Dissecting cellulitis treated with the long-pulsed Nd:YAG laser. *Dermatol Surg* 2006; 32:1039.
- Navarinni AA, et al:** 3 cases of dissecting cellulitis of the scalp treated with adalimumab. *Arch Dermatol* 2010; 146:517–520.
- Prasad SC, et al:** Successful treatment with alitretinoin of dissecting cellulitis of the scalp in keratitis-ichthyosis-deafness syndrome. *Acta Derm Venereol* 2013; 93:473–474.

## ACNE MILIARIS NECROTICA (ACNE VARIOLIFORMIS)

Acne miliaris necrotica consists of follicular vesicopustules, sometimes occurring as solitary lesions that usually are

extremely itchy. They appear anywhere in the scalp or adjacent areas, rupture early, and dry up after a few days. In some patients, especially those who manipulate the lesions, *S. aureus* may be cultured. If the lesions leave large scars, the term acne varioliformis is used; they are not separate diseases.

Treatment is with culture-directed antibiotics, or if the culture is negative, oral doxycycline. Doxepin is helpful if patients manipulate their lesions.

**Fisher DA:** Acne necroticans and *Staphylococcus aureus*. *J Am Acad Dermatol* 1988; 18:1136.

**Zirn JR, et al:** Chronic acneiform eruption with crateriform scars. *Arch Dermatol* 1996; 132:1365.

## ROSACEA

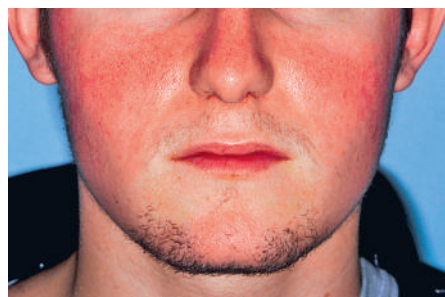### Clinical features

Rosacea is characterized by a persistent erythema of the convex surfaces of the face, with the cheeks and nose most frequently affected, followed by involvement of the brow and chin. There is a tendency to spare the periocular skin. Rosacea occurs most often in light-skinned women age 30–50. However, the severe type with phymatous changes occurs almost exclusively in men. Additional common features include telangiectasia, flushing, erythematous papules, and pustules. These tend to cluster in patterns, allowing for the identification of several subsets of patients; their recognition is important because the therapeutic implications differ.

The erythrotelangiectatic type is characterized by a prominent history of a prolonged (>10 min) flushing reaction to various stimuli, such as emotional stress, hot drinks, alcohol, spicy foods, exercise, cold or hot weather, or hot baths and showers (Fig. 13-22). Often, a burning or stinging sensation accompanies the flush, but with no sweating, lightheadedness, or palpitations. The skin is finely textured, may have a roughness and scaling of the affected central facial sites, and is easily irritated. Over time, a purplish suffusion and prominent telangiectasia may result.

The papulopustular subset of patients manifests a strikingly red central face accompanied by erythematous papules often surmounted by a pinpoint pustule (Fig. 13-23). The history of flushing is also present in most patients, but usually symptoms of irritancy are not prominent. The skin is of normal or at times slightly sebaceous quality, and edema of the affected sites may be present. Such edema may dominate the clinical presentation, with the forehead, eyelids, and cheeks variably affected. This has been termed Morbihan's disease and is most likely to complicate the papulopustular and glandular types.

In the glandular type of rosacea, men with thick, sebaceous skin predominate. The papules are edematous, the pustules are often 0.5–1.0 cm in size, and nodulocystic lesions may be present (Fig. 13-24). They tend to cluster in the central face, but in affected women the chin is favored. There is frequently a history of adolescent acne, and typical scars may be seen.

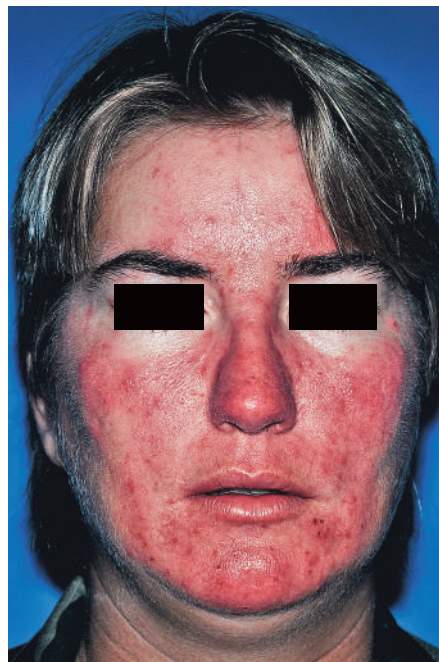

**Fig. 13-22**  
Erythrotelangiectatic  
rosacea.

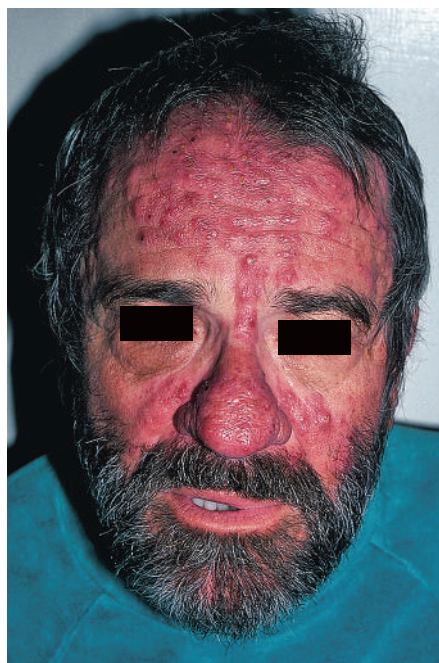Flushing is less common, as is telangiectasia, but persistent edema may be problematic. Rhinophyma most often occurs in this glandular subtype (Fig. 13-25). Large, hypertrophic, hyperemic nodular masses are centered over the distal half of the nose. Differentiation of this hypertrophic tissue from a basal cell skin cancer or a cutaneous B-cell lymphoma is at times difficult. Rarely, such soft tissue overgrowth can affect the chin, ears, or forehead. Hugely dilated follicles contain long, vermicular plugs of sebum and keratin. The histologic features are pilosebaceous gland hyperplasia with fibrosis, inflammation, and telangiectasia.

### Etiology

The cause of rosacea remains unknown. Most patients have an abnormal vasomotor response to thermal and other



**Fig. 13-23**  
Papulopustular  
rosacea. (Courtesy of  
Curt Samlaska, MD.)



**Fig. 13-24** Glandular  
rosacea.



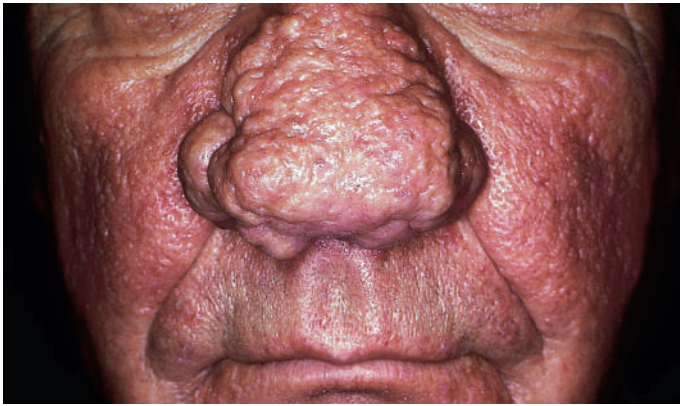

Fig. 13-25 Rhinophyma.

stimuli, as previously described. Early in the process, dysregulation of the innate immune system and neurovascular control is documented. Additionally, chronic solar damage is an important contributor in producing damage to the dermal matrix and ground substance, especially in the erythrotelangiectatic subtype. Chronic vasodilation, edema, and compromise of lymphatic drainage occur and lead to telangiectasia and fibrosis. Pilosebaceous unit abnormalities are not typically thought to be part of the pathogenesis of this condition; however, some evidence points to abnormalities being present, especially in the patient with the glandular type. As expected, the pathogenic factors will vary among the subsets of patients. *Demodex* and *Helicobacter pylori* have been extensively investigated and do not appear to be central to the etiology of rosacea.

### Other clinical considerations

#### Ocular findings

Blepharitis, recurrent chalazion, and conjunctivitis may be seen in all subsets of rosacea (Fig. 13-26). The eye itself may be affected, with keratitis, iritis, and episcleritis. An abnormal Schirmer test occurs in 40% of rosacea patients. Complaints are often of a gritty, stinging, itchy, or burning sensation in the eye. Light sensitivity and a foreign body sensation are also present at times. Ocular rosacea occurs equally in men and women. Such eye findings may occur before the skin disease. These findings have therapeutic implications, and patients will not always complain of them to their dermatologist, so these signs and symptoms should be actively sought when evaluating rosacea patients.

#### Extrafacial lesions

Flushing may involve the ears, lateral facial contours, neck, upper chest, and scalp. Papules and pustules may be present in persistent erythema of the scalp or the earlobes.

#### Topical corticosteroid use

Long-term use of topical corticosteroids on the face may result in persistent erythema, papules, and pustules. The sites involved correspond to the areas of application and are not necessarily limited to the central convexities. Treatment is discontinuance of the corticosteroid and institution of topical tacrolimus in combination with short-term minocycline. Topical tacrolimus itself has paradoxically been reported to induce a rosacea-like reaction, so coverage with minocycline

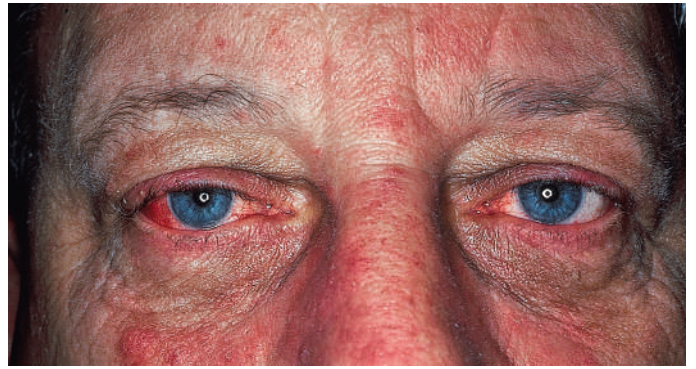


Fig. 13-26 Ocular rosacea.

while discontinuing topical steroids is necessary. Additionally, drinking alcohol after application of tacrolimus or pimecrolimus may induce flushing, which may be confused with new-onset flushing related to rosacea.

#### Perioral dermatitis

Although perioral dermatitis has been classified with rosacea variants, its distribution, signs, and symptoms vary such that it is discussed separately later in this chapter.

#### Granulomatous lesions

Some patients with persistent facial erythema of the convexities, on biopsy of an erythematous papule, show a granulomatous response closely resembling sarcoidosis or a necrotizing granuloma. Many experienced clinicians will accurately predict such findings from the clinical examination. The most important consideration in this case is that the patient's response to treatment may be slower. When involvement of granulomatous facial papules includes the eyelids and upper lip and is not associated with vascular manifestations, such as flushing, erythema, or telangiectasia, the term granulomatous facial dermatitis is preferred. This condition is discussed separately.

#### Differential diagnosis

The persistent erythema of the central face should be differentiated from that seen in polycythemia vera, carcinoid, mastocytosis, and connective tissue disease (lupus erythematosus, dermatomyositis, mixed connective tissue disease). These conditions do not have associated papules and pustules and will manifest a variety of systemic symptoms and extrafacial signs, and specific laboratory markers are available to confirm clinical suspicions. Haber syndrome is a genodermatosis characterized by a rosacea-like facial dermatosis and multiple verrucous lesions on non-sun-exposed skin. Onset of the facial lesions is in the first two decades of life, in contrast to the later onset of rosacea. Whereas rosacea may occur in human immunodeficiency virus (HIV) disease, a papulonodular eruption of the face that may simulate acne rosacea also occurs in patients with acquired immunodeficiency syndrome (AIDS). On expressing the contents of hair follicles with a comedo extractor, numerous *Demodex* mites are seen. In such cases, success with permethrin cream and lindane has been reported. Lotions containing 5% benzoyl peroxide and 5% precipitated sulfur (Sulfoxy) are also reported to be helpful.

## Treatment

Treatments are directed at specific findings manifested by rosacea patients. Because erythema, telangiectases, papules and pustules, phymas, flushing, ocular symptoms, and skin sensitivity are variably present in the three subsets of disease, the specific approach used will differ according to the factors present. Other treatments are useful in all patients.

## General nonpharmacologic and nonsurgical interventions

Sunscreens are an important component of therapy for all rosacea patients and should be applied each morning. Sunscreens containing physical blockers in a dimethicone or cyclo-methicone vehicle generally are better tolerated, especially by the erythrotelangiectatic patients, than those with chemical agents. General avoidance of irritants such as astringents, peeling or acidic agents, and abrasive or exfoliant preparations is recommended. Cosmetic coverage of the erythema and telangiectases is best with a light-green or yellow-tinted foundation set with powder.

If flushing is induced by specific trigger factors, these should be avoided as much as possible. The central face may be predisposed to rosacea because the edema and lack of movement of tissues with muscular movement may lead to lymphedema and inflammation. Circular massage for several minutes a day has led to impressive improvement. This benign intervention may be considered and should be studied. Artificial tears and cleansing the lids with warm water twice daily will help ocular symptoms.

## Topical therapy

Metronidazole, sodium sulfacetamide, sulfur cleansers and creams, ivermectin, and azelaic acid are utilized in rosacea. These are the most commonly prescribed medications and are especially useful for the papulopustular patients and some patients with the erythrotelangiectatic type. Benzoyl peroxide and topical clindamycin, alone or in combination, are often beneficial and well tolerated by the glandular subset of rosacea patients. If oral antibiotics are needed, the topical products may be used to maintain remission after discontinuance of oral preparations.

Pimecrolimus or tacrolimus may also improve select patients' erythema, especially those with an accompanying roughness or scaling of the skin surface. Both agents help the irritated erythrotelangiectatic and at times the papulopustular patients but are not effective in the glandular type, and tacrolimus in its ointment base may exacerbate the inflammatory component in these patients. These drugs calm inflammation and abate symptoms but require brief (no longer than 1 week) pretreatment with a potent topical corticosteroid to be tolerated initially. The role of topical retinoids requires study. Many rosacea patients may tolerate a nighttime application of tretinoin if Cetaphil lotion is used immediately before use. Retinoids may help repair sun-damaged skin and normalize some of the abnormalities present. The  $\alpha$ -adrenergic receptor agonist brimonidine is available as a gel for the treatment of facial redness. It is applied once in the morning, which induces vasoconstriction for up to 12 hours. Irritation allergy is not uncommon.

## Oral therapy

Oral antibiotics, particularly doxycycline, in a subantimicrobial dose of 40-mg extended-release formulation, or 50–100 mg

once or twice daily, usually controls more aggressive papular and pustular lesions and helps treat ocular lesions. Oral antibiotics should be discontinued once clearance of the inflammatory lesions is obtained; usually, 2 or 3 months is necessary. The topical approved preparations listed earlier should be used as long-term maintenance after clearance with the oral medications, because the disease will recur in most patients if all therapy is stopped. If significant ocular symptoms are present, oral antibiotics are an effective and convenient method of relieving both the skin and the eye concerns. Isotretinoin given in lower doses than in acne vulgaris (0.3 mg/kg), and at times as a long-term suppressant, may be necessary for management of more resistant disease, including patients with a granulomatous histology. Isotretinoin produces dramatic improvement even in cases resistant to other forms of therapy, but relapse often occurs in a few weeks or months. The authors rarely use oral metronidazole (side effects) or the macrolides (lack of efficacy) despite their reported utility in rosacea.

Oral medications for reduction of flushing are infrequently helpful. Occasionally, an escalating dose of propranolol, carvedilol, or clonidine is helpful in reducing symptomatic flushing, but most affected patients find the side effects occur before the beneficial effects are evident. One method is to start propranolol at 10 mg three times daily, and if no response is seen in 2 weeks, to increase the dose by 10 mg at one dose, then again every 2 weeks until side effects require discontinuation or response occurs. Responses are mostly seen at a dose of 20–40 mg three times daily.

## Surgical intervention

Surgical approaches to the reshaping of rhinophyma have included the use of a heated scalpel, electrocautery, dermabrasion, laser ablation, tangential excision combined with scissors sculpting, and radiofrequency electrosurgery. Often, a combination of these approaches is used to obtain the best esthetic result. Lasers and light devices are useful for treating the erythema and telangiectases, but the cost is not covered by insurance, which limits their availability. In a comparative study, the pulsed dye laser and intense pulsed-light device both significantly reduced erythema, telangiectasia, and patient-reported symptoms and performed similarly well. Some vascular and CO<sub>2</sub> fractionated lasers may also help in dermal collagen remodeling and nonablative rejuvenation, such that the dermal matrix may be strengthened. For the patient incapacitated by flushing, burning, and stinging, endoscopic transthoracic sympathectomy may be considered, but this extreme measure should only rarely be considered because serious complications may result. An approach to these patients should include only the medications previously discussed, but for those with significant dysesthesia, treatment with neuroleptics (e.g., gabapentin), tricyclic antidepressants, and pain-modifying antidepressants (e.g., duloxetine) may be necessary.

An advocacy group that supports research and education in rosacea, the National Rosacea Society, is an excellent resource for patients.

**Barzilai A, et al:** Cutaneous B-cell neoplasms mimicking granulomatous rosacea or rhinophyma. *Arch Dermatol* 2012; 148:824–831.

**Craige H, et al:** Symptomatic treatment of idiopathic and rosacea-associated cutaneous flushing with propranolol. *J Am Acad Dermatol* 2005; 53:881.

**Del Rosso JQ:** Management of facial erythema of rosacea. *J Am Acad Dermatol* 2013; 69:S44–S56.

**Del Rosso JQ, et al:** Consensus recommendations from the American Acne and Rosacea Society on the management of rosacea. Part 1. *Cutis* 2013; 92:234–240.

**Elewski BE, et al:** Rosacea. *J Eur Acad Dermatol Venereol* 2011; 25:188–200.



**Garg G, et al:** Clinical efficacy of tacrolimus in rosacea. *J Eur Acad Dermatol Venereol* 2009; 23:239.

**Hsu C-C, et al:** Carvedilol for the treatment of refractory flushing and persistent erythema of rosacea. *Arch Dermatol* 2011; 147:1258–1260.

**Izikson L, et al:** The flushing patient. *J Am Acad Dermatol* 2006; 55:193.

**Kilty S, et al:** Surgical treatment of rhinophyma. *J Otolaryngol Head Neck Surg* 2008; 37:269.

**Kim M-B et al:** Pimecrolimus 1% cream for the treatment of rosacea. *J Dermatol* 2011; 38:1135–1139.

**Neuhaus IM, et al:** Comparative efficacy of nonpurpuragenic pulsed dye laser and intense pulsed light for erythematotelangiectatic rosacea. *Dermatol Surg* 2009; 35:920.

**Ogunleye T, et al:** Ethanol-induced flushing with topical pimecrolimus use. *Dermatitis* 2008; 19:E1.

**Rallis E, Korfitis C:** Isotretinoin for the treatment of granulomatous rosacea: case report and review of the literature. *J Cutan Med Surg* 2012; 16:438–441.

**Scharschmidt TC, et al:** Neurogenic rosacea. *Arch Dermatol* 2011; 147:123–125.

**Schram AM, et al:** Neurogenic rosacea treated with endoscopic thoracic sympathectomy. *Arch Dermatol* 2012; 148:270–271.

**Steinhoff M, et al:** New insights into rosacea pathophysiology. *J Am Acad Dermatol* 2013; 69:S15–S26.

**Swanson LA, et al:** Allergic contact dermatitis to topical brimonidine tartrate gel 0.33% for treatment of rosacea. *J Am Acad Dermatol* 2014; 71:832.

**Taieb A, et al:** Superiority of ivermectin 1% cream over metronidazole 0.75% cream in treating inflammatory lesions of rosacea. *Br J Dermatol* 2014; Sep 16.

**Tan J, et al:** Rosacea: current state of epidemiology. *J Am Acad Dermatol* 2013; 69:S27–S35.

**Tanghetti E, et al:** Consensus recommendations from the American Rosacea Society on the management of rosacea. Part 4. *Cutis* 2014; 93:71.

**Teraki Y, et al:** Tacrolimus-induced rosacea-like dermatitis. *Dermatology* 2012; 224:309–314.

**Uslu M, et al:** Rosacea treatment with intermediate-dose isotretinoin. *Acta Derm Venereol* 2013; 92:73–77.

**Van Zuuren E, et al:** Interventions for rosacea. *Cochrane Database Syst Rev* 2011; 3:CD003262.

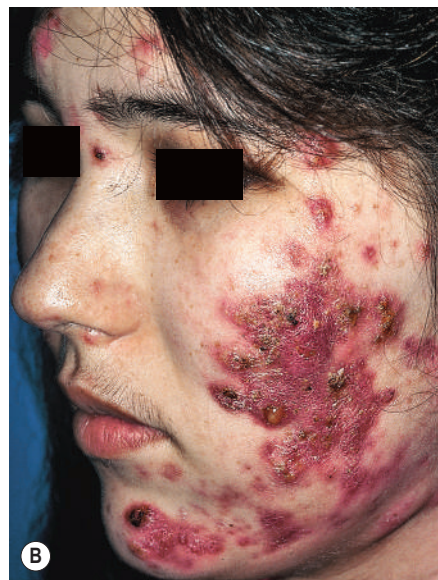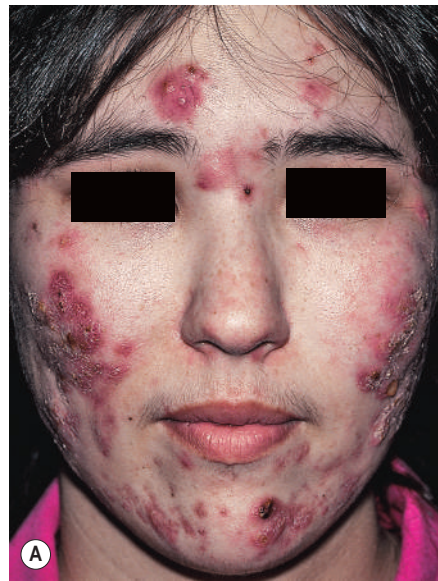
**Van Zuuren EJ, et al:** Effective and evidence-based management strategies for rosacea. *Br J Dermatol* 2011; 165:760–781.

**Vieira AC, et al:** Ocular rosacea. *J Am Acad Dermatol* 2013; 69:S36–S41.

## PYODERMA FACIALE

Pyoderma faciale is an uncommon eruptive facial disorder consisting of a dramatically fulminant onset of superficial and deep abscesses, cystic lesions (Fig. 13-27), and sometimes sinus tracts. Edema and at times an intense reddish or cyanotic erythema accompany this pustular process. The lesions often contain greenish or yellowish purulent material. Older cysts contain an oily substance. The condition occurs mostly in post-adolescent women. It is distinguished from acne by the absence of comedones, rapid onset, fulminating course, and absence of acne on the back and chest. Pyoderma faciale is differentiated from rosacea by the inconsistent history of flushing, the absence of preexisting erythema or telangiectases of the convex portions of the face, and the large abscesses and nodules. After therapy, a residual erythema often persists. This condition is also known as rosacea fulminans, a designation many prefer after Plewig categorized it as such.

Treatment is similar to that of acne fulminans. Oral steroids are given for several weeks, followed by the addition of isotretinoin, 10–20 mg, increasing to 0.5–1 mg/kg only after the acute inflammatory component is well under control. Steroids may usually be discontinued after several weeks of isotretinoin, but the latter should be given for a full 120–150 mg/kg total dose. Because patients are predominately women of childbearing age, pregnancy issues require full discussion.



**Fig. 13-27** A and B, Pyoderma faciale. (Courtesy of Curt Samlaska, MD.)

Indeed, four of Plewig et al.'s patients were pregnant and thus could not use isotretinoin. In such patients, amoxicillin, erythromycin, azithromycin, or clindamycin, all pregnancy category B drugs, may be considered.

**Crawford GH, et al:** Pyoderma faciale. *J Am Acad Dermatol* 2005; 53:1106.

**Fender AB, et al:** Pyoderma faciale. *Cutis* 2008; 81:488.

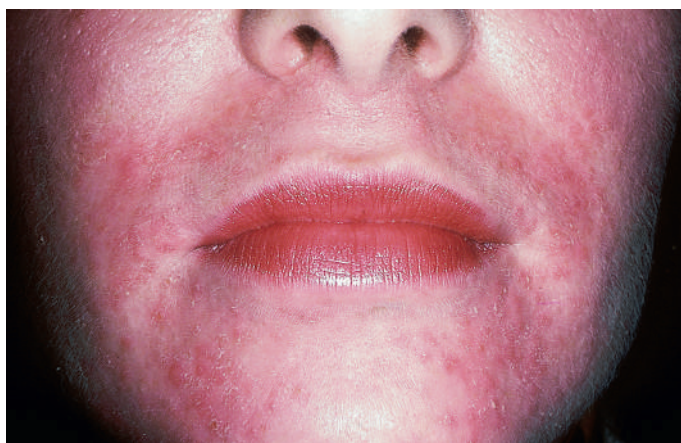**Fuentelsaz V, et al:** Rosacea fulminans in pregnancy: successful treatment with azithromycin. *Clin Exp Dermatol* 2011; 36:674–676.

**Plewig G, et al:** Pyoderma faciale. *Arch Dermatol* 1992; 128:1611.

**Ribeiro LB, et al:** Rosacea fulminans. *Cutis* 2013; 92:29–32.

## PERIORAL DERMATITIS

Perioral dermatitis is a common eruption consisting of discrete papules and pustules on an erythematous and at times scaling base. It is a distinctive dermatitis confined symmetrically around the mouth, with a clear zone of about 5 mm between the vermilion border and the affected skin (Fig. 13-28). There is no itching, although an uncomfortable burning sensation may be present. It occurs almost exclusively in women age 20–35. The use of fluorinated topical corticosteroids is the most frequently identified cause. Exposure may be in the form of creams, ointments, or inhalers.



**Fig. 13-28** Perioral dermatitis.

Treatment of perioral dermatitis includes discontinuing topical corticosteroids or protecting the skin from the inhaled product. Additionally, doxycycline will lead to control. Tacrolimus ointment 0.1% or pimecrolimus cream will prevent flaring after stopping steroid use. In patients without steroid exposure, oral or topical antibiotics and topical adapalene, azelaic acid, and metronidazole have all been successful in clearing the eruption.

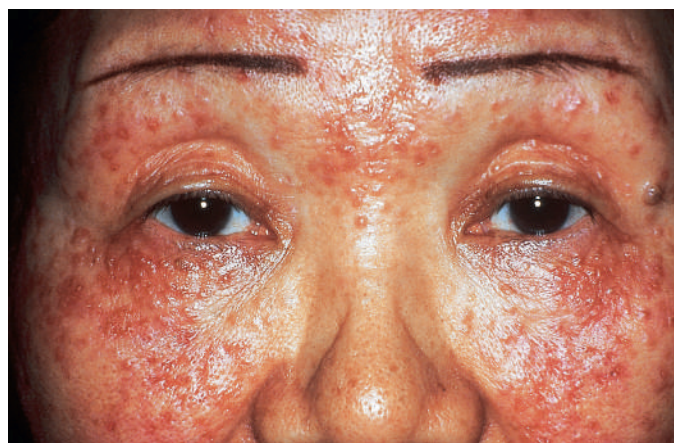
### Periorbital dermatitis

Periorbital (periocular) dermatitis is a variant of perioral dermatitis occurring on the lower eyelids and skin adjacent to the upper and lower eyelids. Fluorinated topical corticosteroids have been implicated as the cause. If intranasal inhaled corticosteroids are used, a perinasal distribution may be seen. Prompt response to the same treatment employed in the perioral site is expected.

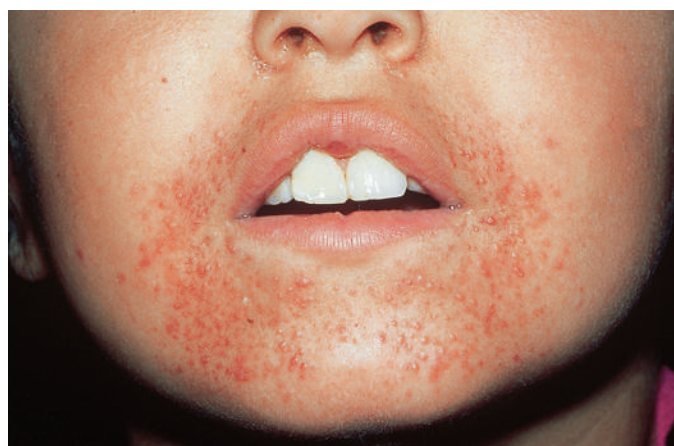- Feser A, et al:** Periorbital dermatitis. *J Dtsch Dermatol Ges* 2010; 8:159–165.
- Hall CS, et al:** Evidence based review of perioral dermatitis therapy. *G Ital Dermatol Venereol* 2010; 145:433–444.
- Peralta L, et al:** Perioral dermatitis. *Cutan Ocul Toxicol* 2012; 31:160–163.
- Poulos GA, et al:** Perioral dermatitis associated with an inhaled corticosteroid. *Arch Dermatol* 2007; 142:1460.
- Schwarz T, et al:** A randomized, double-blind, vehicle-controlled study of 1% pimecrolimus cream in adult patients with perioral dermatitis. *J Am Acad Dermatol* 2008; 59:34.
- Tempark T, et al:** Perioral dermatitis. *Am J Clin Dermatol* 2014; 15:101.
- Wollenberg A, et al:** Perioral dermatitis. *J Dtsch Dermatol Ges* 2011; 9:422–427.

## GRANULOMATOUS FACIAL DERMATITIS

Several dermatoses of the face characterized by granulomas are included in this category. Patients with persistent facial erythema involving one or more convex surfaces of the face may have lesions that show a granulomatous reaction histologically, and they are included within rosacea. Some patients have no other stigmata of rosacea, and their nosology is unclear. These other entities, which meet no other criteria for rosacea other than having pink papules on the face, are included here. Skowron et al. proposed the term facial idiopathic granulomas with regressive evolution (FIGURE).



**Fig. 13-29** Lupus miliaris.



**Fig. 13-30** Childhood granulomatous facial dermatitis.

### Lupus miliaris disseminatus faciei

Firm, yellowish-brown or red, 1–3 mm, monomorphic, smooth-surfaced papules are present not only on the butterfly areas but also on the lateral areas, below the mandible, and periorificially (Fig. 13-29). The eyelid skin is characteristically involved in patients with lupus miliaris disseminatus faciei (LMDF). The discrete papules appear as yellowish brown lesions on diascopy and as caseating epithelioid cell granulomas histologically. Patients usually lack a history of flushing, do not have persistent erythema or telangiectasia, have involvement of the eyelids, and heal with scarring, as opposed to rosacea patients. Long-term therapy with minocycline or isotretinoin may be used, often with gratifying results. Eventually, self-involution is expected but may take several years. Tranilast helped two patients with LMDF.

### Granulomatous perioral dermatitis in children

In otherwise healthy prepubertal children, a profusion of grouped papules may develop on the perioral, periocular, and perinasal areas (Fig. 13-30). Eight of the initial 59 reported patients also had generalized lesions. Besides extremity and truncal lesions, several girls had dramatic lesions of the labia majora. Both genders are affected equally. Children with skin of color (Afro-Caribbean, African American, and Asian) dominate the reports, but white patients are also susceptible. Because the histologic appearance is granulomatous,



sarcoidosis is often considered. Topical corticosteroids, however, may worsen the condition, and systemic involvement is not present. Topical metronidazole, erythromycin, sulfacetamide-sulfur combinations, and an oral macrolide or tetracycline-type antibiotic all are often effective. In some patients, the combination of prednisone and dapsone has proved beneficial.

**Al-Mutairi N:** Nosology and therapeutic options for lupus miliaris disseminatus faciei. *J Dermatol* 2011; 38:864–873.

**Amiruddin D, et al:** Clinical evaluation of 35 cases of lupus miliaris disseminatus faciei. *J Dermatol* 2010; 37:618–620.

**Gutte R, et al:** Childhood granulomatous periorificial dermatitis in children with extrafacial involvement. *Indian J Dermatol Venereol Leprol* 2011; 77:703–706.

**Koike Y, et al:** Lupus miliaris disseminatus faciei successfully treated with tranilast: report of two cases. *J Dermatol* 2011; 38:588–592.

**Lucas CR, et al:** Granulomatous periorificial dermatitis. *J Cutan Med Surg* 2009; 13:115.

**Skowron F, et al:** FIGURE: facial idiopathic granulomas with regressive evolution. *Dermatology* 2000; 201:289.



Bonus images for this chapter can be found online at

[expertconsult.inkling.com](http://expertconsult.inkling.com)

**eFig. 13-1** Upper chest involvement with acne.

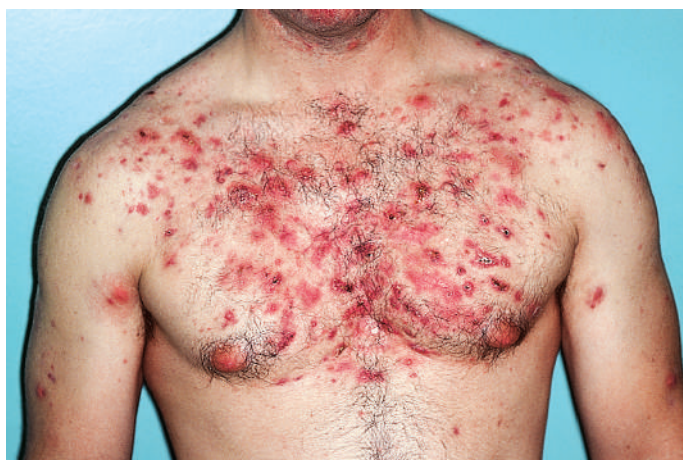**eFig. 13-2** Minocycline-induced pigmentation at sites of inflammation in patient with acne.

**eFig. 13-3** Staphylococcal infection in patient taking isotretinoin. (Courtesy of Curt Samlaska, MD.)

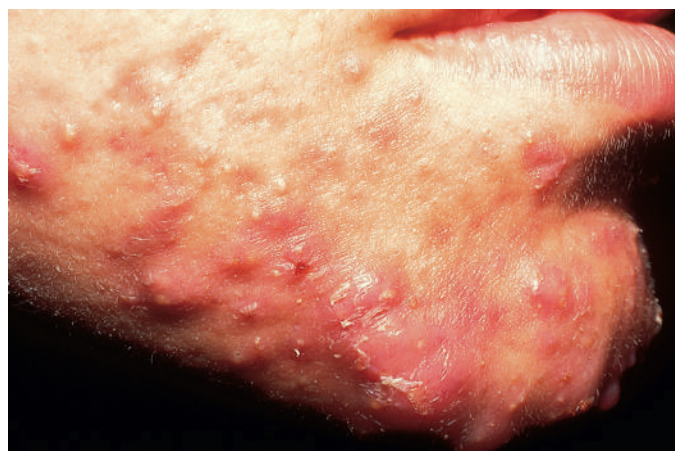**eFig. 13-4** Acne conglobata.

**eFig. 13-5** Rosacea.

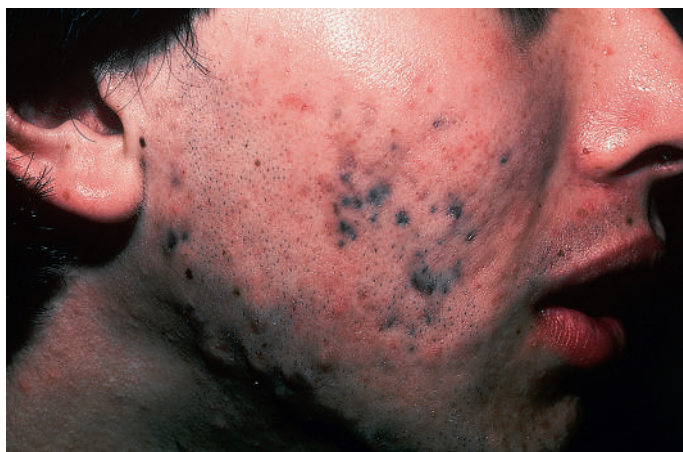**eFig. 13-6** Steroid rosacea.



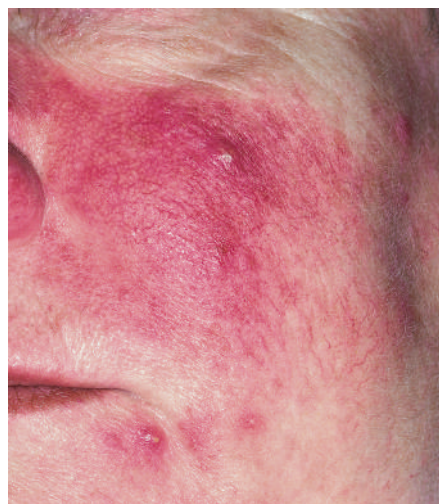**eFig. 13-1** Upper chest involvement with acne.



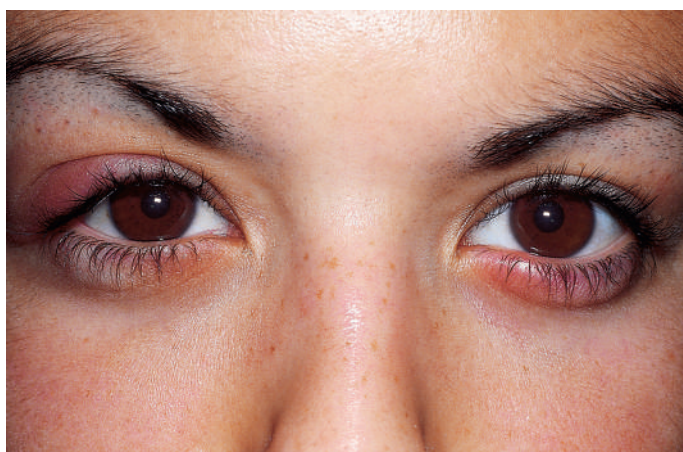**eFig. 13-4** Acne conglobata.



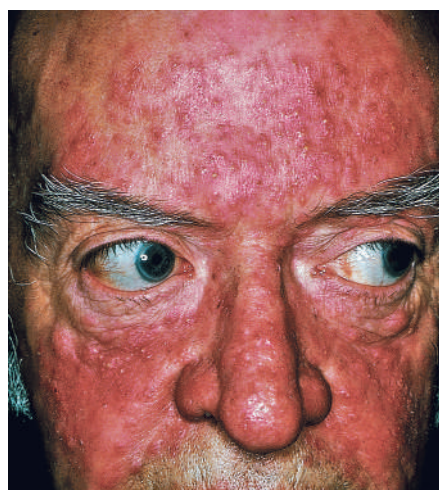**eFig. 13-2** Minocycline-induced pigmentation at sites of inflammation in patient with acne.



**eFig. 13-5** Rosacea.



**eFig. 13-3** Staphylococcal infection in patient taking isotretinoin. (Courtesy of Curt Samlaska, MD.)



**eFig. 13-6** Steroid rosacea.



## Bacterial Infections

Bacterial infections in the skin often have distinct morphologic characteristics that should alert the clinician that a potentially treatable and reversible condition exists. These cutaneous signs may be an indication of a generalized systemic process or simply an isolated superficial event. Immunodeficiencies with low immunoglobulin levels, neutropenia, reduced neutrophil migration or killing, and disease caused by the human immunodeficiency virus (HIV) may be associated with severe or refractory pyogenic infections. Patients with atopic dermatitis and syndromes with atopic-like dermatitis are also predisposed to bacterial infections. The categorization of bacterial infections in this chapter first addresses diseases caused by gram-positive bacteria, followed by those caused by gram-negative bacteria, and then several miscellaneous diseases caused by the rickettsiae, mycoplasmas, chlamydiae, and spirochetes.

**Centers for Disease Control and Prevention:** STD treatment guidelines 2010. *MMWR* 2010; 59(RR-12):1–110.

**Chon SY, et al:** Antibiotic overuse and resistance in dermatology. *Dermatol Ther* 2012; 25:55–69.

**Dawson AL, et al:** Infectious skin diseases. *Dermatol Clin* 2012; 30:141–151.

**Drucker CR:** Update on topical antibiotics in dermatology. *Dermatol Ther* 2012; 25:6–11.

**Dumville JC, et al:** Preoperative skin antiseptics for preventing surgical wound infections after clean surgery. *Cochrane Database Syst Rev* 2013; 3:CD003949.

**Grice EA, et al:** Topographical and temporal diversity of the human skin microbiome. *Science* 2009; 324:1190.

**Mistry RD:** Skin and soft tissue infections. *Pediatr Clin North Am* 2013; 60:1063–1082.

**Petry V, et al:** Bacterial skin colonization and infections in patients with atopic dermatitis. *An Bras Dermatol* 2012; 87:729–734.

### INFECTIONS CAUSED BY GRAM-POSITIVE ORGANISMS

#### STAPHYLOCOCCAL INFECTIONS

The skin lesions induced by the gram-positive staphylococci usually appear as pustules, furuncles, or erosions with honey-colored crusts. However, bullae, widespread erythema and desquamation, or vegetating pyodermas may also be indicators of *Staphylococcus aureus* infection. Purulent purpura may indicate bacteremia or endocarditis caused by *S. aureus* or, in immunocompromised patients, *S. epidermidis*. Two distinctive cutaneous lesions that occur with endocarditis are the Osler node and Janeway lesion or spot. The Osler node is a painful, erythematous nodule with a pale center located on the fingertips. The Janeway spot is a nontender, angular hemorrhagic lesion of the soles and palms (Fig. 14-1). These lesions are likely caused by septic emboli.

*Staphylococcus aureus* is a normal inhabitant of the anterior nares in 20–40% of adults and also resides on the hands and perineum in smaller numbers of individuals. Nasal carriers are particularly prone to infections with *S. aureus* because of its continuous presence on the skin and nasal mucosa. Spread of infection in the hospital setting is frequently traced to the hands of a health care worker. Proper handwashing technique is essential in preventing this nosocomial complication. HIV-infected patients are at least twice as often nasal carriers, and they tend to harbor *S. aureus* in higher frequency and density at other sites of the body, thus predisposing them to skin and systemic infection.

Antibiotic resistance has become a clinically important consideration in many infections. Methicillin-resistant *Staphylococcus aureus* (MRSA) is an important pathogen in nosocomial and community-acquired skin infections. MRSA infection may be suspected from knowledge of local patterns of resistance, lack of response to initial methicillin-sensitive *S. aureus* (MSSA)-directed therapy (e.g., cefalexin), and factors predisposing to colonization and infection with this organism. Predisposing factors include age (>65), exposure to others with MRSA infection, prior antibiotic therapy, trauma to the skin, rectal or nasal colonization, crowded households, child care attendance, contact sports, chronic skin disease, pets, and recent hospitalization or chronic illness. In patients with risk factors, multidrug resistance is likely, and treatment with intravenous (IV) vancomycin or linezolid may be necessary. In community-acquired infection in patients without risk factors, clindamycin, trimethoprim-sulfamethoxazole (TMP-SMX, alone or combined with rifampin), doxycycline, or oral linezolid often are effective. TMP-SMX and doxycycline do not cover group A streptococci; therefore, if a mixed infection is suspected, adding cephalexin or penicillin is necessary, or clindamycin alone will treat both pathogens. Definitive antibiotic therapy may be tailored to the antibiotic susceptibility of the cultured organism.

#### Superficial pustular folliculitis (impetigo of Bockhart)

Bockhart impetigo is a superficial folliculitis with thin-walled pustules at the follicle orifices. Susceptible locations are the extremities and scalp, although it is also seen on the face, especially periorally. These fragile, yellowish white, domed pustules develop in crops and heal in a few days. *S. aureus* is the most frequent cause. The infection may secondarily arise in scratches, insect bites, or other skin injuries.

#### Sycosis vulgaris (sycosis barbae)

Sycosis vulgaris, also known as “barber’s itch” or sycosis barbae, is a perifollicular, chronic, pustular staphylococcal

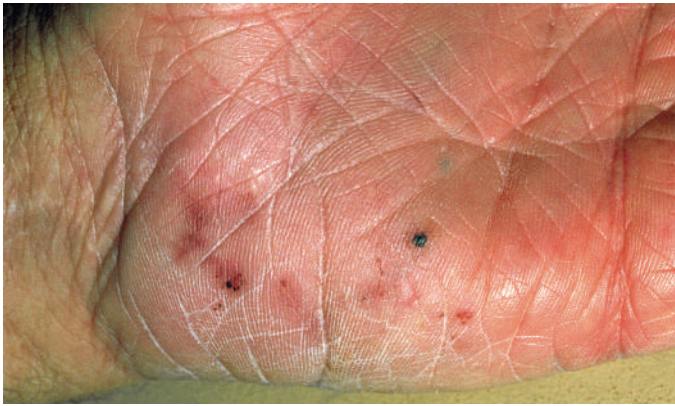

Fig. 14-1 Janeway lesion in subacute bacterial endocarditis.

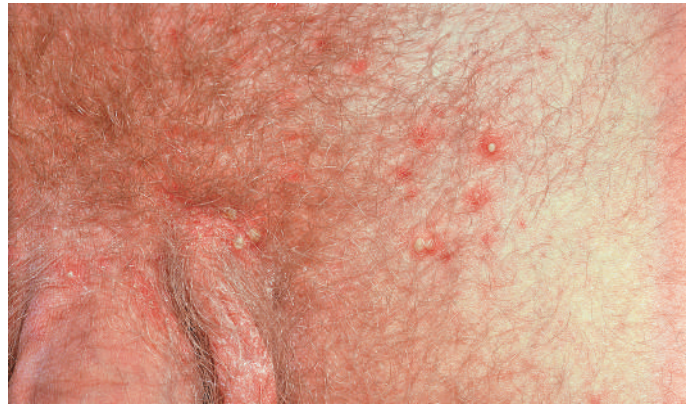

Fig. 14-3 Staphylococcal folliculitis.

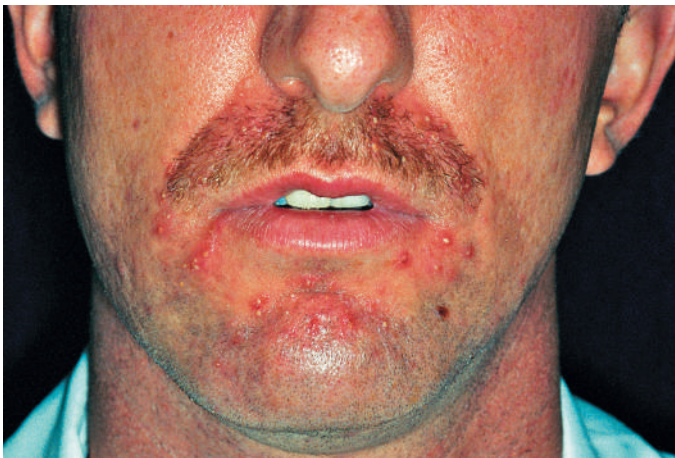

Fig. 14-2 Sycosis barbae.

infection of the bearded region characterized by inflammatory papules and pustules, and a tendency to recurrence (Fig. 14-2). The disease begins with erythema and burning or itching, usually on the upper lip near the nose. In 1 or 2 days, one or more pinhead-sized pustules, pierced by hairs, develop. These rupture after shaving or washing and leave an erythematous spot, which is later the site of a fresh crop of pustules. In this manner, the infection persists and gradually spreads, at times extending deep into the follicles. A hairless, atrophic scar bordered by pustules and crusts may result. Marginal blepharitis with conjunctivitis is usually present in severe cases of sycosis.

Sycosis vulgaris is to be distinguished from tinea, acne vulgaris, pseudofolliculitis barbae, and herpetic sycosis. Tinea barbae rarely affects the upper lip, which is a common location for sycosis. In tinea barbae, involvement is usually in the sub-maxillary region or on the chin, and spores and hyphae are found in the hairs. Pseudofolliculitis barbae manifests torpid papules at sites of ingrowing beard hairs in black men. In herpes simplex virus (HSV) infection, duration is usually only a few days, and even in persistent cases there are vesicles, which help to differentiate HSV from sycosis vulgaris.

### Folliculitis

Staphylococcal folliculitis may affect areas such as the eyelashes, axillae, pubis, and thighs (Fig. 14-3). On the pubis, it may be transmitted among sexual partners, and “mini” epidemics of folliculitis and furunculosis of the genital and gluteal areas may be considered a sexually transmitted disease (STD). Staphylococcal folliculitis has also been reported frequently in

patients with acquired immunodeficiency syndrome (AIDS) and may be a cause of pruritus. An atypical, plaquelike form has been reported.

### Treatment

Deep lesions of folliculitis represent small follicular abscesses and must be drained. Superficial pustules will rupture and drain spontaneously. Many patients will heal with drainage and topical therapy. Bacitracin (Bactroban) or retapamulin ointment and topical clindamycin (Cleocin) solution are effective topical agents. Skin surface staphylococcal carriage in abrasions and eczematous areas may be addressed with these topical antibiotics, topical chlorhexidine, or bleach baths ( $\frac{1}{2}$  cup bleach added to tub of bathwater). If drainage and topical therapy fail, or if there is accompanying soft tissue infection, a first-generation cephalosporin or penicillinase-resistant penicillin (e.g., dicloxacillin) is indicated, unless MRSA is suspected (see earlier). When the inflammation is acute, hot wet soaks with aluminum acetate (Burow) solution diluted 1:20 (Domeboro) are beneficial. An anhydrous formulation of aluminum chloride (Drysol, Xerac-AC) is effective when used once nightly for chronic folliculitis, especially of the buttocks. Antibiotic ophthalmic ointments are used for blepharitis.

### Furunculosis

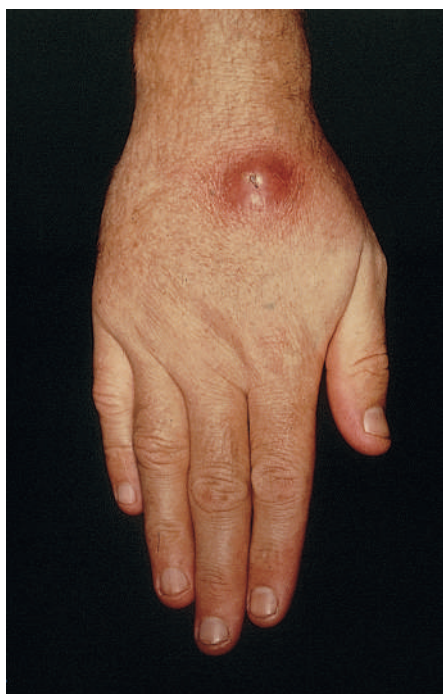A furuncle, or boil, is an acute, round, tender, circumscribed, perifollicular staphylococcal abscess that generally ends in central suppuration (Fig. 14-4). A carbuncle is merely two or more confluent furuncles, with separate heads.

The lesions begin in hair follicles and often continue for a prolonged period by autoinoculation. Some lesions disappear before rupture, but most undergo central necrosis and rupture through the skin, discharging purulent, necrotic debris. Sites of predilection are the nape, axillae, and buttocks, but boils may occur anywhere.

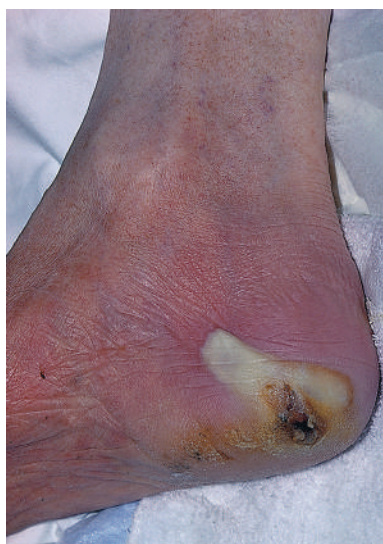The integrity of the skin surface may be impaired by irritation, pressure, friction, hyperhidrosis, dermatitis, dermatophytosis, shaving, and other factors. Local barrier compromise predisposes to infection by providing a portal of entry for the ubiquitous *S. aureus*. The proximate cause is either contagion or autoinoculation from a carrier focus, usually in the nose or groin.

Certain systemic disorders may predispose to furunculosis: alcoholism; malnutrition; blood dyscrasias; disorders of neutrophil function; iatrogenic or other immunosuppression (e.g., AIDS); and diabetes (Fig. 14-5). Patients with several of these diseases, as well as those receiving renal dialysis or





**Fig. 14-4**  
Staphylococcal  
abscess.



**Fig. 14-5** Staphylococcal  
abscess in a diabetic  
patient.

isotretinoin or acitretin therapy, are often nasal carriers of *S. aureus*. Additionally, atopic dermatitis also predisposes to the *S. aureus* carrier state, which helps explain the observed increases in the incidence of infections in these diseases.

### Hospital furunculosis

Epidemics of staphylococcal infections occur in hospitals. Marked resistance to antibacterial agents in these cases is common. Attempts to control these outbreaks center on meticulous handwashing. In nurseries, a fall in neonatal colonization and infections with *S. aureus* and non-group A streptococci may be achieved by using a 4% solution of chlorhexidine for skin and umbilical cord care.

### Treatment

When the lesions are incipient and acutely inflamed, incision should be strictly avoided, and warm compresses and oral

antibiotics are administered. A penicillinase-resistant penicillin or first-generation cephalosporin should be given orally in a dose of 1–2 g/day, according to the severity of the case. Methicillin-resistant and even vancomycin-resistant strains occur and, if suspected, are treated with trimethoprim-sulfamethoxazole double strength twice daily, clindamycin 300 to 450 mg three times daily, or doxycycline or minocycline 100 mg two times daily. In patients with staphylococcal infections unresponsive to these usual measures, antibiotic-resistant strains should be suspected and sensitivities checked. Mupirocin ointment applied to the anterior nares daily for 5 days and bleach baths may help prevent recurrence.

When the furuncle has become localized and shows definite fluctuation, incision with drainage is indicated. The cavity should be packed with iodoform or petrolatum gauze. In these cases, oral antibiotics are not usually necessary. Indications for antibiotics in addition to drainage are high fever, lesion larger than 5 cm or located in a critical location or difficult-to-drain area, multiple furuncles, or signs and symptoms persisting after drainage.

In boils of the external auditory canal, upper lip, and nose, incision and drainage are generally only performed if antibiotic therapy fails. In these patients, antibiotic ointment should be applied and antibiotics given internally. Warm saline-solution compresses should be applied liberally.

### Chronic furunculosis

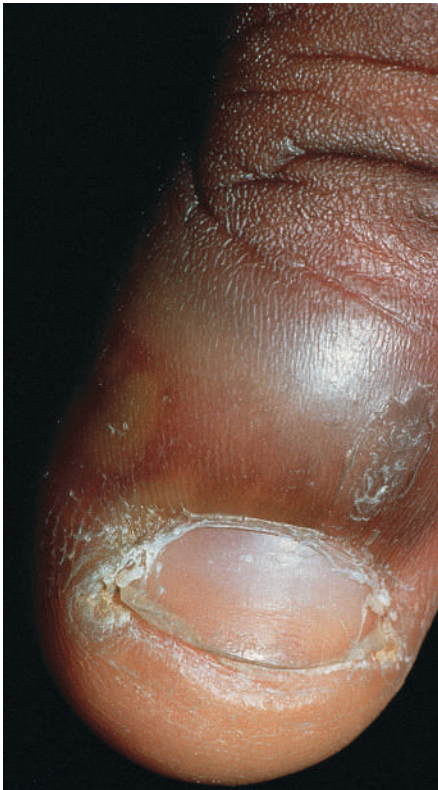Despite treatment, recurrences of some boils may be anticipated. Usually, no underlying predisposing disease is present; rather, autoinoculation and intrafamilial spread among colonized individuals are responsible.

One of the most important factors in prevention is to avoid autoinoculation. It is important to emphasize that the nasal carrier state predisposes to chronic furunculosis. The skin surface in the region of the furuncles may be a source of colonization, especially if there are cuts, excoriation, or eczematous changes. In addition, the hazard of contamination from the perianal and intertriginous areas must be considered. In general, indications for elimination of the carriage state are recurrent infection, evidence of spread to others, and high-risk individuals in the household.

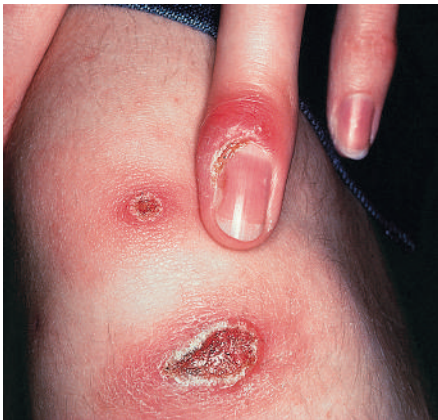Routine precautions to take in attempting to break the cycle of recurrent furunculosis include a daily chlorhexidine wash, with special attention to the axillae, groin, and perianal area; laundering of bedding and clothing on a daily basis initially; use of bleach baths; and frequent handwashing. Additionally, the application of mupirocin ointment twice daily to the nares of patients and family members every fourth week has been found to be effective. Rifampin (600 mg/day) for 10 days, combined with dicloxacillin for MSSA or TMP-SMX for MRSA, or low-dose (150 mg/day) clindamycin for 3 months is also effective in eradicating the nasal carriage state. The use of bacitracin ointment inside the nares twice daily throughout the course of isotretinoin therapy eliminates, or greatly reduces, the risk of inducing nasal carriage of *S. aureus* and thus staphylococcal infections.

### Pyogenic paronychia

Paronychia is an inflammatory reaction involving the folds of the skin surrounding the fingernail. It is characterized by acute or chronic purulent, tender, and painful swellings of the tissues around the nail, caused by an abscess in the nail-fold. When the infection becomes chronic, horizontal ridges appear at the base of the nail. With recurrent bouts, new ridges appear.



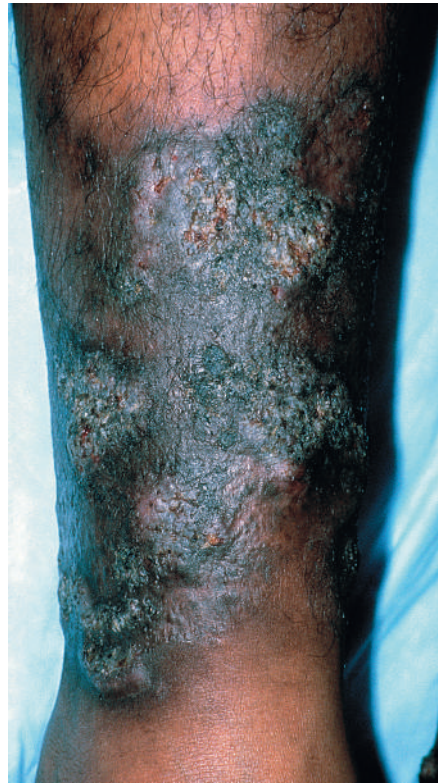**Fig. 14-6**  
Staphylococcal  
paronychia.



**Fig. 14-7**  
Streptococcal  
paronychia and  
impetigo.

The primary predisposing factor that is identifiable is separation of the eponychium from the nail plate. The separation is usually caused by trauma as a result of moisture-induced maceration of the nailfolds from frequent wetting of the hands. The relationship is close enough to justify treating chronic paronychia as a work-related condition in bartenders, food servers, nurses, and others who often wet their hands. The moist grooves of the nail and nailfold become secondarily invaded by pyogenic cocci and yeasts. The causative bacteria are usually *S. aureus*, *Streptococcus pyogenes*, *Pseudomonas* species, *Proteus* species, or anaerobes. The pathogenic yeast is most frequently *Candida albicans*.

The bacteria usually cause acute abscess formation (*Staphylococcus*; Fig. 14-6) or erythema and swelling (*Streptococcus*; Fig. 14-7), and *C. albicans* most frequently causes a chronic swelling. If an abscess is suspected, applying light pressure with the index finger against the distal volar aspect of the affected digit will better demonstrate the extent of the collected pus by inducing a well-demarcated blanching. Smears of purulent material will help confirm the clinical impression. Myrmecial



**Fig. 14-8**  
Botryomycosis.

warts may mimic paronychia. Subungual black macules, followed by edema, pain, and swelling, have been reported as a sign of osteomyelitis caused by *S. aureus* or *Streptococcus viridans*, in children with atopic dermatitis.

Treatment of pyogenic paronychia consists mostly of protection against trauma and concentrated efforts to keep the affected fingernails meticulously dry. Rubber or plastic gloves over cotton gloves should be used whenever the hand must be placed in water. Acutely inflamed pyogenic abscesses should be incised and drained. The abscess may often be opened by pushing the nailfold away from the nail plate. In acute suppurative paronychia, especially if stains show pyogenic cocci, a semisynthetic penicillin or a cephalosporin with excellent staphylococcal activity should be given orally. If these are ineffective, MRSA or a mixed-anaerobic bacteria infection should be suspected. TMP-SMX for the latter or treatment dictated by the sensitivity of the cultured organism will improve cure rates. Rarely, long-term antibiotic therapy may be required.

While *Candida* is the most frequently recovered organism in chronic paronychia, topical or oral antifungals lead to cure in only about 50% of cases. If topical corticosteroids are used to decrease inflammation and allow for tissue repair, cure results more reliably (almost 80% in one study). Often, an antifungal liquid such as miconazole is combined with a topical corticosteroid cream or ointment.

### Botryomycosis

Botryomycosis is an uncommon, chronic, indolent disorder characterized by nodular, crusted, purulent lesions (Fig. 14-8). Sinuses that discharge sulfur granules are present. These heal with atrophic scars. The granules most frequently yield *S. aureus* on culture, although cases caused by *Pseudomonas aeruginosa*, *Escherichia coli*, *Proteus*, *Bacteroides*, and *Streptococcus* have been reported. Botryomycosis often occurs in patients with altered immune function, such as those with neutrophilic



defects. Other predisposing factors include diabetes, HIV infection, alcoholism, and Job syndrome. Appropriate antibiotics, surgical drainage, and surgical excision are methods used to treat botryomycosis.

### Blastomycosis-like pyoderma

Large, verrucous plaques with elevated borders and multiple pustules occur. Most patients with blastomycosis-like pyoderma have some underlying systemic or local host compromise. Bacteria such as *S. aureus*, *P. aeruginosa*, *Proteus*, *E. coli*, or streptococci may be isolated. Antibiotics appropriate for the organism isolated are curative; however, response may be delayed and prolonged therapy required. Acitretin may also be useful.

### Pyomyositis

*Staphylococcus aureus* abscess formation within the deep, large, striated muscles usually presents with fever and muscle pain. It is typically hematogenous in origin. Pyomyositis is more common in the tropics, where it may affect adults but most frequently occurs in children. In temperate climates, it occurs in children and patients with AIDS. The most frequent site in tropical disease is the thigh, whereas in HIV-infected patients, the deltoid muscle is most often involved, followed closely by the quadriceps. Swelling and occasionally erythema or yellow or purplish discoloration are visible signs of pyomyositis, but these are late findings. Non-*S. aureus* infections may also cause this same clinical picture. Magnetic resonance imaging (MRI) with gadolinium injection will help delineate the extent of disease. Drainage of the abscess and appropriate systemic antibiotics are the recommended treatment.

### Impetigo contagiosa

Impetigo contagiosa is a staphylococcal, streptococcal, or combined infection characterized by discrete, thin-walled vesicles that rapidly become pustular and then rupture. Impetigo occurs most frequently on the exposed parts of the body: the face, hands, neck, and extremities (Fig. 14-9). Impetigo on the scalp is a frequent complication of pediculosis capitis.

The disease begins with 2-mm erythematous macules, which may shortly develop into vesicles or bullae. As soon as these lesions rupture, a thin, straw-colored, seropurulent discharge

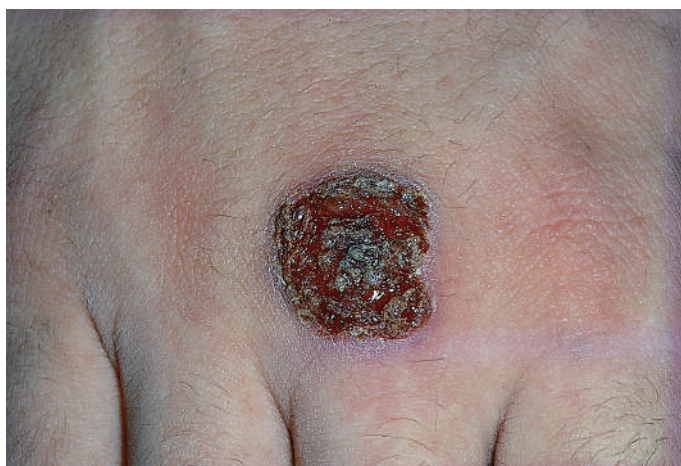

Fig. 14-9 Impetigo.

is noted. The exudate dries to form loosely stratified, golden-yellow crusts, which accumulate layer upon layer until they are thick and friable. The crusts can usually be removed readily, leaving a smooth, red, moist surface that soon collects droplets of fresh exudate again; these are spread to other parts of the body by fingers or towels. As the lesions spread peripherally and the skin clears centrally, large circles are formed by fusion of the spreading lesions to produce gyrate patterns. In streptococcal-induced impetigo, regional lymphadenopathy is common, but not serious.

Most studies find 50–70% of cases are caused by *S. aureus*, with the remainder from either *S. pyogenes* or a combination of these two organisms. Streptococci may represent an early pathogen in the development of impetigo, with staphylococci replacing streptococci as the lesion matures. Group B streptococci are associated with newborn impetigo, and groups C and G are rarely isolated from impetigo, unlike the usual group A.

Impetigo occurs most frequently in early childhood (Fig. 14-10), although all ages may be affected. It occurs in the temperate zone, mostly during the summer in hot, humid weather. Common sources of infection for children are pets, dirty fingernails, and other children in schools, day care centers, or crowded housing areas; sources for adults include infected children and self-inoculation from nasal or perineal carriage. Impetigo often complicates pediculosis capitis, scabies, HSV, insect bites, poison ivy, eczema, and other exudative, pustular, or itching skin diseases.

Group A  $\beta$ -hemolytic streptococcal skin infections are sometimes followed by acute glomerulonephritis (AGN). Nephritogenic streptococci are generally associated with impetigo rather than with upper respiratory tract infections. There is no evidence that AGN occurs with staphylococcal impetigo. The important factor predisposing to AGN is the serotype of the streptococcus producing the impetigo. Type 49, 55, 57, and 60 strains and strain M-type 2 are related to nephritis.

The incidence of AGN with impetigo varies from about 2% to 5% (10–15% with nephritogenic strains of streptococcus) and occurs most frequently in childhood, generally before age 6. The prognosis in children is mostly excellent, but in adults it is not as good. Treatment, however early and appropriate, is not believed to reduce the risk of AGN.

Impetigo may simulate several diseases. The circinate patches are frequently mistaken for ringworm, but clinically are quite different. Impetigo is characterized by superficial, very weepy lesions covered by thick, bright-yellow or orange crusts with loose edges, which do not resemble the scaling patches with peripheral erythema seen in tinea. Impetigo may be mistaken for *Toxicodendron* dermatitis, but it is more crusted and pustular and more likely to involve the nostrils, corners of the mouth, and ears. Impetigo is not associated with the

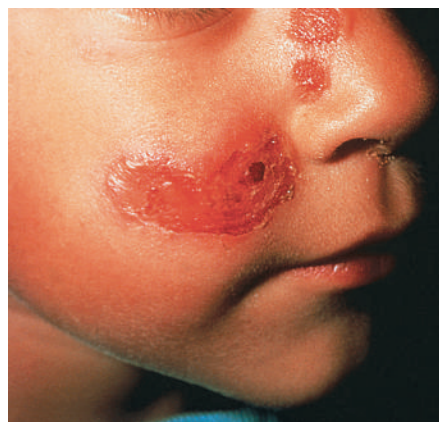

Fig. 14-10 Impetigo of early childhood.

eyelid puffiness, the linear lesions, or the itchiness typically present in dermatitis and caused by poison ivy or oak. In ecthyma, the lesions are crusted ulcers, not erosions.

## Treatment

Systemic antibiotics combined with topical therapy are recommended for patients with impetigo contagiosa. Because most cases are caused by *Staphylococcus*, a semisynthetic penicillin or a first-generation cephalosporin is recommended, unless MRSA is suspected, as detailed earlier. All treatment should be given for 7 days. It is necessary to soak off the crusts frequently, after which an antibacterial ointment should be applied. If the lesions are localized, especially if facial, and are present in an otherwise healthy child, topical therapy may be effective as the sole treatment.

Applying antibiotic ointment as a prophylactic to sites of skin trauma will prevent impetigo in high-risk children attending day care centers. In one study, infections were reduced by 47% with antibiotic ointment versus 15% with placebo. Additionally, if recurrent staphylococcal impetigo develops, a culture of the anterior nares may yield this organism. Such carrier states may be treated by application of mupirocin ointment to the anterior nares twice daily or by a 10-day course of rifampin, 600 mg/day, combined with dicloxacillin (for MSSA) or TMP-SMX (for MRSA).

## Bullous impetigo

The bullous variety of impetigo occurs characteristically in newborns, although it may occur at any age. The neonatal type is highly contagious and is a threat in nurseries. In most cases, the disease begins between the fourth and tenth days of life with the appearance of bullae, which may appear on any part of the body. Common early sites are the face and hands. Constitutional symptoms are absent at first, but weakness and fever or a subnormal temperature may be present later. Diarrhea with green stools frequently occurs. Bacteremia, pneumonia, or meningitis may develop rapidly, with fatal termination.

In warm climates particularly, adults may have bullous impetigo (Fig. 14-11), most often in the axillae or groins, but also on the hands. Usually, no scalp lesions are present. The lesions are strikingly large, fragile bullae, suggestive of pemphigus. When these rupture, they leave circinate, weepy, or crusted lesions, and in this stage it may be called impetigo circinata. Children with bullous impetigo may give a history of an insect bite at the site of onset of lesions. The majority are caused by phage types 71 or 55 coagulase-positive *S. aureus* or a related group 2 phage type. Bullous impetigo may be an early manifestation of HIV infection.

## Staphylococcal scalded skin syndrome

Staphylococcal scalded skin syndrome (SSSS) is a generalized, confluent, superficially exfoliative disease, occurring most often in neonates and young children. It occurs rarely in adults, usually with renal compromise or immunosuppression as a predisposing factor. SSSS is a febrile, rapidly evolving, desquamative infectious disease in which the skin exfoliates in sheets. Skin does not separate at the dermoepidermal junction, as in toxic (drug-induced) epidermal necrolysis (TEN), but within the granular layer. The lesions are thus much more superficial and less severe than in TEN, and healing is much more rapid. They also extend far beyond areas of actual staphylococcal infection, by action of the exfoliative exotoxins types

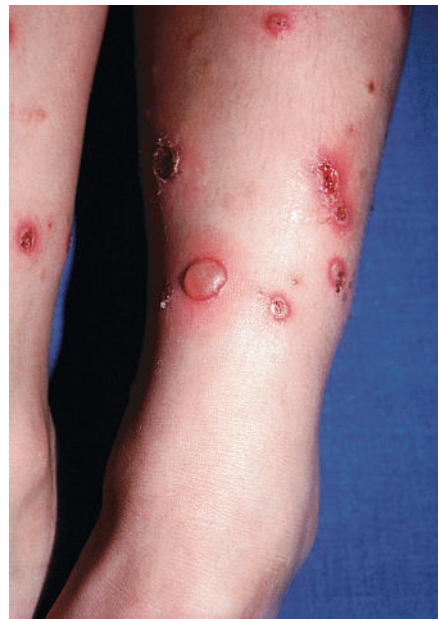

Fig. 14-11 Bullous impetigo.

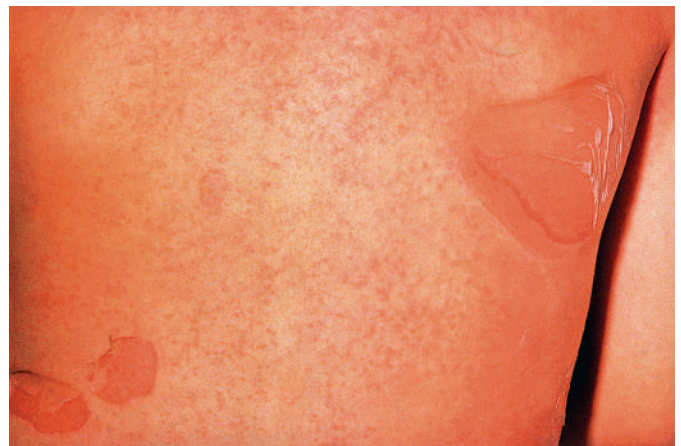


Fig. 14-12 Staphylococcal scalded skin syndrome.

A and B, elaborated by the staphylococcus in remote sites. Usually, staphylococci are present at a distant focus, such as the pharynx, nose, ear, or conjunctiva. Septicemia or a cutaneous infection may also be the causative focus.

Clinical manifestations of SSSS begin abruptly with fever, skin tenderness, and erythema involving the neck, groins, and axillae (Fig. 14-12). There is sparing of the palms, soles, and mucous membranes. Nikolsky's sign is positive. Generalized exfoliation follows within the next hours to days, with large sheets of epidermis separating. Group 2 *S. aureus*, usually phage types 71 or 55, is the causative agent in most cases. If taken, cultures should be obtained from the mucous membranes because the skin erythema and desquamation are caused by the distant effects of the exfoliative toxins, unlike in bullous impetigo, where *S. aureus* is present in the lesions.

Rapid diagnosis of SSSS can be made by examining frozen sections of a blister roof and observing that the full thickness of the epidermis is not necrotic, as in TEN, but rather is cleaved below the granular layer. The exfoliative toxins A, B, and D specifically cleave desmoglein 1, the antigenic target of autoantibodies in pemphigus foliaceus, thus accounting for the clinical and histologic similarity to pemphigus observed in SSSS and bullous impetigo. Treatment of choice is a penicillinase-resistant penicillin such as dicloxacillin combined with fluid therapy and general supportive measures. If



MRSA is cultured and response is sluggish, antibiotics directed according to the susceptibility of the recovered organism are needed. The prognosis is good in children, but mortality in adults can reach 60%.

## Gram-positive toxic shock syndromes

Toxic shock syndrome (TSS) is an acute, febrile, multisystem illness, with one of its major diagnostic criteria being a widespread macular erythematous eruption. It is usually caused by toxin-producing strains of *S. aureus*, most of which were initially isolated from the cervical mucosa in menstruating young women. Currently, cases are most often caused by infections in wounds, catheters, contraceptive diaphragms, or nasal packing. Mortality in these nonmenstrual cases is higher (up to 20%) compared with menstrual-related cases (<5%), probably as a result of delayed diagnoses. Also, a similar syndrome has been defined in which the cause is group A, or rarely group B, streptococci. This latter multiorgan disease has systemic components similar to classic staphylococcal TSS; however, the infection is usually a rapidly progressive, destructive soft tissue infection such as necrotizing fasciitis. Women with an underlying chronic illness, recently recovered from varicella, or using nonsteroidal anti-inflammatory drugs (NSAIDs) are predisposed. It has a case-fatality rate of 30%. The streptococci are usually of M-types 1 and 3, with 80% of the isolates producing pyrogenic exotoxin A.

The Centers for Disease Control and Prevention (CDC) case definition of staphylococcal TSS includes a temperature of 38.9°C (102°F) or higher, an erythematous eruption, desquamation of the palms and soles 1–2 weeks after onset (Fig. 14-13), hypotension, and involvement of three or more other systems: gastrointestinal (GI; vomiting, diarrhea), muscular (myalgias, increased creatinine kinase level), mucous membrane (hyperemia), renal (pyuria without infection or raised creatinine or blood urea nitrogen levels), hepatic (increased bilirubin/serum glutamic oxaloacetic transaminase/serum glutamic pyruvic transaminase), hematologic (platelets <100 000/mm<sup>3</sup>), or central nervous system (CNS; disorientation). In addition, serologic tests for Rocky Mountain spotted fever, leptospirosis, and rubeola, and cultures of blood, urine, and cerebrospinal fluid should be negative. Procalcitonin, an indicator of severe bacterial infection, may be a biologic marker for the toxic shock syndromes. Bulbar conjunctival hyperemia and palmar edema are two additional clinical clues. Streptococcal TSS is defined by isolation of group A  $\beta$ -hemolytic streptococci, hypotension, and two or more of the following: renal impairment, coagulopathy, hepatic involvement, acute respiratory distress syndrome, a generalized erythematous macular eruption that may desquamate, and soft tissue necrosis, myositis, or gangrene.

About 90% of the early cases of TSS occurred in young women between the first and sixth days of a menstrual period. During the initial outbreak, the majority were using a super-absorbent tampon. Cases now usually occur in women using contraceptive sponges, in patients with nasal packing after rhinoplasty, and in patients with staphylococcal infections of bone, lung, or soft tissue. The offending *S. aureus* strain produces one or more exotoxins.

Histologic findings are spongiosis and neutrophils scattered throughout the epidermis, individual necrotic keratinocytes, perivascular and interstitial infiltrates composed of lymphocytes and neutrophils, and edema of the papillary dermis. TSS must be differentiated from viral exanthems, Kawasaki's disease, scarlet fever, recurrent toxin-mediated perianal erythema, drug eruptions, Rocky Mountain spotted fever, systemic lupus erythematosus (SLE), TEN, and SSSS.

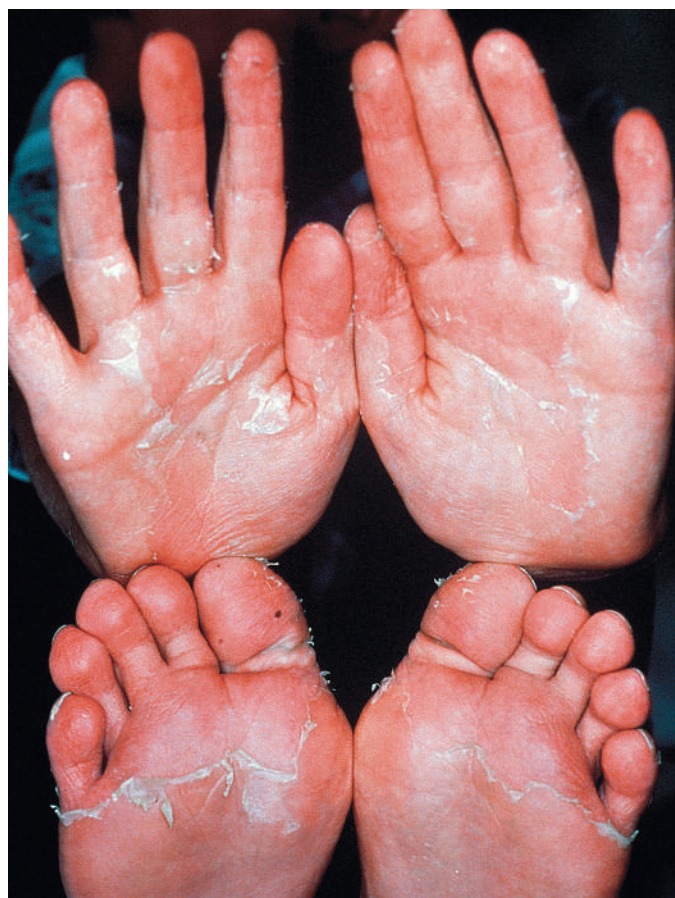

Fig. 14-13 Desquamation of the palms and soles.

Treatment of TSS consists of systemic antibiotics such as vancomycin, which may be combined with nafcillin, 1–1.5 g intravenously every 4 h in critically ill patients; vigorous fluid therapy to treat shock; and drainage of the *S. aureus*-infected site.

**Agarwal V, et al:** Pyomyositis. *Neuroimaging Clin North Am* 2011; 21:975–983.

**Al-Najar M, et al:** Primary extensive pyomyositis in an immunocompetent patient. *Clin Rheumatol* 2010; 29:1469–1472.

**Antoniu T, et al:** Prevalence of community-associated methicillin-resistant *Staphylococcus aureus* colonization in men who have sex with men. *Int J STD AIDS* 2009; 20:180.

**Atanaskova N, et al:** Innovative management of recurrent furunculosis. *Dermatol Clin* 2010; 28:479.

**Bangert S, et al:** Bacterial resistance and impetigo treatment trends. *Pediatr Dermatol* 2012; 29:243–248.

**Berk DR, et al:** MRSA, staphylococcal scalded skin syndrome, and other cutaneous bacterial emergencies. *Pediatr Ann* 2010; 39:627–633.

**Brewer JD, et al:** Staphylococcal scalded skin syndrome and toxic shock syndrome after tooth extraction. *J Am Acad Dermatol* 2008; 59:342.

**Burdette SD, et al:** *Staphylococcus aureus* pyomyositis compared with non-*Staphylococcus aureus* pyomyositis. *J Infect* 2012; 64:507–512.

**Caum RS, et al:** Skin and soft-tissue infections caused by methicillin-resistant *Staphylococcus aureus*. *N Engl J Med* 2007; 357:380.

**Datta R, et al:** Risk of infection and death due to methicillin-resistant *Staphylococcus aureus* in long-term carriers. *Clin Infect Dis* 2008; 47:176.

**Demos M, et al:** Recurrent furunculosis. *Br J Dermatol* 2012; 167:725–735.

**Durupt F, et al:** Prevalence of *Staphylococcus aureus* toxins and nasal carriage in furunculosis and impetigo. *Br J Dermatol* 2007; 157:43.

**Elliott DJ, et al:** Empiric antimicrobial therapy for pediatric skin and soft-tissue infections in the era of methicillin-resistant *Staphylococcus aureus*. *Pediatrics* 2009; 123:e959.

- Elston DM:** How to handle a CA-MRSA outbreak. *Dermatol Clin* 2009; 27:43.
- Forcade NA, et al:** Antibacterials as adjuncts to incision and drainage for adults with purulent methicillin-resistant *Staphylococcus aureus* (MRSA) skin infections. *Drugs* 2012; 72:339–351
- Garcia C, et al:** *Staphylococcus aureus* causing tropical pyomyositis, Amazon Basin, Peru. *Emerg Infect Dis* 2013; 19:123–125.
- Gutierrez K, et al:** Staphylococcal infections in children, California, USA, 1985–2009. *Emerg Infect Dis* 2013; 19:10–20.
- Jackson MA, et al:** Staphylococcal infections in the era of MRSA. *Pediatr Rev* 2011; 32:522–532.
- Kato M, et al:** Procalcitonin as a biomarker for toxic shock syndrome. *Acta Derm Venereol* 2010; 90:441.
- Kirkland EB, et al:** Methicillin-resistant *Staphylococcus aureus* and athletes. *J Am Acad Dermatol* 2008; 59:494.
- Lappin E, et al:** Gram-positive toxic shock syndromes. *Lancet Infect Dis* 2009; 9:281.
- Low DE:** Toxic shock syndrome: major advances in pathogenesis, but not treatment. *Crit Care Clin* 2013; 29:651–675.
- Mitsionis GI, et al:** Pyomyositis in children. *J Pediatr Surg* 2009; 44:2173–2178.
- Neylon O, et al:** Neonatal staphylococcal scalded skin syndrome. *Eur J Pediatr* 2010; 169:1503–1509.
- Ouchi T, et al:** A case of blastomycosis-like pyoderma caused by mixed infection of *Staphylococcus epidermidis* and *Trichophyton rubrum*. *Am J Dermatopathol* 2011; 33:397–399.
- Patel GK, et al:** Staphylococcal scalded skin syndrome. *Am J Med* 2010; 123:505–507.
- Patrizi A, et al:** Recurrent toxin-mediated perineal erythema. *Arch Dermatol* 2008; 144:239.
- Piechowicz L, et al:** Outbreak of bullous impetigo caused by *Staphylococcus aureus* strains of phage type 3C/71 in a maternity ward linked to nasal carriage of a healthcare worker. *Eur J Dermatol* 2012; 22:252–255.
- Rertveit S, et al:** Impetigo in epidemic and non-epidemic phases. *Br J Dermatol* 2007; 157:100.
- Ritting AW, et al:** Acute paronychia. *J Hand Surg Am* 2012; 37:1068–1070.
- Rubenstein E, et al:** Botryomycosis-like pyoderma in the genital region of a human immunodeficiency virus (HIV)-positive man successfully treated with dapsone. *Int J Dermatol* 2010; 49:842.
- Scheinflug K, et al:** Staphylococcal scalded skin syndrome in an adult patient with T-lymphoblastic non-Hodgkin's lymphoma. *Oncologie* 2008; 31:616.
- Sica RS, et al:** Prevalence of methicillin-resistant *Staphylococcus aureus* in the setting of dermatologic surgery. *Dermatol Surg* 2009; 35:420.
- Van Rijen M, et al:** Mupirocin ointment for preventing *Staphylococcus aureus* infections in nasal carriers. *Cochrane Database Syst Rev* 2008; 4:CD006216.

## STREPTOCOCCAL SKIN INFECTIONS

Specific diseases caused by direct infection with *Streptococcus pyogenes* and its toxins, as discussed in this chapter, also have immune-mediated consequences, including acute rheumatic fever, chronic rheumatic heart disease, and acute poststreptococcal glomerulonephritis. The last two only occur after pharyngitis or tonsillitis. Although most of such complications occur in resource-poor countries, the global burden of these sequelae is significant.

### Ecthyma

Ecthyma is an ulcerative staphylococcal or streptococcal pyoderma, almost always of the shins or dorsal feet. The disease begins with a vesicle or vesicopustule, which enlarges and in a few days becomes thickly crusted. When the crust is removed, there is a superficial, saucer-shaped ulcer with a raw base and elevated edges (Fig. 14-14). In urban areas, these lesions are

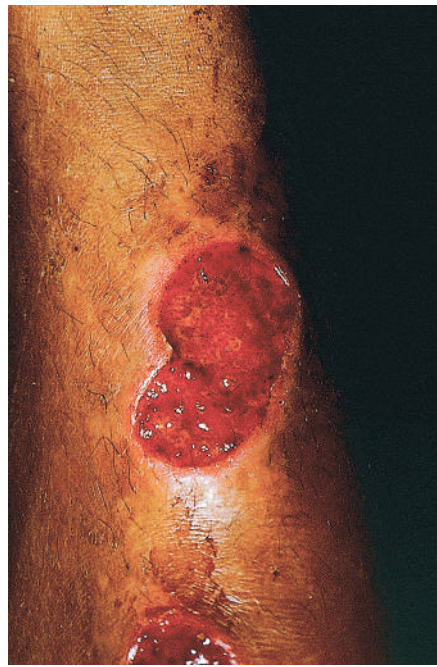

Fig. 14-14 Ecthyma.

caused by *S. aureus* and are seen in intravenous drug users and HIV-infected patients.

The lesions tend to heal after a few weeks, leaving scars, but rarely may proceed to gangrene when resistance is low. Debilitated patients often have a focus of pyogenic infection elsewhere. Local adenopathy may be present. Uncleanliness, malnutrition, and trauma are predisposing causes.

Treatment is cleansing with soap and water after soaking off the crust with compresses, followed by the application of mupirocin, retapamulin, or bacitracin ointment, twice daily. Oral dicloxacillin or a first-generation cephalosporin is also indicated, with adjustments made according to the cultured organism's susceptibilities.

### Scarlet fever

Scarlet fever is a diffuse, erythematous exanthem that occurs during the course of streptococcal pharyngitis. It affects primarily children, who develop the eruption 24–48 h after onset of pharyngeal symptoms. The tonsils are red, edematous, and covered with exudate. The tongue has a white coating through which reddened, hypertrophied papillae project, giving the so-called white strawberry tongue appearance. By the fourth or fifth day the coating disappears, the tongue is bright red, and the red strawberry tongue remains.

The cutaneous eruption begins on the neck, then spreads to the trunk and finally the extremities (Fig. 14-15). Within the widespread erythema are 1–2 mm papules, which give the skin a rough, sandpaper quality. There is accentuation over the skinfolds, and a linear petechial eruption, called Pastia lines, is often present in the antecubital and axillary folds. There is facial flushing and circumoral pallor. A branny desquamation occurs as the eruption fades, with peeling of the palms and soles taking place about 2 weeks after the acute illness. The latter may be the only evidence that the disease has occurred.

The eruption is produced by erythrogenic exotoxin-producing group A streptococci. Cultures of the pharynx will recover these organisms. Rarely, scarlet fever may be related to a surgical wound or burn infection with streptococci. An elevated antistreptolysin O titer may provide evidence of



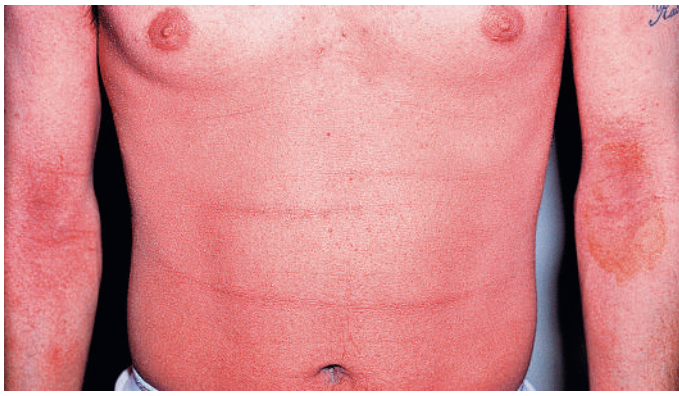

Fig. 14-15 Scarlet fever.

recent infection if cultures are not taken early. A condition known as staphylococcal scarlatina has been described that mimics scarlet fever; however, the strawberry tongue is not seen.

Penicillin, erythromycin, or dicloxacillin treatment is curative for scarlet fever, and the prognosis is excellent.

### Recurrent toxin-mediated perianal erythema

This condition manifests as a perineal, erysipelas-like erythema that resolves with desquamation. Strawberry tongue, erythema of the hands with desquamation, and a mild fever 1 or 2 days before the eruption are other signs. In some patients, a staphylococcal or streptococcal pharyngitis, impetigo, or perianal streptococcal dermatitis is present. There may be recurrences in individual patients. Streptococcal pyrogenic exotoxins A and B or TSS toxin 1 may be responsible for the skin findings.

### Erysipelas

Also once known as St. Anthony's fire and ignis sacer, erysipelas is an acute  $\beta$ -hemolytic group A streptococcal infection of the skin involving the superficial dermal lymphatics. Occasional cases caused by streptococci of group C or G are reported in adults. Group B streptococcus is often responsible in the newborn and may be the cause of abdominal or perineal erysipelas in postpartum women. It is characterized by local redness, heat, swelling, and a highly characteristic raised, indurated border (Fig. 14-16, A). The onset is often preceded by prodromal symptoms of malaise for several hours, which may be accompanied by a severe constitutional reaction with chills, high fever, headache, vomiting, and joint pains. There is usually a polymorphonuclear leukocytosis of 20,000 cells/mm<sup>3</sup> or more. However, many cases present solely as an erythematous lesion without associated systemic complaints.

The skin lesions may vary from transient hyperemia followed by slight desquamation to intense inflammation with vesicles or bullae. The eruption begins at any one point as an erythematous patch and spreads by peripheral extension. In the early stages, affected skin is scarlet, hot to the touch, branny, and swollen. A distinctive feature of the inflammation is the advancing edge of the patch. This is raised and sharply demarcated and feels like a wall to the palpating finger. In some cases, vesicles or bullae that contain seropurulent fluid occur and may result in local gangrene.

The legs and face are the most common sites affected. On the face, the inflammation generally begins on the cheek near the nose or in front of the lobe of the ear and spreads upward

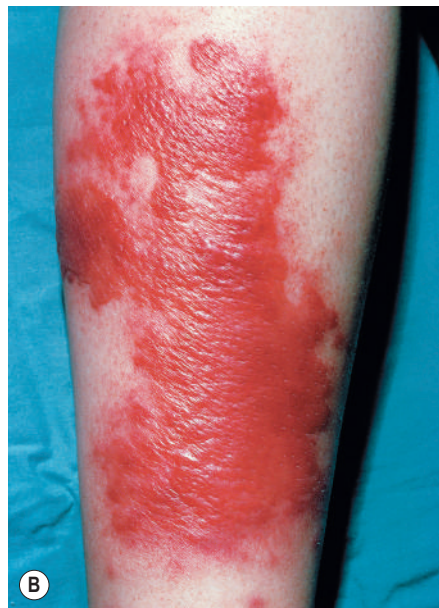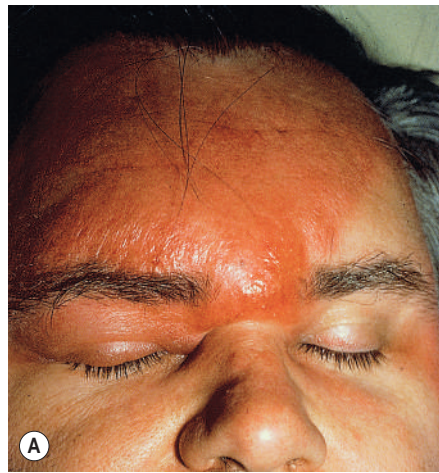


Fig. 14-16 A and B, Erysipelas.

to the scalp, with the hairline sometimes acting as a barrier against further extension. On the legs, edema and bullous lesions are prominent features in many patients (Fig. 14-16, B). Septicemia, deep cellulitis, necrotizing fasciitis, and abscess formation may be complications, especially in obese patients and those with chronic alcohol abuse. Predisposing causes are surgical wounds, which may lead to gluteal and thigh involvement; fissures in the nares, in the auditory meatus, under the earlobes, on the anus or penis, and between or under the toes, usually the little toe; abrasions or scratches; venous insufficiency; obesity; lymphedema; and chronic leg ulcers.

Recognition of erysipelas generally is not difficult. It may be confused with contact dermatitis from plants, drugs, or dyes and with angioneurotic edema, but with each of these, fever, pain, and tenderness are absent and itching is severe. A butterfly pattern on the face may mimic lupus erythematosus, and ear involvement may suggest relapsing polychondritis.

Systemic penicillin is rapidly effective. Improvement in the general condition occurs in 24–48 h, but resolution of the cutaneous lesion may require several days. Vigorous treatment with antibiotics should be continued for at least 10 days. Locally, ice bags and cold compresses may be used. Leg involvement, especially when bullae are present, will more likely require hospitalization with intravenous antibiotics. Elderly patients, those with underlying immunocompromise, a longer duration of illness before presentation, and patients

with leg ulcers will require longer inpatient stays. A small group will have recurrent disease, in whom long-term antibiotic prophylaxis may be beneficial.

## Cellulitis

Cellulitis is a suppurative inflammation involving the subcutaneous tissue. Usually, but not always, this follows some discernible wound. On the leg, tinea pedis is the most common portal of entry. Mild local erythema and tenderness, malaise, and chilly sensations or a sudden chill and fever may be present at the onset. The erythema rapidly becomes intense and spreads (Fig. 14-17). The area becomes infiltrated and pits on pressure. The central part may become nodular and surmounted by a vesicle that ruptures and discharges pus and necrotic material. Streaks of lymphangitis may spread from the area to the neighboring lymph glands (Fig. 14-18). Gangrene, metastatic abscesses, and severe sepsis may follow. These complications are unusual in immunocompetent adults, but children and immunocompromised adults are at higher risk.

The diagnosis of cellulitis is usually made on clinical grounds. It is uncommon for blood studies, including cultures, and skin biopsies or aspirates to be positive. If, however, an open wound is present, there is a high probability of a culture being positive. Streptococci continue to cause approximately 75% of cases and staphylococci the majority of the remainder. Stasis dermatitis may mimic cellulitis. It does not hurt or cause fever, may be circumferential or centered over the medial malleoli, and is usually bilateral. Allergic contact dermatitis is itchy but not painful.

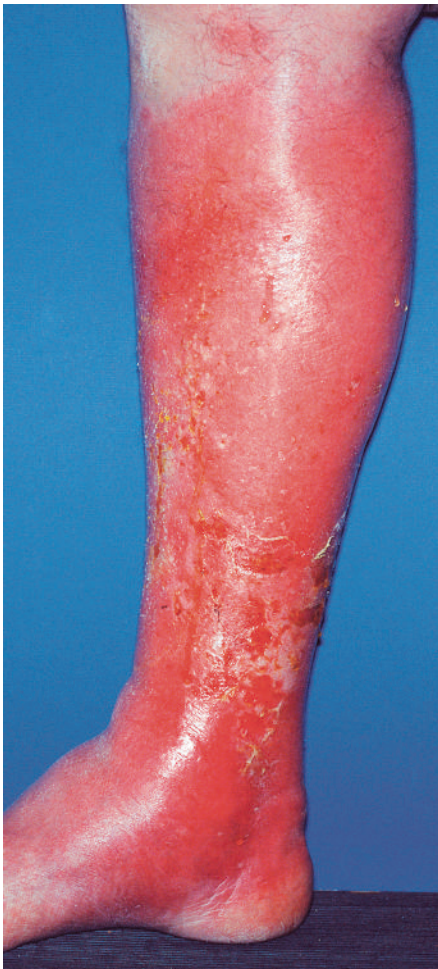

Fig. 14-17 Cellulitis.

Patients with stasis dermatitis without systemic toxicity can be managed as outpatients. Initial empiric therapy with dicloxacillin or cephalexin for 5 days will usually suffice. If MRSA is strongly suspected because of risk factors, treatment strategies are as outlined for staphylococcal infections at the start of this chapter.

## Chronic recurrent erysipelas, chronic lymphangitis

Erysipelas or cellulitis may be recurrent. Predisposing factors include alcoholism, diabetes, immunodeficiency, tinea pedis, venous stasis, lymphedema with or without lymphangiectasias, prosthetic surgery of the knee, a history of saphenous phlebectomy, lymphadenectomy, or irradiation. Chronic lymphedema is the end result of recurrent bouts of bacterial lymphangitis and obstruction of the major lymphatic channels of the skin. The final result is a permanent hypertrophic fibrosis called elephantiasis nostras. It must be differentiated from lymphangioma, acquired lymphangiectasia, and other causes such as neoplasms or filariasis.

During periods of active lymphangitis, antibiotics in large doses are beneficial, and their use must be continued in smaller maintenance doses, such as 250 mg of cephalexin or penicillin, for long periods to achieve their full benefits. Compression therapy to decrease lymphedema will aid in the prevention of recurrence.

## Necrotizing fasciitis

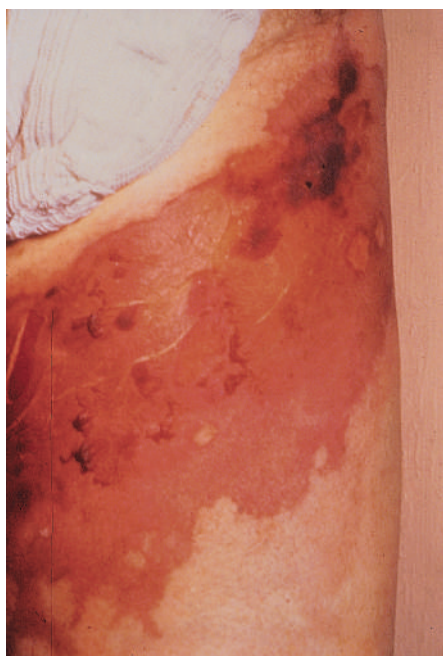
Necrotizing fasciitis is an acute necrotizing infection involving the fascia. It may follow surgery or perforating trauma or may occur de novo. Within 24–48 h, redness, pain, and edema quickly progress to central patches of dusky-blue discoloration, with or without serosanguineous blisters (Fig. 14-19). Anesthesia of the involved skin is characteristic. By the fourth or fifth day, these purple areas become gangrenous. Many forms of virulent bacteria have been cultured from necrotizing fasciitis, including microaerophilic  $\beta$ -hemolytic streptococci, hemolytic staphylococcus, coliforms, enterococci, *Pseudomonas*, and *Bacteroides*. Both aerobic and anaerobic cultures should always be taken.

Early surgical debridement is an essential component of successful therapy. Laboratory studies may help in assessing the risk of a patient having necrotizing fasciitis. One scoring system gives points for abnormalities in C-reactive protein, white blood cell count, hemoglobin, sodium, creatinine, and glucose. Based on the total score, patients are stratified into low-risk, medium-risk, and high-risk categories. The most definitive confirmatory test is MRI. At the bedside, the clinician may infiltrate the site with anesthetic, make a 2-cm

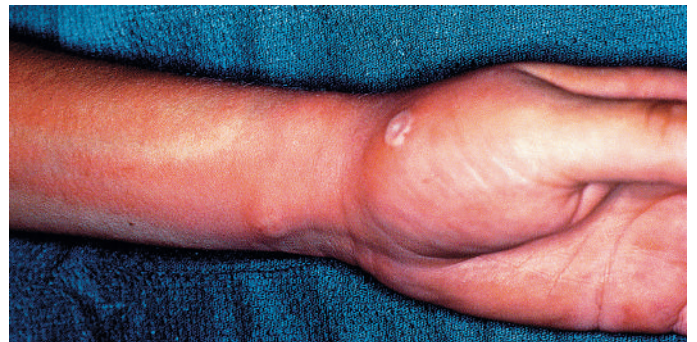

Fig. 14-18 Lymphangitis.





**Fig. 14-19** Necrotizing fasciitis.

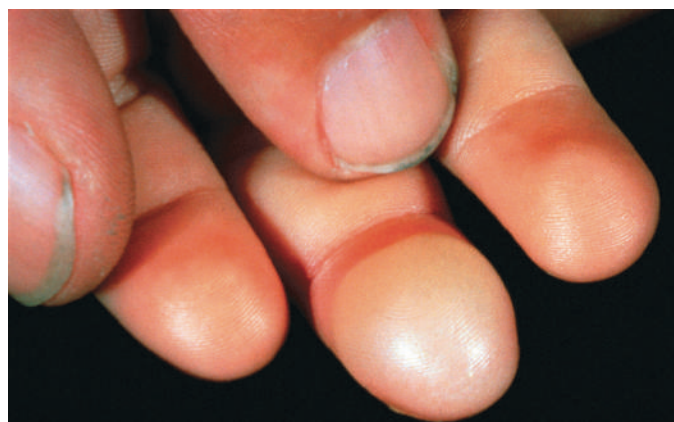incision down to the fascia, and probe with the finger. Lack of bleeding, a murky discharge, and lack of resistance to the probing finger are ominous signs. If done, a biopsy should be obtained from normal-appearing tissue near the necrotic zone. Treatment should include early surgical debridement, appropriate IV antibiotics, and supportive care. Mortality may be 20% even in the best of circumstances. Poor prognostic factors are age over 50, underlying diabetes or atherosclerosis, delay of more than 7 days in diagnosis and surgical intervention, and infection on or near the trunk rather than the more often involved extremities. Neonatal necrotizing fasciitis most frequently occurs on the abdominal wall and has a higher mortality rate than in adults.

### Blistering distal dactylitis

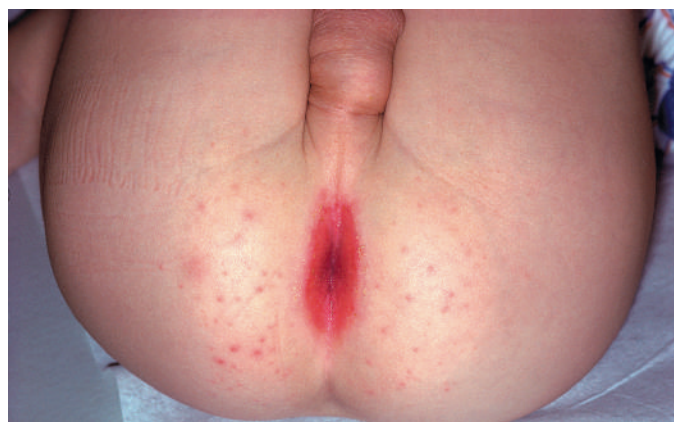Blistering distal dactylitis is characterized by tense superficial blisters occurring on a tender erythematous base over the volar fat pad of the phalanx of a finger or thumb or occasionally a toe (Fig. 14-20). The typical patient is age 2–16 years. Group A  $\beta$ -hemolytic streptococci or *S. aureus* is the most common cause. These organisms may be cultured from blister fluid and occasionally from clinically inapparent infections of the nasopharynx or conjunctiva.

### Perineal dermatitis

Clinically, perineal dermatitis presents most often as a superficial, perianal, well-demarcated rim of erythema (Fig. 14-21); fissuring may also be seen. Pain or tenderness, especially prominent on defecation, may lead to fecal retention in affected patients, who are usually between ages 1 and 8. It may not resemble cellulitis, but rather dermatitis. It may also affect the vulval and penile tissues. Group A streptococci are most often the cause; however, *S. aureus* may be recovered rarely, and when this occasionally occurs in adults, the usual cause is group B streptococci. The vast majority of infections are caused by streptococci, so a systemic penicillin or erythromycin combined with a topical antiseptic or antibiotic is the treatment of choice. The duration should be 14–21 days,



**Fig. 14-20** Blistering dactylitis.



**Fig. 14-21** Perianal dermatitis.

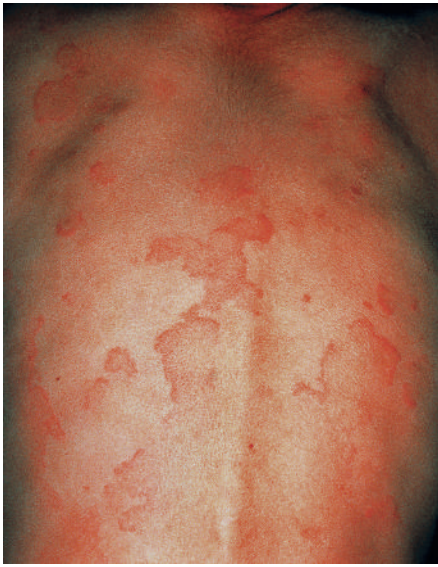depending on clinical response. Posttreatment swabs and urinalysis to monitor for poststreptococcal glomerulonephritis are recommended.

### Streptococcal intertrigo

Infants and young children may develop a fiery-red erythema and maceration in the neck, axillae, or inguinal folds. There are no satellite lesions. It may be painful and have a foul odor. Group A  $\beta$ -hemolytic streptococci are the cause, and topical antibiotics and oral penicillin combined with a low-potency topical corticosteroid is curative in streptococcal intertrigo.

### Erythema marginatum

Delayed nonsuppurative sequelae of streptococcal infections include erythema nodosum, poststreptococcal glomerulonephritis, and rheumatic fever. The latter only follows pharyngitis or tonsillitis, but two skin signs are among the diagnostic criteria of rheumatic fever: erythema marginatum and subcutaneous nodules. The remaining major signs making up the revised Jones criteria are carditis, polyarthritides, and chorea. Erythema marginatum appears as a spreading, patchy erythema that migrates peripherally and often forms polycyclic configurations (Fig. 14-22). It is evanescent, appearing for a few hours or days on the trunk or proximal extremities. Heat may make it more visible, and successive crops may appear over several weeks. It is usually part of the early phase of the



**Fig. 14-22** Erythema marginatum.

disease, coexisting with carditis but usually preceding the arthritis. Children younger than 5 years are more likely to manifest the eruption than older patients. A skin biopsy will show a perivascular and interstitial polymorphonuclear leukocyte predominance. In contrast, the subcutaneous nodules occur over bony prominences and appear as a late manifestation. The lesions of erythema marginatum usually are asymptomatic and resolve spontaneously.

### Group B streptococcal infection

*Streptococcus agalactiae* is the major cause of bacterial sepsis and meningitis in neonates. It may cause orbital cellulitis or facial erysipelas in these patients. Up to 25% of healthy adults harbor group B streptococci in their genital or GI tract. A guideline by Money et al. emphasizes prevention of such disastrous infections in the newborn through culture identification of mothers at risk and prophylactic antibiotics before delivery in culture-positive women. *S. agalactiae* has been reported to cause balanitis, vulvar pain due to fine fissures with minimal erythema, toxic shocklike syndrome, cellulitis, perianal dermatitis, recurrent erysipelas, or blistering dactylitis in adults. Diabetes mellitus, neurologic impairment, cirrhosis, and peripheral vascular disease predispose patients to infection with *S. agalactiae*. In the postpartum period, abdominal or perineal erysipelas may be caused by this organism.

### *Streptococcus iniae* infections

Cellulitis of the hands may be caused by the fish pathogen *Streptococcus iniae*. In Asian cuisine, tilapia (also known as St Peter's fish or Hawaiian sunfish) is often purchased live from aquariums in retail stores. In cleaning the freshly killed fish before cooking, puncture wounds of the skin may be sustained from the dorsal fin, a fish bone, or a knife. Preparation of other raw seafood may also lead to *S. iniae* infection. Within 24 h, fever, lymphangitis, and cellulitis without skin necrosis or bulla formation occur. Treatment with penicillin is curative. A similar scenario occurred with a newly described species, *Streptococcus hongkongensis* sp nov. Amoxicillin-clavulanate was effective in the one reported case.

**Bachmeyer C, et al:** Relapsing erysipelas of the buttock due to *Streptococcus agalactiae* in an immunocompetent woman. *Clin Exp Dermatol* 2009; 34:267.

**Baiano JC, et al:** Toward control of *Streptococcus iniae*. *Emerg Infect Dis* 2009; 15:1891–1896.

**Bailey E, et al:** Cellulitis. *Dermatol Ther* 2011; 24:229–239.

**Buckland GT 3rd, et al:** Persistent periorbital and facial lymphedema associated with group A beta-hemolytic streptococcal infection. *Ophthalm Plast Reconstr Surg* 2007; 23:161.

**Carvalho SM, et al:** Rheumatic fever: presentation and outcome. *Rev Bras Rheumatol* 2012; 52:241–246.

**Del Giudice P, et al:** Severe relapsing erysipelas associated with chronic *Streptococcus agalactiae* vaginal colonization. *Clin Infect Dis* 2006; 43:1141.

**El Bouch R, et al:** A case of recurrent toxin-mediated perineal erythema. *Arch Dis Child* 2013; 98:776.

**Fretzayas A, et al:** MRSA blistering distal dactylitis and review of reported cases. *Pediatr Dermatol* 2011; 28:433–435.

**Glatz M, et al:** Erysipelas of the thigh and gluteal region. *Dermatology* 2012; 225:277–283.

**Gunderson CG, et al:** A systematic review of bacteremias in cellulitis and erysipelas. *J Infect* 2012; 64:148–155.

**Hakkarainen TW, et al:** Necrotizing soft tissue infections. *Curr Probl Surg* 2014; 51:344–362.

**Hirschmann JV, et al:** Lower limb cellulitis and its mimics. *J Am Acad Dermatol* 2012; 67:163.e1-12, 177.e1-9.

**Jamal N, et al:** Necrotizing fasciitis. *Pediatr Emerg Care* 2011; 27:1195–1199.

**Kahlke V, et al:** Perianal streptococcal dermatitis in adults: its association with pruritic anorectal diseases is mainly caused by group B streptococci. *Colorectal Dis* 2013; 15:602–607.

**Kilburn SA, et al:** Interventions for cellulitis and erysipelas. *Cochrane Database Syst Rev* 2010; 6:CD004299.

**Koh TH, et al:** Streptococcal cellulitis following preparation of fresh raw seafood. *Zoonoses Public Health* 2009; 56:206.

**Krasagakis K, et al:** Local complications of erysipelas. *Clin Exper Dermatol* 2010; 36:351–354.

**Kutsuna S, et al:** Scarlet fever in an adult. *Intern Med* 2014; 53:167–168.

**Lamden KH:** An outbreak of scarlet fever in a primary school. *Arch Dis Child* 2011; 96:394–397.

**Lau SK, et al:** *Streptococcus hongkongensis* sp. nov., isolated from a patient with an infected puncture wound and from a marine flatfish. *Int J Syst Evol Microbiol* 2013; 63:2570–2576.

**Laucerotto L, et al:** Necrotizing fasciitis. *J Trauma* 2012; 72:560–566.

**Mirowski GW, et al:** Cutaneous vulvar streptococcal infection. *J Low Genit Tract Dis* 2012; 16:281–284.

**Mittal MK, et al:** Group B streptococcal cellulitis in infancy. *Pediatr Emerg Care* 2007; 23:324.

**Money D, et al:** The prevention of early-onset neonatal group B streptococcal disease. *J Obstet Gynaecol Can* 2013; 35:939–951.

**Patrizi A, et al:** Recurrent toxin-mediated perineal erythema. *Arch Dermatol* 2008; 144:239.

**Phoenix G, et al:** Diagnosis and management of cellulitis. *BMJ* 2012; 345:e4955.

**Picard D, et al:** Risk factors for abscess formation in patients with superficial cellulitis (erysipelas) of the leg. *Br J Dermatol* 2012; 168:859–863.

**Ralph AP, et al:** Group A streptococcal diseases and their global burden. *Curr Top Microbiol Immunol* 2013; 368:1–27.

**Shimizu T, et al:** Necrotizing fasciitis. *Intern Med* 2010; 49:1051.

**Silverman RA, et al:** Streptococcal intertrigo of the cervical folds in a five-month-old infant. *Pediatr Infect Dis J* 2012; 31:872–873.

**Singer AJ, et al:** Management of skin abscesses in the era of methicillin-resistant *Staphylococcus aureus*. *N Engl J Med* 2014; 370:1039–1047.

**Sun JR, et al:** Invasive infection with *Streptococcus iniae* in Taiwan. *J Med Microbiol* 2007; 56:1246.

**Thomas K, et al:** Prophylactic antibiotics for the prevention of cellulitis (erysipelas) of the leg. *Br J Dermatol* 2012; 166:169–178.

**Thomas KS, et al:** Penicillin to prevent recurrent leg cellulitis. *N Engl J Med* 2013; 368:1695–1703.

**Wasserrug O, et al:** A cluster of ecthyma outbreaks caused by a single clone of invasive and highly infective *Streptococcus pyogenes*. *Clin Infect Dis* 2009; 48:1213.



## MISCELLANEOUS GRAM-POSITIVE SKIN INFECTIONS

### Erysipeloid of Rosenbach

The most frequent form of erysipeloid is a purplish marginated swelling on the hands. The first symptom is pain at the site of inoculation, followed by swelling and erythema. The most distinctive feature is the sharply marginated and often polygonal patches of bluish erythema (Fig. 14-23). The erythema slowly spreads to produce a sharply defined, slightly elevated zone that extends peripherally as the central portion fades away. If the finger is involved, the swelling and tenseness make movement difficult. Vesicles frequently occur.

Another characteristic of the disease is its migratory nature; new purplish red patches appear at nearby areas. If the infection originally involved one finger, eventually all the fingers and the dorsum of the hand, the palm, or both may become infected, with the erythema appearing and disappearing; or extension may take place by continuity. The disease involutes without desquamation or suppuration. A diffuse or generalized eruption in regions remote from the site of inoculation may occur, with fever and arthritic symptoms. Rarely, septicemia may eventuate in endocarditis, with prolonged fever and constitutional symptoms.

The infection is caused by *Erysipelothrix rhusiopathiae*. *E. rhusiopathiae* is present on dead matter of animal origin. Swine are more frequently infected than any other animal. A large percentage of healthy swine are carriers of the organism. Turkeys are also often infected, and the disease may arise from handling contaminated dressed turkeys. It is also present in the slime of saltwater fish, on crabs, and on other shellfish. The disease is widespread along the entire Atlantic seacoast among commercial fishermen who handle live fish, crabs, and shellfish. The infection also occurs among veterinarians and in the meatpacking industry, principally from handling pork products. *E. rhusiopathiae* is a rod-shaped, nonmotile, gram-positive organism that tends to form long-branching filaments. The organism is cultured best on media fortified with serum, at room temperature.

### Treatment

The majority of the mild cases of erysipeloid run a self-limited course of about 3 weeks. In some patients, after a short period of apparent cure, the eruption reappears either in the same area or, more likely, in an adjacent, previously uninvolved area.

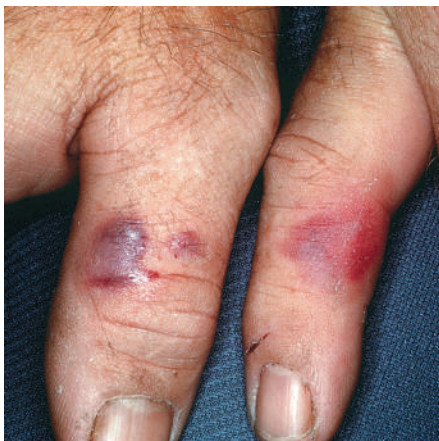

Fig. 14-23 Erysipeloid.

Penicillin, 1 g/day for 5–10 days, or ampicillin, 500 mg four times daily, is the best treatment for localized disease. If penicillin cannot be used, ciprofloxacin, clindamycin, or imipenem may be used. For systemic forms, 12–20 million units/day of IV penicillin for up to 6 weeks may be necessary.

**Veraldi S, et al:** Erysipeloid. *Clin Exp Dermatol* 2009; 34:859.

**Werner K, et al:** Erysipeloid (*Erysipelothrix rhusiopathiae* infection) acquired from a dead kakapo. *Arch Dermatol* 2011; 147:1456–1458.

### Pneumococcal cellulitis

Cellulitis may be caused by *Streptococcus pneumoniae*. Children present with facial or periorbital cellulitis, which may manifest a violaceous hue or bullae. Most patients under 36 months of age are previously healthy. Fever, leukocytosis, and septicemia are almost universal. Response to treatment with penicillin or, in resistant cases, vancomycin is excellent. Most reported disease was caused by the strains included in the pneumococcal vaccine, so this condition has become rare, as has occurred with *Haemophilus influenzae* cellulitis. Chronically ill or immunosuppressed adults also may develop pneumococcal cellulitis or other soft tissue infections, such as abscesses or pyomyositis. In patients with diabetes or substance abuse, extremity involvement is the rule, whereas in those with SLE, nephritic syndrome, hematologic disorders, or HIV disease, the head, neck, and upper torso are typically affected. Skin involvement may also be seen as a surgical wound infection. Because septicemia, tissue necrosis, and suppurative complications are common, aggressive management is crucial, with surgical drainage and IV antibiotics directed at the susceptibility of the cultured organism.

**Garcia-Lechuz JM, et al:** *Streptococcus pneumoniae* skin and soft tissue infections. *Eur J Clin Microbiol Infect Dis* 2007; 26:247.

**Khan T, Martin DH:** *Streptococcus pneumoniae* soft tissue infections in human immunodeficiency virus. *Am J Med Sci* 2011; 342:235–238.

### Anthrax

Cutaneous anthrax is uncommon in much of the world; human infection generally results from contact with infected animals or the handling of hides or other animal products from stock that has died from splenic fever. Cattlemen, woolsorters, tanners, butchers, and workers in the goat-hair industry are most liable to infection. Human-to-human transmission has occurred from contact with dressings from lesions. The spores of *Bacillus anthracis* persist and may be aerosolized, so it is a bioterrorism threat. In 2001, an outbreak of cutaneous disease resulted from powder-containing envelopes sent through the mail.

Anthrax is an acute infectious disease characterized by a rapidly necrosing, painless eschar with associated edema and suppurative regional adenitis. Four forms of the disease occur in humans: *cutaneous*, accounting for 95% of cases worldwide and almost all U.S. cases; *inhalational*, known as woolsorter's disease; *gastrointestinal*, the first case of which occurred in the United States in 2010; and *injectional*, more than 50 cases of which occurred in the United Kingdom and Germany. It is a complication of IV drug use, primarily in heroin addicts.

The first clinical manifestation of the cutaneous form is an inflammatory papule, which begins about 3–7 days after inoculation, usually on an exposed site. The inflammation develops rapidly, and a bulla surrounded by intense edema and infiltration forms within another 24–36 h. It then ruptures spontaneously, and a dark-brown or black eschar is visible, surrounded by vesicles situated on a red, hot, swollen, and

indurated area. The lesion is neither tender nor painful. This is of diagnostic importance. Pustules are almost never present. The regional lymph glands become tender and enlarged and frequently suppurate.

In patients with severe disease, the inflammatory signs increase; there is extensive edematous swelling, and other bullae and necrotic lesions develop, accompanied by a high temperature and prostration, terminating in death in a few days or weeks. This may occur in up to 20% of untreated patients. In mild cases, the constitutional symptoms are sometimes slight; the gangrenous skin sloughs, and the resulting ulcer heals.

Internally, inhalational anthrax is manifested as a necrotizing, hemorrhagic mediastinal infection. Anthrax spores involve the alveoli, then the hilar and tracheobronchial nodes. Bacteremia followed by hemorrhagic meningitis is the usual sequence of events, almost always ending in death. Gastrointestinal anthrax results when spores are ingested and multiply in the intestinal submucosa. A necrotic ulcerative lesion in the terminal ileum or cecum may lead to hemorrhage. Patients with injection disease present with fever and swelling of an extremity.

The disease is produced by *Bacillus anthracis*, a large, square-ended, rod-shaped gram-positive organism that occurs singly or in pairs in smears from the blood or in material from the local lesion, or in long chains on artificial media, where it tends to form spores. The bacillus possesses three virulence factors: a polyglutamate acid capsule inhibiting phagocytosis; an edema toxin, composed of edema factor and a transport protein termed protective antigen; and lethal toxin, composed of lethal factor plus protective antigen.

A biopsy should be obtained. This allows for immunohistochemical and polymerase chain reaction (PCR) studies, as well as routine histology and tissue Gram stain. Microscopically, there is loss of the epidermis at the site of the ulcer, with surrounding spongiosis and intraepidermal vesicles. Leukocytes are abundant in the epidermis. The dermis is edematous and infiltrated with abundant erythrocytes and neutrophils. Vasodilation is marked. The causative organisms are numerous and are easily seen, especially with Gram stain.

The diagnosis is made by demonstration of the causative agent in smears and cultures of the local material. The characteristic gangrenous lesion, surrounded by vesiculation, intense swelling and redness, lack of pain, and the patient's occupation are accessory factors. PCR identification is readily available due to its bioterrorism threat. Staphylococcal carbuncle is the most easily confused entity, but here tenderness is prominent.

Early diagnosis and prompt treatment with ciprofloxacin (500 mg) or doxycycline (100 mg), twice daily for 60 days, are curative in the cutaneous form when there are no systemic symptoms, lesions are not on the head or neck and are without significant edema, and the patient is not a child younger than 2 years. In these latter conditions, more aggressive IV therapy is required, as outlined in the CDC management guidelines available at the CDC website. Asymptomatic exposed individuals should be given prophylactic treatment with a 6-week course of doxycycline or ciprofloxacin. A vaccine is available.

**Aquino LL, et al:** Cutaneous manifestations of category A bioweapons. *J Am Acad Dermatol* 2011; 65:1213.

**Doganay M, et al:** A review of cutaneous anthrax and its outcome. *J Infect Public Health* 2010; 3:98–105.

**Hendricks KA, et al:** Centers for Disease Control and Prevention expert panel meetings on prevention and treatment of anthrax in adults. *Emerg Infect Dis* 2014. Feb 20.

**Hicks CW, et al:** An overview of anthrax infection including the recently identified form of disease in injection drug users. *Intensive Care Med* 2012; 38:1092–104.

## Listeriosis

*Listeria monocytogenes* is a gram-positive bacillus with rounded ends that may be isolated from soil, water, animals, and asymptomatic individuals. Human infection probably occurs through the GI tract; in the majority of patients, however, the portal of entry is unknown. Infections in humans usually produce meningitis or encephalitis with monocytosis. Risk factors include alcoholism, advanced age, pregnancy, and immunosuppression.

Cutaneous listeriosis is a rare disease. Veterinarians may contract cutaneous listeriosis from an aborting cow. The organism in the skin lesions is identical to that isolated from the fetus. The eruption consists of erythematous tender papules and pustules scattered over the hands and arms. There may be axillary lymphadenopathy, fever, malaise, and headache. Treatment with sulfonamides is effective.

Neonates are also at risk. The endocarditis, meningitis, and encephalitis caused by *Listeria* may be accompanied by petechiae, pustules, and papules in the skin.

Cases of listeriosis may easily be missed on bacteriologic examination, because the organism produces few colonies on original culture and may be dismissed as a streptococcus or as a contaminant diphtheroid because of the similarity in gram-stained specimens. Serologic tests help to make the diagnosis.

*Listeria monocytogenes* is sensitive to most antibiotics. Ampicillin is the antibiotic of choice, and TMP-SMX is an effective alternate.

**Gilchrist M:** Cutaneous *Listeria* infection. *Br J Hosp Med (Lond)* 2009; 70:659.

**Godshall CE, et al:** Cutaneous listeriosis. *J Clin Microbiol* 2013; 51:3591–3596.

**Zelenik K, et al:** Cutaneous listeriosis in a veterinarian with evidence of zoonotic transmission. *Zoonoses Public Health* 2014; 61:238–241.

## Cutaneous diphtheria

Cutaneous diphtheria is common in tropical areas. Most of the U.S. cases are in nonimmunized migrant farmworker families and in elderly alcoholics. Travelers to developing countries may also import disease.

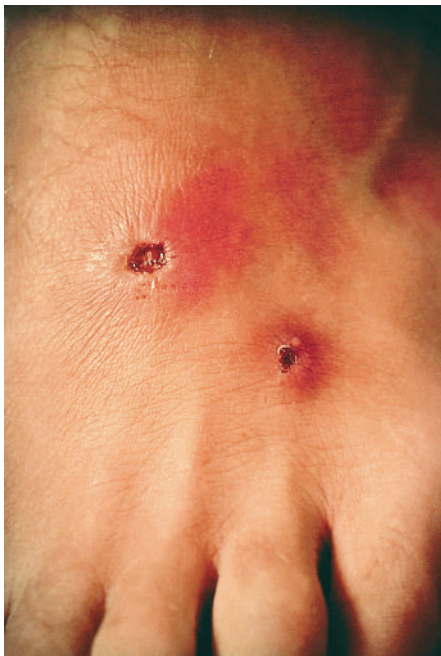Skin lesions are caused by infection with *Corynebacterium diphtheriae*, usually in the form of ulcerations. The ulcer is punched out and has hard, rolled, elevated edges with a pale-blue tinge (Fig. 14-24). Often, the lesion is covered with a leathery, grayish membrane. Regional lymph nodes may be affected. Other types of skin involvement include eczematous, impetiginous, vesicular, and pustular lesions. Postdiphtherial paralysis and potentially fatal cardiac complications may occur. These are mediated by a potent exotoxin, which stops protein production at the ribosome level.

Treatment consists of intramuscular (IM) injections of diphtheria antitoxin, 20,000–40,000 U, after a conjunctival test has been performed to rule out hypersensitivity to horse serum. One drop of antitoxin diluted 1:10 is placed in one eye and 1 drop of saline in the other eye. If after 30 min there is no reaction, 20,000–40,000 U of antitoxin is given. Erythromycin, 2 g/day, is the drug of choice, unless large proportions of resistant organism are known in the area. In severe cases, IV penicillin G, 600,000 U/day for 14 days, is indicated. Rifampin, 600 mg/day for 7 days, will eliminate the carrier state.

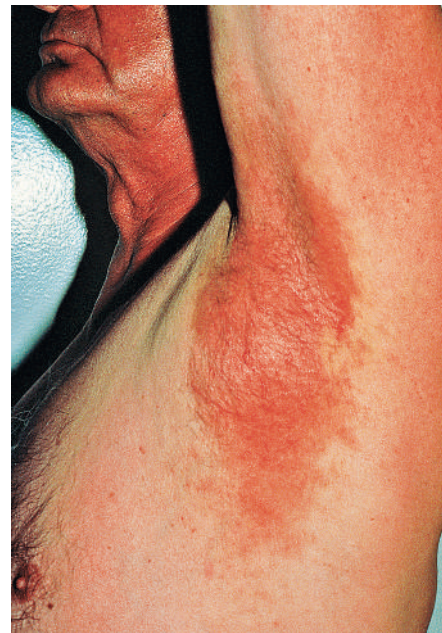**Lowe CF, et al:** Cutaneous diphtheria in the urban poor populations of Vancouver, British Columbia. *J Clin Microbiol* 2011; 49:2664–2666.

**Orouji A, et al:** Cutaneous diphtheria in a German man with travel history. *Acta Derm Venereol* 2012; 92:179–180.





**Fig. 14-24** Cutaneous diphtheria.



**Fig. 14-25** Erythrasma.

**Sears A, et al:** Cases of cutaneous diphtheria in New Zealand. *NZ Med J* 2012; 125:64–71.

### ***Corynebacterium jeikeium* sepsis**

*Corynebacterium jeikeium* colonizes the skin of healthy individuals, with the highest concentration being in the axillary and perineal areas. Hospitalized patients are more heavily colonized. Patients with granulocytopenia, indwelling catheters, prosthetic devices, exposure to multiple antibiotics, and valvular defects are at highest risk for the development of sepsis or endocarditis. A papular eruption, cellulitis, subcutaneous abscesses, tissue necrosis, hemorrhagic pustules, and palpable purpura may be seen on the skin. Vancomycin is the drug of choice. Mortality is greater than 30% in those with leukopenia, but only 5% if the marrow recovers. Hematopoietic growth factors should then be considered as adjunctive therapy in these patients.

**Olson JM, et al:** Cutaneous manifestations of *Corynebacterium jeikeium* sepsis. *Int J Dermatol* 2009; 48:886.

### **Erythrasma**

Erythrasma is characterized by sharply delineated, dry, brown, slightly scaling patches occurring in the intertriginous areas, especially the axillae (Fig. 14-25), the genitocrural crease, and the webs between the fourth and fifth toes and less often the third and fourth toes. There may also be patches in the intergluteal cleft, perianal skin, and inframammary area. The vulvar mucosa can be affected by thick, desquamating, yellowish hyperkeratosis. Rarely, widespread eruptions with lamellated plaques occur. The lesions are asymptomatic except in the groins, where there may be some itching and burning. Patients with extensive erythrasma have been found to have diabetes mellitus or other debilitating diseases.

Erythrasma is caused by the diphtheroid *Corynebacterium minutissimum*. This non-spore-forming, rod-shaped, gram-positive organism may occasionally cause cutaneous granulomas or bacteremia in immunocompromised patients. Two other diseases caused by *Corynebacterium*, pitted keratolysis and trichomycosis axillaris, may occur as a triad with

erythrasma. In the differential diagnosis, tinea cruris caused by fungi, intertrigo, seborrheic dermatitis, inverse psoriasis, candidiasis, and lichen simplex chronicus must be considered.

The Wood's light is the diagnostic medium for erythrasma. The affected areas show a coral-red fluorescence, which results from the presence of a porphyrin. Washing of the affected area before examination may eliminate the fluorescence. Topical erythromycin solution or topical clindamycin is easily applied and rapidly effective. Oral erythromycin (250 mg four times daily for 1 week), clarithromycin (single 1-g dose), and topical miconazole are equally effective.

**Chodkiewicz HM, et al:** Erythrasma. *Int J Dermatol* 2013; 52:516–518.

**Keita S, et al:** Dermatitis in the folds of black Africans in Bamako, Mali. *Int J Dermatol* 2012; 51(Suppl 1):37–40, 41–44.

**Rho N-K, et al:** A corynebacterial triad. *J Am Acad Dermatol* 2008; 58:S57.

**Wilson BB, et al:** An atypical presentation of erythrasma. *J Am Acad Dermatol* 2012; 67:e217–e218.

### ***Arcanobacterium haemolyticum* infection**

This pleomorphic, nonmotile, non-spore-forming,  $\beta$ -hemolytic, gram-positive bacillus causes pharyngitis and an exanthem in young adults. Acute pharyngitis in the 10–30-year-old age group is only caused by group A streptococci in 10–25% of cases. A proportion of the remainder will be caused by *Arcanobacterium haemolyticum*.

The exanthem is an erythematous morbilliform or scarlatiniform eruption involving the trunk and extremities. Although it usually spares the face, palms, and soles, atypical acral involvement has been reported. The general clinical presentation may include mild pharyngitis, severe diphtheria-like illness, or even septicemia.

Cultures for *A. haemolyticum* should be done on 5% blood agar plates and observed for 48 h. The diagnostic features are enhanced by a 5–8% CO<sub>2</sub> atmosphere during incubation at 37°C. Routine pharyngeal specimens are done on sheep blood agar and will miss the growth of this organism because of its slow hemolytic rate and growth of normal throat flora. Treatment of choice is erythromycin, or in the case of severe infection, high-dose penicillin G.

**Gaston DA, Zurowski SM:** *Arcanobacterium haemolyticum* pharyngitis and exanthem. *Arch Dermatol* 1996; 132:61.

**Mehta CL:** *Arcanobacterium haemolyticum*. *J Am Acad Dermatol* 2003; 48:298.

## Intertrigo

Intertrigo is a superficial inflammatory dermatitis occurring where two skin surfaces are in apposition. It is discussed here because of its clinical association with several bacterial diseases in this chapter. As a result of friction (skin rubbing skin), heat, and moisture, the affected fold becomes erythematous, macerated, and secondarily infected. There may be erosions, fissures, and exudation, with symptoms of burning and itching. Intertrigo is most frequently seen during hot and humid weather, chiefly in obese persons. Children and elderly persons are also predisposed. This type of dermatitis may involve the retroauricular areas; the folds of the upper eyelids; the creases of the neck, axillae, and antecubital areas; finger webs; inframammary area; umbilicus; inguinal, perineal, and intergluteal areas; popliteal spaces; and toe webs.

As a result of the maceration, a secondary infection by bacteria or fungi is induced. The inframammary area in obese women is most frequently the site of intertriginous candidiasis. The groins are also frequently affected by fungal (yeast or dermatophyte) infection. Bacterial infection may be caused by streptococci, staphylococci, *Pseudomonas*, or *Corynebacterium*. If *Pseudomonas* is involved, it may stain the underwear bluish green. Streptococcal intertrigo favors the neck, axillary, and inguinal folds of young children. There is a well-demarcated, fiery-red, moist, shiny surface and a foul smell, with an absence of satellite lesions.

In the differential diagnosis, seborrheic dermatitis typically involves the skinfolds. Intertriginous psoriasis and erythroasma are frequently overlooked, especially when the inguinal and intergluteal areas or fourth toe webs are involved, as in erythroasma. Fissured groin lesions may be a manifestation of Langerhans cell histiocytosis.

Treatment of intertrigo is directed at elimination of the maceration. Appropriate antibiotics or fungicides are applied locally. The apposing skin surfaces may be separated with gauze or other appropriate dressings; for example, InterDry Ag textile has an antimicrobial silver complex impregnated within the fabric that when placed in the folded area not only wicks away moisture, but also retains the activity against fungi and bacteria for up to 5 days. Botulinum toxin type A has been used to dry out areas predisposed to recurrent disease. Castellani paint is also useful, as is an antibacterial ointment. Low-potency topical corticosteroids and topical tacrolimus are helpful to reduce inflammation, but these should always be used in conjunction with a topical antifungal or antimicrobial agent.

**Kaya TI, et al:** Blue underpants sign. *J Am Acad Dermatol* 2005; 53:869–871.

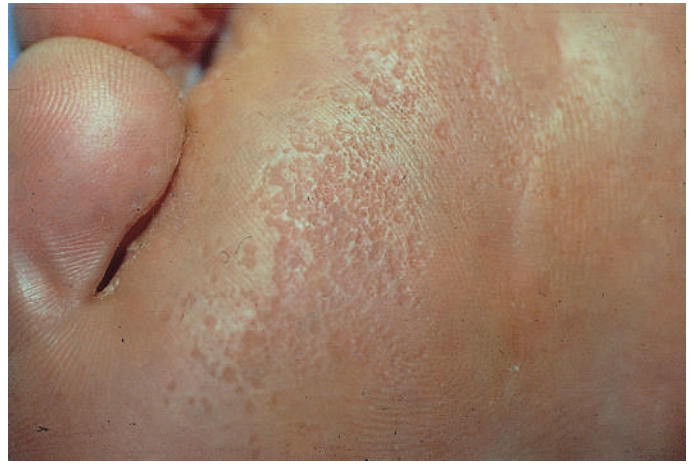**Muller N:** Intertrigo in the obese patient. *Ostomy Wound Manage* 2011; 57:16.

**Santiago-et-Sanchez-Mateos JL, et al:** Botulinum toxin type A for the preventative treatment of intertrigo in a patient with Darier's disease and inguinal hyperhidrosis. *Dermatol Surg* 2008; 34:1733.

**Silverman RA, et al:** Streptococcal intertrigo of the cervical folds in a five-month-old infant. *Pediatr Infect Dis J* 2012; 31:872–873.

## Pitted keratolysis

In pitted keratolysis, a bacterial infection of the plantar stratum corneum, the thick, weight-bearing portions of the soles



**Fig. 14-26** Pitted keratolysis. (Courtesy of Shyam Verma, MD.)

become gradually covered with shallow, asymptomatic, discrete round pits 1–3 mm in diameter, some of which become confluent, forming furrows (Fig. 14-26). Men with very sweaty feet during hot, humid weather are most susceptible. Rarely, palmar lesions may occur. No discomfort is produced, although the lesions are often malodorous.

Most disease is caused by *Kytococcus sedentarius*. It produces two serine proteases that can degrade keratin. Clinical diagnosis is not difficult, based on its unique appearance. Histologic examination generally demonstrates keratin pits lined by small cocci as well as filamentous bacteria.

Topical erythromycin or clindamycin is curative in pitted keratolysis. Miconazole or clotrimazole cream and Whitfield ointment are effective alternatives. Both 5% benzoyl peroxide gel and a 10–20% solution of aluminum chloride may be used. Botulinum toxin helps if there is associated hyperhidrosis.

**Blaise G, et al:** *Corynebacterium*-associated skin infections. *Int J Dermatol* 2008; 47:884.

**Van der Snoek EM, et al:** Pitted keratolysis. *J Eur Acad Dermatol Venereol* 2013; 27:1120–1126.

**Walling HW:** Primary hyperhidrosis increases the risk of cutaneous infection. *J Am Acad Dermatol* 2009; 61:242.

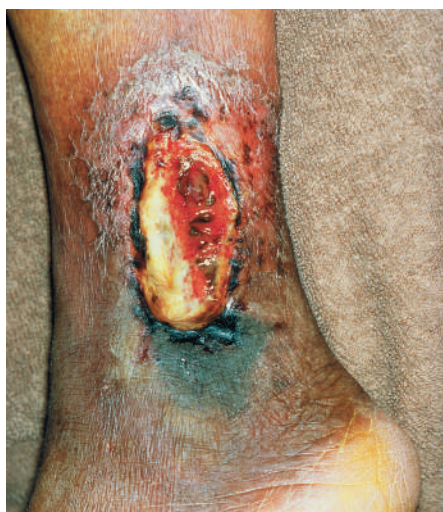## CLOSTRIDIAL INFECTIONS AND GANGRENE OF THE SKIN

Gangrene of the skin results from loss of the blood supply of a particular area and, in some cases, from bacterial invasion that promotes necrosis and sloughing of the skin. The various forms of bacterial infection causing gangrene are discussed here. The infectious causes are often severe and acute and may involve deep tissues; MRI may delineate the depth of involvement. Vascular gangrene, purpura fulminans, and diabetic gangrene are covered in Chapter 35; vaccinia gangrenosa in Chapter 19; and necrotizing fasciitis earlier in this chapter.

### Gas gangrene (clostridial myonecrosis)

Gas gangrene is the most severe form of infectious gangrene; it develops in deep lacerations of muscle tissue (Fig. 14-27). The incubation period is only a few hours. Onset is usually sudden and is characterized by a chill, a rise in temperature, marked prostration, and severe local pain. Gas bubbles (chiefly hydrogen) produced by the infection cause crepitation when the area is palpated. A mousy odor is characteristic. A plain radiograph will demonstrate the air. Gas gangrene is caused by a variety of *Clostridium* species, most frequently *Clostridium*





**Fig. 14-27** Clostridial gas gangrene.

*perfringens*, *C. oedematiens*, *C. septicum*, *C. difficile*, and *C. haemolyticum*. These are thick, gram-positive rods. *Clostridium* spores are resistant to skin sterilization chemicals; if injecting a site that is being soiled by stool incontinence, a mechanical wash before the sterile procedure, followed by an occlusive sterile dressing, is recommended.

A subacute variety of gas gangrene may be caused by an anaerobic streptococcus (peptostreptococcus), *Bacteroides*, or *Prevotella*. This nonclostridial myositis may be clinically similar, but with delayed onset (several days). The purulent exudate has a foul odor, and gram-positive cocci in chains are present. It is important to distinguish these two entities, since involved muscle may recover in nonclostridial myositis, and debridement may safely be limited to removal of grossly necrotic muscle. Infections with both clostridial and nonclostridial organisms such as *Streptococcus faecalis*, *S. anginosus*, *Proteus*, *Escherichia coli*, *Bacteroides*, and *Klebsiella* species may also cause crepitant cellulitis, when the infection is limited to the subcutaneous tissue. Treatment of all clostridial infections is wide surgical debridement and intensive antibiotic therapy with IV penicillin G and clindamycin. In occasional cases of clindamycin-resistant *Clostridium perfringens*, vancomycin may be an effective alternative. Hyperbaric oxygen therapy may be of value if immediately available. Infected patients with cirrhosis and diabetes have a poorer prognosis.

### Chronic undermining burrowing ulcers (Meleney gangrene)

Chronic burrowing ulcer was first described by Meleney as postoperative progressive bacterial synergetic gangrene. It usually follows drainage of peritoneal abscess, lung abscess, or chronic empyema. After 1 or 2 weeks, the wound markings or retention suture holes assume a carbuncloid appearance, finally differentiating into three skin zones: outer, bright red; middle, dusky purple; and inner, gangrenous with a central area of granulation tissue. The pain is excruciating. In Meleney postoperative progressive gangrene, the essential organism is a microaerophilic, nonhemolytic streptococcus (peptostreptococcus) in the spreading periphery of the lesion, associated with *Staphylococcus aureus* or Enterobacteriaceae in the zone of gangrene.

This disease is differentiated from ecthyma gangrenosum, which begins as vesicles, rapidly progressing to pustulation and gangrenous ulceration in debilitated patients, and is caused by *Pseudomonas aeruginosa*. Amebic infection with gangrene usually follows amebic abscess of the liver. The margins

of the ulcer are raised and everted, and the granulations have the appearance of raw beef covered with shreds of necrotic material. Glairy pus can be expressed from the margins. Pyoderma gangrenosum occurs in a different setting, lacks the bacterial findings, and does not respond to antibiotic therapy. Fusospirochetal gangrene occurs after a human bite.

Wide excision and grafting are primary therapy for Meleney gangrene. Antimicrobial agents, penicillin, and an aminoglycoside should be given as adjunctive therapy.

### Fournier gangrene of the penis or scrotum

Fournier syndrome is a gangrenous infection of the penis, scrotum, or perineum that may be caused by infection with group A streptococci or with mixed enteric bacilli and anaerobes. This is usually considered a form of necrotizing fasciitis because it spreads along fascial planes. Peak incidence is between ages 20 and 50, although cases have been reported in children. Diabetes mellitus, obesity, poor personal hygiene, long-standing oral corticosteroid therapy, and chronic alcoholism are predisposing factors. Culture for aerobic and anaerobic organisms should be carried out, and appropriate antibiotics started; surgical debridement and general support should be instituted.

**Aridogan IA, et al:** Epidemiological characteristics of Fournier's gangrene: a report of 71 patients. *Urol Int* 2012; 89:457–461.

**Kaafarani HM, et al:** Necrotizing skin and soft tissue infections. *Surg Clin North Am* 2014; 94:155–163.

**Khan F, et al:** Fournier's gangrene associated with intradermal injection of cocaine. *J Sex Med* 2013; 10:1184–1186.

**Khanna N:** Clindamycin-resistant *Clostridium perfringens* cellulitis. *J Tissue Viability* 2008; 17:95.

**Ling I, et al:** The crackling thigh. *NZ Med J* 2009; 122:81.

**McHugh RC, et al:** Clostridial sacroiliitis in a patient with fecal incontinence. *Pain Phys* 2008; 11:249.

**Oncel S, et al:** Rapidly developing gas gangrene due to a simple puncture wound. *Pediatr Emerg Care* 2010; 26:434–435.

**Ullah S, et al:** Fournier's gangrene. *Surgeon* 2009; 7:138.

### Actinomycosis

*Actinomyces* are anaerobic, gram-positive, filamentous bacteria that colonize the mouth, colon, and urogenital track. Infections are seen most often in the cervicofacial area but also on the abdominal region, thoracic area, or pelvis. Middle-age men are affected most often. Diabetic and immunosuppressed patients and alcoholics with poor dental hygiene are particularly at risk. The lesions begin as firm nodules or plaques and develop draining sinuses. Grains or sulfur granules may be present in the exudate, as in fungal mycetomas. In the cervicofacial region, the infection is known as lumpy jaw. The underlying bone may be involved with periostitis or osteomyelitis. Mandibular infection is seen four times as often as maxillary involvement (Fig. 14-28). The abdomen may be involved after a ruptured appendix or GI surgical procedure. Extension of the infection into the abdominal wall may produce draining sinuses on the abdominal skin. In the thoracic region, lung infection may spread to the thoracic wall.

Oropharyngeal actinomycosis is usually caused by *Actinomyces israelii* and *A. gerencseriae*. The condition is often clinically misdiagnosed as a malignancy, and the histologic appearance of the characteristic granules allows diagnosis. Sulfur granules consist of fine, delicate branching filaments. Eosinophilic clubs composed of immunoglobulin are seen at the periphery of the granule (Splendore-Hoeppli phenomenon). They resemble rays; hence the name, ray fungus (*Actinomyces*). Gram stain demonstrates long, gram-positive filaments.

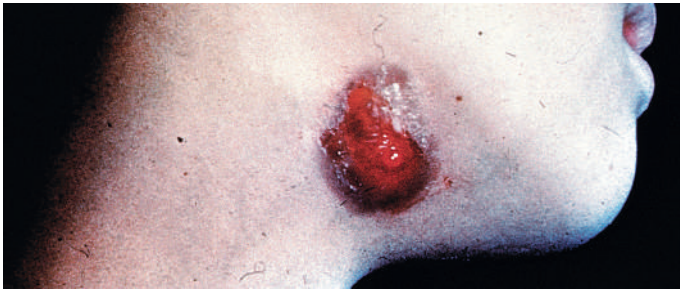

Fig. 14-28 Actinomycosis.

The crushed granule is used for inoculating cultures containing brain-heart infusion blood agar, incubated under anaerobic conditions at 37°C. Culture is difficult; therefore direct microscopy is important.

Penicillin G in large doses, 10–20 MU/day for 1 month, followed by 4–6 g/day of oral penicillin for another 2 months, may produce successful and lasting results. Other effective medications have been ampicillin, erythromycin, tetracyclines, ceftriaxone, and clindamycin. Surgical incision, drainage, and excision of devitalized tissue are important.

**Acevedo F, et al:** Actinomycosis: a great pretender. *Int J Infect Dis* 2008; 12:358.

**Briceño G, et al:** Cutaneous fistula due to pulmonary actinomycosis in a Mapuche girl. *Pediatr Dermatol* 2013; 30:504–505.

**Garner JP, et al:** Abdominal actinomycosis. *Int J Surg* 2007; 5:441.

**Gupta V, et al:** Primary cutaneous actinomycosis of upper extremity masquerading as soft tissue neoplasm. *Trop Doct* 2012; 42:58–59.

**Lancelli A, et al:** Two unusual presentations of cervicofacial actinomycosis and a review of the literature. *Acta Otorhinolaryngol Ital* 2008; 28:89.

**Wong VK, et al:** Actinomycosis. *BMJ* 2011; 343:d6099.

## Nocardiosis

Nocardiosis usually begins as a pulmonary infection from which dissemination occurs. Dissemination occurs most frequently in association with debilitating conditions, such as Hodgkin disease, periarteritis nodosa, leukemia, AIDS, organ transplants, or SLE. Skin involvement is seen in 10% of disseminated cases in the form of abscesses, erosions, or vesiculopustular lesions (Fig. 14-29). Primary cutaneous disease also occurs in healthy individuals in the form of a draining abscess or lymphangitic nodules following a cutaneous injury.

*Nocardia asteroides* is usually responsible for the disseminated form of nocardiosis. *Nocardia brasiliensis* is the most common cause of primary cutaneous disease. A prick by a thorn or briar, other penetrating injury, or an insect bite or sting may be the inciting event.

Nocardia are gram-positive, partially acid-fast, aerobic, filamentous bacteria. Some are branched, but filaments tend to be shorter and more fragmentary than those of *Actinomyces*. The surrounding red layer of immunoglobulin tends to be smooth rather than club shaped. On Sabouraud dextrose agar, without antibacterial additives, there are creamy or moist, white colonies, which later become chalky and orange colored.

The drug of first choice for cutaneous nocardial infection is TMP-SMX, 4 tablets twice daily for 6–12 weeks. Minocycline for *N. asteroides* and amoxicillin-clavulanate for *N. brasiliensis* infection are alternatives. Linezolid is active, but potential adverse effects limit its use. Amikacin and imipenem are effectively used in combination with a variety of antibiotics for disseminated infection.

**Bryant E, et al:** Lymphocutaneous nocardiosis. *Cutis* 2010; 85:73–76

**Dodiuk-Gad R, et al:** Cutaneous nocardiosis. *Int J Dermatol* 2010; 49:1380–1385.

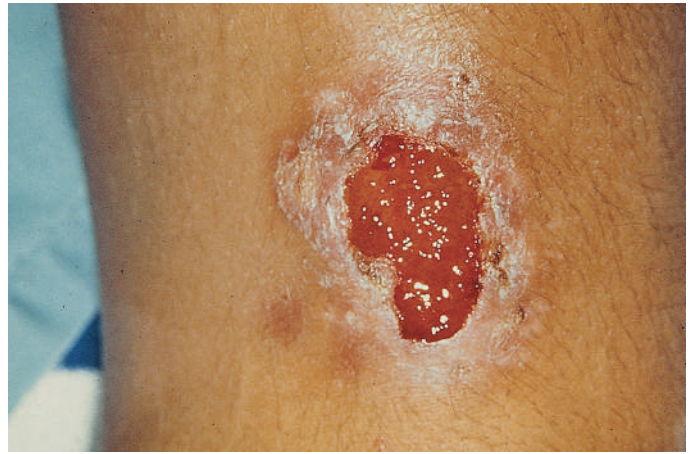

Fig. 14-29 Nocardiosis.

**Hardak E, et al:** Clinical spectrum and outcome of *Nocardia* infection: experience of 15-year period from a single tertiary medical center. *Am J Med Sci* 2012; 343:286–290.

**Wilson JW:** Nocardiosis. *Mayo Clin Proc* 2012; 87:403–407.

## INFECTIONS CAUSED BY GRAM-NEGATIVE ORGANISMS

### PSEUDOMONAS INFECTIONS

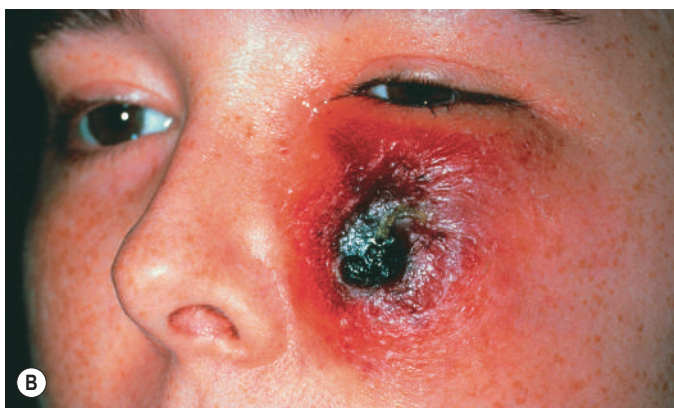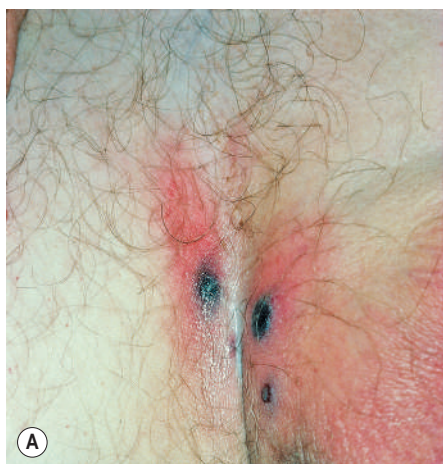#### Ecthyma gangrenosum

In the severely ill patient with ecthyma gangrenosum, opalescent, tense vesicles or pustules are surrounded by narrow, pink to violaceous halos. These lesions quickly become hemorrhagic and violaceous and rupture to become round ulcers with necrotic black centers (Fig. 14-30). They are usually on the buttocks and extremities and are often grouped closely together. Ecthyma gangrenosum occurs in debilitated persons who may be suffering from leukemia, in the severely burned patient, in pancytopenia or neutropenia, or in patients with a functional neutrophilic defect, terminal carcinoma, or other severe chronic disease. Healthy infants may develop lesions in the perineal area after antibiotic therapy in conjunction with maceration of the diaper area.

The classic vesicle suggests the diagnosis. The contents of the vesicles or hemorrhagic pustules will show gram-negative bacilli on Gram staining, and cultures will be positive for *Pseudomonas aeruginosa*. Because this is usually a manifestation of sepsis, the blood culture will also show *P. aeruginosa*. However, in healthy infants with diaper-area lesions, in patients with HIV infection, and in other occasional cases, early lesions may occur at a portal of entry, allowing for diagnosis and treatment before evolution into sepsis occurs. Although ecthyma gangrenosum is classically associated with *P. aeruginosa* infection, similar hemorrhagic pustules may occur from a variety of other gram-negative organisms (e.g., *Serratia marcescens*, *Klebsiella pneumoniae*, *Aeromonas hydrophilia*, *Xanthomonas maltophilia*, *Morganella morganii*, *Escherichia coli*, *Citrobacter freundii*), fungal infections (e.g., *Candida albicans*, *Aspergillus fumigatus*, *Fusarium solani*, *Scytalidium dimidiatum*), and at times, *Staphylococcus aureus*.

Recommended treatment is the immediate institution of IV antipseudomonal penicillin. The addition of granulocyte-macrophage colony-stimulating factor to stimulate both proliferation and differentiation of myeloid precursors is an adjunct in a patient with myelodysplasia or treatment-induced neutropenia. Patients have a poorer prognosis if there are





**Fig. 14-30** A and B, Ecthyma gangrenosum.

multiple lesions, if there is a delay in diagnosis and institution of appropriate therapy, and if neutropenia does not resolve by the end of a course of antibiotics. Instrumentation or catheterization increases the risk of this infection.

Other lesions also seen with *Pseudomonas* septicemia include sharply demarcated areas of cellulitis, macules, papules, plaques, and nodules, characteristically found on the trunk. *Pseudomonas mesophilica*, *Burkholderia cepacia*, *Citrobacter freundii*, and *Stenotrophomonas maltophilia* may also produce such skin lesions in immunocompromised individuals.

### Green nail syndrome

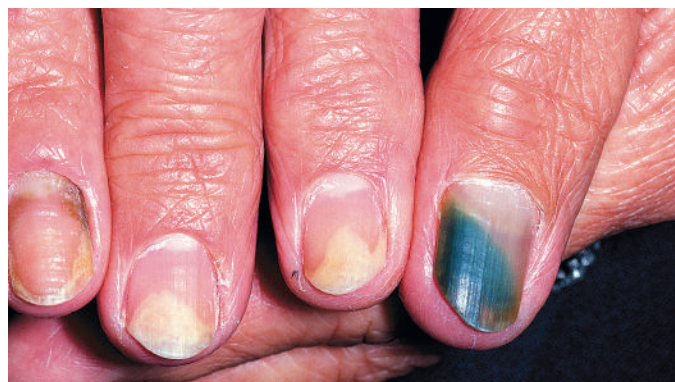Green nail syndrome is characterized by onycholysis of the distal portion of the nail and a striking greenish discoloration in the separated areas (Fig. 14-31). It is frequently associated with paronychia in persons whose hands are often in water. Overgrowth of *P. aeruginosa* accounts for the pigment. Soaking the affected finger in a 1% acetic acid solution twice a day has been found to be helpful. Trimming the onycholytic nail plate, followed by application of Neosporin solution twice a day, is also effective.

Green foot syndrome results from colonization of rubber sports shoes with *P. aeruginosa*. The organism produces pyoverdinin, which stains the foot and toenails.

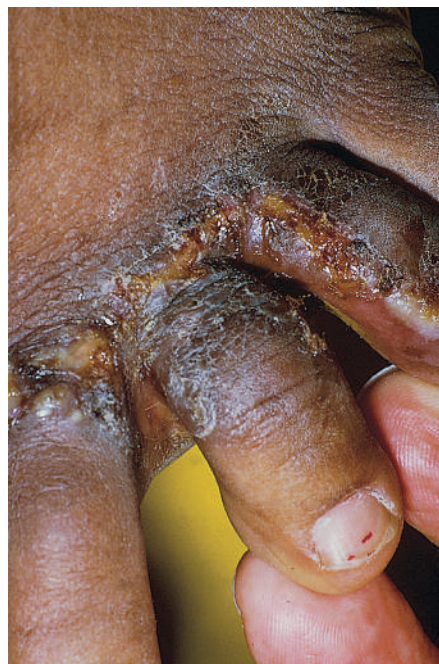### Gram-negative toe web infection

Toe web infection often begins with dermatophytosis. With increasing inflammation and maceration, dermatophytosis may progress to dermatophytosis complex, in which many types of gram-negative organism may be recovered; however, it is more difficult to culture dermatophytes. Eventually, denudation with purulent or serous discharge and marked edema and erythema of the surrounding tissue may be seen (Fig. 14-32). Prolonged immersion may also cause hydration and maceration of the interdigital spaces, with overgrowth of gram-negative organisms. *P. aeruginosa* is the most prominent, but frequently a mixture of other gram-negative organisms, such as *E. coli* and *Proteus*, are present. Patients may have red, painful nodules of the calf that do not drain, spontaneously involute, then reappear 1–2 weeks later. Culture of these subcutaneous abscesses will reveal *Pseudomonas* or other gram-negative bacteria, which likely originate in the macerated toe webs.

Early dermatophytosis, dermatophytosis simplex, may simply be treated with topical antifungal agents. However,



**Fig. 14-31** Green nail syndrome complicating onycholysis.



**Fig. 14-32** Gram-negative toe web infection.

once the scaling and peeling progress to white maceration, soggy scaling, bad odor, edema, and fissuring, treatment must also include topical antibiotics or acetic acid compresses. Drying of the interdigital spaces with a fan is a helpful adjunct. Full-blown gram-negative toe web infection with widespread denudation and erythema, purulence, and edema requires sys-

temic antibiotics. A third-generation cephalosporin or a fluoroquinolone is recommended.

### Blastomycosis-like pyoderma

Large verrucous plaques with elevated borders and multiple pustules may occur as a chronic vegetating infection. Most patients have an underlying systemic or local host compromise. Bacteria such as *P. aeruginosa*, *S. aureus*, *Proteus*, *E. coli*, and streptococci may be isolated. Appropriate antibiotics for the cultured organism may be augmented by acitretin.

### *Pseudomonas aeruginosa* folliculitis (hot tub folliculitis)

Pseudomonal folliculitis is characterized by pruritic follicular, maculopapular, vesicular, or pustular lesions occurring within 1–4 days after bathing in a hot tub, whirlpool, or public swimming pool (Fig. 14-33). As the water temperature rises, free chlorine levels fall, even though total chlorine levels appear adequate. This allows the bacteria to proliferate. Diving suits may become colonized, and wearing them may result in *P. aeruginosa* folliculitis. One case occurred limited to the hand and wrist occluded under colonized rubber gloves.

Most lesions occur on the sides of the trunk, axillae, buttocks, and proximal extremities. The apocrine areas of the breasts and axillae are often involved. Associated complaints may include earache, sore throat, headache, fever, and malaise. Rarely, systemic infection may result; breast abscess and bacteremia have been reported. Large community outbreaks have occurred associated with public pools, and 27 employees of a cardboard manufacturing facility who were exposed to wet work developed *Pseudomonas* folliculitis of the extremities as an occupational disorder. *Aeromonas hydrophilia* was found to be responsible for a clinically similar folliculitis that affected two siblings playing in an inflatable swimming pool.

The folliculitis involutes usually within 7–14 days without therapy, although multiple prolonged recurrent episodes have occasionally been reported. In patients with fever, constitutional symptoms, or prolonged disease, a third-generation oral cephalosporin or a fluoroquinolone such as ciprofloxacin or ofloxacin may be useful. Preventive measures have been water filtration, automatic chlorination to maintain a free chlorine level of 1 ppm, maintenance of water at pH 7.2–7.8, and frequent changing of the water. Bromination of the water and ozone ionization are other options.

*Pseudomonas* hot foot syndrome was reported in a group of 40 children who developed painful, erythematous plantar

nodules or pustules after wading in a community pool whose floor was coated with abrasive grit. One biopsy showed neutrophilic eccrine hidradenitis; another revealed dermal microabscesses. Most were treated symptomatically, and resolution occurred within 2 weeks. Other patients have been reported after exposure to sauna and hot tubs.

### External otitis

Swelling, maceration, and pain may be present. In up to 70% of cases, *P. aeruginosa* may be cultured. External otitis is especially common in swimmers. Local application of antipseudomonal and anti-inflammatory Cortisporin otic solution or suspension, or 2% acetic acid compresses with topical corticosteroids, will help clear this infection. In patients with otorrhea or pus emanating from the canal, if the symptoms have been present for 1 week or more, or if diabetes or an immunologic defect is present, cleansing the canal, visualizing the tympanic membrane for perforation, and other precautions will be most readily handled by an otolaryngology consultation. Application of otic Domeboro solution after swimming will help prevent recurrence. Fungi such as *Candida* and *Aspergillus* are other causes. Antifungal solutions (e.g., ciclopiroxolamine) combined with corticosteroid solutions are effective in otomycosis. There is also a threat of external otitis occurring after ear surgery (Fig. 14-34). If the patient is a swimmer or has diabetes, acetic acid compresses for 1 or 2 days before surgery may prevent this complication.

External otitis must be distinguished from allergic contact dermatitis due to neomycin in Cortisporin otic suspension. Allergic contact dermatitis produces severe pruritus, although tenderness may also be noted. Dermatitis may extend down the side of the cheek in a pattern suggesting drainage of the suspension.

A severe type, referred to as malignant external otitis, occurs in elderly patients with diabetes or in those immunocompromised with HIV infection, receiving chemotherapy, or living with organ transplants. The swelling, pain, and erythema are more pronounced, with purulence and a foul odor. Facial nerve palsy develops in 30% of patients, and cartilage necrosis may occur. This is a life-threatening infection in these older, compromised individuals and requires swift institution and prolonged administration (4–6 weeks) of oral quinolone antibiotics.

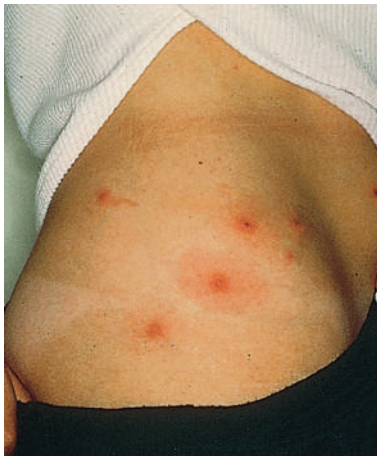

Fig. 14-33 *Pseudomonas* hot tub folliculitis.

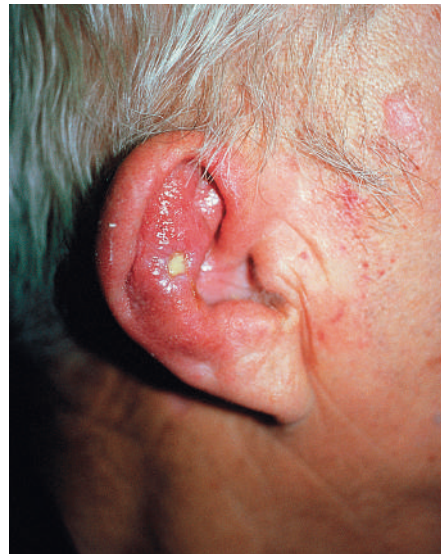

Fig. 14-34 *Pseudomonas* external otitis after shave biopsy.



Lastly, commercial ear piercing of the upper ear cartilage may lead to infection with *Pseudomonas*, with resulting cosmetic deformity a reported complication.

## Gram-negative folliculitis

Although gram-negative folliculitis is usually caused by Enterobacteriaceae, *Klebsiella*, *Escherichia*, *Proteus*, or *Serratia*, occasional cases caused by *Pseudomonas* have been seen. They differ from gram-negative infection in patients with acne in that the site of *Pseudomonas* colonization is the external ear, and topical therapy alone to the face and ears is sufficient for cure. Also, an outbreak of gram-negative pustular dermatitis on the legs, arms, torso, and buttocks occurred in a group of college students who hosted a mud-wrestling social event.

- Aygenel G, et al:** *Burkholderia cepacia* as a cause of ecthyma gangrenosum-like lesions. *Infection* 2008; 36:271.
- Bae JM, et al:** Green foot syndrome. *J Am Acad Dermatol* 2013; 69:e198–e199.
- Carfrae MJ, et al:** Malignant otitis externa. *Otolaryngol Clin North Am* 2008; 41:537.
- Chang AY, et al:** Nonpseudomonal ecthyma gangrenosum associated with methicillin-resistant *Staphylococcus aureus* infection. *Cutis* 2012; 90:67–69.
- Cho SB, et al:** Green nail syndrome associated with military footwear. *Clin Exp Dermatol* 2008; 33:791.
- Goolamali SI, et al:** Ecthyma gangrenosum. *Clin Exp Dermatol* 2009; 34:e180.
- Handley RT:** Otitis externa. *JAAPA* 2009; 22:44.
- Hui CP et al:** Acute otitis externa. *Paediatr Child Health* 2013; 18:96–101.
- Kaitlin V, et al:** Macerated foot dermatitis related to occlusive footwear. *WV Med J* 2013; 109:8–9.
- Keene WE, et al:** Outbreak of *Pseudomonas aeruginosa* infections caused by commercial piercing of the upper ear cartilage. *JAMA* 2004; 291:981.
- Lambor DV, et al:** Necrotising otitis externa. *J Laryngol Otol* 2013; 127:1071–1077.
- Lu XL, et al:** Good response of a combined treatment of acitretin and antibiotics in blastomycosis-like pyoderma. *Eur J Dermatol* 2009; 19:261–262.
- Manresa MJ, et al:** *Aeromonas hydrophilia* folliculitis associated with an inflatable swimming pool. *Pediatr Dermatol* 2009; 26:601–603.
- Mazza J, et al:** *Pseudomonas* folliculitis contracted from rubber gloves. *J Am Acad Dermatol* 2013; 69:e93–e94.
- Michl RK, et al:** Outbreak of hot-foot syndrome caused by *Pseudomonas aeruginosa*. *Klin Paediatr* 2012; 224:252–255.
- Nieves D, et al:** Smoldering gram-negative cellulitis. *J Am Acad Dermatol* 1999; 41:319.
- Patel JK, et al:** Ecthyma gangrenosum caused by *Escherichia coli* bacteremia. *Cutis* 2009; 84:261–267.
- Prindaville B, et al:** Chronic granulomatous disease presenting with ecthyma gangrenosum in a neonate. *J Am Acad Dermatol* 2014; 71:e44–45.
- Segna KG, et al:** “Hot tub” folliculitis from a nonchlorinated children’s pool. *Pediatr Dermatol* 2011; 28:590–591.
- Tsuyhima K, et al:** Ecthyma gangrenosum with *Citrobacter freundii* infection. *J Eur Acad Dermatol Venereol* 2009; 23:709–710.
- Yan W, et al:** Ecthyma gangrenosum and multiple nodules. *Pediatr Dermatol* 2011; 28:204–205.

## MALACOPLAKIA (MALAKOPLAKIA)

This rare granuloma was originally reported only in the genitourinary tract of immunosuppressed renal transplant recipients, but malacoplakia may also occur in the skin and subcutaneous tissues of other immunocompromised patients, as with HIV infection. Patients are unable to resist infections with *S. aureus*, *P. aeruginosa*, and *E. coli*. There is defective

intracellular digestion of the bacteria once they have been phagocytosed.

The granulomas may arise as masslike lesions or nodules, abscesses, or ulcerations. They favor the perineum but also affect the abdominal wall, thorax, extremities, and axilla. The tongue is also a site of appearance, usually presenting as a mass lesion. Histologically, foamy eosinophilic Hansemann macrophages contain calcified, concentrically laminated, intracytoplasmic bodies (Michaelis-Gutmann). Scattered immunoblasts, neutrophils, and lymphocytes are found in the dermis.

Successful treatment of malacoplakia depends on the isolated organism; a fluoroquinolone such as ciprofloxacin or ofloxacin typically is useful.

- Alfonso JP, et al:** Cutaneous malakoplakia. *An Bras Dermatol* 2013; 88:432–437.
- Diapera MJ, et al:** Malacoplakia of the tongue. *Am J Otolaryngol* 2009; 30:101.
- Flann S, et al:** Cutaneous malakoplakia in an abdominal skin fold. *J Am Acad Dermatol* 2010; 62:896.
- Rubinson R, et al:** Malakoplakia. *Pediatr Dermatol* 2012; 29:541–543.
- Verma SB:** Cutaneous malakoplakia. *Int J Dermatol* 2011; 50:184–186.

## HAEMOPHILUS INFLUENZAE CELLULITIS

*Haemophilus influenzae* type B causes a distinctive bluish or purplish red cellulitis of the face, accompanied by fever in children younger than 2 years. The condition is rarely seen in countries where the vaccination is available. It is given at 2, 4, and 6 months of age. The importance of recognizing *H. influenzae* cellulitis is related to the bacteremia that often accompanies the cellulitis. The bacteremia may lead to meningitis, orbital cellulitis, osteomyelitis, or pyarthrosis. Cultures of the blood and needle aspirates of the cellulitis should yield the organism. Cefotaxime or ceftriaxone is effective. In a family with children under age 4, the index case, both parents, and children at risk (unvaccinated) should be given rifampin to clear the nasal carriage state and prevent secondary cases. *H. influenzae* type A is not covered by the vaccine, and reports of this organism causing invasive infection, including cellulitis, are increasing.

- Bruce MG, et al:** *Haemophilus influenzae* serotype A invasive disease, Alaska, USA, 1983–2011. *Emerg Infect Dis* 2013; 19:932–937.
- Rimon A, et al:** Periorbital cellulitis in the era of *Haemophilus influenzae* type B vaccine. *J Pediatr Ophthalmol Strabismus* 2008; 45:300.

## CHANCROID

Chancroid (soft chancre) is an infectious, ulcerative STD caused by the gram-negative bacillus *Haemophilus ducreyi* (the Ducrey bacillus). One or more deep or superficial, tender ulcers on the genitalia and painful inguinal adenitis in 50%, which may suppurate, are characteristic of the disease. Men outnumber women manyfold.

Chancroid begins as an inflammatory macule or pustule 1–5 days, or rarely as long as 2 weeks, after intercourse. It generally appears on the distal penis or perianal area in men or on the vulva, cervix, or perianal area in women. However, many cases of extragenital infection on the hands, eyelids, lips, or breasts have been reported. Autoinoculation frequently forms kissing lesions on the genitalia, and women are apt to have more numerous lesions. The pustule ruptures early with the formation of a ragged ulcer that lacks the induration of a chancre, usually being soft with an indefinite inflammatory thickening. The ulcers appear punched out or have undermined, irregular edges surrounded by mild hyperemia

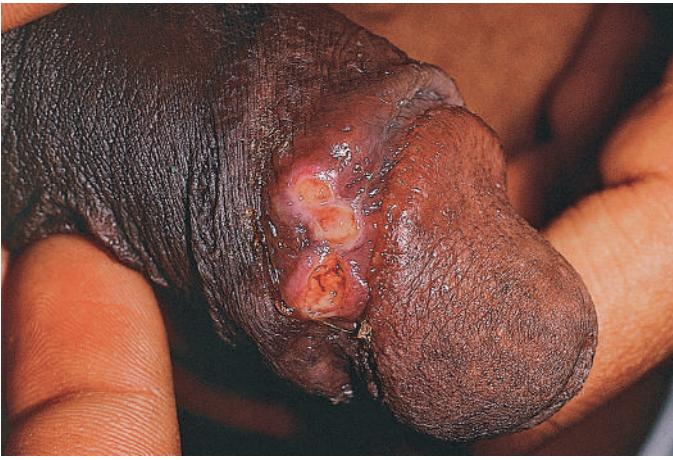

Fig. 14-35 Chancroid.

(Fig. 14-35). The base is covered with a purulent, dirty exudate. The ulcers bleed easily and are very tender.

A number of clinical variants have been described, including granuloma inguinale-like, giant ulcers, serpiginous ulcers, transient chancroid, and follicular and papular variants.

Only about half the cases of genital chancroid manifest inguinal adenitis. Suppuration of the bubo (inguinal lymph node) may occur despite early antibiotic therapy. The lymphadenitis of chancroid, mostly unilateral, is tender and may rupture spontaneously. Left untreated, the site of perforation of the broken-down bubo may assume the features of a soft chancre (chancrous bubo).

As a result of mixed infection, phagedenic and gangrenous features may develop. Chronic, painful, destructive ulcers, which begin on the prepuce or glans and spread by direct extension along the shaft of the penis, are present. They may sometimes attack the scrotum or pubes. The edges of the ulcer are likely to be elevated, firm, and undermined. The granulating base, which bleeds easily, is covered with a thick, purulent exudate and dirty, necrotic detritus. The neighboring skin may be edematous and dusky red, and the regional lymph glands may be swollen, although this is not necessarily a marked feature. There is severe mutilation as a result of sloughing, with no evidence of spontaneous healing.

This type of phagedena (spreading and sloughing ulceration) is a rare complication of chancroidal infections together with another, secondary bacterial infection. Treatment is by the use of antibiotics locally and internally, directed against secondary bacteria, as well as the primary process. Multiple infections may be present, such as chancroid, syphilis, or granuloma inguinale.

On histologic investigation, the ulcer may include a superficial necrotic zone with an infiltrate consisting of neutrophils, lymphocytes, and red blood cells. Deep to this, new vessel formation is present, with vascular proliferation. Deeper still is an infiltrate of lymphocytes and plasma cells. Ducrey bacilli may or may not be seen in the sections.

The definitive diagnosis of chancroid requires identification by culture. Solid-media culture techniques have allowed definitive diagnosis and sensitivity testing; however, culture is unavailable in many settings, and recovery is only about 80% successful. Specimens for culture should be taken from the purulent ulcer base and active border without extensive cleaning. They should be inoculated in the clinic; transport systems have not been evaluated. The selective medium contains vancomycin, and cultures are done in a water-saturated environment with 1–5% CO<sub>2</sub>, at a temperature of 33°C. Occasional outbreaks are caused by vancomycin-sensitive strains.

In these cases, culture will only be successful using vancomycin-free media.

Smears are only diagnostic in 50% of cases in the best hands. A probable diagnosis is made by a clinically compatible examination and negative testing for conditions that may mimic chancroid in presentation. Chancroid probably is most frequently mistaken for herpes progenitalis. A history of recurrent grouped vesicles at the same site should help eliminate the chance of a misdiagnosis. Traumatic ulcerations should also be ruled out; these occur mostly along the frenulum or as multiple erosions on the prepuce. Adenopathy is absent, and some degree of phimosis is present.

The clinical features that differentiate chancroid from syphilitic chancre are described in Chapter 18. However, the diagnosis of chancroid does not rule out syphilis. Either the lesion may already be a mixed sore or the subsequent development of syphilis should be anticipated, since the incubation period of the chancre is much longer than that of chancroid. Repeated darkfield examinations for *Treponema pallidum* are necessary, even in a sore where the diagnosis of chancroid has been established. Serologic tests for syphilis should be obtained initially, then monthly for the next 3 months, and serologic testing for HIV infection should also be done. Chancroidal genital ulcer disease facilitates the transmission of HIV infection. In HIV-infected patients, chancroid may have a prolonged incubation period, the number of ulcers may be increased, extragenital sites are more frequently affected, antibiotic therapy fails more often, and healing is slower when it does occur. Complications such as penile amputation from a deep, transverse ulcer may result.

## Treatment

The treatment of choice for chancroid is azithromycin, 1 g orally in a single dose. Erythromycin, 500 mg four times a day for 7 days; ceftriaxone, 250 mg intramuscularly in a single dose; and ciprofloxacin, 500 mg orally twice a day for 3 days, are also recommended treatments. Ciprofloxacin should not be used in pregnant or lactating women or in children younger than 17 years. Partners who have had sexual contact with the patient within the 10 days before the onset of symptoms should be treated with a recommended regimen.

Phimosis that does not subside after irrigation of the preputial cavity may have to be relieved by a dorsal slit. Circumcision should be deferred for at least 2 or 3 months. If frank pus is already present, repeated aspirations (not incisions) may be necessary.

**Basta-Juzbasic A, et al:** Chancroid, lymphogranuloma venereum, granuloma inguinale, genital herpes simplex infection, and molluscum contagiosum. *Clin Dermatol* 2014; 32:290–298.

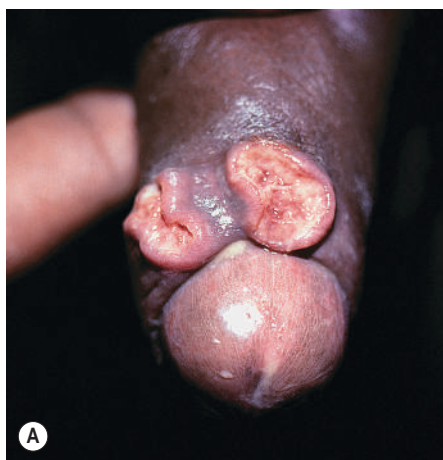**Canhoto M, et al:** *Haemophilus ducreyi* and *Treponema pallidum* co-infection in and HIV-negative male presenting with anal ulcerations. *Colorectal Dis* 2012; 14:e749–e750.

**Kemp M, et al:** European guidelines for the management of chancroid, 2011. *Int J STD AIDS* 2011; 22:241–244.

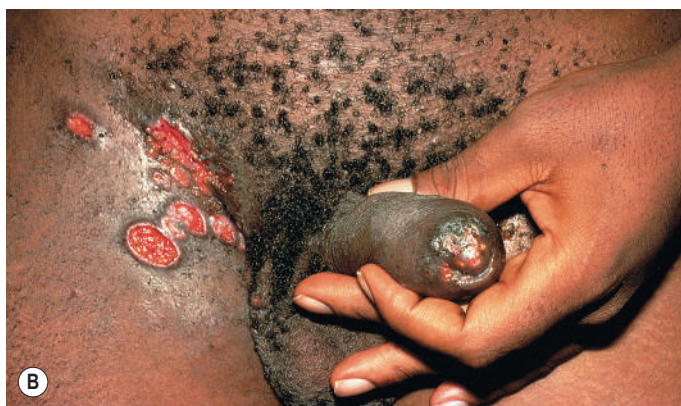## GRANULOMA INGUINALE (GRANULOMA VENEREUM, DONOVANOSIS)

Granuloma inguinale is a mildly contagious, chronic, granulomatous, locally destructive disease characterized by progressive, indolent, serpiginous ulcerations of the groins, pubes, genitalia, and anus. The disease begins as single or multiple subcutaneous nodules, which erode through the skin to produce clean, sharply defined lesions, which are usually painless (Fig. 14-36, A). More than 80% of cases demonstrate





**Fig. 14-36** A and B, Granuloma inguinale.



hypertrophic, vegetative granulation tissue, which is soft, has a beefy-red appearance, and bleeds readily. Approximately 10% of cases have ulcerative lesions with overhanging edges and a dry or moist floor (Fig. 14-36, B). A membranous exudate may cover the floor of fine granulations, and the lesions are moderately painful. Occasional cases are misdiagnosed as carcinoma of the penis. The lesions enlarge by autoinoculation and peripheral extension with satellite lesions and by gradual undermining of tissue at the advancing edge.

The genitalia are involved in 90% of cases, inguinal region in 10%, anal region in 5–10%, and distal sites in 1–5%. Lesions are limited to the genitalia in approximately 80% of patients and to the inguinal region in less than 5%. The lesions most frequently occur on the prepuce or glans in men and on the labia in women. The incubation period is unknown; it may vary between 8 and 80 days, with a 2- to 3-week period being most common.

Persisting sinuses and hypertrophic scars, devoid of pigment, are fairly characteristic of granuloma inguinale. The regional lymph nodes are usually not enlarged. In later stages, as a result of cicatrization, the lymph channels are sometimes blocked, and pseudoelephantiasis of the genitals (esthiomene) may occur. Mutilation of the genitals and destruction of deeper tissues are observed in some patients. Dissemination from the inguinal region may be by hematogenous or lymphatic routes. There may be involvement of liver, other organs, eyes, face, lips, larynx, chest, and, rarely, bones. During childbearing, the cervical lesions may extend to the internal genital organs. Squamous cell carcinoma may rarely supervene.

Granuloma inguinale is caused by the gram-negative bacterium *Klebsiella granulomatis*. It is sexually transmitted in the majority of cases, with conjugal infection occurring in 12–52% of marital or steady sexual partners. Also, it is speculated that

*K. granulomatis* is an intestinal inhabitant that leads to granuloma inguinale through autoinoculation, or sexually through vaginal intercourse if the vagina is contaminated by enteric bacteria, or through rectal intercourse, heterosexual or homosexual. *K. granulomatis* probably requires direct inoculation through a break in the skin or mucosa to cause infection. Those affected are generally young adults.

On histologic investigation, in the center of the lesion, the epidermis is replaced by serum, fibrin, and polymorphonuclear leukocytes. At the periphery, the epidermis demonstrates pseudoepitheliomatous hyperplasia. In the dermis, there is a dense granulomatous infiltration composed chiefly of plasma cells and histiocytes, and scattered throughout are small abscesses containing polymorphonuclear leukocytes. Characteristic pale-staining macrophages that have intracytoplasmic inclusion bodies are found. The parasitized histiocytes may measure 20  $\mu\text{m}$  or more in diameter. The ovoid Donovan bodies measure 1–2  $\mu\text{m}$  and may be visualized by using Giemsa or silver stains. The best method, however, is toluidine blue staining of semithin, plastic-embedded sections. Crushed smears of fresh biopsy material stained with Wright or Giemsa permit the demonstration of Donovan bodies and provide rapid diagnosis.

Granuloma inguinale may be confused with ulcerations of the groin caused by syphilis or carcinoma, but it is differentiated from these diseases by its long duration and slow course, by the absence of lymphatic involvement, and in the case of syphilis, by a negative test for syphilis and failure to respond to antisyphilitic treatment. It should not be overlooked that other venereal diseases, especially syphilis, often coexist with granuloma inguinale. Additionally, all patients presenting with STDs should be tested for HIV infection and their sexual partners evaluated. Lymphogranuloma venereum (LGV) at an early stage would most likely be accompanied by inguinal adenitis. In later stages, when stasis, excoriations, and enlargement of the outer genitalia are common to granuloma inguinale and LGV, the absence of a positive LGV complement fixation test and the presence of Donovan bodies in the lesions permit the diagnosis of granuloma inguinale.

## Treatment

Oral TMP-SMX (1 double-strength tablet) or doxycycline (100 mg) twice daily for a minimum of 3 weeks is the recommended regimen. Therapy should be continued until all lesions have healed completely. Alternative regimens are oral ciprofloxacin, 750 mg twice daily; erythromycin base, 500 mg four times daily; and azithromycin, 1 g once weekly, all for at least 3 weeks. The addition of an IV aminoglycoside such as gentamicin, 1 mg/kg every 8 h, should be considered if lesions do not respond within the first few days and in HIV-infected patients.

**Basta-Juzbasic A, et al:** Chancroid, lymphogranuloma venereum, granuloma inguinale, genital herpes simplex infection, and molluscum contagiosum. *Clin Dermatol* 2014; 32: 290–298.

**Bezerra SM, et al:** Granuloma inguinale. *An Bras Dermatol* 2011; 86: 585–586.

**Narang T, et al:** Genital elephantiasis due to donovanosis. *Int J STD AIDS* 2013; 23:835–836.

## GONOCOCCAL DERMATITIS

Primary gonococcal dermatitis is a rare infection that occurs after primary inoculation of the skin from an infected focus. It may present as grouped pustules on an erythematous base on the finger, simulating herpetic whitlow, with or without an ascending lymphangitis. Scalp abscesses in infants may occur

secondary to direct fetal monitoring in mothers with gonorrhea. It may also cause an inflammation of the median raphe or a lymphangitis of the penis with or without accompanying urethritis. Treatment is the same as that of gonorrheal urethritis. A single oral dose of cefixime, 400 mg, is usually curative. Ceftriaxone is also effective as a 125-mg single IM dose.

### Gonococemia

Gonococemia is characterized by a hemorrhagic vesiculopustular eruption, bouts of fever, and arthralgia or actual arthritis of one or several joints. The skin lesions begin as tiny erythematous macules that evolve into vesicopustules on a deeply erythematous or hemorrhagic base or into purpuric macules that may be as much as 2 cm in diameter (Fig. 14-37). These purpuric lesions occur acrally, mostly on the palms and soles, and over joints. They are accompanied by fever, chills, malaise, migratory polyarthralgia, myalgia, and tenosynovitis. The vesicopustules are usually tender and sparse and occur mainly on the extremities. Involution of the lesions takes place in about 4 days.

Many patients are women with asymptomatic anogenital infections in whom dissemination occurs during pregnancy or menstruation. Liver function abnormalities, myocarditis, pericarditis, endocarditis, and meningitis may complicate this infection. In severe or recurrent cases, complement deficiency, especially of the late (C5, C6, C7, or C8) components, should be investigated.

The causative organism is *Neisseria gonorrhoeae*. These organisms can at times be demonstrated in the early skin lesion histologically, by smears, and by cultures. Gonococci may be found in the blood, genitourinary tract, pharynx, joints, and skin. The skin lesions of gonococemia may be identical to those seen in meningococemia, nongonococcal bacterial endocarditis, rheumatoid arthritis, the rickettsial diseases, SLE, periarteritis nodosa, Haverhill fever, and typhoid fever. Septic emboli with any gram-negative organism or *Candida* classically manifest as hemorrhagic pustules.

The treatment of choice for disseminated gonococcal infection is ceftriaxone, 1 g/day intravenously or intramuscularly for 24–48 h after improvement begins. Therapy then may be switched to cefixime, 400 mg orally twice daily for at least 1 week. Alternative initial drugs include cefotaxime or ceftizoxime, 1 g every 8 h. Spectinomycin, 2 g intramuscularly every 12 h, may be used for persons allergic to  $\beta$ -lactam drugs.

If a cephalosporin is used, either doxycycline, 100 mg twice daily for 7 days, or azithromycin, 1 g as a single dose, should

be given to treat coexisting chlamydial infection. Serologic testing for HIV infection should also be done, as well as screening for syphilis. Sex partners within 30 days for symptomatic infection and 60 days for asymptomatic infection should be referred for treatment.

**Dutertre M, et al:** Gonococemia mimicking a lupus flare in a young woman. *Lupus* 2014; 23:81–83.

**Mahendran SM:** Disseminated gonococcal infection presenting as cutaneous lesions in pregnancy. *J Obstet Gynecol* 2007; 27:617.

**Suzaki A, et al:** Disseminated gonococcal infection in Japan. *Intern Med* 2011; 50:2039–2043.

### MENINGOCOCCEMIA

Acute meningococemia presents with fever, chills, hypotension, and meningitis. Half to two thirds of patients develop a petechial eruption, most frequently on the trunk and lower extremities, which may progress to ecchymoses, bullous hemorrhagic lesions, and ischemic necrosis (Fig. 14-38). Often, acral petechiae are present, and petechiae may be noted on the eyelids. Angular infarctive lesions with an erythematous rim and gun-metal gray interior are characteristic of meningococcal sepsis. Occasionally, a transient, blanchable, morbilliform eruption is the only cutaneous finding. The oral and conjunctival mucous membranes may be affected.

Meningococemia primarily affects young children, males more frequently than females. Patients with asplenia, immunoglobulin deficiencies, or inherited or acquired deficiencies of the terminal components of complement or properdin are predisposed to infection.

A rare variant is chronic meningococemia. There are recurrent episodes of fever, arthralgias, and erythematous macules that may evolve into lesions with central hemorrhage. Acral hemorrhagic pustules, similar to those found in gonococcal sepsis, may be seen. Patients are generally young adults with fevers lasting 12 h interspersed with 1–4 days of well-being.

Meningococemia is caused by the fastidious gram-negative diplococcus *Neisseria meningitidis*. It has a polysaccharide capsule that is important in its virulence and serotyping. The human nasopharynx is the only known reservoir, with carriage rates in the general population estimated to be 5–10%.

Treatment is with IV ceftriaxone, 2 g four times daily, or penicillin G, 300,000 U/kg/day up to 24 MU/day for 7 days. Dexamethasone, cefotaxime, chloramphenicol, and TMP-SMX are alternatives. One dose of ciprofloxacin, 500 mg, is given after the initial course of antibiotics to clear nasal carriage. Household members and day care and close school contacts

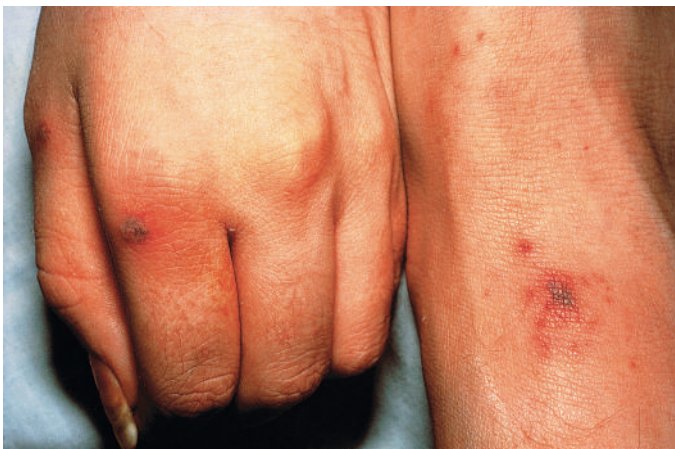

Fig. 14-37 Gonococemia.

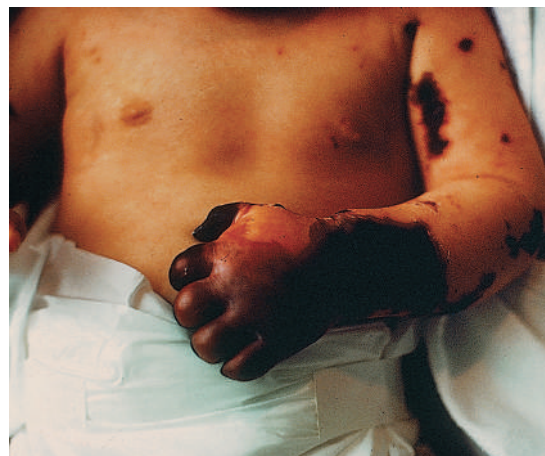

Fig. 14-38 Meningococemia.



should receive prophylactic therapy. Rifampin, 10 mg/kg every 12 h for 2 days, is an alternative prophylactic therapy for children. A polyvalent vaccine is effective against groups A, C, Y, and W-135 and is recommended for high-risk groups.

**Abbas A, Mujeeb AA:** Purpura fulminans caused by meningococemia in an infant. *BMJ Case Rep* 2013; Aug 6.

**Duggal S, et al:** Recent outbreak of meningococcal meningitis: a microbiological study with brief review of the literature. *J Commun Dis* 2007; 39:209.

**Gunawardane ND, et al:** Purpura fulminans from meningococemia mimicking Stevens-Johnson syndrome in an adult patient taking etanercept. *Arch Dermatol* 2012; 148:1429–1431.

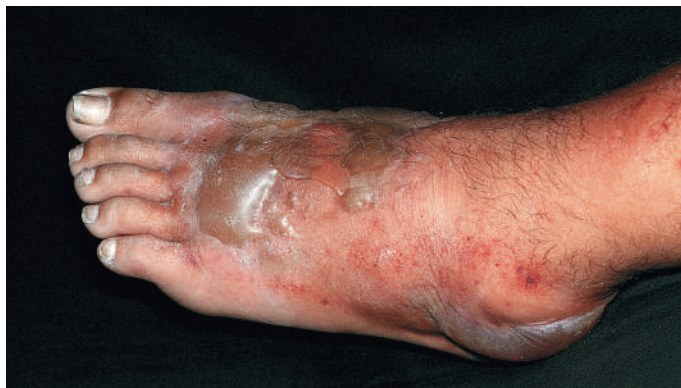## VIBRIO VULNIFICUS INFECTION

Infection with *Vibrio vulnificus*, a gram-negative rod of the noncholera group of vibrios, may produce either a rapidly expanding cellulitis or a life-threatening septicemia in patients exposed to the organism. This infection mainly occurs along the Atlantic seacoast. It may be acquired through the GI tract; after being ingested with raw oysters or other seafood, the bacterium enters the bloodstream at the level of the duodenum. Pulmonary infection by the aspiration of seawater has been reported. Localized skin infection may result after exposure of an open wound to seawater.

Skin lesions characteristically begin within 24–48 h of exposure, with localized tenderness followed by erythema, edema, and indurated plaques. Lesions occur in almost 90% of patients and are most common on the lower extremities. A purplish discoloration develops centrally and then undergoes necrosis, forming hemorrhagic bullae or ulcers (Fig. 14-39). Other reported lesions include hemorrhagic bullae, pustules, petechiae, generalized macules or papules, and gangrene.

If the skin is invaded primarily, septicemia may not develop, but the lesions may be progressive, and at times, limb amputation may be necessary. With septicemia, cellulitic lesions are the result of seeding of the subcutaneous tissue during bacteremia. Patients with advanced liver disease are at particular risk for developing septicemia. Other predisposing disorders are immunosuppression, alcoholism, adrenal insufficiency, diabetes, renal failure, male gender, and iron-overload states. The virulence of the bacterium is related to the production of exotoxin and various other factors. The mortality in patients with septicemia is greater than 50%.

Treatment of this fulminant infection, which rapidly produces septic shock, includes antibiotics, surgical debridement, and appropriate resuscitative therapy. Doxycycline together with ceftriaxone is the treatment of choice. In patients with preexisting hepatic dysfunction or immunocompromise and whose wounds are exposed to or acquired in saltwater,



**Fig. 14-39** *Vibrio vulnificus* infection. (Courtesy of Curt Samlaska, MD.)

prophylactic antibiotic coverage with doxycycline, 100 mg every 12 h, and cleansing with 0.025% sodium hypochlorite solution may prevent progressive infection.

**Cazorla C, et al:** Fatal *Vibrio vulnificus* infection associated with eating raw oysters, New Caledonia. *Emerg Infect Dis* 2011; 17:136–137.

**Kuo Chou TN, et al:** Predictors of mortality in skin and soft-tissue infections caused by *Vibrio vulnificus*. *World J Surg* 2010; 34:1669–1675.

**Kuo YL, et al:** Necrotizing fasciitis caused by *Vibrio vulnificus*. *Eur J Clin Microbiol Infect Dis* 2007; 26:785.

**Matsuoka Y, et al:** Accurate diagnosis and treatment of *Vibrio vulnificus* infection. *Braz J Infect Dis* 2013; 17:7–12.

**Tsai YH, et al:** Necrotizing soft-tissue infections and primary sepsis caused by *Vibrio vulnificus* and *Vibrio cholerae* non-01. *J Trauma* 2009; 66:899.

## CHROMOBACTERIOSIS AND AEROMONAS INFECTIONS

*Chromobacterium* is a genus of gram-negative rods that produce various discolorations on gelatin broth. Chromobacteria have been shown to be common water and soil saprophytes of the southeastern United States and Australia. Several types of cutaneous lesions are caused by chromobacteria, ranging from fluctuating abscesses and local cellulitis to anthraxlike carbuncular lesions with lymphangitis and fatal septicemia. *Chromobacterium violaceum*, the most common species, produces a violet pigment. Patients with chronic granulomatous disease may be at particular risk. A fluoroquinolone in combination with an aminoglycoside is best for treatment. After several weeks of parenteral antimicrobial therapy, an oral agent (e.g., TMP-SMX, tetracycline, fluoroquinolone) is given for 2 or 3 months.

A gram-negative bacterium, *Aeromonas hydrophilia*, another typical soil and water saprophyte, may cause similar skin infections as *C. violaceum*, manifesting as cellulitis, pustules, furuncles, gas gangrene, or ecthyma gangrenosum-like lesions, after water-related trauma and abrasions. Folliculitis caused by *A. hydrophilia* may mimic *Pseudomonas* folliculitis. The treatment of choice is ciprofloxacin.

**Manresa MJ, et al:** *Aeromonas hydrophilia* folliculitis associated with an inflatable swimming pool. *Pediatr Dermatol* 2009; 26:601–603.

**Mulholland A, et al:** A possible new cause of spa bath folliculitis: *Aeromonas hydrophilia*. *Australas J Dermatol* 2008; 49:39.

**Tsai YH, et al:** Necrotizing soft-tissue infections and sepsis caused by *Vibrio vulnificus* compared with those caused by *Aeromonas* species. *J Bone Joint Surg Am* 2007; 89:631.

**Yang CH, et al:** *Chromobacterium violaceum* infection. *J Chin Med Assoc* 2011; 74:435–441.

## SALMONELLOSIS

*Salmonella* is a genus of gram-negative rods that exist in humans either in a carrier state or as a cause of active enteric or systemic infection. Most cases of typhoid fever caused by *Salmonella typhi* are acquired by ingestion of contaminated food or water. Pets such as lizards, snakes, and turtles carry salmonellae, and acquisition of the organism in petting zoos has also been reported. Poultry and poultry products are the most important sources and are believed to be the cause in about half of common-source epidemics. Handwashing and thorough cooking of meats are recommended preventive measures.

After an incubation period of 1–2 weeks, there is usually an acute onset of fever, chills, headache, constipation, and bronchitis. After 7–10 days of fever and diarrhea, skin lesions,

rose-colored macules or papules (“rose spots”) 2–5 mm in diameter, appear on the anterior trunk, between the umbilicus and nipples. They occur in crops, each group of 10–20 lesions lasting 3–4 days, the total duration of the exanthem being 2–3 weeks in untreated cases. Rose spots occur in 50–60% of patients. A more extensive erythematous eruption occurring early in the course, erythema typhosum, is rarely reported, as are erythema nodosum, urticaria, and ulcers or subcutaneous abscesses.

The diagnosis is confirmed by culturing the organism from blood, stool, skin, or bone marrow. If the organism is not grown on *Shigella-Salmonella* medium or is not analyzed correctly, *S. typhi* may be erroneously reported as a coliform. The preferred antibiotic for therapy is ciprofloxacin or ceftriaxone.

Occasionally, *S. typhi* may cause skin lesions without systemic infection. Also, infection with nontyphoid *Salmonella*, such as *S. enterica*, may cause enteric fever with rose spots.

**Coburn B, et al:** *Salmonella*, the host and disease. *Immunol Cell Biol* 2007; 85:112.

**Nishie H, et al:** Non-typhoid *Salmonella* infection associated with rose spots. *Br J Dermatol* 1999; 140:558.

**Patel TA, et al:** Imported enteric fever. *Am J Trop Med Hyg* 2010; 82:1121–1126.

## SHIGELLOSIS

Shigellae are small, gram-negative rods that cause bacillary dysentery, an acute diarrheal illness. Most cases are a result of person-to-person transmission; however, widespread epidemics have resulted from contaminated food and water. Small, blanchable, erythematous macules on the extremities, as well as petechial or morbilliform eruptions, may occur. Men who have sex with men (MSM) may develop a furuncle on the penis caused by *Shigella flexneri*. Shigellosis may then occur as a purely cutaneous form of STD. *Shigella* and *Salmonella* are among the organisms reported to induce the postdysenteric form of Reiter syndrome. Therapy with a fluoroquinolone is curative.

**Carter JD, et al:** Reactive arthritis. *Rheum Dis Clin North Am* 2009; 35:21.

## HELICOBACTER CELLULITIS

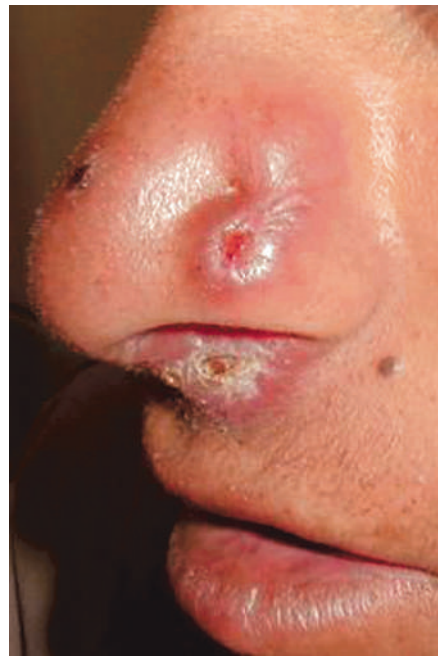Fever, bacteremia, cellulitis, and arthritis may all be caused by *Helicobacter cinaedi* or *H. canis*. Generally, these manifestations occur in HIV-infected patients; however, malignancy, diabetes, and alcoholism are other predisposing conditions. Occasionally, *Helicobacter* has been reported to cause postsurgical wound infections and sepsis in otherwise healthy individuals. The cellulitis may be multifocal and recurrent and may have a distinctive red-brown or copper color with minimal warmth. Ciprofloxacin is generally effective for treatment.

**Itamura T, et al:** *Helicobacter cinaedi* cellulitis and bacteremia in immunocompetent hosts after orthopedic surgery. *J Clin Microbiol* 2007; 45:31.

**Shimizu S, et al:** Cutaneous manifestations of *Helicobacter cinaedi* infection. *Acta Derm Venereol* 2013; 93:165–167.

## RHINOSCLEROMA

Rhinoscleroma is a chronic, inflammatory, granulomatous disease of the upper respiratory tract characterized by sclerosis, deformity, remission, and eventual debility. Death resulting from obstructive sequelae may occur. The infection



**Fig. 14-40**  
Rhinoscleroma.  
(Courtesy of Jason  
Robbins, MD.)

is limited to the nose, pharynx, and adjacent structures. The disease begins insidiously with nasal catarrh, increased nasal secretion, and subsequent crusting. Gradually, there ensues a nodular or rather diffuse sclerotic enlargement of the nose, upper lip, palate, or neighboring structures (Fig. 14-40). The nodules at first are small, hard, subepidermal, and freely movable, but they gradually fuse to form sclerotic plaques that adhere to the underlying parts. Ulceration is common. The lesions have a distinctive stony hardness, are insensitive, and are of a dusky purple or ivory color. Hyperpigmentation can be expected in dark-complexioned individuals. In the more advanced stages of rhinoscleroma, the reactive growth produces extensive mutilation of the face and marked disfigurement. Complete obstruction of the nares, superficial erosions, and seropurulent exudation may occur.

A microorganism, *Klebsiella pneumoniae*, ssp. *rhinoscleromatis*, first isolated by von Frisch, is the causative agent. The rhinoscleroma bacillus is a gram-negative rod, short, nonmotile, round at the ends, always encapsulated in a gelatinous capsule, and measuring 2–3  $\mu\text{m}$ . It is found in the throats of scleroma patients only.

The disease occurs in both genders and is most common during the third and fourth decades of life. Although endemic in tropical countries in Africa and Central America, it is occasionally found in the United States. Rare familial cases have been reported, in which the condition may present in childhood.

In the primary stage of nasal catarrh, the histologic picture is that of a mild, nonspecific inflammation. When proliferation and tumefaction develop, the granulomatous tumor consists largely of plasma cells, Mikulicz cells, an occasional hyaline degenerated plasma cell (Russell body), a few spindle cells, and fibrosis. The bacilli are found within foamy macrophages (Mikulicz cells) and are best visualized with the Warthin-Starry silver stain.

Rhinoscleroma has such distinctive features that its diagnosis should not be difficult. The diagnosis depends on bacteriologic, histopathologic, and serologic tests. Heat-killed antigen gives a positive complement fixation reaction with scleroma patients' serum. Titers run as high as 1:1280. Clinically, rhinoscleroma can be confused with syphilitic gumma, sarcoid, leishmaniasis, frambesia (yaws), keloid, lepra, hypertrophic forms of tuberculosis, and rhinosporidiosis.



## Treatment

Rhinoscleroma is usually progressive and resistant to therapy. However, it may respond well to the fluoroquinolones, although therapy should be prolonged, lasting at least 3 or 4 months, to limit the chance of relapse. Corticosteroids are useful in the acute phase. Surgical intervention or CO<sub>2</sub> laser treatments may be needed to prevent airway obstruction or to correct deformities.

**Chou TC, et al:** Emperipolexis is not pathognomonic for Rosai-Dorfman disease. *J Am Acad Dermatol* 2013; 69:1066–1067.

**De Pontual L, et al:** Rhinoscleroma: a French national retrospective study of epidemiological and clinical features. *Clin Infect Dis* 2008; 47:1396.

**Suchanova PP, et al:** Rhinoscleroma in an urban nonendemic setting. *Otolaryngol Head Neck Surg* 2012; 147:173–174.

**Tan SL, et al:** Rhinoscleroma. *Singapore Med J* 2012; 53:e24–e27.

## PASTEURELLOSIS

Primary cutaneous (ulceroglandular) *Pasteurella haemolytica* (*Mannheimia haemolytica*) infection may occur in patients with skin injury and exposure to this organism. *P. haemolytica* is a common pathogen of domestic animals associated with shipping fever in cattle and septicemia in lambs and newborn pigs. The open sites become inflamed, lymphangitis and fever develop, and axillary lymph nodes become enlarged. Diagnosis is based on demonstration of the bacteria on culture of the lesions.

*Pasteurella multocida* is a small, nonmotile, gram-negative, bipolar-staining bacterium. It is known to be part of the normal oral and nasal flora of cats and dogs, but it may also be an animal pathogen. The most common type of human infection follows injuries from animal bites, principally cat and dog bites, but also cat scratches. After animal trauma, erythema, swelling, pain, and tenderness develop within a few hours of the bite, with a gray-colored serous or sanguinopurulent drainage from the puncture wounds (Fig. 14-41). There may or may not be regional lymphadenopathy or evidence of systemic toxicity such as chills and fever. Septicemia may follow the local infection in rare cases, and tenosynovitis and osteomyelitis appear with some frequency. Although *P. multocida* is a gram-negative bacillus, treatment is with systemic penicillin G in addition to careful cleansing and tetanus prophylaxis.

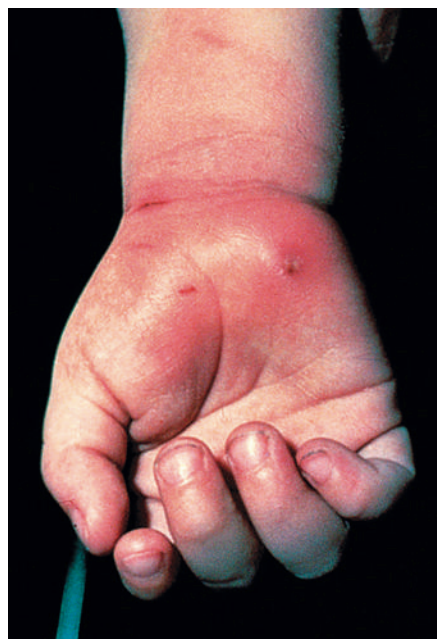**Blasiak RC, et al:** *Pasteurella multocida* cellulitis in a 15-year-old male with chronic lymphedema. *J Am Acad Dermatol* 2013; 68:e183–e184.

**Wilkie IW, et al:** *Pasteurella multocida*. *Curr Top Microbiol Immunol* 2012; 361:1–22.

## DOG AND HUMAN BITE PATHOGENS

It is recommended that all cat bites and scratches, all sutured wounds of any animal source, and any other animal injuries of an unusual type or source be treated with antibiotics in addition to careful cleansing and tetanus prophylaxis. While *Pasteurella* species (*P. canis* in dogs and *P. multocida* in cats) are usually present in bite site cultures, a complex mix of various other pathogens, such as streptococci, staphylococci, *Moraxella*, *Neisseria*, *Fusobacterium*, *Bacteroides*, and those individually discussed next, make the combination amoxicillin-clavulanate the best choice of initial therapy. Gatifloxacin and linezolid are other effective medications.

*Capnocytophaga canimorsus* is a gram-negative rod that is part of the normal oral flora of dogs and cats. It is associated with severe septicemia after dog bites. Patients who have undergone splenectomy are at particular risk. Alcoholism, chronic



**Fig. 14-41** *Pasteurella multocida* infection.

respiratory disease, and other medical conditions also predispose to infection; only one quarter of patients were healthy before infection with *C. canimorsus*. A characteristic finding is a necrotizing eschar at the site of the bite. Fever, nausea, and vomiting occur abruptly within 1–3 days, and the eschar develops soon thereafter. Disseminated intravascular coagulation and extensive dry gangrene may complicate the course. Sepsis after a dog bite is another hazard faced by splenectomized patients, in addition to their particular problems with pneumococcus, *Haemophilus influenzae* group B, babesiosis, *Neisseria meningitidis*, and group A streptococcus. *C. canimorsus* is difficult to identify by conventional cultures. Laboratory personnel need to be aware of the clinical suspicion of infection with this organism. A false-positive latex agglutination test for cryptococcal antigen in the CSF may occur. Treatment is with intensive IV antibiotics. In less severely affected patients, amoxicillin-clavulanate may be effective.

*Neisseria* species and *Bergeyella zoohelcum* are other oral and nasal commensals in dogs; thus, most reports of human disease follow animal bites. *Eikenella corrodens*, a facultative gram-negative bacillus, is a normal inhabitant of the human mouth. Most infections are caused by human bites or fist fights. Amoxicillin-clavulanate or penicillin G is effective.

**Babovic N, et al:** Cat bite infections of the hand. *J Hand Surg Am* 2014; 39:286–290.

**Brook I:** Management of human and animal bite wound infection. *Curr Infect Dis Rep* 2009; 11:389–395.

**Christiansen CB, et al:** Two cases of infectious purpura fulminans and septic shock caused by *Capnocytophaga canimorsus* transmitted from dogs. *Scand J Infect Dis* 2012; 44:635–639.

**Gastra W, Lipman LJ:** *Capnocytophaga canimorsus*. *Vet Microbiol* 2010; 140:339–346.

**Lohiya GS, et al:** Human bites. *J Natl Med Assoc* 2013; 10:92–95.

**Thomas N, Brook I:** Animal bite-associated infections. *Expert Rev Anti Infect Ther* 2011; 9:215–226.

## GLANDERS

Once known as equinia, farcy, and malleus, glanders is a rare, usually fatal infectious disease that occurs in humans by inoculation with *Burkholderia mallei*. It is encountered in those who handle horses, mules, or donkeys. The distinctive skin lesion is an inflammatory papule or vesicle that arises at the site of

inoculation, rapidly becomes nodular, pustular, and ulcerative, and forms an irregular excavation with undermined edges and a base covered with a purulent and sanguineous exudate. In a few days or weeks, other nodules (called “farcy buds”) develop along the lymphatics in the adjacent skin or subcutaneous tissues and subsequently break down. In the acute form, the skin involvement may be severe and accompanied by extreme diarrhea. Patients with the chronic form have few skin lesions and milder constitutional symptoms, but repeated cycles of healing and breakdown of nodules may occur for weeks.

The respiratory mucous membranes are especially susceptible to glanders. After accidental inhalation, catarrhal symptoms are first present, and there may be epistaxis or a mucoid nasal discharge. The nasal discharge is a characteristic feature of the disease. The diagnosis is established by finding the gram-negative organism in this discharge or in the skin ulcers and should be confirmed by serum agglutination. This organism has been fatal to many laboratory workers, and exposure in this setting is increasing, with *B. mallei* considered a bioterrorism threat.

Treatment is chiefly by immediate surgical excision of the inoculated lesions and antibiotics. Amoxicillin-clavulanate, doxycycline, or TMP-SMX for up to 5 months may be effective in disease limited to the skin, whereas parenteral ceftazidime can be used for severe or septic infection. Imipenem and doxycycline in combination cured an infected laboratory worker.

Bovine farcy also occurs and is caused by *Mycobacterium farcinogenes* and *M. senegalense*. It is present mostly in sub-Saharan Africa and presents as a suppurative granulomatous inflammation of the skin and lymphatics.

**Anderson PD, et al:** Bioterrorism. *J Pharm Pract* 2012; 25:521–529.

**Dvorak GD, et al:** Glanders. *J Am Vet Med Assoc* 2008; 233:570.

**Hamid ME:** Epidemiology, pathology, immunology and diagnosis of bovine farcy. *Prev Vet Med* 2012; 105:1–9.

**Whitlock GC, et al:** Glanders. *FEMS Microbiol Lett* 2007; 277:115.

## MELIOIDOSIS

Melioidosis (Whitmore’s disease) is a specific infection caused by a glanderslike bacillus, *Burkholderia pseudomallei*. The disease has an acute pulmonary and septicemic form in which multiple miliary abscesses in the viscera occur, resulting in rapid death. Less often, it runs a chronic course, with subcutaneous abscesses and multiple sinuses of the soft tissues. Its clinical characteristics are similar to glanders, disseminated fungal infections, and tuberculosis. Severe urticaria and necrotizing fasciitis are uncommon complications.

Melioidosis is endemic in India, Southeast Asia, and northern Australia and should be suspected in military personnel and travelers who have characteristic symptoms of a febrile illness and have been in that region. Recrudescence of disease after a long latency period may occur. Diagnosis is made from the recovery of the bacillus from the skin lesions or sputum and by serologic tests.

Effective therapy is guided by the antibiotic sensitivity of the specific strain. For the acute septicemic phase, ceftazidime, meropenem, or imipenem is indicated for 2 weeks, followed by maintenance oral therapy with TMP-SMX. The majority of chronic cutaneous infections respond well to oral treatment alone. Maintenance oral therapy in both situations should continue for 3 to 6 months.

**Limmathurotsakul D, et al:** Melioidosis. *Br Med Bull* 2011; 99:125–139.

**Tzeng WT, et al:** Recurrent cutaneous melioidosis treated with surgery and antibiotics. *J Plast Reconstr Aesthet Surg* 2009; 62:280.

**Wiersinga WJ, et al:** Melioidosis. *N Engl J Med* 2012; 367:1035–1044.

## INFECTIONS CAUSED BY BARTONELLA

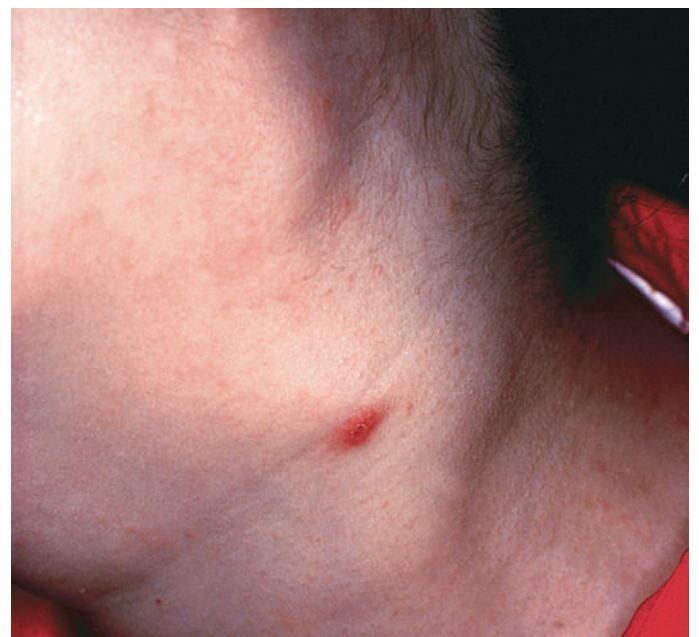Bartonellae are aerobic, fastidious, gram-negative bacilli. Several species cause human diseases, including *Bartonella henselae* (cat-scratch disease and bacillary angiomatosis), *B. quintana* (trench fever and bacillary angiomatosis), *B. bacilliformis* (verruca peruana and Oroya fever), *B. grahamii* (cat-scratch disease), and *B. clarridgeiae* (possible cause of cat-scratch disease). These agents are transmitted by arthropod vectors in some cases. Unique to this genus is the ability to cause vascular proliferation, as seen in bacillary angiomatosis and verruca peruana. The bartonellae in affected tissue stain poorly with tissue Gram staining and are usually identified in tissue using modified silver stains such as Warthin-Starry. They are difficult to culture, making tissue identification of characteristic bacilli an important diagnostic test. Electron microscopy and PCR can be used if routine staining is negative.

### Cat-scratch disease

Cat-scratch disease is relatively common. About 22,000 cases are reported annually in the United States, with 60–90% occurring in children and young adults. Cat-scratch disease is the most frequent cause of chronic lymphadenopathy in children and young adults.

*Bartonella henselae* causes the vast majority of cases of cat-scratch disease. The infectious agent is transmitted from cat to cat by fleas and from cats to humans by cat scratches or bites. Rarely, dog bites may transmit this infection. *B. henselae* can be found in the primary skin and conjunctival lesions, lymph nodes, and other affected tissues. In geographic areas where cat fleas are present, about 40% of cats are asymptotically bacteremic with this organism. An immunocompromised patient with typical cat-scratch disease caused by *Bartonella grahamii* has been reported. This organism infects rodents and is likely acquired by cats through hunting.

The primary skin lesion appears within 3–5 days after the cat scratch and may last for several weeks (Fig. 14-42). It is present in 50–90% of patients. The primary lesion is not crusted, and lymphangitis does not extend from it. The primary



**Fig. 14-42** Primary cat-scratch lesion with lymphadenopathy.



lesion may resemble an insect bite but is not pruritic. It heals within a few weeks, usually with no scarring.

Lymphadenopathy, the hallmark of the disease, appears 1 or 2 weeks after the primary lesions or 10–50 days (average 17) after inoculation. Usually, the lymphadenopathy is regional and unilateral. Because most inoculations occur on the upper extremities, epitrochlear and axillary lymphadenopathy is most common (50%), followed by cervical (25%) or inguinal (18%). Generalized lymphadenopathy does not occur, but systemic symptoms such as fever, malaise, and anorexia may be present. Without treatment, the adenopathy resolves over a few weeks to months, with spontaneous suppuration occurring in 10–50% of patients. If the primary inoculation is in the conjunctiva, there is chronic granulomatous conjunctivitis and preauricular adenopathy—the so-called oculoglandular syndrome of Parinaud. Infrequently, acute encephalopathy, osteolytic lesions, hepatic and splenic abscesses, hypercalcemia, and pulmonary manifestations have been reported. In addition, erythema nodosum and a diffuse exanthem may accompany cat-scratch disease.

Diagnosis is made largely on clinical features. The primary skin lesion or lymph node may be biopsied and the infectious agent identified. Involved lymph nodes and skin lesions demonstrate granulomatous inflammation with central “stellate” necrosis. A serologic test is available, and although not reproducibly positive early in the disease, a titer of more than 1:256 is considered diagnostic of acute infection. Cat-scratch skin testing (Hanger and Rose test) can be used but is rarely done if the history and clinical features are characteristic. Other infectious and neoplastic causes of localized lymphadenopathy, such as tularemia, sporotrichosis, atypical mycobacterial infection, and Hodgkin disease, may need to be excluded.

The vast majority of cases of cat-scratch disease resolve spontaneously without antibiotic therapy. Such therapy has not been demonstrated to shorten the duration of the disease in most typical cases. Fluctuant lymph nodes should be aspirated, not incised and drained. In patients with severe disease, azithromycin was found to be more effective than placebo in one trial.

### Trench fever

Trench fever is caused by *Bartonella quintana*, which is spread from person to person by the body louse. Urban cases of trench fever caused by this agent are now most often seen in louse-infested homeless persons. Patients present with fever that initially lasts about 1 week and then recurs about every 5 days. Other symptoms are headache and neck, shin, and back pain. Endocarditis may occur. There are no skin lesions. Treatment has not been studied systematically. Combination IV gentamicin and oral doxycycline is recommended.

### Bacillary angiomatosis

Bacillary angiomatosis describes a clinical condition characterized by vascular skin lesions resembling pyogenic granulomas (Fig. 14-43). Only two organisms have been proven to cause bacillary angiomatosis: *Bartonella henselae* (cause of cat-scratch disease) and *B. quintana* (cause of trench fever). The skin lesions caused by these two organisms are identical. If the bacillary angiomatosis is caused by *B. henselae*, there is usually a history of cat exposure, and the same *Bartonella* can also be isolated from the blood of the source cat. Bacillary angiomatosis caused by *B. quintana* is associated with homelessness and louse infestation. The incubation period is unknown but may be years.

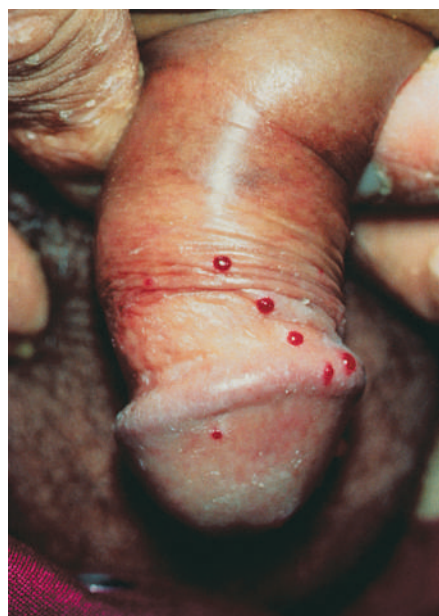

Fig. 14-43 Bacillary angiomatosis.

Bacillary angiomatosis occurs primarily in the setting of immunosuppression, especially AIDS, and may be the presenting sign of this condition. The helper T-cell count is usually less than 50 cells/mL. Other immunosuppressed patients, such as those with leukemia or transplant, may acquire the condition. Rarely, bacillary angiomatosis can occur in HIV-negative patients with no apparent immune impairment. In immunoincompetent hosts, the bacteria proliferate locally and are frequently blood-borne. The local proliferation of bacteria produces the angiogenic vascular endothelial growth factor (VEGF), leading to endothelial cell proliferation and the characteristic skin lesions. Immunocompetent hosts generally resist this bacterial proliferation, resulting in granulomatous and necrotic, rather than angiomatous, lesions.

Several different forms of cutaneous lesions occur. The most common form resembles pyogenic granuloma, which may exhibit a surrounding collarette of scale. Less often, subcutaneous masses, plaques, and ulcerations may occur. A single patient may exhibit several of these morphologies. Lesions are tender and bleed easily. Subcutaneous nodules are also tender and may be poorly marginated. Lesions may number from one to thousands, usually with the number gradually increasing over time if the patient is untreated.

In the setting of bacillary angiomatosis, the infection must be considered disseminated. Bacteremia is detected in about 50% of affected AIDS patients, leading to involvement of many visceral sites, most frequently the lymph node, liver and spleen, and bone. Less frequently, pulmonary, GI, muscle, oral, and brain lesions can occur. *B. henselae* is usually associated with lymph node and liver and spleen involvement, whereas *B. quintana* more often causes bone disease and subcutaneous masses. Visceral disease can be confirmed by appropriate radiologic or imaging studies. Bone lesions are typically lytic, resembling osteomyelitis. In the liver and spleen, “peliosis” occurs. Liver function tests characteristically demonstrate a very elevated lactic dehydrogenase level, an elevated alkaline phosphatase level, slight elevation of the levels of hepatocellular enzymes, and a normal bilirubin level. Lesions on other epithelial surfaces, in muscle, and in lymph nodes are usually angiomatous.

Biopsies of bacillary angiomatosis skin lesions have the same low-power appearance as a pyogenic granuloma, with the proliferation of endothelial cells, forming normal small blood vessels. Bacillary angiomatosis is distinguished from

pyogenic granuloma by the presence of neutrophils throughout the lesion, not just on the surface, as seen in a pyogenic granuloma. The neutrophils are sometimes aggregated around granular material that stains slightly purple. This purple material represents clusters of organisms, which can at times be confirmed by modified silver stain such as Steiner. Tissue Gram stain does not routinely stain the bacteria in bacillary angiomatosis lesions. Electron microscopy may identify bacteria in cases in which special stains are negative. Bacillary angiomatosis is easily distinguished histologically from Kaposi sarcoma. In patch or plaque lesions of Kaposi sarcoma, the new blood vessels are abnormal in appearance, being angulated. Endothelial proliferation in Kaposi sarcoma is seen in the dermis around the eccrine units, follicular structures, and existing normal vessels. Nodular Kaposi sarcoma is a spindle cell tumor with slits rather than well-formed blood vessels. Neutrophils and purple granular material are not found in Kaposi sarcoma, but intracellular hyaline globules are present.

The natural history of bacillary angiomatosis is extremely variable. In most patients, however, lesions remain stable or the size or number of lesions gradually increases over time. The initial lesions are usually the largest, and multiple satellite or disseminated smaller lesions occur, representing miliary spread. Untreated bacillary angiomatosis can be fatal, with patients dying of visceral disease or respiratory compromise from obstructing lesions.

The diagnosis of bacillary angiomatosis is virtually always made by identifying the infectious agent in affected tissue. The organisms can also be cultured from the lesions and the patient's blood. However, these organisms grow very slowly, so cultures may not be positive for more than 1 month. Thus, tissue and blood cultures are usually confirmatory in nature. Antibodies to *Bartonella* can be detected in most patients by an indirect fluorescence assay. Because of its limited availability and background positivity in the general population of cat owners, however, this test is not generally useful in establishing the diagnosis of bacillary angiomatosis.

## Treatment

Bacillary angiomatosis is dramatically responsive to erythromycin, 500 mg four times daily, or doxycycline, 100 mg twice daily. Minocycline, tetracycline, clarithromycin, azithromycin, roxithromycin, and chloramphenicol may also be effective. TMP-SMX, ciprofloxacin, penicillins, and cephalosporins are not effective. Prophylactic regimens containing a macrolide antibiotic or rifampin prevent the development of bacillary angiomatosis. Treatment duration depends on the extent of visceral involvement. Patients with only skin lesions or bacteremia require at least 8 weeks of treatment. For liver and spleen involvement, 3–6 months of treatment is recommended, and for bone disease, at least 6 months of treatment should be considered. Once treatment is begun, symptoms begin to resolve within hours to days. A Jarisch-Herxheimer reaction may occur with the first dose of antibiotic. If patients relapse after an apparently adequate course of treatment, chronic suppressive antibiotic therapy should be considered.

## Oroya fever and verruga peruana

Oroya fever and verruga peruana represent two stages of the same infection. Oroya fever (Carrión's disease) is the acute febrile stage, and verruga peruana the chronic delayed stage. These conditions are limited to and endemic in Peru and a few neighboring countries in the Andes and are restricted to valleys 500–3200 m above sea level. Both these conditions are

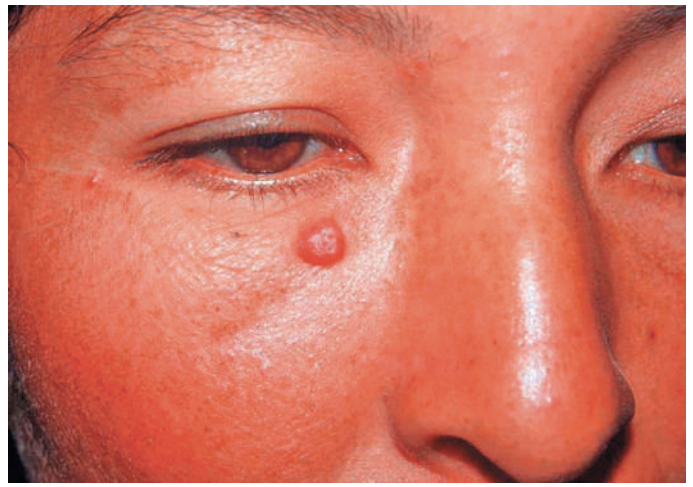

Fig. 14-44 Verruga peruana. (Courtesy of Francisco Bravo, MD.)

caused by *Bartonella bacilliformis*, which is transmitted by a sandfly, usually *Lutzomyia verrucarum*. A novel agent named *Candidatus Bartonella ancashi* was the causative organism in one reported case of verruga peruana. Humans represent the only known reservoir. Men represent about three quarters of cases, and all ages may be affected.

After an incubation period averaging 3 weeks, the acute infection, Oroya fever, develops. Symptomatology is highly variable. Some patients have very mild symptoms. Others may have high fever, headache, and arthralgias. Severe hemolytic anemia can develop, sometimes with leukopenia and thrombocytopenia. Untreated, the fatality rate is 40–88%, and with antibiotic treatment, is still 8%. After the acute infection resolves, a latency period follows, lasting from weeks to months. The verruga peruana eruptions then occur; these are angiomatous, pyogenic granuloma-like lesions, virtually identical clinically and histologically to the lesions of bacillary angiomatosis (Fig. 14-44). The lesions may be large and few in number (mular form), small and disseminated (miliary form), or nodular and deep. Visceral disease has not been found in verruga peruana, which is rarely fatal. Lesions usually heal spontaneously over several weeks to months without scarring. A lasting immunity results from infection.

The diagnosis of Oroya fever is made by identifying the bacteria within or attached to circulating erythrocytes using a Giemsa stain. Verruga peruana can be diagnosed by skin biopsy, showing the same features as bacillary angiomatosis, but with the organisms staining with Giemsa.

The antibiotic treatment of choice for Oroya fever is chloramphenicol, 2 g/day, because *Salmonella* coinfection is the most frequent cause of death. Protection from sandfly bites is all important.

**Al-Thunayan A, et al:** Bacillary angiomatosis presenting as a pyogenic granuloma of the hand in an otherwise apparently healthy patient. *Ann Plast Surg* 2013; 70:652–653.

**Blazes DL, et al:** Novel *Bartonella* agent as a cause of verruga peruana. *Emerg Infect Dis* 2013; 19:1111–1114.

**Chen TC, et al:** Cat scratch disease from a domestic dog. *J Formos Med Assoc* 2007; 106:S65.

**Chomel BB, et al:** Bartonellosis, an increasingly recognized zoonosis. *J Appl Microbiol* 2010; 109:743–760.

**Maguina C, et al:** Bartonellosis. *Clin Dermatol* 2009; 27:271.

**Mejia F, et al:** Bacillary angiomatosis. *Am J Trop Med Hyg* 2014; 91:439.

**Oksi J, et al:** Cat scratch disease caused by *Bartonella grahamii* in an immunocompromised patient. *J Clin Microbiol* 2013; 51:2781–2784.

**Pierad-Franhimont C, et al:** Skin disease associated with *Bartonella* infection. *Clin Dermatol* 2010; 28:483–488.



**Psarros G, et al:** *Bartonella henselae* infections in solid organ transplant recipients. *Medicine* 2012; 91:111–121.

**Zangwill KM:** Cat scratch disease and other *Bartonella* infections. *Adv Exp Med Biol* 2013; 764:159–166.

**Zarraga M, et al:** Bacillary angiomatosis in an immunocompetent child. *Am J Dermatopathol* 2011; 33:513.

## PLAGUE

Plague normally involves an interaction among *Yersinia pestis*, wild rodents, and fleas parasitic on the rodents. Infection in humans with *Y. pestis* is accidental and usually presents as bubonic plague. Other clinical forms include pneumonic and septicemic plague. In the milder form, the initial manifestations are general malaise, fever, and pain or tenderness in areas of regional lymph nodes, most often in the inguinal or axillary regions. In more severe infections, findings of toxicity, prostration, shock, and occasionally hemorrhagic phenomena prevail. Less common symptoms include abdominal pain, nausea, vomiting, constipation followed by diarrhea, generalized macular erythema, and petechiae. Rarely, vesicular and pustular skin lesions occur.

Plague is caused by *Y. pestis*, a pleomorphic, gram-negative bacillus. The principal animal hosts involved have been rock squirrels, prairie dogs, chipmunks, marmots, skunks, deer mice, wood rats, rabbits, and hares. Transmission occurs through contact with infected rodent fleas or rodents, pneumonic spread, or infected exudates. *Xenopsylla cheopis* (Oriental rat flea) has traditionally been considered the vector in human outbreaks, but *Diamanus montanus*, *Thrassis bacchi*, and *Opisocrostis hirsutus* are species of fleas on wild animals responsible for spreading sylvatic plague in the United States. Rodents carried home by dogs or cats are a potential source—and an important one in veterinarians—of infection. The bites, scratches, or contact with other infectious material while handling infected cats are an increasing risk factor as residential development continues in areas of plague foci in the western United States. Since 1945, 89% of U.S. cases have occurred in the Rocky Mountain states.

Blood, bubo or parabubo aspirates, exudates, and sputum should be examined by smears stained with Gram stain or specific fluorescent antibody techniques, culture, and animal inoculation. A retrospective diagnosis can be made by serologic analysis.

The most effective drugs against *Y. pestis* are gentamicin and streptomycin, which should be given intravenously. Other effective drugs include chloramphenicol, the tetracyclines, and ciprofloxacin. Almost all cases are fatal if not treated promptly.

**Anderson PD, et al:** Bioterrorism. *J Pharm Pract* 2012; 25:521–529.

**Eisen RJ, et al:** Transmission of flea-borne zoonotic agents. *Annu Rev Entomol* 2012; 57:61–82.

**Lieberman JM:** North American zoonoses. *Pediatr Ann* 2009; 38:193.

**Prentice MB, et al:** Plague. *Lancet* 2007; 369:1196.

## RAT-BITE FEVER

Rat-bite fever is a systemic illness usually acquired by direct contact with rats or other small rodents, which carry the gram-negative organisms *Spirillum minor* and *Streptobacillus moniliformis* among their oropharyngeal flora. *S. moniliformis* is the principal cause in the United States, whereas *S. minor* is seen mostly in Asia. Crowded living conditions, homelessness, working with rats in medical research or in pet shops, or having one as a pet are predisposing factors in some infected patients. Although it usually follows a rat bite, infection may

follow the bites of squirrels, cats, weasels, pigs, and a variety of other carnivores that feed on rats.

There are at least two distinct forms of rat-bite fever: “sodoku,” caused by *Spirillum minor*; and septicemia, caused by *Streptobacillus moniliformis*, otherwise known as epidemic arthritic erythema or Haverhill fever. The latter usually follows the bite of a rat, but some cases have been caused by contaminated milk. The clinical manifestations of these two infections are similar in that both produce a systemic illness characterized by fever, rash, and constitutional symptoms. However, clinical differentiation is possible.

In the streptobacillary form, incubation is brief, usually lasting 10 days after the bite, when chills and fever occur. Within 2–4 more days, the generalized morbilliform eruption appears and spreads to include the palms and soles. It may become petechial. Arthralgia is prominent, and pleural effusion may occur. Endocarditis, pneumonia, and septic infarcts often follow, and 10% of untreated patients may die from these causes.

Although infection with *S. minor* also begins abruptly with chills and fever, the incubation period is longer, 1–4 weeks. The bite site is often inflamed and may become ulcerated. Lymphangitis may be present. The eruption begins with erythematous macules on the abdomen, resembling rose spots, which enlarge, become purplish red, and form extensive indurated plaques. Arthritis may rarely occur. Endocarditis, nephritis, meningitis, and hepatitis are potential complications. About 6% of untreated patients die.

In both types of rat-bite fever, a leukocytosis of 15,000–30,000 cells/mm<sup>3</sup> is present, sometimes with eosinophilia. A biologic false-positive Venereal Disease Research Laboratories (VDRL) test is found in 25–50% of patients. The course of *S. minor* infection without treatment is generally from 1 to 2 weeks, though relapses may occur for months.

The diagnosis is confirmed by culturing the causative organism from the blood or joint aspirate, or demonstration of an antibody response in the streptobacillary form. *S. minor* is demonstrable by animal inoculation with the patient’s blood, usually in the guinea pig or mouse. Their blood will show large numbers of organisms in Wright-stained smears. Demonstration of *S. minor* in a darkfield preparation of exudate from an infected site establishes the diagnosis.

Rat-bite fever must be differentiated from erysipelas, pyogenic cellulitis, viral exanthems, gonococcemia, meningococcemia, and Rocky Mountain spotted fever.

Prompt cauterization of bites by nitric acid may prevent the disease. Cleansing of the wound, tetanus prophylaxis, and 3 days of penicillin (2 g/day) are recommended for patients seen shortly after a bite. Both types respond readily to penicillin, tetracycline, or streptomycin therapy.

**Barnelee P, et al:** Rat bite fever, a fatal case of *Streptobacillus moniliformis* infection in a 14-year-old boy. *J Forensic Sci* 2011; 56:531–533.

**Chean R, et al:** Rat bite fever as a presenting illness in a patient with AIDS. *Infection* 2012; 40:319–320.

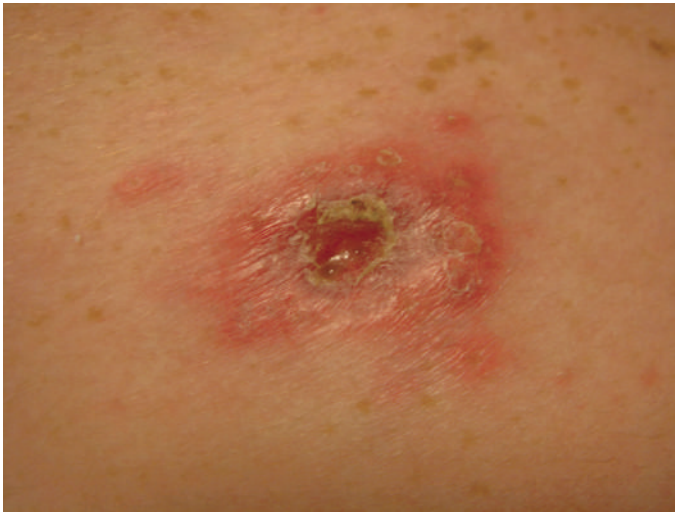
**Lewis BK, et al:** Rat bite fever. *Pediatr Dermatol* 2012; 29:767–768.

**McKee G, et al:** Rat bite fever. *CMAJ* 2013; 185:1346.

## TULAREMIA

Tularemia, also known as Ohara’s disease or deer fly fever, is a febrile disease caused by *Francisella tularensis*, a short, non-motile, non-spore-forming, gram-negative coccobacillus. Tularemia is characterized by sudden onset, with chills, headache, and leukocytosis, after an incubation period of 2–7 days. Its clinical course is divided into several general types. The causative organism poses a bioterrorism threat.

The vast majority of tularemia cases are the ulceroglandular type, which begins with a primary papule or nodule that



**Fig. 14-45** Tularemia. (Courtesy of Steve Hess, MD.)

rapidly ulcerates at the site of infection. This usually occurs through contact with tissues or body fluids of infected mammals from an abrasion or scratch (Fig. 14-45), usually on the fingers, neck, or conjunctiva. The bites of a tick, *Dermacentor andersoni* or *Amblyomma americanum*, and of a deer fly, *Chrysops discalis*, also transmit this disease, and in such cases, primary lesions are usually found on the legs or the perineum. The primary ulcer is tender, firm, indolent, and punched out, with a necrotic base that heals with scar formation in about 6 weeks. A lymphangitis spreads from the primary lesion; the regional lymph glands become swollen, painful, and inflamed, and tend to break down, forming suppurative subcutaneous nodules resembling those of sporotrichosis. The ulcers extend in a chain from the ulcer to the enlarged lymphatic glands.

The course of the ulceroglandular type is marked in the early stages by headache, anorexia, and vomiting, as well as articular and muscular pains. The fever is at first continuous, varying between 102 and 104°F (38.8 and 40°C), and later shows morning remissions, then falls by lysis to normal. Other skin lesions encountered in the disease course are not characteristic and are probably of a toxic nature. A macular, papular, vesicular, or petechial exanthem may occur. Erythema multiforme and erythema nodosum often occur. The clinical similarity of the primary ulcer of tularemia to a chancre of sporotrichosis is important in the differential diagnosis.

In the typhoidal type, the site of inoculation is not known, and there is no local sore or adenopathy. This form of tularemia is characterized by persistent fever, malaise, GI symptoms, and the presence of specific agglutinins in the blood serum after the first week. Other, uncommon types include an oculoglandular form, in which primary conjunctivitis is accompanied by enlargement of the regional lymph nodes. The pneumonic type occurs rarely in laboratory workers and is most severe. The oropharyngeal form may occur after ingestion of infected and inadequately cooked meat. In the glandular type, there is no primary lesion at the site of infection, but there is enlargement of regional lymph glands followed by generalized involvement. Several cases, mostly in children, have been acquired from cat bites, the cats having previously bitten infected rabbits.

The most frequent sources of human infection are the handling of wild rabbits and the bite of deer flies or ticks. Outbreaks of tularemia occur chiefly at times of the year when contact with these sources of infection is likely. No instance of the spread of the infection from person to person by

contact has been reported. The disease occurs most often in the western and southern United States, although cases have been reported in almost all states and in Japan. In Russia and other countries in the Northern Hemisphere, tularemia may be contracted from polluted water contaminated by infected rodent carcasses.

A definite diagnosis is made by staining smears obtained from the exudate with specific fluorescent antibody. *F. tularensis* can be cultured only on special media containing cystine glucose blood agar or other selective media. Routine culture media do not support growth. The bacilli can be identified by inoculating guinea pigs intraperitoneally with sputum or with bronchial or gastric washings, exudate from draining lymph nodes, or blood. The agglutination titer becomes positive in the majority of patients after 2 weeks of illness. A fourfold rise in titer is diagnostic; a single convalescent titer of 1:160 or greater is diagnostic of past or current infection. PCR is also successful in identifying the infectious agent.

The main histologic feature of tularemia is that of a granuloma; the tissue reaction consists primarily of a massing of endothelial cells and the formation of giant cells. Central necrosis and liquefaction occur, accompanied by polymorphonuclear leukocyte infiltration. Surrounding this is a tubercloid granulomatous zone, and peripherally lymphocytes form a third zone. Small secondary lesions may develop. These pass through the same stages and tend to fuse with the primary lesion.

All butchers, hunters, cooks, and others who dress rabbits should wear protective gloves. Thorough cooking destroys the infection in a rabbit, thus rendering an infected animal harmless as food. Ticks should be removed promptly, and tick repellents may be of value for people with occupations that require frequent exposure.

Streptomycin, 1 g intramuscularly every 12 h for 10 days, is the treatment of choice. Obvious clinical improvement occurs after 48 h, although the fever may persist for as long as 1 week after treatment is begun. Gentamicin is also effective, but the tetracyclines are useful only if given in high doses for 15 days. In vitro testing and numerous case reports and small case series are documenting the excellent effects of the quinolones, especially ciprofloxacin, 500–750 mg twice daily for 10 days, or levofloxacin, 500 mg/day for 2 weeks.

**Carvalho CL, et al:** Tularemia. *Comp Immunol Microbiol Infect Dis* 2014; 37:85–96.

**Joseph B, et al:** Current concepts in the management of biologic and chemical warfare casualties. *J Trauma Acute Care Surg* 2013; 75:582–589.

**Nigrovic LE, et al:** Tularemia. *Infect Dis Clin North Am* 2008; 22:489.

**Snowden J, et al:** Tularemia. *Clin Pediatr (Phila)* 2011; 50:64–68.

**Tularemia—Missouri:** 2000–2007. *MMWR* 2009; 58:744.

## BRUCELLOSIS

Brucellosis is also known as undulant fever. Brucellae are gram-negative rods that produce an acute febrile illness with headache, or at times an indolent chronic disease characterized by weakness, malaise, and low-grade fever. Brucellosis is acquired primarily by contact with infected animals or animal products. Workers in the meatpacking industry are mainly at risk; however, veterinarians, pet owners, and travelers who consume unpasteurized milk or cheese may also contract the disease. Approximately 5–10% of patients develop skin lesions. The large variety of cutaneous manifestations reported include erythematous papules, diffuse erythema, abscesses, erysipelas-like lesions, leukocytoclastic vasculitis, thrombocytopenic purpura, Stevens-Johnson syndrome, and erythema nodosum-like lesions. Biopsy may reveal noncaseating granulomas.



Diagnosis is by culture of blood, bone marrow, or granulomas and may be confirmed by a rising serum enzyme-linked immunosorbent assay (ELISA) or agglutination titer. PCR is available as well. Treatment is with doxycycline and streptomycin in combination for 6 weeks.

**Buzgan T, et al:** Clinical manifestations and complications in 1028 cases of brucellosis. *Int J Infect Dis* 2010; 14:e469–e478.

**Pappas G, et al:** Brucellosis. *N Engl J Med* 2005; 352:2325.

**Ulu-Kilic A, et al:** Clinical presentations and diagnosis of brucellosis. *Recent Pat Antiinfect Drug Discov* 2013; 8:34–41.

## RICKETTSIAL DISEASES

Rickettsiae are obligate, intracellular, gram-negative bacteria. The natural reservoirs of these organisms are the blood-sucking arthropods; when transmitted to humans through insect inoculation, the rickettsiae may produce disease. Most of the human diseases incurred are characterized by skin eruptions, fever, headache, malaise, and prostration. Diagnosis is usually made on a clinical basis and is confirmed by indirect fluorescence antibody testing, which may be verified by Western blot or PCR. Therapy is with doxycycline, 100 mg twice daily for 7 days. In addition to the diseases discussed in the following sections, Q fever, caused by *Coxiella burnetii*, is an acute febrile illness from this general class that infrequently has skin manifestations, but these are nonspecific and nondiagnostic in nature.

## TYPHUS GROUP

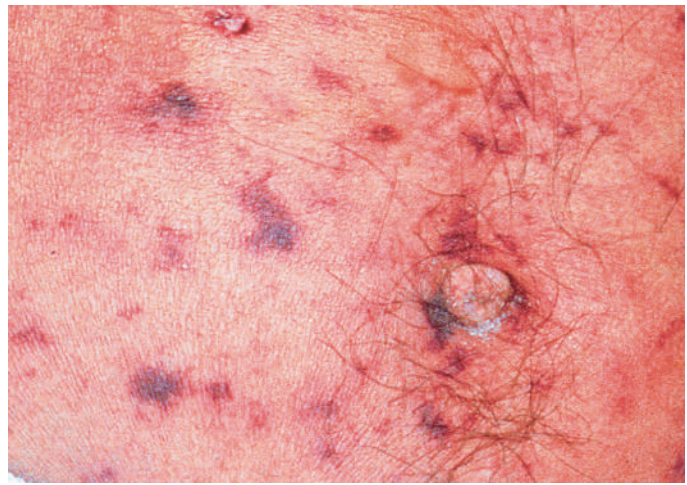
Louse-borne epidemic typhus, caused by *Rickettsia prowazekii*; mouse, cat, or rat flea-borne endemic typhus, caused by *Rickettsia typhi*; and scrub typhus, a mite-borne infection caused by *Rickettsia tsutsugamushi*, constitute the typhus group.

### Epidemic typhus

Humans contract epidemic typhus from an infestation by body lice (*Pediculus humanus* var. *corporis*), which harbor the rickettsiae. *R. prowazekii* is not transmitted transovarially because it kills the louse 1–3 weeks after infection. For many years, humans were the only known vector, but several cases of sporadic disease have been reported involving direct or indirect contact with the flying squirrel, and a reservoir exists in this animal. While the louse feeds on the person's skin, it defecates. The organisms in the feces are scratched into the skin. Some 2 weeks after infection, the prodromal symptoms of chills, fever, aches, and pains appear. After 5 days, a pink macular eruption appears on the trunk and axillary folds and rapidly spreads to the rest of the body, but usually spares the face, palms, and soles. These macules may later become hemorrhagic, and gangrene of the fingers, toes, nose, and earlobes may occur. Mortality is 6–30% in epidemics, with the highest death and complication rates occurring in patients over age 60.

Serologic testing using immunofluorescent antibody (IFA) and Western blot for specificity becomes positive after the 8th–12th day of illness. Doxycycline, 100 mg twice daily for 7 days, is curative. Prophylaxis is by vaccination and delousing; people who succumb are usually living under miserable sanitary conditions, as occur during war and after natural disasters. Vaccination is suggested only for special high-risk groups.

Brill-Zinsser disease may occur as a recrudescence of previous infection, with a similar but milder course of illness that more closely resembles endemic typhus.



**Fig. 14-46** Endemic typhus. (Courtesy of Richard DeVillez, MD.)

### Endemic typhus

Endemic (murine) typhus is a natural infection of rats and mice by *R. typhi*, sporadically transmitted to humans by the rat flea, *Xenopsylla cheopis*. In south Texas, the disease is transmitted by the cat flea, *Ctenocephalides felis*, with opossums as the natural reservoir of disease. Endemic typhus has the same skin manifestations as epidemic typhus (Fig. 14-46), but these are less severe, and gangrene does not supervene. Approximately 50% of patients with murine typhus have a skin eruption. Serologic testing using IFA and Western blot for specificity becomes positive in 50% of patients at 1 week and almost all by 2 weeks. Fever and severe headache are suggestive early symptoms. Endemic typhus occurs worldwide. In the United States, the southeastern states bordering the Gulf of Mexico, especially Texas, and California and Hawaii have been the most common sites of incidence. It most often occurs in urban settings, with peak incidence in the summer and fall. Treatment is the same as that for louse-borne (epidemic) typhus.

### Scrub typhus

Also known as tsutsugamushi fever, scrub typhus is characterized by fever, chills, intense headache, skin lesions, and pneumonitis. The primary lesion is an erythematous papule at the site of a mite bite, most often on the scrotum, groin, or ankle. It becomes indurated, and a multilocular vesicle rests atop the papule. Eventually, a necrotic ulcer with eschar and surrounding indurated erythema develops, and there is regional lymphadenopathy. About 10 days after a mite bite, fever, chills, and prostration develop, and within another 5 days, pneumonitis and the skin eruption evolve. The erythematous macular eruption begins on the trunk, extends peripherally, and fades in a few days. Deafness and tinnitus occur in about one fifth of untreated patients.

Scrub typhus is caused by *R. tsutsugamushi*. The vector is the trombiculid red mite (chigger), which infests wild rodents in scrub or secondary vegetation in transitional terrain between forests and clearings in Far Eastern countries such as Japan, Korea, Southeast Asia, and Australia. Serologic diagnosis and treatment are as for other forms of rickettsias; however, in areas of the world where there is reduced susceptibility to tetracyclines, such as Thailand, rifampin is more reliable.

## SPOTTED FEVER GROUP

The spotted fever group includes Rocky Mountain spotted fever, caused by *Rickettsia rickettsii*; Mediterranean (boutonneuse) fever, which when seen in Africa has been called Kenyan or South African tick-bite fever, caused by *R. conorii*; North Asian tick-borne rickettsiosis, caused by *R. sibirica*; Queensland tick typhus, caused by *R. australis*; African tick-bite fever, caused by *R. africae*; Flinders Island spotted fever, caused by *R. honei*; Yucatan spotted fever, caused by *R. felis* carried by the cat flea vector *Ctenocephalides felis*; Japanese spotted fever, caused by *R. japonica*; a spotted fever in the United States caused by *R. parkeri* and one in California caused by *Rickettsia* 364D; Russian vesicular rickettsiosis, caused by *R. akari* and a novel case in Brazil caused by *Rickettsia* sp. in the Atlantic rainforest. Additionally, tick-borne lymphadenopathy (TIBOLA) and *Dermacentor*-borne necrosis-eschar-lymphadenopathy (DEBONEL) are linked to a disease transmitted by the *Dermacentor* tick; they have distinctive features. The tick usually attaches to the scalp and will cause an eschar and sometimes alopecia. Adenopathy, fever, and a spotted eruption occur.

Only the first two types of spotted fever listed, Rocky Mountain and Mediterranean, are discussed here in detail. All spotted fevers are characterized by headache, fever, and a rash, the latter most frequently being a pink papular eruption, which may have petechiae, and in the case of African tick-bite fever, eschars. All are treated with doxycycline, 100 mg twice daily for 7 days. Most patients respond well, and complications are minimal. Ticks are the vectors of all except Yucatan spotted fever. Tick prevention strategies are outlined in Chapter 20.

### Rocky Mountain spotted fever

At 1–2 weeks after the tick bite, chills, fever, and weakness occur. An eruption appears, but unlike typhus, it begins on the ankles, wrists, and forehead rather than the trunk. The initial lesions are small, red macules, which blanch on pressure and rapidly become papular in untreated patients. Spread to the trunk occurs over 6–18 h, and the lesions become petechial and hemorrhagic over 2–4 days (Fig. 14-47).

A vasculitis of the skin is the pathologic process, and *R. rickettsii* can be found in these initial macules by applying a fluorescent antibody technique to frozen sections. This is a very specific, but not very sensitive, method. In the 10–20% of

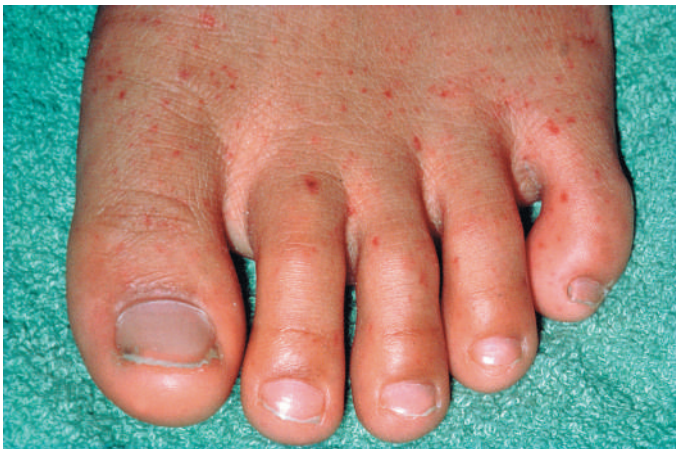

Fig. 14-47 Rocky Mountain spotted fever.

patients without a rash, the risk of a delay in diagnosis and a fatal outcome is greatest, with the case-fatality rate rising precipitously if antibiotics are not initiated before the fifth day. An eschar is occasionally present at the tick-bite site and is a subtle clue to the diagnosis. In untreated patients with severe disease, a multisystem disorder appears, with renal, pulmonary, CNS, and peripheral nervous system abnormalities and hepatomegaly most often found. Mortality in older patients approaches 60%, but is much lower in younger patients.

Ticks spread the causative organism, *R. rickettsii*. Principal offenders are the wood tick (*Dermacentor andersoni*), the dog tick (*D. variabilis* and *R. sanguineus* in Arizona), and the Lone Star tick (*Amblyomma americanum*). Antibodies become positive in the second or third week of illness, too late to be of help when the decision to institute therapy is necessary. This decision is made by clinical considerations. A clue may be the recent illness of a pet dog, because *R. rickettsii* will cause symptomatic illness in infected dogs. Treatment is with doxycycline, 100 mg twice daily for 7 days.

### Mediterranean spotted fever

Boutonneuse fever, or Mediterranean fever, is an acute febrile disease endemic in southern Europe and northern Africa; it is the prototype of the spotted fever group of diseases. It affects primarily children and is characterized by a sudden onset with chills, high fever, headache, and lassitude. The tick bite produces an indurated papule known as tache noire, which becomes a necrotic ulcer (Fig. 14-48). The erythematous macular and papular eruption develops on the trunk, palms, and soles (Fig. 14-49).

The causative organism is *Rickettsia conorii*, transmitted by the dog tick, *Rhipicephalus sanguineus*. As with all rickettsial diseases, the diagnosis is confirmed with serology and treatment is with doxycycline. Even without therapy, the prognosis is good, and complications are rare with Mediterranean fever.

### RICKETTSIALPOX

First recognized in New York in 1946, rickettsialpox has been found in other U.S. cities and in Russia. It is an acute febrile disease characterized by the appearance of an initial lesion at the site of the mite bite about a week before the onset of the fever. This firm, 5–15 mm, round or oval vesicle persists for 3–4 weeks and heals with a small, pigmented scar. Regional

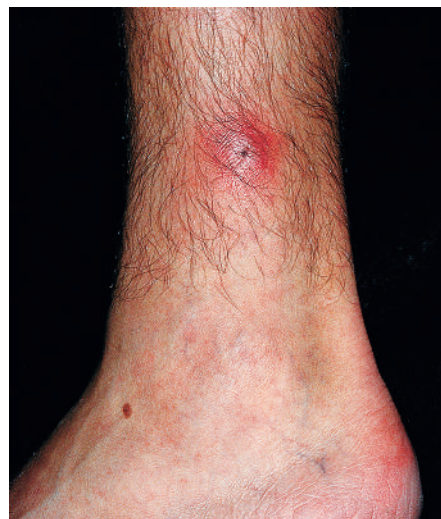
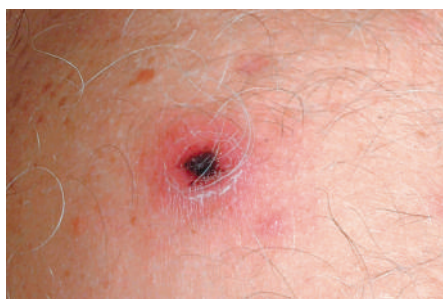
Fig. 14-48 Tache noire in boutonneuse fever.





**Fig. 14-49**  
Rickettsialpox.

lymphadenitis is present. The fever is remittent and lasts about 5 days. Chills, sweats, headache, and backache accompany the fever. A rash resembling varicella develops 3 or 4 days after onset of fever. This secondary eruption is papulovesicular, numbers about 5 up to 50 lesions, and is generalized in distribution. It fades in about 1 week.

The rodent mite, *Allodermanyssus (Liponyssoides) sanguineus*, transmits the causative organism, *Rickettsia akari*. The house mouse, *Mus musculus*, is the reservoir. All cases have occurred in neighborhoods infested by mice, on which the rodent mite has been found. Diagnosis is confirmed by serologic testing. The disease is self-limited, and complete involution occurs in, at most, 2 weeks. Doxycycline is the agent of choice for treatment of rickettsialpox.

**Badiaga S, Brouqui P:** Human louse-transmitted infectious diseases. *Clin Microbiol Infect* 2012; 18:332–337.

**Badiaga S, et al:** Murine typhus in the homeless. *Comp Immunol Microbiol Infect Dis* 2012; 35:39–43.

**Bechah Y, et al:** Epidemic typhus. *Lancet Infect Dis* 2008; 8:417.

**Botelho-Nevers E, et al:** Treatment of *Rickettsia* spp. infections. *Expert Rev Anti Infect Ther* 2012; 10:1425–1437.

**Channick RN, et al:** A 60-year-old man with weakness, rash and renal failure. *N Engl J Med* 2012; 366:1434–1443.

**Cragun WC, et al:** The expanding spectrum of eschar-associated rickettsioses in the United States. *Arch Dermatol* 2010; 146:641.

**Eisen RJ, et al:** Transmission of flea-borne zoonotic agents. *Annu Rev Entomol* 2012; 57:61–82.

**Elston DM:** Tick bites and skin rashes. *Curr Opin Infect Dis* 2010; 23:132.

**Faucher JF, et al:** Brill-Zinsser disease in a Moroccan man. *Emerg Infect Dis* 2012; 18:171–172.

**Gan SD, et al:** Fever and a solitary papule on the foot. *JAMA Dermatol* 2014; 150:203–204.

**Graham J, et al:** Tick borne diseases. *Pediatr Emerg Care* 2011; 27:141–150.

**Koh GC, et al:** Diagnosis of scrub typhus. *Am J Trop Med Hyg* 2010; 82:368–370.

**Liddell PW, et al:** Murine typhus. *Clin Lab Sci* 2012; 25:81–87.

**Maya RM, et al:** Rocky Mountain spotted fever in a patient treated with anti-TNF- $\alpha$  inhibitors. *Dermatol Online J* 2013; 19:7.

**McQuiston JH, et al:** Brill-Zinsser disease in a patient following infection with sylvatic epidemic typhus associated with flying squirrels. *Clin Infect Dis* 2010; 51:712–715.

**Nachega JB, et al:** Travel-acquired scrub typhus. *J Travel Med* 2007; 14:352.

**Shapiro MR, et al:** *Rickettsia* 364D. *Clin Infect Dis* 2010; 50:541–548.

**Spolidorio MG, et al:** Novel spotted fever group Rickettsiosis, Brazil. *Emerg Infect Dis* 2010; 16:521–523.

**Walter G, et al:** Murine typhus in returned travelers. *Am J Trop Med Hyg* 2012; 86:1049–1053.

**Woods CR:** Rocky Mountain spotted fever in children. *Pediatr Clin North Am* 2013; 60:455–470.

## EHRlichiosis

The tick-borne ehrlichial organisms, which affect phagocytic cells, manifest as a febrile illness accompanied by headache

and a rash. Human monocytic ehrlichiosis (HME) is caused by *Ehrlichia chaffeensis*; human granulocytic anaplasmosis (HGA) by *Anaplasma phagocytophilia* groups; Sennetsu fever, a mononucleosis-type illness, by *Ehrlichia sennetsu*; and *Ehrlichia ewingii* all produce a similar symptomatic illness. HME is transmitted by *Amblyomma americanum* or *Dermacentor variabilis*. It is most common in men age 30–60. The predominant U.S. regions reporting ehrlichiosis are the south-central, southeastern, and mid-Atlantic states. The same *Ixodes* ticks that transmit Lyme disease and babesiosis transmit HGA, and the infection occurs in the same geographic areas, the northeast and Pacific northwestern United States. Coinfection with these agents occurs.

Skin eruptions are present in only about one third of HME patients and 10% of HGA patients. The lesions are usually present on the trunk and are nondiagnostic. A mottled or diffuse erythema, a fine petechial eruption, lower extremity vasculitis, and a macular, papular, vesicular, or urticarial morphology have all been seen. Acral edema with desquamation and petechiae of the palate may be present. Involvement of the kidneys, lungs, and CNS occurs in severe cases.

If the diagnosis is suspected, a complete blood count will usually show thrombocytopenia and leukopenia. The leukocytes should be inspected microscopically for intracytoplasmic microcolonies called morulae, seen more frequently in HGA than HME. IFA testing and PCR analysis are positive, but asymptomatic infection is common, and seroprevalence rates are high in endemic areas. Culture of the organism is diagnostic. Doxycycline is the treatment of choice, 100 mg twice daily for 7 days. Life-threatening disease is usually seen in the immunosuppressed population.

**Ismail N, et al:** Human ehrlichiosis and anaplasmosis. *Clin Lab Med* 2010; 30:261.

**Shah RG, et al:** Clinical approach to known and emerging tick-borne infections other than Lyme disease. *Curr Opin Pediatr* 2013; 25:407–418.

**Thomas RJ, et al:** Current management of human granulocytic anaplasmosis, human monocytic ehrlichiosis and *Ehrlichia ewingii* ehrlichiosis. *Expert Rev Anti-Infect Ther* 2009; 7:709–722.

## LEPTOSPIROSIS

Leptospirosis is also known as Weil's disease, pretibial fever, and "Fort Bragg fever." It is a systemic disease caused by many strains of the genus *Leptospira*. After an incubation period of 8–12 days, Weil's disease (icteric leptospirosis) starts with an abrupt onset of chills, followed by high fever, intense jaundice, petechiae, and purpura on both skin and mucous membranes, and renal disease, manifested by proteinuria, hematuria, and azotemia. Death may occur in 5–10% of patients as a result of renal failure, vascular collapse, or hemorrhage. Leukocytosis of 15,000–30,000 cells/mm<sup>3</sup> and lymphocytosis in CSF are usually present.

Pretibial fever (Fort Bragg fever, anicteric leptospirosis) has an associated acute exanthematous infectious erythema, generally most marked on the shins. High fever, conjunctival suffusion, nausea, vomiting, and headache characterize the septicemic first stage. This lasts 3–7 days, followed by a 1–3-day absence of fever. During the second stage, when IgM antibody develops, headache is intense, fever returns, and ocular manifestations, such as conjunctival hemorrhage and suffusion, ocular pain, and photophobia, are prominent. At this time, the eruption occurs. It consists of 1–5 cm erythematous patches or plaques that histologically show only edema and nonspecific perivascular infiltrate. The skin lesions resolve spontaneously after 4–7 days. There may be different clinical manifestations from identical strains of *Leptospira*.

*Leptospira interrogans*, serotype *icterohaemorrhagiae*, has been the most common cause of Weil's disease, whereas pretibial fever is most often associated with serotype *autumnalis*. Humans acquire both types accidentally from urine or tissues of infected animals or indirectly from contaminated soil or from drinking or swimming in contaminated water. Travelers to the tropics who engage in water sports are at risk. In the continental United States, dogs and cats are the most common animal source; worldwide, rats are more often responsible. *Leptospira* enter the body through abraded or diseased skin and the GI or upper respiratory tract.

Leptospirosis may be diagnosed by finding the causative spirochetes in the blood by darkfield microscopy during the first week of illness, as well as by blood cultures, guinea pig inoculation, and the demonstration of rising antibodies during the second week of the disease. The microagglutination serologic test is the test of choice, but PCR and ELISA testing are also available.

Treatment with tetracyclines and penicillin shortens the disease duration if given early. Doxycycline, 100 mg/day for 1 week, is effective in mild disease; however, IV penicillin is necessary in severely affected patients. A dose of 200 mg once weekly may help prevent infection while visiting a hyperendemic area.

**Brett-Major DM, et al:** Antibiotic prophylaxis for leptospirosis. *Cochrane Database Syst Rev* 2009; CD007342.

**Forbes AE, et al:** Leptospirosis and Weil's disease in the UK. *Q J Med* 2012; 105:1151–1162.

**Guerra MA:** Leptospirosis. *J Am Vet Med Assoc* 2009; 234:472.

**Picardeau M:** Diagnosis and epidemiology of leptospirosis. *Med Mal Infect* 2013; 43:1–9.

## BORRELIOSIS

Spirochetes of the genus *Borrelia* are the cause of Lyme disease. This multisystem infection first presents with skin findings, and over time, multiple cutaneous signs may occur. These microorganisms are also the cause of relapsing fever, an acute illness characterized by paroxysms of fever. The more common type of relapsing fever is tick-borne, occasionally being reported in the United States. A louse-borne type is endemic only in Ethiopia. The nonspecific macular or petechial eruption occurs near the end of the 3–5-day febrile crisis.

## Lyme disease

*Borrelia burgdorferi* sensu lato species complex are responsible for inducing Lyme disease. These spirochetes are transmitted to humans by various members of the family of hard ticks, Ixodidae. Thirteen genomic strains are recognized to be geographically prominent and cause varying skin and systemic disease manifestations. *Borrelia burgdorferi* sensu stricto causes Lyme disease in the United States. *Borrelia lonestari* (a relapsing fever type of *Borrelia*, not in the *B. burgdorferi* sensu lato complex) causes disease in the southern states, in which the only skin finding is the diagnostic early manifestation, erythema migrans. *B. lonestari*, transmitted by the bite of the Lone Star tick (*Amblyomma americanum*), is the cause of southern tick-associated rash illness (STARI), or Masters disease, a condition characterized by erythema migrans, headache, stiff neck, myalgia, and arthralgia. *Borrelia garinii* and *Borrelia afzelii* are two major strains present in Europe, with *B. garinii* the principal agent of Lyme neuroborreliosis and *B. afzelii* associated with acrodermatitis chronica atrophicans, lymphocytoma, and in some cases, morphea and lichen sclerosis et atrophicus. If disease is not treated in the early stage, chronic

arthritis and neurologic and cardiac complications frequently develop. Other strains are present in Europe and Asia, with a few reports implicating them in rare cases of Lyme disease.

Diagnosing early Lyme disease depends on recognition of the skin eruption. Approximately 50% of patients recall a tick bite, which leaves a small, red macule or papule at the site. The areas most often involved are the legs, groins, and axilla, with adults having lower extremity lesions most often and children more likely to manifest erythema migrans on the trunk. Between 3 and 32 days (median 7) after the bite, there is gradual expansion of the redness around the papule (Fig. 14-50, A). The advancing border is usually slightly raised, warm, red to bluish red, and free of any scale. Centrally, the site of the bite may clear, leaving only a ring of peripheral erythema, or it may remain red, becoming indurated, vesicular, or necrotic. In Europe, the large annular variety is most common, whereas in the United States the lesions are usually homogeneous or have a central redness. The annular erythema usually grows to a median diameter of 15 cm but may range from 3–68 cm (Fig. 14-50, B). It is accompanied by a burning sensation in half of patients; rarely is it pruritic or painful. Localized alopecia may develop at the site of erythema migrans.

From 25–50% of patients will develop multiple secondary annular lesions, similar in appearance to the primary lesion, but without indurated centers and generally of smaller size (Fig. 14-51). The lesions, 2–100 in number, spare the palms and soles. Without treatment, erythema migrans and the secondary lesions fade in a median of 28 days, although some may be present for months. Of untreated patients, 10% experience recurrences of erythema migrans over the following months. European cases of *Borrelia*-induced lymphocytoma occur early in general, from the time of erythema migrans until 10 months later. These are B-cell proliferations and present as red, indurated papules and plaques, which occur most often on the areola or earlobe.

Diffuse urticaria, malar erythema, and conjunctivitis may be present during this early period. Malaise, fever, fatigue, headaches, stiff neck, arthralgia, myalgia, lymphadenopathy, anorexia, and nausea and vomiting may accompany early signs and symptoms of infection. Usually, the symptoms are of mild severity, mimicking a slight flulike illness, except in patients coinfecting with babesiosis, as in approximately 10% of cases in southern New England. *Ehrlichia* coinfections may also occur, because the latter two diseases are also tick-transmitted infections.

About 10% of untreated patients eventually develop a chronic arthritis of the knees, which in half of patients leads to severe disability. Cardiac involvement occurs most often in young men, with fluctuating degrees of atrioventricular block or complete heart block occurring over a brief time, 3 days to 6 weeks, early in the course of the illness. In European cases, a dilated cardiomyopathy may eventuate. Neurologic findings include stiff neck, headache, meningitis, cognitive deficits, paresthesias and radiculopathy, Bell palsy, optic neuritis, vestibular neuronitis, oculomotor palsy, and cranial and peripheral neuropathies and are much more frequently manifested in European patients. Nonspecific findings include an elevated erythrocyte sedimentation rate in 50% and an elevated IgM level, mild anemia, and elevated liver function tests in 20% of patients.

Males and females are equally affected, and the age range most often affected is of bimodal type, with an early peak at 5–19 and a later peak at 55–69 years. Onset of illness is generally between May and November, with more than 80% of cases in the Northern Hemisphere identified in June, July, or August. In the United States, tick transmission of Lyme disease is by *Ixodes scapularis* in the Northeast and Midwest, and



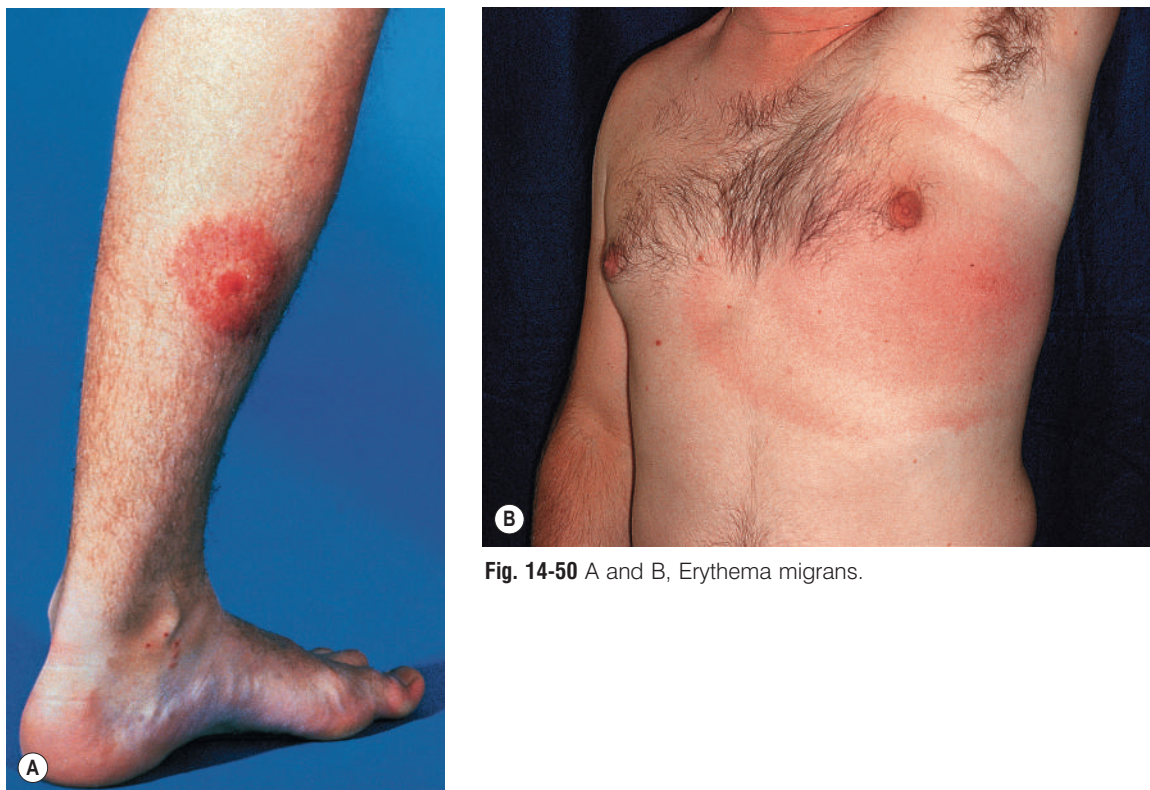

Fig. 14-50 A and B, Erythema migrans.

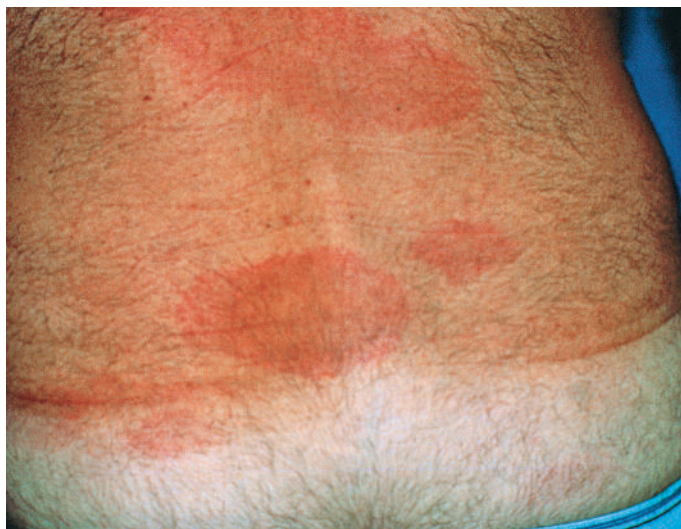

Fig. 14-51 Secondary lesions of erythema migrans.

*Ixodes pacificus* is incriminated in the West. European cases are transmitted by the ticks *Ixodes ricinus* and *I. persulcatus*, and in Asia by *I. ovatus* and *I. persulcatus*.

The different subtypes of *Borrelia* present in Europe account for the clinical illness resulting from infection being somewhat different from that seen in the United States. European erythema migrans occurs more often in females and is less likely to have multiple lesions. Untreated lesions last longer; there are more laboratory abnormalities in Lyme disease; the arthritis symptoms are prominent in the United States but unusual in Europe; and the neurologic manifestations differ. In Europe, infection may lead to Bannwarth syndrome, which is characterized by focal, severe, radicular pains; lymphocytic meningitis; and cranial nerve paralysis. Acrodermatitis chronica atrophicans, lymphocytoma cutis, and some cases of morphea, atrophoderma of Pasini and Pierini, anetoderma, and lichen

sclerosus et atrophicus are late cutaneous sequelae of *Borrelia afzelii* or *B. garinii* infection in Europe. Some patients with morphea-type lesions may have histopathologic features of an interstitial granulomatous dermatitis with histiocytic pseudorosettes present.

Several cases of transplacental transmission of *Borrelia* resulting in infant death have been reported. However, studies of Lyme disease in pregnancy have generally failed to implicate an association with fetal malformations directly.

On histologic investigation, there is a superficial and deep perivascular and interstitial mixed-cell infiltrate. Lymphocytes, plasma cells, and eosinophils may be seen, the latter especially prominent when the center of the lesion is biopsied. Warthin-Starry staining may reveal spirochetes in the upper dermis.

The clinical finding of erythema migrans is the most sensitive evidence of early infection. Serologic conversion in U.S. patients is as follows: 27% when symptoms present for fewer than 7 days, 41% with symptoms for 7–14 days, and 88% with symptoms longer than 2 weeks. For this reason, the diagnosis is made through recognition of erythema migrans. Although culture with PCR analysis is specific, it is not sensitive and is not available in most areas. Serologic testing is then the confirmatory test. The screening examination is ELISA, which is 89% sensitive and 72% specific. Western blot is used to confirm the result. There are three antigenic bands used in the IgM test and 10 in the IgG test. Two of three in the IgM and 5 of 10 in the IgG must be positive to diagnose Lyme disease. False-positive tests occur in syphilis, pinta, yaws, leptospirosis, relapsing fever, infectious mononucleosis, and disease associated with autoantibody formation. The VDRL is negative in *B. burgdorferi* infection. Patients with erythema migrans secondary to STARI usually have negative serology for Lyme disease.

## Treatment

The treatment of choice in adults with Lyme disease is doxycycline, 100 mg twice daily for 3 weeks. Amoxicillin, 500 mg

twice daily for 21 days, or cefuroxime axetil, 500 mg twice daily for 21 days, is also effective. Doxycycline is also effective against *Ehrlichia*, but the  $\beta$ -lactams are not. Children under age 9 should be treated with amoxicillin, 20 mg/kg/day in divided doses. Pregnant women with localized early Lyme disease should take amoxicillin; however, if disseminated disease is present, parenteral penicillin G or ceftriaxone is used. Immunodeficient patients may also benefit from IV penicillin or ceftriaxone, although the data are not robust for this recommendation.

More aggressive regimens are necessary for carditis and neurologic and arthritic involvement, with parenteral dosing regimens often indicated.

Tick control environmental measures and personal avoidance strategies are worthwhile when outdoor activities are planned in tick-infested areas. Inspecting for ticks after returning from outdoor activity is a good preventive measure. The tick needs to be attached for more than 24 h to transmit disease in the United States. Nymphs are small and may be difficult to see; be aware of the freckle that moves. Prophylactic antibiotic therapy, with one dose of 200-mg doxycycline after a known tick bite with a partially engorged *Ixodes scapularis* in high-incidence areas, is 87% effective. An effective vaccine was withdrawn from the market because of poor sales.

### Acrodermatitis chronica atrophicans

Also known as primary diffuse atrophy, acrodermatitis chronica atrophicans (ACA) is characterized by the appearance on the extremities of diffuse reddish or bluish red, paper-thin skin. The underlying blood vessels are easily seen through the epidermis. It occurs almost exclusively in Europe. The disease begins on the backs of the hands and feet, then gradually spreads to involve the forearms, the arms, and the lower extremities, knees, and shins. Occasionally, even the trunk may become involved. In the beginning, the areas may be slightly edematous and scaly, but generally they are level with the skin and smooth. After several weeks to months, the skin has a smooth, soft, thin, velvety feel and may easily be lifted into fine folds. It may have a peculiar pinkish gray color and a crumpled-cigarette-paper appearance. Well-defined, smooth, edematous, bandlike thickenings develop and may extend from a finger to the elbow (ulnar bands) or may develop in the skin over the shins. With progression of ACA, marked atrophy of the skin occurs.

Subcutaneous fibrous nodules may form, chiefly over the elbows, wrists, and knees. Nodules may be single or multiple and are firm and painless. Diffuse extensive calcification of the soft tissues may be revealed by radiographic examination. Xanthomatous tumors may occur in the skin. Hypertrophic osteoarthritis of the hands is frequently observed. Occasionally, atrophy of the bones of the involved extremities is encountered. Ulcerations and carcinoma may supervene on the atrophic patches. ACA is slowly progressive but may remain stationary for long periods. Patches may change slightly from time to time, but complete involution never occurs.

A spirochetosis, ACA is a late sequel of infection with *Borrelia afzelii*, transmitted by the tick *Ixodes ricinus*. Almost all patients with ACA have a positive test for antibodies to the spirochete, and Warthin-Starry stains demonstrate *B. afzelii* in tissue in some cases. The organism has been cultured from skin lesions of ACA.

Histologically, there is marked atrophy of the epidermis and dermis without fibrosis. The elastic tissue is absent, and the cutaneous appendages are atrophic. In the dermis, a bandlike lymphocytic infiltration is seen, which varies in abundance

according to the stage of the disease. The epidermis is slightly hyperkeratotic and flattened, and beneath it, there is a distinctive narrow zone of connective tissue in which the elastic tissue is intact.

Antibiotic therapy, as for other forms of borreliosis, cures most patients with ACA.

- Aberer E:** What should one do in case of a tick bite? *Curr Probl Dermatol* 2009; 37:155.
- Bhate C, et al:** Lyme disease. *J Am Acad Dermatol* 2011; 64:619–653.
- Cutler SJ:** Relapsing fever. *J Appl Microbiol* 2010; 108:1115–1122.
- Eisendle K, et al:** The expanding spectrum of cutaneous borreliosis. *G Ital Dermatol Venereol* 2009; 144:157.
- Esposito S, et al:** *Borrelia burgdorferi* infection and Lyme disease in children. *Int J Infect Dis* 2013; 17:e153–e158.
- Feder HM Jr:** Lyme disease in children. *Infect Dis Clin North Am* 2008; 22:315.
- Feder HM Jr, et al:** Southern tick-associated rash illness (STARI) in the North: STARI following a tick bite in Long Island, New York. *Clin Infect Dis* 2011; 53:e142–e146.
- Masters EJ, et al:** STARI, or Masters disease. *Infect Dis Clin North Am* 2008; 22:361.
- Mullegger RR:** Skin manifestations of Lyme borreliosis. *Am J Clin Dermatol* 2008; 9:355.
- Murray TS, et al:** Lyme disease. *Clin Lab Med* 2010; 30:311.
- Smetanick MT, et al:** Acrodermatitis chronica atrophicans. *Cutis* 2010; 85:247.
- Shapiro ED:** Clinical practice. Lyme disease. *N Engl J Med*. 2014; 370:1724–1731.
- Tiger JB, et al:** Bullous Lyme disease. *J Am Acad Dermatol* 2014; 71:e133–134.
- Stanek G, et al:** Lyme borreliosis. *Lancet* 2012; 379:461–473.
- Walsh CA, et al:** Lyme disease in pregnancy. *Obstet Gynecol Surv* 2007; 62:41.

### MYCOPLASMA

*Mycoplasma* organisms are distinct from true bacteria in that they lack a cell wall and differ from viruses in that they grow on cell-free media. *Mycoplasma pneumoniae* (Eaton agent) is an important cause of acute respiratory disease in children and young adults. In the summer, it may account for an estimated 50% of pneumonias. Skin eruptions occur during the course of infection in approximately 25% of patients. The most frequently reported is Stevens-Johnson syndrome. Erythema nodosum and Gianotti-Crosti syndrome have been occasionally reported, as well as isolated mucositis without skin lesions (Fuchs syndrome, or Stevens-Johnson syndrome without skin lesions). Other exanthems include urticarial, vesicular, vesiculopustular, maculopapular, scarlatiniform, petechial, purpuric, and morbilliform lesions, distributed primarily on the trunk, arms, and legs. Ulcerative stomatitis and conjunctivitis may be present.

The diagnosis of *M. pneumoniae* infection is made in the acute situation by clinical means, but definitive diagnosis is made by enzyme immunoassay, PCR, or complement fixation techniques. Cold agglutinins with a titer of 1:128 or more are usually caused by *M. pneumoniae* infection. Occasionally, acrocyanosis may occur secondary to cold agglutinin disease, which clears with antibiotic therapy. Treatment is with either a macrolide (erythromycin, azithromycin, or clarithromycin) or doxycycline for 7 days.

- Atkinson TP, et al:** Epidemiology, clinical manifestations, pathogenesis and laboratory detection of *Mycoplasma pneumoniae* infections. *FEMS Microbiol Rev* 2008; 32:956.
- Li K, et al:** Stevens-Johnson syndrome without skin lesions (Fuchs syndrome). *Arch Dermatol* 2012; 148:963–964.
- Meyer Sauter PM, et al:** Fuchs syndrome associated with *Mycoplasma pneumoniae* (Stevens-Johnson syndrome without skin lesions). *Pediatr Dermatol* 2011; 28:474–476.



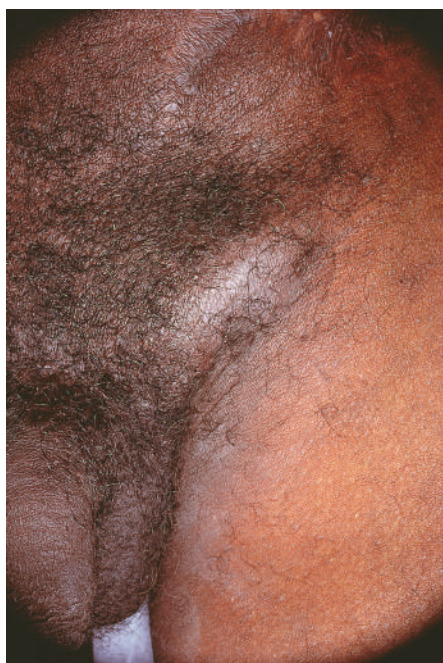## CHLAMYDIAL INFECTIONS

Two species of chlamydiae, *Chlamydia trachomatis* and *Chlamydia psittaci*, have been recognized. The two species share a major common antigen, and there are numerous serotypes within each species. In humans, *Chlamydia* causes trachoma, inclusion conjunctivitis, nongonococcal urethritis, cervicitis, epididymitis, proctitis, endometritis, salpingitis, pneumonia in the newborn, psittacosis (ornithosis), and lymphogranuloma venereum.

## LYMPHOGRANULOMA VENEREUM

Lymphogranuloma venereum (LGV) is an STD caused by microorganisms of the *Chlamydia trachomatis* group and characterized by suppurative inguinal adenitis with matted lymph nodes, inguinal bubo with secondary ulceration, and constitutional symptoms. After an incubation period of 3–20 days, a primary lesion consisting of a 2–3 mm herpetiform vesicle or erosion develops on the glans penis, prepuce, or coronal sulcus, or at the meatus. In MSM, the lesion may be in the rectum. In women, it occurs on the vulva, vagina, or cervix. The lesion is painless and soon becomes a shallow ulceration. The initial symptom may be urethritis or proctitis. Extragenital primary infections of LGV are rare. An ulcerating lesion may appear at the site of infection on the fingers, lips, or tongue. In patients with HIV infection, a painful perianal ulcer may occur. Primary lesions heal in a few days.

About 2 weeks after the appearance of the primary lesion, enlargement of the regional lymph nodes occurs (Fig. 14-52). In one third of patients, the lymphadenopathy is bilateral. In the rather characteristic inguinal adenitis of LGV in men, the nodes in a chain fuse together into a large mass. The color of the skin overlying the mass usually becomes violaceous, the swelling is tender, and the bubo may break down, forming multiple fistulous openings. Adenopathy above and below the Poupart ligament produces the characteristic, but not



**Fig. 14-52**  
Lymphogranuloma venereum.

diagnostic, groove sign. Along with the local adenitis, there may be systemic symptoms of malaise, joint pains, conjunctivitis, loss of appetite, weight loss, and fever, which may persist for several weeks. Patients with septic temperatures, enlarged liver and spleen, and even encephalitis have occasionally been observed.

Primary lesions of LGV are rarely observed in female patients; women also have a lower incidence of inguinal buboes. Their bubo is typically pararectal in location. The diagnosis is recognized only much later, when the patient presents with an increasingly pronounced inflammatory stricture, which may be annular or tubular, of the lower rectal wall. Because most of the lymph channels running from the vulva drain into the nodes around the lower part of the rectum, an inflammatory reaction in these nodes results in secondary involvement of the rectal wall. The iliac nodes may also be involved. LGV may start in the rectum as proctitis, which may then progress to the formation of a stricture. The clinical hallmark is bloody, mucopurulent rectal discharge. The stricture can usually be felt with the examining finger 4–6 cm above the anus. Untreated rectal strictures in men and women may eventually require colostomy. With or without rectal strictures, women in later stages of the disease may show elephantiasis of the genitals with chronic ulcerations and scarring of the vulva (esthiomene). Such a reaction is rare in men.

Cutaneous eruptions take the form of erythema nodosum, erythema multiforme, photosensitivity, and scarlatiniform eruptions. Arthritis associated with LGV involves the finger, wrist, ankle, knee, or shoulder joints. Marked weight loss, pronounced secondary anemia, weakness, and mental depression are often encountered in the course of the anorectal syndrome. Colitis resulting from LGV is limited to the rectum and rectosigmoid structures. Perianal fistulas or sinuses are often seen in cases of anorectal LGV. The various extragenital manifestations include glossitis with regional adenitis, unilateral conjunctivitis with edema of the lids caused by lymphatic blockage with lymphadenopathy, acute meningitis, meningoencephalitis, and pneumonia.

The diagnosis by nucleic acid amplification tests identifies *C. trachomatis* in a wide variety of specimens, including urine; urethral, rectal, and ulcer swabs; bubo aspirates; and biopsy specimens. The complement fixation test is the most feasible and the simplest serologic test for detecting antibodies in resource-poor locales. These antibodies become detectable about 4 weeks after onset of illness; a titer of 1:64 is highly suggestive. Microhemagglutination inhibition assays are also available and not only confirm the diagnosis, but also identify the strain. Three serotypes, designated L1, L2, and L3, are known for the LGV chlamydia. Characteristic surface antigens allow separation of the LGV chlamydiae from the agents that cause trachoma, inclusion conjunctivitis, urethritis, and cervicitis, which also belong to the *C. trachomatis* group.

Lymphogranuloma venereum occurs in all races, and the highest incidence is found in the 20–40-year-old group. Asymptomatic female contacts who shed *C. trachomatis* from the cervix are an important reservoir of infection. The classic disease in men is uncommon in the United States, whereas anorectal LGV is increasing in MSM.

The characteristic changes in the lymph nodes consist of an infectious granuloma with the formation of stellate abscesses. There is an outer zone of epithelioid cells with a central necrotic core composed of debris of lymphocytes and leukocytes. In lesions of long duration, plasma cells may be present. Stellate abscess also occurs in cat-scratch disease, atypical mycobacterial infection, tularemia, and sporotrichosis.

In contrast to LGV, with chancroid a primary chancre or multiple chancroidal ulcers are present and may permit the demonstration of *Haemophilus ducreyi*. The skin lesions

are characteristic and usually much larger and more persistent than the primary lesion of LGV. Donovan bodies are demonstrable in granuloma inguinale; however, inguinal adenitis is not characteristic. Esthiomene may also be seen in both diseases.

If the primary lesion of LGV is well developed, it may be confused with the primary lesion of syphilis. In any genital lesion, darkfield examination for *Treponema pallidum* is indicated if available. Syphilitic inguinal adenitis shows small, hard, nontender glands. It should be emphasized again that all venereal infections may be mixed infections and that observation for simultaneous or subsequent development of another venereal disease should be unrelenting. This includes serologic testing for HIV disease. Late stages of LGV esthiomene with ulcerating and cicatrizing lesions need to be differentiated from syphilis by a search for spirochetes, the serologic tests for syphilis, and complement fixation tests.

## Treatment

The recommended treatment of LGV is doxycycline, 100 mg twice daily for 3 weeks. An alternative is erythromycin, 500 mg four times daily for 21 days. Sexual partners within the prior 30 days should also be treated. The fluctuant nodules are aspirated from above through healthy, adjacent, normal skin to prevent rupture.

**Basta-Juzbasic A, et al:** Chancroid, lymphogranuloma venereum, granuloma inguinale, genital herpes simplex infection, and molluscum contagiosum. *Clin Dermatol* 2014; 32:290–298.

**Bebear C, et al:** Genital *Chlamydia trachomatis* infections. *Clin Microbiol Infect* 2009; 15:4.

**Mistangelo M, et al:** Rectal lymphogranuloma venereum. *Colorectal Dis* 2012; 14:e792–e793.

**Patel S, Hay P:** Lymphogranuloma venereum and HIV infection: misdiagnosed as Crohn's disease. *BMJ Case Rep* 2010; Nov 26.

**Singhrao T, et al:** Lymphogranuloma venereum presenting as perianal ulceration. *Sex Transm Dis* 2011; 87:123–124.

**White JA:** Manifestations and management of lymphogranuloma venereum. *Curr Opin Infect Dis* 2009; 22:57.

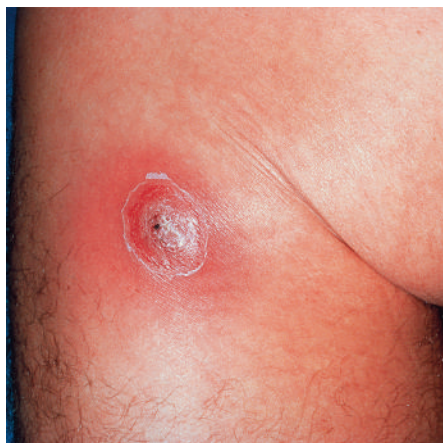

Bonus images for this chapter can be found online at

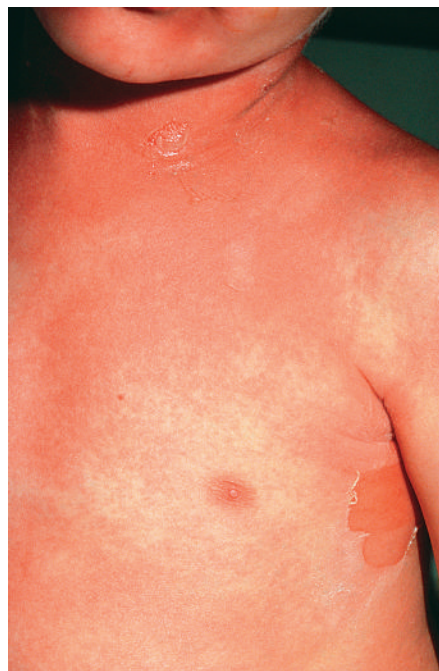[expertconsult.inkling.com](http://expertconsult.inkling.com)

- eFig. 14-1 Staphylococcal abscess.
- eFig. 14-2 Impetigo.
- eFig. 14-3 Sporotrichoid staphylococcal abscesses.
- eFig. 14-4 Staphylococcal scalded skin syndrome.
- eFig. 14-5 Ecthyma.
- eFig. 14-6 Erysipelas.
- eFig. 14-7 Erysipelas.
- eFig. 14-8 Necrotizing fasciitis.
- eFig. 14-9 Erythrasma.
- eFig. 14-10 Pitted keratolysis.
- eFig. 14-11 Nocardiosis.
- eFig. 14-12 Gram-negative toe web infection.
- eFig. 14-13 *Pseudomonas* folliculitis.
- eFig. 14-14 Chancroid.
- eFig. 14-15 Granuloma inguinale.
- eFig. 14-16 Gonococcemia.
- eFig. 14-17 Meningococcemia.
- eFig. 14-18 Primary lesion of lymphogranuloma venereum.
- eFig. 14-19 Tularemia.
- eFig. 14-20 Bouton-neuse fever.

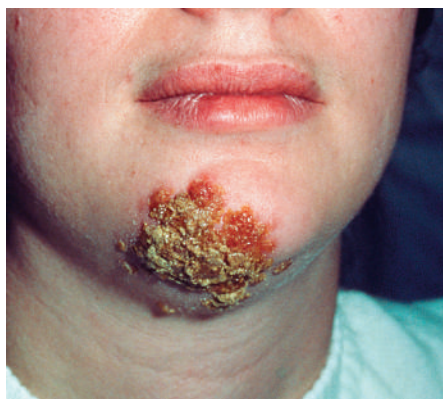



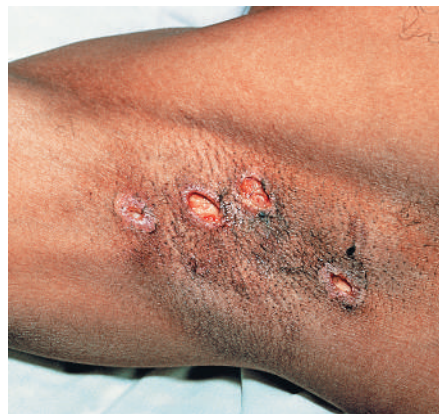**eFig. 14-1**  
Staphylococcal abscess.



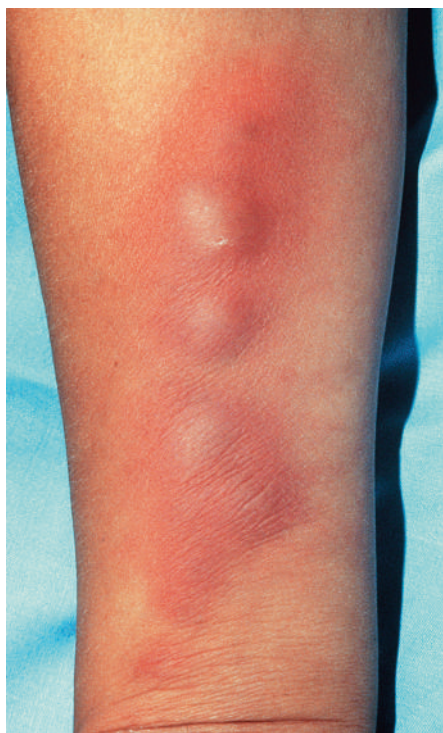**eFig. 14-4**  
Staphylococcal scalded skin syndrome.



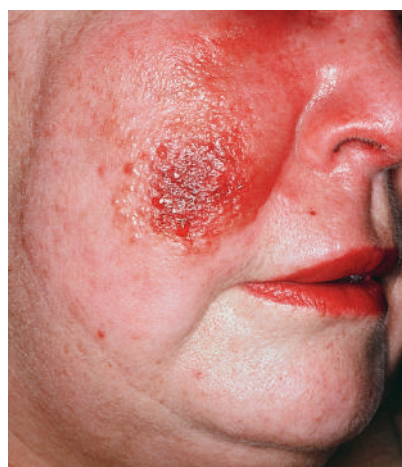**eFig. 14-2** Impetigo.



**eFig. 14-5** Ecthyma.

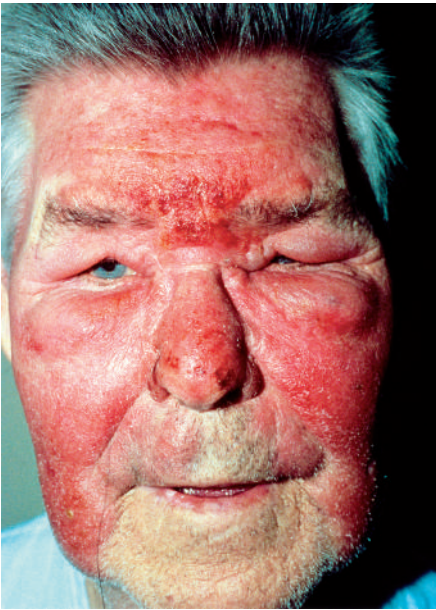

**eFig. 14-3**  
Sporotrichoid staphylococcal abscesses.

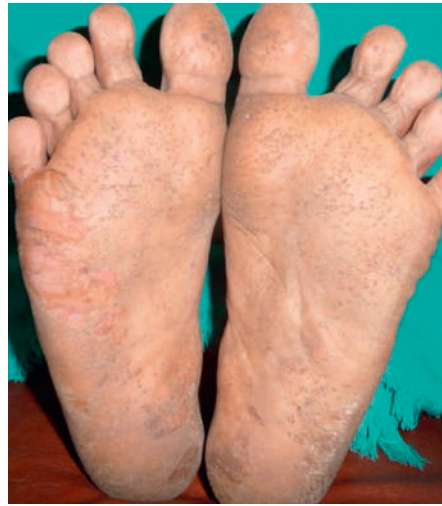

**eFig. 14-6** Erysipelas.

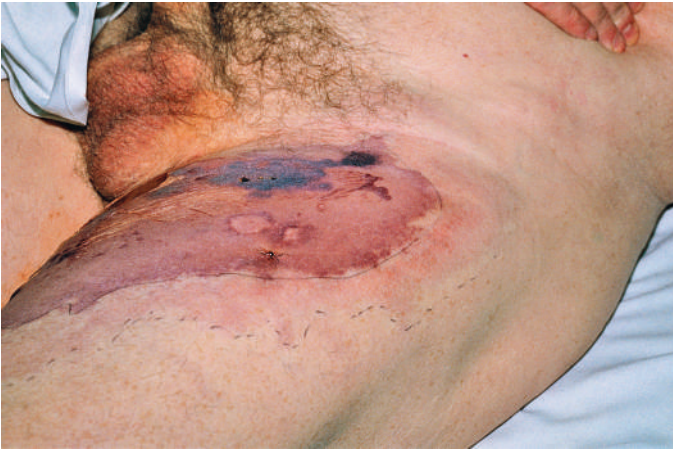



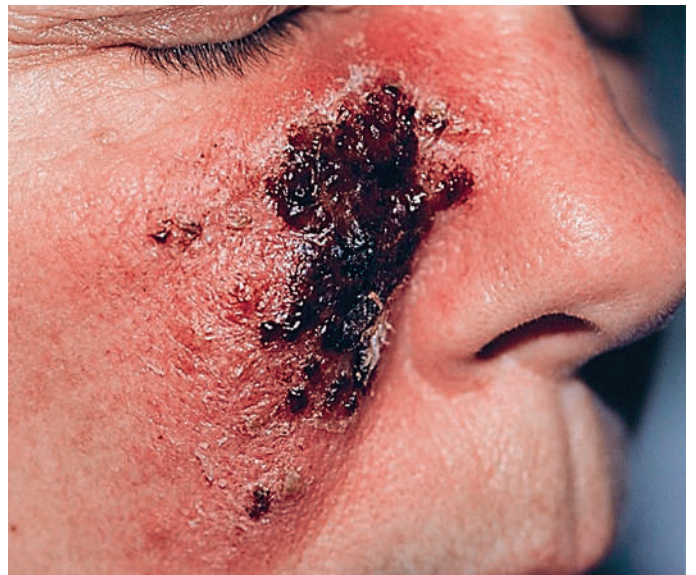eFig. 14-7 Erysipelas.



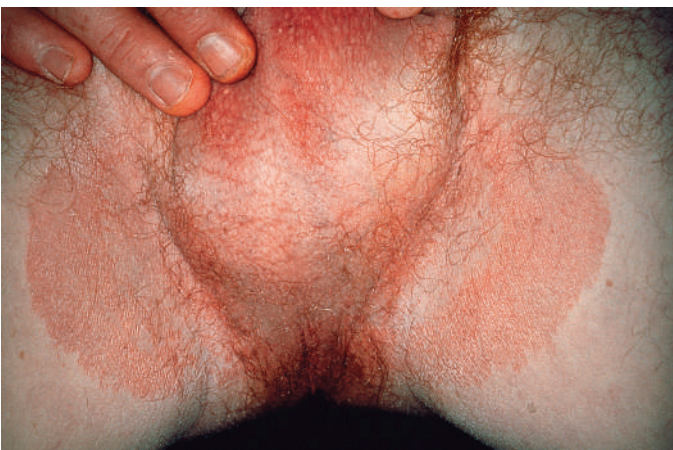eFig. 14-10 Pitted keratolysis.



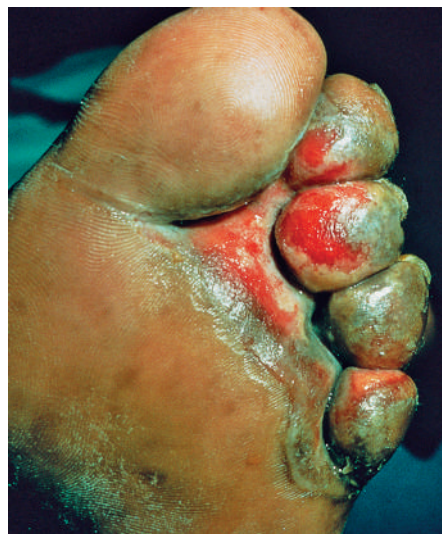eFig. 14-8 Necrotizing fasciitis.



eFig. 14-11 Nocardiosis.

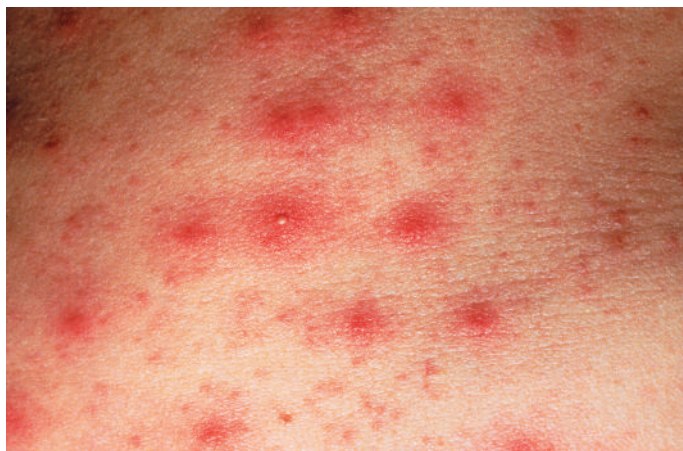

eFig. 14-9 Erythrasma.

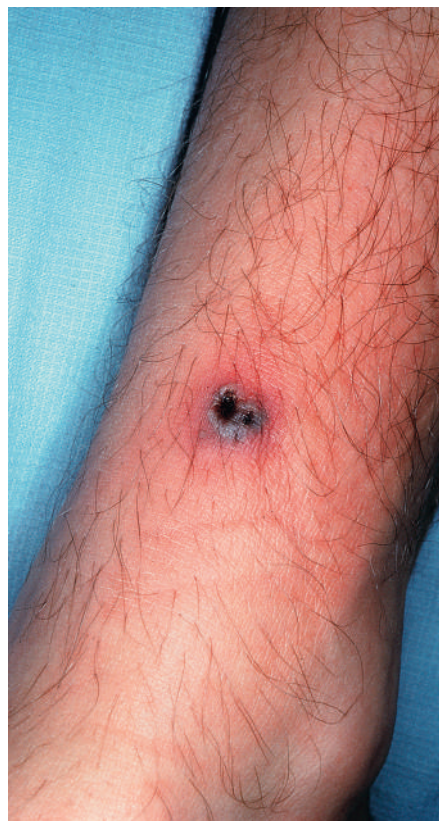

eFig. 14-12 Gram-negative toe web infection.

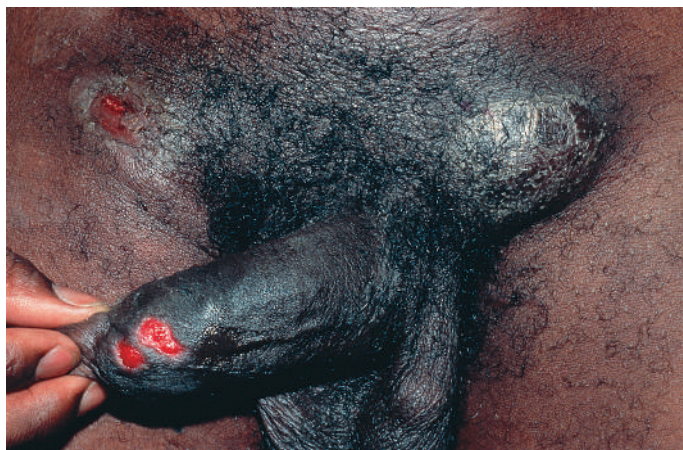



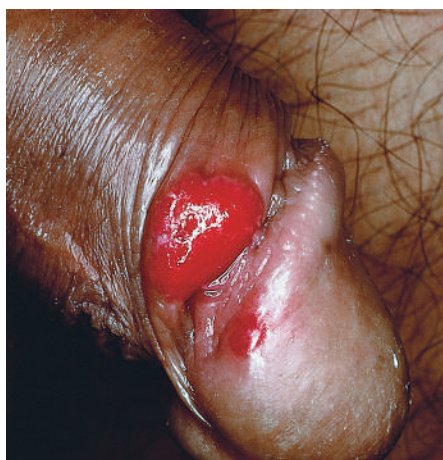eFig. 14-13 *Pseudomonas* folliculitis.



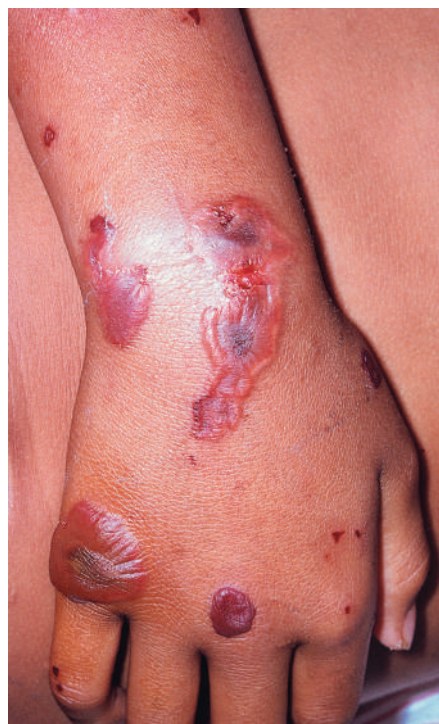eFig. 14-16  
Gonococemia.



eFig. 14-14 Chancroid.

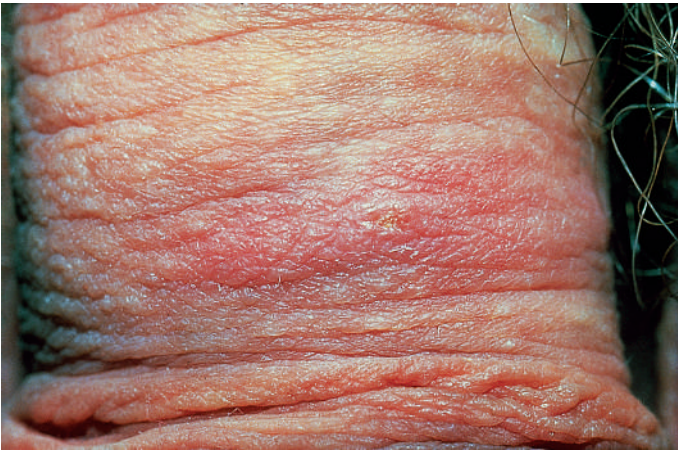


eFig. 14-15 Granuloma  
inguinale.

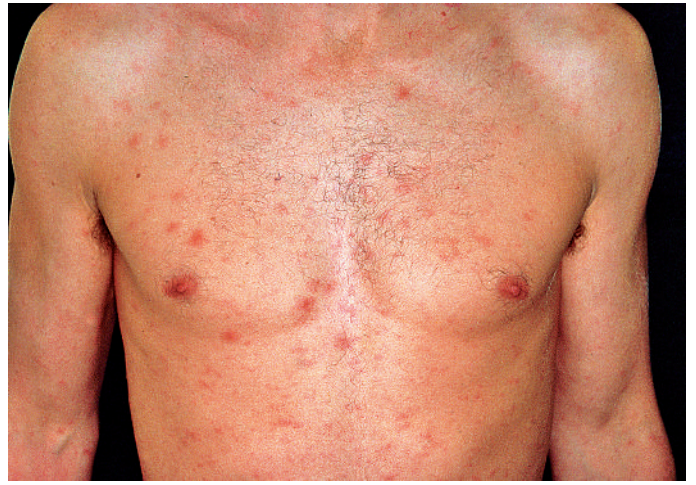

eFig. 14-17  
Meningococemia.

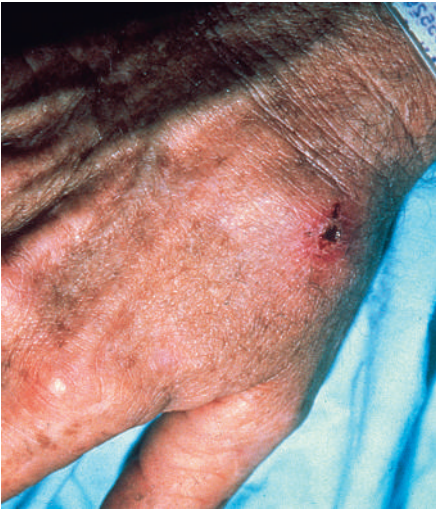



**eFig. 14-18** Primary lesion of lymphogranuloma venereum.



**eFig. 14-20** Boutonneuse fever.



**eFig. 14-19** Tularemia.



## Diseases Resulting from Fungi and Yeasts

### SUPERFICIAL AND DEEP MYCOSES

An estimated 20–25% of the world's population has some form of fungal infection, usually an anthropophilic *Trichophyton* infection, making fungal infections the most common type of infection worldwide. Cutaneous infections are divided into superficial and deep mycoses. Most mycotic infections are superficial and are limited to the stratum corneum, hair, and nails. In contrast, most deep mycoses are evidence of disseminated infection, typically with a primary pulmonary focus. Although blastomycosis, histoplasmosis, and coccidioidomycosis generally present as skin lesions, they are almost always evidence of a systemic infection. A few deep mycoses result from direct inoculation into the skin by a thorn or other foreign body, including cutaneous lymphangitic sporotrichosis, primary cutaneous phaeohyphomycosis, and chromomycosis. Phaeohyphomycosis generally begins as a skin infection, but immunosuppressed patients are at great risk of dissemination and death. Even cutaneous sporotrichosis may occasionally disseminate. Although most cutaneous aspergillosis represents cutaneous embolization from a systemic (often a pulmonary) focus, in burn victims, *Aspergillus* typically colonizes the burn eschar. This colonization may often be treated with debridement alone. Deep incisional biopsies are required to determine if viable tissue has been invaded beneath the eschar. Evidence of viable tissue invasion suggests a likelihood of systemic dissemination and is usually an indication for systemic antifungal therapy.

The major fungi that cause only stratum corneum, hair, and nail infection are the dermatophytes. They are classified in three genera: *Microsporum*, *Trichophyton*, and *Epidermophyton*. The identity of the pathogen may be important for determining a zoonotic reservoir of infection: cat or dog for *Microsporum canis* infections, cattle for *Trichophyton verrucosum*, and rats for granular zoophilic *Trichophyton mentagrophytes*.

### Susceptibility and prevalence

Local immunosuppression from a potent topical corticosteroid or calcineurin inhibitor may promote widespread tinea infection. A defective cutaneous barrier, as in patients with ichthyosis, can also predispose to widespread tinea infection. Patients with blood type A are somewhat more prone to chronic disease, and those with autosomal recessive CARD9 deficiency are susceptible to invasive fungal infection with dissemination to lymph nodes and the central nervous system (CNS). Many individuals will carry *Trichophyton rubrum* asymptotically, which may be an autosomal dominant inherited tendency. When they are exposed to a hot, humid climate or occlusive footwear, these patients often become symptomatic. Reported prevalence rates are therefore greatly affected by climate, footwear, and lifestyle.

### Antifungal therapy

Topical agents provide safe, cost-effective therapy for limited superficial fungal infections. When considering the use of an oral antifungal agent, factors include the type of infection, organism, spectrum, pharmacokinetic profile, safety, compliance, and cost. Griseofulvin has a long safety record but requires much longer courses of therapy than newer agents. Topical antifungals remain very cost-effective for limited cutaneous disease.

Various classes of antifungals are in use. The imidazoles include clotrimazole, miconazole, econazole, sulconazole, oxiconazole, voriconazole, efinaconazole, and ketoconazole. They work by inhibition of cytochrome P450 14 $\alpha$ -demethylase, an essential enzyme in ergosterol synthesis. Nystatin is a polyene that works by irreversibly binding to ergosterol, an essential component of fungal cell membranes. Naftifine, terbinafine, and butenafine are allylamines, and their mode of action is inhibition of squalene epoxydation. The triazoles include itraconazole and fluconazole, which affect the CYP450 system.

For both itraconazole and griseofulvin, food increases absorption. For itraconazole and ketoconazole, antacids, H<sub>2</sub> antagonists, and proton pump inhibitors lower absorption. Terbinafine is less active against *Candida* and *Microsporum* species (spp.) in vitro. In vivo, adequate doses can be effective against these organisms. Terbinafine has limited efficacy in the oral treatment of tinea versicolor but is effective topically. Although few drug interactions have been reported with terbinafine, and the bioavailability is unchanged in food, hepatotoxicity, leukopenia, toxic epidermal necrolysis, and taste disturbances occur infrequently. Ketoconazole has a wide spectrum of action against dermatophytes, yeasts, and some systemic mycoses, but has the potential for serious drug interactions and a higher incidence of hepatotoxicity than other available agents.

Fluconazole is mainly used to treat *Candida* infections, but has shown efficacy in the treatment of dermatophytoses both in daily and in weekly doses. Patients may have trouble remembering intermittent dosing schedules.

Both terbinafine and itraconazole have been shown to be effective and well tolerated in several studies of the treatment of tinea capitis and onychomycosis in children. However, itraconazole has been associated with reports of heart failure.

Voriconazole has exceptional activity against a wide variety of yeasts, as well as many other fungal pathogens, but has been associated with photosensitivity, premature photoaging, actinic keratoses, squamous cell carcinoma, melanoma, and porphyria. Posaconazole has significant in vitro activity against *Candida* spp., although some resistance has been reported to this drug.

The echinocandins inhibit  $\beta$ -(1,3)-glucan synthesis, thus damaging fungal cell walls. These drugs are active against most *Candida* spp. and fungistatic against *Aspergillus* spp. The

echinocandins have limited activity against zygomycetes, *Cryptococcus neoformans*, or *Fusarium* spp. Caspofungin was the first drug in this class to be marketed in the United States for refractory invasive aspergillosis. Miconazole also belongs to this antifungal class. Adverse events are uncommon but include phlebitis, fever, elevated liver enzymes, and mild hemolysis. The drugs must be given intravenously. Metabolism is mainly hepatic. In the setting of *Candida* sepsis, results are similar to those achieved with amphotericin B, with substantially lower toxicity. The echinocandins may be used together with other antifungal agents in the treatment of life-threatening systemic fungal infections, such as disseminated aspergillosis refractory to other regimens.

## THE SUPERFICIAL MYCOSES

### TINEA CAPITIS

Tinea capitis, also known as scalp ringworm, can be caused by all the pathogenic dermatophytes except for *Epidermophyton floccosum* and *Trichophyton concentricum*. In the United States, most cases are caused by *Trichophyton tonsurans*, which replaced *Microsporum audouinii* as the most common pathogen. Pet exposure is associated with tinea capitis caused by *Microsporum canis*.

Tinea capitis occurs mainly in children, although it may be seen at all ages. Boys have tinea capitis more frequently than girls; however, in epidemics caused by *T. tonsurans*, both genders are often affected equally. African American children have a higher incidence of *T. tonsurans* infections than Anglo Americans. The infection is also common among Latin American children.

*Trichophyton tonsurans* produces black dot ringworm, as well as subtle, seborrheic-like scaling and inflammatory kerion. Black dot tinea may also be caused by *Trichophyton violaceum*, an organism rarely seen in the United States. Both of these organisms produce chains of large spores within the hair shaft (large-spore endothrix) (Fig. 15-1). They do not produce fluorescence with Wood's light.

The *Microsporum canis* complex includes a group of organisms that produce small spores visible on the outside of the hair shaft (small-spore ectothrix). These fungi fluoresce under Wood's light examination. The *M. canis* complex includes *M. canis*, *M. canis distortum*, *Microsporum ferrugineum*, and *M. audouinii*. *M. canis* infections begin as scaly, erythematous, papular eruptions with loose and broken-off hairs. The lesions typically become highly inflammatory, although *M. audouinii*

is less prone to produce inflammatory lesions. Deep, tender, boggy plaques exuding pus are known as kerion celsii (Fig. 15-2). Kerion may be followed by scarring and permanent alopecia in the areas of inflammation and suppuration. Systemic corticosteroids for a short period, along with appropriate antifungal therapy, will greatly diminish the inflammatory response and reduce the risk of scarring, and this therapy should be considered in the patient with highly inflammatory lesions.

Asymptomatic carriers of *T. tonsurans* are common and represent a source of infection for classmates and siblings. Numerous studies have shown that 5–15% of urban children in Western countries have positive scalp dermatophyte cultures. In one study, 60% of children with a positive scalp culture were asymptomatic. All these children were African American.

The prevalence of dermatophytes varies throughout the world. Where animal herding is an important part of the economy, zoonotic fungi account for a significant proportion of cases of tinea. In Asia, organisms vary significantly by region. In a study of 204 Iraqi schoolchildren with tinea capitis, *Trichophyton verrucosum* was the most common organism. Both *T. rubrum* and *T. mentagrophytes* var. *mentagrophytes* were more common than *T. tonsurans*. In south-central Asia, *T. violaceum* is the most common dermatophytic species isolated, with *M. audouinii* a close second. Other common organisms include *Trichophyton schoenleinii*, *T. tonsurans*, *Microsporum gypseum*, *T. verrucosum*, and *T. mentagrophytes*. In East Asia, *T. violaceum* and *M. ferrugineum* are important pathogens. In Europe, African and Caribbean immigrants account for a large proportion of new patients with tinea capitis. Important pathogens include *T. tonsurans*, *M. audouinii* var. *langeronii*, *Trichophyton soudanense*, and *T. violaceum*. *Trichophyton megninii* is a rare cause of tinea capitis largely restricted to southwestern Europe. In Africa, large-scale epidemics are associated with *T. soudanense*, *T. violaceum*, *T. schoenleinii*, and *Microsporum* spp. In Australia, the predominantly white population experiences infections, mostly with *M. canis*, but *T. tonsurans* is now equal in prevalence in some areas of the continent. Recent immigrants have a high incidence of tinea capitis with organisms common in their regions of origin. Among African and Arab immigrants, *T. soudanense*, *T. violaceum*, and *M. audouinii* are particularly common.

### Favus

Favus, which is extremely rare in the United States, appears chiefly on the scalp but may affect the glabrous skin and nails.

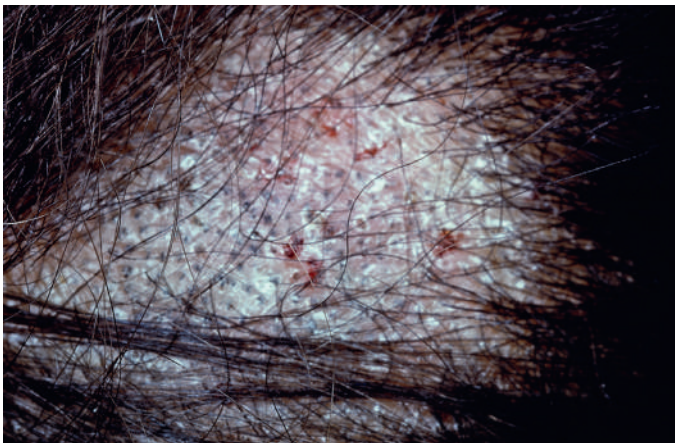


Fig. 15-1 Black dot ringworm.

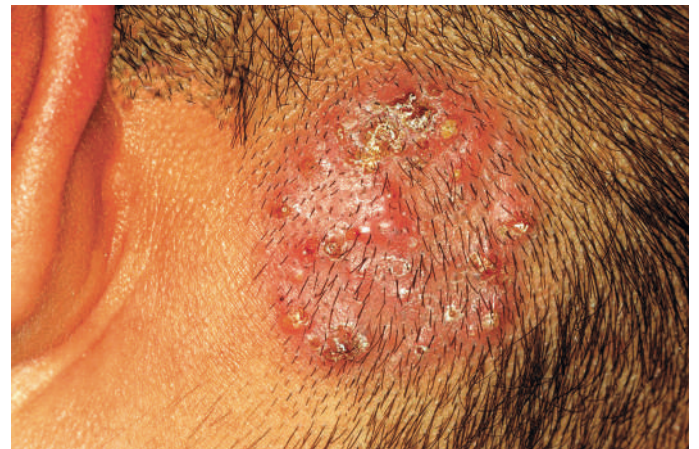

Fig. 15-2 Kerion.



On the scalp, concave sulfur-yellow crusts form around loose, wiry hairs. Atrophic scarring ensues, leaving a smooth, glossy, thin, paper-white patch. On the glabrous skin, the lesions are pinhead to 2 cm in diameter with cup-shaped crusts called scutulae, usually pierced by a hair as on the scalp. The scutulae have a distinctive mousy odor. When the nails are affected, they become brittle, irregularly thickened, and crusted under the free margins.

Favus among the Bantus in South Africa is called, in Afrikaans, witkop (whitehead). It is also prevalent in the Middle East, southeastern Europe, and the countries bordering the Mediterranean Sea.

## Pathogenesis and natural history

The incubation period of anthropophilic tinea capitis lasts 2–4 days, although the period is highly variable, and asymptomatic carriers are common. The hyphae grow downward into the follicle, on the hair's surface, and the intrafollicular hyphae break up into chains of spores. There is a period of spread (4 days to 4 months) during which the lesions enlarge and new lesions appear. At about 3 weeks, hairs break off a few millimeters above the skin surface. Within the hair, hyphae descend to the upper limit of the keratogenous zone and here form Adamson "fringe" on about the 12th day. No new lesions develop during the refractory period (4 months to several years). The clinical appearance is constant, with the host and parasite at equilibrium. This is followed by a period of involution in which the formation of spores gradually diminishes. Zoonotic fungal infections often are more highly inflammatory but undergo similar phases of evolution.

## Diagnosis

### Wood's light

Ultraviolet (UV) light of 365-nm wavelength is obtained by passing the beam through a Wood's filter composed of nickel oxide-containing glass. This apparatus, commonly known as the Wood's light, is used to demonstrate fungal fluorescence. Fluorescent-positive infections are caused by *M. audouinii*, *M. canis*, *M. ferrugineum*, *M. distortum*, and *T. schoenleinii*. In a darkroom, the skin under this light fluoresces faintly blue, and dandruff usually is bright blue-white. Infected hair fluoresces bright green or yellow-green. The fluorescent substance is a pteridine. Large-spore endothrix organisms (e.g., *T. tonsurans*, *T. violaceum*) and *T. verrucosum* (a cause of large-spore ectothrix) do not fluoresce.

### Laboratory examination

For demonstration of the fungus in a highly inflammatory plaque, two or three loose hairs are carefully removed with epilating forceps from the suspected areas. If fluorescence occurs, it is important to choose these hairs. Bear in mind that hairs infected with *T. tonsurans* do not fluoresce. In black dot ringworm or in patients with seborrheic scale, small broken fragments of infected hair will adhere to a moist gauze pad rubbed across the scalp. The hairs are placed on a slide and covered with a drop of a 10–20% potassium hydroxide (KOH) solution. A coverslip is then applied, and the specimen is warmed until the hairs are macerated. Dimethyl sulfoxide (DMSO) can be added to the KOH solution in concentrations of up to 40%. This additive allows for rapid clearing of keratin without heating. Once the hairs have softened, they are compressed through the coverslip and examined first with a

low-power objective and then with a high-power objective for detail. The patterns of endothrix and ectothrix involvement described earlier, together with local prevalence data, allow for identification of the organism.

Exact identification of the causative fungus is generally determined by culture, although molecular sequencing offers a more rapid alternative. For culture, several infected hairs are planted on Sabouraud dextrose agar, Sabouraud agar with chloramphenicol, Mycosel agar, or dermatophyte test medium (DTM). Cultures are best collected by rubbing the lesion vigorously with a moistened cotton swab or gauze pad, then streaking the cotton over the agar surface. On the first three media, a distinctive growth appears within 1–2 weeks. Most frequently, the diagnosis is made by the gross appearance of the culture growth, together with the microscopic appearance. With *Trichophyton* spp., growth on different nutrient agars is often required to identify the organisms beyond genus. DTM not only contains antibiotics to reduce growth of contaminants, but also contains a colored pH indicator to denote the alkali-producing dermatophytes. A few nonpathogenic saprophytes will also produce alkalization, and in the occasional case of onychomycosis of toenails caused by airborne molds, a culture medium containing an antibiotic may inhibit growth of the true pathogen.

### *Trichophyton tonsurans*

*Trichophyton tonsurans* grows slowly in culture to produce a granular or powdery, yellow to red, brown, or buff colony. Crater formation with radial grooves may be produced. Swollen microconidia may be seen regularly. Diagnosis is confirmed by cultures growing poorly or not at all without thiamine.

### *Trichophyton mentagrophytes*

The *T. mentagrophytes* colony is velvety, granular, or fluffy. It may be flat or furrowed, light buff, white, or sometimes pink. The back of the culture can vary from buff to dark red. Round microconidia borne laterally and in clusters confirm the diagnosis within 2 weeks. Spiral hyphae are sometimes prominent.

### *Trichophyton verrucosum*

Growth is slow and cannot be observed well for at least 3 weeks. The *T. verrucosum* colony is compact, glassy, velvety, heaped or furrowed, and usually white, but may be yellow or gray. The colony may crack the agar. Chlamydospores (round swellings along the hyphal structure) are present in early cultures, and microconidia may be seen.

### *Microsporum audouinii*

Culture of *M. audouinii* typically shows a slowly growing, matted, velvety, light-brown colony, the back of which is reddish brown to orange. The colony edge is generally striate rather than smooth. Microscopically, a few large, multiseptate macroconidia may be seen. Microconidia in a lateral position on the hyphae are clavate. Racquet mycelia, terminal chlamydospores, and pectinate hyphae are sometimes seen.

### *Microsporum canis*

The *M. canis* culture grossly shows profuse, cottony, aerial mycelia that are distinctly striate at the periphery, while sometimes tending to become powdery in the center. The color is buff to light brown. The back of the colony is lemon to orange-yellow. There are numerous spindle-shaped, thick-walled, echinulate macroconidia. Clavate microconidia may be found, along with chlamydospores and pectinate bodies.

## Differential diagnosis

Tinea capitis must be differentiated clinically from chronic staphylococcal folliculitis, pediculosis capitis, psoriasis, seborrheic dermatitis, secondary syphilis, trichotillomania, alopecia areata, lupus erythematosus (LE), lichen planus, lichen simplex chronicus, and various inflammatory follicular conditions. The distinctive clinical features of tinea capitis are broken-off stumps of hairs, often in rounded patches in which there are crusts or pustules and few hairs. The broken-off hairs are loose and when examined are found to be surrounded by, or to contain, the fungus. Diffuse seborrheic scaling with hair loss is a common presentation of *T. tonsurans* infections.

In alopecia areata, the affected patches are bald, and the skin is smooth and shiny without signs of inflammation or scaling. Stumps of broken-off hairs are infrequently found, and no fungi are demonstrable. In seborrheic dermatitis, the involved areas are covered by fine, dry, or greasy scales. Hair may be lost, but the hairs are not broken. Atopic dermatitis is rarely associated with localized scalp involvement, and clinical examination frequently reveals more typical generalized findings. In psoriasis, well-demarcated, sometimes diffuse, areas of erythema and white or silver scaling are noted. Lichen simplex chronicus is frequently localized to the inferior margin of the occipital scalp. In trichotillomania, as in alopecia areata, inflammation and scaling are absent. Circumscribed lesions are very rare. Serologic testing, scalp biopsies, and immunofluorescent studies may be indicated if the alopecia of secondary syphilis or lupus erythematosus is a serious consideration. It should be noted that adult patients with LE are susceptible to tinea capitis, which may be photosensitive and difficult to distinguish from LE plaques without biopsy and KOH examinations.

## Treatment

Numerous clinical trials have demonstrated the effectiveness of itraconazole, terbinafine, and fluconazole. Despite these studies, griseofulvin remains the most frequently used antifungal agent in children. It has a long safety record, and pediatricians and family practitioners are generally comfortable with griseofulvin. A meta-analysis of published studies shows mean efficacy for griseofulvin treatment of about 68% for *Trichophyton* spp. and 88% for *Microsporum*. For the ultramicrosized form, doses start at 10 mg/kg/day. The tablets can be crushed and given with ice cream. Grifulvin V oral suspension is less readily absorbed. The dose is 20 mg/kg/day. Treatment should continue for 2–4 months, or for at least 2 weeks after negative laboratory examinations are obtained. Doses much higher than those reflected in drug labeling are often needed. For *Trichophyton* infections, terbinafine is usually effective in doses of 3–6 mg/kg/day for 1–4 weeks. Alternate dosing schedules for terbinafine include one 250-mg tablet for patients over 40 kg, 125 mg ( $\frac{1}{2}$  tablet) for those 20–40 kg, and 62.5 mg ( $\frac{1}{4}$  tablet) for those under 20 kg. *Microsporum* infections require higher doses and longer courses of therapy with terbinafine. Itraconazole has been shown to be effective in doses of 5 mg/kg/day for 2–3 weeks, and fluconazole at doses of 6 mg/kg/day for 2–3 weeks, performing almost as well as griseofulvin. Reports of heart failure with itraconazole have limited its use.

Selenium sulfide shampoo or ketoconazole shampoo left on the scalp for 5 min three times a week can be used as adjunctive therapy to oral antifungal agents to reduce the shedding of fungal spores. Combs, brushes, and hats should be cleaned carefully, and natural bristle brushes must be discarded.

## Prognosis

Recurrence is uncommon when adequate amounts of griseofulvin, fluconazole, or terbinafine have been taken, although exposure to infected persons, asymptomatic carriers, or contaminated fomites will increase the relapse rate. Without medication, there is spontaneous clearing at about age 15 years, except with *T. tonsurans*, which often persists into adult life.

## DERMATOPHYTIDS

In cases of inflammatory tinea capitis, widespread “id” eruptions may appear concomitantly on the trunk and extremities. These are vesicular, lichenoid, papulosquamous, or pustular and represent a systemic reaction to fungal antigens. Although the eruptions are usually refractory to topical corticosteroids, they typically clear rapidly after treatment of the fungal infection.

The most common type of id reaction is seen on the hands and sides of the fingers when there is an acute fungus infection of the feet. These lesions are mostly vesicular and are extremely pruritic and even tender. Secondary bacterial infection may occur; however, fungus is not demonstrable in a true dermatophytid. The onset can be accompanied by fever, anorexia, generalized adenopathy, spleen enlargement, and leukocytosis. Dermatophytid reactions from inflammatory tinea capitis may occasionally present as widespread eruption, usually follicular, lichenoid, or papulosquamous. Rarely, the eruption may be morbilliform or scarlatiniform. The erysipelas-like dermatophytid is most frequently seen on the shin, where it appears as an elevated, sharply defined, erysipelas-like plaque about the size of the hand, usually with toe web tinea on the same side. This form of id reaction responds to systemic corticosteroids and treatment of the tinea.

The histologic picture is characterized by spongiotic vesicles and a superficial, perivascular, predominantly lymphohistiocytic infiltrate. Eosinophils may be present. Diagnosis of a dermatophytid reaction depends on the demonstration of a fungus at some site remote from the suspect lesions of the dermatophytid, the absence of fungus in the id lesion, and involution of the lesion as the fungal infection subsides.

## TINEA BARBAE

Ringworm of the beard, also known as tinea sycosis and barber’s itch, is not a common disease. It occurs chiefly among those in agricultural pursuits, especially those in contact with farm animals. The involvement is mostly one sided on the neck or face. Two clinical types are distinguished: deep, nodular, suppurative lesions and superficial, crusted, partially bald patches with folliculitis (Fig. 15-3).

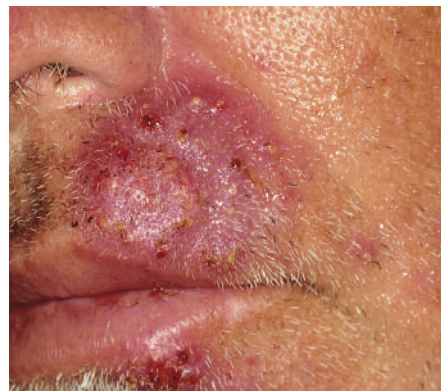

Fig. 15-3 Tinea barbae.



The deep type develops slowly and produces nodular thickenings and kerionlike swellings, usually caused by *T. mentagrophytes* or *T. verrucosum*. As a rule, the swellings are confluent and form diffuse, boggy infiltrations with abscesses. The overlying skin is inflamed, the hairs are loose or absent, and pus may be expressed through the remaining follicular openings. Generally, the lesions are limited to one part of the face or neck in men. The superficial crusted type is characterized by a less inflammatory pustular folliculitis and may be associated with *T. violaceum* or *T. rubrum*. The affected hairs can sometimes be easily extracted. Rarely, *Epidermophyton floccosum* may cause widespread verrucous lesions known as verrucous epidermophytosis.

## Diagnosis

The clinical diagnosis of tinea barbae is confirmed by the microscopic mounts of extracted hairs or a biopsy specimen. Culture can be performed on extracted hairs or tissue homogenates of biopsy specimens.

## Differential diagnosis

The differential diagnosis includes staphylococcal folliculitis (sycosis vulgaris) and herpetic infections. Tinea barbae differs from sycosis vulgaris by usually sparing the upper lip and by often being unilateral. In sycosis vulgaris, the lesions are pustules and papules, pierced in the center by a hair, which is loose and easily extracted after suppuration has occurred. Herpetic infections usually demonstrate umbilicated vesicles. Tzanck preparations have a low diagnostic yield, but viral culture or direct fluorescent antibody is virtually always positive.

## Treatment

As in tinea capitis, oral antifungal agents are required to cure tinea barbae. Topical agents are only helpful as adjunctive therapy. Oral agents are used in the same doses and for the same durations as in tinea capitis.

## TINEA FACIEI

Fungal infection of the face is frequently misdiagnosed (Fig. 15-4). Typical annular rings are usually lacking, and the lesions

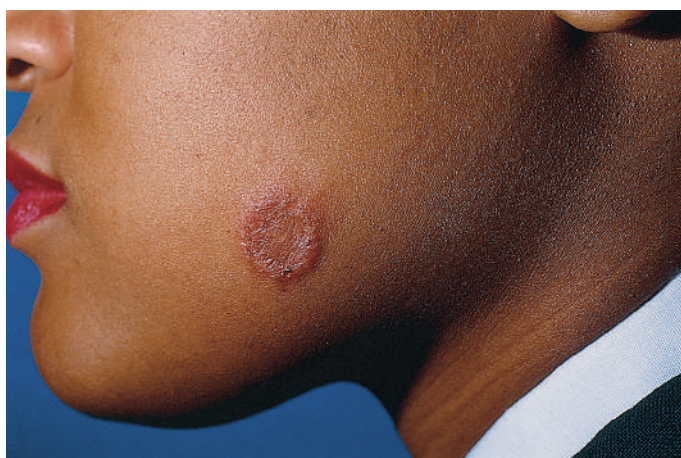

Fig. 15-4 Tinea faciei.

are exquisitely photosensitive. Frequently, a misdiagnosis of LE is made. Biopsies for direct immunofluorescence often demonstrate some reactants on sun-exposed skin, adding to the possible diagnostic confusion. Erythematous, slightly scaling, indistinct borders may be present at the periphery of the lesions and are the best location for KOH examination. If topical corticosteroids have been used, fungal folliculitis is a frequent finding. A biopsy may be required to establish the diagnosis. A high index of suspicion is required, because fungal hyphae may be few in number or confined to hair follicles. The inflammatory pattern may be psoriasiform spongiotic or vacuolar interface. The latter pattern has the potential to perpetuate confusion with LE.

Usually, the infection is caused by *T. rubrum*, *T. mentagrophytes*, or *M. canis*. Tinea faciei caused by *Microsporum nanum* has been described in hog farmers. If fungal folliculitis is present, oral medication is required. If no folliculitis is present, the infection generally responds well to topical therapy. Oral agents are appropriate for widespread infections.

## TINEA CORPORIS (TINEA CIRCINATA)

Tinea corporis includes all superficial dermatophyte infections of the skin other than those involving the scalp, beard, face, hands, feet, and groin. This form of ringworm is characterized by one or more circular, sharply circumscribed, slightly erythematous, dry, scaly, usually hypopigmented patches. An advancing scaling edge is usually prominent (Fig. 15-5). Progressive central clearing produces annular outlines that give them the name "ringworm." Lesions may widen to form rings many centimeters in diameter. In some cases, concentric circles or polycyclic lesions form, making intricate patterns. Widespread tinea corporis may be the presenting sign of acquired immunodeficiency syndrome (AIDS) or may be related to the use of a topical corticosteroid or calcineurin inhibitor.

In the United States, *T. rubrum*, *M. canis*, and *T. mentagrophytes* are common causes, although infection can be caused by any of the dermatophytes. Multiple small lesions are usually caused by exposure to a pet with *M. canis*. Other zoonotic fungi, such as granular zoophilic *T. mentagrophytes* related to Southeast Asian bamboo rats, can cause widespread epidemics of highly inflammatory tinea corporis.

Tinea gladiatorum is a common problem for wrestlers. In Pennsylvania, during the 1998-1999 wrestling season, about 85% of responding teams had at least one wrestler diagnosed with ringworm, despite that 97% used preventive practices. One third of these teams reported that a wrestler missed a

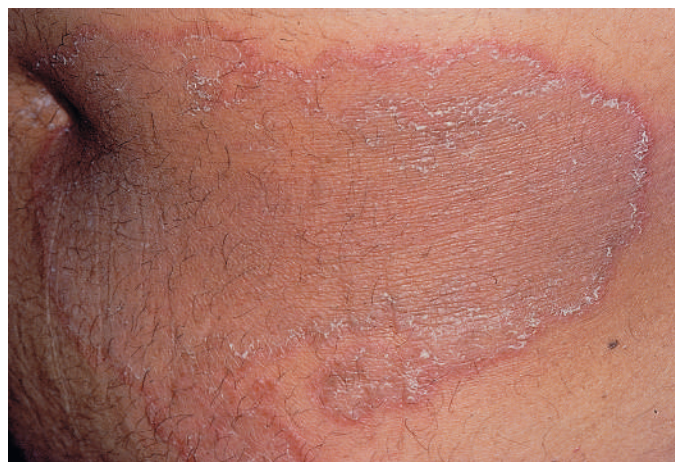

Fig. 15-5 Tinea corporis.

match because of the infection. Opponents, equipment, and mats represent potential sources of infection.

## Diagnosis

The diagnosis of tinea corporis is relatively easy to make by finding the fungus under the microscope in skin scrapings. In addition, skin scrapings can be cultured on a suitable medium. Growth of the fungus on culture medium is apparent within 1 week or 2 weeks at most, and in most cases is identifiable to the genus level by the gross and microscopic appearance of the culture. (Biopsy of a chronic refractory dermatosis often reveals tinea incognito.)

Other diseases that may closely resemble tinea corporis are pityriasis rosea, impetigo, nummular dermatitis, secondary and tertiary syphilids, seborrheic dermatitis, and psoriasis. These are distinguished by KOH examination and culture.

## Treatment

Localized disease without fungal folliculitis may be treated with topical therapy. Sulconazole (Exelderm), oxiconazole (Oxistat), miconazole (Monistat cream or lotion, or Micatin cream), clotrimazole (Lotrimin or Mycelex cream), econazole (Spectazole), naftifine (Naftin), ketoconazole (Nizoral), ciclopirox olamine (Loprox), terbinafine (Lamisil), efinaconazole, and butenafine (Mentax) are currently available and effective. Most treatment times are between 2 and 4 weeks with twice-daily use. Econazole, ketoconazole, oxiconazole, and terbinafine may be used once a day. With terbinafine, the course can be shortened to 1 week. Combination products with a potent corticosteroid such as clotrimazole/betamethasone frequently produce widespread tinea and fungal folliculitis. Their use should be discouraged.

Extensive disease or fungal folliculitis requires systemic antifungal treatment. When tinea corporis is caused by *T. tonsurans*, *T. mentagrophytes*, or *T. rubrum*, griseofulvin, terbinafine, itraconazole, and fluconazole are all effective. Shorter courses are possible with newer antifungals. Terbinafine therapy for *M. canis* typically requires higher doses and longer courses of therapy.

The ultramicronized form of griseofulvin may be effective in doses of 500–1000 mg/day for 4–6 weeks. Approximately 10% of patients will experience nausea or headache with griseofulvin. These symptoms typically respond to a temporary reduction in dosage. Absorption of griseofulvin is improved when given with whole milk or ice cream. Effective blood levels in children occur at doses of 10–20 mg/kg/day, although higher doses are often needed. Terbinafine, 250 mg/day for 1–2 weeks; itraconazole, 200 mg/day for 1 week; and fluconazole, 150 mg once weekly for 4 weeks, have been effective in adults.

## Other forms of tinea corporis

### Fungal folliculitis (Majocchi granuloma) and tinea incognito

Occasionally, a deep, pustular type of tinea circinata resembling a carbuncle or kerion is observed on the glabrous skin (Fig. 15-6). This type of lesion is a fungal folliculitis caused most often by *T. rubrum* or *T. mentagrophytes* infecting hairs at the site of involvement. It presents as a circumscribed, annular, raised, crusty, and boggy granuloma in which the follicles are

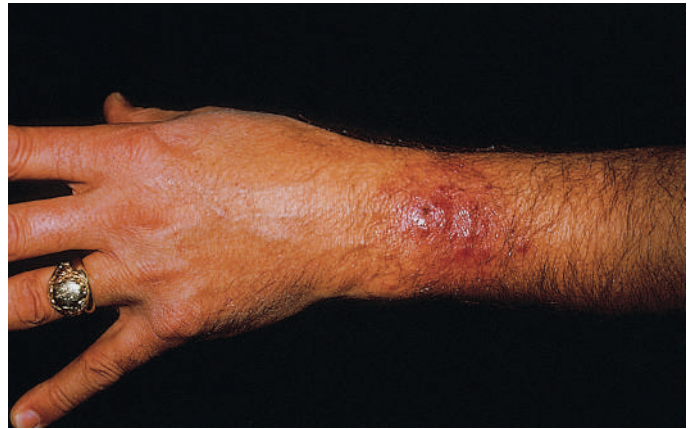

Fig. 15-6 Majocchi granuloma.

distended with viscid purulent material. These occur most frequently on the shins or wrists. The lesions are often seen in areas of occlusion or shaving, or when a topical corticosteroid has been used. In immunosuppressed patients, the lesions may be deep and nodular. Often, patients have been treated with a “shotgun approach,” using both topical corticosteroids and antifungal agents. If a topical antifungal has been used recently, KOH examination and culture may be negative. A biopsy may be required to establish the diagnosis. Oral therapy is necessary to cure the lesions.

Tinea incognito is a term applied to atypical clinical lesions of tinea, usually produced by treatment with a topical corticosteroid or occasionally a calcineurin inhibitor. The lesions are often widespread and may lack an advancing, raised, scaly border. The diagnosis may be established by KOH examination or biopsy.

### Tinea imbricata (Tokelau)

Tinea imbricata is a superficial fungal infection limited to southwest Polynesia, Melanesia, Southeast Asia, India, and Central America. It is characterized by concentric rings of scales forming extensive patches with polycyclic borders. Erythema is typically minimal. The eruption begins with one or several small, rounded macules on the trunk and arms. The small macular patch splits in the center and forms large, flaky scales attached at the periphery. As the resultant ring spreads peripherally, another brownish macule appears in the center and undergoes the process of splitting and peripheral extension. This cycle is repeated over and over again. When fully developed, the eruption is characterized by concentrically arranged rings or parallel, undulating lines of scales overlapping each other like shingles on a roof (*imbrex* means “shingle”).

The causative fungus is *Trichophyton concentricum*, although a similar pattern may be produced by *T. mentagrophytes* and *T. tonsurans*. Microscopically, the scrapings show interlacing, septate, mycelial filaments that branch dichotomously. Polyhedral spores are also present. Griseofulvin has been used, but the recurrence rate is high. In one study, terbinafine, 250 mg/day for 4 weeks, was effective in all of 43 patients with tinea imbricata. Itraconazole at a dose of 100 mg/day failed in 4 of 40 patients, but this may reflect the dose used in the study.

### Tinea cruris

Tinea cruris, also known as jock itch and crotch itch, occurs most frequently in men on the upper and inner surfaces of the thighs, especially during the summer when the humidity is high. It begins as a small, erythematous, and scaling or



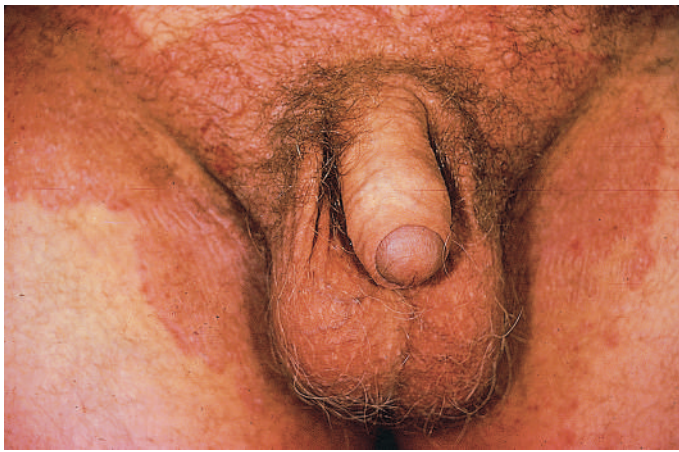

Fig. 15-7 Tinea cruris.

vesicular and crusted patch that spreads peripherally and partly clears in the center, so that the patch is characterized chiefly by its curved, well-defined border, particularly on its lower edge (Fig. 15-7). The border may have vesicles, pustules, or papules. It may extend downward on the thighs and backward on the perineum or about the anus. The scrotum is rarely involved.

### Etiology and differential diagnosis

Ringworm of the groin is usually caused by *T. rubrum*, *T. mentagrophytes*, or *E. floccosum*. Infection with *Candida albicans* may closely mimic tinea cruris, but is usually moister, more inflammatory, and associated with satellite macules. *Candida* often produces collarette scales and satellite pustules.

The crural region is also a common site for erythrasma, seborrheic dermatitis, pemphigus vegetans, and intertriginous psoriasis. Erythrasma often has a copper color and is diagnosed by Wood's light examination, which produces coral-red fluorescence. Seborrheic dermatitis generally involves the central chest and axillae in addition to the groin. Pemphigus vegetans produces macerated and eroded lesions. Diagnosis of tinea cruris is established by biopsy and immunofluorescence. Inverse psoriasis may be associated with collarette scales or with serpiginous arrays of pustules at the border of inflammatory lesions. When more typical lesions of psoriasis are lacking, a biopsy may be required to establish the diagnosis.

### Treatment

The reduction of perspiration and enhancement of evaporation from the crural area are important prophylactic measures. The area should be kept as dry as possible by the wearing of loose underclothing and trousers. Plain talcum powder or antifungal powders are helpful. Specific topical and oral treatment for tinea cruris is the same as that described earlier for tinea corporis.

## TINEA OF HANDS AND FEET

Dermatophytosis of the feet, long popularly called athlete's foot, is by far the most common fungal disease. *T. rubrum* causes the majority of infections, and there may be an autosomal dominant predisposition to this form of infection. *T. rubrum* typically produces a relatively noninflammatory type of dermatophytosis characterized by a dull erythema and pronounced silvery scaling that may involve the entire sole and sides of the foot, giving a moccasin or sandal appearance. One hand may be involved. The eruption may also be limited to a small patch adjacent to a fungus-infected toenail or to a patch

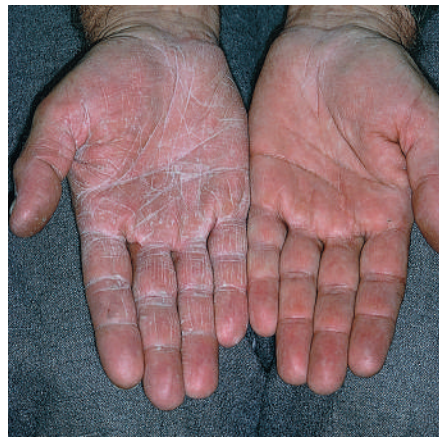

Fig. 15-8 One hand of "two foot, one hand" fungal infection; both feet were infected.

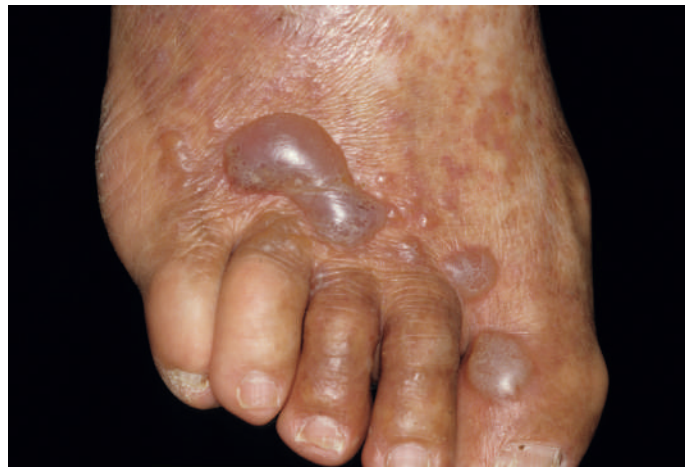

Fig. 15-9 Bullous tinea.

between or under the toes. In some patients, an extensive patchy, scaly eruption covers most of the trunk, buttocks, and extremities. Rarely, there is a patchy hyperkeratosis resembling verrucous epidermal nevus.

Generally, tinea infection of the hands is of the dry, scaly, and erythematous type suggestive of *T. rubrum* infection. Other areas are frequently affected at the same time, especially the combination of both feet and one hand (Fig. 15-8). Tinea pedis caused by anthropophilic *T. mentagrophytes* (*interdigitale*) presents with three distinct appearances: (1) multilocular bullae involving the thin skin of the plantar arch and along the sides of the feet and heel, (2) erythema and desquamation between the toes, and (3) white superficial onychomycosis. In the human immunodeficiency virus (HIV)-positive population, this latter syndrome is usually caused by *T. rubrum*. Interdigital tinea must be distinguished from simple maceration caused by a closed web space, which does not respond to antifungal therapy. Interdigital tinea must also be distinguished from gram-negative toe web infection. Diabetic patients develop interdigital fungal infections at a younger age than patients without diabetes.

*Trichophyton mentagrophytes* often produces acutely inflammatory multilocular bullae (Fig. 15-9). The burning and itching that accompany the formation of the vesicles may cause great discomfort, which is relieved by opening the tense vesicles. They contain a tenacious, clear, straw-colored fluid. Extensive or acute eruptions on the soles may be incapacitating. The fissures between the toes, as well as the vesicles, may become secondarily infected with pyogenic cocci, which may lead to

recurrent attacks of lymphangitis and inguinal adenitis. Gram-negative toe web infections may also supervene. Hyperhidrosis is frequently present in this type of dermatophytosis. The sweat between the toes and on the soles has a high pH, and damp keratin is a good culture medium for the fungi.

Dermatophytid of the hands may be associated with inflammatory tinea of the feet and begins with the appearance of groups of minute, clear vesicles on the palms and fingers. The itching may be intense. As a rule, both hands are involved, and the eruption tends to be symmetric; in some cases, however, only one hand is affected. The dorsa and sides of the feet may also be affected.

## Diagnosis

Demonstration of the fungus by microscopic examination of the scrapings taken from the involved site establishes the diagnosis. Copious dry scale from the instep, heel, and sides of the foot can be gathered by scraping with the edge of a glass microscope slide. Bullae should be unroofed, and either the entire roof is mounted intact or scrapings are made from the underside of the roof. A drop of a 10–20% KOH solution is added to the material on the glass slide. A coverslip is placed over the specimen and pressed down firmly. Gentle heat is applied until the scales are thoroughly macerated. The addition of 20–40% DMSO speeds clearing of keratin without the need for heating. A staining method using 100 mg of chlorazol black E dye in 10 mL of DMSO and adding it to a 5% aqueous solution of KOH can be helpful. Toluidine blue 0.1% can also be used on thin specimens, but contains no clearing agent to dissolve keratin.

The mycelia may be seen under low-power microscopy, but better observation of both hyphae and spores is obtained by the 10× objective with the condenser cranked down or the light aperture closed by two-thirds (Fig. 15-10). The lines of juncture of normal epidermal cells dissolve into a branching network that may easily be mistaken for fungus structures (“mosaic false hyphae”). This is the most common artifact misinterpreted as a positive KOH examination. Cotton and synthetic fibers from socks may also mimic hyphae.

Material may also be placed on Sabouraud dextrose agar, Sabouraud agar with chloramphenicol, Mycosel agar, or DTM. The last three agars inhibit growth of bacterial or saprophytic contaminants. The last two may inhibit some pathogenic non-dermatophytes. The alkaline metabolites produced by growth of dermatophytes change the color of the pH indicator in DTM medium from yellow to red.

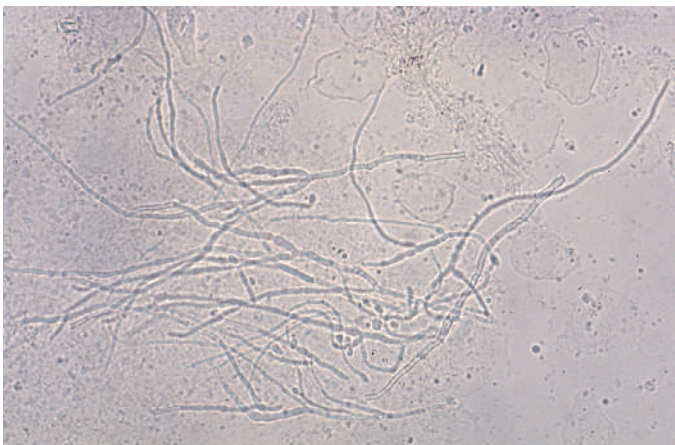


Fig. 15-10 Positive KOH examination.

## Prophylaxis

Hyperhidrosis is a predisposing factor for tinea infections. Because the disease often starts on the feet, the patient should be advised to dry the toes thoroughly after bathing. Cold water laundering does not inactivate fungal elements in socks, which may serve as a source of recolonization. Dryness is essential to reduce the incidence of symptomatic reinfection.

The use of a good antiseptic powder on the feet after bathing, particularly between the toes, is strongly advised for susceptible persons. Tolnaftate powder (Tinactin) or Zeasorb medicated powder is an excellent dusting powder for the feet. Plain talc, cornstarch, or rice powder may be dusted into socks and shoes to keep the feet dry. Periodic use of a topical antifungal agent may be required, especially when hot occlusive footwear is worn.

## Treatment

Clotrimazole, miconazole, sulconazole, oxiconazole, ciclopirox, econazole, ketoconazole, naftifine, terbinafine, flutrimazol, bifonazole, efinaconazole, and butenafine are effective topical antifungal agents. When there is significant maceration between the toes, the toes may be separated by foam or cotton inserts in the evening. Aluminum chloride 10% solution or aluminum acetate, 1 part to 20 parts of water, can be beneficial. Interdigital tinea can also be treated with antifungal-impregnated socks. Topical antibiotic ointments, such as gentamicin (Garamycin), that are effective against gram-negative organisms are helpful additions in some moist interdigital lesions. In the ulcerative type of gram-negative toe web infections, systemic antibiotic therapy is necessary (see Chapter 14). Keratolytic agents containing salicylic acid, resorcinol, lactic acid, and urea may be useful in some cases, although all may lead to maceration if occluded.

Treatment of fungal infection of the skin of the feet and hands with griseofulvin, 500–1000 mg/day, can be effective. Dosage for children is 10–20 mg/kg/day. The period of therapy depends on the response of the lesions. Repeated KOH scrapings and cultures should be negative. Much shorter courses are possible with newer antifungal agents. Recommended adult dosing for terbinafine is 250 mg/day for 1–2 weeks; for itraconazole, 200 mg twice daily for 1 week; and for fluconazole, 150 mg once weekly for 4 weeks. Abbreviated schedules and intermittent dosing with other agents may be possible but require further study. In one small study, itraconazole, 100 mg twice daily, was given immediately after meals on 2 consecutive days. The regimen produced good to excellent responses in all patients within 14 days.

## Onychomycosis (tinea unguium)

Onychomycosis is defined as the infection of the nail plate by fungus and represents up to 30% of diagnosed superficial fungal infections. *T. rubrum* accounts for most cases, but many fungi may be causative. Other etiologic agents include *E. floccosum* and various species of *Microsporum* and *Trichophyton* fungi. It may also be caused by yeasts and nondermatophytic molds.

The four classic types of onychomycosis are as follows:

1. Distal subungual onychomycosis primarily involves the distal nailbed and the hyponychium, with secondary involvement of the underside of the nail plate of fingernails and toenails (Fig. 15-11). It is usually caused by *T. rubrum*.



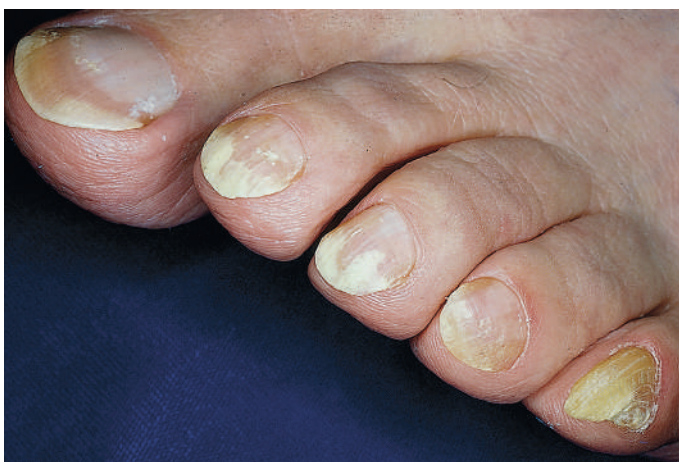

Fig. 15-11 Distal subungual onychomycosis and tinea pedis.

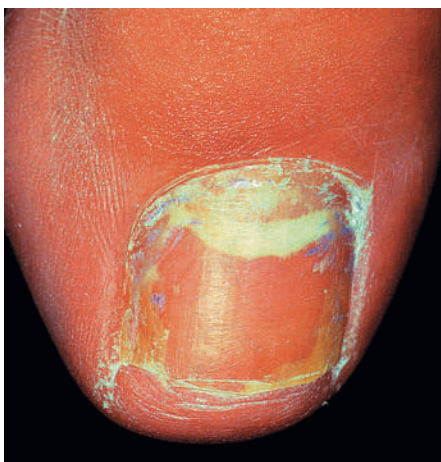

Fig. 15-12 White proximal subungual onychomycosis.

2. White superficial onychomycosis (leukonychia trichophytica) is an invasion of the toenail plate on the surface of the nail. It is produced by *T. mentagrophytes*, *Cephalosporium*, *Aspergillus*, and *Fusarium oxysporum* fungi. In the HIV-positive population, it is typically caused by *T. rubrum*.
3. Proximal subungual onychomycosis involves the nail plate mainly from the proximal nailfold, producing a specific clinical picture (Fig. 15-12). It is produced by *T. rubrum* and *Trichophyton megninii* and may be an indication of HIV infection.
4. *Candida* onychomycosis produces destruction of the nail and massive nail bed hyperkeratosis. It is caused by *C. albicans* and is seen in patients with chronic mucocutaneous candidiasis.

Onychomycosis caused by *T. rubrum* usually starts at the distal corner of the nail and involves the junction of the nail and its bed. A yellowish discoloration occurs, which spreads proximally as a streak in the nail. Later, subungual hyperkeratosis becomes prominent and spreads until the entire nail is affected. Gradually, the entire nail becomes brittle and separated from its bed as a result of the piling up of subungual keratin. Fingernails and toenails present a similar appearance, and the skin of the soles is likely to be involved, with characteristic branny scaling and erythema.

Onychomycosis caused by *T. mentagrophytes* is usually superficial, and there is no paronychia inflammation. The infection generally begins with scaling of the nail under the overhanging cuticle and remains localized to a portion of

the nail. In time, however, the entire nail plate may be involved. White superficial onychomycosis is the name given to one type of superficial nail infection caused by this fungus in which small, chalky white spots appear on or in the nail plate. These are so superficial that they may be easily shaved off. *T. violaceum*, *T. schoenleinii*, and *T. tonsurans* occasionally invade the nails, as does *Trichosporon beigelii*.

*Scopulariopsis brevicaulis* has been infrequently isolated from onychomycosis. Infection usually begins at the lateral edge of the nail, burrows beneath the plate, and produces large quantities of cheesy debris. *Natrassia mangiferae* (*Hendersonula toruloides*) and *Scytalidium hyalinum* have been reported to cause onychomycosis, as well as a moccasin-type tinea pedis. In addition to the more common features of onychomycosis, such as nail plate thickening, opacification, and onycholysis, features of infection with these fungi include lateral nail invasion alone, paronychia, and transverse fracture of the proximal nail plate. When these agents are suspected, culture must be done with a medium that does not contain cycloheximide (found in Mycosel agar). Oral ketoconazole and griseofulvin are not effective in the treatment of these organisms.

The pathogen is heavily influenced by heredity, geography, and footwear. In the United States, most tinea pedis and onychomycosis are caused by *T. rubrum*. In a rural school in Mexico where most people wear nonocclusive leather sandals, *Trichosporon cutaneum*, *Candida* spp., and *T. mentagrophytes* accounted for most infections. *T. rubrum* was not isolated in any patient. Cutaneous *Scytalidium* infections are common in patients from the tropics, especially the West Indies and Africa. They usually carry the organism with them, even when they emigrate to more temperate climates.

## Diagnosis

The demonstration of fungus is made by microscopic examination or by culture. The submitted clippings or curettings must include dystrophic subungual debris. Samples obtained by a drilling technique may have a higher yield than those obtained by curettage. Immediate examination may be made if very thin shavings or curettings are taken from the diseased nail bed and examined with KOH solution with or without an added stain. Histologic examination, polymerase chain reaction (PCR), and calcofluor white microscopy and culture have also been used.

Histopathologic examination with periodic acid-Schiff (PAS) stain has been found to be 41–93% sensitive in various studies. It has proved more sensitive than either KOH or culture in several studies. In one study, in which histology was 85% sensitive, KOH dissolution and centrifugation combined with PAS was 57% sensitive, with calcofluor white fluorescent staining and chlorazol black E were each 53% sensitive. Immunofluorescent microscopy without calcofluor white is comparable to PAS staining, but high background eosin fluorescence can make the sections difficult to read. Culture on Sabouraud agar with chloramphenicol and cycloheximide (Mycosel) agar was 32% sensitive. Other studies have shown the sensitivity of culture to be 30–70%. Combining KOH and culture has yielded sensitivities in the range of 80–85%.

Both office and central laboratories can be used to isolate fungi, but false-negative results are common in both settings. In one study, office DTM culture was positive in 102 of 184 patients (55%), and the central laboratory detected the infection in 78 of 184 (42%). The two tests were in agreement (both positive or both negative) in 114 of 184 patients (62%). In a similar study, DTM cultures were positive in 51% (n = 345), and central laboratory cultures were positive in 44% (n = 297). The two cultures were in agreement in 68% of cases. Dermatophytes accounted for about 90% of the confirmed

infections in each study. PCR is emerging as an alternative method of detection.

Because no single method offers 100% sensitivity, a variety of methods are still in use. KOH has the advantage of being performed rapidly in the office. Histologic examination usually provides results within 24 h, whereas culture can take days to weeks. Identification of genus and species is only possible with culture or PCR.

## Differential diagnosis

Dystrophic nails can be produced by psoriasis, lichen planus, eczema, and contact dermatitis and may be clinically indistinguishable from fungal nails. Confirmatory tests to identify the fungus are mandatory to establish a diagnosis. Psoriasis may involve other nails with pitting, onycholysis, oil spots, and salmon patches or by heaped-up subungual keratinization. Typical features of psoriasis may be present on other areas of skin. Lichen planus may produce rough nails or pterygium formation and may involve the oral mucosa or skin. Eczema and contact dermatitis affect the adjacent nail-fold. Hyperkeratotic ("Norwegian") scabies can also produce dystrophic nails, but this is associated with generalized hyperkeratosis.

Onychomycosis among psoriasis patients is reported with varying prevalence but occurs in about 22%, compared with 13% for patients with other skin diseases. Onychomycosis occurs more frequently in men than in women with psoriasis.

## Treatment

Many patients with onychomycosis are not symptomatic and may not seek treatment. Patients with diabetes or peripheral neuropathy may be at higher risk for complications related to onychomycosis, and the benefits of treatment may be greater in this population. These factors, as well as cost, risk of recurrence, and spread to other family members should be considered as part of the decision to treat onychomycosis.

The topical management of onychomycosis has improved with the introduction of ciclopirox and amorolfine nail lacquers. These agents are modestly effective at moderate cost. A lacquer containing encencalin extract of *Ageratina pichinchensis*, efinaconazole, and topical bifonazole following urea ablation also appear promising. Most other topical agents are of minimal benefit, and no topical agent achieves the cure rates possible with oral therapy.

For disease involving fingernails, terbinafine is given in doses of 250 mg/day for 6–8 weeks. For toenails, the course of treatment is generally 12–16 weeks. Itraconazole is generally given as pulsed dosing, 200 mg twice daily for 1 week of each month, for 2 months when treating fingernails and for 3–4 months when treating toenails. Fluconazole, 150–300 mg once weekly for 6–12 months, appears to be effective. Albaconazole also appears promising. About 20% of patients will not respond to treatment. The presence of a dermatophytoma within the nail may be associated with a higher risk of failure. Dermatophytomas present as yellow streaks within the nail and may respond to unroofing and curettage. Recurrence rates may be lower with itraconazole than with terbinafine monotherapy, and combined therapy does not result in a lower rate of recurrence.

Several studies suggest that continuous therapy with terbinafine for 4 months is cost-effective compared with other possible agents and regimens. Most clinical trials have been industry sponsored, however, and little independent research is available for review. For onychomycosis in children, topical

treatment with ciclopirox lacquer may be more effective than in adults and may be worth a clinical trial. Terbinafine, itraconazole, and fluconazole have all been shown to be effective. Dosage depends on body weight, as previously indicated. Duration of treatment is the same as for adults.

Treatment with systemic antifungals is generally effective in onychomycosis caused by *Aspergillus* spp. *Scopulariopsis brevicaulis* and *Fusarium* spp. infection is difficult to eradicate, and treatment with both systemic antifungals and topical nail lacquers may be appropriate. Nail avulsion represents another option. *Candida* onychomycosis is always a sign of immunodepression. Systemic treatment with itraconazole or fluconazole is usually effective, but relapses are the rule. When treating *Candida* infections, combinations of topical and systemic treatment can be used for synergistic effect. The combination of topical amorolfine and oral itraconazole, which interferes with different steps of ergosterol synthesis, has been shown to exhibit substantial synergy in this setting. Combination treatment with topical amorolfine and two pulses of itraconazole may be as effective as three pulses of itraconazole, with lower cost.

The U.S. Food and Drug Administration (FDA) has issued a health advisory to announce serious risks associated with the use of itraconazole and terbinafine. The advisory states that both have been associated with serious liver problems resulting in liver failure, the need for transplantation, and death. There is a small but real risk of developing congestive heart failure associated with the use of itraconazole. Terbinafine has been associated with subacute cutaneous LE. Significant drug interactions may occur in patients taking itraconazole who are also treated with drugs metabolized by the CYP450 pathway. Interactions with terbinafine and the tricyclic antidepressant desipramine have been reported.

Itraconazole pulsed treatment has been shown to have a low incidence of liver function abnormalities (alanine transaminase [ALT], aspartate transaminase [AST], alkaline phosphatase, total bilirubin). Product labeling recommends liver function tests (LFTs) for patients receiving continuous itraconazole for periods exceeding 1 month. Monitoring is required for the pulsed regimen if the patient has a history of hepatic disease, has abnormal baseline LFTs, or development of signs or symptoms suggestive of liver dysfunction. Phenobarbital shows potential for the cytoprotection of hepatocytes to itraconazole-induced, but not fluconazole-induced, cytotoxicity in vitro, suggesting the possibility of regimens to reduce the risk of toxicity further.

Molds are sensitive to ozone gas, UV light, and visible light. *T. rubrum* in culture has been shown to be susceptible to UVC radiation, photodynamic therapy (PDT), psoralen with UVA (PUVA), and various forms of laser light. However, the mechanism of action and degree of effectiveness of these therapies require further study. For PDT with broad-band white light, the phthalocyanines and Photofrin displayed a fungistatic effect, whereas porphyrins caused photodynamic killing of the dermatophyte. 5,10,15-*Tris*(4-methylpyridinium)-20-phenyl-(21H,23H)-porphine trichloride and deuteroporphyrin monomethylester showed superior results in vitro. Further study of various methods of phototherapy is warranted.

**Barot BS, et al:** Drug delivery to the nail: therapeutic options and challenges for onychomycosis. *Crit Rev Ther Drug Carrier Syst* 2014; 31:459–494.

**Becker C, et al:** Lasers and photodynamic therapy in the treatment of onychomycosis: a review of the literature. *Dermatol Online J* 2013; 19(9):19611.

**Bonifaz A, et al:** Dermatophyte isolation in the socks of patients with tinea pedis and onychomycosis. *J Dermatol* 2013; 40(6):504–505.



- Bristow IR:** The effectiveness of lasers in the treatment of onychomycosis: a systematic review. *J Foot Ankle Res* 2014; 7:34.
- Carney C, et al:** Treatment of onychomycosis using a submillisecond 1064-nm neodymium:yttrium-aluminum-garnet laser. *J Am Acad Dermatol* 2013; 69(4):578–582.
- El-Gohary M, et al:** Topical antifungal treatments for tinea cruris and tinea corporis. *Cochrane Database Syst Rev* 2014; 8:CD009992. doi: 10.1002/14651858.CD009992.pub2.
- Elewski BE, et al:** Onychomycosis: an overview. *J Drugs Dermatol* 2013; 12(7):s96–s103.
- Friedlander SF, et al:** Onychomycosis does not always require systemic treatment for cure: a trial using topical therapy. *Pediatr Dermatol* 2013; 30(3):316–322.
- Ghannoum MA, et al:** Molecular analysis of dermatophytes suggests spread of infection among household members. *Cutis* 2013; 91(5):237–245.
- Gupta AK, et al:** Recurrences of dermatophyte toenail onychomycosis during long-term follow-up after successful treatments with mono- and combined therapy of terbinafine and itraconazole. *J Cutan Med Surg* 2013; 17(3):201–206.
- Gupta AK, et al:** Medical devices for the treatment of onychomycosis. *Dermatol Ther* 2012; 25(6):574–581.
- Idriss MH, et al:** The diagnostic value of fungal fluorescence in onychomycosis. *J Cutan Pathol* 2013; 40(4):385–390.
- Jarratt M, et al:** Luliconazole for the treatment of interdigital tinea pedis: A double-blind, vehicle-controlled study. *Cutis* 2013; 91(4):203–210.
- Lanternier F, et al:** Deep dermatophytosis and inherited CARD9 deficiency. *N Engl J Med* 2013; 369(18):1704–1714.
- Miyajima Y, et al:** Rapid real-time diagnostic PCR for *Trichophyton rubrum* and *Trichophyton mentagrophytes* in patients with tinea unguium and tinea pedis using specific fluorescent probes. *J Dermatol Sci* 2013; 69(3):229–235.
- Neri I, et al:** Corkscrew hair: a trichoscopy marker of tinea capitis in an adult white patient. *JAMA Dermatol* 2013; 149(8):990–991.
- Shemer A:** Update: medical treatment of onychomycosis. *Dermatol Ther* 2012; 25(6):582–593.
- Shemer A, et al:** Treatment of tinea capitis—griseofulvin versus fluconazole—a comparative study. *J Dtsch Dermatol Ges* 2013; 11(8):737–741, 737–742.
- Tietz HJ, et al:** Efficacy of 4 weeks topical bifonazole treatment for onychomycosis after nail ablation with 40% urea: a double-blind, randomized, placebo-controlled multicenter study. *Mycoses* 2013; 56(4):414–421.
- Yuen CW, et al:** Treatment of interdigital-type tinea pedis with a 2-week regimen of wearing hygienic socks loaded with antifungal microcapsules: a randomized, double-blind, placebo-controlled study. *J Am Acad Dermatol* 2013; 69(3):495–496.

## CANDIDIASIS

Candidiasis is also known as candidosis or moniliasis. *Candida albicans* is a common inhabitant of the human gastrointestinal (GI) and genitourinary tracts, and skin. Under the right conditions, *C. albicans* becomes a pathogen, causing lesions of the skin, nails, and mucous membranes. The intertriginous areas are frequently affected. Here warmth, moisture, and maceration of the skin permit the organism to thrive. The areas most often involved are the perianal and inguinal folds, abdominal creases, inframammary creases, interdigital areas, nailfolds, and axillae.

*Candida albicans* is largely an opportunistic organism, acting as a pathogen in the presence of impaired immune response, or where local conditions favor growth. Warmth and moisture favor candidal growth, as can reductions in competing flora during antibiotic therapy. Higher skin pH also favors candidal growth. Diapers, panty liners, and other occlusive products raise skin pH and may predispose to skin infections of *C. albicans*. A topical acidic buffer may be helpful as a preventive measure for recurrent *Candida*-induced skin rash.

## Diagnosis

Microscopically, the KOH preparation may show spores and pseudohyphae. On Gram stain the yeast forms dense, gram-positive, ovoid bodies, 2–5 µm in diameter. A combination of Gomori methenamine silver (GMS) and Congo red staining can be helpful in the differential diagnosis of fungal infections. *Blastomyces* and *Pityrosporum* are positive for both, whereas *Candida* and *Histoplasma* are GMS positive and Congo red negative.

*Candida* proliferates in both budding and mycelial forms in the stratum corneum or superficial mucosa. Budding yeast and pseudohyphae are easier to detect in histologic section with a PAS stain. Whereas dermatophyte hyphae tend to run parallel to the skin surface, *Candida* pseudohyphae are more prone to vertical orientation.

In culture, *C. albicans* should be differentiated from other forms of *Candida* that are only rarely pathogenic, such as *C. krusei*, *C. stellatoidea*, *C. tropicalis*, *C. pseudotropicalis*, and *C. guilliermondii*. Culture on Sabouraud glucose agar shows a growth of creamy, grayish, moist colonies in about 4 days. In time, the colonies form small, rootlike penetrations into the agar. Microscopic examination of the colony shows clusters of budding cells. When inoculated into cornmeal agar culture, thick-walled, round chlamydospores characteristic of *C. albicans* are produced.

## Topical anticandidal agents

Most of the topical agents marketed for tinea are also effective for candidiasis. These include clotrimazole (Lotrimin, Mycelex), econazole (Spectazole), ketoconazole (Nizoral), miconazole (Monistat-Derm Lotion, Micatin), oxiconazole (Oxistat), sulconazole (Exelderm), naftifine (Naftin), terconazole, ciclopirox olamine (Loprox), butenafine (Mentax), terbinafine (Lamisil), nystatin, and topical amphotericin B lotion. Older agents, such as gentian violet, Castellani paint, and boric acid, are still sometimes used. Oral nystatin is as effective as intravenous (IV) fluconazole at preventing invasive *Candida* infections in preterm neonates. The oral preparation is more easily administered and is lower in cost.

## Other agents

Fluconazole has a remarkable safety record, even when used long term in patients with *Candida* related to genodermatoses. Posaconazole, itraconazole, voriconazole, echinocandins, anidulafungin, and amphotericin B are also used in various settings. Various flavonoid compounds, including apigenin and kaempferol, alkaloid ibogaine (an indole), and the protoberberine alkaloid berberine, have been studied for their inhibitory effects. Kaempferol has shown a survival benefit in patients with systemic infections. Topical application of each of these agents accelerated elimination from cutaneous sites of inoculation.

## Oral candidiasis (thrush)

The mucous membrane of the mouth may be involved in healthy infants. In the newborn, infection may be acquired from contact with the vaginal tract of the mother. In older children and adults, thrush is often seen after antibiotic therapy. It may also be a sign of immunosuppression.

Grayish white membranous plaques are found on the surface of the mucous membrane. The base of these plaques is moist,

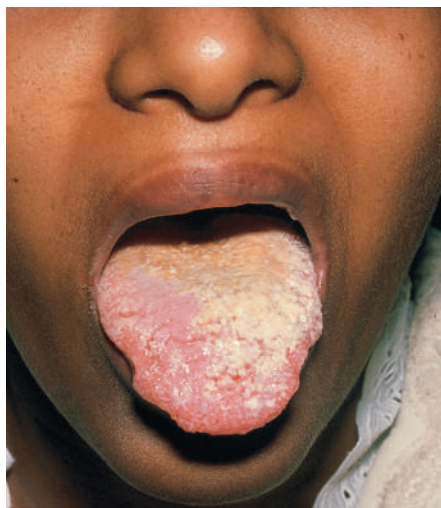

Fig. 15-13 Thrush.

reddish, and macerated (Fig. 15-13). In its spread, the angles of the mouth may become involved, and lesions in the intertriginous areas may occur, especially in marasmic infants. The diaper area is especially susceptible to candidiasis. Most of the intertriginous areas and even the exposed skin may be involved, with small pustules that quickly turn into macerated and erythematous scaling patches.

In adults, the appearance may resemble that seen in children or may be drier and more erythematous. Saliva inhibits the growth of *Candida*, and a dry mouth predisposes to candidal growth. Broad-spectrum antibiotics also predispose to candidiasis. The papillae of the tongue may appear atrophic, with the surface smooth, glazed, and bright red. Frequently, the infection extends onto the angles of the mouth to form perleche. This appearance is common in elderly, debilitated, and malnourished patients and in patients with diabetes. It is often the first manifestation of AIDS and is present in almost all untreated patients with full-blown AIDS. The observation of oral "thrush" in an adult with no known predisposing factors warrants a search for other evidence of infection with HIV, such as lymphadenopathy, leukopenia, or HIV antibodies in the serum.

Various treatment options for oral candidiasis are available. Infants are usually treated with oral nystatin suspension. An adult can let clotrimazole troches dissolve in the mouth. A single, 150-mg dose of fluconazole is effective for many mucocutaneous infections in adults. In immunosuppressed patients, 200 mg/day is the starting dose, but much higher doses are often needed. Itraconazole, 200 mg/day for 5–10 days, can also be effective. Although terbinafine is often regarded as a dermatophyte drug, it can also be effective for *Candida* infections at doses of 250 mg/day.

### Perleche

Perleche, or angular cheilitis, is characterized by maceration and transverse fissuring of the oral commissures. The earliest lesions are poorly defined, grayish white, thickened areas with slight erythema of the mucous membrane at the oral commissure. When more fully developed, this thickening has a bluish white or mother-of-pearl color and may be contiguous with a wedge-shaped, erythematous scaling dermatitis of the skin portion of the commissure. Fissures, maceration, and crust formation ensue. Soft, pinhead-sized papules may appear. Involvement is usually bilateral. Perleche is frequently related to *C. albicans* but may also harbor coagulase-positive

*Staphylococcus aureus* and gram-negative bacteria. Similar changes may occur in riboflavin deficiency or other nutritional deficiency.

Identical fissuring occurs at the mucocutaneous junction from drooling in persons with malocclusion caused by poorly fitting dentures and in older patients in whom atrophy of the alveolar ridges ("closing" the bite) has caused the upper lip to overhang the lower at the commissures. There is sometimes a vertical shortening of the lower third of the face.

If infection is caused by *C. albicans*, anticandidal creams are effective, but the response is more rapid if they are used in combination with a midstrength topical corticosteroid. If the perleche is caused by vertical shortening of the lower third of the face, dental or oral surgical intervention may be helpful. Injection of collagen into the depressed sulcus at the oral commissure can be beneficial.

### Candidal vulvovaginitis

*Candida albicans* is a common inhabitant of the vaginal tract. Overgrowth can cause severe pruritus, burning, and discharge. The labia may be erythematous, moist, and macerated and the cervix hyperemic, swollen, and eroded, showing small vesicles on its surface. The vaginal discharge is not usually profuse and varies from watery, to thick and white or curdlike.

Candidal infection may develop during pregnancy, in diabetes, or secondary to therapy with broad-spectrum antibiotics. Among diabetic patients, candidal overgrowth is related to the degree of hyperglycemia. Recurrent vulvovaginal candidiasis has also been associated with long-term tamoxifen treatment. Candidal balanitis may be present in an uncircumcised sexual partner. Diagnosis is established by the clinical symptoms and findings, as well as the demonstration of the fungus by KOH microscopic examination and culture.

Oral fluconazole, 150 mg given once, is easy and effective. In some patients with predisposing factors, longer courses of fluconazole, 100–200 mg/day, or itraconazole, 200 mg/day, for 5–10 days may be needed. Topical options include miconazole, nystatin, clotrimazole, and terconazole. Clotrimazole exerts anti-inflammatory as well as anticandidal effects. Probiotic, anticandidal bacteria and yogurt have demonstrated some ability to decrease *Candida* colonization.

*Candida glabrata* vaginitis may be refractory to azole drugs and can be difficult to eradicate. Topical boric acid, amphotericin B, and flucytosine may be helpful.

### Candidal intertrigo

The pruritic intertriginous eruptions caused by *C. albicans* may arise between the folds of the genitals; in groins or armpits; between the buttocks; under large, pendulous breasts; under overhanging abdominal folds; or in the umbilicus. The pink to red, intertriginous moist patches are surrounded by a thin, overhanging fringe of somewhat macerated epidermis ("collarete" scale). Some eruptions in the inguinal region may resemble tinea cruris, but usually there is less scaliness and a greater tendency to fissuring. Persistent excoriation and subsequent lichenification and drying may modify the original appearance over time. Often, tiny, superficial, white pustules are observed closely adjacent to the patches. When present, *Candida* can cause flares of inverse psoriasis, although prevalence of *Candida* is not increased in the intertriginous areas of patients with either psoriasis or atopic dermatitis.

Topical anticandidal preparations are usually effective, but recurrence is common. Combinations of a topical anticandidal



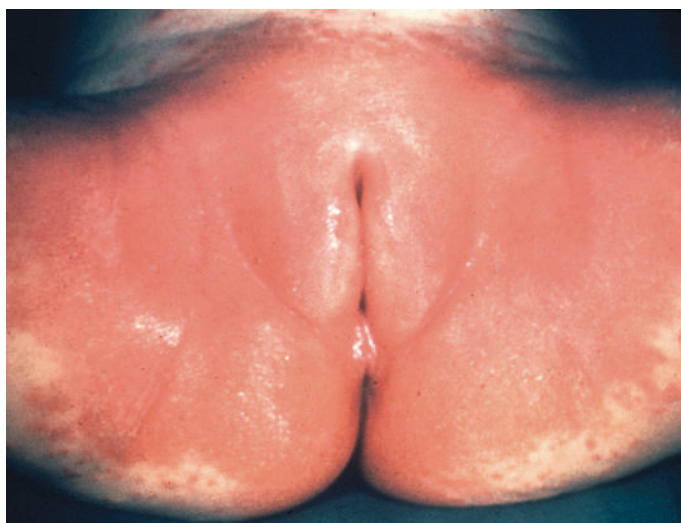

Fig. 15-14 Diaper candidiasis.

agent with a midstrength corticosteroid may lead to more rapid relief. Castellani paint may also be helpful. Patients often prefer colorless paint.

### Diaper candidiasis

The diagnosis of candidiasis may be suspected from involvement of the folds and occurrence of many small, erythematous desquamating “satellite” or “daughter” lesions scattered along the edges of the larger macules (Fig. 15-14). Topical anticandidal agents are effective, sometimes compounded in zinc oxide ointment to act as a barrier against the irritating effect of urine. Recurrent diaper candidiasis may be associated with oral and gut colonization and may respond to the addition of oral nystatin suspension.

### Congenital cutaneous candidiasis

Premature rupture of membranes together with a birth canal infected with *C. albicans* may lead to congenital cutaneous candidiasis. The eruption is usually noted within a few hours of delivery. Erythematous macules progress to thin-walled pustules, which rupture, dry, and desquamate within about 1 week. Lesions are usually widespread, involving the trunk, neck, and head and sometimes the palms and soles, including the nailfolds. The oral cavity and diaper area are spared, in contrast to the usual type of acquired neonatal infection. The differential diagnosis includes other neonatal vesiculopustular disorders, such as listeriosis, syphilis, staphylococcal and herpes infections, erythema toxicum neonatorum, transient neonatal pustular melanosis, miliaria rubra, drug eruption, and congenital ichthyosiform erythroderma. If infection is suspected early, the amniotic fluid, placenta, and cord should be examined for evidence of infection.

Infants with candidiasis limited to the skin have favorable outcomes; however, systemic involvement may occur. Disseminated infection is suggested by evidence of respiratory distress or other laboratory or clinical signs of neonatal sepsis. Dissemination is more common in infants who weigh less than 1500 g. Treatment with broad-spectrum antibiotics and altered immune responsiveness can also predispose to dissemination. Infants with congenital cutaneous candidiasis and any of the previous factors may be considered for systemic antifungal therapy.

### Perianal candidiasis

Infection with *C. albicans* may present as pruritus ani. Perianal dermatitis with erythema, oozing, and maceration is present. Pruritus and burning can be extremely severe. Satellite lesions may be present, but their absence does not exclude candidiasis. *Candida* growth is also enhanced on abnormal tissue, such as extramammary Paget’s disease. If the tissue does not return to normal after the candidiasis is treated, a biopsy may be warranted.

### Candidal paronychia

Inflammation of the nailfold produces redness, edema, and tenderness of the proximal nailfolds and gradual thickening and brownish discoloration of the nail plates. Usually, only the fingernails are affected. Patients frequently have an atopic background.

Although acute paronychia is usually staphylococcal in origin, chronic paronychia is typically multifactorial. Irritant dermatitis and candidiasis may play important roles. In one study, treatment with a topical corticosteroid was superior to treatment with an anticandidal agent. Avoidance of irritants and wet work is essential. Anticandidal agents may be helpful and may be used in combination with a topical corticosteroid.

Candidal paronychia is frequently seen in diabetic patients, and part of the treatment is bringing the diabetes under control. The avoidance of chronic exposure to moisture and irritants is also essential in these patients. If topical treatment fails, oral fluconazole once a week or itraconazole in pulsed dosing can be effective.

Repetitive contact urticaria or allergic contact dermatitis to foods and spices may mimic candidal paronychia. Patch and radioallergosorbent testing (RAST) may be of value.

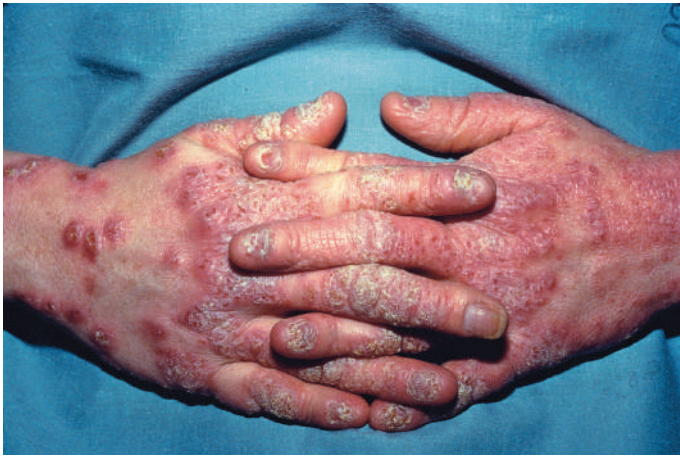### Erosio interdigitalis blastomycetica

A form of candidiasis, *erosio interdigitalis blastomycetica* is seen as an oval-shaped area of macerated white skin on the web between and extending onto the sides of the fingers. Usually, at the center of the lesion, there are one or more fissures with raw, red bases. As the condition progresses, the macerated skin peels off, leaving a painful, raw, denuded area surrounded by a collar of overhanging white epidermis. It is almost always the third web, between the middle and ring fingers, that is affected. The moisture beneath the ring macerates the skin and predisposes to infection. The disease is also seen in patients with diabetes and those who do wet work.

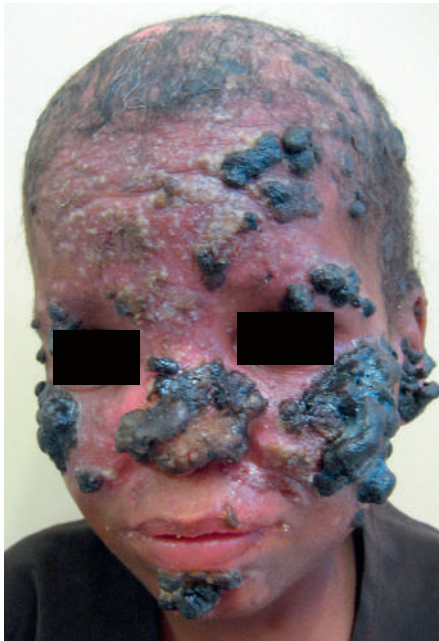Intertriginous lesions between the toes are similar. Usually, the white, sodden epidermis is thick and does not peel off freely. On the feet, it is the fourth interspace that is most often involved, but the areas are apt to be multiple. Clinically, this may be indistinguishable from tinea pedis. Diagnosis of *erosio interdigitalis blastomycetica* is made by culture. Lesions may respond to drying, topical anticandidal agents, or application of filter paper soaked with Castellani paint.

### Chronic mucocutaneous candidiasis

The term chronic mucocutaneous candidiasis (CMCC) designates a heterogeneous group of patients whose infection with *Candida* is chronic but limited to mucosal surfaces, skin, and nails. Onset is typically before age 6 years. Onset in adult life may herald the occurrence of thymoma. These cases may be either inherited or sporadic. Inherited types may be associated



**Fig. 15-15** Hand and nail involvement in chronic mucocutaneous candidiasis.



**Fig. 15-16** Chronic mucocutaneous candidiasis. (Courtesy of Leslie Castelo-Soccio, MD.)

with endocrinopathy. Oral lesions are diffuse, and perleche and lip fissures are common. The nails become thickened and dystrophic, with associated paronychia. Hyperkeratotic, horn-like, or granulomatous lesions are often seen (Figs. 15-15 and 15-16).

Chronic mucocutaneous candidiasis occurs in a number of syndromes. Autosomal dominant signal transducer and activator of transcription 1 (*STAT1*) gain-of-function mutation, impairing interleukin-17 (IL-17)-producing T-cell development, is the best described abnormality. Autosomal recessive IL-17RA and autosomal dominant IL-17F deficiencies have been reported in CMCC patients. Autosomal dominant hyper-IgE syndrome is related to *STAT3* mutations, resulting in low IL-17 T-cell numbers. Dectin 1 and IL-22 encoding genes modulate the response to *Candida* infections through a T-helper cell type 17 (Th17) mechanism, although dectin 1 does not appear to be critical in some models of mucosal candidiasis. CARD9 deficiency predisposes to invasive candidiasis as well as invasive and disseminated dermatophytosis. Autoimmune polyendocrinopathy candidiasis ectodermal dystrophy is an autosomal recessive syndrome caused by mutations of the autoimmune regulator gene (*AIRE*), resulting in failure of

T-cell tolerance within the thymus, with decreased numbers of IL-17 T cells. Hallmarks of the syndrome include CMCC, chronic hypoparathyroidism, hypothyroidism, and Addison's disease.

Abnormalities of type 1 cytokine production in response to *Candida* have been reported. Specifically, there may be greatly impaired IL-12 production and dramatically increased levels of IL-6 and IL-10. Reductions in natural killer (NK) cells have also been noted. In a five-generation Italian family with CMCC affecting only the nails, low serum intercellular adhesion molecule 1 (ICAM-1) was noted. The defect was linked to a 19cM pericentromeric region on chromosome 11.

Systemic fluconazole, itraconazole, or ketoconazole is necessary to control CMCC. Courses are typically prolonged, repeated, and given at higher doses than the usual recommended dose. Patients with achlorhydria may have problems with absorption of itraconazole and ketoconazole. Cimetidine was reported to restore deficient cell-mediated immunity in four adults from one family, at a dose of 300 mg four times daily. Granulocyte colony-stimulating factor (G-CSF) infusion has been reported to restore IL-17 secretion, with subsequent clinical remission.

### Systemic candidiasis

*Candida albicans* is capable of causing disseminated disease and sepsis, invariably when host defenses are compromised. Patients at high risk include those with malignancies, especially leukemia and lymphoma, who may have impaired immune defenses; AIDS patients; debilitated and malnourished patients; those with a transplant who require prolonged immunosuppressive therapy; patients receiving oral cortisone; those who have had multiple surgical operations, especially cardiac surgery; and patients with indwelling IV catheters. IV drug users also are at high risk.

The initial sign of systemic candidiasis may be fever of unknown origin, pulmonary infiltration, GI bleeding, endocarditis, renal failure, meningitis, osteomyelitis, endophthalmitis, peritonitis, proximal muscle weakness and tenderness, or a disseminated maculopapular exanthema. The cutaneous lesions begin as erythematous macules that may become papular, pustular, hemorrhagic, or ulcerative. Deep abscesses may occur. The trunk and extremities are the usual sites of involvement. Proximal muscle tenderness frequently accompanies the exanthema and may be a valuable clue to the correct diagnosis.

The demonstration of microorganisms or a positive culture will substantiate a diagnosis of candidiasis only if the microorganism is found in tissues or fluids ordinarily sterile for *Candida* and if the clinical picture is compatible. *Candida* colonization of endotracheal tubes used in supporting low-birth-weight neonates predisposes to systemic disease. If *Candida* is cultured within the first week of life, there is a high rate of systemic disease.

The mortality attributed to systemic candidiasis has declined because of early empiric antifungal treatment and better prophylaxis. Data in children are similar to those in adults. Although amphotericin B remains the gold standard of treatment in systemic candidiasis, other, safer options are available. Amphotericin B is now available in liposome-encapsulated forms, which appear to be less toxic. Fluconazole has been effective as prophylaxis with bone marrow transplantation, as well as in the treatment of oropharyngeal candidosis and candidemia in nonneutropenic patients. At high doses, fluconazole is sometimes used for *Candida* in neutropenic patients. Voriconazole, a newer triazole antifungal, acts by inhibiting synthesis of ergosterol in the fungal cell membrane.



Posaconazole is a triazole active against *Candida*, although some problems with resistance have been reported. Caspofungin is an echinocandin antifungal that inhibits  $\beta$ -1,3-D-glucan synthesis in the cell wall. Micafungin and anidulafungin are echinocandins. The newer triazoles and echinocandins have broad spectrums and are effective against invasive *Aspergillus* and *Candida* infections. Voriconazole has produced liver abnormalities, rash, and visual disturbances, and these must be monitored during therapy. A meta-analysis of studies of *Candida* sepsis concluded that clinical efficacy was similar among the agents studied, but microbiologic failure was more common with fluconazole than with amphotericin B or anidulafungin. Amphotericin B had a higher rate of adverse events than fluconazole or the echinocandins. Some data favor caspofungin or micafungin over anidulafungin in neutropenic patients. The antiarrhythmic drug amiodarone has some fungicidal activity, and low doses of amiodarone produced a synergistic effect with fluconazole in fluconazole-resistant *C. albicans*.

Despite advances in treatment, mortality associated with systemic candidiasis remains high, with overall mortality of 30–50% and attributable mortality of approximately 30%.

## Candidid

As in dermatophytosis, patients with candidiasis may develop secondary id reactions (candidid). These are much less common than the reactions seen with acute inflammatory dermatophytosis. The reactions, which have been reported to clear with treatment of candidal infection, are usually of the erythema annulare centrifugum or chronic urticaria type.

## Antibiotic (iatrogenic) candidiasis

The use of oral antibiotics, such as the tetracyclines and their related products, may induce clinical candidiasis involving the mouth, GI tract, or perianal area. In addition, vulvovaginitis may occur. It has been suggested that perhaps the bacterial flora in the GI system are changed by suppression of some of the antibiotic-sensitive bacteria, thereby permitting other organisms such as *Candida* to flourish. Fluconazole, 150 mg once, will treat this adequately if antibiotic therapy is given for a limited time. For more prolonged courses of antibiotic therapy, the dose of fluconazole may have to be repeated, or a longer course of a topical agent may be used.

**Al Rushood M, et al:** Autosomal dominant cases of chronic mucocutaneous candidiasis segregates with mutations of signal transducer and activator of transcription 1, but not of toll-like receptor 3. *J Pediatr* 2013; 163(1):277–279.

**Autmizguine J, et al:** Pharmacokinetics and pharmacodynamics of antifungals in children: clinical implications. *Drugs* 2014; 74:891–909.

**Dias MF, et al:** Treatment of superficial mycoses: review. Part II. *An Bras Dermatol* 2013; 88:937–944.

**Dias MF, et al:** Update on therapy for superficial mycoses: review article part I. *An Bras Dermatol* 2013; 88:764–774.

**Griffin AT, Hanson KE:** Update on fungal diagnostics. *Curr Infect Dis Rep* 2014; 16:415.

**Puel A, et al:** Inborn errors of human IL-17 immunity underlie chronic mucocutaneous candidiasis. *Curr Opin Allergy Clin Immunol* 2012; 12(6):616–622.

**Schimke LF, et al:** A novel gain-of-function *IKBA* mutation underlies ectodermal dysplasia with immunodeficiency and polyendocrinopathy. *J Clin Immunol* 2013; 33(6):1088–1099.

**Wildbaum G, et al:** Continuous G-CSF therapy for isolated chronic mucocutaneous candidiasis: complete clinical remission with restoration of IL-17 secretion. *J Allergy Clin Immunol* 2013; 132(3):761–764.

**Wilson D, et al:** Clotrimazole dampens vaginal inflammation and neutrophil infiltration in response to *Candida albicans* infection. *Antimicrob Agents Chemother* 2013; 57(10):5178–5180.

## GEOTRICHOSIS

*Geotrichum candidum* is an ascomycetous anamorph, yeastlike fungus found as part of the natural flora of milk. It is also found on fruit and tomatoes and in soil. It is used commercially as a maturing agent for cheese. Individual strains may be more moldlike or yeastlike. Substantial genetic polymorphism has been noted in *G. candidum*. Strains with a moldlike phenotype tend to have larger genomes than those with a yeastlike phenotype.

In immunosuppressed individuals, *G. candidum* or *Geotrichum capitatum* (*Blastoschizomyces capitatus*) may act as an opportunistic pathogen, causing disseminated or mucocutaneous geotrichosis. Mucocutaneous disease is characterized by erythema, pseudomembranes, and mucopurulent sputum similar to that seen in thrush. The intestinal, bronchial, and pulmonary forms are similar to candidal infection. *G. candidum* is usually isolated as a saprophyte. If cultured repeatedly from diseased tissue, it should be assumed to be acting as a pathogen.

The diagnosis is made by the repeated demonstration of the organism by KOH microscopic examination and by its culture from sputum on Sabouraud dextrose agar. Direct examination shows branching septate mycelium and chains of rectangular cells. In culture, there is a mealy growth at room temperature. The hyphae form rectangular arthrospores.

Treatment of mucocutaneous disease can be accomplished with oral nystatin, or nystatin (Mycostatin) suspension in some cases. For more severe or disseminated disease, liposomal amphotericin B, caspofungin, voriconazole, itraconazole, flucytosine, or combinations of these agents have been effective.

**Martins N, et al:** Candidiasis: predisposing factors, prevention, diagnosis and alternative treatment. *Mycopathologia* 2014; 177:223–240.

## TINEA NIGRA

*Hortaea werneckii* (formerly *Phaeoannellomyces werneckii*) is a black, yeastlike hyphomycete that is widely distributed in hot, humid environments. The organism is common in the tropics. In the United States, the infection is seen along the Gulf Coast. New taxonomic analysis has led some to classify *Cladosporium castellanii* as the etiologic agent of tinea nigra in humans and confirmed that this fungus is the same as *Stenella araguata*.

Tinea nigra presents as one or several brown or black spots on the palms or soles. The lesions may be mistaken for nevi or melanoma. The pigment is confined to the stratum corneum and scrapes off easily. Dermoscopy has also been used to differentiate the lesions from melanocytic tumors. The fungus can easily be demonstrated by means of KOH or culture. In KOH preparations, the hyphae appear brown or golden in color. Young colonies are glossy, black, and yeastlike, but older colonies are filamentous and grayish. The pigment produced by the fungal hyphae is melanin. Culture will identify the organism, and PCR can be useful for rapid identification of *H. werneckii*.

Topical imidazoles and allylamines, such as clotrimazole, miconazole, ketoconazole, sulconazole, econazole, and terbinafine, have been reported as effective. Griseofulvin is not effective. Simply shaving away the superficial epidermis with a blade is frequently both diagnostic and curative of tinea nigra.

## PIEDRA

In black piedra, dark, pinhead- to pebble-sized formations occur on the hairs of the scalp, brows, lashes, or beard. These nodules are distributed irregularly along the length of the shaft. White piedra is typically caused by *Trichosporon* (*Trichosporum*) *beigelii* or *Trichosporon inkin* and occurs more often in temperate climates. Based on molecular analysis, the taxon *T. beigelii* has been replaced by several species. A synergistic corynebacterial infection is often present in white piedra, as demonstrated by culture and electron microscopy. *T. beigelii* has also been implicated as a cause of onychomycosis. *T. inkin* is implicated as an etiologic agent of pubic white piedra. *Trichosporon asahii* causes white piedra and onychomycosis and has been isolated from black piedra. *Trichosporon* spp. can also cause disseminated disease in immunosuppressed patients, and *T. asahii* has produced disseminated cutaneous infections in immunocompetent hosts. In white piedra, patients present with yellow or beige-colored, soft, slimy sheaths coating the hair shafts (Fig. 15-17). The sheaths are composed of hyphae, arthrospores, and bacteria. The culture shows soft, cream-colored colonies composed of blastospores and septate hyphae, which fragment into arthrospores.

Black piedra, usually caused by *Piedraia hortai*, occurs mostly in the tropics, especially in South America and Asia. The nodulike masses in KOH preparations show numerous oval asci containing two to eight ascospores and mycelium. Cultures produce black colonies composed of hyphae and chlamydospores.

Treatment involves cutting or shaving the hair, but this may not be acceptable to the patient. Oral and topical terbinafine have been effective in black piedra. For white piedra, oral itraconazole, topical imidazoles, ciclopirox olamine, 2% selenium sulfide, 6% precipitated sulfur in petrolatum, chlorhexidine solutions, Castellani paint, zinc pyrithione, amphotericin B lotion, and 2-10% glutaraldehyde have all been used successfully.

Essential oils derived from *Cymbopogon winterians*, *Mentha piperita*, *Cinnamomum zeylanicum*, *Melaleuca alternifolia*, and

*Eucalyptus globulus* have demonstrated efficacy against *Trichosporon ovoides*.

**Richini-Pereira VB, et al:** White piedra: molecular identification of *Trichosporon inkin* in members of the same family. *Rev Soc Bras Med Trop* 2012; 45(3):402-404.

**Saxena S, et al:** Inhibitory effect of essential oils against *Trichosporon ovoides* causing piedra hair infection. *Braz J Microbiol* 2012; 43(4):1347-1354.

**Uniyal V, et al:** Screening of some essential oils against *Trichosporon* species. *J Environ Biol* 2013; 34(1):17-22.

## TINEA VERSICOLOR (PITYRIASIS VERSICOLOR)

Tinea versicolor is caused by *Malassezia* spp., although contrary to prior belief, *Malassezia furfur* is not the predominant species isolated from clinical lesions. The major implicated species is *Malassezia globosa*, although *M. restricta*, *M. sympodialis*, *M. furfur*, *M. obtusa*, and *M. slooffiae* have also been implicated. Tinea versicolor typically presents as hypopigmented or hyperpigmented, coalescing scaly macules on the trunk and upper arms (Fig. 15-18). Pink, atrophic, and trichrome variants exist and can produce striking clinical pictures. The eruption is more common during the summer months and favors oily areas of skin. Sites of predilection are the sternal region and the sides of the chest, abdomen, back, pubis, neck, and intertriginous areas. Mild itching and inflammation around the patches may be present. In some patients, many follicular papules are present. The face and scalp may be affected. Facial lesions may occur in infants and immunocompromised patients. The disease may even occur on the scalp, palms, and soles. Penile lesions may develop as well, and the organism is commonly isolated from patients with balanoposthitis.

In hypopigmented tinea versicolor, abnormally small and poorly melanized melanosomes are produced and are not transferred to keratinocytes properly. This becomes most conspicuous in dark-skinned people. This hypopigmentation may persist for weeks or months after the fungal disease is cured, unless an effort is made to regain the lost pigmentation through UV exposure.

## Diagnosis

The *Malassezia* fungus is easily demonstrated in scrapings of the profuse scales that cover the lesions. Tape stripping of the lesions can also be performed. Microscopically, there are short, thick fungal hyphae and large numbers of variously

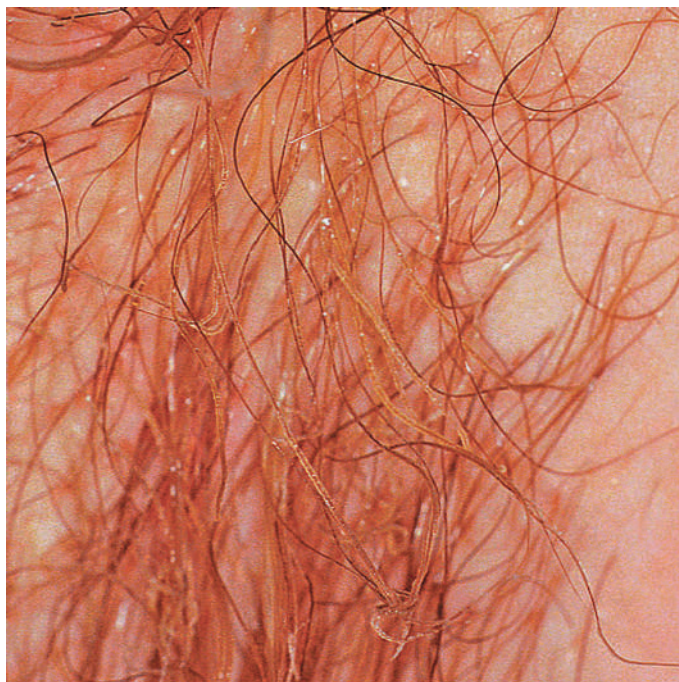

Fig. 15-17 White piedra.

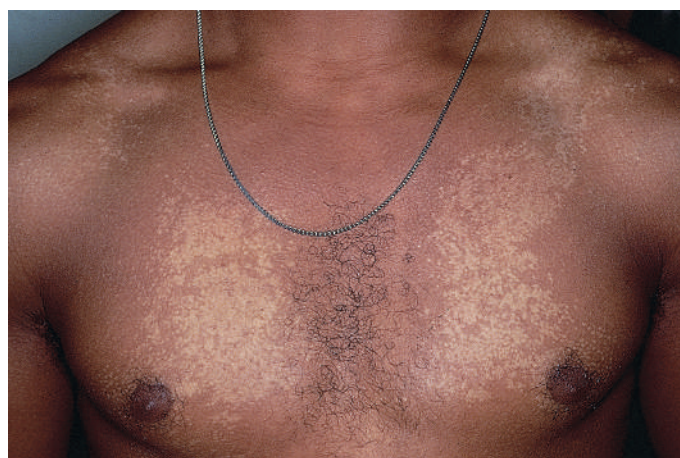

Fig. 15-18 Tinea versicolor.



sized spores. This combination of strands of mycelium and numerous spores is commonly referred to as “spaghetti and meatballs.” The fungus can be highlighted by a variety of stains, including Parker blue-black ink (mixed 1:1 with 20% KOH), 1% Chicago sky blue 6B with 8% KOH, and Gram stain. Identification by culture requires lipid enrichment of the media and is rarely done to establish the diagnosis. Wood’s light examination accentuates pigment changes and may demonstrate yellow-green fluorescence of the lesions in adjacent follicles. Biopsy will demonstrate a thick basket-weave stratum corneum with hyphae and spores. In the atrophic variant, epidermal colonization with hyphae and spores is accompanied by effacement of the rete ridges, subepidermal fibroplasia, pigment incontinence, and elastolysis.

## Differential diagnosis

Tinea versicolor must be differentiated from seborrheic dermatitis, pityriasis rosea, pityriasis rubra pilaris, pityriasis alba, Hansen’s disease, syphilis, and vitiligo. In the atrophic variant, the lesions may suggest parapsoriasis, mycosis fungoides, anetoderma, LE, or steroid atrophy. The diagnosis in all forms of tinea versicolor is generally easily established by KOH examination. In seborrheic dermatitis, the patches have an erythematous yellowish tint, and the scales are soft and greasy, whereas in tinea versicolor the scales are furfuraceous (fluffy). Macular syphilitid consists of faint pink lesions, less than 1 cm in diameter, irregularly round or oval, which are distributed principally on the nape, sides of the trunk, and flexor aspects of the extremities. The lesions are slightly indurated, with a peripheral scale, and may be copper colored. General adenopathy may be present. Serologic tests are positive in this phase of syphilis, but prozone reactions may occur, and the serum may require dilution.

## Treatment

Imidazoles, triazoles, selenium sulfide, ciclopirox olamine, zinc pyrithione, sulfur preparations, salicylic acid preparations, propylene glycol, and benzoyl peroxide have been used successfully as topical agents. Selenium sulfide lotion is very cost-effective and can be applied daily for a week; it is washed off after 10 min and is also effective in a single, overnight application, which can be repeated monthly as prophylaxis. The scalp can be shampooed monthly with selenium sulfide to reduce scalp colonization. Zinc pyrithione soap is also cost-effective and well tolerated for treatment and prophylaxis.

Ketoconazole, in 400-mg doses repeated at monthly intervals, is very effective, but the FDA has warned against the use of ketoconazole as a first-line treatment, making its use problematic. Oral itraconazole, 200 mg once daily for 7 days, is effective and can be followed by prophylactic treatment with itraconazole, 200 mg twice daily on 1 day a month. In a study of 50 patients, 400-mg single-dose itraconazole was equivalent to 200 mg/day of itraconazole for 7 days. Fluconazole, 400 mg once, may also be effective and can be repeated monthly. In a study of 128 patients, weekly dosing with two 150-mg capsules of fluconazole for 2 weeks was equivalent to weekly dosing of two 200-mg tablets of ketoconazole for 2 weeks. The effect of a single dose, not repeated in 2 weeks, was not assessed in this study and may have proved just as effective. Although oral terbinafine has been ineffective, it is effective topically. Twice-daily applications are superior to once-daily applications. Alternatively, 5-aminolevulinic acid PDT has been reported as effective.

Patients should be informed that the hypopigmentation or hyperpigmentation will take time to resolve and is not a sign of treatment failure. Relapse is likely if prophylactic doses are not given occasionally, but many prophylactic options are available. After initial therapy, patients may prefer weekly washing with a topical zinc pyrithione bar or single, overnight applications of selenium sulfide, ketoconazole, econazole, or bifonazole shampoo every 30–60 days, or monthly oral therapy.

## *Pityrosporum* folliculitis

*Pityrosporum* folliculitis has been a controversial entity, but its prompt response to antifungal agents suggests that *Pityrosporum* yeast (the yeast phase of *Malassezia* spp.) are indeed pathogenic. Criteria for diagnosis include characteristic morphology, demonstration of yellow-green Wood’s light fluorescence of the papules or identification of *Pityrosporum* yeast in smears or biopsies, and prompt response to antifungal treatment. Fungal stains, Gram stain, and May-Grünwald-Giemsa stain have been used. Lesions tend to be chronic, moderately itchy, dome-shaped follicular papules and tiny pustules involving the upper back and adjacent areas. The face and scalp may be involved, and the lesions are sometimes found in association with either tinea versicolor or seborrheic dermatitis. *Pityrosporum* folliculitis is more common in organ or marrow transplant recipients. *Pityrosporum* yeast is a normal part of the follicular flora, so alterations in flora may favor uncontrolled growth of the yeast. Such a case occurs when *Propionibacterium acnes* is suppressed by tetracycline therapy.

The eruption responds to oral fluconazole, 400 mg once; ketoconazole, 400 mg once; or itraconazole, 200 mg/day for 5–7 days. As previously noted, the FDA strengthened warnings about ketoconazole use. Topical therapy with 2.5% selenium sulfide applied overnight is also generally effective. Other treatments include 30–50% propylene glycol in water and topical imidazole creams. PDT may be considered in refractory disease. Relapses are common, but prophylaxis may be successful with monthly applications of selenium sulfide or maintenance doses of topical econazole.

**Akaza N, et al:** *Malassezia globosa* tends to grow actively in summer conditions more than other cutaneous *Malassezia* species. *J Dermatol* 2012; 39(7):613–616.

**Durdu M, et al:** Epidemiological characteristics of *Malassezia* folliculitis and use of the May-Grünwald-Giemsa stain to diagnose the infection. *Diagn Microbiol Infect Dis* 2013; 76(4):450–457.

**Gupta AK, Lyons DC:** Pityriasis versicolor: an update on pharmacological treatment options. *Expert Opin Pharmacother* 2014; 15:1707–1713.

**Gupta AK, et al:** Systematic review of systemic treatments for tinea versicolor and evidence-based dosing regimen recommendations. *J Cutan Med Surg* 2014; 18:79–90.

**Lee JW, et al:** Topical photodynamic therapy with methyl aminolevulinic acid may be an alternative therapeutic option for the recalcitrant *Malassezia folliculitis*. *Int J Dermatol* 2011; 50(4):488–490.

**Mostafa WZ, et al:** Hair loss in pityriasis versicolor lesions: a descriptive clinicopathological study. *J Am Acad Dermatol* 2013; 69(1):e19–e23.

**Saad M, et al:** Molecular epidemiology of *Malassezia globosa* and *Malassezia restricta* in Sudanese patients with pityriasis versicolor. *Mycopathologia* 2013; 175(1-2):69–74.

**Spence-Shishido A, et al:** In vivo Gram staining of tinea versicolor. *JAMA Dermatol* 2013; 149(8):991–992.

## THE DEEP MYCOSES

Most deep cutaneous fungal infections are a manifestation of systemic infection from inhalation of aerosolized fungus.

When primary infection is introduced directly into the skin from puncture wounds, abrasions, or other trauma, a chancri-form or verrucous lesion will form that may be accompanied by secondary lymphangitis. Chest radiographs should be taken when investigating patients with deep mycoses, except for the classic inoculation types, such as sporotrichosis, mycetoma, chromoblastomycosis, and phaeohyphomycosis.

## COCCIDIOIDOMYCOSIS

Coccidioidomycosis is also known as coccidioidal granuloma, valley fever, and San Joaquin Valley fever.

### Primary pulmonary coccidioidomycosis

Inhalation of *Coccidioides immitis* or *C. posadasii*, followed by an incubation period of 10 days to several weeks, produces a respiratory infection that may be mild, with only a low-grade fever resembling a flulike illness. Approximately 60% of infected persons are entirely asymptomatic. Severe symptoms of chills, high fever, night sweats, severe headache, backache, and malaise may ensue in a minority. A large percentage of patients show lung changes on radiographic examination. These include hilar adenopathy, peribronchial infiltration, or an infiltrate compatible with bronchopneumonia. At the time of onset, a generalized maculopapular eruption may be present, which may be confused with a drug eruption, measles, or scarlet fever.

Within a few weeks, the pulmonary symptoms subside. In about 30% of women and in 15% of men, skin manifestations appear in the form of erythema nodosum over the shins and sometimes over the thighs, hips, and buttocks. These tender lesions may become confluent, gradually turn from purple to brown, and then disappear in about 3 weeks. Erythema nodosum is a favorable prognostic sign and occurs mostly in white individuals with transient self-limited disease. Sometimes, erythema multiforme may develop in a similar clinical setting.

Although valley fever is usually self-limited and patients recover spontaneously, a small percentage steadily progress into the chronic, progressive, disseminated form. The propensity for disseminated disease is several-fold higher in Hispanics and Native Americans and many times higher for African Americans, Filipinos, and Vietnamese. In women, pregnancy may predispose to systemic disease. Infants, the elderly population, persons with blood types B or AB, and immunosuppressed patients, such as those with AIDS, a history of organ transplantation, or a hematogenous malignancy or those receiving immunosuppressive therapy, are also at increased risk for severe disease. Donor-derived organ transplant transmission has been documented many times; risk is primarily in the first year after transplant. Autosomal dominant interferon- $\gamma$  receptor 1 deficiency also may predispose to disseminated disease.

### Disseminated coccidioidomycosis (coccidioidal granuloma)

Dissemination occurs in less than 1% of infections, but its incidence is heavily influenced by the factors previously listed. Target organs include the bones, joints, viscera, brain, meninges, and skin. A single organ or multiple organs may be involved. Skin lesions occur in 15–20% of patients with disseminated disease and may appear as verrucous nodules (Fig. 15-19), as pink papules resembling basal cell carcinoma, or as subcutaneous abscesses. The face is frequently involved.

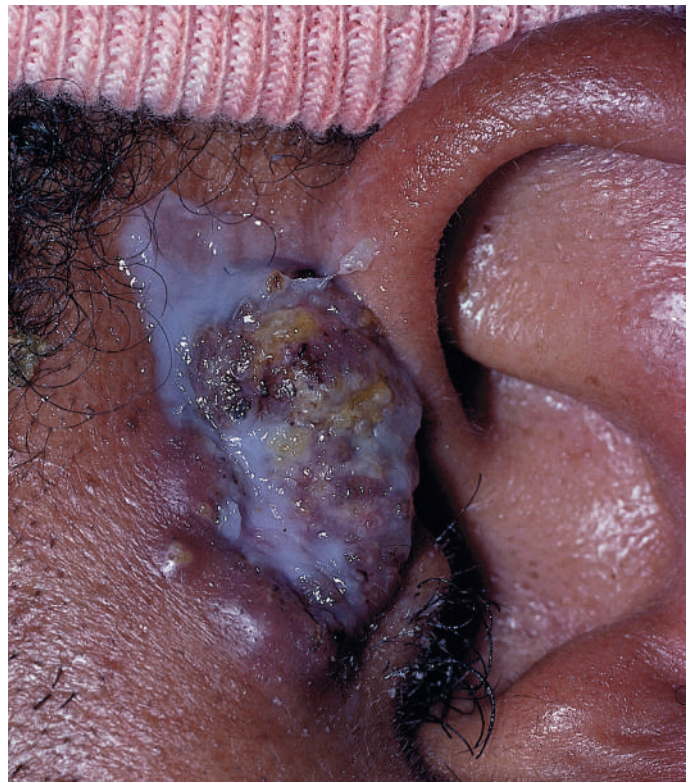

Fig. 15-19 Disseminated coccidioidomycosis. (Courtesy of Curt Samlaska, MD.)

Some chronic lesions develop into plaques that resemble mycosis fungoides or North American blastomycosis. In AIDS patients, umbilicated papules may mimic molluscum contagiosum. Umbilicated papules are more often associated with cryptococcosis but can occur with a variety of fungi.

### Primary cutaneous coccidioidomycosis

The primary form occurs rarely, and skin disease should be considered a manifestation of disseminated disease unless there is a definite history of inoculation, or a colonized splinter is found in the lesion. Between 1 and 3 weeks after inoculation, an indurated nodule develops that may ulcerate. Later, nodules appear along the lymphatic vessels. Spontaneous recovery may result after several weeks, although most patients are treated with systemic agents.

### Etiology and pathology

The causative organism, *C. immitis*, has been isolated from the soil and from vegetation. It is commonly found in the burrows of rodents, often at a depth of about 20 cm. Epidemics occur when the soil is disrupted to a depth of 20 cm or more. This can occur as a result of road work, laying of telephone or electric cable, dust storms, and earthquakes. Outbreaks occur sporadically in California and Arizona.

*Coccidioides immitis* is dimorphous, reproducing brittle mycelia at room temperature, and spherules in tissue. Spherules are unencapsulated with a thick, refractile wall and a granular interior. They measure 5–200  $\mu\text{m}$  in diameter but average 20  $\mu\text{m}$ . Endosporulation can occur, and although the organism can resemble *Rhinosporidium*, *Coccidioides* is typically much smaller and more uniform in size. It also lacks the small, central nucleus that is uniformly present in nonsporulating *Rhinosporidium*.



## Culture

*Coccidioides* is readily grown at room temperature and is highly infectious. For this reason, culture of deep fungi should never be attempted in the office setting. Cultures should be performed only in laboratories with biocontainment hoods. The colonies appear on Sabouraud dextrose agar within 2–7 days as small, slightly raised disks penetrating the medium. Older cultures become covered with a dusty layer of aerial hyphae and assume a brownish color with age. In culture, spherical bodies throw out filaments of barrel-shaped arthrospores. Mycelia are branched and septate, 2–8  $\mu\text{m}$  in diameter. PCR primers and a DNA hybridization probe test that targets organism-specific ribosomal RNA are available for rapid identification.

## Epidemiology

Coccidioidomycosis principally occurs in limited areas in the Western Hemisphere. The original diagnosis was in a soldier from Argentina, where the disease is endemic in the Gran Chaco area. It is also endemic in northern Mexico, Venezuela, and the southwestern United States (lower Sonoran Life Zone). In highly endemic areas, most residents will have been infected, and new residents have a good chance of becoming infected within 6 months. Very few will develop disseminated disease, although the attack rate has recently increased in both California and Arizona.

## Differential diagnosis

Clinically, it is extremely difficult to differentiate coccidioidomycosis from blastomycosis, which it closely resembles. Definite diagnosis depends on serologic testing and the demonstration of *C. immitis* or *C. posadasii* microscopically, culturally, or by PCR or animal inoculation. Guinea pigs inoculated with *C. immitis* die from the systemic infection, whereas no evidence of infection is apparent after inoculation with *Blastomyces*. Intradermal testing with coccidioidin or spherulin has largely been replaced by serologic testing. A positive reaction of the delayed tuberculin type develops early and remains high in those who resist the disease well. A negative skin test occurs with dissemination.

## Immunology

Precipitin, latex agglutination, immunodiffusion, a widely used nuclei acid hybridization test, and complement fixation serologic tests have been developed. The precipitin, immunodiffusion, enzyme-linked immunosorbent assay (ELISA), and latex agglutination tests are useful in recent infection because a maximum titer is reached in 1–2 weeks. They permit detection of coccidioidal IgM in early coccidioidomycosis. In later infections, the complement fixation test is useful. In primary coccidioidomycosis, the titer is low, whereas in subsequent dissemination, there is a rapid rise in titer. When the disease has disseminated, cerebrospinal, synovial, and peritoneal fluid can be tested for coccidioidal antibody. The *Coccidioides*-specific ELISA detects antigenuria in about 70% of patients with coccidioidomycosis and is negative in more than 99% of controls without fungal infections. Cross-reactions with other systemic mycoses occur in 10.7% of patients. An isolated positive enzyme immunoassay (EIA) IgM test usually means disseminated disease. Serologic titers may be falsely negative in patients receiving immunosuppressive therapy.

## Treatment

Fluconazole, 400–800 mg/day, or itraconazole, 200 mg three times daily, have similar efficacy in progressive nonmeningeal disease. Treatment must be continued for 12 to 18 months. Many patients will require ongoing suppressive therapy. In patients infected with HIV, lifetime suppressive doses of 200 mg/day are advised, and potent antiretroviral therapy is associated with improved outcomes. In coccidioidomycotic meningitis, fluconazole, 400–1000 mg/day, or itraconazole plus intrathecal amphotericin B is given, with the azole therapy continued indefinitely. Liposomal amphotericin is effective in animal models of meningeal disease without the need for intrathecal administration. Newer agents that have activity against *C. immitis* include voriconazole, caspofungin, and posaconazole. Voriconazole has been used successfully in meningeal disease. These are second-line agents. Azole resistance has been reported and should be suspected in patients with refractory disease.

**Adam RD, et al:** The spectrum and presentation of disseminated coccidioidomycosis. *Am J Med* 2009; 122:770–777.

**Ampel NM:** New perspectives on coccidioidomycosis. *Proc Am Thorac Soc* 2010; 7:181–185.

**Carpenter JB, et al:** Clinical and pathologic characteristics of disseminated coccidioidomycosis. *J Am Acad Dermatol* 2010; 62:831–837.

**Cummings KC, et al:** Point-source outbreak of coccidioidomycosis in construction workers. *Epidemiol Infect* 2010; 138:507–511.

**Fernandez-Flores A, et al:** Morphological findings of deep cutaneous fungal infections. *Am J Dermatopathol* 2014; 36:531–553.

**Kim MM, et al:** Treatment of refractory coccidioidomycosis with voriconazole or posaconazole. *Clin Infect Dis* 2011; 53:1061–1066.

**Masannat FY, et al:** Coccidioidomycosis in patients with HIV-1 infection in the era of potent antiretroviral therapy. *Clin Infect Dis* 2010; 50:1–7.

**Miller SS, et al:** Disseminated coccidioidomycosis in a patient managed with adalimumab for Crohn's disease. *Nat Rev Gastroenterol Hepatol* 2010; 7:231–235.

**Ondo AL, et al:** Primary cutaneous coccidioidomycosis. *Clin Exp Dermatol* 2010; 35:e42–e43.

**Tessari G, et al:** Incidence and clinical predictors of primary opportunistic deep cutaneous mycoses in solid organ transplant recipients. *Clin Transplant* 2010; 24:328–333.

**Vin DC, et al:** Refractory disseminated coccidioidomycosis and mycobacteriosis in interferon-gamma receptor 1 deficiency. *Clin Infect Dis* 2009; 49:e62–e65.

**Welsh O, et al:** Coccidioidomycosis. *Clin in Dermatol* 2012; 30: 573–591.

## HISTOPLASMOSIS

Histoplasmosis is caused by inhalation of airborne spores. It may be asymptomatic or may cause limited lung disease. Dissemination to other organs, including the skin, occurs in about 1 in 2000 patients with acute infection. Immunodeficiency, old age, and systemic corticosteroids predispose to widespread disease. Donor-derived organ transplant transmission has often been documented. Cases misdiagnosed as sarcoidosis and treated with corticosteroids have disseminated widely. In disseminated disease, mucous membranes are involved much more frequently than skin. Primary cutaneous disease is exceedingly rare.

### Primary pulmonary histoplasmosis

Primary pulmonary histoplasmosis is usually a benign, self-limited form of acute pneumonitis characterized by fever,

malaise, night sweats, chest pain, cough, and hilar adenopathy. Resolution of the pneumonitis occurs rapidly, and the only residua may be calcifications in the lung and a positive skin test to histoplasmin. However, serious pneumonitis caused by histoplasmosis does occur. Such cases have been reported among cave workers in Mexico and travelers returning from Central America. A chronic pulmonary form may occur in patients with emphysema.

Approximately 10% of patients with acute symptomatic infection develop arthritis and erythema nodosum. During a large Midwestern U.S. epidemic, about 4% of patients diagnosed with histoplasmosis presented with erythema nodosum. Erythema multiforme has also been described.

### Progressive disseminated histoplasmosis

Most patients who develop this severe, progressive, disseminated form are immunocompromised or taking systemic corticosteroids. Leukemia, lymphoma, lupus erythematosus, renal transplantation, or AIDS are frequent predisposing diseases. Cases have also been reported in patients receiving low-dose methotrexate for psoriasis and in patients receiving anti-TNF therapy. Approximately 20% have no identifiable risk factor.

The reticuloendothelial system, genitourinary tract, adrenals, GI tract, adrenal glands, and heart may be involved. Ulcerations and granulomas of the oronasopharynx are the most common mucocutaneous lesions, occurring in about 20% of patients with disseminated histoplasmosis (Fig. 15-20). Beginning as solid, indurated plaques, the lesions ulcerate and become deep-seated, painful, and secondarily infected. Perianal lesions may also occur.

Skin lesions are present in approximately 6% of patients with dissemination but may occur in 10–25% of patients with AIDS and in renal transplant recipients. The morphologic patterns are nonspecific and protean, including umbilicated nodules, papules, plaques (Fig. 15-21), ulcers, cellulitis, abscesses, pyoderma, pustules, and furuncles. Demonstration of the organisms is readily made from histologic sections and cultures of the exudate. The most common manifestation in children is purpura, which usually appears a few days before death and is probably caused by severe involvement of the reticuloendothelial system, with emaciation, chronic fever, and severe GI symptoms. In the HIV-positive population, dyspnea, platelet count less than  $100,000/\text{mm}^3$ , and lactate dehydrogenase level more than twofold the upper limit of normal are poor prognostic factors and independently associated with death during the first 30 days of antifungal treatment.

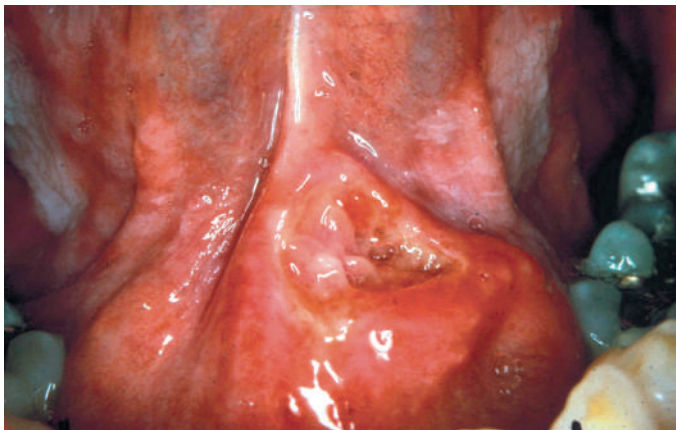

Fig. 15-20 Ulcer of disseminated histoplasmosis.

### Primary cutaneous histoplasmosis

The rare primary cutaneous form is characterized by a chancre-type lesion with regional adenopathy.

### African histoplasmosis

African histoplasmosis is caused by *Histoplasma capsulatum* var. *duboisii*. Skin lesions are much more common and include superficial cutaneous granulomas, subcutaneous granulomas, and osteomyelitic lesions with secondary involvement of the skin (cold abscesses). Papular, nodular, circinate, eczematoid, and psoriasiform lesions may be seen. The granulomas are dome-shaped nodules, painless but slightly pruritic. There may be skin and mucous membrane manifestations such as ulcerations of the nose, mouth, pharynx, genitals, and anus. These ulcers are chronic, superficial lesions with no induration or noticeable inflammatory reaction. Erythema nodosum occurs frequently. Emaciation and chronic fevers are common systemic signs.

### Etiology and pathology

Histoplasmosis was first discovered in Panama by S.T. Darling in 1905. It is caused by *H. capsulatum*, a dimorphic fungus that exists as a soil saprophyte. The organism is frequently found in bat and bird feces.

In tissue, there are 2–3  $\mu\text{m}$  round bodies within the cytoplasm of large macrophages. A pseudocapsule surrounds each organism. The organisms bear a striking resemblance to those of leishmaniasis but lack a kinetoplast and are distributed evenly throughout the cytoplasm, whereas leishmanial organisms often line up at the periphery of the cell. Budding forms may rarely be present, and mycelial and pleomorphic budding forms are sometimes seen in cavitary pulmonary disease, endocardial disease, aortic plaques, or skin lesions. Morphologically, these forms resemble *Candida* more than typical intracellular *Histoplasma*. On direct examination, the organism may be demonstrated in the peripheral blood, sputum, bronchial washings, cerebrospinal fluid, sternal marrow, lymph node touch smears, or ulcers when stained with Giemsa, PAS, or GMS. In African histoplasmosis, the organisms are 10–13  $\mu\text{m}$  in diameter and are typically found within multinucleated giant cells.

The mycelial phase may be demonstrated on Sabouraud dextrose agar, Mycosel medium, or brain-heart infusion agar to which blood has been added. A white, fluffy colony is found, with microconidia and echinulate macroconidia. One set of cultures should be inoculated at room temperature to demonstrate the mycelial phase and another at  $37^\circ\text{C}$  to produce

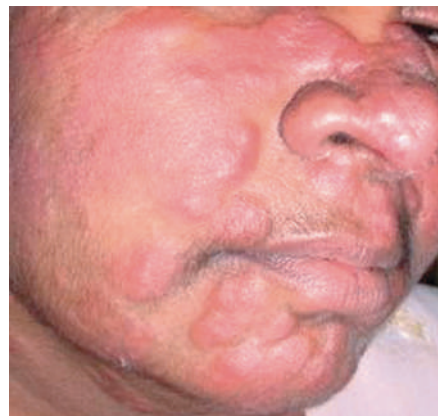

Fig. 15-21 Disseminated histoplasmosis. (Courtesy of Shyam Verma, MD.)



the yeast phase. In disseminated disease, the bone marrow is frequently involved. Blood, urine, and tissue from oral and skin lesions should also be cultured. PCR probes are available for rapid culture confirmation.

## Epidemiology

Although histoplasmosis occurs throughout the world, it is most common in North America, especially in the central U.S. states along the Mississippi River basin. Histoplasmosis is found frequently in river valley areas in the tropical and temperate zones. The Nile River Valley seems to be one exception. Besides the Mississippi and Ohio river valleys, it has been found along the Potomac, Delaware, Hudson, and St. Lawrence rivers. It has been reported in the major river valleys of South America, Central Africa, China, and Southeast Asia. The disease is heavily endemic in Puerto Rico and Nicaragua.

Transmission of the disease does not occur between individuals; instead, the infection is contracted from the soil by inhalation of the spores, especially in a dusty atmosphere. Feces of birds and bats contain the fungus. The spores have been demonstrated in the excreta of starlings, chickens, turkeys, and bats. The disease may be contracted by persons who enter caves inhabited by bats or birds. Epidemics have been reported from exposure to silos, abandoned chicken houses, and storm cellars.

In the 1978 histoplasmosis outbreak in Indianapolis, Indiana, 488 clinically recognized cases occurred, and 55 had disseminated disease. The actual number infected persons was probably well over 100,000. Nineteen died, none of whom was under age 1 year. Fatal or disseminated infections occurred in 74% of immunosuppressed persons, compared with 6.5% of those not immunosuppressed. Age over 54 was a worse prognostic factor than chronic lung disease in nonimmunosuppressed persons. Disseminated histoplasmosis is seen as an opportunistic infection in HIV-infected patients.

## Immunology

The best diagnostic test for histoplasmosis has been urinary ELISA, but PCR assays are now available and demonstrate excellent sensitivity. Serologic testing for antibodies requires that the patient has normal immune responsiveness and is further limited by a high rate of false-positive and false-negative results, especially cross-reactions with blastomycosis. The complement fixation test, when positive at a titer of 1:32 or greater, indicates active or recent infection. Because of the limitations of serologic studies, culture remains the gold standard.

## Treatment

Whereas minimal disease heals spontaneously in the majority of patients with histoplasmosis, moderate to severe disease requires therapy. Amphotericin B is the treatment of choice in severely ill patients and all immunocompromised patients. In HIV-infected patients, a suppressive dose of itraconazole, 200 mg/day, follows the IV amphotericin and may be needed as lifelong treatment. For moderate disease in immunocompetent patients, itraconazole, 200 mg three times daily for 3 days, followed by 200 mg once or twice daily depending on severity, for 9 months may be given. Most patients initially treated with amphotericin B respond quickly and can be switched to itraconazole. Voriconazole or posaconazole may be used in patients with inadequate response to this therapy.

**Akin L, et al:** Oral presentation of disseminated histoplasmosis. *J Oral Maxillofac Surg* 2011; 69:535–541.

**Buitrago MJ, et al:** A case of primary cutaneous histoplasmosis acquired in the laboratory. *Mycoses* 2011; 54:e859–e861.

**Chang P, et al:** Skin lesions of histoplasmosis. *Clin Dermatol* 2012; 30:592–598.

**Galandiuk S, et al:** Infliximab-induced disseminated histoplasmosis in a patient with Crohn's disease. *Nat Clin Pract Gastroenterol Hepatol* 2008; 5:283–287.

**Kauffman CA:** Diagnosis of histoplasmosis in immunosuppressed patients. *Curr Opin Infect Dis* 2008; 21:421–425.

**Rosaado-Odom VM, et al:** Cutaneous presentation of progressive disseminated histoplasmosis nine years after renal transplantation. *Transpl Infect Dis* 2013; 15:e64–e69.

**Sun NZ, et al:** Cutaneous histoplasmosis in renal transplant recipients. *Clin Transplant* 2014; 28:1069–1074.

**Tsiodras S, et al:** African histoplasmosis following mudbaths. *Am J Trop Med Hyg* 2012; 86:261–263.

## CRYPTOCOCCOSIS

Cryptococcosis generally begins as a pulmonary infection and remains localized to the lung in 90% of patients. In the remaining 10%, the organisms hematogenously disseminate to other organs, with the CNS and the skin the two most common secondary sites. Patients in the 10% group are usually immunocompromised or debilitated. The incidence of dissemination is much higher in patients with AIDS, occurring in up to 50% of this population.

Primary pulmonary cryptococcosis infection may be so mild that the symptoms of fever, cough, and pain may be absent. On the other hand, some cases may be severe enough to cause death. Radiographic studies will reveal disease at this stage.

When dissemination occurs, the organism has a special affinity for the CNS. Cryptococcosis is the most common cause of mycotic meningitis. The patient may have restlessness, hallucinations, depression, severe headache, vertigo, nausea and vomiting, nuchal rigidity, epileptiform seizures, and symptoms of intraocular hypertension. Other organs, such as the liver, skin, spleen, myocardium, and skeletal system, as well as the lymph nodes, may be involved. Disseminated cryptococcosis can present in many organ systems; hepatitis, osteomyelitis, prostatitis, pyelonephritis, peritonitis, and skin involvement have all been reported as initial manifestations of disease. The incidence of skin involvement in patients with cryptococcosis is 10–15%, although it is lower in the HIV-infected population. Cutaneous lesions may precede overt systemic disease by 2–8 months.

Skin infection with cryptococcosis occurs most frequently on the head and neck. A variety of morphologic lesions have been reported, including subcutaneous swellings, abscesses, blisters, tumorlike masses, molluscum contagiosum-like lesions, draining sinuses, ulcers, eczematous plaques, granulomas, papules, nodules, pustules, acneiform lesions, plaques, and cellulitis (Fig. 15-22). Approximately 50% of patients with HIV and disseminated cryptococcosis will develop molluscum contagiosum-like lesions. In these patients, there is often a central hemorrhagic crust. Lesions may first become evident in HIV-infected patients during highly active antiretroviral therapy (HAART). Solitary cutaneous lesions and indolent cellulitis may be the presenting signs of disseminated disease.

Primary inoculation cryptococcosis is a rare disease. To establish the diagnosis, there should be a clear history of implantation or a foreign body found in association with the organism. Usually, primary inoculation disease presents as a solitary skin lesion on an exposed area, frequently in the form

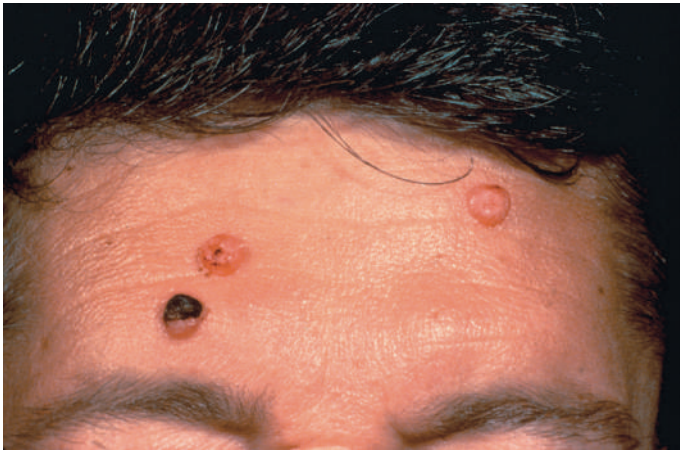

Fig. 15-22 Disseminated cryptococcosis.

of a whitlow. Risk factors include outdoor activities and exposure to bird droppings. *Cryptococcus neoformans* serotype D is more often associated with primary cutaneous disease. Although primary cutaneous disease exists, for all practical purposes, identification of cryptococci in the skin indicates disseminated disease with a poor prognosis, and it requires a search for other sites of involvement.

### Etiology and pathology

The causative organism is *C. neoformans* or in subtropical or tropical areas, *Cryptococcus gattii*. It appears in tissue as a pleomorphic budding yeast. The organisms vary greatly in size and shape, in contrast to most other fungal organisms. The capsule is usually prominent, although it is inversely proportional to the extent of the granulomatous reaction. Generally, the capsule is easily identified in hematoxylin and eosin (H&E) sections, although mucicarmine, methylene blue, or alcian blue staining can also be used. Usually, multiple yeast share a common capsule. *Cryptococcus* stains well with the Fontana-Masson stain for melanin.

### Epidemiology

Cryptococcosis has a worldwide distribution and affects both humans and animals. The organism has been recovered from human skin, soil, dust, and pigeon droppings; when deposited on window ledges in large cities, pigeon droppings are a source of infection. The patient with disseminated cryptococcosis usually has a concomitant debilitating disease, such as AIDS, cancer, leukemia, lymphoma, renal failure, hepatitis, alveolar proteinosis, severe diabetes mellitus, sarcoidosis, tuberculosis, or silicosis. Long-term oral prednisone or immunosuppressive therapy for chronic illnesses, such as renal transplantation, sarcoidosis, or connective tissue disease, may also be a factor. Cases are being reported in association with anti-tumor necrosis factor (TNF)- $\alpha$  biologic agents. The portal of entry is the lung. Males outnumber females 2:1. Cryptococcosis is most frequent in persons age 30–60 years.

Patients with AIDS are particularly at risk for disseminated disease. Cryptococcosis is the fourth leading cause of opportunistic infection and the second most common fungal opportunist, with 5–9% of patients manifesting symptomatic disease. Dissemination occurs in 50% of patients with AIDS, with skin involvement reported in 6%.

### Immunology

The latex slide agglutination test is sensitive and specific. It may give false-positive results in the presence of rheumatoid factor. Direct microscopic examination and latex agglutination have been used with lesional skin scrapings to aid in rapid diagnosis. The complement fixation test for cryptococcal polysaccharide, indirect fluorescence test, and ELISA for cryptococcal antigen detection are all helpful, although ELISA is capable of detecting the presence of antigen earlier and at a lower concentration than the other two tests.

### Mycology

For direct examination, a drop of serum or exudate is placed on a slide and a coverslip inserted. If examination shows yeast, 1 drop of 10% KOH can be added to half the coverslip and 1 drop of India ink to the other half to demonstrate the capsule.

The organism produces a moist, shiny, white colony on Sabouraud dextrose agar. With aging, the culture may turn to a cream and then a tan color. Subcultures from Sabouraud agar may be made onto cornmeal agar and urea medium to aid in distinguishing the yeast from *Candida* and other yeasts. A commercially available DNA probe detection assay allows rapid culture confirmation.

### Treatment

In seriously ill patients, amphotericin B intravenously initially, followed by fluconazole orally, is standard treatment. In less severely ill non-AIDS patients, fluconazole, 400–600 mg/day for 8–10 weeks, may be effective. In non-AIDS meningitis, flucytosine is given in combination with amphotericin B, and in patients infected with HIV, fluconazole is given indefinitely at a suppressive dose of 200 mg/day. In one study of AIDS patients with cryptococcal meningitis, 600 mg/day of fluconazole or itraconazole showed efficacy. The availability of voriconazole has expanded the number of options available. In disease refractory to other drugs, voriconazole has shown a response rate of 40%. Caspofungin has limited activity against cryptococcosis.

**Hoang JK, et al:** Localized cutaneous *Cryptococcus albidus* infection in a 14-year-old boy on etanercept therapy. *Pediatr Dermatol* 2007; 24:285–288.

**Ikeda T, et al:** Disseminated cryptococcosis-induced skin ulcers in a patient with autoimmune hepatitis. *Case Rep Dermatol* 2014; 6:98–102.

**Nasser N, et al:** Primary cutaneous cryptococcosis in an immunocompetent patient. *An Bras Dermatol* 2011; 86:1178–1180.

**Negróni R:** Cryptococcosis. *Clin Dermatol* 2012; 30:599–609.

**Pietras TA, et al:** Coexistent Kaposi sarcoma, cryptococcosis, and *Mycobacterium avium intracellulare* in a solitary cutaneous nodule in a patient with AIDS. *J Am Acad Dermatol* 2010; 62:676–680.

**Vazquez-Gonzalez D, et al:** Opportunistic yeast infections. *J Dtsch Dermatol Ges* 2013; 11:381–393.

**Wilson ML, et al:** Primary cutaneous cryptococcosis during therapy with methotrexate and adalimumab. *J Drugs Dermatol* 2008; 7:53–54.

### NORTH AMERICAN BLASTOMYCOSIS

North American blastomycosis is also known as Gilchrist's disease, blastomycosis, and blastomycetic dermatitis.

Most cutaneous blastomycosis is the result of dissemination from a primary pulmonary focus. The lesions are chronic, slowly progressive, verrucous, and granulomatous and are characterized by thick crusts, warty vegetations, discharging



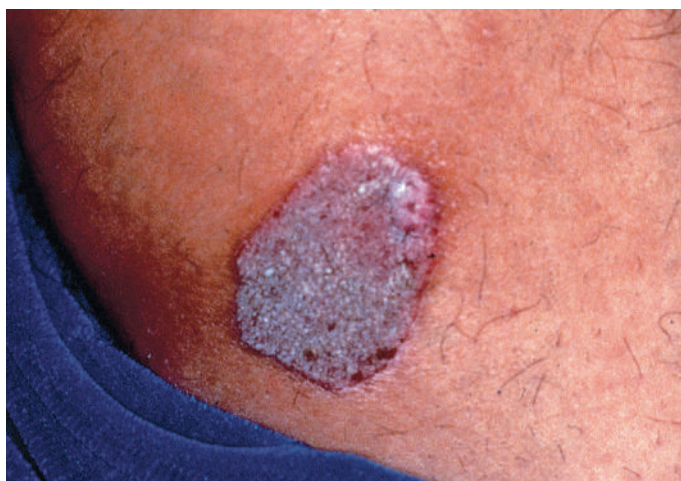

Fig. 15-23 North American blastomycosis.

sinuses, and pustules along the advancing edge (Fig. 15-23). The lesions are often multiple and are located mostly on exposed skin. Papillomatous proliferation is most pronounced in lesions on the hands and feet, where the patches become very thick. The patches tend to involute centrally and to form white scars as they spread peripherally. The crusts are thick and dirty gray or brown. Beneath the crusts, exuberant granulations are covered with a seropurulent exudate, which oozes out of small sinuses that extend down to indolent subcutaneous abscesses. Lower extremity nodules and plaques clinically and histologically suggestive of Sweet syndrome have also been described.

The primary infection is almost always in the upper or middle lobes of the lungs, and most cases of blastomycosis never develop cutaneous dissemination. When dissemination does occur, the most common site is the skin, accounting for at least 80% of cases of disseminated disease. It also frequently disseminates to bone, especially the ribs and vertebrae. Other targets are the CNS, liver, spleen, and genitourinary system.

Cutaneous blastomycosis rarely occurs as a result of primary cutaneous inoculation. Such patients have a clear history of inoculation and present with a small primary nodule and subsequent secondary nodules along the draining lymphatics, creating a picture similar to sporotrichosis. Healing takes place within several months.

### Etiology and pathology

The fungus *Blastomyces dermatitidis* causes North American blastomycosis and was first described by Gilchrist in 1894. It is frequently found in soil and animal habitats. *B. dermatitidis* is a dimorphic fungus with a mycelial phase at room temperature and a yeast phase at 37°C. Direct microscopic examination of a KOH slide of the specimen should always be made, since culture of the fungus is difficult and the organism may be found in purulent exudates obtained from skin lesions. The specimen should be cultured by a qualified laboratory on Sabouraud dextrose agar, Mycosel, and brain-heart infusion agar to which blood has been added. Aerial mycelium will develop in 10–14 days, forming a white, cottony growth that turns tan with age. The structures are septate mycelia with characteristic conidia on the sides of hyphae. The conidia are 3–5 µm and variously shaped from round to oval forms. Culture at 37°C produces a slow-growing wrinkled yeast with spherules, single budding cells, and some abortive hyphae. A DNA probe detection assay is available for rapid culture confirmation.

Cutaneous blastomycosis usually demonstrates marked pseudoepitheliomatous hyperplasia of the epidermis with neutrophilic abscesses. Giant cells are frequently present in the dermal infiltrate. Organisms are typically few in number and are most frequently found within giant cells or intraepidermal abscesses. The organism is a thick-walled yeast, usually 5–7 µm in diameter, although giant forms have been reported in tissue. *B. dermatitidis* lacks a capsule but has a thick and distinctly asymmetric refractile wall. Broad-based budding may occasionally be noted. Rarely, acute skin lesions may lack pseudoepitheliomatous hyperplasia and demonstrate a diffuse neutrophilic dermal infiltrate. They may present as cutaneous nodules, sometimes with a localized distribution.

Primary cutaneous blastomycosis demonstrates a neutrophilic infiltrate with many budding cells of blastomycetes. In later lesions, a granulomatous infiltrate is found. The lymph nodes may show marked inflammatory changes, giant cells containing the organisms, lymphocytes, and plasma cells. Lung involvement may show many changes that are suggestive of tuberculosis with tubercle formation. Purulent abscesses may occur in the lungs and bone.

### Epidemiology

North American blastomycosis is prevalent in the southeastern United States and the Ohio and Mississippi river basins, reaching epidemic proportions in Kentucky and Mississippi; the latter has the highest prevalence of blastomycosis in North America. There is a male/female ratio of approximately 6:1, and most patients are over age 60. Often, the cutaneous form occurs in patients without a known history of pulmonary lesions.

Outdoor activity after periods of heavy rain is a risk factor for acute pulmonary disease. Beaver lodges are a common site for the fungus, and some reports have linked outbreaks of disease with outings near a beaver lodge. Blastomycosis has also been reported from the bite of a dog with pulmonary blastomycosis. Transmission has been reported between men with prostatic involvement and their sexual partners.

Risk factors for symptomatic disease include preexisting illness. In one study, one quarter of patients with blastomycosis had underlying immunosuppression, including those with organ transplantation, and 22% had diabetes mellitus. In the southern states, blacks have a higher incidence than whites, and mortality is also higher among African Americans.

### Immunology

Serologic tests are performed by immunodiffusion or ELISA. Commercial antigen test kits are available for rapid diagnosis.

### Differential diagnosis

Blastomycosis may closely resemble halogenoderma, blastomycosis-like pyoderma, pemphigus vegetans, tuberculosis verrucosa cutis, syphilis, granuloma inguinale, drug eruptions, and trichophytic granuloma. The diagnosis is established by demonstration of *B. dermatitidis* or serologic testing. The course of blastomycosis is more rapid and involvement more extensive than in verrucous tuberculosis. Vegetative lesions of tertiary syphilis are usually accompanied by other signs of the disease and have a predilection for the scalp and mucocutaneous junctions. Bromide and iodide eruptions are generally more acutely inflammatory but may be indistinguishable from blastomycosis. Biopsy, drug history, and blood

iodine or bromine levels may be required to distinguish the two conditions.

## Treatment

Itraconazole, 200–400 mg/day for 6 months, is the treatment of choice for North American blastomycosis. Amphotericin B, for a total dose of 1.5 g, may be required for extremely ill patients. Some data suggest that for those with life-threatening disease, initial treatment with a lipid formulation of amphotericin B should be followed by a prolonged course of oral voriconazole. Fluconazole, 400–800 mg/day for at least 6 months, is effective in 85% of patients with non-life-threatening disease. Voriconazole has also been used alone for patients with less serious blastomycosis.

**Azar MM, et al:** Cutaneous blastomycosis masquerading as pyoderma gangrenosum. *J Clin Microbiol* 2014; 52:1298–1300.

**Brick KE, et al:** Cutaneous and disseminated blastomycosis. *Pediatr Dermatol* 2013; 30:23–28.

**Kauffman CA, et al:** Endemic fungal infections in solid organ and hematopoietic cell transplant recipients enrolled in the TRANSNET. *Transpl Infect Dis* 2014; 16:213–224.

**Lopez-Martinez R, et al:** Blastomycosis. *Clin Dermatol* 2012; 30:565–572.

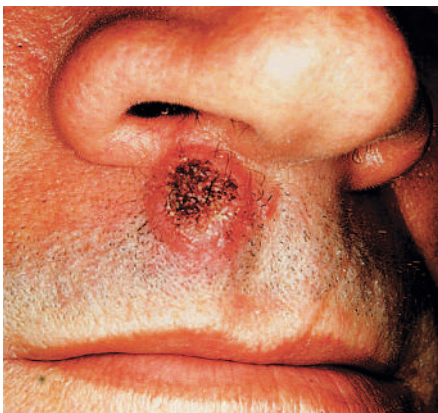**Patel AJ, et al:** Diagnosis of blastomycosis in surgical pathology and cytopathology: correlation with microbiologic culture. *Am J Surg Pathol* 2010; 34:256–261.

**Rucci J, et al:** Blastomycosis of the head and neck. *Am J Otolaryngol* 2014; 35:390–395.

## SOUTH AMERICAN BLASTOMYCOSIS

Mucocutaneous involvement in South American blastomycosis, also known as paracoccidioidomycosis, is almost always a sign of disseminated disease, primarily in the lungs. Rare cases may arise from inoculation. In Brazil, the disease causes about 200 deaths per year.

The mucocutaneous type usually begins in the mouth, where small papules and ulcerations appear. Gingival lesions are most common, followed by lesions of the tongue and lips. With time, adjacent tissues are affected, and extensive ulcerations eventually destroy the nose, lips, and face (Fig. 15-24). Skin lesions may show ulcerations, pseudoepitheliomatous hyperplasia, and microabscesses. The lymphangitic type manifests itself by enlargement of the regional lymph nodes soon after the appearance of the initial lesions about the mouth. The adenopathy may extend to the supraclavicular and axillary regions. Nodes may become greatly enlarged and break down



**Fig. 15-24** Paracoccidioidomycosis. (Courtesy of Maria Silvia Negrao, MD.)

with ulcerations that secondarily involve the skin, causing severe pain and dysphagia with progressive cachexia and death. Primary skin lesions are less common. The infection may closely simulate Hodgkin disease, especially when the suprahyoid, preauricular, or retroauricular groups of lymph nodes are involved.

There is a visceral type, caused by hematogenous spread of the disease to the liver, adrenal glands, spleen, intestines, and other organs. There is also a mixed type that has the combined symptomatology of the mucocutaneous, lymphangitic, and visceral types. South American blastomycosis may present as a rapidly progressive acute disease or follow a subacute course, or it may occur as a chronic, slowly advancing form.

## Etiology and pathology

Lutz first described South American blastomycosis in Brazil in 1908. It is caused by the fungus *Paracoccidioides brasiliensis*.

Biopsies may demonstrate pseudoepitheliomatous hyperplasia, abscess formation, or ulceration. A granulomatous inflammatory infiltrate is frequently present, consisting of lymphocytes, epithelioid cells, and Langerhans giant cells. The organism appears as a round cell, 10–60  $\mu\text{m}$  in diameter, with a delicate wall. Multiple buds may be present, creating a resemblance to a mariner's wheel.

This chronic granulomatous disease is endemic in Brazil and also occurs in Argentina and Venezuela. Occasional cases have been reported in the United States, Mexico, Central America, Europe, and Asia. Most of these patients have a travel history to endemic areas. The disease is generally found among laborers, mostly in men. Although the initial infection is usually respiratory, some individuals may become infected by picking their teeth with twigs or from chewing leaves. Armadillos may harbor the disease.

South American blastomycosis is 15 times more common in men, which is of particular interest because it has been shown that 17 $\beta$ -estradiol inhibits transition from the mycelial to the tissue-invasive yeast form. *P. brasiliensis* can lodge in periodontal tissues and some cases start after extraction of teeth. Many cases have been reported in patients with AIDS or organ transplant recipients, in whom the course is usually acute and severe.

## Mycology

In culture, the fungal colony is cream colored, compact, and powdery. Chlamydoconidia are round or oval. Elongate lateral conidia may be present.

## Immunology

Complement fixation tests are positive in 97% of severe cases, and the titer rises as the blastomycosis becomes more severe. With improvement, the titer decreases. Immunodiffusion tests are often used for diagnosis and posttherapy follow-up. The test is highly specific but only about 90% sensitive.

## Treatment

Itraconazole, 200 mg/day for 12 months, is the treatment of choice for most patients with South American blastomycosis because it is well tolerated and shows an excellent response in 85%. Ketoconazole, 400 mg/day for 6–18 months,



is equally effective but not as well tolerated. Trimethoprim-sulfamethoxazole (TMP-SMX) at 800/160 mg two to three times daily for 30 days, then 400/80 mg/day for 3–5 years, is effective in about 50% of patients, although sulfa resistance has been reported. Patients with severe disease or those intolerant to the prior therapies may respond to amphotericin B. When HIV patients are infected, lifelong therapy is the rule.

**Bonifaz A, et al:** Endemic systemic mycoses. *J Dtsch Dermatol Ges* 2011; 9:705–715.

**Borges SR, et al:** Itraconazole vs. trimethoprim-sulfamethoxazole: a comparative cohort study of 200 patients with paracoccidioidomycosis. *Med Mycol* 2014; 52:303–310.

**Marques SA.** Paracoccidioidomycosis: epidemiological, clinical, diagnostic and treatment up-dating. *An Bras Dermatol* 2013; 88:700–711.

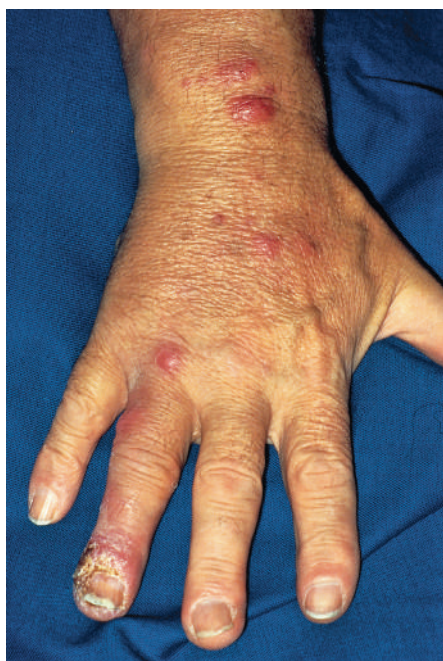**Safe IP, et al:** Extra-pulmonary manifestations of paracoccidioidomycosis associated with acquired immunodeficiency syndrome. *An Bras Dermatol* 2014; 89:150–153.

**Zavascki AP, et al:** Paracoccidioidomycosis in organ transplant recipient. *Rev Inst Med Trop São Paulo* 2004; 46:279–281.

## SPOROTRICHOSIS

Sporotrichosis usually results from direct inoculation by a thorn, cat's claw, or other minor penetrating injury. The earliest manifestation may be a small nodule that may heal and disappear before the onset of other lesions. In the course of a few weeks, nodules generally develop along the draining lymphatics (Fig. 15-25). These lesions are at first small, dusky red, painless, and firm. In time, the overlying skin becomes adherent to them and may ulcerate. When the lesions occur on the face, the lymphatic drainage is radial, rather than linear, and secondary nodules occur as rosettes around the primary lesion.

Regional lymphangitic sporotrichosis is the common type, accounting for 75% of cases. Fixed cutaneous sporotrichosis is seen in 20% of cases and is characterized by a solitary ulcer, plaque, or crateriform nodule without regional lymphangitis (Fig. 15-26). It may also present as localized rosacea-like lesions of the face without regional lymphangitis. Increased host resistance, a smaller inoculum, facial location, and variations in strain pathogenicity have all been suggested as triggers for the



**Fig. 15-25** Sporotrichosis.

fixed cutaneous form. The distribution in children is similar to that in adults.

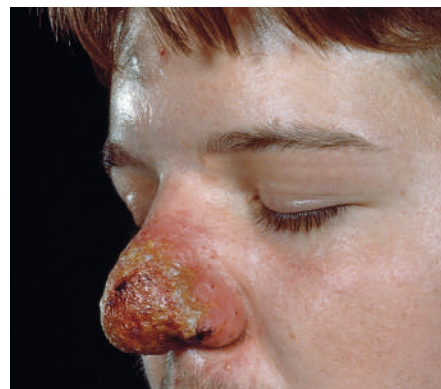Disseminated sporotrichosis is the least common form. Factors that predispose to extracutaneous disease include oral prednisone therapy, other immunosuppressive drugs (including TNF- $\alpha$  inhibitors), chronic alcoholism, diabetes mellitus, hematologic malignancies, and AIDS. Systemic invasion may produce cutaneous, pulmonary, GI, articular, and brain lesions. Arthritis or bone involvement occurs in most patients. The cutaneous lesions are reddish, tender nodules, which soften, form cold abscesses, and eventually suppurate, leaving chronic ulcers or fistulas. These are usually around arthritic joints and the face and scalp, but may occur anywhere on the skin. At times, only internal involvement is apparent.

## Etiology and pathology

Sporotrichosis is caused by the *Sporothrix schenckii* complex, with more than six species identified by molecular techniques. These fungi are dimorphic in that they grow in a yeast form at 37°C and in a mycelial form at room temperature. Cutaneous disease typically presents with palisading granulomatous dermatitis surrounding a stellate suppurative abscess. Organisms appear as cigar-shaped yeast in tissue but are rarely seen in North American cases. In Asian cases of sporotrichosis, the organisms are frequently more numerous. Asteroid bodies and mycelial elements are prevalent in regional lymphangitic sporotrichosis. PCR methods of detection have been developed.

## Epidemiology

There seems to be no geographic limitation to the occurrence of sporotrichosis. Most often, the primary invasion is seen as an occupational disease in gardeners, florists, and laborers following injuries by thorns, straw, or sphagnum moss. The pathogen typically lives as a saprophyte on grasses, shrubs, and other plants. Carnations, rose bushes, barberry shrubs, and sphagnum moss are common sources. High humidity and high temperature favor infection. Experimentally, it has been produced in many laboratory animals, and spontaneous cases have been observed in horses, mules, dogs, cats, mice, and rats. In cats, sporotrichosis usually produces disseminated disease. The organism may be found on the claws and may be transmitted to humans through cat scratches. Epidemics related to cat exposure have been documented. This is becoming the most common mode of transmission in many areas of the world. Multiple family members or veterinary workers may be infected by a single cat.



**Fig. 15-26** Fixed cutaneous sporotrichosis.

## Mycology

On Sabouraud agar, a moist, white colony develops within 3–7 days. The surface becomes wrinkled and folded. Later, the culture turns tan and ultimately black because the organism is capable of producing melanin. In slide culture preparations, the colony shows septate branching mycelia. Conidia are found in clusters or in sleeve-like arrangements on delicate sterigmata. If the culture is grown at 37°C, grayish yellow, velvety yeastlike colonies are produced. Cigar-shaped, round or oval, budding cells, hyphae, and conidia may be seen microscopically.

## Immunology

Culture extracts from *S. schenckii*, known as sporotrichins, will produce a delayed tuberculin-type reaction in persons who have had sporotrichosis. The test is fairly reliable but only indicates previous exposure. Agglutination testing has been developed, but clinical diagnosis, biopsy, and culture remain the most common means of establishing a diagnosis.

## Differential diagnosis

Demonstration by culture establishes the diagnosis, and it is important to differentiate sporotrichosis from other lymphangitic infections. Atypical mycobacteriosis (especially *Mycobacterium marinum*), leishmaniasis, and nocardiosis all produce lymphangitic spread. In contrast, tuberculosis, cat-scratch disease, tularemia, glanders, melioidosis, lymphogranuloma venereum, and anthrax produce ulceroglandular syndromes (ulcer with regional lymphadenopathy rather than ulcer with nodules along lymphatic vessels).

## Treatment

Itraconazole is effective for cutaneous and lymphocutaneous sporotrichosis at a dose of 200 mg/day for 2–4 weeks after all lesions have resolved, usually 3–6 months. If there is no response, the dose may be doubled, or terbinafine, 500 mg two times daily, is a further option. Lesser doses of itraconazole, 100 mg/day, and terbinafine, 250 mg/day, have been used with excellent cure rates.

For cutaneous forms, potassium iodide, 3–6 g/day, remains an effective and inexpensive therapeutic option and may be effective when itraconazole therapy fails. Decades of experience demonstrate the effectiveness of potassium iodide despite the absence of published high-level evidence. Iodide therapy usually requires 6–12 weeks of treatment. Generally, it is best to begin with 5 drops of the saturated solution in grapefruit or orange juice three times daily after meals. The drops can also be put in milk, but strong-flavored citrus juices are better at masking the taste. The dose should be gradually increased up to 40–50 drops three times daily. Potassium iodide is not suitable for pregnant women. Adverse effects of iodide therapy include nausea, vomiting, parotid swelling, acneiform rash, coryza, sneezing, swelling of the eyelids, hypothyroidism, a brassy taste, increased lacrimation and salivation, flares of psoriasis, and occasionally depression. Most of the side effects can be controlled by stopping the drug for a few days and reinstating therapy at a reduced dosage.

Application of local hot compresses, hot packs, or a heating pad twice a day has been advocated as a useful adjunct, because *S. schenckii* is intolerant to temperatures above 38.5°C (101°F).

In adult disseminated sporotrichosis, amphotericin B, given as a lipid formulation at 3–5 mg/kg daily, is recommended, followed by 200 mg twice daily for at least 1 year. In immunocompromised patients, treatment with 200 mg/day may need to be lifelong. *Sporothrix schenckii* is more sensitive to itraconazole than voriconazole or posaconazole, although the latter drugs also represent therapeutic options.

**Bonifaz A, et al:** Sporotrichosis in childhood. *Pediatr Dermatol* 2007; 24:369–372.

**De Lima Barros MB, et al:** Treatment of cutaneous sporotrichosis with itraconazole: study of 645 patients. *Clin Infect Dis* 2011; 52:e200–e206.

**Francesconi G, et al:** Terbinafine (250 mg/day): an effective and safe treatment of cutaneous sporotrichosis. *J Eur Acad Dermatol Venereol* 2009; 23:1273–1276.

**Freitas DF, et al:** Sporotrichosis in HIV-infected patients. *Med Mycol* 2012; 50:170–178.

**Gewehr P, et al:** Sporotrichosis in renal transplant patients. *Can J Infect Dis Med Microbiol* 2013; 24:e47–e49.

**Hay RJ, et al:** Outbreaks of sporotrichosis. *Curr Opin Infect Dis* 2008; 21:119–121.

**Kauffman CA, et al:** Clinical practice guidelines for the management of sporotrichosis: 2007 update by the Infectious Diseases Society of America. *Clin Infect Dis* 2007; 45:1255–1265.

**Macedo PM, et al:** New posology of potassium iodide for the treatment of cutaneous sporotrichosis. *J Eur Acad Dermatol Venereol* 2014; Sep 17.

**Schubach A, et al:** Epidemic sporotrichosis. *Curr Opin Infect Dis* 2008; 21:129–133.

**Sharon VR, et al:** Disseminated cutaneous sporotrichosis. *Lancet Infect Dis* 2013; 13:95.

**Tang MM, et al:** Cutaneous sporotrichosis. *Int J Dermatol* 2012; 51:702–708.

**Vásquez-del-Mercado E, et al:** Sporotrichosis. *Clin Dermatol* 2012; 30:437–443.

**Yamada K, et al:** Cutaneous sporotrichosis treatment with potassium iodide. *Rev Inst Med Trop São Paulo* 2011; 53:89–93.

## CHROMOBLASTOMYCOSIS

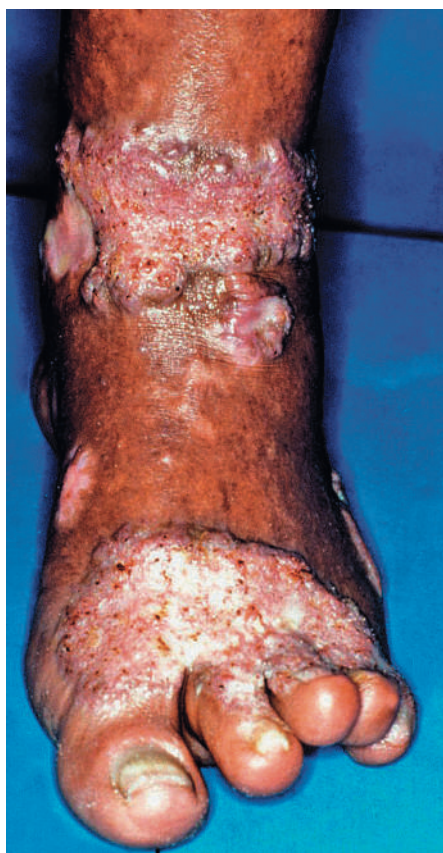Chromoblastomycosis usually affects one of the lower extremities (Fig. 15-27). It occurs as a result of direct inoculation of the organism into the skin. As a rule, lesions begin as a small, pink, scaly papule or warty growth on some part of the foot or lower leg, then slowly spread through direct extension and satellite lesions. With time, they develop a verrucous or nodular border and central atrophy and scarring. Small lesions may resemble common warts. Regional lymphadenitis may result from secondary bacterial infection, and a lymphangitic pattern of infection has been reported. In rare cases, the disease begins on an upper extremity or the face. Rarely, CNS involvement has been reported, both with and without associated skin lesions.

There is a 4:1 male predominance, and farmers account for almost 75% of patients with chromoblastomycosis. The disease is slowly progressive, and the average time between the appearance of lesions and diagnosis is almost 15 years. Lesions occur at sites of minor trauma. Squamous cell carcinoma may occur in long-standing cases.

## Etiology and pathology

Most cases are caused by one of several dematiaceous fungi. *Fonsecaea pedrosoi* is the most common cause and accounts for 90% or more of the cases reported in South America. It has also been reported as the most common cause in other parts of the world. Other agents include *Phialophora verrucosa*, *Fonsecaea compacta*, *Cladosporium carrionii*, and *Rhinocladiella aquaspersa*. *Exophiala spinifera* and *Exophiala jeanselmei* have been reported





**Fig. 15-27**  
Chromoblastomycosis.  
(Courtesy of Maria  
Silvia Negrao, MD.)

in isolated cases. Patients may have more than one organism, and cutaneous lesions caused by both paracoccidioidomycosis and chromoblastomycosis have been reported in the same patient. Patients may also have chromoblastomycosis concurrently with mycetoma or invasive phaeohyphomycosis.

Histopathologically, lesions are characterized by pseudoepitheliomatous hyperplasia with intraepidermal abscess, a dermal granulomatous reaction, and the presence of pigmented fungal sclerotic bodies. The fungi often appear in clusters that reproduce by equatorial septation, rather than by budding. The presence of sclerotic bodies (Medlar bodies, "copper pennies") rather than hyphae distinguishes the infection from invasive phaeohyphomycosis. The organisms are often seen in association with an embedded splinter. Medlar bodies are usually easily identified, but Ziehl-Neelsen and Wade-Fite stains have also been used to identify the pathogenic organisms, as has duplex PCR.

Staining for fungal antigens has demonstrated that they accumulate in macrophages and occasionally in factor XIIIa-positive dendrocytes or Langerhans cells. The immune response to the organism appears to affect the clinical and histologic presentation. Patients with verrucous plaques demonstrate a T-helper type 2 (Th2) immunologic response, whereas those with erythematous atrophic plaques have a Th1 response.

## Epidemiology

Chromoblastomycosis was first recognized in Brazil by Pedroso in 1911. Since then, it has been found in other parts of South America and the Caribbean, Madagascar, South Asia, East Asia, the United States, Russia, and many other countries. Barefooted farm workers bear the largest burden of infection. Trauma from wood products and soil exposure results in implantation of the organism, and dissemination is rare.

## Mycology

The microorganisms produce black, slowly growing, heaped-up colonies. The genera differ according to the type of conidiphore produced. All produce melanin.

## Treatment

Treatment is difficult, and chromoblastomycosis often affects those who cannot afford medication. In some series, only about 30% of patients were cured, although almost 60% improved. About 10% fail therapy, and recrudescence of the disease is noted in more than 40% of patients. Smaller lesions are best treated by surgical excision or cryotherapy. In one study of 22 patients, the number of cryosurgeries varied from 1 to 22, and treatment lasted for up to 126 months. Only three patients did not respond. If the lesions are extensive, chronic, or burrowing, itraconazole, 200–400 mg/day, is given for 6–12 months or until there is a response. Terbinafine, 500–1000 mg/day, alone or in combination with itraconazole, 200–400 mg/day, has been effective in some patients, as has posaconazole, 800 mg/day. Cryotherapy, CO<sub>2</sub> laser vaporization, PDT, and local hyperthermia are adjuncts. Combination amphotericin B and itraconazole has been used in resistant cases, as has isolated limb infusion with melphalan and actinomycin D. Despite these options, some lesions remain resistant, and amputation may be unavoidable in some patients.

**Ameen M:** Chromoblastomycosis. *Clin Exp Dermatol* 2009; 34:849–854.

**Garnica M, et al:** Difficult mycoses of the skin: advances in the epidemiology and management of eumycetoma, phaeohyphomycosis and chromoblastomycosis. *Curr Opin Infect Dis* 2009; 22:559–563.

**Krzysciak PM, et al:** Chromoblastomycosis. *Postepy Dermatol Allergol* 2014; 31:310–321.

**Naveen KN, et al:** Chromoblastomycosis presenting as a phagedenic ulcer on the face. *Int J Dermatol* 2012; 51:576–578.

**Queiroz-Telles F, et al:** Challenges in the therapy of chromoblastomycosis. *Mycopathologia* 2013; 175:477–488.

**Torres E, et al:** Chromoblastomycosis associated with lethal squamous cell carcinoma. *An Bras Dermatol* 2010; 85:267–270.

**Torres-Guerrero E, et al:** Chromoblastomycosis. *Clin Dermatol* 2012; 30:403–408.

## PHAEOHYPHOMYCOSIS

This heterogeneous group of mycotic infections is caused by dematiaceous fungi with morphologic characteristics in tissue that include hyphae, yeastlike cells, or a combination of these. This contrasts with chromomycosis, in which the organism forms round, sclerotic bodies.

There are many types of clinical lesions caused by these organisms. Tinea nigra is an example of superficial infection. Alternariosis can also present as a superficial pigmented fungal infection in immunocompetent patients. Subcutaneous disease occurs most frequently as indolent abscesses at the site of minor trauma (so called "phaeomycotic cyst"). *Exophiala jeanselmei* is the most common cause of this presentation in temperate climates. Systemic phaeohyphomycosis is largely a disease of immunocompromised patients, including solid-organ transplant recipients, although primary cerebral forms occur in immunocompetent patients. Localized forms generally result from primary inoculation of the organism into the skin. Disseminated disease may also begin as a skin infection, although catheter sepsis is a recognized cause of disseminated infection. The lesions usually appear as dry, black, leathery eschars with a scalloped, erythematous, edematous border (Fig. 15-28). *Bipolaris spicifera* is the most common cause of disseminated disease, although *Scedosporium prolificans* has

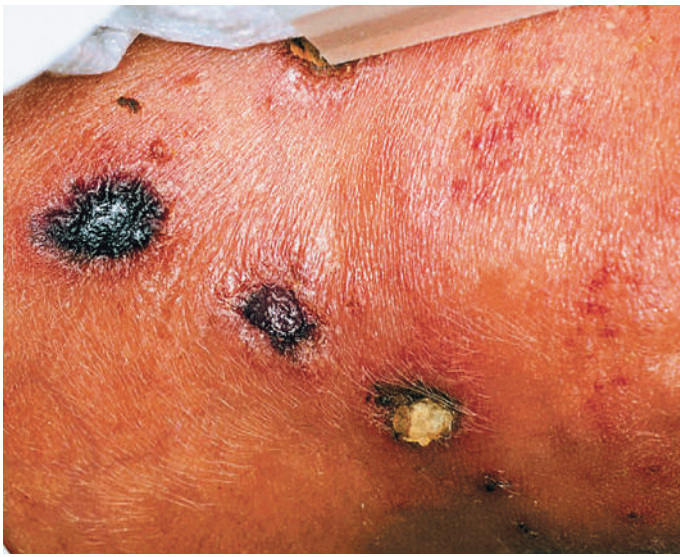

Fig. 15-28 Phaeohyphomycosis.

been reported as the most common organism in some areas. The presence of melanin in the cell wall may be a virulence factor for these fungi. Eosinophilia is noted in about 10% of patients with disseminated disease. Phaeohyphomycosis often disseminates to many organs. Endocarditis is mostly reported on porcine valves. In some series, mortality from disseminated disease is about 80%. More than half of patients with primary CNS disease have no known underlying immunodeficiency. Mortality rates from CNS infections are high regardless of immune status.

### Etiology and pathology

Many black molds are capable of causing phaeohyphomycosis, including *E. jeanselmei*, *B. spicifera*, *Alternaria* spp., *Dactylaria gallopava*, *Phialophora parasitica*, *Cladosporium sphaerospermum*, *Wangiella dermatitidis*, *Exserohilum rostratum*, *Cladophialophora bantiana*, *Wallemia sebi*, and *Chaetomium globosum*. Some fungi, such as *Phialophora verrucosa*, can cause both phaeohyphomycosis and chromoblastomycosis. Some fungi, such as *E. jeanselmei*, may cause mycetoma (characterized by grain formation) in some patients and phaeohyphomycosis or chromoblastomycosis in others.

All these organisms produce pigmented hyphae in tissue and culture, although the pigment may only be visible focally in some histologic sections. Melanin can be stained by the Fontana-Masson method, but many molds produce enough melanin to stain positive, and a positive stain should not be misinterpreted as proof of phaeohyphomycosis. Organisms as diverse as zygomycetes and dermatophytes can stain with Fontana-Masson. When hyphae appear brown in tissue, there is little question as to the diagnosis, but when the organism appears hyaline in tissue, the presence of melanin staining must be interpreted in the context of the fungal morphology. Most organisms of phaeohyphomycosis produce thick, refractile walls and have prominent bubbly cytoplasm. This contrasts with the thin, delicate walls of organisms such as *Aspergillus*, *Fusarium*, and dermatophytes. Zygomycetes are aseptate and usually appear hollow in tissue sections. Their thick, refractile wall usually stains intensely red with H&E, contrasting with the pale wall of a phaeomycotic organism. Some organisms, such as *Bipolaris*, produce round, dilated structures that resemble spores in tissue. The mix of round structures and hyphae is a helpful clue to the presence of a black mold in tissue.

### Treatment

Phaeomycotic cysts are best treated with excision. Superficial phaeohyphomycosis may respond to topical antifungal agents and superficial debridement. For invasive and disseminated disease, surgical excision should generally be combined with antifungal therapy. Itraconazole has the best record of treating this group of infections, and doses of 400 mg/day or higher are usually needed for at least 6 months. Reproducible fungal sensitivity studies are available through a few reference laboratories, but the process is slow, and patients with disseminated disease have little time to spare. Case reports indicate success with voriconazole and terbinafine or itraconazole and terbinafine. For CNS disease, posaconazole has been effective, as may combinations of amphotericin B, flucytosine, and itraconazole. Complete excision of primary brain lesions may be prudent, when possible. In widely disseminated disease, excision of lesions becomes impractical, but debulking of skin disease may be of some value.

### ALTERNARIOSIS

*Alternaria* is a genus of molds recognized as common plant pathogens but also as a cause of human infection. As a pigmented fungus, it is one cause of phaeohyphomycosis. Most reported cases of invasive infection have occurred in immunocompromised patients, with the most frequent risk factors being solid-organ transplantation and Cushing syndrome. Cutaneous alternariosis usually presents as focal ulcerated papules and plaques or pigmented patches on exposed skin of the face, forearms and hands, or knees of immunocompetent patients. Topical corticosteroids may predispose to local infection. Localized disease in immunocompetent patients may respond to local debridement, hyperthermia, wide surgical excision, or Mohs micrographic surgery. Itraconazole has been successful, although resistance has also been reported. Terbinafine, posaconazole, voriconazole, ketoconazole, caspofungin, and intralesional miconazole have also been used successfully.

**Coutinho I, et al:** Cutaneous alternariosis—a case series of an increasing phaeohyphomycosis. *J Eur Acad Dermatol Venereol* 2014; Jun 9.

**Fukai T, et al:** A case of phaeohyphomycosis caused by *Exophiala oligosperma* successfully treated with local hyperthermia. *Med Mycol J* 2013; 54:297–301.

**Isa-Isa R, et al:** Subcutaneous phaeohyphomycosis (mycotic cyst). *Clin Dermatol* 2012; 30:425–431.

**Pastor FJ, et al:** *Alternaria* infections: laboratory diagnosis and relevant clinical features. *Clin Microbiol Infect* 2008; 14:734–746.

**Schieffelin JS, et al:** Phaeohyphomycosis fungal infections in solid organ transplant recipients: clinical presentation, pathology, and treatment. *Transpl Infect Dis* 2014; 16:270–278.

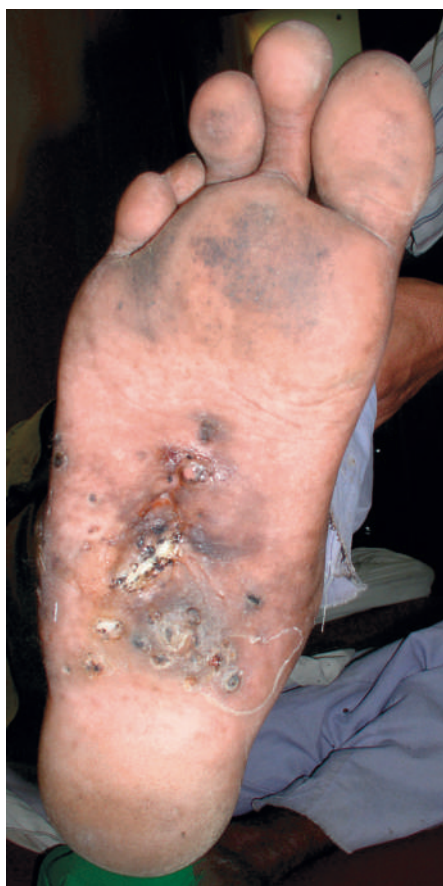**Seyfarth F, et al:** Successful treatment of cutaneous alternariosis with caspofungin in a renal transplant patient. *Mycoses* 2012; 55:457–462.

**Tong Z, et al:** Generalized subcutaneous phaeohyphomycosis caused by *Phialophora verrucosa*. *Mycopathologia* 2013; 175:301–306.

### MYCETOMA

Mycetoma, also known as Madura foot and maduromycosis, is a chronic, granulomatous, subcutaneous, inflammatory disease caused by filamentous bacteria (actinomycetoma) or true fungi (eumycetoma). The organisms enter the skin by traumatic inoculation. Both forms of mycetoma present as a triad of progressive subcutaneous swelling with sinus tracts that discharge grains (Fig. 15-29).





**Fig. 15-29** Mycetoma. (Courtesy of Shyam Verma, MD.)

The disease progresses slowly. Mycetomas generally begin on the instep or the toe webs. The lesion usually is relatively painless, nontender, and firm. The overlying skin may be normal or attached to the underlying tumor. Mature lesions often have nodules and draining sinuses. Not only the skin and subcutaneous tissues, but also the underlying fascia and bone are involved. Other parts of the body, such as the hands, arms, chest, jaw, and buttocks, may be involved. Exposed sites are most common, and lesions in covered areas are almost always actinomycetomas.

### Etiology and pathology

Mycetoma is divided into actinomycetoma, produced by bacteria, and eumycetoma, produced by true fungi. Actinomycetomas are caused by *Nocardia*, *Actinomadura*, and *Streptomyces*. Eumycetomas are caused by true fungi, including pigmented fungi such as *Madurella* spp., and hyaline fungi such as *Pseudallescheria*. Causative dematiaceous organisms include *Madurella grisea*, *M. mycetomatis*, *Leptosphaeria senegalensis*, *L. tompkinsii*, *Exophiala jeanselmei*, *Pyrenochaeta romeri*, *Phialophora verrucosa*, *Curvularia lunata*, and *C. geniculata*. The hyaline or white fungi that cause mycetoma include *Pseudallescheria boydii* (which may occasionally disseminate as the anamorph or asexual form, *Scedosporium apiospermum*), *Acremonium falciforme*, *A. ricifei*, *Fusarium moniliforme*, *F. solanii*, *Aspergillus nidulans*, and *Neotestudina rosatii*. Examples of actinomycetomas are those caused by *Nocardia asteroides*, *N. brasiliensis*, *N. caviae*, *N. otitidiscaviarum*, *Actinomadura madurae*, *Actinomadura pelletieri*, *Actinomyces israelii*, and *Streptomyces somaliensis*. *A. israelii* is the major cause of lumpy jaw, a form of mycetoma.

Almost all actinomycetomas produce light-colored grains, as do hyaline fungi. Red grains are usually produced by *A. pelletieri*. Pigmented fungi produce dark grains.

Histologic sections demonstrate stellate abscesses containing grains. Gram stain of an actinomycotic grain shows gram-positive, thin filaments, 1–2  $\mu\text{m}$  thick, embedded in a gram-negative amorphous matrix. Club formation in the periphery of a grain may be seen. Special stains for demonstration of fungi, such as PAS and GMS, will clearly show hyphae and other fungal structures within the grain. Hyphae of 2–5  $\mu\text{m}$  in thickness suggest true fungal mycetoma.

### Epidemiology

The mycetoma belt stretches between the latitudes of 15° south and 30° north. Relatively arid areas have higher rates of infection than humid areas. In the Western Hemisphere, the incidence is highest in Mexico, followed by Venezuela and Argentina. In Africa, it is found most frequently in Senegal, Sudan, and Somalia. Mycetomas are also reported in large numbers in India. Actinomycetomas outnumber eumycetomas by 3:1, which is fortunate because actinomycetomas are much more responsive to therapy. The male/female ratio varies from 2:1 to 5:1.

### Mycology

For true fungi (eumycetoma), cultures are made from the grains on Sabouraud dextrose agar containing 0.5% yeast extract and suitable antibiotics. Cultures should be incubated at 37°C and room temperature. For actinomycetes grains, culture should be made in brain-heart infusion agar, incubated aerobically and anaerobically at 37°C, and on Sabouraud dextrose agar with 0.5% yeast extract, incubated aerobically at 37°C and room temperature. The specimen for culture should be taken from a deep site, preferably from the base of a biopsy. Cultures should be processed by a reference laboratory and should not be grown in an office laboratory.

### Diagnosis

Mycetoma may be diagnosed with consideration of the triad of signs: tumefaction, sinuses, and granules. Pus gathered from a deep sinus will show the granules when examined microscopically. The slide containing the specimen should have 1 drop of 10% NaOH added and a coverslip placed on top. A biopsy may be required. Radiographs will show the bone involvement, and magnetic resonance images may show the “dot in a circle” sign, corresponding to grains.

### Treatment

Actinomycetomas generally respond to antibiotic therapy, although patients with advanced disease may also need surgery. In *A. israelii* infection, penicillin in large doses is curative. *N. asteroides* or *N. brasiliensis* is usually treated with sulfonamides. A combination of rifampicin and cotrimoxazole has also been used. Severe refractory disease may respond to imipenem.

Patients in the early stage of eumycetoma may be successfully treated by surgical removal of the area. In the more advanced stages, a combination of antifungal therapy and surgery may be successful. In some patients with eumycetoma, amputation will be necessary. Voriconazole alone or combined with surgical excision is the treatment of choice for cases caused by *P. boydii*; other options include surgery combined with itraconazole, 200 mg twice daily until clinically

well, or with posaconazole, 400 mg twice daily. *P. boydii* is not generally responsive to amphotericin.

**Ameen M, et al:** Efficacy of imipenem therapy for *Nocardia* actinomycetomas refractory to sulfonamides. *J Am Acad Dermatol* 2010; 62:239–246.

**Bonifaz A, et al:** Subcutaneous mycoses. *J Dtsch Dermatol Ges* 2010; 8:619–628.

**Castro LG, et al:** Clinical and mycologic findings and therapeutic outcome of 27 mycetoma patients from São Paulo, Brazil. *Int J Dermatol* 2008; 47:160–163.

**Gosselink C, et al:** Nocardiosis causing pedal actinomycetoma: a case report and review of the literature. *J Foot Ankle Surg* 2008; 47:457–462.

**Van de Sande WW:** Global burden of human mycetoma. *PLoS Negl Trop Dis* 2013; 7:e2550.

**Welsh O, et al:** Lobomycosis. *Ther Clin Risk Manag* 2014; 10:851–860.

## KELOIDAL BLASTOMYCOSIS (LOBOMYCOSIS OR LACAZIOSIS)

Keloidal blastomycosis was originally described by Jorge Lobo in 1931. Most cases have occurred in countries in Central and South America. One case occurred in an aquarium attendant in Europe who cared for an infected dolphin; and another in an American who had walked under the pounding water of Angel Falls on a trip to South America. In the United States, the disease has been identified in a significant proportion of dolphins inhabiting the Indian River Lagoon in Florida and estuarine waters near Charleston, South Carolina. Low albumin levels and a defective immune response are found in infected dolphins, and infection is linked to freshwater effluents emptying into the bodies of water.

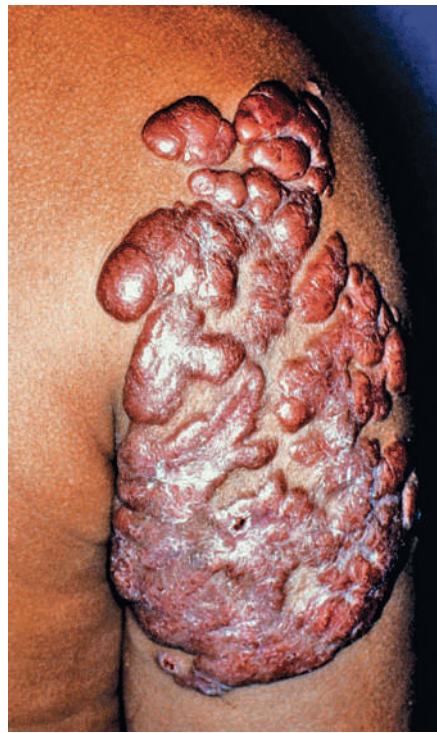Keloidal blastomycosis may involve any part of the body, and the lesions appear characteristically keloidal (Fig. 15-30). Fistulas may occur. The nodules gradually increase in size by invasion of the surrounding normal skin or through the superficial lymphatics. Long-standing cases may involve the regional lymph nodes. A common location is the ear, which may resemble the cauliflower ear of a boxer. Disseminated disease has also been described.

The fungus is probably acquired from water, soil, or vegetation in forested areas where the disease is prevalent. Agricultural laborers have been most frequently affected, with 90% of cases occurring in men.

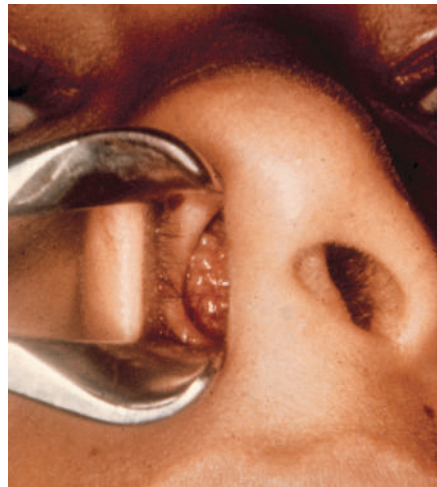The causative organism, *Lacazia loboi*, is an obligate parasite. Culture has not been successful, but the organism can grow in mouse footpads. Histologically, the epidermis is atrophic. The organisms are thick-walled, refractile spherules, larger than those of *P. brasiliensis*. One or two buds may be seen, but never multiple budding as in *Paracoccidioides brasiliensis*. The organisms are typically numerous and appear in chains of spheres connected by short, narrow tubes. The cellular infiltrate is composed of histiocytes, giant cells, and lymphocytes. In dolphin tissue, the organism appears significantly smaller than in human tissue. This may be a manifestation of the host response or may indicate that the organism in the two hosts may not be identical.

Surgical excision of the affected areas may be curative when the lesions are small, but recurrence is common. Complete resolution of keloidal blastomycosis has been reported in a patient treated for 1 year with a combination of itraconazole, 100 mg/day, and clofazimine, 100 mg/day. Combination therapy with excision, itraconazole, and cryotherapy has also been reported.

**Carneiro FP, et al:** Lobomycosis: diagnosis and management of relapsed and multifocal lesions. *Diagn Microbiol Infect Dis* 2009; 65:62–64.



**Fig. 15-30**  
Lobomycosis.  
(Courtesy of Maria  
Silvia Negrao, MD.)



**Fig. 15-31**  
Rhinosporidiosis.

**Francesconi VA, et al:** Lobomycosis. *Ther Clin Risk Manag* 2014; 10:851–60.

**Francesconi F, et al:** Lobomycosis. *N Engl J Med* 2012; 364:e2.

**Paniz-Mondolfi A, et al:** Lobomycosis. *Mycoses* 2012; 55:298–309.

**Talhari S, et al:** Lobomycosis. *Clin Dermatol* 2012; 30:420–424.

## RHINOSPORIDIOSIS

Rhinosporidiosis is a polypoid disease usually involving mucosal surfaces, especially the nasal mucosa (Fig. 15-31). Conjunctival, lacrimal, oral, and urethral tissues may also be involved, and genital lesions may resemble condylomata. The lesions begin as small papillomas and develop into pedunculated tumors with fissured and warty surfaces. Grayish white flecks may be noted on the tissue, corresponding to transepithelial elimination of large sporangia. Bleeding occurs easily. Disseminated cutaneous lesions are rare. Conjunctival lesions begin as small, pinkish papillary nodules, which later become larger, dark, and lobulated. Rectal and vaginal lesions have been reported. As with penile lesions, they may resemble condylomata or polyps. Widespread dissemination rarely occurs,



and bone involvement has been described. The disease is endemic in Sri Lanka and India but also occurs in parts of East Asia and in Latin America. Rhinosporidiosis has been seen in the southern United States, the United Kingdom, and Italy.

*Rhinosporidium seeberi*, a lower aquatic fungus found in stagnant water, is the causative organism. The organisms appear as spherules 7–10 µm in diameter, which are contained within large, cystic sporangia that may be as large as 300 µm in diameter. When the organism does not form endospores, it resembles *Coccidioides immitis* spherules, but differs by the regular presence of a central nucleus within each organism. The organisms are usually present within a polypoid structure. A granulomatous response is seen in about 50% of patients, and gigantic foreign body giant cells can rarely be noted filled with organisms.

Suppurative inflammation may be observed at the site of rupture of sporangia. Transepithelial elimination of sporangia is common. Destruction of the involved area by excision or electrocautery is the most common method of treatment. Antifungal agents have been of little value. Culture of the organism is easiest when it is grown together with the cyanobacterium *Microcystis aeruginosa*. These are unicellular prokaryotic organisms found in pond water together with *R. seeberi*. The two organisms have also been shown to grow together in tissue, suggesting that rhinosporidiosis may represent a synergistic infection of the fungus and cyanobacterium. Drugs such as ciprofloxacin are active against *M. aeruginosa*, so trials of antibiotic therapy may be of value.

**Ganne P, et al:** Conjunctival rhinosporidiosis. *JAMA Ophthalmol* 2014; Nov 6.

**Sudarshan V, et al:** Rhinosporidiosis in Raipur, Chhattisgarh: a report of 462 cases. *Indian J Pathol Microbiol* 2007; 50:718–721.

**Verma R, et al:** A case of disseminated cutaneous rhinosporidiosis presenting with multiple subcutaneous nodules and a warty growth. *Indian J Dermatol Venereol Leprol* 2012; 78:520.

## ZYGOMYCOSIS (PHYCOMYCOSIS)

There are a number of important pathogens in the class Zygomycetes. The two orders within this class that cause cutaneous infection most often are the Mucorales and Entomophthorales.

### Entomophthoromycosis

Infections caused by the order Entomophthorales have been named entomophthoromycosis, rhinoentomophthoromycosis, conidiobolomycosis, or basidiobolomycosis. Infection occurs usually in healthy individuals, and unlike mucormycosis, often runs an indolent course. The infections may be classified as cutaneous, subcutaneous, visceral, or disseminated. Subcutaneous lesions occur in two basic types, each involving different anatomic sites, either as well-circumscribed subcutaneous masses involving the nose, paranasal tissue, and upper lip, or as nodular, subcutaneous lesions located on the extremities, buttocks, and trunk.

### Etiology

*Conidiobolus coronatus* typically causes the perinasal disease, whereas *Basidiobolus ranarum* causes the type of subcutaneous disease seen on the face.

### Epidemiology

Occurrence is worldwide. Entomophthoromycosis was first reported in Indonesia, where it is prevalent. Since then, reports

have come from Africa, Asia, and the Americas. Generally, infection occurs in a belt between 15° north and 15° south of the equator.

### Diagnosis

Isolation and identification of the causative fungus are fundamental to the diagnosis. Culture on Sabouraud dextrose agar is made of nasal discharge, abscess fluid, or biopsy specimens. Biopsy specimens will show fibroblastic proliferation and an inflammatory reaction with lymphocytes, plasma cells, histiocytes, eosinophils, and giant cells. The organisms appear as broad hyphae that are generally aseptate and may be branched at right angles. The Splendore-Hoeppli phenomenon is common and appears as eosinophilic sleeves around the hyphae. Pythiosis, caused by *Pythium insidiosum*, a primitive aquatic hyphal organism that acts as a zoonotic pathogen, may affect humans and has a similar appearance.

### Treatment

Potassium iodide has been the drug of choice for entomophthoromycosis, although amphotericin B, cotrimoxazole, ketoconazole, itraconazole, and fluconazole have also been used successfully. Excision of small lesions is an alternative method of management, but the recurrence rate is significant. Rare human cases of pythiosis have responded to amphotericin B.

## Mucormycosis

Mucormycosis refers to infections caused by the order Mucorales of the class Zygomycetes. When invasive, infections characteristically are acute, rapidly developing, and often fatal. In some series, mortality is about 80%. Most infections occur in ketoacidotic patients with diabetes, but leukemia, lymphoma, AIDS, iatrogenic immunosuppression in transplant patients, chronic renal failure, and malnourishment all predispose to these infections. Infection has also been associated with methotrexate, prednisone, and infliximab therapy. Healthy individuals may also develop these infections. In them, primary cutaneous disease occurs often after trauma, burns, or as a result of contaminated surgical dressings.

The five major clinical forms of mucormycosis (rhinocerebral, pulmonary, cutaneous, GI, disseminated) all demonstrate vasculotropism of the organisms. This leads to infarction, gangrene, and the formation of black, necrotic, purulent debris. Ulceration, cellulitis, ecthyma gangrenosum-like lesions, and necrotic abscesses may occur. The infection may involve the skin through traumatic implantation or by hematogenous dissemination.

### Etiology

The fungi that cause this infection are ubiquitous molds common in the soil, on decomposing plant and animal matter, and in the air. The pathogenic genera include *Rhizopus*, *Absidia*, *Mucor*, *Cunninghamella*, *Apophysomyces*, *Rhizomucor*, *Saksenaea*, *Mortierella*, and *Cokeromyces*.

### Diagnosis

Tissue obtained by biopsy or curettage is examined microscopically and cultured. Prompt diagnosis of mucormycosis is essential in this rapidly fatal infection. Histologically, the organism generally appears as eosinophilic, thick-walled hyphae that look hollow in cross section. The organism is quite irregular in outline, and right-angle branching is common. The

organisms are highly vasculotropic and dissect along the media of muscular vessels, resulting in infarction of tissue.

## Treatment

A combination of excision of affected tissue and antifungal therapy, usually with liposomal amphotericin B, is necessary in most patients with mucormycosis. The alternative is posaconazole, 400 mg twice daily with meals. Very limited disease may be treated with excision alone, but this approach may be risky.

Mohs micrographic surgery has been used for margin control during excision of infected tissue. This approach may be curative in primary cutaneous disease in an immunocompetent patient. The speed of interpretation of each stage and the potential for tissue conservation are advantages of this method. Fungal stains, such as GMS, have been used in this setting, but zygomycetes show variable staining with fungal stains. Often, H&E is the optimal stain, and the organisms may stain avidly with a tissue Gram stain.

**Davuodi S, et al:** Fatal cutaneous mucormycosis after kidney transplant. *Exp Clin Transplant* 2014; Nov 5.

**El-Shabrawi MH, et al:** Entomophthoromycosis: a challenging emerging disease. *Mycoses* 2014; Oct 16.

**Gordon CL, et al:** Entomophthoromycosis caused by *Basidiobolus ranarum* in tropical northern Australia. *Pathology* 2012; 44:375–379.

**Krajaejun T, et al:** Clinical and epidemiological analyses of human pythiosis in Thailand. *Clin Infect Dis* 2006; 43:569–576.

**Petrikkos G, et al:** Epidemiology and clinical manifestations of mucormycosis. *Clin Infect Dis* 2012; 54(Suppl 1):S23–S34.

**Rüping MJ, et al:** Forty-one recent cases of invasive zygomycosis from a global clinical registry. *J Antimicrob Chemother* 2010; 65:296–302.

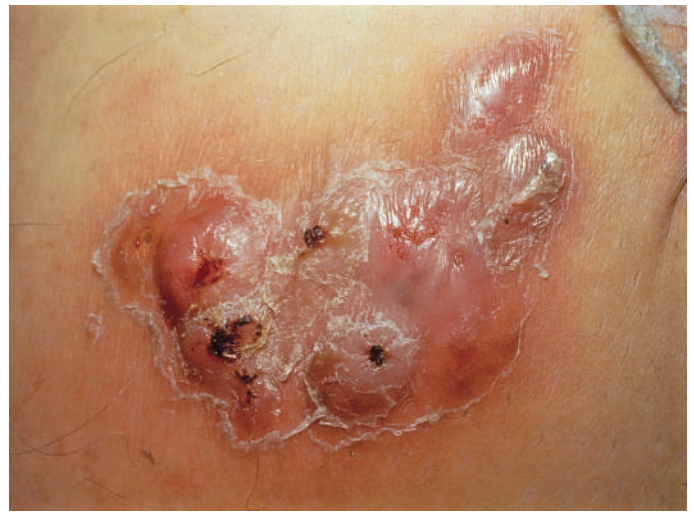**Skiada A, et al:** Global epidemiology of cutaneous zygomycosis. *Clin Dermatol* 2012; 30:628–632.

**Skiada A, et al:** Diagnosis and treatment of mucormycosis in patients with hematological malignancies. *Haematologica* 2013; 98:492–504.

## HYALOPHYCOMYCOSIS

The term hyalohyphomycosis contrasts with phaeohyphomycosis and refers to opportunistic mycotic infections caused by nondematiaaceous molds. Most of these organisms are septate, and compared with black molds, most have delicate walls. Organisms include *Penicillium*, *Acremonium*, *Trichoderma*, *Scedosporium*, and *Paecilomyces*. Disseminated infections with *Scedosporium apiospermum* (asexual form of *Pseudallescheria boydii*) are also grouped in this category. Some authors use the term broadly to encompass infections with all light-colored molds, including *Fusarium*. Although *Aspergillus* is a light-colored mold that appears similar in tissue to other forms of hyalohyphomycosis, it is usually grouped separately, because organisms other than *Aspergillus* are more likely to cause wide dissemination and CNS disease in some reported series.

These organisms are ubiquitous; they occur as saprophytes in soil or water or on decomposing organic debris. They generally do not cause disease except in immunocompromised patients. *Fusarium solani* (keratomycosis) and *Fusarium oxysporum* (white superficial onychomycosis) are exceptions. Localized hyalohyphomycosis has also occurred in immunocompetent patients after traumatic implantation. There is no classic clinical morphology to the lesions, but keratotic masses, ulcerations, ecthyma gangrenosum-like lesions, erythematous nodules, dark eschars, and disseminated erythema have been described (Fig. 15-32).



**Fig. 15-32** Hyalohyphomycosis caused by *Paecilomyces*. (Courtesy of Dan Loo, MD.)

*Penicillium marneffeii* infection is an indicator of HIV disease, especially in Southeast Asia. This organism is dimorphic and appears in tissue as small, intracellular organisms within histiocytes. The histologic similarity to histoplasmosis is striking.

Most of these infections are treated with a combination of excision and amphotericin B. *Scedosporium* and *Paecilomyces* respond in some cases to voriconazole or posaconazole. In *Penicillium* infections in HIV patients, itraconazole is used indefinitely after initial therapy with amphotericin B.

## FUSARIOSIS

*Fusarium* has emerged as an important pathogen, especially in patients with hematologic malignancy, neutropenia, and T-cell immunodeficiency, particularly those with hematopoietic stem cell transplants and graft-versus-host disease (GVHD). Skin involvement is present in about 70% of patients, and the infection may begin in the skin and then disseminate. Many cases begin in the lungs or sinuses, then disseminate to the skin. Blood cultures usually are positive, but skin biopsies provide the highest diagnostic yield. Contaminated hospital plumbing may be a source of fusariosis. *Fusarium* has been cultured from drains, water tanks, sink faucet aerators, and shower heads. Aerosolization of *Fusarium* spp. by shower heads has been documented.

The mortality rate is high but has improved with the availability of new antifungal agents. Neutropenia, a factor predicting mortality, must be controlled with colony-stimulating factors. Liposomal amphotericin B is the drug of choice; voriconazole and posaconazole are second-line drugs. Posaconazole can raise calcineurin inhibitor levels in the blood, and these must be closely monitored during therapy.

## ASPERGILLOSIS

Aspergillosis is second only to candidiasis in frequency of opportunistic fungal disease in patients with leukemia and other hematologic neoplasia. Neutropenia remains the key risk factor for invasive aspergillosis in this population. Lymphocytes, especially NK cells, are also critical in host defense, and immunosuppressive agents create a risk of infection. Other risk factors include prolonged corticosteroid therapy, GVHD, and cytomegalovirus infection. Solid-organ transplant



patients are also predisposed to *Aspergillus* infections. Pulmonary involvement is usually present in invasive disease; skin lesions are present in only about 10% of patients. Biopsy of a skin lesion may establish the diagnosis when other studies have failed. Blood culture is an insensitive method of diagnosis.

*Aspergillus fumigatus* is the most common cause of disseminated aspergillosis with cutaneous involvement. The organism grows on media without cycloheximide in 24 h or longer. In tissue, the organisms appear as slender hyphae with delicate walls and bubbly cytoplasm. The appearance is identical to that of *Fusarium*, except for the lack of vesicular swellings along hyphae. The hyphae in both are septate with 45-degree branching. Both tend to be vasculotropic and are associated with cutaneous necrosis. *Aspergillus flavus* rarely causes fungus balls in the lungs but is a common cause of fungal sinusitis and skin lesions. *Aspergillus niger* is a rare cause of disseminated infection with skin lesions. In third-degree burns, *Aspergillus* often colonizes the eschar. Deep incisional biopsies are required to distinguish invasive disease from colonization.

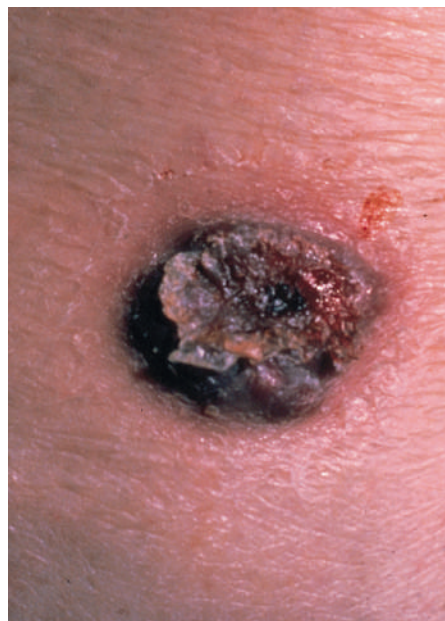### Primary cutaneous aspergillosis

Primary cutaneous aspergillosis is a rare disease. Most cases occur at the site of IV cannulas in immunosuppressed patients. Hemorrhagic bullae and necrotic ulcers may be present (Fig. 15-33). *A. flavus* is most frequently associated with this form of infection. Patients must be treated aggressively because the fungus may disseminate from the skin lesion.

*Aspergillus* is a frequent contaminant in cultures from thickened, friable, dystrophic nails, and various *Aspergillus* spp. have been implicated as true etiologic agents of onychomycosis. Nail infection may respond to itraconazole.

### Otomycosis

The ear canal may be infected by *Aspergillus fumigatus*, *A. flavus*, and *A. niger*. Pathogenic bacteria, especially *Pseudomonas aeruginosa*, are often found concurrently. The colonization may be benign, but malignant otitis may occasionally occur, especially in diabetic or iatrogenically immunosuppressed patients. Invasive disease must be treated with systemic agents. Topical clotrimazole ear drops are effective in immunocompetent patients.



**Fig. 15-33** Primary aspergillosis.

### Treatment

Voriconazole is the treatment of choice for invasive aspergillosis, although visual disturbances, photosensitivity, skin cancer, and skin eruptions can be a problem with this drug. Liposomal amphotericin B, caspofungin, micafungin, posaconazole, and itraconazole are alternate therapies.

**Das S, et al:** *Acremonium* species. *Mycopathologia* 2010; 170:361–375.

**Gardner JM, et al:** Chronic cutaneous fusariosis. *Arch Dermatol* 2005; 141:794–795.

**Karthaas M, et al:** Invasive aspergillosis. *Curr Pharm Des* 2013; 19:3569–3594.

**Keskar VS, et al:** Subcutaneous hyalohyphomycosis caused by *Fusarium* in a kidney transplant recipient. *Ren Fail* 2014; 36:1129–1132.

**Naggie S, et al:** Molds: hyalohyphomycosis, phaeohyphomycosis, and zygomycosis. *Clin Chest Med* 2009; 30:337–353.

**Ozen M, et al:** Invasive aspergillosis in children with hematological malignancies. *Expert Rev Anti Infect Ther* 2011; 9:299–306.

**Rogdo B, et al:** Primary cutaneous aspergillosis in a preterm neonate. *BMJ Case Rep* 2014; Sept 1.

**Segal BH:** Aspergillosis. *N Engl J Med* 2009; 360:1870–1884.

**Vennwald I et al:** Otomycosis. *Clin Dermatol* 2010; 28:202–211.

**Yang YS, et al:** A rare skin presentation of *Penicillium marneffei* infection in an AIDS patient. *Int J STD AIDS* 2012; 23:64–65.

### DISEASE CAUSED BY ALGAE (PROTOTHECOSIS)

Protothecosis is caused by the *Prototheca* genus of saprophytic, achloric (nonpigmented) algae. These organisms reproduce asexually by internal septation or morulation. This reproductive method, along with the absence of glucosamine and muramic acid in the cell wall, separates the genus from the bacteria and fungi. Two *Prototheca* species cause disease in humans, *Prototheca wickerhamii* and *Prototheca zopfii*. Stagnant water, tree slime, and soil appear to be the source of infection in most cases.

Skin lesions may present as verrucous lesions, ulcers, papulonodular lesions, or crusted papules with umbilication. Protothecosis of the olecranon bursa is usually seen in healthy individuals, but cutaneous infections have been most often reported in patients receiving immunosuppressive therapy and in those with renal failure, liver disease, AIDS, hematologic malignancy, or diabetes mellitus. Neutropenia is not a common risk factor.

*Prototheca* spp. are easily recognized in PAS-stained tissue specimens when the characteristic morulating cells are visible. These are more common in *P. wickerhamii*. The organism also appears with a single, black nucleus and a thick, slightly asymmetric, refractile wall. It grows on most routine mycologic media, but cycloheximide will suppress growth of *Prototheca* spp. Colonies on Sabouraud agar are smooth, creamy, and yeastlike. The use of fluorescent antibody reagents permits the rapid and reliable identification of *Prototheca* spp. in culture and tissue.

Intravenous amphotericin B remains the most effective agent for disseminated *Prototheca* infections. *P. wickerhamii* is susceptible to voriconazole in vitro, and *P. zopfii* appears susceptible to posaconazole. Itraconazole and fluconazole have been successful in individual cases. Surgery, as well as topical amphotericin B and doxycycline, has been used for isolated cutaneous disease.

**Hillesheim PB, et al:** Cutaneous protothecosis. *Arch Pathol Lab Med* 2011; 135:941–944.

**Lu S, et al:** Cutaneous protothecosis. *Int J Dermatol* 2012; 51:328–331.

**Mayorga J, et al:** Protothecosis. *Clin Dermatol* 2012; 30:432–436.



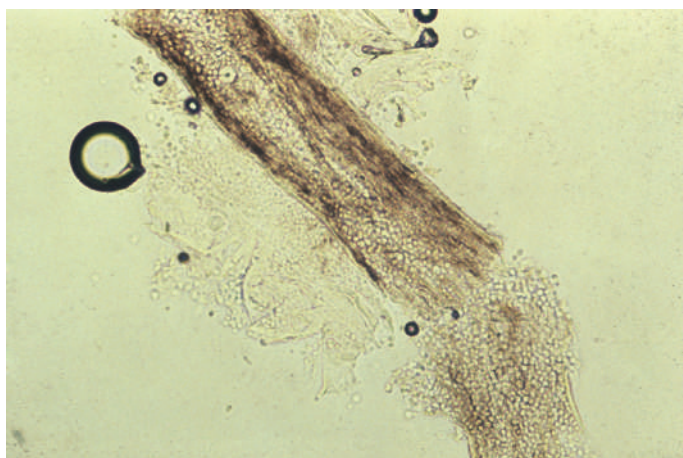
Bonus images for this chapter can be found online at [expertconsult.inkling.com](http://expertconsult.inkling.com)

**eFig. 15-1** Endothrix hair mount; note spores within the hair shaft.  
**eFig. 15-2** Id reaction.  
**eFig. 15-3** Tinea faciei.  
**eFig. 15-4** Tinea corporis.  
**eFig. 15-5** Majocchi granuloma.  
**eFig. 15-6** Tinea imbricata.  
**eFig. 15-7** Superficial white onychomycosis.  
**eFig. 15-8** Candida intertrigo.  
**eFig. 15-9** Tinea nigra.  
**eFig. 15-10** Tinea nigra; note golden color of mycelia.

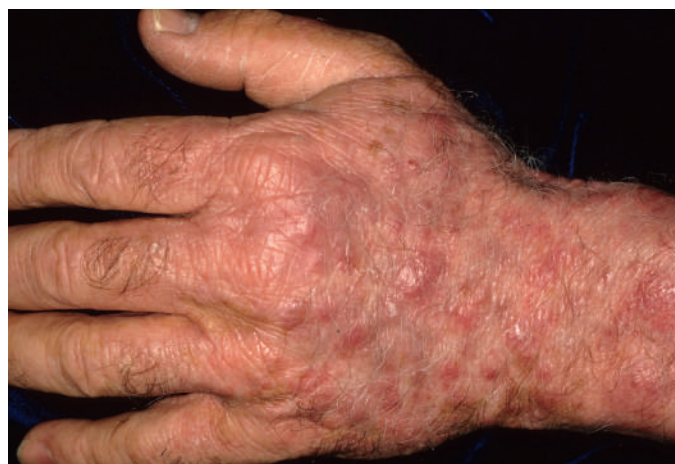**eFig. 15-11** White piedra.  
**eFig. 15-12** Tinea versicolor.  
**eFig. 15-13** Coccidioidomycosis. (Courtesy of Larry Anderson, MD, Brooke Army Medical Center Teaching File.)  
**eFig. 15-14** Molluscumlike lesions of cryptococcosis.  
**eFig. 15-15** Single budding yeast of North American blastomycosis.  
**eFig. 15-16** Paracoccidioidomycosis. (Courtesy of Maria Silvia Negrao, MD.)  
**eFig. 15-17** Paracoccidioidomycosis. (Courtesy of Maria Silvia Negrao, MD.)

**eFig. 15-18** Sporotrichosis transmitted by cat scratch.  
**eFig. 15-19** Mycetoma.  
**eFig. 15-20** Lobomycosis. (Courtesy of Maria Silvia Negrao, MD.)  
**eFig. 15-21** Lobomycosis. (Courtesy of Maria Silvia Negrao, MD.)  
**eFig. 15-22** *Paecilomyces* demonstrated histologically from biopsy. (Courtesy of Dan Loo, MD.)  
**eFig. 15-23** *Aspergillus* demonstrated microscopically.

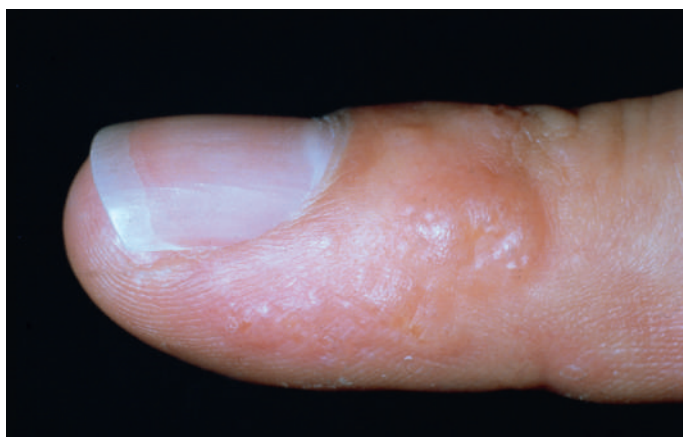



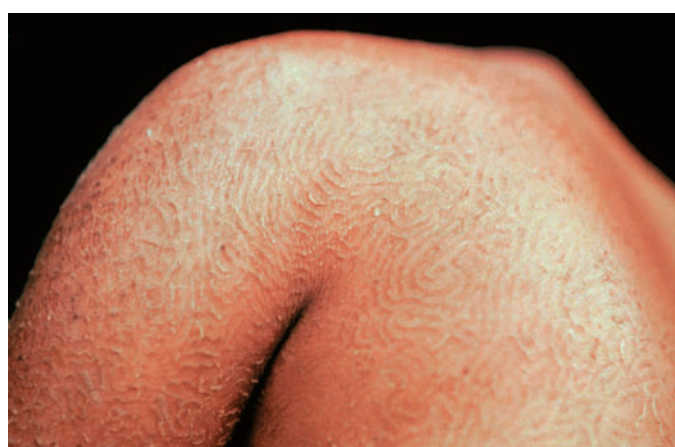**eFig. 15-1** Endothrix hair mount; note spores within the hair shaft.



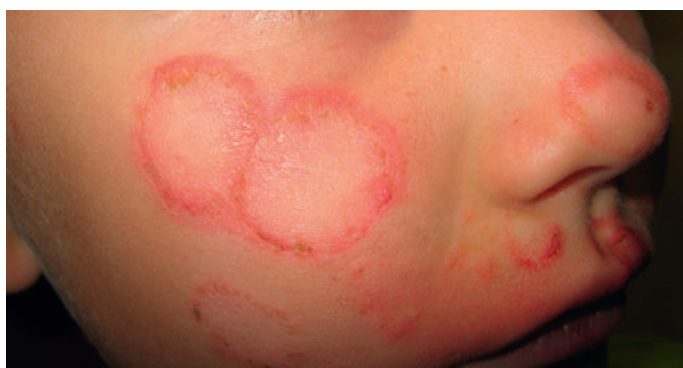**eFig. 15-5** Majocchi granuloma.



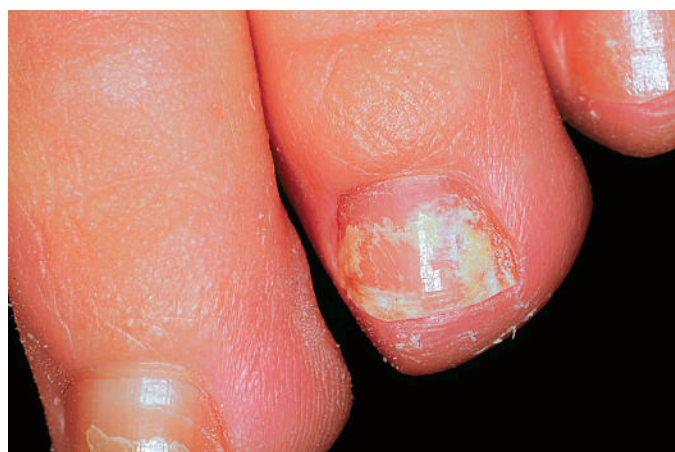**eFig. 15-2** Id reaction.



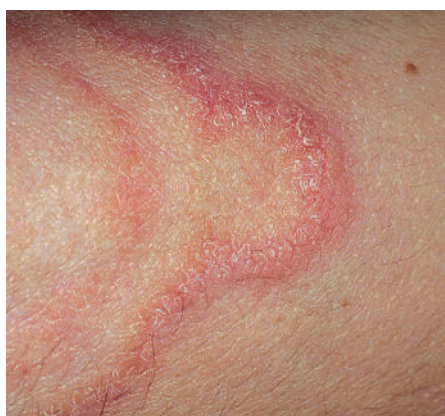**eFig. 15-6** Tinea imbricata.



**eFig. 15-3** Tinea faciei.

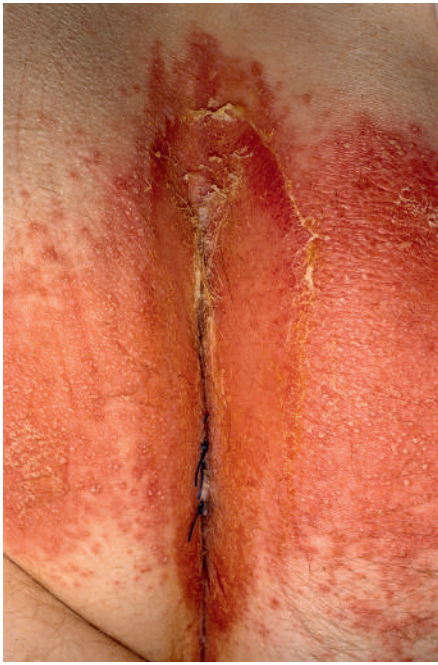

**eFig. 15-7** Superficial white onychomycosis.




**eFig. 15-4** Tinea corporis.

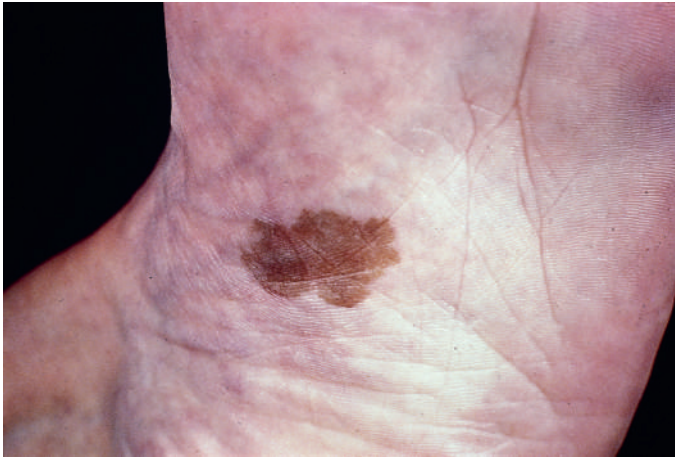




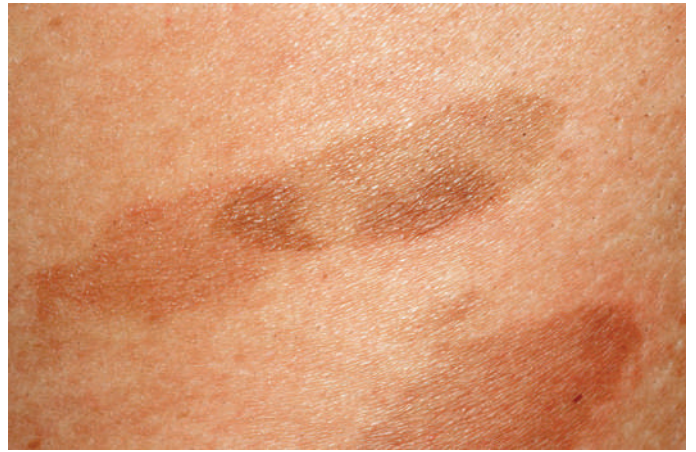
**eFig. 15-8** Candida intertrigo.



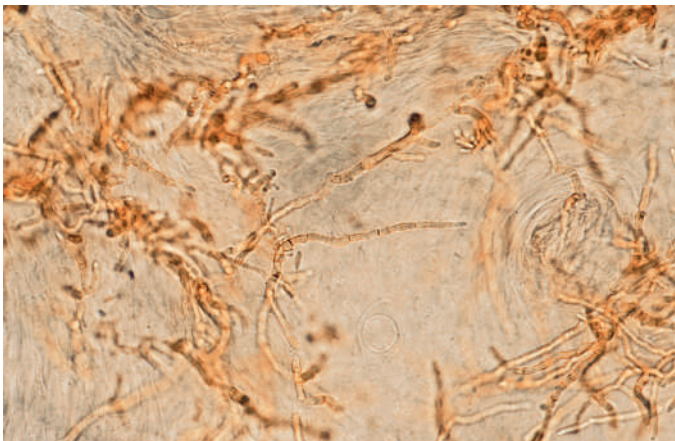
**eFig. 15-11** White piedra.



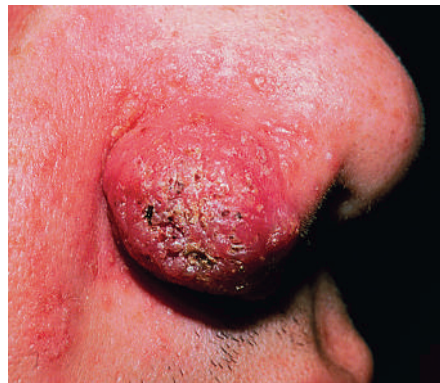**eFig. 15-9** Tinea nigra.



**eFig. 15-12** Tinea versicolor.

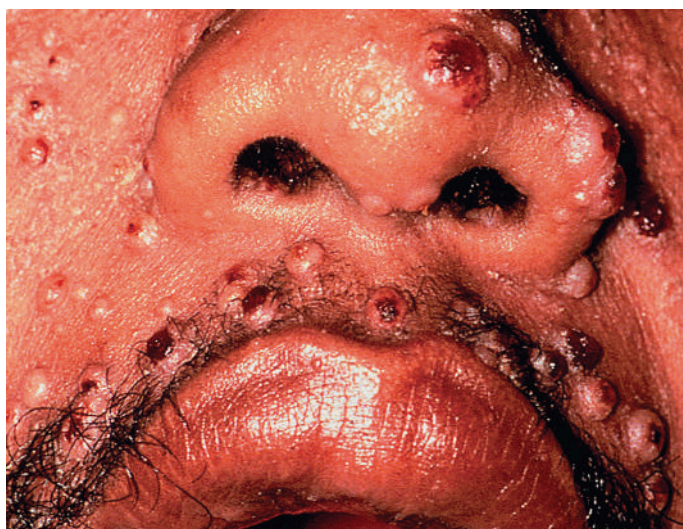

**eFig 15-10** Tinea nigra; note golden color of mycelia.

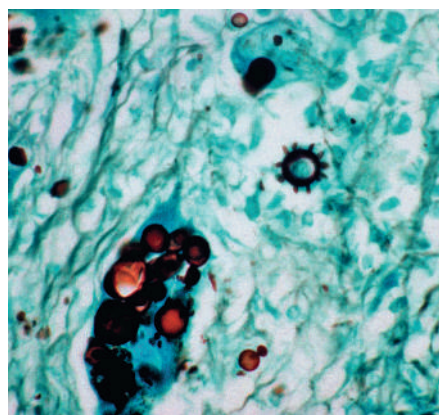


**eFig. 15-13**  
Coccidioidomycosis.  
(Courtesy of Larry Anderson, MD,  
Brooke Army Medical  
Center Teaching File.)

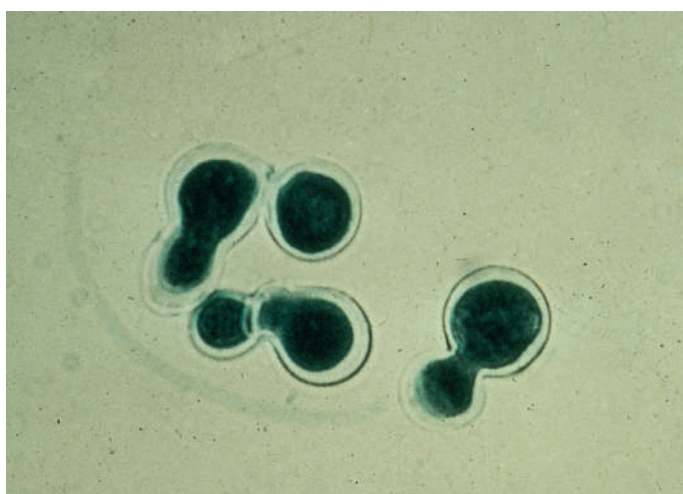




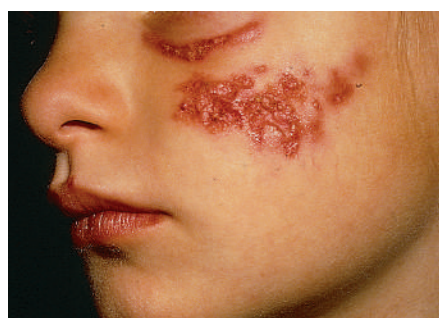**eFig. 15-14** Molluscumlike lesions of cryptococcosis.



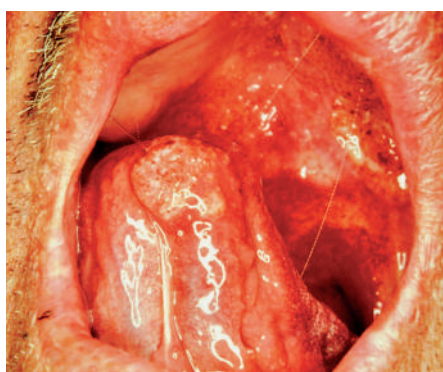
**eFig. 15-17** Paracoccidioidomycosis. (Courtesy of Maria Silvia Negro, MD.)



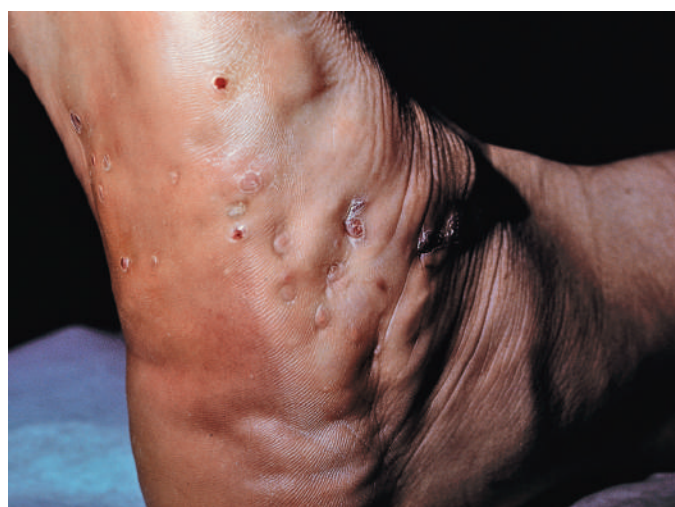**eFig. 15-15** Single budding yeast of North American blastomycosis.



**eFig. 15-18** Sporotrichosis transmitted by cat scratch.

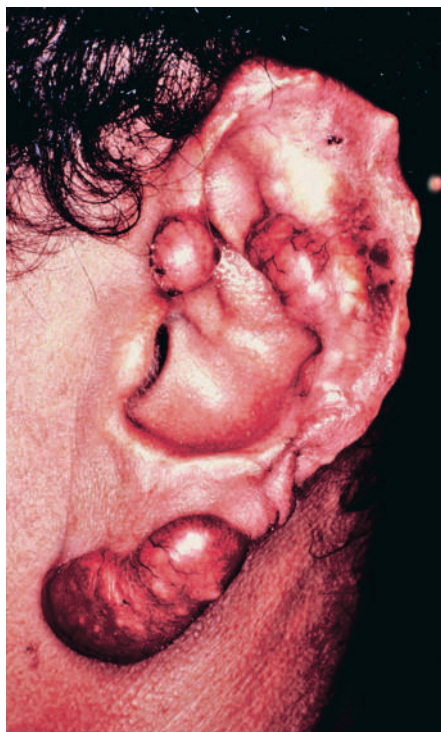

**eFig. 15-16** Paracoccidioidomycosis. (Courtesy of Maria Silvia Negro, MD.)

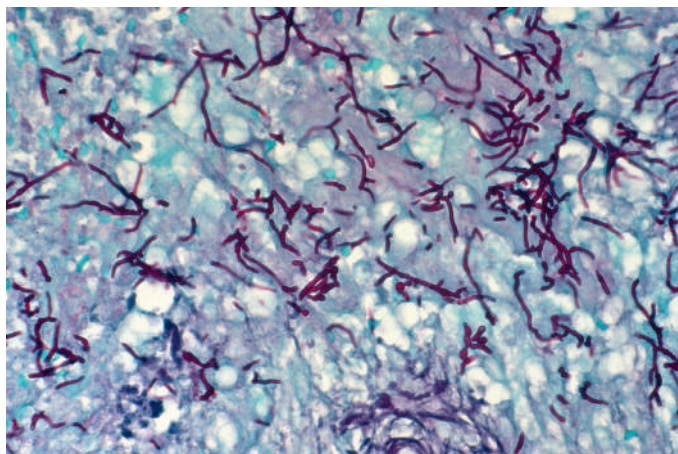


**eFig. 15-19** Mycetoma.

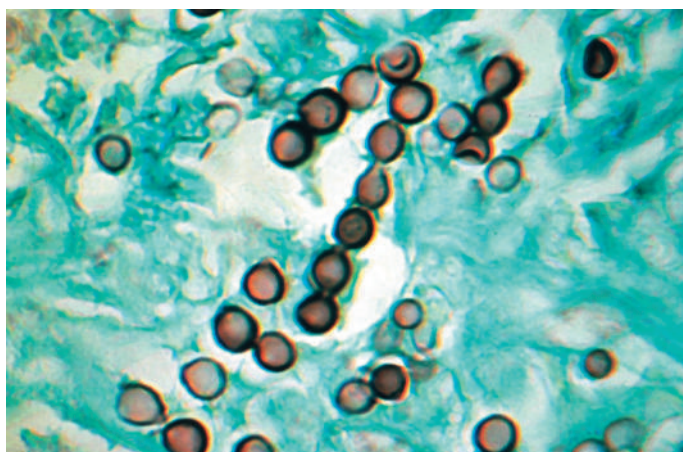




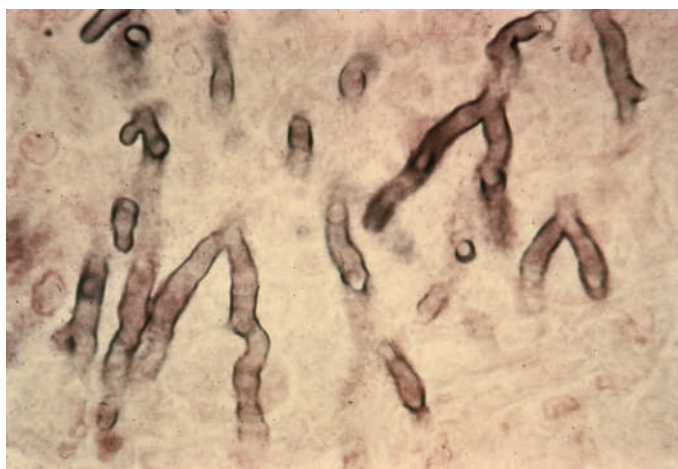**eFig. 15-20**  
Lobomycosis.  
(Courtesy of Maria  
Silvia Negrao, MD.)



**eFig. 15-22** *Paecilomyces* demonstrated histologically from biopsy.  
(Courtesy of Dan Loo, MD.)



**eFig. 15-21** Lobomycosis. (Courtesy of Maria Silvia Negrao, MD.)



**eFig. 15-23** *Aspergillus* demonstrated microscopically.





# Mycobacterial Diseases

# 16

## TUBERCULOSIS

No ideal classification scheme exists for cutaneous tuberculosis, but the system listed here is logical and takes into account the mechanism of disease acquisition. Unfortunately, unlike in Hansen's disease, these categories do not correlate perfectly to host immunity. The four major categories of cutaneous tuberculosis are as follows:

1. Inoculation from an exogenous source (primary inoculation tuberculosis, tuberculosis verrucosa cutis)
2. Endogenous cutaneous spread contiguously or by autoinoculation (scrofuloderma, tuberculosis cutis orificialis)
3. Hematogenous spread to the skin (lupus vulgaris; acute miliary tuberculosis; tuberculosis ulcer, gumma, or abscess; tuberculous cellulitis) (Lupus vulgaris can also occur adjacent to lesions of scrofuloderma, suggesting that both hematogenous spread and local spread are capable of triggering this reaction pattern.)
4. Tuberculids (erythema induratum [Bazin disease], papulonecrotic tuberculid, lichen scrofulosorum)

The finding of mycobacterial DNA by polymerase chain reaction (PCR) in tuberculids suggests that tuberculids also represent hematogenous dissemination of tuberculosis (TB), which is quickly controlled by the host, usually resulting in the absence of detectable organisms by culture and histologic methods. Miliary TB is the form with least effective host immunity. Tuberculous ulcer/abscess/cellulitis and tuberculosis cutis orificialis are conditions of poor host immunity against *Mycobacterium tuberculosis*. Bacilli are prominent in these forms of cutaneous TB, and histologic and microbiologic confirmation is usually straightforward. This is fortunate, since cellular-based diagnostic modalities (purified protein derivative [PPD], interferon- $\gamma$  release assay [IGRA]) may be negative. Tuberculosis verrucosa cutis and lupus vulgaris are conditions of high host immunity to TB, and tuberculin skin tests and IGRA for TB will usually be positive. Scrofuloderma is usually associated with a positive PPD, and identification by culture and histologic methods is positive in only 20% and 40% of cases, respectively. In its initial stage, primary inoculation TB will be multibacillary and culture positive. As host immunity develops, the skin test becomes positive, and the number of organisms on biopsy diminishes. The tuberculids also represent high host immune response manifestations of TB, and bacilli are rarely found.

## Epidemiology

The increase in the numbers of cases of TB that started in the mid-1980s in the United States was associated with three phenomena: large numbers of immigrants from high-prevalence

countries, the human immunodeficiency virus/acquired immunodeficiency syndrome (HIV/AIDS) epidemic, and an increasing number of persons in congregative facilities (shelters for homeless persons, prisons). Asians, African Americans, and Hispanics have the greatest risk for developing TB in the United States. Aggressive diagnosis and treatment programs have led to a reduction in new U.S. cases of TB. The infection rate in the U.S.-born population of adults is now at the lowest recorded, 1.5 cases per 100,000 population. However, local pockets of TB are still found in U.S. regions of otherwise very low incidence. This is partly attributable to the persistently high infection rate in the foreign-born U.S. population, which has also fallen dramatically over the years, but is still at 17.7 cases per 100,000.

In the developing world, TB is a tremendous health problem. In Africa reside 29% of all persons with TB worldwide. The incidence of TB in Africa doubled between 1990 and 2005, with new cases appearing at a rate of more than 6:1000 in some countries. This has been driven largely by the HIV/AIDS epidemic. One third or more of HIV-infected persons in Africa are also infected with *M. tuberculosis*. Latent TB is 100 times more likely to reactivate in persons with HIV infection, and HIV-infected persons are much more likely to acquire new tuberculous infection. In countries such as India, although great progress has been made, TB is still common, with 1.8 million new cases diagnosed every year, or 2 new cases per 1000 population per year. Infection rates are particularly high in India among health care workers, with 17 new cases of TB for every 1000 medical residents per year.

Tuberculosis has increasingly become resistant to first-line treatments. Strains classified as multidrug-resistant tuberculosis (MDR-TB) are resistant to at least isoniazid and rifampin. Extensively drug-resistant tuberculosis (XDR-TB) is, in addition, resistant to any fluoroquinolone and at least one of capreomycin, kanamycin, or amikacin. The emergence of these resistant strains of TB has made treatment more costly and more difficult. However, aggressive treatment protocols using multiple drugs for up to 2 years and, when indicated, surgical techniques can cure up to 60% of even XDR-TB patients.

Cutaneous TB is an uncommon complication of tuberculous infection, with less than 2% of TB patients having skin lesions, even in highly endemic areas. The types of cutaneous lesion that the patient will develop depend on the following host factors:

1. *Age*: About 25% of scrofuloderma cases and most cases of lichen scrofulosorum occur in children.
2. *Gender*: Women are 10 times more likely to develop erythema induratum, but men are two to three times more likely to have other forms of cutaneous TB.
3. *Anatomic location*: Lupus vulgaris occurs on the face and extremities, whereas tuberculosis verrucosa cutis occurs predominantly on the hands.

4. *Nutritional status:* Tuberculous abscesses and scrofuloderma are associated with malnutrition.

The pattern of cutaneous TB has been changing over the last few decades and is different in developed than in developing nations. The average age of patients with cutaneous TB has increased in developed countries, and tuberculids, especially erythema induratum, represent a larger proportion of cases. In Hong Kong, 85% of cases of cutaneous TB are tuberculids. This suggests that most cutaneous TB in adults will be found in patients infected in the distant past who are reactivating their disease, not recently infected persons. Cutaneous TB is uncommon in immunosuppressed hosts; when they acquire new TB or reactivate their TB, it usually reactivates at a non-cutaneous site and is diagnosed before skin disease occurs. Miliary TB is the most frequently reported form of cutaneous TB in the HIV-infected patient. In areas of high TB endemicity in the developing world, cutaneous TB is still common. More than 50% of cases will occur before age 19. The likelihood of finding associated systemic TB is higher in children than adults. Nonetheless, unlike in all other forms of extrapulmonary TB, failure to find an underlying focus of TB in patients with cutaneous TB can occur. Between 3% and 12% of patients with cutaneous TB will have an abnormal chest radiograph. Most often, TB of the lymph nodes will be found.

### Tuberculin testing

The tuberculin skin test (TST) is designed to detect a memory cell-mediated immune response to *M. tuberculosis*. The test becomes positive 2–10 weeks after infection and remains positive for many years, although it may wane with age. PPD preparations are currently used for testing in the United States and Canada at a dose of 5 TU (tuberculin units). The intradermal, or Mantoux, test is the standard and offers the highest degree of consistency and reliability. The test is read 48–72 h after intradermal injection. Induration measuring 5 mm or more is considered positive in HIV-infected patients, in those with risk factors for developing TB (e.g., patients who will receive anti-TNF therapy), in recent close contacts, or in those with chest x-ray findings consistent with healed TB. Because children are at increased risk of developing active TB after exposure, a 5-mm or larger reaction in contact investigations is considered positive. If the PPD measures more than 10 mm, it is considered positive in injection (intravenous) drug users (IDUs), HIV-negative IDUs, those born in foreign countries of high TB prevalence, mycobacteriology laboratory personnel, residents and employees in high-risk congregate facilities, and those with medical conditions that predispose to TB. If induration is more than 15 mm, it is positive in all others; 0–4 mm induration is negative.

The lower the threshold for positivity for the TST, the less this represents true positivity (the higher number of false-positives). This is why a TST of less than 15 mm is considered positive only in patients at higher risk for having latent TB. Conversely, as the cutoff for true positivity is raised, the number of infected persons the TST detects will decrease (the number of false-negatives increases). A TST of over 6 mm will detect 89% of persons with latent TB, over 10 mm will detect 75%, and over 15 mm will detect only 47% of latently infected patients. At least 7% of patients with latent TB will have a completely negative TST. Many intermediate TST responses may represent cross-reaction with atypical mycobacteria. Bacillus (bacille) Calmette-Guérin (BCG) immunization leads to a positive tuberculin result in immunized children, but this reaction usually does not persist beyond 10 years. Repeated BCG immunization or BCG administration after age 2 years is

more likely to result in a persistently positive TST on this basis. However, positive reactions in adults should not automatically be attributed to childhood BCG administration.

Reactivity to the tuberculin protein is impaired in certain conditions in which cellular immunity is impaired. Lymphoproliferative disorders, sarcoidosis, corticosteroid and immunosuppressive drugs (including tumor necrosis factor [TNF] inhibitors), severe protein deficiency, chronic renal failure, and numerous infectious illnesses, including HIV infection, are capable of diminishing tuberculin reactivity. In overwhelming TB (miliary disease), more than 50% of patients have a negative skin test before beginning therapy. A negative or doubtful reaction to a PPD preparation does not rule out TB infection, particularly in the patient with suggestive symptoms and signs.

Until recently, the TST had been the gold standard to confirm the presence of infection with *M. tuberculosis*. TST has significant limitations, however, including low sensitivity in persons with a compromised immune system, negative tests in a substantial number of patients with active TB (sensitivity only 77%), repeat visits to interpret, technical competence of person applying the test, booster effect of repeat testing creating potential false-positive results, and false-positive tests in persons with prior BCG vaccination. To overcome these obstacles, antigen-specific in vitro assays have been developed. These assays measure the amount of interferon (IFN)- $\gamma$  released by peripheral blood T cells (IGRAs; e.g., QuantiFERON-TB Gold, ELISpot<sup>PLUS</sup>, T-SPOT). Results are variable with respect to the sensitivity and specificity of these assays, but they appear to be valuable in certain settings. IGRAs are no more sensitive or only slightly more sensitive than TST in detecting latent TB. However, the assays are considerably more specific in the BCG-vaccinated population, in whom the TST is only 60% specific, whereas IGRAs are 93% specific. In addition, in HIV-infected patients and those receiving corticosteroids, IGRAs are much more likely to be positive than a TST in those with *M. tuberculosis* infection. The clinical settings in which TSTs and IGRAs give either false-positive or false-negative values are different. If the TST is combined with an IGRA and the tests are concordant, false-negative results are 2% and false-positive tests only 1%. This suggests that the combination of TST and IGRA would be the optimal testing to assess for *M. tuberculosis* infection (latent or active). Either the two tests can be done simultaneously, or if screening for latent TB in an otherwise immunologically normal person, TST can be applied first, then IGRA performed in all persons with a positive TST of more than 6 mm.

Appropriate screening before initiating anti-TNF therapy or immunosuppression in a dermatology patient would include the following:

1. Screen for active TB by history and physical examination (and chest x-ray where suspicion for TB is elevated).
2. Administer a TST and perhaps an IGRA.
3. Interpret the test results with caution in patients already on significant iatrogenic immunosuppressive or anti-TNF treatments.
4. Regularly monitor patients on anti-TNF agents for the development of TB with appropriate history, physical examination, and laboratory testing; and suspect and screen for TB if clinical symptoms may indicate infection.

### BCG vaccination

Bacille Calmette-Guérin is a live attenuated strain of *Mycobacterium bovis* used in most parts of the world (except North America and Western Europe) to immunize infants. It enhances immunity to TB and is effective in reducing childhood TB,



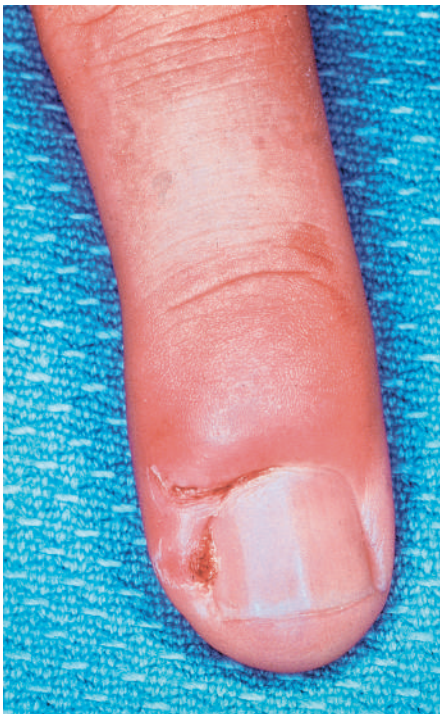especially if given to neonates. Once the patient has been vaccinated, the TST becomes positive and remains so for a period of less than 10 years (unless the person is BCG-immunized after age 2 or repeatedly immunized). In an adult who was vaccinated as a child in a foreign country with a high prevalence of TB and whose TST measures more than 10 mm, active TB should be assumed. The use of BCG instillation in the bladder to treat bladder cancer has been associated with disseminated disease, usually pneumonitis, hepatitis, prostatitis, and abdominal aneurysms.

Dermatologic complications of BCG vaccination are rarely seen. Localized abscesses and regional suppurative adenitis occur at a rate of about 0.4 per 1000 vaccines. Excessive ulceration may occur if the BCG is inoculated too deeply. Scrofuloderma is rare. Disseminated infection is seen in 1–4 cases per 1 million infants vaccinated and is associated with high mortality. Disseminated BCG develops only in the setting of immunodeficiency. Lupus vulgaris can occur rarely at the vaccination site or at a distant site and will respond to appropriate antituberculous treatment. Papular and papulonecrotic tuberculids, as well as erythema induratum, can occur after BCG immunization, appearing 10 days to several months after vaccination. Treatment may not be necessary for the BCG-induced tuberculids; they frequently heal in a few months with no treatment.

### Inoculation cutaneous tuberculosis from exogenous source

#### Primary inoculation tuberculosis (primary tuberculous complex, tuberculous chancre)

Primary inoculation TB develops at the site of inoculation of tubercle bacilli into a TB-free individual (Fig. 16-1). Regional lymphadenopathy usually occurs, completing the “complex.” It occurs chiefly in children and affects the face or extremities. The inoculation can occur during tattooing, medical injections, nose piercing, or external physical trauma. The earliest lesion,



**Fig. 16-1** Primary inoculation tuberculosis.

appearing 2–4 weeks after inoculation, is a painless brown-red papule that develops into an indurated nodule or plaque that may ulcerate. This is the tuberculous chancre. Prominent regional lymphadenopathy appears 3–8 weeks after infection and, occasionally, suppurative and draining lesions may appear over involved lymph nodes. Primary tuberculous complex occurs on the mucous membranes in about one third of patients. Spontaneous healing usually occurs within 1 year, with the skin lesion healing first, then the lymph node, which is often persistently enlarged and calcified. Delayed suppuration of the affected lymph node, lupus vulgaris overlying the involved node, and occasionally dissemination may follow this form of cutaneous TB.

Histologically, there is a marked inflammatory response during the first 2 weeks, with many polymorphonuclear leukocyte neutrophils (PMNs) and tubercle bacilli. During the next 2 weeks, the picture changes. Lymphocytes and epithelioid cells appear and replace the PMNs. Distinct tubercles develop within 3 or 4 weeks of inoculation. Simultaneously, with the appearance of epithelioid cells, the number of tubercle bacilli decreases rapidly.

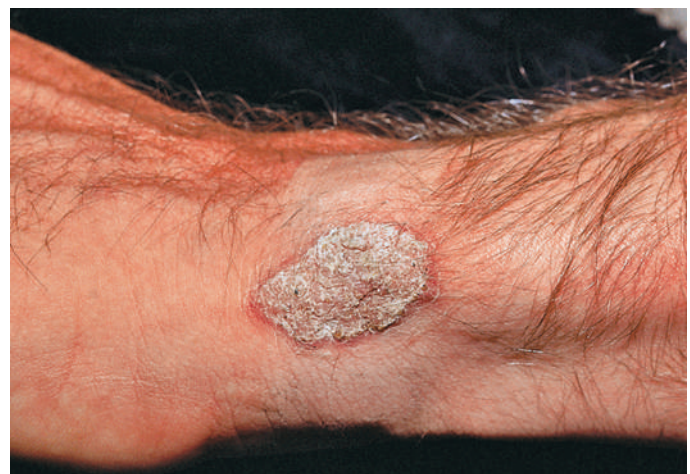The differential diagnosis of primary inoculation TB extends over the spectrum of chancriform conditions of deep fungal or bacterial origin, such as sporotrichosis, blastomycosis, histoplasmosis, coccidioidomycosis, nocardiosis, syphilis, leishmaniasis, yaws, tularemia, and atypical mycobacterial disease. Pyogenic granuloma and cat-scratch disease must also be considered.

#### Paucibacillary cutaneous tuberculosis from exogenous or endogenous source in persons with high immunity

##### *Tuberculosis verrucosa cutis*

Tuberculosis verrucosa cutis occurs from exogenous inoculation of bacilli into the skin of a previously sensitized person with strong immunity against *M. tuberculosis*. The tuberculin test is strongly positive. The prosecutor's wart resulting from inoculation during an autopsy is the prototype of tuberculosis verrucosa cutis.

Clinically, the lesion begins as a small papule, which becomes hyperkeratotic, resembling a wart. The lesion enlarges by peripheral expansion, with or without central clearing, sometimes reaching several centimeters or more in diameter (Fig. 16-2). Fissuring of the surface may occur, discharging purulent exudate. Lesions are almost always solitary, and regional



**Fig. 16-2** Tuberculosis verrucosa cutis.

adenopathy is usually present only if secondary bacterial infection occurs. Frequent locations for tuberculosis verrucosa cutis are on the dorsa of the fingers and hands in adults and the ankles and buttocks in children. The lesions are persistent but usually superficial and limited in extent. Local scarring, as seen in lupus vulgaris, can occur. Although sometimes separated by exudative or suppurative areas, the lesions seldom ulcerate and may heal spontaneously.

Histologically, there is pseudoepitheliomatous hyperplasia of the epidermis and hyperkeratosis. Suppurative and granulomatous inflammation is seen in the upper and middle dermis, sometimes perforating through the epidermis. Caseation is rare. The number of acid-fast bacilli (AFB) is usually scant, and failure to find AFB should not be used to exclude the diagnosis. Culture will be positive in slightly more than 50% of cases.

### Differential diagnosis

Tuberculosis verrucosa cutis is differentiated only by culture from atypical mycobacteriosis caused by *Mycobacterium marinum*. It must also be distinguished from North American blastomycosis, chromoblastomycosis, verrucous epidermal nevus, hypertrophic lichen planus, halogenoderma, and verruca vulgaris.

### Lupus vulgaris

Lupus vulgaris may appear at sites of inoculation, in scrofuloderma scars, or most frequently at distant sites from the initial infectious focus, probably by hematogenous dissemination. Approximately half of such cases will have evidence of TB elsewhere, so a complete evaluation is mandatory. Because lupus vulgaris is associated with moderately high immunity to TB, most patients will have a positive tuberculin test.

Lupus vulgaris typically is a single plaque composed of grouped red-brown papules, which, when blanched by diascopic pressure, have a pale, brownish yellow or "apple jelly" color. The papules, called lupomas, tend to heal slowly in one area and progress in another. They are minute, translucent, and embedded deeply and diffusely in the infiltrated dermis, expanding by the development of new papules at the periphery, which coalesce with the main plaque (Figs. 16-3 and 16-4). The plaques are slightly elevated. The disease is destructive, frequently causes ulceration, and on involution leaves deforming scars as it slowly spreads peripherally over the years.

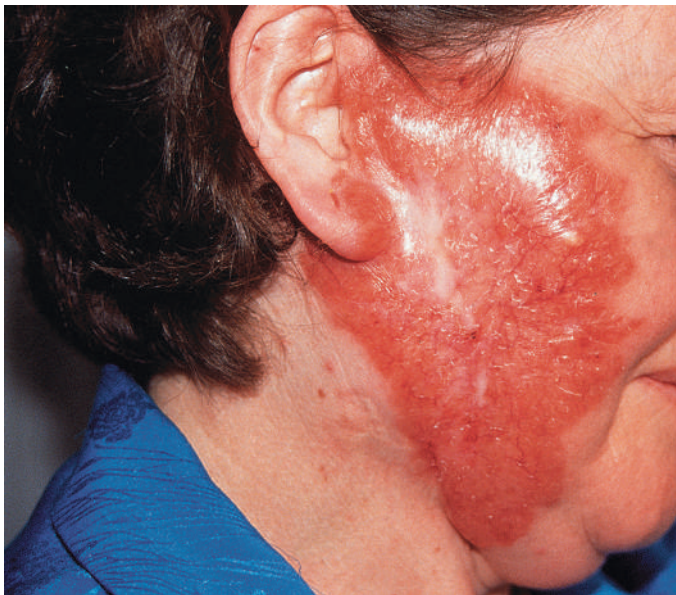

Fig. 16-3 Lupus vulgaris. (Courtesy of Dr Tavares-Bello, MD.)

Lupus vulgaris lesions of the head and neck can be associated with lymphangitis or lymphadenitis in some cases. If lesions involve the nose or the earlobes, these structures are shrunken and scarred, as if nibbled away. Atrophy is prominent, and ectropion and eclabion may occur. The tip of the nose may be sharply pointed and beaklike, or the whole nose may be destroyed, with only the orifices and the posterior parts of the septum and turbinates visible. The upper lip, a site of predilection, may become diffusely swollen and thickened, with fissures, adherent thin crusts, and ulcers. On the trunk and extremities, lesions may be annular or serpiginous or may form gyrate patterns. On the hands and feet and around the genitals or buttocks, lesions may cause mutilation by destruction, scar formation, warty thickenings, and elephantiasis enlargement.

An unusual form of lupus vulgaris may follow measles or another significant febrile illness. The window of immune deficiency caused by the acute illness results in dissemination of the TB hematogenously from a single focus of lupus vulgaris. Multiple erythematous papules in a generalized distribution appear a month or more after the illness. These lesions evolve to small papules and plaques, clinically and histologically resembling lupus vulgaris. The TST is negative during the immediate period following the febrile illness, then rapidly reverts to strongly positive. This is called "lupus vulgaris postexanthematicus."

Although classically considered a scarring and atrophying process, lesions of the lips and ears may be quite hyperplastic. The lips may resemble cheilitis granulomatosa clinically and histologically. Uniform hyperplasia of the ear pinna and lobe may closely mimic "turkey ear," as described in sarcoidosis. When the mucous membranes are involved, the lesions become papillomatous or ulcerative. They may appear as circumscribed, grayish, macerated, or granulating plaques. On the tongue, irregular, deep, painful fissures occur, sometimes associated with microglossia to the degree that nutrition is compromised.

The rate of progression of lupus vulgaris is slow, and a lesion may remain limited to a small area for several decades. The onset may be in childhood and persist throughout life. It may slowly spread, and new lesions may develop in other

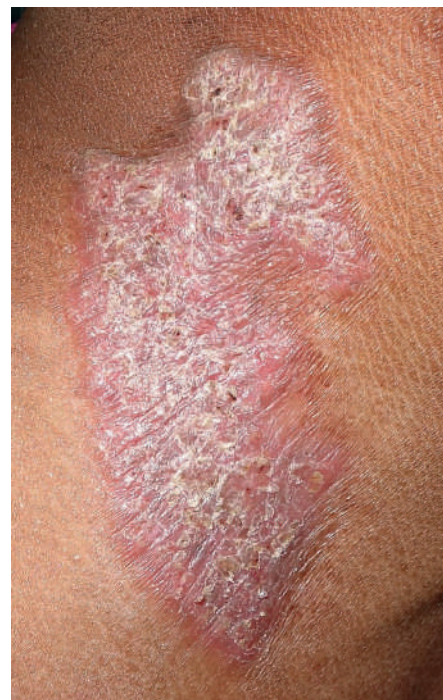

Fig. 16-4 Lupus vulgaris. (Courtesy of Dr. Debabrata Bandyopadhyay.)



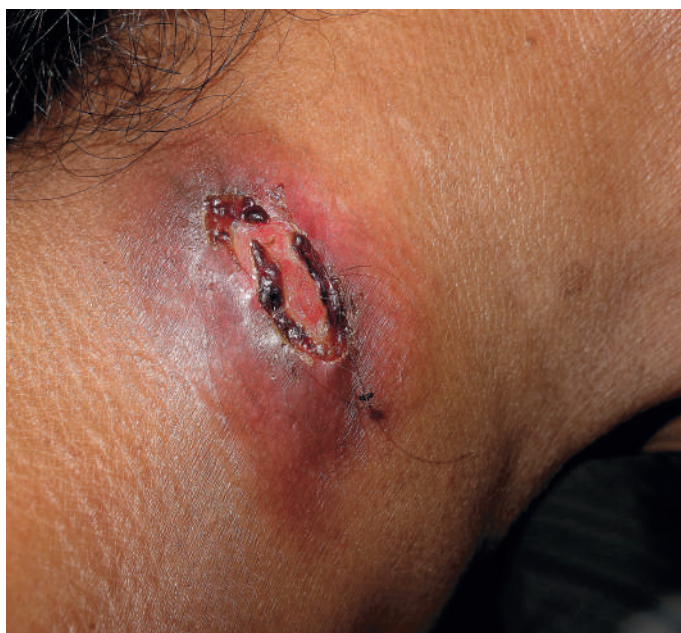regions. In some patients, the lesions become papillomatous, vegetative, or thickly crusted, with a rupioid appearance. Squamous cell carcinoma may develop in long-standing lesions.

Histologically, classic tubercles are the hallmark of lupus vulgaris. Caseation within the tubercles is seen in about half the cases and is rarely marked. Sarcoidosis may be simulated. The epidermis is affected secondarily, sometimes flattened and at other times hypertrophic. AFB are found in 10% or less of cases with standard acid-fast stains. PCR still lacks the sensitivity and specificity to diagnose paucibacillary forms of cutaneous TB reproducibly and will be positive in up to one quarter of cases. Cultures of the skin lesions grow *M. tuberculosis* in about half the cases.

Colloid milia, acne vulgaris, sarcoidosis, and rosacea may simulate lupus vulgaris. Differentiation from tertiary syphilis, chronic discoid lupus erythematosus, Hansen's disease, systemic mycoses, and leishmaniasis may be more difficult, and biopsy and tissue cultures may be required.

### Cutaneous tuberculosis from endogenous source by direct extension (scrofuloderma and periorificial tuberculosis)

Scrofuloderma is tuberculous involvement of the skin by direct extension from an underlying focus of infection. It occurs most frequently over the cervical lymph nodes but also may occur over bone or around joints if these are involved. Clinically, the lesions begin as subcutaneous masses, which enlarge to form nodules. Suppuration occurs centrally. They may be erythematous or skin colored, and usually the skin temperature is not increased over the mass. Lesions may drain, forming sinuses, or they may ulcerate with reddish granulation at the base (Figs. 16-5 and 16-6). Surgical procedures may incite lesions of scrofuloderma over joints or the abdominal cavity, apparently by releasing the loculated focus and contaminating the track along which instruments are inserted. Scrofuloderma heals with characteristic cordlike scars, frequently allowing the diagnosis to be made many years later.



**Fig. 16-5** Scrofuloderma. (Courtesy of Dr. Debabrata Bandyopadhyay.)

Perianal TB is characterized by a chronic anal fistula characteristically in men age 30–60. The intestinal tract, especially the rectum, is involved in most of these cases. Anal strictures and involvement of the scrotum may occur if disease is untreated.

Histologically, in scrofuloderma, the tuberculous process begins in the underlying lymph node or bone and extends through the deep dermis. Necrosis occurs with formation of a cavity filled with liquefied debris and PMNs. At the periphery, more typical granulomatous inflammation is seen, along with AFB observed in slightly less than half of cases.

Scrofuloderma should be differentiated from atypical mycobacterial infection, sporotrichosis, actinomycosis, coccidioidomycosis, and hidradenitis suppurativa. Lymphogranuloma venereum (LGV) favors the inguinal and perineal areas, with positive serologic tests for LGV.

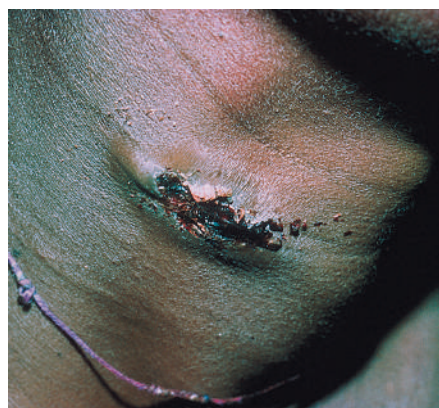Tuberculosis cutis orificialis is a form of cutaneous TB that occurs at the mucocutaneous borders of the nose, mouth, anus, urinary meatus, and vagina and on the mucous membrane of the mouth or tongue. It is caused by autoinoculation from underlying active visceral TB, particularly of the larynx, lungs, intestines, and genitourinary tract. It indicates failing resistance to the disease. Consequently, tuberculin positivity is variable but usually positive. Lesions ulcerate from the beginning and extend rapidly, with no tendency to spontaneous healing. The ulcers are usually soft and punched out and have undermined edges. Histologically, the ulcer base is usually composed largely of granulation tissue infiltrated with PMNs. Deep and lateral to the ulcer, granulomatous inflammation may be found, and AFB are numerous.

### Cutaneous tuberculosis from hematogenous spread

#### Miliary (disseminated) tuberculosis

Miliary TB appears in the setting of fulminant TB of the lung or meninges. Generally, patients have other unmistakable signs of severe disseminated TB. It is most common in children but may occur in adults. Most reported cases of cutaneous TB seen in patients with AIDS are of this type. Miliary TB may also follow infectious illnesses that reduce immunity, especially measles. Because this represents uncontrolled hematogenous infection, the TST is negative. Lesions are generalized and may appear as erythematous macules or papules, pustules, subcutaneous nodules, and purpuric “vasculitic” lesions. Ulceration may occur, and the pain in the infarcted lesions may be substantial. The prognosis is guarded.

Skin biopsies show diffuse suppurative inflammation of the dermis or subcutis with predominantly PMNs, at times forming abscesses. Caseating granulomas may be seen. AFB are abundant.



**Fig. 16-6** Scrofuloderma.

## Metastatic tuberculous abscess, ulceration, or cellulitis

The hematogenous dissemination of mycobacteria from a primary focus may result in firm, nontender, erythematous plaques (resembling cellulitis) or nodules. The nodules can evolve to form abscesses, ulcers, or draining sinus tracts. This form of cutaneous TB is usually seen in children, and most patients have decreased immunity from malnutrition, infection, or an immunodeficiency state. Patients presenting with tuberculous skin ulcers may or may not have other foci of TB identified. Aerosolization of mycobacteria may occur during incision and drainage and during dressing changes, leading to secondary cases among surgical and nursing staff treating these ulcers. Histologically, abscess formation and numerous AFB are seen.

## Sporotrichoid tuberculosis

Although TB is usually thought to be spread either by direct extension or hematogenously, in about 3% of patients with cutaneous TB, the lesions occur in a sporotrichoid pattern, suggesting lymphatic spread. Classically, this begins with a distal lesion, and new lesions appearing more proximally. Less often, a proximal lesion is present initially, and new lesions appear distally (retrograde lymphatic spread). The draining proximal lymph nodes may be enlarged. The individual lesions have the same morphology in any given patient, but different patients can have different morphologies. A string of lupus vulgaris-like lesions is most common. Less often, a string of deep nodules may become fluctuant, drain to the surface, or ulcerate, forming linear scrofuloderma-like lesions. The draining lymph node may be enlarged (more often than in sporotrichoid atypical mycobacterial infection). The TST is positive. Underlying foci of systemic TB are often not found. Biopsy of the lesions (and affected lymph nodes) typically shows granulomatous inflammation, but AFB stains are usually negative. Culture may be positive.

This form of TB presents significant diagnostic problems, because sporotrichoid lesions would more often result from atypical mycobacteria or sporotrichosis. Since atypical mycobacteria, especially *M. marinum*, may result in a positive TST, confirming the diagnosis is difficult, even if AFB are found on biopsy. This is a clinical scenario in which IGRA to analyze the patient's immunologic response specifically to *M. tuberculosis*, with PCR to speciate the infecting organism from the biopsy, can be useful.

## Tuberculous mastitis

Rarely, TB will present as subcutaneous nodules on the breast. The lesions can suppurate, forming abscesses, or break down, forming sinus tracts. The condition favors women of childbearing age but can also affect men. Tuberculous mastitis may closely resemble breast cancer, so biopsies are frequently done. Abscesses may be incised and drained. The consequence of the ongoing inflammation, destroying the fat of the breast, and the surgical procedures can be a severely disfigured breast. An underlying focus of TB may be present in the underlying bone or at a distant site in some cases. TST is positive. Histology shows granulomatous inflammation with negative AFB stains. Culture is usually negative. The diagnosis of tuberculous mastitis should be considered in all patients with granulomatous mastitis from endemic areas of TB.

## Tuberculids

Tuberculids are a group of skin eruptions associated with an underlying or silent focus of TB. They are diagnosed by their characteristic clinical features, histologic findings, a positive TST or IGRA, sometimes by the finding of TB at a distant site, and resolution of the eruption with antituberculous therapy. Tuberculids represent cutaneous lesions induced by hematogenous dissemination of tubercle bacilli to the skin. Lupus vulgaris may develop at the sites of tuberculids, and *M. tuberculosis* DNA may be found in tuberculid lesions by PCR. Tuberculids usually occur in persons with a strong immunity to TB (and thus a positive PPD). This results in rapid destruction of the bacilli and autoinvolvement of individual lesions in many cases. New lesions continue to appear, however, since hematogenous dissemination from the underlying focus continues. Tuberculids tend to be bilaterally symmetric eruptions because they result from hematogenous dissemination.

## Papulonecrotic tuberculid

Papulonecrotic tuberculid is usually an asymptomatic, chronic disorder, presenting in successive crops. Lesions are symmetrically distributed on the extensor extremities, especially on the tips of the elbows and on the knees; dorsal surfaces of the hands and feet; buttocks; face and ears; and glans penis. Lesions may favor pernio-prone sites and may be worse during winter months. Two thirds of cases occur before age 30, and females are affected 3:1 over males. Evidence of prior or active TB is found in one third to two thirds of patients, especially in the lymph nodes. The TST is positive and may generate a necrotic reaction.

Typical lesions vary in size from 2 to 8 mm and are firm, inflammatory papules that become pustular or necrotic. Lesions resolve slowly over several weeks, but occasional ulcers persist longer. Varioliform scarring follows the lesions. Crops recur over months to years.

Papulonecrotic tuberculids may appear in association with other cutaneous manifestations of TB, particularly erythema induratum or scrofuloderma. Associated clinical phenomena have included tuberculous arteritis with gangrene in young adult Africans and development of lupus vulgaris from the lesions. HIV-infected persons may develop papulonecrotic tuberculid.

Histologically, the epidermis is ulcerated in well-developed lesions. A palisaded collection of histiocytes surrounds an ovoid or wedge-shaped area of dermal necrosis. Well-formed tubercles are not seen, except in nonhealing lesions evolving into lupus vulgaris. Vascular changes are prominent, ranging from a mild lymphocytic vasculitis to fibrinoid necrosis and thrombotic occlusion of vessels. This is not a neutrophilic leukocytoclastic vasculitis, but rather a chronic granulomatous, small-vessel vasculitis. Capillaries, venules, and arterioles may be involved. AFB stains are negative, but PCR may detect mycobacterial DNA in up to half of patients with papulonecrotic tuberculid.

Papulopustular secondary syphilis, pityriasis lichenoides et varioliformis acuta, Churg-Strauss granuloma, lymphomatoid papulosis, perforating granuloma annulare, perforating collagenosis, and necrotizing or septic vasculitis share clinical and histologic features with papulonecrotic tuberculid.

## Lichen scrofulosorum

Lichen scrofulosorum consists of groups of indolent, minute, keratotic discrete papules scattered over the trunk. The lesions



are 2–4 mm, follicular or perifollicular, and yellow-pink to reddish brown. They are firm and flat topped or surmounted by a tiny pustule or thin scale. The lesions are arranged in nummular or discoid groups, where they persist unchanged for months and cause no symptoms. They may slowly undergo spontaneous involution, followed at times by recurrence. About 95% of cases of lichen scrofulosorum occur in children and adolescents under age 20. Active TB at a distant site, usually the bones or lymph nodes, is present in about three quarters of patients. The tuberculin test is always positive.

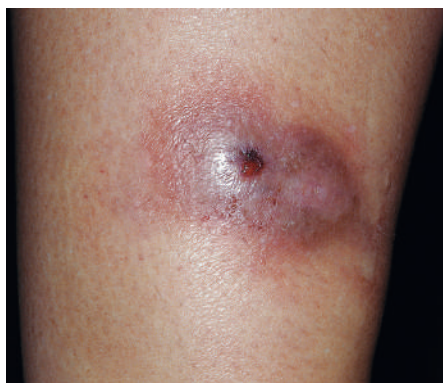Histologically, lichen scrofulosorum shows noncaseating tuberculoid granulomas just beneath the epidermis, between and surrounding hair follicles. Normally, tubercle bacilli are not seen in the pathologic specimens and cannot be cultured from biopsy material.

Lichen nitidus, lichen planus, secondary syphilis, and sarcoidosis should be considered in the differential diagnosis.

### Erythema induratum and vascular reactions caused by tuberculosis (nodular tuberculid and nodular granulomatous phlebitis)

Erythema induratum (Bazin disease) is chronic and occurs predominantly (80%) in women of middle age. Lesions favor the posterior lower calf, which may also show acrocyanosis. Individual lesions are tender, erythematous or violaceous, 1–2 cm subcutaneous nodules (Fig. 16-7). Lesions resolve spontaneously, with or without ulceration, over several months and can heal with scarring. A clinically similar but less common condition called nodular granulomatous phlebitis also affects women primarily but involves both the lower legs and the thighs, usually along the course of the saphenous vein. Individual lesions evolve over weeks to months but may recur for years in a seasonal pattern. They do not ulcerate or heal with scarring. The TST is positive. Idiopathic nodular vasculitis unassociated with TB may have identical clinical and histologic features, and this diagnosis is made when the PPD is negative.

The primary pathology occurs in the subcutaneous fat, which shows lobular panniculitis with fat necrosis. Granulomatous inflammation occurs in two thirds of cases and is noncaseating. In addition, a granulomatous vasculitis of arterioles can be present in the fat and is the apparent cause of the fat necrosis. Biopsies of nodular granulomatous phlebitis show thrombosis of and granulomatous inflammation centered around veins in the deep dermis. AFB are not found on special stains or cultures of the biopsy. PCR may help to confirm these diagnoses; however, the positive PPD obviates the need for it. At times, necrotizing vasculitis is present at the dermohypodermal junction. This reaction has been termed nodular tuberculid. The



**Fig. 16-7** Erythema induratum. (Courtesy of Curt Samlaska, MD.)

histology of nodular tuberculid may be identical or very similar to polyarteritis nodosa. More rarely, small-vessel vasculitis (leukocytoclastic vasculitis) or Sweet syndrome–like lesions may be seen as a “reaction” to an underlying focus of TB.

Erythema induratum must be distinguished from erythema nodosum, nodular vasculitis, polyarteritis nodosa, tertiary syphilis, and other infectious and inflammatory panniculitides. Erythema nodosum is of relatively short duration, develops rapidly, and chiefly affects the anterior rather than the posterior calves. It produces tender, painful, scarlet or contusiform nodules that appear simultaneously and do not ulcerate. Histology demonstrates a septal panniculitis. In erythema induratum patients, the pain is less severe, and the lesions tend to evolve serially or in crops. A syphilitic gumma is usually unilateral and single or may appear as a small, distinct group of lesions.

### Diagnosis of cutaneous tuberculosis

Biopsy with acid-fast staining should be done when the history and physical examination suggest cutaneous TB. PCR is increasingly used to identify mycobacterial DNA in tissue specimens and other biologic samples. It may be positive when both stains and cultures are negative; in paucibacillary disease, however, PCR is not reliably positive. Culture remains the gold standard and provides the means to determine antibiotic sensitivity and response to treatment.

### Treatment

Testing for HIV is recommended for all patients diagnosed with TB because HIV-infected patients may require longer courses of therapy. In addition, every effort should be made to culture the organism for sensitivity testing because MDR-TB is common in some communities. For all forms of cutaneous TB, multidrug chemotherapy is recommended. The recommendations of the local health clinics that manage other forms of TB should be followed. Three-drug or four-drug regimens are usually recommended for initial empiric treatment. Directly observed therapy is a strategy designed to ensure cure. “Priority patients” are those with prior treatment failure, pulmonary TB with a positive smear, HIV coinfection, current or prior drug use, drug-resistant disease, psychiatric illness, memory impairment, or previous nonadherence to therapy. Surgical excision is useful for the treatment of isolated lesions of lupus vulgaris and tuberculosis verrucosa cutis, and surgical intervention also may benefit some patients with scrofuloderma. In many cases of cutaneous TB, the organism has not been identified by either histology or culture, so treatment is inherently empiric. Virtually all forms of cutaneous TB will have begun to respond to treatment by 6 weeks. Failure to respond within this period should result in reconsideration of the diagnosis, assessment for compliance, and concern about drug resistance.

**Almagro M, et al:** Metastatic tuberculosis abscesses in an immunocompetent patient. *Clin Exp Dermatol* 2005; 30:247.

**Camacho D, et al:** Lichen scrofulosorum mimicking lichen planus. *Am J Dermatopathol* 2011; 33:186–191.

**Canpolat F, et al:** Acquired cutaneous lymphangiectasia secondary to scarring from scrofuloderma. *Int Soc Dermatol* 2010; 49:595–596.

**Dias MF, et al:** Update on cutaneous tuberculosis. *An Bras Dermatol* 2014; 89:925–938.

**Doherty S, et al:** National Psoriasis Foundation consensus statement on screening for latent tuberculosis infection in patients with psoriasis treated with systemic and biologic agents. *J Am Acad Dermatol* 2008; 59:209.

- Dongre AM, et al:** Papulonecrotic tuberculid at the site of tuberculin test in a patient with concomitant erythema induratum and papulonecrotic tuberculid. *Indian J Dermatol Venerol Leprol* 2013; 79:248–250.
- Dorman SE, et al:** Interferon- $\gamma$  release assays and tuberculin skin testing for diagnosis of latent tuberculosis infection in healthcare workers in the United States. *Am J Respir Crit Care Med* 2014; 189:77–87.
- Fernandez C, et al:** Papulonecrotic tuberculid in a human immunodeficiency virus type-1 patient with multidrug-resistant tuberculosis. *J Eur Acad Dermatol Venereol* 2004; 18:369.
- Fraser SJ, et al:** Cutaneous tuberculosis revealed by infliximab therapy for presumed sarcoidosis. *Clin Exp Dermatol* 2009; 35:e141–e142.
- Ghosh S, et al:** Tuberculosis verrucosa cutis presenting as diffuse plantar keratoderma. *Indian J Dermatol* 2014; 59:80–81.
- Gyldenlove M, et al:** Cutaneous necrotic ulceration due to BCG re-vaccination. *Hum Vaccin Immunother* 2012; 8:424.
- Haase O, et al:** Recurrent abscesses of the neck: scrofuloderma. *JAMA Dermatol* 2014; 150:909–910.
- Heller MM, et al:** Fatal case of disseminated BCG infection after vaccination of an infant with in utero exposure to infliximab. *J Am Acad Dermatol* 2011; 65:870.
- Jimenez-Gallo D, et al:** Tuberculosis cutanea periorificial vulvar. *Actas Dermosifiliogr* 2012; 103:929–930.
- Joshi HS, et al:** Lichen scrofulosorum. *BMJ Case Rep* 2014; pii: bcr2013200858.
- Kar S, et al:** Scrofuloderma: a case series from rural India. *Indian J Tuberc* 2011; 58:189–195.
- Khaira A, et al:** Tuberculosis verrucosa cutis in a renal transplant recipient. *Int J Dermatol* 2009; 48:516–517.
- Kim JE, et al:** Tuberculous cellulitis as a manifestation of military tuberculosis in a patient with malignancy-associated dermatomyositis. *J Am Acad Dermatol* 2011; 65:450–452.
- Kumar U, et al:** Psoriasiform type of lichen scrofulosorum. *Pediatr Dermatol* 2011; 28:532–534.
- Laws PM, et al:** Nonhealing vegetating plaque on the finger. *Cutis* 2011; 87:30–33.
- Leocata P, et al:** Squamous cell carcinoma arising from long-term (50-year) lupus vulgaris. *Infez Med* 2009; 17:249–253.
- Leon-Mateo A, et al:** Perianal ulceration: a case of tuberculosis cutis officialis. *J Eur Acad Dermatol Venereol* 2005; 19:364.
- Lin CY, et al:** Perianal tuberculosis during neutropenia: a rare case report and review of literature. *Ann Hematol* 2006; 85:547.
- Ljubenovic MS, et al:** Cutaneous tuberculosis and squamous-cell carcinoma. *An Bras Dermatol* 2011; 86:541–544.
- Makkar VR, et al:** Lupus vulgaris postexanthematicus: a rare variant of lupus vulgaris with sarcoid-like histopathology. *Clin Exp Dermatol* 2005; 30:187.
- McHugh A, et al:** Nodular granulomatous phlebitis: a phlebitic tuberculid. *Australas J Dermatol* 2008; 49:220.
- Motswaledi HM, et al:** Superficial thrombophlebitic tuberculid. *Int J Dermatol* 2006; 45:1337.
- Motswaledi MH, Doman C:** Lupus vulgaris with squamous cell carcinoma. *J Cutan Pathol* 2007; 34:939.
- Mukherjee A, et al:** Status and current role of interferon gamma release assays vs. tuberculin skin testing in diagnosis of tubercular disease. *Indian J Pediatr* 2013; 80:334–336.
- Projapati V, et al:** Erythema induratum. *J Cutan Med Surg* 2013; Suppl 1:6–11.
- Rajagopala S, Agarwal R:** Tuberculosis mastitis in men: case report and systematic review. *Am J Med* 2008; 121:539.
- Ramesh V:** Sporotrichoid cutaneous tuberculosis. *Clin Exp Dermatol* 2007; 32:680.
- Regnier S, et al:** Cutaneous military resistant tuberculosis in a patient infected with human immunodeficiency virus. *Clin Exp Dermatol* 2009; 34:e690–e692.
- Rhodes J, et al:** Lupus vulgaris. *Australas J Dermatol* 2013; 54:e53–e55.
- Romy RMC, et al:** Cutaneous complication after BCG vaccination. *J Dermatol Treat* 2011; 22:315–318.
- Sethuraman G, et al:** Cutaneous tuberculosis in children. *Pediatr Dermatol* 2013; 30:7–16.
- Shibuya R, et al:** Cutaneous miliary tuberculosis in a patient with long-term steroid treatment for microscopic polyangiitis. *Eur J Dermatol* 2013; 23:286–287.
- Singal A, et al:** Lichen scrofulosorum: a prospective study of 39 patients. *Int J Dermatol* 2005; 44:489.
- Singal A, et al:** Ulcerated lupus vulgaris at the site of bacille Calmette-Guérin vaccination. *Pediatr Dermatol* 2013; 30:147–148.
- Takeuchi G, et al:** Disseminated lupus vulgaris diagnosed more than 63 years after onset due to early misdiagnosis as a port wine stain. *Clin Exp Dermatol* 2010; 35:e28–e29.
- Tekbas G, et al:** Skin ulcers. *Respir Care* 2011; 56:1853–1856.
- Tissot C, et al:** Life-threatening disseminated tuberculosis as a complication of treatment by infliximab for Crohn's disease. *J Crohns Colitis* 2012; 6:946–949.
- Vera-Kellet C, et al:** Usefulness of interferon- $\gamma$  release assays in the diagnosis of erythema induratum. *Arch Dermatol* 2011; 147:949–952.
- Wang H, et al:** Cutaneous tuberculosis: a diagnostic and therapeutic study of 20 cases. *J Dermatol Treat* 2011; 22:310–314.
- Williams C, et al:** Turkey ear: a diagnosis or a physical sign? *Br J Dermatol* 2007; 157:816.
- Wolf T, et al:** Tuberculosis skin test, but not interferon- $\gamma$ -releasing assays, is affected by BCG vaccination in HIV patients. *J Infect* 2013; 66:376–380.
- Wong HW, et al:** Papular eruption on a tattoo: a case of primary inoculation tuberculosis. *Australas J Dermatol* 2005; 46:84.
- Yodmalai S, et al:** Cutaneous military tuberculosis in a renal transplant patient. *Southeast Asian J Trop Med Public Health* 2011; 42:674–678.

## ATYPICAL MYCOBACTERIOSIS

Many facultative pathogens and saprophytes, which are acid-fast mycobacteria but do not cause TB or Hansen's disease, are grouped under the designation "atypical mycobacteria." They exist in a wide variety of natural sources, such as soil, water, and animals; most human disease is acquired from the environment. The number of cases of human infection with these organisms is increasing, or increasingly recognized. This is a result of improved culture and identification techniques and the increasingly large immunocompromised population.

## Classification of mycobacteria

The old Runyon classification scheme based on identifying atypical mycobacteria in the laboratory was as follows:

- Group I: photochromogens (*Mycobacterium marinum*, *M. kansasii*, *M. simiae*)
- Group II: scotochromogens (*Mycobacterium scrofulaceum*, *M. gordonae*, *M. xenopi*, *M. szulgai*)
- Group III: nonchromogens (*Mycobacterium avium-intracellulare* complex, *M. haemophilum*, *M. ulcerans*, *M. malmaoense*, *M. terrae*, *M. genavense*, *M. bovis*, *M. nonchromogenicum*)
- Group IV: rapid growers (*Mycobacterium fortuitum*, *M. chelonae*, *M. smegmatis*, *M. abscessus*, *M. immunogenum*, *M. mucogenicum*, *M. goodii*, *M. wolinskyi*, *M. cosmeticum*, *M. franklinii*)

*Mycobacterium marinum*, *M. ulcerans*, and *M. haemophilum* are now recognized as common pathogens in certain settings and geographic locations. Rapidly growing mycobacteria of the *Mycobacterium fortuitum*, *chelonae*, and *abscessus* group are usually associated with previous surgery, injection, or trauma. An increasing number of patients receiving anti-TNF therapy and those with solid-organ or stem cell transplants have been reported with infections caused by atypical mycobacteria. Only select organisms that most frequently affect the skin are discussed in detail here.

The number of new species of nontuberculous mycobacteria has been growing dramatically, with now at least 100 known species. Many of these organisms do not cause infection and are simply commensals or saprophytes. They are found in water and soil, and their identification after contamination of



clinical specimens has at times been responsible for pseudo-outbreaks of infection.

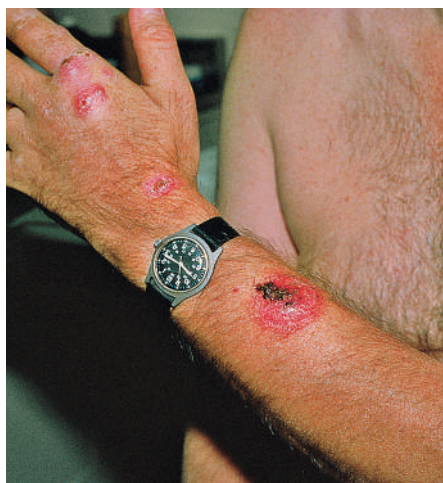The clinical care of the patient with atypical mycobacterial infection depends on culturing and identifying the responsible agent from tissue specimens. The laboratory should be familiar with the special media, necessary incubation times and temperature, and identification characteristics of these organisms. Even with modern techniques, recovery of these organisms from infections is not universal. Granuloma formation may not occur in histologic sections, and AFB stains may be negative. For this reason, if atypical mycobacteria infection is suspected, a biopsy should be done, part of which should be cultured at high and low temperatures and on special media; AFB stains of the tissue should be performed; and in select patients, PCR for specific species from fresh tissue or the paraffin-fixed material should be considered. In some patients, a clinical diagnosis must be made and empiric therapy given.

### Swimming pool granuloma (aquarium granuloma)

*Mycobacterium marinum* is found in fresh and salt water and can infect fish, often killing home aquarium fish. It grows optimally at 30°C. The vast majority of infections in the United States and Europe are now associated with home aquariums. Fishermen, fish sellers, and persons involved in aquaculture are also at risk. Skin lesions favor males (60%). History of an injury preceding or simultaneous with exposure to contaminated water is usually present. Exposure can be indirect, such as contact with a bucket used to empty an aquarium.

An indolent lesion usually starts about 3 weeks after exposure as a small papule or nodule located on the hands, knees, elbows, or feet. It often has a keratotic or warty surface. A sporotrichoid pattern with a succession of nodules ascending the arm is common (Fig. 16-8). Less often, ulcers and abscesses may be the presentation, especially in immunosuppressed hosts. Tenosynovitis, bursitis, arthritis, and osteitis are the most frequent forms of deep structure involvement. There may be involvement of the tendon sheaths of the dorsal hands and less frequently the palms. This may limit range of motion and result in significant thickening and induration. Such patients may require surgical as well as medical management. The natural history is for slow progression, and lesions may be relatively indolent for years. Spontaneous resolution may occur in 10–20% of patients with skin lesions only after many months. Immunosuppressed patients may develop widely disseminated lesions that are progressive.

Histopathologically, there is a suppurative and granulomatous reaction with overlying hyperkeratosis and acanthosis.



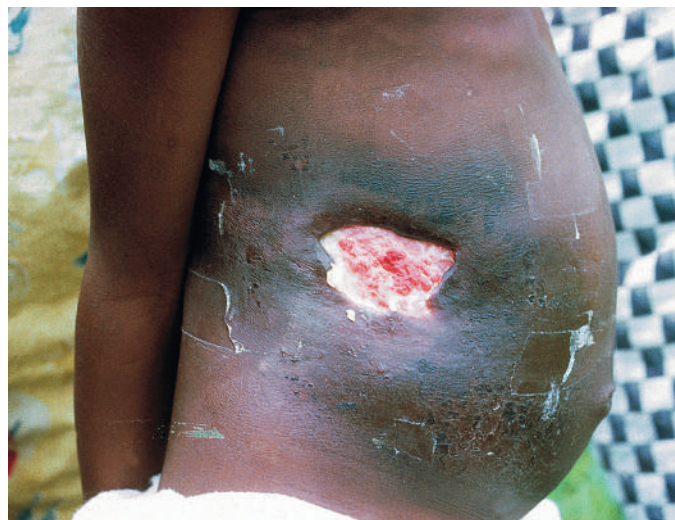**Fig. 16-8** Sporotrichoid *Mycobacterium marinum* infection.

Acid-fast organisms are found in only about 20% of cases. Tissue culture will be positive in about three quarters of cases. The TST and IGRA to *M. tuberculosis* usually become positive in those who have had *M. marinum* infection.

Treatment is determined by the extent of the infection and the patient's immune status. Optimal treatment has not yet been established, and favorable outcome cannot be related to any specific antibiotic or antibiotic combination. Failure of every antibiotic used has been documented. Single-agent therapy is acceptable for immunocompetent patients with infections limited to skin and soft tissue. Minocycline, 100 mg twice daily, seems to be the single best agent, with doxycycline (100 mg twice daily), clarithromycin (500 mg twice daily), or trimethoprim-sulfamethoxazole (TMP-SMX, 160/800 mg twice daily) as alternative therapy. Some patients have failed doxycycline therapy but responded to minocycline. Combination treatment with minocycline plus clarithromycin or with rifampin, rifabutin, or amikacin added to minocycline and/or clarithromycin seems appropriate based on in vitro sensitivities of numerous isolates. Ethambutol and the quinolones have poor minimum inhibitory concentration, and their use is associated with treatment failure. The sensitivities of the organism isolated can be used in cases failing initial empiric treatment. Immunosuppressed hosts and patients with involvement of deep structures should receive combination treatment. For localized lesions in the immunocompetent host, treatment is recommended for at least 1–2 months after resolution of lesions, which is usually 3–4 months in total. More than 90% of such patients will be cured. Only about 75% of patients with deep structure infections will be cured with antibiotics, with or without supplemental surgery. In this situation, treatment is often prolonged – many months to years.

### Buruli ulcer

Buruli ulcer is also known as Bairnsdale ulcer and Searl ulcer. This is the third most common type of mycobacterial skin infection in immunocompetent people. In Africa, 75% of cases occur in children, and elderly persons are disproportionately affected. In endemic areas in Australia, elderly people are seven times more likely to be infected. Lesions favor the extremities. The lesion begins as a solitary, hard, painless, subcutaneous nodule called the “preulcerative stage.” There can be significant local edema at this point. If untreated, some lesions ulcerate and expand by undermining the surrounding skin (Fig. 16-9). They may become very large, exposing muscle



**Fig. 16-9** Buruli ulcer.

and tendon over a large portion of an affected extremity. Despite their appearance, the lesions are remarkably painless. Persons with hemoglobin SS or SC are as much as five times more likely to develop osteomyelitis from *M. ulcerans*. Histologically, there is extensive coagulative necrosis, minimal cellular infiltrate, and numerous clumps of AFB in the center of the necrotic area.

*Mycobacterium ulcerans* is the cause of Buruli ulcer. This organism occurs in Australia, numerous African nations (especially in Central and West Africa), Asia, French Guyana, Peru, Suriname, Mexico, and Brazil. The pathogenesis of this infection is now well defined. *M. ulcerans* produces a toxin, mycolactone, responsible for the extensive necrosis and ulceration. In addition to having cellular toxicity, mycolactone is also locally immunosuppressive. Tissue necrosis creates a microaerophilic environment that favors the growth of *M. ulcerans*. Strains of *M. ulcerans* lacking mycolactone are not capable of producing disease. This toxin is also critical in maintaining the life cycle of the organism.

*Mycobacterium ulcerans* grows under a biofilm on aquatic plants. Snails and other water animals eat the contaminated plants, and carnivorous insects eat the plant-consuming molluscs. *M. ulcerans* moves from the gut of the carnivorous insects to their salivary glands. Only *M. ulcerans* species producing mycolactone are capable of establishing a reservoir in the insect salivary gland. *M. ulcerans* is found in no other tissue in the biting insects and produces no biofilm in the insect salivary gland. When these insects bite a human, they inoculate the mycobacteria into the host and begin the infection. Infection in the human is again associated with the production of the biofilm, which makes treatment difficult. This explains the association between infection and exposure to water, especially swampy water. Interestingly, being repeatedly bitten by these carnivorous insects results in the production of antibodies against the insect salivary contents. This immune response to the insect saliva is protective against *M. ulcerans* infection, explaining why persons working regularly in swampy water are at lower risk for infection than those visiting the area, and perhaps why children and elderly persons are at greater risk for infection, because of reduced production of these antibodies. In Australia, mosquito bites are associated with the development of *M. ulcerans* infection, and the bacteria can be isolated from trapped insects in areas of *M. ulcerans* epidemics. Whether the mosquitoes carry the infection by the same mechanism as the carnivorous water insects is unknown.

The diagnosis of Buruli ulcer is often made clinically in areas of endemicity. AFB smears of the edge of ulcerative lesions or of aspirates from the center of preulcerative lesions, culture of the lesion, PCR, and histologic examination all can confirm the diagnosis. AFB stains are positive in up to 80% of lesions. Culture has a similar positivity rate. PCR may be slightly less sensitive. When AFB smears, culture, and PCR were all done on the same lesion, one test was positive in 94% of cases, two were positive in 83%, and only 50% of cases yielded positive results by all three methods. About 6% of cases will be negative with all three tests. Preulcerative lesions give the highest culture results, because ulcerative lesions contain fewer organisms and are contaminated. AFB smears and PCR have similar sensitivity in preulcerative and ulcerative lesions. *M. ulcerans* is very stable in transport and has been cultured up to 26 weeks after sample collection, if transported to the laboratory appropriately.

Treatment of Buruli ulcer includes systemic antibiotics and surgery. Daily observed treatment for 8 weeks with streptomycin, 15 mg/kg intramuscularly, and rifampin, 10 mg/kg orally, is dramatically effective. The overall efficacy of this treatment regimen was 73% of patients and 96% in lesions less than 10 cm in diameter (early lesions) without surgery. Healing

is slow, with half of lesions healing by 24 weeks (with only 8 weeks of antibiotic treatment) and some requiring more than 9 months to heal. Clarithromycin, 7.5 mg/kg orally once daily, may be substituted for the last 4 weeks of streptomycin therapy with virtually equal efficacy. In larger lesions (>15 cm) and in lesions failing antibiotic treatment alone, surgical excision with delayed grafting is the standard treatment offered. In a large series of more than 200 patients, all patients who completed the full course of antibiotics with or without surgery were cured—a success rate of 100% by 3 months after the antibiotics were completed. At 1-year follow-up, only 1.4% of patients had recurrence.

Severe scarring can result from untreated and large lesions, leading to contracture deformity or amputation. If the periocular tissues are affected, enucleation of the eye may be required. Multiple metastatic skin lesions can occur. Bone lesions are uncommon and in three quarters of patients, occur at a site distant from the primary Buruli ulcer. Rarely, death may result.

## Other atypical mycobacterial infections

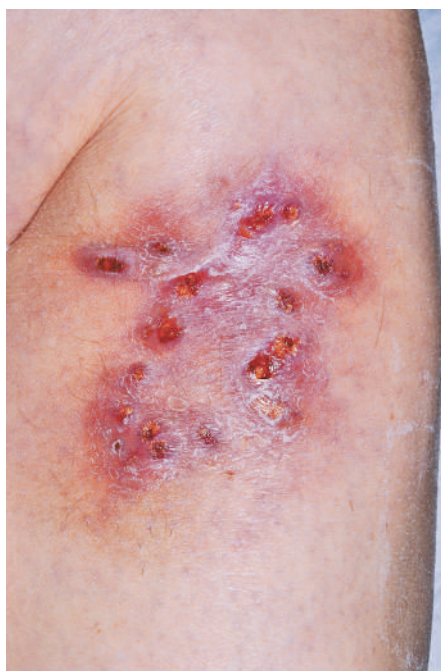### *Mycobacterium haemophilum*

*Mycobacterium haemophilum* most often infects immunosuppressed patients with AIDS, with organ transplant, receiving anti-TNF agents, or with leukemia or lymphoma. The reservoir for the organism is unknown but thought to be water. Because *M. haemophilum* grows preferentially at 30–32°C, skin lesions at acral sites predominate. Papules, plaques (at times cellulitis-like), and dermal or subcutaneous nodules are the primary lesions. These initial lesions break down in many cases, forming painful, draining ulcers. Cutaneous infections after acupuncture, following application of permanent eyebrow makeup, and within tattoos have been reported in immunocompetent and immunosuppressed patients. Septic arthritis, osteomyelitis, and pulmonary nodules may occur. *M. haemophilum* has specific growth requirements, so isolation is not possible using routine laboratory culture techniques. If *M. haemophilum* infection is suspected, the laboratory should be notified so that it can prepare the special media necessary to isolate it. *M. haemophilum* is sensitive to ciprofloxacin, clarithromycin, amikacin, rifampin, and rifabutin. It is resistant to ethambutol, isoniazid, and pyrazinamide. Combination therapy is recommended. Treatment is for 1 year.

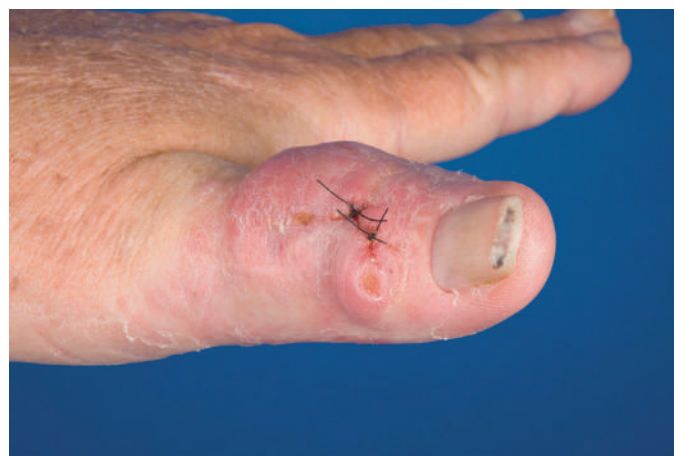## Rapidly growing mycobacteria

The organisms of the *Mycobacterium fortuitum* group and *M. chelonae/abscessus* group usually cause subcutaneous abscesses or cellulitis. These rapidly growing mycobacteria (RGM) are frequently resistant to standard antituberculosis medications. Infections usually occur after trauma in immunocompetent patients. Infections may follow a variety of cosmetic surgery procedures (e.g., CO<sub>2</sub> laser resurfacing, laser hair removal, injection with dermal fillers, mesotherapy, liposuction), skin piercing, or catheterization and may occur within tattoos. Outbreaks of leg abscesses caused by *M. fortuitum* have been acquired in nail salon whirlpool footbaths. Most RGM cases are restricted to the skin and start as small erythematous papules, many of which spontaneously heal. Others progress to large, fluctuant abscesses, which are quite painful and can ulcerate (Fig. 16-10). Sporotrichoid or disseminated disease may occur in immunocompromised patients (Fig. 16-11), but proximal adenopathy is rarely found. Shaving of the legs before visiting the nail salon appears to be a risk factor for

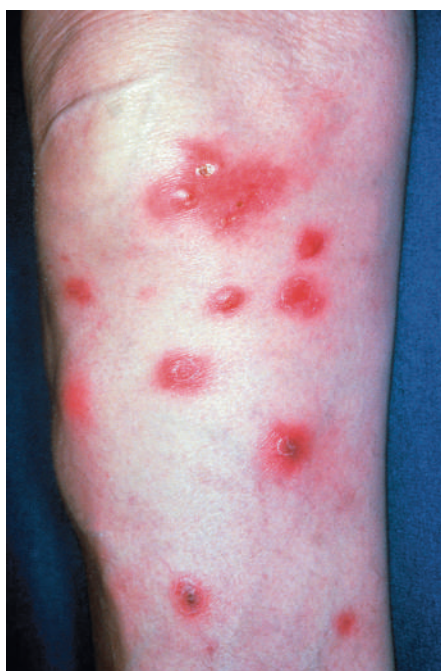



**Fig. 16-10**  
*Mycobacterium fortuitum* infection.



**Fig. 16-12** *Mycobacterium avium-intracellulare* complex, primary inoculation in a healthy woman.



**Fig. 16-11**  
Disseminated  
*Mycobacterium chelonae* infection.

acquiring infection with RGM. In renal transplant patients, tender, nodular lesions of the legs are most common. Deep extension into bone underlying a chronic ulcer can occur. Since these infections on the skin are indolent and the organisms grow rapidly, waiting for susceptibilities can be considered.

Treatment is determined by extent of disease and immune status of the patient. For *M. chelonae/abscessus* infections, clarithromycin, 500 mg twice daily for 6 months or more, is effective and well tolerated in many patients with disseminated cutaneous infection. Monotherapy may allow resistance to occur, but this rarely happens in immunocompetent patients with simple skin infections. In severe cases and in the setting of immunosuppression, combination treatment should be used. Tobramycin, amikacin, linezolid, clarithromycin, and tigecycline have the highest percentage of susceptible isolates

of *M. chelonae/abscessus*. The optimal regimen for treatment of *M. fortuitum* has not been defined, and combination treatment is often recommended. Amikacin plus cefoxitin and probenecid or a quinolone can be recommended for initial therapy for 6 weeks, followed by doxycycline or TMP-SMX for up to 1 year. If only oral agents are to be used for skin-limited disease, minocycline (100 g twice daily), doxycycline (100 mg twice daily), TMP-SMX (1 double-strength tablet twice daily), or levofloxacin (500–750 mg once daily) are acceptable agents. Surgical excision, debridement, and drainage may reduce duration of therapy.

A newly recognized RGM species that has been separated from *M. chelonae* is *Mycobacterium franklinii*. It is distinct taxonomically, similar in epidemiology, but is distinguished by its susceptibility to cefoxitin.

### ***Mycobacterium avium-intracellulare* complex**

The *M. avium-intracellulare* complex was an uncommon cause of skin infection before the AIDS epidemic. In patients with AIDS who develop disseminated *M. avium-intracellulare* infections, the skin may be involved by hematogenous dissemination and may present as nodules, ulcers, or pustules or may have a cellulitis-like appearance. Immunocompromised children with chronic pulmonary infections are also at risk. Only occasional reports of immunocompetent patients with inoculation-type lesions have been reported (Fig. 16-12). Therapy for disseminated infection is undertaken with at least three agents, most often clarithromycin or azithromycin, ethambutol, and rifabutin. Adequate antiretroviral therapy should be assured in HIV-infected persons.

### ***Mycobacterium kansasii***

*Mycobacterium kansasii* rarely causes skin infection, usually after minor trauma. Three quarters of cases occur in immunosuppressed persons. Lesions can be papules, nodules, pustules, cellulitis, or sporotrichoid. Treatment is not standardized, but initial treatment with isoniazid, rifampin, and ethambutol until 12 months after clearing has been proposed. Azithromycin or clarithromycin can be added if necessary. However, individual cases have responded to single-agent therapy with minocycline or erythromycin. Surgical removal can be beneficial if practical. In immunosuppressed patients, cutaneous lesions can occur through hematogenous dissemination, and a visceral source, especially pulmonary, should be sought.

- Aslam A, et al:** Cutaneous *Mycobacterium haemophilum* infection in a patient receiving infliximab for psoriasis. *Br J Dermatol* 2013; 168:446–447.
- Atkins BL, et al:** Skin and soft tissue infections caused by nontuberculous mycobacteria. *Curr Opin Infect Dis* 2014; 27:137–145.
- Boleira M, et al:** Buruli ulcer. *An Bras Dermatol* 2010; 85:281–298.
- Caron J, et al:** Aggressive cutaneous infection with *Mycobacterium marinum* in two patients receiving anti-tumor necrosis factor- $\alpha$  agents. *J Am Acad Dermatol* 2011; 65:1060–1062.
- Chany A-C, et al:** History, biology and chemistry of *Mycobacterium ulcerans* infections (Buruli ulcer disease). *Nat Prod Rep* 2013; 30:1527–1567.
- Cheung JP, et al:** *Mycobacterium marinum* infection on the hand and wrist. *J Orthop Surg* 2012; 20:214–218.
- Collins CS, et al:** Disseminated *Mycobacterium haemophilum* infection in a 72-year-old patient with rheumatoid arthritis on infliximab. *BMJ Case Rep* 2013; pii: bcr2012008034.
- Conejero R, et al:** Infeccion por *Mycobacterium chelonae* en paciente en tratamiento con adalimumab. *Actas Dermosifilogr* 2012; 103:69–71.
- Converse PJ, et al:** Treating *Mycobacterium ulcerans* disease (Buruli ulcer). *Future Microbiol* 2011; 6:1185–1198.
- Culton DA, et al:** Nontuberculous mycobacterial infection after fractionated CO<sub>2</sub> laser resurfacing. *Emerg Infect Dis* 2013; 19:365–370.
- Drage LA, et al:** An outbreak of *Mycobacterium chelonae* infections in tattoos. *J Am Acad Dermatol* 2010; 62:501–506.
- Ducharlet K, et al:** Recurrent *Mycobacterium haemophilum* in a renal transplant recipient. *Nephrology* 2014; Suppl 1:14–17.
- Eberst E, et al:** Epidemiological, clinical, and therapeutic pattern of *Mycobacterium marinum* infection. *J Am Acad Dermatol* 2012; 66:e15–e16.
- Ferreira J, et al:** *Mycobacterium marinum*. *Am Coll Gastroenterol* 2012; 107:1268–1269.
- Fowler J, et al:** Localized cutaneous infections in immunocompetent individuals due to rapidly growing mycobacteria. *Arch Pathol Lab Med* 2014; 138:1106–1109.
- Giulieri S, et al:** Outbreak of *Mycobacterium haemophilum* infections after permanent makeup of the eyebrows. *Clin Infect Dis* 2011; 52:488–491.
- Goldman J, et al:** Outbreak of *Mycobacterium chelonae* in France. *BMJ* 2010; 341:906.
- Guevara-Patino A, et al:** Soft tissue due to *Mycobacterium fortuitum* following acupuncture: a case report and review of the literature. *J Infect Dev Ctries* 2010; 4:521–525.
- Han SH, et al:** Disseminated *Mycobacterium kansasii* infection associated with skin lesions. *J Korean Med Sci* 2010; 25:304–308.
- Iyengar KP, et al:** *Mycobacterium chelonae* hand infection following ferret bite. *Infection* 2013; 41:237–241.
- Jacobs S, et al:** Disseminated *Mycobacterium marinum* infection in a hematopoietic stem cell transplant recipient. *Transpl Infect Dis* 2012; 14:410–414.
- Kay MK, et al:** Tattoo-associated *Mycobacterium haemophilum* skin infection in immunocompetent adult. *Emerg Infect Dis* 2011; 17:1734–1736.
- Kelley CF, et al:** Disseminated *Mycobacterium haemophilum* infection. *Lancet Infect Dis* 2011; 11:571–578.
- Kennedy BS, et al:** Outbreak of *Mycobacterium chelonae* infection associated with tattoo ink. *N Engl J Med* 2012; 367:1020–1024.
- Kim MJ, et al:** *Mycobacterium chelonae* wound infection after liposuction. *Emerg Infect Dis* 2010; 16:1173–1175.
- Kump PK, et al:** A case of opportunistic skin infection with *Mycobacterium marinum* during adalimumab treatment in a patient with Crohn's disease. *J Crohns Colitis* 2013; 7:e15–e18.
- Lavendar CJ, et al:** Risk of Buruli ulcer and detection of *Mycobacterium ulcerans* in mosquitoes in southeastern Australia. *PLoS Negl Trop Dis* 2011; 5:e1305.
- Lavender CJ, et al:** Buruli ulcer disease in travelers and differentiation of *Mycobacterium ulcerans* strains from northern Australia. *J Clin Microbiol* 2012; 50:3717–3721.
- Lindeboom JA, et al:** Clinical manifestations, diagnosis, and treatment of *Mycobacterium haemophilum* infections. *Clin Microbiol Rev* 2011; 24:701–717.
- Lopez Avenir D, et al:** *Mycobacterium fortuitum* infection in continuous subcutaneous insulin infusion sites. *Br J Dermatol* 2014; 171:418–420.
- Macente S, et al:** Disseminated folliculitis by *Mycobacterium fortuitum* in an immunocompetent woman. *An Bras Dermatol* 2013; 88:102–104.
- Merritt RW, et al:** Ecology and transmission of Buruli ulcer disease: a systemic review. *PLoS Negl Trop Dis* 2010; 4:e911.
- Mitha M, et al:** Cutaneous *Mycobacterium kansasii* infection in a patient with AIDS post initiation of antiretroviral therapy. *J Infect Dev Ctries* 2011; 5:553–555.
- Mustaq RF, et al:** Skin, subcutaneous tissue, and allograft infection with *Mycobacterium fortuitum* in a renal transplant recipient. *Saudi J Kidney Dis Transpl* 2014; 25:1248–1250.
- Nakanaga K, et al:** Nineteen cases of Buruli ulcer diagnosed in Japan from 1980 to 2010. *J Clin Microbiol* 2011; 49:3829–3836.
- Oh CC, et al:** *Mycobacterium haemophilum* in an elderly Chinese woman. *Int J Dermatol* 2014; 53:1129–1132.
- Palm MD, et al:** *Mycobacterium chelonae* infection after fractionated carbon dioxide facial resurfacing (presenting as an atypical acneiform eruption). *Dermatol Surg* 2010; 36:1473–1481.
- Quinones C, et al:** An outbreak of *Mycobacterium fortuitum* cutaneous infection associated with mesotherapy. *J Euro Acad Dermatol Venerol* 2010; 24:604–606.
- Rao J, et al:** Atypical mycobacterial infection following blepharoplasty and full-face skin resurfacing with CO<sub>2</sub> laser. *Dermatol Surg* 2012; 28:768–771.
- Rodriguez JM, et al:** *Mycobacterium chelonae* facial infections following injection of dermal filler. *Aesthet Surg J* 2013; 33:265–269.
- Sergeant A, et al:** *Mycobacterium chelonae* infection: a complication of tattooing. *Clin Exp Dermatol* 2013; 38:140–142.
- Simmon KE, et al:** *Mycobacterium chelonae-abscessus* complex associated with sinopulmonary disease, northeastern USA. *Emerg Infect Dis* 2011; 17:1692–1700.
- Suwanasuthi S, et al:** *Mycobacterium fortuitum* cutaneous infection from amateur tattoo. *J Med Assoc Thai* 2012; 95:834–837.
- Thanou-Stravraki A, et al:** Noodling and *Mycobacterium marinum* infection mimicking seronegative rheumatoid arthritis complicated by anti-tumor necrosis factor  $\alpha$  therapy. *Arthritis Care Res* 2011; 63:160–164.
- Wu TS, et al:** Fish tank granuloma caused by *Mycobacterium marinum*. *PLoS One* 2012; 7:e41296.



Bonus images for this chapter can be found online at

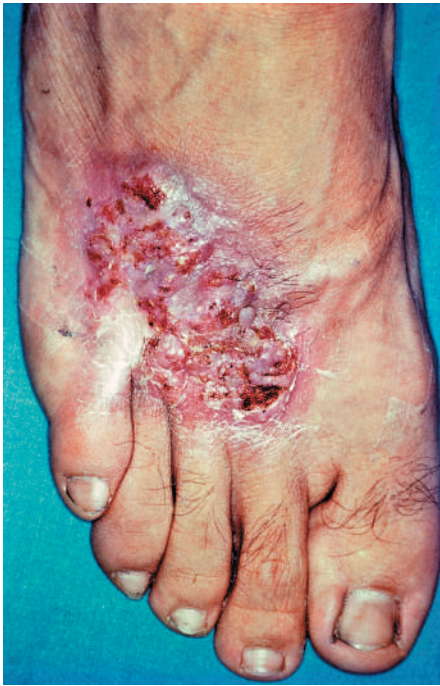[expertconsult.inkling.com](http://expertconsult.inkling.com)

**eFig. 16-1** *Mycobacterium marinum* infection.

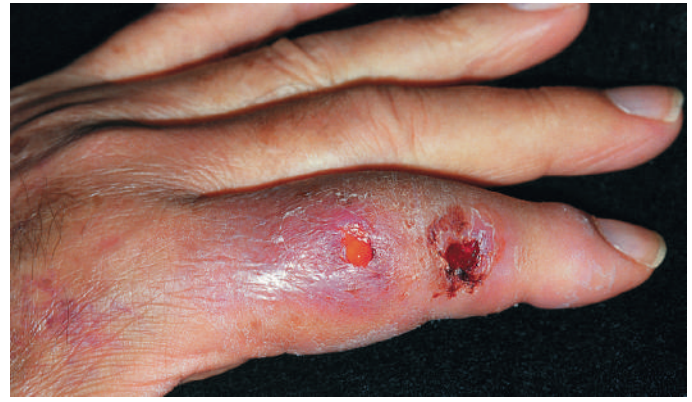**eFig. 16-2** Disseminated *Mycobacterium marinum* infection in systemic lupus erythematosus. (Courtesy of Curt Samlaska, MD.)

**eFig. 16-3** *Mycobacterium avium-intracellulare* complex ulceration.

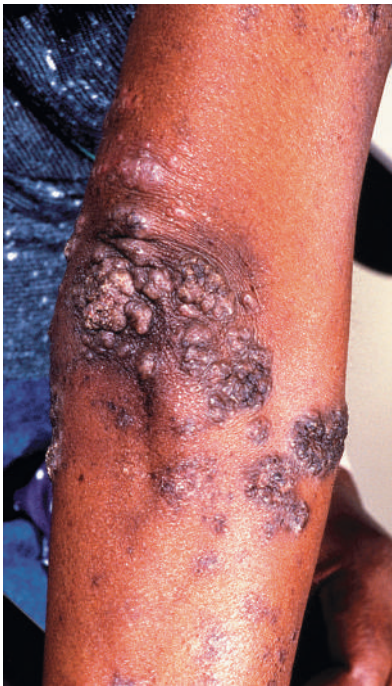



**eFig. 16-1**  
*Mycobacterium marinum* infection.



**eFig. 16-3** *Mycobacterium avium-intracellulare* complex ulceration.



**eFig. 16-2** Disseminated *Mycobacterium marinum* infection in systemic lupus erythematosus. (Courtesy of Curt Samlaska, MD.)



# Hansen's Disease

# 17

## EPIDEMIOLOGY

The World Health Organization (WHO) has committed itself to eliminating Hansen's disease as a public health problem. Elimination (not eradication) is considered as a prevalence of less than 1 case in 10,000 persons in any country. This target was globally met in 2000. The number of new cases worldwide of Hansen's disease declined from more than 750,000 in 2001 to 220,000 in 2012. Hansen's disease is endemic in certain regions, with 95% of cases reported from 16 countries. Brazil, India, and Indonesia account for 80% of all cases worldwide. In the United States, 168 new cases of Hansen's disease were reported in 2012. Although 90% of diagnosed U.S. cases are imported, Hansen's disease is endemic in the coastal southeastern United States and in Hawaii. In the southeastern states, cases may be related to exposure to armadillos, a natural host for the infectious agent.

It is believed that more than 90% of persons exposed to *Mycobacterium leprae* are able to resist infection. In endemic areas, between 1.7% and 31% of the population is seropositive for antibodies to leprosy-specific antigens, suggesting widespread exposure to the bacillus. About 17% of household contacts of multibacillary patients have *M. leprae*, which is detectable by polymerase chain reaction (PCR) on skin swabs, with 4% detectable in nasal swabs. This clears after the multibacillary patient has been treated with multidrug therapy (MDT) for 2 months. Thus, although many persons can be transiently infected, they apparently are able to resist overt clinical infection.

There appears to be a genetic basis for susceptibility to acquire Hansen's disease. Monozygotic twins have concordant disease in 60–85% of cases, and dizygotic twins in only 15–25%. Numerous genes have been identified as possibly conferring susceptibility to infection with *M. leprae*. Different genes have been identified in different populations, suggesting that multiple genetic causes of susceptibility to infection are possible with *M. leprae*. Tight genetic linkage with the PARK2/PACRG regulatory region, HLA-DRB1, and lymphotoxin A (LTA+80) has been detected. *PARK2* is a gene involved in the development of Parkinson's disease, and LTA+80 is a low-production lymphotoxin A allele associated with malaria parasitemia. Interleukin (IL)-17F single nucleotide polymorphism (SNP) is associated with an increased susceptibility to Hansen's disease, and type 1 reactions in paucibacillary patients. In Chinese patients, susceptibility was linked to multiple genes, including *CCDC12*, *C13orf31*, and a series of genes known to be associated with susceptibility to other mycobacterial diseases, including *NOD2*, *IL12B*, *RIP2K*, and *TNFSF15*.

In adult cases, men outnumber women 1.5:1. Although Hansen's disease occurs at all ages, most cases appearing or acquired in endemic areas present before age 35. Patients exposed to armadillos present on average at age 50. The latency period between exposure and overt signs of disease is usually 5 years for paucibacillary cases and an average of 10 years in

multibacillary cases. Infected women are likely to present during or immediately after pregnancy.

The mode of transmission remains controversial. Except for cases associated with armadillo exposure, other patients with Hansen's disease are thought to be the only possible source of infection. Rarely, tattooing or other penetrating injury to the skin can be the route of infection. Multibacillary cases are much more infectious than paucibacillary cases, so the nature of the source case is the most important factor in transmission. Contact is associated with acquiring infection. Household contacts represent 28% of new Hansen's disease patients; there is an 8–10 times greater risk of acquiring disease if the household contact has lepromatous disease, versus only 2–4 times if the contact has tuberculoid leprosy. In 80% of all new cases of Hansen's disease, there is a clear history of social contact with an untreated patient with Hansen's disease. PCR can detect *M. leprae* on the intact skin by saline washings in up to 90% of multibacillary patients with a high bacterial load (bacterial index [BI] >3). Up to 70% of nasal swabs are similarly positive. Whereas the swabs from the patients remain positive after 3 months of MDT, the swabs of household contacts become negative, suggesting that the bacilli seen in patients are nonviable, and that the risk of transmission is substantially reduced after the index patient is treated. Unfortunately, persons may be infectious from their skin or nasal secretions, with no clinical evidence of Hansen's disease (multibacillary patients who are not yet symptomatic and without identifiable skin lesions). This may make strategies relying on treatment of contacts of known Hansen's disease patients ineffective in eradicating the disease. In nonendemic areas, transmission to contacts is rare, a reassuring fact for the families of patients diagnosed in areas where Hansen's disease is uncommon. The last case of secondary transmission of Hansen's disease in the United Kingdom (UK) was in 1923!

## THE INFECTIOUS AGENT

Until recently, it had been thought that all cases of human and animal leprosy are caused by the same organism, *Mycobacterium leprae*. This is a weakly acid-fast organism that has not been successfully cultured in vitro. *M. leprae* grows best at temperatures (30°C) below the core body temperature of humans. This explains the localization of Hansen's disease lesions to cooler areas of the body and the sparing of the midline and scalp. The organism may be cultivated in mouse footpads and most effectively in armadillos, whose lower body temperature is more optimal for growth of *M. leprae*. Phenolic glycolipid 1 (PGL-1) is a surface glycolipid unique to the leprosy bacillus. In infected tissues, the leprosy bacillus favors intracellular locations, within macrophages and nerves. The genome of the leprosy bacillus has been sequenced and compared to its close relative, the tuberculous bacillus. The genome of *M. leprae* contains only 50% functional genes, apparently the result of significant reductive evolution. As



with other intracellular parasites, and in the absence of the ability to share DNA with other bacteria, *M. leprae* has lost many nonessential genes, including those involved in energy metabolism, making it dependent on the intracellular environment for essential nutrients. This may explain the extremely long generation time, 12–14 days, and the inability to culture *M. leprae* in vitro.

A second organism, “*Mycobacterium lepromatosis*,” has been isolated from Hansen’s disease patients in Mexico and reported as the major cause of leprosy in some regions. Some patients are infected with both *M. leprae* and *M. lepromatosis*. This second mycobacterium is specifically associated with the diffuse type of lepromatous leprosy (DLL), also known as “Lucio’s leprosy.” These are the patients who develop Lucio’s phenomenon. Invasion of the endothelial cells characterizes infection with the new organism. Although not all researchers accept “*M. lepromatosis*” as a second, separate species capable of causing Hansen’s disease, it does suggest more than one causative organism for leprosy.

## DIAGNOSIS

A diagnosis of Hansen’s disease must be considered in any patient with neurologic and cutaneous lesions. The diagnosis is frequently delayed in the developed world; clinicians do not readily think of Hansen’s disease because they may never have seen it. In the United States, this diagnostic delay averages 1½–2 years. In the UK, in more than 80% of patients with Hansen’s disease, the correct diagnosis was not suspected during the initial medical evaluation.

Hansen’s disease is diagnosed, as with other infectious diseases, by identifying the infectious organism in affected tissue. Because the organism cannot be cultured, this may be very difficult. Biopsies from skin or nerve lesions, stained for the bacillus with Fite-Faraco stain, are usually performed in the developed world. In some Hansen’s disease clinics, and in the developing world where the disease is endemic, organisms are identified in slit smears of the skin. Smears are very specific, but 70% of all patients with Hansen’s disease have negative smears. Smears are taken from lesions and cooler areas of the skin, such as the earlobes, elbows, and knees. If organisms are found on skin smears, the patient is said to be multibacillary. If the results of skin smears are negative (and there are five or fewer lesions), the patient is called paucibacillary.

Nerve involvement is detected by enlargement of peripheral nerves and lesional loss of sensation. Enlarged nerves are found in more than 90% of patients with multibacillary Hansen’s disease and in 75–85% of patients with paucibacillary disease. About 70% of lesions have reduced sensation, but

lesional dysesthesia is not detected in patients with multibacillary Hansen’s disease, the most infectious form.

Serologic tests to detect antibodies against *M. leprae*-unique antigens (PGL-1) and PCR to detect small numbers of organisms in infected tissue have not improved diagnosis. These are universally positive in patients with multibacillary disease, in whom the diagnosis is not difficult. In paucibacillary patients, these tests are often negative, and in endemic areas there is a high background rate of positivity of serologic tests. These tests are therefore of no real value in the diagnosis of patients with cutaneous Hansen’s disease. In pure neural Hansen’s disease, however, about 50% of patients are seropositive, and serologic testing might be of use. Seropositivity might also be used to identify persons in endemic areas at risk of developing Hansen’s disease, and these persons could receive chemoprophylaxis. Also, seropositivity for antibodies to PGL-1 may be used as a surrogate field marker for high bacterial load (multibacillary status) and to identify patients who might require longer therapy to cure their infection. Since PGL-1 antibody tests are best for detecting patients with poor cell-mediated immunity against *M. leprae*, and who consequently have high humoral immunity against *M. leprae* and multibacillary disease, there is a need for a diagnostic test to identify those persons who have adequate cell-mediated immunity, but who may be at risk of developing paucibacillary Hansen’s disease. The lepromin skin test has not served this need, in contrast to tuberculin skin testing. Based on the technology of the T-cell interferon- $\gamma$  (IFN- $\gamma$ ) production-based assays for *M. tuberculosis* infection, researchers have identified unique peptides of *M. leprae* and developed a research IFN- $\gamma$  release assay (IGRA). This was able to detect all paucibacillary cases in a Hansen’s disease cohort. In addition, 13 of 14 household contacts of Hansen’s disease patients were positive with IGRA. Ideally, in endemic areas, both serologic and cell-based assays can be used to detect all patients with Hansen’s disease.

In endemic areas, active surveillance of contacts is recommended. In Brazil, about 2% of both in-domicile and extradomiciliary contacts are found to have Hansen’s disease. Most cases are associated with patients who have multibacillary Hansen’s disease.

## CLASSIFICATION

Hansen’s disease may present with a broad spectrum of clinical diseases. The Ridley and Jopling scale classifies cases based on clinical, bacteriologic, immunologic, and histopathologic features (Table 17-1). In many exposed patients, the infection apparently clears spontaneously, and no clinical lesions develop. Patients who do develop clinical disease are broadly

**Table 17-1** Spectrum of host-parasite relationship in Hansen’s disease

	High resistance		Unstable resistance		No resistance
	Tuberculoid (TT)	Borderline tuberculoid (BT)	Borderline (BB)	Borderline lepromatous (BL)	Lepromatous (LL)
Lesions	1–3	Few	Few or many asymmetric	Many	Numerous and symmetric
Smear for bacilli	0	1+	2+	3+	4+
Lepromin test	3+	2+	+	+	0
Histology	Epithelioid cells decreasing → Nerve destruction, sarcoidlike granuloma			Increasing histiocytes, foam cells, granuloma, xanthomalike	

Modified from Dr. J.H. Pettit.

classified into two groups for the purposes of treatment and for trials that compare treatment strategies. Paucibacillary patients have few or no organisms in their lesions and usually have three to five lesions or fewer (for treatment purposes, the finding of acid-fast bacilli by stains or smears classifies a patient as having multibacillary Hansen's disease). Multibacillary patients have multiple, symmetric lesions and organisms detectable by biopsy or smears. The individual's cell-mediated immune response to the organism determines the form that Hansen's disease will take in the individual. If the cell-mediated immune response against *M. leprae* is strong, the number of organisms will be low (paucibacillary), and conversely, if this response is inadequate, the number of organisms will be high (multibacillary).

The most common outcome after exposure is probably spontaneous cure. If skin disease does appear, the initial clinical lesion may be a single, hypopigmented patch, perhaps with slight anesthesia. This is called indeterminate disease, since the course of the disease cannot be predicted at this stage. The lesion may clear spontaneously or may progress to any other form of Hansen's disease.

The spectrum of Hansen's disease has two stable poles, the tuberculoid and lepromatous forms (see Table 17-1). These so-called polar forms do not change; the patient remains in one or the other form throughout the course of the disease. The polar tuberculoid form (called TT), the type with high cell-mediated immunity, is characterized by less than five lesions (often only one) and very few organisms (paucibacillary disease). The patient has strong cell-mediated immunity against the organism. The natural history of many TT leprosy patients is for spontaneous cure over several years. The polar lepromatous form (LL) has very limited cell-mediated immunity against the organism; lesions are numerous and contain many organisms (multibacillary). Between these two poles is every possible degree of infection, forming the borderline spectrum. Cases near the tuberculoid pole are called borderline tuberculoid (BT), those near the lepromatous pole are called borderline lepromatous (BL), and those in the middle are called borderline borderline (BB). Borderline Hansen's disease is characteristically unstable, and with time, cases move from the TT to the LL pole, a process called downgrading.

Hansen's disease may involve only the nerves. This pure neural disease may be indeterminate, tuberculoid, or lepromatous (paucibacillary or multibacillary) and is so classified. In Nepal and India, pure neural Hansen's disease may represent as much as 5% of all new cases.

### Early and indeterminate Hansen's disease

Usually, the onset of Hansen's disease is insidious. Prodromal symptoms are generally so slight that the disease is not recognized until the appearance of a cutaneous eruption. Actually, the first clinical manifestation in 90% of patients is numbness, and years may elapse before skin lesions or other signs are identified. The earliest sensory changes are loss of the senses of temperature and light touch, most often in the feet or hands. The inability to discriminate hot from cold may be lost before pinprick sensibility. Such dissociation of sensibility is especially suspicious. The distribution of these neural signs and their intensity will depend on the type of disease that is evolving.

Often, the first lesion noted is a solitary, poorly defined, hypopigmented macule that merges into the surrounding normal skin. Less often, erythematous macules may be present. Such lesions are most likely to occur on the cheeks, upper arms, thighs, and buttocks. Examination reveals that sensory functions are either normal or minimally altered. Peripheral

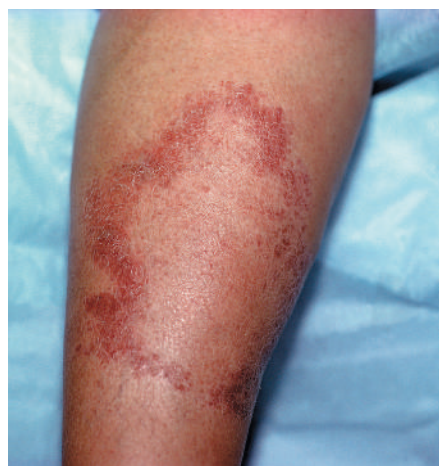

Fig. 17-1 Tuberculoid leprosy.

nerves are not enlarged, and plaques and nodules do not occur. Histologically, a variable lymphocytic infiltrate (without granulomas) is seen, sometimes with involvement of the cutaneous nerves. Usually, no bacilli, or only a few, are seen on biopsy of this indeterminate form. It is the classification, not the diagnosis, that is indeterminate. Few cases remain in this state; they evolve into lepromatous, tuberculoid, or borderline types, or (if cell-mediated immunity is good) often spontaneously resolve and never develop other signs or symptoms of Hansen's disease.

### Tuberculoid leprosy

Tuberculoid lesions are solitary or few in number (five or less) and asymmetrically distributed. Lesions may be hypopigmented or erythematous and are usually dry, scaly, and hairless (Fig. 17-1). The typical lesion of tuberculoid leprosy is the large, erythematous plaque with a sharply defined and elevated border that slopes down to a flattened atrophic center. This has been described as having the appearance of "a saucer right side up." Lesions may also be macular and hypopigmented or erythematous, resembling clinically indeterminate lesions. The presence of palpable induration and neurologic findings distinguish tuberculoid lesions from indeterminate lesions clinically. The most common locations are the face, limbs, or trunk; the scalp, axillae, groin, and perineum are not involved.

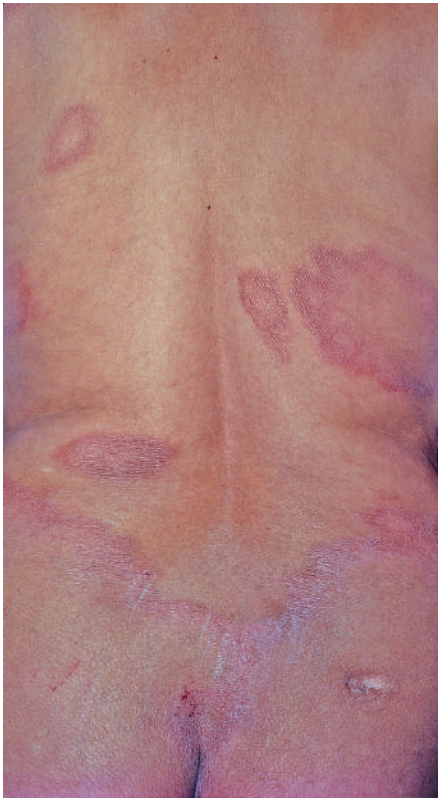
A tuberculoid lesion is anesthetic or hypesthetic and anhidrotic, and superficial peripheral nerves serving or proximal to the lesion are enlarged, tender, or both. The greater auricular nerve and the superficial peroneal nerve may be visibly enlarged. Nerve involvement is early and prominent in tuberculoid leprosy, leading to characteristic changes in the muscle groups served. There may be atrophy of the interosseous muscles of the hand, with wasting of the thenar and hypothenar eminences, contracture of the fingers, paralysis of the facial muscles, and footdrop. Facial nerve damage dramatically increases the risk for ocular involvement and vision loss.

The evolution of the lesions is generally slow. There is often spontaneous remission of the lesions in about 3 years, or remission may result sooner with treatment. Spontaneous involution may leave pigmentary disturbances.

### Borderline tuberculoid (BT) leprosy

Borderline tuberculoid lesions are similar to tuberculoid lesions, except that they are smaller and more numerous





**Fig. 17-2** Borderline tuberculoid leprosy.

(Fig. 17-2). Satellite lesions around large macules or plaques are characteristic.

### Borderline borderline (BB) leprosy

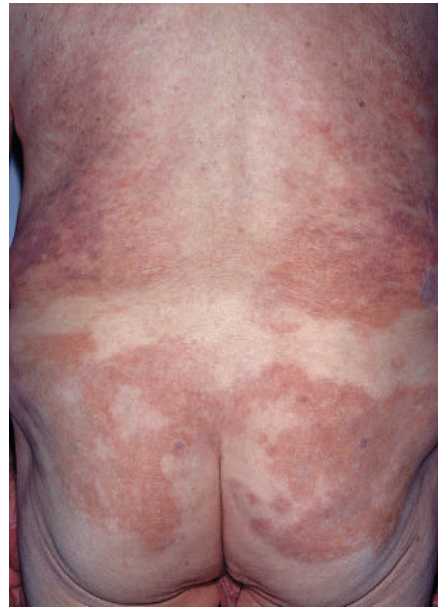
In borderline leprosy, the skin lesions are numerous (but countable) and consist of red, irregularly shaped plaques. Small satellite lesions may surround larger plaques. Lesions are generalized but asymmetric. The edges of lesions are not as well defined as the ones seen at the tuberculoid pole. Nerves may be thickened and tender, but anesthesia is only moderate in the lesions.

### Borderline lepromatous (BL) leprosy

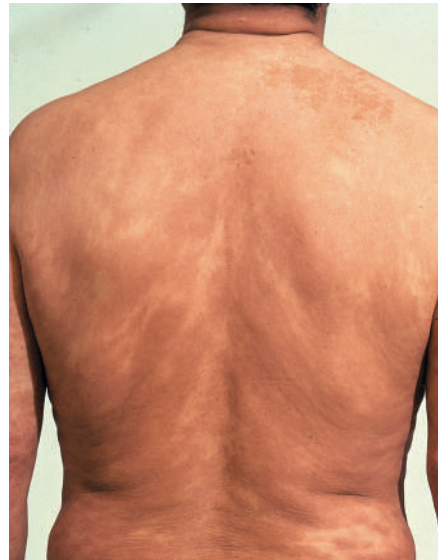In borderline lepromatous leprosy, the lesions are symmetric and numerous (too many to count) and may include macules, papules, plaques, and nodules (Fig. 17-3). The number of small, lepromatous lesions outnumbers the larger, borderline-type lesions. Nerve involvement appears later; nerves are enlarged, tender, or both, and it is important to note that involvement is symmetric. Sensation and sweating over individual lesions are normal. Patients usually do not show the features of full-blown lepromatous leprosy, such as madarosis (loss of the eyebrows), keratitis, nasal ulceration, and leonine facies.

### Lepromatous leprosy

Lepromatous leprosy may begin as such or develop following indeterminate leprosy or from downgrading of borderline leprosy. The cutaneous lesions of lepromatous leprosy consist mainly of pale macules (Fig. 17-4) or diffuse infiltration of the skin. There is a tendency for the disease to become progressively worse without treatment. Lepromatous leprosy may be



**Fig. 17-3** Borderline lepromatous leprosy.

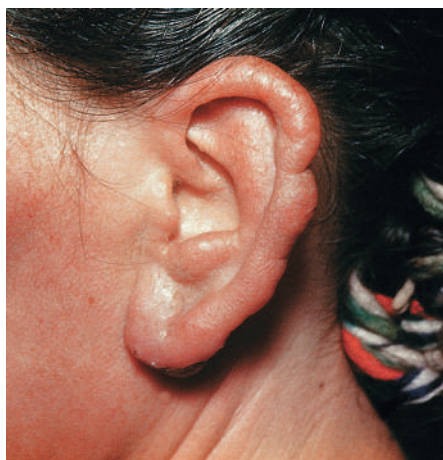

**Fig. 17-4** Lepromatous leprosy.

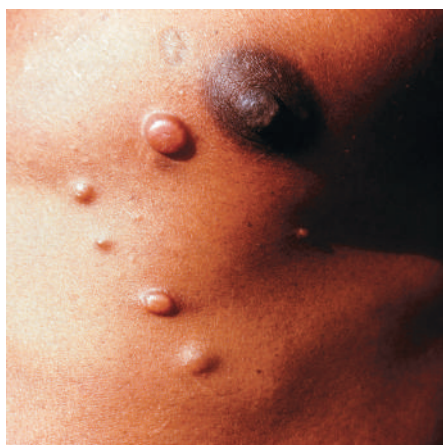divided into a polar form (LLp) and a subpolar form (LLs); these forms may behave differently.

Macular lepromatous lesions are diffusely and symmetrically distributed over the body. Tuberculoid macules are large and few in number, whereas lepromatous macules are small and numerous. Lepromatous macules are poorly defined, show no change in skin texture, and blend imperceptibly into the surrounding skin. There is minimal or no loss of sensation over the lesions, no nerve thickening, and no change in sweating. A slow, progressive loss of hair takes place from the outer third of the eyebrows, then the eyelashes, and finally the body; however, the scalp hair usually remains unchanged.

Lepromatous infiltrations may be divided into the diffuse, plaque, and nodular types. The diffuse type is characterized by the development of a diffuse infiltration of the face, especially the forehead, madarosis, and a waxy, shiny appearance of the skin, sometimes described as "varnished." Diffuse leprosy of Lucio (DLL) is a striking form, uncommon except in western Mexico and certain other Latin American areas, where almost one-third of lepromatous cases may be of this type. This form of lepromatous leprosy is characterized by diffuse lepromatous infiltration of the skin; localized lepromas



**Fig. 17-5** Lepromatous leprosy, ear involvement.



**Fig. 17-6** Histoid leprosy.

do not form. A unique complication of this subtype is the reactionary state referred to as Lucio's phenomenon (erythema necroticans).

The infiltrations may be manifested by the development of nodules called lepromas. The early nodules are poorly defined and occur most often in acral parts: ears (Fig. 17-5), brows, nose, chin, elbows, hands, buttocks, or knees.

Nerve involvement invariably occurs in lepromatous leprosy but develops very slowly. As with the skin lesions, nerve disease is bilaterally symmetric, usually in a stocking-glove pattern. This is frequently misdiagnosed as diabetic neuropathy in the United States if it is the presenting manifestation.

## Histoid leprosy

Histoid leprosy is an uncommon form of multibacillary Hansen's disease in which skin lesions appear as large, yellow-red, shiny papules and nodules in the dermis or subcutaneous tissue (Fig. 17-6). Lesions appear on a background of normal skin. They vary in size from 1 to 15 mm in diameter, and may appear anywhere on the body but favor the buttocks, lower back, face, and bony prominences. They may closely resemble molluscum contagiosum. This pattern may appear de novo but has mostly been described in patients with resistance to dapsone.

## NERVE INVOLVEMENT

Nerve involvement is characteristic and unique to Hansen's disease. This neural predilection or neurotropism is a histo-

pathologic hallmark of Hansen's disease. Nerve involvement is responsible for the clinical findings of anesthesia within lesions (paucibacillary and borderline leprosy), and of a progressive stocking-glove peripheral neuropathy (lepromatous leprosy). The neuropathy is termed "primary impairments" (WHO grade 1). Secondary (or visible) impairments (WHO grade 2) are a consequence of the neuropathy and include skin fissures, wounds, clawing of digits, contractures, shortening of digits, and blindness. Neural damage leads to deformities and in endemic regions results in Hansen's disease being a major cause of "limitations of activity" (formerly called disability) and "restrictions in social participation" (formerly termed handicap). Neuropathy is present in 1.3–3.5% of paucibacillary patients and 7.5–24% of multibacillary patients undergoing MDT. Secondary impairments occur in 33–56% of multibacillary patients. Neuropathy may progress, even after effective MDT, and secondary impairments may continue to appear for years as a consequence of the neuropathy. This requires patients with neuropathy to be constantly monitored, even though they are "cured" of their infection.

Nerve enlargement is rare in other skin diseases, so the finding of skin lesions with enlarged nerves should suggest Hansen's disease. Nerve involvement tends to occur with skin lesions, and the pattern of nerve involvement parallels the skin disease. Tuberculoid leprosy is characterized by asymmetric nerve involvement localized to the skin lesions. Lepromatous nerve involvement is symmetric and not associated with skin lesions. Nerve involvement without skin lesions, called pure neural leprosy, can occur and may be either tuberculoid (paucibacillary) or lepromatous (multibacillary). Nerve disease can be symptomatic or asymptomatic.

Leprosy bacilli may be delivered to the nerves through the perineural and endoneural blood vessels. Once the bacilli transgress the endothelial basal lamina and are in the endoneurium, they enter resident macrophages or selectively enter Schwann cells. Damage to the nerves could then occur by the following mechanisms:

1. Obstruction of neural vessels
2. Vasculitis of neural vessels
3. Interference with metabolism of the Schwann cell, making it unable to support the neuron
4. Immunologic attack on endothelium or nerves
5. Infiltration and proliferation of *M. leprae* in the closed and relatively nonexpandable endoneural and perineural spaces

Different and multiple mechanisms may occur in different forms of Hansen's disease and in the same patient over time. The selective ability of *M. leprae* to enter Schwann cells is unique among bacteria. *M. leprae*-unique PGL-1, expressed abundantly on the surface of leprosy bacilli, binds selectively to the  $\alpha 2 G$  module of laminin 2. This  $\alpha 2$  chain is tissue restricted and specifically expressed on peripheral nerve Schwann cells. The binding of *M. leprae* to laminin 2 places it in apposition to the Schwann cell basement membrane when laminin 2 binds to the dystroglycan complex on the Schwann cell membrane. These bound *M. leprae* bacteria are endocytosed into the Schwann cells, giving *M. leprae* selective access to the inside of Schwann cells. Other accessory binding molecules may facilitate the binding and endocytosis. The nerves become immunologic targets when they present *M. leprae* antigens on their surface in the context of major histocompatibility complex (MHC) class II molecules. Schwann cells and thus nerves are usually protected from immunologic attack mediated by the adaptive immune system because they rarely present MHC class II antigens on their surface. In Hansen's disease, expression of these immunologic molecules occurs on the surface of



Schwann cells, making them potential targets for CD4+ cytotoxic T cells. This mechanism may be important in the nerve damage that occurs in type 1 (reversal) reactions.

Schwann cells have been infected with *M. leprae* in vitro. Infected Schwann cells with high bacterial load are reprogrammed into mesenchymal stem cell-like cells. In association with Schwann cells, these dedifferentiated cells attract histiocytes and form granulomas. The attracted histiocytes are infected by the mycobacteria-containing Schwann cells and are released from the granulomas. If this process also occurs in vivo, it may be the mechanism by which multibacillary disease is spread throughout the body from a reservoir of infected nerves.

The neural signs in Hansen's disease are dysesthesia, nerve enlargement, muscular weakness and wasting, and trophic changes. The lesions of the vasomotor nerves accompany the sensory disturbances or may precede them. Dysesthesia develops in a progressive manner. The first symptom is usually an inability to distinguish hot and cold. Subsequently, the perception of light touch is lost, then that of pain, and lastly the sense of deep touch. At times, the sensory changes in large Hansen's disease lesions are not uniform because of the variation in the involvement of the individual neural filaments supplying the area. Therefore, the areas of dysesthesia may not conform to the distribution of any particular nerve and, except in lepromatous cases, are not symmetric.

Nerve involvement mainly affects (and is most easily observed in) the more superficial nerve trunks, such as the ulnar, median, radial, peroneal, posterior tibial, fifth and seventh cranial, and especially the great auricular nerve. Beaded enlargements, nodules, or spindle-shaped swellings may be found, which at first may be tender. Neural abscesses may form. The ulnar nerve near the internal condyle of the humerus may be as thick as the little finger, round, and stiff and is often easily felt several centimeters above the elbow.

Because the presentation of neural involvement in Hansen's disease is variable, the diagnosis is often not suspected, especially in nonendemic areas. Even in endemic areas, the diagnosis may be delayed. Between one half and one third of patients with pure neural Hansen's disease, a biopsy of hypesthetic skin can show specific leprotic skin changes, and if nonspecific inflammation is considered confirmatory, the positivity of such biopsies is greater than 50%. Therefore, skin biopsy of a hypesthetic skin site should be considered before nerve biopsy when pure neural Hansen's disease is a possibility.

As a result of the nerve damage, areas of anesthesia, paralysis, and trophic disorders in the peripheral parts of the extremities gradually develop. Muscular paralysis and atrophy generally affect the small muscles of the hands and feet or some of the facial muscles, producing weakness and progressive atrophy. Deeper motor nerves are only rarely involved. The fingers develop contractures, with the formation of a clawhand (Fig. 17-7). Also, as the result of resorption of phalangeal bones, fingers and toes become shorter. Ptosis, ectropion, and a masklike appearance occur from damage to the fifth and seventh cranial nerves.

Subsequent to nerve damage, ulceration, hyperkeratosis, bullae, alopecia, anhidrosis, and mal perforans pedis can develop. Trophic ulceration usually manifests as a perforating ulcer on the ball or heel of the foot.

## OCULAR INVOLVEMENT

Corneal erosions, exposure keratitis, and ulcerations may result from involvement of the seventh cranial nerve in Hansen's disease patients. Specific changes may include corneal

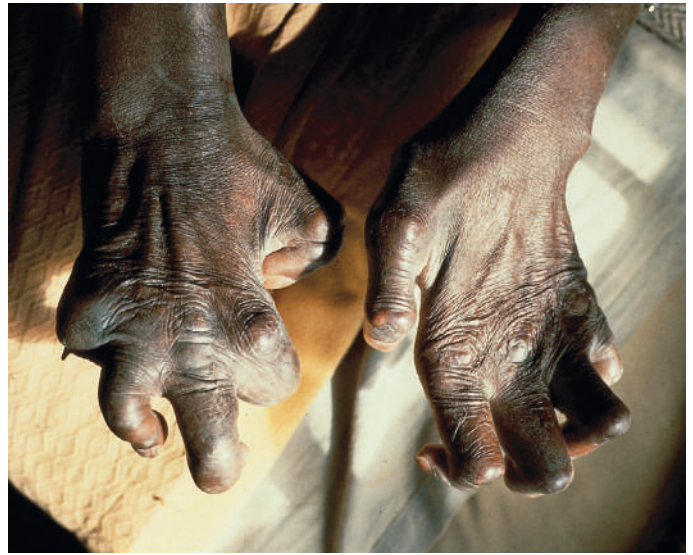

Fig. 17-7 Claw hand of Hansen's disease.

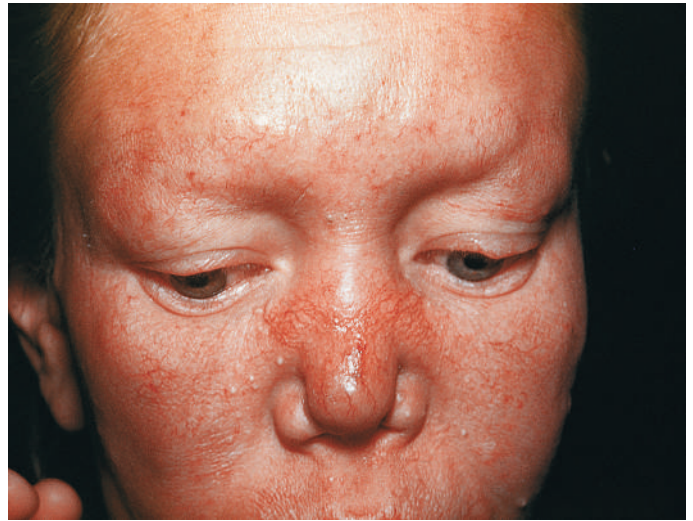

Fig. 17-8 Lepromatous leprosy with collapse of nasal bridge.

opacity, avascular keratitis, pannus formation, interstitial keratitis, and corneal lepromas. The corneal opacities enlarge and finally form visible white flecks called "pearls." When (in borderline lepromatous or lepromatous cases only) the iris and the ciliary body become involved, miliary lepromas (iris pearls), nodular lepromas, chronic granulomatous iritis, and acute diffuse iridocyclitis may result. Of multibacillary patients, 2.8–4.6% are blind at diagnosis, and 11% will have a potentially blinding process.

## MUCOUS MEMBRANE INVOLVEMENT

The mucous membranes may also be affected, especially in the nose, mouth, and larynx. The nasal mucosa is most frequently involved, and lepromatous patients frequently complain of chronic nasal congestion. By far the most common lesions in the nose are infiltrations and nodules. Perforation of the nasal septum may occur in patients with advanced Hansen's disease, with collapse of the nasal bridge (Fig. 17-8). Saddle-nose deformities and loss of the upper incisor teeth can occur.

Nodules occurring on the vocal cords will produce hoarseness.

## VISCERAL INVOLVEMENT

In lepromatous leprosy, the body is diffusely involved and bacteremia occurs. Except for the gastrointestinal tract, lungs, and brain, virtually every organ can contain leprosy bacilli. The lymph nodes, bone marrow, liver, spleen, and testicles are most heavily infected. Visceral infection is restricted mostly to the reticuloendothelial system, which despite extensive involvement rarely produces symptoms or findings. Testicular atrophy with loss of androgens can result in gynecomastia (hypertrophy of nipple) and/or gynecomastia, or premature osteoporosis. Secondary amyloidosis with renal impairment may complicate multibacillary leprosy. Glomerulonephritis occurs in more than 5% and perhaps as many as 50% of Hansen's disease patients and is not correlated with bacillary load or the presence of erythema nodosum leprosum.

## SPECIAL CLINICAL CONSIDERATIONS AND HANSEN'S DISEASE

### Pregnancy

Hansen's disease may be complicated in several ways by pregnancy. As a state of relative immunosuppression, pregnancy may lead to an exacerbation or reactivation after apparent cure. In addition, pregnancy or, more often, the period immediately after delivery may be associated with the appearance of reactional states in patients with Hansen's disease. Pregnant patients with Hansen's disease cannot be given certain medications used to treat the disease, such as thalidomide, ofloxacin, and minocycline. MDT is tolerated by pregnant women if these restricted agents are avoided.

### Human immunodeficiency virus

Human immunodeficiency virus (HIV) infection, although a cause of profound immunosuppression of the cell-mediated immune system, does not seem to have an adverse effect on the course of Hansen's disease. Patients are treated with the same agents and can be expected to have similar outcomes in general. Duration of treatment with MDT may need to be extended in patients with HIV infection. Treatment of HIV-infected patients with Hansen's disease using effective antiretroviral drugs may be associated with the appearance of reactional states (usually type 1) as part of the immune reconstitution syndrome. This virtually always occurs in the first 6 months of antiviral therapy.

### Organ transplantation

Hansen's disease has been reported in organ transplant recipients (renal, liver, heart, and bone marrow). If the disease has been treated and the patient is then given a transplant, Hansen's disease can recur, apparently as a result of the immunosuppressive regimen. In addition, transplant patients may present with new Hansen's disease, most frequently toward the lepromatous pole (BL or LL). Erythema nodosum leprosum may occur. The correct management of the organ transplant recipient with Hansen's disease is not known, but MDT with highly active agents is usually given.

Patients with Hansen's disease may also acquire a second cutaneous mycobacterial infection. This may occur as a complication of corticosteroid treatment for reactional states.

*Mycobacterium fortuitum* has been reported in one case, and one of the authors has seen coinfection with *M. haemophilum*. In these patients, the MDT plan should include agents effective against both Hansen's disease and the second mycobacterial infection.

## IMMUNOPATHOGENESIS

The patient's immune reaction to the leprosy bacillus is a critical element in determining the outcome of infection. Tuberculoïd patients make well-formed granulomas that contain helper T cells, whereas lepromatous patients have poorly formed granulomas, and suppressor T cells predominate. The cytokine profile in tuberculoïd lesions is good cell-mediated immunity, with IFN- $\gamma$  and interleukin-2 (IL-2) present. In lepromatous patients, these cytokines are reduced, and IL-4, IL-5, and IL-10, cytokines that downregulate cell-mediated immunity and enhance suppressor function and antibody production, are prominent. Lepromatous leprosy thus represents a classic T-helper cell type 2 (Th2) response to *M. leprae*. Lepromatous patients have polyclonal hypergammaglobulinemia and high antibody titers to *M. leprae*-unique antigens and may have false-positive syphilis serology, rheumatoid factor, and antinuclear antibodies. Although the cell-mediated immune response of lepromatous patients to *M. leprae* is reduced, these patients are not immunosuppressed for other infectious agents. Tuberculosis behaves normally in patients with lepromatous leprosy.

## HISTOPATHOLOGY

Ideally, biopsies should be performed from the active border of typical lesions and should extend into the subcutaneous tissue. Punch biopsies are usually adequate. Fite-Faraco stain is optimal for demonstrating *M. leprae*. Because the diagnosis of Hansen's disease is associated with significant social implications, evaluation must be complete, including evaluation of multiple sections in paucibacillary cases. Consultation with a pathologist experienced in the diagnosis of Hansen's disease can be helpful if the diagnosis is suspected but organisms cannot be identified in the affected tissue, especially in paucibacillary disease and reactional states. PCR has not been very useful; it is positive in only 50% of paucibacillary cases. The histologic features of Hansen's disease correlate with the clinical pattern of disease. Nerve involvement is characteristic, and histologic perineural and neural involvement should suggest Hansen's disease.

### Tuberculoïd leprosy

Dermal tuberculoïd granulomas, consisting of groups of epithelioid cells with giant cells, are found in tuberculoïd leprosy. The granulomas are elongated and generally run parallel to the surface, following neurovascular bundles. The epithelioid cells are not vacuolated or lipidized. The granulomas extend up to the epidermis, with no grenz zone. Lymphocytes are found at the periphery of the granulomas. Acid-fast bacilli are rare. The most important specific diagnostic feature, besides finding bacilli, is selective destruction of nerve trunks and the finding of perineural concentric fibrosis. An S-100 stain may show this selective neural destruction by demonstrating unrecognizable nerve remnants in the inflammatory foci. Bacilli are most frequently found in nerves, but the subepidermal zone and arrector pili muscles are other fruitful areas.



## Borderline tuberculoid leprosy

The histopathology of borderline tuberculoid leprosy is similar to that seen in the tuberculoid variety. However, epithelioid cells may show some vacuolation, bacilli are more abundant, and a grenz zone separates the inflammatory infiltrate from the overlying epidermis in BT leprosy.

## Borderline leprosy

In borderline leprosy, granulomas are less well organized, giant cells are not seen, the macrophages have some foamy cytoplasm, and organisms are abundant.

## Borderline lepromatous leprosy

In borderline lepromatous lesions, foamy histiocytes, rather than epithelioid cells, make up the majority of the granuloma. Lymphocytes are still present and may be numerous in the granulomas but are dispersed diffusely within them, not organized at the periphery. Perineural involvement with lymphocyte infiltration may be present. Organisms are abundant and may be found in clumps.

## Lepromatous leprosy

In lepromatous leprosy, granulomas are composed primarily of bacilli-laden and lipid-laden histiocytes. These are the so-called lepra cells or foam cells of Virchow. The infiltrate is localized in the dermis and may be purely perivascular or sheetlike and separated from the epidermis by a well-defined grenz zone. Acid-fast bacilli are typically abundant and appear as round clumps (globi). Pure polar lepromatous leprosy differs from the subpolar type primarily in the paucity of lymphocytes in the pure polar form.

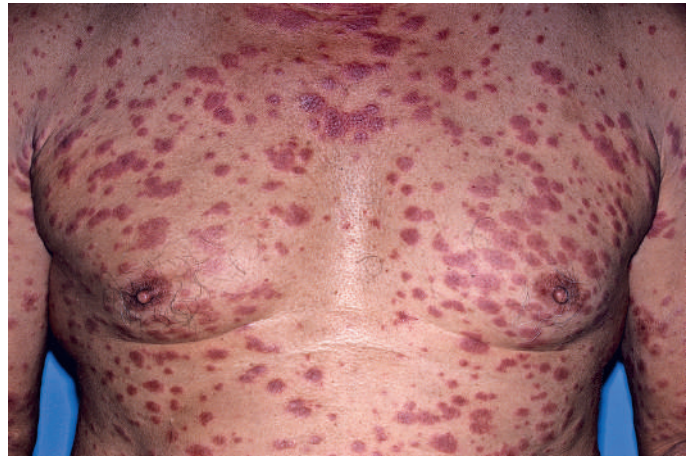## REACTIONAL STATES

Reactions are a characteristic and clinically important aspect of Hansen's disease. About 50% of patients will experience a reaction after the institution of MDT. In addition to antibiotic therapy, intercurrent infections, vaccination, pregnancy, vitamin A, iodides, and bromide may trigger reactions. Reactions can be severe and are an important cause of permanent nerve damage in borderline patients. Reactional states frequently appear abruptly, unlike Hansen's disease itself, which changes slowly. A reaction is therefore a common reason why patients seek consultation. In addition, if a patient believes that the chemotherapy is triggering the reaction, the patient will tend to discontinue the treatment, leading to treatment failure.

Reactional states are divided into two forms, called type 1 and type 2 reactions. Type 1 reactions are caused by cell-mediated immune inflammation within existing skin lesions. These generally occur in patients with borderline leprosy (BT, BB, BL). Type 2 reactions are mediated by immune complexes and occur in lepromatous patients (BL, LL).

### Type 1 reactions (reversal, lepra, and downgrading reactions)

Type 1 reactions represent an enhanced cell-mediated immune response to *M. leprae* and usually occur after treatment is



**Fig. 17-9** Type 1 reaction in Hansen's disease. (Courtesy of Curt Samlaska, MD.)

initiated. If the reactions occur with antibiotic chemotherapy, they are called reversal reactions, and if they occur as borderline disease shifts toward the lepromatous pole (downgrading), they are called downgrading reactions. These two reaction types are clinically identical. Patients in all parts of the borderline spectrum may be affected by type 1 reactions, but these are most severe in patients with borderline lepromatous leprosy who have a large amount of *M. leprae* antigen and therefore have prolonged and repeated reactions during treatment.

Type 1 reactions clinically present with inflammation of existing lesions (Fig. 17-9). The patient has no systemic symptoms, such as fever, chills, or arthralgias. Lesions swell, become erythematous, and are sometimes tender, simulating cellulitis. In severe cases, ulceration can occur.

Patients may state that new lesions appeared with the reaction, but these probably represent subclinical lesions that were highlighted by the reaction. The major complication of type 1 reactions is nerve damage. As the cell-mediated inflammation attacks *M. leprae* antigen, any infected tissue compartment can be damaged. Because bacilli are preferentially in nerves, neural symptoms and findings are often present. Reversal reaction occurring within a nerve may lead to sudden loss of nerve function and permanent damage to that nerve. This makes type 1 reactions an emergency. In this setting, affected nerves are enlarged and tender. In other patients, the neuritis may be subacute or chronic and of limited acute symptomatology, but may still result in severe nerve damage. Histologically, skin lesions show perivascular and perineural edema and large numbers of lymphocytes. Severe reactions may demonstrate tissue necrosis. Bacilli are reduced.

### Type 2 reactions (erythema nodosum leprosum)

Erythema nodosum leprosum (ENL) occurs in half of patients with borderline lepromatous or lepromatous leprosy, 90% of the time within a few years of institution of antibiotic treatment for Hansen's disease or during pregnancy. ENL is a circulating immune complex-mediated disease. As such, in contrast to type 1 reactions, type 2 (ENL) can result in multi-system involvement and is usually accompanied by systemic symptoms (fever, myalgias, arthralgias, anorexia). Skin lesions are characteristically erythematous, subcutaneous, and dermal nodules that are widely distributed (Fig. 17-10). They do not occur at the sites of existing skin lesions. Severe skin lesions can ulcerate. Unlike classic erythema nodosum, lesions of ENL are generalized and favor the extensor arms and medial thighs.

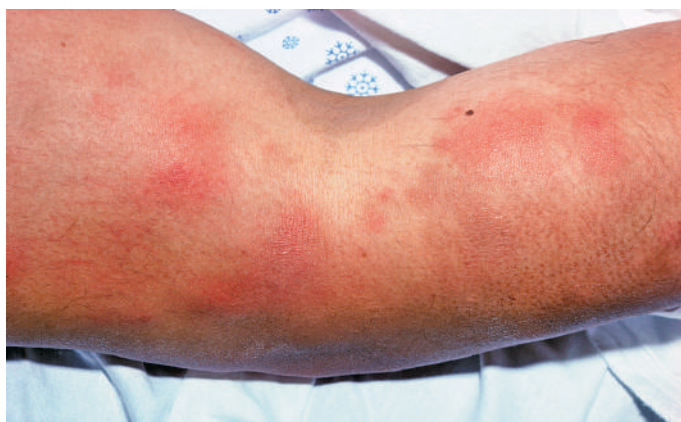

Fig. 17-10 Erythema nodosum leprosum.

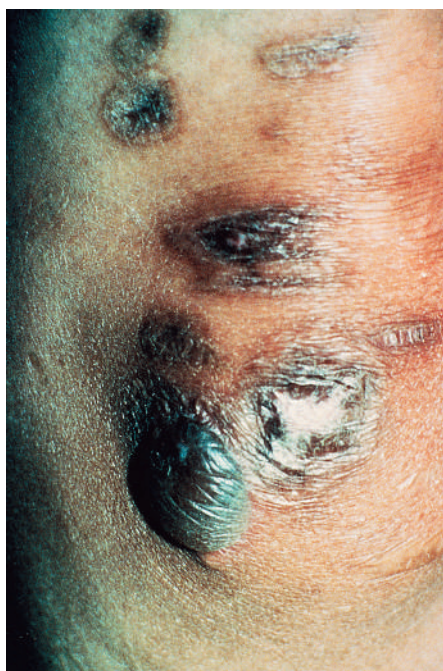


Fig. 17-11 Lucio's phenomenon, early bullous lesions.

A multisystem disease, ENL can produce conjunctivitis, neuritis, keratitis, iritis, synovitis, nephritis, hepatosplenomegaly, orchitis, and lymphadenopathy. The intensity of the reaction may vary from mild to severe and may last from a few days to weeks, months, or even years. Histologically, ENL demonstrates a leukocytoclastic vasculitis. Laboratory evaluation will reveal an elevated sedimentation rate, increased C-reactive protein, and a neutrophilia.

### Lucio's phenomenon

Lucio's phenomenon is an uncommon and unusual reaction that occurs in patients with diffuse lepromatous leprosy (DLL) of the "la bonita" type, most often found in western Mexico. Some consider it a subset of ENL, but Lucio's reaction differs in that it lacks neutrophilia and systemic symptoms. It is not associated with institution of antibiotic treatment as is ENL, and Lucio's phenomenon is frequently the reason for initial presentation in affected patients. Purpuric macules evolve to bullous lesions that rapidly ulcerate, especially below the knees (Fig. 17-11). These may be painful but may also be relatively asymptomatic. Histologically, bacilli are numerous and, in addition to being in the dermis, are seen within blood

vessel walls with thrombosis of middermal vessels, resulting in cutaneous infarction. Fever, splenomegaly, lymphadenopathy, glomerulonephritis, anemia, hypoalbuminemia, polyclonal gammopathy, and hypocalcemia may be associated conditions. If the patient is diagnosed early, before significant metabolic and infectious complications occur, the outcome is favorable.

### TREATMENT

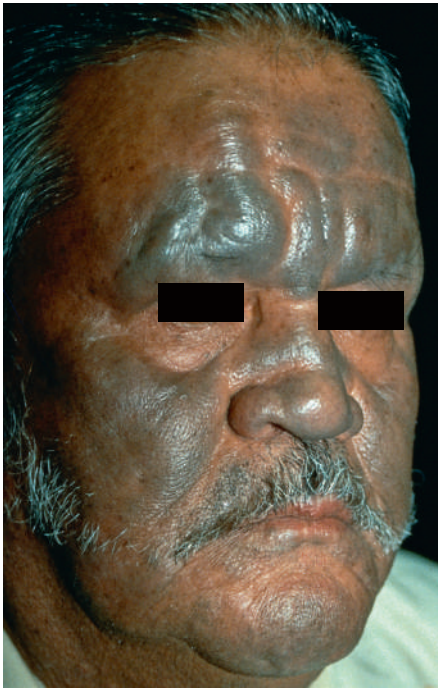Before 1982, dapsone monotherapy was the standard treatment for Hansen's disease; it was effective in many patients, but primary and secondary dapsone-resistant cases occurred. In addition, multibacillary patients required lifelong treatment, which had inherent compliance problems. To circumvent these problems and shorten therapeutic courses, WHO proposed multidrug therapy. MDT has been very effective in treating active cases of Hansen's disease. The number of antibiotics used and the duration of treatment are determined by the bacterial load the patient exhibits. This can be assessed by slit skin smear, where finding any bacilli classifies the patient as multibacillary. On skin biopsy, the same criterion is used: finding any bacilli identifies the patient as multibacillary. The number of lesions constitutes the "field" classification system, and patients are classified as having 1 lesion, 2-5 lesions in one anatomic region (paucibacillary), or more than 5 (multibacillary). This classification can result in undertreatment of patients with few lesions, but who are actually multibacillary. Three other factors can result in undertreatment of patients, as follows:

1. Failure or inability to do a skin biopsy
2. Classifying patients with more than five lesions as "tuberculoid" and thus "paucibacillary"
3. Failure to understand that, although the patient has histologic and clinical features of "tuberculoid" disease, organisms are identified on skin biopsy, and thus the patient requires treatment for multibacillary disease

All patients with more than five lesions and those with organisms identified on skin biopsy should be treated for multibacillary Hansen's disease. Failure may also result from non-compliance, drug resistance, relapse after apparent clinical and bacteriologic cure, and persistence. "Persisters" are viable organisms that, by mouse footpad testing, are sensitive to the antimicrobial agents given but persist in tissue despite bactericidal tissue levels in the patient. They are usually found in macrophages or nerves. These persisters correlate with relapse occurring 6-9 years after MDT. Since relapses may occur many years after MDT, where adequate health care resources exist, multibacillary patients should be followed annually to examine for evidence of relapse, reaction, or progression of neuropathy.

There are several different sets of MDT recommendations, but only two are given here—those recommended by the U.S. Public Health Service for patients in the United States and those recommended by WHO. Because dapsone resistance is less common in U.S. patients, and effective compliance programs can be developed to enhance monotherapy, dapsone monotherapy may still be considered after MDT in the United States. For paucibacillary patients (no organisms found on skin smears or skin biopsy,  $\leq 5$  lesions, indeterminate and tuberculoid leprosy) in U.S. patients, the recommendation is 600 mg/day of rifampin and 100 mg/day of dapsone for 12 months. Paucibacillary patients who relapse with paucibacillary disease are treated with an appropriate regimen for multibacillary disease. In the United States, multibacillary patients receive 100 mg/day of dapsone, 50 mg/day of clofazimine,





**Fig. 17-12**  
Lepromatous leprosy  
with discoloration  
secondary to  
clofazimine.

and 600 mg/day of rifampin, or a standard WHO regimen (see next) for 2 years (Fig. 17-12). For multibacillary patients who refuse clofazimine, 100 mg of minocycline or 400 mg/day of ofloxacin may be substituted. Clarithromycin, 500 mg/day, may also be used in treatment regimens. Patients with multibacillary relapses, whether the initial diagnosis was paucibacillary or multibacillary disease, should have a mouse footpad sensitivity study and should receive an appropriate multidrug regimen for 2 years, followed by daily lifelong dapsone or clofazimine, depending on sensitivity testing.

The WHO-recommended protocols are shorter and less expensive than the U.S. recommendations. There is concern that the reduction of MDT from 2 years to 1 year may lead to increased numbers of relapses, especially among patients with high bacillary loads (BI >4 on skin smear). The WHO recommendation for paucibacillary disease (no bacilli on smears or biopsy, ≤5 lesions, indeterminate and tuberculoid patients) is 600 mg of rifampin under supervision once monthly for 6 months and 100 mg/day of dapsone for 6 months, unsupervised, with completion of the treatment within 9 months. For single-lesion paucibacillary disease, a single dose of 600 mg of rifampin, 400 mg of ofloxacin, and 100 mg of minocycline (ROM), all at one time, is given. This one-dose ROM treatment is less effective than the 6-month regimen for paucibacillary disease. Multibacillary patients (BT, BB, BL, and LL; >5 lesions; any bacilli seen on smears or biopsies) are treated with rifampin, 600 mg, and clofazimine, 300 mg, once monthly under supervision, with dapsone, 100 mg/day, and clofazimine, 50 mg/day. Treatment is for 12 months. For patients intolerant of clofazimine, an alternative regimen is rifampin, 600 mg; ofloxacin, 400 mg; and minocycline, 100 mg, all once monthly for 24 doses. An alternative for the patient intolerant of or resistant to rifampin or dapsone is clofazimine, 50 mg; ofloxacin, 400 mg; and minocycline, 100 mg, daily for 6 months, followed by 18 months of clofazimine, 50 mg daily, plus either ofloxacin, 400 mg/day, or minocycline, 100 mg/day.

Newer regimens have been proposed that could be more effective and of shorter duration or may require only monthly treatment. These can be considered especially in patients with compromised immunity and in those with multibacillary disease with a very high bacterial load. Therapies consist of an

intensive regimen for 6–12 months that can be followed by a continuous phase for another 18 months. Rifapentine, 900 mg, appears superior to rifampin in these combinations. Proposed newer “intensive” drug regimens for rifampin-sensitive multibacillary patients include rifapentine, 900 mg; moxifloxacin, 400 mg; and clarithromycin, 1000 mg (or minocycline, 200 mg), all once monthly for 12 months. For rifampin-resistant patients, moxifloxacin, 400 mg; clofazimine, 50 mg; clarithromycin, 500 mg; and minocycline, 100 mg, are given daily, supervised for 6 months. The continuous phase of treatment could comprise moxifloxacin, 400 mg; clarithromycin, 1000 mg; and minocycline, 200 mg, once monthly, supervised for an additional 18 months.

Drug resistance is widespread and has even recently been reported in the United States. It should be suspected if the patient fails to respond to treatment. There are currently available PCR techniques to detect drug resistance from biopsy specimens.

At the end of treatment, visible skin lesions are often still present, especially with the WHO short-duration treatments. Paucibacillary lesions tend to clear 1–2 years after the 6-month treatment course. In the United States, treatment could be continued until skin lesions are clear, even if the recommended duration of treatment has been passed. With short-duration MDT, it is very difficult to distinguish clinical relapse (failure of treatment) from late type 1 reactions causing skin lesions to reappear. Pathologic examination (biopsy) or an empiric trial of prednisone for several months may be considered in these patients.

Significant disagreement surrounds the effectiveness of the 1-year or 2-year WHO-recommended MDT regimens. Relapse rates for multibacillary patients treated with MDT for 1 or 2 years have been reported to be as high as 7–20% overall, and 13–39% with BI of 4 or greater at diagnosis. Based on this information, patients with BL/LL disease with a BI of 4 or greater are at highest risk for relapse and should be treated beyond the 1-year recommended period, with treatment continued until smear negativity.

Treatment of Hansen's disease patients with effective antibiotic regimens usually does not result in regaining of neurologic deficits. When deficits do recover, it appears to be mostly from elimination of the perineural inflammation, rather than regeneration of the affected nerves. Therefore, early treatment of patients when neurologic deficits are minimal and aggressive treatment of type 1 reactions are the key to limiting neural damage in Hansen's disease.

### Adjunctive treatments

Once neurologic complications have occurred, patients with Hansen's disease should be offered occupational therapy. This should include training on how to avoid injury to insensitive skin of the hands and feet. Special shoes may be required. Ocular complications are common, and an ophthalmologist with specific skill in treating patients with Hansen's disease is an invaluable member of the treatment team.

### MANAGEMENT OF REACTIONS

Even though reactions may appear after drug treatment is instituted, it is not advisable to discontinue or reduce anti-leprosy medication because of these. In mild reactions—those without neurologic complications or severe systemic symptoms or findings—treatment may be supportive. Bed rest and administration of aspirin or nonsteroidal anti-inflammatory drugs may be used.

Type 1 reactions are usually managed with systemic corticosteroids. Prednisone is given orally, starting at a dose of 40–60 mg/day. Neuritis and eye lesions are urgent indications for systemic steroid therapy. Nerve abscesses may also need to be surgically drained immediately to preserve and recover nerve function. The corticosteroid dose and duration are determined by the clinical course of the reaction. Once the reaction is controlled, the prednisone may need to be tapered slowly, over months to years. The minimum dose required and alternate-day treatment should be used in corticosteroid courses more than 1 month in duration. Clofazimine appears to have some activity against type 1 reactions and may be added to the treatment in doses of up to 300 mg/day if tolerated. Cyclosporine can be used if steroids fail or as a steroid-sparing agent. The starting dose would be 5–10 mg/kg. If during treatment the function of some nerves fails to improve while the function of others normalizes, the possibility of mechanical compression should be evaluated by surgical exploration. Transposition of the ulnar nerve does not seem to be more effective than immunosuppressive treatment for ulnar nerve dysfunction.

Thalidomide has been demonstrated to be uniquely effective against ENL and is the treatment of choice. Thalidomide is a potent teratogen and should not be given to women of child-bearing age. The initial recommended dosage is up to 400 mg/day in patients weighing more than 50 kg. This dose is highly sedating in some patients, and patients may complain of central nervous system side effects, even at doses of 100 mg/day. For this reason, such a high dose should be used for only a brief period, or in milder cases, treatment may be started at a much lower dose, such as 100–200 mg/day. In patients with an acute episode of ENL, the drug may be discontinued after a few weeks to months. In chronic type 2 reactions, an attempt to discontinue the drug should be made every 6 months. Systemic corticosteroids are also effective in type 2 reactions, but long-term use may lead to complications. Clofazimine in higher doses, up to 300 mg/day, is effective in ENL and may be used alone or to reduce corticosteroid or thalidomide doses. The combination of pentoxifylline, 400–800 mg twice daily, and clofazimine, 300 mg/day, can be given to patients with ENL when thalidomide cannot be used or to avoid the use of systemic steroids to manage severe ENL. Pentoxifylline alone is inferior to steroids and thalidomide but can be considered in milder cases. Tumor necrosis factor (TNF) inhibitors, specifically infliximab, have been reported to be effective in treating recurrent ENL.

Lucio's phenomenon is poorly responsive to both corticosteroids and thalidomide. Effective antimicrobial chemotherapy for lepromatous leprosy is the only recommended treatment, combined with wound management for leg ulcers.

## PREVENTION

Because a defect in cell-mediated immunity is inherent in the development of Hansen's disease, vaccine therapies are being tested. Bacille Calmette-Guérin (BCG) vaccination alone provides about 34–80% protection against *M. leprae* infection. In the UK, BCG immunization is given to household contacts younger than 12 years. Vaccines have been produced and are effective. It is unclear if vaccine will be needed except in the areas of highest endemicity, because MDT has been effective in reducing the prevalence of Hansen's disease. Since 80% of patients have contact with multibacillary patients, prevention depends on treating active multibacillary patients and examining exposed persons on an annual basis to detect early evidence of infection. Prophylactic antibiotic regimens have been used in such exposed patients and demonstrate a reduction in

new Hansen's disease cases by more than 50% in the first 2 years. Interestingly, patients who had less contact with the source patient benefited more. In the UK, close contacts under age 12 whose source case was lepromatous are given rifampin, 15 mg/kg once monthly for 6 months. Several trials of chemoprophylaxis in whole endemic regions (once-yearly MDT with single-dose rifampin, minocycline, and clofazimine) have shown early promise and may be useful in hyperendemic regions.

**Alcaïs A, et al:** Stepwise replication identifies a low-producing lymphotoxin- $\alpha$  allele as a major risk factor for early-onset leprosy. *Nat Genet* 2007; 39:517.

**Araújo S, et al:** Unveiling healthy carriers and subclinical infections among household contacts of leprosy patients who play potential roles in the disease chain of transmission. *Mem Inst Oswaldo Cruz* 2012; 107:5.

**Ardalan M, et al:** Lepromatous leprosy in a kidney transplant recipient: a case report. *Exp Clin Transpl* 2011; 9:203.

**Balamayooran G, et al:** The armadillo as an animal model and reservoir host for *Mycobacterium leprae*. *Clin Dermatol* 2015; 33:108.

**Batista M, et al:** Leprosy reversal reaction as immune reconstitution inflammatory syndrome in patients with AIDS. *Clin Infect Dis* 2008; 46:56.

**Brito e Cabral P, et al:** Anti-PGL1 salivary IgA/IGM, serum IgG/IgM and nasal *Mycobacterium leprae* DNA in individuals with household contact with leprosy. *Int J Infect Dis* 2013; 17:e1005.

**Bruce S, et al:** Armadillo exposure and Hansen's disease: an epidemiologic survey in southern Texas. *J Am Acad Dermatol* 2000; 43:223.

**Chaitanya VS, et al:** Interleukin-17F single-nucleotide polymorphism (7488T>C) and its association with susceptibility to leprosy. *Int J Immunogenet* 2013; 41:131.

**Chander R, et al:** Molluscum contagiosum-like lesions in histoid leprosy in a 10-year-old Indian boy. *Pediatr Dermatol* 2013; 30:e261.

**Chopra R, et al:** Mapping of PARK2 and PACRG overlapping regulatory region reveals LD structure and functional variants in association with leprosy in unrelated Indian population groups. *PLoS Genet* 2013; 9:e1003578.

**Deps P, et al:** Clinical and histological features of leprosy and human immunodeficiency virus co-infection in Brazil. *Clin Exp Dermatol* 2013; 38:470.

**Dogra S, et al:** Clinical characteristics and outcome in multibacillary (MB) leprosy patients treated with 12 months WHO MDT-MBR: a retrospective analysis of 730 patients from a leprosy clinic at a tertiary care hospital of Northern India. *Lepr Rev* 2013; 84:65.

**Dos Santos DS, et al:** Kinship and leprosy in the contacts of leprosy patients: cohort at the Souza Araújo Outpatient Clinic, Rio de Janeiro, RJ, 1986–2010. *J Trop Med* 2013; 2013:596316.

**Eichelmann K, et al:** Leprosy: an update—definition, pathogenesis, classification, diagnosis, and treatment. *Actas Dermosifiliogr* 2013; 104:554.

**Eiglmeier K, et al:** The decaying genome of *Mycobacterium leprae*. *Lepr Rev* 2001; 72:387.

**Faber WR, et al:** Treatment of recurrent erythema nodosum leprosum with infliximab. *N Engl J Med* 2006; 17:355.

**Fava V, et al:** Genetics of leprosy reactions: an overview. *Mem Inst Oswaldo Cruz* 2012; 107:132.

**Garbino JA, et al:** Primary neural leprosy: systematic review. *Arq Neuropsiquiatr* 2013; 71:397.

**Gelber RH:** Relapse rate in MB leprosy patients treated with 2 years of WHO-MDT is not low. *Int J Lepr Other Mycobact Dis* 2004; 72:493.

**Geluk A:** Biomarkers for leprosy: would you prefer T (cells)? *Lepr Rev* 2013; 84:3.

**Geluk A, et al:** Rational combination of peptides derived from different *Mycobacterium leprae* proteins improves sensitivity for immunodiagnosis of *M. leprae* infection. *Clin Vaccine Immunol* 2008; 15:522.

**Ghorpade A:** Inoculable leprosy. *Int J Dermatol* 2009; 48:1267.

**Global leprosy:** update on the 2012 situation. *Wkly Epidemiol Rec* 2013; 88:365.

**Guditi S, et al:** Leprosy in a renal transplant recipient: review of the literature. *Transpl Infect Dis* 2009; 11:557.

**Han XY, Jessurun J:** Severe leprosy reactions due to *Mycobacterium lepromatosis*. *Am J Med Sci* 2013; 345:65.

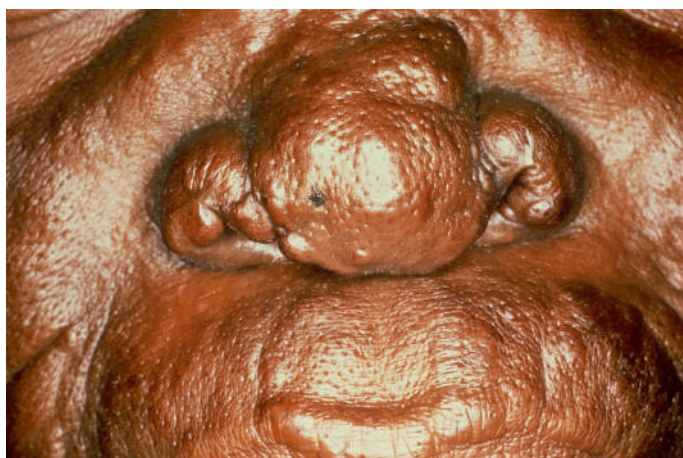

- Han XY, et al:** The leprosy agents *Mycobacterium lepromatosis* and *Mycobacterium leprae* in Mexico. *Int J Dermatol* 2012; 51:952.
- Hossain D:** Using Methotrexate to treat patients with ENL unresponsive to steroids and clofazimine: a report on 9 patients. *Lepr Rev* 2013; 84:105.
- Illarramendi X, et al:** Cutaneous lesions, sensory impairment, recovery, and nerve regeneration in leprosy patients. *Mem Inst Oswaldo Cruz* 2012; 107:68.
- Jaiswal AK, Subbarao NT:** Gynecotheilia—a common yet ignored sign of multibacillary leprosy in males: a case series with review of literature. *Lepr Rev* 2012; 83:384.
- Job CK, et al:** Transmission of leprosy: a study of skin and nasal secretions of household contacts of leprosy patients using PCR. *Am J Trop Med Hyg* 2008; 78:518.
- Jurado F, et al:** Lucio's leprosy: A clinical and therapeutic challenge. *Clin Dermatol* 2015; 33:66.
- Kar HK, Gupta R:** Treatment of leprosy. *Clin Dermatol* 2015; 33:55.
- Klioze AM, Ramos-Caro FA:** Visceral leprosy. *Int J Dermatol* 2000; 39:641.
- Li J, et al:** Association study of the single nucleotide polymorphisms of *PARK2* and *PACRG* with leprosy susceptibility in Chinese population. *Eur J Hum Genet* 2012; 20:488.
- Manickam P, et al:** Efficacy of single-dose chemotherapy (rifampicin, ofloxacin and minocycline—ROM) in PB leprosy patients with 2 to 5 skin lesions, India: randomised double-blind trial. *Indian J Lepr* 2012; 84:195.
- Manzoni C:** LRRK2 and autophagy: a common pathway for disease. *Biochem Soc Trans* 2012; 40:1147.
- Masaki T, et al:** Reprogramming adult Schwann cells to stem cell-like cells by leprosy bacilli promotes dissemination of infection. *Cell* 2013; 152:51.
- Massone C, et al:** Histopathology of the lepromatous skin biopsy. *Clin Dermatol* 2015; 33:38.
- Menicucci LA, et al:** Microscopic leprosy skin lesions in primary neuritic leprosy. *J Am Acad Dermatol* 2005; 52:648.
- Modi K, et al:** Lepromatous leprosy in a heart transplant recipient. *Am J Transplant* 2003; 3:1600.
- Moet FJ, et al:** Effectiveness of single-dose rifampicin in preventing leprosy in close contacts of patients with newly diagnosed leprosy: cluster randomised controlled trial. *Br Med J* 2008; 5:761.
- Moschella S:** An update on the diagnosis and treatment of leprosy. *J Am Acad Dermatol* 2004; 51:417.
- Moura ML, et al:** Active surveillance of Hansen's disease (leprosy): importance for case finding among extra-domiciliary contacts. *PLoS Negl Trop Dis* 2013; 7:32093.
- Nair SP, Nanda Kumar G:** A clinical and histopathological study of histoid leprosy. *Int J Dermatol* 2013; 52:580.
- Nath I, et al:** Immunology of leprosy and diagnostic challenges. *Clin Dermatol* 2015; 33:90.
- Orlova M, et al:** Gene set signature of reversal reaction type I in leprosy patients. *PLoS Genet* 2013; 9:e1003624.
- Polycarpou A, et al:** New findings in the pathogenesis of leprosy and implications for the management of leprosy. *Curr Opin Infect Dis* 2013; 26:413.
- Rao PN, Jain S:** Newer management options in leprosy. *Indian J Dermatol* 2013; 58:6.
- Reja AH, et al:** Fite-Faraco staining in combination with multiplex polymerase chain reaction: a new approach to leprosy diagnosis. *Indian J Dermatol Venereol Leprol* 2013; 79:693.
- Richardus JH, Oskam L:** Protecting people against leprosy: chemoprophylaxis and immunoprophylaxis. *Clin Dermatol* 2015; 33:19.
- Sauer ME, et al:** Genetics of leprosy: expected and unexpected developments and perspectives. *Clin Dermatol* 2015; 33:99.
- Sales AM, et al:** Profession of leprosy disability after discharge: is multidrug therapy enough? *Trop Med Int Health* 2013; 18:1145.
- Santos VS, et al:** Evaluation of agreement between clinical and histopathological data for classifying leprosy. *Int J Infect Dis* 2013; 17:e189.
- Savage JA, Levis WR:** The utility of QuantiFERON-TB Gold assay in patients with leprosy: a possible measure of anergy. *J Am Acad Dermatol* 2014; 71:996.
- Scharschmidt TC, et al:** Immune reconstitution reactions in human immunodeficiency virus–negative patients. *JAMA Dermatol* 2013; 149:74.
- Scollard DM, et al:** Mechanisms of nerve injury in leprosy. *Clin Dermatol* 2015; 33:46.
- Scollard DM, et al:** Risk factors for leprosy reactions in three endemic countries. *Am J Trop Med Hyg* 2014. [Epub ahead of print.]
- Scollard DM, et al:** Hansen's disease (leprosy) complicated by secondary mycobacterial infection. *J Am Acad Dermatol* 2011; 64:593.
- Spierings E, et al:** The role of Schwann cells, T cells and *Mycobacterium leprae* in the immunopathogenesis of nerve damage in leprosy. *Leprosy Rev* 2000; 71:S121.
- Talhari C, et al:** Clinical aspects of leprosy. *Clin Dermatol* 2015; 33:26.
- Trindade MA, et al:** Leprosy in transplant recipients: report of a case after liver transplantation and review of the literature. *Transpl Infect Dis* 2011; 13:63.
- Velayati AA, et al:** Case report: interferon-gamma receptor-1 gene promoter polymorphisms and susceptibility to leprosy in children of a single family. *Am J Trop Med Hyg* 2011; 84:627.
- Vera-Cabrera L, et al:** Case of diffuse lepromatous leprosy associated with "Mycobacterium lepromatosis." *J Clin Microbiol* 2011; 49:4366.
- Walker SL, et al:** International workshop on erythema nodosum leprosum (ENL): consensus report. The formation of ENLIST, the ENL International Study Group. *Lepr Rev* 2012; 83:396.
- Wegner, M:** Mighty bugs: leprosy bacteria turn Schwann cells into stem cells. *Cell* 2013; 152:15.
- Williams DL, et al:** Primary multi-drug resistant leprosy, United States. *Emerg Infect Dis* 2013; 19:179.

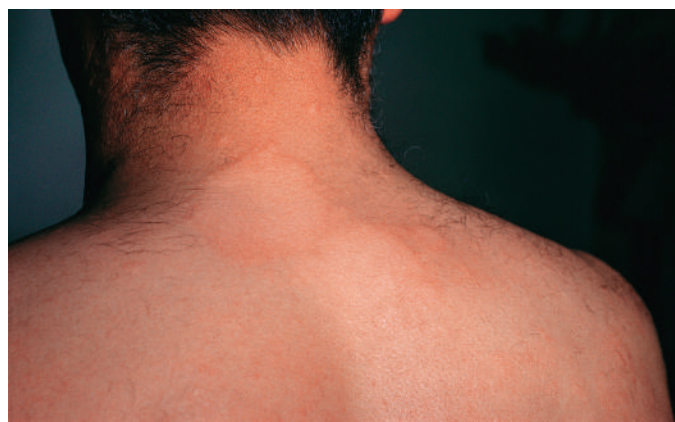

Bonus images for this chapter can be found online at  
[expertconsult.inkling.com](http://expertconsult.inkling.com)

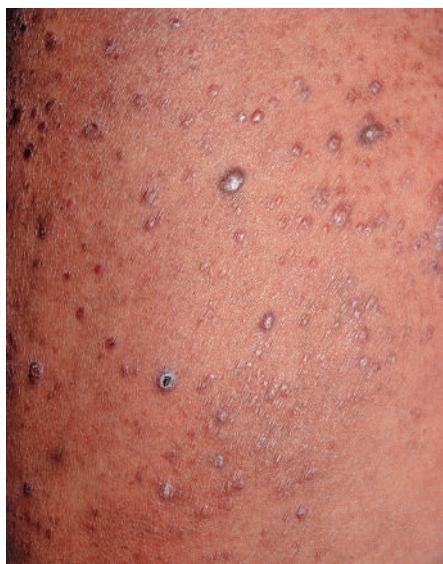- eFig. 17-1** Lepromatous leprosy.
- eFig. 17-2** Lepromatous leprosy, multiple papules and nodules.
- eFig. 17-3** Borderline tuberculoid leprosy.
- eFig. 17-4** Borderline leprosy.
- eFig. 17-5** Type 1 reaction in Hansen's disease.
- eFig. 17-6** Lepromatous leprosy, acral burns caused by peripheral sensory neuropathy.



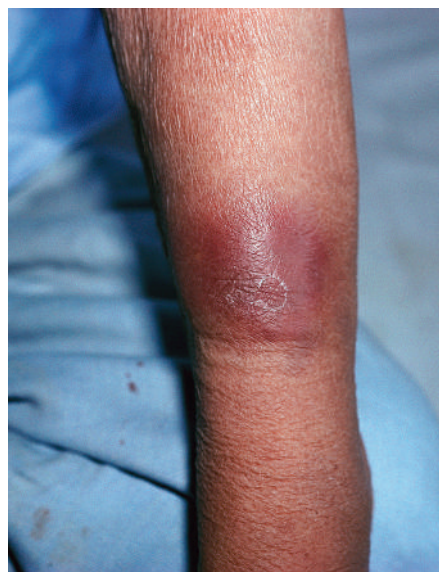**eFig. 17-1** Lepromatous leprosy.



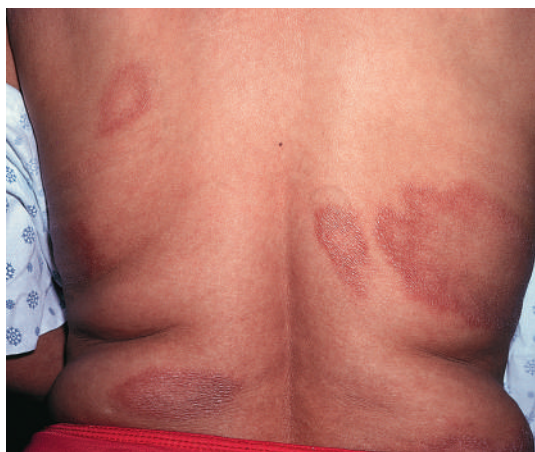**eFig. 17-4** Borderline leprosy.



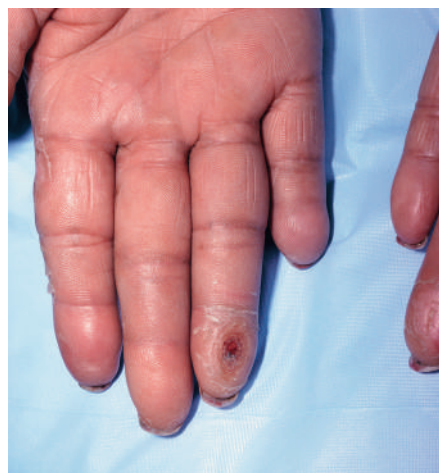**eFig. 17-2** Lepromatous leprosy, multiple papules and nodules.



**eFig. 17-5** Type 1 reaction in Hansen's disease.



**eFig. 17-3** Borderline tuberculoid leprosy.



**eFig. 17-6** Lepromatous leprosy, acral burn caused by peripheral sensory neuropathy.





# Syphilis, Yaws, Bejel, and Pinta

# 18

## SYPHILIS

Syphilis, also known as lues, is a contagious, sexually transmitted disease caused by the spirochete *Treponema pallidum* subspecies *pallidum*. The only known host is the human. The spirochete enters through the skin or mucous membranes, where the primary manifestations are seen. In congenital syphilis, the treponeme crosses the placenta and infects the fetus. The risk of acquiring infection from sexual contact with an infected partner in the previous 30 days is 16–30%. Syphilis results in multiple patterns of skin and visceral disease and can be lifelong.

Syphilis, yaws, pinta, and endemic syphilis are closely related infectious conditions caused by “genetically monomorphic bacteria,” with less than 2% difference in the genomes of the treponemes (treponemas) that cause these infections. Historically, yaws first arose with humans in Africa and spread with human migrations to Europe and Asia. Endemic syphilis evolved from yaws and became endemic in the Middle East and the Balkans at some later date. Yaws moved with human migration to the New World and became endemic in South America. Syphilis, *T. pallidum pallidum*, may have originated in the New World from *T. pallidum pertenue*, the organism causing yaws, much as human immunodeficiency virus (HIV) evolved in Africa from simian immunodeficiency virus (SIV). A tribe in Guyana with a spirochetal infection with features of both yaws and syphilis was identified. Sequencing the genome of this spirochete suggested that it was the ancestor of *T. pallidum pallidum*. This lends support to the theory that syphilis originated more recently in the New World and was brought back to Europe by sailors who went to the New World with Christopher Columbus. Exactly how and when it became primarily a venereally transmitted disease is unclear, but apparently this happened toward the end of the 15th century.

*Treponema pallidum* is a delicate, spiral spirochete that is actively motile. The number of spirals varies from 4 to 14, and the entire length is 5–20  $\mu\text{m}$ . It can be demonstrated in preparations from fresh primary or secondary lesions by darkfield microscopy or by fluorescent antibody techniques. The motility is characteristic, consisting of three movements: a projection in the direction of the long axis, a rotation on its long axis, and a bending or twisting from side to side. The precise uniformity of the spiral coils is not distorted during these movements. Microscopic characteristics of *T. pallidum* cannot be distinguished from commensal oral treponemes, so darkfield examination of oral lesions is unreliable. Direct fluorescent antibody testing can be used for confirmation.

The genome of *T. pallidum* has been sequenced and contains about one quarter of the number of genes of most bacteria. It lacks significant metabolic capacity. It is very sensitive to temperature, with some enzymes working poorly at typical body temperature (perhaps explaining why fever therapy was effective). These two factors may contribute to the inability to

culture the organism in vitro. *T. pallidum* is an effective pathogen because it disseminates widely and rapidly after infection. It is in the bloodstream within hours of intratesticular injection and in numerous organs, including the brain, within 18 hours after inoculation. Once the organisms reach a tissue, they are able to persist for decades. In each tissue, the number of organisms is very low, perhaps below a “critical antigenic mass.” In addition, *T. pallidum* expresses very few antigenic targets on its surface (only about 1% as many as *Escherichia coli*). The outer membrane proteins of *T. pallidum* also undergo rapid mutation, so that during an infection, the host accumulates numerous subpopulations of organisms with different surface antigens. This low infection load, widespread dissemination, poor surface antigen expression, and rapid evolution of antigenically distinct subpopulations may allow the infection to persist despite the development by the host of antigen-specific antibodies and immune cells.

Syphilis remains a major health problem worldwide, despite a highly effective and economical treatment for more than 50 years. The story of the U.S. and world epidemiology of syphilis illustrates a movement of infection from one population to another due to changing social conditions and behaviors. Just as the health systems respond to one epidemic, another appears. Using serologic testing, contact tracing, and penicillin treatment, U.S. health departments reduced the incidence of syphilis dramatically from the turn of the 20th century through the mid-1950s. The incidence then gradually increased through the next two decades and into the 1980s. In the early 1980s, half the cases of syphilis diagnosed were in men who have sex with men (MSM). Changes in sexual behavior patterns among gay men in response to the acquired immunodeficiency syndrome (AIDS) epidemic reduced the number of these cases, but in the late 1980s, syphilis again began to increase dramatically, associated with drug use, especially crack cocaine. The incidence of syphilis increased disproportionately among socioeconomically disadvantaged minority populations, especially in major cities. Throughout the 1990s, the rate of syphilis fell in the United States, so that by 1999, the national rate of 2.6 cases in 100,000 population was the lowest level ever recorded. In addition, half of new cases were concentrated in 28 counties, mainly in the southeastern United States and in select urban areas. With the advent of effective antiretroviral therapy for HIV, there was a change in sexual behavior in MSM, including those with HIV infection. Epidemics of syphilis in this group have now occurred in many major North American, European, and Asian cities. This epidemic is characterized by an older average age, anonymous sex partners (often met on the Internet), use of amphetamines and sildenafil citrate (Viagra), HIV-positive status, and oral sex as the sole sexual exposure. In addition, there was a syphilis epidemic in Russia and the newly independent states starting in the late 1990s, with rates of syphilis 34 times that of Western Europe. Beginning in the mid-1990s, China had a syphilis epidemic affecting primarily unmarried men, female sex workers, and

MSM, so that in 2008, one province in China (Guangdong) had more syphilis cases than the whole European Union.

Worldwide, an estimated 12 million persons are infected annually with syphilis, 2 million of whom are pregnant women. The U.S. Centers for Disease Control (CDC) and the World Health Organization (WHO) have undertaken campaigns to eradicate syphilis. The shifting epidemiology of syphilis over more than five decades suggests it will not be an easy task without an effective vaccine. Until then, reporting of all cases to public health departments for tracing and treatment of contacts should be continued, along with widespread screening of persons at risk, including all pregnant women, female sex workers, MSM, and men with HIV infection.

### Serologic tests

Serologic testing for infection with *T. pallidum*, as in tuberculosis, is undergoing changes that incorporate newer technologies into establishing the diagnosis. Currently, most testing in the United States uses older technologies, while in the United Kingdom (UK), newer technologies have been adopted. Tests are considered either “treponemal” or “nontreponemal.” Treponemal tests detect specific antitreponemal antibodies by enzyme immunoassay (EIA) or *T. pallidum* particle assay (TPPA). These new treponemal tests have specificity and sensitivity exceeding 95%, even in patients with primary syphilis. These generate more positive tests that require further testing than do older strategies. Nontreponemal tests are based on the fact that serum of persons with syphilis aggregates a cardiolipin-cholesterol-lecithin antigen. This aggregation can be viewed directly in tubes or on cards or slides, or it can be examined in an autoanalyzer. Because these tests use lipoidal antigens rather than *T. pallidum* or its components, they are called nontreponemal antigen tests. The most widely used nontreponemal tests are the rapid plasma reagin (RPR) and Venereal Disease Research Laboratories (VDRL) tests. These nontreponemal tests are the standard tests used in the United States and generally become positive within 5–6 weeks of infection, shortly before the chancre heals. Tests are usually strongly positive throughout the secondary phase, except in rare patients with AIDS, whose response is less predictable, and usually become negative during therapy, especially if therapy is begun within the first year of infection. Results may also become negative after a few decades, even without treatment. EIA tests are available that detect both IgG- and IgM-specific antibodies against *T. pallidum*. The IgM becomes detectable 2–3 weeks after infection, about the time the chancre appears. The IgG test becomes positive at 4–5 weeks; thus the IgM test is much more useful in diagnosing primary syphilis. The “treponemal” tests used in the United States are the microhemagglutination assay for *T. pallidum* (MHA-TP) or the fluorescent treponemal antibody absorption (FTA-ABS) test. These specific treponemal tests are also positive earlier than the nontreponemal tests and may be used to confirm the diagnosis of primary syphilis in a patient with a negative RPR/VDRL. The EIA, TPPA, FTA-ABS, and MHA-TP remain positive for life in the majority of patients, although in 13–24% of patients, these tests will become negative with treatment, regardless of stage and HIV status. The IgM EIA test, however, becomes negative following treatment in early syphilis, so that at 1 year, 92% of these patients are negative on the IgM EIA.

All these tests can have false-positive results, so all positive results are confirmed by another test. In most U.S. cities, this involves screening the patient with a nontreponemal test, usually an RPR, and confirming all positives with a specific treponemal test, usually an MHA-TP. If a treponemal test, such as the TPPA or EIA, is used for initial screening, either a

nontreponemal test or the other, specific treponemal test should be used to confirm the first test. A nontreponemal RPR/VDRL is also performed on all positives to determine the titer and monitor treatment success. If the initial screening treponemal-specific test is positive, but the nontreponemal test is negative, a history of prior syphilis and treatment should be sought. If prior syphilis and adequate treatment can be documented, and if examination shows no evidence of either primary or late syphilis, the patient is followed and considered serofast after treatment. If the nontreponemal test is negative, but a second treponemal test is positive, and if no prior history of syphilis and its treatment can be found, the patient is considered to have late latent syphilis (less likely, recent infection) and is treated appropriately. This patient is considered noninfectious. If the two treponemal tests are discordant, one positive and the other negative, a third treponemal-specific test can be ordered, or the case can be referred to a public health department for expert consultation. Because the nontreponemal tests are falsely negative in 25% or more of patients with primary syphilis and in up to 40% with late syphilis, in these patients, a specific treponemal test should also be performed as a screening test.

In resource-poor countries, serologic testing for syphilis is largely unavailable because reagents require refrigeration or the tests require electrical equipment for processing. In Bangladesh and in some countries in sub-Saharan Africa and South America, more than 75% of women receive prenatal care, but only about 40% receive prenatal syphilis screening. Syphilis is endemic in these regions, with infection rates in pregnant women exceeding 1%, and thus millions of pregnant women with syphilis go undiagnosed. More than half a million babies die of congenital syphilis in sub-Saharan Africa every year. New, rapid treponemal-specific tests that can be used in these resource-poor countries have been developed. They cost only \$0.31–0.41 (U.S.) per test and await available funding to be put into use.

Nontreponemal tests are very valuable in following the efficacy of treatment in syphilis. By diluting the serum serially, the strength of the reaction can be stated in dilutions; the number given is the highest dilution giving a positive test result. In primary infection, the titer may be only 1:2; in secondary syphilis, it is regularly high, 1:32–1:256, or higher; in late syphilis, generally much lower, perhaps 1:4 or 1:8. The rise of titer in early infection is of great potential diagnostic value, as is the fall after proper treatment or the rise again if there is reinfection or relapse. Patients with very high antibody titers, as occur in secondary syphilis, may have a false-negative result when undiluted serum is tested. This “prozone” phenomenon will be overcome by diluting the serum.

### Biologic false-positive test results

“Biologic false-positive” (BFP) is used to denote a positive serologic test for syphilis in persons with no history or clinical evidence of syphilis. The term BFP is usually applied to the situation of a positive nontreponemal test and a negative treponemal test. About 90% of BFP test results are of low titer (<1:8). “Acute” BFP reactions are defined as those that revert to negative in less than 6 months; those that persist for more than 6 months are categorized as “chronic.” Acute BFP reactions may result from vaccinations, infections (infectious mononucleosis, hepatitis, measles, typhoid, varicella, influenza, lymphogranuloma venereum, malaria), and pregnancy. Chronic BFP reactions are seen in connective tissue diseases, especially systemic lupus erythematosus (SLE) (44%), chronic liver disease, multiple blood transfusions/intravenous drug use, and advancing age.



False-positive results to specific treponemal tests are less common but have been reported to occur in lupus erythematosus, drug-induced lupus, scleroderma, rheumatoid arthritis, smallpox vaccination, pregnancy, other related treponemal infections (see next), and genital herpes simplex infections. A pattern of beaded fluorescence associated with FTA-ABS testing may be found in the sera of patients without treponemal disease who have SLE. The beading phenomenon, however, is not specific for SLE or even for connective tissue diseases.

## Cutaneous syphilis

### Chancre (primary stage)

The chancre is usually the first cutaneous lesion, appearing 18–21 days after infection. The typical incipient chancre is a small red papule or a crusted superficial erosion. In a few days to weeks, it becomes a round or oval, indurated, slightly elevated papule, with an eroded but not ulcerated surface that exudes a serous fluid (Fig. 18-1). On palpation, it has a cartilage-like consistency. The lesion is usually, but not invariably, painless. This is the uncomplicated or classic hunterian chancre. The regional lymph nodes on one or both sides are usually enlarged, firm, and nontender and do not suppurate. Adenopathy begins 1 or 2 weeks after the chancre appears. The hunterian chancre leaves no scar when it heals.

Chancres generally occur singly, although they may be multiple, especially on the penis in MSM who are infected through oral intercourse (Fig. 18-2). The lesions vary in diameter from a few millimeters to several centimeters. The genital chancre is less often observed in women because of its location within the vagina or on the cervix. Extensive edema of the labia or cervix may occur. In men, the chancre is commonly located in the coronal sulcus or on either side of the frenum. A chancre in the prepuce, being too hard to bend, will flip over all at once when the prepuce is drawn back, a phenomenon called a “dory flop” (resembling a broad-beamed skiff or dory being turned upside down). Untreated, the chancre tends to heal spontaneously in 1–4 months. About the time it disappears, or slightly before, constitutional symptoms and objective signs of generalized (secondary) syphilis occur (Fig. 18-3).

Extragenital chancres may be larger than those on the genitalia. They affect the lips, tongue, tonsil, female breast, index finger, and especially in MSM, the anus. Oral chancres form firm, eroded papules on the lip, tongue, uvula, or tonsillar pillar and are associated with a history of oral sex. Unilateral cervical adenopathy can be present. The presenting complaints

of an anal chancre include an anal sore or fissure and irritation or bleeding on defecation. Anal chancre must be ruled out in any anal fissure not at the 6 or 12 o’clock positions. When there is a secondary eruption, no visible chancre, and the glands below Poupart’s ligament are greatly enlarged, anal chancre should be suspected.

Atypical chancres are common. Simultaneous infection by a spirochete and another microbial agent may produce an atypical chancre. The mixed chancre caused by infection with *Haemophilus ducreyi* and *Treponema pallidum* will produce a lesion that runs a course different from either chancroid or primary syphilis alone. Such a sore begins a few days after exposure, since the incubation period for chancroid is short, and later the sore may transform into an indurated syphilitic lesion. A phagedenic chancre results from the combination of a syphilitic chancre and contaminating bacteria that may cause severe tissue destruction and result in scarring. Edema indurativum, or penile venereal edema, is marked solid edema of the labia or the prepuce and glans penis accompanying a chancre. Chancre redux is relapse of a chancre with insufficient treatment, accompanied by enlarged lymph nodes. Pseudochancres

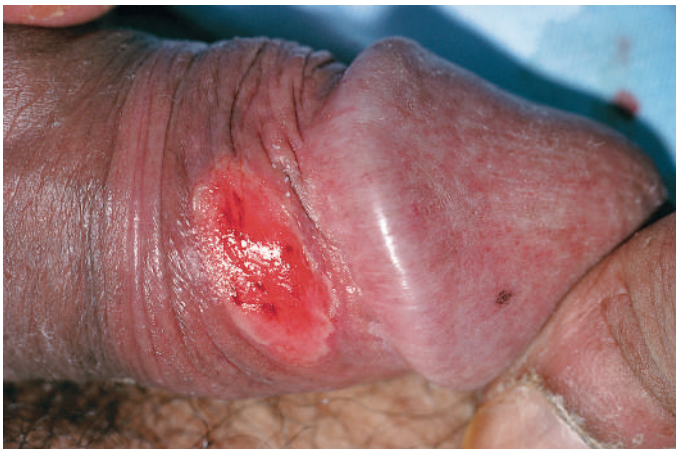

Fig. 18-1 Primary syphilis, chancre.

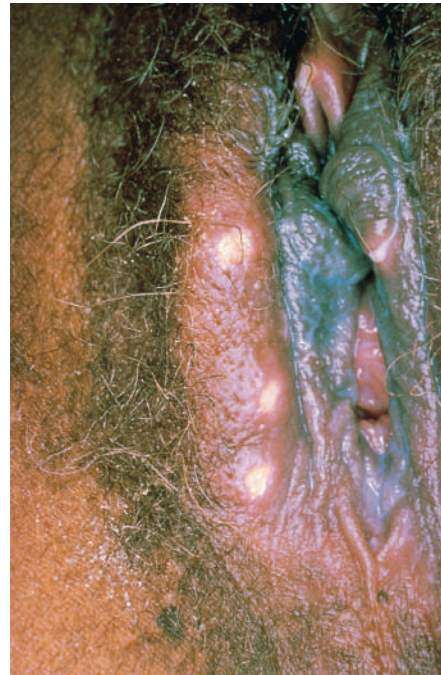

Fig. 18-2 Multiple syphilitic chancres in a woman.

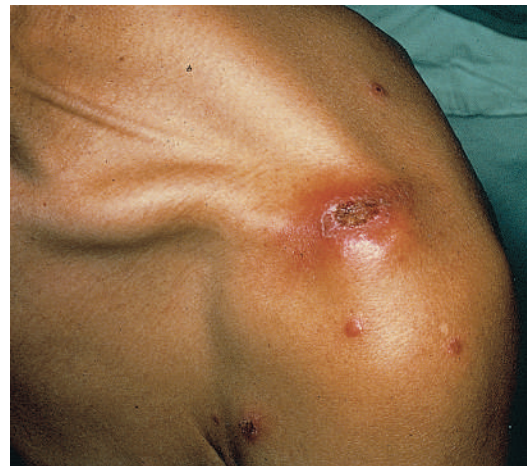

Fig. 18-3 Primary syphilis, chancre on shoulder with secondary lesions present.

redux is a gumma occurring at the site of a previous chancre; it is distinguished from relapsing chancre by the absence of lymphadenopathy and a negative darkfield examination. Syphilitic balanitis of Follmann may occur in the absence of a chancre. The lesions may be exudative, circinate, or erosive.

Histologic evaluation of a syphilitic chancre reveals an ulcer covered by neutrophils and fibrin. Subjacent, there is a dense infiltrate of lymphocytes and plasma cells. Blood vessels are prominent with plump endothelial cells. Spirochetes are numerous in untreated chancres and can be demonstrated with an appropriate silver stain, such as the Warthin-Starry, Levaditi, or Steiner methods, or by immunoperoxidase staining. Spirochetes are best found in the overlying epithelium or adjacent or overlying blood vessels in the upper dermis.

In a patient who presents with an acute genital ulceration, darkfield examination should be performed if available. The finding of typical *T. pallidum* in a sore on the cutaneous surface establishes a diagnosis of syphilis. *Treponema pertenue*, which causes yaws, and *Treponema carateum*, which causes pinta, are both indistinguishable morphologically from *T. pallidum*, but the diseases that they produce are usually easy to recognize. Commensal spirochetes of the oral mucosa are indistinguishable from *T. pallidum*, making oral darkfield examinations unreliable. If the darkfield examination results are negative, the examination should be repeated daily for several days, especially if the patient has been applying a topical antibacterial agent.

The lesion selected for examination is cleansed with water and dried. It is grasped firmly between the thumb and index finger and abraded sufficiently to cause clear or faintly blood-stained plasma to exude when squeezed. In the case of an eroded chancre, a few vigorous rubs with dry gauze are usually sufficient. If the lesion is made to bleed, it is necessary to wait until free bleeding has stopped to obtain satisfactory plasma. The surface of a clean coverslip is touched to the surface of the lesion so that plasma adheres. Then it is dropped on a slide and pressed down so that the plasma spreads out in as thin a film as possible. Immersion oil forms the interface between the condenser and slide and between the coverslip and objective. The specimen must be examined quickly, before the thin film of plasma dries.

An alternative to darkfield microscopy is the direct fluorescent antibody test (DFAT-TP) for the identification of *T. pallidum* in lesions. Serous exudate from a suspected lesion is collected as just described, placed on a slide, and allowed to dry. Many health departments will examine such specimens with fluorescent antibodies specific to *T. pallidum*. The method, unlike the darkfield examination, can be used for diagnosing oral lesions. Multiplex polymerase chain reaction (PCR) is also an accurate and reproducible method for diagnosing genital ulcerations, with the advantage of being able to diagnose multiple infectious agents simultaneously. In genital ulcer disease outbreaks, PCR should be made available.

The results of serologic tests for syphilis are positive in 75% (nontreponemal tests) to 90% (treponemal tests) of patients with primary syphilis; both these tests should be performed in every patient with suspected primary syphilis. The likelihood of positivity depends on the duration of infection. If the chancre has been present for several weeks, test results are usually positive.

A syphilitic chancre must be differentiated from chancroid. The chancre has an incubation period of 3 weeks; is usually a painless erosion, not an ulcer; has no surrounding inflammatory zone; and is round or oval. The edge is not undermined, and the surface is smooth and at the level of the skin. It has a dark, velvety red, lacquered appearance; it has no overlying membrane; and it is cartilage hard on palpation. Lymphadenopathy may be bilateral and is nontender and

nonsuppurative. Chancroid, on the other hand, has a short incubation period of 4–7 days; the ulcer is acutely inflamed, is extremely painful, and has a surrounding inflammatory zone. The ulcer edge is undermined and extends into the dermis. It is covered by a membrane and feels soft. Lymphadenopathy is usually unilateral and tender and may suppurate. Chancroid lesions are usually multiple and extend into each other. Cultures for chancroid on special media confirm the diagnosis. However, since a combination of a syphilitic chancre and chancroid (mixed sores) is indistinguishable from chancroid alone, appropriate direct and serologic testing should be performed to investigate the presence of syphilis. Again, multiplex PCR allows for the simultaneous diagnosis of many infectious agents in genital ulcer diseases.

The primary lesion of granuloma inguinale begins as an indurated nodule that erodes to produce hypertrophic, vegetative granulation tissue. It is soft and beefy-red and bleeds readily. A smear of clean granulation tissue from the lesion stained with Wright or Giemsa reveals Donovan bodies in the cytoplasm of macrophages.

The primary lesion of lymphogranuloma venereum (LGV) is usually a small, painless, transient papule or a superficial nonindurated ulcer. It most often occurs on the coronal sulcus, prepuce, or glans in men or on the fourchette, vagina, or cervix in women. A primary genital lesion is noticed by about 30% of infected heterosexual men, but less frequently in women. Primary lesions are followed in 7–30 days by adenopathy of the regional lymph nodes. LGV is confirmed by serologic tests.

Herpes simplex begins with grouped vesicles, often accompanied or preceded by burning pain. After rupture of the vesicles, irregular, scalloped, tender, soft erosions form.

## Secondary syphilis

### Cutaneous lesions

The skin manifestations of secondary syphilis occur in 80% or more of patients with secondary syphilis. The early eruptions are symmetric, more or less generalized, superficial, nondestructive, exanthematous, transient, and macular; later they are maculopapular or papular eruptions, which are usually polymorphous, and less often, scaly, pustular, or pigmented. The early manifestations tend to be distributed over the face, shoulders, flanks, palms and soles, and anal or genital regions. The severity varies widely. The presence of lesions on the palms and soles is strongly suggestive. However, a generalized syphilitid can spare the palms and soles. The individual lesions are generally less than 1 cm in diameter, except in the later secondary or relapsing secondary eruptions.

### Macular eruptions

The earliest form of macular secondary syphilis begins with the appearance of an exanthematous erythema 6–8 weeks after the development of the chancre, which may still be present. The syphilitic exanthem extends rapidly, so that it is usually pronounced a few days after onset. It may be evanescent, lasting only a few hours or days, or it may last several months, or partially recur after having disappeared. This macular eruption appears first on the sides of the trunk, about the navel, and on the inner surfaces of the extremities.

Individual lesions of macular secondary syphilis consist of round, indistinct macules that are nonconfluent and rarely may be slightly elevated or urticarial. The color varies from a light pink or rose to brownish red. The macular eruption may not be noticed on black skin and may be so faint that it is also not recognized on other skin colors. Pain, burning, and itching are usually absent, although pruritus may be present in 10–40% of patients. Simultaneous with the onset of the eruption, there



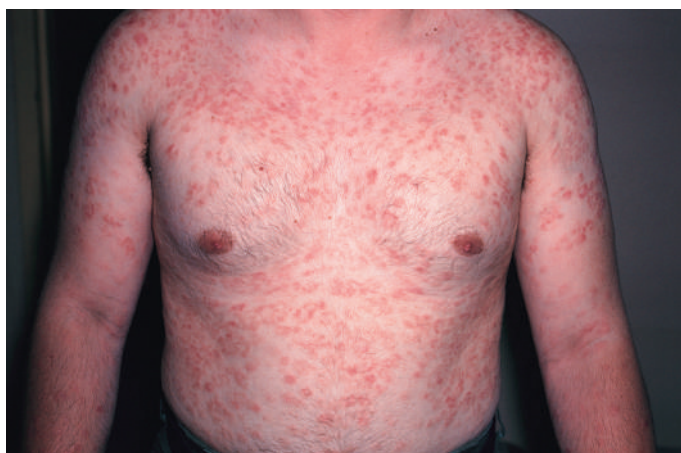

Fig. 18-4 Secondary syphilis, lichenoid lesions.

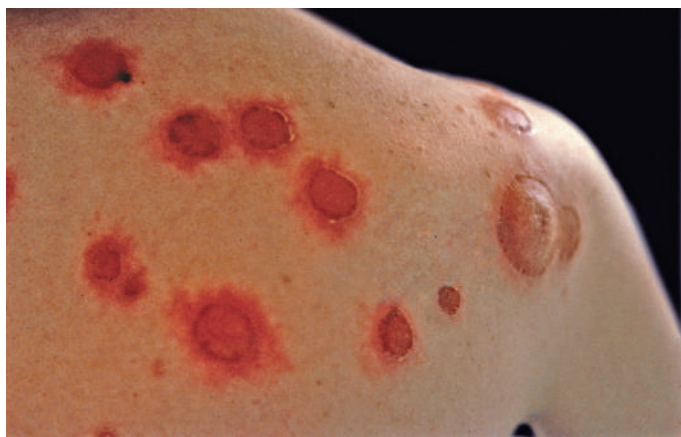

Fig. 18-5 Secondary syphilis.

is a generalized shotty adenopathy, most readily palpable in the posterior cervical, axillary, and epitrochlear areas. Rarely, secondary syphilis may cause livedo reticularis. The macular eruption may disappear spontaneously after a few days or weeks without residua or may result in postinflammatory hyperpigmentation. After a varying interval, macular syphilis may be followed by other eruptions.

### Papular eruptions

Papular eruptions usually arise slightly later than the macular eruption. The fully developed lesions are round and of a raw-ham or coppery shade (Fig. 18-4). Although papules most frequently are 2–5 mm in diameter, nodules coalescing to large plaques can occur (Fig. 18-5). Lesions often are only slightly raised, but a deep, firm infiltration is palpable. The surface is smooth, sometimes shiny, and at other times covered with a thick, adherent scale. When this desquamates, it leaves a characteristic collarette of scales overhanging the border of the papule.

Papules are frequently distributed on the face and flexures of the arms and lower legs and are often distributed all over the trunk. Palmar and plantar involvement characteristically appears as indurated, yellowish red spots (Fig. 18-6). Ollendorff's (Buschke-Ollendorff) sign is present; the papule is exquisitely tender to the touch of a blunt probe. Healing lesions frequently leave hyperpigmented spots that, especially on the palms and soles, may persist for weeks or months. Split papules are hypertrophic, fissured papules that form in the creases of the alae nasi and at the oral commissures. These may persist for a long period. The papulosquamous syphilids, in

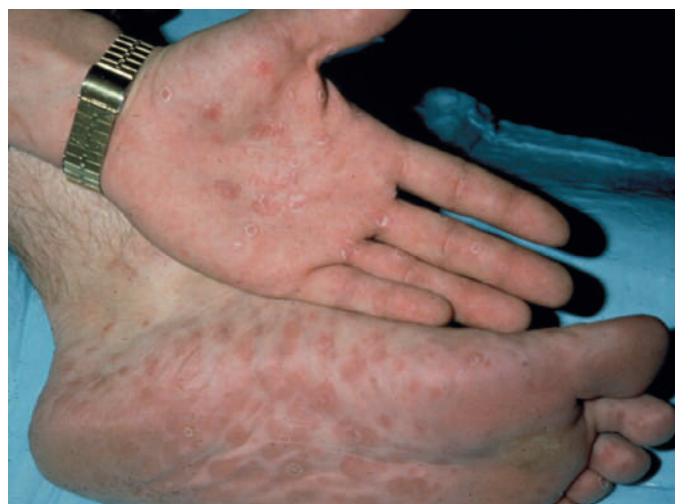

Fig. 18-6 Secondary syphilis; red, flat-topped papules of the palms and soles.

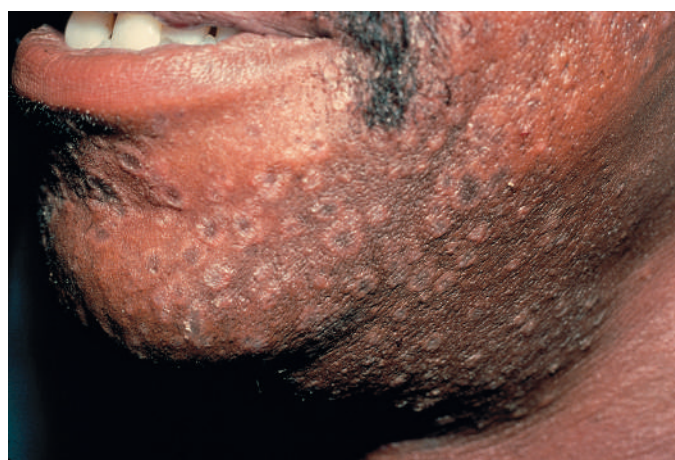

Fig. 18-7 Annular secondary syphilis.

which the adherent scales covering the lesions more or less dominate the picture, may produce a psoriasiform eruption. Follicular or lichenoid syphilids appear as minute, scale-capped papules. If they are at the ostia of hair follicles, syphilids are likely to be conical; elsewhere on the skin, they are domed. Often, syphilids are grouped to form scaling plaques in which the tiny, coalescing papules are still discernible.

As with the other syphilids, papular eruptions tend to be disseminated but may also be localized, asymmetric, configurate, hypertrophic, or confluent. The arrangement may be corymbose or in patches, rings, or serpiginous patterns.

The annular syphilid, as with sarcoidosis, which it may mimic, is more common in blacks (Fig. 18-7). It is often located on the cheeks, especially close to the angle of the mouth, where it may form annular, arcuate, or gyrate patterns of delicate, slightly raised, infiltrated, finely scaling ridges. These ridges are made up of minute, flat-topped papules, and the boundaries between ridges may be difficult to discern. An old term for annular syphilids was "nickels and dimes."

The corymbose syphilid is another infrequent variant, usually occurring late in the secondary stage, in which a large central papule is surrounded by a group of tiny satellite papules. The pustular syphilids are among the rarer manifestations of secondary syphilis. They occur widely scattered over the trunk and extremities, but they usually involve the face, especially the forehead. The pustule usually arises on a red,

infiltrated base. Involution is usually slow, resulting in a small, rather persistent, crust-covered, superficial ulceration. Lesions in which the ulceration is deep are called ecthymatous. Closely related is the rupial syphilitid, a lesion in which a relatively superficial ulceration is covered with a pile of terraced crusts resembling an oyster shell. Lues maligna is a rare form of secondary syphilis with severe ulcerations, pustules, or rupioid lesions, accompanied by severe constitutional symptoms. This form of secondary syphilis appears to be more common in HIV-infected men.

Involvement of the palms and soles is a characteristic feature of secondary syphilis. In some cases, instead of discrete lesions, the whole area of the palms and soles can be symmetrically involved, resembling keratoderma blennorrhagicum, hyperkeratotic hand eczema, or even an acquired keratoderma, such as Howel-Evans syndrome. Similarly, cutaneous lesions can be very psoriasiform, and if they develop in a person with known psoriasis, lesions can be mistaken for a flare of that disease. Anetoderma may occur after treatment of secondary syphilis.

Condylomata lata are papular lesions, relatively broad and flat, located on folds of moist skin, especially around the genitalia and anus, but also at the angles of the mouth, nasolabial fold, and toe webs. They may become hypertrophic and, instead of infiltrating deeply, protrude above the surface, forming a soft, red, often mushroomlike mass 1–3 cm in diameter, usually with a smooth, moist, weeping, gray surface (Fig. 18-8). Condyloma lata may be lobulated but are not covered by the digitate elevations characteristic of venereal warts (condylomata acuminata). Secondary syphilis may initially present with perianal erosions and plaques that may mimic cutaneous Crohn's disease.

Syphilitic alopecia is irregularly distributed so that the scalp has a moth-eaten appearance. It is unusual, occurring in about 5% of patients with secondary syphilis. Smooth, circular areas of alopecia mimicking alopecia areata may occur in syphilis, and an ophiasis pattern may rarely be seen.

Mucous membrane lesions are present in one third of patients with secondary syphilis and may be the only manifestation of the infection. The most common mucosal lesion in the early phase is the syphilitic sore throat, a diffuse pharyngitis that may be associated with tonsillitis or laryngitis. Hoarseness and sometimes complete aphonia may be present. On the tongue, smooth, small or large, well-defined patches devoid of papillae may be seen, most frequently on the dorsum near the median raphe (Fig. 18-9). Ulcerations may occur on the tongue and lips during the late secondary period, at times resembling aphthae or major aphthae. A rare variant of syphilis is one presenting with oral and cutaneous erosions that

histologically show the features of pemphigus vulgaris, with a suprabasilar acantholytic blister as well as positive direct and indirect immunofluorescence findings of pemphigus.

Mucous patches are the most characteristic mucous membrane lesions of secondary syphilis. They are macerated, flat, grayish, rounded erosions covered by a delicate, soggy membrane. These highly infectious lesions are about 5 mm in diameter and teem with treponemas. They occur on the tonsils, tongue, pharynx, gums, lips, and buccal areas or on the genitalia, chiefly in women, in whom the lesions are most common on the labia minora, vaginal mucosa, and cervix. Such mucous erosions are transitory and change from week to week, or even from day to day. Lesions of the oral mucosa frequently contain plasma cells, so the oral pathologist may not consider syphilis. Because the oral lesions of secondary syphilis are usually teeming with spirochetes, a *T. pallidum*-specific immunoperoxidase stain is useful in confirming the diagnosis.

### Relapsing secondary syphilis

The early lesions of syphilis undergo involution either spontaneously or with treatment. Relapses occur in about 25% of untreated patients, 90% within the first year. Such relapses may take place at the site of previous lesions, on the skin or in the viscera. Recurrent eruptions tend to be more configurate or annular, larger, and asymmetric.

### Systemic involvement

The lymphatic system in secondary syphilis is characteristically involved. The lymph nodes most frequently affected are the inguinal, posterior cervical, postauricular, and epitrochlear. The nodes are shotty, firm, slightly enlarged, nontender, and discrete.

Acute glomerulonephritis, gastritis or gastric ulceration, proctitis, hepatitis, acute meningitis, unilateral sensorineural hearing loss, iritis, anterior uveitis, optic neuritis, Bell palsy, multiple pulmonary nodular infiltrates, periostitis, osteomyelitis, polyarthritis, and tenosynovitis may all be seen in secondary syphilis.

### Histopathology

Macules of secondary syphilis feature superficial and deep perivascular infiltrates of lymphocytes, macrophages, and plasma cells without epidermal change, or accompanied by slight vacuolar change at the dermoepidermal junction.

Papules and plaques of secondary syphilis usually show dense, superficial and deep infiltrates of lymphocytes, macrophages, and plasma cells. These cells are usually distributed in a bandlike pattern in the papillary dermis and cuffed around

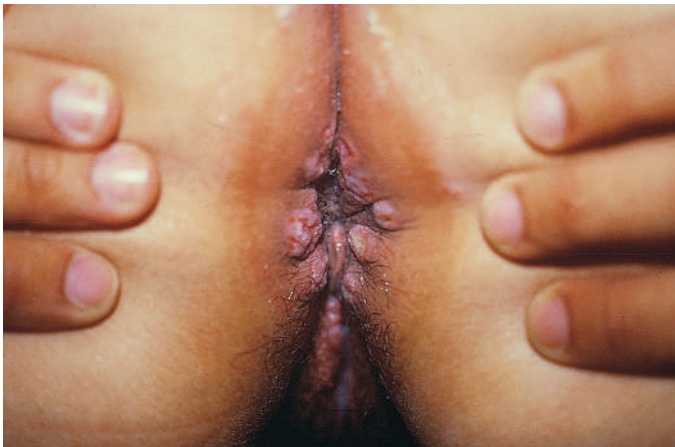

Fig. 18-8 Condylomata lata.

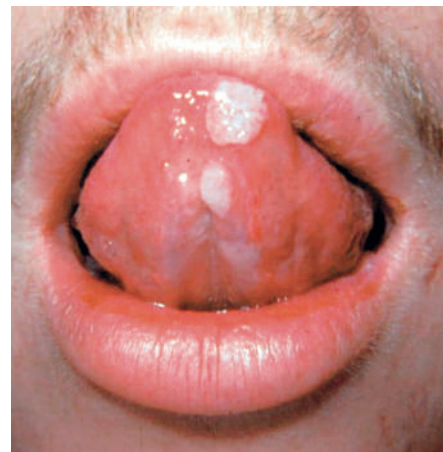

Fig. 18-9 Mucous patches of secondary syphilis.



blood vessels, accompanied by psoriasiform epidermal hyperplasia and hyperkeratosis. Clusters of neutrophils are usually present within the stratum corneum. The presence of numerous macrophages often gives the infiltrates a pallid appearance under scanning magnification. Vacuolar degeneration of keratinocytes is often present, giving the lesions a “psoriasiform and lichenoid” histologic pattern with slender, elongated rete ridges. Plasma cells are reportedly absent in 10–30% of cases. As lesions age, macrophages become more numerous, so that in late secondary lesions, granulomatous foci are often present, mimicking sarcoidosis, or less often, a granuloma annulare-like pattern. Condylomata lata show spongiform pustules within areas of papillated epithelial hyperplasia, and spirochetes are numerous.

In early-syphilis skin lesions, spirochetes are most numerous within the epidermis and around superficial vessels. Silver stains are technically difficult, but since the number of organisms is high in early syphilis, the tests are usually positive. PCR and immunoperoxidase assay may identify *T. pallidum* infection when silver stains are negative. However, immunoperoxidase stains may be negative and silver stains positive; therefore, if suspicion of early syphilis is high, both silver stains and immunoperoxidase assays may need to be performed.

### Diagnosis and differential diagnosis

Syphilis has long been known as the “great imitator,” because the various cutaneous manifestations may simulate almost any cutaneous or systemic disease. Pityriasis rosea may be mistaken for secondary syphilis, especially because both begin on the trunk. The herald patch, the oval patches with a fine scale at the edge, patterned in the lines of skin cleavage, the absence of lymphadenopathy, and infrequent mucous membrane lesions help to distinguish pityriasis rosea from secondary syphilis. Drug eruptions may produce a similar picture to secondary syphilis but tend to be morbilliform and also pruritic, whereas secondary syphilis is not. Drug eruptions in pityriasis rosea are often pruritic, whereas those in secondary syphilis usually are not.

Lichen planus may resemble papular syphilid. The characteristic papule of lichen planus is flat topped and polygonal, has Wickham’s striae, and exhibits Koebner phenomenon. Pruritus is severe in lichen planus but is less common and less severe in syphilis. Psoriasis may be distinguished from papulosquamous secondary syphilis by the presence of adenopathy, mucous patches, and alopecia in the latter. Sarcoidosis may produce lesions morphologically identical to secondary syphilis. Histologically, multisystem involvement, adenopathy, and granulomatous inflammation are common to both diseases. Serologic testing and biopsy specimens will distinguish sarcoidosis from syphilis.

The differential diagnosis of mucous membrane lesions of secondary syphilis is of importance. Infectious mononucleosis may cause a biologic false-positive test for syphilis but is diagnosed by serology. Geographic tongue may be confused with the desquamative patches of syphilis or with mucous patches. Lingua geographica occurs principally near the edges of the tongue in relatively large areas, which are often fused and have lobulated contours. It continues for several months or years and changes in extent and degree of involvement from day to day. Recurrent aphthous ulceration produces one or several painful ulcers, 1–3 mm in diameter, surrounded by hyperemic edges, with a grayish covering membrane, on nonkeratinized mucosal epithelium, especially in the gingival sulcus. A prolonged, recurrent history is characteristic. Syphilis of the lateral tongue may resemble oral hairy leukoplakia.

### Latent syphilis

After the lesions of secondary syphilis have involuted, a latent period occurs. This may last for a few months or continue for the remainder of the infected person’s life. Between 60% and 70% of untreated infected patients remain latently asymptomatic for life. During this latent period, there are no clinical signs of syphilis, but the serologic tests for syphilis are reactive. During the early latent period, infectivity persists; for at least 2 years, a woman with early latent syphilis may infect her unborn child. For treatment purposes, it is important to distinguish early latency (<1-year duration) from late latency (>1 year or unknown duration).

### Late syphilis

For treatment purposes, late syphilis is defined by the CDC as infection of more than 1 year in duration and by the WHO as more than 2 years in duration. Only about one third of patients with late syphilis will develop complications of their infection.

### Tertiary cutaneous syphilis

Tertiary syphilids most often occur 3–5 years after infection. About 16% of untreated patients will develop tertiary lesions of the skin, mucous membrane, bone, or joints. Skin lesions tend to be localized, to occur in groups, to be destructive, and to heal with scarring. Treponemas are usually not found by silver stains or darkfield examination but may be demonstrated by immunoperoxidase techniques.

Two main types of cutaneous tertiary syphilis are recognized, the nodular syphilid and the gumma, although the distinction is sometimes difficult to make. The nodular, noduloulcerative, or tubercular type consists of firm, reddish brown or copper-colored papules or nodules, 2 mm in diameter or larger. The individual lesions are usually covered with adherent scales or crusts (Fig. 18-10). The lesions tend to form rings and to undergo involution as new lesions develop just beyond them, producing characteristic circular or serpiginous patterns. A distinctive type is the kidney-shaped lesion, which

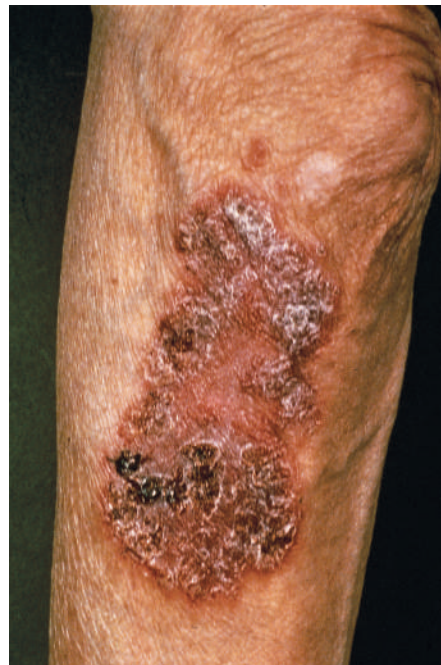
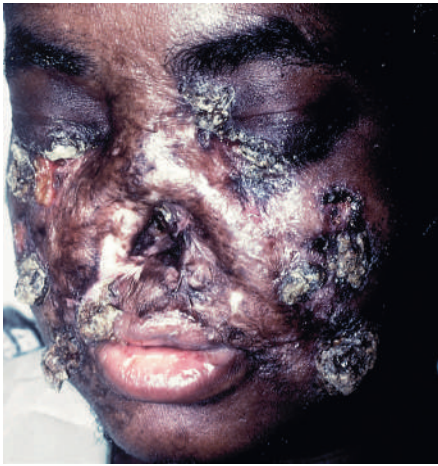
Fig. 18-10 Tertiary syphilis.



**Fig. 18-11** Destruction of the central face in tertiary syphilis.

typically occurs on the extensor surfaces of the arms and on the back. Individual lesions are composed of nodules in different stages of development, so that scars and pigmentation often are found together with fresh as well as ulcerated lesions. On the face, the nodular eruption closely resembles lupus vulgaris. When the disease is untreated, the process may last for years, slowly marching across large areas of skin. The nodules may enlarge and eventually break down to form painless, rounded, smooth-bottomed ulcers a few millimeters deep. These punched-out ulcers arise side by side and form serpiginous syphilitic ulcers, palm sized in aggregate, enduring for many years (Fig. 18-11).

Gummas may occur as unilateral, isolated, single or disseminated lesions, or in serpiginous patterns resembling those of the nodular syphilid. They may be restricted to the skin or, originating in the deeper tissues, break down and secondarily involve the skin. The individual lesions, which begin as small nodules, slowly enlarge to several centimeters. Central necrosis is extensive and may lead to the formation of a deep, punched-out ulcer with steep sides and a gelatinous, necrotic base. Again, progression may take place in one area while healing proceeds in another. Perhaps the most frequent site of isolated gummas is the lower legs, where deep punched-out ulcers are formed, often in large, infiltrated areas. On the lower extremities, gummas are frequently mistaken for erythema induratum.

Lesions may be isolated to the mucous membranes, often the tongue, on which nonindurated punched-out ulcers occur. A superficial glossitis may cause irregular ulcers, atrophy of the papillae, and smooth, shiny scarring, a condition known as smooth atrophy. In interstitial glossitis, there is an underlying induration. In the advanced stages, tertiary syphilis of the tongue may lead to a diffuse enlargement (macroglossia). Perforation of the hard palate from gummatous involvement is a characteristic tertiary manifestation. It generally occurs near the center of the hard palate. Destruction of the nasal septum may also occur.

Histologically, nodular lesions of late syphilis usually have changes that resemble those of secondary lesions, with the addition of tuberculoid granulomas containing varying numbers of multinucleate giant cells. The epidermis is often atrophic rather than hyperplastic. In gummas, necrosis within granulomas and fibrosis occur as lesions resolve. Spirochetes are scant.

For diagnosis of late syphilis, clinicians rely heavily on specific treponemal tests. The nontreponemal tests, such as the VDRL and RPR, are positive in approximately 60% of patients. When there are mucous membrane lesions, for which a diagnosis of carcinoma must also be considered, histologic exami-

nation is performed. Darkfield examination is not indicated, since it is always negative. When not ulcerated, lesions of tertiary syphilis must be distinguished from malignant tumors, leukemias, and sarcoidosis. The ulcerated tertiary syphilids must be differentiated from other infections, such as scrofuloderma, atypical mycobacterial infection, and deep fungal infection. Wegener's granulomatosis and ulcerated cutaneous malignancies must be considered. Histology and appropriate cultures may be required.

### Late osseous syphilis

Occasionally, gummatous lesions involve the periosteum and the bone. Skeletal tertiary syphilis most often affects the head and face and the tibia. Late manifestations of syphilis may produce periostitis, osteomyelitis, osteitis, and gummatous osteoarthritis. Osteocope (bone pain), most often at night, is a suggestive symptom.

Syphilitic joint lesions also occur, with the Charcot joint being the most prevalent manifestation. These are often associated with tabes dorsalis and occur most frequently in men. Although any joint may be involved, the knees and ankles are most often affected. There is hydrops, then loss of the contours of the joint, hypermobility, and no pain. Joint lesion is readily diagnosed by x-ray examination.

### Neurosyphilis

Central nervous system (CNS) infection can occur at any stage of syphilis, even the primary stage. Up to 100% of patients with syphilis may develop CNS infection, but in 80% it is spontaneously cleared by the immune system. This explains why most persons with CNS involvement have no symptoms. About one third of patients who do not spontaneously clear their CNS infection will develop symptomatic neurosyphilis. Finding cerebrospinal fluid (CSF) pleocytosis or a positive CSF-VDRL test has been used to confirm the diagnosis of CNS infection by *T. pallidum*. Unfortunately, a significant proportion of patients with CSF infection with *T. pallidum* will have a negative CSF-VDRL (46%) and nondiagnostic CSF pleocytosis (<20 white blood cells/ $\mu$ L) (33%). In patients with a negative CSF-VDRL but pleocytosis, FTA test can be performed on CSF, thought by many to be 100% sensitive but not specific for CNS syphilis. Combining this with flow cytometry to look for B cells in the CSF, which is 100% specific but only 40% sensitive, will allow the confirmation or exclusion of neurosyphilis in most patients with CSF pleocytosis. The likelihood of having CNS infection is 10-fold greater in persons with RPR of 1:32 or greater. HIV-negative persons with negative CSF examinations have almost no risk of developing neurosyphilis. However, CSF evaluations are not routinely performed in asymptomatic persons with early syphilis, so identifying those at risk for symptomatic neurosyphilis is problematic. *T. pallidum* CNS infection may also be strain dependent, and eventually, typing the infecting strain may predict those at highest risk for neurosyphilis.

Because CNS infection is common and the recommended treatments with benzathine penicillin do not reach treponemidal levels in the CSF, persistent concern surrounds the failure to diagnose and treat asymptomatic neurosyphilis. Apparently, although treatment does not clear the spirochetes from the CSF, most non-HIV-infected persons are able to clear the CNS infection spontaneously. CSF evaluation is recommended in all patients with syphilis with any neurologic, auditory, or ophthalmic signs or symptoms, possibly resulting from syphilis, independent of stage or HIV status. In borderline cases, those with RPR of 1:32 or greater should have CSF evaluation. The indications for lumbar puncture in patients



with coexistent HIV infection and early syphilis (<1 or 2 years' duration) remains unclear. The two factors predicting the likelihood of CNS infection are RPR of 1:32 or more and CD4 count of 350 cells/ $\mu$ L or less. Patients with latent syphilis or syphilis of unknown duration should have CSF evaluation if they are HIV positive or fail initial therapy, or if therapy other than penicillin is planned for syphilis of more than 1 year in duration. Patients with tertiary syphilis should have CSF evaluation before treatment to exclude neurosyphilis. An appropriate fall in the serum RPR after treatment for neurosyphilis predicts clearing of the CNS infection, so a repeat lumbar puncture after therapy is not required in HIV-negative or HIV-positive patients adequately treated for neurosyphilis.

### **Early neurosyphilis**

Early neurosyphilis is mainly meningeal, occurs in the 2 years of infection, and affects 1.4%-6% of untreated persons with syphilis. Meningeal neurosyphilis manifests as meningitis, with fever, headache, stiff neck, nausea, vomiting, cranial nerve disorders (loss of hearing, often unilateral, and facial weakness), photophobia, blurred vision, seizures, and delirium.

### **Meningovascular neurosyphilis**

Meningovascular neurosyphilis most frequently occurs 5-12 years after infection, affecting about 3% of untreated syphilis patients. It is caused by thrombosis of vessels in the CNS and presents, as in other CNS ischemic events, with acute onset of symptoms. Hemiplegia, aphasia, hemianopsia, transverse myelitis, and progressive muscular atrophy may occur. Cranial nerve palsies may also occur, such as eighth nerve deafness and eye changes. The eyes may show fixed pupils, Argyll Robertson pupils, or anisocoria.

### **Late (parenchymatous) neurosyphilis**

Parenchymatous neurosyphilis tends to occur more than 10 years after infection. There are two classic clinical patterns: tabes dorsalis and general paresis.

Tabes dorsalis is the degeneration of the dorsal roots of the spinal nerves and of the posterior columns of the spinal cord. The symptoms and signs are numerous. Gastric crisis with severe pain and vomiting is the most frequent symptom. Other symptoms are lancinating pains, urination difficulties, paresthesias (numbness, tingling, burning), spinal ataxia, diplopia, strabismus, vertigo, and deafness. The signs that may be present are Argyll Robertson pupils, absent or reduced reflexes, Romberg sign, deep tendon tenderness, loss of proprioception and vibratory sensation, atonic bladder, trophic changes, *malum perforans pedis*, Charcot joints, and optic atrophy.

Paresis has prodromal manifestations of headache, fatigability, and inability to concentrate. Later, personality changes occur, along with memory loss and apathy. Grandiose ideas, megalomania, delusions, hallucinations, and finally dementia may occur.

### **Late cardiovascular syphilis**

Late cardiovascular syphilis occurs in about 10% of untreated patients. Aortitis is the basic lesion of cardiovascular syphilis, resulting in aortic insufficiency, coronary artery disease, and ultimately aortic aneurysm.

## **Congenital syphilis**

Congenital syphilis has reappeared with heterosexual syphilis epidemics. There were 195 cases of congenital syphilis reported in New York City from 2000 to 2009. Cases are also reported from Asia and Europe. In sub-Saharan Africa, where prenatal

syphilis testing is not available, even for women with prenatal care, congenital syphilis is common. A total of 21% of all perinatal deaths in sub-Saharan Africa are caused by congenital syphilis. Prenatal syphilis is acquired in utero from the mother, who usually has early syphilis. Infection through the placenta usually does not occur before the fourth month, so treatment of the mother within the first two trimesters will almost always prevent negative outcomes. For this reason, prenatal care with syphilis serologies done in the early second trimester and at delivery (and any time in between if there is clinical suspicion of syphilis or high risk of acquisition of syphilis) is recommended. Common causes for failure to prevent congenital syphilis in mothers who received prenatal care are (1) lack of documented treatment of syphilis diagnosed before pregnancy, (2) absence of serologic testing during pregnancy, (3) late or no maternal treatment, and (4) treatment with a non-penicillin regimen. If any of these is noted in the maternal history, congenital syphilis should still be suspected.

Recent reports from China suggest that preschool children may acquire syphilis by nonsexual close contact. In all cases, a caregiver had infectious syphilis, but sexual abuse was apparently excluded. This report suggests that the diagnosis of syphilis should be considered whenever the clinical manifestations suggest this possibility.

If the mother has early syphilis and prenatal infection occurs soon after the fourth month, fetal death and miscarriage occur in about 40% of pregnancies. During the remainder of the pregnancy, infection is equally likely to produce characteristic physical developmental stigmata or, after the eighth month, active, infectious congenital syphilis. About 40% of pregnant women with untreated early syphilis will have a syphilitic infant. Infant mortality from congenital syphilis can exceed 10%. In utero infection of the fetus is rare when the pregnant mother has had syphilis for 2 or more years. Two thirds of neonates with congenital syphilis are normal at birth and only detected by serologic testing. Lesions occurring within the first 2 years of life are called early congenital syphilis, and those developing thereafter, late congenital syphilis. The clinical manifestations of these two syndromes are different.

### **Early congenital syphilis**

Early congenital syphilis describes those cases presenting within the first 2 years of life. Cutaneous manifestations usually appear during the third week of life, but sometimes occur as late as 3 months after birth. Neonates born with findings of congenital syphilis are usually severely affected. They may be premature and are often marasmic, fretful, and dehydrated. The face is pinched and drawn, resembling that of an old man or woman. Multisystem disease is characteristic.

Snuffles, a form of rhinitis, is the most frequent and often the first specific finding. The nose is blocked, often with blood-stained mucus, and a copious discharge of mucus runs down over the lips. The nasal obstruction often interferes with the child's nursing. In persistent and progressive snuffles, ulcerations develop that may involve the bones and ultimately cause perforation of the nasal septum or development of saddle nose, which are important stigmata later in the disease.

Cutaneous lesions of congenital syphilis resemble those of acquired secondary syphilis and occur in 30-60% of infants with syphilis. The early skin eruptions are usually morbilliform and more rarely, purely papular. The lesions are at first a bright or violaceous red, later fading to a coppery color. The papules may become large and infiltrated; scaling often is pronounced. There is secondary pustule formation with crusting, especially in lesions that appear 1 year or more after birth. The eruption shows a marked predilection for the face, arms, buttocks, legs, palms, and soles.

Syphilitic pemphigus, a bullous eruption, usually on the palms and soles, is a relatively uncommon lesion. Lesions are present at birth or appear in the first week of life. They are teeming with spirochetes. The bullae quickly become purulent and rupture, leaving weeping erosions. They are found also on the eponychium, wrists, ankles, and infrequently on other parts of the body. Even in the absence of bullous lesions, desquamation is common, often preceded by edema and erythema, especially on the palms and soles.

Various morphologies of cutaneous lesions occur on the face, perineum, and intertriginous areas. These are usually fissured lesions resembling mucous patches. In these sites, radial scarring often results, leading to rhagades. Condylomata lata, large, moist, hypertrophic papules, are found around the anus and in other folds of the body. They are more common about the first year of life than in the newborn period. In the second or third year, recurrent secondary eruptions are likely to take the papulopustular form. Annular lesions occur, similar to those in adults. Mucous patches in the mouth or on the vulva are seen infrequently.

Bone lesions occur in 70–80% of infants with early congenital syphilis. Epiphysitis is common and apparently causes pain on motion, leading to the infant refusing to move (Parrot pseudoparalysis). Radiologic features of the bone lesions in congenital syphilis during the first 6 months after birth are quite characteristic, and x-ray films are an important part of the evaluation of a child suspected of having congenital syphilis. Bone lesions occur chiefly at the epiphyseal ends of the long bones. The changes may be classified as osteochondritis, osteomyelitis, and osteoperiostitis.

A general enlargement of the lymph nodes usually occurs, with enlargement of the spleen. Clinical evidence of liver involvement is common, manifested by both hepatomegaly and elevated liver function test results, and interstitial hepatitis is a frequent finding at autopsy. The nephrotic syndrome and less often acute glomerulonephritis have been reported in congenital syphilis.

Symptomatic or asymptomatic neurosyphilis, as demonstrated by a positive CSF serologic test, may be present. Of infants with congenital syphilis diagnosed by clinical and laboratory findings born to mothers with untreated early syphilis, 86% will have CNS involvement, compared with only 8% of those with no clinical or laboratory findings. All infants with early congenital syphilis are treated as if they have neurosyphilis because it is very common, and CSF-VDRL test may be negative, even in documented CNS infection. Clinical manifestations may not appear until the third to sixth month of life and are meningeal or meningovascular in origin. Meningitis, obstructive hydrocephalus, cranial nerve palsies, and cerebrovascular accident (stroke) may all occur.

## Late congenital syphilis

Although no sharp line can be drawn between early and late congenital syphilis, children who appear normal at birth and develop the first signs of the disease after age 2 years show a different clinical picture. Lesions of late congenital syphilis are of two types: persistent inflammatory foci and malformations of tissue affected at critical growth periods (stigmata).

### Inflammatory lesions

Lesions of the cornea, bones, and CNS are the most important. Interstitial keratitis, which begins with intense pericorneal inflammation and persists to characteristic diffuse clouding of the cornea without surface ulceration, occurs in 20–50% of children with late congenital syphilis. If persistent, it leads to permanent, partial or complete opacity of the cornea. Syphilitic interstitial keratitis must be differentiated from Cogan

syndrome, consisting of nonsyphilitic interstitial keratitis, usually bilateral, associated with vestibuloauditory symptoms, such as deafness, tinnitus, vertigo, nystagmus, and ataxia. It is congenital.

Perisynovitis (Clutton joints), which affects the knees, leads to symmetric, painless swelling. Gummas may also be found in any of the long bones or in the skull. Ulcerating gummas are frequently seen and probably begin more often in the soft parts or in the underlying bone than in the skin itself. When they occur in the nasal septum or palate, ulcerating gummas may lead to painless perforation.

The CNS lesions in late congenital syphilis are, as in late adult neurosyphilis, usually parenchymatous (tabes dorsalis or generalized paresis). Seizures are a frequent symptom in congenital cases.

### Malformations (stigmata)

The destructive effects of syphilis in young children often leave scars or developmental defects called stigmata, which persist throughout life and confirm a diagnosis of congenital syphilis. Hutchinson emphasized the diagnostic importance of changes in the incisor teeth, opacities of the cornea, and eighth cranial nerve deafness, which have since become known as the Hutchinson triad. Hutchinson's teeth, corneal scars, saber shins, rhagades of the lips, saddle nose, and mulberry molars are of diagnostic importance (Fig. 18-12).

Hutchinson's teeth are a malformation of the central upper incisors that appear in the secondary or permanent teeth. The characteristic teeth are cylindrical rather than flattened, the cutting edge is narrower than the base, and in the center of the cutting edge a notch may develop (Fig. 18-13). The mulberry molar, usually the first molar and appearing about age 6 years, is a hyperplastic tooth; its flat occlusal surface is covered with a group of little knobs representing abortive cusps. Nasal chondritis in infancy results in flattening of the nasal bones, forming a so-called saddle nose. The unilateral thickening of the inner third of one clavicle (Higouménaki's sign) is a hyperostosis resulting from syphilitic osteitis in individuals who have had late congenital syphilis. The lesion appears typically on the right side in right-handed persons and on the left side in left-handed persons.

### Diagnosis

Infants of women who meet the following criteria should be evaluated for congenital syphilis:

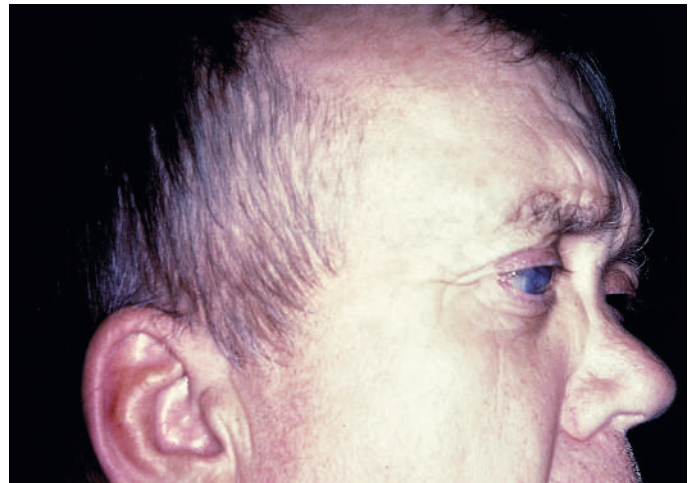
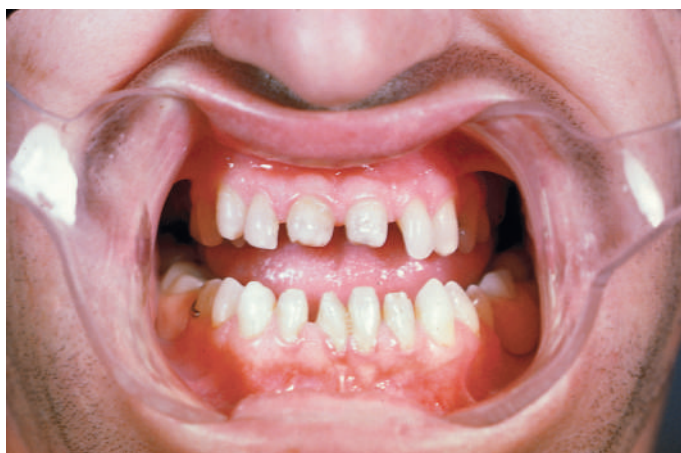

Fig. 18-12 Frontal bossing, interstitial keratitis, and saddle nose in congenital syphilis.





**Fig. 18-13** Hutchinson's teeth in congenital syphilis.

1. Maternal untreated syphilis, inadequate treatment, or no documentation of adequate treatment
2. Treatment of maternal syphilis with nonpenicillin regimen
3. Treatment less than 1 month before delivery
4. Inadequate maternal response to treatment
5. Appropriate treatment before pregnancy, but insufficient serologic follow-up to document adequacy of therapy

The results of serologic tests for syphilis for every woman delivering a baby must be known before the discharge of that baby from the hospital. Serologic testing of the mother and child at delivery are recommended. Evaluation of the children as just noted might include the following:

1. A complete physical examination for findings of congenital syphilis
2. Nontreponemal serology of the infant's serum (not cord blood)
3. Central nervous system evaluation
4. Pathologic evaluation of the placenta using specific antitreponemal antibody staining

## Treatment

Penicillin remains the drug of choice for treatment of all stages of syphilis. Erythromycin is not recommended for treatment of any stage or form of syphilis. HIV testing is recommended in all patients with syphilis. Treatment for HIV-infected patients is discussed later. Patients with primary, secondary, or early latent syphilis known to be of less than 1 year in duration can be treated with a single intramuscular injection of 2.4 million units (megaunits, MU) of benzathine penicillin G. In nonpregnant, penicillin-allergic, HIV-negative patients, tetracycline, 500 mg orally four times daily, or doxycycline, 100 mg orally twice daily for 2 weeks, is recommended. Ceftriaxone, 1 g intramuscularly or intravenously for 8–10 days, is an acceptable alternative if the patient cannot tolerate the previous options. Azithromycin and erythromycin can no longer be recommended as treatment for syphilis because of the worldwide presence of macrolide resistance, caused by a mutation in the gene encoding part of the ribosome responsible for binding macrolides. Close follow-up is recommended for all patients treated with non-penicillin-based regimens. These alternative agents are not recommended for persons with HIV infection and syphilis.

The recommended treatment of late or late latent syphilis of more than 1-year duration in an HIV-negative patient is

benzathine penicillin G, 2.4 MU intramuscularly once weekly for 3 weeks. In a penicillin-allergic, nonpregnant, HIV-negative patient, tetracycline, 500 mg orally four times daily, or doxycycline, 100 mg orally twice daily, for 30 days is recommended. CSF evaluation is recommended if neurologic or ophthalmologic findings are present, if there is evidence of active late (tertiary) syphilis, if treatment has previously failed, if the nontreponemal serum titer is 1:32 or higher, or if any regimen not based on penicillin is planned.

Recommended treatment regimens for neurosyphilis include penicillin G crystalline, 3–4 MU intravenously every 4 h for 10–14 days, or procaine penicillin, 2.4 MU/day intramuscularly, plus probenecid, 500 mg orally four times daily, both for 10–14 days. These regimens are shorter than those for treatment of late syphilis, so they may be followed by benzathine penicillin G, 2.4 MU intramuscularly, once weekly for 3 weeks. Patients allergic to penicillin should have their allergy confirmed by skin testing. If allergy exists, desensitization and treatment with penicillin are recommended.

Treatment of congenital syphilis in the neonate is complex. Therapy should be undertaken in consultation with a pediatric infectious disease specialist. Management strategies can be found in the CDC *Guidelines for the Management of Sexually Transmitted Diseases*. Older children with congenital syphilis should have a CSF evaluation and should be treated with aqueous crystalline penicillin G, 200,000–300,000 U/kg/day intravenously or intramuscularly (50,000 U every 4–6 h) for 10–14 days.

Pregnant women with syphilis should be treated with penicillin in doses appropriate for the stage of syphilis. A second dose of benzathine penicillin, 2.4 MU intramuscularly, may be administered 1 week after the initial dose in pregnant women with primary, secondary, or early latent syphilis. Sonographic evaluation of the fetus in the second half of pregnancy for signs of congenital infection may facilitate management and counseling. Expert consultation should be sought when evidence of fetal syphilis is found, because fetal treatment failure is increased in this situation. Follow-up quantitative serologic tests should be performed monthly until delivery. Pregnant women who are allergic to penicillin should be skin-tested and desensitized if test results are positive.

## Jarisch-Herxheimer or Herxheimer reaction

A febrile reaction often occurs after the initial dose of anti-syphilitic treatment, especially penicillin, is given. Although historically reported to occur in more than 50% of patients treated for early syphilis, a recent report found a rate of only 10%. The reaction generally occurs 6–8 h after treatment and consists of shaking chills, fever, malaise, sore throat, myalgia, headache, tachycardia, and exacerbation of the inflammatory reaction at sites of localized spirochetal infection. A vesicular Herxheimer reaction can occur. A Herxheimer reaction in pregnancy may induce premature labor and fetal distress. Every effort should be made to avoid this complication. Early in pregnancy, women should rest and take acetaminophen for fever. Women treated after 20 weeks of pregnancy should seek obstetric evaluation if they experience fever, decreased fetal movement, or regular contractions within 24 h of treatment. Increased inflammation in a vital structure may have serious consequences, as when aneurysm of the aorta or iritis is present. When the CNS is involved, avoiding the Herxheimer reaction is especially important, even though the paralyses that may result are often transitory. It is important to distinguish the Herxheimer reaction from a drug reaction to penicillin or other antibiotics. The reaction has also been described in other spirochetal diseases, such as leptospirosis and louse-borne relapsing fever.

## Treatment of sex partners

Sexual partners of persons with syphilis should be identified. Persons who are exposed within 90 days of the diagnosis of primary, secondary, or early latent syphilis, even if seronegative, should be treated presumptively. If the exposure occurred before 90 days of diagnosis but follow-up is uncertain, presumptive treatment should be given. If the infectious source has a serologic titer of greater than 1:32, the patient should be presumed to have infectious early syphilis, and sexual partners should be treated. At-risk partners are identified as those exposed within 3 months plus the duration of the primary lesions, for 6 months plus the duration of the secondary lesions, or 1 year for latent syphilis. Treatment of sexual partners is based on their clinical and serologic findings. If they are seronegative but had exposures as previously outlined, treatment would be as for early syphilis, with benzathine penicillin, 2.4 MU intramuscularly as one dose.

## Serologic testing after treatment

Before therapy and then regularly thereafter, quantitative VDRL or RPR testing should be performed on patients who are to be treated for syphilis to ensure appropriate response. For primary and secondary syphilis in an HIV-negative nonpregnant patient, testing is repeated every 3 months in the first year, every 6 months in the second year, and yearly thereafter. At least a fourfold decrease in titer would be expected 6 months after therapy, but 15% of patients with recommended treatment will not achieve this serologic response by 1 year. Patients with prior episodes of syphilis may respond more slowly. If response is inadequate, HIV testing (if HIV status is unknown) and CSF evaluation are recommended. For HIV-negative patients who fail to respond and who have a normal CSF evaluation, optimal management is unclear. Close follow-up must be ensured. If it is decided to retreat the patient, injection of benzathine penicillin G 2.4 MU weekly for 3 weeks is recommended. A fourfold increase in serologic titer clearly indicates treatment failure or reinfection. These patients should have HIV testing and CSF analysis, with treatment determined by test results.

The serologic response for patients with latent syphilis is slower, but a fourfold decrease in titer should be seen by 12–24 months. If no such response occurs, HIV testing and CSF evaluation are recommended. Patients treated for latent or late syphilis may be serofast, so failure to observe a titer fall in these patients does not in itself indicate a need for retreatment. If the titer is less than 1:32, the possibility of a serofast state exists, and retreatment should be planned on an individual basis.

Seroreversion in specific treponemal tests can occur. By 36 months, 24% of patients treated for early syphilis had a negative FTA-ABS and 13% had a negative MHA-TP.

## Syphilis and HIV disease

Syphilis and other genital ulcer diseases enhance the risk of transmission and acquisition of HIV. This may result from early lesions of syphilis containing mononuclear cells with enhanced expression of CCR5, the co-receptor for HIV-1. HIV testing is recommended in all patients with syphilis.

Most HIV-infected patients with syphilis exhibit the classic clinical manifestations with appropriate serologic titers for that stage of disease. Response to treatment, both clinical and serologic in HIV-infected patients with syphilis, generally follow the clinical and serologic patterns seen in patients without coexisting HIV infection. In a large study that com-

pared HIV-positive and HIV-negative patients with syphilis, the former were more likely to present with secondary syphilis (53% vs. 33%) and were more likely to have a chancre that persisted when they had secondary syphilis (43% vs. 15%). Unusual clinical manifestations of syphilis in HIV range from florid skin lesions to few atypical ones, but these are exceptions, not the rule. Because most HIV-infected patients in large urban areas in the United States and Western Europe who acquire syphilis are MSM, chancres may be in atypical locations, such as the lips, tongue, or anus.

In general, the nontreponemal tests are of higher titer in HIV-infected persons. Rarely, the serologic response to infection may be impaired or delayed, and seronegative secondary syphilis has been reported. Biopsy of the skin lesions and histopathologic evaluation with special stains will confirm the diagnosis of syphilis in such patients. This approach, along with darkfield examination of appropriate lesions, should be considered if the clinical eruption is characteristic of syphilis and the serologic tests yield negative results.

Neurosyphilis has been frequently reported in HIV-infected persons, even after appropriate therapy for early syphilis. Manifestations have been those of early neurosyphilis or meningal or meningovascular syphilis. These have included headache, fever, hemiplegia, and cranial nerve (CN) deficits, especially deafness (CN VIII), decreased vision (CN II), and ocular palsies (CNs III and VI). Whether HIV-infected persons are at increased risk for these complications or whether they occur more quickly is unknown. It is known that spirochetes are no more likely to remain in the CSF after treatment in HIV-infected persons than in HIV-negative persons. Whether the impaired host immunity allows these residual spirochetes to cause clinical relapse more frequently or more quickly in the setting of HIV is unknown.

Patients with HIV infection who have primary or secondary syphilis, who are not allergic to penicillin, and who have no neurologic or psychiatric findings should be treated with benzathine penicillin G, 2.4 MU intramuscularly. There is no evidence that additional treatment will reduce the risk of treatment failure. Patients who are allergic to penicillin should be desensitized and treated with penicillin. Following treatment, the patient should have serologic follow-up with quantitative nontreponemal tests at 3, 6, 9, 12, and 24 months. Failure of the titer to fall is an indication for reevaluation, including lumbar puncture. Factors associated with treatment failure in HIV disease include a low initial serological titer (RPR <1:16), a history of prior syphilis, and a CD4 count less than 350 cells/mL.

Because of the concerns about neurologic relapse in the syphilitic patient with HIV disease, more careful CNS evaluation is advocated. Lumbar puncture is recommended in HIV-infected patients with latent syphilis (of any duration), with late syphilis (even with a normal neurologic examination), and with any neurologic or psychiatric signs or symptoms. If RPR is 1:32 or greater and CD4 count is less than 350 cells/mL, neurosyphilis is more likely, and lumbar puncture can be considered. Treatment in these patients will be determined by the result of their CSF evaluation. HIV-infected patients with primary or secondary syphilis should be counseled about their possible increased risk of CNS relapse.

Benzathine penicillin, 2.4 MU intramuscularly, should be used to treat all HIV-infected contacts of patients with syphilis who are at risk of acquiring infection.

**Andrade P, et al:** Solitary frontal ulcer: a syphilitic gumma. *Dermatol Online J* 2010; 16:5.

**Aquilina C, et al:** Secondary syphilis simulating oral hairy leukoplakia. *J Am Acad Dermatol* 2003; 49:749.

**Barbosa IG, et al:** Neurosyphilis presenting as mania. *Bipolar Disord* 2012; 14:309.



- Battistella M, et al:** Extensive nodular secondary syphilis with prozone phenomenon. *Arch Dermatol* 2008; 144:1078.
- Bekkali, N, et al:** An annular patch of the scalp reveals tertiary syphilis. *Int J Dermatol* 2014; 53:e185.
- Bernabeu-Wittel J, et al:** Primary syphilitic chancre on the hand with regional adenopathy. *Sex Transm Dis* 2010; 37:467.
- Bowring J, et al:** Stroke in pregnancy associated with syphilis. *J Obstet Gynaecol Res* 2008; 34:405.
- Centers for Disease Control and Prevention:** Syphilis testing algorithms using treponemal tests for initial screening—four laboratories, New York City, 2005–2006. *MMWR* 2008; 57:872.
- Centers for Disease Control and Prevention:** Sexually transmitted diseases treatment guidelines 2010. *MMWR* 2010; 59:1.
- Cha JM, et al:** Rectal syphilis mimicking rectal cancer. *Yonsei Med J* 2010; 51:276.
- Chan SY, et al:** Syphilis causing hearing loss. *Int J STD AIDS* 2008; 19:721.
- Chen JQ, et al:** Photo quiz: asymptomatic plaques on toe web. *Clin Infect Dis* 2012; 55:1164.
- Cheng S, French P:** Unilateral penile swelling: an unusual presentation of primary syphilis. *Int J STD AIDS* 2008; 19:640.
- Chiu HY, Tsai TF:** A crusted plaque on the right nipple. *JAMA* 2012; 308:403.
- Cid PM, et al:** Pathologically confirmed malignant syphilis using immunohistochemical staining: report of 3 cases and review of the literature. *Sex Transm Dis* 2014; 41:94.
- Cordato DJ, et al:** Prevalence of positive syphilis serology and meningovascular neurosyphilis in patients admitted with stroke and TIA from a culturally diverse population (2005–09). *J Clin Neurol* 2013; 20:943.
- Czerninski R, et al:** Oral syphilis lesions: a diagnostic approach and histologic characteristics of secondary stage. *Quintessence Int* 2011; 42:883.
- Emer J, et al:** Generalized anetoderma after intravenous penicillin therapy for secondary syphilis in an HIV patient. *J Clin Aesthet Dermatol* 2013; 6:23.
- Farhi D, Dupin N:** Management of syphilis in the HIV-infected patient: facts and controversies. *Clin Dermatol* 2010; 28:539.
- Flynn TR, et al:** A 37-year-old man with a lesion on the tongue. *N Engl J Med* 2010; 362:740.
- Galvao TF, et al:** Safety of benzathine penicillin for preventing congenital syphilis: a systematic review. *PLoS One* 2013; 8:e56463.
- Ghanem KG:** Neurosyphilis: a historical perspective and review. *CNS Neurosci Ther* 2010; 16:e157.
- Ghanem KG, Workowski KA:** Management of adult syphilis. *Clin Infect Dis* 2011; 53:S110.
- Grillo E, et al:** Multiple penile lesions: a case study. *Aust Fam Physician* 2012; 41:701.
- Harding AS, Ghanem KG:** The performance of cerebrospinal fluid treponemal-specific antibody tests in neurosyphilis: a systematic review. *Sex Transm Dis* 2012; 39:291.
- Hawkes SJ, et al:** Early antenatal care: does it make a difference to outcomes of pregnancy associated with syphilis? A systematic review and meta-analysis. *PLoS One* 2013; 8:e56713.
- Ho EL, Lukehart SA:** Syphilis: using modern approaches to understand an old disease. *J Clin Invest* 2011; 121:4584.
- Hu QH, et al:** Risk factors associated with prevalent and incident syphilis among an HIV-infected cohort in Northeast China. *BMC Infect Dis* 2014; 14:658.
- Hunt R, et al:** Circumscribed lenticular anetoderma in an HIV-infected man with a history of syphilis and lichen planus. *Dermatol Online J* 2011; 17:2.
- Husein-El Ahmed H, Ruiz-Carrascosa JC:** Secondary syphilis presenting as rash and annular hyperkeratotic lesions. *Int J Infect Dis* 2011; 15:e220.
- Hwang SW, et al:** A case of syphilitic keratoderma concurrent with syphilitic uveitis. *Ann Dermatol* 2009; 21:399.
- Ibrahim FW, Malu MK:** Sudden deafness in a patient with secondary syphilis. *J Laryngol Otol* 2009; 123:1262.
- Jalili A, et al:** Malignant syphilis in an HIV-infected patient. *Sex Transm Dis* 2010; 37:1.
- Jeans AR, et al:** Sensorineural hearing loss due to secondary syphilis. *Int J STD AIDS* 2008; 19:355.
- Jinno S, et al:** Predictors of serological failure after treatment in HIV-infected patients with early syphilis in the emerging era if universal antiretroviral therapy use. *BMC Infect Dis* 2013; 13:605.
- Kenyon C, et al:** Syphilis reinfections pose problems for syphilis diagnosis in Antwerp, Belgium—1992 to 2012. *Euro Surveill* 2014; 19:22.
- Kim JK, et al:** Congenital syphilis presenting with a generalized bullous and pustular eruption in a premature newborn. *Ann Dermatol* 2011; 23:S127.
- Knaute DF, et al:** Serological response to treatment of syphilis according to disease stage and HIV status. *Clin Infect Dis* 2012; 55:1615.
- Larson BA, et al:** Finding a needle in the haystack: the costs and cost-effectiveness of syphilis diagnosis and treatment during pregnancy to prevent congenital syphilis in Kalomo district of Zambia. *PLoS One*; 9:e113868. doi: 10.1371/journal.pone.0113868. eCollection 2014.
- Lee SH, et al:** Early congenital syphilis presenting with vesicobullous eruptions beyond palmoplantar regions. *Acta Derm Venereol* 2014; 94:321.
- Leuci S, et al:** Oral syphilis: a retrospective analysis of 12 cases and a review of the literature. *Oral Dis* 2013; 19:738.
- Long FQ, et al:** Acquired secondary syphilis in preschool children by nonsexual close contact. *Sex Transm Dis* 2012; 39:588.
- Marra C, et al:** Normalization of serum rapid plasma reagin titer predicts normalization of cerebrospinal fluid and clinical abnormalities after treatment of neurosyphilis. *Clin Infect Dis* 2008; 47:893.
- McComb ME, et al:** Secondary syphilis presenting as pseudolymphoma of the skin. *J Am Acad Dermatol* 2003; 49:S174.
- Mignogna MD, et al:** Secondary syphilis mimicking pemphigus vulgaris. *J Eur Acad Dermatol Venereol* 2008; 23:479.
- Miller WM, et al:** Jarisch-Herxheimer reaction among syphilis patients in Rio de Janeiro, Brazil. *Int J STD AIDS* 2010; 21:806.
- Monastirli A, et al:** Lichen planus-like secondary syphilis in an 83-year-old woman. *Clin Exp Dermatol* 2008; 33:780.
- Morshed MG, Singh AE:** Recent trends in the serologic diagnosis of syphilis. *Clin Vaccine Immunol* [Epub ahead of print.]
- Oanță A, Irimie M:** Syphilitic balanitis of Follman. *Int J Dermatol* 2013; 53:830.
- Parker SR, et al:** Seronegative syphilis: another case for the great imitator. *Int J Infect Dis* 2014; 18:104.
- Pastuszczyk M, Wojas-Pelc A:** Current standards for diagnosis and treatment of syphilis: selection of some practical issues, based on the European (IUSTI) and U.S. (CDC) guidelines. *Postepy Dermatol Alergol* 2013; 30:203.
- Patel SJ, et al:** Missed opportunities for preventing congenital syphilis infection in New York City. *Obstet Gynecol* 2012; 120:882.
- Pinto-Almeida T, et al:** Secondary syphilis on a psoriatic patient under cyclosporine: a challenging case. *Int J Dermatol* 2014; 53:e35.
- Pintye J, et al:** Association between male circumcision and incidence of syphilis in men and women: a prospective study in HIV-1 serodiscordant heterosexual African couples. *Lancet Glob Health* 2014; 2:e664.
- Punia V, et al:** Stroke after initiating IV penicillin for neurosyphilis: a possible Jarisch-Herxheimer reaction. *Case Rep Neurol Med* 2014; 2014:548179.
- Qiao J, Fang H:** Syphilitic chancre of the mouth. *CMAJ* 2011; 183:2015.
- Qiao J, Fang H:** Moth-eaten alopecia: a sign of secondary syphilis. *CMAJ* 2013; 185:61.
- Rajan J, et al:** Malignant syphilis with human immunodeficiency virus infection. *Indian Dermatol Online J* 2011; 2:19.
- Rallis E, Pappazos V:** Malignant syphilis as the first manifestation of HIV infection. *Infect Dis Rep* 2012; 4:e15.
- Rodriguez-Caruncho C, et al:** Picture of the Month—quiz case: early congenital syphilis. *Arch Pediatr Adolesc Med* 2012; 166:767.
- Rodriguez-Cerdeira C, et al:** Congenital syphilis in the 21st century. *Actas Dermosifilogr* 2012; 103:679.
- Rysgaard C, et al:** Nodular secondary syphilis with associated granulomatous inflammation: case report and literature review. *J Cutan Pathol* 2014; 41:370.
- Schotanus M, et al:** A patient with multifocal tabetic arthropathy: a case report and review of the literature. *Sex Transm Dis* 2013; 40:251.
- Sezer E, et al:** Secondary syphilis with an interstitial granuloma annulare-like histopathologic pattern. *J Cutan Pathol* 2011; 38:439.
- Shockman S, et al:** Syphilis in the United States. *Clin Dermatol* 2014; 32:213.
- Simms I, Broutet N:** Congenital syphilis re-emerging. *J Dtsch Dermatol Ges* 2008; 6:269.

- Šmajš D, et al:** Genetic diversity in *Treponema pallidum*: implications for pathogenesis, evolution and molecular diagnostics of syphilis and yaws. *Infect Genet Evol* 2012; 12:191.
- Streit E, et al:** Solitary lesion on finger. Primary syphilitic lesion on finger. *Acta Derm Venereol* 2013; 93:251.
- Tipple C, Taylor GP:** Syphilis testing, typing, and treatment follow-up: a new era for an old disease. *Curr Opin Infect Dis* [Epub ahead of print.]
- Tucker JD, et al:** An expanding syphilis epidemic in China: epidemiology, behavioral risk and control strategies with a focus on low-tier female sex workers and men who have sex with men. *Sex Transm Infect* 2011; 87:ii16.
- Unemo M, Janier M:** The 2014 European guideline on the management of syphilis has now been published. *Euro Surveill* 2014; 19:42.
- Vasconcelos P, et al:** Secondary syphilis mimicking inflammatory bowel disease. *Sex Transm Infect* 2013; 89:98.
- Veraldi S, et al:** Multiple aphthoid syphilitic chancres of the oral cavity. *Int J STD AIDS* 2008; 19:486.
- Vinay K, et al:** Malignant syphilis. *Int J Infect Dis* 2013; 17:e930.
- Wang H, et al:** A case of lues maligna in an AIDS patient. *Int J STD AIDS* 2012; 23:599.
- Wendel GD, et al:** Treatment of syphilis in pregnancy and prevention of congenital syphilis. *Clin Infect Dis* 2002; 35:S200.
- Yayli S, et al:** Late secondary syphilis with nodular lesions mimicking Kaposi sarcoma in a patient with human immunodeficiency virus. *Int J Dermatol* 2014; 53:e71.
- Zhang HL, et al:** Clinical spectrum of neurosyphilis among HIV-negative patients in the modern area. *Dermatology* 2013; 226:148.
- Zheng S, et al:** Primary syphilis presenting as bilateral nipple-areola eczematoid lesions. *Acta Derm Venereol* 2014; 94:617.

## NONVENEREAL TREPONEMATOSES: YAWS, ENDEMIC SYPHILIS, AND PINTA

This group of diseases is called the endemic or nonvenereal treponematoses. They share many epidemiologic and pathologic features. As with venereal syphilis, the clinical manifestations are divided into early and late stages. Early disease is considered infectious and lasts for approximately 5 years. There are periods of latency. The histology is similar in all the diseases and resembles venereal syphilis. Cutaneous manifestations are prominent. The bones and mucosa may also be involved in some cases (except in pinta). Cardiovascular and nervous system involvement and congenital disease are not seen. Children younger than 15 years are primarily affected. Person-to-person contact or sharing of a drinking vessel is the mode of transmission.

The endemic treponematoses are closely related to poverty and a lack of available health services. They are described as occurring “where the road ends.” These diseases tend to occur in the tropics, especially yaws, and the wearing of few clothes and a hot, humid climate are associated with higher prevalence. In endemic areas, as hygiene improves, “attenuated” forms of yaws and endemic syphilis appear. A larger percentage of the population is latently infected, and secondary lesions are fewer in number, drier, and limited to moist skinfolds. Instead of several “crops” of eruptions lasting months to years, infected persons have only a single crop. Transmission is thus reduced, although a large percentage of the population may be infected.

Yaws has been eradicated from many previously endemic areas, and the number of cases currently is less than 5% of that 50 years ago. Unfortunately, yaws is still focally endemic in Africa (especially among the pygmies), Indonesia, Timor Leste, Papua New Guinea, the Solomon Islands, and Vanuatu. The discovery of treponemal infection with a high genetic similarity to yaws in monkeys in Africa suggests a possible animal reservoir for this infection, further complicating eradication efforts.

## Yaws (pian, frambesia, bouba)

Yaws is caused by *Treponema pallidum* subsp. *pertenue*. It is transmitted nonsexually, by contact with infectious lesions. Yaws predominantly affects children younger than 15 years. The disease has a disabling course, affecting the skin, bones, and joints, and is divided into early (primary and secondary) and late (tertiary) disease.

### Early yaws

A primary papule or group of papules appears at the site of inoculation after an incubation period of about 3 weeks (10 days to 3 months), during which there may be headache, malaise, and other mild constitutional symptoms. The initial lesion becomes crusted and larger (2–5 cm) and is known as the “mother yaw” (maman pian). The crusts are amber-yellow. They may be knocked off, forming an ulcer with a red, pulpy, granulated surface, but quickly reform, so that the typical yaws lesion is crusted. The lesion is not indurated. There may be some regional adenopathy.

Exposed parts are most frequently involved—the extremities, particularly the lower legs, feet, buttocks, and face—although the mother’s breasts and trunk may be infected by her child. The lesion is almost always extragenital, and when genital, is a result of accidental contact rather than intercourse. After being present for about 3–6 months, the mother yaw spontaneously disappears, leaving slight atrophy and depigmentation.

Weeks or months after the primary lesion appears, secondary yaws develops. Secondary lesions resemble the mother yaw, but they are smaller and may appear around the primary lesions or in a generalized pattern. The secondary lesions may clear centrally and coalesce peripherally, forming annular lesions (ringworm yaws or tineas yaws) (Fig. 18-14). The palms and soles may be involved, resembling secondary syphilis. In some sites, especially around the body orifices and in the armpits, groins, and gluteal crease, condylomatous lesions may arise, resembling condyloma latum of secondary syphilis. In drier endemic regions and during drier seasons, lesions tend to be fewer, less papillomatous, and more scaly, and instead of being generalized, favor the folds of the axillae, groin, and oral cavity. Yaws in the dry seasons and dry geographic areas closely resembles endemic syphilis. The palms and soles may develop thick, hyperkeratotic plaques that fissure. They are painful, resulting in a crablike gait (crab yaws). At times there is paronychia. Generalized lymphadenopathy, arthralgias, headaches, and malaise are common.

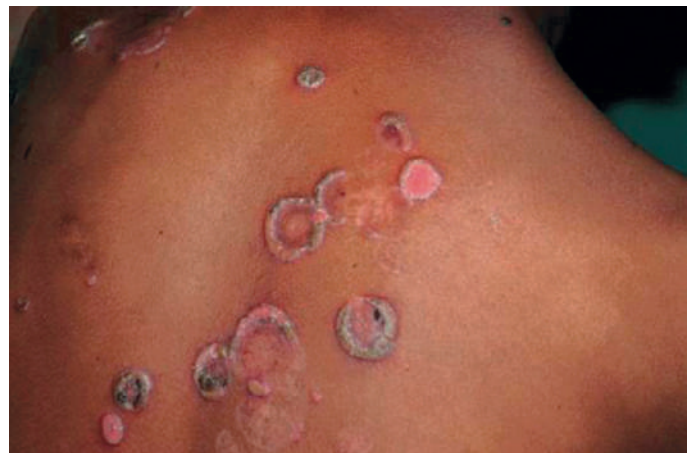

Fig. 18-14 Yaws, secondary lesions.



With improved nutrition and hygiene, an “attenuated” form, with only scattered, flat, gray lesions in intertriginous areas, has been described.

Over a few weeks or months, the secondary lesions may undergo spontaneous involution, leaving either no skin changes or hypopigmented macules that later become hyperpigmented. However, the eruption may persist for many months as a result of fresh, recurrent outbreaks. The course is slower in adults than in children, in whom the secondary period rarely lasts longer than 6 months. During latency, skin lesions may relapse for as long as 5 years. Painful osteoperiostitis and polydactylitis may present in early yaws as fusiform swelling of the hands, feet, arms, and legs.

## Late yaws

The disease usually terminates with the secondary stage, but in about 10% of patients, it progresses to the late stage, usually 5–10 years after initial infection. The typical late-yaws skin lesions are gummas that present as indolent ulcers with clean-cut or undermined edges. They tend to fuse and form configurate and occasionally serpiginous patterns clinically indistinguishable from those of tertiary syphilis. On healing, these lesions scar, leading to contractures and deformities. Hyperkeratotic palmoplantar plaques and keratoderma frequently recur in the late stage.

Similar processes may occur in the skeletal system and other deep structures, leading to painful nodes on the bones, or destruction of the palate and nasal bone (gangosa). There may be periostitis, particularly of the tibia (saber shin, saber tibia), epiphysitis, chronic synovitis, and juxta-articular nodules. Goundou is a rare proliferative osteitis initially affecting the nasal aspects of the maxilla. Two large, hard tumors form on the lateral aspects of the nose. These can significantly obstruct vision. The process may extend into other bones of the central face, affecting the palate and nose, and resulting in protrusion of the whole central face as a mass. Although yaws is classically thought to spare the eye and nervous system, abnormal CSF findings in early yaws and scattered reports of eye and neurologic findings in patients with late yaws suggest that yaws, like syphilis, has the potential to cause neurologic or ophthalmic sequelae, although rarely.

## Histopathology

Early yaws shows epidermal edema, acanthosis, papillomatosis, neutrophilic intraepidermal microabscesses, and a moderate to dense perivascular infiltrate of lymphocytes and plasma cells. Treponemas are usually demonstrable in the primary and secondary stages with the use of the same silver stains employed in diagnosing syphilis. Tertiary yaws shows features identical to the gumma of tertiary syphilis.

## Diagnosis

The diagnosis should be suspected from the typical clinical appearance in a person living in an endemic region. The presence of keratoderma palmaris et plantaris in such a person is highly suggestive of yaws. Darkfield demonstration of spirochetes in the early lesions and a reactive VDRL or RPR test can be used to confirm primary and secondary yaws.

## Endemic syphilis (bejel)

Bejel is a Bedouin term for this nonvenereal treponematoses, which occurs primarily in the seminomadic tribes who live in the arid regions of North Africa, Southwest Asia, and the

eastern Mediterranean. The etiologic agent of bejel is *Treponema pallidum* subsp. *endemicum*. It occurs primarily in childhood and is spread by skin contact or from mouth to mouth by kissing or use of contaminated drinking vessels. The skin, oral mucosa, and skeletal system are primarily involved.

Primary lesions are rare, probably occurring undetected in the oropharyngeal mucosa. The most common presentation is with secondary oral lesions resembling mucous patches. These are shallow, relatively painless ulcerations, occasionally accompanied by laryngitis. Split papules, angular cheilitis, condylomatous lesions of the moist folds of the axillae and groin, and a nonpruritic generalized papular eruption may be seen. Generalized lymphadenopathy is common. Osteoperiostitis of the long bones may occur, causing nocturnal leg pains.

Untreated secondary bejel heals in 6–9 months. The tertiary stage can occur between 6 months and several years after the early symptoms resolve. In the tertiary stage, leg pain (periostitis) and gummatous ulcerations of the skin, nasopharynx, and bone occur. Gangosa (rhinopharyngitis mutilans) can result. Rarely reported neurologic sequelae seem to be restricted to the eye, including uveitis, choroiditis, chorioretinitis, and optic atrophy. As with yaws, with improved nutrition, an attenuated form of endemic syphilis occurs, often presenting with leg pain from periostitis. The diagnosis of bejel is confirmed by the same means as for venereal syphilis.

## Pinta

Pinta is an infectious, nonvenereal, endemic treponematoses caused by *Treponema carateum*. The mode of transmission is unknown, but repeated, direct, lesion-to-skin contact is likely. Only skin lesions occur. By contrast with yaws and bejel, pinta affects persons of all ages, favoring those 14–30 years old. It was once prevalent in the forests and rural areas of Central and South America and Cuba, but it is now rarely reported. The manifestations of pinta may be divided into primary, secondary (early), and tertiary (late) stages. Historically, however, patients may describe continuous evolution from secondary dyspigmented lesions to the characteristic achromic lesions of tertiary pinta.

## Primary stage

It is believed that the initial lesion appears 7–60 days after inoculation. The lesion begins as a tiny red papule that becomes an elevated, poorly defined, erythematous, infiltrated plaque up to 10–12.5 cm in diameter over 2–3 months. Expansion of the primary lesion may occur by fusion with surrounding satellite macules or papules. Ultimately, it becomes impossible to distinguish the primary lesion from the secondary lesions. At no time is there erosion or ulceration such as occurs in the syphilitic chancre. Most initial lesions of pinta develop on the legs and other uncovered parts. The RPR and VDRL tests are nonreactive in the primary stage. Darkfield examination may be positive.

## Secondary stage

The secondary stage of pinta appears 5 months to 1 year or more after infection. It begins with small, scaling papules that may enlarge and coalesce, simulating psoriasis, ringworm, eczema, syphilis, or Hansen’s disease. The papules are located mostly on the extremities and face and frequently are somewhat circinate. Over time, the initially red to violaceous lesions show postinflammatory hyperpigmentation, in shades of gray, blue, or brown, or hypopigmentation. Secondary lesions

are classified as erythematous, desquamative, hypochromic, or hyperchromic. Multiple different morphologies may be present simultaneously, giving a very polymorphous appearance. Nontreponemal tests for syphilis are reactive in the secondary stage in about 60% of pinta patients. Darkfield examination may show spirochetes.

### Late dyschromic stage

Until the 1940s, the late pigmentary changes were the only recognized clinical manifestations of pinta. These have an insidious onset, usually in adolescents or young adults, of widespread depigmented macules resembling vitiligo. The lesions are located chiefly on the face, waistline, wrist flexures, and trochanteric region, although diffuse involvement may occur, so that large areas on the trunk and extremities are affected. The lesions are symmetric in more than one third of patients. Hemipinta is a rare variety of the disease in which the pigmentary disturbances affect only half the body. In the late dyschromic stage of pinta, the serologic test for syphilis is positive in nearly all patients.

### Histopathology

Skin lesions in early pinta show moderate acanthosis; occasionally, lichenoid changes with basal layer vacuolization; and an upper dermal perivascular infiltrate of lymphocytes and plasma cells. Melanophages are prominent in the upper dermis. Spirochetes may be demonstrated in the epidermis by special stains in primary, secondary, and hyperpigmented lesions of tertiary pinta. In tertiary pinta, the depigmented skin shows a loss of basal pigment, pigmentary incontinence, and virtually no dermal inflammatory infiltrate. Spirochetes are rarely found in depigmented tertiary lesions.

### Treatment

The treatment of choice for all endemic treponematoses is benzathine penicillin G, 1.2–2.4 MU intramuscularly (0.6–1.2 MU for children under age 10). In penicillin-allergic patients, tetracycline, 500 mg four times daily for adults, or erythromycin, 8–10 mg/kg four times daily for children, for 15 days is recommended. Penicillin-resistant yaws has been reported from New Guinea. In tertiary pinta, the blue color gradually disappears, as do the areas of partial depigmentation. The vitiliginous areas, if present for more than 5 years, are permanent.

Eradication of the endemic treponematoses is possible with persistent and effective treatment strategies, including the following:

1. Screening of the whole population in endemic areas
2. Diagnosis of patients seen at health services and by community outreach
3. Health education
4. Improved hygiene (soap and water)

If more than 10% of the population is affected, the whole population is treated (mass treatment). If 5–10% of the population is affected, treat all active cases, all children younger than 15, and all contacts (juvenile mass treatment). If less than 5% of the population is infected, treat all active cases and all household and close personal contacts (selective mass treatment). Unfortunately, with the areas affected by the endemic treponematoses also struggling with epidemics of HIV, tuberculosis, and malaria, eradication programs have been largely discontinued.

**Asiedu K, et al:** Eradication of yaws: historical efforts and achieving WHO's 2020 target. *PLoS Negl Trop Dis* 2014; 8:e3016.

**Ayove T, et al:** Sensitivity and specificity of a rapid point-of-care test for active yaws: a comparative study. *Lancet Glob Health* 2014; 2: e415.

**Fanella S, et al:** Local transmission of imported endemic syphilis, Canada, 2011. *Emerg Infect Dis* 2012; 18:1002.

**Giacani L, Lukehart SA:** The endemic treponematoses. *Clin Microbiol Rev* 2014; 27:89.

**Kazadi WM, et al:** Epidemiology of yaws: an update. *Clin Epidemiol* 2014; 6:119.

**Marks M, et al:** Endemic treponemal diseases. *Trans R Soc Trop Med Hyg* 2014; 108:601.

**Marks M, et al:** Yaws. *Int J STD AIDS* 2014 [Epub ahead of print.]

**Maurice J:** Neglected tropical diseases. Oral antibiotic raises hopes of eradicating yaws. *Science* 2014; 344:142.

**Mitja O, et al:** Outcome predictors in treatment of yaws. *Emerg Infect Dis* 2011; 17:1083.

**Mitja O, et al:** Short report: challenges in recognition and diagnosis of yaws in children in Papua New Guinea. *Am J Trop Med Hyg* 2011; 85:113.

**Mitja O, et al:** Single-dose azithromycin versus benzathine benzylpenicillin for treatment of yaws in children in Papua New Guinea: an open-label, non-inferiority, randomized trial. *Lancet* 2012; 379:342.

**Mitja O, et al:** Advances in the diagnosis of endemic treponematoses: yaws, bejel, and pinta. *PLoS Negl Trop Dis* 2013; 7:e2283.

**Mitja O, et al:** Yaws. *Lancet* 2013; 381:763.

**Satter EK, Tokarz VA:** Secondary yaws: an endemic treponemal infection. *Pediatr Dermatol* 2010; 27:364.

**Vabres P:** Endemic treponemal infections in international adoptees and immigrant children: how common are they? *Pediatr Dermatol* 2011; 28:214.



Bonus images for this chapter can be found online at

[expertconsult.inkling.com](http://expertconsult.inkling.com)

**eFig. 18-1** Primary syphilis, chancre with induration and erosion.

**eFig. 18-2** Primary syphilis, chancre of the upper lip.

**eFig. 18-3** Primary syphilis, atypical chancres.

**eFig. 18-4** Secondary syphilis.

**eFig. 18-5** Secondary syphilis; late, larger lesions.

**eFig. 18-6** Secondary syphilis; red, flat-topped papules of the soles.

**eFig. 18-7** Secondary syphilis, psoriasiform papules.

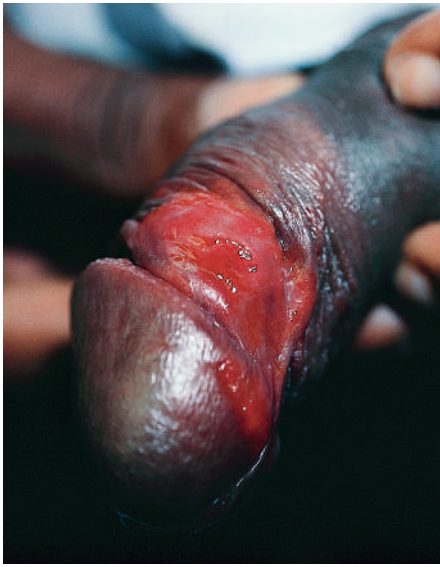**eFig. 18-8** Alopecia of secondary syphilis.

**eFig. 18-9** Condylomata of the scrotum.

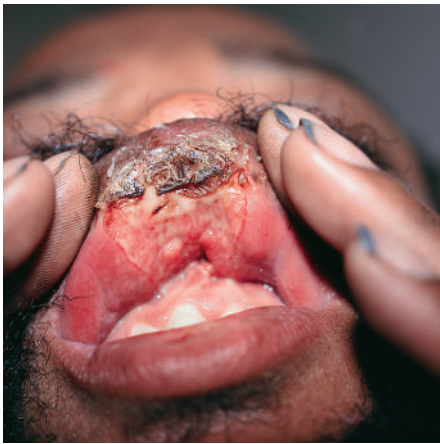**eFig. 18-10** Tertiary syphilis.

**eFig. 18-11** Pinta, late dyschromic stage.

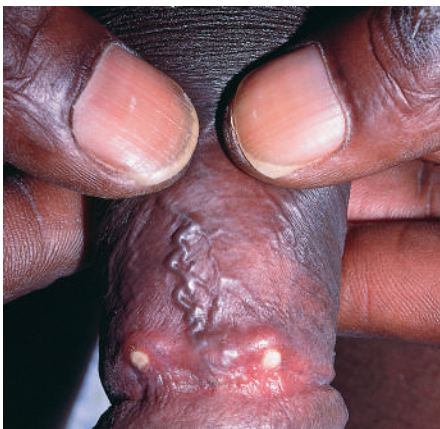



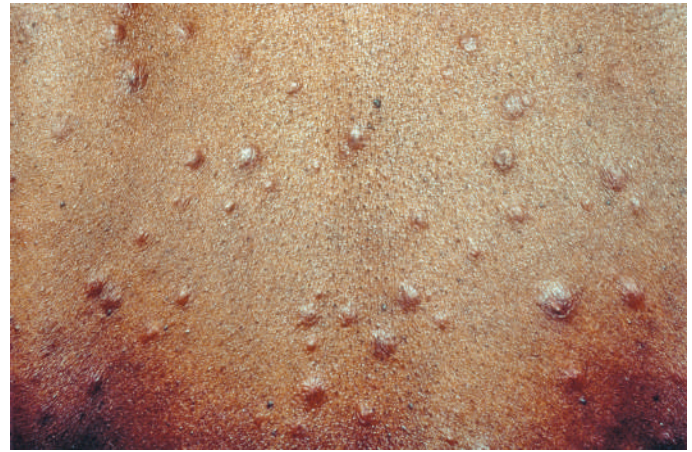**eFig. 18-1** Primary syphilis, chancre with induration and erosion.



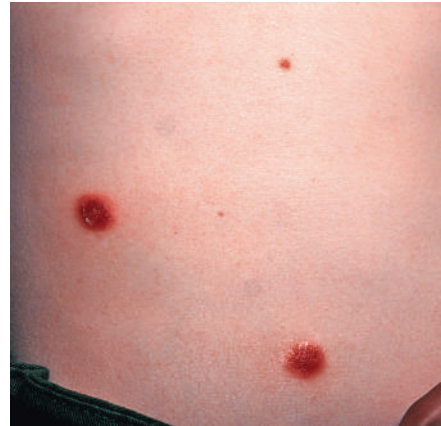**eFig. 18-2** Primary syphilis, chancre of the upper lip.



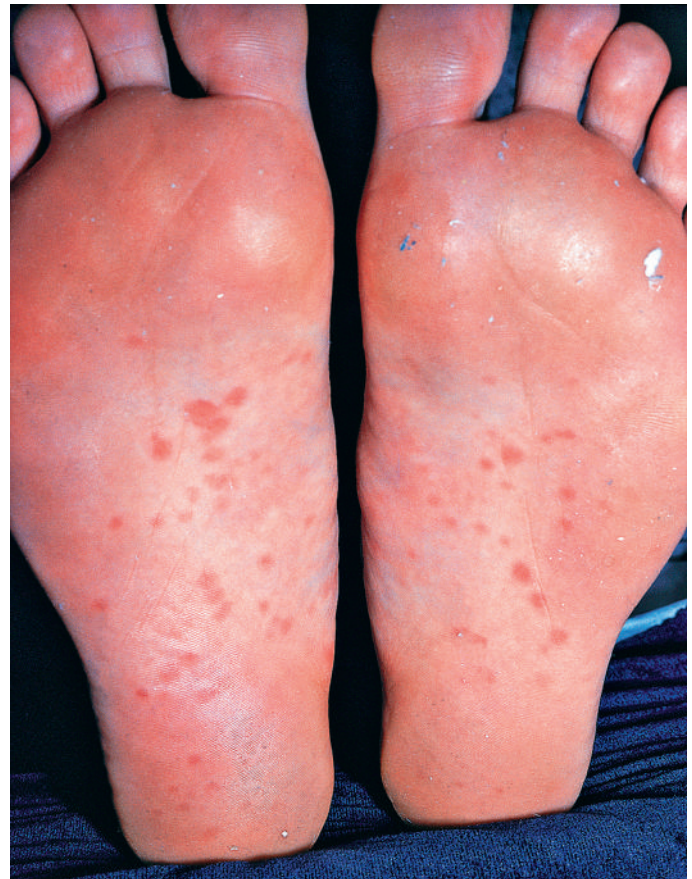**eFig. 18-3** Primary syphilis, atypical chancres.



**eFig. 18-4** Secondary syphilis.

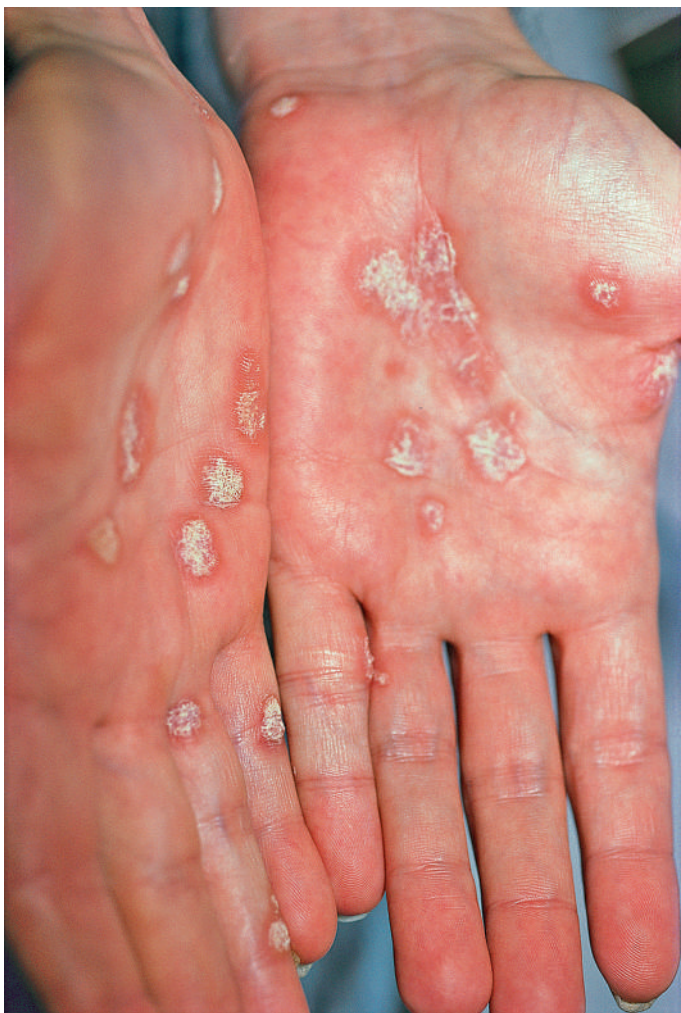

**eFig. 18-5** Secondary syphilis; late, larger lesions.

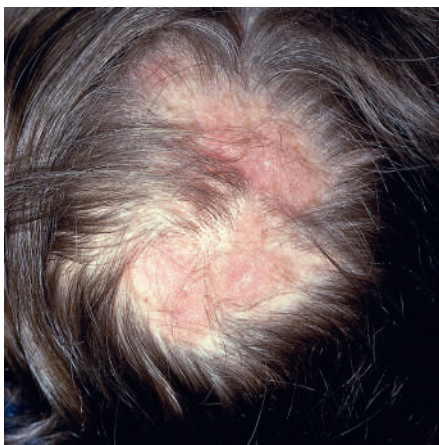


**eFig. 18-6** Secondary syphilis; red, flat-topped papules of the soles.

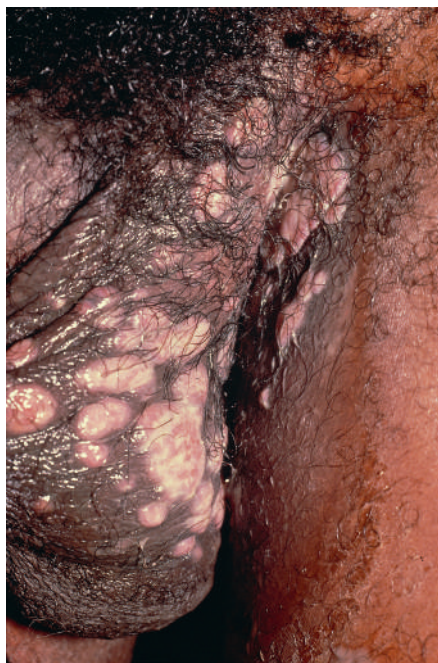



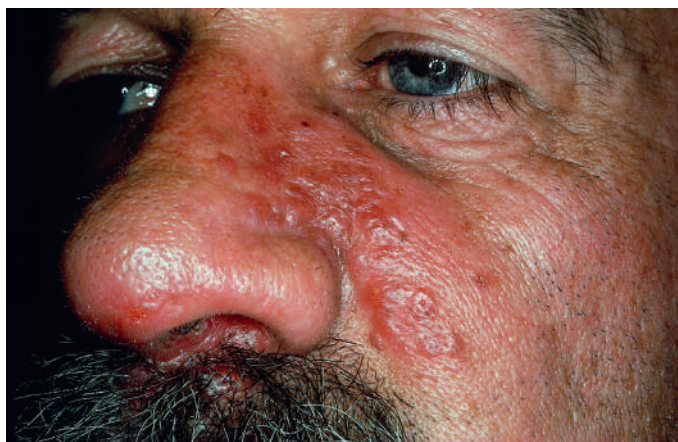**eFig. 18-7** Secondary syphilis, psoriasiform papules.



**eFig. 18-8** Alopecia of secondary syphilis.

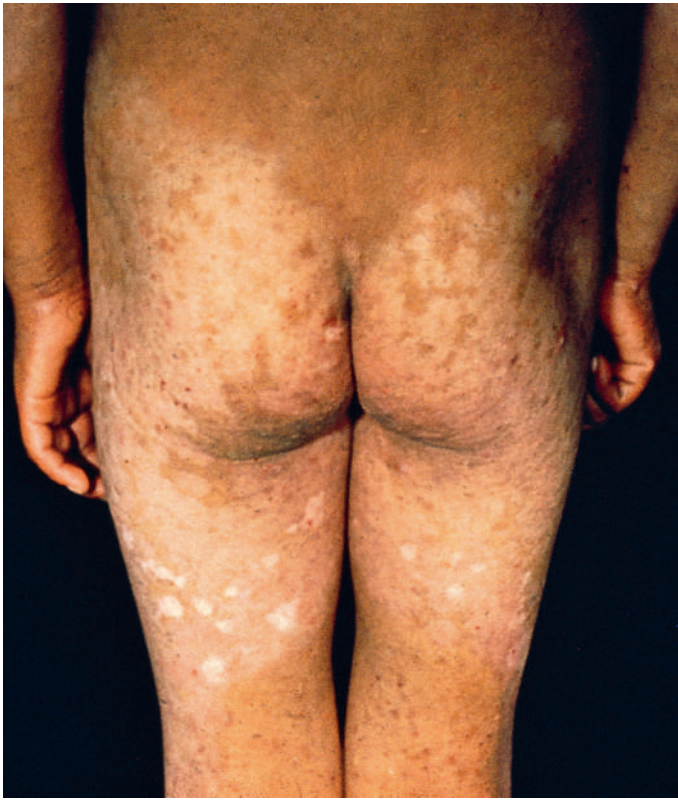

**eFig. 18-9**  
Condylomata of the scrotum.



**eFig. 18-10** Tertiary syphilis.





**eFig. 18-11** Pinta, late dyschromic stage.



## Viral Diseases

# 19

Viruses are obligatory intracellular parasites. The structural components of a viral particle (virion) consist of a central core of nucleic acid, a protective protein coat (capsid), and (in certain groups of viruses only) an outermost membrane or envelope. The capsid of the simplest viruses consists of many identical polypeptides (structural units) that fold and interact with one another to form morphologic units (capsomeres). The number of capsomeres is believed to be constant for each virus with cubic symmetry, and it is an important criterion in the classification of viruses. The protein coat determines serologic specificity, protects the nucleic acid from enzymatic degradation in biologic environments, controls host specificity, and increases the efficiency of infection. The outermost membrane of the enveloped viruses is essential for the attachment to, and penetration of, host cells. The envelope also contains important viral antigens.

Two main groups of viruses are distinguished: DNA and RNA. The DNA virus types are parvovirus, papovavirus, adenovirus, herpesvirus, and poxvirus. RNA viruses are picornavirus, togavirus, reovirus, coronavirus, orthomyxovirus, retrovirus, arenavirus, rhabdovirus, and paramyxovirus. Some viruses are distinguished by their mode of transmission: arthropod-borne viruses, respiratory viruses, fecal-oral or intestinal viruses, venereal viruses, and penetrating-wound viruses.

### HERPESVIRUS GROUP

The herpesviruses are medium-sized viruses that contain double-stranded (ds) DNA and replicate in the cell nucleus. They are characterized by the ability to produce latent but lifelong infection by infecting immunologically protected cells (immune cells and nerves). Intermittently, they have replicative episodes with amplification of the viral numbers in anatomic sites conducive to transmission from one host to the next (genital skin, orolabial region). The vast majority of infected persons remain asymptomatic. Viruses in this group are varicella-zoster virus (VZV; HHV-3), herpes simplex virus types 1 and 2 (HSV-1, HSV-2), cytomegalovirus (CMV), Epstein-Barr virus (EBV), human herpesviruses (HHV-6, HHV-7, HHV-8), *Herpesvirus simiae* (B virus), and other viruses of animals.

### Herpes simplex

Infection with HSV is one of the most prevalent infections worldwide. HSV-1 infection, the cause of most cases of orolabial herpes, is more common than infection with HSV-2, the cause of most cases of genital herpes. Between 30% and 95% of adults (depending on the country and group tested) are seropositive for HSV-1, although seroprevalence of HSV-1 has

decreased by more than 20% in the United States among adolescents (age 14–19 years) over the last decade. Seroprevalence for HSV-2 is lower, and it appears at the age of onset of sexual activity. In Scandinavia, the rate of infection with HSV-2 increases from 2% in 15-year-olds to 25% in 30-year-olds. About 2.4% of adults become infected annually with HSV-2 in their third decade of life. In the United States, about 25% of adults are infected with HSV-2, with black men and women twice as likely to be HSV-2 infected as whites. In sexually transmitted disease (STD) clinic patients, the infection rate is 30–50%. In sub-Saharan Africa, infection rates are 60–95%. Worldwide, the seroprevalence is higher in persons infected with human immunodeficiency virus (HIV). Serologic data show that many more people are infected than give a history of clinical disease. For HSV-1, about 50% of infected persons give a history of orolabial lesions. For HSV-2, 20% of infected persons are completely asymptomatic (latent infection), 20% have recurrent genital herpes they recognize, and 60% have clinical lesions that they do not recognize as genital herpes (subclinical or unrecognized infection). Most persons with HSV-2 infection are asymptomatic, but the majority do not recognize that their symptoms are caused by HSV. All persons infected with HSV-1 and HSV-2 are potentially infectious even if they have no clinical signs or symptoms.

Herpes simplex infections are classified as either “first episode” or “recurrent.” Most patients have no lesions or findings when they are initially infected with HSV. When patients have their first clinical lesion, this is usually a recurrence. Because the initial clinical presentation is not associated with a new infection, the previous terminology of “primary” infection has been abandoned. Instead, the initial clinical presentation is called a first episode and may represent a true primary infection or a recurrence. Persons with chronic or acute immunosuppression may have prolonged and atypical clinical courses.

Infections with HSV-1 or HSV-2 are diagnosed by specific and nonspecific methods. The most common procedure used in the office is the Tzanck smear. It is nonspecific because both HSV and VZV infections result in the formation of multinucleate epidermal giant cells. The multiple nuclei are molded or fit together as pieces of a puzzle. Although the technique is rapid, its success depends heavily on the skill of the interpreter. The accuracy rate is 60–90%, with a false-positive rate of 3–13%. The direct fluorescent antibody (DFA) test is more accurate and will identify virus type; results can be available in hours if a virology laboratory is nearby. Viral culture is very specific and relatively rapid, compared with serologic tests, because HSV is stable in transport and grows readily and rapidly in culture. Results are often available in 48–72 h. Polymerase chain reaction (PCR) is as specific as viral culture but four times more sensitive and can be performed on dried or fixed tissue. Skin biopsies of lesions can detect viropathic changes caused by HSV, and with specific HSV antibodies,



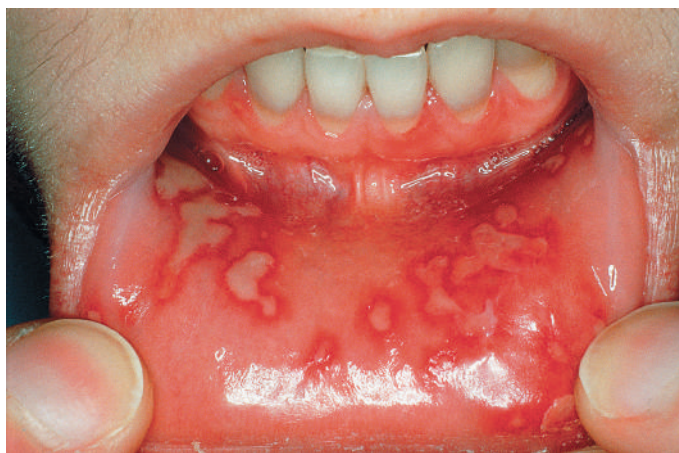immunoperoxidase (IP) techniques can accurately diagnose infection. The accuracy of various tests depends on lesion morphology. Only acute, vesicular lesions are likely to be positive with Tzanck smears. Crusted, eroded, or ulcerative lesions are best diagnosed by viral culture, DFA, histologic methods, or PCR.

Serologic tests are generally not used in determining whether a skin lesion is caused by HSV infection. A positive serologic test indicates only that the individual is infected with that virus, not that the viral infection is the cause of the current lesion. Second-generation enzyme-linked immunosorbent assay (ELISA) tests and G protein-specific Western blot serologic tests can detect specific infection with HSV-1 and HSV-2 but cannot determine the duration or source of that infection. In addition to determining the infection rate in various populations, serologic tests are most useful in evaluating couples in which only one partner gives a history of genital herpes (discordant couples), in couples (if childbearing) at risk for neonatal herpes infection, and for possible HSV vaccination (when available).

### Orolabial herpes

Orolabial herpes is virtually always caused by HSV-1. In 1% or less of newly infected persons, herpetic gingivostomatitis develops, mainly in children and young adults (Fig. 19-1). The onset is often accompanied by high fever, regional lymphadenopathy, and malaise. The herpetic lesions in the mouth are usually broken vesicles that appear as erosions or ulcers covered with a white membrane. The erosions may become widespread on the oral mucosa, tongue, and tonsils, and the gingival margin is usually eroded. Herpetic gingivostomatitis produces pain, foul breath, and dysphagia. In young children, dehydration may occur. It may cause pharyngitis, with ulcerative or exudative lesions of the posterior pharynx. The duration, untreated, is 1–2 weeks. If the initial episode of herpetic gingivostomatitis or herpes labialis is so severe that intravenous (IV) administration is required, IV acyclovir, 5 mg/kg three times daily, is recommended. Oral therapeutic options include acyclovir suspension, 15 mg/kg five times daily for 7 days; valacyclovir, 1 g twice daily for 7 days; or famciclovir, 500 mg twice daily for 7 days. This therapy reduces the duration of the illness by more than 50%.

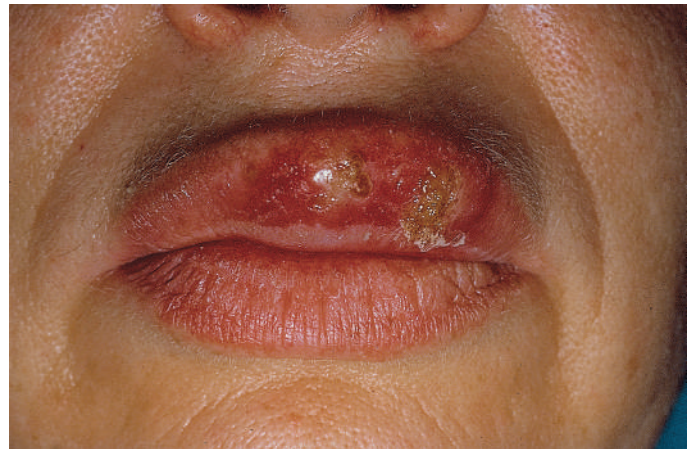The most frequent clinical manifestation of orolabial herpes is the “cold sore” or “fever blister.” Recurrent HSV-1 is the cause of 95% or more of cases and typically presents as grouped blisters on an erythematous base. The lips near the vermilion are most frequently involved (Fig. 19-2), although lesions may



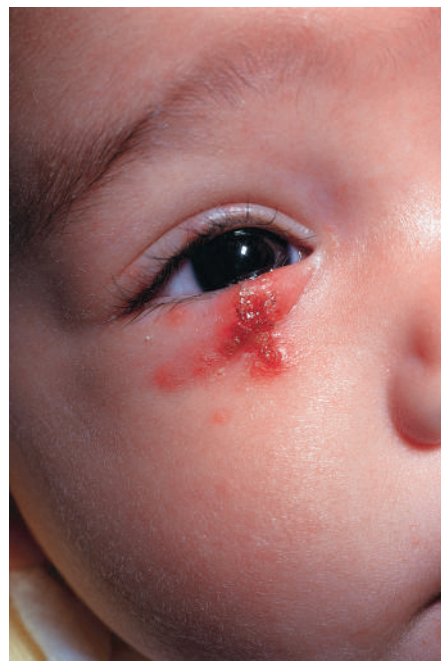**Fig. 19-1** Herpetic gingivostomatitis, extensive erosions of the oral mucosa.

occur wherever the virus was inoculated or proliferated during the initial episode (Fig. 19-3). Recurrences may be seen on the cheeks, eyelids, and earlobes. Oral recurrent HSV usually affects the keratinized surfaces of the hard palate and attached gingiva. Outbreaks are variable in severity, partly related to the trigger of the outbreak. Some outbreaks are small and resolve rapidly, whereas others may be severe, involving both the upper and the lower lip. In severe outbreaks, lip swelling is often present. Patient symptomatology is variable. A prodrome of up to 24 h of tingling, itching, or burning may precede the outbreak. Local discomfort, as well as headache, nasal congestion, or mild flulike symptoms, may occur. Ultraviolet (UV) exposure, especially UVB, is a frequent trigger of recurrent orolabial HSV, and severity of the outbreak may correlate with intensity of the sun exposure. Surgical and dental procedures of the lips (or other areas previously affected with HSV) may trigger recurrences, and a history of prior HSV should be solicited in all patients in whom such procedures are recommended (see next).

In most patients, recurrent orolabial herpes represents more of a nuisance than a disease. Because UVB radiation is a common trigger, use of a sunblock daily on the lips and facial skin may reduce recurrences. All topical therapies for the acute



**Fig. 19-2** Orolabial, recurrent herpes simplex



**Fig. 19-3** HSV-1, eyelid infection from a “kiss” from an infected adult.



treatment of recurrent orolabial herpes have limited efficacy, reducing disease duration and pain by 1 day or less. Tetracaine cream, penciclovir cream, and acyclovir cream (not ointment) have some limited efficacy. Topical acyclovir ointment and docosanol cream provide minimal to no reduction in healing time or discomfort. The minimal benefit from these topical agents suggests that they should not be recommended when patients present to dermatologists for significant symptomatic orolabial herpes outbreaks. If oral therapy is contemplated for patients with severely symptomatic recurrences of orolabial HSV, it must be remembered that much higher doses of oral antivirals are required than for treatment of genital herpes. Intermittent treatment with valacyclovir, 2 g twice daily for 1 day, or famciclovir, 1.5 g as a single dose, starting at the onset of the prodrome, are simple and effective oral, 1-day regimens. Since the patient's own inflammatory reaction against the virus contributes substantially to the severity of lesions of orolabial herpes simplex, topical therapy with a high-potency topical corticosteroid (fluocinonide gel 0.05%, three times daily) in combination with an oral antiviral agent more rapidly reduces pain and reduces maximum lesion area and time to healing. In nonimmunosuppressed patients, if episodic treatment for orolabial HSV is recommended and an oral agent is used, the addition of a high-potency topical corticosteroid should be considered.

Although most patients with orolabial herpes simplex do not require treatment, certain medical and dental procedures may trigger outbreaks of HSV. If the cutaneous surface has been damaged by the surgical procedure (e.g., dermabrasion, chemical peel, laser resurfacing), the surgical site can be infected by the virus and may result in prolonged healing and possible scarring. Prophylaxis is regularly used before such surgeries in patients with a history of orolabial herpes simplex. Famciclovir, 250 mg twice daily, and valacyclovir, 500 mg twice daily, or oral acyclovir 400 mg three times daily, are prophylactic options, to be begun 24 h before the procedure. Duration of treatment in part depends on severity of the skin insult and rate of healing but should be at least 1 week and could be as long as 14 days. For routine surgeries at sites of HSV recurrences (upper or lower lip), acyclovir, 200 mg five times daily; famciclovir, 250 mg three times daily; or valacyclovir, 1 g twice daily, starting 2–5 days before the procedure and continuing for 5 days, can be considered. Prophylaxis could also be considered before skiing or tropical vacations and before extensive dental procedures, at the same dosages. Reactivation of orolabial herpes has also been associated with hyaluronic acid filler injections in about 1.5% of patients; and extensive facial HSV-1 infection has followed intense inhaled corticosteroid therapy. Kissing of the penis during ritual Jewish circumcision can lead to penile HSV-1 infection, which can present acutely, or even years after the initial exposure. Some of these infants have died of disseminated or central nervous system HSV infection.

### Herpetic sycosis

Recurrent or initial herpes simplex infections (usually from HSV-1) may primarily affect the hair follicle. The clinical appearance may vary from a few eroded follicular papules (resembling acne excoriée) to extensive lesions involving the whole beard area in men (Fig. 19-4). Close razor blade shaving immediately before initial exposure or in the presence of an acute orolabial lesion may be associated with a more extensive eruption. The onset may be acute (over days) or more subacute or chronic. Diagnostic clues include the tendency for erosions, a self-limited course of 2–3 weeks, and an appropriate risk behavior. The diagnosis may be confirmed by biopsy. Although the herpes infection is primarily in the follicle, surface cultures

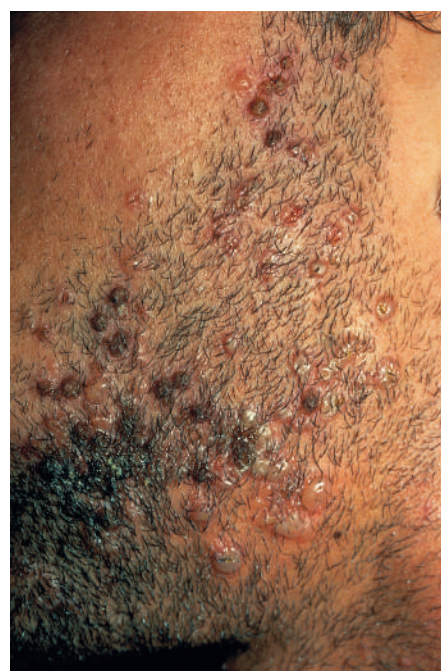

Fig. 19-4 Herpetic sycosis.

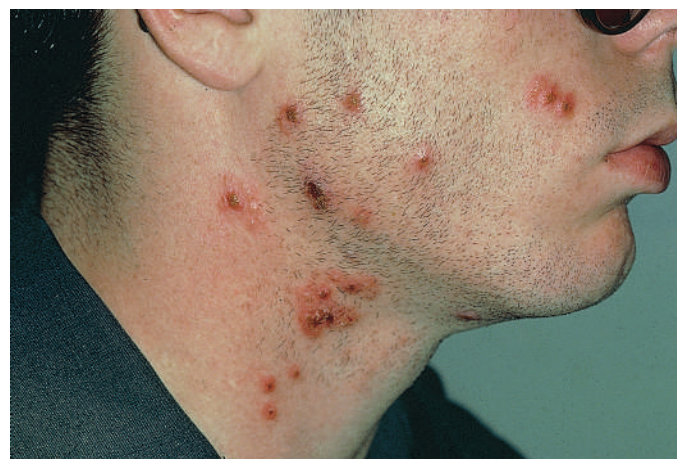

Fig. 19-5 Herpes gladiatorum, cheek and neck lesions of HSV-1.

of eroded lesions will usually be positive in the first 5–7 days of the eruption.

### Herpes gladiatorum

Infection with HSV-1 is highly contagious to susceptible persons who wrestle with an infected individual with an active lesion. One third of susceptible wrestlers will become infected after a single match. In tournaments and wrestling camps, outbreaks can be epidemic, affecting up to 20% of all participants. Lesions usually occur on the lateral side of the neck, the side of the face, and the forearm, all areas in direct contact with the face of the infected wrestler (Fig. 19-5). Vesicles appear 4–11 days after exposure, often preceded by 24 h of malaise, sore throat, and fever. Ocular symptoms may occur. Lesions are frequently misdiagnosed as a bacterial folliculitis. Any wrestler with a confirmed history of orolabial herpes should be taking suppressive antiviral therapy during all periods of training and competition. Rugby players, especially forwards who participate in scrums; mixed-martial arts fighters; and even boxers are also at risk.



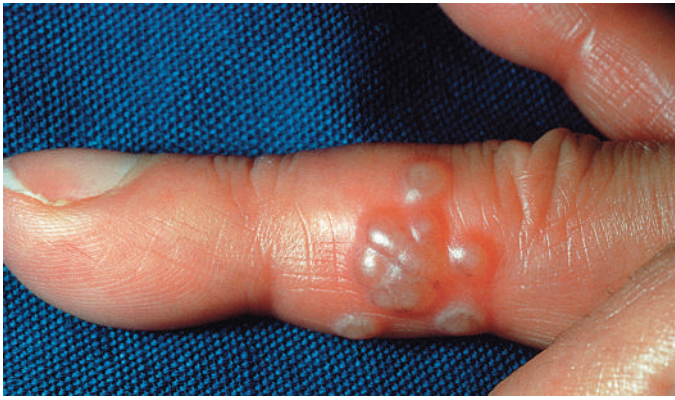

Fig. 19-6 Herpetic whitlow, classic grouped vesicles.

## Herpetic whitlow

Herpes simplex infection may occur infrequently on the fingers or periungually. Lesions begin with tenderness and erythema, usually of the lateral nailfold or on the palm. Deep-seated blisters develop 24–48 h after symptoms begin (Fig. 19-6). The blisters may be tiny, requiring careful inspection to detect them. Deep-seated lesions that appear unilocular may be mistaken for a paronychia or other inflammatory process. Lesions may progress to erosions or may heal without ever impairing epidermal integrity because of the thick stratum corneum in this location. Herpetic whitlow may simulate a felon. Swelling of the affected hand can occur. Lymphatic streaking and swelling of the epitrochlear or axillary lymph nodes may occur, mimicking a bacterial cellulitis. Repeated episodes of herpetic lymphangitis may lead to persistent lymphedema of the affected hand. Herpetic whitlow has become much less common among health care workers since the institution of universal precautions and glove use during contact with the oral mucosa. Currently, most cases are seen in persons with herpes elsewhere. Children may be infected while thumb sucking or nail biting during their initial herpes outbreak or by touching an infectious lesion of an adult. Herpetic whitlow is bimodal in distribution, with about 20% of cases occurring in children younger than 10 years and 55% of cases in adults between ages 20 and 40. Virtually all cases in children are caused by HSV-1, and there is often a coexisting herpetic gingivostomatitis. In adults, up to three quarters of cases are caused by HSV-2. Among adults, herpetic whitlow is twice as common in women. Herpetic whitlow in health care workers can be transmitted to patients. In patients whose oropharynx is exposed to the ungloved hands of health care workers with herpetic whitlow, 37% develop herpetic pharyngitis.

## Herpetic keratoconjunctivitis

Herpes simplex infection of the eye is a common cause of blindness in the United States. It occurs as a punctate or marginal keratitis or as a dendritic corneal ulcer, which may cause disciform keratitis and leave scars that impair vision. Topical corticosteroids in this situation may induce perforation of the cornea. Vesicles may appear on the lids, and preauricular nodes may be enlarged and tender. Recurrences are common. Ocular symptoms in any person with an initial outbreak of HSV could represent ocular HSV, and an ophthalmologic evaluation should be performed to exclude this possibility.

## Genital herpes

Genital herpes infection is usually caused by HSV-2. In the mid-1980s, the prevalence of genital herpes caused by HSV-1

began to increase because of changes in sexual habits and decreasing prevalence of orolabial HSV-1 infection in developed nations. In women under age 25, HSV-1 represents more than 50% of cases of genital herpes, whereas in women over 25 and in men of all ages, HSV-2 remains the most common cause of genital herpes. HSV-1 in the genital area is much less likely to recur. Only 20–50% of patients have a recurrence; when it does recur, the average patient experiences only about one outbreak per year.

Genital herpes is spread by skin-to-skin contact, usually during sexual activity. The incubation period averages 5 days. Active lesions of HSV-2 contain live virus and are infectious. Persons with recurrent genital herpes shed virus asymptotically between outbreaks (asymptomatic shedding). Even persons who are HSV-2 infected but have never had a clinical lesion (or symptoms) shed virus, so everyone who is HSV-2 infected is potentially infectious to a sexual partner. Asymptomatic shedding occurs simultaneously from several anatomic sites (penis, vagina, cervix, rectum) and can occur through normally appearing intact skin and mucosae. In addition, persons with HSV-2 infection may have lesions they do not recognize as being caused by HSV (unrecognized outbreak) or have recurrent lesions that do not cause symptoms (subclinical outbreak). Most transmission of genital herpes occurs during subclinical or unrecognized outbreaks, or while the infected person is shedding asymptotically.

The risk of transmission in monogamous couples, in which only one partner is infected, is about 5–10% annually, with women being at much greater risk than men for acquiring HSV-2 from their infected partner. Prior HSV-1 infection does not reduce the risk of being infected with HSV-2 but does make it more likely that initial infection will be asymptomatic. There is no strategy that absolutely prevents herpes transmission. All prevention strategies are more effective in reducing the risk of male-to-female transmission than female-to-male transmission. Condom use for all sexual exposures and avoiding sexual exposure when active lesions are present have been shown to be effective strategies, as has chronic suppressive therapy of the infected partner with valacyclovir, 500 mg/day.

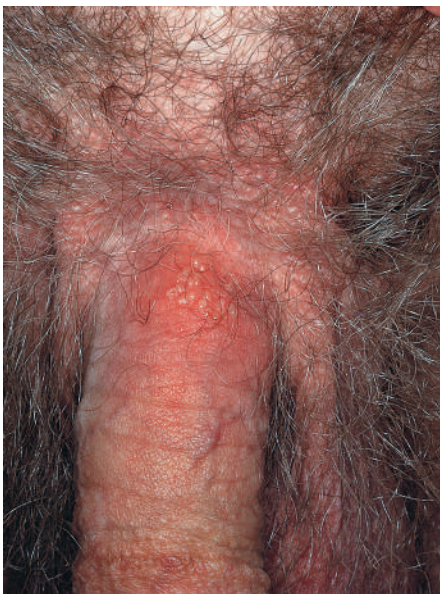The symptomatology during acquisition of infection with HSV-2 has a broad clinical spectrum, from totally asymptomatic to severe genital ulcer disease (erosive vulvovaginitis or proctitis). Only 57% of new HSV-2 infections are symptomatic. Clinically, the majority of symptomatic initial herpes lesions are classic, grouped blisters on an erythematous base. At times, the initial clinical episode is that of typical grouped blisters, but with a longer duration of 10–14 days. Although uncommon and representing 1% or fewer of new infections, severe first-episode genital herpes can be a significant systemic illness. Grouped blisters and erosions appear in the vagina, in the rectum, or on the penis, with continued development of new blisters over 7–14 days. Lesions are bilaterally symmetric and often extensive, and the inguinal lymph nodes can be enlarged bilaterally. Fever and flulike symptoms may be present, but in women the major complaint is vaginal pain and dysuria (herpetic vulvovaginitis). The whole illness may last 3 weeks or more. If the inoculation occurs in the rectal area, severe proctitis may occur from extensive erosions in the anal canal and on the rectal mucosa. The initial clinical episode of genital herpes is treated with oral acyclovir, 200 mg five times or 400 mg three times daily; famciclovir, 250 mg three times daily; or valacyclovir, 1000 mg twice daily, all for 7–10 days. It is clinically difficult to distinguish true initial (or primary) HSV-2 infection from a recurrence, so all patients with their initial clinical episode receive the same therapy. Only serology can determine whether the person is totally HSV naïve and experiencing a true primary episode, is partially immune from prior HSV-1 infection, or is already HSV-2 infected with first

clinical presentation actually a recurrence. In fact, 25% of “initial” clinical episodes of genital herpes are actually recurrences.

Virtually all persons infected with HSV-2 will have recurrences, even if the initial infection was subclinical or asymptomatic. HSV-2 infection results in recurrences in the genital area six times more frequently than HSV-1. Twenty percent of persons with HSV-2 infection are truly asymptomatic, never having had either an initial lesion or a recurrence. Twenty percent of patients have lesions they recognize as recurrent genital herpes, and 60% have clinical lesions that are culture positive for HSV-2, but that are unrecognized by the patient as being caused by genital herpes. This large group of persons with subclinical or unrecognized genital herpes are infectious, at least intermittently, and represent one factor in the increasing number of new HSV-2 infections.

Typical recurrent genital herpes begins with a prodrome of burning, itching, or tingling. Usually within 24 h, red papules appear at the site, progress to blisters filled with clear fluid over 24 h, form erosions over the next 24–36 h, and heal in another 2–3 days (Fig. 19-7). The average total duration of a typical outbreak of genital herpes is 7 days. Lesions are usually grouped blisters and evolve into coalescent grouped erosions, which characteristically have a scalloped border. Erosions or ulcerations from genital herpes are usually very tender and not indurated (unlike chancre of primary syphilis). Lesions tend to recur in the same anatomic region, although not at exactly the same site (unlike fixed drug eruption). Less classic clinical manifestations are tiny erosions or linear fissures on the genital skin. Lesions occur on the vulva, vagina, and cervical mucosa, as well as on the penile and vulval skin. The upper buttock is a common site for recurrent genital herpes in both men and women. Intraurethral genital herpes may present with dysuria and a clear penile discharge and is usually misdiagnosed as a more common, nongonococcal urethritis such as *Chlamydia* or *Ureaplasma* infection. Inguinal adenopathy may be present. Looking into the urethra and culturing any erosions will establish the diagnosis. Recurrent genital herpes usually heals without scarring.

The natural history of untreated recurrent genital herpes is not well studied. Over the first few years of infection, the frequency of recurrences usually stays the same. Over periods longer than 3–5 years, the frequency of outbreaks decreases in at least two thirds of patients treated with suppressive antiviral therapy.



**Fig. 19-7** Recurrent genital herpes.

Recurrent genital herpes is a problematic disease because of the associated social stigma. Because it is not curable, patients frequently have a significant emotional response when first diagnosed, including anger (at presumed source of infection), depression, guilt, and feelings of unworthiness. During the visit, the health care worker should ask about the patient's feelings and any psychological complications. This psychological component of genital herpes must be recognized, addressed directly with the patient, and managed properly for the therapy of recurrent genital herpes to be successful.

Management of recurrent genital herpes should be individualized. A careful history, including a sexual history, should be obtained. Examination should include seeing the patient during an active recurrence so that the infection can be confirmed. The diagnosis of recurrent genital herpes should not be made on clinical appearance alone because of the psychological impact of the diagnosis. The diagnosis is best confirmed by a viral culture or DFA examination, allowing for typing of the causative virus. If clinical lesions are not present, serology can determine if the patient is infected with HSV-2. If the patient is HSV-1 seropositive but HSV-2 seronegative, the possibility of genital HSV-1 disease cannot be excluded.

Treatment depends on several factors, including the frequency of recurrences, severity of recurrences, infection status of the sexual partner, and psychological impact of the infection on the patient. For patients with few or mildly symptomatic recurrences, treatment is often unnecessary. Counseling regarding transmission risk is required. In patients with severe but infrequent recurrences and in those with severe psychological complications, intermittent therapy may be useful. To be effective, intermittent therapy must be initiated at the earliest sign of an outbreak. The patient must be given the medication before the recurrence so that treatment can be started by the patient when the first symptoms appear. Intermittent therapy only reduces the duration of the average recurrence by about 1 day. However, it is a powerful tool in the patient who is totally overwhelmed by each outbreak. The treatment of recurrent genital herpes is acyclovir, 200 mg five times daily or 800 mg twice daily, or famciclovir, 125 mg twice daily, for 5 days. Shorter regimens that are equally effective include valacyclovir, 500 mg twice daily for 3 days; acyclovir, 800 mg three times daily for 2 days; or famciclovir, 1 g twice daily for 1 day.

For patients with frequent recurrences (>6–12 yearly), suppressive therapy may be more reasonable. Acyclovir, 400 mg twice daily, 200 mg three times daily, or 800 mg once daily, will suppress 85% of recurrences, and 20% of patients will be recurrence free during suppressive therapy. Valacyclovir, 500 mg/day (or 1000 mg/day for those with >10 recurrences/year), or famciclovir, 250 mg twice daily, is an equally effective alternative. Up to 5% of immunocompetent patients will have significant recurrences on these doses, and the dose of the antiviral may need to be increased. Chronic suppressive therapy reduces asymptomatic shedding by almost 95%. After 10 years of suppressive therapy, many patients can stop treatment, with substantial reduction in frequency of recurrences. Chronic suppressive therapy is safe, and laboratory monitoring is not required.

### Intrauterine and neonatal herpes simplex

Neonatal herpes infection occurs in 1:3000 to 1:20,000 live births, resulting in 1500–2200 cases of neonatal herpes annually in the United States. Eighty-five percent of neonatal herpes simplex infections occur at delivery; 5% occur in utero with intact membranes; and 10–15% occur from nonmaternal sources after delivery. In utero infection may result in fetal anomalies, including skin lesions and scars, limb hypoplasia,



microcephaly, microphthalmos, encephalitis, chorioretinitis, and intracerebral calcifications. It is either fatal or complicated by permanent neurologic sequelae.

Seventy percent of neonatal herpes simplex infections are caused by HSV-2. Neonatal HSV-1 infections are usually acquired postnatally through contact with a person with orolabial disease, but can also occur intrapartum if the mother is genitally infected with HSV-1. The clinical spectrum of perinatally acquired neonatal herpes can be divided into the following three forms:

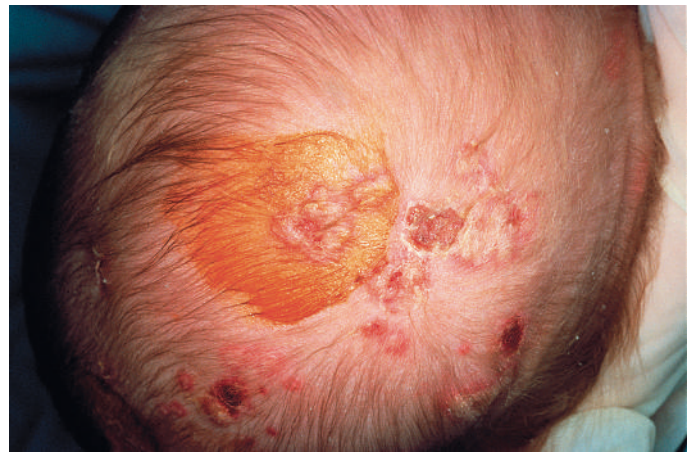1. Localized infection of the skin, eyes, and/or mouth (SEM)
2. Central nervous system (CNS) disease
3. Disseminated disease (encephalitis, hepatitis, pneumonia, and coagulopathy).

The pattern of involvement at presentation is important prognostically. With treatment, localized disease (skin, eyes, or mouth) is rarely fatal, whereas brain or disseminated disease is fatal in 15–50% of neonates so affected. In treated neonates, long-term sequelae occur in 10% of infants with localized disease. More than 50% of patients with CNS or disseminated neonatal herpes have neurologic disability.

In 68% of infected babies, skin vesicles are the presenting sign and are a good source for virus recovery. However, 39% of neonates with disseminated disease, 32% with CNS disease, and 17% with SEM disease never develop vesicular skin lesions. Because the incubation period may be as long as 3 weeks and averages about 1 week, skin lesions and symptoms may not appear until the child has been discharged from the hospital.

The diagnosis of neonatal herpes is confirmed by viral culture or preferably immediate DFA staining of material from skin or ocular lesions. CNS involvement is detected by PCR of the cerebrospinal fluid (CSF). PCR of the CSF is negative in 24% of neonatal CNS herpes infections, so pending other testing, empiric therapy may be required. Neonatal herpes infections are treated with IV acyclovir, 60 mg/kg/day for 14 days for SEM disease and for 21 days for CNS and disseminated disease.

Seventy percent of mothers of infants with neonatal herpes simplex are asymptomatic at delivery and have no history of genital herpes. Thus, extended history taking is of no value in predicting which pregnancies may be complicated by neonatal herpes. The most important predictors of infection appear to be the nature of the mother's infection at delivery (first episode vs. recurrent) and the presence of active lesions on the cervix, vagina, or vulvar area. The risk of infection for an infant delivered vaginally when the mother has active recurrent genital herpes infection is 2–5%, whereas it is 26–56% if the maternal infection at delivery is a first episode. One strategy to prevent neonatal HSV would be to prevent transmission of HSV to at-risk women during pregnancy, eliminating initial HSV episodes during pregnancy. To accomplish this, pregnant women and their partners would be tested to identify discordant couples for HSV-1 and HSV-2. If the woman is HSV-1 negative and the man is HSV-1 positive, orogenital contact during pregnancy should be avoided and a condom used for all episodes of sexual contact. Valacyclovir suppression of the infected male could also be considered but might have limited efficacy. If the woman is HSV-2 seronegative and her partner is HSV-2 seropositive, barrier protection for sexual contact during gestation is recommended, and valacyclovir suppression of the man could be considered. Abstinence from intercourse during the third trimester would also reduce the chances of an at-risk mother acquiring genital herpes that might first present perinatally. These strategies have not been tested and could not be guaranteed to prevent all cases of neonatal HSV. At a

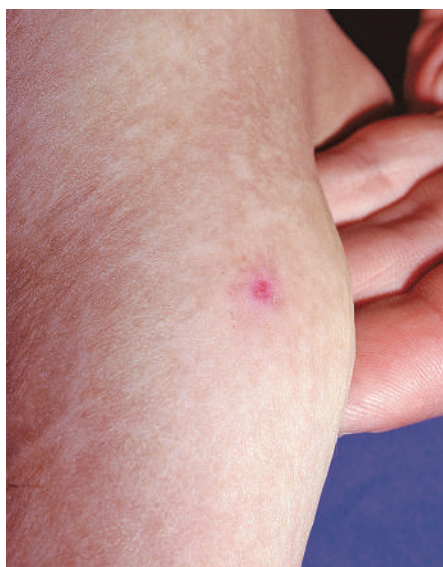

**Fig. 19-8** Neonatal herpes; a scalp monitor was associated with infection of this infant.

minimum, discordant couples should be informed of the increased risk to the fetus from the mother's acquisition of HSV during pregnancy.

The appropriate management of pregnancies complicated by genital herpes is complex and still controversial. Routine prenatal cultures are not recommended for women with recurrent genital herpes because they do not predict shedding at delivery. Such cultures may be of value in women with primary genital herpes during pregnancy. Scalp electrodes should be avoided in deliveries where cervical shedding of HSV is possible; they can increase the risk of neonatal infection by up to sevenfold (Fig. 19-8). Vacuum-assisted delivery also increases the relative risk of neonatal transmission of HSV 2–27 times. Genital HSV-1 infection appears to be much more frequently transmitted intrapartum than HSV-2. The current recommendation is still to perform cesarean section in the mother with active genital lesions or prodromal symptoms. This will reduce the risk of transmission of HSV to the infant from 8% to 1% for women who are culture positive from the cervix at delivery. However, this approach will not prevent all cases of neonatal herpes, is expensive, and has a high maternal morbidity (US\$2.5 million to prevent each case of neonatal herpes, 1580 excess cesarean sections for every poor-outcome case of neonatal HSV prevented, and 0.57 maternal deaths for every neonatal death prevented.) Because the risk of neonatal herpes is much greater in mothers who experience their initial episode during pregnancy, antiviral treatment of all initial episodes of genital HSV in pregnancy is recommended (except in the first month of gestation, when there may be an increased risk of spontaneous abortion). Standard acyclovir doses for initial episodes, 400 mg three times daily for 10 days, are recommended. This is especially true for all initial episodes in the third trimester. Chronic suppressive therapy with acyclovir has been used from 36 weeks' gestation to delivery in women with an initial episode of genital HSV during pregnancy, to reduce outbreaks and prevent the need for cesarean section. This approach has been recommended by the American College of Obstetrics and Gynecology and may also be considered for women with recurrent genital herpes.

The condition of extensive congenital erosions and vesicles healing with reticulate scarring may represent intrauterine neonatal herpes simplex (Fig. 19-9). The condition is rare because intrauterine HSV infection is rare and usually fatal. Probably only a few children survive to present later in life with the characteristic widespread reticulate scarring of the whole body. This may explain the associated CNS manifestations seen in many affected children. One author treated a child with this condition who developed infrequent wide-



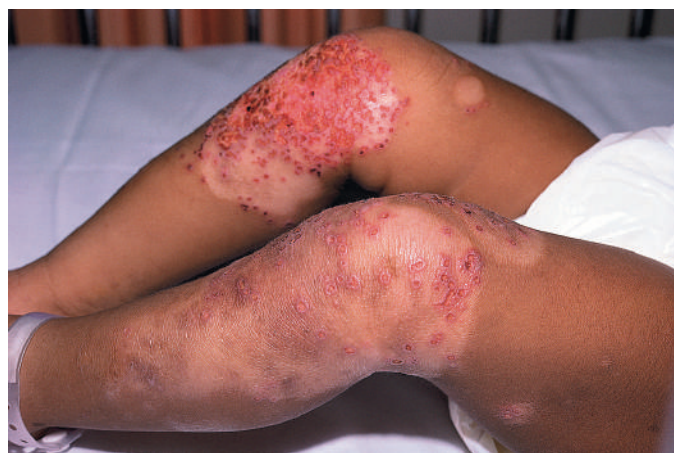**Fig. 19-9** Extensive congenital erosions and vesicles healing with reticulate scarring (erosion on arm was culture positive for HSV-1).

spread cutaneous blisters from which HSV could be cultured. Modern obstetric practices, which screen for herpes in pregnant women, and prophylactic treatment with acyclovir in the third trimester may prevent the condition, explaining the lack of recent cases.

### Eczema herpeticum (Kaposi varicelliform eruption)

Infection with herpesvirus in patients with atopic dermatitis (AD) may result in spread of herpes simplex throughout the eczematous areas, called eczema herpeticum (EH) or Kaposi varicelliform eruption (KVE). In a large series, development of EH was associated with more severe AD, higher IgE levels, elevated eosinophil count, food and environmental allergies (as defined by radioallergosorbent testing [RAST]), and onset of AD before age 5 years. EH patients are also more likely to have *Staphylococcus aureus* and molluscum contagiosum infections. All these features identify AD patients who have significant T-helper type 2 cell (Th2) shift of their immune system. The use of topical calcineurin inhibitors (TCIs) has been repeatedly associated with EH development. Bath or hot tub exposure has been reported as a risk factor. The Th2 shift of the immune system and TCIs are both associated with a decrease in antimicrobial peptides in the epidermis, an important defense against cutaneous HSV infection. Increased interleukin-10 (IL-10)-producing proinflammatory monocytes lead to local expansion of regulatory T cells and may contribute to the development of EH. HLA-B7 and local IL-25 expression are also associated with EH. In Japan, polymorphisms in the gene for IL-19 are associated with EH complicating TCI treatment. The repair of the epidermal lipid barrier with physiologic lipid mixtures reverses some of the negative effects of the TCIs and may reduce the risk of EH.

Cutaneous dissemination of HSV-1 or HSV-2 may also occur in severe seborrheic dermatitis, scabies, Darier's disease, benign familial pemphigus, pemphigus (foliaceus or vulgaris), pemphigoid, cutaneous T-cell lymphoma, Wiskott-Aldrich syndrome, allergic and photoallergic contact dermatitis, and burns. In its severest form, hundreds of umbilicated vesicles may be present at the onset, with fever and regional adenopathy. Although the cutaneous eruption is alarming, the disease is often self-limited in healthy individuals. Much milder cases are considerably more common and probably go unrecognized and untreated. They present as a few superficial erosions or even small papules (Fig. 19-10). In patients with systemic immunosuppression in addition to an impaired barrier, such



**Fig. 19-10** Eczema herpeticum, sudden appearance of uniform erosions, accentuated in areas of active dermatitis.

as patients with pemphigus and cutaneous T-cell lymphoma, KVE can be fatal, usually from *S. aureus* septicemia, but also from visceral dissemination of herpes simplex.

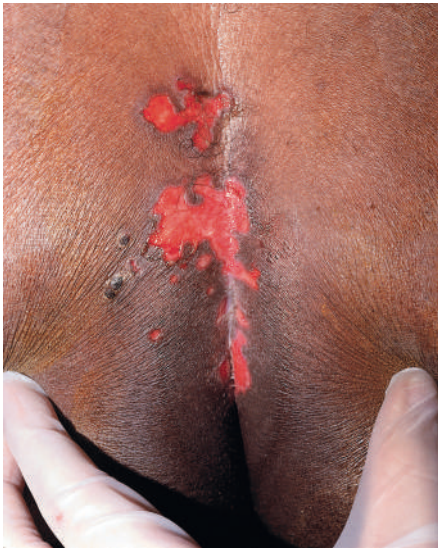Psoriasis patients treated with immunosuppressives may develop KVE as well, although this is less common. It usually occurs in the setting of worsening disease or erythroderma. Patients present with erosive lesions in the axilla and erosions of the psoriatic plaques. Lesions extend cephalad to caudad, and the development of large, ulcerated, painful plaques can occur. The lesions are often coinfecting with bacteria and yeast. Cultures positive for other pathogens do *not* exclude the diagnosis of KVE, and specific viral culture, DFA, and biopsy should be done if diagnosis of KVE is suspected. Given the limited toxicity of systemic antiviral therapy, treatment should be started immediately, pending the return of laboratory confirmation. Depending on the severity of the disease, either IV or oral antiviral therapy should be given for KVE patients.

### Immunocompromised patients

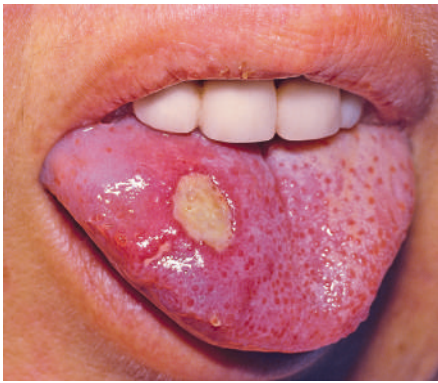In patients with suppression of the cell-mediated immune system by cytotoxic agents, corticosteroids, or congenital or acquired immunodeficiency, primary and recurrent cases of herpes simplex are more severe, persistent, and symptomatic and more resistant to therapy. In some settings, such as in bone marrow transplant recipients, the risk of severe reactivation is so high that prophylactic systemic antivirals are administered. In immunosuppressed patients, any erosive mucocutaneous lesion should be considered to be herpes simplex until proved otherwise, especially lesions in the genital and orolabial regions. Atypical morphologies are also seen. HSV reactivation is common with institution of effective antiretroviral therapy and can be part of the immune reconstitution inflammatory syndrome (IRIS). After 3 months, HSV shedding decreases to pretreatment levels. Oral antivirals prevent this reactivation and can be considered in the HIV-infected patient who will receive antiretroviral therapy.

Typically, lesions appear as erosions or crusts (Fig. 19-11). The early vesicular lesions may be transient or never seen. The three clinical hallmarks of HSV infection are pain, an active vesicular border, and a scalloped periphery. Untreated erosive lesions may gradually expand, but they may also remain fixed and even become papular or vegetative, mimicking a wart or granulation tissue. In the oral mucosa, numerous erosions may be seen, involving all surfaces, unlike the hard, keratinized surfaces usually involved by recurrent oral herpes simplex in the immunocompetent host. The tongue may be affected with geometric fissures on the central dorsal surface (Fig. 19-12).





**Fig. 19-11** Herpes simplex, HSV-2, in patient receiving chronic prednisone therapy.



**Fig. 19-12** Immunocompromised patient with tongue ulcer and fissures secondary to HSV.

Symptomatic stomatitis associated with cancer chemotherapy may be caused or exacerbated by HSV infection. Herpetic whitlow presents as a painful paronychia that is initially vesicular and involves the lateral or proximal nailfolds. Untreated, it may lead to loss of the nail plate and ulceration of a large portion of the digit.

Despite the frequent and severe skin infections caused by HSV in the immunosuppressed patient, visceral dissemination is unusual. Extension of oral HSV into the esophagus or trachea may develop spontaneously or as a complication of intubation through an infected oropharynx. Ocular involvement can occur from direct inoculation, and if lesions are present around the eye, careful ophthalmologic evaluation is required.

In an immunosuppressed host, most herpetic lesions are ulcerative and not vesicular. Viral cultures taken from the ulcer margin are positive. DFA testing is specific, rapid, and helpful in immunosuppressed hosts who require expeditious therapeutic decision making. At times, these tests are negative, but a skin biopsy will show typical herpetic changes in the epithelium adjacent to the ulceration. If an ulceration does not respond to treatment in 48 h and cultures are negative, a biopsy is recommended, since it may be the only technique that demonstrates the associated herpesvirus infection.

Therapy often can be instituted on clinical grounds pending confirmatory tests. Acyclovir, 400 mg orally three times daily; famciclovir, 500 mg twice daily; or valacyclovir, 1 g twice daily, all for a minimum of 5–10 days, is used. Therapy should continue until lesions are essentially healed. In severe infection, or in the hospitalized patient with moderate disease, IV acyclovir (5 mg/kg) can be given initially to control the

disease. In patients with acquired immunodeficiency syndrome (AIDS) and those with persistent immunosuppression, consideration should be given to chronic suppressive therapy with acyclovir, 400–800 mg two or three times daily, or valacyclovir or famciclovir, 500 mg twice daily.

In the immunosuppressed host (but not in the immunocompetent host), long-term treatment with acyclovir and its analogs, or treatment of large herpetic ulcerations, may be complicated by the development of acyclovir resistance. This resistance may be caused by selection of acyclovir-resistant wild-type virus, which is present in large numbers on the surface of such large herpes lesions. In the immunocompetent host, these acyclovir-resistant mutants are few in number and eradicated by the host's immune system. The immunosuppressed host has much more HSV in the lesions, and the host's immune system is ineffective in killing the virus. These acyclovir-resistant viral strains may be difficult to culture and may be identified only by skin biopsy or PCR of the ulceration. Antiviral resistance is suspected if maximum oral doses of acyclovir, valacyclovir, or famciclovir do not lead to improvement. IV acyclovir, except if given by constant infusion, will also invariably fail in such patients. Resistance to one drug is associated with resistance to all three of these drugs, usually from loss of the viral thymidine kinase. HSV isolates can be tested for sensitivity to acyclovir and some other antivirals. The standard treatment of acyclovir-resistant herpes simplex is IV foscarnet. In patients intolerant of or resistant to foscarnet, IV cidofovir may be used. Smaller lesions can sometimes be treated with topical trifluorothymidine (Viroptic) with or without topical or intralesional interferon (IFN) alpha, or topical or intralesional cidofovir. Imiquimod may be of benefit in healing these lesions, perhaps through activation of cystatin A. Destruction of small lesions by desiccation, followed by the previous therapies, may also be curative. If an HIV-infected patient with previous acyclovir-resistant genital herpes has a recurrence, half will be acyclovir sensitive, so a trial of standard antivirals is acceptable. If an AIDS patient has a nonhealing genital ulcer that harbors HSV, there may be dual infection with cytomegalovirus, and only treatment with an agent active against both HSV and CMV will lead to improvement.

## Histopathology

The vesicles of herpes simplex are intraepidermal. The affected epidermis and adjacent inflamed dermis are infiltrated with leukocytes. Ballooning degeneration of the epidermal cells produces acantholysis. The most characteristic feature is the presence of multinucleated giant cells, which tend to mold together, forming a crude jigsaw puzzle appearance. The steel-gray color of the nucleus and peripheral condensation of the nucleoplasm may be clues to HSV infection, even if multinucleate cells are not seen. IP stains can detect HSV infection even in paraffin-fixed tissue, allowing the diagnosis to be absolutely confirmed from histologic material.

## Differential diagnosis

Herpes labialis most often must be differentiated from impetigo. Herpetic lesions are composed of groups of tense, small vesicles, whereas in bullous impetigo, the blisters are unilocular, occur at the periphery of a crust, and are flaccid. A mixed infection is not unusual and should especially be suspected in immunosuppressed hosts and when lesions are present in the typical herpetic regions around the mouth. Herpes zoster presents with clusters of lesions along a dermatome, but early on, if the number of zoster lesions is limited, it can be relatively indistinguishable from herpes simplex. In general, herpes zoster will be more painful and over 24 hours will progress to

involve more of the affected dermatome. DFA testing can rapidly make this distinction.

A genital herpes lesion, especially on the glans or corona, can be mistaken for a syphilitic chancre or chancroid. Darkfield examination, multiplex PCR, and cultures for *Haemophilus ducreyi* on selective media will aid in making the diagnosis, as will diagnostic tests for HSV (Tzanck, culture, or DFA). Combined infections occur in up to 20% of patients, so finding a single pathogen may not complete the diagnostic evaluation.

Herpetic gingivostomatitis is often difficult to differentiate from aphthosis, streptococcal infections, diphtheria, coxsackievirus infections, and oral erythema multiforme. Aphthae tend to occur mostly on the buccal and labial mucosae. They usually form shallow, grayish erosions, generally surrounded by a prominent ring of hyperemia. Aphthae typically occur on nonattached mucosa, whereas recurrent herpes of the oral cavity primarily affects the attached gingiva and palate.

**Aga IE, Hollier LM:** Managing genital herpes infections in pregnancy.

Womens Health (Lond) 2009; 5:165.

**Bal A, et al:** Fulminant hepatitis due to father-to-newborn transmission of herpes simplex virus type 1. Open Virol J 2013; 7:96.

**Beck LA, et al:** Phenotype of atopic dermatitis subjects with a history of eczema herpeticum. J Allergy Clin Immunol 2009; 124:260.

**Bernstein DI, et al:** Epidemiology, clinical presentation, and antibody response to primary infection with herpes simplex virus type 1 and type 2 in young women. Clin Infect Dis 2013; 56:344.

**Bisaccia E, Scarborough D:** Herpes simplex virus prophylaxis with famciclovir in patients undergoing aesthetic facial CO<sub>2</sub> laser resurfacing. Cutis 2003; 72:327.

**Bradley H, et al:** Seroprevalence of herpes simplex virus types 1 and 2—United States, 1999–2010. J Infect Dis 2014; 209:325.

**Brown ZA, et al:** Effect of serologic status and cesarean delivery on transmission rates of herpes simplex virus from mother to infant. JAMA 2003; 289:203.

**Butler DF, et al:** Acquired lymphedema of the hand due to herpes simplex virus type 2. Arch Dermatol 1999; 135:1125.

**Cárdenas AM, et al:** Development and optimization of a real-time PCR assay for detection of herpes simplex and varicella-zoster viruses in skin and mucosal lesions by use of the BD Max Open System. J Clin Microbiol 2014; 52:4375.

**Centers for Disease Control and Prevention:** Neonatal herpes simplex virus infection following Jewish ritual circumcisions that included direct orogenital suction—New York City, 2000–2011. MMWR 2012; 61:405.

**Chen CY, Ballard RC:** The molecular diagnosis of sexually transmitted genital ulcer disease. Methods Mol Biol 2012; 903:103.

**Chia KY, et al:** A less known dermatological emergency. Ann Acad Med Singapore 2012; 41:366.

**Chosidow O, et al:** Valacyclovir as a single dose during prodrome of herpes facialis: a pilot randomized double-blind clinical trial. Br J Dermatol 2003; 148:142.

**Corey L, et al:** Once-daily valacyclovir to reduce the risk of transmission of genital herpes. N Engl J Med 2004; 354:11.

**Dickson N, et al:** HSV-2 incidence by sex over four age periods to age 38 in a birth cohort. Sex Transm Infect 2014; 90:243.

**Elangovan S, et al:** Hospital-based emergency department visits with herpetic gingivostomatitis in the United States. Oral Surg Oral Med Oral Pathol Oral Radiol 2012; 113:505.

**Fatahzadeh M, Schwartz RA:** Human herpes simplex virus infections: epidemiology, pathogenesis, symptomatology, diagnosis, and management. J Am Acad Dermatol 2007; 57:737.

**Garceau R, et al:** Herpes simplex virus type 1 is the leading cause of genital herpes in New Brunswick. Can J Infect Dis Med Microbiol 2012; 23:15.

**Garcia-Medina JJ, et al:** Herpetic blepharitis and inhaled budesonide. Ophthalmology 2011; 118:2520.e5.

**Gazzola R, et al:** Herpes virus outbreaks after dermal hyaluronic acid filler injections. Aesthet Surg J 2012; 32:770.

**Gupta AK, et al:** Extensive congenital erosions and vesicles healing with reticulate scarring. J Am Acad Dermatol 1987; 17:369.

**Hirokawa D, et al:** Treatment of recalcitrant herpes simplex virus with topical imiquimod. Cutis 2011; 88:276.

**Hoff NP, Gerber PA:** Herpetic whitlow. CMAJ 2012; 184:E924.

**Hollier LM, et al:** Third trimester antiviral prophylaxis for preventing maternal genital herpes simplex virus (HSV) recurrences and neonatal infection. Cochrane Database Syst Rev 2008; 1:CD004946.

**Johansson AB, et al:** Lower-limb hypoplasia due to intrauterine infection with herpes simplex virus type 2: possible confusion with intrauterine varicella-zoster syndrome. Clin Infect Dis 2004; 38:e57.

**Jones CA, et al:** Antiviral agents for treatment of herpes simplex virus infection in neonates. Cochrane Database Syst Rev 2009; 3:CD004206.

**Kan Y, et al:** Imiquimod suppresses propagation of herpes simplex virus 1 by upregulation of cystatin A via the adenosine receptor A<sub>1</sub> pathway. J Virol 2012; 86:10338.

**Karpathios T, et al:** HSV-2 meningitis disseminated from a herpetic whitlow. Paediatr Int Child Health 2012; 32:121.

**Kim BE, et al:** IL-25 enhances HSV-1 replication by inhibiting filaggrin expression, and acts synergistically with Th2 cytokines to enhance HSV-1 replication. J Invest Dermatol 2013; 133:2678.

**Kim M, et al:** Topical calcineurin inhibitors compromise stratum corneum integrity, epidermal permeability and antimicrobial barrier function. Exp Dermatol 2010; 19:501.

**Kimberlin DW:** The scarlet H. J Infect Dis 2014; 209:315.

**Kohelet D, et al:** Herpes simplex virus infection after vacuum-assisted vaginally delivered infants of asymptomatic mothers. J Perinatol 2004; 24:147.

**Kortekangas-Savolainen O, et al:** Epidemiology of genital herpes simplex virus type 1 and 2 infections in southwestern Finland during a 10-year period (2003–2012). Sex Transm Dis 2014; 41:268.

**Kotzbauer D, et al:** Clinical and laboratory characteristics of central nervous system herpes simplex virus infection in neonates and young infants. Pediatr Infect Dis J 2014; 33:1187.

**Lanzafame M, et al:** Unusual, rapidly growing ulcerative genital mass due to herpes simplex virus in a human immunodeficiency virus–infected woman. Br J Dermatol 2003; 149:193.

**Lautenschlager S, Eichmann A:** Urethritis: an underestimated clinical variant of genital herpes in men? J Am Acad Dermatol 2002; 46:307.

**Leung DY:** Why is eczema herpeticum unexpectedly rare? Antiviral Res 2013; 98:153.

**Lubbe J, et al:** Adults with atopic dermatitis and herpes simplex and topical therapy with tacrolimus: what kind of prevention? Arch Dermatol 2003; 139:670.

**Mathais RA, et al:** Atopic dermatitis complicated by eczema herpeticum is associated with HLA B7 and reduced interferon- $\gamma$ -producing CD8+ T cells. Br J Dermatol 2013; 169:700.

**McKeough MB, Spruance SL:** Comparison of new topical treatments for herpes labialis: efficacy of penciclovir cream, acyclovir cream, and *n*-docosanol cream against experimental cutaneous herpes simplex virus type 1 infection. Arch Dermatol 2001; 137:1153.

**Money D, et al:** Guideline for the management of herpes simplex virus in pregnancy. J Obstet Gynaecol 2008; 208:518.

**Muluneh B, et al:** Successful clearance of cutaneous acyclovir-resistant, foscarnet-refractory herpes virus lesions with topical cidofovir in an allogeneic hematopoietic stem cell transplant patient. J Oncol Pharm Pract 2013; 19:181.

**Osawa K, et al:** Relationship between Kaposi's varicelliform eruption in Japanese patients with atopic dermatitis treated with tacrolimus ointment and genetic polymorphisms in the IL-19 gene promoter region. J Dermatol 2007; 34:531.

**Pichler M, et al:** Premature newborns with fatal intrauterine herpes simplex virus-1 infection: first report of twins and review of the literature. J Eur Acad Dermatol Venereol 2014 [Epub ahead of print.]

**Robinson JL, et al:** Prevention, recognition and management of neonatal HSV infections. Expert Rev Anti Infect Ther 2012; 10:675.

**Rojek NW, Norton SA:** Diagnosis of neonatal infection with herpes simplex virus. JAMA 2014; 311:527.

**Sacks SL:** Efficacy of docosanol. J Am Acad Dermatol 2003; 49:558.

**Santmyre-Rosenberger BR, et al:** Psoriasis herpeticum: three cases of Kaposi's varicelliform eruption in psoriasis. J Am Acad Dermatol 2005; 53:52.

**Schoenfeld J, et al:** Cutaneous co-infected cytomegalovirus and herpes simplex virus perigenital ulcers in human immunodeficiency virus patients. J Clin Aesthet Dermatol 2013; 6:41.



**Seang S, et al:** Long-term follow-up of HIV-infected patients once diagnosed with acyclovir-resistant herpes simplex virus infection. *Int J STD AIDS* 2014; 25:676.

**Shenoy R, et al:** Eczema herpeticum in a wrestler. *Clin J Sport Med* 2014 [Epub ahead of print.]

**Spruance SL, McKeough MB:** Combination treatment with famciclovir and a topical corticosteroid gel versus famciclovir alone for experimental ultraviolet radiation-induced herpes simplex labialis: a pilot study. *J Infect Dis* 2000; 181:1906.

**Spruance SL, et al:** Single-dose, patient-initiated famciclovir: a randomized, double-blind, placebo-controlled trial for episodic treatment of herpes labialis. *J Am Acad Dermatol* 2006; 55:47.

**Takahashi R, et al:** Pathological role of regulatory T cells in the initiation and maintenance of eczema herpeticum lesions. *J Immunol* 2014; 192:969.

**Tobian AA, et al:** Reactivation of herpes simplex virus type 2 after initiation of antiretroviral therapy. *J Infect Dis* 2013; 208:839.

**Tuokko H, et al:** Herpes simplex virus type 1 genital herpes in young women: current trend in Northern Finland. *Sex Transm Infect* 2014; 90:160.

**Walker D, et al:** JAAD Grand Rounds quiz. A painful eruption in a woman with Darier disease. *J Am Acad Dermatol* 2012; 67:1089.

**Wanat KA, et al:** Intralesional cidofovir for treating extensive genital verrucous herpes simplex virus infection. *JAMA Dermatol* 2013; 149:811.

**Whitley RJ:** Changing epidemiology of herpes simplex virus infections. *Clin Infect Dis* 2013; 56:352.

**Wilson EK, et al:** Cutaneous infections in wrestlers. *Sports Health* 2013; 5:423.

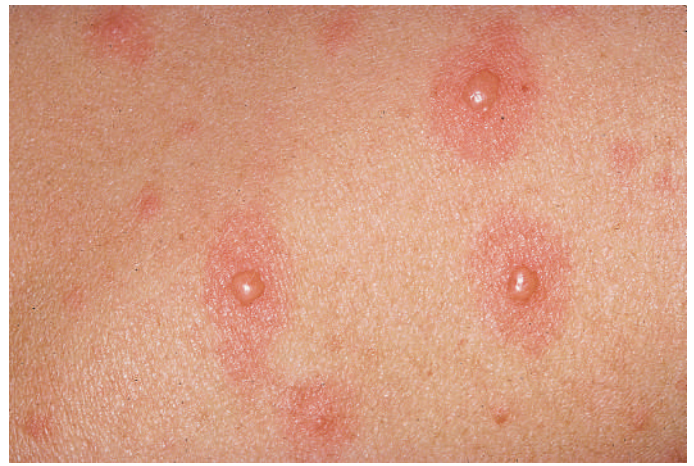**Wollenberg A, et al:** Predisposing factors and clinical features of eczema herpeticum: a retrospective analysis of 100 cases. *J Am Acad Dermatol* 2003; 49:198.

**Yossepowitch O, et al:** Penile herpes simplex virus type 1 infection presenting two and a half years after Jewish ritual circumcision of an infant. *Sex Transm Dis* 2013; 40:516.

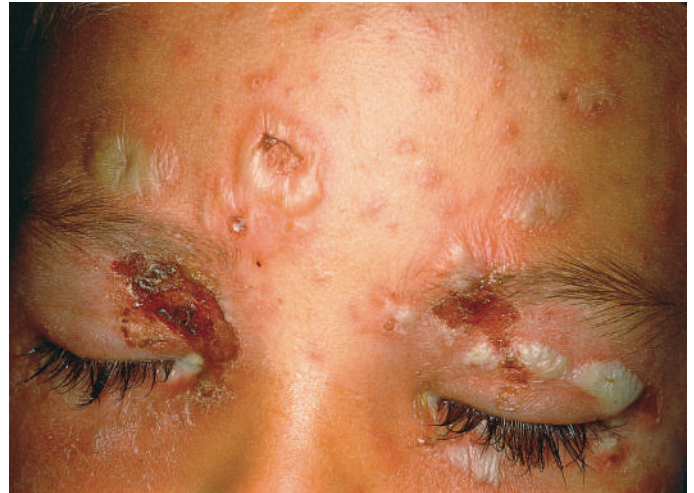## Varicella

Varicella, commonly known as chickenpox, is the primary infection with the varicella-zoster virus. In temperate regions, 90% of cases occur in children younger than 10 years, with the highest age-specific incidence in ages 1–4 in unvaccinated children. More than 90% of adults in temperate countries have evidence of prior infection and are “immune” to varicella. In tropical countries, however, varicella tends to be a disease of teenagers, and only 60% of adults are “immune” serologically. Outbreaks among non-U.S.-born crew members have occurred on cruise ships.

The incubation period of VZV is 10–21 days, usually 14–15 days. Transmission is by the respiratory route and less often by direct contact with the lesions. A susceptible person may develop varicella after exposure to the lesions of herpes zoster. Infected persons are infectious from 5 days before the eruption appears and are most infectious 1–2 days before the rash appears. Infectivity usually ceases 5–6 days after the eruption appears. There is an initial viral replication in the nasopharynx and conjunctiva, followed by viremia and infection of the reticuloendothelial system (liver, spleen) between days 4 and 6. A secondary viremia occurs at days 11–20, resulting in infection of the epidermis and the appearance of the characteristic skin lesions. Low-grade fever, malaise, and headache are usually present but slight. The severity of the disease is age dependent, with adults having more severe disease and a greater risk of visceral disease. In healthy children, mortality from varicella is 1.4 in 100,000 cases; in adults, 30.9 in 100,000 cases. Pregnant women have five times greater risk of an adverse outcome. As with most viral infections, immunosuppression may worsen the course of the disease. Lifelong immunity follows varicella, and second episodes of “varicella” indicate either immunosuppression or another viral infection such as coxsackievirus.



**Fig. 19-13** Varicella.



**Fig. 19-14** Varicella with bullous impetigo as a complication.

Varicella is characterized by a vesicular eruption consisting of delicate “teardrop” vesicles on an erythematous base (Fig. 19-13). The eruption starts with faint macules that develop rapidly into vesicles within 24 h. Successive fresh crops of vesicles appear for a few days, mainly on the trunk, face, and oral mucosa. Initially, the exanthem may be limited to sun-exposed areas, the diaper area of infants, or sites of inflammation. The vesicles quickly become pustular and umbilicated, then crusted. Since the lesions appear in crops, lesions of various stages are present at the same time, a useful clue to the diagnosis. Lesions tend not to scar, but larger lesions and those that become secondarily infected may heal with a characteristic round, depressed scar.

Secondary bacterial infection with *Staphylococcus aureus* or a streptococcus is the most common complication of varicella (Fig. 19-14). Rarely, it may be complicated by osteomyelitis, other deep-seated infections, or septicemia. Other complications are rarer. Pneumonia is uncommon in normal children but is seen in 1 in 400 adults with varicella. It may be bacterial or caused by VZV, a difficult differential diagnosis. Cerebellar ataxia and encephalitis are the most common neurologic complications. Asymptomatic myocarditis and hepatitis may occur in children with varicella, but rarely are significant and resolve spontaneously with no treatment. Reye syndrome, with hepatitis and acute encephalopathy, is associated with the use of aspirin to treat the symptoms of varicella. Aspirin is absolutely contraindicated in patients with varicella. Any child with varicella and severe vomiting should be referred immediately to

exclude Reye syndrome. Symptomatic thrombocytopenia is a rare manifestation of varicella, which can occur either with the exanthem or several weeks after. Purpura fulminans, a form of disseminated intravascular coagulation associated with low levels of proteins C and S, may complicate varicella.

The diagnosis of varicella is easily made clinically. Tzanck smear from a vesicle will usually show characteristic multinucleate giant cells. If needed, the most useful clinical test is DFA, which is rapid and will both confirm the infection and type the virus. VZV grows poorly and slowly in the laboratory, so viral culture is rarely indicated.

## Treatment

Both immunocompetent children and adults with varicella benefit from acyclovir therapy if started early, within 24 h of the eruption's appearance. Therapy does not seem to alter the development of adequate immunity to reinfection. Because the complications of varicella are infrequent in children, routine treatment is not recommended; therapeutic decisions are made on a case-by-case basis. Acyclovir therapy appears mainly to benefit secondary cases within a household, which tend to be more severe than the index case. In this setting, therapy can be instituted earlier. Therapy does not return children to school sooner, however, and the impact on parental workdays missed is not known. The dose of acyclovir is 20 mg/kg, maximum 800 mg per dose, four times daily for 5 days. Aspirin and other salicylates should not be used as antipyretics in varicella because their use increases the risk of Reye syndrome. Topical antipruritic lotions, oatmeal baths, dressing the patient in light, cool clothing, and keeping the environment cool may all relieve some of the symptomatology. Children living in warm homes and kept very warm with clothing have anecdotally been observed to have more numerous skin lesions. Children with AD, Darier's disease, congenital ichthyosiform erythroderma, diabetes, cystic fibrosis, conditions requiring chronic salicylate or steroid therapy, and inborn errors of metabolism should be treated with acyclovir, because they may have more complications or exacerbations of their underlying illness with varicella.

Varicella is more severe and complications are more common in adults. Between 5% and 14% of adults will have pulmonary involvement. Smokers and those with preexisting lung disease (but not asthma) are at increased risk. The pneumonitis can progress rapidly and be fatal. Adults with varicella and at least one other risk factor should be evaluated with physical examination, pulse oximetry, and chest radiography. Antiviral treatment is recommended in all adolescents and adults (13 and older) with varicella. The dose is 800 mg four or five times daily for 5 days. Severe, fulminant cutaneous disease and visceral complications are treated with IV acyclovir, 10 mg/kg every 8 h, adjusted for creatinine clearance. If the patient is hospitalized for therapy, strict isolation is required. Patients with varicella should not be admitted to wards with immunocompromised hosts or to pediatric wards, but rather are best placed on wards with healthy patients recovering from acute trauma.

## Pregnant women and neonates

Maternal VZV infection may result in severe illness in the mother, and if the infection occurs before 28 weeks of gestation, and especially before 20 weeks, a risk of infection of the fetus (congenital varicella syndrome). In one study, 4 of 31 women with varicella in pregnancy developed varicella pneumonia. The risk for spontaneous abortion by 20 weeks is 3%; in an additional 0.7% of pregnancies, fetal death occurs after 20 weeks. The risk of preterm labor, as reported in various

studies, has varied from no increased risk to a threefold increase. Severe varicella and varicella pneumonia or disseminated disease in pregnancy should be treated with IV acyclovir. All varicella in pregnancy should be treated with oral acyclovir, 800 mg five times daily for 7 days, except perhaps during the first month, when a specialist should be consulted. In all women past 35 weeks of gestation or with increased risk of premature labor, admission and IV acyclovir, 10 mg/kg three times daily, should be recommended. The patient should be evaluated for pneumonia, renal function should be carefully monitored, and the patient should be switched to oral therapy once lesions stop appearing (usually in 48–72 h).

Varicella-zoster immune globulin (VZIG) should not be given once the pregnant woman has developed varicella. VZIG should be given for significant exposures (see next section) within the first 72–96 h to ameliorate maternal varicella and prevent complications. Its use should be limited to seronegative women because of its cost and the high rate of asymptomatic infection in U.S. patients. The lack of a history of prior varicella is associated with seronegativity in only 20% or fewer of the U.S. population.

Congenital varicella syndrome is characterized by a series of anomalies, including hypoplastic limbs (usually unilateral and lower extremity), cutaneous scars, and ocular and CNS disease. This may not be identified until months after infection. Repeated sonographic examination can be used to monitor at-risk pregnancies. Female fetuses are affected more often than males. The overall risk for this syndrome is about 0.4%; the highest risk, about 2%, is from maternal varicella between weeks 13 and 20. Infection of the fetus in utero may result in zoster occurring postnatally, often in the first 2 years of life. This occurs in about 1% of varicella-complicated pregnancies, and the risk for this complication is greatest in varicella occurring in weeks 25–36 of gestation. The value of VZIG in preventing or modifying fetal complications of maternal varicella is unknown. In one study, however, of 97 patients with varicella in pregnancy treated with VZIG, none had complications of congenital varicella syndrome or infantile zoster, suggesting some efficacy for VZIG. Although apparently safe in pregnancy, acyclovir's efficacy in preventing fetal complications of maternal varicella is unknown.

If the mother develops varicella between 5 days before and 2 days after delivery, neonatal varicella can occur and may be severe because of inadequate transplacental delivery of anti-varicella antibody. These neonates develop varicella at 5–10 days of age. In such cases, administration of VZIG is warranted, and IV acyclovir therapy should be considered.

## Varicella vaccine

Live attenuated viral vaccine for varicella is a currently recommended childhood immunization. Two doses are now recommended, one between age 12 and 15 months and the second at 4–6 years. This double-vaccination schedule is recommended since epidemics of varicella still occurred in children ages 9–11 in well-immunized communities, suggesting a waning of immunity by this age. Complications of varicella vaccination are uncommon. A mild skin eruption from which virus usually cannot be isolated, occurring locally at the injection site within 2 days or generalized 1–3 weeks after immunization, occurs in 6% of children. Many of the breakthrough cases in vaccinated children are mild, and many reported skin lesions were not vesicular (see [Modified varicella-like syndrome](#)). Prevention of severe varicella is virtually 100%, even when the vaccine is given within 36 h of exposure. Immunized children with no detectable antibody also have reduced severity of varicella after exposure. Secondary complications of varicella, including scarring, are virtually eliminated by vaccination.



Household exposure of immunosuppressed children to recently immunized siblings does not appear to pose a great risk. Children whose leukemia is in remission are also protected by the vaccine but may require three doses. Leukemic children still receiving chemotherapy have a complication rate from vaccination (usually a varicella-like eruption) approaching 50%. They may require acyclovir therapy. Unprotected close contacts develop varicella 15% of the time. In leukemic children, adequate immunization results in complete immunity in some and partial immunity in the others, protecting them from severe varicella. Immunization also reduces the attack rate for zoster in leukemic children.

### Modified varicella-like syndrome

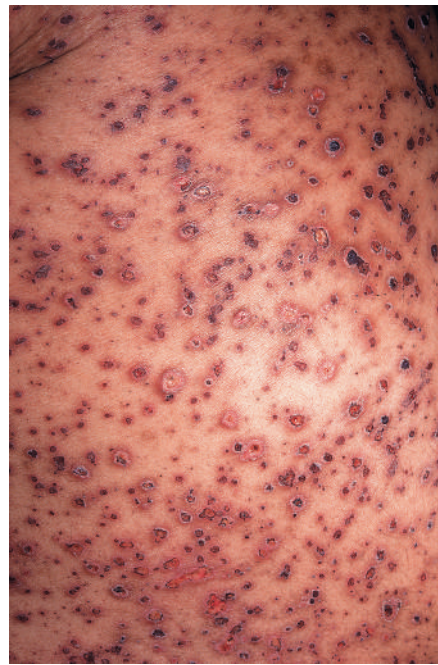
Children immunized with live attenuated varicella vaccine may develop varicella of reduced severity on exposure to natural varicella. This has been called modified varicella-like syndrome (MVLS). The frequency of MVLS is between 0% and 2.7% per year, and children with lower antibody titers are more likely to develop the illness. MVLS occurs an average of 15 days after exposure to varicella and consists primarily of macules and papules with relatively few vesicles. The average number of lesions is about 35–50, compared with natural varicella, which usually has about 300 lesions. The majority of patients are afebrile and the illness is mild, lasting fewer than 5 days on average.

### Immunocompromised patients

Varicella cases can be extremely severe and even fatal in immunosuppressed patients, especially in individuals with impaired cell-mediated immunity. Before effective antiviral therapy, almost one third of children with cancer developed complications of varicella and 7% died. In this setting, varicella pneumonia, hepatitis, and encephalitis are common. Prior varicella does not always protect the immunosuppressed host from multiple episodes. The skin lesions in the immunosuppressed host are usually identical to varicella in the healthy host; however, the number of lesions may be numerous (Fig. 19-15). In an immunosuppressed patient, the lesions more frequently become necrotic, and ulceration may occur. Even if the lesions are few, the size of the lesion may be large, up to several centimeters, and necrosis of the full thickness of the dermis may occur. In patients with HIV infection, varicella may be severe and fatal. Atypical cases of a few scattered lesions without a dermatomal distribution usually represent reactivation disease with dissemination. Chronic varicella may complicate HIV infection, resulting in ulcerative (ecthymatous) or hyperkeratotic (verruccous) lesions. These patterns of infection may be associated with acyclovir resistance.

The degree of immunosuppression likely to result in severe varicella has been debated. There are case reports of severe and even fatal varicella in otherwise healthy children given short courses of oral corticosteroids or even using only inhaled corticosteroids. In a case-control study, however, corticosteroid use did not appear to be a risk factor for development of severe varicella. In the United Kingdom (UK), any patient receiving or having received systemic corticosteroids in the prior 3 months, regardless of dose, is considered at increased risk for severe varicella. Inhaled steroids are not considered an indication for prophylactic VZIG or antiviral treatment. A "high-risk" or significant exposure is defined as follows:

1. Household contact (i.e., living in same house as a patient with chickenpox or zoster)
2. Face-to-face contact for at least 5 min with a patient who has chickenpox



**Fig. 19-15** Varicella in a patient with advanced Hodgkin disease.

3. Contact indoors for more than 1 h with a patient who has chickenpox or herpes zoster or, in a hospital setting, a patient with chickenpox or herpes zoster in an adjacent bed or the same open ward

Immunosuppressed children with no prior history of varicella and a high-risk exposure should be treated with VZIG as soon as possible after exposure (within 96 h). Preengraftment bone marrow transplant patients should receive the same therapy. VZIG treatment does not reduce the frequency of infection, but it does reduce the severity of infection and complications. The value of prophylactic antivirals is unknown. Parents of immunosuppressed children and their physicians should be aware that severe disease can occur and counseled to return immediately after significant exposure or if varicella develops.

An unusual variant of recurrent varicella is seen in elderly patients with a history of varicella in childhood, who have a malignancy of the bone marrow and are receiving chemotherapy. They develop a mild illness with 10–40 widespread lesions and usually no systemic findings. This type of recurrent varicella tends to relapse. It is different from typical varicella because all the lesions are in a single stage of development, and thus it could be easily confused with smallpox.

Ideally, management of varicella in the immunocompromised patient would involve prevention through varicella vaccination before immunosuppression. Vaccination is safe if the person is more than 1 year from induction chemotherapy, if chemotherapy is halted about the time of vaccination, and if lymphocyte count is higher than  $700/\text{mm}^3$ . IV acyclovir, 10 mg/kg three times daily (or 500 mg/m<sup>2</sup> in children) is given as soon as the diagnosis of varicella is suspected. IV therapy is continued until 2 days after all new vesicles have stopped. Oral antivirals are continued for a minimum of 10 days of treatment. VZIG is of no proven benefit once clinical disease has developed, but may be given if the patient has life-threatening disease and is not responding to IV acyclovir.

In HIV-infected adults, treatment is individualized. Persons with typical varicella should be evaluated for the presence of pneumonia or hepatitis. Valacyclovir, 1 g three times daily; famciclovir, 500 mg three times daily; or acyclovir, 800 mg every 4 h, may be used if no visceral complications are present. Valacyclovir and famciclovir may be preferable to acyclovir

because of their enhanced oral bioavailability. Visceral disease mandates IV therapy. If the response to oral antiviral agents is not rapid, IV acyclovir therapy should be instituted. The optimal duration of oral antiviral treatment is unknown but must be at least until all lesions are crusted and have no elevated or active borders. Given the safety and efficacy of oral antivirals, treatment duration of at least 10 days and perhaps longer should be considered. Most cases of chronic or acyclovir-resistant VZV infection are associated with initial inadequate oral doses of acyclovir (too short in duration, too low a dose, or in patients with gastrointestinal [GI] disease, in whom reduced GI absorption may be associated with inadequate blood levels of acyclovir). Patients with atypical disseminated disease must be treated aggressively until all lesions resolve. The diagnosis of acyclovir-resistant VZV infection may be difficult. Acyclovir-resistant VZV strains may be difficult to culture, and sensitivity testing is still not standardized or readily available for VZV. Acyclovir-resistant varicella is treated with foscarnet or, in nonresponsive patients, with cidofovir.

**Bate J, et al:** Varicella postexposure prophylaxis in children with cancer: urgent need for a randomized controlled trial. *Arch Dis Child* 2012; 97:853.

**Baxter R, et al:** Long-term effectiveness of varicella vaccine: a 14-year prospective cohort study. *Pediatrics* 2013; 131:e1389.

**Centers for Disease Control and Prevention:** Evolution of varicella surveillance—selected states, 2000–2010. *MMWR* 2012; 61:609.

**Centers for Disease Control and Prevention:** FDA approval of an extended period for administering VariZIG for postexposure prophylaxis of varicella. *MMWR* 2012; 61:212.

**Clements DA:** Modified varicella-like syndrome. *Infect Dis Clin North Am* 1996; 10:617.

**Cramer EJ, et al:** Management and control of varicella on cruise ships: a collaborative approach to promoting public health. *J Travel Med* 2012; 19:226.

**Creed E, et al:** Varicella zoster vaccines. *Dermatol Ther* 2009; 22:143.

**Feeney S, et al:** Varicella infection and the impact of late entry into the Irish healthcare system. *J Infect Public Health* 2012; 3:106.

**Ferrada MA:** A man with skin lesions and ataxia: a case of disseminated varicella zoster. *Int J Infect Dis* 2014 [Epub ahead of print.]

**Flatt A, Breuer J:** Varicella vaccines. *Br Med Bull* 2012; 103:115.

**Gershon AA, Gershon MD:** Pathogenesis and current approaches to control of varicella-zoster virus infections. *Clin Microbiol Rev* 2013; 26:728.

**Gnann JW:** Varicella-zoster virus: prevention through vaccination. *Clin Obstet Gynecol* 2012; 55:560.

**Kao CM, et al:** Child and adolescent immunizations: selected review of recent U.S. recommendations and literature. *Curr Opin Pediatr* 2014; 26:383.

**Kasper WJ, et al:** Fatal varicella after a single course of corticosteroids. *Pediatr Infect Dis* 1990; 9:729.

**Lamont RF, et al:** Varicella-zoster virus (chickenpox) infection in pregnancy. *Br J Obstet Gynecol* 2011; 118:1155.

**Levin MJ:** Varicella-zoster virus and virus DNA in the blood and oropharynx of people with latent or active varicella-zoster virus infections. *J Clin Virol* 2014; 61:487.

**Marin M, et al:** Varicella prevention in the United States: a review of successes and challenges. *Pediatrics* 2008; 122:e744.

**Patel H, et al:** Recent corticosteroid use and the risk of complicated varicella in otherwise immunocompetent children. *Arch Pediatr Adolesc Med* 1996; 150:409.

**Posfay-Barbe KM, et al:** Varicella-zoster immunization in pediatric liver transplant recipients: safe and immunogenic. *Am J Transplant* 2012; 12:2974.

**Sharma CM, Sharma D:** A classical case of neonatal varicella. *J Clin Neonatol* 2013; 2:200.

**Shinoh M, et al:** Updated data on effective and safe immunizations with live-attenuated vaccines for children after living donor liver transplantation. *Vaccine* 2014 [Epub ahead of print.]

**Souty C, et al:** Vaccination against varicella as post-exposure prophylaxis in adults: a quantitative assessment. *Vaccine* 2014 [Epub ahead of print.]

**Sugiura K, et al:** Varicella zoster virus-associated generalized pustular psoriasis in a baby with heterozygous IL36RN mutation. *J Am Acad Dermatol* 2014; 71:e216.

**Tongsong T, et al:** Prenatal sonographic diagnosis of congenital varicella syndrome. *J Clin Ultrasound* 2012; 40:176.

**Tunbridge AJ, et al:** Chickenpox in adults: clinical management. *J Infect* 2008; 57:95.

**Wilson DA, et al:** Should varicella-zoster virus culture be eliminated? A comparison of direct immunofluorescence antigen detection, culture, and PCR with a historical review. *J Clin Microbiol* 2012; 50:4120.

**Zampogna JC, Flowers FP:** Persistent verrucous varicella as the initial manifestation of HIV infection. *J Am Acad Dermatol* 2001; 44:391.

**Zhang X, et al:** The epidemiology and risk factors for breakthrough varicella in Beijing Fengtai district. *Vaccine* 2012; 30:6186.

## Zoster (shingles, herpes zoster)

Zoster is caused by reactivation of VZV. Following primary infection or vaccination, VZV remains latent in the sensory dorsal root ganglion cells. The virus begins to replicate at some later time, traveling down the sensory nerve into the skin. Immunosuppression, including use of tumor necrosis factor inhibitors, and age-related deficiency of cell-mediated immunity are the two most common causes of zoster. A family history of zoster is associated with an increased risk of developing zoster, suggesting a genetic risk component. Patients on hemodialysis and those with comorbidities have increased risk of zoster, possibly related to the association between zoster risk and cholesterol level. Statin use also slightly increases the risk for zoster. Zoster patients are more likely to be subsequently diagnosed with a malignancy, especially a lymphoid malignancy. The risk is greatest in the first 180 days but persists for several years.

The incidence of zoster increases with age. Under age 45, the annual incidence is less than 1 in 1000 persons. Among patients older than 75, the rate is more than four times greater. For white persons older than 80, the lifetime risk of developing zoster is 10–30%. Overall, about one in three unvaccinated persons will develop herpes zoster. For unknown reasons, being nonwhite reduces the risk for herpes zoster, with African Americans four times less likely to develop zoster. Immunosuppression, especially hematologic malignancy and HIV infection, dramatically increases the risk for zoster. In HIV-infected patients, annual incidence is 30 in 1000 persons, or an annual risk of 3%. With the universal use of varicella vaccination and decrease in pediatric and adolescent varicella cases, older persons will no longer have periodic boosts of the anti-VZV immune activity. This could result in an increase in the incidence of zoster.

Herpes zoster classically occurs unilaterally within the distribution of a cranial or spinal sensory nerve, often with some overflow into the dermatomes above and below. The dermatomes most frequently affected are the thoracic (55%), cranial (20%, with the trigeminal nerve being the most common single nerve involved), lumbar (15%), and sacral (5%). The cutaneous eruption is frequently preceded by one to several days of pain in the affected area, although the pain may appear simultaneously or even following the skin eruption, or the eruption may be painless. The eruption initially presents as papules and plaques of erythema in the dermatome (Fig. 19-16). Within hours the plaques develop blisters. Lesions continue to appear for several days. The eruption may have few lesions or reach total confluence in the dermatome. Lesions may become hemorrhagic, necrotic, or bullous. Rarely, the patient may have pain, but no skin lesions (zoster sine herpette). Pain severity correlates with extent of the skin lesions, and elderly persons tend to have severer pain. In patients under age 30, the pain may be minimal. Scattered lesions can occur outside the dermatome, usually fewer than 20. In the typical case, new



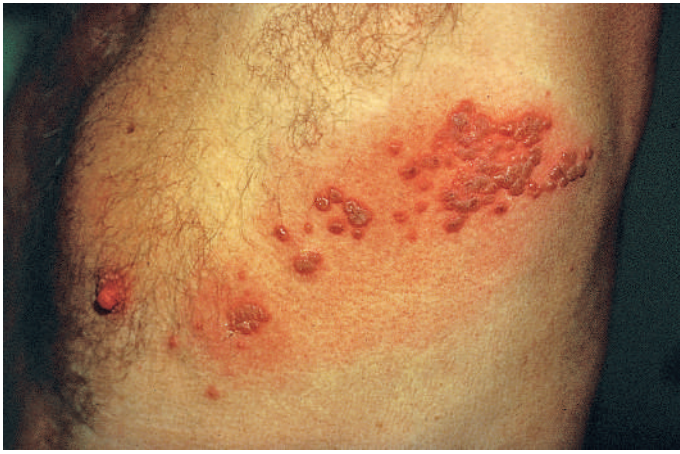

Fig. 19-16 Herpes zoster, classic dermatomal distribution.

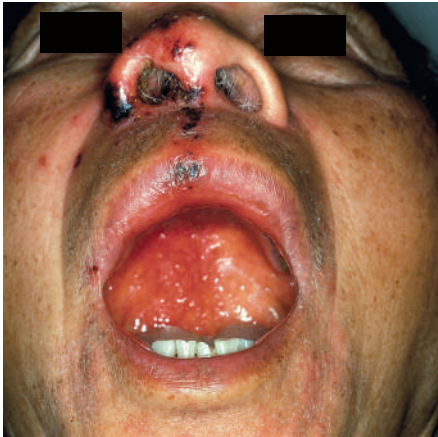

Fig. 19-17 Oral zoster.

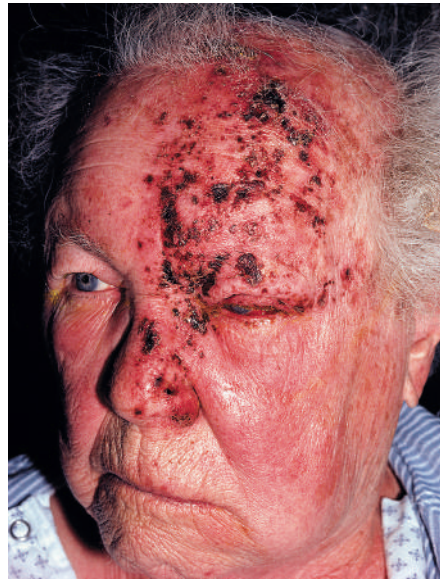

Fig. 19-18 Herpes zoster, involvement of the V1 dermatome.

vesicles appear for 1–5 days, become pustular, crust, and heal. The total duration of the eruption depends on three factors: patient age, severity of eruption, and presence of underlying immunosuppression. In younger patients, the total duration is 2–3 weeks, whereas in elderly patients, the cutaneous lesions of zoster may require 6 weeks or more to heal. Scarring is more common in elderly and immunosuppressed patients. Scarring also correlates with the severity of the initial eruption. Lesions may develop on the mucous membranes within the mouth in zoster of the maxillary division (Fig. 19-17) or mandibular division of the facial nerve, or in the vagina with zoster in the S2 or S3 dermatome. Zoster may appear in recent surgical scars and may follow injections of botulinum toxin.

Zoster may rarely be seen in children under age 1 year. This can result from intrauterine exposure to VZV or exposure to VZV during the first few months of life. The maternal antibodies still present result in muted expression of varicella—subclinical or very mild disease. The immaturity of the infant's immune system results in poor immune response to the infection, allowing for early relapse in the form of zoster.

### Disseminated herpes zoster

Disseminated herpes zoster is defined as more than 20 lesions outside the affected dermatome. It occurs chiefly in older or debilitated individuals, especially in patients with lymphoreticular malignancy or AIDS. Low levels of serum antibody against VZV are a highly significant risk factor in predicting dissemination of disease. The dermatomal lesions are sometimes hemorrhagic or gangrenous. The outlying vesicles or bullae, which are usually not grouped, resemble varicella and

are often umbilicated and may be hemorrhagic. Visceral dissemination to the lungs and CNS may occur in the patient with disseminated zoster. Disseminated zoster requires careful evaluation and systemic antiviral therapy. Initially, IV acyclovir is given, which may be changed to an oral antiviral agent once visceral involvement has been excluded and the patient has received at least 2–3 days of IV therapy.

### Ophthalmic zoster

In herpes zoster ophthalmicus, the ophthalmic division of the fifth cranial nerve is involved. If the external division of the nasociliary branch is affected, with vesicles on the side and tip of the nose (Hutchinson's sign), the eye is involved 76% of the time, compared with 34% when it is not involved (Fig. 19-18). Vesicles on the lid margin are virtually always associated with ocular involvement. In any case, the patient with ophthalmic zoster should be seen by an ophthalmologist. Systemic antiviral therapy should be started immediately, pending ophthalmologic evaluation. Ocular involvement is most often in the form of uveitis (92%) and keratitis (50%). Less common but more severe complications include glaucoma, optic neuritis, encephalitis, hemiplegia, and acute retinal necrosis. These complications are reduced from 50% of patients to 20–30% with effective antiviral therapy. Unlike the cutaneous lesions, ocular lesions of zoster and their complications tend to recur, sometimes as long as 10 years after the zoster episode.

### Other complications

Motor nerve neuropathy occurs in about 3% of patients with zoster and is three times more common if zoster is associated with underlying malignancy. About 75% of patients slowly recover, leaving 25% with some residual motor deficit. Thoracic zoster may be associated with motor neuropathy of the abdominal muscles resulting in a bulge on the flank or abdomen, called a "postherpetic pseudotumor." If the sacral dermatome S3, or less often S2 or S4, is involved, urinary hesitancy or actual urinary retention may occur. Hematuria and pyuria may also be present. The prognosis is good for complete recovery. Similarly, pseudo-obstruction, colonic spasm, dilation, obstipation, constipation, and reduced anal sphincter tone can occur with thoracic (T6–T12), lumbar, or sacral zoster. Recovery is complete. Maxillary and mandibular alveolar bone necrosis may occur an average of 30 days after zoster of

the maxillary or mandibular branches of the trigeminal nerve. Limited or widespread loss of teeth may result.

Ramsay Hunt syndrome results from involvement of the facial and auditory nerves by VZV. Herpetic inflammation of the geniculate ganglion is thought to be the cause of this syndrome. The presenting features include zoster of the external ear or tympanic membrane; herpes auricularis with ipsilateral facial paralysis; or herpes auricularis, facial paralysis, and auditory symptoms. Auditory symptoms include mild to severe tinnitus, deafness, vertigo, nausea and vomiting, and nystagmus.

Herpes zoster can be associated with delayed complications, many of which are caused by vasculopathies affecting the CNS or even the peripheral arteries. Delayed contralateral hemiparesis, simulating cerebrovascular accident (stroke), is a rare but serious complication of herpes zoster that occurs weeks to months (mean 7 weeks) after an episode of zoster affecting the first branch of the trigeminal nerve. By direct extension along the intracranial branches of the trigeminal nerve, VZV gains access to the CNS and infects the cerebral arteries. Patients present with headache and hemiplegia. Arteriography is diagnostic, demonstrating thrombosis of the anterior or middle cerebral artery. This form of vasculopathy can also occur following varicella and may be the cause of up to one third of ischemic strokes in children. The recognized vasculopathic complications of VZV have been expanded to include changes in mental status, aphasia, ataxia, hemisensory loss, and both hemianopia and monocular visual loss. Monocular vision loss can occur up to 6 months following zoster. Aneurysm, subarachnoid or cerebral hemorrhage, carotid dissection, and even peripheral vascular disease are other recognized forms of VZV vasculopathy. The vasculopathy may be multifocal and involve both large and small arteries. In more than one third of cases, VZV vasculopathy occurs without a rash. Magnetic resonance imaging (MRI) is virtually always abnormal. The diagnosis is confirmed by VZV PCR and anti-VZV IgG antibody testing of the CSF. Since this is caused by active viral replication in the vessels, the treatment is IV acyclovir, 10–15 mg/kg three times daily for a minimum of 14 days. In some patients, months of oral antivirals are given if symptoms are slow to resolve. A short burst of systemic corticosteroids is also given in some cases.

## Treatment

Middle-age and elderly patients with herpes zoster are urged to restrict their physical activities or even stay home in bed for a few days. Bed rest may be of paramount importance in the prevention of neuralgia. Younger patients may usually continue with their customary activities. Local applications of heat, as with an electric heating pad or a hot water bottle, are recommended. Simple local application of gentle pressure with the hand or with an abdominal binder often gives great relief.

Antiviral therapy is the cornerstone in the management of herpes zoster. Because antiviral therapy does not reduce the rate of zoster-associated pain, clinicians may underappreciate the tremendous benefit that antivirals provide. The main benefit of therapy is reduction of the duration and severity of zoster-associated pain. Therefore, treatment in immunocompetent patients is indicated for those at highest risk for persistent pain—those over age 50. It is also recommended to treat all patients with painful or severe zoster, ophthalmic zoster, Ramsay Hunt syndrome, immunosuppression, cutaneous or visceral dissemination, and motor nerve involvement. In the most severe cases, especially in ophthalmic zoster and disseminated zoster, initial IV therapy may be considered. Therapy should be started as soon as the diagnosis is suspected, pending laboratory confirmation. It is preferable for

treatment to be instituted within the first 3 or 4 days. In immunocompetent patients, the efficacy of starting treatment beyond this time is unknown. Treatment leads to more rapid resolution of the skin lesions and, most importantly, substantially decreases the duration of zoster-associated pain. Valacyclovir, 1000 mg, and famciclovir, 500 mg, may be given three times daily. These agents are as effective as or superior to acyclovir, 800 mg five times daily, probably because of better absorption and the higher blood levels achieved. Valacyclovir and famciclovir are as safe as acyclovir and, if not contraindicated, are preferred. Side-by-side trials have demonstrated valacyclovir and famciclovir to be of similar efficacy, but one study from Japan showed famciclovir to result in more rapid reduction in acute zoster pain.

In the immunocompetent host, a total of 7 days of treatment has been as effective as 21 days. Valacyclovir and famciclovir must be dose-adjusted in patients with renal impairment. In an elderly patient, if the renal status is unknown, the valacyclovir and famciclovir may be started at twice-daily dosing (which is almost as effective), pending evaluation of renal function, or acyclovir can be used. For patients with renal failure (creatinine clearance <25 mL/min), acyclovir is preferable. In the patient with known or acquired renal failure, acyclovir neurotoxicity can occur from IV acyclovir or oral valacyclovir therapy. This can present in the acute setting as hallucinations or with prolonged elevated blood levels, disorientation, dizziness, loss of decorum, incoherence, photophobia, difficulty speaking, delirium, confusion, agitation, and death delusion. Because acyclovir can reduce renal function, the patient's baseline renal function may have been normal, but high doses of acyclovir may have reduced renal function, leading to neurotoxic acyclovir levels.

In the immunosuppressed patient, an antiviral agent should always be given because of the increased risk of dissemination and zoster-associated complications. The doses are identical to those used in immunocompetent hosts. Immunosuppressed patients with ophthalmic zoster, disseminated zoster, or Ramsay Hunt syndrome and those failing oral therapy should receive IV acyclovir, 10 mg/kg three times daily, adjusted for renal function.

Since some of the pain during acute zoster (acute zoster neuritis) may have an inflammatory component, corticosteroids have been used during the acute episode. The use of corticosteroids in this setting is controversial. In selected older patients, corticosteroid use is associated with better quality-of-life measures, reduction in time to uninterrupted sleep, quicker return to usual activities, and reduced analgesic use. A tapering dose of systemic corticosteroids, starting at about 1 mg/kg and lasting 10–14 days, is adequate to achieve these benefits. Systemic corticosteroids should not be used in immunosuppressed patients or when there is a contraindication. All factors considered, the benefits of corticosteroid therapy during acute zoster appear to outweigh the risks in treatment-eligible patients. Reduction in postherpetic neuralgia by corticosteroids has never been documented despite multiple studies, but this is also true of antiviral therapy, which reduces the severity and duration but not the prevalence of postherpetic neuralgia.

## Zoster-associated pain (postherpetic neuralgia)

Pain is the most troublesome symptom of zoster; 84% of patients over age 50 will have pain preceding the eruption, and 89% will have pain with the eruption. Various terminologies are used to classify the pain. The simplest approach is to refer to all pain occurring immediately before or after zoster as "zoster-associated pain" (ZAP). Another classification system separates acute pain (within first 30 days), subacute pain (30–120 days), and chronic pain (>120 days).



Two different mechanisms are proposed to cause ZAP: sensitization and deafferentation. Nociceptors (sensory nerves mediating pain) become sensitized after injury, resulting in ongoing discharge and hyperexcitability (peripheral sensitization). Prolonged discharge of the nociceptor enhances the dorsal horn neurons to afferent stimuli and expands the dorsal horn neuron's receptive field (central sensitization), leading to allodynia and hyperalgesia. In addition, neural destruction causes spontaneous activity in deafferented central neurons, generating constant pain. The spinal terminals of mechanoreceptors may contact receptors formerly occupied by C fibers, leading to hyperalgesia and allodynia. The loss of function or death of dorsal horn neurons, which have an inhibitory effect on adjacent neurons, contributes to increased activity transmitted up the spinal cord. The central sensitization is initially temporary (self-limited) but may become permanent.

The quality of the pain associated with herpes zoster varies, but three basic types have been described: the constant, monotonous, usually burning or deep, aching pain; the shooting, lancinating (neuritic) pain; and triggered pain. The last is usually allodynia (pain with normal nonpainful stimuli such as light touch) or hyperalgesia (severe pain produced by a stimulus normally producing mild pain). The character and quality of acute zoster pain are identical to the pain that persists after the skin lesions have healed, although these may be mediated by different mechanisms.

The rate of resolution of pain after herpes zoster is reported over a wide range. The following data are from a prospective study and do not represent selected patients, as are recruited in drug trials for herpes zoster. The tendency to have persistent pain is age dependent, occurring for longer than 1 month in only 2% of persons under age 40. Fifty percent of persons over age 60 and 75% of those over 70 continue to have pain beyond 1 month. Although the natural history is for gradual improvement in persons over age 70, 25% have some pain at 3 months and 10% have pain at 1 year. Severe pain lasting longer than 1 year is uncommon, but 8% of persons over 60 have mild pain and 2% still have moderate pain at 1 year.

The ZAP, especially that of long duration, is very difficult to manage. Adequate medication should be provided to control the pain from the first visit. Once established, neuropathic pain is difficult to control. Every effort should be made to prevent neuronal damage. In addition, chronic pain may lead to depression, complicating pain management. Patients with persistent, moderate to severe pain may benefit from referral to a pain clinic. With this background, the importance of early and adequate antiviral therapy and pain control cannot be overemphasized.

Oral antiviral agents are recommended in all patients over age 50 with pain who still have blisters, even if the drugs are not given within the first 96 h of the eruption. Oral analgesia should be maximized using acetaminophen, nonsteroidal anti-inflammatory drugs (NSAIDs), and opiate analgesia as required. The combination of oral gabapentin and valacyclovir was reported to reduce postherpetic neuralgia (PHN), but there was no control group in this study, and gabapentin alone has not been shown to be highly effective in other zoster trials. Capsaicin applied topically every few hours may reduce pain, but the application itself may cause burning, and the benefits are modest. Local anesthetics, such as 10% lidocaine in gel form, 5% lidocaine-prilocaine, or lidocaine patches (Lidoderm), may acutely reduce pain. These topical measures may provide some short-term analgesic effect, but do not appear to have any long-term benefit in reducing the severity or prevalence of ZAP. Patients with PHN have lower vitamin C levels than controls, and vitamin C supplementation intravenously (not orally) has been associated with PHN reduction. Sublesional anesthesia, epidural blocks (with or without

ketamine), and sympathetic blocks with and without corticosteroids are reported in large series (but rarely studied in controlled trials) to provide acute relief of pain. Although the benefit of nerve blocks in preventing or treating persistent ZAP remains to be proved, these are a reasonable consideration in the acute setting if the patient is having severe pain (unable to eat or sleep) and if oral therapy has yet to be effective. Nerve blocks may also be used in patients who have failed the standard therapies listed next. A transcutaneous electrical nerve stimulation (TENS) unit may be beneficial for persistent neuralgia. Botulinum toxin, 100 U, spread out over the affected area in a checkerboard or fanlike pattern with 5 U per route, has dramatically improved PHN in anecdotal reports.

Despite this vast array of medication options, PHN is typically difficult to treat for two reasons. First, the recommended medications are simply often not effective. Second, in elderly patients, who are most severely affected by PHN, these medications have significant and often intolerable side effects, limiting the dose that can be prescribed. If multiple agents are combined to reduce the toxicity of any one agent, their side effects overlap (sedation, depression, constipation) and drug-drug interactions may occur, limiting combination treatment options.

Three classes of medication are used as standard therapies to manage ZAP and PHN: tricyclic antidepressants (TCAs), antiseizure medications, and long-acting opiates. If opiate analgesia is required, it should be provided by a long-acting agent, and the duration of treatment should be limited and the patient transitioned to another class of agent. Constipation is a major side effect in elderly persons. During painful zoster, these patients ingest less fluid and fiber, enhancing the constipating effects of the opiates. Bulk laxatives should be recommended. Tramadol is an option for acute pain control, but drug interactions with the TCAs must be monitored. TCAs such as amitriptyline (or nortriptyline) and desipramine are well tested and documented as effective for the management of PHN and are considered first-line agents. The TCAs are dosed at 25 mg/night (or 10 mg for those over age 65–70). The dose is increased by the same amount nightly until pain control is achieved or the maximum dose is reached. The ultimate dose is between 25 and 100 mg in a single nightly dose. The early use of amitriptyline was able to reduce the pain prevalence at 6 months, suggesting that early intervention is optimal. Venlafaxine (Effexor) may be used in patients who do not tolerate TCAs, at a starting dose of 25 mg/night, gradually titrated upward as required. Gabapentin (Neurontin) and pregabalin (Lyrica) have been documented as helping to reduce zoster-associated pain. The starting dose of gabapentin is usually 300 mg three times daily, escalating up to 3600 mg/day. A minimum total dose of 600 mg or more is needed to obtain optimal benefit. Pregabalin has improved pharmacokinetics and is given at 300 mg or 600 mg daily, depending on renal function, with better absorption and steadier blood levels. The anticonvulsants diphenylhydantoin, carbamazepine, and valproate; neuroleptics such as chlorprothixene and phenothiazines; and H<sub>2</sub> blockers such as cimetidine cannot be recommended because they have been not been studied critically, many are poorly tolerated by elderly patients, and some are associated with significant side effects. If the patient fails to respond to local measures, oral analgesics (including opiates), TCAs, gabapentin, and venlafaxine, referral to a pain center is recommended.

### Immunosuppressed patients

The use of tumor necrosis factor (TNF) inhibitors increases the risk of development of zoster by 1.6 times (or 60%). This is

significant enough that prophylactic immunization should be considered, if not contraindicated, before a patient starts a TNF inhibitor. VZV immunization of patients already receiving TNF inhibition who have had prior varicella has not led to increased zoster or adverse events, and it has reduced the rate of zoster with anti-TNF therapy. This strategy should be considered on a case-by-case basis, perhaps in consultation with an infectious disease specialist.

Patients with malignancy, especially Hodgkin disease and leukemia, are five times more likely to develop zoster than their age-matched counterparts. Patients who also have a higher incidence of zoster include those with deficient immune systems, such as individuals who are immunosuppressed for organ transplantation or by connective tissue disease, or by the agents used to treat these conditions, especially corticosteroids, chemotherapeutic agents, cyclosporine, sirolimus, and tacrolimus. After stem cell transplantation for leukemia, up to 68% of patients will develop herpes zoster in the first 12 months (median 5 months). The cumulative incidence of VZV reactivation in this group may exceed 80% in the first 3 years. Since zoster is 30 times more common in HIV-infected persons, the zoster patient under age 50 should be questioned about HIV risk factors. In pediatric patients with HIV infection and in other immunosuppressed children, zoster may rapidly follow primary varicella.

The clinical appearance of zoster in the immunosuppressed patient is usually identical to typical zoster, but the lesions may be more ulcerative and necrotic and may scar more severely. Dermatomal zoster may appear, progress to involve the dermatome, and persist without resolution. Multidermatomal zoster is more common in immunosuppressed patients, including the rare variant "herpes zoster duplex bilateralis," with involvement of two different contralateral dermatomes. Visceral dissemination and fatal outcome are extremely rare in immunosuppressed patients (about 0.3%), but cutaneous dissemination is possible, occurring in 12% of cancer patients, especially those with hematologic malignancies. In bone marrow transplant patients with zoster, 25% develop disseminated zoster and 10–15%, visceral dissemination. Disseminated zoster may be associated with the syndrome of inappropriate antidiuretic hormone secretion (SIADH) and present with hyponatremia, abdominal pain, and ileus. This later presentation has been reported in stem cell transplant patients. Despite treatment with IV acyclovir, the SIADH can be fatal. In this patient, the number of skin lesions may be small, and the lesions resemble "papules" rather than vesicles. Mortality in patients with zoster who have undergone bone marrow transplantation is 5%. VZV IgG serostatus is determined before transplant, and all seropositive patients receive prophylaxis with either acyclovir, 800 mg twice daily, or valacyclovir, 500 mg twice daily, for 1 year or longer if the patient is receiving immunosuppressive therapy. In AIDS patients, ocular and neurologic complications of herpes zoster are increased. Immunosuppressed patients often have recurrences of zoster, up to 25% in patients with AIDS (Fig. 19-19).

Two atypical patterns of zoster have been described in AIDS patients: ecthymatous lesions, which are punched-out ulcerations with a central crust, and verrucous lesions (Fig. 19-20). These patterns were not reported before the AIDS epidemic. Atypical clinical patterns, especially the verrucous pattern, may correlate with acyclovir resistance.

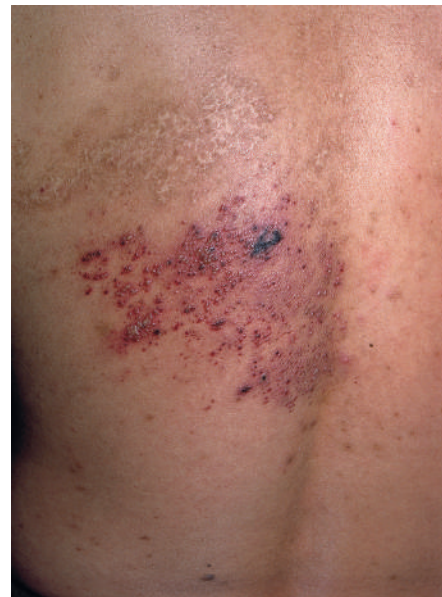## Diagnosis

The same techniques used for the diagnosis of varicella are used to diagnose herpes zoster. The clinical appearance is often adequate to suggest the diagnosis, and an in-office Tzanck smear can rapidly confirm the clinical suspicion.

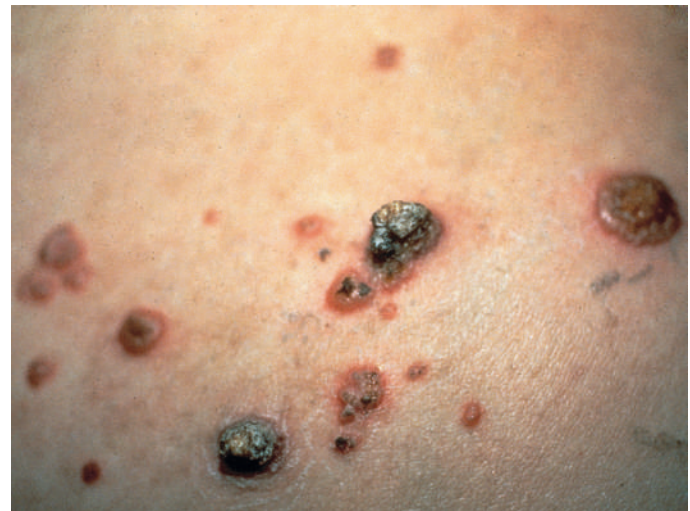Zosteriform herpes simplex can also have a positive Tzanck smear, but the number of lesions is usually more limited and the degree of pain substantially less than with zoster. Beyond Tzanck preparation, DFA testing is preferred to a viral culture because it is rapid, types the virus, and has a higher yield than culture. Compared with documented VZV infections, Tzanck smear was 75% positive (with up to 10% false-positives and high variability, depending on skill of examiner), and culture only 44% positive. PCR testing is 97% positive. In atypical lesions, biopsy may be necessary to demonstrate the typical herpesvirus cytopathic effects. IP stain tests can then be performed on paraffin-fixed tissue to identify VZV specifically. When acyclovir fails clinically, viral culture may be attempted and acyclovir sensitivity testing performed. It is not as standardized for VZV as it is for HSV, and its availability is limited.

## Histopathology

As with herpes simplex, the vesicles in zoster are intraepidermal. Within and at the sides of the vesicle are large, swollen cells called balloon cells, which are degenerated cells of the spinous layer. Acidophilic inclusion bodies similar to those



**Fig. 19-19** Recurrent zoster in AIDS patient.



**Fig. 19-20** Verrucous zoster in AIDS patient.



seen in HSV are present in the nuclei of the cells of the vesicle epithelium. Multinucleated keratinocytes, nuclear molding, and peripheral condensation of the nucleoplasm are characteristic and confirmatory of an infection with either HSV or VZV. In the vicinity of the vesicle, there is marked intercellular and intracellular edema. In the upper part of the dermis, vascular dilation, edema, and perivascular infiltration of lymphocytes and polymorphonuclear leukocytes (PMNs) are present. Atypical lymphocytes may also be found. An underlying leukocytoclastic vasculitis suggests VZV infection over HSV. Inflammatory and degenerative changes are also noted in the posterior root ganglia and in the dorsal nerve roots of the affected nerve. The lesions correspond to the areas of innervation of the affected nerve ganglion, with necrosis of the nerve cells.

## Differential diagnosis

The distinctive clinical picture of zoster permits a diagnosis with little difficulty. A unilateral, painful eruption of grouped vesicles along a dermatome, with hyperesthesia and on occasion regional lymph node enlargement, is typical. Occasionally, segmental cutaneous paresthesias or pain may precede the eruption by 4 or 5 days. In such patients, prodromal symptoms are easily confused with the pain of angina pectoris, duodenal ulcer, biliary or renal colic, appendicitis, pleurodynia, or early glaucoma. The diagnosis becomes obvious once the cutaneous eruption appears. Herpes simplex and herpes zoster are confused if the lesions of HSV are linear (zosteriform HSV), or if the number of zoster lesions is small and localized to one site (not involving whole dermatome). DFA testing or viral culture will distinguish them; DFA is generally preferred because it is rapid and sensitive.

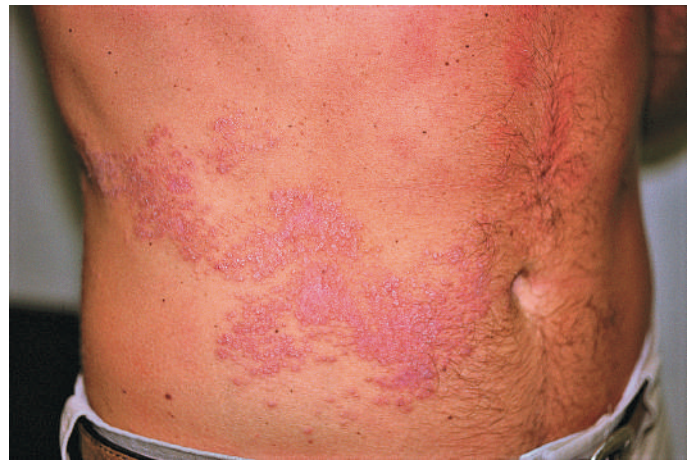
## Prevention of zoster

A vaccine using the same attenuated virus as in the varicella vaccination, but at much higher titers, has been licensed for the prevention of herpes zoster (Zostavax). It is recommended in all persons 60 years or older. This vaccination reduces the incidence of zoster by 50%. In addition, PHN was 67% lower in the vaccine recipients, and duration of ZAP was shortened. Burden of illness was also reduced. Those vaccinated between ages 60 and 69 had a greater reduction in zoster incidence than those over 70, but in both groups, PHN and burden of illness were reduced similarly. Since it is a live virus vaccine, persons taking antiviral medications must stop them 24 hours before immunization and not take them for 14 days after immunization. Immunosuppressed patients can be safely immunized following specific guidelines.

Institutionalized patients who develop herpes zoster are infectious to other patients and the health care team. Prior immunization with varicella vaccine and "adequate serologic titers" may not prevent acquiring infection, especially in immunosuppressed patients. Covering the cutaneous lesions specifically with semipermeable dressings (not just gauze bandages) appears to reduce transmission.

## Inflammatory skin lesions after zoster infection (isotopic response)

Following zoster, inflammatory skin lesions may rarely occur within the affected dermatome. Lesions usually appear within 1 month, or rarely, longer than 3 months, after the zoster. Clinically, the lesions are usually flat-topped or annular papules in the dermatome. Histologically, such papules most frequently demonstrate various patterns of granulomatous



**Fig. 19-21** Dermatome previously affected by zoster developed a granulomatous dermatitis histologically consistent with granuloma annulare.

inflammation from typical granuloma annulare to sarcoid-like reactions or even granulomatous vasculitis (Fig. 19-21). Persistent viral genome has not been detected in these lesions, suggesting that continued antiviral therapy is not indicated. Persistent VZV glycoproteins may be the triggering antigens. Topical and intralesional therapy with corticosteroids is beneficial, but the natural history of these lesions is generally spontaneous resolution. Less often, other inflammatory skin diseases have been reported in areas of prior zoster, including lichen planus, lichen sclerosus, vitiligo, Kaposi sarcoma, graft-versus-host disease (GVHD), morphea, and benign or even atypical lymphoid infiltrates. Leukemic infiltrates and lymphomas may affect zoster scars, as can metastatic carcinomas (inflammatory oncotaxis) or nonmelanoma skin cancers.

**Antoniou T, et al:** Statins and the risk of herpes zoster: a population-based cohort study. *Clin Infect Dis* 2014; 58:350.

**Asahi T, et al:** Valacyclovir neurotoxicity: clinical experience and review of the literature. *Eur J Neurol* 2009; 16:457.

**Au WY, et al:** Disseminated zoster, hyponatremia, severe abdominal pain and leukaemia relapse: recognition of a new clinical quartet after bone marrow transplantation. *Br J Dermatol* 2003; 149:862.

**Beal B, et al:** Gabapentin for once-daily treatment of post-herpetic neuralgia: a review. *Clin Interv Aging* 2012; 7:249.

**Borumandi F:** Jaw necrosis after herpes zoster infection due to HIV/AIDS as underlying disease. *Aust Dent J* 2013; 58:539.

**Breuer J:** Herpes zoster: new insights provide an important wake-up call for management of nosocomial transmission. *J Infect Dis* 2008; 197:635.

**Breuer J, et al:** Herpes zoster as a risk factor for stroke and TIA: a retrospective cohort study in the UK. *Neurology* 2014; 82:206.

**Castronovo C, Nikkels AF:** Chronic herpes zoster duplex bilateralis. *Acta Derm Venereol* 2012; 92:148.

**Che H, et al:** Risk of herpes/herpes zoster during anti-tumor necrosis factor therapy in patients with rheumatoid arthritis: systematic review and meta-analysis. *Joint Bone Spine* 2014; 81:215.

**Chen JY, et al:** Plasma vitamin C is lower in postherpetic neuralgia patients and administration of vitamin C reduces spontaneous pain but not brush-evoked pain. *Clin J Pain* 2009; 25:562.

**Chen PH, et al:** Herpes zoster associated voiding dysfunction: a retrospective study and literature review. *Arch Phys Med Rehabil* 2002; 83:1624.

**Chewrnev I:** Herpes zoster duplex bilateralis. *Dermatol Online J* 2014; 20:3.

**Chiu HY, Lin SJ:** A painful bulge in the left flank. *JAMA* 2013; 310:639.

**Chodkiewicz HM, et al:** Ramsay Hunt syndrome revisited. *Cutis* 2013; 91:181.

**Cohen JI:** Strategies for zoster vaccination in immunocompromised patients. *J Infect Dis* 2008; 197:S237.

**Cohen JI:** Herpes zoster. *N Engl J Med* 2013; 369:255.

- Donati D, et al:** Successful response on non-recovering Ramsay Hunt syndrome to intravenous high dose methylprednisolone. *J Neurol Sci* 2012; 318:160.
- Felt N:** Gabapentin not shown to prevent postherpetic neuralgia. *Arch Dermatol* 2012; 148:400.
- Fleming J, et al:** Varicella zoster virus brachioplexitis associated with granulomatous vasculopathy. *Clin Exp Dermatol* 2013; 38:378.
- Gilden D, et al:** Varicella zoster virus vasculopathies: diverse clinic manifestations, laboratory features, pathogenesis, and treatment. *Lancet* 2009; 8:731.
- Graber EM, et al:** Two cases of herpes zoster appearing after botulinum toxin type A injections. *J Clin Aesthet Dermatol* 2011; 4:49.
- Green CB, Stratman EJ:** Prevent rather than treat postherpetic neuralgia by prescribing gabapentin earlier in patients with herpes zoster. *Arch Dermatol* 2011; 147:908.
- Gupta S, et al:** Necrodestructive herpes zoster. *Indian J Dermatol* 2012; 57:136.
- Harpaz R, et al:** Prevention of herpes zoster. *MMWR* 2008; 57:1.
- He L, et al:** Corticosteroids for preventing postherpetic neuralgia. *Cochrane Library* 2009; 3.
- Hedge S, et al:** Extensive herpes zoster involvement following mycophenolate mofetil therapy for sarcoidosis. *J Ophthalmol Inflamm Infect* 2012; 2:47.
- Hernandez PO, et al:** Family history and herpes zoster risk in the era of shingles vaccination. *J Clin Virol* 2011; 52:344.
- Hui F, et al:** A randomized controlled trial of a multifaceted integrated complementary-alternative therapy for chronic herpes zoster-related pain. *Altern Med Rev* 2012; 17:57.
- Iglar K, et al:** Herpes zoster as a marker of underlying malignancy. *Open Med* 2013; 7:e68.
- Izu K, et al:** Herpes zoster occurring as a solitary nodule on the index finger. *Br J Dermatol* 2004; 150:365.
- Joeseof RM, et al:** Chronic medical conditions as risk factors for herpes zoster. *Mayo Clin Proc* 2012; 87:961.
- Kakuta R, et al:** Unusually extensive disseminated herpes zoster with multiple ulcer formation in a methotrexate-treated rheumatoid arthritis patient. *J Dermatol* 2014; 41:181.
- Kanodia SK, et al:** Dose-related efficacy of gabapentin in acute herpetic neuralgia among geriatric patients. *Indian J Dermatol* 2012; 57:362.
- Kapoor S:** Vitamin C for attenuating postherpetic neuralgia pain: an emerging treatment alternative. *J Headache Pain* 2012; 13:591.
- Kawai K, et al:** Cost-effectiveness of vaccination against herpes zoster and postherpetic neuralgia: a critical review. *Vaccine* 2014; 32:1645.
- Kolšek M:** TENS—an alternative to antiviral drugs for acute herpes zoster treatment and postherpetic neuralgia prevention. *Swiss Med Wkly* 2012; 141:w13229.
- Kuo CC, et al:** Risk of herpes zoster in patients treated with long-term hemodialysis: a matched cohort study. *Am J Kidney Dis* 2012; 59:428.
- Kurlan JG, et al:** Herpes zoster in the first year of life following postnatal exposure to varicella-zoster virus. *Arch Dermatol* 2004; 140:1268.
- Lapolla W, et al:** Incidence of postherpetic neuralgia after combination treatment with gabapentin and valacyclovir in patients with acute herpes zoster: open label study. *Arch Dermatol* 2011; 147:901.
- Lasserre A, et al:** Herpes zoster: family history and psychological stress: case-control study. *J Clin Virol* 2012; 55:153.
- Lee CK, Baek BJ:** Lingual zoster. *N Engl J Med* 2011; 365:1726.
- Lee JY, et al:** The effect of ketamine as an additive in epidural block on the intractable herpetic neuralgia: a case report. *Korean J Anesthesiol* 2014; 66:64.
- Li Q, et al:** Antiviral treatment for preventing postherpetic neuralgia. *Cochrane Library* 2009; 3.
- Liu YC, et al:** Herpes zoster is associated with an increased risk of subsequent lymphoid malignancies: a nationwide population-based matched-control study in Taiwan. *BMC Cancer* 2012; 12:503.
- Lo CH, Chiang CP:** Herpes zoster duplex bilateralis. *Intern Med* 2013; 52:2841.
- Long MD, et al:** Increased risk of herpes zoster among 108,604 patients with inflammatory bowel disease. *Aliment Pharmacol Ther* 2013; 37:420.
- Mahajan VK, et al:** Spontaneous tooth exfoliation after trigeminal herpes zoster: a case series of an uncommon complication. *Indian J Dermatol* 2013; 58:244.
- Makharita MY, et al:** Single paravertebral injection for acute thoracic herpes zoster: a randomized controlled trial. *Pain Pract* 2014; Feb 17. [Epub ahead of print.]
- Mehra T, et al:** Isotopic response of graft versus host disease following herpes zoster infection: case report and review of the literature. *Acta Derm Venereol* 2012; 92:339.
- Nalamachu S, et al:** Influence of anatomic location of lidocaine patch 5% on effectiveness and tolerability for postherpetic neuralgia. *Patient Prefer Adherence* 2013; 7:551.
- Nikkels AF, et al:** Atypical recurrent varicella in 4 patients with hemopathies. *J Am Acad Dermatol* 2003; 48:442.
- Ono F, et al:** Comparison between famciclovir and valacyclovir for acute pain in adult Japanese immunocompetent patients with herpes zoster. *J Dermatol* 2012; 39:902.
- Pirmohamed M:** Statins, immunomodulation, and infections: a complex and unresolved relationship. *Clin Infect Dis* 2014; 58:357.
- Puri N:** Modified Jaipur block for the treatment of post-herpetic neuralgia. *Int J Dermatol* 2011; 50:1417.
- Rabaud C, et al:** Early antiviral treatment fails to completely prevent herpes-related pain. *Med Mal Infect.* 2013; 43:461.
- Ruocco E, et al:** Segmental immune disorders related to herpes zoster. *Int J Dermatol* 2014; 53:e303.
- Sabatowski R, et al:** Safety and efficacy outcomes of long-term treatment up to 4 years with 5% lidocaine medicated plaster in patients with post-herpetic neuralgia. *Curr Med Res Opin* 2012; 28:1337.
- Sampathkumar P, et al:** Herpes zoster (shingles) and postherpetic neuralgia. *Mayo Clin Proc* 2009; 84:274.
- Sang CN, et al:** Gastroretentive gabapentin (G-GR) formulation reduces intensity of pain associated with postherpetic neuralgia (PHN). *Clin J Pain* 2013; 29: 281.
- Schencking M, et al:** Intravenous vitamin C in the treatment of shingles: results of a multicenter prospective cohort study. *Med Sci Monit* 2012; 18:CR215.
- Snedecor SJ, et al:** Systematic review and meta-analysis of pharmacological therapies for pain associated with postherpetic neuralgia and less common neuropathic conditions. *Int J Clin Pract* 2014; 68:900.
- Song HJ, et al:** Herpes zoster complicated by delayed intracranial haemorrhage. *Clin Exp Dermatol* 2008; 34:518.
- Sotiriou E, et al:** Severe post-herpetic neuralgia successfully treated with botulinum toxin A: three case reports. *Acta Derm Venereol* 2009; 89:214.
- Stidd DA, et al:** Peripheral nerve stimulation for trigeminal neuropathic pain. *Pain Physician* 2012; 15:27.
- Styczyski J, et al:** Management of HSV, VZV and EBV infections in patients with hematological malignancies and after SCT: guidelines from the Second European Conference on Infections in Leukemia. *Bone Marrow Transpl* 2009; 43:757.
- Terao M, et al:** Vitiligo exacerbated after herpes zoster. *J Dermatol* 2012; 39:938.
- Tsai J, et al:** Zoster paresis: asymptomatic MRI lesions far beyond the site of rash and focal weakness. *J Neurol Sci* 2013; 330:119.
- Tyring SK:** Management of herpes zoster and postherpetic neuralgia. *J Am Acad Dermatol* 2007; 57:S136.
- Umezawa Y, et al:** Risk of herpes zoster in psoriatic patients undergoing biologic treatment. *J Dermatol* 2014; 41:168.
- Uscategui T, et al:** Antiviral therapy for Ramsay Hunt syndrome (herpes zoster oticus with facial palsy) in adults. *Cochrane Library* 2009; 3.
- Watanabe K, Funaki M:** Zoster of the tympanic membrane. *N Engl J Med* 2011; 365:e40.
- Watanabe T, et al:** Papules on the nape: postherpetic granuloma annulare-like reaction (Wolf isotopic response). *Arch Dermatol* 2009; 145:589.
- Weinberg JM:** Herpes zoster: epidemiology, natural history, and common complications. *J Am Acad Dermatol* 2007; 57:S130.
- Yan C, et al:** Herpes zoster duplex bilateralis in an immunocompetent adolescent boy: a case report and literature review. *Pediatr Dermatol* 2014; 31:341.
- Zhang J, et al:** Association between vaccination for herpes zoster and risk of herpes zoster infection among older patients with selected immune-mediated diseases. *JAMA* 2012; 308:43.

## Epstein-Barr virus

Epstein-Barr virus (EBV) is a  $\gamma$ -herpesvirus. It infects human mucosal epithelial cells and B lymphocytes, and infection persists for the life of the host. EBV infection may be latent – not



producing virions, but simply spread from mother cell to both daughter cells by copying the viral DNA with each host cell replication. Intermittently, infection may be productive, resulting in production and release of infectious virions. EBV infection may transit between latent and productive infection many times. The ability of EBV to maintain persistent infection is aided by the expression of the EBV nuclear antigen 1 (EBNA-1) viral gene product, which prevents cytotoxic T-lymphocyte response to the virus.

Initial infection with EBV occurs in childhood or early adulthood, so that by their early twenties, 95% of the population has been infected. The virus is shed into the saliva, so contact with oral secretions is the most common route of transmission. Primary infection may be asymptomatic or may produce only a mild, nonspecific febrile illness, especially in younger children. In young adults, primary infection is more likely to be symptomatic and in 50% of cases produces a syndrome termed infectious mononucleosis (IM). The incubation period is 3–7 weeks. IM is characterized by a constellation of findings: fever (up to 40°C), headache, lymphadenopathy, splenomegaly, and pharyngitis (sore throat).

Cutaneous and mucous membrane lesions are present in about 10% of IM patients. Exanthems occur in less than 5%, more often in children. Edema of the eyelids and a macular or morbilliform eruption are most common. The eruption is usually on the trunk and upper extremities. Other, less common eruptions are urticarial, vesicular, bullous, petechial, erythema multiforme, and purpuric types. Cold urticaria transiently occurs in 5% of patients with IM. Leukocytoclastic vasculitis and large-vessel arteritis have been seen in chronic EBV infection, often in the setting of immunodeficiency. The mucous membrane lesions consist of distinctive pinhead-sized petechiae, 5–20 in number, at the junction of the soft and hard palate (Forchheimer spots). Gianotti-Crosti syndrome (GCS) and the papular-purpuric glove-and-socking (or gloves-and-socks) syndrome are two specific viral exanthem patterns that may occur in the patient with asymptomatic primary EBV infection. EBV is now the leading cause of GCS worldwide. EBV reactivation has been infrequently associated with drug-induced hypersensitivity syndrome. EBV is also associated with enhanced insect bite reactions.

Painful genital ulcerations may precede the symptomatic phase of IM, especially in premenarcheal girls. The ulcerations are up to 2 cm in diameter, single or multiple, and may be accompanied by marked swelling of the labia. Lesions last several weeks and heal spontaneously, often as the patient is developing symptoms of IM. Transmission to patients through orogenital sex has been proposed, but the virus may also reach the vulvar mucosa hematogenously. EBV has been recovered by culture from these genital ulcerations. The lesions closely resemble herpetic ulcerations and fixed drug eruption, which must be considered in the differential diagnosis.

Laboratory evaluation in patients with IM frequently shows an absolute lymphocytosis of greater than 50% and monocytosis with abnormally large, “atypical” lymphocytes. The white blood cell (WBC) count ranges from 10,000 to 40,000 cells/mm<sup>3</sup>. Liver function tests (LFTs) may be elevated. Heterophile antibodies will be present in 95% or more of cases. In acute primary EBV infection, IgM antibodies to early antigen (EA) and viral capsid antigen (VCA) are found in high titer and decrease during recovery. Antibodies to VCA and EBNA appear in the recovering phase and persist for years after primary infection. There is no specific therapy, and in most IM patients, no treatment is required. Acyclovir is not effective in altering the length or severity of IM, although it is active against EBV in doses used for VZV. If patients have severe pharyngeal involvement with encroachment on the airway, 4 days of oral corticosteroid therapy (40–60 mg/day of prednisone) is useful

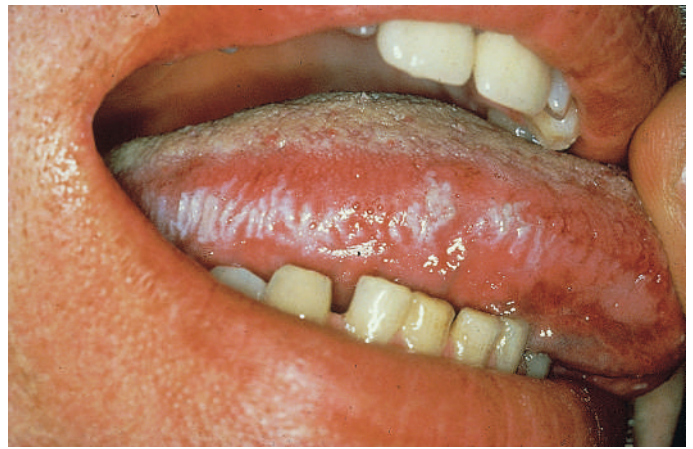

Fig. 19-22 Oral hairy leukoplakia.

to induce a prompt reduction in pharyngeal swelling. Most patients recover completely.

Patients with IM treated with ampicillin, amoxicillin, or other semisynthetic penicillins typically develop a generalized, pruritic, erythematous to copper-colored macular exanthem on the 7th–10th day of therapy. The eruption starts on the pressure points and extensor surfaces, generalizes, and becomes confluent. The eruption lasts about 1 week and resolves with desquamation. The eruption often does not recur when these medications are given after the acute mononucleosis has resolved.

Oral hairy leukoplakia (OHL) is a distinctive condition strongly associated with HIV. It appears as poorly demarcated, corrugated white plaques seen on the lateral aspects of the tongue (Fig. 19-22). Lesions on the other areas of the oral mucosa are simply white plaques without the typical corrugations. OHL can be distinguished from thrush by the fact that OHL cannot be removed by firm scraping with a tongue blade. More than one-third of patients with AIDS have OHL, but is not restricted to patients with HIV infection; it also occurs in other immunosuppressed hosts, especially renal and bone marrow transplant recipients, and those using inhaled steroids for chronic obstructive pulmonary disease. OHL can be a part of the immune reconstitution inflammatory syndrome (IRIS). EBV does not establish infection in the basal cell layer of the oral epithelium but is maintained by repeated direct infection of the epithelium by EBV in the oral cavity. Only chronically immunosuppressed patients continuously shed EBV in their oral secretions, thus explaining the restriction of OHL to immunosuppressed hosts. In normal persons, a similar morphologic and histologic picture can be seen (pseudo-OHL), but EBV is not found in these patients' lesions. Thus, the finding of OHL warrants immunologic evaluation. A biopsy of the OHL lesions searching for EBV in the epithelium can be useful in this setting. OHL is usually asymptomatic and requires no treatment. If treatment is requested in immunosuppressed patients, podophyllin, applied for 30 s to 1 min to the lesions once each month, is the simplest approach. Tretinoin gel, applied topically twice daily, or oral acyclovir, 400 mg five times daily, is also effective. Lesions recur when treatment is discontinued.

In immunosuppressed and immunocompetent hosts, EBV may be responsible for benign and malignant disorders, some of which can be fatal. These include Kikuchi disease (histiocytic necrotizing lymphadenitis), hydroa vacciniforme (HV) and HV-like lymphoma, hypereosinophilic syndrome, leiomyomas and leiomyosarcomas, lymphomatoid granulomatosis, erythema multiforme, and multiple types of lymphoma and lymphoproliferative disorders, especially in organ transplant

recipients. Richter syndrome (development of lymphoma in the patient with chronic lymphocytic leukemia) can present in the skin and may be associated with fludarabine treatment of EBV infection.

## Cytomegalic inclusion disease

Congenital cytomegalovirus (CMV) infection, as documented by CMV excretion, is found in 1% of newborns, 90% of whom are asymptomatic. Clinical manifestations in infants may include jaundice, hepatosplenomegaly, cerebral calcifications, chorioretinitis, microcephaly, mental retardation, and deafness. Cutaneous manifestations may result from thrombocytopenia, with resultant petechiae, purpura, and ecchymoses. Purpuric lesions, which may be macular, papular, or nodular, may show extramedullary hematopoiesis (dermal erythropoiesis), producing the "blueberry muffin baby." A generalized vesicular eruption may rarely occur. Most symptomatic cases occur within the first 2 months of life. Neonatal disease is more severe and sequelae are more frequent in neonates of mothers with primary rather than recurrent CMV disease in pregnancy.

Between 50% and 80% of immunocompetent adults and up to 100% of HIV-infected men who have sex with men (MSM) are infected with CMV. Infection in adults may be acquired by exposure to infected children, sexual transmission, and transfusion of CMV-infected blood. Symptomatic primary infection in adults is unusual and is identical to IM caused by EBV. An urticarial or morbilliform eruption or erythema nodosum may occur in primary CMV infection in immunocompetent adults. Ampicillin and amoxicillin administration will often result in a morbilliform eruption in acute CMV infection, similar to that seen in acute EBV infection.

Infection with CMV is common in AIDS patients, most frequently causing retinitis (20% of patients), colitis (15%), cholangitis, encephalitis, polyradiculomyopathy, and adrenalitis. It occurs in the setting of very advanced HIV infection, usually with CD4 counts below 50, and has become much less common in the era of highly active antiretroviral therapy (HAART).

Cytomegalovirus infection in tissues is usually identified by the histologic finding of a typical CMV cytopathic effect. In a very small percentage of AIDS patients with CMV infection, skin lesions may occur that contain such cytopathic changes. In most cases, CMV is found in association with another infectious process, and the treatment of that other infection will lead to resolution of the CMV in the skin without its treatment. This is especially true of perianal HSV ulcerations. CMV may even be found in totally normal skin in CMV-viremic AIDS patients, suggesting that finding the CMV cytopathic effect is insufficient alone to imply a causal relationship of the CMV to any cutaneous lesion. Only in the case of perianal and oral ulcerations has the pathogenic role of CMV been documented. In unusual cases of extremely painful genital ulcerations, only CMV infection is found histologically, or the ulceration persists after effectively treating HSV, with CMV identified histologically. The CMV cytopathic changes may be noted in the nerves at the base of these ulcerations, suggesting that CMV neuritis may be producing the severe pain that characterizes these cases. The diagnosis of CMV ulceration is one of exclusion. CMV cytopathic changes must be seen in the lesion and cultures, and histologic evidence of any other infectious agent must be negative. In these ulcerations, clinically suggested by their location (genital or oral) and painful nature, specific treatment with valganciclovir, foscarnet, or cidofovir will lead to healing of the ulceration and dramatic resolution of the pain.

The CMV infecting endothelial cells may produce a vasculopathy in CMV-viremic or partially reactivating patients. This

can lead to prominent vasculopathic changes, including Raynaud phenomenon, deep venous thrombosis, digital gangrene, and reticulated purpura. Anticardiolipin antibodies may be positive. Anti-CMV therapy can reverse the syndrome and clear the anticardiolipin antibodies.

- Ardalan M:** Rare presentations of cytomegalovirus infection in renal allograft recipients. *Nephro-Urol Mon* 2012; 4:431.
- Chiu HY, et al:** Concurrent cytomegalovirus and herpes simplex virus infection in pemphigus vulgaris treated with rituximab and prednisolone. *Acta Derm Venereol* 2013; 93:200.
- Dauden E, et al:** Mucocutaneous presence of cytomegalovirus associated with human immunodeficiency virus infection. *Arch Dermatol* 2001; 137:443.
- Durkin J, et al:** A 7-week-old Nepali girl with a perianal ulcer: brief report. *Pediatr Dermatol* 2014; 31:e65.
- Fernandez-Flores A:** Epstein-Barr virus in cutaneous pathology. *Am J Dermatopathol* 2013; 35:763.
- Gabrib G, et al:** Atypical presentation of exophytic herpes simplex virus type 2 with concurrent cytomegalovirus infection: a significant pitfall in diagnosis. *Am J Dermatopathol* 2013; 35:371.
- Hancox JG, et al:** Perineal ulcers in an infant: an unusual presentation of postnatal cytomegalovirus infection. *J Am Acad Dermatol* 2006; 54:536.
- Klion AD, et al:** Chronic active Epstein-Barr virus infection: a novel cause of lymphocytic variant hypereosinophilic syndrome. *Blood* 2013; 121:2364.
- Lee HY, et al:** Primary Epstein-Barr virus infection associated with Kikuchi's disease and hemophagocytic lymphohistiocytosis: a case report and review of the literature. *J Microbiol Immunol Infect* 2010; 43:253.
- Lehloeny R, Meintjes G:** Dermatologic manifestations of the immune reconstitution inflammatory syndrome. *Dermatol Clin* 2006; 24:549.
- Mendoza N:** Mucocutaneous manifestations of Epstein-Barr virus infection. *Am J Clin Dermatol* 2008; 9:295.
- Molina-Ruiz AM, et al:** Cytomegalovirus-induced cutaneous microangiopathy manifesting as lower limb ischemia in a human immunodeficiency virus-infected patient. *J Cutan Pathol* 2012; 39:945.
- Nakai H, et al:** A case of erythema multiforme associated with primary Epstein-Barr virus infection. *Pediatr Dermatol* 2011; 28:23.
- Pahlow Mose A, et al:** Antiviral treatment of a boy with EBV-associated hydroa vacciniforme. *BMJ Case Rep* 2014 [Epub ahead of print.]
- Park BM, et al:** Chronic active Epstein-Barr virus infection-associated hydroa vacciniforme-like eruption and Behçet's-like orogenital ulcers. *Dermatol* 2013; 226:212.
- Piperi E, et al:** Oral hairy leukoplakia in HIV-negative patients: report of 10 Cases. *Int J Surg Pathol* 2010; 18:177.
- Ramdial PK, et al:** Cytomegalovirus neuritis in perineal ulcers. *J Cutan Pathol* 2002; 29:439.
- Ramdial PK, et al:** Dermal Epstein Barr virus-associated leiomyosarcoma: tocsin of acquired immunodeficiency syndrome in two children. *Am J Dermatopathol* 2011; 33:392.
- Ramirez-Amador VA, et al:** Identification of oral candidosis, hairy leukoplakia and recurrent oral ulcers as distinct cases of immune reconstitution inflammatory syndrome. *Int J STD AIDS* 2009; 20:250.
- Ryan, C et al:** Cytomegalovirus-induced cutaneous vasculopathy and perianal ulceration. *J Am Acad Dermatol* 2011; 64:1216.
- Tetzlaff MT, et al:** Epstein-Barr virus-associated leiomyosarcoma with cutaneous involvement in an African children with human immunodeficiency virus: a case report and review of the literature. *J Cutan Pathol* 2011; 38:731.
- Yu L, et al:** Cutaneous Richter syndrome: report of 3 cases from one institution. *J Am Acad Dermatol* 2012; 67:e187.

## Human herpesviruses 6 and 7

Infection with HHV-6 is almost universal in adults, with seropositivity in the 80–85% range in the United States, and seroprevalence almost 100% in children. There are intermittent periods of viral reactivation throughout life; persistent infection occurs in several organs, particularly in the CNS. Acute seroconversion to HHV-6 and to HHV-7 each appears to be responsible for about one third of roseola cases, and in the remaining third, neither is found. HHV-6 infection occurs



earlier than HHV-7, and second episodes of roseola in HHV-6-seropositive children may be caused by HHV-7. Primary infection with HHV-6 is associated with roseola in only 9% of cases, and 18% of children with seroconversion have a rash. Primary infection may occur with only fever and no rash, or rash without fever. Other common findings include otitis media, diarrhea, and bulging fontanelles, sometimes with findings of meningoencephalitis. Infrequently, hepatitis, intussusception, and even fatal multisystem disease may occur. In adults, acute HHV-6 infection resembles acute mononucleosis.

As with other herpesviruses, the pattern of disease in HHV-6 may be different in immunosuppressed hosts. HHV-6 reactivation is common after transplantation: 32% after solid-organ and 48% after bone marrow transplantation. These patients can be quite ill, with fever, diarrhea, and elevated LFTs, simulating GVHD. Engraftment can be delayed. HHV-6 viremia, detected by PCR, can confirm the diagnosis. Chronic macular erythema has been reported in several cases. Careful histologic evaluation has identified HHV-6-infected lymphocytes and histiocytes in the macular erythema, confirming the diagnosis. Antiviral therapy with ganciclovir, foscarnet, or valganciclovir can lead to improvement.

### Roseola infantum (exanthem subitum, sixth disease)

Roseola infantum is a common cause of sudden, unexplained high fever in young children between 6 and 36 months of age. Prodromal fever is usually high and may be accompanied by convulsions and lymphadenopathy. Suddenly, on about the fourth day, the fever drops. Coincident with the decrease in temperature, a morbilliform erythema of discrete, rose-colored macules appears on the neck, trunk, and buttocks and sometimes on the face and extremities. Often, there is a blanched halo around the lesions. The eruption may also be papular or rarely even vesicular. The mucous membranes are spared. Complete resolution of the eruption occurs in 1–2 days. A case of spontaneously healing, generalized eruptive histiocytosis has been reported following exanthem subitum.

### Human herpesvirus 8

A  $\gamma$ -herpesvirus, HHV-8 is most closely related to EBV. HHV-8 has been found in all patients with Kaposi sarcoma (KS), including those who have AIDS (Fig. 19-23), in African cases; in elderly men from the Mediterranean basin; and in transplant patients. In addition, the seropositivity rate (infection rate) for this virus correlates with the prevalence of KS in a given population.

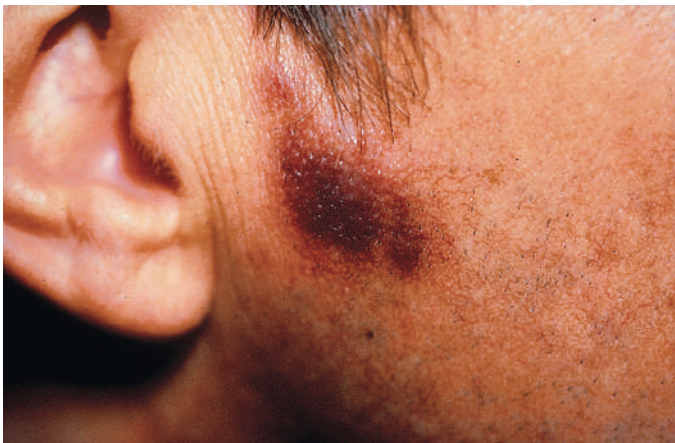

Fig. 19-23 Kaposi sarcoma.

The background seroprevalence rate of HHV-8 in North America and Northern Europe is near zero. Seroprevalence is highest in KS-endemic areas in sub-Saharan Africa (50–100%). In the general population in Italy, the seroprevalence is 10–15% (6–10% in children under age 16, 22% after age 50). In south-central Italy and in Sardinia, seroprevalence rates are higher, 20–25% for the general population. In Italy, high rates of HHV-8 seropositivity are also seen in HIV-infected gay men (up to 60%), in female prostitutes (40%), and in heterosexual men who have had sex with prostitutes (40%). Infection with HHV-8 precedes and predicts subsequent development of KS in HIV-infected men. In addition to KS lesions, HHV-8 can be found in saliva and in circulating blood cells in HHV-8-infected patients. HHV-8 is also found in the semen of up to 20% of KS patients. Heterosexual partners of patients with classic KS have high rates of HHV-8 seropositivity (>40%). These epidemiologic features all strongly support sexual transmission as an important mechanism of the spread of HHV-8. The finding of a significant number of infections in prepubertal children, however, suggests that nonsexual methods of transmission also exist. HHV-8 seroprevalence rate in heterosexual IV drug users and persons with HIV infection acquired through blood transfusion are not increased above that in the general population, suggesting that HHV-8 is poorly transmitted by blood and blood products.

Human herpesvirus 8 is present in a rare type of B-cell lymphoma called body cavity-based B-cell lymphoma or primary effusion lymphoma (PEL), which presents with pleural, pericardial, and peritoneal malignant effusions. Rarely, this form of lymphoma may be associated with skin lesions or may present as an intravascular lymphoma. The cutaneous lesions can resemble a CD30-positive, anaplastic, large T-cell lymphoma. HHV-8 is also found in all patients with multicentric Castleman's disease (MCD) associated with HIV infection and in 10–50% of HIV-negative patients with MCD. Cytokine production, specifically IL-6 from Kaposi syndrome herpesvirus (KSHV)-infected cells (vIL-6) and host inflammatory cells (hIL-6), appears causal. Exanthems and cutaneous nodules may accompany MCD, and HHV-8 has been identified in the skin lesions. KSHV inflammatory cytokine syndrome (KICS) is an inflammatory syndrome analogous to MCD but lacking the prominent lymphadenopathy. It is also mediated by IL-6 and other cytokines. In HHV-8-associated MCD and KICS, HHV-8 viral loads are much higher than in patients with KS, perhaps aiding in the diagnosis.

**Cattani P, et al:** Age-specific seroprevalence of human herpesvirus 8 in Mediterranean regions. *Clin Microbiol Infect* 2003; 9:274.

**Crane GM, et al:** HHV-8-positive and EBV-positive intravascular lymphoma: an unusual presentation of extracavitary primary effusion lymphoma. *Am J Surg Pathol* 2014; 38:426.

**Galan A, et al:** Fatal HHV6 infection in an immunocompromised patient presenting with skin involvement. *J Cutan Pathol* 2010; 37:277.

**Li MF, et al:** Human herpesvirus 8-associated lymphoma mimicking cutaneous anaplastic large T-cell lymphoma in a patient with human immunodeficiency virus infection. *J Cutan Pathol* 2012; 39:274.

**Müzes G, et al:** Successful tocilizumab treatment in a patient with human herpesvirus 8-positive and human immunodeficiency virus-negative multicentric Castleman's disease of plasma cell type nonresponsive to rituximab-CVP therapy. *APMIS* 2013; 121:668.

**Peker D, et al:** Complete remission in 4 patients with human herpesvirus 8-associated multicentric Castleman disease using rituximab and liposomal doxorubicin, a novel chemotherapy combination. *Clin Adv Hematol Oncol* 2012; 10:204.

**Polizzotto MN, et al:** Clinical manifestations of Kaposi sarcoma herpesvirus lytic activation: multicentric Castleman disease (KSHV-MCD) and the KSHV inflammatory cytokine syndrome. *Front Microbiol* 2012; 3:73.

**Roux J, et al:** Human herpesvirus-6 cytopathic inclusions: an exceptional and recognizable finding on skin biopsy during HHV6 reactivation after autologous stem-cell transplantation. *Am J Dermatopathol* 2012; 34:e73.

**Sayer R, et al:** Can plasma HHV8 viral load be used to differentiate multicentric Castlemann disease from Kaposi sarcoma? *Int J STD AIDS* 2011; 22:585.

**Schwartz RA, et al:** Kaposi sarcoma: a continuing conundrum. *J Am Acad Dermatol* 2008; 59:179.

**Tamiya H, et al:** Generalized eruptive histiocytoma with rapid progression and resolution following exanthema subitum. *Clin Exper Dermatol* 2005; 30:294.

**Wolz MM, et al:** Human herpesvirus 6, 7, and 8 from a dermatologic perspective. *Mayo Clin Proc* 2012; 87:1004.

**Yoshida M, et al:** Exanthema subitum (roseola infantum) with vesicular lesions. *Br J Dermatol* 1995; 132:614.

## B virus

B virus (*Herpesvirus simiae*) is endemic in Asiatic Old World monkeys (macaques) and may infect other monkeys housed in close quarters with infected monkeys. In macaques, *H. simiae* disease is a recurrent vesicular eruption analogous to HSV in humans, with virus shed from conjunctiva, oral mucosa, and urogenital area. Humans become infected after being bitten, scratched, or contaminated by an animal shedding B virus. Usually, patients are animal handlers or researchers. Rare cases of respiratory or human-to-human contact spread have been reported. Within a few days of the bite, vesicles, erythema, necrosis, or edema appear at the site of inoculation. Regional lymph nodes are enlarged and tender. Fever is typically present. In a substantial number of human infections, rapid progression to neurologic disease occurs. This is initially manifested by peripheral nerve involvement (dysesthesia, paresthesia), then progresses to spinal cord involvement (myelitis and ascending paralysis with hyporeflexia), and finally to brain disease (decreased consciousness, seizures, respiratory depression). Of 22 reported patients, 15 have died, and all survivors of encephalitis had severe neurologic sequelae. Treatment with acyclovir or ganciclovir has been successful in some, but other patients similarly treated have died.

**Estep RD, et al:** Simian herpesviruses and their risk to humans. *Vaccine* 2010; 28:878.

**Fan Q, et al:** Herpes B virus utilizes human nectin-1 but not HVEM or PILR for cell-cell fusion and virus entry. *J Virol* 2012; 86:4468.

## INFECTIOUS HEPATITIS

### Hepatitis B virus

Hepatitis B virus (HBV) is a dsDNA virus that is spread by blood and blood products, and sexually in Europe and the Western Hemisphere. In Africa and Asia, infection often occurs perinatally. HBV is the primary cause of hepatocellular carcinoma and may also cause liver failure and cirrhosis. Acute infection with HBV is associated with anorexia, nausea, right upper quadrant pain, and malaise. Between 20% and 30% of patients with acute HBV infection have a serum sickness-like illness with urticaria, arthralgias, and occasionally arthritis, glomerulonephritis, or vasculitis. These symptoms appear 1–6 weeks before onset of clinically apparent liver disease. Immune complexes containing hepatitis B surface antigen (HBsAg) and hypocomplementemia are found in serum and joint fluid. The process spontaneously resolves as antigen is cleared from the blood.

Hepatitis B is associated with polyarteritis nodosa (PAN) but in only 5% of patients because of widespread immunization. PAN usually occurs within the first 6 months of infection, even

during the acute phase, but may occur as long as 12 years after infection. Unlike the urticarial reaction, which is usually associated eventually with development of clinical hepatitis, HBV infection associated with PAN may be silent.

Immunosuppressive treatments can lead to reactivation of silent HBV infection. Before initiating treatment with an immunosuppressive agent (including TNF inhibitors), the patient should be screened for HBV infection by checking hepatitis B core antibody (and possibly HBsAg and antibody). Only two thirds of patients who receive immunomodulators will be HBsAg positive. Although 75% of HBV-infected patients will remain asymptomatic during immunomodulator treatment, a third will develop severe hepatitis, and more than 10% will die or develop fulminant hepatitis. Rituximab and cyclophosphamide cause reactivation early. Most of these patients would be candidates for preemptive antiviral therapy, so all patients with serologic evidence of HBV infection in whom immunosuppressive treatment or TNF inhibitor therapy is being considered should be referred to a hepatologist before initiating immunosuppressive therapy.

A highly effective vaccine is available to prevent HBV infection. It is recommended as a part of standard childhood immunizations, and all health care workers should be immunized. Patients who will receive TNF inhibitor treatment and who are not immunized may be considered for immunization.

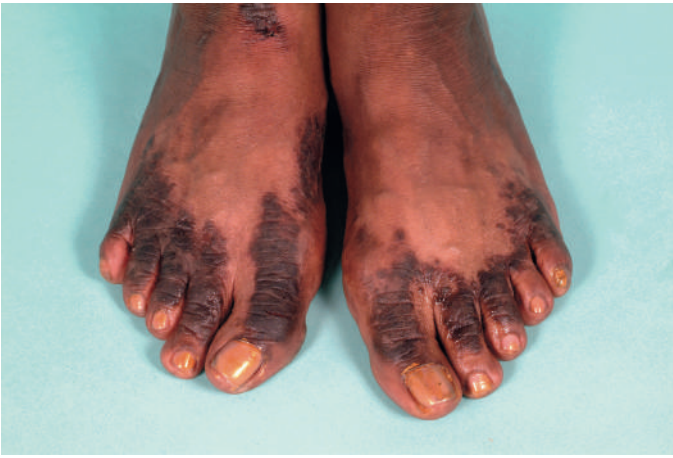### Hepatitis C virus

Hepatitis C virus (HCV) is a single-stranded (ss) RNA virus that causes most cases of non-A, non-B viral hepatitis. Now that a serologic test is available to screen blood products for HCV infection, the vast majority of new cases of HCV infection are parenterally transmitted by IV drug use. Compared with hepatitis B, sexual transmission is uncommon (<1% transmission/year of exposure). Mother-to-infant spread occurs in 5% of cases. Only about one third of patients are symptomatic during acute infection. Between 55% and 85% of patients will have chronic infection. Although most patients have minimal symptoms for the first one to two decades of infection, cirrhosis and liver failure, as well as hepatocellular carcinoma, are common sequelae. Chronic HCV infection is associated with various skin disorders, either by direct effect or from the associated hepatic damage.

Cutaneous necrotizing vasculitis, which is usually associated with a circulating mixed cryoglobulin, occurs in approximately 1% of patients with chronic HCV infection. In 84% of patients with type II cryoglobulinemia, HCV infection is present. The most common clinical presentation is palpable purpura of the lower extremities (90% of cases). Livedo reticularis, urticaria, and subcutaneous nodules showing a granulomatous vasculitis may also occur. Arthropathy, glomerulonephritis, and neuropathy frequently accompany the skin eruption. Leg ulcers can occur in 10–20%. Histologically, a leukocytoclastic vasculitis is seen in all patients. In some, the vasculitis may involve small arteries, giving a histologic pattern similar to that seen in PAN. In various studies, 5–20% of patients with PAN were HCV positive, suggesting that both HBV and HCV can cause PAN. The presence of anti-HCV antibodies should not be used as the sole diagnostic test in patients with PAN, because PAN may cause a false-positive ELISA test for HCV. Rheumatoid factor, a type II cryoglobulin, and hypocomplementemia are found in up to 80% of cases. HCV-infected patients with mixed cryoglobulinemia are 35 times more likely to develop non-Hodgkin lymphoma, usually of the B-cell type.

Patients with porphyria cutanea tarda (PCT) often have hepatocellular abnormalities. Depending on the prevalence of HCV infection in the population studied, 10–95% of sporadic





**Fig. 19-24** Necrolytic acral erythema.

(not familial) PCT cases are HCV associated. Treatment of the HCV infection may lead to improvement of the PCT.

Hepatitis C infection has been associated with lichen planus, with about a fourfold increased risk for its development in the HCV-positive patient. The likelihood of identifying HCV infection in a patient with lichen planus is greatest in geographic regions with high rates of HCV infection. Patients with mucosal ulcerative lichen planus are also more likely to be HCV infected. Serologic testing in a patient should be considered if the patient has HCV risk factors or abnormal LFTs or is from a geographic region where, or from population in whom, HCV infection is common. HCV may also be associated with cutaneous B-cell lymphoma. In studies from Japan and Israel, patients with HCV infection were almost twice as likely to develop psoriasis, especially men over 40 years. They were less obese but had higher rates of hypertension and diabetes mellitus. Approximately 15% of patients with HCV infection have pruritus. Pruritus virtually always is associated with advanced liver disease and abnormal LFTs. Patients with pruritus and normal LFTs and no history of hepatitis rarely will be infected with HCV.

Necrolytic acral erythema is an uncommon condition uniquely associated with HCV infection. It affects uniquely persons of African origin and occurs in less than 2% of HCV-infected patients in the United States. It resembles the “deficiency” dermatoses, except that it has an acral distribution. The clinical lesions are painful or pruritic, keratotic, well-defined plaques with raised red scaly borders or diffuse hyperkeratosis (Fig. 19-24). Erosion and flaccid blisters may occur, contributing to the discomfort. The dorsal feet (less often the dorsal hands) as well as the lower extremities may be involved. Histologically, there is necrosis of the superficial portion of the epidermis, along with hyperkeratosis, papillomatosis, loss of the granular cell layer, and parakeratosis. Intraepidermal spongiosis foci are present, which may be macroscopic at times, with the cleavage plane between the necrotic and viable epidermis. Zinc, essential fatty acid, and glucagon levels are normal, but the patients may be hypoalbuminemic and have low serum amino acids because of their liver disease. Treatment of the associated HCV infection with IFN and ribavirin, IFN plus zinc, and liver transplantation has resulted in resolution. Hyperalimentation was also partially effective in some patients, as was amino acid supplementation with zinc.

A combination of IFN alpha and ribavirin is used to treat patients with chronic HCV infection, with sustained responses in slightly over 50% of patients. Combined IFN and ribavirin therapy may be complicated by an eczematous eruption with pruritus in about 8% of patients and severe pruritus in about 1%. Eczema typically affects the distal extremities, dorsal hands, face, neck, and less frequently the trunk, axillae, and

buttocks. The eruption may be photodistributed and photoexacerbated. These eczematous eruptions typically begin 2–4 months after initiation of treatment. In affected patients, prior treatment with IFN alone was usually not associated with an eczematous eruption. Histologically, the eruptions show a spongiotic dermatitis. The eruption resolves completely if treatment is stopped for 2–3 weeks but will recur when treatment is restarted. Aggressive therapy with antihistamines, emollients, and potent topical corticosteroids will usually control the eczema, allowing uninterrupted continuation of treatment.

Adding telaprevir, an HCV protease inhibitor, greatly enhances the response of HCV infection to treatment, especially for HCV-1 and HCV-4 serotypes, which respond less well to IFN with ribavirin. This newer agent, however, is associated with a high rate of adverse skin reactions (60–80% of patients). About two thirds of reactions occur in the first 10 days of telaprevir administration, although these can continue to appear for weeks. More than 90% of telaprevir-associated drug reactions are graded as mild (localized, grade 1) or moderate (diffuse, grade 2) and can be treated with topical agents and oral antipruritics, and telaprevir therapy can be continued. Reactions are eczematous but can have a photoexacerbation. If reactions are progressive, systemic corticosteroids have been used. The median time to resolution was 44 days, with some reactions lasting longer than 1 year. Grade 3 reactions (any epidermal detachment, targets, or purpura/nonblanching erythema) occur in 2–9% of patients, and treatment must be stopped. Three cases of Stevens-Johnson syndrome and 11 cases (0.6% of treated patients) of drug-induced hypersensitivity syndrome (DRESS) occurred in the Phase III trials. A widespread papulosquamous eruption closely resembling pityriasis rubra pilaris has been reported. Patients receiving IFN alpha for HCV infection may develop unsightly granulomatous nodules at filler injection sites.

**Albeldawi M, et al:** A cutaneous marker of hepatitis C virus. *Gastroenterology* 2013; 144:275.

**Birkenfeld S, et al:** A study on the association with hepatitis B and hepatitis C in 1557 patients with lichen planus. *J Eur Acad Dermatol Venereol* 2011; 25:436.

**Cacoub P, et al:** Dermatological side effects of hepatitis C and its treatment: patient management in the era of direct-acting antivirals. *J Hepatol* 2012; 56:455.

**Descamps V, et al:** Facial cosmetic filler injections as possible target for systemic sarcoidosis in patients treated with interferon for chronic hepatitis C: two cases. *Dermatology* 2008; 217:81.

**Droz D, et al:** Kinetic profiles and management of hepatitis B virus reactivation in patients with immune-mediated inflammatory disease. *Arthritis Care Res* 2013; 65:1504.

**Hall LD, et al:** Epstein-Barr virus: dermatologic associations and implications. Part I. Mucocutaneous manifestations of Epstein-Barr virus and nonmalignant disorders. *J Am Acad Dermatol* 2015; 72:1.

**Imafuku S, et al:** Possible association of hepatitis C virus infection with late-onset psoriasis: a hospital-based observational study. *J Dermatol* 2013; 40:813.

**Kishi A, et al:** Biphasic skin reactions during telaprevir-based therapy of Japanese patients infected with hepatitis C virus. *J Am Acad Dermatol* 2014; 70:584.

**Montaudié H, et al:** Drug rash with eosinophilia and systemic symptoms due to telaprevir. *Dermatology* 2010; 221:303.

**Motaparthy K, et al:** From the Medical Board of the National Psoriasis Foundation: recommendations for screening for hepatitis B infection prior to initiating anti-tumor necrosis factor- $\alpha$  inhibitors or other immunosuppressive agents in patients with psoriasis. *J Am Acad Dermatol* 2013; 70:178.

**Raphael BA, et al:** Low prevalence of necrolytic acral erythema in patients with chronic hepatitis C virus infection. *J Am Acad Dermatol* 2012; 67:962.

**Rebora A:** Skin diseases associated with hepatitis C virus: facts and controversies. *Clin Dermatol* 2010; 28:489.

**Roujeau JC, et al:** Telaprevir-related dermatitis. *JAMA Dermatol* 2013; 149:2.

**Stalling SS, et al:** Telaprevir-induced pityriasis rubra pilaris–like drug eruption. *Arch Dermatol* 2012; 148:1215.

**Tsilika K, et al:** Secondary hyperpigmentation during interferon alfa treatment for chronic hepatitis C virus infection. *JAMA Dermatol* 2013; 149:675.

**Vazquez-Lopez F, et al:** Eczema-like lesions and disruption of therapy in patients treated with interferon-alfa and ribavirin for chronic hepatitis C: the value of an interdisciplinary assessment. *Br J Dermatol* 2004; 150:1028.

### Gianotti-Crosti syndrome (papular acrodermatitis of childhood, papulovesicular acrolocated syndrome)

Gianotti-Crosti syndrome (GCS) is a characteristic viral exanthem. It was initially associated with the early anicteric phase of HBV infection. With universal HBV immunization, HBV is now a rare cause of GCS. EBV is now the most common cause of GCS worldwide. Other implicated infectious agents have included adenovirus, CMV, enteroviruses (coxsackie A16, B4, and B5), vaccinia virus, rotavirus, hepatitis A and C, respiratory syncytial virus, parainfluenza virus, parvovirus B19, rubella virus, HHV-6, streptococcus, and *Mycobacterium avium*. Immunizations against poliovirus, diphtheria, pertussis, Japanese encephalitis, influenza, and hepatitis B and measles (together) have also caused GCS.

The clinical features are identical, independent of the cause. GCS typically affects children 6 months to 14 years of age (median age 2 years, 90% of cases occurring before the age of 4), and may rarely be seen in adults (women only). Proposed diagnostic criteria involve the following positive clinical features of GCS:

1. Monomorphic, flat-topped, pink-brown papules or papulovesicles of 1–10 mm in diameter (Figs. 19-25 and 19-26)
2. Any three or all four sites involved – face, buttocks, forearms, and extensor legs
3. Symmetry
4. Duration of at least 10 days

Negative clinical features include:

1. Extensive truncal lesions
2. Scaly lesions

The lesions develop over a few days but last longer than most viral exanthems (>10 days and up to many weeks). Lesion numbers may vary from a few to a generalized eruption coalescing to form plaques covering the face, trunk, and upper extremities. Early in the course of the eruption, the lesions will demonstrate a Koebner phenomenon. Pruritus is variable, and the mucous membranes are spared, except when inflamed by the associated infectious agent. Depending on the cause, the lymph nodes, mainly inguinal and axillary, are moderately enlarged for 2–3 months. No treatment appears to shorten the course of GCS, which is self-limited.

**Brandt O, et al:** Gianotti-Crosti syndrome. *J Am Acad Dermatol* 2006; 54:136.

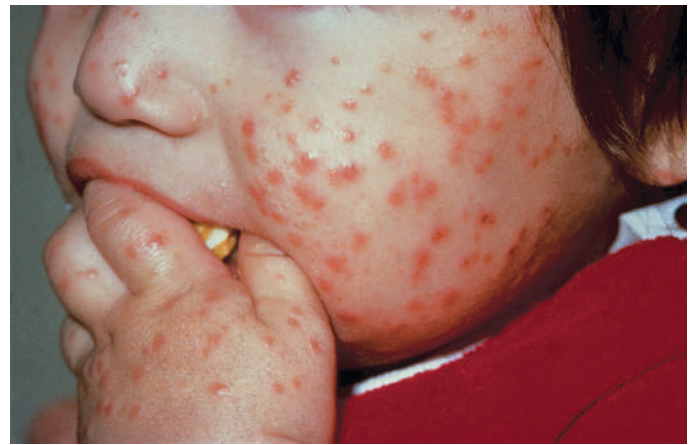**Hall LD, et al:** Epstein-Barr virus: dermatologic associations and implications. Part I. Mucocutaneous manifestations of Epstein-Barr virus and nonmalignant disorders. *J Am Acad Dermatol* 2015; 72:1.

**May J, Pollack R:** Gianotti-Crosti syndrome associated with type A influenza. *Pediatr Dermatol* 2011; 28:733.

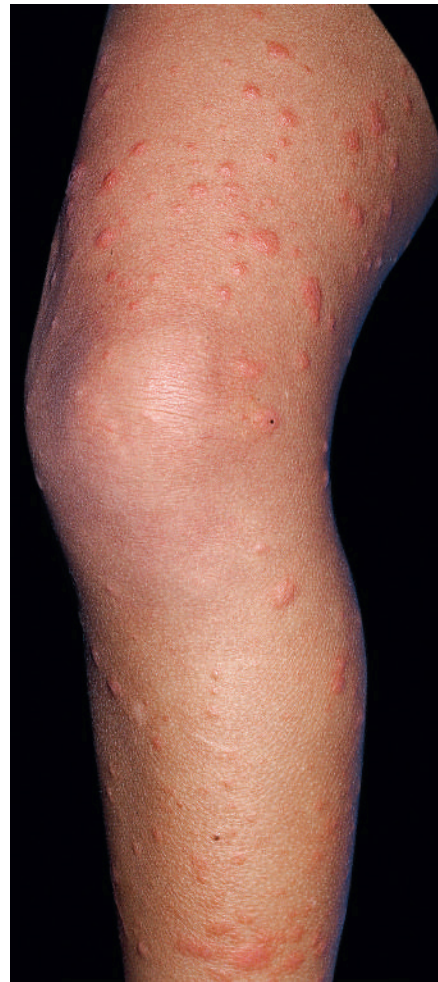**Roeskop AK, et al:** Gianotti-Crosti syndrome after H1N1-influenza vaccine. *Pediatr Dermatol* 2011; 28:596.

## POXVIRUS GROUP

The poxviruses are DNA viruses of a high molecular weight. The viruses are 200–300 nm in diameter and thus can be seen



**Fig. 19-25** Gianotti-Crosti syndrome.



**Fig. 19-26** Papules on the leg, Gianotti-Crosti syndrome. (Courtesy of Curt Samlaska, MD.)

in routine histologic material. Molluscum contagiosum virus and the now-eliminated variola virus are the only poxviruses for which humans represent the primary host and reservoir. The other poxviruses are primarily infections of animals, from whom humans accidentally become infected. The orthopoxviruses that have infected humans include vaccinia, monkeypox, cowpox, buffalopox, and camelpox. The parapoxviruses causing human disease include orf, bovine papular stomatitis, and sealpox. Many other genera of poxviruses have recently been discovered but are primarily pathogens in wild animals, so human disease is extremely rare or is not yet identified.



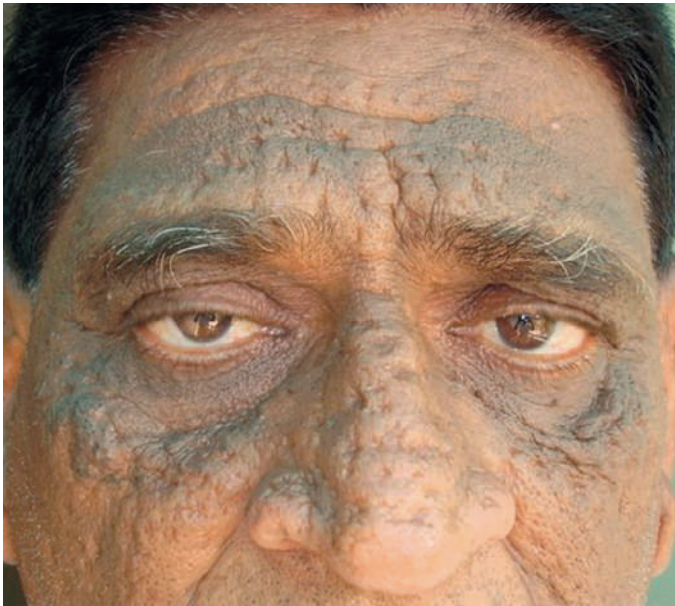

Fig. 19-27 Smallpox scars. (Courtesy of Shyam Verma, MD.)

### Variola major (smallpox)

Smallpox was eradicated worldwide in 1977. It continues to be of interest to dermatologists as a potential biologic warfare agent. Variola is spread by the respiratory route, with 37–88% of unvaccinated contacts becoming infected. The incubation period for smallpox is 7–17 days (average 10–12 days). The prodromal phase consists of 2–3 days of high fever ( $>40^{\circ}\text{C}$ ), severe headache, and backache. The fever subsides, and an exanthem covers the tongue, mouth, and oropharynx. This is followed in 1 day by the appearance of skin lesions, distributed in a centrifugal pattern, with the face, arms, and legs more heavily involved than the trunk. Lesions appear first on the palms and soles and feel like firm “BBs” under the skin. Beginning as erythematous macules (days 1–2), the lesions all in synchrony become 2–3 mm papules (days 2–4) and evolve to 2–5 mm vesicles (days 4–7) and 4–6 mm pustules (days 5–15). The pustules umbilicate, collapse, and form crusts beginning in the second week. The total evolution averages 2 weeks. Lesions on the palms and soles persist the longest. The crusts separate after about 1 more week, leaving scars (Fig. 19-27), which are permanent in 65–80% of the survivors. Patients are infectious from the onset of the exanthem through the first 7–10 days of the eruption. A variety of complications occur, including pneumonitis, blindness caused by viral keratitis or secondary infection (1% of patients), encephalitis ( $<1\%$  of patients), arthritis (2% of children), and osteitis. Immunity is lifelong. The mortality rate was 5–40% in undeveloped countries (and before current intensive care and antiviral management).

Diagnosis is made by electron microscopy, viral culture, and PCR. Special laboratories, usually associated with city and state health departments in the United States, can process these specimens and confirm the diagnosis. The differential diagnosis is primarily varicella, especially the more severe form seen in adults. In varicella, the prodrome lasts for 1–2 days; fever begins with onset of the eruption (not preceding it by 1–3 days, as in variola); the eruption is concentrated on the torso (not centrifugally); and individual lesions of different stages are present and evolve from vesicles to crust within 24 h. The diagnostic test of choice in these patients is a Tzanck smear or DFA test, which can rapidly confirm varicella.

Treatment of smallpox includes strict isolation and protection of health care workers. Only vaccinated persons should

treat the patient, and any of those exposed should immediately be vaccinated because this modifies the disease. Cidofovir modifies infections by other orthopoxviruses and may be indicated.

**Breman JG, Henderson DA:** Diagnosis and management of smallpox.

*N Engl J Med* 2002; 346:1300.

**Jahrling PB, Tomori O:** Variola virus archives: a new century, a new approach. *Lancet* 2014; 383:1525.

**Thèves C, et al:** The rediscovery of smallpox. *Clin Microbiol Infect* 2014; 20:210.

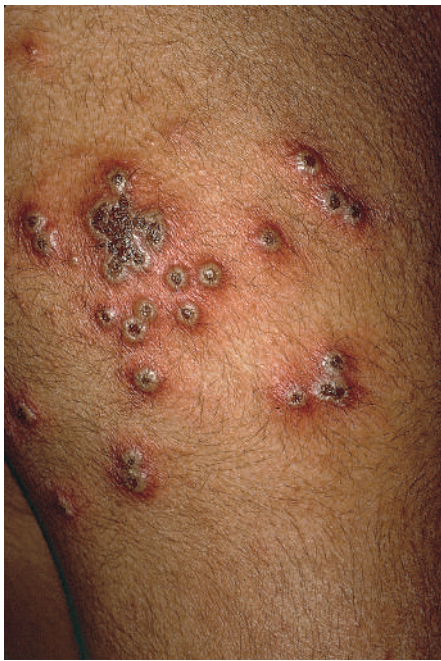### Vaccinia

The vaccinia virus has been propagated in laboratories for immunization against smallpox. There are multiple strains used in vaccines, and the rates of complications vary somewhat, depending on the strain used. The available antiviral agents with activity against vaccinia are limited. If a case of vaccinia is encountered, the state health department or the U.S. Centers for Disease Control and Prevention (CDC) should be contacted immediately for optimal management. Vaccinia virus (VACV) appears to have been initially isolated by Jenner from horse hooves and is closely related to horsepoxvirus. There have been epidemics of VACV infections on the teats of dairy cattle, the mouths of their calves, and the hands of dairy farmers in Brazil since the 1990s. VACV has also been isolated from wild rodents in Brazil.

### Vaccination

Vaccination is inoculation of live vaccinia virus into the epidermis and upper dermis by the multiple puncture technique. Between 3 and 5 days after inoculation, a papule forms, which becomes vesicular at days 5–8, then pustular, reaching a maximum size at days 8–10. The pustule dries from the center outward, revealing the pathognomonic umbilicated pustule, and forms a scab that separates 14–21 days after vaccination, resulting in a pitted scar. Formation by days 6–8 of a papule, vesicle, ulcer, or crusted lesion, surrounded by a rim of erythema and induration, is termed a “major reaction” or “take.” The rim of erythema averages 3.5–4 cm in diameter in new vaccinees and peaks on days 9–11. Repeat vaccinees have reactions of a similar time course, but the maximum diameter of the erythema is only 1–2 cm. Reactions that do not match this description are considered equivocal, and such persons cannot be considered immune; revaccination should be considered. A large vaccination reaction, or “robust take,” is the development of a plaque of erythema and induration greater than 10 cm at the site of inoculation. This occurs in 10% of initial vaccinees. It peaks at days 8–10 and resolves without treatment within 72 h. Cellulitis secondary to vaccination occurs on days 1–5 after vaccination or after several weeks and progresses without treatment. Management should be expectant, but a bacterial culture may be taken. Vaccinated patients may have fever on days 8–10 after vaccination, so culture is not helpful in separating cellulitis from a “robust take.” Rarely, patients will develop lesions at the site of vaccination an average of 2 months later. Their nature is unknown, but these lesions have not been identified as containing live virus and are self-limited.

Vaccination involves the inoculation of a live virus. Complications result from an abnormal response to the vaccination by the host or from inadvertent transmission to another person. Persons with defective cutaneous or systemic immunity are at particular risk for adverse outcomes from vaccination. Because some complications may be fatal, extremely careful steps must be taken to avoid complications.



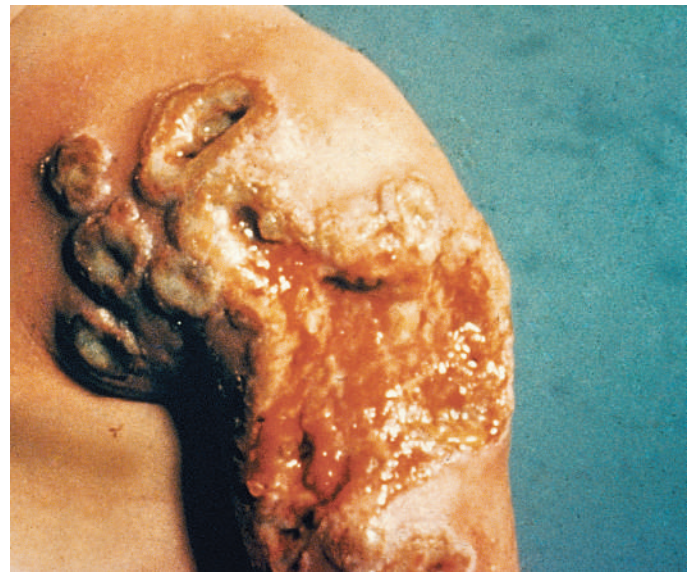
**Fig. 19-28**  
Autoinoculation  
vaccinia.

### Inadvertent inoculation and autoinoculation

Inadvertent inoculation of vaccinia may occur by transmission of virus by hands or fomites from the vaccination site to another skin area or the eye, or to another person. Accidental autoinoculation occurs in about 1 in 1000 vaccinees. Autoinoculation most often occurs around the eyes and elsewhere on the face, but the groin and other sites may be involved (Fig. 19-28). These lesions evolve in parallel with the primary vaccination site and, except for ocular lesions, cause no sequelae, except scarring at times. Any evidence of ocular inflammation in a recently vaccinated individual could represent ocular vaccinia infection and requires immediate ophthalmologic evaluation. Transmission to others (secondary transfer) is rare if the vaccination site is kept covered until it heals (7.4 in 100,000 primary vaccinees). It usually occurs within a household or through intimate contact. Serial transmission can occur among male sports partners and has been reported in serial sexual partners. Correct bandaging of the vaccination site using foam or occlusive dressings, not gauze bandages, and treating the inoculation site with povidone-iodine ointment beginning 7 days after immunization both can reduce viral shedding and might reduce autoinoculation and secondary cases.

### Generalized vaccinia

From 6 to 9 days after vaccination, a generalized vaccinia eruption may occur, in about 81 per 1 million new vaccinees or 32 per 1 million repeat vaccinees. The lesions are papulovesicles that become pustules and involute in 3 weeks, although successive crops may occur within that time. Generalized vaccinia may be accompanied by fever, but patients do not appear ill. Lesions may be generalized or limited to one anatomic region and can number from a few to hundreds. They can be confused with multisite autoinoculation, as well as erythema multiforme. The diagnosis is confirmed by biopsy, viral culture, or PCR. Generalized vaccinia is self-limited and does not require treatment in the immunocompetent host. In the patient with underlying immunodeficiency, early intervention with vaccinia immune globulin intravenous (VIGIV) may be beneficial.



**Fig. 19-29** Vaccinia necrosum.

### Eczema vaccinatum

Eczema vaccinatum is analogous to eczema herpeticum, representing vaccinia virus infection superimposed on a chronic dermatitis, especially atopic dermatitis. Patients with Darier's disease, Netherton syndrome, and other disorders of cornification may also be at risk. Since patients with atopic dermatitis or any past history of atopic dermatitis should not be vaccinated, most cases of eczema vaccinatum represent secondary transfer to an at-risk individual from a recent vaccinee, usually a family member. The vesicles appear suddenly, mostly in areas of active dermatitis. The lesions are sometimes umbilicated and appear in crops, resembling smallpox or chickenpox. The onset is sudden, and fresh vesicles appear for several days. Scarring is common. Often, cervical adenopathy and fever occur, and affected persons are systemically ill (unlike those with generalized vaccinia). Secondary bacterial infection can complicate eczema vaccinatum. The mortality rate for eczema vaccinatum is 30–40% if untreated. VIGIV reduces mortality to 7%. Multiple doses of VIGIV and perhaps treatment with effective antivirals may be required.

### Progressive vaccinia (vaccinia necrosum, vaccinia gangrenosum)

Progressive vaccinia is a rare, severe, and often fatal complication of vaccination that occurs in immunodeficient persons. Most cases occur when infants with undiagnosed immunodeficiency are immunized. The initial vaccination site continues to progress and fails to heal after more than 15 days. The vaccination site is characterized by a painless but progressive necrosis and ulceration (Fig. 19-29), with or without metastatic lesions to distant sites (skin, bones, viscera). No inflammation is present at the sites of infection, even histologically. Untreated progressive vaccinia is virtually always fatal. Progressive vaccinia is diagnosed by skin biopsy, viral culture, or PCR. VIGIV should be given, and antiviral antibiotics available from the CDC have been effective in this rare condition.

### Cutaneous immunologic complications

A spectrum of erythematous eruptions follows vaccination. These eruptions are more common than generalized vaccinia, with which they are often confused. Cases of Stevens-Johnson



syndrome after vaccination have been seen in the past, primarily in children, but apparently are rare in adult vaccinees.

### **Benign hypersensitivity reactions to vaccinia**

About 0.08% of vaccinees will develop a diffuse cutaneous eruption during the second week after vaccination, around the peak of the immunization site reaction. These reactions have been classified as exanthematous (by far the most common), urticarial, and erythema multiforme (EM)-like (the most rare). A follicular eruption has also been reported (see next section). All these reaction patterns evolve over 1–2 days and resolve over days. Patients may have mild symptoms but are afebrile. At times, the eruption may evolve from around the inoculation site and generalize, called “roseola vaccinia” in the past. Primary vaccinees are more likely to develop these reactions. Histology is nonspecific, showing features of a viral exanthem (mild spongiotic dermatitis). These reactions are distinguished from generalized vaccinia by a later onset (end of second week vs. days 6–9 after vaccination), prominent erythema, lack of vesicles and pustules, and negative laboratory testing for vaccinia virus. The eruptions described as EM-like lack mucosal involvement and blistering and more closely resemble urticaria multiforme (see Chapter 7). They are distinguished from EM/Stevens-Johnson syndrome by the absence of atypical purpuric or typical targetoid lesions, lack of mucosal involvement, and histologic evaluation.

### **Postvaccination follicular eruption**

A generalized variant of the eruption occurred in 2.7% of new vaccinees and a localized variant in 7.4% during a trial of Aventis Pasteur smallpox vaccine. In the second week, 9–11 days after vaccination, multiple follicular, erythematous papules appeared, primarily on the face, trunk, and proximal extremities. Lesions were mildly pruritic. Over several days, the lesions evolved to pustules, which resolved without scarring. Lesions were simultaneously at different stages of development. The number of lesions was usually limited and rarely exceeded 50. Lesions spontaneously resolved over a few days. Histologic evaluation revealed a suppurative folliculitis. No virus was detected in the lesions by PCR or viral culture.

### **Other skin lesions at vaccination scars**

Melanomas, basal cell carcinomas, and squamous cell carcinomas have all occurred in vaccination scars. Benign lesions with a tendency to occur in scars, such as dermatofibromas, sarcoidosis, and granuloma annulare, also can occur in vaccination scars.

**Bessinger GT, et al:** Benign hypersensitivity reactions to smallpox vaccine. *Int J Dermatol* 2007; 46:460.

**Bruner DI, Butler BS:** Smallpox vaccination-associated myopericarditis is more common with the newest smallpox vaccination. *J Emerg Med* 2014; 46:e85.

**Bunick CG, et al:** Expanding the histologic findings in smallpox-related post-vaccinial non-viral folliculitis. *J Cutan Pathol* 2013; 40:305.

**Centers for Disease Control and Prevention:** Secondary and tertiary transmission of vaccinia virus after sexual contact with a smallpox vaccine—San Diego, California, 2012. *MMWR* 2013; 62:145.

**Curry JL, et al:** Occurrence of a basal cell carcinoma and dermatofibroma in a smallpox vaccination scar. *Dermatol Surg* 2008; 34:132.

**De Assis FL, et al:** Reemergence of vaccinia virus during zoonotic outbreak, Pará State, Brazil. *Emerg Infect Dis* 2013; 19:2017.

**Hammarlund E, et al:** Traditional smallpox vaccination with reduced risk of inadvertent contact spread by administration of povidone iodine ointment. *Vaccine* 2008; 26:430.

**Hivnor C, James W:** Autoinoculation vaccinia. *J Am Acad Dermatol* 2003; 50:139.

**Montgomery JR, et al:** Case report: chest pain in service members following smallpox vaccination. *MSMR* 2012; 19:6.

## **Human monkeypox**

Human monkeypox (virus, MPXV), caused by an orthopoxvirus, is a sporadic zoonosis that occurs in remote areas of the tropical rainforests in central and western Africa, primarily the Democratic Republic of Congo. The mortality rate is 1–8%. The number of cases has dramatically increased since the 1980s. The main vector for monkeypox is wild African rodents and monkeys. Humans are accidental hosts. Direct contact with an infected animal or person appears to be required to acquire the infection. In Africa, more than 90% of cases occur in children under 15 years of age, in whom the fatality rate is 11%. The secondary attack rate in African households is 10–12%. An outbreak of 81 cases of monkeypox occurred in the United States. Prairie dogs became infected when housed with infected African rodents. Persons who purchased the prairie dogs become infected, most frequently through bites or scratches or areas of damaged skin. The pattern of monkeypox seen in the U.S. cases was different from that of African cases; transmission was believed to be by inoculation, and many of the affected persons were previously immunized with vaccinia. Primary skin lesions occurred at sites of inoculation and limited spread occurred thereafter, with the appearance of 1–50 additional satellite and disseminated lesions over several days. Patients often had fever, respiratory symptoms, and characteristic lymphadenopathy (67%). About one-quarter required hospitalization, and only two children had serious clinical illness, one with encephalitis and one with severe oropharyngeal lesions.

In Africa, monkeypox is clinically similar to smallpox, with an incubation period of 10–14 days. Patients develop headache (100%); fever, sweats, and chills (82%); and lymphadenopathy (90%). Lymphadenopathy is not a feature of smallpox. The prodrome lasts 2 days, followed by the appearance of 2–5 mm papules. The lesions spread centrifugally and progress from papules to vesicles, then pustules all in 14–21 days. In 80% of patients, the lesions are largely monomorphic but are more pleomorphic than smallpox. The distribution is generalized, and the buccal mucosa can be affected. Lesions resolve with hemorrhagic crusts. The disease is self-limited. It is less severe in persons previously vaccinated against smallpox.

## **Buffalopoxvirus**

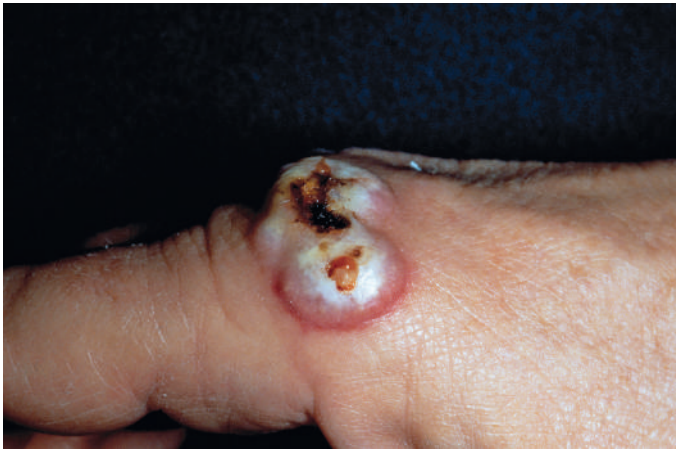Buffalopoxvirus (BPXV) is an orthopoxvirus closely related to VACV. It affects buffalo, cows, and humans, and multiple outbreaks have occurred in India. Wild rodents are probably the natural reservoir. Lesions occur on the hands and arms of animal handlers and resemble a milder form of cowpox. Family members may be affected, and children have developed lesions resembling eczema vaccinatum.

## **Zoonotic poxvirus infections**

The diagnosis of zoonotic poxvirus infection is usually by epidemiologic history, clinical features, and electron microscopy, which can separate the various poxvirus genera. Laboratory culture is slow, and PCR analysis of the viral DNA allows for speciation. Rarely is antiviral therapy indicated; most diseases are self-limited. Cidofovir would be thought to have activity against the zoonotic poxviruses.

## **Cowpox**

Cowpox (virus, CPXV) is an orthopoxvirus that is geographically restricted to the UK, Europe, Russia, and adjacent states. It is largely a zoonosis that rarely affects cattle. The domestic



**Fig. 19-30** Milker's nodule.

cat is the usual source of human infection. Cats acquire infection from wild animal reservoirs (small wild rodents such as mice and voles). Lesions first appear on the head and then on the paws and ears. Feline infection may be asymptomatic, or the cat may be very ill. Most human cases occur in the late summer and in fall. The recent popularity of pet rats in Europe has led to several cases of rat-to-human transmission of CPXV, especially in children too young to have received smallpox vaccination.

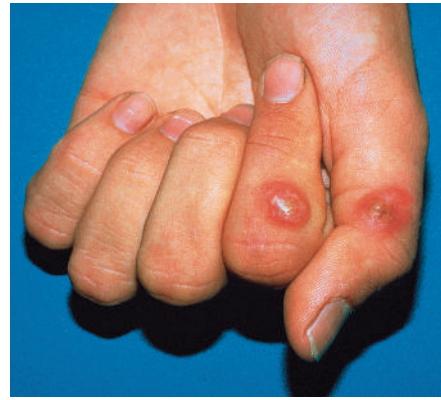The incubation period of CPXV is about 7 days. There is then an abrupt onset of fever, malaise, headache, and muscle pain. Lesions are usually solitary (72%), with co-primary lesions in 25% of cases. Lesions occur on the hands and fingers in half the cases and the face in another third. Pet rats seem to infect children usually on the neck. Secondary lesions are uncommon and generalized disease is rare, usually occurring in patients with atopic dermatitis and Darier's disease. The lesion progresses from a macule through a vesicular stage, then a pustule that becomes blue-purple and hemorrhagic. A hard, painful, 1–3 cm, indurated eschar develops after 2–3 weeks and may resemble cutaneous anthrax. In anthrax, however, the eschar forms by day 6. Lesions are always painful, and there is local lymphadenopathy, which is usually tender. The amount of surrounding edema and induration is much more marked than in orf. Patients are systemically ill until the eschar stage. Healing usually takes 6–8 weeks. Scarring is common after cowpox.

## Farmyard pox

Because closely related parapoxviruses of sheep and cattle cause similar disease in humans, orf and milker's nodules have been collectively called farmyard pox. The epidemiologic features are discussed separately, but the clinical and histologic features, which are identical, are discussed jointly. The diagnosis of these infections is based on taking an accurate history and can virtually always be confirmed by routine histologic evaluation.

### ***Bovine-associated parapoxvirus infections: milker's nodules, bovine papular stomatitis (BPSV), and pseudocowpox (PCPV)***

Bovine-associated parapoxvirus infections cause worldwide occupational disease of milkers or veterinarians, most often transmitted directly from the udders (milker's nodules) or muzzles (bovine papular stomatitis) of infected cows. Lesions are usually solitary or few in number and are confined to the hands or forearms (Fig. 19-30). Numerous lesions have been reported in healing first-degree and second-degree burns in



**Fig. 19-31** Orf.

milker's nodules. These cases occurred on farms with infected cattle, but the patients had not had direct contact with the cattle, suggesting indirect viral transmission.

## Orf

Also known as *ecthyma contagiosum*, orf is a common disease in goat-farming and sheep-farming regions throughout the world. Direct transmission from active lesions on lambs is most common, but infection from fomites also frequently occurs because the virus is resistant to heat and dryness. Autoinoculation to the genital area can occur, but human-to-human transmission is rare. One patient receiving etanercept developed a giant lesion and progressive disease. He was successfully treated with surgical removal, cryotherapy, and topical imiquimod, with discontinuation of the etanercept.

### **Clinical features**

The incubation period for farmyard pox is about 1 week. Lesions are usually solitary and occur on the hands, fingers (Fig. 19-31), or face. Lesions evolve through the following six stages:

1. A papule forms, which then becomes a target lesion with a red center surrounded by a white ring and then a red halo.
2. In the acute stage, a red, weeping nodule appears, resembling pyogenic granuloma.
3. In a hairy area, temporary alopecia ensues.
4. In the regenerative stage, the lesion becomes dry with black dots on the surface.
5. The nodule then becomes papillomatous.
6. The nodule finally flattens to form a dry crust, eventually healing.

Lesions are usually about 1 cm in diameter, except in immunosuppressed patients, in whom giant lesions may occur. Spontaneous resolution occurs in about 6 weeks, leaving minimal scarring. Mild swelling, fever, pain, and lymphadenitis may accompany the lesions, but these symptoms are milder than those seen in cowpox. Orf may be associated with an EM-like eruption in about 5% of patients. Treatment is supportive, although shave excision may accelerate healing. Topical cidofovir and imiquimod have been effective.

### **Histologic features**

Histologic features of farmyard pox correlate with the clinical stage. Nodules show a characteristic pseudoepitheliomatous hyperplasia covered by a parakeratotic crust. Keratinocytes always demonstrate viropathic changes of nuclear vacuolization and cytoplasmic, 3–5 μm, eosinophilic inclusions surrounded by a pale halo. The papillary dermis is severely edematous. The dermal infiltrate, which is dense and extends from the interface to the deep dermis, consists of lymphocytes, histiocytes, neutrophils, and eosinophils. Massive capillary proliferation and dilation are present in the upper dermis.



## Human tanapox

Tanapox infection is a yatapoxvirus infection endemic to equatorial Africa. It is spread from its natural hosts, nonhuman primates, through minor trauma. Human-to-human transmission is rare. Tanapox infection is manifested by mild fever of abrupt onset lasting 3–4 days, followed by the appearance of one or two pock lesions. Lesions are firm and cheesy, resembling cysts. The disease is self-limited, and smallpox vaccination would not be expected to be protective. Rare cases have been imported into Europe and the United States.

- Assis FL, et al:** Group 2 vaccinia virus, Brazil. *Emerg Infect Dis* 2012; 18:2035.
- Blacklaws BA, et al:** Molecular characterization of poxviruses associated with tattoo skin lesions in UK cetaceans. *PLoS One* 2013; 8:e71734.
- Cann JA, et al:** Comparative pathology of smallpox and monkeypox in man and macaques. *J Comp Pathol* 2013; 148:6.
- Centers for Disease Control and Prevention:** Update: multistate outbreak of monkeypox—Illinois, Indiana, Kansas, Missouri, Ohio, and Wisconsin, 2003. *Arch Dermatol* 2003; 139:1229.
- Damon IK:** Status of human monkeypox: clinical disease, epidemiology and research. *Vaccine* 2011; 29:5:D54.
- Dhar AD, et al:** Tanapox infection in a college student. *N Engl J Med* 2004; 350:361.
- Dina J, et al:** Genital ulcerations due to a cowpox virus: a misleading diagnosis of herpes. *J Clin Virol* 2011; 50:345.
- Elsendoorn A, et al:** Severe ear chondritis due to cowpox virus transmitted by a pet rat. *J Infect* 2011; 63:391.
- Favier A, et al:** Necrotic ulcerated lesion in a young boy caused by cowpox virus infection. *Case Rep Dermatol* 2011; 3:186.
- Haase O, et al:** Generalized cowpox infection in a patient with Darier disease. *Br J Dermatol* 2011; 164:1107.
- Herder V, et al:** Poxvirus infection in a cat with presumptive human transmission. *Vet Dermatol* 2011; 22:220.
- Koufakis T, et al:** Orf disease: a report of a case. *Braz J Infect Dis* 2014; 18:568.
- Lederman ER, et al:** Progressive vaccinia: case description and laboratory-guided therapy with vaccinia immune globulin, ST-246, and CMX001. *J Infect Dis* 2012; 206:1372.
- Lieu TJ, et al:** Photo quiz: a generalized eruption in a rancher. *Clin Infect Dis* 2013; 56:1613.
- MacNeil A, et al:** Diagnosis of bovine-associated parapoxvirus infections in humans: molecular and epidemiological evidence. *Zoonoses Public Health* 2010; 57:e161.
- McCollum AM, Damon IK:** Human monkeypox. *Clin Infect Dis* 2014; 58:260.
- McCollum AM, et al:** Investigation of the first laboratory-acquired human cowpox virus infection in the United States. *J Infect Dis* 2012; 206:63.
- Nougairede A, et al:** Sheep-to-human transmission of orf virus during Eid al-Adha religious practices, France. *Emerg Infect Dis* 2013; 19:102.
- Orgaz-Molina J, et al:** Multiple finger nodules and an erythematous rash: a case study. *Aust Fam Physician*. 2012; 41:885.
- Quenelle DC, et al:** Cutaneous infections of mice with vaccinia or cowpox viruses and efficacy of cidofovir. *Antiviral Res* 2004; 63:33.
- Rørdam OM, et al:** Giant orf with prolonged recovery in a patient with psoriatic arthritis treated with etanercept. *Acta Derm Venereol* 2013; 93:487.
- Reynolds MG, Damon IK:** Outbreaks of human monkeypox after cessation of smallpox vaccination. *Trends Microbiol* 2012; 20:80.
- Rütten A, et al:** Acute circumscribed necrosis on the left cheek in a 19-year-old woman. *J Dtsch Dermatol Ges* 2012; 10:843.
- Schupp CJ, et al:** A 14-year-old girl with a vesicle on her finger and lymphadenitis. *J Clin Virol* 2011; 50:1.
- Shchelkunov SN:** An increasing danger of zoonotic orthopoxvirus infection. *PLoS Pathog* 2013; 9:e1003756.
- Simmons JF, et al:** Painless, red nodule on the finger of a veterinary student. *Am Fam Physician* 2012; 86:77.
- Turan E, et al:** A case of orf (ecthyma contagiosum) with multiple lesions. *J Pak Med Assoc* 2013; 63:786.
- Vogel S, et al:** The Munich outbreak of cutaneous cowpox infection: transmission by infected pet rats. *Acta Derm Venereol* 2012; 92; 126.
- Zijlstra M, et al:** *BMJ Case Rep* 2013; 2013 Sep 2.

## Molluscum contagiosum

Molluscum contagiosum (MC) is caused by up to four closely related types of poxvirus, MCV-1 to MCV-4, and their variants. Although the proportion of infection caused by the various types varies geographically, MCV-1 infections are most common worldwide. In small children, virtually all infections are caused by MCV-1. There is no difference in the anatomic region of isolation with regard to infecting type, in contrast to HSV, for example. In patients infected with HIV, however, MCV-2 causes the majority of infections (60%), suggesting that HIV-associated molluscum does not represent recrudescence of childhood molluscum.

Infection with MCV is worldwide and increasing. Three groups are primarily affected: young children (highest in ages 1–4 years), sexually active young adults (ages 20–29), and immunosuppressed persons, especially those with HIV infection. MC is most easily transmitted by direct skin-to-skin contact, especially if the skin is wet. Bathing with affected siblings may be a risk factor. Swimming pools have been associated with infection, sometimes even plantar lesions.

In all forms of MC infection, the lesions are relatively similar. Individual lesions are smooth-surfaced, firm, dome-shaped, pearly papules, averaging 3–5 mm in diameter (Fig. 19-32). “Giant” lesions may be up to several centimeters in diameter. A central umbilication is characteristic. Irritated lesions may become crusted and even pustular, simulating secondary bacterial infection. This may precede spontaneous resolution. Lesions that rupture into the dermis may elicit a marked suppurative inflammatory reaction that resembles an abscess.

The clinical pattern depends on the risk group affected. In young children, the lesions are usually generalized and number from a few to more than 100. Lesions tend to be on the face, trunk, and extremities. Genital lesions, as part of a wider distribution, occur in 10% of childhood cases. When MC is restricted to the genital area in a child, sexual abuse must be considered. Children with atopic dermatitis (AD), either active or inactive, are four times more likely than nonatopic children to have more than 50 lesions. Transmission from the mother’s skin can occur during vaginal delivery and may be associated with presentation in the first few months of life.

Several forms of inflammation occur in children with MC. The most common inflammatory response, seen in 40% of affected children, is “molluscum dermatitis.” More common in atopic children, it is a mild, eczematous eruption surrounding the individual lesions. This is *not* associated with more rapid resolution of the MC, and treatment of this dermatitis with topical corticosteroids does not appear to lead to increased MC. Inflamed MC is characterized by erythema and swelling

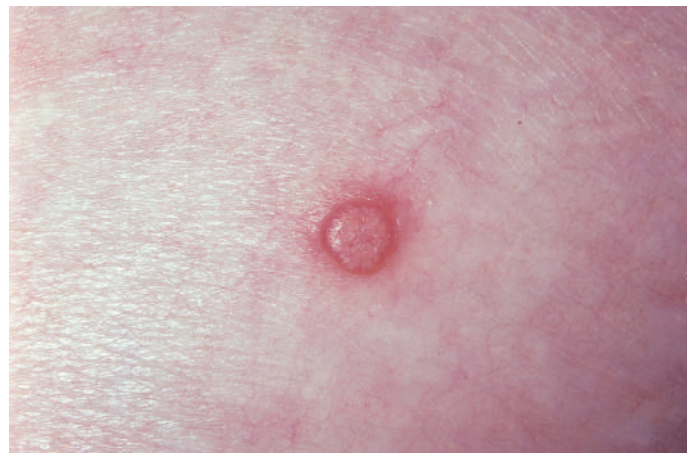
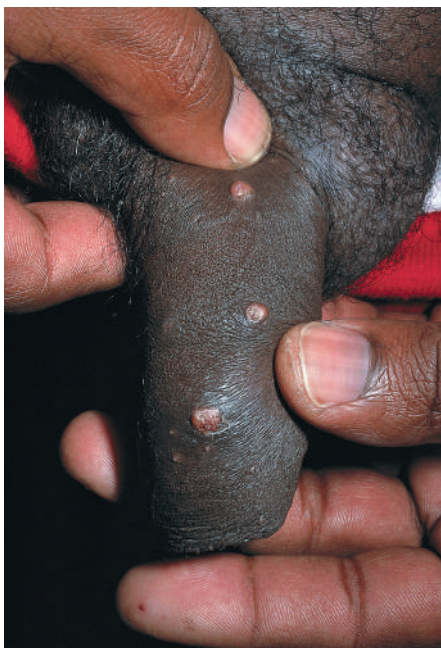
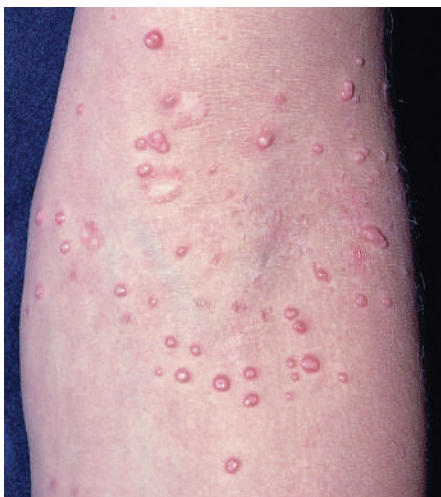Fig. 19-32 Molluscum contagiosum.



**Fig. 19-33** Molluscum contagiosum of the penis.



**Fig. 19-34** Molluscum contagiosum in child with atopic dermatitis.

of the individual lesions, sometimes with pustulation or fluctuance. It occurs in 20% of children with MC and usually heralds the resolution of disease. The rarest inflammatory response is a GCS-like reaction, occurring in 5% of children with MC. It presents as numerous edematous, erythematous papules or papulovesicles distant from the MC lesions and favors the elbows and knees, but also affects the buttocks and face. Pruritus is prominent.

In adults, MC is sexually transmitted, and other STDs may coexist. There are usually fewer than 20 lesions; these favor the lower abdomen, upper thighs, and penile shaft in men (Fig. 19-33). Pubic hair removal by shaving, clipping, or waxing is a risk factor for acquiring MC by sexual contact. Mucosal involvement is very uncommon.

Immunosuppression, either systemic T-cell immunosuppression (usually HIV, but also sarcoidosis, immunosuppressive medications, and malignancies) or abnormal cutaneous immunity (as in atopic dermatitis or topical steroid use), predisposes the individual to infection. In AD patients, lesions tend to be confined to dermatitic skin (Fig. 19-34).

Secondary infection may occur, but most inflamed MC are *not* infected, but rather undergoing spontaneous involution by the immune response. Rarely, erythema annulare

centrifugum may be associated with MC. Lesions on the eyelid margin or conjunctiva may be associated with a conjunctivitis or keratitis. Rarely, the molluscum lesions may present as a cutaneous horn. Between 10% and 30% of AIDS patients not receiving antiretroviral therapy (ART) have MC. Virtually all HIV-infected patients with MC already have an AIDS diagnosis and a helper T-cell (Th) count of less than 100. In untreated HIV disease, lesions favor the face (especially the cheeks, neck, and eyelids) and genitalia. Lesions may be few or numerous, forming confluent plaques. Giant lesions can occur and may be confused with a skin cancer. Involvement of the oral and genital mucosa may occur, virtually always indicative of advanced AIDS (Th count <50). Facial disfigurement with numerous lesions can occur. Recurrence or new appearance of MC may be seen in AIDS patients starting ART as a part of IRIS.

Molluscum contagiosum has a characteristic histopathology. Lesions primarily affect the follicular epithelium. The lesion is acanthotic and cup shaped. In the cytoplasm of the prickle cells, numerous small, eosinophilic and later basophilic inclusion bodies form, called molluscum bodies or Henderson-Paterson bodies. Eventually, their bulk compresses the nucleus to the side of the cell. In the fully developed lesion, each lobule empties into a central crater. Inflammatory changes are slight or absent. Characteristic brick-shaped poxvirus particles are seen on electron microscopy in the epidermis. Latent infection has not been found, except in untreated AIDS patients, in whom even normal-appearing skin may contain viral particles. Resolving and inflamed lesions may contain a dense inflammatory infiltrate of lymphocytes and neutrophils. Some of the lymphocytes may be large and CD30 positive. MCV contains an IL-18-binding protein gene that it apparently acquired from humans. This blocks the host's initial effective Th1 immune response against the virus by reducing local IFN- $\gamma$  production.

The diagnosis of MC is easily established in most cases because of the distinctive central umbilication of the dome-shaped lesion. This may be enhanced by light cryotherapy, which leaves the umbilication appearing clear against a white (frozen) background. For confirmation, the pasty core of a lesion is expressed, squashed between two microscope slides (or slide and coverslip), and stained with Wright, Giemsa, or Gram. Firm compression between the slides is required.

Treatment is determined by the clinical setting. In young immunocompetent children, especially those with numerous lesions, the most practical course may be *not* to treat or to use only topical tretinoin. Aggressive treatment may be emotionally traumatic and can cause scarring. Spontaneous resolution is virtually a certainty in this setting, avoiding these sequelae. Individual lesions last 2–4 months each; duration of infection is about 2 years. Continuous application of surgical tape to each lesion daily after bathing for 16 weeks led to cure in 90% of children. Topical cantharidin, applied for 4–6 h to approximately 20 lesions per setting, led to resolution in 90% of patients, and 8% of patients improved. This therapy is well tolerated, has a very high satisfaction rate for patients and their parents, and complications are rare. If lesions are limited and the child is cooperative, nicking the lesions with a blade to express the core (with or without comedo extractor), squeezing the lesion with a tissue forceps, light cryotherapy, application of trichloroacetic acid (TCA, 35–100%), and removal by curettage are all alternatives. The application of lidocaine-prilocaine (EMLA) cream for 1 h before any painful treatments has made the management of MC in children much easier. No controlled trials have confirmed the efficacy of imiquimod, and two large trials have shown that it is no more effective than placebo; it cannot be recommended for MC treatment. Intralesional immunotherapy with candidal antigen injections



in up to three lesions led to complete resolution of all lesions in 55% of children. Oral cimetidine has been similarly used for its immunomodulatory effects. Hydrogen peroxide 1% cream, ingenol mebutate, pulse dye laser, and potassium hydroxide 10% are other reported therapies.

In adults with genital molluscum, removal by cryotherapy or curettage is very effective. Neither imiquimod nor podophyllotoxin has been demonstrated to be effective. In fact, the failure of these agents to improve “genital warts” suggests the diagnosis of genital MC. Sexual partners should be examined; screening for coexistent STDs is mandatory.

In patients with AD, application of EMLA followed by curettage or cryotherapy is most practical. Caustic chemicals should not be used on atopic skin. Topical corticosteroid application to the area should be reduced to the minimum strength possible. In immunosuppressed patients, especially those with AIDS, management of MC can be difficult. Aggressive treatment of the HIV infection with ART, if it leads to improvement of the Th count, is predictably associated with a dramatic resolution of the lesions. This response is delayed 6–8 months from the institution of treatment, so reports of resolution with certain agents in the HIV patient is confounded by the coexistent ART therapy, which is probably the active component of the treatment cocktail. MC occurs frequently in the beard area, so shaving with a blade razor should be discontinued to prevent its spread. If lesions are few, curettage or core removal with a blade and comedo extractor is most effective. EMLA application may permit treatment without local anesthesia. Cantharone or TCA may be applied to individual lesions. Temporary dyspigmentation and slight surface irregularities may occur. Cryotherapy may be effective but must be used with caution in persons of color. When lesions are numerous or confluent, treatment of the whole affected area may be required because of possible latent infection. TCA peels above 35% concentration (medium depth) or daily applications of 5-fluorouracil (5-FU) to the point of skin erosion may eradicate lesions, at least temporarily. At times, removal by curette is required. In patients with HIV infection, continuous application of tretinoin cream once nightly at the highest concentration tolerated seems to reduce the rate of appearance of new lesions. Topical 1–3% cidofovir application and systemic infusion of this agent have been reported to lead to dramatic resolution of molluscum in patients with AIDS.

**Arora S, et al:** Idiopathic CD4 lymphocytopenia presenting as recurrent giant molluscum contagiosum. *Indian J Dermatol Venereol Leprol* 2013; 79:555.

**Bansal S, et al:** Disseminated molluscum contagiosum in a patient on methotrexate therapy for psoriasis. *Indian J Dermatol Venereol Leprol* 2014; 80:179.

**Berbegal-DeGracia L:** Neonatal molluscum contagiosum: five new cases and a literature review. *Australas J Dermatol* 2013; Dec 18. [Epub ahead of print.]

**Berger EM, et al:** Experience with molluscum contagiosum and associated inflammatory reactions in a pediatric dermatology practice. *Arch Dermatol* 2012; 148:1257.

**Butala N, et al:** Molluscum BOTE sign: a predictor of imminent resolution. *Pediatrics* 2013; 131:e1650.

**Can B, et al:** Treatment of pediatric molluscum contagiosum with 10% potassium hydroxide solution. *J Dermatolog Treat* 2014; 25:246.

**Chen X, et al:** Molluscum contagiosum virus infection. *Lancet Infect Dis* 2013; 13:877.

**Cohen PR, Tschen JA:** Plantar molluscum contagiosum: a case report of molluscum contagiosum occurring on the sole of the foot and a review of the world literature. *Cutis* 2012; 90:35.

**Desreuelles F, et al:** Pubic hair removal: a risk factor for “minor” STI such as molluscum contagiosum. *Sex Transm Infect* 2013; 89:212.

**Drain PK, et al:** Recurrent giant molluscum contagiosum immune reconstitution inflammatory syndrome (IRIS) after initiation of antiretroviral therapy in an HIV-infected man. *Int J STDS AIDS* 2014; 25:235.

**Enns LL, Evans MS:** Intralesional immunotherapy with *Candida* antigen for the treatment of molluscum contagiosum in children. *Pediatr Dermatol* 2011; 28:254.

**Erickson C, et al:** Efficacy of intravenous cidofovir in the treatment of giant molluscum contagiosum in a patient with human immunodeficiency virus. *Arch Dermatol* 2011; 147:652.

**Foissac M, et al:** Efficacy and safety of intravenous cidofovir in the treatment of giant molluscum contagiosum in an immunosuppressed patient. *Ann Dermatol Venereol* 2014; 141:620.

**Heng YK, et al:** Verrucous plaques in a pemphigus vulgaris patient on immunosuppressive therapy. *Int J Dermatol* 2012; 51:1044.

**Hoyt BS, et al:** Molluscum contagiosum of the areola and nipple: case report and literature review. *Dermatol Online J* 2013; 19:18965.

**Javed S, Tying SK:** Treatment of molluscum contagiosum with ingenol mebutate. *J Am Acad Dermatol* 2014; 70:e105.

**Katz, KA:** Imiquimod is not an effective drug for molluscum contagiosum. *Lancet* 2014; 14:372.

**Kim MS, et al:** Atypical molluscum contagiosum accompanied by CD30-positive lymphoid infiltrates. *Pediatr Dermatol* 2013; 30:141.

**Lao M, et al:** Safe and speedy cantharidin application. *J Am Acad Dermatol* 2013; 69:e47.

**Le Treut C, et al:** Molluscum contagiosum surrounded by a white halo and Sezary syndrome. *J Eur Acad Dermatol Venereol* 2014 [Epub Ahead of Print.]

**McCollum AM, et al:** Molluscum contagiosum in a pediatric American Indian population: incidence and risk factors. *PLoS One* 2014; 9:e103419.

**Moye VA, et al:** Safety of cantharidin: a retrospective review of cantharidin treatment in 405 children with molluscum contagiosum. *Pediatr Dermatol* 2014; 13:458.

**Nguyen HP, et al:** Treatment of molluscum contagiosum in adult, pediatric, and immunodeficient populations. *J Cutan Med Surg* 2014; 18:299.

**Olsen JR, et al:** Epidemiology of molluscum contagiosum in children: a systematic review. *Fam Pract* 2014; 31:130.

**Omi T, et al:** Recalcitrant molluscum contagiosum successfully treated with the pulsed dye laser. *Laser Ther* 2013; 22:51.

**Osio A, et al:** Clinical characteristics of molluscum contagiosum in children in a private dermatology practice in the greater Paris area, France: a prospective study in 661 patients. *Dermatology* 2011; 222:314.

**Pereira de Carvalho CH, et al:** Intraoral molluscum contagiosum in a young immunocompetent patient. *Oral Surg Oral Med Oral Pathol Oral Radiol* 2012; 114:e57.

**Pompei DT, et al:** Cantharidin therapy: practice patterns and attitudes of health care providers. *J Am Acad Dermatol* 2013; 68:1045.

**Potassium hydroxide 5%** for the treatment of molluscum contagiosum. *Drug Ther Bull* 2014; 52:118.

**Semkova K, et al:** Hydrogen peroxide 1% cream under occlusion for treatment of molluscum contagiosum in an 8-month-old infant: an effective and safe treatment option. *Clin Exp Dermatol* 2014; 39:560.

**Shinkai K, Fox LP:** The diagnosis: inflamed molluscum contagiosum as a manifestation of immune reconstitution inflammatory syndrome. *Cutis* 2012; 89:219.

**Siah TW, et al:** Gross generalized molluscum contagiosum in a patient with autosomal recessive hyper-IgE syndrome, which resolved spontaneously after haematopoietic stem-cell transplantation. *Clin Exp Dermatol* 2013; 38:197.

**Sim JH, Lee ES:** Molluscum contagiosum presenting as a cutaneous horn. *Ann Dermatol* 2011; 23:262.

**Van der Wouden JC, et al:** Interventions for cutaneous molluscum contagiosum. *Cochrane Database Syst Rev* 2009; 4:CD004767.

**Villa L, et al:** Molluscum contagiosum: a 20-year study in a sexually transmitted infections unit. *Sex Transm Dis* 2010; 37:423.

**Woldow AB, et al:** The diagnosis: molluscum contagiosum on the sole of the foot. *Cutis* 2011; 87:172.

**Xiang Y, Moss B:** Molluscum contagiosum virus interleukin-18 (IL-18) binding protein is secreted as a full-length form that binds cell surface glycosaminoglycans through the C-terminal tail and a furin-cleaved form with only IL-18 binding domain. *J Virol* 2003; 77:2623.

## PICORNAVIRUS GROUP

Picornavirus designates viruses that were originally called enteroviruses (polioviruses, coxsackieviruses, and echoviruses), plus the rhinoviruses. The picornaviruses are small,

ssRNA, icosahedral viruses varying in size from 24 to 30 nm. Only the coxsackieviruses, echoviruses, and enterovirus types 70 and 71 are significant causes of skin disease.

## Enterovirus infections

Person-to-person transmission occurs by the intestinal-oral route and less often the oral-oral or respiratory routes. Enteroviruses are identified by type-specific antigens. The type-specific antibodies appear in the blood about 1 week after infection has occurred and attain their maximum titer in 3 weeks. Viral cultures obtained from the rectum, pharynx, eye, and nose may isolate the infecting agent. Usually, the diagnosis is by clinical characteristics, and except in specific clinical settings, the causative virus is not identified. Enteroviral infections most frequently occur in children between ages 6 months and 6 years.

Many nonspecific exanthems and exanthems that occur during the summer and early fall are caused by coxsackievirus or echovirus. The exanthems most typically are diffuse macular or morbilliform erythemas, which sometimes also contain vesicular lesions or petechial or purpuric areas. Echovirus 9 has caused an eruption resembling acute meningococcemia. Each type of exanthem has been associated with many subtypes of coxsackievirus or echovirus (one exanthem, many possible viral causes). Echovirus 9, the most prevalent enterovirus, causes a morbilliform exanthem, initially on the face and neck, then the trunk and extremities. Only occasionally is there an eruption on the palms and soles. Small, red or white lesions on the soft palate may occur. The most common specific eruptions caused by enteroviruses are hand-foot-and-mouth disease, herpangina, and roseola-like illnesses. Rare reported presentations of enterovirus infection include a unilateral vesicular eruption simulating herpes zoster, caused by echovirus 6; a fatal dermatomyositis-like illness in a patient with hypogammaglobulinemia, caused by echovirus 24; and a widespread vesicular eruption in AD that simulated Kaposi varicelliform eruption, caused by coxsackievirus A16. Pleconaril and other new antienteroviral agents may be useful in severe enteroviral infections.

Although the cutaneous eruptions caused by these viruses are quite benign, infections with enterovirus 71 can be severe, with the development of brainstem encephalitis and fatal neurogenic pulmonary edema, as well as ascending flaccid paralysis resembling poliomyelitis. Epidemics with severe disease have been reported in Bulgaria, Hungary, Hong Kong, Japan, Australia, Malaysia, and Singapore. Taiwan had the worst epidemic, affecting more than 1 million people with 78 deaths in 1998.

## Herpangina

Herpangina, a disease of children worldwide, is caused by multiple types of coxsackievirus (most frequently A8, A10, and A16), echoviruses, and enterovirus 71. In the severe outbreaks in Taiwan, 10% of patients with fatal cases had herpangina. It begins with acute onset of fever, headache, sore throat, dysphagia, anorexia, and sometimes, stiff neck. The most significant finding, which is present in all patients, is one or more yellowish white, slightly raised, 2-mm vesicles in the throat, usually surrounded by an intense areola (Fig. 19-35). The lesions are found most frequently on the anterior faucial pillars, tonsils, uvula, or soft palate. Only one or two lesions might appear during the course of the illness, or the entire visible pharynx may be studded with them. The lesions often occur in small clusters and later coalesce. Usually, the individual or coalescent vesicles ulcerate, leaving a shallow, punched-out, grayish yellow crater 2–4 mm in diameter. The

lesions disappear in 5–10 days. Treatment is supportive, consisting of topical anesthetics.

Herpangina is differentiated from aphthosis and primary herpetic gingivostomatitis by the location of the lesions in the posterior oropharynx and by isolation of an enterovirus. Coxsackievirus A10 causes acute lymphonodular pharyngitis, a variant of herpangina, characterized by discrete, yellow-white papules in the same distribution as herpangina.

## Hand-foot-and-mouth disease

Hand-foot-and-mouth disease (HFMD) is usually a mild illness caused primarily by coxsackievirus A16, but also other coxsackie A and B viruses, as well as enterovirus 71. It primarily affects children age 2–10 years, but exposed adults may also develop disease. Infection begins with a fever and sore mouth. In 90% of patients, oral lesions develop; these consist of small (4–8 mm), rapidly ulcerating vesicles surrounded by a red areola on the buccal mucosa, tongue, soft palate, and gingiva. Lesions on the hands and feet are asymptomatic red papules that quickly become small, gray, 3–7 mm vesicles surrounded by a red halo. They are often oval, linear, or crescentic and run parallel to the skin lines on the fingers and toes (Fig. 19-36). They are distributed sparsely on the dorsa of the fingers and toes and more frequently on the palms and soles. Especially in children who wear diapers, vesicles and erythematous, edematous papules may occur on the buttocks

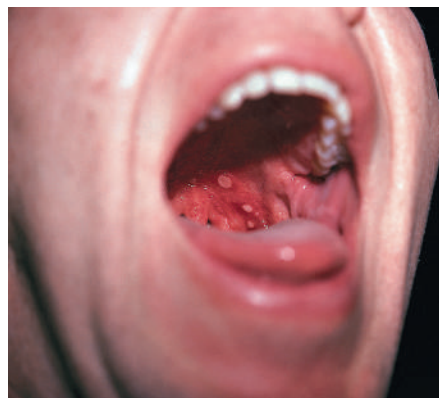

Fig. 19-35 Herpangina.

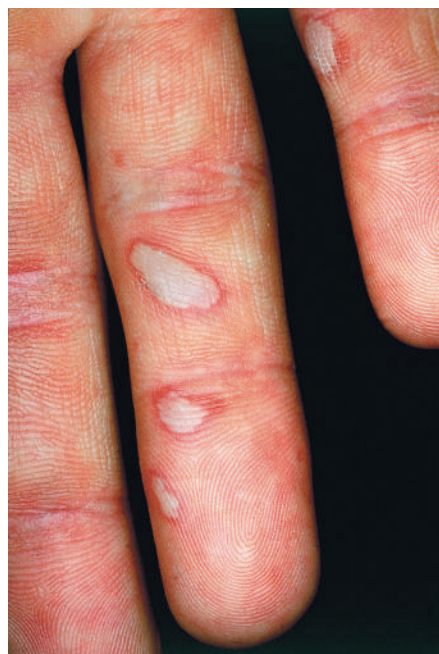
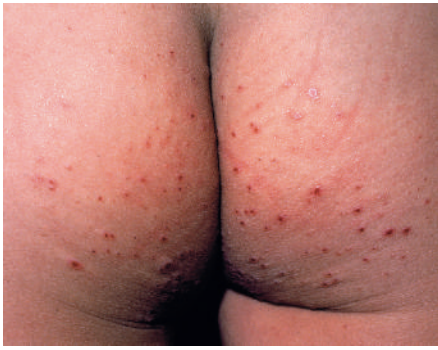
Fig. 19-36 Hand-foot-and-mouth disease.





**Fig. 19-37** Hand-foot-and-mouth disease.

(Fig. 19-37). The infection is usually mild and seldom lasts more than 1 week.

Cocksackievirus A6 (CVA6) has become a common cause of “atypical HFMD” in Europe, the United States, and Asia. CVA6 can cause typical HFMD but also a more widespread eruption with numerous lesions on the trunk in addition to the characteristic locations. Perioral lesions suggest CVA6 HFMD, and when severe, can suggest Stevens-Johnson syndrome. Hospitalization may be required for severe dehydration and pain management. Child-to-adult transmission can occur because most adults are not immune to CVA6. In adults, numerous widespread purpuric lesions can occur, simulating a vasculitis or the atypical targets of EM major. In children with AD, CVA6 causes a vesicular and erosive eruption concentrated in the areas of dermatitis, similar to eczema herpeticum, called “eczema cocksackium.” Treatment is supportive, with oral or topical anesthetics. The use of oral glucocorticoids is associated with worse outcomes. Onychomadesis may follow enteroviral infection and HFMD, about 1 month after the acute viral syndrome.

In the severe Taiwanese enterovirus 71 outbreak, 80% of cases with CNS disease had the skin lesions of HFMD. No cases of HFMD associated with CNS disease were caused by coxsackievirus A16, and CNS disease also appears uncommon with CVA6 HFMD. The virus may be recovered from the skin vesicles. Histopathologic findings are those of an intraepidermal blister formed by vacuolar and reticular degeneration of keratinocytes, similar to other viral blisters. Inclusion bodies and multinucleated giant cells are absent. HFMD is distinguished from herpangina by the distribution of the oral lesions and the presence of skin lesions. HFMD usually requires no treatment.

### Eruptive pseudoangiomatosis

Eruptive pseudoangiomatosis has been described in two clusters, in the Mediterranean region and in South Korea. It favors the summer months in both regions. The disorder is characterized by the sudden appearance of 2–4 mm, blanchable red papules that resemble angiomas. In children, it is usually associated with a viral syndrome, but most affected adults have no viral symptoms. In adults, females outnumber males 2:1. The red papules blanch on pressure and are often surrounded by a 1–2 mm pale halo. Lesions often number about 10 but may be much more numerous. Most lesions appear on the exposed surfaces of the face and extremities, but the trunk may also be affected. In children, lesions are short-lived, virtually always resolving within 10 days. Lesions may last slightly longer in adults. Annual recrudescences may occur. Epidemics have been described in adults, and even health care workers caring for patients with eruptive pseudoangiomatosis have developed lesions. Histologically, dilated upper dermal vessels, but not increased numbers of blood vessels, with prominent endothelial cells are seen. Echoviruses 25 and 32 had been impli-

cated in the initial reports. The occurrence in young children and the presence of miniepidemic outbreaks suggest an infectious trigger. This disorder closely resembles “erythema punctatum Higuchi,” which is common in Japan and known to be caused by *Culex pipiens pallens* bites. It appears that mosquito bites, viral infection, or enhanced insect bite reaction due to intercurrent viral infection are possible pathogenic causes of eruptive pseudoangiomatosis.

**Ben-Chetrit E, et al:** Coxsackievirus A6–related hand foot and mouth disease: skin manifestations in a cluster of adult patients. *J Clin Virol* 2014; 59:201.

**Chung WH, et al:** Clinicopathologic analysis of coxsackievirus A6 new variant induced widespread mucocutaneous bullous reactions mimicking severe cutaneous adverse reactions. *J Infect Dis* 2013; 208:1968.

**Feder HM, et al:** Atypical hand, foot, and mouth disease: a vesiculobullous eruption caused by Coxsackie virus A6. *Lancet Infect Dis* 2014; 14:83.

**He Y, et al:** Risk factors for critical disease and death from hand, foot, and mouth disease. *Pediatr Infect Dis* 2014; 33:966.

**Hubiche T, et al:** Dermatological spectrum of hand, foot and mouth disease from classical to generalized exanthema. *Pediatr Infect Dis J* 2014; 33:e92.

**Kaminska K, et al:** Coxsackievirus A6 and hand, foot and mouth disease: three case reports of familial child-to-immunocompetent adult transmission and a literature review. *Case Rep Dermatol* 2013; 5:203.

**Kim JE, et al:** Clinicopathologic review of eruptive pseudoangiomatosis in Korean adults: report of 32 cases. *Int J Dermatol* 2013; 52:41.

**Lott JP, et al:** Atypical hand-foot-and-mouth disease associated with coxsackievirus A6 infection. *J Am Acad Dermatol* 2013; 69:736.

**Mathes EF, et al:** “Eczema cocksackium” and unusual cutaneous findings in an enterovirus outbreak. *Pediatrics* 2013; 132:3149.

**Matsuzawa M, et al:** Coxsackie A16 virus–associated atypical hand-foot-and-mouth disease. *Intern Med* 2014; 53:643.

**Oka K, et al:** Two cases of eruptive pseudoangiomatosis induced by mosquito bites. *J Dermatol* 2012; 39:301.

**Sabanathan S, et al:** Enterovirus 71 related severe hand, foot and mouth disease outbreaks in South-East Asia: current situation and ongoing challenges. *J Epidemiol Community Health* 2014; 68:500.

**Shin JY, et al:** A clinical study of nail changes occurring secondary to hand-foot-mouth disease: onychomadesis and Beau’s lines. *Ann Dermatol* 2014; 26:280.

**Stewart CL, et al:** Coxsackievirus A6–induced hand-foot-mouth disease. *JAMA Dermatol* 2013; 149:1419.

## FILOVIRUS

The viruses in the Filovirus genus are single-stranded with negative polarity. On electron micrographs they appear filamentous, hence the name. This group of viruses is most closely related to the human viruses that cause measles and rabies. Filoviruses are among the most virulent and hazardous pathogens for humans and nonhuman primates. There are two genera, Marburg virus (MARV) and Ebola virus (EBOV). The animal reservoir for these viruses is four fruit bat species found in Africa. Transmission occurs in humans through contact with female bat blood and infected nonhuman primates and by contact with the bodily fluids of infected humans (including but not limited to blood, urine, sweat, semen, and breast milk). Infected humans can transmit the virus from the time they become febrile. The diagnoses of these agents is by detection of EBOV RNA via PCR.

The case fatality rate approaches 90% in African outbreaks but appears to be much lower if aggressive supportive medical care is available. Due to the highly contagious nature of these viruses, healthcare workers are particularly at risk of becoming infected, and special precautions must be taken when managing infected patients.

The incubation period is 1 to 21 days. The initial symptomatic phase (phase I) is characterized by abrupt onset of fever,

headache (usually occipital), myalgias, and arthralgias. Phase II starts 2 to 4 days after symptom onset and lasts for 7 to 10 days. Abdominal pain, watery diarrhea, and violent sore throat occur. In phase II a nonpruritic morbilliform eruption resembling measles appears 4 to 5 days after symptom onset in more than half of patients. The onset of the eruption begins as pinpoint dark red follicular papules. The exanthema may begin acral and spread centripetally to the trunk or vice versa, beginning proximally and extending centrifugally. By day 8 the skin has a generalized, dark, livid erythema. The eruption resolves over a few days in the survivors, followed by desquamation of the affected skin, especially of the palms and soles. Mucosal lesions are also seen in half of patients with bilateral conjunctival congestion, aphthouslike oral lesions, gingivitis, glossitis, and with extension down the throat, dysphagia. The oral lesions can have a gray exudate or small (tapioca granule) white lesions on the soft palate. Phase III is the terminal phase with shock and multiorgan failure. In this stage, supportive care can maintain the patient until the spontaneous eradication of the virus. Convalescence is prolonged with intense fatigue and migratory arthralgias. Neutralizing antibodies from survivors and experimental antivirals are being tested as therapies.

In the nonepidemic setting the initial presentation of the symptoms and skin findings are not specific and can be mistaken for viral or bacterial gastroenteritis, Lassa fever, Dengue, Chikungunya, and even measles, which have overlapping signs and symptoms. In the epidemic setting rapid recognition, establishment of high-quality isolation facilities to treat victims, and absolutely rigid infection control measures to handle infected persons, corpses, and EBOV-infected material are essential.

**Dixon MG, et al:** Ebola viral disease outbreak—West Africa 2014. *MMWR Morb Mortal Wkly Rep* 2014; 63:548.

**Gatherer D:** The 2014 Ebola virus disease outbreak in West Africa. *J Gen Virol* 2014; 95:1619.

**Nkoghe D, et al:** Cutaneous manifestations of Filovirus infections. *Int J Dermatol* 2012; 51:1037.

## PARAMYXOVIRUS GROUP

The paramyxoviruses are RNA viruses that range in size from 100 to 300 nm. In this group, the viral diseases of dermatologic interest are measles (rubeola) and German measles (rubella). Other viruses of this group are mumps virus, parainfluenza virus, Newcastle disease virus, and respiratory syncytial virus.

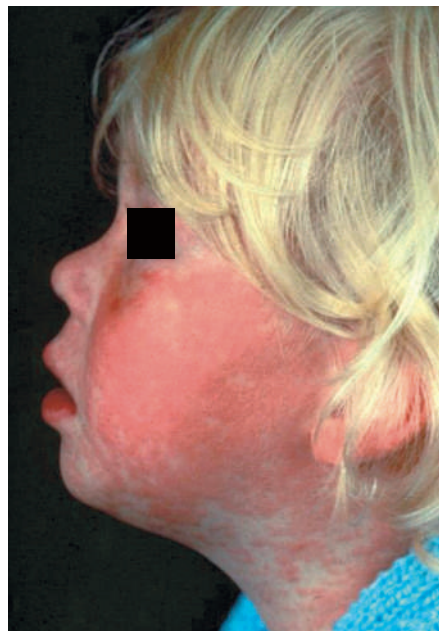
### Measles

Measles is a highly infectious and potentially fatal viral infection. Highly effective two-dose vaccines are available, and when countries reach a rate of 95% vaccination, measles elimination has been achieved. However, measles remains a major health problem in many nations, including developed countries that provide immunizations to their population. More than 12,000 cases of measles occurred in Europe over 2 years, 2006–2007. This epidemic is ongoing and has spurred an elimination program. Numerous hospitalizations and even deaths from measles are still occurring in these developed nations. The majority of cases are in unvaccinated persons, supporting the concept that vaccination (specifically two doses) is protective, and that these measles epidemics and deaths are preventable. Low vaccination levels exist in these countries for many reasons, both philosophic and socioeconomic. Since the children in unvaccinated groups may share common schools, camps, and social networks, they provide a prime breeding

ground for epidemics. Some developed European and Asian countries (notably Japan, with 200,000 cases annually) have not been able to achieve high immunization levels, meaning that their populations are still at risk. The lack of “herd” immunity in these nations leaves at particular risk those infants and susceptible children who cannot be immunized because of other medical conditions. Cases of measles continue to be imported into the United States, which have resulted in numerous “outbreaks” due to significant numbers of nonimmune persons. Affected persons have not been adequately immunized and, when exposed to a person from an endemic area, develop disease. Dermatologists and pediatricians in the Americas need to be alert for cases of measles when seeing persons from these countries or unvaccinated persons from the Americas who have traveled to nations known to have ongoing measles outbreaks.

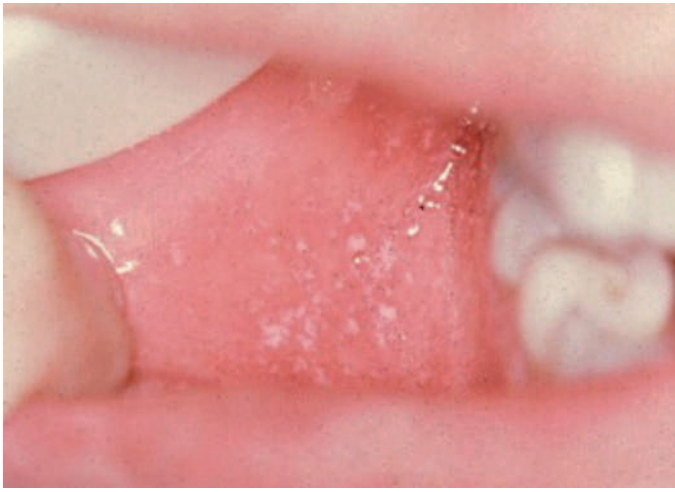Also known as rubeola and morbilli, measles was a worldwide disease that most often affected children under 15 months of age. In the current epidemics, however, older children, adolescents, and adults can be affected. The vast majority of those developing disease have not been adequately immunized. Measles is spread by respiratory droplets and has an incubation period of 9–12 days.

The prodrome consists of fever, malaise, conjunctivitis, and prominent upper respiratory symptoms (nasal congestion, sneezing, coryza, cough). After 1–7 days, the exanthem appears, usually as macular or morbilliform lesions on the anterior scalp line and behind the ears. Lesions begin as discrete erythematous papules that gradually coalesce. The rash spreads quickly over the face (Fig. 19-38), then by the second or third day (unlike the more rapid spread of rubella) extends down the trunk to the extremities. By the third day, the whole body is involved. Lesions are most prominent and confluent in the initially involved areas and may be more discrete on the extremities. Purpura may be present, especially on the extremities, and should not be confused with “black measles,” a rare, disseminated intravascular coagulation–like complication of measles. Koplik spots, which are pathognomonic, appear during the prodrome (Fig. 19-39). The spots appear first on the buccal mucosa nearest to the lower molars as 1-mm white papules on an erythematous base. They may spread to involve other areas of the buccal mucosa and pharynx. They have been less frequently reported in recent outbreaks. After 6–7 days, the exanthem clears, with simultaneous subsidence of the fever.



**Fig. 19-38** Measles.





**Fig. 19-39** Koplik spots.

Complications include otitis media, pneumonia, encephalitis, and thrombocytopenic purpura. Encephalitis, although rare (<1% of cases), can be fatal. Infection in pregnant patients is associated with fetal death. Complications and fatalities are more common in children who are undernourished or have T-cell deficiencies. In HIV-infected children, the exanthem may be less prominent.

Modified measles occurs in a partially immune host as a result of prior infection, persistent maternal antibodies, or immunization, and this is a milder disease. Patients may have only fever, or fever and a rash. The course is shorter, the exanthem less confluent, and Koplik spots may be absent. It is difficult to differentiate modified measles from other viral exanthems.

A diagnosis of measles is established by the presence of a high fever, Koplik spots, the characteristic conjunctivitis, upper respiratory symptoms, and typical exanthem. Lymphopenia is common, with a decreased WBC count. Biopsies of skin lesions may show syncytial keratinocytic giant cells, similar to those seen in respiratory secretions. Laboratory confirmation can be with acute and convalescent serologic tests. Identification of virus-specific IgM (5 days after the rash presents) is highly suggestive of infection in an unimmunized individual. If done too early, however, a serum IgM assay may lead to a false-negative result, and the test should be repeated. Virus isolation is also possible. The combination of IgM serologic testing and virus isolation is the current gold standard for diagnosis. New PCR-based technologies can rapidly detect the measles virus genome in urine, oropharyngeal secretions, and blood and are highly useful in modified and previously vaccinated patients. Rubella, scarlet fever, secondary syphilis, enterovirus infections, and drug eruptions are in the differential diagnosis.

Administration of high doses of vitamin A will reduce the morbidity and mortality of hospitalized children with measles. Two doses of retinyl palmitate, 200,000 IU 24 h apart, are recommended for all children 6–24 months of age, immunodeficient children, children with malnutrition or evidence of vitamin A deficiency, and recent immigrants from areas of high measles mortality. Otherwise, treatment is symptomatic, with bed rest, analgesics, and antipyretics.

Live virus vaccination is recommended at age 12 months, with a booster before entering school (age 4–5 years). A faint maculopapular exanthem may occur 7–10 days after immunization. Prophylaxis with vaccination and immune globulin should be offered to exposed susceptible persons. It must be provided within the first few days after exposure, so identification of susceptible persons is critical. Vaccination can be effective if given within 3 days of exposure, and immune

globulin is given at a dose of 0.25 mL/kg up to 6 days after contact. In an Australian outbreak, these strategies prevented 80% of possible secondary cases.

## Rubella

Rubella, commonly known as German measles, is caused by a togavirus and probably spreads by respiratory secretions. The incubation period is 12–23 days (usually 15–21). Live virus vaccination is highly effective, providing lifelong immunity.

There is a prodrome of 1–5 days consisting of fever, malaise, sore throat, eye pain, headache, red eyes, runny nose, and adenopathy. Pain on lateral and upward eye movement is characteristic. The exanthem begins on the face and progresses caudad, covering the entire body in 24 h and resolving by the third day. The lesions are typically pale-pink, morbilliform macules, smaller than those of rubeola. The eruption may resemble roseola or erythema infectiosum. An exanthem of pinhead-sized red macules or petechiae on the soft palate and uvula (Forchheimer's sign) may be seen. Posterior cervical, suboccipital, and postauricular lymphadenitis occurs in more than half of cases. Rubella is in general a much milder disease than rubeola. Arthritis and arthralgias are common complications, especially in adult women, lasting 1 month or longer. The diagnosis is confirmed by finding rubella-specific IgM in oral fluids or the serum. This IgM develops rapidly, but 50% of sera drawn on the first day of the rash are negative. The virus is rapidly cleared from the blood, being absent by day 2 of the rash. However, the virus is found in oral secretions for 5–7 days after the rash has appeared. PCR-based techniques to identify virus in oral secretions may detect infection more effectively in earlier samples. The combination of PCR-based virus detection tests and identification of rubella virus-specific IgM will result in rapid confirmation of most cases of rubella within the first few days of appearance of disease symptoms.

## Congenital rubella syndrome

Infants born to mothers who had rubella during the first trimester of pregnancy may have congenital cataracts, cardiac defects, and deafness. Numerous other manifestations, such as glaucoma, microcephaly, and various visceral abnormalities, may emerge. Among the cutaneous expressions are thrombocytopenic purpura; hyperpigmentation of the navel, forehead, and cheeks; bluish red, infiltrated, 2–8 mm lesions ("blueberry muffin" type), which represent dermal erythropoiesis; chronic urticaria; and reticulated erythema of the face and extremities.

- Andersen DV, Jørgensen IM:** MMR vaccination of children with egg allergy is safe. *Dan Med J* 2013; 60:A4573.
- Caseris M, et al:** French 2010–2011 measles outbreak in adults: report from a Parisian teaching hospital. *Clin Microbiol Infect* 2014; 20:O242.
- Centers for Disease Control and Prevention:** Recommendations from an ad hoc meeting of the WHO Measles and Rubella Laboratory Network (LabNet) on use of alternative diagnostic samples for measles and rubella surveillance. *MMWR* 2009; 57:657.
- Gahr P, et al:** An outbreak of measles in an undervaccinated community. *Pediatrics* 2014; 134:e220.
- Giusti D, et al:** Virological diagnosis and management of two cases of congenital measles. *J Med Virol* 2013; 85:2136.
- Muscat M, et al:** Measles in Europe: an epidemiological assessment. *Lancet* 2009; 373:383.
- Nagai M, et al:** Modified adult measles in outbreaks in Japan, 2007–2008. *J Med Virol* 2009; 81:1094.
- Nakayama T:** Laboratory diagnosis of measles and rubella infection. *Vaccine* 2009; 27:3228.
- Ortega-Sanchez IR, et al:** The economic burden of sixteen measles outbreaks on United States public health departments in 2011; *Vaccine* 2014; 32:1311.

- Sammons JS:** Ready or not: responding to measles in the postelimination era. *Ann Intern Med* 2014; 161:145.
- Sheikine Y, et al:** Histopathology of measles exanthem: a case with characteristic features and eosinophils. *J Cutan Pathol* 2012; 39:667.
- Sheppard V, et al:** The effectiveness of prophylaxis for measles contacts in NSW. *NSW Public Health Bull* 2009; 20:81.
- Tanne JH:** Rise in US measles cases is blamed on unimmunized travelers. *BMJ* 2014; 348:g3478.
- Tapisiz A, et al:** Prevention of measles spread on a paediatric ward. *Epidemiol Infect* 2014; May 30. [Epub ahead of print.]
- Tod B, et al:** Dermatological manifestations of measles infection in hospitalized paediatric patients observed in the 2009–2011 Western Cape epidemic. *S Afr Med J* 2012; 102:356.
- Young MK, et al:** Post-exposure passive immunization for preventing measles. *Cochrane Database Syst Rev* 2014; 4:CD010056.
- Zipprich J, et al:** Measles—California, January 1–April 18, 2014. *MMWR* 2014; 63:362.

### Asymmetric periflexural exanthem of childhood (APEC)

This clinical syndrome, also known as unilateral laterothoracic exanthem, occurs primarily in the late winter and early spring and appears to be most common in Europe. It affects girls more often than boys (1.2:1 to 2:1). It occurs in children 8 months to 10 years of age, but most cases are between 2 and 3 years. Multiple cases have been reported in adults. The cause is unknown, but a viral origin has been proposed because it occurs in young children and is seasonal, and secondary cases in families have been reported. No reproducible viral etiology has been implicated; however, at least three cases attributed to parvovirus B19 have been reported. Clinically, two thirds to three quarters of affected children have symptoms of a mild upper respiratory or GI infection, usually preceding the eruption. The lesions are usually discrete, 1-mm erythematous papules that coalesce to poorly margined morbilliform plaques. Pruritus is usually present but is mild. Lesions begin unilaterally close to a flexural area, usually the axilla (75% of cases). Spread is centrifugal, with new lesions appearing on the adjacent trunk and proximal extremity. Normal skin may intervene between lesions. The contralateral side is involved in 70% of cases after 5–15 days, but the asymmetric nature is maintained throughout the illness. Lymphadenopathy of the nodes on the initially affected side occurs in about 70% of patients. The APEC syndrome lasts 2–6 weeks on average, but may last more than 2 months, and resolves spontaneously. Topical corticosteroids and oral antibiotics are of no benefit, but oral antihistamines may help associated pruritus. Histologically, a mild to moderate lymphocytic (CD8+ T-cell) infiltrate surrounds and involves the eccrine ducts but not the secretory coils. There may be an accompanying interface dermatitis of the upper eccrine duct and adjacent epidermis.

- Arun B, Salim A:** Transient linear eruption: asymmetric periflexural exanthem or blaschkitis. *Pediatr Dermatol* 2010; 27:301.
- Chan PKS, et al:** Asymmetric periflexural exanthema in an adult. *Clin Exp Dermatol* 2004; 29:311.
- Guimera-Martin-Neda G, et al:** Asymmetric periflexural exanthem of childhood: report of two cases with parvovirus B19. *J Eur Acad Dermatol Venereol* 2006; 20:461.

### PARVOVIRUS GROUP

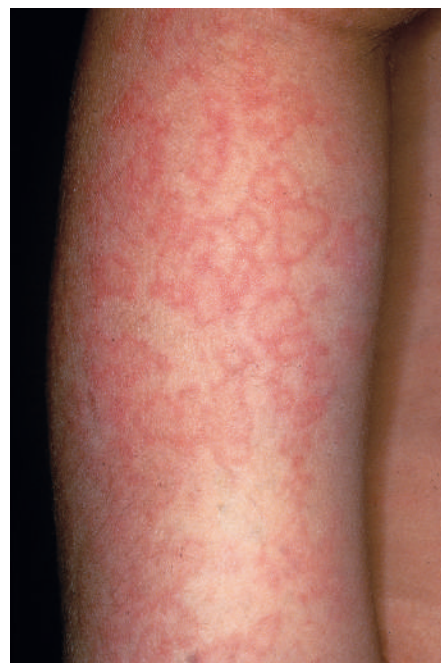Parvovirus B19 is the most common agent in this *Erythrovirus* genus to cause human disease. Infection is worldwide, occurring in 50% of persons by age 15. The vast majority of elderly adults are seropositive. Infections are more common in the spring in temperate climates. Epidemics in communities occur

about every 6 years. The virus is spread by the respiratory route, and infection rates are very high within households. Most infections are asymptomatic. The propensity for parvovirus B19 to affect the bone marrow is reflected by the presence of thrombocytopenia or leukopenias during the acute infection. Parvovirus B19 is the prototype for the concept of “one virus, many exantheas.” The patient may have multiple types of exantheas simultaneously or sequentially. Erythema infectiosum and papular-purpuric gloves-and-socks syndrome are both strongly associated with parvovirus B19 infection. Parvovirus B19 may also play a role in some cases of GCS and APEC. Other known complications of this viral infection include arthropathy (especially in middle-age females), aplastic crisis in hereditary spherocytosis and sickle cell disease, and chronic anemia in immunosuppressed patients. Infection of a pregnant woman leads to transplacental infection in 30% of cases and a fetal loss rate of 5–9%. Acute viral myocarditis and pericarditis are frequently secondary to parvovirus B19 infection.

### Erythema infectiosum (fifth disease)

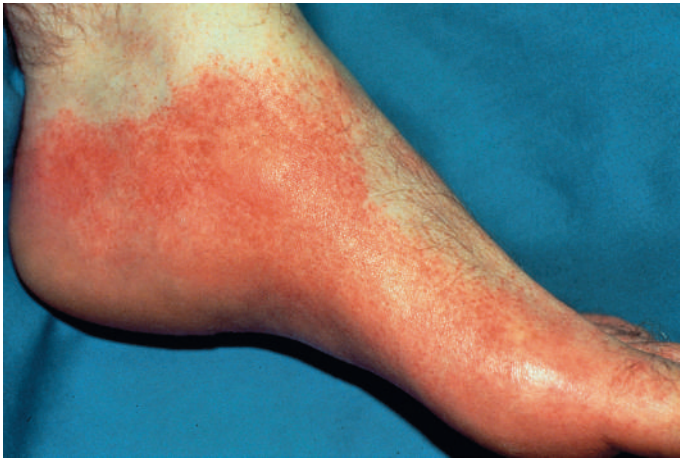Erythema infectiosum is a worldwide benign infectious exanthem that occurs in epidemics in the late winter and early spring. In normal hosts (but not immunosuppressed or sickle cell patients in crisis), viral shedding has stopped by the time the exanthem appears, making isolation unnecessary. The incubation period is 4–14 days (average 7 days). Infrequently, a mild prodrome of headache, runny nose, and low-grade fever may precede the rash by 1 or 2 days.

Erythema infectiosum has three phases. It begins abruptly with an asymptomatic erythema of the cheeks, referred to as “slapped cheek.” The erythema is typically diffuse and macular, but tiny translucent papules may be present. It is most intense beneath the eyes and may extend over the cheeks in a butterfly-wing pattern. The perioral area, lids, and chin are usually unaffected. After 1–4 days, the second phase begins, consisting of discrete erythematous macules and papules on the proximal extremities and later the trunk. This evolves into a reticulate or lacy pattern (Fig. 19-40). These two phases typically last 5–9 days. A characteristic third phase is the recurring stage. The eruption is greatly reduced or invisible, only to recur after the patient is exposed to heat (especially



**Fig. 19-40** Erythema infectiosum.





**Fig. 19-41** Papular-purpuric gloves-and-socks syndrome.

when bathing) or sunlight, or in response to crying or exercise. About 7% of children with erythema infectiosum have arthralgias, whereas 80% of adults, especially women, have joint involvement. Necrotizing lymphadenitis may also occur in the cervical, epitrochlear, supraclavicular, and intra-abdominal lymph nodes. Children with aplastic crisis caused by parvovirus B19 usually do not have a rash. However, even healthy children can develop significant bone marrow complications, although transient and self-limited.

### Papular-purpuric gloves-and-socks syndrome

The papular-purpuric gloves-and-socks (or glove-and-stock) syndrome (PPGSS), which is less common than erythema infectiosum, occurs primarily in teenagers and young adults. Pruritus, edema, and erythema of the hands and feet appear, and a fever is present. The lesions are sharply cut off at the wrists and ankles (Fig. 19-41). Over a few days, they become purpuric. There is a mild erythema of the cheeks, elbows, knees, and groin folds. Oral erosions, shallow ulcerations, aphthous ulcers on the labial mucosa, erythema of the pharynx, Koplik spots, or petechial lesions may be seen on the buccal or labial mucosa. The lips may be red and swollen. Vulvar edema and erythema accompanied by dysuria may be seen. An unusual variant is a unilateral petechial and erythematous eruption of the axilla. The acral erythema may rarely move proximally along lymphatics, simulating a lymphangitis. Transient lymphocytopenia, decreased platelet count, and elevated LFTs may be seen. PPGSS resolves within 2 weeks. Evidence of seroconversion for parvovirus B19 has been found in most reported patients. Histologically, a dermal infiltrate of CD30+ T lymphocytes surrounds the upper dermal vessels. There is an interface component and prominent extravasation of red blood cells in petechial lesions. Parvovirus B19 antigen has been found in the endothelial cells, sweat glands and ducts, and epidermis. Because the antigen is located in the endothelial cells, a leukocytoclastic vasculitis picture both clinically and histologically may be seen. Similarly, a Degos' disease-like morphology can occur. In HIV-infected patients who develop PPGSS, the eruption is more persistent, lasting 3 weeks to 4 months, and is associated with anemia.

Not all cases of PPGSS are caused by parvovirus B19. In adults, it may be associated with HBV infection. In children, the syndrome occurs at an average age of 23 months. The eruption lasts an average of 5 weeks. Also in children, CMV and EBV are the most common documented causes in Taiwan, where PPGSS appears to be very common in the last quarter of the year.

### Other skin findings attributed to parvovirus B19

In some patients, the exanthem of parvovirus B19 affects primarily the flexural areas, especially the groin. This may present as APEC (see earlier), petechiae in the groin, or an erythema studded with pustules in the groin and to a lesser degree in the axillae, resembling baboon syndrome. The petechial eruption of PPGSS may also involve the perioral area and has been termed the "acropetechial syndrome." An outbreak in Kerala, India, described 50 children, mostly under age 2 years, who presented with high fever and a diffuse, intensely erythematous, tender skin eruption. The children were very irritable and cried when held. Their skin was extremely swollen, and whole-body edema was present. The acute exanthem was followed by diffuse desquamation. There were no secondary cases. IgM for parvovirus B19 was detected in 15 of 24 cases tested. The authors called this "red baby syndrome."

Infection with parvovirus B19 may trigger a hemophagocytic (or macrophage activation) syndrome. This presents with progressive cytopenias, liver dysfunction, coagulopathy, high ferritin level, and hemophagocytosis. Numerous nonspecific eruptions have been described with hemophagocytic syndrome, including nodules, ulcers, purpura, and panniculitis. The diagnostic hemophagocytic cells may occasionally be identified in skin biopsies. Infection with parvovirus B19 may lead to cutaneous necrosis in persons with a hypercoagulable state, such as paroxysmal nocturnal hemoglobinuria. The presence of edema, purpuric lesions, facial erythema, fever, cytopenias, and hypocomplementemia, even with positive antinuclear antibodies, allows for severe cases of parvovirus B19 infection to be confused with systemic lupus erythematosus.

- Bello S, et al:** Papular-purpuric gloves and socks syndrome due to parvovirus B19: a report of two simultaneous cases in cohabitant families. *Reumatismo* 2013; 65:40.
- Butler GJ, et al:** Parvovirus B19 infection presenting as "bathing trunk" erythema with pustules. *Australas J Dermatol* 2006; 47:286.
- Cooray M, et al:** Parvovirus infection mimicking systemic lupus erythematosus. *CMAJ* 2013; 185:1342.
- Cugler T, et al:** Severe glomerulonephritis and encephalopathy associated with parvovirus B19 infection mimicking systemic lupus erythematosus. *Scand J Rheumatol* 2012; 41:79.
- Cunha BA, Chandrankunnel J:** Parvovirus B19 with a scarlatiniform/rubelliform rash and small joint arthritis mimicking rubella in an adult. *Trav Med Infect Dis* 2012; 10:208.
- Dyrsen ME, et al:** Parvovirus B19-associated catastrophic endothelialitis with a Degos-like presentation. *J Cutan Pathol* 2008; 35:20.
- Eng S, et al:** Fever and petechial rash in a 9-year-old boy. *Pediatr Rev* 2012; 33:369.
- Fruhauf J, et al:** Bullous papular-purpuric gloves and socks syndrome in a 42-year-old female: molecular detection of parvovirus B19 DNA in lesional skin. *J Am Acad Dermatol* 2008; 60:691.
- Gutermuth J, et al:** Papular-purpuric gloves and socks syndrome. *Lancet* 2011; 378:198.
- Hashimoto H, Yuno T:** Parvovirus B19-associated purpuric-petechial eruption. *J Clin Virol* 2011; 52:269.
- Magu V, et al:** Different patterns of skin manifestations associated with parvovirus B19 primary infection in adults. *J Am Acad Dermatol* 2014; 71:62.
- McNeeley M, et al:** Generalized petechial eruption induced by parvovirus B19 infection. *J Am Acad Dermatol* 2005; 52:S109.
- Pedrossa AF, et al:** Haemophagocytic syndrome with a fatal outcome triggered by parvovirus B19 infection in the skin. *Clin Exp Dermatol* 2014; 39:216.
- Sakai H, et al:** Hemophagocytic syndrome presenting with a facial erythema in a patient with systemic lupus erythematosus. *J Am Acad Dermatol* 2007; 57:S111.
- Santonja C, et al:** Immunohistochemical detection of parvovirus B19 in "gloves and socks" papular purpuric syndrome: direct evidence for viral endothelial involvement—report of three cases and review of the literature. *Am J Dermatopathol* 2011; 33:790.

**Sasidharan CK, et al:** Red baby syndrome: a new disease due to parvovirus B-19 observed in Kerala. *Indian J Pediatr* 2009; 76:309.  
**Valentin MN, Cohen PJ:** Pediatric parvovirus B19: spectrum of clinical manifestations. *Cutis* 2013; 92:179.  
**Wiggli B, et al:** Water, water, everywhere. *Lancet* 2013; 381:776.

## ARBOVIRUS GROUP (TOGAVIRIDAE)

The arboviruses comprise the numerous arthropod-borne RNA viruses. These viruses multiply in vertebrates, as well as in arthropods. The vertebrates usually act as reservoirs and the arthropods as vectors of the various diseases.

### West Nile fever

West Nile virus (WNV) is a flavivirus that is endemic in East Africa. It first appeared in eastern North America in 1999 and reached California by 2004. It is primarily an infection of the crow family (crows, ravens, magpies, and bluejays). It is spread by *Culex* mosquitoes. Approximately 80% of infected persons will have no symptoms. After an incubation period of 3–15 days, a febrile illness of sudden onset occurs. Headache, myalgia, arthralgia, conjunctivitis, pharyngitis, cough, adenopathy, abdominal pain, hepatitis, pancreatitis, and myocarditis are recognized clinical manifestations. The primary complications, however, are neurologic disease, including seizures (10% of symptomatic adults), ascending flaccid paralysis (as in poliomyelitis), ataxia, meningitis, encephalitis, myelitis, cranial neuropathies, optic neuritis, and reduced level of consciousness. A significant percentage of affected persons are left with permanent neurologic sequelae. About 20% of hospitalized patients will have an exanthem. The exanthema of WNV is nonpruritic and composed of 50–100 erythematous, poorly defined macules 0.5–1 cm in diameter, primarily on the trunk and proximal extremities. It lasts 5–7 days and resolves without scaling.

### Sandfly fever

Sandfly fever is also known as phlebotomus fever and pap-pataci fever. The vector, *Phlebotomus papatasi*, is found in the Mediterranean area (Sicilian fever, Naples fever, and Toscana virus), Russia, China, and India. Sicilian and Naples sandfly fever viral infections disappeared or dramatically decreased with mosquito eradication programs, Toscana virus infection is still common. Although most infected persons are asymptomatic, 80% of aseptic meningitis cases in the summer in endemic areas are caused by this agent. Small, pruritic papules appear on the skin after the sandfly bite and persist for 5 days. After an incubation period of another 5 days, fever, headache, malaise, nausea, conjunctival injection, stiff neck, and abdominal pains suddenly develop. The skin manifestations consist of a scarlatiniform eruption on the face and neck. Recovery is slow, with recurring bouts of fever. No specific treatment is available.

### Dengue

More than 100 million cases of dengue occur annually worldwide, and the global prevalence is growing. In European hospitals that evaluate patients with fever after trips to the tropics, dengue is the most common febrile illness in travelers returning from Southeast Asia who develop a fever within 1 month of the trip. It is transmitted by *Aedes* mosquitoes, which have

adapted well to living around humans in urban environments. It affects primarily tropical regions where temperatures rarely drop below 20°C, favoring the reproduction of the mosquito vector. Southeast Asia and the Western Pacific are the most severely affected regions, but India, Cuba, and the tropical Americas also have numerous cases. There have been several U.S. outbreaks, in Houston, Texas, and Key West, Florida, and many of these cases appear *not* to have been imported, suggesting dengue is potentially endemic in these climates. Persons of African ancestry seem to be at much less risk of developing dengue.

Dengue fever begins 2–15 days after the infectious mosquito bite. The clinical features are characteristic and consist of the sudden onset of high fevers accompanied by myalgias, headache, retro-orbital pain, and severe backache (breakbone fever). Common associated laboratory findings include elevated LFTs (about three times normal on average), thrombocytopenia (platelet count <100,000 in 50% of patients), and a leukopenia. These are present during the acute illness and help to suggest dengue as the correct diagnosis. About 50% of patients will develop a characteristic skin eruption. In 90% of patients, the eruption begins between days 3 and 5 of the illness, often as the fever defervesces. The skin eruption occurs in less than 10% of patients before the onset of fever. The eruption is most often generalized (50%) or involves only the extremities (30%) or the trunk (20%). Lesions are macular or morbilliform and are usually confluent, characteristically sparing small islands of normal skin—“islands of white in a sea of red” (Fig. 19-42). Persistent blanching after pressing the skin can also be seen. Facial flushing may be prominent. The rash is either asymptomatic or only mildly pruritic. Petechiae may be present, but the finding of cutaneous hemorrhage should raise the suspicion of dengue hemorrhagic fever/dengue shock syndrome (DHF/DSS, severe dengue). Complete recovery occurs in 7–10 days. Biopsy of the exanthem shows minimal findings and is of no value in predicting the severity of the patient’s condition or in identifying DHF/DSS/severe dengue.

There are four serotypes of dengue. After infection with one serotype, the individual is resistant to reinfection with that serotype. However, if that person becomes infected with another serotype, the individual is at risk of developing severe complications from the second episode of dengue. The patient’s antidengue antibodies are incapable of preventing infection by or replication of the new dengue virus type. However, antibodies do trigger increased viral phagocytosis by mononuclear cells and amplified cytokine production. The World Health

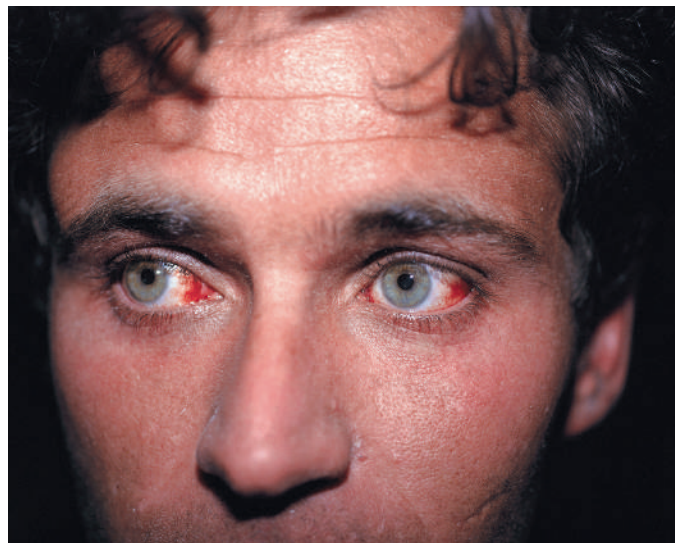

Fig. 19-42 Dengue.



Organization (WHO) 2009 classification system divides cases into dengue without warning signs, dengue with warning signs, and severe dengue. This more objective schema is more sensitive in identifying patients with early, severe dengue. The potentially fatal syndromes that can occur in dengue infection are characterized by hemorrhage (dengue hemorrhagic fever/DHF), at times with extensive plasma leakage (dengue shock syndrome/DSS/severe dengue). The fatality rate for severe dengue may be as high as 40%. The diagnosis of dengue is made by detection of dengue-specific IgM in the sera by ELISA, with acute and convalescent serologies demonstrating seroconversion. Some laboratories can detect viral RNA in acute serum samples. An effective vaccine has not been developed; the only preventive strategy for travelers is to avoid mosquito bites. In children, dengue fever and Kawasaki disease have occurred simultaneously. These two syndromes may be almost identical in their presentation, so this differential diagnosis can be extremely difficult. When both diagnoses have been made simultaneously, the patient had persistent fever (>1 week), a reactive thrombocytosis after the initial thrombocytopenia, and in some cases, characteristic cardiac lesions.

## Alphavirus

### Sindbis virus

In Finland, Sindbis virus infection is transmitted by the *Culiseta* mosquito. An eruption of multiple, erythematous, 2–4 mm papules with a surrounding halo is associated with fever and prominent arthralgias. The eruption and symptoms resolve over a few weeks. Histologically, the skin lesions show a perivascular lymphocytic infiltrate with large, atypical cells, simulating lymphomatoid papulosis. CD30 does not stain the large cells, however, allowing their distinction.

### Chikungunya virus

Chikungunya virus is transmitted by the *Aedes* mosquito. Derived from the Makonde language of sub-Saharan Africa, *chikungunya* means “that which bends up,” describing the characteristic stooped posture resulting from the joint symptoms of the disease. It is endemic in Africa, India, Sri Lanka, Southeast Asia, the Philippines, Hong Kong, the islands of the Indian Ocean, and the Caribbean region. The first U.S. cases of chikungunya infection were reported during summer 2014 in southern Florida. The incubation period is 2–7 days. The patient presents with abrupt onset of high fever. Significant joint symptoms are characteristic and occur in 40% of infected patients. Most often, there is swelling and pain in the small joints of the hands and feet. The joint symptoms may persist for weeks to months, with about 50% of patients still having some symptoms at 6 months. Patients may develop neuropathic acral findings, including Raynaud phenomenon, erythromelalgia, or severe acral coldness, as late sequelae. Headache occurs in 70% of patients and nausea and vomiting in 60%. Lymphopenia, thrombocytopenia, and elevated LFTs can be observed in the first week of the illness. Although generally a nonfatal and self-limited illness, severe complications can occur with chikungunya infection, causing death in about 1 in 1000 infected patients.

About half to three quarters or more of patients with chikungunya virus infection develop a rash. It is pruritic in 20–50% of the patients. The most common and characteristic exanthem is described as morbilliform and most frequently affects the arms, upper trunk, and face. It can be confluent, and islands of sparing can be seen. It appears by the second day of the fever in more than half of patients, and in another 20% on the third or fourth day; only about one-fifth of patients develop

the eruption after the fifth day of the illness. Ecchymoses may appear during the acute illness. Aphthouslike ulcerations can occur in the oral, penoscrotal, and less often the axillary regions. These may be preceded by intense erythema and pain in the affected area. After acute chikungunya infection, hyperpigmentation of the skin may occur.

A bullous eruption may occur in acute chikungunya virus infection. About 90% of those with a bullous eruption are under 1 year of age, and most of the severe cases occur before age 6 months. In children, 17% develop a vesiculobullous component to their eruption, compared with only 3% of adults. There is an initial exanthem, followed in hours or days by flaccid or tense nonhemorrhagic blisters that rupture easily. Nikolsky's sign is positive. The genitalia, palms, and soles are spared. There is a close resemblance to toxic epidermal necrolysis (TEN), and up to 80% of the total body surface area may become denuded. High titers of virus are recovered from blister fluid (in excess of that present in blood). Biopsy demonstrates an intraepidermal blister with acantholytic cells floating free in the blister cavity. These patients are managed similar to burn patients, and most recover. Skin grafting usually is not required.

The diagnosis of chikungunya virus infection is made by detecting virus-specific IgM in the serum. Confirmation is by seroconversion over the next several months, with development of virus-specific IgG. PCR-based methods may detect viral genome in the blisters or serum during the acute illness.

It may be difficult to differentiate dengue from chikungunya fever, because both are endemic in the same geographic regions, and their clinical symptoms and laboratory findings are similar. Arthralgias occur in a significant percentage of patients with chikungunya virus infection, approaching 100% in those with a rash, but also occur in patients with dengue. Neutropenia is seen in 80% of dengue patients and only 10% of chikungunya patients. A positive tourniquet test does not distinguish these two infections, but thrombocytopenia is more common in dengue (85+%) than chikungunya (35%) patients.

- Bandyopadhyay D, et al:** Mucocutaneous features of chikungunya fever: a study from an outbreak in west Bengal, India. *Int J Dermatol* 2008; 47:1148.
- Borgherini G, et al:** Outbreak of chikungunya on Reunion Island: early clinical and laboratory features in 157 adult patients. *Clin Infect Dis* 2007; 44:1401.
- Bouri N, et al:** Return of epidemic dengue in the United States: implications for the public health practitioner. *Public Health Rep* 2012; 127:259.
- Chen TC, et al:** Dengue hemorrhagic fever complicated with acute idiopathic scrotal edema and polyneuropathy. *Am J Trop Med Hyg* 2008; 78:8.
- Dang TN, et al:** A replication study confirms the association of GWAS-identified SNPs at MICB and PLCE1 in Thai patients with dengue shock syndrome. *BMC Med Genet* 2014; 15:58.
- De la C, et al:** Race: a risk factor for dengue hemorrhagic fever. *Arch Virol* 2007; 152:533.
- Del Giudice P, et al:** Skin manifestations of West Nile virus infection. *Dermatology* 2005; 211:348.
- Hochedez P, et al:** Management of travelers with fever and exanthema, notably dengue and chikungunya infections. *Am J Trop Med Hyg* 2008; 87:710.
- Ju H, Brasier AR:** Variable selection methods for developing a biomarker panel for prediction of dengue hemorrhagic fever. *BMC Res Notes* 2013; 6:365.
- Kenzaka T, Kumabe A:** Skin rash from dengue fever. *BMJ Case Rep* 2013; Nov 25; bcr2013201598.
- Lupi O, Tyring SK:** Tropical dermatology: viral tropical diseases. *J Am Acad Dermatol* 2003; 49:979.
- Macedo GA, et al:** Sensitivity and specificity of the World Health Organization dengue classification schemes for severe dengue assessment in children in Rio de Janeiro. *PLoS One* 2014; 9:e96314.
- Mahboob A, et al:** Dermatological manifestations of dengue fever. *J Ayub Med Coll Abbottabad* 2012; 24:52.

**Murray KO, et al:** Identification of dengue fever cases in Houston, Texas, with evidence of autochthonous transmission between 2003 and 2005. *Vector Borne Zoonotic Dis* 2013; 13:835.

**Rathakrishnan A, et al:** Clinical and immunological markers of dengue progression in a study cohort from a hyperendemic area in Malaysia. *PLoS One* 2014; 9:e92021.

**Ribeiro E, et al:** Primary dengue fever associated with hemophagocytic syndrome: a report of three imported cases, Bordeaux, France. *Intern Med* 2014; 53:899.

**Robin S, et al:** Severe bullous skin lesions associated with chikungunya virus infection in small infants. *Eur J Pediatr* 2010; 169:67.

**Saadiah S, et al:** Skin histopathology and immunopathology are not of prognostic value in dengue haemorrhagic fever. *Br J Dermatol* 2008; 158:836.

**Singh S, et al:** Dengue fever and Kawasaki disease: a clinical dilemma. *Rheumatol Int* 2009; 29:717.

**Thomas EA, et al:** Mucocutaneous manifestations of dengue fever. *Indian J Dermatol* 2010; 55:79.

**Valassina M, et al:** A Mediterranean arbovirus: the Toscana virus. *J Neuroviro* 2003; 9:577.

**Wong JG, et al:** Self-reported pain intensity with the numeric reporting scale in adult dengue. *PLoS One* 2014; 9:e96514.

## PAPOVAVIRUS GROUP

Papovaviruses are naked dsDNA viruses characterized as slow growing. They replicate inside the nucleus. Because papovaviruses contain no envelope, they are resistant to drying, freezing, and solvents. In addition to the human papillomaviruses, which cause warts, papillomaviruses of rabbits and cattle, polyomaviruses of mice, and vacuolating viruses of monkeys are some of the other viruses in the papovavirus group.

## Warts (verruca)

There are more than 150 types of human papillomavirus (HPV). The genome of HPV consists of early genes (*E1*, *E2*, *E4*, *E5*, *E6*, and *E7*), two late genes (*L1* and *L2*), and in between an upstream regulatory region (URR). *L1* and *L2* code for the major and minor capsid proteins. *L1* encodes for the major capsid protein and self-assembles into viruslike particles (VLPs). These VLPs are the antigens in currently available HPV vaccines. The *L2* gene encodes the minor capsid protein and has at least two important functions. *L2* protein helps expose the keratinocyte-binding determinant of the *L1* protein, allowing for the HPV to bind onto the basal keratinocyte and to be taken into the cell. The processing of HPV surface proteins in the skin takes up to 24 hours, allowing for exposure to anti-HPV antibodies. The *L2* protein also is immunomodulatory, downregulating the function of Langerhans cells through the phosphoinositide 3-kinase pathway. A new HPV type is defined when there is less than 90% DNA homology with any other known type in the *L1* and *E6* genes. Viruses with 90–98% homology are classified as subtypes. The gene sequences from HPVs throughout the world are similar. Most HPV types cause specific types of warts and favor certain anatomic locations, such as plantar warts, common warts, and genital warts. HPVs 1, 2, 27, and 57 cause the vast majority of cutaneous (nongenital) warts. HPV-1 is associated with plantar warts in children younger than 12 years. HPV-2 is more common in hand warts. HPV-27 and HPV-57 are associated with common and plantar warts in adults (>21 years). External genital warts are caused by HPV-6/11 and anogenital dysplasia by HPV-16/18. A large proportion of the HPV types rarely cause warts and appear to be pathogenic only in immunosuppressed patients or those with epidermodysplasia verruciformis. However, many persons may carry, or may be latently infected with, these rare wart types, explaining the uniformity of gene sequence and clinical presentation worldwide. In the

immunosuppressed patient, HPV types may cause warty lesions of a different clinical morphology than in an immunocompetent host.

Infection with HPV may be clinical, subclinical, or latent. Clinical lesions are visible by gross inspection. Subclinical lesions may be seen only by aided examination (e.g., acetic acid soaking). Latent infection describes the presence of HPV or viral genome in apparently normal skin. Latent infection is thought to be common, especially in genital warts, and explains in part the failure of destructive methods to eradicate warts.

Infection with HPV is extremely common; most people will experience infection during their lifetime. In Australia, 22%, and in The Netherlands, 33% of schoolchildren were found to have nongenital cutaneous warts. Common warts are found in about 10–15% of children, plantar warts in 6–20% (higher in The Netherlands than Australia), and flat warts are only reported in schoolchildren from Australia (2%). White persons have visible cutaneous warts twice as frequently as other ethnicities. Genital warts begin to appear with sexual activity, with 10% of women acquiring HPV infection before they have intercourse, suggesting oral/digital/genital-to-genital contact is capable of transmitting HPV. HPV infection rates, including latent infection, exceed 50% in sexually active populations in many parts of the world.

Human papillomaviruses have coexisted with humans for many millennia, and humans are their primary host and reservoir. HPVs have been successful pathogens of human because they evade the human immune response. This is achieved primarily through avoiding the expression of antigens on the surface of keratinocytes until the keratinocytes are above the level of the antigen-presenting cells in the epidermis. HPVs also reduce Langerhans cells in the vicinity of infection and inactivate them through the *L2* protein on their surface. Through *E6* and *E7*, HPV reduces local production of key immune reactants (e.g., TLR9, IL-8), muting the local immune response. HPVs thus live in equilibrium with their human hosts through a combination of immune evasion and programmed immune suppression (tolerance).

Management of warts is based on their clinical appearance and location and the patient's immune status. In general, warts of all types are more common and more difficult to treat in persons with suppressed immune systems. Except in WHIM syndrome (warts, hypogammaglobulinemia, infection, and myelokathexis: gain-of-function mutation of *CXCR4*), syndromes of reduced immunoglobulin production or B-cell function are not associated with increased HPV infection. Medical conditions or treatments associated with suppression of cell-mediated immunity are associated with high rates of clinical HPV infection and HPV-induced neoplasias. The common clinical scenarios are iatrogenic medications (e.g., in organ transplant recipients), viral infections that result in T-cell deficiency (e.g., HIV), and congenital syndromes of T-cell immunodeficiency. Patients with GATA2 deficiency frequently present with extensive warts. WILD syndrome is the association of primary lymphedema, disseminated warts, and anogenital dysplasia with depressed cell-mediated immunity and probably represents GATA2 deficiency. Idiopathic CD4 lymphopenia and autosomal recessive hyper-IgE syndrome caused by *DOCK8* deficiency are two other T-cell immunodeficiency states associated with HPV infection. Because warts in some anatomic regions are important cofactors in cancer, histologic evaluation of warty lesions in the immunodeficient patient can be critically important.

## Verruca vulgaris

Common warts are a significant cause of concern and frustration for patients (Figs. 19-43 and 19-44). Social activities can be affected, lesions can be uncomfortable or bleed, and treatment



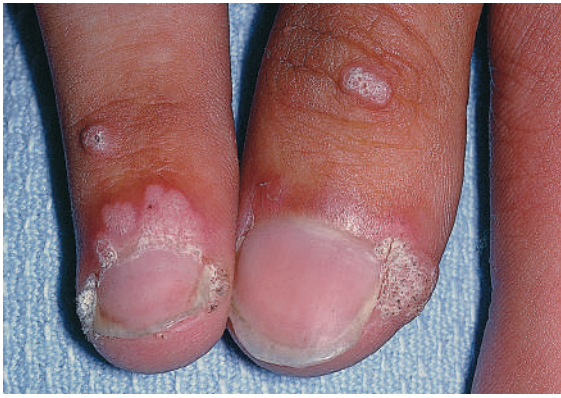

Fig. 19-43 Verruca vulgaris.

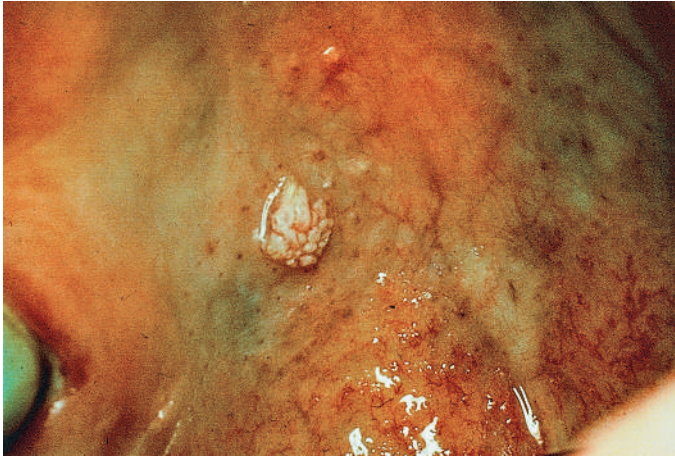


Fig. 19-44 Verruca, nail biter with perioral warts.

is often painful and frustratingly ineffective. Human papillomavirus types 1, 2, 4, 27, 57, and 63 cause common warts. Common warts occur mainly between ages 5 and 20, and only 15% occur after age 35. Frequent immersion of hands in water is a risk factor for common warts. Having family members and schoolmates with warts is associated with having warts; public exposures such as swimming pools, public showers, and going barefoot are associated to a lesser degree. Meat handlers (butchers), fish handlers, and other abattoir workers have a high incidence of common warts of the hands. The prevalence reaches 50% in those who have direct contact with meat. Warts in butchers are caused by HPV-2 and HPV-4; up to 27% of hand warts from butchers are caused by HPV-7, which is found only on the hands where there is direct contact with meat. HPV-7 is rarely found in warts in the general population (<0.3%). The source of HPV-7 is unknown, but HPV-7 is not bovine papillomavirus and does not come from the slaughtered animals. HPV-57 has been reported to cause dystrophy of all 10 fingernails, with marked subungual hyperkeratosis and destruction of the nail plate without periungual involvement.

The natural history of common warts is for spontaneous resolution. Reported clearance rates in children are 23% at 2 months, 30% at 3 months, 50% at 1 year, 65–78% at 2 years, and 90% over 5 years. Common warts are usually located on the hands, favoring the fingers and palms. Periungual warts are more common in nail biters and may be confluent, involving the proximal and lateral nailfolds. Fissuring may lead to bleeding and tenderness. Lesions range in size from pinpoint to more than 1 cm, most averaging about 5 mm. They grow in size for weeks to months and usually present as elevated, rounded papules with a rough, grayish surface, which is so

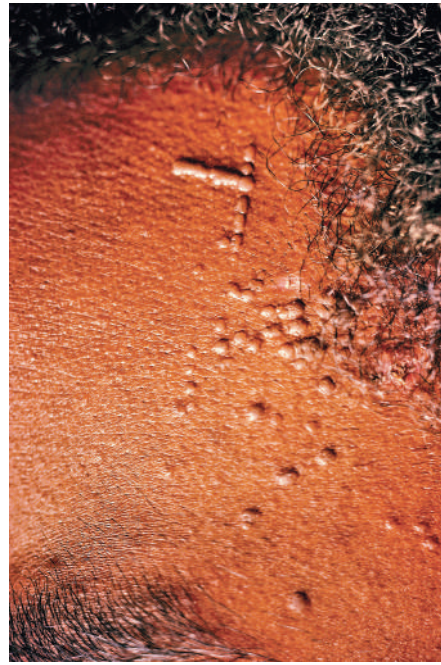

Fig. 19-45 Verruca plana, flat wart with koebnerization.

characteristic that it has given us the word “verrucous,” used to describe lesions with similar surface character (e.g., seborrheic keratosis). In some cases, a single wart (mother wart) appears and grows slowly for a long time, and then suddenly many new warts erupt. On the surface of the wart, tiny black dots may be visible, representing thrombosed, dilated capillaries. Trimming the surface keratin makes the capillaries more prominent and may be used as an aid in diagnosis. Warts do not have dermatoglyphics (fingerprint folds), in contrast to calluses, in which these lines are accentuated.

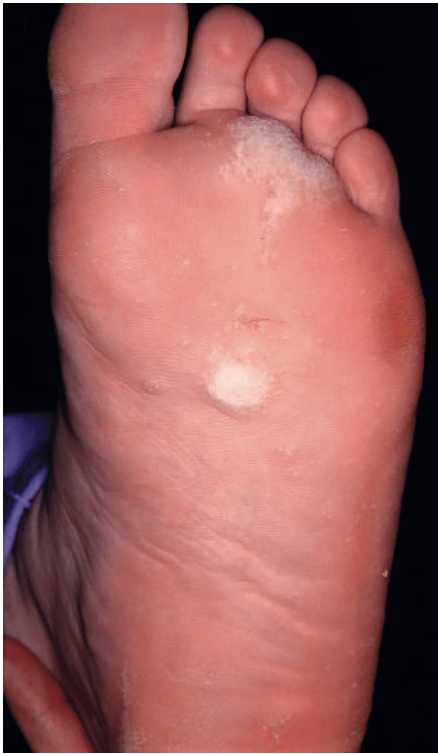Common warts may occur anywhere on the skin, apparently spreading from the hands by autoinoculation. In nail biters, warts may be seen on the lips and tongue, usually in the middle half, and infrequently in the commissures. Digitate or filiform warts tend to occur on the face and scalp and present as single or multiple spikes stuck on the surface of the skin.

### Pigmented warts

Pigmented warts have frequently been reported in Japan. They appear on the hands or feet and resemble common warts or plantar warts, except for their hyperpigmentation. They are caused by HPVs 4, 65, and 60. The pigmentation is caused by melanocytes in the basal cell layer of the HPV-infected tissue, which contain large amounts of melanin. This is proposed to be caused by “melanocyte blockade,” or the inability of the melanocytes to transfer melanin to the HPV-infected cells.

### Flat warts (verruca plana)

Human papillomavirus types 3, 10, 28, and 41 most often cause flat warts. Children and young adults are primarily affected. Sun exposure appears to be a risk factor for acquiring flat warts. They are common on swimmers and on the sun-exposed surfaces of the face and lower legs. Flat warts present most often as 2–4 mm, flat-topped papules that are slightly erythematous or brown on pale skin and hyperpigmented on darker skin. They are generally multiple and are grouped on the face, neck, dorsa of the hands, wrists, elbows, or knees (Fig. 19-45). The forehead, cheeks, and nose, and particularly the area around the mouth and the backs of the hands, are the favorite locations. In men who shave their beards and in



**Fig. 19-46** Plantar warts, verruca plantaris.

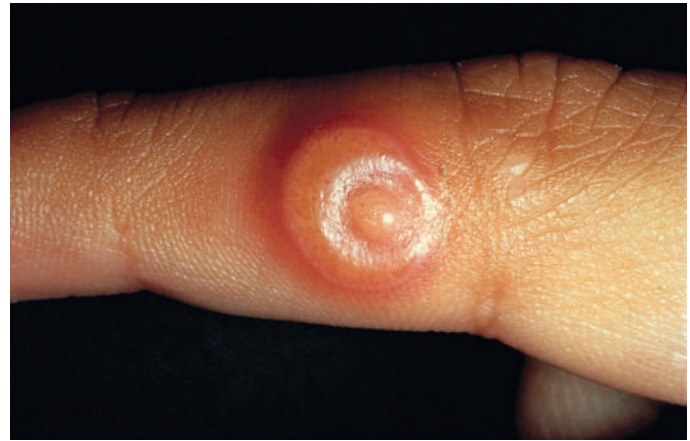women who shave their legs, numerous flat warts may develop as a result of autoinoculation. A useful finding is the tendency for the warts to undergo koebnerization, forming linear, slightly raised, papular lesions. Hyperpigmented lesions occur, and when scarcely elevated, may be confused with lentigines or ephelides. Plaquelike lesions may be confused with verrucous nevus, lichen planus, and molluscum contagiosum. When lesions occur only on the central face and are erythematous, they can be easily confused with papular acne vulgaris. Of all clinical HPV infections, flat warts have the highest rate of spontaneous remission.

### Plantar warts (verruca plantaris)

Human papillomaviruses 1, 2, 27, and 57 cause plantar warts. These warts generally appear at pressure points on the ball of the foot, especially over the midmetatarsal area, but may be anywhere on the sole. Frequently, several lesions develop on one foot (Fig. 19-46). Sometimes they are grouped, or several contiguous warts fuse so that they appear as one. Such a plaque is known as a mosaic wart. The soft, pulpy cores are surrounded by a firm, horny ring. Over the surface of the plantar wart, most clearly if the top is shaved off, multiple small, black points may be seen that represent dilated capillary loops within elongated dermal papillae. Plantar warts may be confused with corns or calluses but have a soft, central core and black or bleeding points when pared down, features that calluses lack.

The myrmecia type of verruca occurs as smooth-surfaced, deep, often inflamed and tender papules or plaques, mostly on the palms or soles, but also beside or beneath the nails, or less often on the pulp of the digits (Fig. 19-47). They are distinctively dome shaped and much bulkier beneath the surface than they appear. Myrmecia are caused by HPV-1. They can be mistaken for a paronychia or digital mucinous cyst.

Human papillomaviruses 60 causes a peculiar type of plantar wart called a ridged wart because of the persistence of the dermatoglyphics across the surface of the lesion. Typically, the warts are slightly elevated, skin-colored, 3–5 mm papules. They occur on non-weight-bearing areas and lack the typical



**Fig. 19-47** Myrmecia.

features of plantar warts. HPV-60 also causes plantar verrucous cysts, 1.5–2 cm, epithelium-lined cysts on the plantar surface. These cysts tend to occur on weight-bearing areas, suggesting that HPV-infected epidermis is implanted into the dermis, forming the cyst. It is common to see ridged warts near plantar verrucous cysts.

### Histologic features

Typical nongenital warts rarely require histologic confirmation, although a biopsy may be useful in several settings. Histology can be used to distinguish warts from corns and other keratotic lesions that they resemble. This is enhanced by IP staining for HPV capsid antigen. Cytologic atypia and extension into the dermis suggest the diagnosis of an HPV-induced squamous cell carcinoma. There is a correlation between HPV type and the histologic features of the wart, allowing identification of the HPV types that cause specific lesions, a useful feature in the diagnosis of epidermodysplasia verruciformis, for example.

### Treatment

The quality of evidence regarding the efficacy of therapies for common and plantar warts is very low. Studies have not used standard treatment protocols, and until recently, HPV type has not been evaluated along with treatment response. This hinders the development of evidence-based guidelines. The form of therapy used depends on the type of wart being treated, the patient's age and immune status, and previous therapies used and their success or failure. With any treatment modality, at least 3 months of sustained management is considered a reasonable therapeutic trial. With immunologic treatments, this may be insufficient to see a response. No treatment should be abandoned too quickly. Since many nongenital warts will spontaneously regress, the treatment algorithm should allow for nonaggressive options, and the patient should be offered the option of no treatment. Indications for treatment are pain, interference with function, social embarrassment, and risk of malignancy. The ideal aims of therapy are as follows:

1. To result in the wart(s) disappearing
2. Not to produce scarring or permanent sequelae from the treatment
3. Ideally, to induce lifelong immunity to that HPV type to prevent recurrence

### Flat warts

Flat warts frequently undergo spontaneous remission, so therapy should be as mild as possible, and potentially scarring



therapies should be avoided. If lesions are few, light cryotherapy is a reasonable consideration. Topical salicylic acid products can also be used. Treatment with topical tretinoin once or twice daily, in the highest concentration tolerated to produce mild erythema of the warts without frank dermatitis, can be effective over several months. Tazarotene cream or gel may also be effective. Imiquimod 5% cream used up to once daily can be effective. If the warts fail to react initially to the imiquimod, tretinoin may be used in conjunction. Should this fail, 5-FU cream 5%, applied twice daily, may be effective. Anthralin, although staining, could be similarly used for its irritant effect. For refractory lesions, laser therapy in very low fluences or photodynamic therapy (PDT) might be considered before electrodesiccation because of the reduced risk of scarring. Ranitidine, 300 mg twice daily, cleared 56% of refractory flat warts in one study, with similar results using cimetidine (25–40 mg/kg). Three months of oral isotretinoin therapy at 30 mg/day was highly successful and might be considered when the previous topical approaches have failed. Immunotherapy with dinitrochlorobenzene (DNCB), squaric acid, or diphencyprone, or intralesional *Candida* or other antigens, can be used on limited areas of flat warts, with the hope that the immune response will clear distant warts. The induced dermatitis requires careful dose monitoring when treating facial lesions.

### Common warts

Treatments for common warts involve two basic approaches: destruction of the wart and induction of local immune reactions (immunotherapy). Destructive methods are most often used as initial therapy by most practitioners. Cryotherapy is a reasonable first-line therapy for most common warts. For non-plantar warts, it is more effective than salicylic acid. The cure rate is 20–50% with repeated applications over several months. The wart should be frozen adequately to produce a blister after 1 or 2 days. This correlates with a thaw time of 30–45 s for most common warts. A sustained 10-s freeze with a spray gun was found to be more effective than simply freezing to obtain a 2–3 mm halo around the wart. Aggressive cryotherapy can produce significant blistering and may be complicated by significant postprocedural pain for several days. A single freeze-thaw cycle was found to be as effective as two cycles. The ideal frequency of treatment is every 2 or 3 weeks, just as the old blister peels off. A spray device, while more costly, is quicker and cannot spread infectious diseases (especially viral hepatitis) from one patient to the next. Children may be frightened by such a device, so a cotton-tipped swab is an option for them. Cryotherapy can be effective for periungual warts. Damage to the matrix is unusual or rare, because periungual warts usually affect the lateral nailfolds, not the proximal one. Complications of cryotherapy include hypopigmentation, infrequently scarring, and rarely, damage to the digital nerve from freezing too deeply on the side of the digit. Patients with Fanconi anemia, cryoglobulinemia, poor peripheral circulation, and Raynaud phenomenon may develop severe blisters when cryotherapy is used to treat their warts. Doughnut warts, with central clearing and an annular recurrence, may complicate cryotherapy.

Products containing salicylic acid with or without lactic acid are effective patient-applied treatments. Results have been conflicting, with some studies showing equal efficacy with cryotherapy and others showing marked inferiority to cryotherapy. To optimize salicylic acid treatment, the following treatment approach is suggested. After the wart-affected area is soaked in water for 5–10 min, the topical medication is applied, allowed to dry, and covered with a strip bandage for 24 h. This is repeated daily. The superficial keratinous debris may be removed by scraping with a table knife, pumice stone, or emery board.

Alternatively, a small amount of Cantharone (0.7% cantharidin) is applied to the wart, allowed to dry, and covered with occlusive tape for 24 h or until the patient experiences burning. A blister, similar to that produced by cryotherapy, develops in 24–72 h. These blisters may be as painful as or more painful than those following cryotherapy. Treatment is repeated every 2–3 weeks. Perhaps more than any other method, cantharidin tends to produce doughnut warts, a round wart with a central clear zone at the site of the original wart. Nonetheless, Cantharone is a very useful adjunct in the management of difficult-to-treat verrucae. It also has the advantage it can be applied painlessly to children.

The initial enthusiasm for occlusive therapy with tape (e.g., duct tape) has not been substantiated by follow-up studies. Occlusive therapy is inferior to cryotherapy, and success rates in adults are about the same as with placebo. If occlusive therapy is contemplated, a relatively impermeable tape should be used and the wart kept occluded at least 6½ and up to 7 days of the week. The key appears to be keeping the wart occluded as much of the time as possible. Duct tape, moleskin, or transparent tape (Blenderm) is a practical option. Fenestrated and semipermeable dressings have not been studied and may not be effective. Occlusive therapy is a good initial option for young children (<12 years) with plantar warts, in whom spontaneous resolution is high, and for others unwilling to have alternate forms of treatment. Unfortunately, in adults, the efficacy of duct tape for common warts is very low. Two months of treatment resolved common warts in only 20% of patients, and 75% of “resolved” warts recurred.

Bleomycin has high efficacy and is an important treatment for recalcitrant common warts. It is used at a concentration of 1 U/mL, which is injected into and immediately beneath the wart until it blanches. The multipuncture technique of Shelley—delivering the medication into the wart by multiple punctures with a needle through a drop of bleomycin—may also be used, as may an air jet injector. Even a concentration of 0.1 U/mL injected by this method can be effective. For small warts (<5 mm), 0.1 mL is used, and for larger warts, 0.2 mL. The injection is painful enough to require local anesthesia in some patients. Pain can occur for up to 1 week. The wart becomes black, and the black eschar separates in 2–4 weeks. Treatment may be repeated every 3 weeks, but it is unusual for common warts to require more than one or two treatments. Scarring is rare. Response rates vary by location, but average 90% with two treatments for most common, nonplantar warts, even periungual ones. Treatment of finger warts with bleomycin infrequently may be complicated by localized Raynaud phenomenon of treated fingers. Bleomycin treatment of digital warts may rarely result in digital necrosis and permanent nail dystrophy, so extreme caution should be used in treating warts around the nailfolds. Lymphangitis/cellulitis is a rare complication. In a patient receiving a total of 14 U for plantar warts, flagellate urticaria followed by characteristic bleomycin flagellate hyperpigmentation occurred. Intralesional 5-FU and topical 5-FU have been used with variable results. Trials in which 5-FU cream was applied after cryotherapy demonstrated no additional benefit over the cryotherapy alone.

Surgical ablation of warts can be effective treatment, but even complete destruction of a wart and the surrounding skin does not guarantee that the wart will not recur. Surgical methods should be reserved for warts that are refractory to more conservative approaches. Pulsed dye laser therapy initially appeared to have similar efficacy to cryotherapy, but low fluences were used. In recent reports, therapies with high efficacy for refractory warts (70–90%) used fluences of 12.5–15 J/cm<sup>2</sup> (average 14 J/cm<sup>2</sup> in one study). Local anesthesia is required in the majority of patients. A short pulse duration (1.5 ms) is most effective. A 7-mm spot size is used, and

treatment is extended 2 mm beyond the visible wart. The cryo-spray is inactivated because epidermal destruction is the goal. Immediately after treatment, the skin has a gray-black discoloration from thermal damage. The treated area becomes an eschar over 10–14 days. Treatment is repeated every 2–4 weeks, as soon as the eschar falls off, and multiple treatments may be required. In immunocompetent patients, response rates for refractory common and plantar warts are 70–90% with this approach. The pulsed dye laser can also be used to treat warts around the nail that may have extended below the nail plate, because the laser will penetrate the nail plate. Carbon dioxide (CO<sub>2</sub>) laser destruction requires local anesthesia, causes scarring, and may lead to nail dystrophy. Efficacy is 56–81% in refractory warts. A potentially infectious plume is produced with the CO<sub>2</sub> laser. Frequency-doubled neodymium:yttrium-aluminum-garnet (Nd:YAG) laser, 532-nm potassium titanyl phosphate (KTP) laser, and PDT are options in refractory cases.

Oral cimetidine, 25–40 mg/kg/day, has been anecdotally reported to lead to resolution of common warts, perhaps because of its immunomodulatory effects. When used as a single agent, however, in both children and adults, the efficacy is low (30%), comparable with placebo. Cimetidine may be beneficial as an adjunct to other methods, especially for patients using immunotherapy without a brisk response to the antigen. Side effects appear to be limited. Heat treatment, either localized to the wart and delivered by radiofrequency or applied to the affected part by soaking it in a hot bath, has been reported to be effective. Treatment for 15 min at 43–50°C (107.6–122°F) to as short as 30 s at higher temperatures has been used. Extreme caution must be exercised to avoid scalding. Oral administration of acitretin or isotretinoin may also be used in refractory cases.

Immunotherapy with topical and intralesional agents has become a mainstay of wart therapy. The goal is not only that the wart will be eradicated, but that the immune reaction induced in the wart may also lead to widespread and permanent immunity against warts. The agents typically used are topical DNCB, squaric acid dibutyl ester, and diphencyprone, as well as intralesional *Candida* or mumps antigen. In a population previously immunized with bacille Calmette-Guérin, BCG antigen may be used. For the topical immunogens, patients may be initially sensitized at a distant site (usually the inner upper arm) with the topical agents, or the agents may be applied initially to the warts directly. Two treatment approaches are used, and their efficacies have not been compared. Some practitioners apply topical agents in the office in higher concentrations (2–5%), but only about every 2 weeks. Others give their patients take-home prescriptions to use up to daily, although initially at lower concentrations (0.2–0.5%). In most cases, the agents are dissolved in acetone. The treated wart should be kept covered for 24 h after application. If the reaction is overly severe, the strength of the application may be reduced. Wart tenderness may indicate the need to reduce treatment concentration. Warts may begin to resolve within 1 or 2 weeks, but on average, 2–3 months or more of treatment is required. For intralesional *Candida* antigen, treatments are repeated every 3–4 weeks. Overall cure rates for all three topical sensitizers and for intralesional antigen injection is 60–80%. Side effects of treatment include local pruritus, local pain, and mild eczematous dermatitis. Intralesional *Candida* injections may be associated with cytokine-mediated side effects, such as swelling, fever, shaking chills, and a flulike feeling. These begin 6–8 hours after treatment and resolve over 24–48 hours. Patients should be advised of these possible side effects. Most patients have no limitation of activities or function with topical immunotherapy. Scarring has not been reported.

The efficacy of imiquimod for common warts appears to be significantly less than with cryotherapy or topical immuno-

therapy and is considerably more expensive. The routine use of imiquimod in the treatment of common or plantar warts cannot be recommended. Unpublished placebo-controlled trials demonstrated no better response than placebo, with cure rates of about 10%. Topical cidofovir has been used in difficult situations and in immunosuppressed patients. It is compounded in a 1–5% concentration and applied directly to the wart once or twice daily. The method of compounding is critical to the efficacy of topical cidofovir, so a reliable source known to compound an active gel is important. It is extremely expensive, however, and local irritation and erosion may occur. Cidofovir may also be delivered intralesionally in up to 5% concentration.

The value of quadrivalent HPV vaccination for the treatment of common warts is unknown. One study reported resolution of common and plantar warts in four young persons (three under 12 years) after HPV immunization.

### Plantar warts

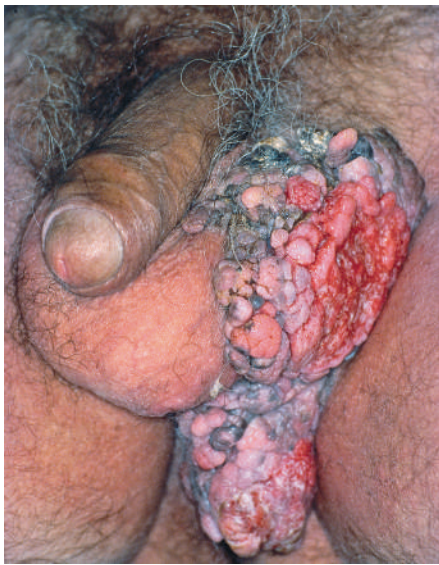In general, plantar warts are more refractory to any form of treatment than are common warts. The exception is HPV-1-induced plantar warts in children under 12 years, which have a high response rate (>50%). Initial treatment usually involves daily application of salicylic acid in liquid, film, or plaster after soaking. In failures, cryotherapy or cantharidin application may be attempted. A second freeze-thaw cycle is beneficial when treating plantar warts with cryotherapy. In trials comparing salicylic acid with cryotherapy for plantar warts versus common warts, cryotherapy is no more effective than patient-applied salicylic acid. In fact, no trial has demonstrated cryotherapy to be superior to placebo in treating plantar warts. Bleomycin injections, laser therapy, or immunotherapy, as previously discussed, may be used in refractory cases. Combination use of bleomycin injections or *Candida* antigen injections with pulse dye laser may be useful in particularly refractory periungual and plantar warts. Surgical destruction with cautery or blunt dissection should be reserved for failures with nonscarring techniques, since a plantar scar may be persistently painful. CO<sub>2</sub> laser may also result in plantar scars. PDT may be effective in some cases. The optimum photosensitizing agent and light source are unknown.

### Genital warts (external genital warts)

Genital warts are the most common STD. Among sexually active young adults in the United States and Europe, infection rates as high as 50% in some cohorts have been found using sensitive PCR techniques. It is estimated that the lifetime risk for infection in sexually active young adults may be as high as 80%. The number of new U.S. cases of genital wart infection diagnosed yearly may approach 1 million. In the about two thirds of couples in whom one has evidence of HPV infection, the partner will be found to be concordantly infected. A large portion of genital HPV infection is either subclinical or latent. Unfortunately, the infectivity of subclinical and latent infection is unknown. Subclinical and latent infection is probably responsible for most “recurrences” after treatment of genital warts. Because the methodology for determining HPV infection in men is less accurate, and women have the major complication of HPV infection, cervical cancer, virtually all data on HPV infection rates and epidemiology are derived from studies of women.

Genital HPV infection is closely linked to cancer of the cervix, glans penis, anus, vulvovaginal area, and periungual skin. Cancer occurs when there is integration of the HPV genome into the host DNA. In high-risk genital HPV types, E6 and E7 gene products bind to and inactivate p53 and retinoblastoma protein (pRb), respectively. This is thought to be



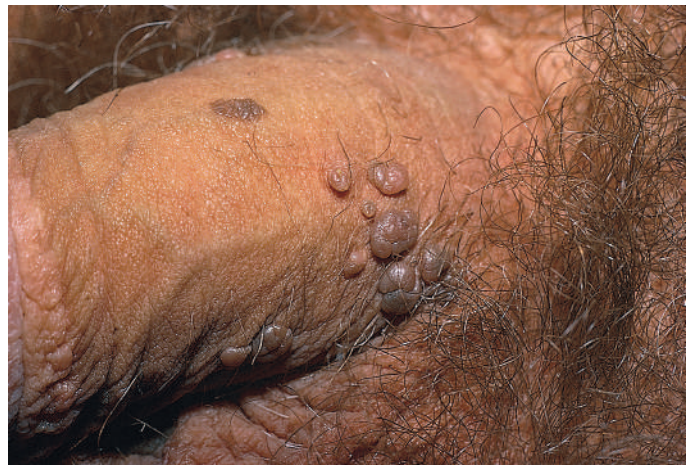

**Fig. 19-48** Squamous cell carcinoma in persistent HPV infection.

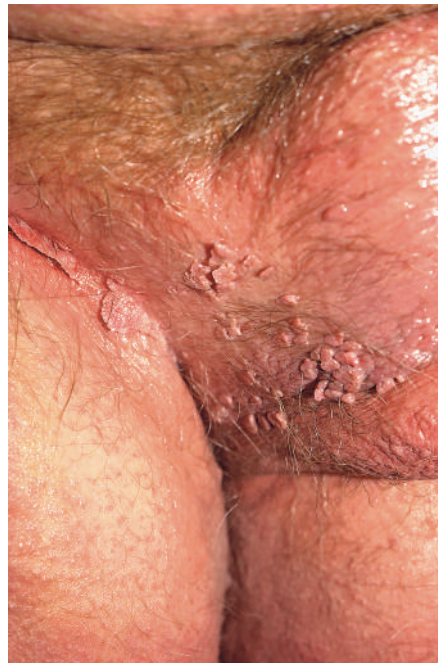important in their ability to cause cancer. In most persons, genital HPV infection appears to be transient, lasting about 1–2 years, and results in no sequelae. In a small proportion, about 2% of immunocompetent persons, infection persists, and in a small proportion of those with persistent HPV infection, cancer may develop (Fig. 19-48). Certain cofactors, such as the HPV type causing the infection, location of infection, cigarette smoking, uncircumcised status, and immunosuppressed status, are associated with progression to cancer. The transition zones of the cervix and anus are at highest risk for the development of cancer.

More than 30 HPV types are associated with genital warts. Patients are typically infected with multiple HPV types, although one HPV type probably causes most of the clinical lesions. Many HPV types are found in studies where the surface is sampled, but deeper in the epithelium, one type of HPV predominates, making studies that use surface sampling difficult to interpret. The HPV types producing genital infection are divided into two broad categories: those that produce benign lesions, or low-risk types, and those associated with cancer, the so-called high-risk or oncogenic types. The most common low-risk genital HPV types are HPV-6 and HPV-11, and most HPV-induced genital dysplasias are caused by HPV-16 and HPV-18. A strong correlation exists between the HPV type and the clinical appearance of HPV-induced genital lesions. Virtually all condylomata acuminata are caused by “benign” HPV-6 and HPV-11. High-risk HPV-16/18 produce flat or sessile, often hyperpigmented lesions. For this reason, biopsy and HPV typing of typical condyloma is rarely necessary.

Genital HPV infection is strongly associated with sexual exposure. Female virgins rarely harbor HPV (about 1%). For women, insertive vaginal intercourse is strongly associated with acquiring genital HPV infection, with 50% of women testing positive for genital HPV within 5 years of the first sexual intercourse. However, sexual contact does not need to be penile-vaginal; the risk of acquiring genital HPV infection was 10% in women who had nonpenetrative sexual exposure versus 1% of women who had no such exposure. This suggests oral/digital/genital-genital exposure can transmit HPV infection to the introital skin. This infection may then be spread to other sites by self-inoculation. For this reason, women who have sex with women may have genital HPV infection and still require regular gynecologic evaluation. Condom use may be partly, but not completely, protective for acquisition of genital



**Fig. 19-49** Condylomata acuminata.



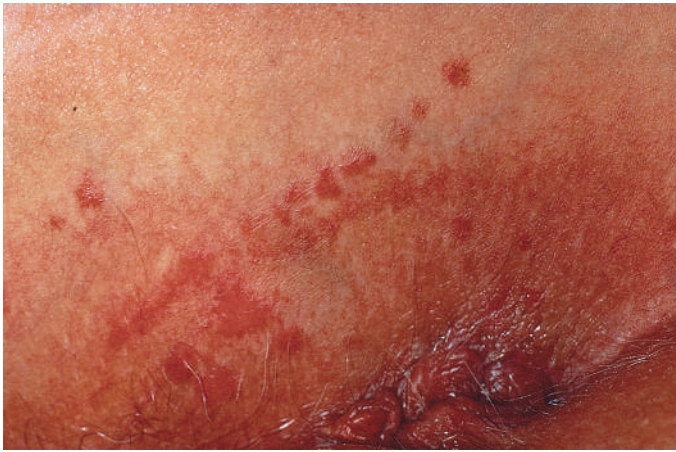**Fig. 19-50** Genital warts.

HPV infection. In men, risk of genital HPV infection is associated with being uncircumcised, having had sex before age 17, having had more than six sexual partners in their lifetime, and having had sex with professional sex workers. Smokers are at increased risk to develop genital warts.

### **Condylomata acuminata**

Condylomata on the skin surface appear as lobulated papules that average 2–5 mm in size, but they may range from microscopic to many centimeters in diameter and height. Lesions are frequently multifocal. Numerous genital warts may appear during pregnancy. Condylomata acuminata occur in men anywhere on the penis (Fig. 19-49) or about the anus. Scrotal condylomata occur in only 1% of immunocompetent male patients with warts (Fig. 19-50). Intraurethral condylomata may present with terminal hematuria, altered urinary stream, or urethral bleeding. In women, lesions appear on the mucosal surfaces of the vulva or cervix, on the perineum, or about the anus. Cauliflower-like masses may develop in moist, occluded areas such as the perianal skin, vulva, and inguinal folds. As a result of accumulation of purulent material in the clefts, these may be malodorous. Their color is generally gray, pale yellow, or pink. When perianal lesions occur, a prior history





**Fig. 19-51** Genital warts, bowenoid papulosis.

of receptive anal intercourse will usually predict whether intra-anal warts are present and will help to determine the need for anoscopy. Immunosuppressed individuals and those with infection by known high-risk HPV types at other sites should have routine anal Papanicolaou (Pap) smears to detect malignant change.

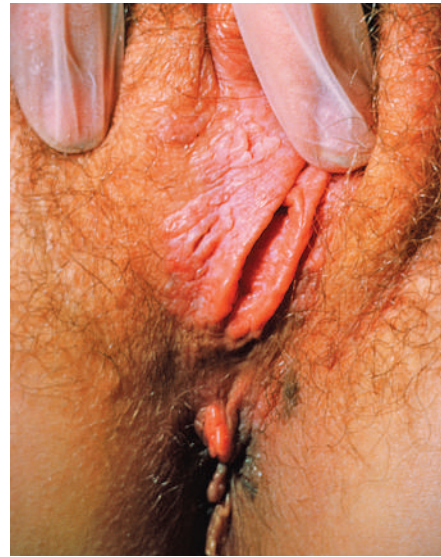Genital warts are sexually transmitted, and other STDs may be found in patients with genital warts. A complete history should be taken and the patient screened for other STDs as appropriate. The whole genital area should be carefully examined because external genital wart (EGW) infection is often multifocal. HIV testing is recommended. Women with EGWs should have a routine cervical cytologic screening to detect cervical dysplasia, but the presence of EGWs alone does not require more frequent Pap smears or gynecologic evaluation.

### ***Bowenoid papulosis and HPV-induced genital dysplasias***

Bowenoid papulosis is characterized by flat, often hyperpigmented papules a few millimeters to several centimeters in diameter. These occur singly or, more often, may be found in multiples on the penis, near the vulva, or perianally (Fig. 19-51). At times, similar lesions are seen outside the genital area in the absence of genital bowenoid papulosis. They occur most frequently on the neck or face and are more common in men. They contain HPV-16, HPV-18, or other high-risk HPV types. In the new standard terminology for lower anogenital squamous lesions, this is called HSIL (high-grade squamous intraepithelial lesion). It is usually caused by HPV-16. On the glabrous external genitalia, bowenoid papulosis usually behaves similar to other EGWs but may progress to squamous cell carcinoma (SCC). Patients may simultaneously have bowenoid papulosis of the genitalia and SCC in situ, especially in the periungual area, both caused by the same HPV type. On the glans penis of an uncircumcised male and on the cervical, vaginal, or rectal mucosa, progression to invasive SCC is more likely (Fig. 19-52). Female partners of men with bowenoid papulosis and women with bowenoid papulosis have an increased risk of cervical dysplasia. Histologically, the biopsies of squamous cell carcinoma in situ and HSIL caused by HPV (bowenoid papulosis) are very similar. Pigmentation of the epithelium and numerous mitoses, especially in metaphase, are characteristic but not diagnostic of HPV-induced HSIL on the external genitalia.

### ***Giant condyloma acuminatum (Buschke-Lowenstein tumor)***

Giant condyloma acuminatum is a rare, aggressive, wartlike growth that is a verrucous carcinoma. Unlike other HPV-



**Fig. 19-52** Genital Bowen's disease.

induced genital carcinomas, this tumor is usually caused by HPV-6. It occurs most often on the glans or prepuce of an uncircumcised male; less often, it may occur on perianal skin or the vulva. Despite its bland histologic picture, it may invade deeply, and infrequently it may metastasize to regional lymph nodes. Treatment is by complete surgical excision. Recurrence after radiation therapy may be associated with a more aggressive course.

### ***Diagnosis***

Even in women with confirmed cervical HPV infection, serologic tests are positive in only 50%, making serologic diagnosis of HPV infection of no use to the practicing clinician. HPV cannot be cultured. HPV typing by in situ hybridization or PCR is useful in managing HPV infection of the cervix and in some cases of prepubertal HPV infection, but not in the management of EGW. Virtually all condylomata can be diagnosed by inspection. Bright lighting and magnification should be used when examining for genital HPV infection. Flat, sessile, and pigmented lesions suggest bowenoid papulosis and may require a biopsy. Subclinical and latent infections are no longer sought or investigated because they are very common, and no management strategy is known to eradicate these forms of HPV infection. Soaking with acetic acid is not generally necessary but may be helpful to detect early lesions under the foreskin. In patients with multiple recurrences, acetic acid soaking may determine the extent of infection, helping to define the area for application of topical therapies. The procedure is performed by soaking the external genitalia in men and the vagina and cervix in women with 3–5% acetic acid for up to 10 min. Genital warts turn white (acetowhitening), making them easily identifiable. Any process that alters the epidermal barrier will be acetowhite (e.g. dermatitis), however, so only typical acetowhite lesions should be treated as warts. In atypical cases, a 2-week trial is attempted with a 1% hydrocortisone preparation plus a topical anticandidal imidazole cream. If the acetowhitening persists, a biopsy is performed and histologic evidence of HPV infection sought. IP or in situ hybridization (ISH) methods may aid in evaluation. PCR should probably not be performed on such biopsied specimens, except possibly in childhood cases. The high background rate of latent infection (up to 50%) makes interpretation of a positive PCR impossible. In contrast, chromogenic ISH clearing demonstrates the localization of positive nuclei within the lesion and can confirm a lesion to be HPV induced.



## Treatment

Because no effective virus-specific agent exists for their treatment, genital warts frequently recur. Treatment is not proved to reduce transmission to sexual partners or to prevent progression to dysplasia or cancer. Specifically, the treatment of male sexual partners of women with genital warts does not reduce the recurrence rate of warts in these women. Therefore, the goals of treatment must first be discussed with the patient and perhaps with the sexual partner. Observation represents an acceptable option for some patients with typical condylomata acuminata. In some patients, only wart-free periods are achieved. Because genital warts may cause discomfort, genital pruritus, foul odor, bleeding, and substantial emotional distress, treatment is indicated if requested by the patient. Bleeding genital warts may increase the sexual transmission of HIV and hepatitis B and C. Bowenoid papulosis may be treated as discussed next when it occurs on the external genitalia. Lesions with atypical histology (high-grade squamous intraepithelial) on mucosal surfaces and periungually are special cases, and treatment must be associated with histologic confirmation of eradication in patients receiving topical treatments.

The treatment chosen is in part dictated by the size of the warts and their location. The number of EGWs at the initial evaluation is strongly predictive of wart clearance. Patients with four or fewer EGWs will be clear with three or fewer treatments, whereas only 50% of patients with 10 or more EGWs will be clear after three treatments. Only 1% of patients with one to four EGWs will still have lesions after eight treatments, but 20% of patients with 10 or more EGWs will still have lesions after eight treatments. A more effective or aggressive treatment approach might be considered in patients with high numbers of EGWs.

Podophyllin is more effective in treating warts on occluded or moist surfaces, such as on the mucosa or under the prepuce. It is available as a crude extract, usually in 25% concentration in tincture of benzoin. It is applied weekly by the physician and can be washed off 4–8 h later by the patient, depending on the severity of the reaction. After six consecutive weekly treatments, approximately 40% of patients are free of warts, and 17% are free of warts at 3 months after treatment. Purified podophyllotoxin 0.5% solution or gel is applied by the patient twice daily for 3 consecutive days of each week in 4- to 6-week treatment cycles. Efficacy approaches 60% for typical condylomata, and side effects are fewer than with standard, physician-applied podophyllin preparations. Therefore, whenever possible, podophyllotoxin should be used instead of classic podophyllin solutions.

Imiquimod, an immune response modifier that induces IFN locally at the site of application, has efficacy similar to cryotherapy (about 50%) and yields a low recurrence rate (22%). Imiquimod is available in a 250-mg sachet containing a 5% cream formulation and in a 3.75% 7.5-g pump dispensing 0.235 g. One 5% sachet can cover up to 350 cm<sup>2</sup> when applied appropriately, allowing for several treatments with a single sachet if the treatment area is limited. The 5% cream is applied daily or every other day for up to 16 weeks. The 3.75% cream is applied daily for 2 weeks, followed by a 2-week rest period, to a maximum of 8 weeks of treatment. Imiquimod 5% cream is more effective than podophyllotoxin in treating women with EGW infection, but only equally or slightly less effective in men, especially for warts on the penile shaft. Imiquimod is less effective than cryotherapy in the treatment of EGWs. The 3.75% cream is less effective than the 5% cream, resulting in only a 33% clearance. Therapeutic response to imiquimod is slow, requiring several weeks in some patients to see any effect. Treatment results in mild to moderate irritation, less than with podophyllin or cryotherapy in men, but with a

similar side effect profile in women. The 3.75% cream has less side effects. Rare complications reported with the 5% cream include flaring of psoriasis and psoriatic arthritis, vitiligo-like hypopigmentation, induction of genital ulcers in a patient with Behçet's disease, and the production of a local neuropathy. Imiquimod should be used cautiously in persons with psoriasis. Neuropathy is associated with application of excessive amounts, occlusion of the medication, and application to an eroded mucosa.

Imiquimod may be used to treat penile condyloma in circumcised and uncircumcised men, anal and perianal condyloma, and vulvar condyloma. It may be used as the initial treatment or when recurrence has been frequent after attempting other forms of treatment. Several trials demonstrated that the use of imiquimod after electrosurgical destruction of warts results in a significant reduction in recurrences (20% vs. 65% in one study and 8% vs. 25% in another). Although the percentage of recurrences differed significantly in these studies, the imiquimod-treated patients in both studies had a threefold to fourfold reduction in wart recurrence. The use of imiquimod after surgical destruction of condyloma should be considered in all immunocompetent patients, especially those with recurrence after a previous surgical procedure. It is unclear whether the imiquimod should be started before the surgical procedure or after postsurgical healing. The duration of continued imiquimod therapy after ablation is also unknown, but most recurrences are during the first 3–6 months, so 3 months of therapy would be reasonable. Application of imiquimod three times weekly after surgery may be more effective than only twice weekly, although these two approaches have not been compared. Suppositories containing about 5 mg of imiquimod appear to reduce the risk of recurrence of anal condyloma in immunocompetent men after surgical ablation of extensive anal disease. Imiquimod has been effective in the treatment of bowenoid papulosis.

The topical application of green tea extract containing sin catechins (Polyphenon E or Veregen) can be effective in treating EGWs. A 15% ointment applied three times daily leads to EGW clearance in 60% of women and 45% of men. Placebo cleared 35% of patients in this blinded study. If only the patients treated in the United States are considered, complete clearance occurred in 24% of patients. The average time to complete clearance is 16 weeks. Erythema and erosions at the application site occur in 50% of patients, and 67% had moderate to severe reactions.

Bichloroacetic acid or TCA 35–85% can be applied to condylomata weekly or biweekly. TCA is safe for use in pregnant patients. Compared with cryotherapy, TCA has the same or lower efficacy and causes more ulcerations and pain. It is not generally recommended for EGWs, because other available treatments are more effective and cause less morbidity.

Cryotherapy with liquid nitrogen is more effective than podophyllin and imiquimod, approaching 70–80% resolution during treatment and 55% at 3 months after treatment. One or two freeze-thaw cycles are applied to each wart every 1–3 weeks. A zone of 2 mm beyond the lesion is frozen. Cryotherapy is effective in dry as well as moist areas. Perianal lesions are more difficult to eradicate than other genital sites, and two freeze-thaw cycles are recommended in this location. Cryotherapy is safe to use in pregnant patients. EMLA cream with or without subsequent lidocaine infiltration may be beneficial in reducing the pain of cryotherapy. The addition of podophyllin to cryotherapy does not result in statistically better results after 2 months of therapy and cannot be recommended as standard treatment.

Electrofulguration or electrocauterization with or without snip removal of the condyloma is more effective than TCA, cryotherapy, imiquimod, or podophyllin. Wart clearance

during therapy is almost 95%, and wart cure at 3 months exceeds 70%. Local anesthesia is required, and scarring may occur. Surgical removal is ideal for large, exophytic warts that might require multiple treatments with other methods. It has high acceptance in patients who have had recurrences from other methods because results are immediate and cure rates higher.

The use of CO<sub>2</sub> laser in the treatment of genital warts has not been shown to be more effective than simpler surgical methods. Although visible warts are eradicated by the laser, HPV DNA can still be detected at the previous site of the wart. The CO<sub>2</sub> laser has the advantage of being bloodless, but it is costlier and requires more technical skill to avoid complications. It should be reserved for treatment of extensive lesions in which more cost-effective methods have been attempted and failed. Adjunctive PDT does not prevent recurrence of EGW after CO<sub>2</sub> laser ablation. Compared with CO<sub>2</sub> laser ablation of EGWs, 5-aminolevulinic acid (ALA) with PDT demonstrated higher efficacy and fewer recurrences and was less painful. ALA-PDT response rate is about 75%. ALA-PDT should be considered before CO<sub>2</sub> laser ablation for the treatment of multiple small, but refractory condyloma.

Any surgical method that generates a smoke plume is potentially infectious to the surgeon. HPV DNA is detected in the plumes generated during CO<sub>2</sub> laser or electrocoagulation treatment of genital warts. The laser-generated plume results in longer-duration HPV aerosol contamination and wider spread of detectable HPV DNA. If these methods of wart treatment are used, an approved face mask should be worn, a smoke evacuator used at the surgical site during the procedure to remove the plume, and the equipment decontaminated after the surgery.

5-Fluorouracil 5% cream applied twice daily may be effective, especially in the treatment of flat, hyperpigmented lesions, such as those in Bowenoid papulosis. Care must be taken to avoid application to the scrotum, because scrotal skin is prone to painful erosions. Twice-daily instillation of 5-FU into the urethra can be used to treat intraurethral condylomata. The cone from a tube of lidocaine (Xylocaine) jelly will fit onto the thread of the 5-FU tube, or the cream may be instilled with a syringe. It is typically left in place for 1 h before the patient voids. Care should be taken that drips of urine containing the medication do not contact the scrotum. 5-FU may also be used to treat intravaginal warts by instillation in the vagina, but this is often associated with severe irritation. Intermittent therapy (twice weekly for 10 weeks) is better tolerated than daily therapy. 5-FU is not usually recommended for the treatment of typical EGWs because other methods of treatment are available.

Immunotherapy can also be effective for refractory EGWs. This is usually delivered by injection of *Candida*, BCG, purified protein derivative (PPD), or some other antigen, rather than through topical application, because of the difficulty in preventing exposure of normal skin with a topical solution. Immunotherapy may be combined with destructive methods in refractory cases. The injection of HPV-6 VLPs was found to speed the clearance of warts simultaneously treated with cryotherapy, podophyllin, or TCA.

### Human papillomavirus vaccination

The HPV viruslike particles (VLPs) are composed of spontaneously assembling L1 molecules and have been used to develop a polyvalent vaccine against HPVs 6, 11, 16, and 18. This vaccine is highly effective and is now approved in more than 100 countries for the immunization of prepubertal girls and boys. Vaccination is recommended for unvaccinated females through age 26 and males age 13–21. HIV-infected men and women should receive immunization through age 26. In older

women (age 24–45) the vaccine is also effective and may be given as a “catch-up” vaccine in women with no evidence of prior genital HPV infection with HPVs 6, 11, 16, or 18. Since HPV-16 and HPV-18 are the primary types associated with cervical cancer, it is hoped that the rate of cancers induced by these high-risk genital HPV types can be reduced by vaccination. The protection, thought to be type specific, did not appear to prevent development of squamous intraepithelial lesions from other HPV types in study participants. However, in countries where HPV-16/18 vaccination was widely applied, the burden of HPV disease caused by HPV-6 and HPV-11 has decreased, suggesting some benefit across HPV types. Currently, quadrivalent vaccination is widely given, and the risk of development of condyloma is clearly dose dependent, with most benefit from three doses. The effect of widespread immunization is most dramatically demonstrated by the data from Australia, which had an aggressive campaign of universal immunization of girls and young women; more than 70% coverage was achieved. There was a 77% reduction in HPV-related infections in the vaccine-eligible women and a 90% reduction in EGWs. Even condyloma in nonvaccinated women and men (who were not yet eligible for immunization) were reduced, demonstrating herd immunity. HPV-related genital HSIL was also reduced by 47% in fully vaccinated women.

### Genital warts in children

Children can acquire genital warts through vertical transmission perinatally and through digital inoculation or autoinoculation, fomite or social nonsexual contact, and sexual abuse. HPV typing has demonstrated that most warts in the genital area of children are “genital” HPV types, and most children with genital warts have family members with a genital HPV infection.

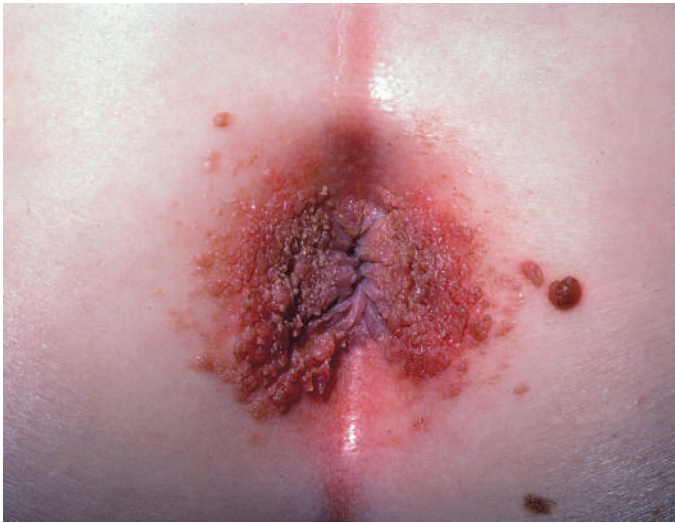Human papillomavirus typing can be performed. However, the presence of genital types of HPV does not prove abuse, and finding a nongenital HPV type does not exclude sexual abuse. In children younger than 1 year, vertical transmission is possible and is probably the most common means of acquisition. The risk for sexual abuse is highest in children older than 3 years. When abuse is suspected, children should be referred to child protection services if the practitioner is not skilled in evaluating children for sexual abuse. Children 1–3 years old are primarily nonverbal and are difficult to evaluate. Management of such patients is on a case-by-case basis. Other STDs should be screened for in children who have a genital HPV infection.

Usually, management of children with anogenital warts requires a multidisciplinary team that should include a pediatrician (Fig. 19-53). Genital warts in children often spontaneously resolve (75%), so no intervention may be a reasonable consideration. Genital warts in children usually respond quickly to topical therapy, such as podophyllotoxin, imiquimod, or light cryotherapy. In refractory cases, surgical removal or electrocautery may be used. A topical anesthetic is recommended before treatment.

### Recurrent respiratory (laryngeal) papillomatosis

Papillomas associated with HPV may occur throughout the respiratory tract, from the nose to the lungs. Recurrent respiratory papillomatosis has a bimodal distribution: in children under age 5 years and after age 15. Affected young children are born to mothers with genital condylomata and present with hoarseness. The HPV types found in these lesions, HPV-6 and HPV-11, are the types seen in genital condylomata. Carcinoma that is often fatal develops in 14% of patients, even in young children. The incidence of carcinoma is higher in those treated with radiation therapy. These patients often have





**Fig. 19-53** Perianal warts in 18-month-old infant.

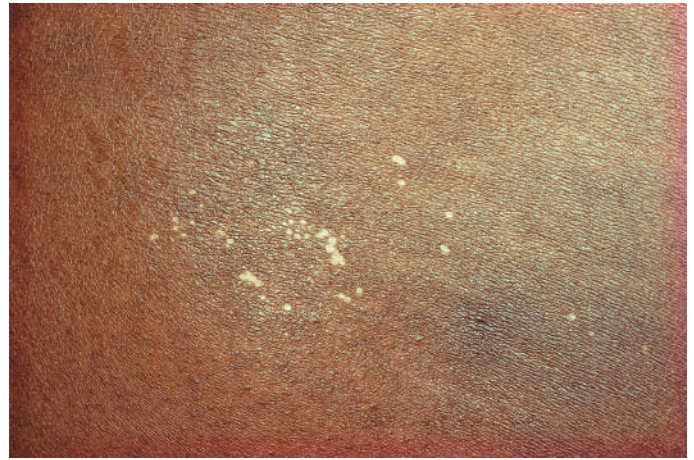
recurrences and require numerous surgeries, usually with the CO<sub>2</sub> laser. Scarring can result from frequent ablations, leading to speech and breathing difficulties. Adjunctive cidofovir has been combined with surgical ablation to help reduce recurrences, with some positive preliminary results. Also, HPV vaccination has been combined with laser ablation, with preliminary results demonstrating reduced recurrences. It is hoped that HPV immunization of young women will reduce the prevalence of HPV-6/11-induced condyloma and thus of respiratory papillomatosis. Routine immunization of children age 11–13 may also have some benefit in preventing the cases that occur after age 15; thus the frequency of this diagnosis is being monitored in some countries.

### Heck's disease

Small, white to pinkish papules occur diffusely in the oral cavity in Heck's disease, also known as focal epithelial hyperplasia. It occurs most frequently in Native Americans of North, Central, and South America; in Inuits; in Greenland Eskimos; and in descendants of Khoi-San in South Africa. In these populations, prevalence rates can be as high as 35%. It is five times more common in females. HPV-13 and HPV-32 have been classically associated with Heck's disease. Clinically, the lesions may be papular or papillomatous and favor the buccal and labial mucosa and the commissures of the mouth. Lesions may spontaneously resolve. Treatment options include cryosurgery, CO<sub>2</sub> laser, electrosurgery, and topical, intralesional, or systemic IFN.

### Epidermodysplasia verruciformis

Epidermodysplasia verruciformis (EV) is a rare, inherited disorder characterized by widespread HPV infection and cutaneous SCCs. Virtually always, EV is inherited as an autosomal recessive trait, although autosomal dominant and X-linked inheritance have also been reported. About 10% of EV patients are from consanguineous marriages. HPV types associated with this syndrome include those infecting normal hosts, such as HPV-3 and HPV-10, as well as many "unique" HPV types, often  $\beta$ -HPVs. These HPV types are called "EV HPVs" and include HPVs 4, 5, 8, 9, 12, 14, 15, 17, 19–25, 36–38, and 47. HPV-5 and HPV-8 are found in 90% of the skin cancers in EV patients. The genetic mutations causing EV are found in two closely linked genes, *EVER1* and *EVER2*. About 75% of all EV cases worldwide have homozygous invalidating mutations in



**Fig. 19-54** Epidermodysplasia verruciformis.

one of these two genes. The *EVER* genes are transmembrane channel-like genes, so *EVER1* is also *TMC-6* and *EVER2* is also *TMC-8*. The function of these genes and how they cause this syndrome are unknown.

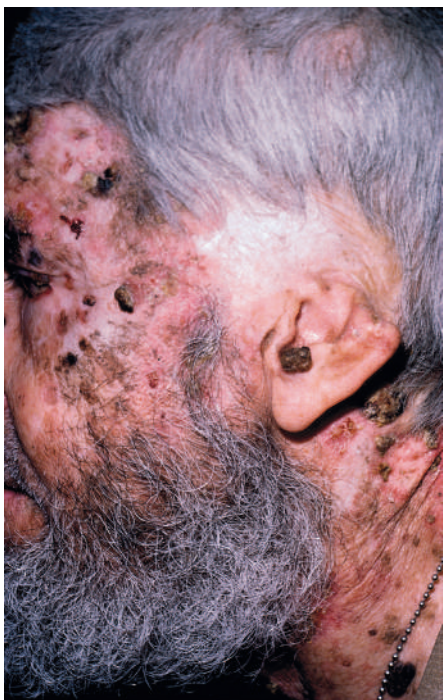The condition presents in childhood and continues throughout life. Skin lesions include flat wart-like lesions of the dorsal hands, extremities, face, and neck. They appear in childhood or young adulthood, apparently earlier in sunnier climates. The characteristic lesions are flatter than typical flat warts and may be quite abundant, growing to confluence (Fig. 19-54). Typical HPV-3/10-induced flat warts may be admixed. In addition, lesions on the trunk are red, tan, or brown patches/plaques or hypopigmented, slightly scaly plaques resembling tinea versicolor. Plaques on the elbows may resemble psoriasis. Seborrheic keratosis-like lesions may also be seen on the forehead, neck, and trunk. Common warts are reported to occur infrequently in some EV cohorts. In other EV patients, common warts of the hands and feet may be present as well.

The histologic features of an EV-specific HPV infection are very characteristic. The cells of the upper epidermis have a clear, smoky, or light-blue pale cytoplasm and a central pyknotic nucleus.

In about one third of EV patients, SCCs develop an average of 24 years after the appearance of the characteristic EV skin lesions. Most often, skin cancers appear on sun-exposed surfaces, but they can appear on any part of the body. SCCs begin to appear at age 20–40, again earlier in patients living in regions with high sun exposure. Skin cancers are less common in African patients, suggesting a protective effect of skin pigmentation. HPV-5 and HPV-8 are found in more than 90% of EV skin cancers. The SCCs may appear de novo, but usually appear on the background of numerous actinic keratoses and lesions of Bowen's disease (Fig. 19-55). Surgical treatment is recommended. Radiation therapy is contraindicated. If skin grafting is required, the grafts should be taken from sun-protected skin, such as the buttocks or inner upper arm.

Aside from surgical intervention for skin cancer, treatment for EV consists largely of preventive measures. Strict sun avoidance and protection should be started as soon as the syndrome is diagnosed. An approach similar to that for children with xeroderma pigmentosa could be instituted. ALA-PDT, topical 5-FU, imiquimod, and oral retinoids may all be used to treat the lesions of patients with EV, but when treatment is discontinued, lesions usually recur.

The mechanism by which cancer occurs in patients with EV is unclear. HPV-5 proteins do not bind to p53 or pRb. The p53 mutations present in the SCCs of patients with EV are characteristic of those induced by UVB light, confirming the close association of UV exposure and the development of cancer in



**Fig. 19-55** Multiple SCCs in epidermodysplasia verruciformis.

patients with EV. HPV DNA of EV has been reported in 35% of the general population in very low copy number, suggesting that the presence of these EV HPVs alone is not the cause of the skin cancers. Rather, the *EVER* genes apparently control important immune responses in the epidermis that control HPV replication, and in their absence, viral replication goes unchecked and can eventually lead to skin cancer in sun-damaged skin. Supporting this concept is the recent report of a polyomavirus-positive Merkel cell carcinoma in an EV patient. Infection with EV HPV types has been reported in immunosuppressed patients, especially those with HIV. This has been called “acquired EV.” Typical flat, scaly lesions resembling tinea versicolor are most common. SCC has not been reported in these patients. Some patients with extensive (>100) common and plantar warts that never resolve and simply grow to confluence have been called “generalized verrucosis.” These patients do not develop skin cancers and live into adulthood. Some of these patients have been identified with mutations in *GATA2*, *DOCK8*, or *CXCR4* or with idiopathic CD4 lymphopenia. Some of these patients, unlike EV patients, are at high risk for anogenital HPV disease and its complications.

### Immunosuppressed patients

Patients with defects in cell-mediated immunity may have an increased frequency of HPV infection. Predisposing conditions include organ transplantation, immunosuppressive medications, congenital immunodeficiency diseases, lymphoma, and HIV infection.

Organ transplant recipients begin to develop warts soon after transplantation, and by 5 years, up to 90% of transplant patients have warts. Initially, these are common and plantar warts, but later, numerous flat warts appear, particularly in sun-exposed areas. Genital warts are also increased, and especially in women, genital dysplasias are more frequent. The presence of keratotic lesions of any type on the skin is a strong predictor for development of nonmelanoma skin cancer (NMSC) in transplant patients. It is especially important in immunosuppressed patients to monitor the genital and anal

areas regularly for changing lesions and to have a low threshold for performing a biopsy.

In HIV disease, common, plantar, flat, oral, and genital warts are all common. Warty keratoses at the angle of the mouth, often bilateral, are a characteristic manifestation of HPV infection in patients with AIDS. The warts are caused predominantly by HPVs 2, 27, and 57. HPV-7 can be found in cutaneous, oral, and perioral warts in nonbutchers with HIV infection. HPV-6 may be found in common warts. Genital warts are increased 15-fold among HIV-infected women. Fifty percent or more of HIV-infected MSM have evidence of anal HPV infection. Genital neoplasia associated with HPV-16 and HPV-18 occurs much more frequently in HIV-infected women and MSM. Infrequently, HIV patients develop HPV-5/8-induced EV-like lesions. Although nongenital skin cancers are also common in some fair-skinned HIV patients, HPV has not been demonstrated in the nongenital SCCs of these patients. With antiretroviral therapy, warts may disappear. Paradoxically, increased rates of genital and oral warts may be seen in HIV patients in the first several years of adequate control of their HIV infection, part of IRIS. The likelihood of clearance of common warts in persons with HIV is related to the nadir of their Th cell count. HIV-infected persons whose Th count never falls below 200 cells are more likely to have sustained remission of their warts.

The treatment of warts in immunosuppressed hosts can be challenging. Although standard methods are used, their efficacy may be reduced. For common and plantar warts, surgically ablative methods, cryotherapy, bleomycin injections, PDT, and aggressive pulsed dye laser therapy would be expected to be more effective, because the agents designed to induce an immune response would be less effective in the immunosuppressed patient. In one study using intralesional *Candida* antigen for common warts, the response rate was less than 50% in HIV patients, and no patient showed a distant benefit for untreated warts. Imiquimod has low efficacy in these patients; only 8% had complete clearance of common warts, and 50% had no response. For genital warts, treatment is determined by size. Any wart larger than 2 cm should be sent for consideration of surgical removal and histologic evaluation. Smaller warts can be treated with electrosurgery, cryotherapy, topical 5-FU, and ALA-PDT. Imiquimod can be attempted and is most effective for EGWs on occluded skin (intra-anal, under the prepuce). Most transplant patients tolerate imiquimod well, without inducing enough systemic immune response to cause rejection of their transplanted organ. However, widespread use of imiquimod in one renal transplant patient led to acute renal failure. Topical cidofovir (1–5% concentration) and intralesional cidofovir (7.5 mg/mL) have been effective in refractory anogenital and common warts in immunodeficient patients. Although topical cidofovir is very expensive, is irritating, and can cause skin erosion and ulceration, it is active against the HPV and thus does not require participation of the patient’s immune system to eradicate the wart. Addition of sirolimus to the immunosuppressive regimen may be associated with a decrease in the number of warts in organ transplant patients. In four pediatric transplant patients, substitution of leflunomide for mycophenolate in the immunosuppressive regimen, with monitoring of leflunomide metabolites for 3–6 months or more, resulted in clearance or dramatic improvement of cutaneous warts and molluscum contagiosum. Mycophenolate was reinstated and leflunomide stopped without recurrence of the warts. In organ transplant patients with widespread actinic damage and many precancerous lesions, PDT can be considered.

**Ahmed I, et al:** Liquid nitrogen cryotherapy of common warts: cryo-spray vs. cotton wool bud. *Br J Dermatol* 2001; 144:1006.



- Alghamdi KM, Khurram H:** Successful treatment of periungual warts with diluted bleomycin using translesional multipuncture technique: a pilot prospective study. *Dermatol Surg* 2011; 37:486.
- Ali H, et al:** Decline in in-patient treatments of genital warts among young Australians following the national HPV vaccination program. *BMC Infect Dis* 2013; 13:140.
- Ayer J, et al:** Successful treatment of Buschke-Lowenstein tumour of the penis with carbon dioxide laser vaporization. *Acta Derm Venereol* 2012; 92:585.
- Bavinck JN, et al:** Treatments for common and plantar warts. *BMJ* 2011; 342:d3119.
- Bleeker MCG, et al:** Penile lesions and human papillomavirus in male sexual partners of women with cervical intraepithelial neoplasia. *J Am Acad Dermatol* 2002; 47:351.
- Borgogna C, et al:** Characterization of skin lesions induced by skin-tropic  $\alpha$ - and  $\beta$ -papillomaviruses in a patient with epidermodysplasia verruciformis. *Br J Dermatol* 2014; Jun 5. [Epub ahead of print.]
- Bouwes Bavinck JN, et al:** Keratotic skin lesions and other risk factors are associated with skin cancer in organ-transplant recipients: a case-control study in The Netherlands, United Kingdom, Germany, France, and Italy. *J Invest Dermatol* 2007; 127:1647.
- Broganelli P, et al:** Intralesional cidofovir for the treatment of multiple and recalcitrant cutaneous viral warts. *Dermatol Ther* 2012; 25:468.
- Brown T, et al:** Vitiligo-like hypopigmentation associated with imiquimod treatment of genital warts. *J Am Acad Dermatol* 2005; 52:715.
- Bruggink SC, et al:** Cutaneous wart-associated HPV types: prevalence and relation with patient characteristics. *J Clin Virol* 2012; 55:250.
- Bruggink SC, et al:** HPV type in plantar warts influences natural course and treatment response: secondary analysis of a randomised controlled study. *J Clin Virol* 2013; 57:227.
- Bruggink SC, et al:** Natural course of cutaneous warts among primary schoolchildren: a prospective cohort study. *Ann Fam Med* 2013; 11:437.
- Bruggink SC, et al:** Warts transmitted in families and schools: a prospective cohort. *Pediatrics* 2013; 131:928.
- Carrasco D, et al:** Treatment of anogenital warts with imiquimod 5% cream followed by surgical excision of residual lesions. *J Am Acad Dermatol* 2002; 47:S212.
- Chen K, et al:** Comparative study of photodynamic therapy vs CO<sub>2</sub> laser vaporization in treatment of condylomata acuminata, a randomized clinical trial. *Br J Dermatol* 2007; 156:516.
- Chirila M, Bolboaca SD:** Clinical efficiency of quadrivalent HPV (types of 6/11/16/18) vaccine in patients with recurrent respiratory papillomatosis. *Eur Arch Otorhinolaryngol* 2014; 271:1135.
- Chow EP, et al:** Ongoing decline in genital warts among young heterosexuals 7 years after the Australian human papillomavirus (HPV) vaccination programme. *Sex Transm Infect* 2014 [Epub ahead of print.]
- Clarke E, et al:** Why are anogenital warts diagnoses decreasing in the UK: bivalent human papillomavirus (HPV) vaccine cross-protection or failure to examine? *Sex Transm Infect* 2014; 90:587.
- Cockayne S, et al:** Cryotherapy versus salicylic acid for the treatment of plantar warts (verrucae): a randomised controlled trial. *BMJ* 2011; 342:d3271.
- Connolly M, et al:** Cryotherapy of viral warts: a sustained 10-s freeze is more effective than the traditional method. *Br J Dermatol* 2001; 145:554.
- Daniel BS, Murrell DF:** Complete resolution of chronic multiple verruca vulgaris treated with quadrivalent human papillomavirus vaccine. *JAMA Dermatol* 2013; 149:370.
- Dharancy S, et al:** Conversion to sirolimus: a useful strategy for recalcitrant cutaneous viral warts in liver transplant recipients. *Liver Transpl* 2006; 12:1883.
- Dicle O, et al:** Choice of immunosuppressants and the risk of warts in renal transplant recipients. *Acta Derm Venereol* 2008; 88:294.
- Dobson JS, Harland CC:** Pulsed dye laser and intralesional bleomycin for the treatment of recalcitrant cutaneous warts. *Laser Surg Med* 2014; 46:112.
- Durani BK, Jappe U:** Successful treatment of facial plane warts with imiquimod. *Br J Dermatol* 2002; 147:1018.
- Fahey LM, et al:** A major role for the minor capsid protein of human papillomavirus type 16 in immune escape. *J Immunol* 2009; 183:6151.
- Fausch SC, et al:** Human papillomavirus can escape immune recognition through Langerhans cell phosphoinositide 3-kinase activation. *J Immunol* 2005; 174:7172.
- Garden JM, et al:** Viral disease transmitted by laser-generated plume (Aerosol). *Arch Dermatol* 2002; 138:1303.
- Garg M, et al:** Giant Buschke-Lowenstein tumour: clinical appraisal of a rare entity. *BMJ Case Rep* 2013; May 24; bcr2013009678.
- Garland SM:** The Australian experience with the human papillomavirus vaccine. *Clin Ther* 2014; 36:17.
- Gianino MM, et al:** A retrospective analysis of the costs and management of genital warts in Italy. *BMC Infect Dis* 2013; 13:470.
- Gibbs S:** Topical immunotherapy with contact sensitizers for viral warts. *Br J Dermatol* 2002; 146:705.
- Gormley RH, Kovarik CL:** Human papillomavirus-related genital disease in the immunocompromised host. Part I. *J Am Acad Dermatol* 2012; 66:867.e1.
- Gormley RH, Kovarik CL:** Human papillomavirus-related genital disease in the immunocompromised host. Part II. *J Am Acad Dermatol* 2012; 66:883.e1.
- Grasso M, et al:** Use of cidofovir in HPV patients with recurrent respiratory papillomatosis. *Eur Arch Otorhinolaryngol* 2014; 271:2983.
- Gul U, et al:** Clinical aspects of epidermodysplasia verruciformis and review of the literature. *Int J Dermatol* 2007; 46:1069.
- Herweijer E, et al:** Association of varying number of doses of quadrivalent human papillomavirus vaccine with incidence of condyloma. *JAMA* 2014; 311:597.
- Hivnor C, et al:** Intravenous cidofovir for recalcitrant verruca vulgaris in the setting of HIV. *Arch Dermatol* 2004; 140:13.
- Horn TD, et al:** Intralesional immunotherapy of warts with mumps, *Candida* and *Trichophyton* skin test antigens: a single-blinded, randomized and controlled trial. *Arch Dermatol* 2005; 141:589.
- Howell-Jones R, et al:** Declining genital warts in young women in England associated with HPV 16/18 vaccination: an ecological study. *J Infect Dis* 2013; 208:1397.
- Jardine D, et al:** A randomized trial of immunotherapy for persistent genital warts. *Hum Vaccin Immunother* 2012; 8:623.
- Kallikourdis M, et al:** The *CXCR4* mutations in WHIM syndrome impair the stability of the T-cell immunologic synapse. *Blood* 2013; 122:666.
- Karaman G, et al:** Ranitidine therapy for recalcitrant warts in adults: a preliminary study. *J Eur Acad Dermatol Venereol* 2001; 15:486.
- Kaspari M, et al:** Application of imiquimod by suppositories (anal tampons) efficiently prevents recurrences after ablation of anal canal condyloma. *Br J Dermatol* 2002; 147:757.
- Kimura U, et al:** Long-pulsed 1064-nm neodymium:yttrium-aluminum-garnet laser treatment for refractory warts on hands and feet. *J Dermatol* 2014; 41:252.
- Kines RC, et al:** The initial steps leading to papillomavirus infection occur on the basement membrane prior to cell surface binding. *Proc Natl Acad Sci USA* 2009; 106:20458.
- Kostaki M, et al:** Giant warts in a kidney transplant patient: regression with sirolimus. *Br J Dermatol* 2010; 162:1138.
- Kralund HH, et al:** Substantial effect of topical cidofovir 1% on recalcitrant warts in a renal-transplanted adolescent: a case report. *Transplantation* 2011; 91:e52.
- Kreuter A, Wieland U:** Giant condyloma acuminatum of Buschke and Löwenstein. *N Engl J Med* 2011; 365:17.
- Kumei A, et al:** Multiple linear bowenoid papulosis without surrounding papules. *J Dermatol* 2012; 39:862.
- Kwok CS, et al:** Topical treatments for cutaneous warts. *Cochrane Database Syst Rev* 2012; 9:CD001781.
- Leiding JW, Holland SM:** Warts and all: human papillomavirus in primary immunodeficiencies. *J Allergy Clin Immunol* 2012; 130:1030.
- Leval A, et al:** Incidence of genital warts in Sweden before and after quadrivalent human papillomavirus vaccine availability. *J Infect Dis* 2012; 206:860.
- Lin JH, et al:** Resolution of warts in association with subcutaneous immunoglobulin in immune deficiency. *Pediatr Dermatol* 2009; 26:155.
- Mammas IN, et al:** Human papilloma virus (HPV) infection in children and adolescents. *Eur J Pediatr* 2009; 168:267.
- Martinelli C, et al:** Resolution of recurrent perianal condylomata acuminata by topical cidofovir in patients with HIV infection. *J Eur Acad Dermatol Venereol* 2001; 15:568.
- Mavrogiani P, et al:** Therapeutic combination of radiofrequency surgical dissection and oral acitretin in the management of perianal Buschke-Löwenstein tumour: a case report. *Int J STD AIDS* 2012; 23:362.
- M'barek LB, et al:** 5% Topical imiquimod tolerance in transplant recipients. *Dermatol* 2007; 215:130.
- McCalmont TH:** Whither bowenoid papulosis? *J Cutan Pathol* 2013; 40:209.

- McDermott DH, et al:** A Phase I clinical trial of long-term, low-dose treatment of WHIM syndrome with the *CXCR4* antagonist Plerixafor. *Blood* 2014; 123:2308.
- Micali G, et al:** Treatment of cutaneous warts with squaric acid dibutylester: a decade of experience. *Arch Dermatol* 2000; 136:557.
- Mizuki D, et al:** Successful treatment of topical photodynamic therapy using 5-aminolevulinic acid for plane warts. *Br J Dermatol* 2003; 149:1087.
- Moresi JM, et al:** Treatment of anogenital warts in children with topical 0.05% podofilox gel and 5% imiquimod cream. *Pediatr Dermatol* 2001; 18:448.
- Nambudiri VE, et al:** Successful treatment of perianal giant condyloma acuminatum in an immunocompromised host with systemic interleukin-2 and topical cidofovir. *JAMA Dermatol* 2013; 149:1068.
- Nguyen L, et al:** Conversion from tacrolimus/mycophenolic acid to tacrolimus/leflunomide to treat cutaneous warts in a series of four pediatric renal allograft recipients. *Transplant* 2012; 94:450.
- Nofal A, et al:** Intralesional antigen immunotherapy for the treatment of warts: current concepts and future prospects. *Am J Clin Dermatol* 2013; 14:253.
- Nofal A, et al:** Treatment of recalcitrant warts with bacille Calmette-Guérin: a promising new approach. *Dermatol Ther* 2013; 26:481.
- Olguin-Garcia MG, et al:** A double-blind, randomized, placebo-controlled trial of oral isotretinoin in the treatment of recalcitrant facial flat warts. *J Dermatol Treat* 2014; Feb 19. [Epub ahead of print.]
- Padilla Espana L, et al:** Topical cidofovir for plantar warts. *Dermatol Ther* 2014; 27:89.
- Paraskevas KI, et al:** Surgical management of giant condyloma acuminatum (Buschke-Lowenstein tumor) of the perianal region. *Dermatol Surg* 2007; 33:638.
- Peterson CL, et al:** Hand warts successfully treated with topical 5-aminolevulinic acid and intense pulsed light. *Eur J Dermatol* 2008; 18:207.
- Ruiz R, et al:** Focal epithelial hyperplasia. *Lancet* 2014; 384(9938):173.
- Said AK, et al:** Focal epithelial hyperplasia: an update. *J Oral Pathol Med* 2013; 42:435.
- Santos-Juanes J, et al:** Acute renal failure caused by imiquimod 5% cream in a renal transplant patient: review of the literature on side effects of imiquimod. *Dermatology* 2011; 222:109.
- Scheinfeld N:** Update on the treatment of genital warts. *Dermatol Online J* 2013; 19:3.
- Schiller JT, Lowy DR:** Understanding and learning from the success of prophylactic human papillomavirus vaccines. *Nat Rev Microbiol* 2012; 10:681.
- Sherrard J, Riddell L:** Comparison of the effectiveness of commonly used clinic-based treatments for external genital warts. *Int J STD AIDS* 2007; 18:365.
- Shi H, et al:** Clinical analysis of five methods used to treat condylomata acuminata. *Dermatology* 2013; 227:338.
- Shim WH, et al:** Bowenoid papulosis of the vulva and subsequent periungual Bowen's disease induced by the same mucosal HPVs. *Ann Dermatol* 2011; 23:493.
- Shimizu A, et al:** Bowenoid papulosis successfully treated with imiquimod 5% cream. *J Dermatol* 2014; 41:545.
- Shofer H, et al:** Randomized, comparative trial on the sustained efficacy of topical imiquimod 5% cream versus conventional ablative methods in external anogenital warts. *Eur J Dermatol* 2006; 16:642.
- Sparreboom EE, et al:** Pulsed dye laser treatment for recalcitrant viral warts: a retrospective case series of 227 patients. *Br J Dermatol* 2014; 171:1270.
- Stefanaki C, et al:** Comparison of cryotherapy to imiquimod 5% in the treatment of anogenital warts. *Int J STD AIDS* 2008; 19:441.
- Szarewski A, et al:** Efficacy of the HPV-16/18 AS04-Adjuvanted vaccine against low-risk HPV types (PATRICIA randomized trial): an unexpected observation. *J Infect Dis* 2013; 208:1391.
- Szeimies RM, et al:** Adjuvant photodynamic therapy does not prevent recurrence of condylomata acuminata after carbon dioxide laser ablation: a Phase III, prospective, randomized, bicentric, double-blind study. *Dermatol Surg* 2009; 35:757.
- Takayama A, et al:** Coexistence of bowenoid papulosis and Bowen's disease in a patient with systemic lupus erythematosus. *J Dermatol* 2012; 39:646.
- Tripoli M, et al:** Giant condylomata (Buschke-Löwenstein tumours): our case load in surgical treatment and review of the current therapies. *Eur Rev Med Pharmacol Sci* 2012; 16:747.
- Turnbull JR, et al:** Regression of multiple viral warts in human immunodeficiency virus-infected patient treated by triple antiretroviral therapy. *Br J Dermatol* 2002; 146:330.
- Van Haalen FM, et al:** Warts in primary schoolchildren: prevalence and relation with environmental factors. *Br J Dermatol* 2009; 161:148.
- Vanhootehem O, et al:** Raynaud phenomenon after treatment of verruca vulgaris of the sole with intralesional injection of bleomycin. *Pediatr Dermatol* 2001; 18:249.
- Vicente A, et al:** High-risk alpha-human papillomavirus types: detection in HIV-infected children with acquired epidermodysplasia verruciformis. *J Am Acad Dermatol* 2012; 68:343.
- Videla S, et al:** Natural history of human papillomavirus infections involving anal, penile and oral sites among HIV-positive men. *Sex Transm Dis* 2013; 40:3.
- Wang YS, et al:** Photodynamic therapy with 20% aminolevulinic acid for the treatment of recalcitrant viral warts in an Asian population. *Int J Dermatol* 2007; 46:1180.
- West ES, et al:** Generalized verrucosis in a patient with GATA2 deficiency. *Br J Dermatol* 2014; 170:1182.
- Wiley DJ, et al:** Smoking enhances risk for new external genital warts in men. *Int J Environ Res Public Health* 2009; 6:1215.
- Wong A, Crawford RI:** Intralesional candida antigen for common warts in people with HIV. *J Cutan Med Surg* 2013; 17:313.
- Wu JK, et al:** Psoriasis induced by topical imiquimod. *Australas J Dermatol* 2004; 45:47.
- Wulf HS, et al:** Topical photodynamic therapy for prevention of new skin lesions in renal transplant recipients. *Acta Derm Venereol* 2006; 86:25.
- Yew YW, Pan JY:** Complete remission of recalcitrant genital warts with a combination approach of surgical debulking and oral isotretinoin in a patient with systemic lupus erythematosus. *Dermatol Ther* 2014; 27:79.
- Zamanian A, et al:** Efficacy of intralesional injection of mumps-measles-rubella vaccine in patients with wart. *Adv Biomed Res* 2014; 3:107.
- Zampetti A, et al:** Acquired epidermodysplasia verruciformis: a comprehensive review and a proposal for treatment. *Dermatol Surg* 2013; 39:974.
- Zhao Y, et al:** Relationship between cervical disease and infection with human papillomavirus types 16 and 18, and herpes simplex virus 1 and 2. *J Med Virol* 2012; 84:1920.

### Trichodysplasia spinulosa

Immunosuppressed patients with lymphoreticular malignancies and organ transplant recipients on immunosuppressive regimens will rarely develop a characteristic eruption of erythematous, 1–3 mm facial papules. The midface, glabella, and chin are primarily affected. Lesions are numerous, may reach confluence, and can cause nasal distortion similar to that seen in rosacea and sarcoidosis (Fig. 19-56). Some papules have a central, keratotic white excrescence. Alopecia of the eyebrows and eyelashes may occur, but the scalp is spared. Histology is characteristic, showing massively distended, bulbous follicles with expansion of the inner root sheath cells and containing numerous trichohyaline granules. Abrupt, inner root, sheath-type cornification is present. Abortive hair shaft-like material may be present in the affected follicles. Electron microscopy demonstrates numerous viral particles in the affected hair

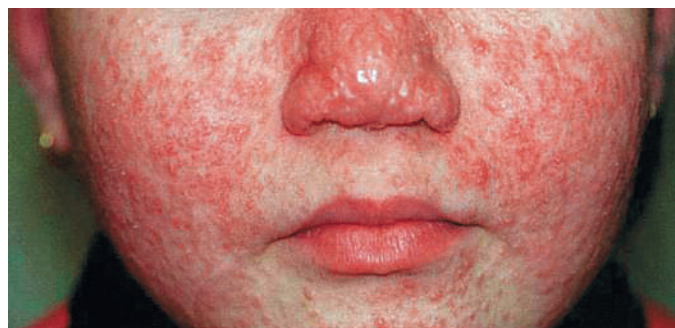

Fig. 19-56 Trichodysplasia. (Courtesy of Len Sperleng, MD.)



follicles. This virus has been identified as a unique polyomavirus called trichodysplasia spinulosa-associated polyomavirus. It differs from the Merkel cell polyomavirus. Treatments that may benefit patients with trichodysplasia spinulosa include reduction of the immunosuppressive regimen, topical cidofovir, and oral valganciclovir.

**Berk DR, et al:** Trichodysplasia spinulosa in an adolescent with cystic fibrosis and lung transplantation. *Int J Dermatol* 2013; 52:1567.

**Burns A, et al:** Keratotic “spiny” papules in an immunosuppressed child. *Arch Dermatol* 2011; 147:1215.

**Celeiro-Munoz C, et al:** Viral-associated trichodysplasia secondary to antineoplastic treatment in a patient with lymphoblastic leukemia. *Am J Dermatopathol* 2014; 36:e105.

**Fischer MK, et al:** Specific detection of trichodysplasia spinulosa-associated polyomavirus DNA in skin and renal allograft tissues in a patient with trichodysplasia spinulosa. *Arch Dermatol* 2012; 148:726.

**Jawa P, et al:** Trichodysplasia spinulosa. *Kidney Int* 2014; 85:715.

**Kazem S, et al:** The trichodysplasia spinulosa-associated polyomavirus: virological background and clinical implications. *APMIS* 2013; 121:770.

**Lee YY, et al:** Trichodysplasia spinulosa: a benign adnexal proliferation with follicular differentiation associated with polyomavirus. *Australas J Dermatol* 2014; 55:e33.

**Matthews MR, et al:** Viral-associated trichodysplasia spinulosa: a case with electron microscopic and molecular detection of the trichodysplasia spinulosa-associated human polyomavirus. *J Cutan Pathol* 2011; 38:420.

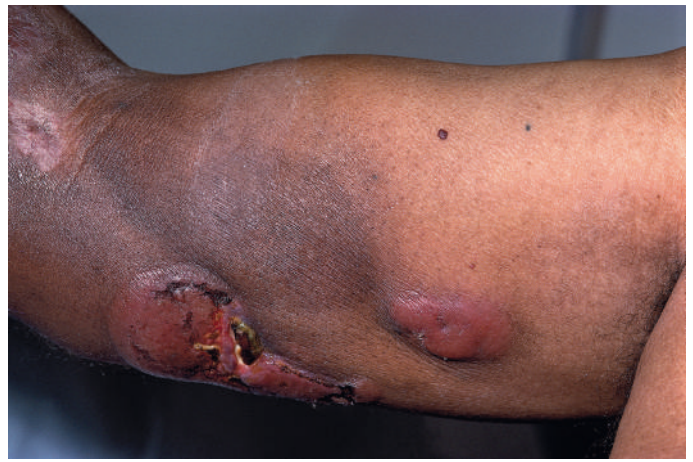## RETROVIRUSES

These oncoviruses are unique in that they contain RNA, which is converted by a virally coded reverse transcriptase to DNA in the host cell. The target cell population is primarily CD4+ lymphocytes (primarily helper T cells), but also, in some cases, macrophages. For this reason, the retroviruses are called human T-lymphotropic viruses (HTLVs). Transmission may be through sexual intercourse, blood products/IV drug use, and from mother to child during childbirth and breastfeeding. There is often a very long “latent” period from time of infection until presentation with clinical disease.

### Human T-lymphotropic virus 1

Human T-lymphotropic virus 1 is endemic in Japan, the Caribbean region, South America (Brazil, Peru, Columbia), sub-Saharan Africa, and Romania; among Australian Aborigines; and in the southeastern United States. In endemic areas, infection rates may be quite high, with only a small percentage of infected patients ever developing clinical disease (estimated 3%). HTLV-1 is spread primarily by mother-to-infant transmission during breastfeeding but also can be transmitted sexually (primarily male to female) or through blood transfusion or IV drug use. HTLV-1 uses the GLUT glucose transporter to enter cells. HTLV-1 is responsible for several clinical syndromes. About 1% of infected persons will develop adult T-cell leukemia-lymphoma (ATL), with more HTLV-1-infected persons in Japan developing ATL than in other populations. Infection in childhood through breastfeeding seems to be a risk factor for developing ATL. HTLV-1-associated myelopathy or tropical spastic paraparesis (HAM/TSP) is a less common degenerative neurologic syndrome.

There are four forms of ATL: smoldering, chronic, acute, and lymphomatous, usually progressing in that order. ATL is characterized by lymphadenopathy, hepatosplenomegaly, hypercalcemia, and skin lesions (60% of patients). Skin lesions in ATL include erythematous papules or nodules (Fig. 19-57). Prurigo may be a prodrome to the development of ATL. Histologically, the cutaneous infiltrates are pleomorphic, atypical lymphocytes with characteristic “flower cells” representing



**Fig. 19-57** HTLV-1-associated adult T-cell leukemia-lymphoma.

HTLV-1-infected lymphocytes. Epidermotropism may be present, mimicking mycosis fungoides.

Three quarters or more of HTLV-1-infected patients will have an abnormal skin examination. The most common skin conditions are dermatophytosis (30%), seborrheic dermatitis (25%), and xerosis/acquired ichthyosis (up to 80%). Vitiligo is also associated. In patients with HAM/TSP, chronic eczema/photosensitivity occurs in up to 20%. Biopsies from the areas of chronic eczema/photosensitivity may show features of ATL in up to 25% of patients (smoldering ATL). Scabies is seen in 2% of asymptomatic HTLV-1-infected patients and in 5% of those with HAM/TSP. The scabies may be of the hyperkeratotic (crusted) type, and the presence of hyperkeratotic scabies in a person from an HTLV-1-endemic region should trigger serologic testing for the virus. The spectrum of skin disease seen in symptomatic HTLV-1-infected patients is remarkably similar to that seen in HIV-infected patients with CNS disease: xerosis/eczema, seborrheic dermatitis, and scabies.

Infective dermatitis, infective dermatitis associated with HTLV 1 infection (IDH), or HTLV-1-associated infective dermatitis (HAID) occurs in children and less frequently in adults with HTLV-1 infection. It is much rarer in Japan than other HTLV-1-endemic, more tropical countries, suggesting climate and malnutrition/socioeconomic factors may play a role. Infective dermatitis is diagnosed by major and minor criteria. Clinically, the children present at an early age (18 months onward) with a chronic eczema of the scalp, axilla, groin, external auditory canal, retroauricular area, eyelid margins, paranasal areas, and neck. Involvement of the scalp and retroauricular area is universal, followed by the body folds (neck, axillae, groin, paranasal skin, and ears). Exudation and crusting are the hallmarks of the skin lesions. Pruritus is mild. Clinically, infective dermatitis resembles a cross between infected AD and infected seborrheic dermatitis. There is a chronic nasal discharge. Cultures from the skin and nares are positive for *Staphylococcus aureus* or  $\beta$ -hemolytic streptococcus, and the condition responds rapidly to antibiotics and topical corticosteroids. Infective dermatitis is relapsing and recurrent. Skin biopsies show a nonspecific dermatitis; however, close examination may show atypical CD4+ cells infiltrating the epidermis, at times simulating ATL or cutaneous T-cell lymphoma. Careful neurologic examination of children with IDH will often reveal abnormal neurologic findings: weakness, lumbar pain, dysesthesias, and urinary disturbances.

**De Oliveira M, et al:** Infective dermatitis associated with human T-cell lymphotropic virus type 1: evaluation of 42 cases observed in Bahia, Brazil. *Clin Infect Dis* 2012; 54:1714.

**Einsiedel L, et al:** Clinical associations of human T-lymphotropic virus type 1 infection in an indigenous Australian population. *PLoS Negl Trop Dis* 2014; 8:e2643.

**Hlela C, Bittencourt A:** Infective dermatitis associated with HTLV-1 mimics common eczemas in children and may be a prelude to severe systemic diseases. *Dermatol Clin* 2014; 32:237.

**McGill NK, et al:** HTLV-1-associated infective dermatitis: updates on the pathogenesis. *Exp Dermatol* 2012; 21:815.

**Okajima R, et al:** High prevalence of skin disorders among HTLV-1 infected individuals independent of clinical status. *PLoS Negl Trop Dis* 2013; 7:e2546.

**Terada T, et al:** T-cell lymphoma of the penis as the first manifestation of adult T-cell lymphoma/leukemia. *Int J Dermatol* 2012; 51:973.

## Human immunodeficiency virus

Human immunodeficiency virus (HIV) infects human helper T (Th) cells, leading to a progressive immunodeficiency disease. In its end stages, HIV infection is called acquired immunodeficiency syndrome (AIDS). Cutaneous manifestations are prominent, affecting up to 90% of HIV-infected persons. Many patients have multiple skin lesions of different types. The skin lesions or combinations of skin conditions are so unique that the diagnosis of HIV infection or AIDS can often be suspected from the skin examination alone. The skin findings can be classified into three broad categories: infections, inflammatory dermatoses, and neoplasms. The skin conditions also tend to appear at a specific stage in HIV progression, making them useful markers of the stage of HIV disease.

The natural history of HIV infection in the vast majority of patients is a gradual loss of Th cells. The rate of this decline is variable, with some patients progressing rapidly and others very slowly or not at all (long-term nonprogressors). Soon after infection, there is a seroconversion syndrome called primary HIV infection, or acute infection (group I). Patients recover from this syndrome and enter a relatively long latent period (asymptomatic infection, or group II), which averages about 10 years. During this period, patients may have persistent generalized lymphadenopathy (group III). When symptoms begin to appear, they are often nonspecific and include fever, weight loss, chronic diarrhea, and mucocutaneous disease (group IVA). Th counts in group II, III, and IVA patients usually range from 200 to 500 cells. The skin findings at this stage (originally called AIDS-related complex, ARC) include seborrheic dermatitis, psoriasis, Reiter syndrome, atopic dermatitis, herpes zoster, acne rosacea, oral hairy leukoplakia, onychomycosis, warts, *S. aureus* skin and soft tissue infections (including recurrent MRSA), and mucocutaneous candidiasis.

Once the Th count is 200 cells or less, the patient is defined as having AIDS. In this stage of HIV disease, the skin lesions are more characteristic of immunodeficiency and include characteristic opportunistic infections: chronic herpes simplex, molluscum contagiosum, bartonellosis (bacillary angiomatosis), systemic fungal infections (cryptococcosis, histoplasmosis, coccidioidomycosis, penicilliosis), and mycobacterial infection. Paradoxically, patients at this stage also have hyperreactive skin and frequently, inflammatory, often pruritic skin diseases. These skin conditions include eosinophilic folliculitis, granuloma annulare, drug reactions, enhanced reactions to insect bites, refractory seborrheic dermatitis, atopic dermatitis, and photodermatitis.

When the Th count falls below 50 cells, the patient is often said to have "advanced AIDS." These patients may have very unusual presentations of their opportunistic infections, including multicentric, refractory molluscum contagiosum; chronic herpes simplex; chronic cutaneous varicella-zoster infection; cutaneous CMV ulcerations, cutaneous acanthamebiasis, cutaneous atypical mycobacterial infections (including *Mycobacterium avium* complex and *Mycobacterium haemophilum*), penicilliosis, and crusted scabies. Treatment of their infec-

tions is often difficult because of the significant chronic immunosuppression.

It is now clear that HIV itself is the cause of the loss of Th cells and that effective treatment of HIV infection may halt or reverse the natural history of HIV disease. The numerous antiretroviral agents are usually used in combinations called "cocktails." This combination treatment is called highly active antiretroviral therapy (HAART). A significant percentage of HIV-infected patients respond to HAART and may show dramatic improvement of their HIV disease. HIV disappears from the blood and Th-cell counts rise. As expected, in patients who respond to HAART, opportunistic infections no longer occur, and subsequently, mortality decreases. This is also true of cutaneous infectious conditions. HIV-associated psoriasis usually improves substantially, especially if the patient did not have psoriasis before HIV infection. Since full reconstitution of the immune system with HAART may take several years, some skin conditions may be slow to resolve (seborrheic dermatitis). Others, such as molluscum contagiosum and Kaposi sarcoma, generally begin to improve within months.

HAART is typically associated with resolution of all forms of HIV-related cutaneous complications. However, some conditions may initially appear or be exacerbated by the sudden improvement of the immune status that occurs with eradication of HIV viremia and with increase in Th-cell counts. This complex of manifestations is called the immune reconstitution inflammatory syndrome. IRIS occurs in 15–25% of HIV-infected persons started on HAART. Persons with an opportunistic infection (OI), specifically cryptococcosis, tuberculosis, penicilliosis, leprosy, or *Pneumocystis* pneumonia, may be at higher risk if HAART is started as the OI is being treated. This marked inflammatory syndrome can be severe, and in resource-poor countries, 5% of AIDS-related deaths in treated patients can be attributed to IRIS during the first year of HAART therapy. Half of IRIS-related conditions are dermatologic. The following three forms of IRIS occur:

1. A hidden OI is unmasked as the reconstituted immune system attacks the hidden pathogen. The presentation may be atypical. The appearance of cutaneous mycobacterial infections with HAART is an example.
2. In the setting of a documented OI, when HAART is started, the patient has worsening of the infection with new findings. This is not treatment failure, but enhanced immune response to the pathogen. This typically occurs with tuberculosis or cryptococcosis.
3. The development of new disorders is seen, infectious or inflammatory, or enhanced inflammatory responses around malignancies, especially Kaposi sarcoma. Eosinophilic folliculitis, acne flares, drug eruptions, Reiter syndrome, lupus erythematosus, alopecia universalis, at times HPV infections (especially oral and genital), increased outbreaks of genital and orolabial herpes simplex, molluscum contagiosum, herpes zoster, CMV ulcerations, type I reactions in Hansen's disease, cutaneous mycobacterial and fungal infections, leishmaniasis, tattoo and foreign body granulomas, and sarcoidosis can be part of IRIS in the skin.

Infection with HIV is now being effectively controlled in many patients through HAART. However, the constant struggle of the immune system to control viral replication and side effects from multiple medications has led to senescence of the immune system similar to that seen with chronological aging. Chronic HIV disease is characterized by the same combination of immunodeficiency and inflammation that occurs with aging. This has led to increased rates and earlier onset of cardiovascular disease, metabolic disorders,



osteoporosis, and some cancers in HIV disease. Frailty, or the variability with which persons acquire health problems and the consequent inability to tolerate stressors (vulnerability), is becoming the primary consequence of HIV infection in many countries.

### Primary HIV infection (acute seroconversion syndrome)

Several weeks after infection with HIV, an acute illness develops in a large proportion of individuals. The clinical syndrome is similar to primary EBV infection, with fever, sore throat, cervical adenopathy, a rash, and oral, genital, and rectal ulceration. The skin eruption can be polymorphous (Figs. 19-58 and 19-59). Most characteristic is a papular eruption of discrete, slightly scaly, oval lesions of the upper trunk. The lesions have a superficial resemblance to pityriasis rosea, but the peripheral scale is not prominent, and there is focal hemorrhage in the lesions. A Gianotti-Crosti-like papular eruption may also occur. Purpuric lesions along the margins of the palms and soles, as seen in immune complex disease, have been reported. The mucosal erosions resemble aphthae but are larger and can affect all parts of the mouth, pharynx, esophagus, and anal mucosa. Dysphagia may be prominent. The Th-cell count falls abruptly during seroconversion. The level of immune impairment may allow oral candidiasis or even *Pneumocystis jirovecii* (formerly *P. carinii*) pneumonia to develop. The diagnosis should be suspected in any at-risk individual with the correct

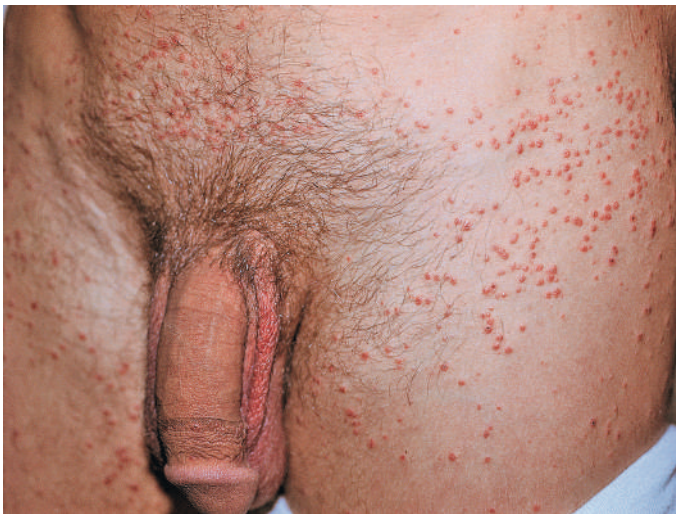

Fig. 19-58 Primary HIV infection.

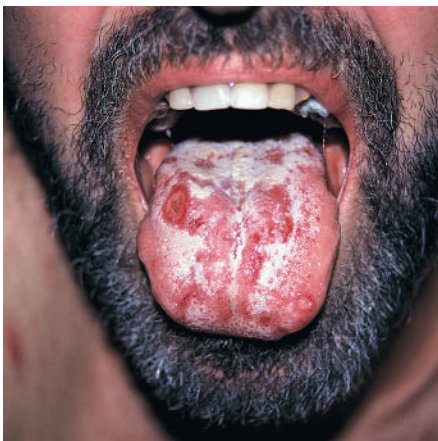


Fig. 19-59 Primary HIV infection. (Courtesy of Ginat Mirowski, MD.)

constellation of symptoms. A direct measurement of HIV viral load will confirm the diagnosis. Combination antiviral therapy is instituted immediately.

### HIV-associated pruritus

From early in the HIV epidemic, it was clear that pruritus was a marker of HIV infection throughout the world, occurring in up to 30% of patients. Pruritus is usually not caused by HIV disease itself but is related to inflammatory dermatoses associated with the disease. "Papular pruritic eruption" is not a specific disease, but rather a "wastebasket diagnosis" used to encompass patients with many forms of HIV-associated pruritus. Worldwide, it most often represents enhanced insect bite reactions. These pruritic eruptions are best subdivided into follicular and nonfollicular eruptions. The relative prevalence of these two patterns of pruritic eruptions is geographically distinct. In tropical and semitropical regions, where biting insects are prominent, nonfollicular eruptions are most common and probably represent insect bite hypersensitivity. In temperate regions, follicular pruritic eruptions are more common.

Eosinophilic folliculitis (EF) is the most common pruritic follicular eruption. It is seen in patients with a Th count of about 200 cells. Clinically, EF presents with urticarial follicular papules on the upper trunk, face, scalp, and neck (Fig. 19-60). Pustular lesions are uncommon; pustules are usually smaller than in bacterial folliculitis and represent end-stage lesions. These lesions are infrequently seen because the pruritus is so severe that the pustules are excoriated before the lesion evolves to this degree. About 90% of lesions occur above the nipple line on the anterior trunk, and lesions typically extend down the midline of the back to the lumbar spine. EF waxes and wanes in severity and may spontaneously clear, only to flare unpredictably. A peripheral eosinophilia may be present, and the serum IgE level may be elevated, suggesting this is a disorder mediated by Th2 cells. Histologically, an infiltrate of mononuclear cells and eosinophils is seen around the upper portion of the hair follicle at the level of the sebaceous gland. As lesions evolve, eosinophils and lymphocytes enter the follicular structure and the sebaceous glands. Pustules are formed late and represent aggregates of eosinophils in the uppermost part of the follicle. Rarely, there will be increased mucin within

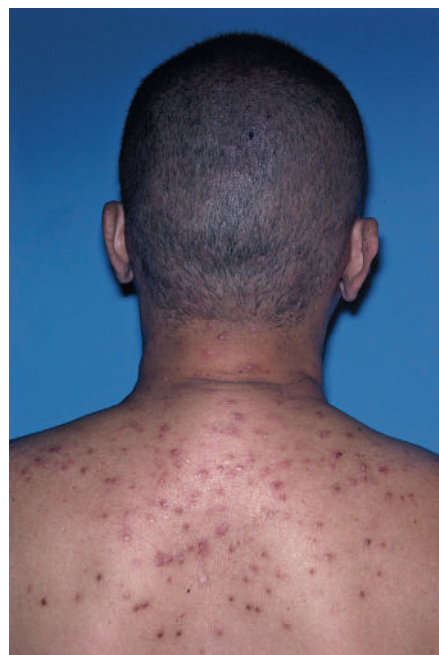

Fig. 19-60 Eosinophilic folliculitis. (Courtesy of Curt Samlaska, MD.)

the follicular epithelium, making distinction from follicular mucinosis difficult.

Initial treatment of EF is topical corticosteroids and antihistamines. If the patient fails to respond, phototherapy (UVB or PUVA) or itraconazole, 200 mg twice daily, may be effective. In some patients, repeated applications of permethrin (every other night for up to 6 weeks) may be of benefit. Permethrin therapy is directed at *Demodex* mites, which may be the antigenic trigger of EF. Isotretinoin is also effective, often after a few months, in a dose of about 0.5–1 mg/kg/day. HAART may lead to a flare of EF (as part of IRIS) but usually leads eventually to its resolution. Staphylococcal folliculitis, which may be severely pruritic in patients with HIV disease, and *Pityrosporum* folliculitis should be included in the differential diagnosis. These are excluded by bacterial culture and skin biopsy, respectively. *Demodex* folliculitis should also be in the differential.

The other pruritic dermatoses that are not follicular can be divided into the primarily papular eruptions and the eczematous reactions. The papular eruptions include scabies, insect bites, transient acantholytic dermatosis, granuloma annulare, and prurigo nodularis. The eczematous dermatoses include atopic-like dermatitis, seborrheic dermatitis, nummular eczema, xerotic eczema, photodermatitis, and drug eruptions. Patients may have multiple eruptions simultaneously, making differential diagnosis difficult. A skin biopsy from a representative lesion of every morphologic type on the patient may elucidate the true diagnosis(es). Treatment is determined by the diagnosis and is similar to treatment in persons without HIV infection with these same dermatoses. Special considerations in AIDS patients include the use of topical therapy plus ivermectin for crusted scabies and thalidomide for prurigo nodularis and photodermatitis. Both these systemic agents are very effective if used appropriately.

## HIV-associated neoplasia

Neoplasia is prominent in HIV infection and in some cases is highly suggestive of HIV infection. Kaposi sarcoma is an example. Other common neoplasms seen in patients with HIV infection include superficial basal cell carcinomas (BCCs) of the trunk, squamous cell carcinomas (SCCs) in sun-exposed areas, genital HPV-induced SCC, and extranodal B-cell and T-cell lymphomas. Lipomas, angioliipomas, and dermatofibromas may occur. In the case of lipomas, their appearance is usually related to the peripheral fat loss that occurs with some HIV treatment regimens and with HIV disease itself.

Nonmelanoma skin cancers (NMSCs) are very common in HIV patients. HAART does not protect against the development of NMSC in HIV infection. BCCs usually occur as superficial multicentric lesions on the trunk in fair-skinned men in their twenties to fifties. The ratio of BCC to SCC is not reversed in HIV disease as it is in organ transplant recipients. BCCs behave in the same manner as they do in the immunocompetent host, and standard management is usually adequate.

Actinically induced SCCs are also quite common and present in the standard manner as nodules, keratotic papules, or ulcerations. In most cases, their behavior is relatively benign and standard management is adequate. Removal of SCCs in sun-exposed areas by curettage and desiccation in patients with HIV infection is associated with an unacceptably high recurrence rate of about 15%. Complete excision is therefore recommended. In a small subset of patients with AIDS, actinic SCCs can be very aggressive; they may double in size over weeks and may metastasize to regional lymph nodes or viscerally, leading to the death of the patient.

Genital SCCs, including cervical, vaginal, anal, penile, and periungual SCC, all occur in patients with HIV infection.

These neoplasms are increased in frequency, and the progression from HPV infection to neoplasia appears to be accelerated. This is analogous to the situation in organ transplant and other immunosuppressed patients. It appears that these cancers are associated with primarily “high-risk” HPV types.

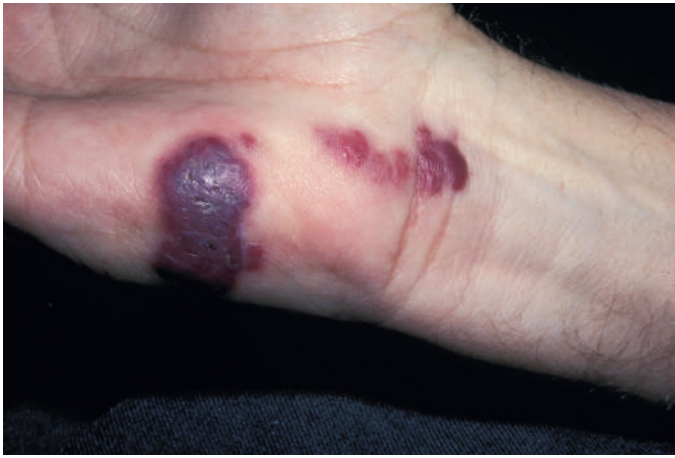High-risk genital HPV infection in patients with HIV can produce perianal dysplasia in MSM who have a history of receptive anal intercourse. Dysplasia in this area may present as velvety white or hyperpigmented plaques involving the whole anal area and extending into the anal canal. These lesions may erode or ulcerate. Histology will demonstrate SCC in situ. The risk of progression of the lesions to anal SCC is unknown but is estimated to be at least 10 times higher than the rate of cervical cancer in women in the general population. The management of such lesions is unclear, but regular follow-up is clearly indicated, and any masses in the anal canal should be immediately referred for biopsy. At some centers, Pap smear equivalents are performed. Imiquimod has been used as an adjunct in the management of genital warts and HPV-associated genital in situ dysplasias (not genital SCC). Although it may be of benefit in patients with reconstituted immune systems receiving HAART, especially in combination with surgical ablation, the response rate is much lower than in immunocompetent patients. In the only placebo-controlled trial, done before standard HAART was available, imiquimod was no more effective than placebo in clearing genital warts (11%) in HIV infection. Small case series of patients receiving HAART suggest clearance rates of about 30–50%. Topical cidofovir can be used to treat genital HPV infection in patients with low-risk and high-risk HPV types.

The vulvar and penile skin may develop flat, white or hyperpigmented macules from a few millimeters to several centimeters in diameter. These show SCC in situ and are analogous to Bowenoid papulosis in the immunocompetent host. Lesions of the penile shaft and glabrous vulvar skin, not at a transition zone or on mucosal surfaces, have a low risk of progressing to invasive SCC. Lesions of the glans penis that are red and fixed should be biopsied. If the changes of SCC in situ are found, these should be managed aggressively as SCC in situ. Topical 5-FU and superficial radiation therapy are effective. Close clinical follow-up is indicated. Periungual SCC has also been seen in patients with HIV infection. Any persistent keratotic or hyperpigmented lesion in the periungual area must be carefully evaluated. Management is surgical excision. Perianal and vulvovaginal lesions should be managed as intraepithelial neoplasia types AIN-3 and VIN-3, respectively.

Extranodal B-cell and less often T-cell lymphomas are associated with the advanced immunosuppression of AIDS. The B-cell lymphomas and some of the T-cell lymphomas present as violaceous or plum-colored papules, nodules, or tumors. Once the diagnosis is established by biopsy, systemic chemotherapy is required. EBV is found in some cases. HAART is both protective against the development of non-Hodgkin lymphoma (NHL) and Hodgkin disease in HIV and substantially improves prognosis of HIV-infected patients with NHL. Mycosis fungoides can also be seen in patients with HIV infection, often in those who have not yet developed AIDS. It presents with pruritic patches or plaques and may progress to tumor stage. EBV is not found in these cases. CD8+ pseudolymphoma is also seen in patients with untreated HIV infection and may resolve with HAART.

Malignant melanoma (MM) is seen at increased rates in persons with HIV infection. HIV-infected melanoma patients demonstrate the same risk factors as other melanoma patients: multiple nevi, fair skin type, and prior intermittent but intense sun exposure. HIV patients with melanoma in the pre-HAART era had significantly shorter disease-free survival and reduced overall survival. Many fair-skinned patients infected with HIV





**Fig. 19-61** Kaposi sarcoma in AIDS patient.

complain of the new onset of atypical moles (analogous to organ transplant patients). Whether these confer an increased risk of melanoma is unknown.

## AIDS and Kaposi sarcoma

Kaposi sarcoma (KS) was, along with *Pneumocystis pneumonia*, the harbinger of the AIDS epidemic. Many MSM and bisexual men presented with this tumor in the early 1980s, with a prevalence of up to 25% in some cohorts. HHV-8, a  $\gamma$ -herpesvirus, has been identified in these lesions. The clinical features of KS in patients with AIDS are different than those seen in elderly men who do not have AIDS. Patients with AIDS present with symmetric widespread lesions, often numerous. Lesions begin as macules that may progress to tumors or nodules (Fig. 19-61). Any mucocutaneous surface may be involved, but areas of predilection include the hard palate, face, trunk, penis, and lower legs and soles. Visceral disease may be present and progressive. Edema may accompany lower leg lesions, and if significant, it is often associated with lymph node involvement in the inguinal area.

A diagnosis of KS is established by skin biopsy, which should be taken from the center of the most infiltrated plaque. Excessive bleeding is not usually a problem. Early macular lesions show atypical, angulated, ectatic vessels in the upper dermis associated with an inflammatory infiltrate containing plasma cells. Plaque lesions show aggregates of small vessels and endothelial cells in the upper dermis and surrounding adnexal structures. Nodules and tumors show the classic pattern of a spindle cell neoplasm with prominent extravasation of red blood cells.

HAART has reduced the incidence of KS in HIV-infected patients by 10-fold. However, KS remains an important complication of HIV infection for the following two reasons:

1. HIV-associated KS is still common in sub-Saharan Africa. With HAART therapy, survival in Africa for HIV-infected persons for more than 1 year is almost 100%, if they do not have KS. In patients with HIV disease and KS, however, survival is only 77%. This results from the lack of effective cytotoxic therapy for KS in Africa. HIV-KS is more common in women than men in some clinics in Africa.
2. Although HAART has substantially reduced the prevalence of KS in HIV disease in the developed world, HAART has not eliminated the disease. In fact, there remains a fairly substantial proportion of primarily gay men with HIV disease who also have KS (up to 13% of

some cohorts). Twenty percent or more of these AIDS-KS patients have well-controlled HIV disease with long-term undetectable viral load and CD4 counts above 300. These patients have an overall good prognosis but still may require cytotoxic or radiation therapy to control their KS. Patients with AIDS-KS and lower CD4 counts and detectable viral loads are more likely to have visceral disease. Up to one third of these AIDS-KS patients died despite HAART and chemotherapy, suggesting that AIDS-KS in the setting of poor HIV control is a poor prognostic finding.

The treatment of AIDS-associated KS depends on the extent and aggressiveness of the disease. Effective HAART after about 6 months is associated with involution of KS lesions in 50% of patients. This should be the initial management in most patients with mild to moderate disease (<50 lesions, and <10 new lesions/month) who are not receiving anti-HIV treatment. Intralesional vinblastine, 0.2–0.4 mg/mL, can be infiltrated into lesions (as for hypertrophic scar), and lesions will involute over several weeks. Hyperpigmentation usually remains. Cryotherapy is also effective but will leave postinflammatory hypopigmentation in pigmented persons. Persistent individual lesions and lesions of the soles and penis respond well to local irradiation therapy (one single treatment of 80 Gy or fractionated treatments to 150 Gy). For patients with moderate disease (>10 lesions, or mucosal or visceral involvement), HAART alone may not be adequate in controlling KS, and liposomal doxorubicin may need to be added to the treatment. For patients with symptomatic visceral disease, aggressive skin disease, marked edema, and pulmonary disease, systemic chemotherapy is indicated.

- Afonso JP, et al:** Pruritus papular eruption and eosinophilic folliculitis associated with human immunodeficiency virus (HIV) infection: a histopathological and immunohistochemical comparative study. *J Am Acad Dermatol* 2012; 67:269.
- Agaba PA, et al:** Presentation and survival of patients with AIDS-related Kaposi's sarcoma in Jos, Nigeria. *Int J STD AIDS* 2009; 29:410.
- Aiberici F, et al:** Ivermectin alone or in combination with benzyl benzoate in the treatment of human immunodeficiency virus-associated scabies. *Br J Dermatol* 2000; 142:969.
- Al-Dawsari NA, et al:** Pigmented Bowen's disease of the penis and scrotum in a patient with AIDS. *Dermatol Online J* 2014; 20:22337.
- Amerson EH, Maurer TA:** Immune reconstitution inflammatory syndrome and tropical dermatoses. *Dermatol Clin* 2011; 29:39.
- Annam V, et al:** Clinicopathological study of itch folliculitis in HIV-infected patients. *Indian J Dermatol Venereol Leprol* 2010; 76:259.
- Blaser N, et al:** Impact of viral load and the duration of primary infection on HIV transmission: systematic review and meta-analysis. *AIDS* 2014; 28:1021.
- Bonnet F, et al:** Malignancy-related causes of death in human immunodeficiency virus-infected patients in the era of highly active antiretroviral therapy. *Cancer* 2004; 101:317.
- Brothers TD, et al:** Frailty in people aging with human immunodeficiency virus (HIV) infection. *J Infect Dis* 2014; 210:1170.
- Bussone G, et al:** Unmasking leprosy: an unusual immune reconstitution inflammatory syndrome in a patient infected with human immunodeficiency virus. *Am J Trop Med Hyg* 2010; 83:13.
- Castelnuovo B, et al:** Cause-specific mortality and the contribution of immune reconstitution inflammatory syndrome in the first 3 years after antiretroviral therapy initiation in an urban African cohort. *Clin Infect Dis* 2009; 49:965.
- Cusini M, et al:** 5% Imiquimod cream for external anogenital warts in HIV-infected patients under HAART therapy. *Int J STD AIDS* 2004; 15:17.
- Davidson A, et al:** Malignancies in South African children with HIV. *J Pediatr Hematol Oncol* 2014; 36:111.
- Diaz-Arrastia C, et al:** Clinical and molecular responses in high-grade intraepithelial neoplasia treated with topical imiquimod 5%. *Clin Cancer Res* 2001; 7:3031.

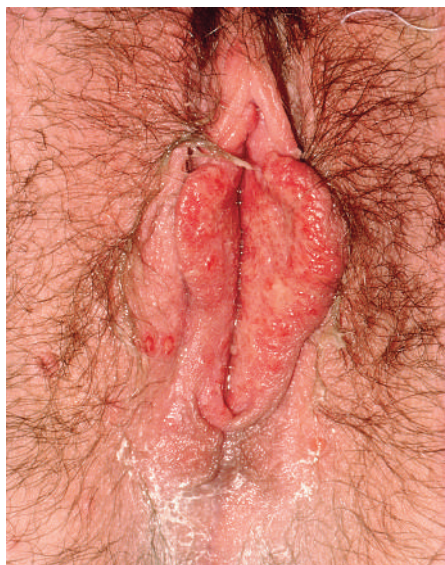- Farsani TT, et al:** Etiology and risk factors associated with a pruritic papular eruption in people living with HIV in India. *J Int AIDS Soc* 2013; 16:17325.
- Frater J, et al:** HIV-1-specific CD4+ responses in primary HIV-1 infection predict disease progression. *AIDS* 2014; 28:699.
- Grinsztejn B, et al:** Effects of early versus delayed initiation of antiretroviral treatment on clinical outcomes of HIV-1 infection: results from the Phase 3 HPTN 052 randomised controlled trial. *Lancet* 2014; 14:281.
- Husak R, et al:** Refractory human papillomavirus-associated oral warts treated topically with 1–3% cidofovir solutions in human immunodeficiency virus type 1-infected patients. *Br J Dermatol* 2005; 153:382.
- Jagannathan P, et al:** Life-threatening immune reconstitution inflammatory syndrome after *Pneumocystis pneumonia*: a cautionary case series. *AIDS* 2009; 23:13.
- Khalil EA, et al:** Post-Kala-Azar dermal leishmaniasis: a paradigm of paradoxical immune reconstitution syndrome in non-HIV/AIDS patients. *J Trop Med* 2013; 2013:275253.
- Kim TG, et al:** Skin disorders in Korean patients infected with human immunodeficiency virus and their association with a CD4 lymphocyte count: a preliminary study. *J Eur Acad Dermatol Venereol* 2010; 24:1476.
- Kreuter A, et al:** Clinical spectrum and virologic characteristics of anal intraepithelial neoplasia in HIV infection. *J Am Acad Dermatol* 2005; 52:603.
- Lehloeny R, Meintjes G:** Dermatologic manifestations of the immune reconstitution inflammatory syndrome. *Dermatol Clin* 2006; 24:549.
- Mani D, et al:** A retrospective analysis of AIDS-associated Kaposi's sarcoma in patients with undetectable HIV viral loads and CD4 counts greater than 300 cells/mm<sup>3</sup>. *J Int Assoc Physicians AIDS Care* 2009; 8:279.
- Martin-Carbonero L, et al:** Pegylated liposomal doxorubicin plus highly active antiretroviral therapy versus highly active antiretroviral therapy alone in HIV patients with Kaposi's sarcoma. *AIDS* 2004; 18:1737.
- Massad LS, et al:** Effect of antiretroviral therapy on the incidence of genital warts and vulvar neoplasia among women with the human immunodeficiency virus. *Am J Obstet Gynecol* 2004; 190:1241.
- Meyer T, et al:** Human immunodeficiency virus (HIV)—associated eosinophilic folliculitis and follicular mucinosis in a black women. *Int J Dermatol* 2010; 49:1308.
- Moussa R, et al:** Buschke-Loewenstein lesion: another possible manifestation of immune restoration inflammatory syndrome? *AIDS* 2004; 18:1221.
- Olson CM, et al:** Risk of melanoma in people with HIV/AIDS in the pre- and post-HAART eras: a systematic review and meta-analysis of cohort studies. *PLoS One* 2014; 9:e95096.
- Post WS, et al:** Associations between HIV infection and subclinical coronary atherosclerosis. *Ann Intern Med* 2014; 160:458.
- Rodgers S, Leslie KS:** Skin infections in HIV-infected individuals in the era of HAART. *Curr Opin Infect Dis* 2011; 2:124.
- Rodrigues LKE, et al:** Altered clinical course of malignant melanoma in HIV-positive patients. *Arch Dermatol* 2002; 138:765.
- Seoane Reula E, et al:** Role of antiretroviral therapies in mucocutaneous manifestations in HIV-infected children over a period of two decades. *Br J Dermatol* 2005; 153:382.
- Sherin K, et al:** What is new in HIV infection? *Am Fam Physician* 2014; 89:265.
- Stammer Jaliff B, et al:** Outcome and reinfection after *Staphylococcus aureus* bacteremia in individuals with and without HIV-1 infection: a case-control study. *BMJ Open* 2014; 4:e004075.
- Stover KR, et al:** A fatal case of Kaposi sarcoma due to immune reconstitution inflammatory syndrome. *Am J Med Sci* 2012; 343:421.
- Weiss DA, et al:** Condyloma overgrowth caused by immune reconstitution inflammatory syndrome. *Urology* 2009; 74:1013.
- Worodria W, et al:** Incidence and predictors of mortality and the effect of tuberculosis immune reconstitution inflammatory syndrome in a cohort of TB/HIV patients commencing antiretroviral therapy. *J Acquir Immune Defic Syndr* 2011; 58:32.
- Xuan L, et al:** Alopecia areata and vitiligo as primary presentations in a young male with human immunodeficiency virus. *Indian J Dermatol* 2014; 59:209.
- Yokobayashi H, et al:** Analysis of serum chemokine levels in patients with HIV-associated eosinophilic folliculitis. *J Eur Acad Dermatol Venereol* 2013; 27:212.



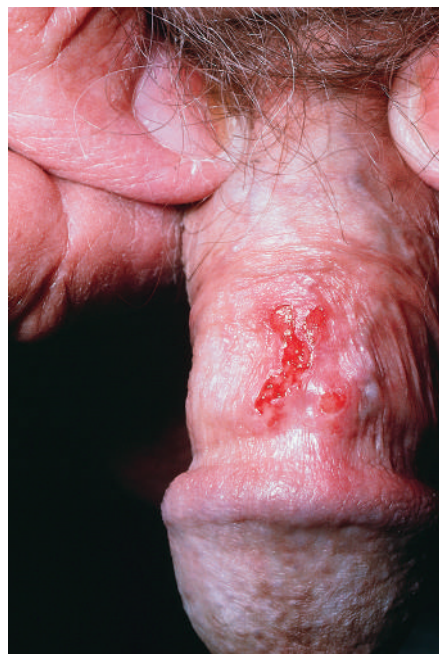Bonus images for this chapter can be found online at [expertconsult.inkling.com](http://expertconsult.inkling.com)

- eFig. 19-1** Initial episode of genital herpes, HSV-2.
- eFig. 19-2** Herpes gladiatorum.
- eFig. 19-3** Herpes gladiatorum, neck lesions of HSV-1.
- eFig. 19-4** Recurrent genital herpes.
- eFig. 19-5** Genital herpes, solitary ulceration.
- eFig. 19-6** Genital herpes, HSV-2, infected areas spontaneously heal while new erosions appear.
- eFig. 19-7** Herpes simplex, HSV-1, in patient with AIDS.
- eFig. 19-8** Varicella.
- eFig. 19-9** Herpes zoster.
- eFig. 19-10** Herpes zoster, necrotic, in elderly patient.
- eFig. 19-11** Herpes zoster, classic dermatomal distribution.
- eFig. 19-12** Herpes zoster, motor nerve involvement.
- eFig. 19-13** Ecthyematous zoster in AIDS patient.
- eFig. 19-14** Herpes zoster, early lesions.
- eFig. 19-15** Oral hairy leukoplakia.
- eFig. 19-16** Oral Kaposi sarcoma in AIDS patient.
- eFig. 19-17** Porphyria cutanea tarda associated with hepatitis C.
- eFig. 19-18** Papules on the arms, Gianotti-Crosti syndrome. (Courtesy of Dr. Curt Samlaska)
- eFig. 19-19** Vaccinia, typical reaction at about 1 week.
- eFig. 19-20** Smallpox scars. (Courtesy of Shyam Verma, MD.)
- eFig. 19-21** Autoinoculation vaccinia.
- eFig. 19-22** Roseola vaccinia.
- eFig. 19-23** Molluscum contagiosum.
- eFig. 19-24** Molluscum contagiosum.
- eFig. 19-25** Molluscum contagiosum and condyloma acuminatum (HPV infection) occurring together.
- eFig. 19-26** Molluscum contagiosum.
- eFig. 19-27** Genital molluscum contagiosum.
- eFig. 19-28** Molluscum contagiosum in AIDS patient.
- eFig. 19-29** Viral enanthem.
- eFig. 19-30** Rubella.
- eFig. 19-31** Papular-purpuric gloves-and-socks syndrome.
- eFig. 19-32** Orf.
- eFig. 19-33** Verruca vulgaris, wart at site of trauma.
- eFig. 19-34** Verruca plana.
- eFig. 19-35** Common warts, verruca vulgaris.
- eFig. 19-36** Grouped warts in area of atopic dermatitis.
- eFig. 19-37** Verruca, nail biter with periungual warts.
- eFig. 19-38** Verruca vulgaris, doughnut wart.
- eFig. 19-39** Epidermodyplasia verruciformis.

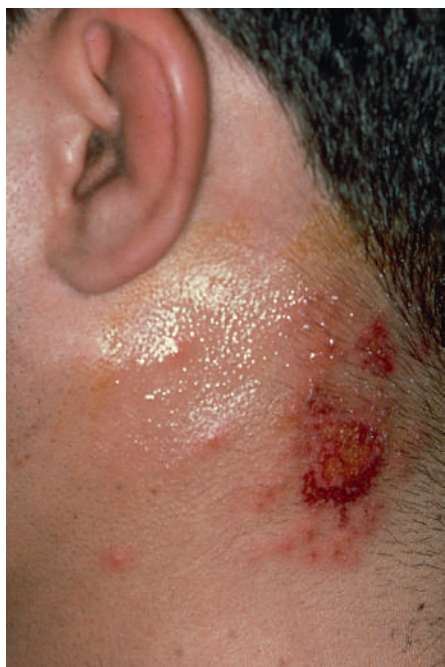



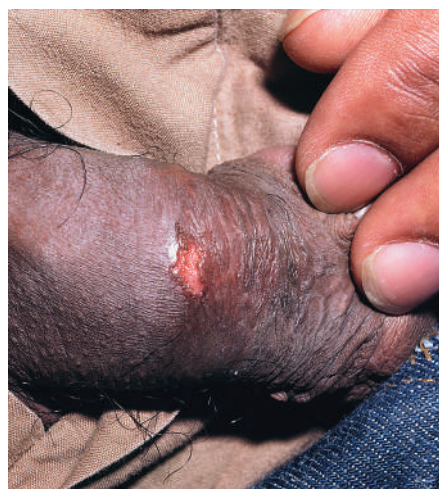**eFig. 19-1** Initial episode of genital herpes, HSV-2.



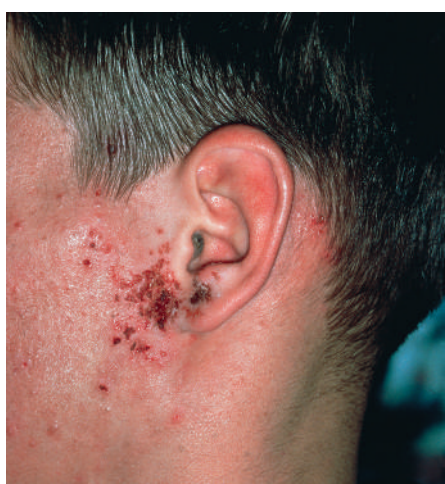**eFig. 19-4** Recurrent genital herpes.



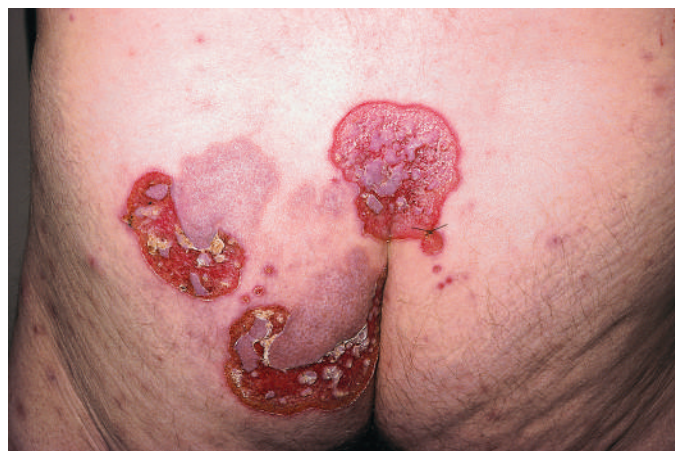**eFig. 19-2** Herpes gladiatorum.



**eFig. 19-5** Genital herpes, solitary ulceration.

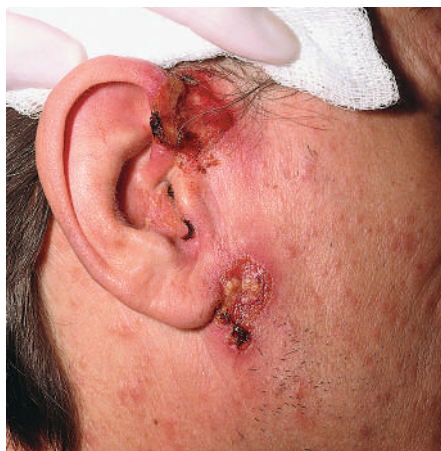

**eFig. 19-3** Herpes gladiatorum, neck lesions of HSV-1.

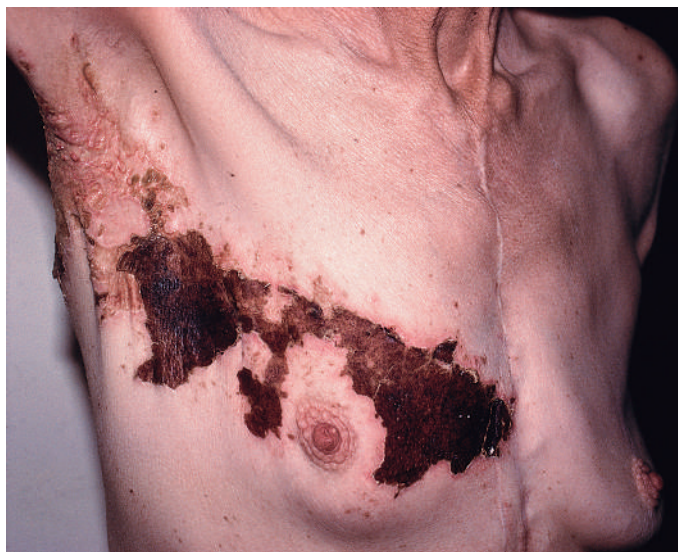

**eFig. 19-6** Genital herpes in AIDS, HSV-2, infected areas spontaneously heal while new erosions appear.

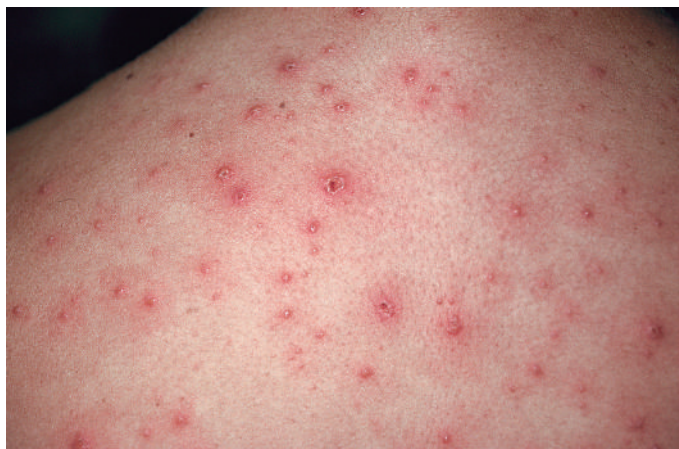



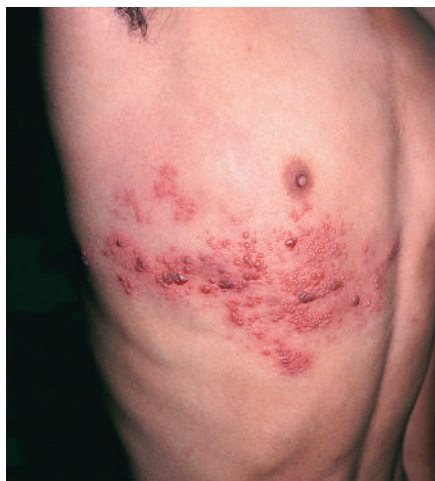**eFig. 19-7** Herpes simplex, HSV-1, in patient with AIDS.



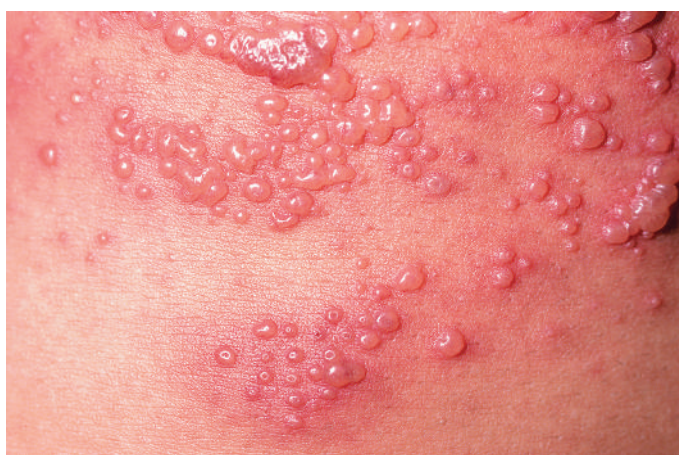**eFig. 19-10** Herpes zoster, necrotic, in elderly patient.



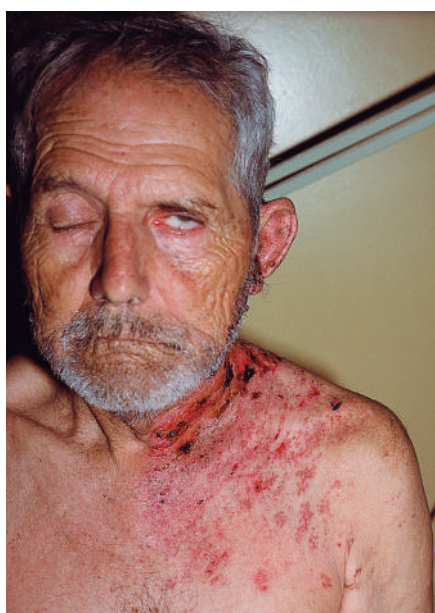**eFig. 19-8** Varicella.



**eFig. 19-11** Herpes zoster, classic dermatomal distribution.

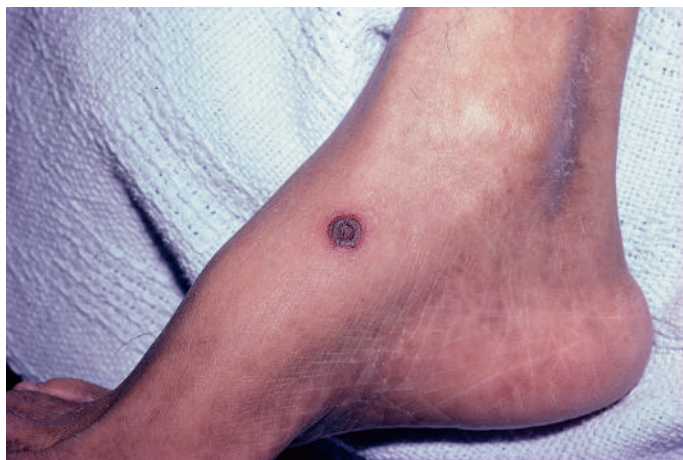

**eFig. 19-9** Herpes zoster.

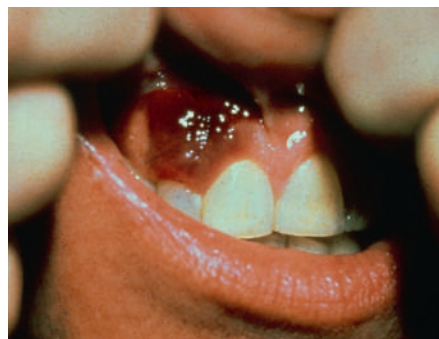

**eFig. 19-12** Herpes zoster, motor nerve involvement.

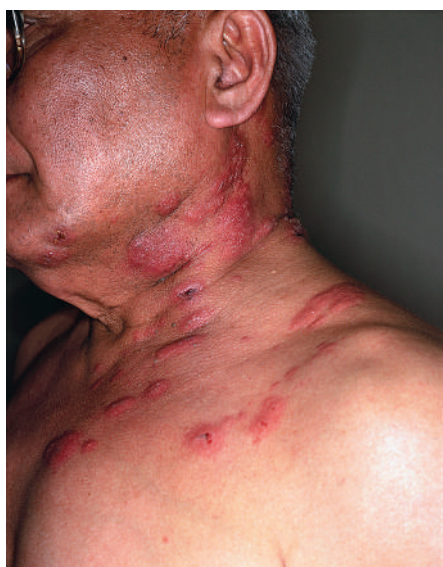



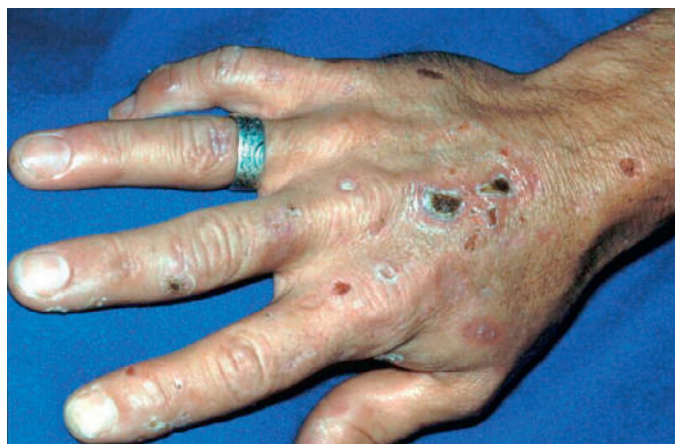**eFig. 19-13** Ecthyematous zoster in AIDS patient.



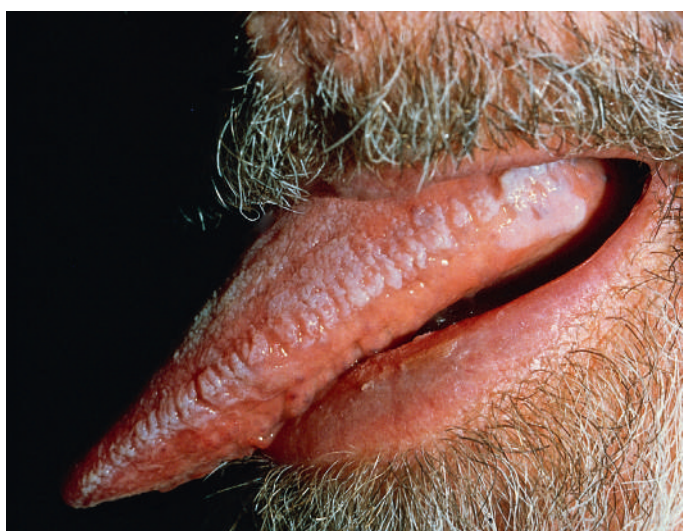**eFig. 19-16** Oral Kaposi sarcoma in AIDS patient.



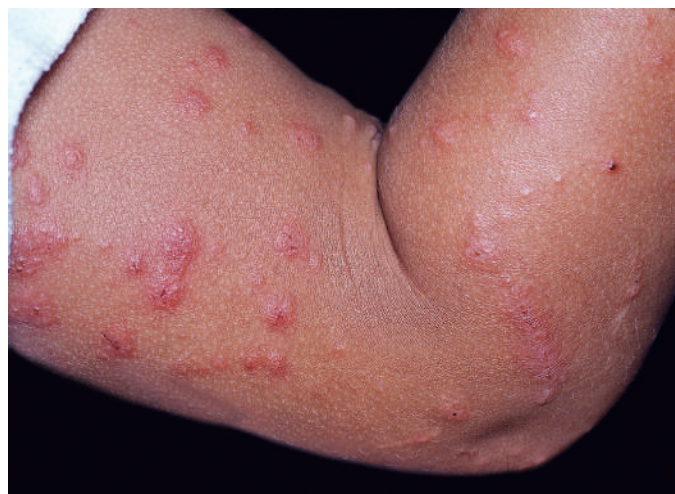**eFig. 19-14** Herpes zoster, early lesions.



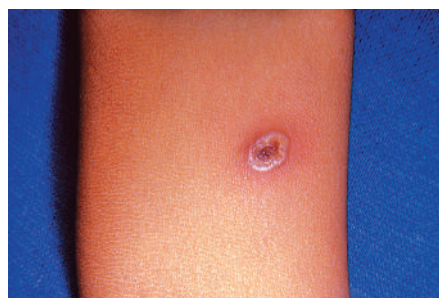**eFig. 19-17** Porphyria cutanea tarda associated with hepatitis C.



**eFig. 19-15** Oral hairy leukoplakia.

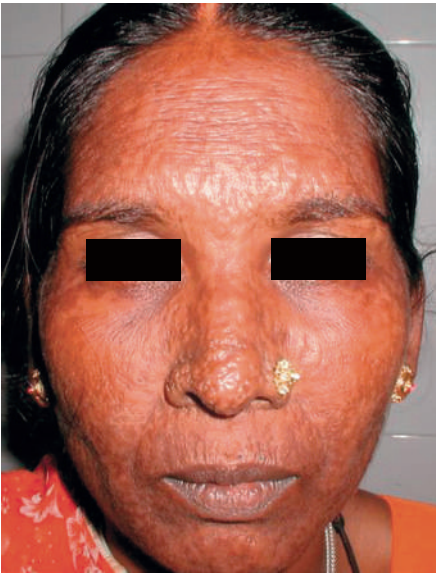

**eFig. 19-18** Papules on the arms, Gianotti-Crosti syndrome. (Courtesy of Dr. Curt Samlaska)

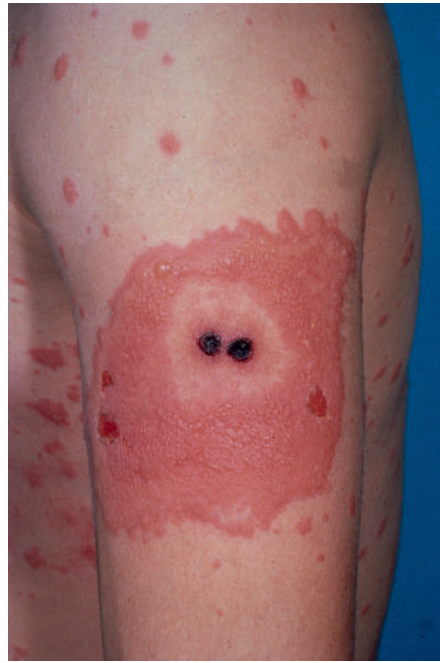

**eFig. 19-19** Vaccinia, typical reaction at about 1 week.

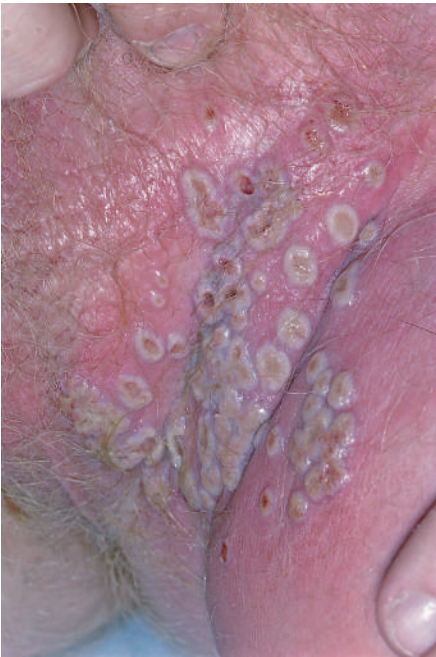



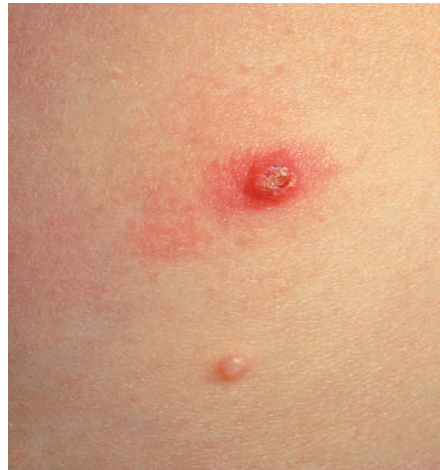**eFig. 19-20** Smallpox scars. (Courtesy of Shyam Verma, MD.)



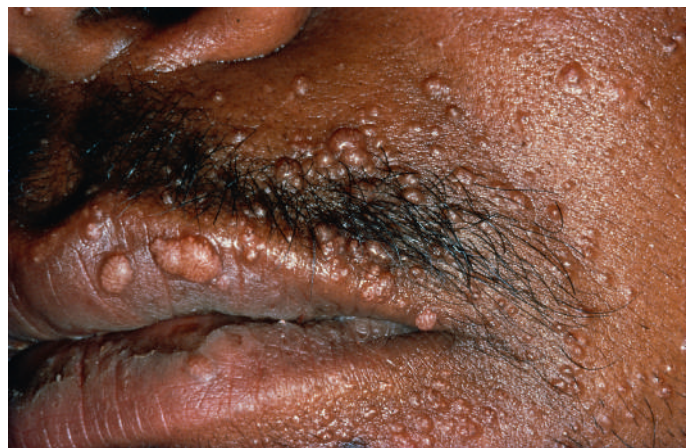**eFig. 19-22** Roseola vaccinia.



**eFig. 19-21**  
Autoinoculation vaccinia.

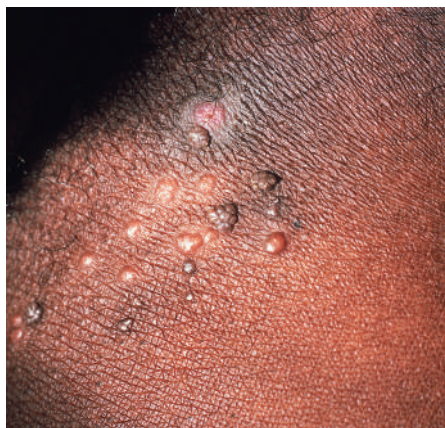

**eFig. 19-23** Molluscum contagiosum.

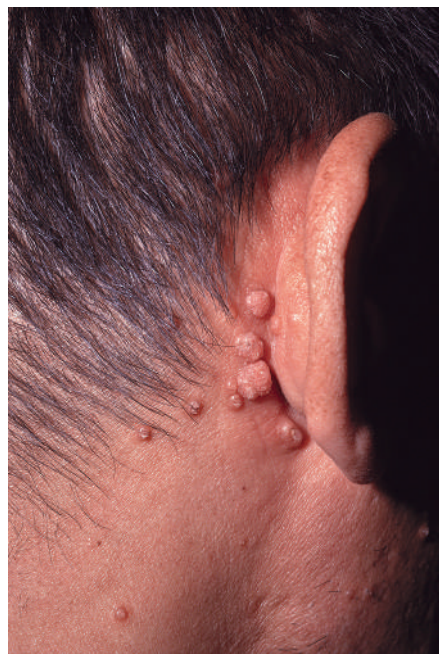

**eFig. 19-24** Molluscum contagiosum.

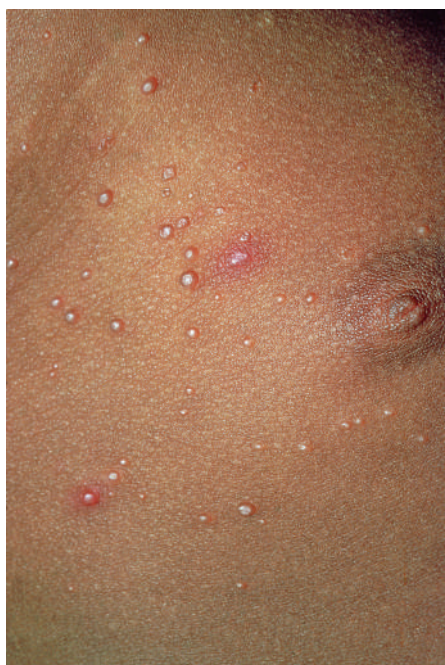



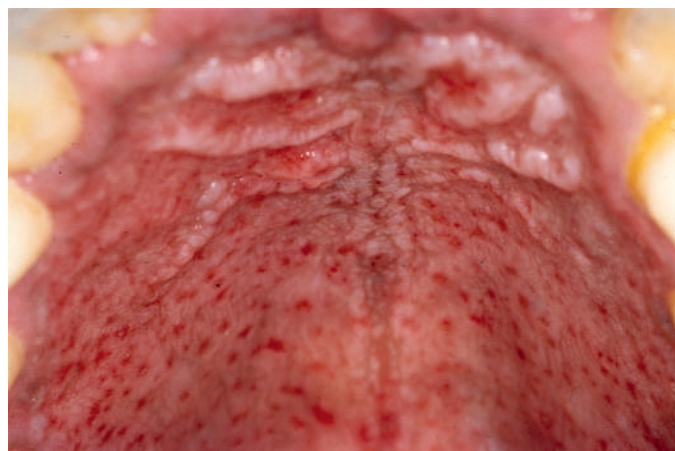**eFig. 19-25** Molluscum contagiosum and condyloma acuminatum (HPV infection) occurring together.



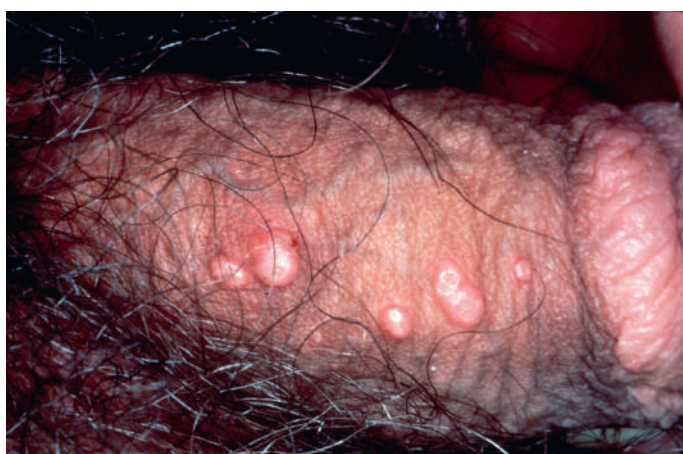**eFig. 19-28** Molluscum contagiosum in AIDS patient.



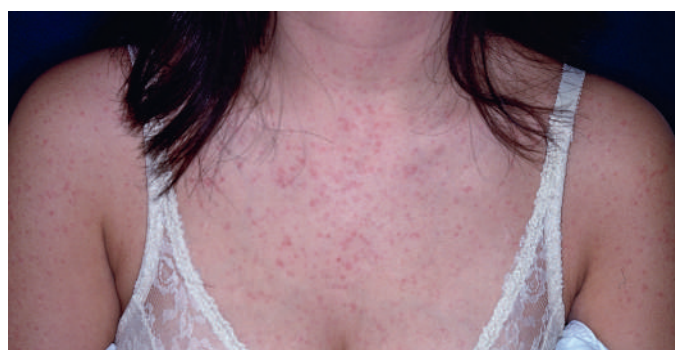**eFig. 19-26** Molluscum contagiosum.



**eFig. 19-29** Viral enanthem.

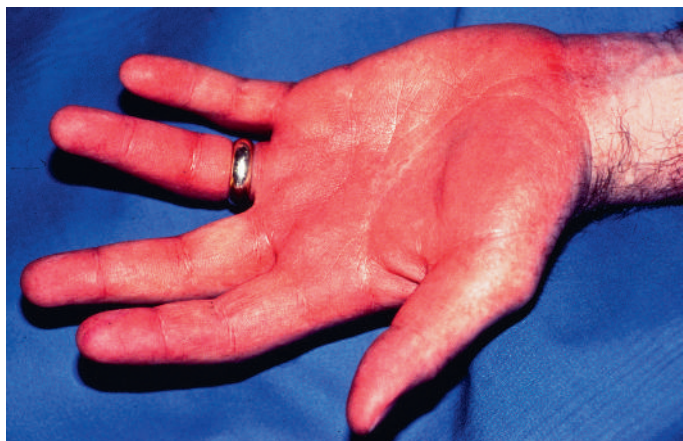

**eFig. 19-27** Genital molluscum contagiosum.

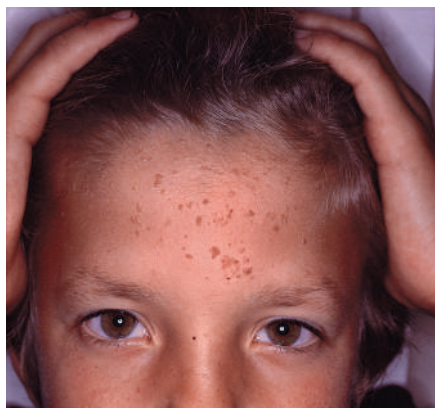

**eFig. 19-30** Rubella.

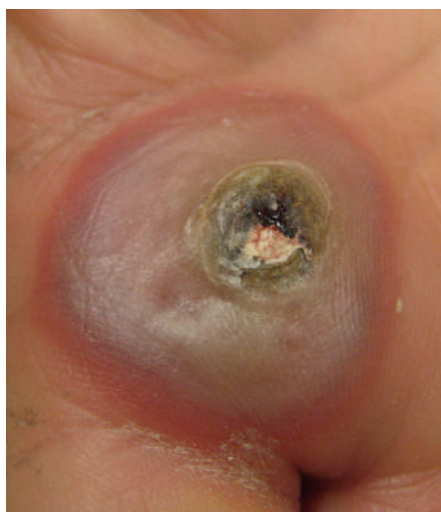




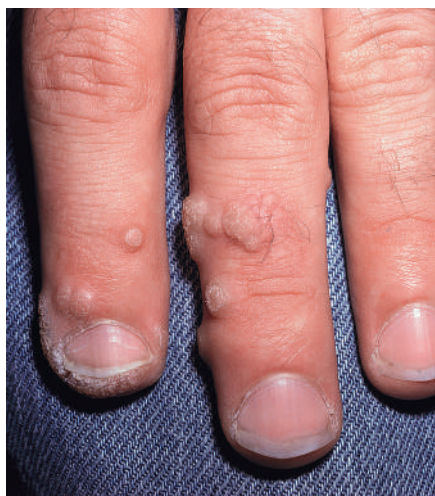**eFig. 19-31** Papular-purpuric gloves-and-socks syndrome.



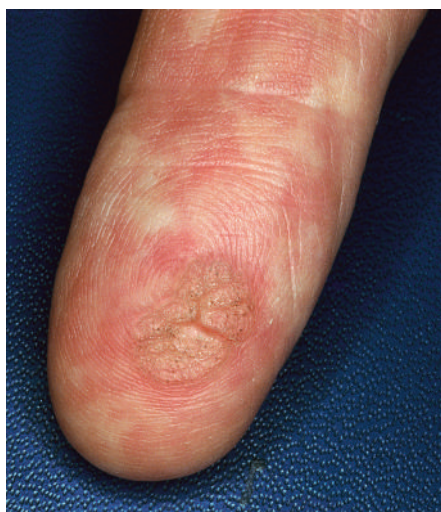**eFig. 19-34** Verruca plana.



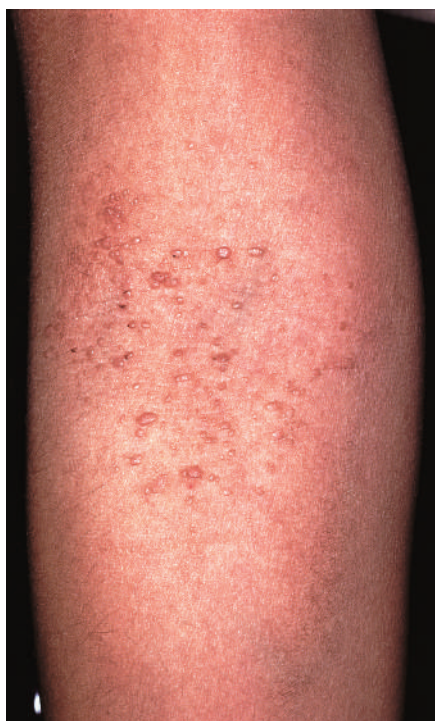
**eFig. 19-32** Orf.



**eFig. 19-35** Common warts, verruca vulgaris.

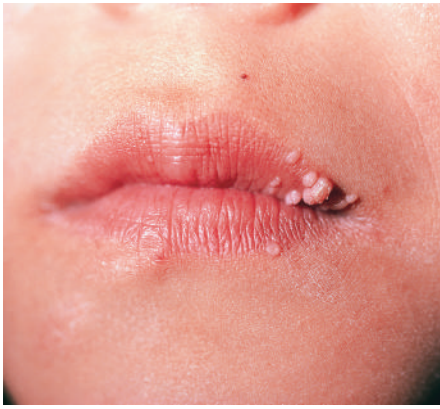

**eFig. 19-33** Verruca vulgaris, wart at site of trauma.

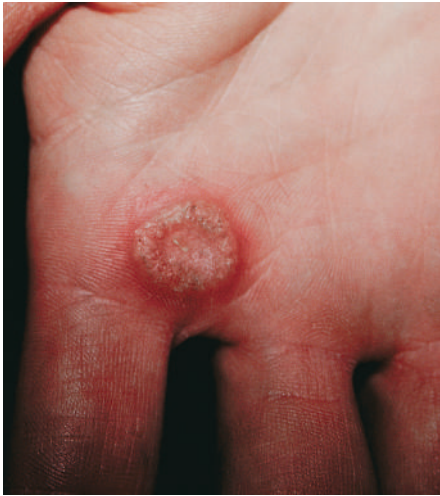

**eFig. 19-36** Grouped warts in area of atopic dermatitis.

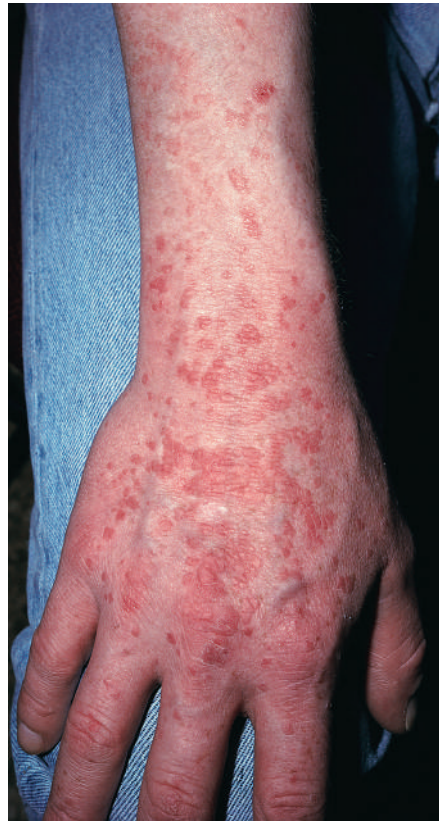



**eFig. 19-37** Verruca, nail biter with periungual warts.



**eFig. 19-38** Verruca vulgaris, doughnut wart.



**eFig. 19-39** Epidermodysplasia verruciformis.

# 20

## Parasitic Infestations, Stings, and Bites

The major groups of animals responsible for bites, stings, and parasitic infections in humans belong to the phyla Arthropoda, Chordata, Cnidaria (formerly Coelenterata), Nematelminthes, Platyhelminthes, Annelida, and Protozoa. This chapter reviews parasitic diseases and the major causes of bites and stings, as well as strategies for prevention.

### PHYLUM PROTOZOA

The protozoa are one-celled organisms, divided into classes according to the nature of their locomotion. Class Sarcodina organisms move by temporary projections of cytoplasm (pseudopods); class Mastigophora by means of one or more flagella; and class Ciliata by short, hairlike projections of cytoplasm (cilia). Class Sporozoa have no special organs of locomotion.

### CLASS SARCODINA

#### Amebiasis cutis

*Entamoeba histolytica* is an intestinal parasite transmitted by the fecal-oral route or by sexual contact. Cutaneous ulcers usually result from extension of an underlying amebic abscess; the most common sites are the trunk, abdomen, buttocks, genitalia, and perineum. Those on the abdomen may result from hepatic abscesses. Penile lesions are usually sexually acquired. Most lesions begin as deep abscesses that rupture and form ulcerations with distinct, raised, cordlike edges, and an erythematous halo approximately 2 cm wide. The base is covered with necrotic tissue and hemopurulent pus containing amebas. These lesions are from a few centimeters to 20 cm wide. Without treatment, slow progression of the ulcer occurs in an increasingly debilitated patient until death ensues. Patients may also present with fistulas, fissures, polypoid warty lesions, or nodules. Deep lesions are more likely to be associated with visceral lesions.

The sole manifestation of early amebiasis may be chronic urticaria. An estimated 10 million invasive cases occur annually, most of them in the tropics. Infection may be asymptomatic, or bloody diarrhea and hepatic abscesses may be present. In the United States, the disease occurs chiefly in institutionalized patients, world travelers, recent immigrants, migrant workers, and men who have sex with men (MSM). Penile ulcers are associated with insertive anal intercourse.

The histologic findings are those of a necrotic ulceration with many lymphocytes, neutrophils, plasma cells, and eosinophils. *E. histolytica* is found in the tissue, within blood and lymph vessels. The organism measures 50–60 µm in diameter and has basophilic cytoplasm and a single, eccentric nucleus with a central karyosome. The organism is frequently demonstrable in fresh material from the base of the ulcer by direct smear. Culture of the protozoa confirms the diagnosis. Indirect

hemagglutination test results remain elevated for years after the initial onset of invasive disease, whereas the results of gel diffusion precipitation tests and counterimmunoelectrophoresis become negative at 6 months. This property can be used to test for recurrent or active disease in persons coming from endemic areas.

When the perianal or perineal areas are involved, granuloma inguinale, lymphogranuloma venereum, deep mycosis, and syphilis must be considered. In chronic urticaria, fresh stool examinations by a trained technician are necessary.

The treatment of choice is metronidazole (Flagyl), 750 mg orally three times daily for 10 days. Abscesses may require surgical drainage.

#### Other amebas

Amebas of the genera *Acanthamoeba* and *Balamuthia* may also cause skin lesions in infected hosts. These organisms are ubiquitous in the environment and are found in soil, water, and air. Granulomatous amebic encephalitis is the most common manifestation of infection with these amebas. In the case of *Acanthamoeba*, invasive infections are almost always in immunocompromised individuals, including those with acquired immunodeficiency syndrome (AIDS) and organ transplant patients, although *Acanthamoeba* can also involve the cornea in those who use homemade contact lens solution. Disseminated lesions present as pink or violaceous nodules that then enlarge, suppurate, and form ulcers with a necrotic eschar (Fig. 20-1). Other findings include fever, nasal congestion or discharge, epistaxis, cough, headaches, lethargy, altered mental status, and seizures. In patients infected with *Acanthamoeba* who have disease of the central nervous system (CNS), death usually occurs within days to weeks. The organisms are visible on skin biopsy, and culture is definitive. In patients without CNS involvement, mortality is 75%, with successfully treated cases often managed with a combination of 5-fluorocytosine and sulfadiazine. In patients infected with *Balamuthia mandrillaris*, involvement of the central face is typical. Treatment paradigms are changing, and in vitro evidence suggests that diminazene aceturate is more active than miltefosine or pentamidine (Fig. 20-2). Chlorhexidine topically and surgical debridement are local adjunctive measures that may prove beneficial.

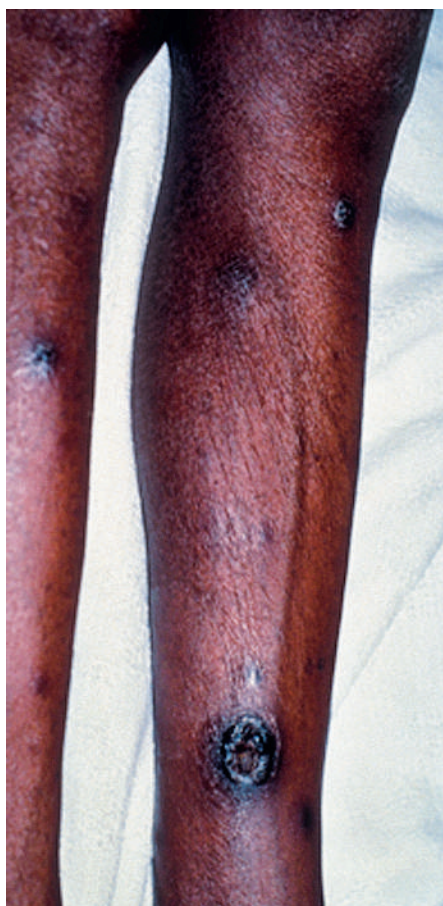**Abdoulrasouli A, et al:** Sexually transmitted penile amoebiasis in Iran: a case series. *Sex Transm Infect* 2012; 88(8):585–588.

**Ahmad AF, et al:** The in vitro efficacy of antimicrobial agents against the pathogenic free-living amoeba *Balamuthia mandrillaris*. *J Eukaryot Microbiol* 2013; 60(5):539–543.

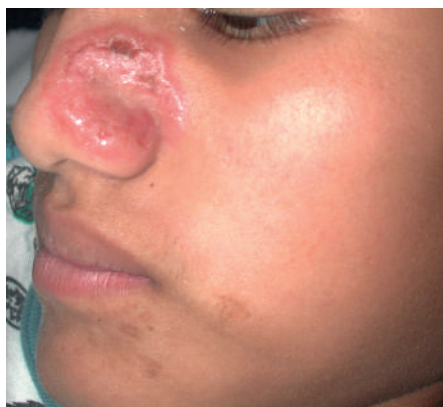**Centers for Disease Control and Prevention:** Investigational drug available directly from CDC for the treatment of infections with free-living amebae. *MMWR* 2013; 62(33):666.

**Cabello-Vilchez AM, et al:** The isolation of *Balamuthia mandrillaris* from environmental sources from Peru. *Parasitol Res* 2014; 113:2509–2513.





**Fig. 20-1** Disseminated acanthameba in HIV disease.



**Fig. 20-2** *Balamuthia* infection. (Courtesy of Paco Bravo, MD.)

## CLASS MASTIGOPHORA

Organisms belonging to this class, the mastigophorans, are also known as flagellates. Many have an undulating membrane with flagella along their crest.

### Trichomoniasis

*Trichomonas* vulvovaginitis is a common cause of vaginal pruritus, with burning and a frothy leukorrhea. The vaginal mucosa appears bright red from inflammation and may be mottled with pseudomembranous patches. The male urethra may also harbor the organism; in the male it causes urethritis and prostatitis. Occasionally, men may develop balanoposthitis. Erosive lesions on the glans and penis or abscesses of the

median raphe may occur. Neonates may acquire the infection during passage through the birth canal, but they require treatment only if symptomatic or if colonization lasts more than 4 weeks. Because this is otherwise almost exclusively a sexually transmitted disease (STD), *Trichomonas* vulvovaginitis in a child should prompt suspicion of sexual abuse.

Trichomoniasis is caused by *Trichomonas vaginalis*, a colorless piriform flagellate 5–15  $\mu\text{m}$  long. *T. vaginalis* is demonstrated in smears from affected areas. Testing by direct immunofluorescence is sensitive and specific, and polymerase chain reaction (PCR) analysis is now available.

Metronidazole, 2 g in a single oral dose, is the treatment of choice. Alternatively, 500 mg twice daily for 7 days may be given, and intravaginal metronidazole/miconazole is also effective. Patients should be warned not to drink alcohol for 24 h after or dosing because of the disulfiram-type effects of this medication. Male sex partners should also be treated. The use of metronidazole is contraindicated in pregnant women, and clotrimazole, applied intravaginally at 100 mg a night for 2 weeks, may be used instead. Disulfiram and nithiamide show in vitro evidence of activity and could prove useful for resistant organisms.

**McGowin CL, et al:** *Trichomonas vaginalis*: common, curable and in the diagnostic spotlight. Clin Lab Sci 2014; 27:53–56.

**Schwebke JR, et al:** Intravaginal metronidazole/miconazole for the treatment of vaginal trichomoniasis. Sex Transm Dis 2013; 40(9):710–714.

## Leishmaniasis

Cutaneous leishmaniasis, American mucocutaneous leishmaniasis, and visceral leishmaniasis (kala-azar), which includes infantile leishmaniasis and post-kala-azar dermal leishmaniasis, are all caused by morphologically indistinguishable protozoa of the family Trypanosomidae, called *Leishmania* (pronounced leesh-may-nea). The clinical features of the leishmaniasis differ, and in general, these diseases have different geographic distribution. The variable clinical manifestations may result from the diversity of the organism and the person's immune status and genetic ability to initiate an effective cell-mediated immune response to the specific infecting organism. It is known that the antigen-specific T-cell responses, which lead to the production of interferon (IFN) and interleukin-12 (IL-12), are important for healing of the lesions and the induction of lifelong, species-specific immunity to reinfection that results after natural infection. Both CD4+ and CD8+ lymphocytes appear to be active in the immune response. IL-10-producing natural regulatory T cells may play a role in the downregulation of infection-induced immunity.

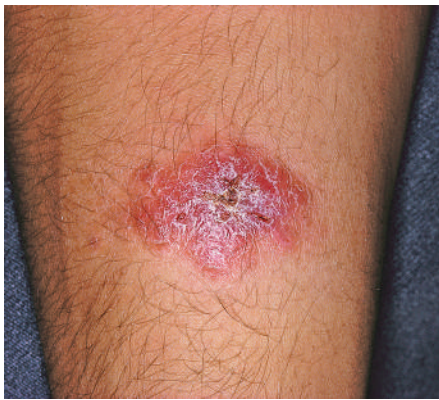### Cutaneous leishmaniasis

There are several types of lesion. All tend to occur on exposed parts because all are transmitted by the sandfly. Old World leishmaniasis manifests mainly in the skin and has also been called Baghdad boil, Oriental sore, leishmaniasis tropica, Biskra button, Delhi boil, Aleppo boil, Kandahar sore, and Lahore sore. Mild visceral disease may occur. Skin lesions of New World infection have been termed uta, pian bois, and bay sore or chiclero ulcer.

#### Clinical features

In Old World leishmaniasis, lesions may present in two distinct types. One is the moist or rural type, a slowly growing, indurated, livid, indolent papule (Fig. 20-3), which enlarges in a few months to form a nodule that may ulcerate in a few weeks to





**Fig. 20-3** Old World leishmaniasis.

form an ulcer as large as 5 cm in diameter. Spontaneous healing usually takes place within 6 months, leaving a characteristic scar. This type is contracted from rodent reservoirs such as gerbils via the sandfly vector. The incubation period is relatively short (1–4 weeks). The dry or urban type has a longer incubation period (2–8 months or longer), develops much more slowly, and heals more slowly than the rural type. In both types, the ulcer or crust forms on a bed of edematous tissue.

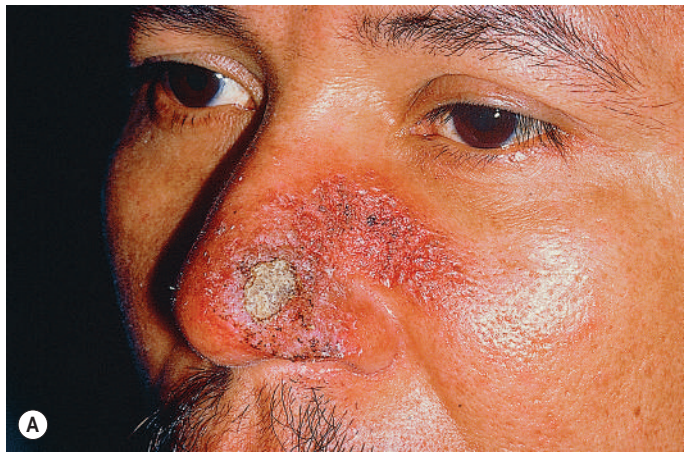Rarely, after the initial or “mother” lesion is healed, at the borders of the healed area, a few soft red papules may appear that are covered with whitish scales and have the “apple jelly” characteristics of granulomatous diseases such as lupus vulgaris. These spread peripherally on a common erythematous base and are the lupoid type. This is also known as leishmaniasis recidivans and occurs most often with the urban type of disease, caused by *Leishmania tropica*. New World disease may also induce purely cutaneous lesions, of varied morphology. The primary papule may become nodular, verrucous, furunculoid, or ulcerated, with an infiltrated red border (Fig. 20-4). Subcutaneous peripheral nodules, which eventually ulcerate, may signal extension of the disease. A linear or radial lymphangitic (sporotrichoid) pattern may occur with lymphadenopathy, and the nodes may rarely yield organisms. Facial lesions may coalesce and resemble erysipelas. Recidivans lesions are unusual in the New World form of disease. In Yucatan and Guatemala, a subtype of New World disease exists: the chiclero ulcer. The most frequent site of infection is the ear (Fig. 20-5). The lesions ulcerate and occur most frequently in workers who harvest chicle for chewing gum in forests, where there is high humidity. This form is a more chronic ulcer that may persist for years, destroying the ear cartilage and leading to deformity. The etiologic agent is *Leishmania mexicana* and the sandfly vector, *Lutzomyia flaviscutellata*.

Uta is a term used by Peruvians for leishmaniasis occurring in mountainous territory at 1200–1800 m above sea level. The ulcerating lesions are found on exposed sites and mucosal lesions do not occur.

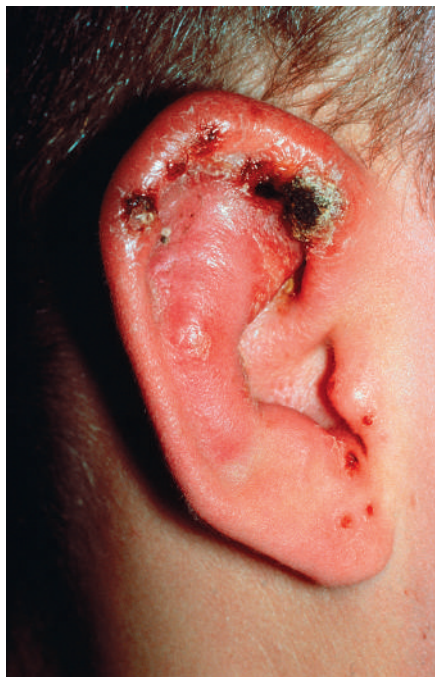Disseminated cutaneous leishmaniasis may be seen in both New and Old World disease. Multiple nonulcerated papules and plaques, chiefly on exposed surfaces, characterize this type. The disease begins with a single ulcer, nodule, or plaque from which satellite lesions may develop and disseminate to cover the entire body. The disease is progressive, and treatment is usually ineffective. It is characterized by anergy to the organism. This type of leishmaniasis must be differentiated from lepromatous leprosy, xanthoma tuberosum, paracoccidoidal granuloma, Lobo’s disease, and malignant lymphoma.

### Etiologic factors

*Leishmania tropica*, *L. major*, *L. aethiops*, and *L. infantum*, the cause of Mediterranean visceral leishmaniasis, may cause



**Fig. 20-4** A and B, New World leishmaniasis.



**Fig. 20-5** Chiclero ulcer in leishmaniasis.

cutaneous leishmaniasis. Purely cutaneous leishmaniasis is also caused by several species present in the New World. *L. mexicana* does not induce mucosal disease. *Leishmania braziliensis guyanensis* produces cutaneous disease, as does *L. b. braziliensis* and *L. b. panamensis*; however, the latter two may also result in mucocutaneous disease.



## Epidemiology

Cutaneous leishmaniasis is endemic in Asia Minor and to a lesser extent in many countries around the Mediterranean. Iran and Saudi Arabia have a high occurrence rate. In endemic areas, deliberate inoculation on the thigh is sometimes practiced so that scarring on the face—a frequent site for Oriental sore—may be avoided. Purely cutaneous lesions may also be found in the Americas. In the United States, leishmaniasis is largely restricted to southern Texas, although rare reports of human cutaneous disease have occurred as far north as Pennsylvania, and visceral leishmaniasis in immunosuppressed humans is being recognized as an emerging infection in areas not previously thought to be endemic for the disease.

## Pathogenesis

The leishmania protozoan has an alternate life in vertebrates and in insect hosts. Humans and other mammals, such as dogs and rodents, are the natural reservoir hosts. The vector hosts are *Phlebotomus* sandflies for the Old World type and *Phlebotomus perniciosus* and *Lutzomyia* sandflies for New World cutaneous leishmaniasis. After the insect has fed on blood, the flagellates (leptomonad, promastigote) develop in the gut in 8–20 days, after which migration occurs into the mouth parts; from here, transmission into humans occurs by a bite. In humans, the flagella are lost, and a leishmanial form (amastigote) is assumed.

## Histopathology

An ulcer with a heavy infiltrate of histiocytes, lymphocytes, plasma cells, and polymorphonuclear leukocytes is seen. The parasitized histiocytes form tuberculoid granulomas in the dermis. Pseudoepitheliomatous hyperplasia may occur in the edges of the ulcer. Leishmanias are nonencapsulated and contain a nucleus and a paranucleus. Wright, Giemsa, and monoclonal antibody staining may be helpful in identifying the organisms within histiocytes, where they often line up at the periphery of a vacuole. PCR primers are available for a variety of species. PCR is more sensitive than microscopy but less sensitive than culture.

## Diagnosis

In endemic areas, the diagnosis is not difficult. In other localities, cutaneous leishmaniasis may be confused with syphilis, yaws, lupus vulgaris, and pyogenic granulomas. The diagnosis is established by demonstration of the organism in smears. A punch biopsy specimen from the active edge of the ulcer is ideal for culture. It can be placed in Nicolle-Novy-MacNeal (NNN) medium and shipped at room temperature. Parasites can also be cultured from tissue fluid. A hypodermic needle is inserted into the normal skin and to the edge of the ulcer base. The needle is rotated to work loose some material and serum, which is then aspirated. A culture on NNN medium at 22–35°C (71.6–95°F) is recommended to demonstrate the leptomonads. As expected, PCR is the most sensitive diagnostic test for cutaneous leishmaniasis.

## Treatment

Spontaneous healing of primary cutaneous lesions occurs, usually within 12–18 months, shorter for Old World disease. Reasons to treat a self-limited infection include avoiding disfiguring scars in exposed areas, avoiding secondary infection, controlling disease in the population, and failure of spontaneous healing. In the diffuse cutaneous and recidivans types, leishmaniasis may persist for 20–40 years if not treated.

In areas where localized cutaneous leishmaniasis is not complicated by recidivans or sporotrichoid forms or by mucocutaneous disease, treatment with such topical modalities as

paromomycin sulfate 15% plus methylbenzethonium chloride 12%, ketoconazole cream under occlusion, cryotherapy, local heat, photodynamic therapy, and laser ablation, or with intralesional sodium stibogluconate antimony or emetine hydrochloride may be effective and safe.

In the setting of Old World cutaneous leishmaniasis, some data suggest that intramuscular meglumine antimoniate in combination with intralesional meglumine antimoniate may be superior to intralesional therapy alone. A meta-analysis of studies of Old World cutaneous leishmaniasis concluded that pentamidine was similar in efficacy to pentavalent antimonials, and that both were superior to the other agents studied. Since then, a Pakistani study concluded that itraconazole was more effective and more economical and had fewer side effects than meglumine antimoniate in both wet and dry types of cutaneous leishmaniasis. The number of patients studied was relatively small, and other studies have been disappointing. Oral fluconazole and zinc sulfate have been used to treat *Leishmania major* infection. A similar meta-analysis of studies of New World cutaneous leishmaniasis concluded that meglumine might be the best agent in its class. Intralesional therapy may be acceptable for small, solitary lesions in areas with a low risk of mucosal disease. Azithromycin has been used in New World disease but is inferior to antimonials. Perilesional injections of IFN- $\gamma$  have also been reported to be effective but are expensive.

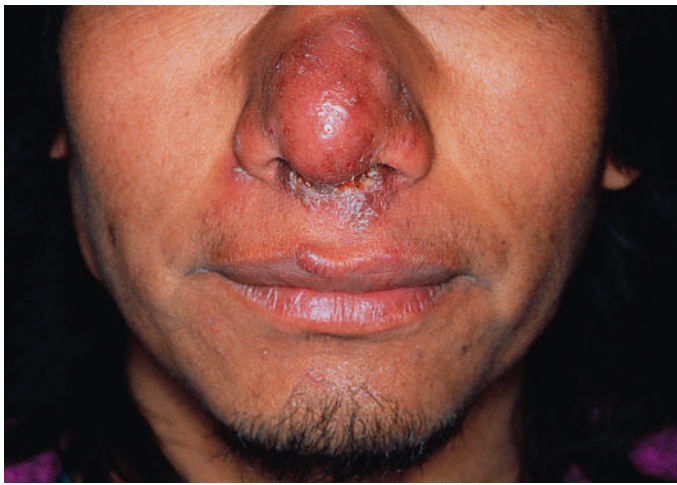In immunosuppressed patients or those who acquire infection in areas where mucocutaneous disease may occur, systemic therapy is recommended. As with topical treatment, many alternatives have been reported to be effective. Sodium antimony gluconate (sodium stibogluconate) solution is given intramuscularly or intravenously, 20 mg/kg/day in two divided doses for 28 days. It can be obtained from the U.S. Centers for Disease Control and Prevention (CDC) Drug Service (Atlanta, GA 30333). Repeated courses may be given. Antimony *n*-methyl glutamine (Glucantime) is used more often in Central and South America because of its local availability.

Other systemic medications reported to be effective include fluconazole (200 mg/day for 6 weeks), ketoconazole, dapsone, rifampicin, and allopurinol. Some of these have not been subjected to controlled clinical trials, as is true of most topical treatments. The recidivans and disseminated cutaneous types may require prolonged courses or adjuvant IFN therapy. Amphotericin B may be used in antimony-resistant disease. Lipid formulations of amphotericin B are highly effective in short courses but are expensive. Liposomal amphotericin B may be especially helpful for *Leishmania braziliensis* and *L. guyanensis* infections. Intramuscular pentamidine is also used for *L. guyanensis* cutaneous leishmaniasis, because this infection is resistant to systemic antimony. Miltefosine is being used for cutaneous disease in some areas of the world and may prove to be the treatment of choice for diffuse cutaneous leishmaniasis and post-kala-azar dermal leishmaniasis. However, some studies have shown miltefosine to be ineffective in *L. major* and *L. braziliensis* infections. Posaconazole has been used in Old World disease. Control depends chiefly on the success of antily measures taken by health authorities and personal protection with protective clothing, screening, and repellents. Vaccines are being investigated but are not available.

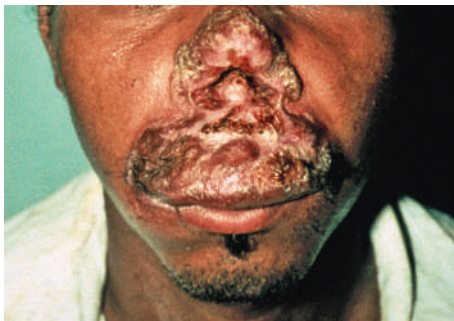## Mucocutaneous leishmaniasis (leishmaniasis americana, espundia)

### Clinical features

The initial leishmanial infection, which occurs at the site of the fly bite, is a cutaneous ulcer. Secondary lesions on the mucosa usually occur at some time during the next 5 years (Fig. 20-6).



**Fig. 20-6** Mucocutaneous leishmaniasis.



**Fig. 20-7** Severe destructive mucocutaneous leishmaniasis. (Courtesy of Debra Kalter, MD.)

The earliest mucosal lesion is usually hyperemia of the nasal septum with subsequent ulceration, which progresses to invade the septum and later the paranasal fossae. Perforation of the septum eventually takes place. For some time, the nose remains unchanged externally, despite the internal destruction. At first, only a dry crust is observed, or a bright-red infiltration or vegetation on the nasal septum, with symptoms of obstruction and small hemorrhages. Despite the mutilating and destructive character of leishmaniasis, it never involves the nasal bones. When the septum is destroyed, the nasal bridge and tip of the nose collapse, giving the appearance of a parrot beak, camel nose, or tapir nose.

It is important to recall that the four great chronic infections—syphilis, tuberculosis, Hansen's disease, and leishmaniasis—have a predilection for the nose. The ulcer may extend to the lips (Fig. 20-7) and continue to advance to the pharynx, attacking the soft palate, uvula, tonsils, gingiva, and tongue. The eventual mutilation is called *espondia*. Two perpendicular grooves at the union of the osseous palate and soft tissues, in the midst of the vegetative infiltration of the entire pharynx, are called the *palate cross of espondia*.

Only in exceptional cases does American leishmaniasis invade the genital or ocular mucous membranes. The frequency of mucous membrane involvement is variable. In Yucatan and Guatemala, it is an exception; in other countries, such as Brazil, it may occur in 80% of cases.

### Etiologic factors

Mucocutaneous leishmaniasis is mainly caused by *Leishmania* (*Viannia*) *braziliensis braziliensis* and *L. b. panamensis*, although some Old World organisms, including *L. infantum*, *L. major*, and *L. tropica*, can cause mucosal ulceration. *Leishmania* has two forms: the nonflagellated form or leishmania, which is found in the tissues of humans and animals susceptible to the

inoculation of the parasite; and the flagellated form or leptomonad, which is found in the digestive tract of the vector insect (*Lutzomyia* in mucocutaneous disease) and in cultures. The typical morphology of leishmania, as found in vertebrates, is round or oval, usually with one extremity more rounded than the other, measuring 2–4  $\mu\text{m}$   $\times$  1.5–2.5  $\mu\text{m}$ , with cytoplasm, nucleus, and blepharoplast or kinetoplast.

### Epidemiology

Mucocutaneous leishmaniasis is predominantly a rural disease. It most often occurs in damp and forested regions. The disease can be contracted at any time of the year, but the risk is highest just after the rainy season. All ages and races and both genders are equally affected. Epidemics parallel the El Niño cycle.

### Histopathology

In ulcerous leishmaniasis, marked irregular acanthosis and sometimes pseudoepitheliomatous hyperplasia can be found. The dermis shows a dense infiltration of histiocytes, lymphocytes, and plasma cells. In new lesions, some neutrophils are observed. Large Langhans giant cells or typical tubercles are occasionally seen. Numerous organisms are present (mostly in histiocytes), which are nonencapsulated and contain a nucleus and a paranucleus. Wright, Giemsa, and monoclonal antibody staining may be helpful in identifying the organisms. In patients with granulomatous infiltrates containing intracellular parasites within histiocytes, leishmaniasis is one of several diseases to be considered, including rhinoscleroma, histoplasmosis, granuloma inguinale, Chagas' disease, *Penicillium marneffe* infection, and toxoplasmosis. Touch smears stained with Giemsa are helpful in many cases of cutaneous and mucocutaneous leishmaniasis.

### Laboratory findings

*Leishmania* is demonstrated in the cutaneous and mucous membrane lesions by direct smears or cultures. In Wright-stained biopsy material, intracellular and extracellular organisms are seen with typical morphology of two chromatic structures: nucleus and parabasal body. In later mucosal lesions, the scarcity of parasites makes identification difficult. The culture is done on NNN medium for leptomnads. PCR is now widely used, and specimens obtained from lesion scarification and blood sample-enriched leukocytes compare favorably with indirect immunofluorescence reaction and culture techniques.

### Prophylaxis

Although it is impractical to eliminate the insect vector, it is still the only valid measure for the control of this prevalent disease. Effective vaccines are not available for mucocutaneous leishmaniasis.

### Treatment

Treatment is the same as described for cutaneous leishmaniasis, except that antimony resistance is common in mucocutaneous disease. Combination therapy using antimonials with drugs such as rifampin or azithromycin, or adding immunomodulators such as IFN- $\gamma$ , IL-2, or imiquimod may result in cure. Amphotericin B treatment may be necessary.

## Visceral leishmaniasis (kala-azar, dum-dum fever)

### Clinical features

The earliest lesion is the cutaneous nodule or leishmanioma, which occurs at the site of the initial sandfly inoculation.



Kala-azar, meaning “black fever,” acquired its name because of the patchy macular darkening of the skin caused by deposits of melanin that develop in the later course of the disease. These patches are most marked over the forehead and temples, periodically, and on the midabdomen.

The primary target for the parasites is the reticuloendothelial system; the spleen, liver, bone marrow, and lymph nodes are attacked. The incubation period is 1–4 months. An intermittent fever, with temperatures ranging from 39° to 40°C (102–104°F), ushers in the disease. Hepatosplenomegaly, agranulocytosis, anemia, and thrombocytopenia occur. Chills, fever, emaciation, weight loss, weakness, epistaxis, and purpura develop as the disease progresses. Susceptibility to secondary infection may produce pulmonary and gastrointestinal (GI) infection, ulcerations in the mouth (cancrum oris), and noma. Death occurs about 2 years from onset in untreated individuals.

Most infections are subclinical or asymptomatic. In patients with AIDS, papular and nodular skin lesions may occur. Dermatofibroma-type or Kaposi sarcoma-like, brown to purple nodules are most frequently reported, although random biopsies of normal skin will reveal organisms. Therefore, clinical correlation is necessary to attribute skin findings to *Leishmania* specifically.

### Etiologic factors

*Leishmania donovani* spp. *donovani*, *infantum*, and *chagasi* cause visceral leishmaniasis and are parasites of rodents, canines, and humans. They are nonflagellate oval organisms about 3 μm in diameter, known as Leishman-Donovan bodies. In the sandfly, it is a leptomonad form with flagella.

### Epidemiology

*Leishmania donovani donovani* causes visceral leishmaniasis in India, with the major reservoir being humans and the vector being *Phlebotomus argentipes*. *L. donovani infantum* occurs in China, Africa, the Near East and Middle East, and the Mediterranean littoral, where the major reservoirs are dogs; *Phlebotomus perniciosus* and *P. ariasi* are the vectors of the Mediterranean type. American visceral leishmaniasis is caused by *L. donovani chagasi* and is transmitted by the sandfly *Lutzomyia longipalpis*. American visceral leishmaniasis principally affects domestic dogs, although explosive outbreaks of the human infection occur sporadically, when the number of *Lutzomyia longipalpis* builds up to a high level in the presence of infected dogs. Canine visceral infections with *Leishmania infantum* have been reported in foxhounds in various parts of the United States and Canada.

### Diagnosis

Leishman-Donovan bodies may be present in the blood in individuals with kala-azar of India. Specimens for examination, in descending order of utility, include spleen pulp, sternal marrow, liver tissue, and exudate from lymph nodes. Culturing on NNN medium may also reveal the organisms.

### Treatment

General supportive measures are essential. Pentavalent antimony has long been the drug of choice. In areas of drug resistance, amphotericin B is usually effective, but it is expensive and toxic, and requires intravenous administration. Miltefosine, an oral alkyl-phosphocholine analog, has proved as effective as amphotericin B in some trials. It is often used to treat visceral disease in India and Ethiopia. Mixed infections involving both *Leishmania* and *Trypanosoma cruzi* are becoming increasingly common in Central and South America because of overlapping endemic areas. Amiodarone has been used as an unconventional antiparasitic drug in this setting in addition to standard therapy.

## Post-kala-azar dermal leishmaniasis

In kala-azar, the leishmanoid (amastigote) forms may be widely distributed throughout apparently normal skin. During and after recovery from the disease, a special form of dermal disease known as post-kala-azar dermal leishmaniasis appears. This condition appears during or shortly after treatment in the African form, but its appearance may be delayed up to 10 years after treatment in the Indian form. It follows the treatment of visceral leishmaniasis in 50% of Sudanese patients and 5–10% of those seen in India. There are two constituents of the eruption: a macular, depigmented eruption found mainly on the face, arms, and upper part of the trunk and a warty, papular eruption in which amastigotes can be found. Because it may persist for up to 20 years, these patients may act as a chronic reservoir of infection. This condition closely resembles Hansen’s disease. High concentrations of IL-10 in the blood of visceral leishmaniasis patients predict those who will be affected by post-kala-azar dermal leishmaniasis. Miltefosine may become the drug of choice.

## Viscerotropic leishmaniasis

Twelve U.S. soldiers developed systemic infection with *Leishmania tropica* while fighting in Operation Desert Storm in Iraq and Kuwait. None had symptoms of kala-azar, but most had fever, fatigue, malaise, cough, diarrhea, or abdominal pain, and none had cutaneous disease. Diagnostic tests yielded positive results on bone marrow aspiration; lymph node involvement was also documented. Treatment with sodium stibogluconate led to improvement.

**Blum J, et al:** Local or systemic treatment for New World cutaneous leishmaniasis? Re-evaluating the evidence for the risk of mucosal leishmaniasis. *Int Health* 2012; 4(3):153–163.

**Elmahallawy EK, et al:** Diagnosis of leishmaniasis. *J Infect Dev Ctries* 2014; 13:961–972.

**Layegh P, et al:** Children and cutaneous leishmaniasis: a clinical report and review. *J Infect Dev Ctries* 2013; 7(8):614–617.

**Mansueto P, et al:** Leishmaniasis in travelers: a literature review. *Travel Med Infect Dis* 2014; 12:563–581.

**Neitzke-Abreu HC, et al:** Detection of DNA from leishmania (viannia): accuracy of polymerase chain reaction for the diagnosis of cutaneous leishmaniasis. *PLoS One* 2013; 8(7):e62473.

**Ravis WR, et al:** Pharmacokinetics and absorption of paromomycin and gentamicin from topical creams used to treat cutaneous leishmaniasis. *Antimicrob Agents Chemother* 2013; 57(10):4809–4815.

**Shirian S, et al:** Three *Leishmania/L. species*—*L. infantum*, *L. major*, *L. tropica*—as causative agents of mucosal leishmaniasis in Iran. *Pathog Glob Health* 2013; 107(5):267–272.

**Singh OP, Sundar S:** Immunotherapy and targeted therapies in treatment of visceral leishmaniasis: current status and future prospects. *Front Immunol* 2014; 26:296.

## Human trypanosomiasis

Three species of trypanosome are pathogenic to humans: *Trypanosoma gambiense* and *T. rhodesiense* in Africa and *T. cruzi* in America. The skin manifestations are usually observed in the earlier stages of trypanosomiasis as evanescent erythema, erythema multiforme, and edema, especially angioedema.

In the early stage of African trypanosomiasis, a trypanosome chancre may occur at the site of a tsetse fly bite. Erythema with circumscribed swellings of angioedema then occurs, with enlargement of the lymph nodes, fever, malaise, headache, and joint pains. In the West African (Gambian) form, the illness is chronic, lasting several years, with progressive

deterioration, whereas the East African (Rhodesian) form is an acute illness, with a stormy, fatal course of weeks to months. The Rhodesian form is more often associated with cutaneous signs. Annular or deep erythema nodosum-like lesions are frequent manifestations (Fig. 20-8). Lymphadenopathy is generalized, but frequently there is a pronounced enlargement of the posterior cervical group (Winterbottom's sign).

In American trypanosomiasis (Chagas' disease), similar changes take place in the skin. The reduviid bug (kissing bug, assassin bug) usually bites at night, frequently at mucocutaneous junctions, where the bug's infected feces are deposited when it feeds (Fig. 20-9). The unsuspecting sleeping person rubs the feces into the bite and becomes infected. If the bite of the infected bug occurs near the eye, Romana's sign develops, consisting of unilateral conjunctivitis and edema of the eyelids, with an ulceration or chagoma in the area. The bite of a "kissing bug" becomes extremely swollen and red, whether or not trypanosomes are involved. Acute Chagas' disease is usually a mild illness of fever, malaise, edema of the face and lower extremities, and generalized lymphadenopathy. Skin lesions occurring in this phase include nodules at the site of inoculation, disseminated nodules, or morbilliform and urticarial lesions. In chronic Chagas' disease, which occurs in 10–30% of infected persons years to decades later, the heart (myocarditis, arrhythmias, thromboembolism, cardiac failure) and GI system (megaesophagus, megacolon) are most often involved. During the remaining infected but asymptomatic indeterminate phase, patients may transmit the disease through transfusion. When such patients become immunosuppressed (with AIDS or

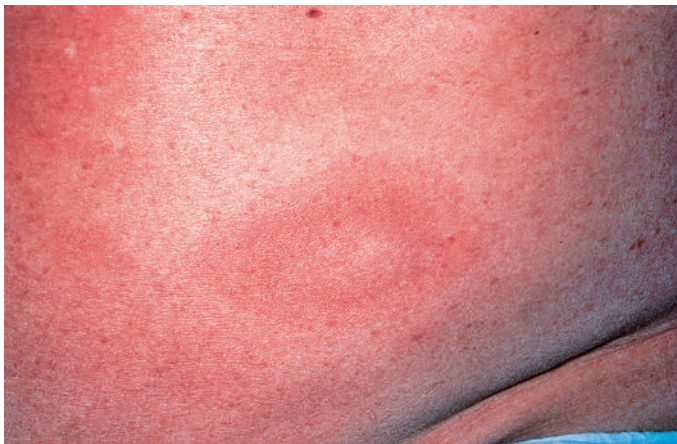

Fig. 20-8 African trypanosomiasis.




Fig. 20-9 Triatome reduviid bug.

organ transplantation), reactivation skin lesions may occur with a wide range of morphologies, including panniculitis.

Rhodesian trypanosomiasis is endemic among the cattle-raising tribes of East Africa, with the savannah habitat of the vectors determining its geographic distribution. Wild game and livestock are reservoir hosts, in addition to humans. The tsetse fly, *Glossina morsitans*, is the principal vector.

For Gambian trypanosomiasis, humans are the only vertebrate host, and the palpalis group of tsetse flies is the invertebrate host. These flies are found close to the water, and their fastidious biologic requirements restrict their distribution and thus that of the disease. Incidence is seasonal, with humidity and temperature being determining factors. The highest incidence is in men age 20–40 in tropical areas of West and Central Africa.

Chagas' disease is prevalent in Central and South America from the United States to Argentina and Chile; the highest incidence is in Venezuela, Brazil, Uruguay, Paraguay, and Argentina. Approximately 29% of all male deaths in the 29–44 age group in Brazil are attributed to Chagas' disease.

Before CNS involvement has occurred in the Rhodesian form, suramin, a complex, non-metal-containing, organic compound, is the treatment of choice. When the CNS is involved, melarsoprol is the drug of choice. Pentamidine isethionate is the drug of choice for the Gambian disease. Eflornithine appears to be a good alternative to melarsoprol for second-stage West African trypanosomiasis. For American trypanosomiasis, treatment is of limited efficacy. Nifurtimox and benznidazole clear the parasitemia and reduce the severity of the acute illness, but there is a high incidence of adverse effects. Although benznidazole reduces parasite load during the acute phase, it does not prevent chronic cardiac lesions. Ruthenium complexation improves bioavailability of benznidazole and has the potential to improve outcomes. Conservative treatment is the typical approach to the patient with congestive heart failure from Chagas' myocarditis, but recent data suggest that clomipramine, a tricyclic antidepressant that inhibits *Trypanosoma cruzi*'s trypanothione reductase, improves the course of cardiac disease in animal models. GI complications may be treated surgically.

**Alviano DS, et al:** Conventional therapy and promising plant-derived compounds against trypanosomatid parasites. *Front Microbiol* 2012; 3:283.

**Chatelain E:** Chagas disease drug discovery: toward a new era. *J Biomol Screen* 2015; 20:22–35.

**Hemmige V, et al:** *Trypanosoma cruzi* infection: a review with emphasis on cutaneous manifestations. *Int J Dermatol* 2012; 51(5):501–508.

**Sekhar GN, et al:** Delivery of antihuman African trypanosomiasis drugs across the blood-brain and blood-CSF barriers. *Adv Pharmacol* 2014; 71:245–275.

## CLASS SPOROZOA

### Toxoplasmosis

Toxoplasmosis is a zoonosis caused by a parasitic protozoan, *Toxoplasma gondii*. Infection may be either congenital or acquired. Cerebral disease has been reported in the setting of rituximab therapy and widespread lesions can mimic melanoma metastases on positron emission tomography (PET) scans. Congenital infection occurs from placental transmission. Abortion or stillbirth may result. However, a full-term child delivered to an infected mother may have a triad of hydrocephalus, chorioretinitis, and cerebral calcification. In addition, there may be hepatosplenomegaly and jaundice. Skin changes in toxoplasmosis are rare and clinically nonspecific.



In congenital toxoplasmosis, macular and hemorrhagic eruptions predominate. Blueberry muffin lesions, reflecting dermatoerythropoiesis, may be seen. Occasionally, abnormal hair growth and exfoliative dermatitis have also been observed. The differential diagnosis of congenital toxoplasmosis is the TORCH syndrome (toxoplasmosis, other agents, rubella, cytomegalovirus, and herpes simplex). In acquired toxoplasmosis, early skin manifestations consist of cutaneous and subcutaneous nodules and macular, papular, and hemorrhagic eruptions. These may be followed by scarlatiniform desquamation, eruptions mimicking roseola, erythema multiforme, and dermatomyositis or lichen planus, as well as exfoliative dermatitis. As a rule, the exanthem is accompanied by high fever and general malaise.

Diagnosis of acquired toxoplasmosis is of special importance to three groups of adults: healthy pregnant women concerned about recent exposure; adults with lymphadenopathy, fever, and myalgia, who might have some other serious disease (e.g., lymphoma); and immunocompromised persons, such as patients with AIDS, in whom toxoplasmosis might be fatal. It is the most common cause of focal encephalitis in AIDS patients, and this may be accompanied by a widespread papular eruption.

*Toxoplasma gondii* is a crescent-shaped, oval, or round protozoan that can infect any mammalian or avian cell. Toxoplasmosis is often acquired through contact with animals, particularly cats. Reservoirs of infection have been reported in dogs, cats, cattle, sheep, pigs, rabbits, rats, pigeons, and chickens. The two major routes of transmission of *T. gondii* in humans are oral and congenital. Meats consumed by humans may contain tissue cysts, thus serving as a source of infection when eaten raw or undercooked. There is no evidence of direct human-to-human transmission, other than from mother to fetus.

The diagnosis cannot be made on clinical grounds alone. It may be established by isolation of *T. gondii*; demonstration of the protozoa in tissue sections, smears, or body fluids by Wright or Giemsa stain; characteristic lymph node histology; and serologic methods. In the patient with bone marrow transplantation, the organism has caused interface dermatitis, creating the potential for misdiagnosis as graft-versus-host disease.

A combination of pyrimethamine (Daraprim) and sulfadiazine acts synergistically and forms an effective treatment. Dosages and total treatment time vary according to the age and immunologic competence of the infected patient.

**Ivanova K, et al:** Acute toxoplasmosis mimicking melanoma metastases: review of conditions causing false-positive results on (18) F-FDG PET/CT. *Dermatology* 2012; 225(4):349–353.

**Safa G, et al:** Cerebral toxoplasmosis after rituximab therapy. *JAMA Intern Med* 2013; 173(10):924–926.

**Vidal Cl, et al:** Cutaneous toxoplasmosis histologically mimicking graft-versus-host disease. *Am J Dermatopathol* 2008; 30(5):492–493.

## PHYLUM CNIDARIA

The cnidarians include the jellyfish, hydroids, Portuguese men-of-war, corals, and sea anemones. These are all radial marine animals, living mostly in ocean water.

### Portuguese man-of-war dermatitis

Stings by the Portuguese man-of-war (*Physalia physalis* in Atlantic or much smaller *Physalia utriculus* or “bluebottle” in Pacific Ocean) are characterized by linear lesions that are erythematous, urticarial, and even hemorrhagic. The forearms,

sides of the trunk, thighs, and feet are common sites of involvement. The usual local manifestation is sharp, stinging, and intense pain. Internally, there may be severe dyspnea, prostration, nausea, abdominal cramps, lacrimation, and muscular pains. Death may occur if the areas stung are large in relation to the patient's size.

The fluid of the nematocysts contains toxin that is carried into the victim through barbs along the tentacle. The venom is a neurotoxic poison that can produce marked cardiac changes. Each Portuguese man-of-war is a colony of symbiotic organisms consisting of a blue to red float or pneumatophore with a gas gland, several gastrozooids measuring 1–20 mm, reproductive polyps, and the fishing tentacles bearing the nematocysts from which the barbs are ejected. The hydroid is found most frequently along the southeastern Florida coastline and in the Gulf of Mexico as well as on windward coasts throughout the mid-Pacific and South Pacific. Safe Sea, a barrier cream, has been reported as being effective at preventing jellyfish stings off the coast of Florida, but studies of barrier creams in general have been mixed.

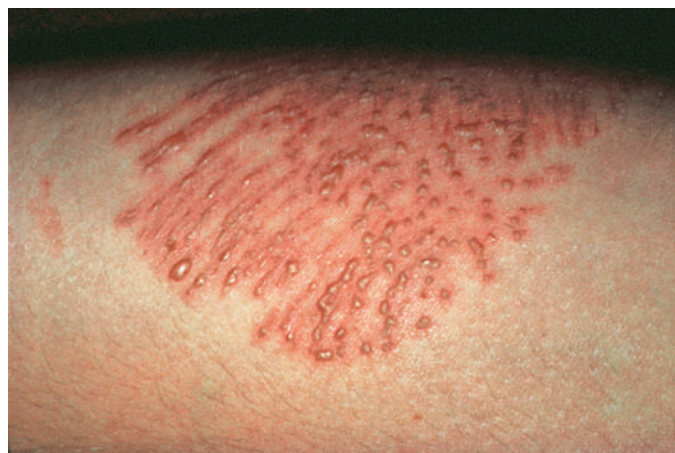### Jellyfish dermatitis

Jellyfish dermatitis produces lesions similar to those of the Portuguese man-of-war, except that the lesions are not so linear (Fig. 20-10). Immediate allergic reactions occur infrequently as urticaria, angioedema, or anaphylaxis. Delayed and persistent lesions also rarely occur.

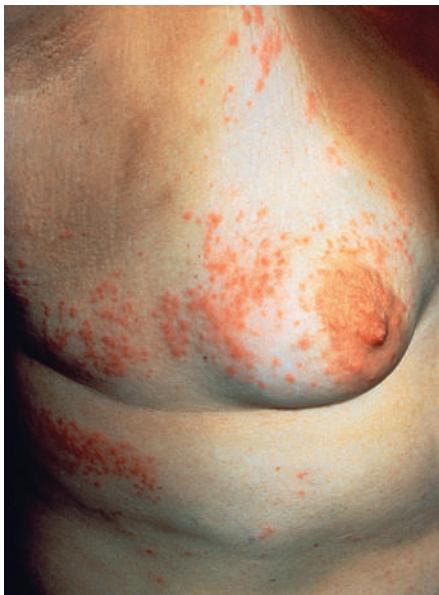The Australian sea wasp, *Chironex fleckeri*, which is colorless and transparent, is the most dangerous of all jellyfish, with a sting that is often fatal. Another sea wasp, *Carybdea marsupialis*, is much less dangerous and occurs in the Caribbean Sea. *Rhopilema nomadica*, common in the Mediterranean Sea, has been reported to cause severe delayed dermatitis.

Seabather's eruption is an acute dermatitis that begins a few hours after bathing in the waters along the Atlantic coast. It affects covered areas of the body as cnidarian larvae become entrapped under the bathing suit and the nematocyst releases its toxin because of external pressure. Thus, the buttocks and waist are affected primarily, with the breast also involved in women (Fig. 20-11). Erythematous macules and papules appear and may develop into pustules or vesicles. Urticarial plaques are also present in a smaller number of patients. Crops of new lesions may occur for up to 72 h, and the eruption persists for 10–14 days on average. It is quite pruritic.

Outbreaks in Florida are usually caused by larvae of the thimble jellyfish, *Linuche unguiculata*, which patients report as



**Fig. 20-10** Jellyfish sting. (Courtesy of Dr. Anthony Slagel.)



**Fig. 20-11** Seabather's eruption.



**Fig. 20-12** Sea anemone.

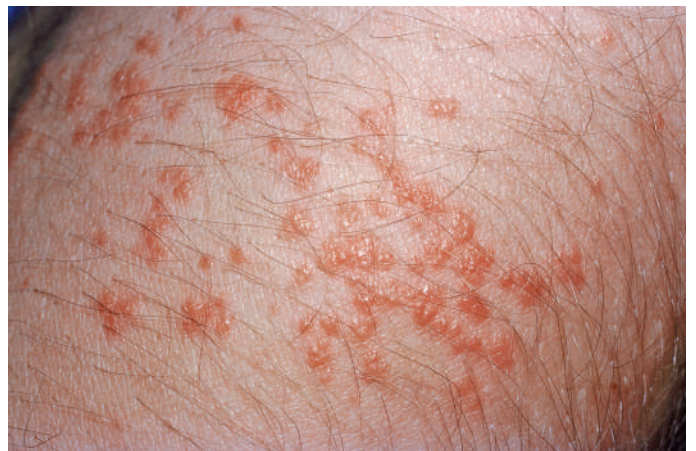“black dots” in the water or their bathing suits. The larvae of the sea anemone *Edwardstella lineata* caused one epidemic of seabather's eruption in Long Island, New York. This organism also has nematocysts; thus the mechanism of the eruption is the same as with the jellyfish-induced eruption. It is likely that different cnidarian envenomations in different waters produce a similar clinical picture. Other reports focus on spring plants, dinoflagellates, protozoans, or crustaceans as potential causes. Because the eruption results from trapping of cnidarian larvae with their nematocysts or other toxic or irritant substances under the bathing suit, it may be limited by seabathers who remove their suit and shower soon after leaving the water.

### Hydroid, sea anemone, and coral dermatitis

Patients contacting the small marine hydroid *Halecium* may develop a dermatitis. The organism grows as a 1-cm-thick coat of moss on the submerged portions of vessels or pilings. Sea anemones (Fig. 20-12) produce reactions similar to those from jellyfish and hydroids. Coral cuts are injuries caused by the exoskeleton of the corals *Milleporina* (Fig. 20-13). They have a reputation for becoming inflamed and infected and for delayed healing. The combination of implantation of fragments of coral skeleton and infection (since cuts occur most often on feet) probably accounts almost entirely for these symptoms. Detoxification as soon as possible after the injury is recommended for all these types of sting or cut.

### Treatment of stings and cuts

Hot water immersion may be an effective remedy for many stings, but scald injuries must be avoided. Undischarged nematocytes may be removed with sea water, but never with fresh water, because this may cause them to discharge. Pacific *Chironex* (box jellyfish) nematocytes should always be inactivated with 5% acetic acid (vinegar) when it is available, but Pacific *Physalia* (bluebottle) nematocytes may discharge on contact with vinegar. Large, visible tentacles may be removed with forceps in a double-gloved hand. Remaining nematocysts may be removed by applying a layer of shaving cream and



**Fig. 20-13** Coral cuts. (Courtesy of Dr. Curt Samlaska.)

shaving the area gently. Meat tenderizer may cause tissue damage and has been shown to be no better than placebo in some studies.

Pressure dressings and abrasion will worsen the envenomation. Topical anesthetics or steroids may be applied after decontamination. Systemic reactions may occur through either large amounts of venom or a previously sensitizing exposure from which anaphylaxis may result, and systemic treatment with epinephrine, antihistamines, or corticosteroids may be needed. Specific antivenin is available for the box jellyfish, *Chironex fleckeri*. This should be administered intravenously to limit myonecrosis. Magnesium sulfate ( $MgSO_4$ ) may also be of value in the setting of box jellyfish envenomation. Recurrent jellyfish reactions have shown partial responses to tacrolimus ointment 0.1%.

### Sponges and bristleworms

Sponges have horny spicules of silicon dioxide and calcium carbonate. Some sponges produce dermal irritants, such as halitoxin and okadaic acid, and others may be colonized by Cnidaria. Allergic or irritant reactions may result. Bristleworms may also produce stinging. All these may be treated by first using adhesive tape to remove the spicules, then applying vinegar soaks, as previously described, and lastly, topical corticosteroids.



## Sea urchin injuries

Puncture wounds inflicted by the brittle, fragile spines of sea urchins, mainly of genus *Diadema* or *Echinothrix*, are stained blue-black by the black spines and may contain fragments of the spines. The spines consist of calcium carbonate crystals, which most frequently induce an irritant reaction with pain and inflammation of several days' duration. Foreign body or sarcoidlike granulomas may develop, as may a vesicular hypersensitivity reaction, 10 days after exposure. Injuries by spines of the genus *Tripneustes* have been reported to cause fatal envenomation, but this genus is not found on U.S. coasts.

Starfish also have thorny spines that can sting and burn if they are stepped on or handled. Several different types of stinging fish also produce puncture wounds. Stingrays, scorpionfish, stonefish, catfish, and weaverfish may cause such envenomations.

These wounds should be immersed in nonscalding water (45°C [113°F]) for 30–90 min or until the pain subsides. Calcified fragments may be visible on x-ray evaluation, with fluoroscopy guiding extraction of spines, especially on the hands and feet. Sea urchin spines have been effectively removed using the erbium:yttrium-aluminum-garnet (YAG) laser. Debridement and possibly antibiotic therapy for deep puncture wounds of the hands and feet are recommended. There is a specific antivenin for stonefish stings.

## Seaweed dermatitis

Although caused by a marine alga and not by an animal, seaweed dermatitis deserves mention with other problems associated with swimming or wading. The dermatitis occurs 3–8 h after the individual emerges from the ocean. The distribution is in parts covered by a bathing suit: scrotum, penis, perineum, and perianal area. The dermatitis is caused by a marine plant, *Lyngbya majuscula* Gomont. It has been observed only in bathers swimming off the windward shore of Oahu, Hawaii. Seabather's eruption, clam digger's itch, and swimmer's itch must be differentiated from seaweed dermatitis caused by marine algae. Prophylaxis is achieved by refraining from swimming in waters that are turbid with such algae. Swimmers should shower within 5 min of swimming. Active treatment in severe cases is the same as for acute burns.

## Dogger Bank itch

Dogger Bank itch is an eczematous dermatitis caused by the sea chervil *Alcyonidium hirsutum*, a seaweedlike animal colony. These sea mosses or sea mats are found on the Dogger Bank, an immense shelflike elevation under the North Sea between Scotland and Denmark.

**Cegolon L, et al:** Jellyfish stings and their management: a review. *Mar Drugs* 2013; 11(2):523–550.

**Kabigting FD, et al:** Sea urchin granuloma secondary to *Strongylocentrotus purpuratus* and *Strongylocentrotus franciscanus*. *Dermatol Online J* 2009; 15(5):9.

**Oituso P:** Aquatic dermatology: encounters with the denizens of the deep (and not so deep): a review. Part I. The invertebrates. *Int J Dermatol* 2013; 52(2):136–152.

**Suput D:** Interactions of cnidarian toxins with the immune system. *Inflamm Allergy Drug Targets* 2011; 10(5):429–437.

## PHYLUM PLATYHELMINTHES

Phylum Platyhelminthes includes the flatworms, of which two classes, trematodes and cestodes, are parasitic to humans. The

trematodes, or blood flukes, parasitize human skin or internal organs. The cestodes are segmented, ribbon-shaped flatworms that inhabit the intestinal tract as adults and involve the subcutaneous tissue, heart, muscle, and eye in the larval form. This is encased in a sac that eventually becomes calcified.

## CLASS TREMATODA

### Schistosome cercarial dermatitis

Cercarial dermatitis is a severely pruritic, widespread, papular dermatitis caused by cercariae of schistosomes for which humans are not hosts; the usual animal hosts are waterfowl and rodents, such as muskrats. The eggs in the excreta of these animals, when deposited in water, hatch into swimming miracidia. These enter a snail, where further development occurs. From the snail, the free-swimming cercariae emerge to invade human skin on accidental contact. The swimming, colorless, multicellular organisms are slightly less than 1 mm long. Exposure to cercariae occurs when a person swims or, more often, wades in water containing them. They attack by burrowing into the skin, where they die. The species that causes this eruption cannot enter the bloodstream or deeper tissues.

After coming out of the water, the bather begins to itch, and a transient erythematous eruption appears, but after a few hours, the eruption subsides, together with the itching. After a quiescent period of 10–15 h, the symptoms then recur, and erythematous macules and papules develop throughout the exposed parts that were in the water (Fig. 20-14). After several days, the dermatitis heals spontaneously. There are two types: the freshwater swimmer's itch and the saltwater marine dermatitis, or clam digger's itch. Cercarial dermatitis is not communicable.

Various genera and species of organism have been reported from various locations worldwide. An outbreak of cercarial dermatitis was reported from Delaware in 1991 in which the avian schistosome *Microbilharzia variglandis* was implicated as the causative organism. *Schistosoma spindale* cercaria caused a recent epidemic in southern Thailand.

Thoroughly washing, then drying with a towel after exposure, can prevent the disease. Some advocate rubbing with alcohol as an additional preventive measure. Snail populations can be controlled, or waterfowl may be treated with medicated feedcorn to destroy the adult schistosomes and prevent outbreaks of swimmer's itch.

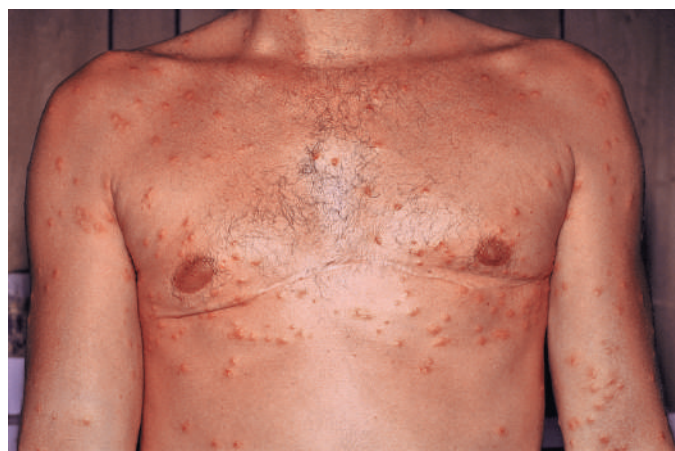

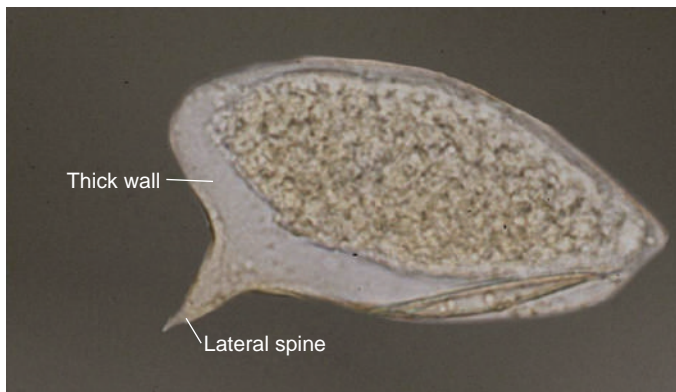
Fig. 20-14 Swimmer's itch.

## Visceral schistosomiasis (bilharziasis)

The cutaneous manifestation of schistosomiasis may begin with mild itching and a papular dermatitis of the feet and other parts after swimming in polluted streams containing cercariae. The types of schistosome causing this disease can penetrate into the bloodstream and eventually inhabit the venous system, draining the urinary bladder (*Schistosoma haematobium*) or the intestines (*Schistosoma mansoni* or *Schistosoma japonicum*). After an asymptomatic incubation period, the person may develop a sudden illness with fever and chills, pneumonitis, and eosinophilia. Petechial hemorrhages may occur.

Cutaneous schistosomal granulomas most frequently involve the genitalia, perineum, and buttocks. The eggs of *S. haematobium* or *S. mansoni* usually cause these bilharziomas (Fig. 20-15). Vegetating, soft, cauliflower-shaped masses, fistulous tracts, and extensive hard masses occur; these are riddled by sinuses that exude a seropurulent discharge with a characteristic odor. Phagedenic ulcerations and pseudoelephantiasis of the scrotum, penis, or labia are sometimes encountered. Histologically, the nodules contain bilharzial ova undergoing degeneration, with calcification and a surrounding cellular reaction of histiocytes, eosinophils, and occasional giant cells. In some cases, eventual malignant changes have been noted in chronic lesions. Animal studies have shown a moderate helper T-cell type 1 (Th1) response to parasite antigens in most tissues, but a strong Th2 response that propagates fibrogenesis within the liver. Infrequently, ectopic or extragenital lesions may occur, mainly on the trunk. This is a papular eruption tending to group in plaques and become darkly pigmented and scaly. A severe urticarial eruption known as urticarial fever or Katayama fever is frequently present along with *S. japonicum* infection; it occurs with the beginning of oviposition, 4–8 weeks after infection. This condition is seen mainly in China, Japan, and the Philippines. In addition to the urticaria, fever, malaise, abdominal cramps, arthritis, and liver/spleen involvement are seen. This is thought to be a serum sickness-like reaction.

Preventive measures include reducing infection sources, preventing contamination by human excreta of snail-bearing waters, control of snail hosts, and avoiding exposure to cercaria-infested waters. Prophylactic measures are constantly sought to control one of the world's worst parasitic diseases, but as yet, none has been found to be practical. For both *S. haematobium* and *S. mansoni*, praziquantel (Biltricide), 40 mg/kg orally for each of two treatments in 1 day, is the therapy of choice. *S. japonicum* treatment requires 60 mg/kg in three



**Fig. 20-15** Ova of *Schistosoma mansoni* are characterized by a thick chitinous wall and lateral spine.

doses in 1 day. Schistosomicides exhibit toxicity for the host as well as for the parasite, and the risk of undesirable side effects may be enhanced by concomitant cardiac, renal, or hepatosplenic disease.

**Lichtenbergová L, et al:** Pathogenicity of *Trichobilharzia* spp. for vertebrates. *J Parasitol Res* 2012; 2012:761968.

**Soldánová M, et al:** Swimmer's itch: etiology, impact, and risk factors in Europe. *Trends Parasitol* 2013; 29(2):65–74.

## Cysticercosis cutis

The natural intermediate host of the pork tapeworm, *Taenia solium*, is the pig, but under some circumstances, humans act in this role. The larval stage of *T. solium* is *Cysticercus cellulosae*. Infection takes place by the ingestion of food contaminated with the eggs or by reverse peristalsis of eggs or proglottides from the intestine to the stomach. Here the eggs hatch, freeing the oncospheres. These enter the general circulation and form cysts in various parts of the body, such as striated muscles, brain, eye, heart, and lung.

In the subcutaneous tissues, the lesions are usually painless nodules that contain cysticerci. They are more or less stationary, usually numerous, and often calcified and are therefore demonstrable radiographically. Pain and ulceration may accompany the lesions. The disease is most prevalent in countries where pigs feed on human feces. It may be confused with gumma, lipoma, and epithelioma. A positive diagnosis is established solely by incision and examination of the interior of the calcified tumor, where the parasite will be found. Fine-needle aspiration has also been used to establish the diagnosis.

Albendazole or praziquantel is effective; however, the status of the CNS, spinal, and ocular involvement needs to be thoroughly assessed before treatment. The length of therapy and use of concomitant corticosteroids depend on the location of the cysts. However, none of the regimens clears the calcified parasites, which need to be surgically removed.

**Sacchidanand S, et al:** Disseminated cutaneous cysticercosis and neurocysticercosis: a rare occurrence. *Indian Dermatol Online J* 2012; 3(2):135–137.

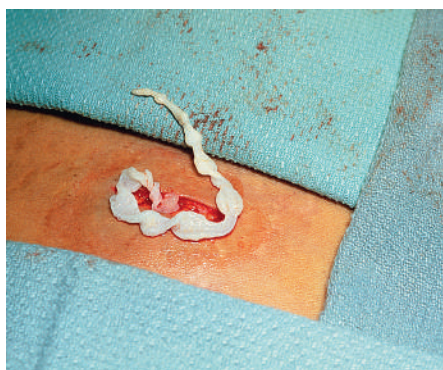
**Trung DD, et al:** Assessing the burden of human cysticercosis in Vietnam. *Trop Med Int Health* 2013; 18(3):352–356.

## Sparganosis

Sparganosis is caused by the larva of the tapeworm *Spirometra*. The adult tapeworm lives in the intestines of dogs and cats. This is a rare tissue infection occurring in two forms. Application sparganosis occurs when an ulcer or infected eye is poulticed with the flesh of an infected intermediate host (such poultices are frequently used in the Orient). The larvae become encased in small nodules in the infected tissue. Ingestion sparganosis occurs when humans ingest inadequately cooked meat, such as snake or frog, or when a person drinks water that is contaminated with *Cyclops*, which is infected with plerocercoid larvae. One or two slightly pruritic or painful nodules may form in the subcutaneous tissue or on the trunk, breast, genitalia, or extremities. Cerebral disease may also occur. Diagnosis is usually made by excision of the nodule, although noninvasive imaging has also been used.

Humans are the accidental intermediate host of the sparganum, which is the alternative name for the plerocercoid larva. Treatment is surgical removal or ethanol injection of the infected nodules (Fig. 20-16). This may be difficult because of the swelling and extensive vascularity.





**Fig. 20-16**  
Sparganosis.

**Anantaphruti MT, et al:** Human sparganosis in Thailand: an overview. *Acta Trop* 2011; 118(3):171–176.

**Koonmee S, et al:** Molecular identification of a causative parasite species using formalin-fixed paraffin embedded (FFPE) tissues of a complicated human pulmonary sparganosis case without decisive clinical diagnosis. *Parasitol Int* 2011; 60(4):460–464.

## Echinococcosis

Echinococcosis is also known as hydatid disease. In humans, infection is produced by the ova reaching the mouth from the hands, in food, or from containers soiled by ova-contaminated feces from an infected dog. This leads to *Echinococcus granulosus* infestation of the liver and the lungs. Soft, fluctuating, semitranslucent, cystic tumors may occur in the skin, sometimes in the supraumbilical area as fistulas from underlying liver involvement. These tumors become fibrotic or calcified after the death of the larva. Eosinophilia, intractable urticaria and pruritus, and even acute generalized exanthematous pustulosis may be present. Such reactive findings may be present as skin manifestations of many of the helminthic infections, including other types of tapeworm. The treatment is excision, with care being taken to avoid rupturing the cyst. Albendazole combined with percutaneous drainage may also be used. *Hymenolepis nana* is a cosmopolitan dwarf tapeworm endemic in the tropics that may cause a treatment-resistant pruritic papular eruption associated with eosinophilia. Stool specimens for ova and parasites are definitive, and praziquantel is curative.

**Islam MN, et al:** Hepatic hydatid cyst presenting as cutaneous abscess. *Mymensingh Med J* 2012; 21(1):165–169.

**Korwar V, et al:** Hydatid disease presenting as cutaneous fistula: review of a rare clinical presentation. *Int Surg* 2011; 96(1):69–73.

## PHYLUM ANNELIDA

### LEECHES

Leeches, of the class Hirudinea, are of marine, freshwater, or terrestrial types. After attaching to the skin, they secrete an anticoagulant, hirudin, and then engorge themselves with blood. Local symptoms at the site of the bite may include bullae, hemorrhage, pruritus, whealing, necrosis, or ulceration. Allergic reactions, including anaphylaxis, may result. Leeches may be removed by applying salt, alcohol, or vinegar or by use of a match flame. Bleeding may then be stopped by direct pressure or by applying a styptic pencil to the site.

Leeches may be used medicinally to salvage tissue flaps that are threatened by venous congestion. However, bleeding, *Aeromonas* infection, anetoderma, and pseudolymphoma may be complications of their attachment.

**Abdualkader AM, et al:** Leech therapeutic applications. *Indian J Pharm Sci* 2013; 75(2):127–137.

**Khelifa E, et al:** Cutaneous pseudolymphomas after leech therapy. *J Dermatol* 2013; 40(8):674–675.

## PHYLUM NEMATHELMINTHES

Phylum Nematelminthes includes the roundworms, both free-living and parasitic forms. Multiplication is usually outside the host. Both the larval and the adult stage may infect humans.

## CLASS NEMATODA

### Enterobiasis (pinworm infection, seatworm infection, oxyuriasis)

The chief symptom of pinworm infestation, which occurs most frequently in children, is nocturnal pruritus ani. There is intense itching accompanied by excoriations of the anus, perineum, and pubic area. The vagina may become infested with the gravid pinworms. A pruritic papular dermatosis of the trunk and extremities may be observed infrequently. Restlessness, insomnia, enuresis, and irritability are a few of the many symptoms ascribed to this exceedingly common infestation. Exacerbation of mastocytosis has been described.

Oxyuriasis is caused by the roundworm *Enterobius vermicularis*, which may infest the small intestines, cecum, and large intestine of humans. The worms, especially gravid ones, migrate toward the rectum and at night emerge to the perianal and perineal regions to deposit thousands of ova; then the worm dries and dies outside the intestine. These ova are then carried back to the mouth of the host on the hands. The larvae hatch in the duodenum and migrate into the jejunum and ileum, where they reach maturity. Fertilization occurs in the cecum, thus completing the life cycle.

Humans are the only known host of the pinworm, which probably has the widest distribution of all the helminths. Infection occurs from hand-to-mouth transmission, often from handling soiled clothes, bedsheets, and other household articles. Ova under the fingernails are a common source of autoinfection. Ova may also be airborne and collect in dust that may be on furniture and the floor. Investigation may show that all members of the family of an affected person also harbor the infection. It is common in orphanages and mental institutions and among people living in communal groups.

Rarely is it feasible to identify a dead pinworm in the stool. Diagnosis is best made by demonstration of ova in smears taken from the anal region early in the morning before the patient bathes or defecates. Such smears may be obtained with a small, eye curette and placed on a glass slide with a drop of saline solution. It is also possible to use cellophane tape, looping the tape sticky-side out over a tongue depressor and then pressing it several times against the perianal region. The tape is then smoothed out on a glass slide. A drop of a solution containing iodine in xylol may be placed on the slide before the tape is applied to facilitate detection of any ova. These tests should be repeated on 3 consecutive days to rule out infection. Ova may be detected under the fingernails of the infected person.

Albendazole, 400 mg, or mebendazole, 100 mg, or pyrantel pamoate, 11 mg/kg (maximum 1 g), given once and repeated in 2 weeks, is effective. Personal hygiene and cleanliness at home are important. Fingernails should be cut short and scrubbed frequently; nails should be thoroughly cleaned on

arising, before each meal, and after using the toilet. Sheets, underwear, towels, pajamas, and other clothing of the affected person should be laundered thoroughly and separately.

**Patrizi A, et al:** Cutaneous mastocytosis exacerbated by pinworms in a young boy. *Pediatr Dermatol* 2012; 29(2):229–230.

**Raghallaigh SN, et al:** *Enterobius vermicularis* dermatitis. *Clin Exp Dermatol* 2010; 35(3):e32–e33.

### Hookworm disease (ground itch, uncinariasis, ancylostomiasis, necatoriasis)

The earliest skin lesions (ground itch) are erythematous macules and papules, which in a few hours become vesicles. These itchy lesions usually occur on the soles, toe webs, and ankles; they may be scattered or in groups. The content of the vesicles rapidly becomes purulent. These lesions are produced by invasion of the skin by the *Ancylostoma* or *Necator* larvae, and they precede the generalized symptoms of hookworm disease by 2 or 3 months. The cutaneous lesions last less than 2 weeks before the larvae continue their human life cycle. There may be as high as 40% eosinophilia about the fifth day of infection.

The onset of the constitutional disease is insidious and is accompanied by progressive iron deficiency anemia and debility. During the course of hookworm disease, urticaria often occurs. The skin ultimately becomes dry and pale or yellowish.

Hookworm is a specific communicable disease caused by *Ancylostoma duodenale* or *Necator americanus*. In the soil, under propitious circumstances, hookworms attain the stage of infective larvae in 5–7 days. When they come into accidental contact with bare feet, these tiny larvae (which can scarcely be seen with a small pocket lens) penetrate the skin and reach the capillaries. They are carried in the circulation to the lungs, where they pass through the capillary walls into the bronchi. They move up the trachea to the pharynx and, after being swallowed, eventually reach their habitat in the small intestine. Here they bury their heads in the mucosa and begin their sexual life.

Hookworm is prevalent in most tropical and subtropical countries and is often endemic in swampy and sandy localities in temperate zones. In these latter regions, the larvae are killed off each winter, but the soil is again contaminated from human sources the following summer. *N. americanus* prevails in the Western Hemisphere, Central and South Africa, South Asia, Australia, and the Pacific islands.

The defecation habits of infected individuals in endemic areas are largely responsible for its widespread distribution, as is the use of human feces for fertilization in many parts of the world. In addition, the climate is usually such that people go barefoot because of the heat or because they cannot afford shoes. Infection is thereby facilitated, especially through the toes.

Finding the eggs in the feces of a suspected individual establishes the diagnosis. The ova appear in the feces about 5 weeks after the onset of infection. The eggs may be found in direct fecal films if the infection is heavy, but in light infections, it may be necessary to resort to zinc sulfate centrifugal flotation or other concentration methods. Mixed infections frequently occur.

Albendazole, 400 mg once, or mebendazole, 100 mg twice daily for 3 days or 500 mg once, or pyrantel pamoate, 11 mg/kg (maximum 1 g) each day for 3 days, is effective. Prophylaxis is largely a community problem and depends on preventing fecal contamination of the soil. This is best attained by proper sanitary disposal of feces, protecting individuals from exposure by educating them about sanitary procedures, and mass treatment through public health methods.

### Nematode dermatitis

A patient in one report developed a persistent widespread folliculitis caused by *Ancylostoma caninum*. It was apparently acquired by lying in grass contaminated by the droppings of the patient's pet dogs and cats. A biopsy revealed hookworm larvae within the hair follicle. Oral thiabendazole was curative.

### Creeping eruption (larva migrans)

Creeping eruption is a term applied to twisting, winding linear skin lesions produced by the burrowing of larvae. People who go barefoot on the beach, children playing in sandboxes, carpenters and plumbers working under homes, and gardeners are often victims. The most common areas involved are the feet, buttocks, genitals, and hands.

Slight local itching and the appearance of papules at the sites of infection characterize the onset. Intermittent stinging pain occurs, and thin, red, tortuous lines are formed in the skin. The larval migrations begin 4 days after inoculation and progress at the rate of about 2 cm/day. However, they may remain quiescent for several days or even months before beginning to migrate. The linear lesions are often interrupted by papules that mark the sites of resting larvae (Fig. 20-17). As the eruption advances, the old parts tend to fade, although purulent manifestations may be caused by secondary infection in some cases; erosions and excoriations caused by scratching frequently occur. If the progress of the disease is not interrupted by treatment, the larvae usually die in 2–8 weeks, with resolution of the eruption, although rarely it has been reported to persist for up to 1 year. At times, the larvae are removed from the skin by the fingernails in scratching. Eosinophilia may be present.

Loeffler syndrome, consisting of a patchy infiltrate of the lungs and eosinophilia as high as 50% in the blood and 90% in the sputum, may complicate creeping eruption.

The majority of U.S. cases of larva migrans occur along the southeast coast and are caused by penetration by the larvae of a cat and dog hookworm, *Ancylostoma braziliense*. It is acquired from body contact with damp sand or earth that has been contaminated by the excreta of dogs and cats. The larvae of *A. caninum*, which also infests the dog and the cat, rarely produce a similar dermatitis. The diagnosis is typically made clinically, although biopsy may sometimes demonstrate the organism, and even dermoscopy has been used.

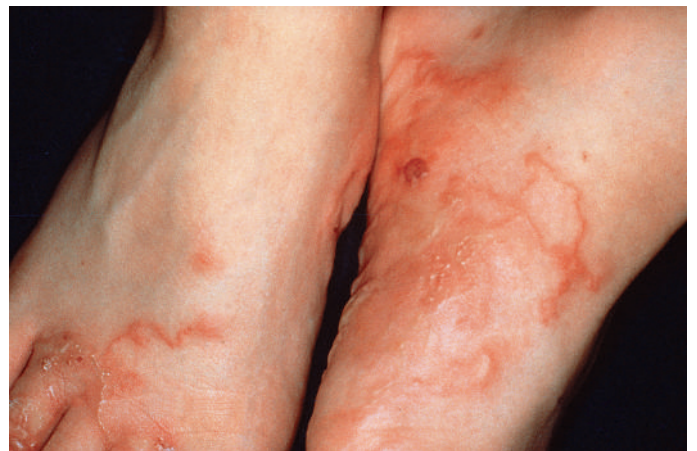

Fig. 20-17 Cutaneous larva migrans.



Ivermectin, 200 µg/kg, generally given as a single 12-mg dose and repeated the next day, or albendazole, 400 mg/day for 3 days, is an effective treatment. Criteria for successful therapy are relief of symptoms and cessation of tract extension, which usually occurs within 1 week. Topical thiabendazole, compounded as a 10% suspension or a 15% cream used four times daily, will result in marked relief from pruritus in 3 days, and the tracts become inactive in 1 week. Topical metronidazole has also been reported to be effective.

Another condition, not to be confused with this helminthic disease, which also is called creeping eruption (or sandworm, as it is known in South Africa, particularly in Natal and Zululand), is caused by a small mite about 300 µm long that tunnels into the superficial layers of the epidermis.

## Gnathostomiasis

Migratory, intermittent, erythematous, urticarial plaques characterize human gnathostomiasis. Each episode of painless swelling lasts from 7–10 days and recurs every 2–6 weeks. Movement of the underlying parasite may be as much as 1 cm/h. The total duration of the illness may be 10 years. Histopathologic examination of the skin swelling will demonstrate eosinophilic panniculitis. The clinical manifestation has been called larva migrans profundus.

The nematode *Gnathostoma dolorosi* or *G. spinigerum* is the cause; most cases occur in Asia or South America. Eating raw flesh from the second intermediate host, most often freshwater fish, in such preparations as sashimi and ceviche, allows humans to become the definitive host. Eating raw squid or snake is a less common exposure. As the larval cyst in the flesh is digested, it becomes motile and penetrates the gastric mucosa, usually within 24–48 h of ingestion. Symptoms then occur as migration of the parasite continues. Surgical removal is the treatment of choice, if the parasite can be located. This may be combined with albendazole, 400 mg/day or twice daily for 21 days, or ivermectin, 200 µg/kg/day for 2 days.

Creeping eruption caused by a recently recognized causative parasite of the nematode superfamily Spiruroidea has been reported in Japan. Eating raw squid was associated with the onset of long, narrow lesions that were pruritic, linear, and migratory. Surgical removal is the treatment of choice currently, as data on ivermectin are mixed.

## Larva currens

Intestinal infections with *Strongyloides stercoralis* may be associated with a perianal larva migrans syndrome called larva currens because of the rapidity of larval migration (currens means “running” or “racing”). Larva currens is an autoinfection caused by penetration of the perianal skin by infectious larvae as they are excreted in the feces. An urticarial band is the prominent primary lesion of cutaneous strongyloidiasis. Strongyloidiasis, as with the creeping eruption secondary to it, is often a chronic disease; infections may persist for more than 40 years. Approximately one third of patients infected are asymptomatic.

Signs and symptoms of systemic strongyloidiasis include abdominal pain, diarrhea, constipation, nausea, vomiting, pneumonitis, urticaria, eosinophilic folliculitis, and a peripheral eosinophilia. The skin lesions originate within 30 cm of the anus and characteristically extend as much as 10 cm/day.

Fatal cases of hyperinfection occur in immunocompromised patients; the parasite load increases dramatically and can produce a fulminant illness. Widespread petechiae and purpura are helpful diagnostic signs of disseminated infection,

and chronic urticaria is a possible presenting sign. Periumbilical ecchymoses may appear as if they were caused by a thumbprint.

Administration of ivermectin, 200 µg/kg/day for 2 days, or thiabendazole, 50 mg/kg/day in two doses (maximum 3 g/day) for 2 days, is the treatment of choice. Immunosuppressed hosts may be treated with thiabendazole, 25 mg/kg twice daily for 7–10 days.

Free-living strongyloides known as *Pelodera* can also produce a creeping eruption. In one reported case, widespread follicular, erythematous, dome-shaped papules and pustules appeared on the patient within 24 h of working under a house. This eruption persisted for 1 month before presentation. Scraping the lesions revealed live and dead larvae of the free-living soil nematode *Pelodera strongyloides*. Treatment with oral thiabendazole led to resolution.

**Laga AC, et al:** Cutaneous gnathostomiasis: report of 6 cases with emphasis on histopathological demonstration of the larva. *J Am Acad Dermatol* 2013; 68(2):301–305.

**Showler A, et al:** Strongyloidiasis presenting as larva currens 38 years after presumed exposure. *J Cutan Med Surg* 2012; 16(6):433–435.

**Upendra Y, et al:** Cutaneous larva migrans. *Indian J Dermatol Venereol Leprol* 2013; 79(3):418–419.

## Dracunculiasis (Guinea worm disease, dracontiasis, Medina worm)

Guinea worm disease is now limited to remote villages in several sub-Saharan African countries. It is caused by *Dracunculus medinensis* and is contracted through drinking water that has been contaminated with infected water fleas in which *Dracunculus* is parasitic. In the stomach, the larvae penetrate into the mesentery, where they mature sexually in 10 weeks. The female worm then burrows to the cutaneous surface to deposit her larvae and thus causes the specific skin manifestations. As the worm approaches the surface, it may be felt as a cordlike thickening and forms an indurated cutaneous papule. The papule may vesiculate, and a painful ulcer develops, usually on the leg. The worm is often visible. When the parasite comes in contact with water, the worm rapidly discharges its larvae, which are ingested by water fleas (*Cyclops*), contaminating the water.

The cutaneous lesion is usually on the lower leg, but it may occur on the genitalia, buttocks, or arms (Fig. 20-18). In addition to the ulcers on the skin, there may be urticaria, GI upset, eosinophilia, and fever.

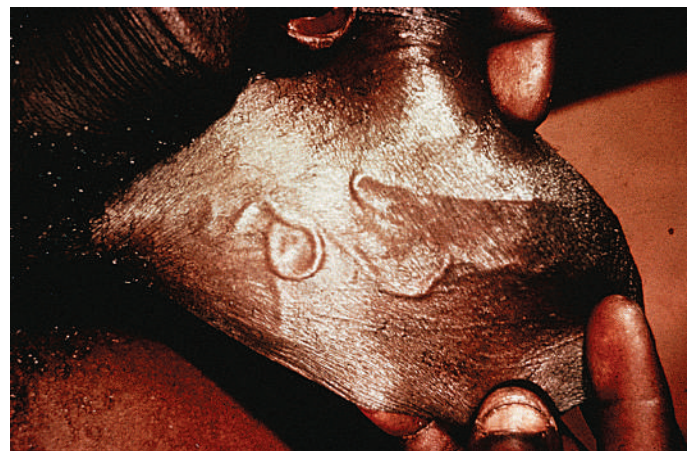

Fig. 20-18 Dracunculiasis.

Dracunculiasis may be prevented by boiling drinking water, providing safe drinking water through boreholes, or filtering the water through mesh fibers. Native treatment consists of gradually extracting the worm a little each day, taking care not to rupture it; otherwise, the larvae escape into the tissues and produce fulminating inflammation. Surgical removal is the treatment of choice. Metronidazole, 500 mg/day, resolves the local inflammation and permits easier removal of the worm. Immersion in warm water promotes emergence of the worm. Global eradication is within reach, and Guinea worm disease may become a historical footnote.

**Gulanikar A:** Dracunculiasis: two cases with rare presentations. *J Cutan Aesthet Surg* 2012; 5(4):281–283.

**Hopkins DR, et al:** Dracunculiasis eradication: and now, South Sudan. *Am J Trop Med Hyg* 2013; 89(1):5–10.

## Filariasis

### Elephantiasis tropica (elephantiasis arabum)

Filariasis is a widespread tropical disorder caused by infestation with filarial worms of *Wuchereria bancrofti*, *Brugia malayi*, or *Brugia timori* species. It is characterized by lymphedema, with resulting hypertrophy of the skin and subcutaneous tissues, and by enlargement and deformity of the affected parts, usually the legs, scrotum, or labia majora. The disease occurs more frequently in young men than women.

The onset of elephantiasis is characterized by recurrent attacks of acute lymphangitis in the affected part, associated with chills and fever (elephantoid fever) that last for several days to several weeks. These episodes recur over several months to years. After each attack, the swelling subsides only partially, and as recrudescences supervene, thickening and hypertrophy become increasingly pronounced. The overlying epidermis becomes stretched, thin, and shiny, and over years, leathery, insensitive, and verrucous or papillomatous from secondary pyogenic infection. The patient may have a dozen or more attacks in a year.

In addition to involvement of the legs and scrotum, the scalp, vulva, penis, female breasts, and arms can be affected, either alone or in association with the other regions. The manifestations vary according to the part involved. When the legs are attacked, both are usually affected somewhat symmetrically, with the principal changes occurring on the posterior aspects above the ankles and on the dorsa of the feet. At first, the thickening may be slight and associated with edema that pits on pressure. Later, the parts become massive and pachydermatous, the thickened integument hanging in apposing folds, between which there is a fetid exudate (Fig. 20-19).

When the scrotum is affected, it gradually reaches an enormous size, and the penis becomes hidden in it. The skin, which at first is glazed, is later coarse and verrucous, or in far-advanced cases, ulcerated or gangrenous. Resistant urticaria may occur. Filarial orchitis and hydrocele are common. A testicle may enlarge rapidly to the size of an apple and may be extremely painful. The swelling may subside within a few days, or the enlargement may be permanent. As a result of obstruction and dilation of the thoracic duct or some of its lower abdominal tributaries into the urinary tract, chyle appears in the urine, which assumes a milky appearance. Lobulated swellings of the inguinal and axillary glands, called varicose glands, are caused by obstructive varix and dilation of the lymphatic vessels.

Filaria are transmitted person to person by the bites of a variety of mosquitoes of the *Culex*, *Aedes*, and *Anopheles*

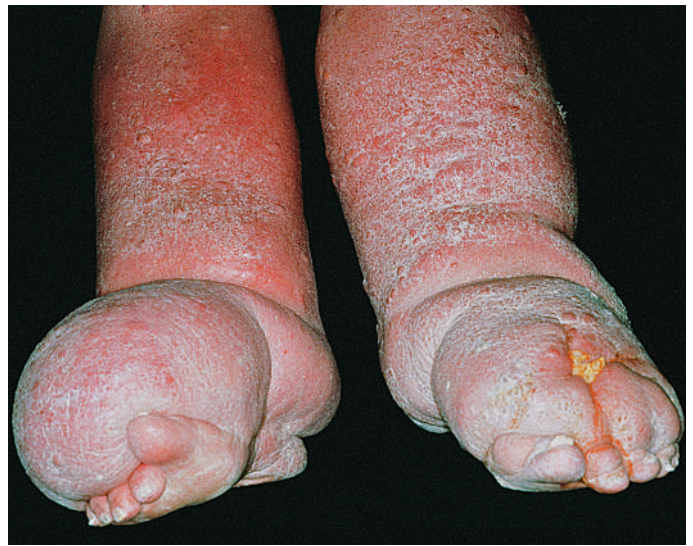

Fig. 20-19 Filarial elephantiasis.

species. The adult worms are threadlike, cylindrical, and creamy white. The females are 4–10 cm long. Microfilarial embryos may be seen as coiled, each in its own membrane near the posterior tip. Fully grown, sheathed microfilariae are 130–320  $\mu\text{m}$  long. The adult worms live in the lymphatic system, where they produce microfilariae. These either remain in the lymphatic vessels or enter the peripheral bloodstream. An intermediate host is necessary for the further development of the parasite.

It is important to realize that infestation by the filaria is often asymptomatic, and elephantiasis usually occurs only if hundreds of thousands of mosquito bites occur over a period of years, with episodes of intercurrent streptococcal lymphangitis. Filariasis was endemic in the considerable Samoan population of Hawaii for half a century, and only one case of elephantiasis has occurred among this group.

The microfilariae should be sought on fresh coverslip films of blood (collected at night), urine, or other body fluid and examined with a low-power objective lens. Calcified adult worms may be demonstrated on x-ray examination, and ultrasound can detect adult worms. At times, adult filariae are found in abscesses or in material taken for pathologic examination. Specific serologic tests and a simple card test for filarial antigen are available. The prognosis in regard to survival is good, but living becomes burdensome unless the condition is alleviated.

Diethylcarbamazine, in increasing doses over a 14-day period, is the treatment of choice. This regimen clears microfilariae but not adult worms. A single dose of ivermectin may also be effective. Doxycycline kills the intracellular symbiotic bacteria, *Wolbachia*. This leads to long-term sterility of adult female worms. Doxycycline is being studied to determine its place in the treatment of both bancroftian filariasis and onchocerciasis. A worldwide effort to eliminate these diseases is underway. Surgical procedures have been devised to remove the edematous subcutaneous tissue from the scrotum and breast. Prophylactic measures consist of appropriate mosquito control. Diethylcarbamazine has been effective in mass prophylaxis. If a trip of over 1 month to areas with endemic *Wuchereria bancrofti* is planned and extensive exposure to mosquitoes is likely, taking diethylcarbamazine, 500 mg/day for 2 days each month, is recommended.

**Nutman TB:** Insights into the pathogenesis of disease in human lymphatic filariasis. *Lymphat Res Biol* 2013; 11(3):144–148.



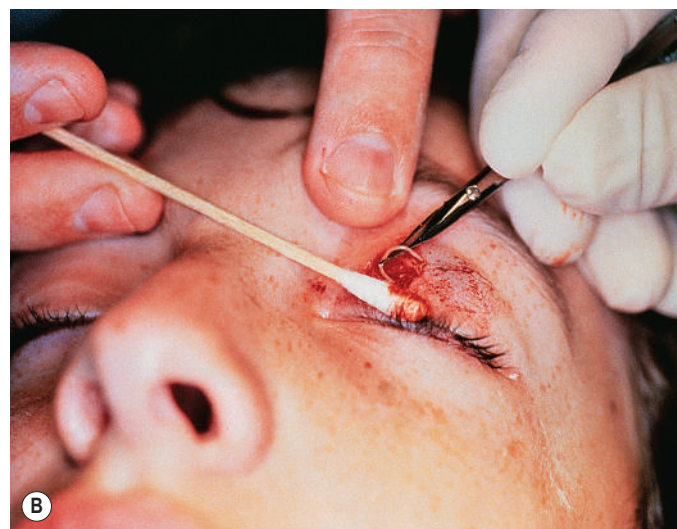
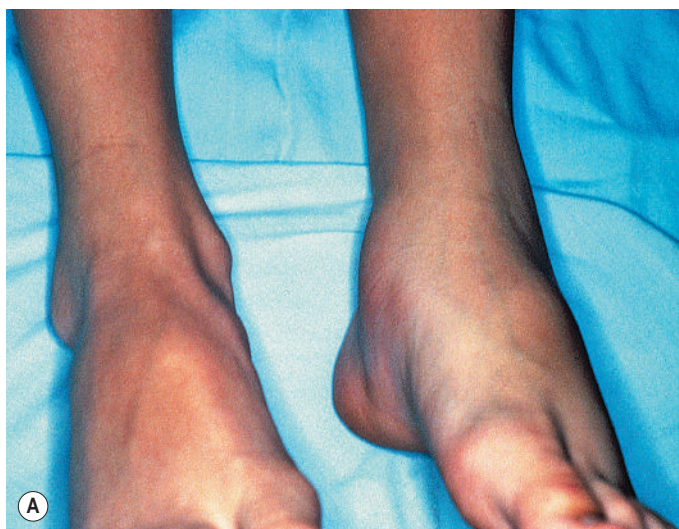
Fig. 20-20 A and B, Loiasis. (Courtesy of Curt Samlaska, MD.)

### Loiasis (Loa loa, Calabar swelling, tropical swelling, fugitive swelling)

Infection with *Loa loa* is often asymptomatic. In infected persons, the parasite develops slowly, and even 3 years can elapse between infection and appearance of symptoms, although the usual interval is 1 year. The first sign is often painful, localized, subcutaneous, nonpitting edema called Calabar or fugitive swelling (Fig. 20-20, A). One or more, slightly inflamed, edematous, transient swellings occur, usually about the size of a hen's egg. They typically last a few days and then subside, although recurrent swellings at the same site may eventually lead to a permanent, cystlike protuberance. These swellings may result from hypersensitivity to the adult worm or to materials elaborated by it. Eosinophilia may be as high as 90% and often is 60–80%.

The filariae may be noticed subcutaneously in the fingers, breasts, eyelids, or submucosally under the conjunctivae. The worm may be in the anterior chamber of the eye, the myocardium, or other sites. It has a predilection for loose tissues such as the eye region, the frenum of the tongue, and the genitalia. The wanderings of the adult parasite may be noticed because of a tingling and creeping sensation. The death of the filaria in the skin may lead to the formation of fluctuant cystic lesions.

Loiasis is widely distributed in West and Central Africa, where it is transmitted by the mango fly, *Chrysops dimidia* or *Chrysops silacea*. This fly bites only in the daytime. Humans are the only important reservoir for the parasite. The observation of the worm under the conjunctiva, Calabar swellings, eosinophilia, and microfilariae in peripheral blood establish the diagnosis. Demonstration of the characteristic microfilariae in the blood during the day is possible in only about 20% of patients. Specific serologic tests are available, and luciferase immunoprecipitation systems can provide rapid diagnostic results, with improved sensitivity and specificity compared with enzyme-linked immunosorbent assay (ELISA).

Removal of the adult parasite whenever it comes to the surface of the skin is mandatory (Fig. 20-20, B). This must be done quickly by seizing the worm with forceps and placing a suture under it before cutting down to it. Worms that are not securely and rapidly grasped may escape into the deeper tissues.

Diethylcarbamazine kills both adults and microfilariae and is given in increasing doses for 21 days. In regions where onchocerciasis and loiasis both are endemic, and where

ivermectin is used in a community-based elimination strategy for onchocerciasis, simultaneously infected patients with a high *L. loa* load have a greater risk of serious side effects. If ivermectin treatment of these patients is undertaken, proper monitoring and appropriate supportive treatment should be available in anticipation of this risk. Diethylcarbamazine is an effective chemopreventive therapy, using 300 mg/week in temporary residents of regions of Africa where *L. loa* is endemic.

**Boussinesq M:** Loiasis: new epidemiologic insights and proposed treatment strategy. *J Travel Med* 2012; 19(3):140–143.

**Gantois N, et al:** Imported loiasis in France: a retrospective analysis of 47 cases. *Travel Med Infect Dis* 2013; 11(6):366–373.

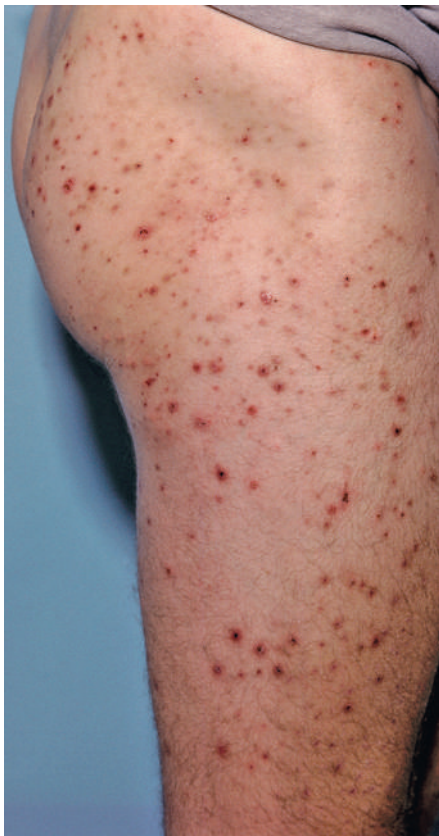### Onchocerciasis

The skin lesions of onchocerciasis are characterized by pruritus, dermatitis, and onchocercomas. The dermatitis is variable in appearance, probably related to chronicity of infection, age of the patient, geographic area where acquired, and relative immune responsiveness. Early in the course of the infection, an itchy papular dermatitis may occur, and in visitors who become infected, this may be localized to one extremity (Fig. 20-21). In Central America, papules may appear only on the head and neck area. This unusual localization of insect bite-appearing papules with excoriations may lead to the diagnosis in travelers returning to their home countries. In Central America, another manifestation of the acute phase of onchocerciasis is acute swelling of the face with erythema and itching, known as erisipela de la costa. In Zaire and Central America, an acute urticarial eruption is seen. The inflammation, which is accompanied by hyperpigmentation, is known as mal morado.

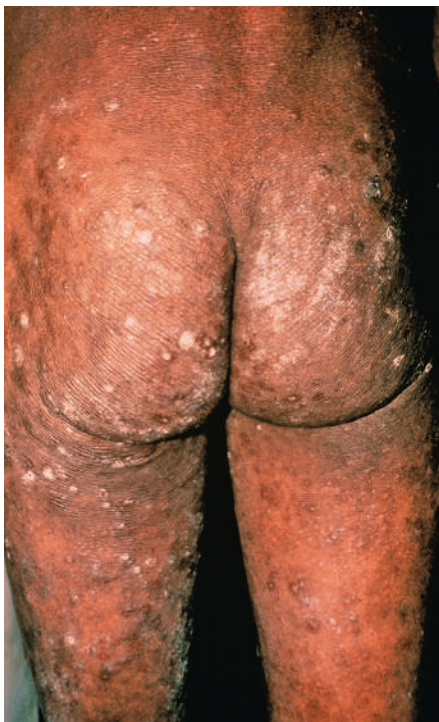As time passes, the dermatitis becomes chronic and remains papular; however, thickening, lichenification, and depigmentation occur (Fig. 20-22). Later, atrophy may supervene. When the depigmentation is spotted, it is known as leopard skin; when the skin is thickened, it is called elephant skin. When local edema and thickened, wrinkled, dry dermatitic changes predominate, it is sometimes called lizard skin.

In Saudi Arabia, Yemen, and East Africa, a localized type of onchocerciasis exists called sowda, Arabic for “black.” It is characterized by localized, pruritic, asymmetric, usually darkly pigmented, chronic lichenified dermatitis of one leg or one body region. It is also known as the chronic hyperreactive

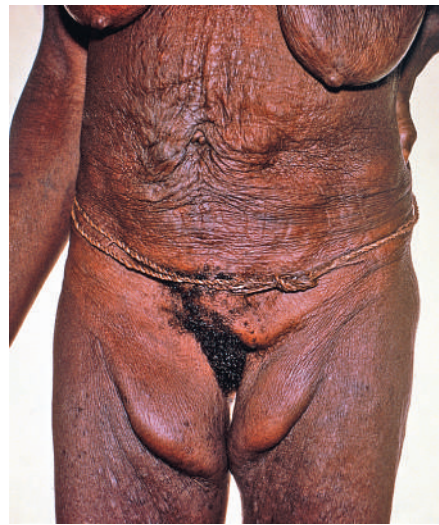



**Fig. 20-21** Early onchocerciasis.



**Fig. 20-22**  
Onchocerciasis.  
(Courtesy of Debra Kalter, MD.)



**Fig. 20-23**  
Onchocerciasis.

type, and an association with antidefensin antibodies suggests a reason for this enhanced reactivity against the parasite.

After a time, firm subcutaneous nodules, pea-sized or larger, develop on various sites of the body. These nodules are onchocercomas containing myriad microfilariae. These occur in crops, are frequently painful, and their site varies. In parts of Africa, where natives are wholly or nearly unclothed, the lesions occur on the trunk, axillae, groin, and perineum. In

Central and South America, the head, especially the scalp, is the usual site of involvement. Firm, nontender lymphadenopathy is a common finding in patients with chronically infected onchocerciasis. "Hanging groin" describes the loose, atrophic skin sack that contains these large inguinal nodes (Fig. 20-23). In about 5% of affected persons, serious eye lesions arise late in the disease, gradually leading to blindness.

Onchocerciasis is caused by *Onchocerca volvulus*, which is transmitted to humans by the bite of the black fly of the genus *Simulium*. It breeds in fast-flowing streams. When the black fly bites, it introduces larvae into the wound. The larvae reach adulthood in the subdermal connective tissue in about 1 year. Millions of the progeny then migrate back into the dermis and the aqueous humor of the eye.

Onchocerciasis occurs in Africa on the west coast, in the Sahara, Sudan, and the Victoria Nile division, where it is known as river blindness. In Central and South America, this disease can be found in Guatemala, Brazil, Venezuela, and southern Mexico.

The presence of eosinophilia, skin lesions, and onchocercomas with ocular lesions is highly suggestive in endemic areas. Frequently, the microfilariae may be found in skin shavings or dermal lymph, even when no nodules are detectable. The scapular area is the favorite site for procuring specimens for examination by means of a skin snip. This is performed in the field or office by lifting the skin with an inserted needle and then clipping off a small, superficial portion of the skin with a sharp knife or scissors. The specimen is laid in a drop of normal saline solution on a slide with a coverslip and examined under the microscope. The filariae wriggle out at the edges of the skin slice.

Specific serologic and PCR-based diagnostic tests from blood and skin biopsies are available. Other filarial parasites can be detected in similar systems. When patients with suspected onchocerciasis were given a single oral dose of 50 mg of diethylcarbamazine, a reaction consisting of edema, itching, fever, arthralgias, and exacerbation of pruritus was described as a positive Mazzotti test reaction, which supported the diagnosis of onchocerciasis.

Onchocercomas may be surgically excised whenever feasible. Ivermectin as a single oral dose of 150 µg/kg is the drug of choice. Skin microfilaria counts remain low at the end of 6 months' observation. Ivermectin should be repeated every 6 months to suppress the dermal and ocular microfilarial counts. More frequent dosing does not appear to reduce microfilarial counts further.

Doxycycline kills the intracellular symbiotic bacteria, *Wolbachia*, that appear to cause Mazzotti reactions and is being



tested for long-term effects and determination of its place in the treatment of onchocerciasis and bancroftian filariasis. If there is eye involvement, prednisone, 1 mg/kg, should be started several days before treatment with ivermectin. Moxidectin and emodepside also appear promising as alternative drugs. Community-based treatment protocols have the objective of eliminating onchocerciasis from endemic areas. Severe reactions may occur in patients simultaneously infected with *Loa loa*.

**Barry MA, et al:** Global trends in neglected tropical disease control and elimination: impact on child health. *Arch Dis Child* 2013; 98(8):635–641.

**Salam RA, et al:** Community-based interventions for the prevention and control of helminthic neglected tropical diseases. *Infect Dis Poverty* 2014; 31:23.

## Trichinosis

Ingestion of *Trichinella spiralis* larva-containing cysts in inadequately cooked pork, bear, or walrus meat may cause trichinosis. It usually causes a puffy edema of the eyelids, redness of the conjunctivae, and sometimes urticaria or angioedema associated with hyperpyrexia, headache, erythema, GI symptoms, muscle pains, and neurologic signs and symptoms. Ten percent of patients develop a bilateral, asymptomatic hand swelling that is especially prominent over the digits, as well as erythema along the perimeters of the palms and volar surfaces of the digits, which progresses to desquamation. In 20% of cases, a nonspecific macular or petechial eruption occurs, and splinter hemorrhages are occasionally present. Eosinophilia is not constant but may be as high as 80%. In the average patient, eosinophilia begins about 1 week after infection and attains its height by the fourth week.

The immunofluorescence antibody test has the greatest value in establishing early diagnosis. The bentonite flocculation test, ELISA, and other serologic tests are limited by their inability to detect infection until the third or fourth week. Diagnosis is confirmed by a muscle biopsy that demonstrates larvae of *T. spiralis* in striated muscle. Unfortunately, trichinae cannot usually be demonstrated unless eosinophilic vasculitis and granulomas have been described on biopsy. A 2-mm-thick slice of the muscle biopsy may be compressed between two glass slides to demonstrate the cysts.

Trichinosis is treated with albendazole, 400 mg twice daily for 14 days. Corticosteroid agents are effective in controlling the often severe symptoms and should be given at doses of 40–60 mg/day.

**Knopp S, et al:** Nematode infections: soil-transmitted helminths and trichinella. *Infect Dis Clin North Am* 2012; 26(2):341–358.

## PNEUMOCYSTOSIS

*Pneumocystis jirovecii* (formerly *P. carinii*) has features characteristic of both protozoa and fungi. It is an opportunistic infection, occurring primarily as a pulmonary infection in AIDS patients. Extrapulmonary involvement is uncommon and usually occurs in the reticuloendothelial system. Skin findings may occur. At least half of reported cases are of nodular growths in the auditory canal, with the remainder having nonspecific, pink to skin-colored papules and nodules that may ulcerate. On biopsy, the dermis contains foamy material within which Giemsa-positive organisms are identified. Mixed cutaneous infection with *Cryptococcus* has been reported; the skin lesions appeared xanthomatous. Cutaneous botryomycosis

caused by combined *Staphylococcus aureus* and *P. jirovecii* has been reported in patients with human immunodeficiency virus (HIV) infection. A 3-week course of trimethoprim-sulfamethoxazole is the treatment of choice. In combined infections, all pathogens require treatment. Dapsone prophylaxis has been associated with acute generalized exanthematous pustulosis.

**Peña ZG, et al:** Mixed *Pneumocystis* and *Cryptococcus* cutaneous infection histologically mimicking xanthoma. *Am J Dermatopathol* 2013; 35(1):e6–e10.

**Vas A, et al:** Acute generalised exanthematous pustulosis induced by *Pneumocystis jirovecii* pneumonia prophylaxis with dapsone. *Int J STD AIDS* 2013; 24(9):745–747.

## PHYLUM ARTHROPODA

Phylum Arthropoda contains more species than all the other phyla combined. The classes of dermatologic significance are Myriapoda, Insecta, and Arachnida. Mosquitoes, flies, ticks, and fleas transmit diseases throughout the world. Although always prevalent, bites and stings increase dramatically after natural disasters such as hurricanes and flooding.

### Prevention of arthropod-related disease

Mosquitoes remain the most important vectors of arthropod-borne disease, and mosquito control programs are an essential component of the public health efforts of many U.S. states. Insect repellents are effective in preventing disease transmission and are especially important during travel to areas where vector-borne disease is endemic. Most are based on DEET (*N,N*-diethyl-3-methylbenzamide, previously called *N,N*-diethyl-*m*-toluamide). DEET has been tested against a wide range of arthropods, including mosquitoes, sandflies, ticks, and chiggers. The American Academy of Pediatrics recommends concentrations of 30% or less in products intended for use in children. Some evidence suggests that children do not have a higher incidence of adverse reactions than adults, but even in adults, neurotoxicity has been occasionally reported. High concentrations of DEET can produce erythema and irritation or bullous eruptions. Extended-release products reduce the need for repeated application and appear to minimize the risk of complications. Overall, DEET has a good safety record in widespread use. Picaridin (KBR 3023) is a piperidine-derived repellent ingredient that is also effective against a range of arthropods. Some studies have shown that picaridin is less irritating than DEET while providing comparable efficacy. The best studies for the evaluation of repellents are field trials that involve a range of arthropods. “Arm box” studies are still performed but must be interpreted with caution.

Citronella candles have little documented efficacy, but neem oil is an effective mosquito repellent used in many areas of the world that are endemic for malaria. Geraniol candles show some efficacy, but only in the area immediately surrounding the candles. Repellency decreases significantly at a distance of even 2 m. Candles with geraniol are twice as effective as those with linalool and five times as effective as those with citronella. IR3535 (ethyl-butyl-acetyl aminopropionate) in a variety of formulations has also demonstrated good efficacy against mosquitoes, with complete protection in field trials of 7.1–10.3 h.

Travelers to malaria-endemic areas should follow CDC guidelines for malaria prophylaxis. They should also avoid nighttime outdoor exposure and use protective measures such as repellents and bed netting. The anopheline mosquitoes that carry malaria tend to bite at night, so bed nets and screens are

important measures. Mosquitoes that carry dengue mostly bite during the day. Repellents play a greater role in protection against dengue, because it is more difficult to limit daytime outdoor activity. Mosquito control programs depend largely on drainage of stagnant water and spraying of breeding areas. In developing countries, water barrels may be stocked with fish or turtles to consume mosquito larvae. Both can soil the water, however, and the relative risks must be evaluated; some studies clearly show the risk favors stocking the barrel. Mosquito traps (e.g., Mosquito Magnet) have been effective for the control of mosquitoes in limited areas. Generally, mosquitoes fly upwind to bite and downwind to return to their resting area. Mosquito traps must be positioned between the breeding and resting areas and the area to be protected. Mosquito traps commonly use carbon dioxide (CO<sub>2</sub>), heat, and chemical attractants. Some *Culex* mosquitoes are repelled by octenol, and the manufacturer may provide guidelines for areas where the attractant should not be used.

### Prevention of disease from ticks and chiggers

Tick-borne diseases include rickettsial fevers, ehrlichiosis, Lyme disease, babesiosis, relapsing fever, and tularemia. Most require a sustained tick attachment of more than 24 h for effective transmission, and frequent tick checks with prompt removal of ticks is an important strategy for the prevention of tick-borne illness. Unfortunately, tick inspections frequently fail to identify the tick in time for prompt removal. Some data suggest that adult ticks are found and removed only 60% of the time within 36 h of attachment. Nymphal ticks are even more difficult to detect and may be removed in as few as 10% of patients within the first 24 h. Because of this, repellents and acaricides remain critical for preventing tick-borne illness.

Permethrin has killing activity against a wide range of arthropods. Some North African *Hyalomma* ticks are resistant to permethrin and may exhibit a paradoxical pheromonelike attachment response when exposed to the agent, but permethrin performs very well with other species of tick, as well as mosquitoes and chiggers. It can be used to treat clothing, sleeping bags, mosquito netting, and tents. Permethrin-treated clothing, used in conjunction with a repellent, provides exceptional protection against bites in most areas of the world. Permethrin has a good record of safety, although there is a report of congenital leukemia with 11q23/*MLL* rearrangement in a preterm female infant whose mother had abused permethrin because of a pathologic fear of spiders. Permethrin can induce cleavage of the *MLL* gene in cell culture, providing a plausible link between the agent and the leukemia. It should be emphasized that permethrin in this case was not used according to the manufacturer's instructions, and the theoretic risk of carcinogenicity should be weighed against the very real risk of death from arthropod-borne disease. Cardiac glycosides have also been used topically as acaricides and have performed well in limited studies.

*Ixodes scapularis* is the major North American vector for Lyme disease, human granulocytic ehrlichiosis, and human babesiosis. A Lyme vaccine marketed in the United States was a commercial failure and withdrawn. Prevention of Lyme disease now centers on prevention of tick attachments and prompt tick removal. Backyards and recreational areas adjacent to wooded areas have higher rates of tick infestation. Tick numbers can be reduced by deer fencing, removal of leaf debris, application of an acaricide, and creation of border beds with wood chip mulch or gravel. Bait boxes and deer feeding stations can deliver a topical acaricide while the animal feeds. Parasitic wasps control tick numbers in nature, but wasp populations may fluctuate, and investment in wasp control may

be a risky venture compared with other forms of tick control. Other natural forms of tick control have been investigated because of their potential to become self-sustaining in the environment, at least for a time; fungi and nematodes show some promise. In southern U.S. states, fire ants control tick populations by eating tick eggs.

### Prevention of flea-borne illness

Fleas are important vectors of plague and endemic typhus. They may also be vectors of cat-scratch disease. Lufenuron is a maturation inhibitor that prevents fleas from breeding. It is often used in oral and injectable forms for the prevention of flea infestation in cats and dogs. Fipronil is used topically for the prevention of flea and tick infestation. Other agents in use include imidacloprid, selamectin, and nitenpyram. House sprays often include pyrethroids or pyriproxyfen. Powdered boric acid may be helpful for the treatment of infested carpets or floor boards. A knowledgeable veterinarian and an exterminator should be consulted.

**Moro ML, et al:** Knowledge, attitudes and practices survey after an outbreak of chikungunya infections. *Int Health* 2010; 2(3):223–227.

**Rappo TB, et al:** Tick bite anaphylaxis: incidence and management in an Australian emergency department. *Emerg Med Australas* 2013; 25(4):297–301

### CLASS MYRIAPODA

Morphologically and genetically, the class Myriapoda is distinct from other groups of arthropod. This group contains the centipedes and millipedes, both capable of producing significant skin manifestations.

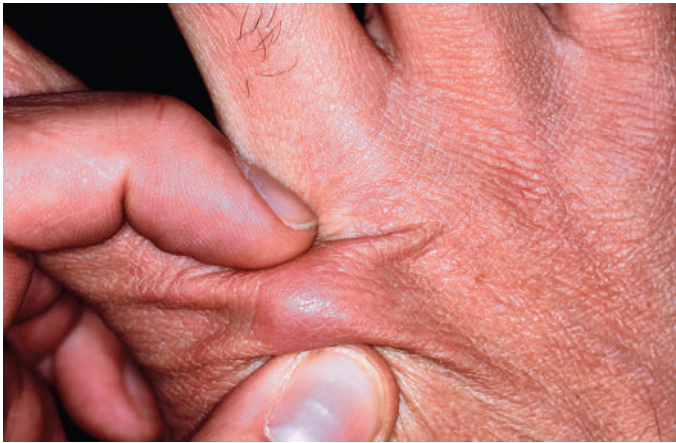### Centipede bites (Chilopoda)

Centipede bites are manifested by paired hemorrhagic marks that form a chevron shape caused by the large, paired mouthparts (Fig. 20-24). The bite is surrounded by an erythematous swelling (Fig. 20-25) that may progress into a brawny edema



Fig. 20-24 Centipede.





**Fig. 20-25** Centipede bite.

or lymphangitis. Locally, there may be intense itching and pain, often associated with toxic constitutional symptoms. Most centipede bites run a benign, self-limited course, and treatment is only supportive. Children are often bitten when they try to handle centipedes. Some species of *Scolopendra* in the western United States will attain a length of 15–20 cm, and the child may describe it as a snake. Recognition of the characteristic chevron shape is important to avoid inappropriate treatment with snake antivenin. In the eastern United States, the common house centipede, *Scutigera coleoptrata*, does not bite humans. *Scolopendra subspinipes*, in Hawaii, inflicts a painful bite. As exotic species appear more often at pet stores and swap meets, envenomation by them will become more common.

In some tropical and subtropical areas, centipede bites account for about 17% of all envenomations, compared with 45% caused by snakes and 20% by scorpions. Most bites occur at home and involve an upper extremity. Local pain and edema occur in up to 96% of patients, depending on the species involved. Treatment is largely symptomatic. Rest, ice, and elevation may be sufficient, but topical or intralesional anesthetics may be required in some cases. Tetanus immunization should be considered if the patient has not been immunized within the past 10 years. Centipede bites can result in Wells syndrome, requiring topical or intralesional corticosteroids. Rarely, bites may produce more serious toxic responses, including rhabdomyolysis, myocardial ischemia, proteinuria, and acute renal failure. These have been reported following the bite of *Scolopendra heros*, the giant desert centipede. Although centipedes have sometimes been found in association with corpses, injuries from the centipede tend to be post-mortem and are rarely the cause of death. Ingestion of centipedes by children is usually associated with transient, self-limited toxic manifestations.

**Fung HT, et al:** Centipede bite victims: a review of patients presenting to two emergency departments in Hong Kong. *Hong Kong Med J* 2011; 17(5):381–385.

**Guerrero AP:** Centipede bites in Hawaii: a brief case report and review of the literature. *Hawaii Med J* 2007; 66(5):125–127.

**Yildiz A, et al:** Acute myocardial infarction in a young man caused by centipede sting. *Emerg Med J* 2006; 23(4):e30.

### Millipede burns (Diplopoda)

Some millipedes secrete a toxic liquid that causes a brownish pigmentation or burn when it comes into contact with skin. Burns may progress to intense erythema and vesiculation. Millipedes may be found in laundry hung out to dry, and



**Fig. 20-26** Millipede.

millipede burns in children have been misinterpreted as signs of child abuse. Recognition of the characteristic curved shape of the burn can be helpful in preventing misdiagnosis. Some millipedes can squirt their venom, and ocular burns are reported. Washing off the toxin as soon as possible will limit the toxic effects. Other treatment is largely symptomatic.

Diplopods have evolved a complex array of chemicals for self-defense (Fig. 20-26). Some primates take advantage of these chemicals. Two millipede compounds, 2-methyl-1,4-benzoquinone and 2-methoxy-3-methyl-1,4-benzoquinone, demonstrate a repellent effect against *Aedes aegypti* mosquitoes. Tufted and white-faced capuchin monkeys anoint themselves with the secretions to ward off mosquitoes. Effective commercial repellents are available for human use; millipede juice is not recommended.

**Dar NR, et al:** Millipede burn at an unusual site mimicking child abuse in an 8-year-old girl. *Clin Pediatr (Phila)* 2008; 47(5):490–492.

**Hendrickson RG:** Millipede exposure. *Clin Toxicol (Phila)* 2005; 43(3):211–212.

## CLASS INSECTA

### Order Lepidoptera

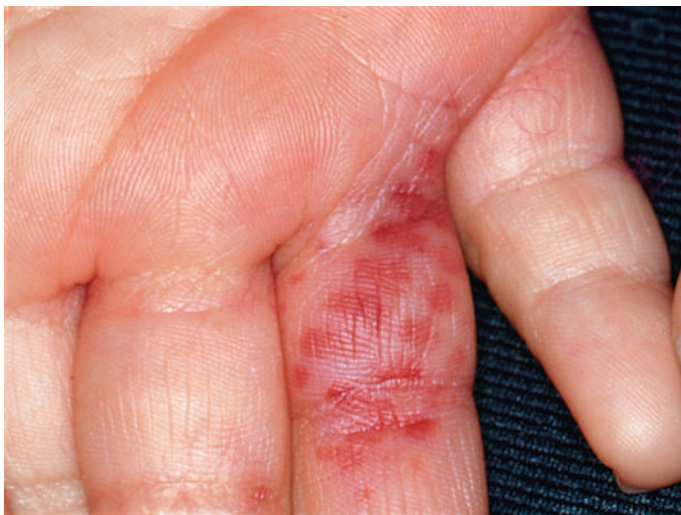Order Lepidoptera includes butterflies, moths, and their larval forms, caterpillars. Severe systemic reactions have resulted from ingestion of some caterpillars, and with some species, the sting alone can produce severe toxicity. *Lonomia achelous*, found in Latin America, can cause a fatal bleeding diathesis. The Spanish pine caterpillar, *Thaumetopoea pityocampa*, causes both dermatitis and anaphylactoid symptoms. Pine caterpillars are also an important cause of systemic reactions in China and Israel. The tussock moth, *Orgyia pseudotsugata*, causes respiratory symptoms in forestry workers in Oregon.

### Caterpillar dermatitis

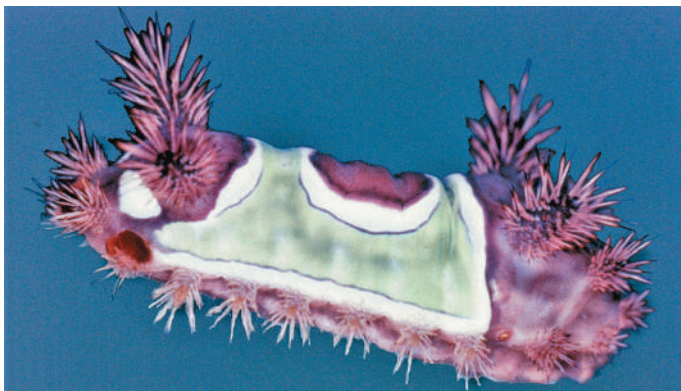
Irritation is produced by contact of caterpillar hairs with the skin. Toxins in the hairs can produce severe pain, local pruritic erythematous macules, and wheals, depending on the species. If the hairs embed in the clothing, widespread persistent dermatitis may result. Not only the caterpillars, but also their egg covers and cocoons usually contain stinging hairs. In the United States, the most common caterpillars of medical importance are the brown-tail moth caterpillar (*Nygmia phoeorrhoea*), puss caterpillar (*Megalopyge opercularis*) (Figs. 20-27 and 20-28), saddleback caterpillar (*Sibine stimulate*; Fig. 20-29), io moth caterpillar (*Automeris io*), crinkled



**Fig. 20-27** Puss caterpillar.



**Fig. 20-28** Characteristic "railroad track" purpura of a puss caterpillar sting.



**Fig. 20-29** Saddleback caterpillar.

flannel moth caterpillar (*Megalopyge crispata*), Oklahoma puss caterpillar (*Lagoa crispata*), Douglas fir tussock moth caterpillar (*Orgyia pseudotsugata*), buck moth caterpillar (*Hemileuca maia*), and flannel moth caterpillar (*Norape cretata*). The hairs of the European processionary caterpillar (*Thaumetopoea processionea*) are especially dangerous to the eyes, but ophthalmia nodosa (papular reaction to embedded hairs) can be seen with a wide variety of caterpillars and moths. Airborne processionary caterpillar hairs have caused large epidemics of caterpillar dermatitis.

## Moth dermatitis

Moth dermatitis may be initiated by the hairs of the brown-tail moth (*Euproctis chrysorrhoea*), goat moth (*Cossus cossus*), puss moth (*Dicranura vinula*), gypsy moth (*Lymantria dispar*), and Douglas fir tussock moth (*Hemenocampa pseudotsugata*). In Latin America, the moths of the genus *Hylesia* are most frequently the cause of moth dermatitis. Severe conjunctivitis and pruritus are the first signs and may persist for weeks aboard ships that have docked in ports where the moth is common. Caripito itch is named after Caripito, Venezuela, a port city where the moth is found. Korean yellow moth dermatitis is caused by *Euproctis flava* Bremer.

Topical applications of various analgesics, antibiotics, and oral antihistaminics are of little help. Topical or oral corticosteroids are sometimes helpful, as is scrubbing and tape stripping of skin. Contaminated clothing may need to be discarded if dermatitis persists after the clothing is washed.

**Haddad V Jr, et al:** Tropical dermatology: venomous arthropods and human skin. Part I. Insecta. *J Am Acad Dermatol* 2012; 67(3):331-e1-e14; quiz 345.

**Hossler EW:** Caterpillars and moths. Part I. Dermatologic manifestations of encounters with Lepidoptera. *J Am Acad Dermatol* 2010; 62(1):1-10.

**Hossler EW:** Caterpillars and moths. Part II. Dermatologic manifestations of encounters with Lepidoptera. *J Am Acad Dermatol* 2010; 62(1):13-28.

**Jourdain F, et al:** The moth *Hylesia metabus* and French Guiana lepidopterism: centenary of a public health concern. *Parasite* 2012; 19(2):117-128.

**Paniz-Mondolfi AE, et al:** Cutaneous lepidopterism: dermatitis from contact with moths of *Hylesia metabus* (Cramer 1775) (Lepidoptera: Saturniidae), the causative agent of Caripito itch. *Int J Dermatol* 2011; 50(5):535-541.

## Order Hemiptera

The true bugs belong to the order Hemiptera. The order includes bedbugs, water bugs, chinch bugs, stink bugs, squash bugs, and reduviid bugs (kissing bugs, assassin bugs). The latter are vectors of South American trypanosomiasis. In most true bugs, the wings are half sclerotic and half membranous and typically overlap. In bedbugs, the wings are vestigial.

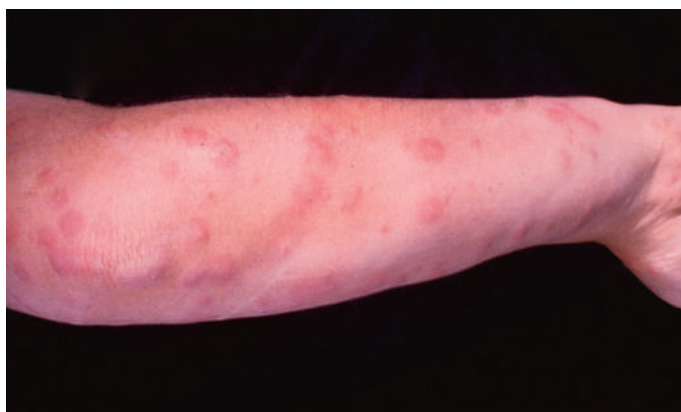
### Cimicosis (bedbug bites)

Bedbugs have flat, oval bodies and retroverted mouthparts used for taking blood meals (**Fig. 20-30**). *Cimex lectularius* is the most common species in temperate climates, and *Cimex*



**Fig. 20-30** Bedbug.





**Fig. 20-31** Bedbug bites.

*hemipterus* is most common in tropical climates. Both are reddish brown and about the size of a tick. *C. hemipterus* is somewhat longer than *C. lectularius*. They breed through traumatic insemination, in which the male punctures the female and deposits sperm into her body cavity. Bedbugs hide in cracks and crevices, then descend to feed while the victim sleeps. It is common for bedbugs to inflict a series of bites in a row (“breakfast, lunch, and dinner”). Bites may mimic urticaria, and patients with papular urticaria commonly have antibodies to bedbug antigens. Unilateral eyelid swelling has been described as a common sign of bedbug bites in children. Bullous and urticarial reactions also occur (Fig. 20-31). Bedbugs have been suggested as vectors for Chagas’ disease and hepatitis B, although data are sparse.

Bedbugs often infest bats and birds, and these hosts may be responsible for infestation in houses. Management of the infestation may require elimination of bird nests and bat roosts. Cracks and crevices should be eliminated and the area treated with an insecticide such as dichlorvos or permethrin. Because most insecticides have poor residual effect on mud bricks, wood, and fabric, frequent retreatment may be necessary. Microencapsulation of insecticides enhances persistence. Permethrin-impregnated bednets have been shown to be effective against bedbugs in tropical climates. Ivermectin treatment is emerging as a potential ancillary measure. Bedbugs that fed once on humans 3 hours after they received 200 µg/kg of oral ivermectin had 63% mortality, and survivors were unable to complete their life cycle.

**Bernardeschi C, et al:** Bed bug infestation. *BMJ* 2013; 346:f138.

**Delaunay P:** Human travel and traveling bedbugs. *J Travel Med* 2012; 19(6):373–379.

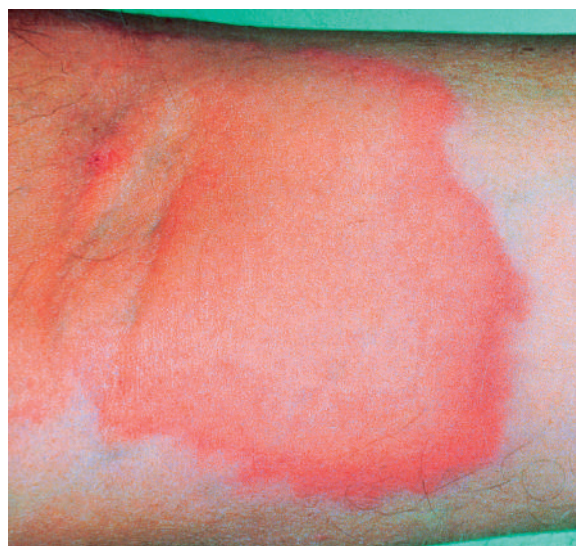
**Steir M, Munoz-Price LS:** Scabies and bedbugs in hospital outbreaks. *Curr Infect Dis Rep* 2014; 16:412.

**Sheele JM, et al:** Ivermectin causes *Cimex lectularius* (bedbug) morbidity and mortality. *J Emerg Med* 2013; 45(3):433–440.

**Vaidyanathan R, et al:** Bed bug detection: current technologies and future directions. *Am J Trop Med Hyg* 2013; 88(4):619–625.

## Reduviid bites

Triatome reduviid bugs (kissing bugs, assassin bugs, conenose bugs) descend on their victims while they sleep and feed on an exposed area of skin. The bite is typically painless, although the bugs are capable of producing a more painful defensive bite. Swelling and itching occur within hours of the bite (Fig. 20-32). Many Latin American species have a pronounced gastrocolic reflex and defecate when they feed. Romana’s sign is unilateral eye swelling after a nighttime encounter with a triatome bug. It resembles the “eyelid sign” associated with bedbugs. *Trypanosoma cruzi* is transmitted by the feces and



**Fig. 20-32** Triatome bite.



**Fig. 20-33** Crab louse.

rubbed into the bite. American trypanosomiasis can produce heart failure and megacolon. Triatome bugs infest thatch, cracks, and crevices, and infestation is associated with poor housing conditions. In nonendemic areas, bites are sporadic and often followed by a red swelling suggestive of cellulitis. Anaphylaxis has also occurred. A related arthropod, the wheel bug *Arius cristatus*, is widely distributed and has an extremely painful defensive bite, but it is not known to carry disease.

**Elston DM:** What’s eating you? Wheel bug (Reduviidae: *Arius cristatus*). *Cutis* 1998; 61:189.

**Kapoor R, et al:** What’s eating you? Triatome reduviids. *Cutis* 2011; 87(3):114–115.

## Order Anoplura

### Pediculosis

Three varieties of the flattened, wingless Anoplura insects infest humans: *Pediculus humanus* var. *capitis* (head louse), *P. humanus* var. *corporis* (body louse), and *Phthirus pubis* (pubic or crab louse) (Fig. 20-33). Rarely, zoonotic lice or louselike psocids will cause infestation.

## ***Pediculosis capitis***

*Pediculosis capitis* is more common in children but also occurs in adults. Patients present with intense pruritus of the scalp and often have posterior cervical lymphadenopathy. Excoriations and small specks of louse dung are noted on the scalp, and secondary impetigo is common. Lice may be identified, especially when combing the hair. Nits may be present throughout the scalp but are most common in the retroauricular region. Generally, only those ova close to the scalp are viable, and nits noted along the distal hair shaft are empty egg cases. In extremely humid climates, however, viable ova may be present along the entire length of the hair shaft. Peripilar keratin (hair) casts are remnants of the inner root sheath that encircle hair shafts and may be mistaken for nits. Whereas nits are firmly cemented to the hair, casts move freely along the hair shaft. Head lice readily survive immersion in water but remain fixed to scalp hairs. There is no evidence that swimming pools contribute to the spread of head lice.

Effective therapeutic agents must kill or remove both lice and ova. Ulesfia (containing benzyl alcohol) is the first nonneurotoxic U.S. Food and Drug Administration (FDA)-approved treatment for lice and represents a significant advancement. Topical spinosad, 4% dimeticone liquid gel, malathion gel, and topical ivermectin are other innovations in the treatment of head lice, but permethrin remains the most widely used pediculicide in the United States, despite widespread resistance. It is available as an over-the-counter (OTC) 1% cream rinse (Nix) and a 5% prescription cream (Elimite) that is marketed for the treatment of scabies. The 1% cream rinse must be applied after shampooing and drying the hair completely. Applying to dry hair lessens dilution of the medication. Product labeling states the medication should be applied for 10 min, then rinsed off, but longer applications may be required. Shampooing should not take place for 24 h afterward. Permethrin has a favorable safety profile, although congenital leukemia has been reported, as noted earlier, and the use of insecticidal shampoos is statistically associated with leukemia. Other reported side effects include acute onset of stuttering in a toddler. Pyrethrins, combined with piperonyl butoxide (RID, A-200, R+C shampoo), are other OTC products. Lindane is rarely used because of low efficacy and potential neurotoxicity. Carbaryl is used in many parts of the world, but not in the United States. Because of the potential toxicity associated with chemical pediculicides, future therapies will be asphyxiating agents, such as those containing benzyl alcohol or dimeticone. Cure rates with dimeticone are significantly higher than with permethrin in some studies. Other agents that asphyxiate or desiccate contain isopropyl myristate 50%.

Nit combing is an important adjunct to treatment but is impractical as a primary method of therapy. Metal combs are more effective than plastic combs. Acidic cream rinses make the hair easier to comb but do not dissolve nit cement, which is similar in composition to amyloid. Various "natural" remedies are marketed that contain coconut oil, anise oil, and ylang ylang oil, but these agents are potential contact allergens, and data are sparse regarding their safety and efficacy. Some data support the efficacy of tea tree oil, which is more potent than lavender or lemon oil. Other studies also support combination lotions containing 5% lavender, peppermint, and eucalyptus oils, or 10% eucalyptus and peppermint oils in various combinations of water and alcohol. The addition of 10% 1-dodecanol improves efficacy.

Aliphatic alcohols show promise as pediculicides, and crota-miton (Eurax), an antiscabietic agent, has some efficacy in the treatment of pediculosis. Because no treatment is reliably ovicidal, retreatment in 1 week is reasonable for all patients.



**Fig. 20-34** Body lice in seams of clothing.

Resistance to pediculicides is an emerging problem in many parts of the world. The emergence of resistance to an agent is related to the frequency of its use. Knockdown resistance (KDR) is a common mechanism of resistance that manifests as lack of immobilization of the lice. Responsible gene mutations (*T929I* and *L932F*) have been identified and can be used to screen for KDR. Cross-resistance among pyrethroids is typical. In the United Kingdom, resistance to malathion has been reported, and multidrug-resistant lice have been identified. KDR results in slower killing of lice, but this may be overcome to some degree by longer applications. Monooxygenase-based resistance to pyrethrins may be overcome by synergism with piperonyl butoxide.

Simple public health measures are also of value when epidemics of louse infestation occur in schools. Hats, scarves, and jackets should be stored separately under each child's desk. Louse education and inspections by the school nurse facilitate targeted treatment of infested individuals.

## ***Pediculosis corporis***

*Pediculosis corporis* (*pediculosis vestimenti*, "vagabond's disease") is caused by body lice that lay their eggs in the seams of clothing (Fig. 20-34). The parasite obtains its nourishment by descending to the skin and taking a blood meal. Generalized itching is accompanied by erythematous, blue and copper-colored macules, wheals, and lichenification. Secondary impetigo and furunculosis are common.

Body louse infestation is differentiated from scabies by the lack of involvement of the hands and feet, although infestation by both lice and scabies is common, and a given patient may have lice, scabies, and flea infestation.

Lice may live in clothing for 1 month without a blood meal. If discarding the clothing is feasible, this is best. Destruction of body lice can also be accomplished by laundering the clothing and bedding. Clothing placed in a dryer for 30 min at 65°C (149°F) is reliably disinfected. Pressing clothing with an iron, especially the seams, is also effective. Permethrin spray or 1% malathion powder can be used to treat clothing and reduce the risk of reinfestation.

Body lice are vectors for relapsing fever, trench fever, and epidemic typhus. These diseases are most prevalent among refugee populations. The trench fever organism is also an important cause of endocarditis among homeless persons.

## ***Pediculosis pubis* (crabs)**

*Phthirus pubis*, the crab louse, is found in the pubic region, as well as hairy areas of the legs, abdomen, chest, axillae, and arms. Pubic lice may also infest the eyelashes and scalp. The lice spread through close physical contact and are usually



transmitted sexually. A diagnosis of pediculosis pubis should initiate a search for other STDs, including HIV infection. Contaminated bedding is also a source of infestation. Pubic louse nits are attached to the hairs at an acute angle. Other than the presence of lice and nits in the hair, the signs and symptoms are similar to those of body louse infestation.

Occasionally, blue or slate-colored macules occur in association with pediculosis pubis. Called maculae ceruleae, these are located chiefly on the sides of the trunk and the inner aspects of the thighs and are probably caused by altered blood pigments.

Treatment of pediculosis pubis is similar to that for head lice. The affected person's sexual contacts should be treated simultaneously. For eyelash involvement, a thick coating of petrolatum can be applied twice daily for 8 days, followed by mechanical removal of any remaining nits. Fluorescein and 4% pilocarpine gel are also effective. Clothing and fomites should be washed and dried by machine, or laundered and ironed.

**Ahmad HM, et al:** Assessment of topical versus oral ivermectin as a treatment for head lice. *Dermatol Ther* 2014; 27:307–310.

**Burgess IF, et al:** Single application of 4% dimeticone liquid gel versus two applications of 1% permethrin creme rinse for treatment of head louse infestation: a randomised controlled trial. *BMC Dermatol* 2013; 13:5.

**Chosidow O, et al:** Topical ivermectin lotion for head lice. *N Engl J Med* 2013; 368(10):968.

**Feldmeier H:** Treatment of pediculosis capitis: a critical appraisal of the current literature. *Am J Clin Dermatol* 2014; 15:401–412.

**Goodman DM, et al:** Head lice (Patient page). *JAMA* 2013; 309(22):2398.

**Lapeere H, et al:** A efficacy of products to remove eggs of *Pediculus humanus capitis* (Phthiraptera: Pediculidae) from the human hair. *J Med Entomol* 2014; 51:400–407.

**Pariser DM, et al:** Topical ivermectin lotion for head lice. *N Engl J Med* 2013; 368(10):967.

## Order Diptera

Order Diptera includes the two-winged biting flies and mosquitoes. Adult dipterids bite and spread disease, while larvae parasitize humans in the form of myiasis. Medically important families of flies include the Tabanidae (horsefly, deerfly, gadfly), which inflict extremely painful bites, and the Muscidae (housefly, stablefly, tsetse fly). Tsetse fly bites transmit African trypanosomiasis. Simuliidae include the black fly (buffalo gnat, turkey gnat), the vector of onchocerciasis. These flies are dark-colored and “hunchbacked.” They may produce extremely painful bites that may be associated with fever, chills, and lymphadenitis. Black flies are seasonal annoyances in the northern United States and Canada.

Psychodidae sandflies (Diptera: Phlebotominae) are small, hairy-winged flies that transmit leishmaniasis, sandfly fever, and verruga peruana. Sandfly fever viruses are a problem in Africa, the Mediterranean basin, and Central Asia and are carried by *Phlebotomus* flies. *Lutzomyia* flies are common in Latin America and south Texas.

Culicidae, or mosquitoes, are vectors of many important diseases, such as filariasis, malaria, dengue, and yellow fever. Their bites may cause severe urticarial reactions. Ceratopogonidae, the biting midges or gnats, fly in swarms and produce erythematous, edematous lesions at the site of their bite.

## Mosquito bites

Moisture, warmth, CO<sub>2</sub>, estrogens, and lactic acid in sweat attract mosquitoes. Drinking alcohol also stimulates mosquito attraction. Mosquito bites are a common cause of papular urticaria. More severe local reactions are seen in young children, individuals with immunodeficiency, and those with new

exposure to indigenous mosquitoes. Immediate-type hypersensitivity can be controlled with antihistamines, and prophylactic rupatadine, 10 mg daily, has been effective in the treatment of immediate mosquito-bite allergy. Both necrotizing fasciitis and the hemophagocytic syndrome have been reported after mosquito bites, and exaggerated hypersensitivity reactions to mosquito bites are noted in a wide variety of Epstein-Barr virus (EBV)-associated lymphoproliferative disorders, especially natural killer (NK) cell proliferations. Mosquito bites may play a key role in reactivation of latent EBV infection.

**Enayati AA, et al:** Electronic mosquito repellents for preventing mosquito bites and malaria infection. *Cochrane Database Syst Rev* 2007; (2):CD005434.

**Karppinen A, et al:** Rupatadine 10 mg in the treatment of immediate mosquito-bite allergy. *J Eur Acad Dermatol Venereol* 2012; 26(7):919–22.

**Singh S, et al:** Insect bite reactions. *Indian J Dermatol Venereol Leprol* 2013; 79(2):151–164.

## Ked itch

The sheep ked (*Melophagus ovinus*) feeds by thrusting its sharp mouthparts into the skin and sucking blood. Occasionally, it attacks woolsorters and shepherders, causing pruritic, often hemorrhagic papules, typically with a central punctum. Deer keds attack humans in a similar way. The papules are persistent and may last for up to 12 months. Favorite locations are the hips and abdomen.

## Myiasis

Myiasis is the infestation of human tissue by fly larvae. Forms of infestation include wound myiasis, furuncular myiasis, plaque myiasis, creeping dermal myiasis, and body cavity myiasis. Wound myiasis occurs when flies lay their eggs in an open wound. Furuncular myiasis often involves a mosquito vector that carries the fly egg. Plaque myiasis typically involves many maggots and occurs after flies lay their eggs on clothing. Creeping myiasis develops when the larvae of the *Gasterophilus* fly wander intradermally. The most common species are *Gasterophilus nasalis* and *Gasterophilus intestinalis*. An itching pink papule develops, followed by a tortuous line that extends by 1–3 cm a day. Body cavity myiasis may involve the orbit, nasal cavity, GI tract, or urogenital system.

The human botfly, *Dermatobia hominis*, is a common cause of furuncular myiasis in the neotropical regions of the New World (Fig. 20-35). The female glues its eggs to the body of a

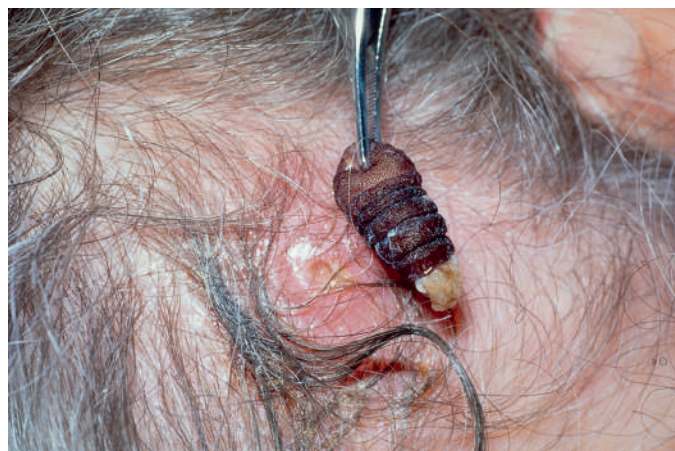

Fig. 20-35 Myiasis.

mosquito, stablefly, or tick. When the unwitting vector punctures the skin by biting, the larva emerges from the egg and enters the skin through the puncture wound. Over several days, a painful furuncle develops in which the larva is present. Other larvae that frequently cause furuncular lesions in North America are the common cattle grub (*Hypoderma lineatum*), rabbit botfly (*Cuterebra cuniculi*), and *Wohlfahrtia vigil*. The *W. vigil* fly can penetrate infant skin, but not adult skin, so almost all reported cases have occurred in infants. The New World screw worm, *Cochliomyia hominivorax*, often involves the head and neck region. Larvae of Calliphoridae flies, especially *Phaenicia sericata*, the green blowfly, cause wound myiasis. Other blowflies, flesh flies (Sarcophagidae), and humpbacked flies (Phoridae) are less common causes of wound myiasis. In tropical Africa, the Tumbu fly (*Cordylobia anthropophaga*) deposits her eggs on the ground or on clothing. The young maggots penetrate the skin and often form a plaque with many furuncular-appearing lesions. *Cordylobia ruandae* and *Cordylobia rodhaini* are less frequent causes of plaque myiasis. *Oestrus ovis* causes ophthalmomyiasis that may be misdiagnosed as bacterial conjunctivitis.

Removal of the maggots of furuncular myiasis can be accomplished by injection of a local anesthetic into the skin, which causes the larva to bulge outward. The opening of the furuncle can also be occluded with hair gel, surgical lubricant, lard, petrolatum, or bacon, causing the larva to migrate outward. Successful treatment with ivermectin has also been reported.

**Akdemir MO, et al:** External ophthalmomyiasis caused by *Oestrus ovis* misdiagnosed as bacterial conjunctivitis. *Trop Doct* 2013; 43(3):120–123.

**Fydryszewski NA:** Myiasis: diagnosis, treatment and medical use of maggots. *Clin Lab Sci* 2013; 26(2):76–81.

**McGraw TA, et al:** Cutaneous myiasis. *J Am Acad Dermatol* 2008; 58(6):907–926.

## Order Coleoptera

### Blister beetle dermatitis

Blister beetle dermatitis occurs after contact with several groups of beetle (Fig. 20-36). The Meloidae and Oedemeridae families produce injury to the skin by releasing a vesicating



**Fig. 20-36** Blister beetle.

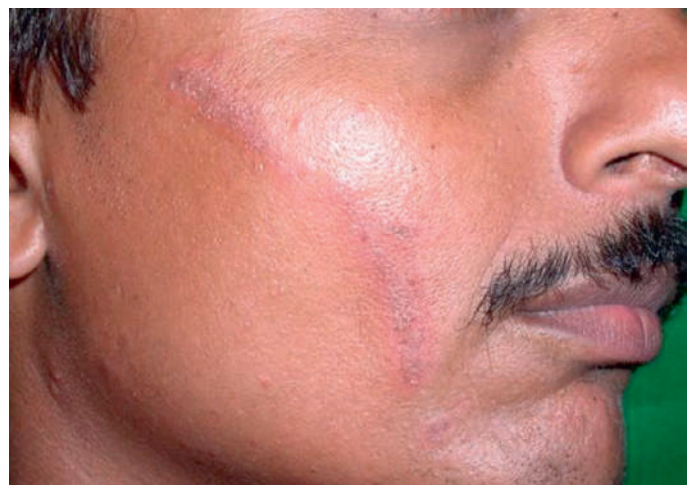agent, cantharidin. Members of the family Staphylinidae (genus *Paederus*) contain a different vesicant, pederin. None of the beetles bites or stings; rather, they exude their blistering fluid if they are brushed against, pressed, or crushed on the skin. Many blister beetles are attracted at night by fluorescent lighting.

Slight burning and tingling of the skin occur within minutes, followed by the formation of bullae, often arranged linearly. “Kissing lesions” are observed when the blister beetle’s excretion is deposited in the flexures of the elbows or other folds. Ingestion of beetles or cantharidin results in poisoning, presenting with hematuria and abdominal pain. In many tropical and subtropical habitats, rove beetles (genus *Paederus*) produce a patchy or linear, erythematous vesicular eruption (dermatitis linearis) (Fig. 20-37). In parts of South America, it is known as podo. It occurs frequently during the rainy season and appears predominantly on the neck and exposed parts. Lymphadenopathy and fever are common. In the southwestern United States, outbreaks of rove beetle dermatitis have followed unusually rainy periods. In southeastern Australia, corneal erosions are caused by small Corylophidae beetles (*Orthoperus* spp). Blister beetle derivatives, including cantharidin, norcantharidin, cantharidimide, and norcantharimide, have significant potential as phosphoprotein phosphatase inhibitors in cancer treatment.

Treatment of blister beetle dermatitis consists of draining the bullae and applying cold wet compresses and topical antibiotic preparations. Early cleansing with acetone, ether, soap, or alcohol may be helpful to remove cantharidin.

### Other beetles

Papulovesicular and urticarial dermatitis is caused by the common carpet beetle (Dermestidae: *Anthrenus scrophulariae*). The eruption involves the chest, neck, and extremities. The larvae inhabit warm houses throughout the winter months. They are reddish brown, fusiform, about 6 mm long, and covered by hairs. A generalized pruritic eruption has been attributed to the larvae of the carpet beetle, *Anthrenus verbasci*. Bombardier beetles of the family Carabidae (subfamily Brachininae) can cause skin burns with a deep yellow-brown color. Chemicals released when these beetles are crushed include acids, phenols, hydrocarbons, and quinines. When the beetle is threatened, chemical reactions produce an explosive spray of boiling-hot benzoquinones from the tip of the abdomen. Dermestidae (skin beetles) and Cleridae (bone beetles) infest exposed human remains and are useful in



**Fig. 20-37** *Paederus* dermatitis. (Courtesy of Dr. Shyam Verma.)



estimating the postmortem interval. Rare cases of allergic angioedema have been reported after exposure to ladybugs.

**Elston DM:** What's eating you? Blister beetles. *Cutis* 2004; 74(5):285–286.

**Singh A, et al:** Blister beetle dermatitis: few observations helping in diagnosis. *Int J Prev Med* 2013; 4(2):241.

## Order Hymenoptera

Hymenopterids include bees, wasps, hornets, and ants. Stings by any of these may manifest the characteristic clinical and histologic features of eosinophilic cellulitis (Wells syndrome), complete with flame figures.

### Bees and wasps

Yellowjackets are the principal cause of allergic reaction to insect stings, because they nest in the ground or in walls and are disturbed by outdoor activity, such as gardening or lawn mowing. Bees are generally docile and sting only when provoked, although Africanized bees display aggressive behavior. The allergens in vespid venom are phospholipase, hyaluronidase, and a protein known as antigen 5. Bee venom contains histamine, mellitin, hyaluronidase, a high-molecular-weight substance with acid phosphatase activity, and phospholipase A. The barbed ovipositor of the honeybee is torn out of the bee and remains in the skin after stinging. The bumblebee, wasp, and hornet are able to withdraw their stinger.

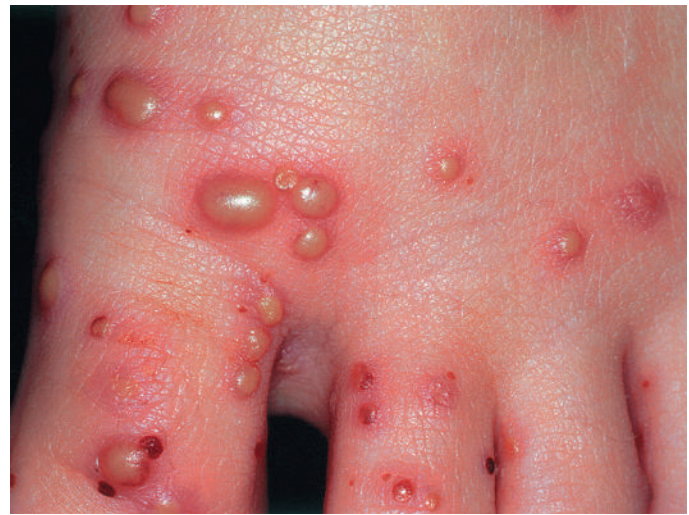The reaction to these stings ranges from pain and mild local edema to exaggerated reactions that may last for days. Serum sickness, characterized by fever, urticaria, and joint pain, may occur 7–10 days after the sting. Severe anaphylactic shock and death may occur within minutes of the sting. Most hypersensitivity reactions have been shown to be mediated by specific IgE antibodies. Anaphylaxis to vespids may also be the presenting symptom of mastocytosis, with no demonstrable, specific IgE against wasp venom. Granuloma annulare and subcutaneous granulomatous reactions have been reported. Contact allergy to propolis is common among beekeepers.

Treatment of local reactions consists of immediate application of ice packs or topical anesthetics. Chronic reaction sites may be injected with triamcinolone suspension diluted to 5 mg/mL with 2% lidocaine. Oral prednisone may be required for severe local reactions.

For severe systemic reactions, 0.3 mL of epinephrine (1:1000 aqueous solution) is injected intramuscularly. This may need to be repeated after 10 min. Susceptible persons should carry a source of injectable epinephrine. Corticosteroids and epinephrine may be required for several days after severe reactions. Hyposensitization by means of venom immunotherapy can reduce the risk of anaphylaxis in people at risk. Those at risk should be evaluated by an allergist. Rush desensitization regimens exist, and ultrarush sublingual immunotherapy looks promising.

### Ants

The sting of most ants is painful, but that of fire ants (*Solenopsis invicta*, *S.s geminata*, or *S. richteri*) is especially painful. Fire ants are vicious and will produce many burning, painful stings within seconds if their mound is disturbed. The sting causes intense pain and whealing. Later, an intensely pruritic, sterile pustule develops at the site (Fig. 20-38). Anaphylaxis, seizures, and mononeuropathy have been reported. The sting of harvester ants and soldier ants may produce similar reactions. Treatment options are similar to those for vespid stings.



**Fig. 20-38** Sterile pustules at the site of fire ant stings.



**Fig. 20-39** Cat flea.

**Stritzke AI, et al:** Age-dependent sting recurrence and outcome in immunotherapy-treated children with anaphylaxis to Hymenoptera venom. *Clin Exp Allergy* 2013; 43(8):950–955.

## Order Siphonaptera

Fleas are wingless, with highly developed legs for jumping. They are blood-sucking parasites, infesting most warm-blooded animals. Fleas are important vectors of plague, endemic typhus, brucellosis, melioidosis, and erysipeloid.

### Pulicosis (flea bites)

The species of flea that most frequently attack humans are the cat flea (*Ctenocephalides felis*; Fig. 20-39), human flea (*Pulex irritans*), dog flea (*Ctenocephalides canis*), and oriental rat flea (*Xenopsylla cheopis*; Fig. 20-40). The stick-tight flea (*Echidnophaga gallinacea*), mouse flea (*Leptopsylla segnis*), and chicken flea (*Ceratophyllus gallinae*) are sometimes implicated.

Fleas are small, brown insects about 2.5 mm long, flat from side to side, with long hind legs. They slip into clothing or jump actively when disturbed. They bite about the legs and waist and may be troublesome in houses where there are dogs or cats. The lesions are often grouped and may be arranged in zigzag lines. Hypersensitivity reactions may appear as papular urticaria, nodules, or bullae. Camphor and menthol preparations, topical corticosteroids, and topical anesthetics can be of benefit.

## Vectors of disease

*Xenopsylla cheopis* and *Xenopsylla braziliensis* are vectors of plague and endemic typhus. The cat flea (*Ctenocephalides felis*) is the vector for *Rickettsia felis*, a cause of endemic typhus. Plague and tularemia are transmitted by the squirrel flea, *Diamanus montanus*. Several species of flea are intermediate hosts of the dog tapeworm and rat tapeworm, which may be an incidental parasite of humans.

## Tungiasis

*Tunga penetrans* is also known as nigua, the chigoe, sand flea, or jigger. It is a reddish brown flea about 1 mm long. It resides in the Caribbean, equatorial Africa, Central and South America, India, and Pakistan. It was first reported in crewmen who sailed with Christopher Columbus.

The female chigoe burrows into the skin, often adjacent to a toenail, where she may be seen with the aid of dermoscopy. Once embedded, the flea becomes impregnated and ova develop. Skin lesions are pruritic swellings the size of a small pea (Fig. 20-41). These may occur on the ankles, feet, and soles, as well as the anogenital areas. The lesions become extremely painful and secondarily infected. Wearing open shoes and the presence of pigs in the area are risk factors for disease.

Curettage or excision of the burrows is recommended. Topical ivermectin, metrifonate, or thiabendazole can be used,



Fig. 20-40 Oriental rat flea.

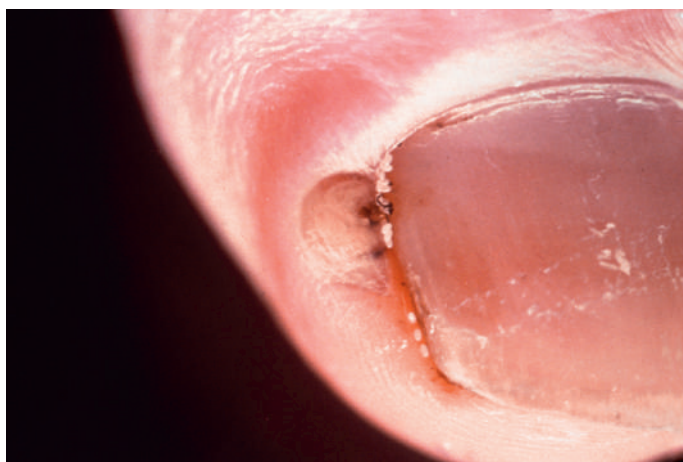

Fig. 20-41 Tungiasis.

and oral thiabendazole, 25 mg/kg/day, has been effective in heavily infested patients. Antibiotics should be used for the secondary infection and tetanus prophylaxis given. These lesions can be prevented by the wearing of shoes. Infested ground and buildings may be disinfected with insecticides and growth inhibitors.

**Criado PR, et al:** Tungiasis under dermoscopy: in vivo and ex vivo examination of the cutaneous infestation due to *Tunga penetrans*. *An Bras Dermatol* 2013; 88(4):649–651.

**Karunamoorthi K:** Tungiasis: a neglected epidermal parasitic skin disease of marginalized populations—a call for global science and policy. *Parasitol Res* 2013; 112(10):3635–3643.

**Thielecke M, et al:** The fate of the embedded virgin sand flea *Tunga penetrans*: hypothesis, self-experimentation and photographic sequence. *Travel Med Infect Dis* 2013; 11(6):440–443.

## CLASS ARACHNIDA

Arachnida includes the ticks, mites, spiders, and scorpions. Adult and nymph stages of arachnids have four pairs of legs, and larval forms have six legs. Their bodies consist of cephalothorax and abdomen, in contrast to insects, which have three body segments.

## Order Acarina

### Tick bite

Several varieties of the family Ixodidae (hard ticks) and Argasidae (soft ticks) will attack human skin, but only hard ticks remain attached. In the United States, *Ornithodoros hermsi*, *O. turicata*, and *O. parkeri* transmit tick-borne relapsing fever. The wood tick (*Dermacentor andersoni*) is an important disease vector in western states. It carries Rocky Mountain spotted fever, tularemia, ehrlichiosis, and Colorado tick fever. The dog tick (*Dermacentor variabilis*; Fig. 20-42) is prevalent in the eastern U.S. states and is the most common vector of Rocky Mountain spotted fever. It also carries tularemia. *Dermacentor marginatus* transmits tick-borne lymphadenopathy in Spain. The brown dog tick (*Rhipicephalus sanguineus*) is a vector of Rocky Mountain spotted fever, tularemia, and boutonneuse fever. The lone star tick (*Amblyomma americanum*; Fig. 20-43) carries Rocky Mountain spotted fever, tularemia, and human monocytic ehrlichiosis. *Ixodes ricinus* in Europe and *I. scapularis* and *I. pacificus* in the United States transmit *Borrelia burgdorferi*, the cause of Lyme disease. *Ixodes* ticks also transmit human granulocytic ehrlichiosis and babesiosis. The risk of disease transmission increases with the duration of tick attachment. Unfortunately, ticks often attach in areas where they are not noticed, allowing them to engorge and transmit disease.

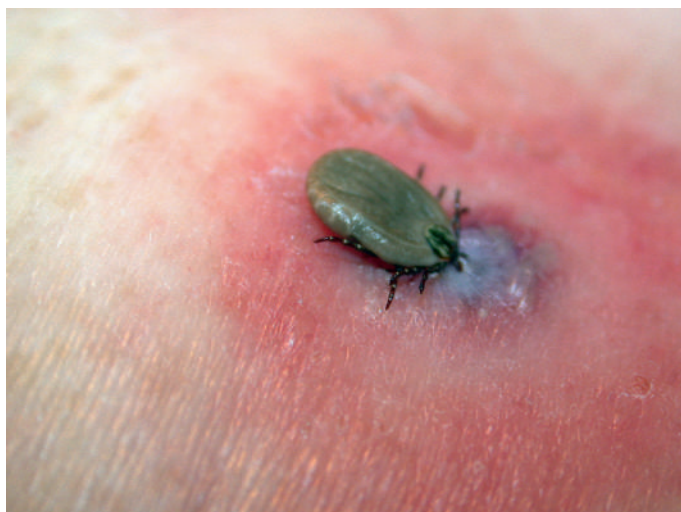

Fig. 20-42  
*Dermacentor variabilis*.





**Fig. 20-43** Lone star tick.



**Fig. 20-44** Tick attached to skin. (Courtesy of Dr. Don Adler.)

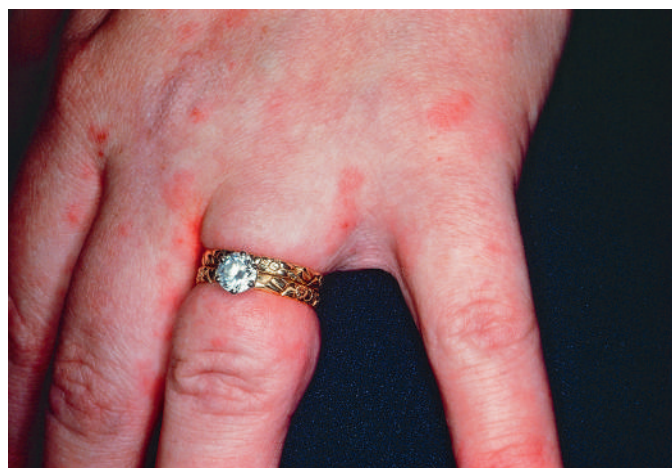The female hard tick attaches itself to the skin by sticking its proboscis into the flesh to suck blood from the superficial vessels. The insertion of the hypostome is generally unnoticed by the subject. The attached tick may be mistaken by the patient for a new mole (Fig. 20-44). The parasite slowly becomes engorged and then falls off. During this time, which may last for 7–12 days, the patient may have fever, chills, headache, abdominal pain, and vomiting (tick bite pyrexia). Removal of the engorged tick causes a subsidence of the general symptoms in 12–36 h.

The bites may be followed by small, severely pruritic, fibrous nodules (tick bite granulomas) that persist for months or by pruritic, circinate and arciform, localized erythemas that may also persist over months. Tick bite-induced alopecia has been reported, and both *Amblyomma americanum* and *Ixodes* tick bites are associated with the development of IgE antibodies to the carbohydrate galactose- $\alpha$ -1,3-galactose, causing delayed urticaria and anaphylaxis after consumption of red meat.

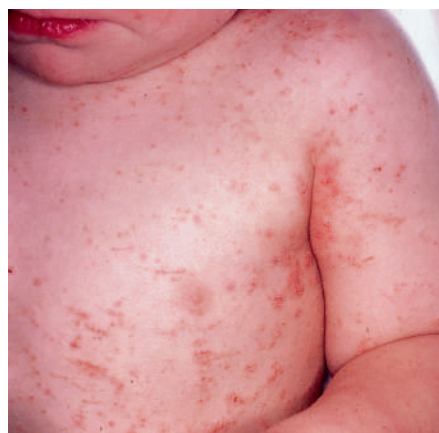Histologically, bite reactions demonstrate wedge-shaped necrosis with a neutrophilic infiltrate and vascular thrombosis or hemorrhage. Chronic bite reactions often have atypical CD30+ lymphocytes and eosinophils. Pseudolymphomas and immunocytomas may occur.

### Tick paralysis

Tick paralysis most often affects children and carries a mortality rate of about 10%. Flaccid paralysis begins in the legs, then the arms, and finally the neck, resembling Landry-Guillain-Barré syndrome. Bulbar paralysis, dysarthria, dysphagia, and death from respiratory failure may occur. Prompt recovery occurs if the tick is found and removed before the terminal stage. *Dermacentor* ticks in North America and *Ixodes* ticks in



**Fig. 20-45** Scabies.



**Fig. 20-46** Scabies.

Australia are the most important causes of tick paralysis. Because *Dermacentor* ticks typically attach to the scalp, they may go unnoticed.

**Commins SP, et al:** Tick bites and red meat allergy. *Curr Opin Allergy Clin Immunol* 2013; 13(4):354–359.

**Garza Ocañas L, et al:** Images in clinical medicine: cutaneous loxoscelism. *N Engl J Med* 2013; 369(5):e6.

**Hamsten C, et al:** Identification of galactose- $\alpha$ -1,3-galactose in the gastrointestinal tract of the tick *Ixodes ricinus*: possible relationship with red meat allergy. *Allergy* 2013; 68(4):549–552.

**Kennedy JL, et al:** Galactose- $\alpha$ -1,3-galactose and delayed anaphylaxis, angioedema, and urticaria in children. *Pediatrics* 2013; 131(5):e1545–e1552.

**Saleh H, et al:** Anaphylactic reactions to oligosaccharides in red meat: a syndrome in evolution. *Clin Mol Allergy* 2012; 10(1):5.

**Wolver SE, et al:** A peculiar cause of anaphylaxis: no more steak? The journey to discovery of a newly recognized allergy to galactose- $\alpha$ -1,3-galactose found in mammalian meat. *J Gen Intern Med* 2013; 28(2):322–325.

### Mites

#### Scabies

*Sarcoptes scabiei*, the itch mite, is an oval, ventrally flattened mite with dorsal spines. The fertilized female burrows into the stratum corneum and deposits her eggs. Scabies is characterized by pruritic papular lesions, excoriations, and burrows. Sites of predilection include the finger webs (Fig. 20-45), wrists, axillae (Fig. 20-46), areolae, umbilicus, lower abdomen, genitals (Fig. 20-47), and buttocks (Fig. 20-48). An imaginary circle intersecting the main sites of involvement—axillae, elbow

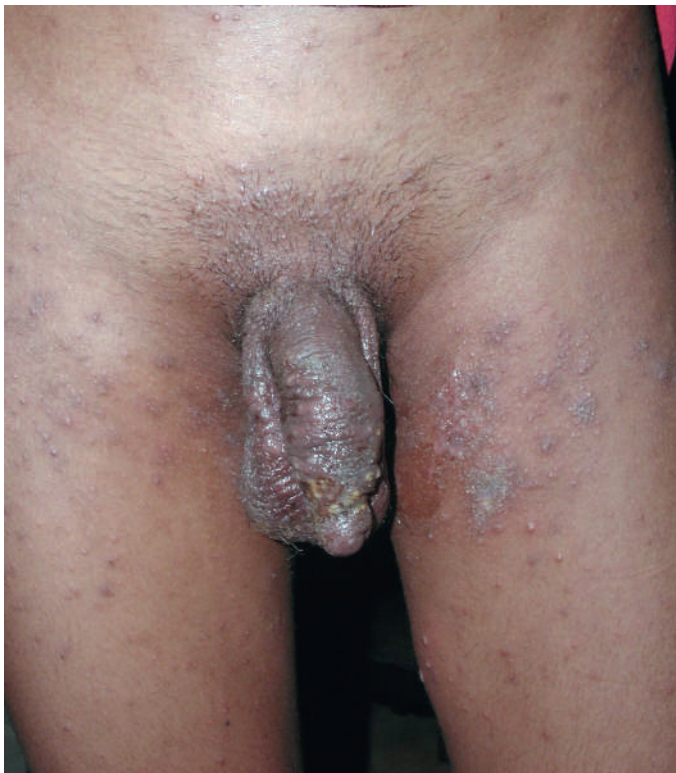

Fig. 20-47 Scabies. (Courtesy of Dr. Shyam Verma.)

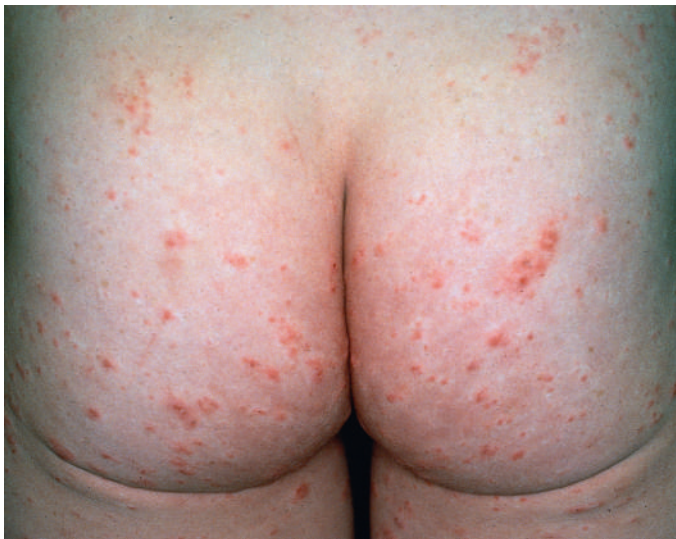

Fig. 20-48 Scabies.

flexures, wrists and hands, and crotch—has long been called the circle of Hebra. In adults, the scalp and face are usually spared, but in infants, lesions are usually present over the entire cutaneous surface. The burrows appear as slightly elevated, grayish, tortuous lines in the skin. A vesicle or pustule containing the mite may be noted at the end of the burrow, especially in infants and children. To identify burrows quickly, a drop of India ink or gentian violet can be applied to the infested area, then removed with alcohol. Thin, threadlike burrows retain the ink.

The eruption varies considerably, depending on the length of infestation, previous sensitization, and prior treatment. It also varies with climate and the host's immunologic status. Lichenification, impetigo, and furunculosis may be present. Bullous lesions may contain many eosinophils, resembling

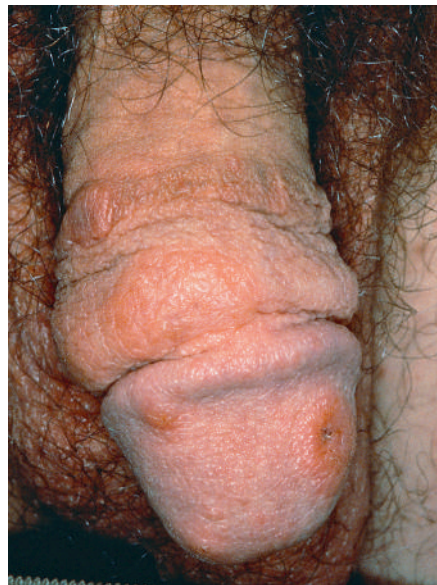

Fig. 20-49 Scabies.

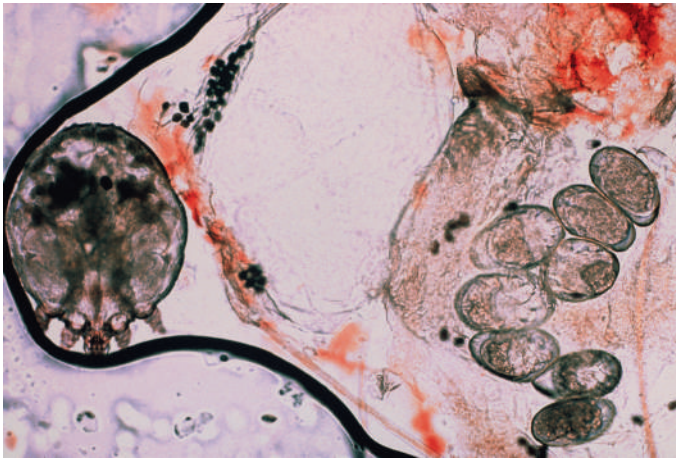
bullous pemphigoid. Positive immunofluorescent findings may also be noted. Scabies has also been reported to trigger epidermolysis bullosa (EB) pruriginosa, a variant of dystrophic EB. Scabies may also resemble Langerhans cell histiocytosis clinically and histologically. Misdiagnosis has led to systemic treatment with toxic agents.

Dull-red nodules may appear during active scabies; these are 3–5 mm in diameter, may or may not itch, and persist on the scrotum, penis (Fig. 20-49), and vulva. Intralesional steroids, tar, or excision are methods of treatment for this troublesome condition, termed nodular scabies. Histologically, the lesions may suggest lymphoma.

Crusted scabies (Norwegian or hyperkeratotic scabies) is found in immunocompromised or debilitated patients, including those with neurologic disorders, Down syndrome, organ transplants, graft-versus-host disease, adult T-cell leukemia, Hansen's disease, or AIDS. In these patients, the infestation assumes a heavily scaling and crusted appearance. Crusts and scales teem with mites, and the face is involved, especially the scalp. Itching may be slight. Psoriasis-like scaling is noted around and under the nails. The tips of the fingers are swollen and crusted and the nails distorted. Severe fissuring and scaling of the genitalia and buttocks may be present. Pressure-bearing areas are the sites of predilection for the heavy keratotic lesions, in which the mites may abound.

Scabies is usually contracted by close personal contact, although it may also be transmitted by contaminated linens and clothing. Screening for other STDs is appropriate. Sensitization begins about 2–4 weeks after onset of infection. During this time, the parasites may be on the skin and may burrow into it without causing pruritus or discomfort. Severe itching begins with sensitization of the host. In reinfections, itching begins within days, and the reaction may be clinically more intense. The itching is most intense at night, whereas during the daytime, the pruritus is tolerable but persistent. The eruption does not involve the face or scalp in adults. In women, itching of the nipples associated with a generalized pruritic papular eruption is characteristic; in men, itchy papules on the scrotum and penis are equally typical. When more than one member of the family has pruritus, scabies should be suspected. Whenever possible, however, it is advisable to identify the mite, because a diagnosis of scabies usually requires treatment of close physical contacts in addition to the patient. Because scabies cannot always be excluded by examination, treatment on presumption of scabies is sometimes necessary.





**Fig. 20-50** Scabies mite, ova, and feces.

Positive diagnosis is made only by the demonstration of the mite under the microscope (Fig. 20-50). A burrow is sought and position of the mite determined. A surgical blade or sterile needle is used to remove the parasite. A drop of mineral or immersion oil can be placed on a lesion and gently scraped away with the epidermis beneath it. The majority of mites are found on the hands and wrists, less frequently (in decreasing order) at the elbows, genitalia, buttocks, and axillae. Children have often gathered mites and ova under the nails when scratching. A blunt curette can be used to gather material from under the nails for examination. Noninvasive techniques include dermoscopy and digital photography.

Permethrin 5% cream (Elimite) is the most widely used and most effective medication for scabies. It is a synthetic pyrethroid that is lethal to mites and has low toxicity for humans, although some concern has been raised about the association between topical insecticides and lymphoma. Lindane ( $\gamma$ -benzene hexachloride) is also effective, with a low incidence of adverse effects when used properly. Because of the availability of less toxic agents, lindane is rarely used as a first-line agent and is banned in some locations. In much of the world, benzyl benzoate and 10% precipitated sulfur in white petrolatum are used to treat scabies. *Tinospora cordifolia* lotion appears promising. The scabicide should be thoroughly rubbed into the skin from the neck to the feet, with particular attention given to the creases, perianal areas, umbilicus, and free nail edge and folds. It is washed off 8–10 h later. Clothing and bed linen are changed and laundered thoroughly. Crotamiton (Eurax) has a lower cure rate than other available agents. When used, it should be applied on five successive nights and washed off 24 h after the last use.

Ivermectin has been used to control onchocerciasis since 1987 and is marketed in the United States for the treatment of strongyloidiasis. Numerous publications attest to its efficacy in treating scabies. It is supplied as 3-mg and 6-mg pills and is usually given at a dose of 200  $\mu$ g/kg. Although an oral treatment is convenient, it may not be any more effective than topical therapy. In the crusted type of scabies, ivermectin should be used in conjunction with a topical agent. It may need to be repeated two or three times at intervals of 1–2 weeks. Ivermectin appears to have a good margin of safety, although neurotoxicity may be possible. Topical ivermectin has been shown to be effective as well.

Individuals in close contact with the patient should be treated. Scabies in long-term health care facilities is an increasing problem. Delays in treating close contacts may result in large numbers of persons requiring treatment.



**Fig. 20-51**  
Nonburrowing cat  
mite (*Cheyletiella*  
*blakei*).

### Animal scabies

Zoonotic scabies and scab mites may affect humans who come in close contact with the animal. The reaction resembles scabies but typically runs a self-limited course. Burrows are usually absent.

### Other mite diseases

#### Demodex mites

*Demodex folliculorum* is a vermiform mite that inhabits the pilosebaceous units of the nose, forehead, chin, and scalp. The mite has a flattened head, four pairs of short, peglike legs, and an elongated abdomen. *Demodex brevis* is shorter and more often found on the trunk.

In dogs, the lesions of demodectic mange contain numerous mites. In humans, there are convincing reports of demodectic blepharitis, demodectic folliculitis, demodectic abscess, and demodectic alopecia that respond to eradication of the mites. Some rosacea-like lesions may also be caused by *Demodex*. Treatment of the eruptions in which *Demodex* has been implicated consists of applying permethrin, sulfur, lindane, benzyl benzoate, or benzoyl peroxide. Oral ivermectin and metronidazole have also been used.

#### *Cheyletiella* dermatitis

*Cheyletiella yasguri*, *Cheyletiella blakei* (Fig. 20-51), and *Cheyletiella parasitovorax* are three species of nonburrowing mite that are parasitic on dogs, cats, and rabbits, respectively, where they present as “walking dandruff.” They may bite humans when there is close contact with the animals, producing an itchy dermatitis resembling scabies or immunobullous disease. The mites are similar in diameter to *Sarcoptes scabiei* but are elongated and have prominent anterior hooked palps. They may be found by brushing the animal’s hair over a dark piece of paper. The brushings can be placed in alcohol, where the scales and hair sink while the mites float. The pet should be treated by a qualified veterinarian.

#### Chigger bite

The trombiculid mites are known as chiggers, mower’s mites, or red bugs. In North America, *Trombicula* (*Eutrombicula*) *alfreddugesi* attacks humans and animals. In Europe, the harvest mite, *Neotrombicula autumnalis*, is a common nuisance. Attacks occur chiefly during the summer and fall, when individuals have more frequent contact with mite-infested grass and bushes. The lesions occur chiefly on the legs (Fig. 20-52) and at the belt line and other sites where clothing causes constriction. Penile lesions are common in males. Lesions generally consist of severely pruritic, hemorrhagic puncta surrounded by red swellings. On the ankles, intensely pruritic, grouped, excoriated papules are noted. Several varieties of trombiculid mite in East Asia and the South Pacific are vectors of scrub typhus (tsutsugamushi fever).

## Gamasoidosis

Gamasoidosis is caused by two genera of mites, *Ornithonyssus* and *Dermanyssus*, and occurs after contact with canaries, pigeons, and poultry. Because of the association with pigeons, the dermatitis is common among urban dwellers, and because of the small size of the mites and their tendency to leave the host after biting, the diagnosis may not be considered. In pet stores, bird mites may be transmitted to rodents with human disease related to contact with a gerbil or hamster. The mites are active at night and hide during the day. The resulting dermatosis occurs chiefly on the hands and arms as itchy macules, papules, or vesicles. Any body area may be attacked, and common additional sites are the groin, areolae, umbilicus, face, and scalp. The mites may wander from bird nests as soon as the young birds begin to fly, and they may infest terrace cushions and patio furniture. The tropical fowl mite (*Ornithonyssus bursa*) and the red chicken mite (*Dermanyssus gallina*) are the major culprits. *Dermanyssus* mites may carry *Erysipelothrix rhusiopathiae*.

## Grocer's itch

Grocer's itch is a pruritic dermatitis of the forearms, with occasional inflammatory and urticarial papules on the trunk. It results from the handling of figs, dates, and prunes, when it is caused by *Carpoglyphus passalarum*, or from exposure to the cheese mite (*Glyciphagus domesticus*). This must be distinguished from grocer's eczema, which is caused by sensitization to flour, sugar, cinnamon, chocolate, and similar items.

## Grain itch

Grain itch is also known as straw itch, barley itch, mattress itch, and prairie itch. Causative mites include *Pyemotes tritici*, *Pyemotes ventricosus*, *Cheyletus malaccensis*, and *Tyrophagus putrescentiae* (copra itch mite). Those mainly affected are harvesters of wheat, hay, barley, oats, and other cereals or farm hands and packers who have contact with straw. Grain itch has a typical lesion consisting of an urticarial papule on which there is a small vesicle. There is intense pruritus, with lesions occurring predominantly on the trunk. Frequently, an initial central hemorrhagic punctum rapidly turns into an ecchymosis with hemosiderin pigmentation.

## Other mite-related dermatitides

*Dermatophagoides pteronyssinus* and *D. farinae* are dust mites implicated in atopic diseases. *Lepidoglyphus destructor* is the hay mite. There have been outbreaks of *Pyemotes boylei* bites in homes fumigated for termites. Although mites do not

appear capable of survival when forced to share an environment with termites, they thrive in locations where there are termite carcasses. Vanillism is a dermatitis caused by *Acarus siro* and occurs in workers handling vanilla pods. Copra itch occurs on persons handling copra who are subject to *Tyrophagus longior* mite bites. Coolie itch is found on tea plantations in India and is caused by *Rhizoglyphus parasiticus*; it causes sore feet. Rat mite itch, caused by *Ornithonyssus bacoti*, the tropical rat mite, may result in an intensely pruritic dermatitis. This papulovesicular urticarial eruption is seen in workers in stores, factories, warehouses, and stockyards. The rat mite may transmit endemic typhus, rickettsialpox, equine encephalitis, tularmia, plague, and relapsing fever. Feather pillow dermatitis is a pruritic papular dermatitis traced to the Psoroptid carpet mite, *Dermatophagoides schereemetewskyi*, which may infest feather pillows. The house mouse mite, *Allodermanyssus (Liponyssoides) sanguineus*, is the vector of *Rickettsia akari*, the causative organism of rickettsialpox.

**Alasaad S, et al:** Advances in studies of disease-navigating webs: *Sarcoptes scabiei* as a case study. *Parasit Vectors* 2014; 7:16.

**Elston CA, et al:** Treatment of common skin infections and infestations during pregnancy. *Dermatol Ther* 2013; 26(4):312–320.

**Engelman D, et al:** Opportunities to investigate the effects of ivermectin mass drug administration on scabies. *Parasit Vectors* 2013; 6:106.

**FitzGerald D, et al:** Interventions for preventing the spread of infestation in close contacts of people with scabies. *Cochrane Database Syst Rev* 2014 Feb 24;2:CD009943.

**Ito T:** Mazzotti reaction with eosinophilia after undergoing oral ivermectin for scabies. *J Dermatol* 2013; 40(9):776–777.

**Kim J, et al:** Epidermolysis bullosa pruriginosa triggered by scabies infestation. *J Dermatol* 2013; 40(7):562–563.

**Shimose L, et al:** Diagnosis, prevention, and treatment of scabies. *Curr Infect Dis Rep* 2013; 15(5):426–431.

**Suwandhi P, Dharmarajan TS:** Scabies in the nursing home. *Curr Infect Dis Rep* 2015; 17:453.

## Order Scorpionidae

### Scorpion sting

Scorpions are different from other arachnids in that they have an elongated abdomen ending in a stinger (Fig. 20-53). They also have a cephalothorax, four pairs of legs, pincers, and mouth pincers. Two poison glands in the back of the abdomen empty into the stinger. Scorpions are found worldwide, especially in the tropics. They are nocturnal and hide during the daytime under tabletops and in closets, shoes, and folded blankets. Ground scorpions may burrow into gravel and children's sandboxes. Buthid scorpions include the most venomous species of medical importance. Important scorpions

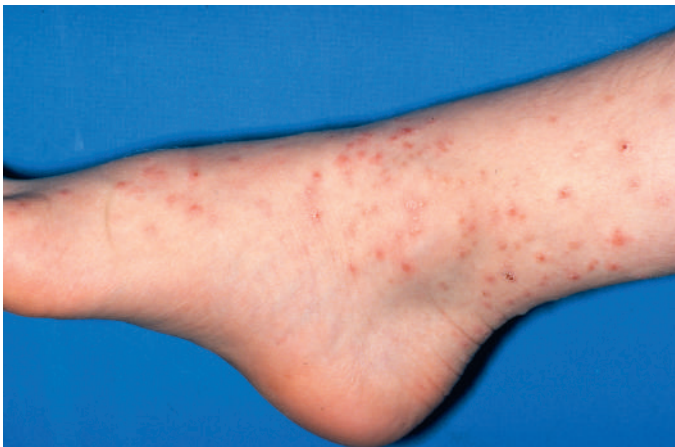

Fig. 20-52 Chigger bites.



Fig. 20-53 Common *Centruroides* scorpion.



include *Tityus serrulatus*, found in Brazil; *Buthotus tamulus*, in India; *Leiurus quinquestriatus* and *Androctonus crassicauda*, in North Africa and southwest Asia; and *Centruroides suffusus*, in Mexico. *Centruroides exilicauda* and *C. sculpturatus* are the most toxic scorpions in the United States. *Vaejovis* scorpions in the southeastern United States have been reported to cause “brown recluse–like” dermonecrotic reactions.

Scorpions sting only by accident or in self-defense. The venom causes pain, paresthesia, and variable swelling at the site. The sting of the Egyptian scorpion (*L. quinquestriatus*) has a mortality rate of 50% in children. The neurotoxic venom may produce numbness at the sting site, laryngeal edema, profuse sweating and salivation, cyanosis, nausea, and paresthesia of the tongue. There is minimal or no visible change at the sting site, and some studies have confirmed the typical absence of histologic inflammation. Death may occur from cardiac or respiratory failure, especially in children. Renal and hepatic toxicity may also occur.

Treatment depends on the species and toxic symptoms. Antiarrhythmics, antiadrenergic agents, vasodilators, and calcium channel blockers may be required. Antivenin is available for many species of scorpion.

**Fialho EM, et al:** Immune cells recruitment and activation by *Tityus serrulatus* scorpion venom. *Toxicon* 2011; 58(6-7):480–485.

## Order Arachnidae

### Arachnidism

Spiders are prevalent throughout the world. Most are beneficial to humans, trapping many insects, but a few species are dangerous. Many spider venoms are not well characterized, and in most cases of envenomation, the responsible spider is never identified. The Brazilian armed spider (*Phoneutria nigriventer*) is well characterized. Its venom contains neurotoxins that may be fatal in children. Various reactions to spider bites have been reported, including dermonecrotic reactions, systemic toxicity, and acute generalized exanthematous pustulosis.

### Latrodectism

The various species of *Latrodectus* have similar toxins and cause similar reactions in humans. The black widow spider, *Latrodectus mactans*, is of chief concern in the continental United States. It may also be found in the Caribbean region. Black widows are web-building spiders and are typically found in woodpiles and under outhouse seats. Their venom may be less potent than that of related brown widow spiders, but black widows inject more venom. *Latrodectus curacaviensis* is native to South America, and Australia and New Zealand have related red-back spiders (*Latrodectus mactans hasselti*). *Latrodectus indistinctus* is found in Africa, and the brown widow, *Latrodectus geometricus*, is native to southern Africa and Madagascar.

The female *L. mactans* spider is 13 mm long and shiny black, with a red hourglass-shaped marking on its abdomen (Fig. 20-54). The legs are long, with a spread of up to 4 cm. The black widow spider is not aggressive and bites only when disturbed. Severe pain usually develops within a few minutes and spreads throughout the extremities and trunk. Within a few hours, the victim may have chills, vomiting, violent cramps, delirium or partial paralysis, spasms, and abdominal rigidity. The abdominal pains are frequently most severe and may be mistaken for appendicitis, colic, or food poisoning. Toxic morbilliform erythema may occur. Myocarditis has also been reported.



**Fig. 20-54** Black widow.



**Fig. 20-55** Brown recluse spider.

Antivenin is indicated for severe symptoms of envenomation. Benzodiazepines reduce the associated tetany.

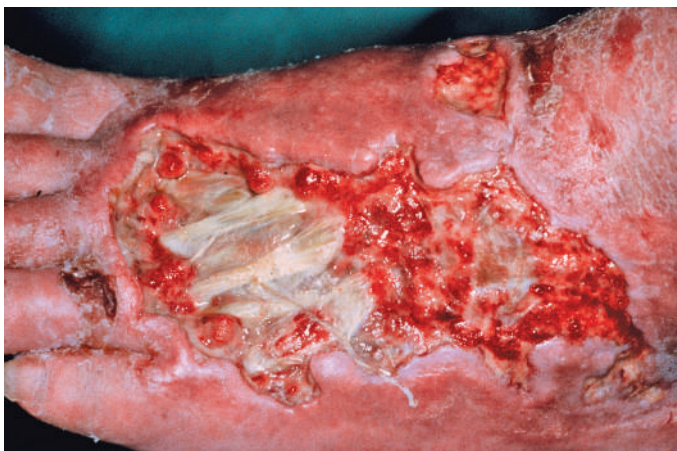### Loxoscelism

The brown recluse spider (*Loxosceles reclusa*) is the major cause of necrotic arachnidism in the United States (Fig. 20-55). It is most common in the lower Midwest and Southwest. This reclusive spider may be identified by a dark, violin-shaped marking over the cephalothorax and three sets of eyes, rather than the usual four. It is light brown and about 1 cm long, with a small body and long delicate legs. It is found in storage closets, basements, and cupboards and among clothing. Outdoors it has been found in woodpiles, in grass, on rocky bluffs, and in barns. It stings in self-defense and is not an aggressive spider. The incidence of brown recluse bites is grossly overestimated. *Loxosceles rufescens*, *L. deserta*, and *L. arizonica* cause lesser degrees of skin necrosis. *Loxosceles laeta*, *L. intermedia*, *L. gaucho*, and *L. similis* are found in Latin America and produce changes similar to those of *L. reclusa*. The venom contains a phospholipase enzyme, sphingomyelinase D, which is the major toxin. Hyaluronidase contributes to a gravity-dependent spread of the necrotic lesions.

In the localized type of reaction, known as necrotic cutaneous loxoscelism, extensive local necrosis develops (Fig. 20-56). A painful, severe edematous reaction occurs within the first 8 h, with development of a bulla with surrounding zones of erythema and ischemia. In about 1 week, the central portion becomes dark, demarcated, and gangrenous. Systemic loxoscelism is rare but may be associated with minor-appearing bite reactions. Systemic toxic symptoms are associated with disseminated intravascular coagulation.

### Treatment

Treatment of loxoscelism consists of rest, ice, and elevation. Tetanus toxoid should be given if the patient has not received



**Fig. 20-56** Brown recluse spider bite.

the immunization within 10 years. Some data suggest a trend toward better outcomes with injection of intralesional triamcinolone, with anecdotal reports of the injection site being spared necrosis but the areas above and below the site showing necrosis. Antibiotics and conservative debridement may be needed for necrotic wounds. Dapsone has been used, but some studies show that it is no better than placebo; dapsone also may be toxic, especially in the setting of venom-induced hemolysis. Colchicine has also been disappointing in animal models, but tetracyclines show some promise and deserve further study.

### Funnel web spiders

Funnel web spiders include *Tegenaria agrestis* (hobo spider or aggressive house spider of Pacific Northwest) and *Atrax robustus* (Sydney funnel web spider of Australia). Australian funnel web spiders are dangerous, but antivenin is available.

### Tarantulas (lycosidae: theraphosidae)

Tarantulas are large, hairy hunting spiders. American species have urticating hairs that produce cutaneous wheal and flare reactions and embed in the cornea, causing ophthalmia nodosa.

**Chatzaki M, et al:** Cutaneous loxoscelism caused by *Loxosceles similis* venom and neutralization capacity of its specific antivenom. *Toxicon* 2012; 60(1):21–30.

**Garza Ocañas L, et al:** Cutaneous loxoscelism. *N Engl J Med* 2013; 369(5):e6.

**Isbister GK, et al:** Spider bite. *Lancet* 2011; 378(9808):2039–2047.

**Malaque CM, et al:** Clinical picture and laboratory evaluation in human loxoscelism. *Toxicon* 2011; 58(8):664–671.

## PHYLUM CHORDATA

### Stingray injury

The two stingray families, Dasyatidae and Myliobatidae, are among the most venomous fish known to humans. Attacks generally occur as a result of an unwary victim stepping on a partially buried stingray. A puncture-type wound occurs about the ankles or feet and later ulcerates. Sharp, shooting pain develops immediately, with edema and cyanosis. Symptoms of shock may occur. Histologically, granulomatous dermatitis and panniculitis with necrosis have been reported.

Persons wading in shallow, muddy waters where stingrays may be found should shuffle their feet through the mud to frighten the fish away. Successful treatment is usually attained

by immersing the injured part in hot water for 30–60 min. The water should be as hot as can be tolerated, since the venom is detoxified by heat. Meperidine hydrochloride administered intravenously or intramuscularly may be necessary. If the ulcer remains unhealed after 8 weeks, excision is indicated.

### Snakebite

Bites by venomous snakes are a serious problem in some parts of the world. In the United States, the rattlesnake, water (cottonmouth) moccasin, copperhead, and coral snake are the venomous snakes most frequently encountered. Patients are usually young men, with 98% of bites on the extremities, most often the hands or arms. In Europe, 39% of envenomations from exotic pets are snakebites from rattlesnakes, cobras, mambas, or other venomous snakes. Almost 30 enzymes are found in snake venom, most of which are hydrolases. Snake venom has effects on the cardiovascular, hematologic, respiratory, and nervous systems. Severe envenomation may mimic brain death, with loss of other brainstem reflexes. Local effects at the bite site include the rapid onset of swelling, erythema, and ecchymosis. In more severe reactions, bullae and lymphangitis may appear. Fang marks are often visible and pain is common, except with Mojave rattlesnake bites. Antivenin is used in severe envenomation, and antitetanus measures are indicated. In the eastern United States, copperheads inflict most snakebites, followed by rattlesnakes and cottonmouths. Most of these children can be managed conservatively, although Crotalidae antivenin, antibiotics, and fasciotomy may be needed.

### Lizard bite

*Heloderma suspectum*, the Gila monster, is found chiefly in Arizona and New Mexico. Another venomous lizard is the beaded lizard of southwestern Mexico, *Heloderma horridum*. Bites from these poisonous lizards may cause paralysis, dyspnea, and convulsions. Systemic toxicity usually resolves spontaneously with supportive care within 1 or 2 days. Death is rare. There is no antivenin.

**Jarvis HC, et al:** Stingray injury to the webspace of the foot. *Orthopedics* 2012; 35(5):e762–e765.

**Tartar D, et al:** Clinical and histopathologic findings in cutaneous sting ray wounds: a case report. *Dermatol Online J* 2013; 19(8):19261.



Bonus images for this chapter can be found online at

[expertconsult.inkling.com](http://expertconsult.inkling.com)

**eFig. 20-1** New World leishmaniasis.

**eFig. 20-2** New World leishmaniasis.

**eFig. 20-3** New World leishmaniasis.

**eFig. 20-4** Leishmaniasis recidivans.

**eFig. 20-5** Mucocutaneous leishmaniasis. (Courtesy of James Fitzpatrick, MD.)

**eFig. 20-6** Disseminated cutaneous leishmaniasis.

**eFig. 20-7** Cutaneous larva migrans.

**eFig. 20-8** Dracunculosis.

**eFig. 20-9** Filarial elephantiasis.

**eFig. 20-10** Trichinosis.

**eFig. 20-11** Engorged bedbugs.

**eFig. 20-12** Human flea.

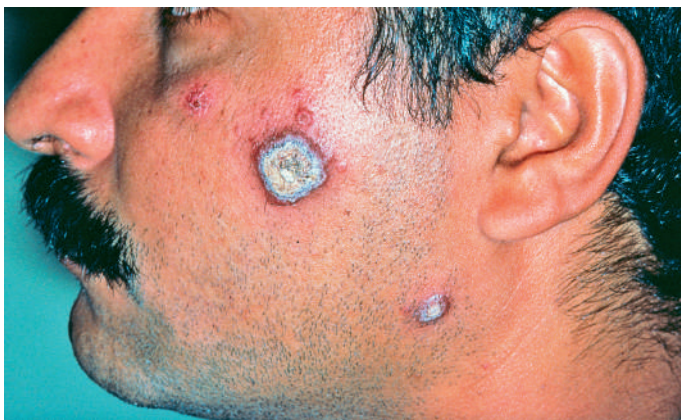**eFig. 20-13** Stick-tight flea.

**eFig. 20-14** *Rhipicephalus* tick, engorged female.

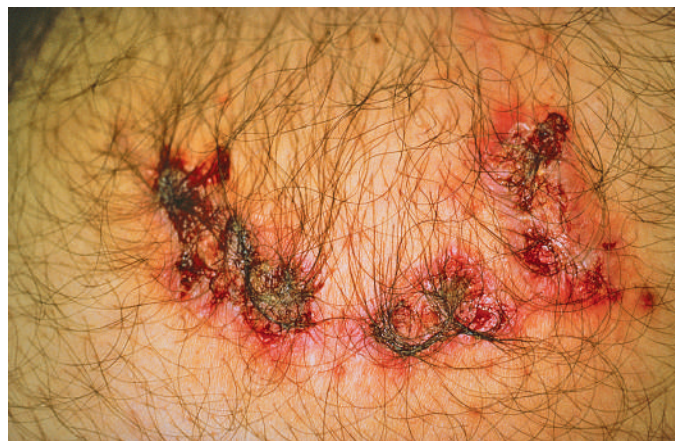**eFig. 20-15** Scabies.

**eFig. 20-16** Snakebite.

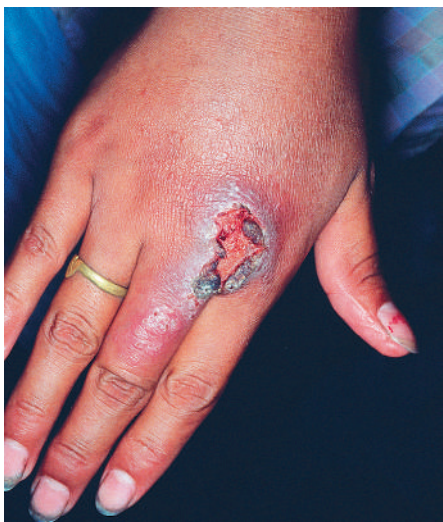



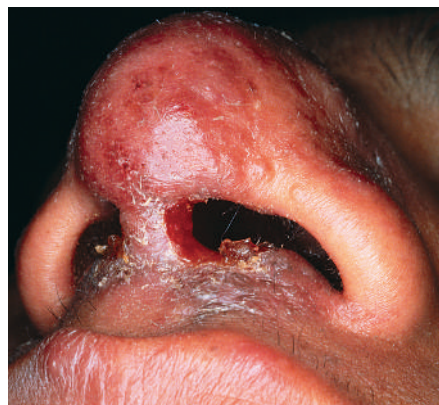eFig. 20-1 New World leishmaniasis.



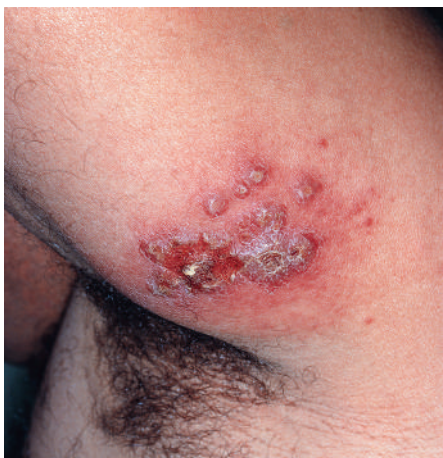eFig. 20-4 Leishmaniasis recidivans.



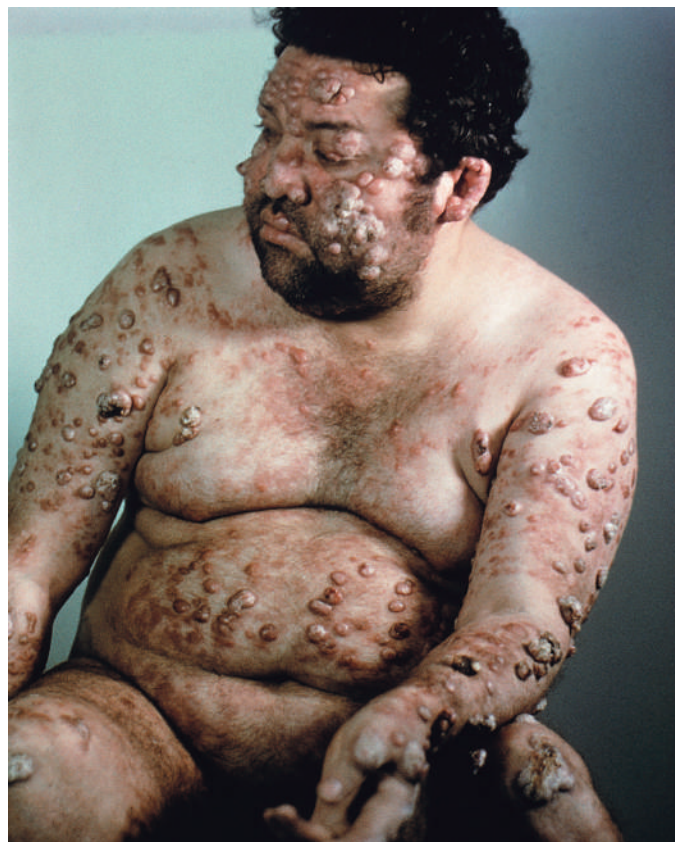eFig. 20-2 New World leishmaniasis.



eFig. 20-5 Mucocutaneous leishmaniasis. (Courtesy of James Fitzpatrick, MD.)

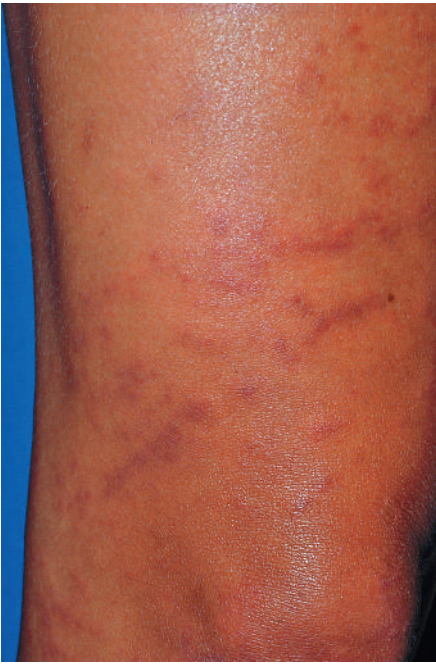

eFig. 20-3 New World leishmaniasis.

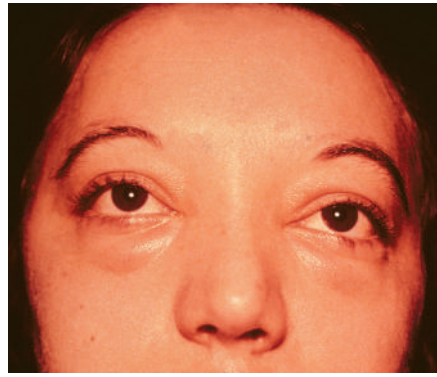


eFig. 20-6 Disseminated cutaneous leishmaniasis.

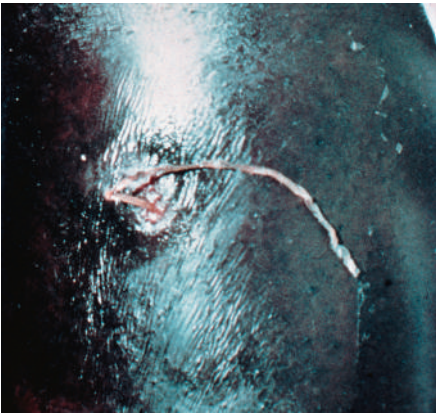




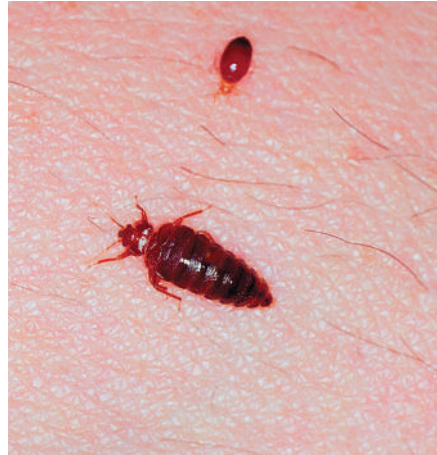eFig. 20-7 Cutaneous larva migrans.



eFig. 20-10 Trichinosis.



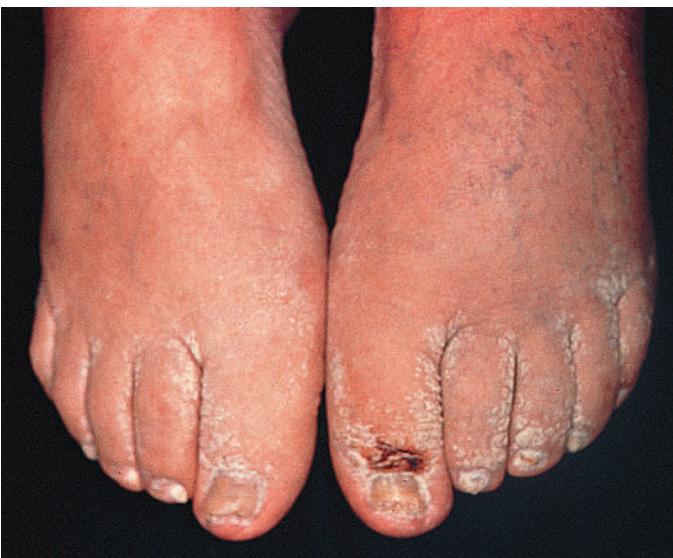eFig. 20-8 Dracunculosis.




eFig. 20-11 Engorged bedbugs.



eFig. 20-12 Human flea.



eFig. 20-9 Filarial elephantiasis.

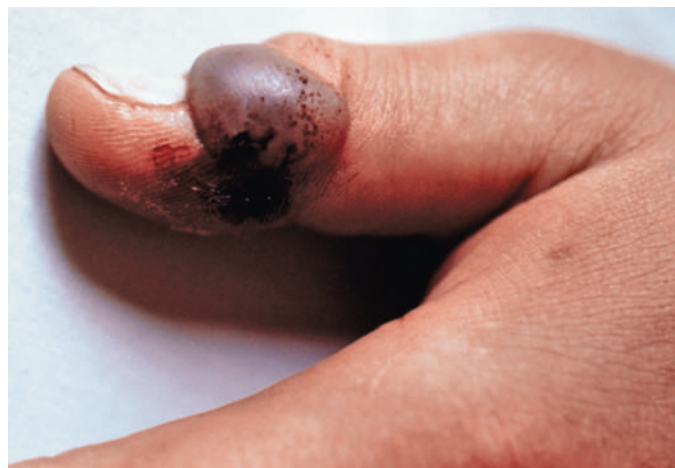

eFig. 20-13 Stick-tight flea.

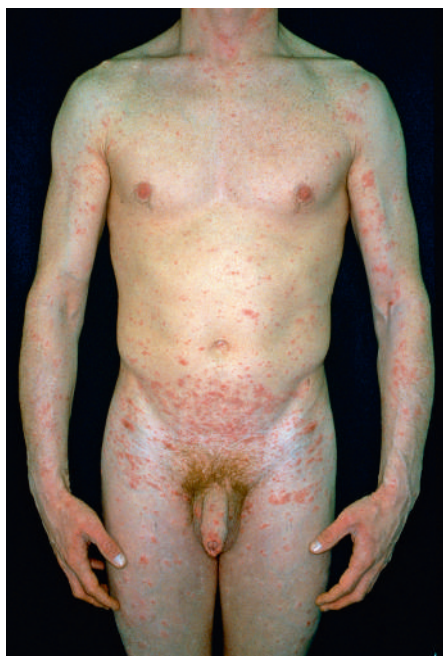



**eFig. 20-14**  
*Rhipicephalus* tick,  
engorged female.



**eFig. 20-16** Snakebite.



**eFig. 20-15** Scabies.

## Chronic Blistering Dermatoses

In noninherited chronic blistering (vesicular or bullous) dermatoses, the cause of blistering is usually an autoimmune reaction, and the pattern of immunofluorescence is critical in establishing the diagnosis. Usually, antibodies are bound in perilesional and nonbullous lesional skin, whereas blistered skin often fails to demonstrate deposits. Lower extremity skin should be avoided, if possible, because it may be prone to false-negative reactions.

Salt-split-skin preparations are useful in determining the site of deposition of the autoantibodies. A 1M solution of sodium chloride (NaCl) predictably splits skin at the level of the lamina lucida. Localization of immune deposits to the roof or floor of this split is diagnostically useful. The identification of n-serrated and u-serrated patterns of immunoglobulin deposition provides the same information and may make salt-split-skin immunofluorescence unnecessary in many cases. An n-serrated pattern corresponds to a split above the basal lamina, whereas a u-serrated pattern corresponds to a sub-lamina densa split (see images on ExpertConsult). The patterns are best seen in areas where the basement membrane zone (BMZ) curves. Immunoprecipitation, enzyme-linked immunosorbent assay (ELISA), and immunoblotting have helped to define the molecular targets of the autoantibodies and have revolutionized testing for immunobullous diseases. Data vary concerning the sensitivity and specificity of these tests. In the setting of bullous pemphigoid, ELISA can produce apparent false-positive results at rates of 7% or higher, based on non-NC16a antibodies, as well as on anti-BP 180 antibodies that bind to the pathogenic NC16a domain but do not produce clinical disease and are not associated with positive indirect immunofluorescent findings. False-negative results also occur and are discussed below.

Transient acantholytic dermatosis (Grover's disease) is an idiopathic nonimmune vesiculobullous disease that may mimic the histologic patterns of immunobullous disease, but shows no specific findings on direct immunofluorescence (DIF). Specific dermatoses of pregnancy are discussed under the differential diagnosis of herpes gestationis.

The outlook for immunobullous diseases has improved since the introduction of rituximab, intravenous immunoglobulins, and less toxic immunosuppressive regimens. Oral and ocular involvement often requires a multidisciplinary approach.

**Arbache ST, et al:** Immunofluorescence testing in the diagnosis of autoimmune blistering diseases: overview of 10-year experience. *Ann Bras Dermatol* 2014; 89:885–889.

**Braunstein I, et al:** Treatment of dermatologic connective tissue disease and autoimmune blistering disorders in pregnancy. *Dermatol Ther* 2013; 26(4):354–363.

**Fine JD:** Prevalence of autoantibodies to bullous pemphigoid antigens within the normal population. *Arch Dermatol* 2010; 146(1):74–75.

**Segura S, et al:** High-dose intravenous immunoglobulins for the treatment of autoimmune mucocutaneous blistering diseases: evaluation of its use in 19 cases. *J Am Acad Dermatol* 2007; 56(6):960–967.

### PEMPHIGUS VULGARIS

#### Clinical features

Pemphigus vulgaris (PV) is characterized by mucosal erosions and by thin-walled, relatively flaccid, easily ruptured bullae that appear on apparently normal skin and mucous membranes or on erythematous bases (Fig. 21-1). The fluid in the bulla is clear at first but may become hemorrhagic or even seropurulent. The bullae rupture to form erosions. The denuded areas soon become partially or totally covered with crusts that have little or no tendency to heal. When they finally heal, lesions often leave hyperpigmented patches but no scarring.

Usually, PV appears first in the mouth (60% of cases; Fig. 21-2) or at the site of a burn, radiation therapy, or other skin injury. Other common sites include the groin, scalp, face, neck, axillae, and genitals. Nikolsky's sign is present (intact epidermis shearing away from underlying dermis, leaving a moist surface). The sign is elicited by slight pressure, twisting, or rubbing. The "bulla-spread phenomenon" (Asboe-Hansen sign) is elicited by pressure on an intact bulla, gently forcing the fluid to spread under the adjacent skin.

Short-lived bullae quickly rupture to involve most of the mucosa with painful erosions. The lesions extend onto the lips and form heavy, fissured crusts on the vermilion. Involvement of the throat produces hoarseness and difficulty in swallowing. The mouth odor is offensive. The esophagus may be involved, and sloughing of its entire lining in the form of a cast (esophagitis dissecans superficialis) may occur, even when the cutaneous disease appears to be well controlled because mucosa lacks desmoglein 1 and depends entirely on desmoglein 3. The conjunctiva, nasal mucosa, vagina, penis, and anus may also be involved. Chronic lesions may involve the face, scalp (Fig. 21-3), or flexures. Widespread cutaneous disease may cause death through sepsis or fluid and electrolyte imbalance (Fig. 21-4).

The diagnosis is made by histology, immunofluorescence pattern of perilesional skin or plucked hairs, indirect immunofluorescence (IIF) testing of serum, or ELISA testing for anti-desmoglein 1 (Dsg1) and anti-Dsg3 autoantibodies. As in other autoimmune diseases, specific antibodies may be present in relatives of patients with pemphigus who do not manifest signs of disease.

#### Epidemiology

Pemphigus vulgaris occurs with equal frequency in men and women, usually in the fifth and sixth decades of life. It is rare in young persons. PV occurs more often in Jewish people and those of Mediterranean descent.



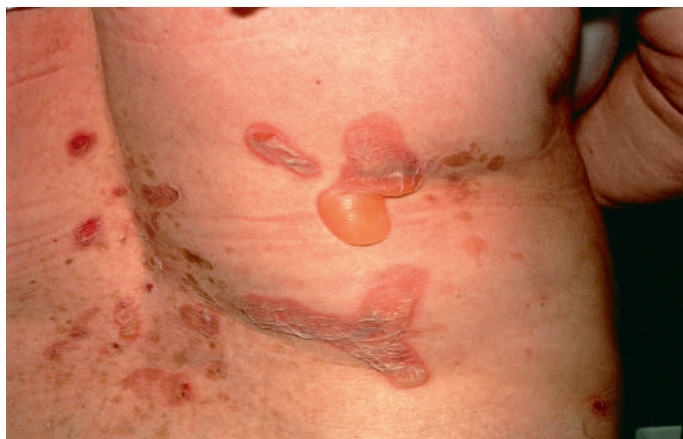

Fig. 21-1 Pemphigus vulgaris. (Courtesy of Dr. Lawrence Lieblich.)

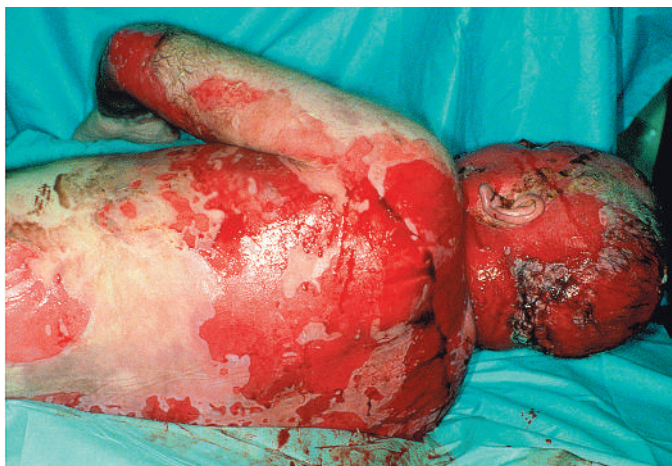

Fig. 21-4 Pemphigus vulgaris.

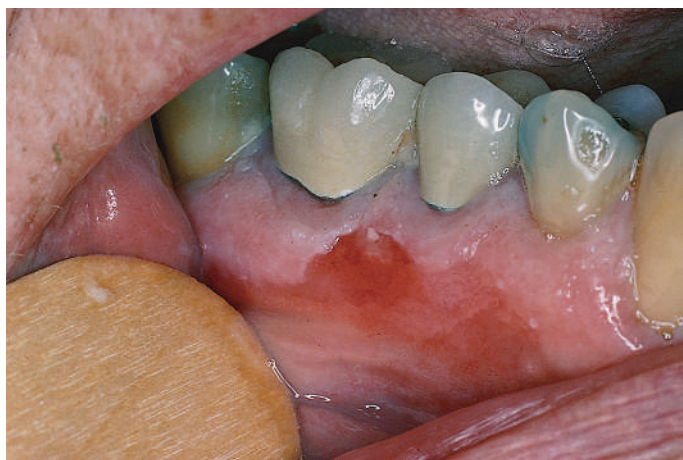

Fig. 21-2 Oral pemphigus vulgaris.

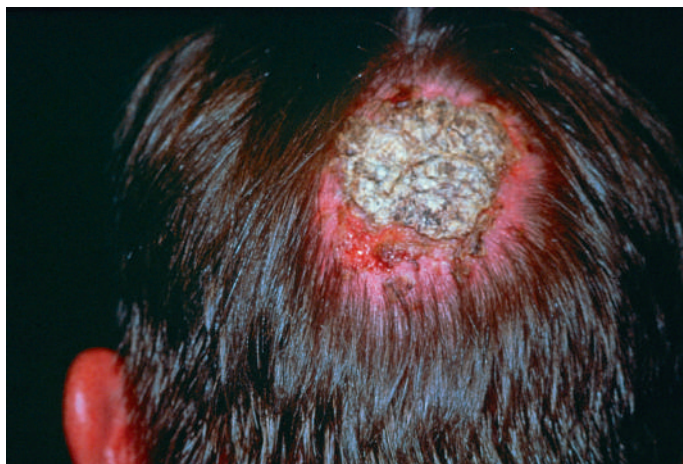

Fig. 21-3 Chronic pemphigus vulgaris of the scalp.

### Etiologic factors

Antibodies in PV are most often directed against Dsg3. The presence of antibodies to both Dsg1 and Dsg3 correlates with mucocutaneous disease. If autoantibodies are only directed against Dsg3, mucosal lesions predominate. Both humoral and cellular autoimmunity are important in the pathogenesis of skin lesions. Antibody alone can produce acantholysis, without complement or inflammatory cells. Both IgG1 and IgG4

autoantibodies to Dsg3 occur in patients with pemphigus, but some data suggest that the IgG4 antibodies are pathogenic. Plasminogen activator is associated with antibody-mediated acantholysis. Involved T cells are usually CD4 cells that secrete a T-helper type 2 (Th2)-like cytokine profile, although Th1 cells may also be involved in antibody production in chronic disease. IgG is found in both involved and clinically normal skin. C3 deposits are heavier in acantholytic areas. DIF may remain positive for years after clinical remission, and conversion to negative predicts sustained remission after withdrawal of therapy. Pemphigus may be associated with myasthenia gravis and thymoma.

The PV antigen (130-kD transmembrane desmosomal glycoprotein) shows homology with the cadherin family of calcium-dependent cell adhesion molecules. With IIF, circulating antibodies can be demonstrated in 80–90% of patients. Circulating intercellular antibodies may also be present in patients with thermal or actinic burns and in patients with drug eruptions. These antibodies are not directed against Dsg3. They do not bind to the epidermis *in vivo* and are often directed against ABO blood-group antigens.

Penicillamine treatment of rheumatoid arthritis has induced pemphigus, most often of the foliaceous type. Almost all the reported cases have had a positive DIF, and more than half have had a positive IIF. Penicillamine and captopril may induce acantholysis in organ explant cultures in the absence of autoantibody. The doses responsible for induction of disease have ranged from 250 to 1500 mg/day, and the drugs were taken for an average of 13 months before the onset of pemphigus. A long list of drugs, including captopril, enalapril, penicillin, thioprolin, interleukin-2 (IL-2), nifedipine, piroxicam, and rifampicin, has also been reported to induce pemphigus. Many of these contain either a sulfhydryl or an amide group. Only 10–15% of patients with drug-induced pemphigus have had oral lesions. Most disease resolves when the medication is discontinued, but some cases have persisted for many months.

Many studies have indicated a genetic predisposition to pemphigus and an association with other autoimmune diseases. Statistical analysis shows a skewed distribution of various human leukocyte antigens (HLAs). Most patients are of HLA phenotype DR4 or DR6. In addition, an HLA-DQ restriction fragment has been identified in many patients with pemphigus. HLA-G is associated with pemphigus in Jewish patients. Thus, there may be a genetically inherited susceptibility to the disease. Additionally, a predisposition to develop other autoimmune diseases may occur in relatives of pemphigus patients.

## Histopathology

The characteristic findings of PV consist of suprabasilar acantholysis with intraepidermal blister formation. Acantholytic cells are round and show no intercellular bridges. Regeneration of the epidermis occurs and may cause the split to appear to be higher as cells regenerate beneath the cleft. At least some areas typically still demonstrate the characteristic “tombstone row” of basal keratinocytes underneath the bulla. An early intact bulla shows the most characteristic histology. Asboe-Hansen modification of Nikolsky’s test may be used to extend the bulla beyond its original margin to where secondary regenerative changes have not taken place.

In early disease, spongiosis with eosinophils may be noted in the epidermis, in the absence of acantholysis. In the setting of immunobullous disease, spongiosis with eosinophils is more likely to represent pemphigoid than pemphigus, and immunofluorescent findings readily distinguish the two. DIF demonstrates a “chicken wire” pattern of intercellular IgG in perilesional skin or plucked hairs. C3 may also be present. The staining is uniform, not granular. IIF shows a similar pattern of staining. Prozone reactions occur, so the serum should be tested at a wide range of dilutions. Positive tests may be confirmed with ELISA for the antibody.

## Treatment

Large-scale, prospective, double-blinded studies are few, and the management of PV is based largely on smaller, open trials and clinical experience. A survey of 24 experienced clinicians showed that half used prednisone in doses of 1 mg/kg/day and half used higher doses. Adjuvant steroid-sparing agents were frequently employed, with almost half the respondents reporting the use of azathioprine. Because of its tolerability and simpler dosing schedule, mycophenolate mofetil (MMF) is often used in place of azathioprine. Other agents used less frequently include cyclophosphamide and methotrexate. Almost 40% of the clinicians aimed to replace prednisone with a steroid-sparing agent, whereas others were content to continue a low dose of prednisone. The survey suggests that, even among the world’s experts, there is significant variation in how this difficult disease is managed. Rituximab and intravenous immune globulin (IVIG) therapy have produced dramatic responses in some patients with refractory disease, and some authorities now consider rituximab appropriate first-line therapy for patients with severe disease.

Most agents used to treat the disease are immunosuppressive, although the mechanism of action may not merely be suppression of T cells and antibody production. Methylprednisolone can directly block pemphigus antibody-induced acantholysis. It also upregulates expression of the genes encoding Dsg3 and periplakin; increases measurable levels of E-cadherin, Dsg1, and Dsg3; and interferes with phosphorylation of these adhesion molecules. Many of these effects antagonize those of pemphigus antibodies. Reversion of DIF to negative predicts sustained remission after withdrawal of medication. Plucked hairs are an alternative to skin biopsy to provide a specimen for immunofluorescence; the pilar sheath epithelium of the anagen hair typically demonstrates immunofluorescence comparable to skin.

## Topical treatment

The skin lesions are extremely painful in advanced cases. When there are extensive raw surfaces, prolonged daily baths are helpful in removing the thickened crusts and reducing the foul odor. Silver sulfadiazine (Silvadene) 1%, widely used for

local therapy of burns, is an effective topical antimicrobial agent, suitable for treatment of limited disease. Silver nitrate-impregnated cotton batting, manufactured for burn units, can be used in more extensive disease. Very localized areas can be treated with silver nitrate-impregnated dressings. Painful ulcerations of the lips and mouth may benefit from topical application of a mixture of equal parts of simethicone (Maalox) and elixir of diphenhydramine hydrochloride (Benadryl) or viscous lidocaine (Xylocaine), especially before meals. The various commercial antiseptic mouthwashes are helpful in alleviating discomfort and malodor. Potent topical corticosteroids and topical tacrolimus have been successful in some patients with limited disease. The likelihood of complete remission is correlated with age of onset and initial mucosal involvement. Infection is a common complication and relates to severity of the pemphigus and the presence of diabetes mellitus.

## Systemic therapy

A common method of treatment for severe PV is to begin with doses of prednisone adequate to control the disease. High doses of prednisone (100–150 mg) are sometimes needed, but prolonged high doses are associated with significant morbidity and mortality, so adjuvant therapy should be started early. During the early phase of therapy, if prednisone at 1 mg/kg/day proves inadequate, the drug is usually increased to a split dose of 1 mg/kg twice daily. As the course of corticosteroid therapy is typically longer than initially anticipated, it is good practice to begin vitamin D, calcium, weight-bearing exercise, and bisphosphonate therapy early in the course of treatment. Common agents include alendronate, 70 mg/wk; risedronate, 35 mg/wk or 150 mg/mo; ibandronate, 150 mg/mo; teriparatide, 20 µg/d; or zoledronic acid, 5 mg infusion yearly.

Mycophenolate mofetil is usually chosen as a steroid-sparing agent, at a dose of 1–1.5 g twice daily. Gastrointestinal (GI) intolerance is the most common side effect, and blood counts must be monitored. If the disease does not respond, either plasmapheresis or IVIG is added to the regimen. Azathioprine is less expensive than MMF and is often used as an alternative when cost is an overriding issue. Azathioprine is best dosed based on measurement of the patient’s thiopurine methyltransferase (TPMT) level. Most patients metabolize the drug quickly and may be underdosed if TPMT is not measured. Patients with high levels of the enzyme may require 2.5–3 mg/kg/day of azathioprine; patients with midrange levels are treated with 1–2.5 mg/kg/day. Patients deficient in TPMT may be treated with very low doses of azathioprine or with a different agent. Allopurinol interferes with metabolism of azathioprine, and increased serum levels may lead to toxicity.

Patients with refractory disease may be treated with rituximab, IVIG, or cyclophosphamide, either alone or with plasmapheresis. Plasmapheresis alone is followed by rebound of antibody production, but the rebounding clone of plasma cells is sensitized to the effects of cytotoxic agents. Both daily cyclophosphamide dosing and pulse dosing schedules can be used alone or in combination with dexamethasone. Pulse dosing is usually given with mesna rescue and is associated with less bladder toxicity. Both dosing schedules should be planned early in the day, with vigorous hydration to minimize the risk of bladder toxicity. Blood counts must be monitored closely. Other risks of therapy with high doses of corticosteroids and immunosuppressants include diabetes, infection, hypertension, and cardiorespiratory disease. All these risks must be monitored, and all patients must receive gentle wound care and fluid and electrolyte management. In patients who cannot tolerate cyclophosphamide, chlorambucil has been used, but it is associated with a greater risk of hematologic malignancy.



Immunoabsorption represents a novel approach to therapy that could replace plasmapheresis. In addition to the use of IVIG as an adjuvant to conventional therapy, it has also been given as monotherapy. Onset of action is fairly rapid and may be seen within 1–2 weeks. There is a trend toward using rituximab early in the course of treatment if patients have significant disease.

The sooner the diagnosis of PV is established and the sooner treatment is given, the more favorable the prognosis. The therapeutic effects are estimated by the number of new lesions per day and the rate of healing of new lesions. In patients with and Dsg3 antibodies, mucosal disease may still be active when cutaneous disease appears to be in remission. Pemphigus antibody titers can be performed on esophageal substrate, watching for a fall in titer. If, after 4–8 weeks of treatment, new blister formation is not suppressed, prednisone dosage may be increased to 150 mg/day. Dosage adjustments are made more frequently and aggressively in severe, progressive disease. Dividing the daily dose will usually result in greater efficacy but will also result in greater adrenal suppression. Additionally, intravenous pulse therapy with megadose corticosteroids, such as methylprednisolone (Solu-Medrol), at a dose of 1 g/day over 2–3 h, repeated daily for 5 days, may be employed for patients unresponsive to oral doses. Untreated disease is often fatal, but the clinician should remember that, in treated patients, side effects of therapy are the most common cause of death. Adjuvant therapy to decrease steroid dependence has reduced mortality.

Medication is continued until clinical disease is suppressed and pemphigus antibody disappears from the serum. Once the antibody is no longer present, a DIF test is repeated. A negative DIF is predictive of sustained remission after withdrawal of therapy.

Immunosuppressant therapy alone has been reported as a successful treatment of patients with early, stable PV. If a contraindication to the use of corticosteroids exists, or if only limited disease is present, these may be used as single agents. In general, however, combined treatment with corticosteroids is superior in gaining early control of the disease. Dexamethasone-cyclophosphamide therapy was studied in 32 patients with PV. Monthly pulses consisted of IV dexamethasone, 136 mg for 3 consecutive days monthly, with IV cyclophosphamide, 500 mg, on the second day. Daily oral cyclophosphamide, 50 mg, and oral tapered courses of oral corticosteroids were given in the intervals between the pulses. All patients responded. Partial remissions were noted after 2–8 pulses; 8–32 pulses were required to achieve complete remission. The duration of pulsed therapy correlated with both the disease severity and the time to achieve remission. Oral cyclophosphamide was successful in 17 of 20 patients who had failed therapy with prednisone and an antimetabolite. The median time to achieve complete remission was 8.5 months, and the median duration of treatment was 17 months. Plasmapheresis was used in nine patients. Hematuria developed in five patients, and infections were noted in six. One patient developed bladder cancer 15 years after therapy.

Intramuscular or oral gold is no longer commonly used. Gold is less effective than immunosuppressive therapy, but its advantages include lack of carcinogenicity and infertility. A minimum of 6 months is required to judge the effectiveness of gold therapy. Rituximab, an anti-CD20 monoclonal antibody, has been used successfully, but may be associated with serious infections and progressive multifocal leukoencephalopathy. Extracorporeal photochemotherapy has been used in a few patients, and dapsone may have some value as a steroid-sparing agent. Nicotinamide and tetracycline can be tried in patients with milder disease; in one study, this was successful in two of six patients, but in another, only successful in 1 of

10 patients. Data on the effectiveness of cyclosporine have been mixed. Etanercept and infliximab have been used successfully in some patients.

## PEMPHIGUS VEGETANS

Pemphigus vegetans may present as localized plaques in the scalp or in two classic forms, the Neumann type, which generally begins and ends as typical pemphigus, and the Hallopeau type, which usually remains localized. Both types show pseudoepitheliomatous hyperplasia, and the Hallopeau type is characterized by eosinophil microabscesses within the epidermis.

Pemphigus vegetans may begin with flaccid bullae that become erosions and form fungating vegetations or papillomatous proliferations, especially in body folds or on the scalp. The tongue often shows cerebriform morphologic features early in the course of the disease. At times, the lesions tend to coalesce to form large patches or to arrange themselves into groups or figurate patterns.

The laboratory findings, etiologic factors, epidemiology, pathogenesis, and treatment of pemphigus vegetans are the same as those for pemphigus vulgaris. Captopril-induced pemphigus vegetans has been reported.

Pemphigus vegetans must be differentiated from other conditions characterized by pseudoepitheliomatous hyperplasia and microabscesses, including halogenoderma, chromoblastomycosis, blastomycosis, granuloma inguinale, blastomycosis-like pyoderma, condyloma lata, and amebic granulomas. The Hallopeau type is distinguished by the presence of eosinophils, and both types by immunofluorescent findings.

**Alexandru A, et al:** Direct immunofluorescence on hair follicles: present and future perspectives. *Am J Dermatopathol* 2013; 35(4):472–476.

**Almugairen N, et al:** Assessment of the rate of long-term complete remission off therapy in patients with pemphigus treated with different regimens including medium- and high-dose corticosteroids. *J Am Acad Dermatol* 2013; 69(4):583–588.

**Atzmony L, et al:** Treatment of pemphigus vulgaris and pemphigus foliaceus: a systematic review and meta-analysis. *Am J Clin Dermatol* 2014; 15:503–515.

**Kalantari-Dehaghi M, et al:** Mechanisms of mitochondrial damage in keratinocytes by pemphigus vulgaris antibodies. *J Biol Chem* 2013; 288(23):16916–16925.

**Kamran B, et al:** Adjuvant rituximab in the treatment of pemphigus vulgaris: a Phase II clinical trial. *Int J Dermatol* 2013; 52(7):862–867.

**McCarty M, Fivenson D:** Two decades of using the combination of tetracycline derivatives and niacinamide as steroid-sparing agents in the management of pemphigus: defining a niche for these low toxicity agents. *J Am Acad Dermatol* 2014; 71:475–479.

**Rao R, et al:** Monitoring the disease activity in pemphigus by direct immunofluorescence of plucked hair: a pilot study. *Indian J Dermatol* 2013; 58(2):164.

**Ruocco E, et al:** Pemphigus: associations and management guidelines—facts and controversies. *Clin Dermatol* 2013; 31(4):382–390.

**Ruocco V, et al:** Pemphigus: etiology, pathogenesis, and inducing or triggering factors—facts and controversies. *Clin Dermatol* 2013; 31(4):374–381.

**Sharma VK, et al:** Evaluation of cyclophosphamide pulse therapy as an adjuvant to oral corticosteroid in the management of pemphigus vulgaris. *Clin Exp Dermatol* 2013; 38(6):659–664.

## PEMPHIGUS FOLIACEUS

Pemphigus foliaceus (PF) is characterized by flaccid bullae and localized or generalized exfoliation. Antibodies target Dsg1. Lesions start as small, flaccid bullae that rupture almost as they appear, leading to crusting. Below each crust is a moist

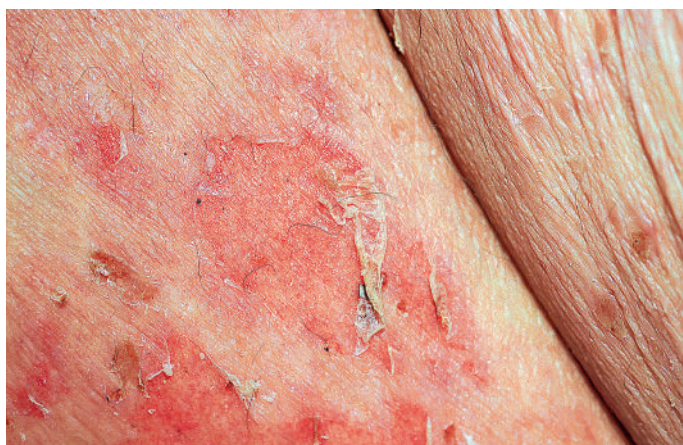

Fig. 21-5 Pemphigus foliaceus.

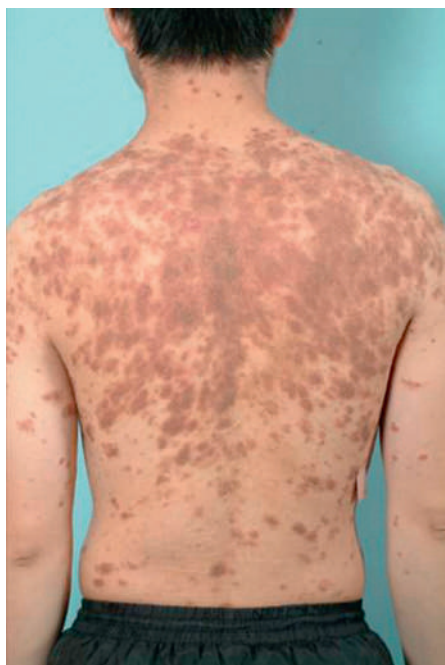

Fig. 21-6 Pemphigus foliaceus.

surface with a tendency to bleed. Nikolsky's sign may be easily elicited by rubbing the skin (Fig. 21-5). After a time, the exfoliative characteristics predominate, with few bullae (Fig. 21-6). Adherent scale crusts may resemble corn flakes. A variant of pemphigus that has clinical features suggestive of dermatitis herpetiformis but has immunologic features of pemphigus has been called herpetiform pemphigus. Most of these patients represent a clinical variant of PF, with the remainder being pemphigus vulgaris (PV) patients. A few have also demonstrated desmocollin antibodies.

Nikolsky's sign is present in PF. Oral lesions are rarely seen, and then only as superficial erosive stomatitis. This may be because Dsg3, present throughout the epithelium, is unaltered in PF and provides enough adherence to maintain clinical integrity. Several patients have been described whose clinical picture shifted from PF to PV, or vice versa, with an accompanying change in antibody profile.

Most patients with PF are not severely ill. They complain of burning, pain, and pruritus. The lesions may persist for many years without affecting general health. PF occurs mostly in adults age 40–50 but has also been reported in children. The genders are affected equally. Prevalence of PF in people of Jewish heritage is much less than with PV. The drugs listed under PV more frequently induce PF.

The principal histologic finding in PF consists of acantholysis in the upper epidermis, usually in the granular layer. The stratum corneum may be missing entirely or separated from the underlying epidermis. Individual elongated acantholytic cells are noted above the epidermis or clinging to the underside of the stratum corneum. DIF demonstrates intercellular IgG throughout the epidermis, although the deposits may be somewhat more prominent in the upper epidermis. IIF is positive in most patients, although prozone reactions occur and a wide range of dilutions should be tested. A sensitive and specific ELISA for detecting antibodies to Dsg1 is now available to confirm positive IIF results.

Patients with a distinct clinical picture of PF or PV may have a mix of antibodies. Western blot has shown Dsg1 in about 86% of PF patients and 25% of PV patients. ELISA has shown anti-Dsg1 antibodies in up to 71% of PF patients and 62% of PV patients. In one study, antibodies to Dsg3 were detected in 19 of 276 patients with PF and fogo selvagem who had only cutaneous disease. The antibody was capable of producing disease in laboratory animals, suggesting it was pathogenic in the PF patients. Therefore, ELISA studies must always be interpreted in the context of clinical, histologic, and immunofluorescent findings. In PV, Dsg3 mediates mucosal disease, and cutaneous disease is associated with antibodies to Dsg1. A shift to predominantly Dsg1 antibodies has accompanied a clinical shift from PV to PF. Patients have also shifted from a pemphigus to a pemphigoid phenotype.

Dsg1, the antigen in PF, was first identified by immunoprecipitation consisting of polypeptides of molecular weight 260, 160, and 85 kilodaltons (kD). The 260-kD molecule is a complex of the 160-kD and 85-kD polypeptides. The PF antibody binds to a 160-kD glycoprotein extracted from normal epidermis. This glycoprotein is identical to Dsg1. The 85-kD glycoprotein is plakoglobin, a desmosomal and adherens junction-associated molecule. Desmogleins are cadherin-type adhesion molecules found in desmosomes. The N-terminal extracellular domain of Dsg1 contains the dominant autoimmune epitopes in both PF and PV. Antibodies include both IgG1 and IgG4 subclasses. IgG4 antibodies appear to be pathogenic in most patients. In a subset of patients, IgG1 autoantibodies are pathogenic. E-cadherin autoantibodies often cross-react with Dsg1.

## Treatment

Treatment of PF is similar to that for PV, and the two diseases often require similarly aggressive treatment. In fact, many clinical trials include patients with both diseases. PF patients are generally less ill and may not need oral corticosteroid therapy. Dapsone and hydroxychloroquine may be useful, either alone in mild cases or to reduce the steroid dose level. Very mild disease may be treated with topical corticosteroids or topical calcineurin inhibitors. Nicotinamide and tetracycline may be more effective than in PV. Azathioprine, MMF, or cyclophosphamide may be needed, as in PV. The anti-CD20 antibody rituximab, the anti-IL6 receptor antibody tocilizumab, IVIG, and immunoablative high-dose cyclophosphamide without stem cell rescue have been used for refractory disease. Etanercept has been used, and immunoabsorption with tryptophan-linked polyvinyl alcohol adsorbers or adsorption with plant lectins, such as wheat germ agglutinin, has been effective and holds promise as adjuvant therapy.

## ENDEMIC PEMPHIGUS (FOGO SELVAGEM)

Endemic pemphigus is found in tropical regions, mostly in certain interior areas of Brazil and Colombia, but also in North



Africa, including Tunisia. Fifteen percent of cases are familial. The disease is common in children, adolescents, and young adults, with about one third of cases occurring before age 20 and two thirds by 40 years. The initial lesions may be flaccid bullae, but later lesions are eczematoid, psoriasiform, impetiginous, or seborrheic in appearance. The midfacial areas may be involved. Melanoderma and verrucous vegetative lesions are not unusual, and exfoliative dermatitis may occur. The mucous membranes usually are not involved. Nikolsky's sign is present. The disease is often seen in those with arthropod exposure and may be initiated by an infectious agent, possibly carried by mosquitoes or black flies.

Histologically and immunohistologically, fogo selvagem is identical to PF. As with PF, antibodies to desmosomal cadherins and E-cadherin may be present. The anti-Dsg1 autoantibodies cross-react with sandfly salivary LJM11 antigen. Endemic pemphigus has also been linked to the kissing bug *Triatoma matogrossensis* and to mercury poisoning. Peripheral blood mononuclear cells from patients produce more IL-1 $\beta$  than those from healthy controls. A strong Th2 bias is also observed. IgM anti-Dsg1 antibodies are common in fogo selvagem, but not in other forms of pemphigus.

A distinct subset has been described in a rural area in north-eastern Colombia. This subset differs from previously described forms of endemic pemphigus and shares some immunoreactivity with paraneoplastic pemphigus. It is not, however, associated with malignant tumors. Clinically, the disease resembles Senear-Usher syndrome. A systemic form may affect internal organs and has a poorer prognosis. All patients appear to have antibodies to Dsg1. In addition, many sera react with desmoplakin I, envoplakin, and periplakin. Direct immunofluorescence is noted in the pilosebaceous unit, adjacent neurovascular bundles and meibomian glands.

A few Brazilian sera also react with plakins. None of the Colombian patients' sera reacted with Dsg3, but about half of Brazilian patients' sera reacted with Dsg3. This area of Colombia is a mining region, and the population is exposed to high environmental levels of mercuric sulfides and selenides; these compounds have been found in the skin of patients with endemic pemphigus.

### PEMPHIGUS ERYTHEMATOSUS (SENEAR-USHER SYNDROME)

In Senear-Usher syndrome, the early lesions are circumscribed patches of erythema and crusting that clinically resemble lupus erythematosus and are immunopathologically positive for the lupus band in 80% of patients. The lesions are erythematous and thickly crusted, bullous, or even hyperkeratotic. These are usually localized on the nose, cheeks, and ears, sites frequently affected by lupus erythematosus. In addition, crusting and impetiginous lesions appear amid bullae on the scalp, chest, and extremities. In most patients, the disease runs an indolent course. Cefuroxime-induced disease has been described.

The histopathology of pemphigus erythematosus is that of PF. DIF shows IgG and complement localized in both intercellular and BMZ sites. At the dermoepidermal junction (DEJ), the deposits are continuous and granular, as in lupus. In the epidermis, they resemble those of pemphigus. Antinuclear antibody is present in low titer in 30% of patients. Patients have demonstrated anti-Dsg1 but not anti-Dsg3 autoantibodies. Additional autoantibodies may be directed against bullous pemphigoid antigen 1 (BP230) and periplakin. Patients often respond to low doses of prednisone and may respond well to topical corticosteroids and sunscreens. Immunosuppressants may be needed in severe cases.

**Aoki V, et al:** Pathogenesis of endemic pemphigus foliaceus. *Dermatol Clin* 2011; 29(3):413–418.

**Assumpção TC, et al:** An insight into the sialotranscriptome of *Triatoma matogrossensis*, a kissing bug associated with fogo selvagem in South America. *Am J Trop Med Hyg* 2012; 86(6):1005–1014.

**Atzmony L, et al:** Treatment of pemphigus vulgaris and pemphigus foliaceus: a systematic review and meta-analysis. *Am J Clin Dermatol* 2014; 15:503–515.

**Baroni A, et al:** Cefuroxime-induced pemphigus erythematosus in a young boy. *Clin Exp Dermatol* 2009; 34(6):708–710.

**Caso F, et al:** Refractory pemphigus foliaceus and Behçet's disease successfully treated with tocilizumab. *Immunol Res* 2013; 56(2-3):390–397.

**Chatterjee M, et al:** Pemphigus foliaceus masquerading as IgA pemphigus and responding to dapsone. *Indian J Dermatol* 2012; 57(6):495–497.

**Di Zenzo G, et al:** Endemic pemphigus foliaceus: towards understanding autoimmune mechanisms of disease development. *J Invest Dermatol* 2012; 132(11):2499–2502.

**Flores G, et al:** IgG autoantibody response against keratinocyte cadherins in endemic pemphigus foliaceus (fogo selvagem). *J Invest Dermatol* 2012; 132(11):2573–2580.

**Pérez-Pérez ME, et al:** Autoantibodies in Senear-Usher syndrome: cross-reactivity or multiple autoimmunity? *Autoimmune Dis* 2012; 2012:296214.

**Qian Y, et al:** Cutting edge: Brazilian pemphigus foliaceus anti-desmoglein 1 autoantibodies cross-react with sand fly salivary LJM11 antigen. *J Immunol* 2012; 189(4):1535–1539.

**Robledo MA:** Chronic methyl mercury poisoning may trigger endemic pemphigus foliaceus "fogo selvagem." *Med Hypotheses* 2012; 78(1):60–66.

### PARANEOPLASTIC PEMPHIGUS

In 1990, Anhalt et al. described five patients with underlying neoplasms who presented with painful mucosal ulcerations and polymorphous skin lesions, which progressed to blistering eruptions on their trunk and extremities. Most patients described since then have had associated neoplasms or Castleman's disease. The mucosal lesions of paraneoplastic pemphigus (PNP) may appear lichenoid or more frequently may resemble Stevens-Johnson syndrome, with crusting of the lips (Fig. 21-7). The skin lesions may appear as erythematous macules, lichenoid lesions, erythema multiforme (EM)-like lesions, flaccid bullae, and erosions typical of pemphigus, or with tense, more deep-set bullae.

Histologically, the lesions demonstrate epidermal acantholysis, suprabasal cleft formation, dyskeratotic keratinocytes,

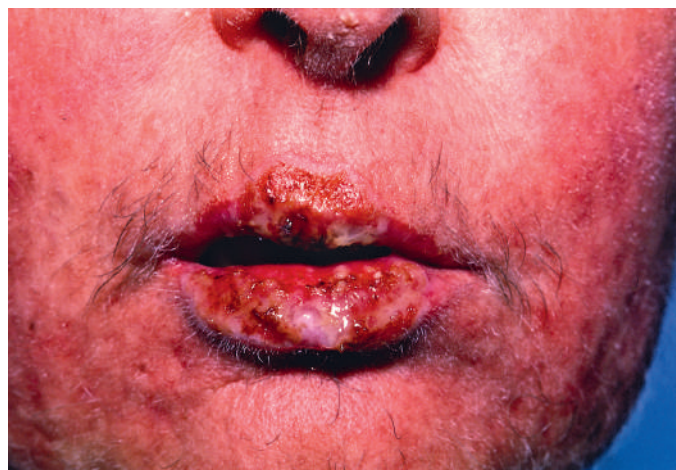

Fig. 21-7 Paraneoplastic pemphigus.

and vacuolar change of the basal epidermis. Biopsies that demonstrate both acantholysis and lichenoid change or individual cell necrosis should raise the suspicion of PNP.

It should be noted that all forms of pemphigus may be paraneoplastic. However, the specific disease dubbed “paraneoplastic pemphigus” has a characteristic clinical appearance as well as diagnostic immunologic findings, but it is not universally associated with a neoplasm. DIF reveals IgG and C3 deposition in the intercellular spaces of the epithelium. IIF shows a similar pattern in a wide range of stratified squamous epithelium and transitional epithelium (e.g., rat bladder). About 25% of cases will be negative, and some EM may be falsely positive. Immunoprecipitation is the definitive test. It reveals a complex immune response with autoantibodies directed against four high-molecular-weight keratinocyte proteins. Antibody targets include desmoplakin 1 (250 kD), envoplakin (210 kD), the major plaque protein of hemidesmosomes BPAg1 (230 kD), and periplakin (190 kD). Many cases also recognize an additional antigen at 170 kD. Antibodies to Dsg3, Dsg1, and anti- $\alpha$ 2-macroglobulin-like-1 are frequently present. ELISA has also been used to detect antienvoplakin and anti-periplakin autoantibodies. On DIF, some cases also demonstrate a linear or granular IgG and/or C3 at the BMZ. Detection of the characteristic immunologic pattern may be delayed, and tests should be repeated if the index of suspicion is high.

Whereas the dominant epitopes in PV reside in N-terminal regions of Dsg3, epitopes on Dsg3 in PNP are distributed more broadly through the extracellular domain. The N-terminal domains are still recognized more frequently than the C-terminal domains. IgG subclasses in PNP are IgG1 and IgG2 dominant, contrasting with the IgG4 dominance in PV. There is a significant association in PNP with HLA-DRB1\*03 allele (61.5% of those studied). In one study, eight of nine fatal PNP cases had distinctive cell surface antibodies detected in a beaded pattern by complement indirect immunofluorescence (CIIF) tests on monkey esophagus. Three long-term survivors with PNP lacked this pattern, suggesting the test may have prognostic value.

A wide variety of both benign and malignant tumors are seen in these patients, and some have no identifiable neoplasm. The most common associations are non-Hodgkin lymphoma, chronic lymphocytic leukemia (CLL), Castleman tumor, sarcoma, and thymoma. Most reported patients die from their tumor. Others have died from bronchiolitis obliterans.

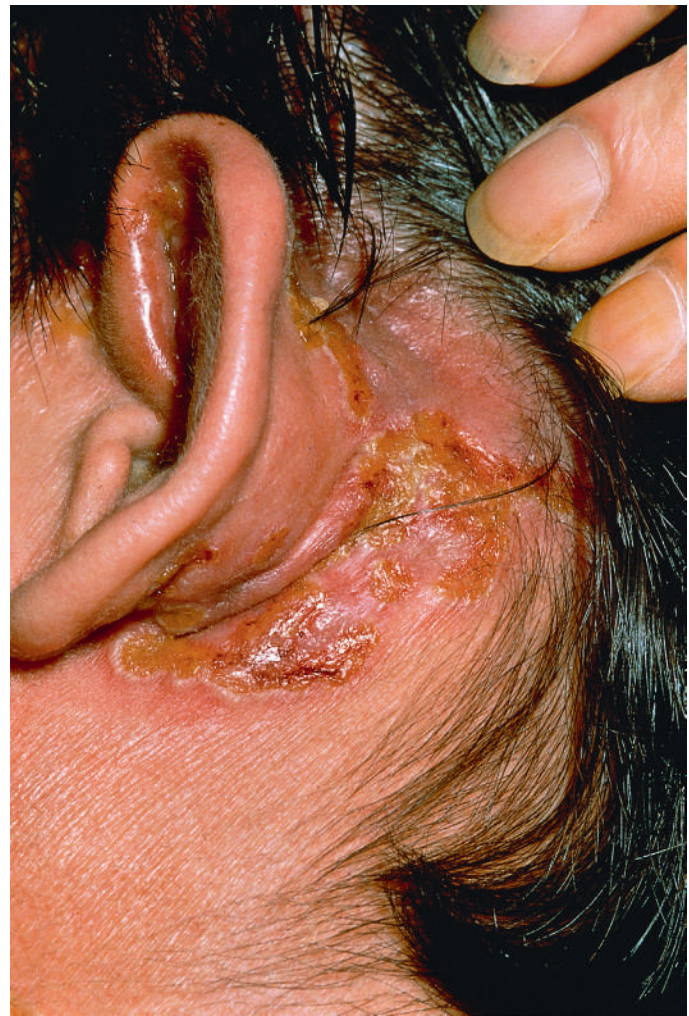Therapy for the bullous dermatoses with prednisone and/or immunosuppressive agents should be balanced with treatment of the tumor. Immunoablative high-dose cyclophosphamide without stem cell rescue, cyclosporin A, plasmapheresis, immunoapheresis, and rituximab and alemtuzumab (in CLL patients) have been successful in some cases. Even with treatment, mortality remains higher than for other immunobullous diseases.

**Arbache ST, et al:** Immunofluorescence testing in the diagnosis of autoimmune blistering diseases: overview of 10-year experience. *An Bras Dermatol* 2014; 89:885–889.

**Numata S, et al:** Anti- $\alpha$ 2-macroglobulin-like-1 autoantibodies are detected frequently and may be pathogenic in paraneoplastic pemphigus. *J Invest Dermatol* 2013; 133(7):1785–1793.

## INTRAEPIDERMAL NEUTROPHILIC IgA DERMATOSIS

In 1985, Huff et al. reported the case of an elderly man having a chronic bullous dermatosis with unique histologic and immunopathologic findings. Clinically, the patient had generalized flaccid bullae, which rapidly ruptured and crusted; no



**Fig. 21-8** Intraepidermal neutrophilic IgA dermatosis.

scarring occurred when the dermatosis healed. No mucosal lesions were present, and the distal extremities, face, and neck were spared. Neither grouping nor symmetry was present. Histologic findings consisted of neutrophilic exocytosis, and in some areas, neutrophils were arranged linearly at the DEJ. Later, intraepidermal abscesses were formed; no acantholysis was present. DIF repeatedly showed an intercellular deposition of IgA within the epidermis, with minimal staining of the basal layer. No circulating antibodies were found.

Since that report, many additional patients with intraepidermal IgA deposition have been described. They have been classified as belonging to two subsets, one closely mimicking pemphigus and the second simulating subcorneal pustular dermatosis (SPD). The former starts with vesicles that become pustular within a few days, enlarge peripherally, and rupture in the center, then form a crust (Fig. 21-8). Continued peripheral vesiculation may lead to a flowerlike appearance. The head, neck, and trunk are frequent sites of involvement. In some patients, the condition is induced by ultraviolet (UV) A light. The second subset, SPD, presents similar to Sneddon-Wilkinson disease, with serpiginous and annular pustules. A pemphigus vegetans-like pattern has also been described. Some cases have been induced by granulocyte-macrophage colony stimulating factor (GM-CSF). Some patients have had associated malignancies, and IgA pemphigus with PNP-like clinical features has been described, showing IgA antibodies to Dsg1/3 and desmocollin 3, as well as IgG and IgA antibodies to the BMZ.



Histologically, intraepidermal bullae with neutrophils, some eosinophils, and acantholysis are seen. DIF shows intraepidermal IgA deposition, usually throughout the epidermis, and IIF may reveal circulating autoantibody that binds to the same location. There is evidence that the IgA specificity in individual cases may be directed at either Dsg1 or Dsg3. Some patients have concurrent IgG intercellular antibodies directed at Dsg1, and some have a monoclonal IgA gammopathy. The antigen in SPD-type IgA pemphigus is desmocolin, a type of desmosomal cadherin. Some patients have a circulating IgA monoclonal gammopathy. It should be noted that IgA antibodies to Dsg1 and Dsg3 may occur in PV, PF, and PNP. Individual patients may express both anti-desmocolin 1 and anti-Dsg1 antibodies.

Therapy with topical corticosteroids may be effective in patients with mild intraepidermal neutrophilic IgA dermatosis. Dapsone is often effective, even at doses as low as 25 mg/day in some patients. Oral corticosteroids may be necessary, and some resistant cases have required immunosuppressive agents and plasmapheresis. Colchicine, acitretin, adalimumab, MMF, and isotretinoin have been effective in some patients.

**Moreno AC, et al:** IgA pemphigus: case series with emphasis on therapeutic response. *J Am Acad Dermatol* 2014; 70:200–201.

**Wolz MM, et al:** Pemphigus vegetans variant of IgA pemphigus, a variant of IgA pemphigus and other autoimmune blistering disorders. *Am J Dermatopathol* 2013; 35(3):e53–e56.

## BULLOUS PEMPHIGOID

### Clinical features

Bullous pemphigoid (BP) was described by Lever in 1953. Clinically, BP is characterized by large, tense, subepidermal bullae with a predilection for the groin, axillae, trunk, thighs (Fig. 21-9), and flexor surfaces of the forearms. Key features distinguishing BP from other immunobullous diseases include subepidermal separation at the DEJ, an inflammatory cell infiltrate that tends to be rich in eosinophils, and antibodies directed against two hemidesmosomal antigens, BP230 and BP180. Antibody detection rates vary by method, and many normal patients will have positive serologic tests but negative IIF.

After the bullae rupture, large denuded areas are seen, but the bullae and denuded areas do not tend to increase in size as they do in PV. Instead, the denuded areas tend to heal spontaneously. In addition to the bullae, there often are

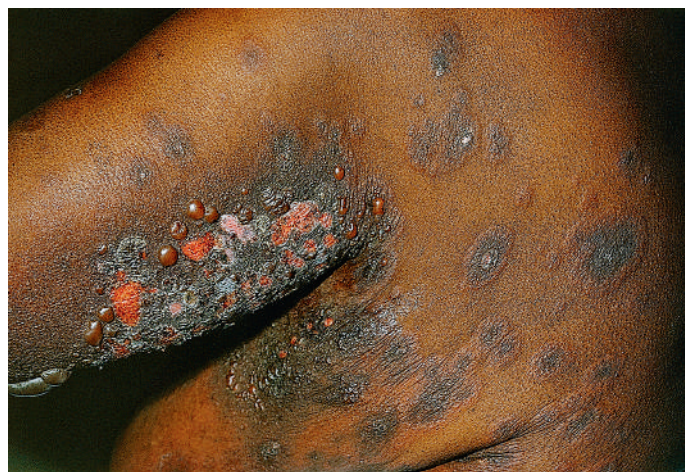

Fig. 21-9 Bullous pemphigoid.

erythematous patches and urticarial plaques (Fig. 21-10), with a tendency to central clearing. These patches and plaques may be present without bullae early in the course of the disease. Later, bullae often occur on an urticarial base. Sometimes, targetoid lesions are present.

Bullous pemphigoid may begin at a localized site, frequently on the shins. The disease may also be limited to areas of radiation therapy, burns, or plaques of psoriasis. BP may remain localized throughout its course or eventuate in generalized pemphigoid. Cases of the localized disease in which a vesicular eruption is limited to the palms or soles (dyshidrosiform pemphigoid) are occasionally observed. Young girls may present with localized vulvar erosions and ulcers that resemble the signs of child abuse (Fig. 21-11). These localized varieties have been shown to have circulating IgG antibody, which immunoprecipitates the 230-kD BP antigen.

Many other variants of BP have been described. A vesicular variant manifested by tense, small, occasionally grouped blisters is termed vesicular pemphigoid. Other patients, mostly women, have papules and nodules of the scalp and extremities, with sparing of the mucous membranes, in a

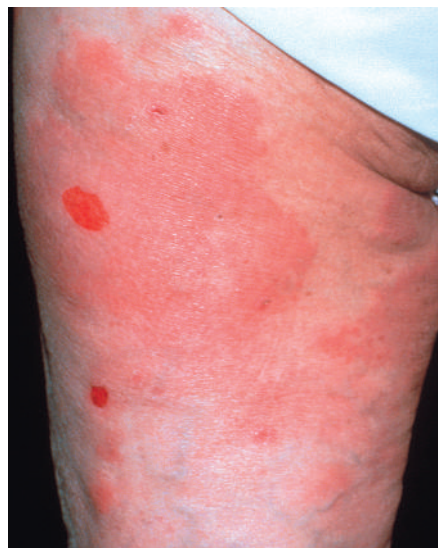

Fig. 21-10 Urticarial bullous pemphigoid.

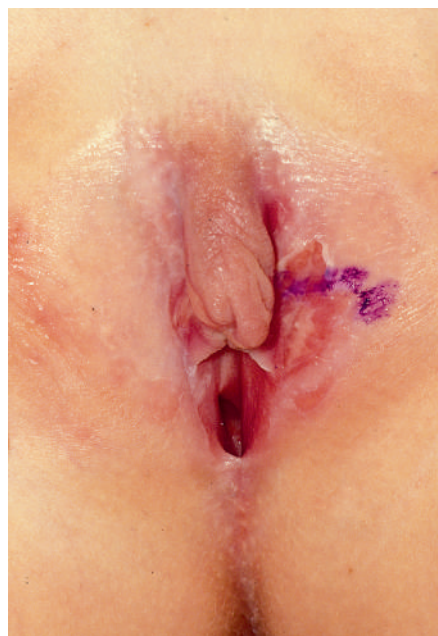
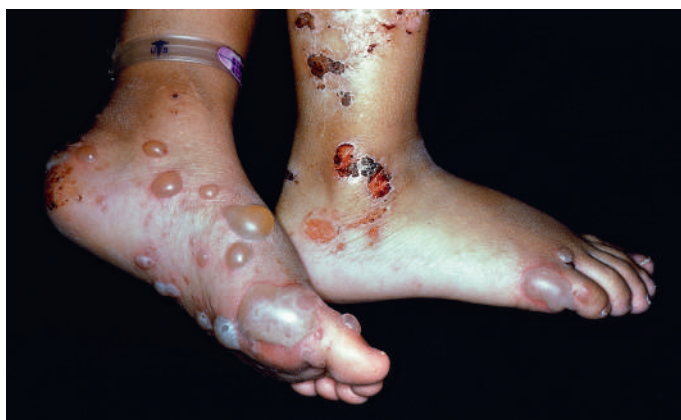
Fig. 21-11 Vulvar pemphigoid.



**Fig. 21-12** Childhood bullous pemphigoid.

pattern resembling prurigo nodularis (pemphigoid nodularis). Cases resembling pemphigus vegetans, but with IgG and C3 at the BMZ, are occasionally observed (pemphigoid vegetans). Erythroderma may be present (erythrodermic pemphigoid), or there may be no bullae at all (nonbullous variant). The latter type may present as generalized pruritus, pruritic eczema, or urticarial eruptions with peripheral eosinophilia. Overall, incidence of oral involvement is about 20%, but involvement of the pharynx, larynx, nasal mucosa, vulva, urethra, and eye is rare.

Bullous pemphigoid occurs most frequently in the elderly population. The age of onset averages 65–75 years. BP also occurs in young children, but with clinical and pathologic findings similar to those in adults. Many of these cases begin with hand and foot bullae (Fig. 21-12). Facial involvement may be somewhat more common in children. In children, the course of disease is usually under 1 year, with most cases lasting 5 months or less.

In patients with lichen planus, a bullous eruption similar to BP may develop. This condition, called lichen planus pemphigoides, is sometimes related to the 230-kD antigen, the 180-kD antigen, or a unique 200-kD subepidermal antigen. A non-scarring eruption, with acute onset, widespread erosions, and severe mucous membrane involvement resembling toxic epidermal necrolysis or PV, has been referred to as anti-p105 pemphigoid. Linear IgG and C3 are noted at the BMZ. The 105-kD antigen is found in the lower portion of the lamina lucida.

### Etiologic factors

Circulating BMZ antibodies of the IgG class are present in approximately 70% of patients with BP. In most cases, the antibodies fix complement in vitro, in contrast to pemphigus antibodies, which fail to do so. Complement is activated by both the classical and the alternate pathway. No close correlation exists between the titer of antibodies and clinical disease activity. Passive-transfer mouse models suggest that subepidermal blistering is initiated by anti-BP180 antibodies. Blister formation involves complement activation, mast cells, and neutrophils. BMZ damage is caused by proteinases and reactive oxygen species released by the infiltrating neutrophils.

The site of IgG binding has been localized to the lamina lucida, with accentuation near hemidesmosomes. BP antigen 1 (BPAg1) is synthesized by the keratinocyte and is an intracytoplasmic hemidesmosomal plaque protein of 230 kD with disulfide-linked chains. The second BP antigen (180-kD BPAg2) is a transmembrane protein with a long C-terminal collagenous domain that projects into the extracellular region below the hemidesmosome. The antibody to BPAg2 is the

primary pathogenic factor. The noncollagenous (NC) 16A domain harbors the major epitopes of autoantibodies in BP. A predominance of the IgG4 subclass has been observed in several studies. In addition to this humoral response, infiltrating T-helper lymphocytes with a mixed Th1/Th2 cytokine profile may play a role in blister formation. Peripheral blood eosinophilia is present in 50% of pemphigoid patients.

Bullous pemphigoid has occasionally been associated with other diseases, such as diabetes mellitus, rheumatoid arthritis, PF, dermatomyositis, ulcerative colitis, myasthenia gravis, and thymoma. Drugs reported to induce BP include penicillamine, furosemide, captopril, penicillin, sulfasalazine, nalidixic acid, and enalapril.

### Histopathology

The histologic changes of BP are characterized by subepidermal bullae, the absence of acantholysis, and a superficial dermal infiltrate containing many eosinophils. The amount of inflammatory infiltrate varies, and individual bullae may be “infiltrate poor” or “infiltrate rich.” Often, the infiltrate contains many eosinophils, although neutrophil-predominant cases exist. Spongiosis with eosinophils occurs more frequently than in pemphigus. Urticarial lesions often demonstrate eosinophils lined up along the DEJ.

Atypical presentations are fairly common. In one study of 23 new cases of BP, only 7 of 22 biopsy specimens showed subepidermal blister formation, and only 12 of these had a predominance of eosinophils in the blister cavity. In 23% of patients, the biopsy was not particularly suggestive of BP. DIF, IIF, immunoblot analysis, and ELISA are critical in establishing the diagnosis in such patients.

The DIF test is more sensitive than IIF, as in pemphigus. In a positive test, continuous linear (tubular or toothpaste pattern) immunofluorescence is seen along the BMZ. IgG and/or C3 are best found in nonbullous lesional or perilesional skin. False-negative tests are somewhat more common on the lower extremities. When using perilesional or nonbullous lesional skin of the trunk, a positive DIF test is found in a high percentage of patients, with C3 most often present and IgG present in about 80% of cases. IgA and IgM are occasionally present. About 20% of patients have negative staining for IgG on DIF, even though C3 is present. In some of these patients, IgG may be present at subthreshold levels that cannot be detected. Also, the major subclass, IgG4, shows limited reactivity with most commercial antihuman IgG conjugates. Double-sandwich antibody immunofluorescence methods have been developed that offer greater sensitivity for IgG4 antibodies.

All histologic features present in BP may also be seen in epidermolysis bullosa acquisita (EBA). Therefore, immunofluorescence testing on salt-split skin is sometimes performed to differentiate EBA from BP. Salt-split skin may be replaced by assessment of u-serrated (EBA) and n-serrated (BP) immunoglobulin patterns in DIF specimens and by serologic testing. C3 deposition is almost always present in BP, whereas it may be absent in EBA. Type IV collagen mapping in BP localizes to the base of the blister; in EBA, it stains the roof.

Bullous scabies can also mimic both the histology and the DIF findings of BP.

### Treatment

Relatively few controlled trials have been performed, and many recommendations for BP therapy are based on experience and consensus of opinion. Using Cochrane criteria, seven randomized controlled trials (RCTs) were identified through



2003, enrolling a total of 634 patients. One comparing prednisolone, 0.75 mg/kg/day, with prednisolone, 1.25 mg/kg/day, found no statistical difference between the two treatments. The same was true of a trial comparing methylprednisolone with prednisolone. Higher doses of prednisolone were associated with more severe side effects in these studies. Two trials confirmed that adjuvant therapy with azathioprine or plasma exchange could reduce the required corticosteroid dose. Another trial failed to confirm the superiority of combination treatment (with either azathioprine or plasma exchange) over corticosteroid alone, and one trial found no statistically significant difference between prednisolone and a combination of tetracycline and niacinamide. The steroid-treated group had more side effects. Another study compared ultrapotent topical corticosteroid treatment (clobetasol propionate cream, 40 g/day) with oral prednisone (0.5–1 mg/kg/day). In those with severe disease, 1-year survival was better in the topical corticosteroid group (76% vs. 58%). Disease control at 3 weeks was also better in the clobetasol than in the prednisone group (99% vs. 91%). Side effects were common in both groups, but more common in the prednisone group (29% vs. 54%). Among those with moderate disease, there were no significant differences between the two groups.

Even in those with fairly extensive disease, topical corticosteroid treatment should be attempted. Prednisone has long been the standard approach to oral therapy, but the complication rate must be weighed carefully, especially in those with severe disease. Oral therapy with tetracycline, 500 mg four times daily, combined with niacinamide, 500 mg three times daily, is effective in some patients. Occasionally, patients with BP may respond to tetracycline or nicotinamide alone. Rituximab has proved effective in adults and has been used in infancy. Dapsone is also effective in some patients. Immunosuppressive therapy may still be necessary in resistant cases, either in combination with systemic or topical corticosteroids or as sole therapy. Azathioprine and MMF demonstrate similar efficacy when used as steroid-sparing agents, and cumulative corticosteroid doses are similar. MMF is more expensive but is easier to dose and associated with less toxicity. Methotrexate, cyclophosphamide, chlorambucil, IVIG, and cyclosporine have also proved effective in some patients, and some data suggest that outcomes are better with methotrexate than with prednisone. Low-dose oral methotrexate has been shown to induce apoptosis of tissue eosinophils in patients with BP. The effectiveness of IVIG is improved by the addition of an immunosuppressive agent. In exceptionally severe cases, pulse therapy with methylprednisolone, 15 mg/kg in 16 mL of bacteriostatic water over 30–60 min/day for three doses, can be rapidly effective. Again, some patients may also respond to dapsone, as well as sulfapyridine; these agents tend to be more effective in neutrophil-rich BP. Oral erythromycin and topical macrolactams have proved effective in some patients.

Double-filtration plasmapheresis (DFPP) may be more effective than conventional plasma exchange, possibly because it removes pathogenic cytokines. DFPP reduces a variety of cytokines, including IL-8, tumor necrosis factor (TNF)- $\alpha$ , and IL-2. IVIG produces faster clearance of antibody titers and may be helpful in inducing and maintaining remission. Some data suggest that single-chain variable fragments of anti-collagen XVII antibodies can interfere with pathogenic binding of autoantibodies, suggesting that interference with antibody binding may represent an alternative treatment approach to BP.

### Course and prognosis

Bullous pemphigoid is usually self-limited over 5–6 years. This period is generally a year or less in children. Relapse

occurs in 10–15% of patients once therapy is discontinued. The presence of circulating anti-BP180 antibodies, but not anti-BP230, is associated with a statistically increased mortality risk in the first year after diagnosis. Other risk factors for death during the first year include older age, higher daily steroid dosage at discharge, low serum albumin, and erythrocyte sedimentation rate greater than 30 mm/h. Much of the morbidity and mortality now relate to infection and side effects of drug therapy, but with improvements in treatment, pemphigoid patients have similar mortality to age-matched controls. Although IIF titers do not always correlate with disease activity, ELISA measurements of BP180NC16a show better correlation. The presence of IgE autoantibodies to BP180 correlate with a more severe course.

**Bakker CV, et al:** Bullous pemphigoid as pruritus in the elderly: a common presentation. *JAMA Dermatol* 2013; 149(8):950–953.

**Chuah SY, et al:** A retrospective review of the therapeutic response with remission in patients with newly diagnosed bullous pemphigoid. *Australas J Dermatol* 2014; 55:149–151.

**Hertl M, et al:** Underrecognition of the heterogeneous clinical spectrum of bullous pemphigoid. *JAMA Dermatol* 2013; 149(8):954–955.

**Khumalo N, et al:** Interventions for bullous pemphigoid. *Cochrane Database Syst Rev* 2005; 20:CD002292.

**Lehman JS, et al:** Infection in autoimmune bullous diseases: a retrospective comparative study. *J Dermatol* 2013; 40(8):613–619.

**Lo Schiavo A, et al:** Bullous pemphigoid: etiology, pathogenesis, and inducing factors—facts and controversies. *Clin Dermatol* 2013; 31(4):391–399.

**Ludwig RJ, et al:** Emerging treatments for pemphigoid diseases. *Trends Mol Med* 2013; 19(8):501–512.

**Shetty S, et al:** Treatment of bullous pemphigoid with rituximab: critical analysis of the current literature. *J Drugs Dermatol* 2013; 12(6):672–677.

**Sladden C, et al:** Biopsy location for direct immunofluorescence in patients with suspected bullous pemphigoid impacts probability of a positive test result. *J Cutan Med Surg* 2014; 18:392–396.

**Spivey J, et al:** Bullous pemphigoid: corticosteroid treatment and adverse effects in long-term care patients. *Consult Pharm* 2013; 28(7):455–462.

## PEMPHIGOID GESTATIONIS (HERPES GESTATIONIS)

### Clinical features

Pemphigoid gestationis (PG) is an autoimmune, inflammatory, bullous disease with onset during pregnancy or during the postpartum period. It occurs in approximately 1 in 50,000 pregnancies. The onset is usually during the second trimester, with urticarial plaques and papules developing around the umbilicus and extremities. Targetoid lesions may be present (Fig. 21-13). As the disease progresses, lesions may spread over the abdomen, back, chest, and extremities, including the palms and soles. The face, scalp, and oral mucosa are usually spared. Within the infiltrated erythematous plaques, tense vesicles and bullae erupt, often in an annular or polycyclic configuration. Pruritus is severe and may be paroxysmal. The disease will often flare shortly after delivery and then remit spontaneously, usually within 3 months. There is no scarring, except that caused by excoriations or secondary infections. Recurrences with subsequent pregnancies are common, and the disease may be provoked by subsequent menstrual periods or oral contraceptives (OCs). A number of cases of persistent disease have been reported.

Most study data suggest that fetal loss is not statistically increased, although infants are often born prematurely and are small for gestational age. In fewer than 5% of cases, infants manifest the disease in the form of urticarial lesions or bullae. The lesions are usually limited, and clear spontaneously

without the need for therapy. Neonatal convulsions have been reported.

## Etiologic factors

Pemphigoid gestationis is an autoimmune, antibody-mediated disease. A complement-fixing IgG antibody is present in the serum and is deposited in the lamina lucida. The antigen, transmembrane collagen XVII, is a component of fetal membranes and promotes migration of placental cytotrophoblastic cells. The antigenic epitopes are usually restricted to the N-terminal portion of the extracellular domain of BP180 (BPAg2). The antigenic N-terminal portion of MCW-1 is located in the noncollagenous domain (NC16A) of BP180. Other antigens are located nearby, and four major PG epitopes are clustered within a 22-amino acid region of the BP180 ectodomain. ELISA-based assays correlate antibody levels to disease activity. Both IgG1 and IgG3 subtypes have been noted, but a more recent study found IgG4 to be the predominant subtype, as in BP.

Studies have documented an increased frequency of HLA-DR3, DR4, and C4 null alleles in patients with PG. A woman may have antibodies directed against her husband's HLA antigens. Black women rarely manifest PG, possibly related to the low incidence of HLA-DR4 in American black persons (Fig. 21-14). There is an increased frequency of Graves' disease in PG patients.

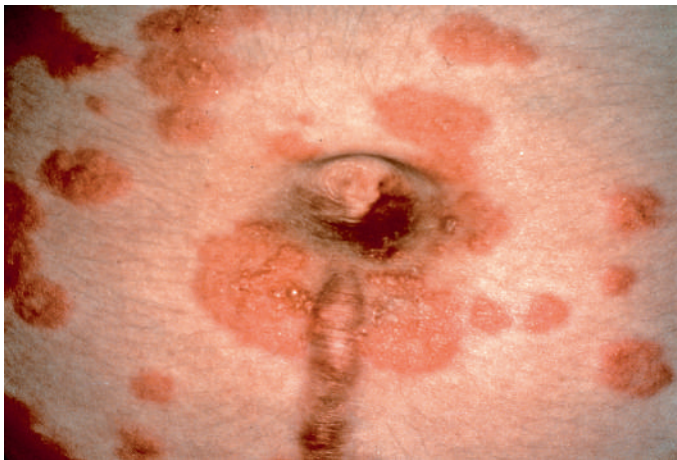

Fig. 21-13 Pemphigoid gestationis.

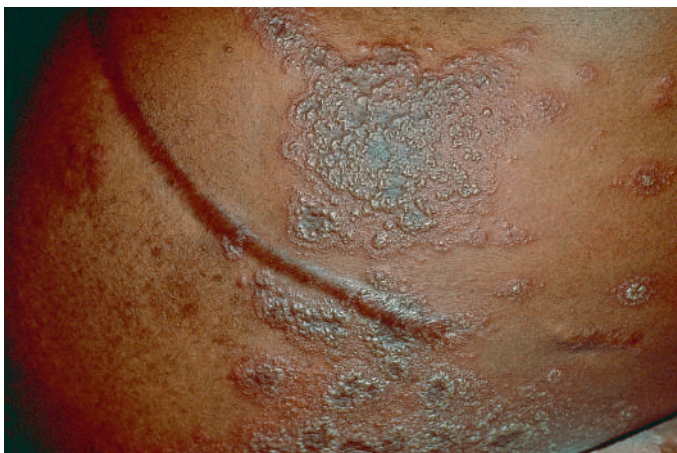

Fig. 21-14 Pemphigoid gestationis.

## Pathogenesis

Pathogenesis is similar to that of BP. However, hormonal factors influence the disease manifestation. In addition to being seen in pregnant patients, menstruating women, and those taking OCs, the disease may occur in association with hydatidiform mole and choriocarcinoma. The IgG antibodies bind to the lamina lucida and fix complement. Activated eosinophils, neutrophils, and T cells with a predominant Th2 phenotype are involved in blister formation. Evidence of fetal microchimerism is lacking.

Patients with chronic PG tend to be older and multigravid, with a history of PG during previous pregnancies. They often have widespread cutaneous and mucosal involvement. The IgG1 subclass is often present. Antibodies to a C-terminal portion of BP180 have been noted in a patient with chronic PG. This same region is targeted in patients with cicatricial pemphigoid and some with BP.

## Histopathology

A subepidermal bulla with eosinophils and some neutrophils is usually present in PG. In the urticarial stage, eosinophils may line up along the DEJ, as in urticarial BP. Civatte bodies may be present. On DIF, all patients have C3 deposited in a linear pattern at the DEJ; 25–40% also have detectable IgG. On conventional IIF testing, approximately 25% of patients have a circulating IgG anti-BMZ antibody, but in almost 75%, the PG factor, a complement-fixing IgG antibody, can be demonstrated by complement-enhanced immunofluorescence. Immunoelectron microscopy has demonstrated that the blister occurs at the level of the lamina lucida, with deposition of C3 and IgG at this site, exactly as in BP.

## Differential diagnosis

The main diagnosis to be considered is pruritic urticarial papules and plaques of pregnancy (PUPPP). The differential diagnosis of PG also includes EM, drug reactions, and bullous scabies. Acrodermatitis enteropathica has also been reported to flare as a bullous eruption with each pregnancy. Biopsy, immunofluorescence findings, and clinical course establish the diagnosis.

## Treatment

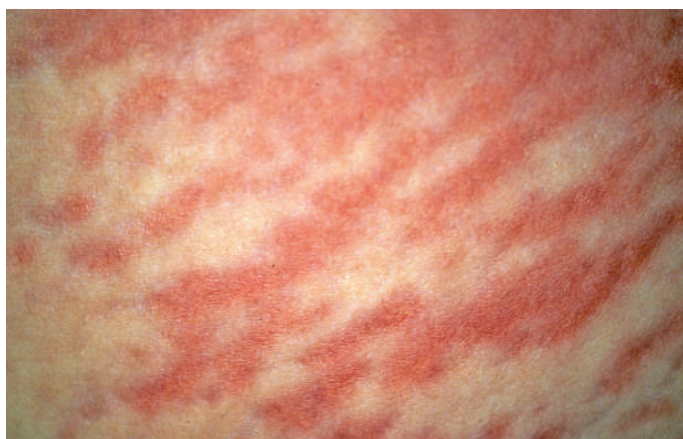
The use of potent topical steroids may be adequate in some patients with milder PG. Prednisone, about 40 mg/day orally, is usually effective in the remaining women. The dose is tapered to the lowest effective amount given on alternate days. Pyridoxine has been reported to be effective in some patients. Persistent PG after delivery has been treated with various tetracyclines, together with nicotinamide. A few women with severe PG have required treatment with rituximab, cyclophosphamide, dapsone, methotrexate, IVIG, or plasmapheresis.

## OTHER PREGNANCY-RELATED DERMATOSES

### Intrahepatic cholestasis of pregnancy (prurigo gravidarum)

Women with prurigo gravidarum have no primary skin lesions and usually manifest only severe, generalized pruritus and





**Fig. 21-15** Pruritic urticarial papules and plaques of pregnancy.

jaundice. Secondary excoriations may be present. The disease is caused by cholestasis, occurs late in pregnancy, resolves after delivery, and recurs with subsequent pregnancies. There is an increased incidence of fetal complications. It has been estimated to occur in 0.5% of 3192 pregnancies. Both ursodeoxycholic acid and *S*-adenosylmethionine improve pruritus, but the former is more effective in improving liver function. Delivery at 37 weeks is associated with better outcomes.

### Polymorphic eruption of pregnancy

Some investigators have proposed grouping all the pruritic inflammatory dermatoses of pregnancy into the designation “polymorphic eruption of pregnancy.” This argument has some merit, because many of the pruritic eruptions of pregnancy are nonspecific or variable manifestations of PUPPP, and there are no consistent hormonal or immunopathogenetic factors that reliably separate them. These eruptions occur in approximately 1 in 120–240 pregnancies. They are more common with male fetuses and multiple gestation pregnancies.

### Pruritic urticarial papules and plaques of pregnancy

Lawley et al. first reported this eruption in seven patients under the name pruritic urticarial papules and plaques of pregnancy in 1979. PUPPP is characterized by erythematous papules and plaques that begin as 1-mm or 2-mm lesions within the abdominal striae (Fig. 21-15). These then spread over a few days to involve the abdomen, buttocks, thighs, and in some cases the arms and legs. The upper chest, face, and mucous membranes are generally spared. The lesions coalesce to form urticarial plaques, sometimes in figurate patterns, and occasionally spongiotic vesicles are present. Intense pruritus is characteristic. In contrast to PG, postpartum onset or exacerbation is uncommon. Fetal and maternal outcomes are not affected by this eruption, and only rarely do newborns manifest transient lesions of PUPPP.

This eruption occurs in primigravidas 75% of the time and rarely recurs with subsequent pregnancies. It begins late in the third trimester and resolves with delivery. Many studies have investigated the relationship of maternal weight gain to the development of this dermatosis. Patients with PUPPP average more weight gain and greater abdominal distention than those without the disease. It is more common in those carrying twins or triplets.

Histologic findings consist of a perivascular lymphohistiocytic infiltrate in the upper and middle dermis, with a variable

number of eosinophils and dermal edema. The epidermis is usually normal, although focal spongiosis, parakeratosis, or scales or crust may be present. The results of a DIF test are negative or nonspecific.

Usually, potent topical corticosteroids are required to control the eruption. A few patients require prednisone. PUPPP remits after delivery.

### Papular dermatitis of pregnancy

Papular dermatitis of pregnancy is a controversial entity. It is defined as a pruritic, generalized eruption of 3–5 mm, erythematous papules, each surmounted by a small, firm, central crust. The lesions may erupt at any time during pregnancy and usually resolve with delivery. Marked elevation of the 24-hour urinary chorionic gonadotropin has been cited as a marker for the condition. Administration of systemic corticosteroids is reportedly effective in controlling the eruption. Papular dermatitis may recur in subsequent pregnancies. The high incidence of fetal deaths reported by Spangler is now thought to have been overstated.

### Prurigo gestationis (Besnier)

Prurigo gestationis consists of pruritic, excoriated papules of the proximal limbs and upper trunk, occurring most often between the 20th and 34th weeks of gestation. It clears in the postpartum period and usually does not recur. Therapy with potent topical corticosteroids is recommended. No adverse effects on maternal or fetal health are seen. This eruption may simply be an expression of atopic dermatitis in pregnancy.

### Pruritic folliculitis of pregnancy

Several authors have reported on pruritic folliculitis in gravid women, with small follicular pustules scattered widely over the trunk appearing during the second or third trimester and resolving by 2 or 3 weeks after delivery. Acute folliculitis and focal spongiosis with exocytosis of polymorphonuclear leukocytes are present on biopsy, and DIF results are negative. This condition may be a type of hormonally induced acne.

### Linear IgM dermatosis of pregnancy

In 1988, Alcalay et al. described a woman who developed small, red, follicular papules and pustules that, on immunofluorescence testing, showed linear deposits of IgM. This finding is common in a wide variety of dermatoses, and is nonspecific.

### Impetigo herpetiformis

Impetigo herpetiformis is a form of severe pustular psoriasis occurring in pregnancy. It consists of an acute, usually febrile onset of grouped pustules on an erythematous base, which begins in the groin, axillae, and neck. There is a high peripheral white blood cell count, and hypocalcemia may be present. The histopathology is that of pustular psoriasis. The condition resolves with delivery, but recurrences with subsequent pregnancies may be expected. Fetal death can occur and results from placental insufficiency. Initial treatment is with systemic corticosteroids, in the range of 40–60 mg/day of oral prednisone. Impetigo herpetiformis is discussed in more detail in Chapter 10.

**Ambros-Rudolph CM, et al:** The specific dermatoses of pregnancy revisited and reclassified: results of a retrospective two-center study on 505 pregnant patients. *J Am Acad Dermatol* 2006; 54(3):395–404.

**Guldris EM, et al:** Pemphigoid gestationis. *J Obstet Gynaecol Can* 2013; 35(8):687.

**Lehrhoff S, et al:** Specific dermatoses of pregnancy and their treatment. *Dermatol Ther* 2013; 26(4):274–284.

**Massone C, et al:** Histopathological diagnosis of atopic eruption of pregnancy and polymorphic eruption of pregnancy: a study on 41 cases. *Am J Dermatopathol* 2014; 36:812–821.

**Rimoin LP, et al:** Female-specific pruritus from childhood to postmenopause: clinical features, hormonal factors, and treatment considerations. *Dermatol Ther* 2013; 26(2):157–167.

## CICATRICAL PEMPHIGOID (BENIGN MUCOSAL PEMPHIGOID)

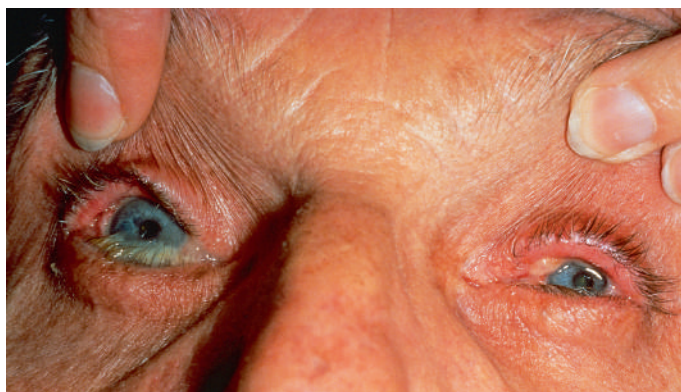
In 1953, Lever suggested the designation “benign mucosal pemphigoid” for what had previously been called ocular pemphigus, cicatricial pemphigoid, or essential shrinkage of the conjunctiva. Because of its scarring nature, the designation cicatricial pemphigoid (CP) has gained predominance. The term encompasses a group of immunologically distinct immunobullous diseases with scarring.

### Clinical features

Cicatricial pemphigoid usually occurs in older women, with a female/male ratio of approximately 2:1. CP is characterized by evanescent vesicles that rupture quickly, leaving behind erosions and ulcers. In most patients, the vesicles primarily occur on the mucous membranes, especially the conjunctiva (Fig. 21-16) and oral mucosa. Oral lesions occur in approximately 90% of patients and conjunctival lesions in 66%. The oral mucosa may be the only affected site for years. Desquamative gingivitis, diffuse erythema of the marginal and attached mucosa associated with mucosal desquamation and pain, is often the presenting sign (Fig. 21-17). The mucosa readily peels away in response to pressure from a cotton-tipped applicator or stream of air from a dental air hose. The gingivae are almost always involved, and the lingual surfaces less regularly. The palate, tongue, and tonsillar pillars may be involved.

The disorder is chronic. In ocular cases, CP leads to scarring and progressive shrinkage of the ocular mucous membranes. Blindness may result. It is usually bilateral and associated with redness and flaccid vesicles on the conjunctiva, xerosis, and fibrous adhesions (symblepharon). Entropion, trichiasis, and corneal opacities develop, and ultimately, the adhesions attach both lids to the eyeball and narrow the palpebral fissure. Scarring may also develop in the pharynx, esophagus, larynx, and anogenital mucosa. Esophageal stricture may occur, and deafness has been reported.

Cutaneous lesions are seen in approximately 25% of CP patients. These begin as tense bullae, similar to those in BP.



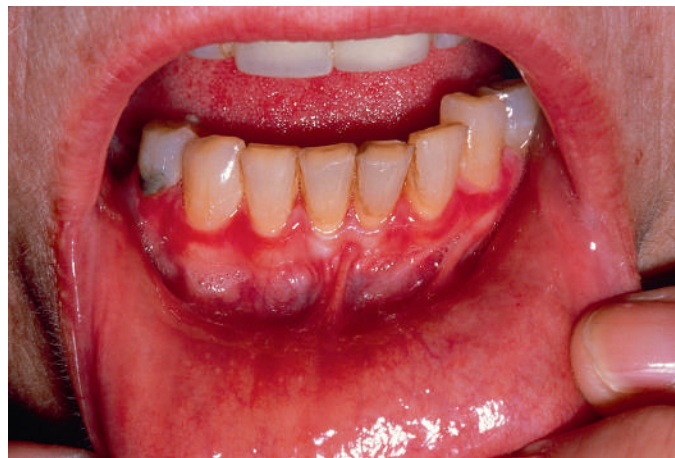**Fig. 21-16** Cicatricial pemphigoid.

The bullae may occur on the face, scalp, neck, inguinal region (Fig. 21-18), or extremities. Generalized lesions may also occur. Some of these patients will have circulating antibodies targeted against the classic BP antigens and should be classified as mucosal-predominant BP. Some have secondary antibodies against other antigens. Some patients have EBA, because the IgG autoantibody was found to target-type VII collagen. Vegetating intertriginous lesions have been dubbed CP vegetans.

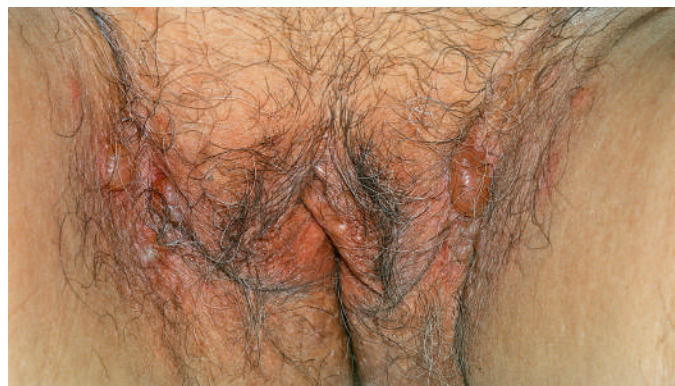In Brunsting-Perry pemphigoid, there are no mucosal lesions, but one or several circumscribed erythematous patches develop, on which recurrent crops of blisters appear. Ultimately, atrophic scarring results. Generally, the areas of involvement are confined to the head and neck. The average age at onset is 58, with a 2:1 male/female ratio. In contrast to BP, CP shows little tendency for remission. Although the disease is chronic and produces significant morbidity, the patient's general health is usually not jeopardized.

### Etiologic factors

Circulating autoantibodies target the hemidesmosomal protein BP180, but the target epitopes differ from those usually targeted in BP. Whereas most BP patients react with the noncollagenous domain (NC16a) on the extracellular N-terminal portion of BP180, most CP antibodies target C-terminal domains. Fluorescence typically is found on the epidermal side of 1M NaCl-split skin.



**Fig. 21-17** Desquamative gingivitis secondary to cicatricial pemphigoid.



**Fig. 21-18** Antilaminin cicatricial pemphigoid with inguinal involvement. Blisters began at the same time colonic cancer was diagnosed.



Although patients share a similar phenotype, CP is a heterogeneous group of autoimmune subepidermal blistering diseases. Although most patients' autoantibodies target BP180, others target laminin 5 (antiepiligrin cicatricial pemphigoid) or the  $\beta 4$  subunit of  $\alpha 6 \beta 4$  integrin. Some patients with a CP phenotype have antibodies to multiple epitopes, including the  $\beta 4$  subunit, BP180, and BP230. Other subsets of patients targeting unique BMZ antigens will likely be identified.

A sensitive ELISA test for laminin 5 antibodies has made it easier to identify this subset of patients. Among those whose antibodies target laminin 5 (antiepiligrin CP), most exhibit antibodies to the  $\alpha$  subunit, especially the G domains of the  $\alpha 3$  subunit. Antibodies may also target the  $\beta 3$  and  $\gamma 2$  subunits. Other patients have been found to have autoantibodies that react with both laminin 6 and laminin 5, prompting the proposed designation of antilaminin cicatricial pemphigoid. In antilaminin cicatricial pemphigoid, IgG anti-BMZ autoantibodies bind to the dermal side of 1M-NaCl split skin. Some data suggest an increased relative risk for solid cancers (mostly adenocarcinomas) in these patients. Tumors are usually found during the first year of the disease. As with other forms of CP, the disease rarely remits spontaneously. In contrast to the increased tumor risk in antilaminin 5 CP, some data suggest that patients with antibodies to the  $\beta 4$  integrin subunit have a decreased risk of cancer. Other data suggest that antilaminin 332 autoantibodies are associated with severe mucous membrane pemphigoid (MMP) but not malignancy.

### Histopathology

The histologic findings of CP are identical to those of BP, except that fibrosis and scarring may be present in the upper dermis. Basement membrane separation occurs in the lamina lucida or below the lamina densa, depending on the targeted antibody. The inflammatory infiltrate is variable. DIF testing of perilesional skin or mucosa reveals C3 and IgG at the lamina lucida in 80–95% of patients. The BMZ of mucosal glands stains as well. IgA may be found occasionally. A circulating antibody to the BMZ is found by IIF in about 20% of CP patients. Immunoelectron microscopy shows that lamina lucida antibodies bind at a deeper level than with BP. Most IIF-positive cases show IgG binding to the epidermal side of salt-split skin, although combined staining and dermal staining may be present in different subtypes, as previously noted. Laser scanning confocal microscopy using fluorescein isothiocyanate-conjugated antihuman IgG antibody has been employed to determine the localization of IgG at the BMZ, and may be of value in patients with negative IIF. "Knockout" skin substrates and fluorescent overlay antigen mapping have also been used to differentiate between antiepiligrin CP and EBA.

### Treatment

A review of studies using the Cochrane criteria found two small RCTs, both in patients with severe eye involvement. In one, 6 months of cyclophosphamide was superior to prednisone. In the second RCT, 20 of 20 patients responded well to 3 months of cyclophosphamide, but only 14 of 20 responded to dapsone. Based on these limited data and other, uncontrolled trials, the reviewers concluded that patients with severe ocular CP respond best to cyclophosphamide combined with corticosteroids, and that those with mild to moderate disease may respond to dapsone. MMF and rituximab have also been used effectively.

In patients with mild CP, oral hygiene, topical corticosteroids, intralesional triamcinolone, topical calcineurin inhibi-

tors, or topical steroids occluded under vinyl inserts may be effective for desquamative gingivitis and other oral, genital, or cutaneous disease. Cream and gel formulations may be used, or the steroid may be compounded in Orabase. Topical sucralfate suspension may decrease the pain and healing time of the oral and genital ulcers. There have been reports of efficacy of thalidomide, tetracycline combined with niacinamide, dapsone, IVIG, etanercept, systemic corticosteroids, and immunosuppressive drugs.

**Bernard P, et al:** Prevalence and clinical significance of anti-laminin 332 autoantibodies detected by a novel enzyme-linked immunosorbent assay in mucous membrane pemphigoid. *JAMA Dermatol* 2013; 149(5):533–540.

**Grau AE, et al:** How to do conjunctival and buccal biopsies to investigate cicatrizing conjunctivitis: improving the diagnosis of ocular mucous membrane pemphigoid. *Br J Ophthalmol* 2013; 97(4):530–531.

**Lee YJ, et al:** Application for tacrolimus ointment in treating refractory inflammatory ocular surface diseases. *Am J Ophthalmol* 2013; 155(5):804–813.

**Nottage JM, et al:** Treatment of mucous membrane pemphigoid with mycophenolate mofetil. *Cornea* 2013; 32(6):810–815.

**Petruzzi M:** Mucous membrane pemphigoid affecting the oral cavity: short review on etiopathogenesis, diagnosis and treatment. *Immunopharmacol Immunotoxicol* 2012; 34(3):363–367.

**Saadoun D, et al:** Biotherapies in inflammatory ocular disorders: interferons, immunoglobulins, monoclonal antibodies. *Autoimmun Rev* 2013; 12(7):774–783.

**Shetty S, et al:** Critical analysis of the use of rituximab in mucous membrane pemphigoid: a review of the literature. *J Am Acad Dermatol* 2013; 68(3):499–506.

**Srikumaran D, et al:** Mucous membrane pemphigoid: recent advances. *Curr Opin Ophthalmol* 2012; 23(6):523–527.

**Suelves AM, et al:** Analysis of a novel protocol of pulsed intravenous cyclophosphamide for recalcitrant or severe ocular inflammatory disease. *Ophthalmology* 2013; 120(6):1201–1209.

**Xu HH, et al:** Mucous membrane pemphigoid. *Dent Clin North Am* 2013; 57(4):611–630.

## EPIDERMOLYSIS BULLOSA ACQUISITA

Criteria for epidermolysis bullosa acquisita (EBA) were proposed in 1971 by Roenigk and included the following:

1. Clinical lesions of dystrophic epidermolysis bullosa, including increased skin fragility, trauma-induced blistering with erosions (Fig. 21-19), atrophic scarring, milia over extensor surfaces, and nail dystrophy
2. Adult onset
3. Lack of a family history of epidermolysis bullosa

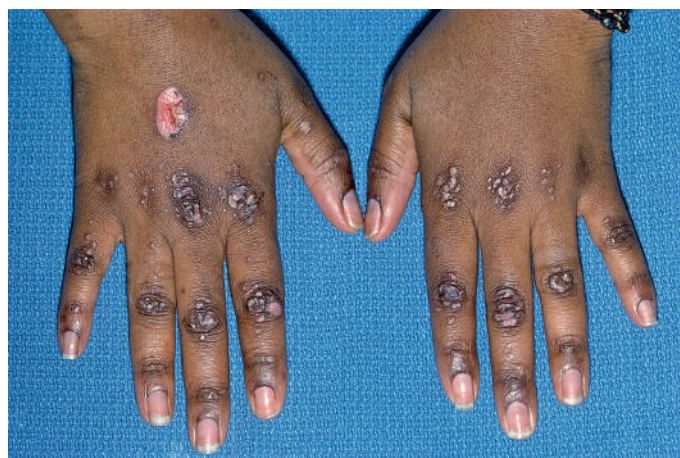

Fig. 21-19 Epidermolysis bullosa acquisita.

4. Exclusion of all other bullous diseases, such as porphyria cutanea tarda, pemphigoid, pemphigus, dermatitis herpetiformis, and bullous drug eruption

In 1981, Roenigk et al. extended these criteria to include:

5. IgG at the basement membrane zone by DIF
6. Demonstration of blister formation beneath the basal lamina
7. Deposition of IgG beneath the basal lamina

The antibodies have been found to target type VII collagen, a major component of anchoring fibrils. The target is the same as that in bullous lupus erythematosus. In some patients, it has been shown that autoantibodies bind to the NC-1 domain of collagen VII within the lamina densa. IIF studies reveal circulating anti-BMZ antibodies in approximately half of cases. B cells, dendritic cells, and macrophages are required to induce the CD4 helper T-cell response that results in the formation of pathogenic antibodies. Type VII collagen ELISA using the NC1 and NC2 domains is useful for diagnosis, and antibody levels have been shown to correlate with disease severity.

The noninflammatory clinical presentation of EBA is the most frequently recognized type. The association of EBA with many systemic diseases, such as myeloma, inflammatory bowel disease (especially Crohn's disease), diabetes, lymphoma, leukemia, amyloidosis, hepatitis C infection, and carcinoma, is well established.

In 1982, Gammon described patients with generalized inflammatory bullous disease that resembled BP clinically (Fig. 21-20), but with immunologic and ultrastructural features of EBA. Many of these patients have associated diabetes mellitus, are HLA-DR2 positive, and progress to the trauma-induced scarring type of EBA in the long term. Approximately 5–10% of patients referred to medical centers as having BP may actually have EBA.

Patients with EBA usually have a predominance of neutrophils over eosinophils, although this is variable. On IIF, EBA patients are more likely to have linear IgG without concomitant C3 deposition than are patients with BP. Immunofluorescence on salt-split skin allows differentiation of the majority of cases without the need to resort to immunoblot techniques or immunoelectron microscopy. By DIF testing of the patient's salt-split-skin biopsy, EBA will manifest IgG deposition only on the dermal side of the split, whereas the majority of BP patients will have IgG bound only to the epidermal side or to both sides. The finding of a u-serrated pattern on DIF may make the salt-split-skin assay unnecessary. As noted earlier, some patients with BP have antibodies that target sub-lamina densa antigen. Absolute differentiation of these diseases is obtained by immunoelectron microscopy or immunoblot

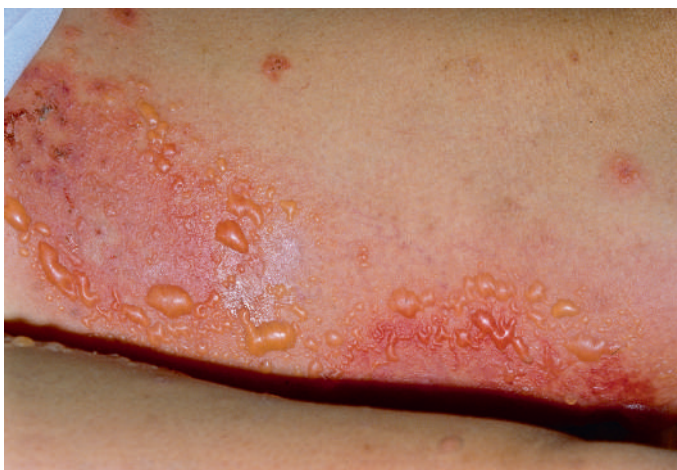

Fig. 21-20 Inflammatory epidermolysis bullosa acquisita.

findings. In EBA, immunoblotting identifies 290-kD and 145-kD proteins, corresponding to type VII collagen. Blistering appears to be T-cell dependent.

Bullous systemic lupus erythematosus (SLE) and EBA demonstrate clinical and histologic overlap, but the following features favor EBA: skin fragility, predilection for traumatized areas, and healing with scars and milia. In bullous SLE, sun-exposed skin is involved by preference, and the patient has a diagnosis of SLE established by American College of Rheumatology criteria; bullous SLE patients usually have a dramatic response to dapsone. In addition to the cases of bullous SLE that show linear IgG staining below the lamina densa with circulating IgG autoantibodies to the 290-kD and 145-kD antigens, some patients will show granular staining of IgG at the BMZ without circulating IgG. EBA-like eruptions are rarely seen as a result of penicillamine therapy.

Purely IgA-mediated EBA has been described. The patients resemble linear IgA dermatosis or inflammatory IgG-mediated EBA. Only a minority demonstrate milia or scarring. Immunoblotting or fluorescence overlay antigen mapping using laser scanning confocal microscopy can distinguish the two diseases.

## Treatment

A review of the literature using Cochrane criteria failed to identify any RCTs. EBA is often resistant to therapy, but good responses have been reported in some patients treated with systemic corticosteroids alone or in combination with azathioprine or dapsone. Other agents reported to be effective include rituximab, MMF, IVIG, cyclosporine, colchicine, plasmapheresis, photophoresis, infliximab, and the humanized murine monoclonal anti-Tac antibody, daclizumab. Supportive therapy, including control of infection, careful wound management, and maintenance of good nutrition, should be emphasized.

**Arbache ST, et al:** Immunofluorescence testing in the diagnosis of autoimmune blistering diseases: overview of 10-year experience. *An Bras Dermatol* 2014; 89:885–889.

**Hellberg L, et al:** Methylprednisolone blocks autoantibody-induced tissue damage in experimental models of bullous pemphigoid and epidermolysis bullosa acquisita through inhibition of neutrophil activation. *J Invest Dermatol* 2013; 133(10):2390–2399.

**Iwata H, et al:** B cells, dendritic cells, and macrophages are required to induce an autoreactive CD4 helper T cell response in experimental epidermolysis bullosa acquisita. *J Immunol* 2013; 191(6):2978–2988.

**Kim JH, et al:** Serum levels of anti-type VII collagen antibodies detected by enzyme-linked immunosorbent assay in patients with epidermolysis bullosa acquisita are correlated with the severity of skin lesions. *J Eur Acad Dermatol Venereol* 2013; 27(2):e224–e230.

**Kim JH, et al:** Successful treatment of epidermolysis bullosa acquisita with rituximab therapy. *J Dermatol* 2012; 39(5):477–479.

**Komorowski L, et al:** Sensitive and specific assays for routine serological diagnosis of epidermolysis bullosa acquisita. *J Am Acad Dermatol* 2013; 68(3):e89–e95.

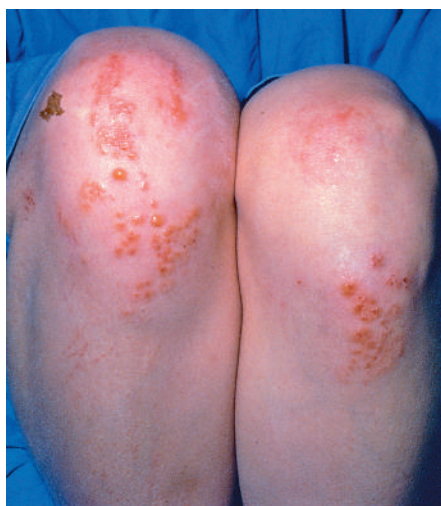**Ludwig RJ:** Clinical presentation, pathogenesis, diagnosis, and treatment of epidermolysis bullosa acquisita. *ISRN Dermatol* 2013; 2013:812029.

**Reddy H, et al:** Epidermolysis bullosa acquisita and inflammatory bowel disease: a review of the literature. *Clin Exp Dermatol* 2013; 38(3):225–229.

**Terra JB, et al:** The n- vs. u-serration is a learnable criterion to differentiate pemphigoid from epidermolysis bullosa acquisita in direct immunofluorescence serration pattern analysis. *Br J Dermatol* 2013; 169(1):100–105.

**Wozniak K, et al:** Fluorescence overlay antigen mapping using laser scanning confocal microscopy differentiates linear IgA bullous dermatosis from epidermolysis bullosa acquisita mediated by IgA. *Br J Dermatol* 2013; 168(3):634–638.





**Fig. 21-21** Dermatitis herpetiformis.

## DERMATITIS HERPETIFORMIS (DUHRING DISEASE)

### Clinical features

Dermatitis herpetiformis (DH) is a chronic, relapsing, severely pruritic disease characterized by grouped, symmetric lesions on extensor surfaces, the scalp, nuchal area, and buttocks. The lesions are severely pruritic and thus generally present as excoriations. The eruption usually occurs on an erythematous base and may be papular, papulovesicular, vesiculobullous (Fig. 21-21), bullous, or urticarial. Linear petechial lesions may be noted on the volar surfaces of the fingers, as well as the palms (see eFig. 21-19 online). Pigmented spots alone over the lumbosacral region should arouse suspicion of DH. The mucous membranes are involved in rare cases, mostly when bullae are numerous. Laryngeal lesions may manifest as hoarseness. Itching is usually intense, but spontaneous remissions lasting as long as 1 week and terminating abruptly with a new crop of lesions are a characteristic feature of the disease. Perimenstrual flares may occur.

Between 77% and 90% of patients with DH and IgA deposits in the skin are HLA-B8 positive, a similar frequency to that observed in gluten-sensitive enteropathy (GSE). HLA antigens DR3 and DQw2 are also increased in frequency. Black and Asian patients are uncommon, possibly because of HLA differences. These HLA markers are associated with other autoimmune diseases and indicate patients who appear to have an overactive immune response to common antigens and who may clear immune complexes slowly. DH is more common in those with affected family members.

In childhood, DH is usually similar to the adult type, has identical histologic and immunofluorescent findings, and has a high incidence of HLA-B8 and DR3 and abnormal jejunal biopsies. Palmar blisters and brown, hemorrhagic, purpuric macules may be more common than in adults. Treatment with sulfones results in prompt response in children, as in adults.

Gluten, a protein found in cereals, except for rice and corn, provokes flares of the disease. Villous atrophy of the jejunum and inflammation of the small bowel occur. IgA is bound to the skin, and this apparently activates complement, primarily through the alternate pathway. Oral iodides will cause a flare of the disease. Patch tests with 50% potassium iodide in petrolatum produce a bulla in uncontrolled DH, but only exceptionally in patients controlled by a gluten-free diet or by sulfone therapy.

### Associated disease

Thyroid disorders are increased in incidence in patients with DH. Neurologic disease, including ataxia, may occur. An increased incidence of malignancy, especially small bowel lymphoma, has also been noted in some studies, although others have reported this increase with celiac disease but not DH. In fact, the incidence of breast cancer may be lower in those with DH than in the general population.

### Enteropathy

Between 70% and 100% of patients with DH have abnormalities in the jejunal mucosa, but most are asymptomatic. If given a high-gluten diet, virtually all patients with DH develop findings indistinguishable from celiac disease, and DH affects approximately 25% of patients presenting with celiac disease.

The dapsons requirement in DH is usually decreased after 3–6 months of a gluten-free diet. The majority of patients who adhere to a strict gluten-free diet can eventually stop their medication or significantly reduce the dosage. A gluten-free diet is not easy to follow but may decrease the incidence of intestinal lymphoma.

### Diagnosis

The distinction of DH from linear IgA bullous dermatosis is often clinically impossible. Other conditions considered in the differential diagnosis at times are BP, bullous EM, scabies, contact dermatitis, atopic dermatitis, nummular eczema, neurotic excoriations, insect bites, and chronic bullous disease of childhood. The finding of IgA in a granular pattern at the DEJ with accentuation in the dermal papillae is specific for DH.

### Autoantibodies

Circulating IgA antibodies against the smooth muscle cell endomysium (antiendomysial antibodies) are present in 70% of DH patients, in almost all patients with active celiac disease, and almost never in other conditions. Tissue transglutaminase (TTG) is the major autoantigen in GSE. IgA antibodies directed at TTG2 are common in patients with DH or celiac disease, but epidermal transglutaminase (TTG3) appears to be the most important antigen. Dietary exposure to gliadin proteins in wheat and related proteins from barley and rye induce flares of the disease. These proteins are high-affinity substrates for TTG. The two are often tightly bound, which may explain why an antibody response is generated against both gliadin and TTG. Gliadins can also be found in rice, corn, and oats, but these proteins are poor substrates for TTG.

### Epidemiology

This disease has an equal male-to-female incidence. The average age of onset is 20–40 years. DH does occur with some frequency in children. Black and Asian persons are rarely affected.

### Histopathology

The initial changes of DH are noted at the tips of the dermal papillae, where edema, focal fibrin, and neutrophilic microabscesses are seen. The cellular infiltrate contains many

neutrophils but may also include a few eosinophils. A subepidermal separation is noted histologically. Ultrastructurally, the split may begin in the lamina lucida. In a study of 24 patients with confirmed DH, 37.5% had nonspecific findings on hematoxylin and eosin (H&E) staining, including a lymphocytic infiltrate, ectatic capillaries, and fibrosis in the dermal papillae. Because of the potential for nonspecific biopsy findings, DIF studies are essential. Histologic differentiation of linear IgA bullous dermatosis from DH is extremely difficult unless DIF is performed. DIF of noninvolved perilesional skin reveals deposits of IgA alone or together with C3 arranged in a granular pattern at the DEJ. The deposits are typically accentuated in the dermal papillae. IgM and IgG deposits are occasionally observed in association with IgA. Deposits may be focal, so multiple biopsies may be needed, and the deposits of antibody are more often seen in previously involved skin or normal-appearing skin adjacent to involved skin. IgA is observed by immunoelectron microscopy, either alone or in conjunction with C3, IgG, or IgM, as clumps in the upper dermis. A vertically oriented fibrillar staining pattern exists in a subset of patients, with immune deposits along dermal microfibrils, creating a "picket fence" pattern of immunofluorescence. The fibrillar pattern is present in a third of Japanese patients, and this group lacks the typical distribution of skin lesions and has a low association with celiac disease. A few patients will have negative DIF despite typical clinical findings and evidence of antiendomysial antibodies. IIF is rarely positive.

## Treatment

The drugs chiefly used for DH are dapsone and sulfapyridine. The most effective sulfone is diaminodiphenylsulfone (dapsone). The dose varies between 50 and 300 mg/day, usually starting with 100 mg/day and increasing gradually to an effective level or until side effects occur. Once a favorable response is attained, the dosage is decreased to the minimum that does not permit recurrence of signs and symptoms. When dapsone is discontinued abruptly, large bullae similar to those seen in BP frequently occur. Hemolytic anemia, leukopenia, methemoglobinemia, agranulocytosis, or peripheral neuropathy may occur with dapsone. Acute hemolytic anemia (which may be severe) occurs in patients with glucose-6-phosphate dehydrogenase (G6PD) deficiency; therefore, G6PD level should be measured before therapy. In those whose ethnic background makes G6PD deficiency unlikely, some authorities begin dapsone at a low starting dose (25 mg/day) and watch the patient closely for dark urine. The patient should be warned to report by telephone any incident of red or brown urine or blue nail beds or lips. A blood count should be done weekly for 4 weeks, bimonthly for the next 3 months, and every 2–6 months thereafter. Liver function tests should be monitored bimonthly for the first 4 months, then checked with the hematologic studies every 4–6 months.

Agranulocytosis is rare. It typically occurs 1–3 months after initiation of drug therapy, and presents with sore throat, aphthae, or evidence of infection. The risk of agranulocytosis is higher in older patients (>60 years) and nonwhite persons. The incidence varies with the disease. It is rarely seen in patients with Hansen's disease, but patients with DH have a 25-fold to 33-fold increased risk.

Sulfapyridine can also be used to treat the disease. After a test dose of 0.5 g of sulfapyridine, 1 tablet (0.5 g) is given four times daily. The dose is then increased if necessary, or reduced if possible. Usually, 1–4 g/day is required for good control. The drug is less water soluble than dapsone, and patients should remain hydrated. Sulfasalazine, 500 mg three

times daily, increased to 1.5 g three times daily as tolerated, may also be used, since sulfapyridine is a metabolic product. GI intolerance may limit the dosage. In rare patients, it is necessary to find alternatives to the sulfone drugs. Tetracycline/nicotinamide and colchicine have controlled individual patients.

## Gluten-free diet

Patients must strictly avoid wheat, barley, and rye. Moderate amounts of oats may be tolerated. In Canada, standards for growing, processing, testing, and labeling of pure, uncontaminated oats have allowed adults to consume up to 70 g (about one-half to three-quarters cup) of oats and children to consume up to 25 g (one-quarter cup) daily without flares of disease. Corn and rice are generally well tolerated, corresponding to the poor binding of their gliadin proteins to TTG, but exacerbation of disease related to cornstarch has been reported. If a gluten-free diet is followed strictly, the patient will almost certainly be able to take less medication or stop it altogether. Some evidence suggests that this may decrease the incidence of associated malignancy; however, it is a very difficult diet to follow.

Once a prolonged remission has been obtained, some gluten may be tolerated in a subset of patients. In one study, 38 patients who had followed a gluten-free diet for a mean of 8 years reintroduced gluten to their diets. Thirty-one experienced recurrence within an average of 2 months, but seven remained in remission for a mean follow-up of 12 years. IgA deposits did not recur in their skin. This report suggests that clinical and histologic remission can be maintained in some patients with DH despite the reintroduction of dietary gluten.

For most patients, however, a gluten-free diet remains an important aspect of disease management. Fortunately, many grocery stores now have a section devoted to gluten-free products. Support may be obtained from the American Celiac Society/Dietary Support Coalition ([www.americancelicsociety.org/diet.html](http://www.americancelicsociety.org/diet.html)) or from celiac societies ([www.nowheat.com/grfx/nowheat/primer/celisoc.htm](http://www.nowheat.com/grfx/nowheat/primer/celisoc.htm) or [www.enabling.org/ia/cealic/groups/groupsus.html](http://www.enabling.org/ia/cealic/groups/groupsus.html)). A commercial website with a search engine can be found at [www.celiac.com](http://www.celiac.com). Another commercial source for products can be found at [www.glutenfreemall.com](http://www.glutenfreemall.com). An Internet search using the terms "celiac society" or "gluten-free diet" is a good starting point for patients with the disease who want more information about the diet and commercially available products.

**Al-Niaimi F, et al:** Dermatitis herpetiformis exacerbated by cornstarch. *J Am Acad Dermatol* 2010; 62(3):510–511.

**Antiga E, et al:** Clinical and immunopathological features of 159 patients with dermatitis herpetiformis: an Italian experience. *G Ital Dermatol Venereol* 2013; 148(2):163–169.

**Fabbri P, et al:** Novel advances in dermatitis herpetiformis. *Clin Dev Immunol* 2012; 2012:450109.

**Fasano A:** Novel therapeutic/integrative approaches for celiac disease and dermatitis herpetiformis. *Clin Dev Immunol* 2012; 2012:959061.

**Huber C, et al:** Negative direct immunofluorescence and nonspecific histology do not exclude the diagnosis of dermatitis herpetiformis Dühring. *Int J Dermatol* 2013; 52(2):248–249.

**Jakes AD, et al:** Dermatitis herpetiformis. *BMJ* 2014; 348:g2557.

**Nakajima K:** Recent advances in dermatitis herpetiformis. *Clin Dev Immunol* 2012; 2012:914162.

**Ohata C, et al:** Distinct characteristics in Japanese dermatitis herpetiformis: a review of all 91 Japanese patients over the last 35 years. *Clin Dev Immunol* 2012; 2012:562168.

**Tu H, et al:** Acral purpura as leading clinical manifestation of dermatitis herpetiformis: report of two adult cases with a review of the literature. *Dermatology* 2013; 227(1):1–4.



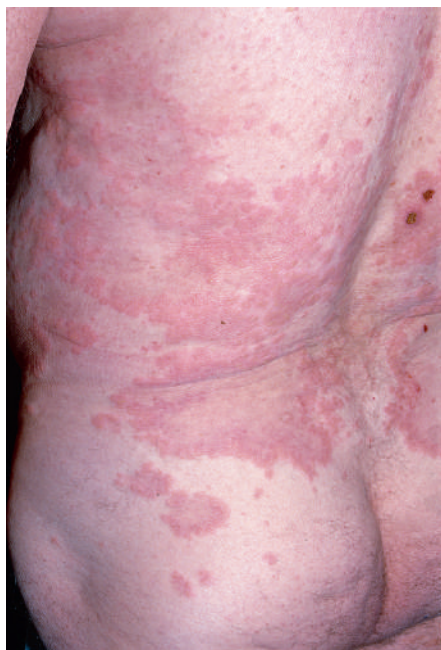## LINEAR IGA BULLOUS DERMATOSIS

Linear IgA bullous dermatosis (LAD) is characterized by subepidermal blisters, a neutrophilic infiltrate, and a circulating IgA anti-BMZ antibody with linear BMZ deposits on DIF. As with CP, LAD is really a group of diseases with a similar immunofluorescent pattern.

### Adult linear IgA disease

Adult patients with LAD may present with a clinical pattern of vesicles indistinguishable from DH or with vesicles and bullae having a BP-like appearance. They may have urticarial lesions, and bullae may occur on an urticarial base, as in BP (Fig. 21-22). Unusual variants include morbilliform, prurigo-like, and eczematous presentation. Mucous membrane involvement may occur in up to 50% of patients. In some, oral and conjunctival lesions dominate the presentation, and scarring may occur, as in CP. In the majority of patients, there is no association with enteropathy or with HLA-B8. The disease remits after several years in approximately 60% of patients. IgA is typically directed against a 97-kD antigen in the lamina lucida. Some patients demonstrate both IgA and IgG antibodies to BP180, and IgA to LAD285. IgA and IgG reactivity has been found to all three portions of the BP180 ectodomain. In some patients, the strongest reactivity is to the C-terminal portion of BP180 (major antigenic area in CP). This may explain cases of clinical overlap with CP. Antigenic targets for LAD are expressed by both keratinocytes and fibroblasts.

Linear IgA dermatosis frequently occurs as a drug-induced disease. In drug-induced LAD, the eruption is self-limited, there is less mucosal involvement, and usually no detectable circulating autoantibody. The IgA may be deposited in the sub-basal lamina area. Implicated drugs include vancomycin, lithium, amiodarone, carbamazepine, captopril, penicillin, amoxicillin, moxifloxacin, PUVA, furosemide, oxaprozin, IL-2, interferon (IFN)- $\alpha$ , phenytoin, diclofenac, statins, tea tree oil, angiotensin receptor antagonists, sulfasalazine, buprenorphine, ustekinumab, and glibenclamide. The antigen identified may be the 97-kD antigen, the 230-kD BP antigen, or the 180-kD BP antigen.



**Fig. 21-22** Adult linear IgA disease.

Some cases have been associated with internal malignancy, paraproteinemia, or infection. Sporadic reports have linked single cases with dermatomyositis, rheumatoid arthritis, acquired hemophilia, and multiple sclerosis, although these may be fortuitous associations.

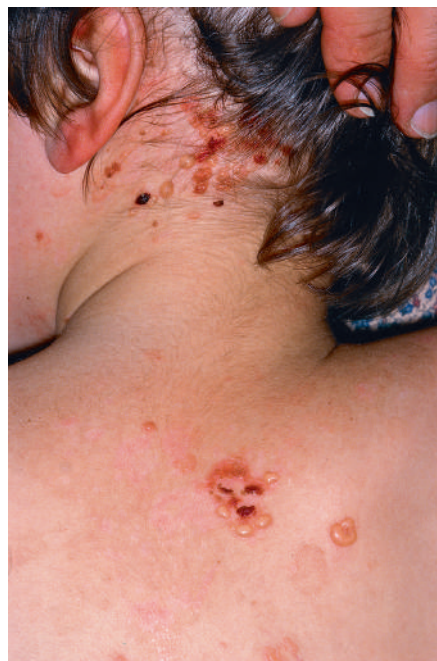Biopsies typically demonstrate papillary dermal microabscess with neutrophils. As in DH, eosinophils may be present. On DIF, a homogeneous linear (tubular or toothpaste) pattern of IgA is present at the BMZ. Some patients will have both linear IgA and IgG in combination at the BMZ. A lack of C3 may be a clue that both immunoglobulins recognize the 97-kD antigen.

By IIF, only a minority of LAD patients will have circulating IgA autoantibody with anti-BMZ specificity, and this is usually present in low titer. On salt-split skin, deposition may occur on the roof or base, or a combination of the two.

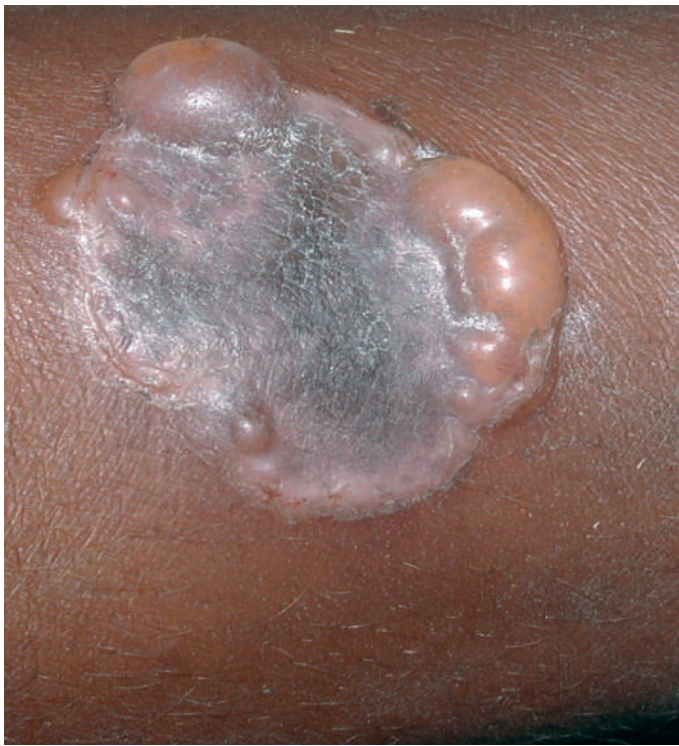In drug-induced disease, the drug must be stopped. Many cases resolve quickly, but some patients require drug therapy with a corticosteroid or dapsone. Idiopathic disease generally responds to dapsone in doses similar to that described for DH. Other patients require topical or systemic corticosteroids in addition, or as sole treatment. A combination of tetracycline, 2 g/day, and nicotinamide, 1.5 g/day, may be effective. Other patients have responded to MMF, IVIG, colchicine, trimethoprim-sulfamethoxazole, or erythromycin. The rare patients with associated GSE may respond to a gluten-free diet.

### Childhood linear IgA disease (chronic bullous disease of childhood)

Chronic bullous disease of childhood (CBDC) is an acquired, self-limited bullous disease that may begin by the time the patient is 2 or 3 years old and usually remits by age 13 (Fig. 21-23). The average age of onset is 5 years. Bullae develop on either erythematous or normal-appearing skin, preferentially involving the lower trunk, buttocks, genitalia, and thighs. Perioral and scalp lesions are common, and oral mucous membrane lesions may occur in up to 75% of patients. Bullae are often arranged in rosettes or an annular array, the so-called string of pearls configuration (Fig. 21-24). Tense individual bullae similar to those in BP are also seen. Pruritus is often severe.



**Fig. 21-23** Chronic bullous disease of childhood.



**Fig. 21-24** Chronic bullous disease of childhood. (Courtesy Dr. Shyam Verma.)

The prime histologic finding is the presence of a subepidermal bulla filled with neutrophils. Eosinophils may be present, and in some cases they predominate. DIF reveals a linear deposition of IgA at the BMZ identical to that seen in the adult forms of the disease. IIF is positive for circulating IgA anti-BMZ antibodies in approximately 50% of patients, usually in low titer. In contrast to adults with LAD, children demonstrate an increased frequency of B8, DR3, and DQ2 and may be homozygous for these antigens. As in the adult disease, immunoelectron microscopy and immunomapping studies may demonstrate immune deposits within the lamina lucida, below the lamina densa, or both. Also as in adult disease, some children have both IgG and IgA deposits. GSE is rare, but IgA nephropathy may occur. Childhood linear IgA disease has occurred in conjunction with Crohn's disease.

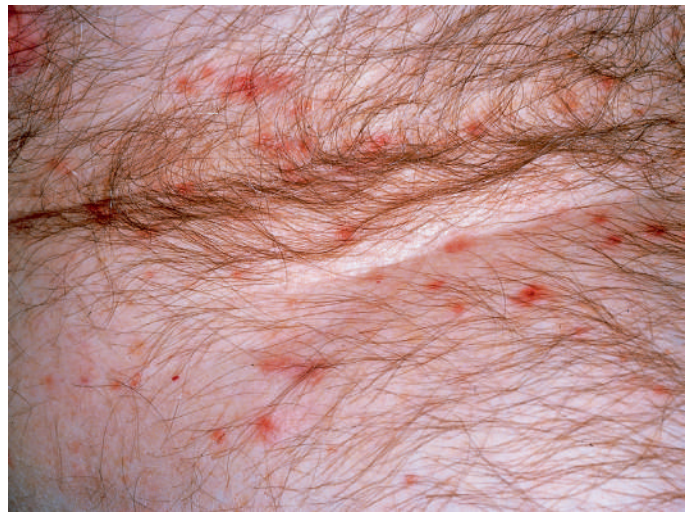Many patients' antibodies target the 97-kD peptide. Some children with sub-basal lamina deposits target type VII collagen and have EBA. Patients with only IgA or with both IgG and IgA circulating autoantibodies may target BP230 or BP180. Individual patients may have a combination of IgA against the 97-kD peptide, and IgG against BP230 and BP180. Collagen XVII/BP180 is a transmembrane protein with a soluble 120-kD ectodomain. In linear IgA dermatosis and CBDC, IgA targets the soluble ectodomain more efficiently than the full-length protein. Some sera target the Col15 domain.

The untreated disease runs a variable course, typically with eventual spontaneous resolution by adolescence. Treatment with either dapsone or sulfapyridine is usually successful. Occasional cases respond to topical corticosteroids alone, and systemic corticosteroids are sometimes necessary. Other patients have responded to MMF, colchicine, topical calcineurin inhibitors, or dicloxacillin.

**Becker JG, et al:** Development of linear IgA bullous dermatosis in a patient with psoriasis taking ustekinumab. *J Am Acad Dermatol* 2012; 67(4):e150–e151.

**Chen S, et al:** Linear IgA bullous dermatosis. *Eplasty* 2013; 13:ic49.

**Maruta Y, et al:** Linear IgA bullous dermatosis with a prurigo nodularis-like appearance. *Eur J Dermatol* 2013; 23(1):107–109.



**Fig. 21-25** Transient acantholytic dermatosis.

## TRANSIENT ACANTHOLYTIC DERMATOSIS (GROVER'S DISEASE)

In 1970, Grover described a new dermatosis that occurred predominantly in persons over 50 years of age and consisted of a sparse eruption of limited duration. The lesions were fragile vesicles that rapidly turned into crusted and keratotic erosions. He termed the condition transient acantholytic dermatosis (TAD). Since then, the majority of cases have been found to persist or recur, and the term "persistent and recurrent acantholytic dermatosis" may be a more accurate description of the disorder. The distribution is predominantly limited to the chest or shoulder girdle area and upper abdomen, and there is a strong male predominance (Fig. 21-25). The condition often appears or flares during periods of heat, sweating, or hospitalization. Many patients are asymptomatic, and the condition may be an incidental finding on examination. Other patients complain of pruritus. Asteatotic eczema occurs five times as often among patients with TAD as in controls. The disorder has been described in the setting of a variety of malignancies, but it may be associated with the hospitalization or type B symptoms rather than the malignancy itself. TAD has been reported with cetuximab. Patients on strict bed rest appear to have a higher incidence of the disease. The clinical differential diagnosis includes Galli-Galli disease, an acantholytic variant of Dowling-Degos disease that may resemble TAD clinically.

There are five histologic types, resembling Darier's disease, PV, PF, benign familial pemphigus, or spongiotic dermatitis. The Darier type predominates. Often, two or more types can be found in a single biopsy specimen. DIF studies yield negative or nonspecific results. Although heat and sweating are significant risk factors, only a minority of cases are associated with acrosyringia histologically. Impairment of keratinocytic cholinergic receptors has been suggested as a pathogenic mechanism.

About 50% of patients respond to topical corticosteroids. Control of fever, hospital discharge, and avoidance of sun and sweating often result in improvement. Sustained remission has been described after a course of systemic corticosteroids. Topical antibiotics, isotretinoin, and dapsone have been successful in some patients. Psoralen plus UVA (PUVA) has been reported to result in an initial flare followed by slow clearance, and UVB therapy may produce clearing in some patients. Photodynamic therapy with red light and 5-aminolevulinic acid



has been reported as successful, and rituximab has produced clearing of TAD in patients being treated for lymphoma.

**Gilchrist H, et al:** Galli-Galli disease: a case report with review of the literature. *J Am Acad Dermatol* 2008; 58(2):299–302.

**Liu S, et al:** Successful novel treatment of recalcitrant transient acantholytic dermatosis (Grover disease) using red light

5-aminolevulinic acid photodynamic therapy. *Dermatol Surg* 2013; 39(6):960–961.

**Paslin D:** Grover disease may result from the impairment of keratinocytic cholinergic receptors. *J Am Acad Dermatol* 2012; 66(2):332–333.



Bonus images for this chapter can be found online at [expertconsult.inkling.com](http://expertconsult.inkling.com)

**eFig. 21-1** An n-serrated immunofluorescent pattern.

**eFig. 21-2** A u-serrated immunofluorescent pattern.

**eFig. 21-3** Oral pemphigus vulgaris.

**eFig. 21-4** Nonhealing crusted lesions of pemphigus vulgaris.

**eFig. 21-5** Nonhealing erosions of pemphigus vulgaris.

**eFig. 21-6** Pemphigus foliaceus.

**eFig. 21-7** Pemphigus foliaceus.

**eFig. 21-8** Pemphigus erythematosus.

**eFig. 21-9** Intraepidermal neutrophilic IgA dermatosis.

**eFig. 21-10** Pemphigoid in psoriatic plaques (psoriasis pemphigoides).

**eFig. 21-11** Bullous pemphigoid.

**eFig. 21-12** Urticarial bullous pemphigoid.

**eFig. 21-13** Bullous pemphigoid.

**eFig. 21-14** Bullous lesions of pemphigoid gestationis. (Courtesy of Dr. Martha McCollough.)

**eFig. 21-15** Cicatricial pemphigoid.

**eFig. 21-16** Antilaminin cicatricial pemphigoid.

**eFig. 21-17** Brunsting-Perry pemphigoid.

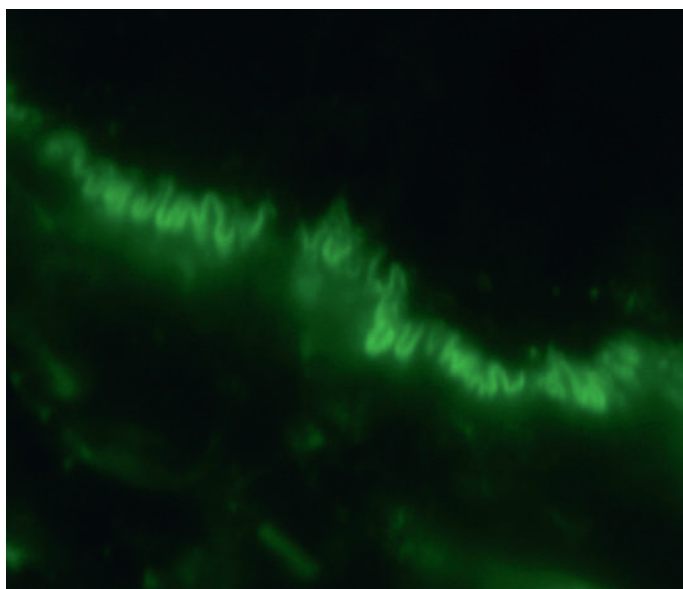
**eFig. 21-18** Epidermolysis bullosa acquisita.

**eFig. 21-19** Characteristic linear petechial lesions on the digits in a patient with dermatitis herpetiformis.

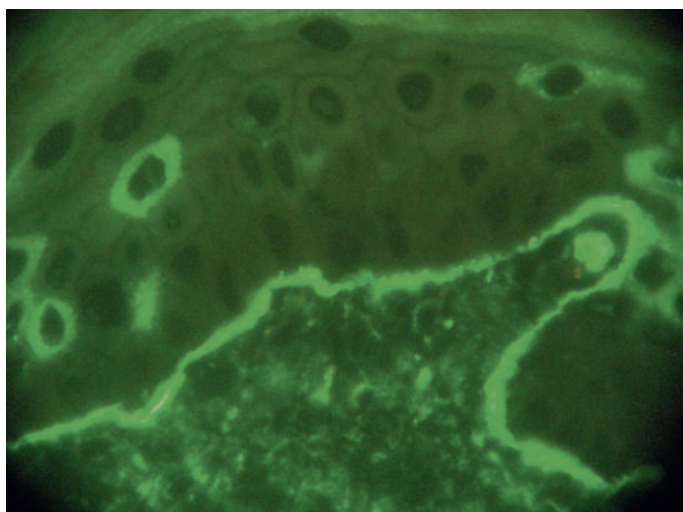
**eFig. 21-20** Dermatitis herpetiformis, neutrophilic microabscesses within dermal papillae.

**eFig. 21-21** Direct immunofluorescence of linear IgA disease.

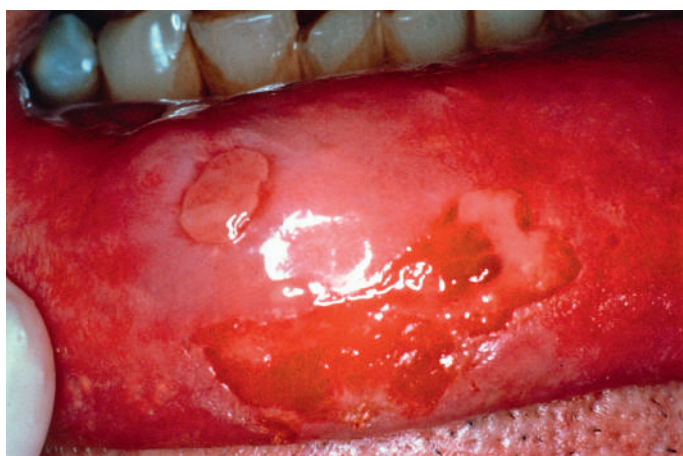
**eFig. 21-22** Chronic bullous disease of childhood.



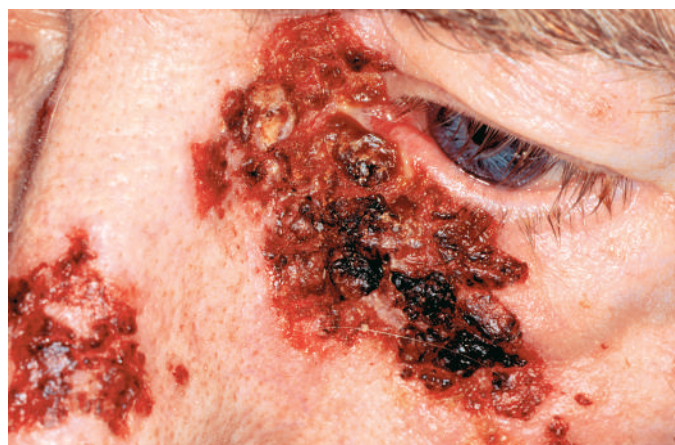eFig. 21-1 An n-serrated immunofluorescent pattern.



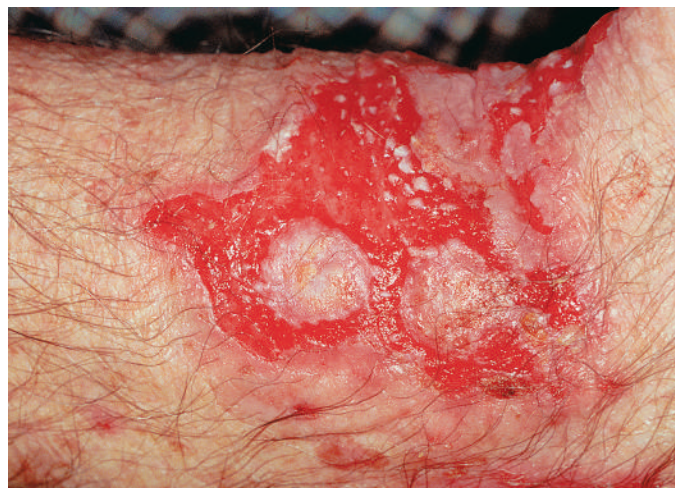eFig. 21-2 A u-serrated immunofluorescent pattern.



eFig. 21-3 Oral pemphigus vulgaris.

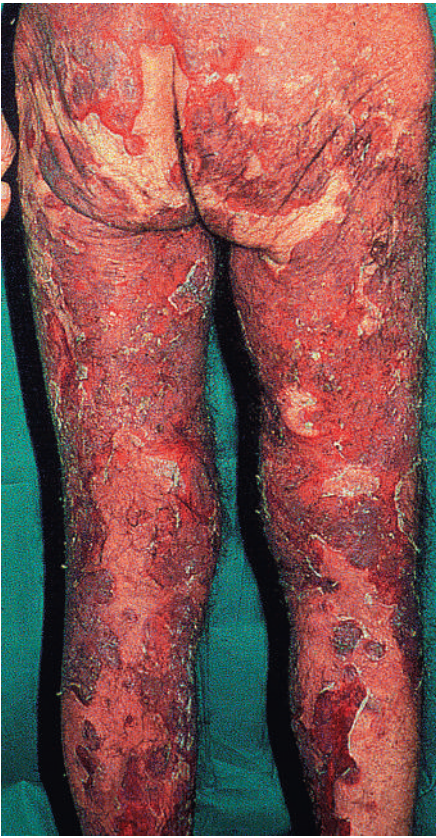

eFig. 21-4 Nonhealing crusted lesions of pemphigus vulgaris.

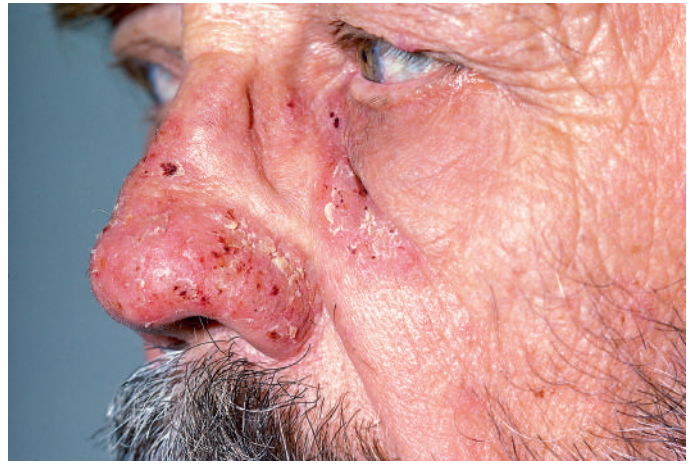

eFig. 21-5 Nonhealing erosions of pemphigus vulgaris.

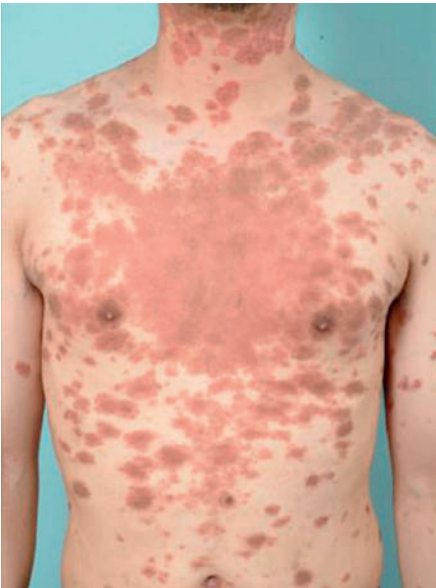



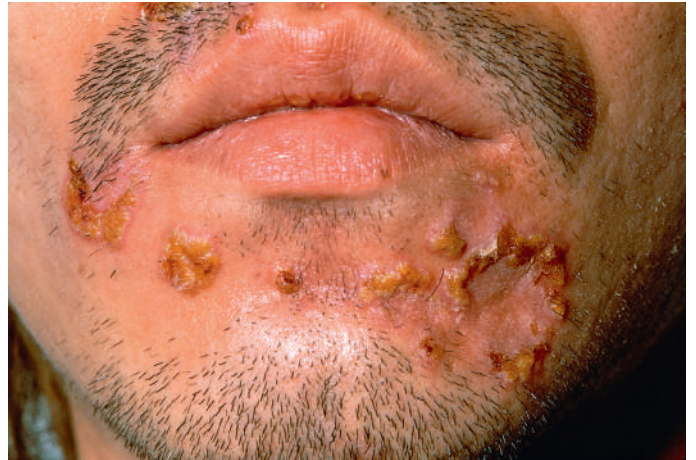**eFig. 21-6**  
Pemphigus  
foliaceus.



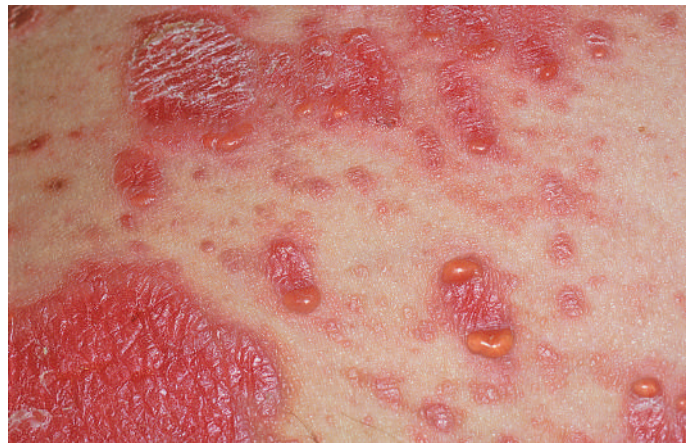
**eFig. 21-8** Pemphigus erythematosus.



**eFig. 21-7** Pemphigus  
foliaceus.

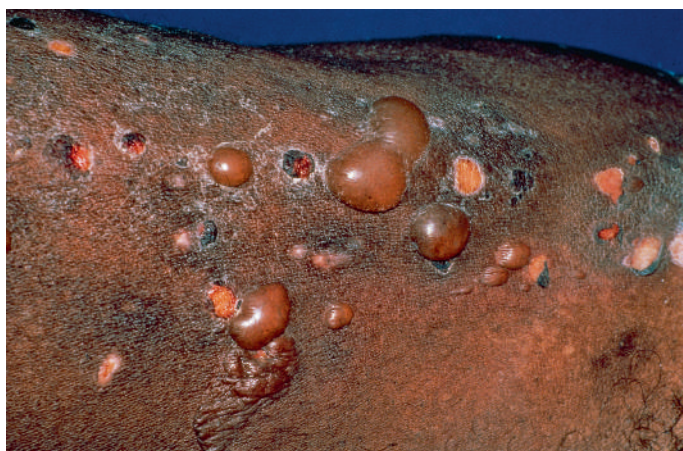

**eFig. 21-9** Intraepidermal neutrophilic IgA dermatosis.

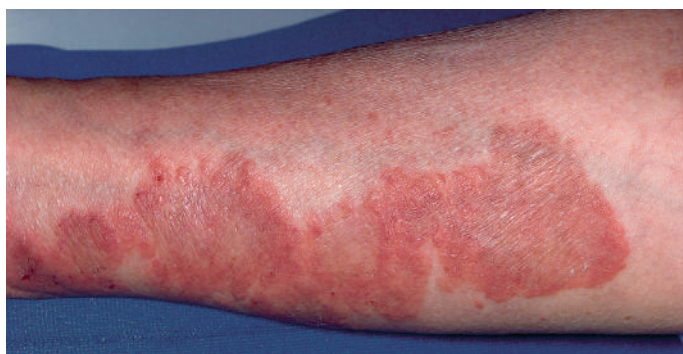


**eFig. 21-10** Pemphigoid in psoriatic plaques (psoriasis pemphigoides).

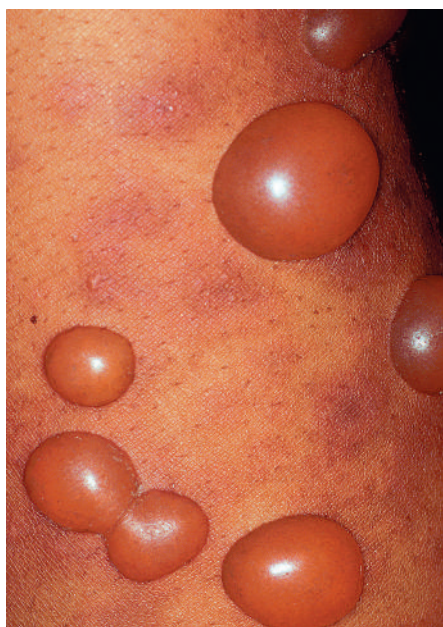



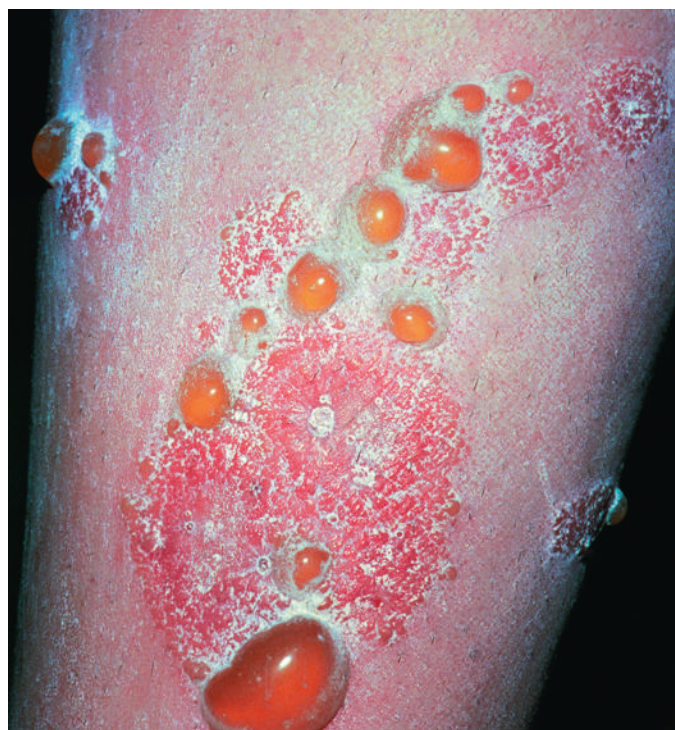eFig. 21-11 Bullous pemphigoid.



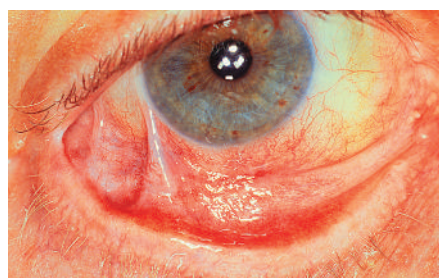
eFig. 21-12 Urticarial bullous pemphigoid.



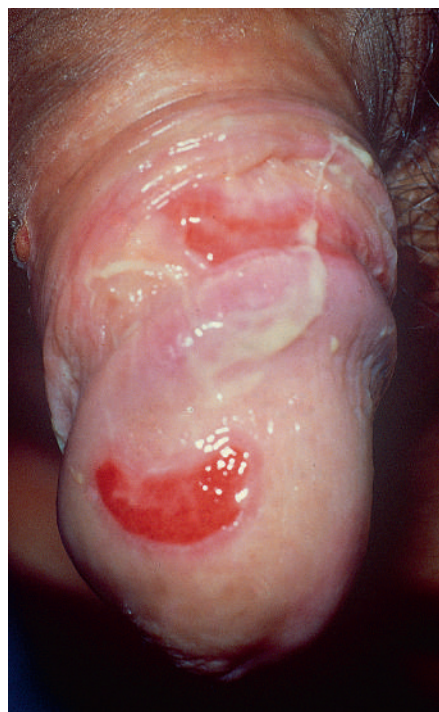eFig. 21-13 Bullous pemphigoid.



eFig. 21-14 Bullous lesions of pemphigoid gestationis. (Courtesy of Dr. Martha McCollough.)

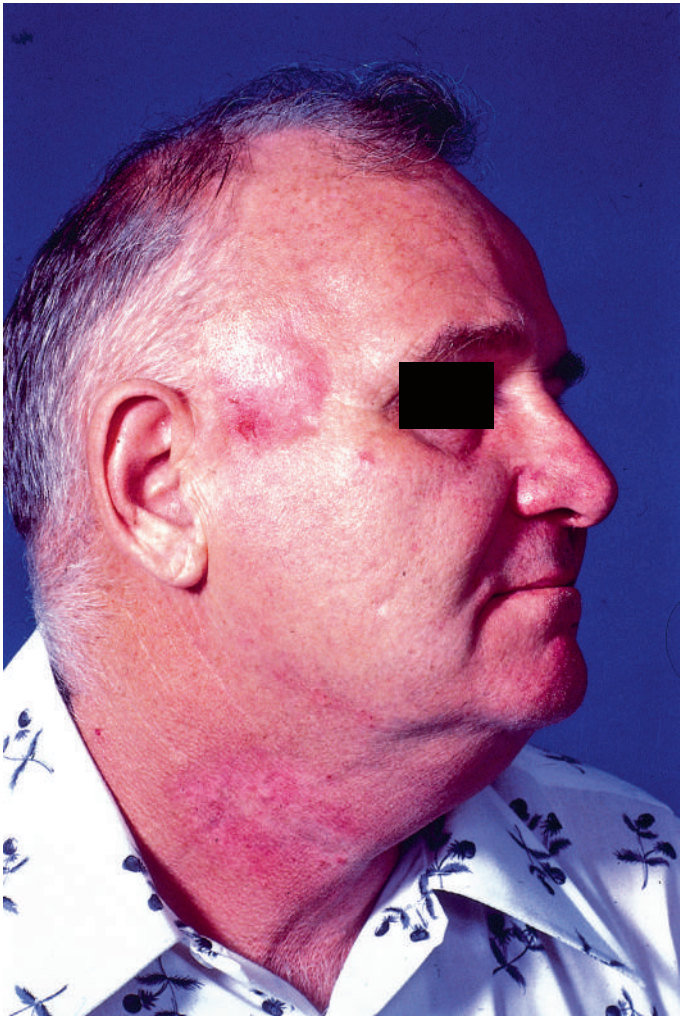

eFig. 21-15 Cicatricial pemphigoid.

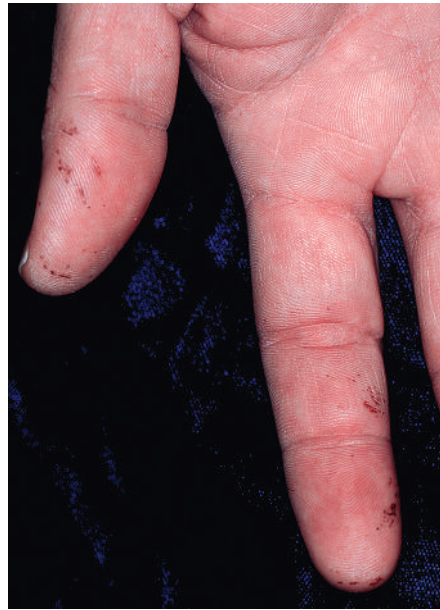

eFig. 21-16 Antilaminin cicatricial pemphigoid.

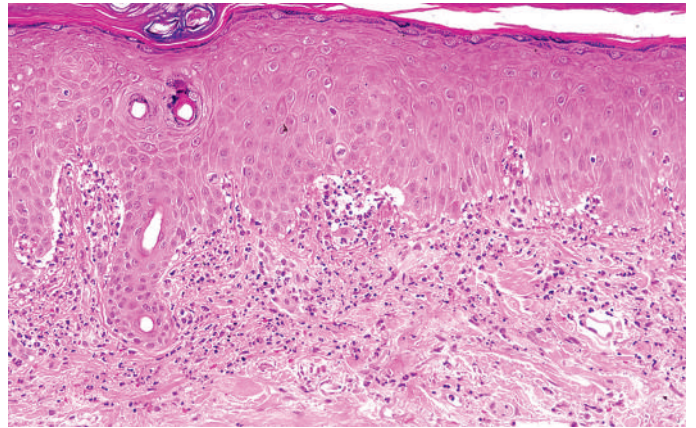




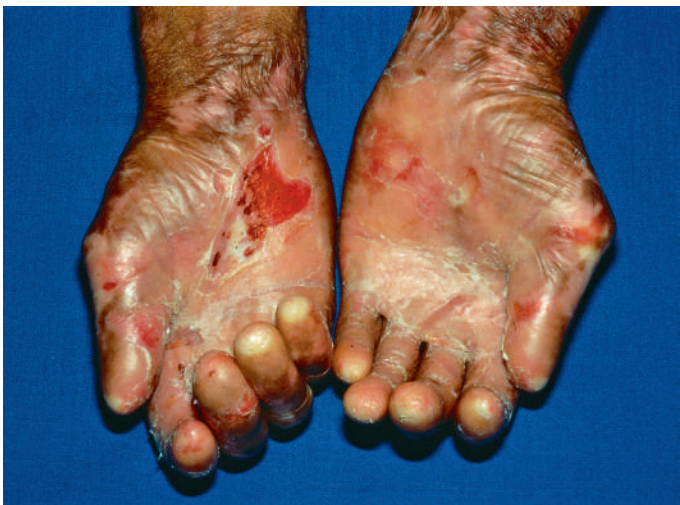**eFig. 21-17** Brunsting-Perry pemphigoid.



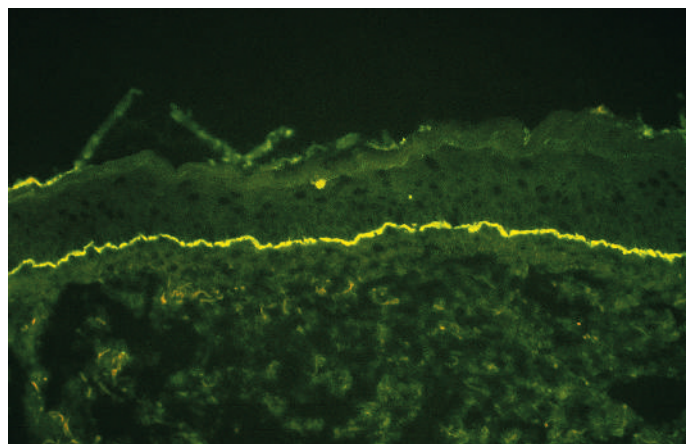
**eFig. 21-19**  
Characteristic linear  
petechial lesions on  
the digits in a patient  
with dermatitis  
herpetiformis.



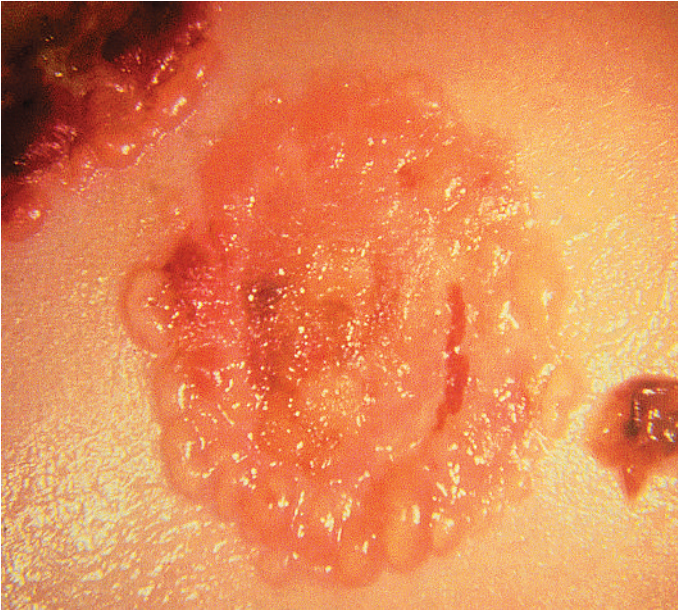
**eFig. 21-20** Dermatitis herpetiformis, neutrophilic microabscesses within dermal papillae.



**eFig. 21-18** Epidermolysis bullosa acquisita.



**eFig. 21-21** Direct immunofluorescence of linear IgA disease.



**eFig. 21-22** Chronic bullous disease of childhood.





## Nutritional Diseases

# 22

A nutritional disease is caused either by insufficiency or, less often, by excess of one or more dietary essentials. Nutritional diseases are particularly common in underdeveloped tropical countries. Infants and children are particularly at risk for deficiency states, especially malnutrition. Frequently, patients have features of several of these disorders if their diet has generally been restricted. An intertriginous or acral eruption, a seborrheic dermatitis-like facial eruption, atrophic glossitis, and alopecia are common features of many nutritional deficiencies. This occurs because these nutrients are essential to overlapping metabolic pathways of fatty acid metabolism, resulting in abnormal differentiation of the epidermis and defective barrier function. The histologic findings in many types of nutritional dermatosis are also similar.

In developed countries, alcoholism is the main cause of nutritional diseases. Nutritional diseases should also be suspected in postoperative patients; psychiatric patients, including those with anorexia nervosa and bulimia; patients on unusual diets; patients with surgical or inflammatory bowel dysfunction, especially Crohn's disease; patients who have had bowel bypass surgery; cystic fibrosis patients; and patients with severe oral erosive disease (e.g., pemphigus) that prevents eating. In the pediatric setting, nutritional deficiency may also occur because of parental ignorance of the nutritional requirements of their infants.

The diagnosis of nutritional deficiency is often missed because physicians fail to take an adequate dietary history. The edema of protein malnutrition may mask the problem; malnourished children may gain weight through edema, staying on the growth curve. The dermatitis produced by elevated glucagon levels from islet cell tumors of the pancreas (necrolytic migratory erythema) and a similar dermatosis seen in hepatitis C infection and other forms of hepatic insufficiency (necrolytic acral erythema, pseudoglucagonoma) probably also represent nutritional deficiency dermatoses. Deficiency states caused by inborn errors of metabolism are discussed in Chapter 26. In most cases, the clinical findings and socioeconomic scenario are adequate to lead to suspicion of a specific deficiency state, and replacement therapy can confirm the diagnosis. Laboratory testing may be costly and inaccurate in some deficiency states, and patients with poor nutrition are often deficient in many nutrients simultaneously. Testing is indicated to confirm the diagnosis of zinc deficiency, in assessing essential fatty acid deficiency, and in evaluating for possible glucagonoma syndrome.

### VITAMIN A

#### Hypovitaminosis A (phrynoderma)

Vitamin A is a fat-soluble vitamin found as retinyl esters in milk, fish oil, liver, and eggs and as carotenoids in plants. Vitamin A deficiency is common in children in the developing world. It is rare in developed countries, where it is most often associated with diseases of fat malabsorption, such as bowel bypass surgery for obesity, pancreatic insufficiency, Crohn's disease, celiac disease, cystic fibrosis, and liver disease. Vitamin A is required for the normal keratinization of many mucosal surfaces. When it is deficient, the resultant abnormal keratinization leads to increased mortality from inflammatory disease of the gut and lung—diarrhea and pneumonia (especially in rubeola). Vitamin A supplementation of 200,000 IU/day for 2 days is recommended for children with rubeola.

Although phrynoderma had classically been ascribed to, and thought to be specific for, vitamin A deficiency, it is in fact most frequently found as a disorder of multiple deficiencies, including vitamins A, B, C, and E and essential fatty acids. Replacing all these deficiencies leads to rapid improvement. Correcting only the B vitamin deficiency leads to more rapid improvement than replacing the vitamin A. This explains patients in whom the cutaneous findings of phrynoderma were found without the classic eye findings of vitamin A deficiency. The skin eruption, termed follicular hyperkeratosis or phrynoderma ("toadskin"), resembles keratosis pilaris. It consists of keratotic papules of various sizes distributed over the extremities and shoulders, surrounding and arising from the pilosebaceous follicles. Individual lesions are firm, pigmented papules containing a central, intrafollicular keratotic plug, which projects from the follicle as a horny spine and leaves a pit when expressed. Lesions are of two sizes: 1–2 mm papules closely resembling keratosis pilaris and the more diagnostic, large, 2–6 mm, crateriform papules filled with a central keratotic plug. These latter lesions may simulate a perforating disorder. The eruption of small lesions usually begins on the anterolateral aspect of the thighs or the posterolateral aspect of the upper arms. It then spreads to the extensor surfaces of both the upper and the lower extremities, the shoulders, abdomen, back, and buttocks and finally reaches the face and posterior aspect of the neck. The hands and feet are not involved, and lesions occur only occasionally on the midline of the trunk or in the axillary and anogenital areas. On the face, the eruption resembles acne because of the presence of many large comedones, but it differs from acne in regard to dryness of the skin. The large, dome-shaped nodules are on the elbows and knees and have a surrounding red or brown rim. The

whole skin displays dryness, fine scaling, and hyperpigmentation. Hair casts may also be seen.

Vitamin A deficiency may mimic vitamin C deficiency because both conditions cause follicular hyperkeratosis, and bleeding and gingival disease can be a feature of vitamin A deficiency as well as scurvy. The histologic findings of "deficiency dermatitis," which are common to many deficiency states (zinc, essential fatty acids, amino acids, glucagonoma, cystic fibrosis) are not features of either vitamin A or vitamin C deficiency.

In vitamin A deficiency, eye findings are prominent and often pathognomonic. These include night blindness, an inability to see bright light, xerophthalmia, xerosis corneae, and keratomalacia. The earliest finding is delayed adaptation to the dark (nyctalopia). Some patients have circumscribed areas of xerosis of the conjunctiva lateral to the cornea, occasionally forming well-defined white spots (Bitot spots); these are triangular, with the apex toward the canthus. Vitamin A deficiency is a major cause of blindness in children in developing countries.

The histologic findings of vitamin A deficiency are hyperkeratosis, horny plugs in the upper portion of the hair follicle, coiled hairs in the upper part of the follicle, severe atrophy of the sebaceous glands, and squamous metaplasia of the secretory cells of the eccrine sweat glands. If the follicles rupture, perifollicular granulomatous inflammation is found.

The diagnosis of vitamin A deficiency is confirmed by determination of the serum retinol level. The treatment is oral vitamin A, 100,000 IU/day for 2–3 days, followed by the recommended dietary requirement. Serum retinol levels are monitored to determine adequacy of supplementation and to avoid vitamin A toxicity.

### Hypervitaminosis A

Because the skin findings of hypervitaminosis A are similar to the side effects of synthetic retinoid therapy, they are well recognized by most dermatologists. Children are at greater risk for toxicity than adults. Excess megavitamin ingestion may be the cause. In adults, doses as small as 25,000 IU/day may lead to toxicity, especially in persons with hepatic compromise from alcoholic, viral, or medication-induced hepatitis. Dialysis patients also are at increased risk, because vitamin A is not removed by dialysis. Standard hyperalimentation solutions contain significant amounts of vitamin A, and in burn victims with renal compromise, vitamin A toxicity can occur. If the patient is taking a synthetic retinoid, all vitamin A supplementation should be stopped.

Most cases of chronic hypervitaminosis A have been reported in children. There is loss of hair and coarseness of the remaining hair, loss of the eyebrows, exfoliative cheilitis, generalized exfoliation and pigmentation of the skin, and clubbing of the fingers. Moderate widespread itching may occur. Hepatomegaly, splenomegaly, hypochromic anemia, depressed serum proteins, and elevated liver function tests may be found. Bone growth may be impaired by premature closure of the epiphyses in children. Pseudotumor cerebri with papilledema may occur early, before any other signs appear. In infants, this may present as a bulging fontanelle.

In adults, the early signs are dryness of the lips and anorexia. These may be followed by joint and bone pains, follicular hyperkeratosis, branny desquamation of the skin, fissuring of the corners of the mouth and nostrils, dryness and loss of scalp hair and eyebrows, and dystrophy of the nails. Fatigue, myalgia, depression, anorexia, headache (from pseudotumor cerebri), strabismus, and weight loss frequently occur. Liver disease may be progressive and may lead to cirrhosis with

chronic toxicity. Hypercalcemia often occurs in dialysis patients. Retinoids are teratogens, and birth defects may occur with excess vitamin A supplementation during pregnancy.

- Bremner NA, et al:** Vitamin A toxicity in burns patients on long-term enteral feed. *Burns* 2007; 22:266.
- Brown CA, et al:** Medical complications of self-induced vomiting. *Eat Disord* 2013; 21:287–294.
- Cheruvattath R, et al:** Vitamin A toxicity: when one a day doesn't keep the doctor away. *Liver Transpl* 2006; 12:1888.
- Girard C, et al:** Vitamin A deficiency phrynoderma associated with chronic giardiasis. *Pediatr Dermatol* 2006; 23:346.
- Grauel E, et al:** Necrolytic acral erythema. *J Drugs Dermatol* 2012; 11:1370.
- Halawi A, et al:** Bariatric surgery and its effects on the skin and skin diseases. *Obes Surg* 2013; 23:408–413.
- Jen M, et al:** Syndromes associated with nutritional deficiency and excess. *Clin Dermatol* 2010; 28:669–685.
- Hasru MR, et al:** Acute hypervitaminosis A in a young lady. *Mymensingh Med J* 2010; 19:294.
- Ocon J, et al:** Phrynoderma. *J Parenter Enteral Nutr* 2012; 36:361–364.
- Raphael BA, et al:** Low prevalence of necrolytic acral erythema in patients with chronic hepatitis C virus infection. *J Am Acad Dermatol* 2012; 67:962–968.
- Romano ME, et al:** Dermatologic findings in the evaluation of adolescents with suspected eating disorders. *Adolesc Med State Art Rev* 2011; 22:119–128.
- Tiang S, et al:** Nyctalopia. *BMJ Case Reports* 2010; Aug 26.

## VITAMIN D

Although active vitamin D is produced in the skin, deficiency of vitamin D has no skin manifestations, except for alopecia. Elderly persons have decreased vitamin D cutaneous photosynthesis because of decreased sun exposure and poor intake of vitamin D, both of which predispose them to osteomalacia. Aggressive photoprotection may also reduce vitamin D levels. Patients with cutaneous lupus and other photosensitive diseases who are counseled to avoid the sun and use high sun protection factor (SPF) sunscreens are at particular risk. Other patients at risk include those who are debilitated with limited sun exposure; those taking anticonvulsants; those with fat malabsorption; and patients with human immunodeficiency virus (HIV) infection, especially dark-skinned patients living in northern climes. Vitamin D<sub>3</sub> supplementation of 600 IU/day should be recommended in all these groups of patients for those up to age 70, and 800 IU for older patients. Dermatologists who have patients at risk should also consider measuring vitamin D blood levels.

- Malloy PJ, et al:** The role of vitamin D receptor mutations in the development of alopecia. *Mol Cell Endocrinol* 2011; 347:90–96.
- Pinzone MR, et al:** Vitamin D deficiency in HIV infection. *Eur Rev Med Pharmacol Sci* 2013; 17:1218.
- Vanchinathan V, et al:** A dermatologist's perspective on vitamin D. *Mayo Clin Proc* 2012; 87:372–380.

## VITAMIN K DEFICIENCY

Dietary deficiency of vitamin K, a fat-soluble vitamin, usually does not occur in adults because it is synthesized by bacteria in the large intestine. However, deficiency may occur in adults because of malabsorption caused by biliary disease, malabsorption syndromes, cystic fibrosis, or anorexia nervosa. Liver disease of all causes produces deficiency. Drugs such as coumarin, salicylates, cholestyramine, and perhaps the cephalosporins may induce a deficiency state. Newborns of mothers taking coumarin or phenytoin and premature infants with an uncolonized intestine can be vitamin K deficient. Standard



practice since 1961 has been to administer intramuscular (IM) vitamin K at birth; however, some parents decline this, and those children are at 81 times greater risk of developing vitamin K bleeding than those who do receive it. Additionally, a rare condition exists that predisposes to bleeding, called hereditary combined deficiency of the vitamin K–dependent clotting factors. The result of vitamin K deficiency is a decrease in the vitamin K–dependent clotting factors II, VII, IX, and X. The resulting cutaneous manifestations are purpura, hemorrhage, and ecchymosis. Treatment is 5–10 mg/day of IM vitamin K for several days. In acute crises, fresh frozen plasma is used.

**Burke CW:** Vitamin K deficiency bleeding. *J Pediatr Health Care* 2013; 27:215–221.

**Centers for Disease Control and Prevention:** Late vitamin K deficiency bleeding in infants whose parents declined vitamin K prophylaxis. *MMWR* 2013; 62:901–902.

**Lapocorella M, et al:** Effective hemostasis during minor surgery in a case of hereditary combined deficiency of vitamin K–dependent clotting factors. *Clin Appl Thromb Hemost* 2010; 16:221.

**Napolitano M, et al:** Hereditary combined deficiency of the vitamin K–dependent clotting factors. *Orphanet J Rare Dis* 2010; 5:21.

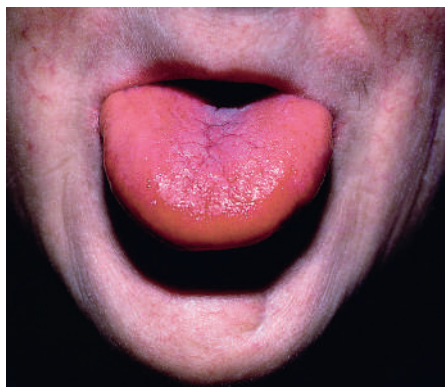## VITAMIN B<sub>1</sub> DEFICIENCY

Vitamin B<sub>1</sub> (thiamine) deficiency results in beriberi. The skin manifestations are limited to edema and red, burning tongue. Peripheral neuropathy is common, and congestive heart failure may develop.

**Lee LW, et al:** Skin manifestations of nutritional deficiency disease in children. *Int J Dermatol* 2012; 51:1407–1418.

## VITAMIN B<sub>2</sub> DEFICIENCY

Vitamin B<sub>2</sub> (riboflavin) deficiency is seen most often in alcoholic patients; however, phototherapy for neonatal icterus, acute boric acid ingestion, hypothyroidism, and chlorpromazine therapy have also been reported as causes. The classic findings are the oral-ocular-genital syndrome. The lips are prominently affected with angular cheilitis (perleche) and cheilosis. The tongue is atrophic and magenta in color (Fig. 22-1). A seborrheic-like dermatitis with follicular keratosis around the nares primarily affects the face. Genital dermatitis is worse in men than in women who have riboflavin deficiency. There is a confluent dermatitis of the scrotum, sparing the midline, with extension onto the thighs. In its mildest form, the dermatitis is slightly “irritating” and pruritic, especially when sweating. As the deficiency progresses, the scrotum goes through a mild, acute dry phase with erythema and slight



**Fig. 22-1** Magenta tongue in riboflavin deficiency.

scale to a severe, chronic dry phase with confluent red papules that spread to involve the perianal area and inner thighs, accompanied by fissuring and pain. Balanitis and phimosis may occur, requiring circumcision. In severe deficiency, the entire scrotum becomes wet, with increasing pain and fissuring. The final stage is accompanied by massive swelling, and the scrotum may reach the size of a football. Photophobia and blepharitis angularis occur. The response to 5 mg/day of riboflavin is dramatic.

**Reamy BV, et al:** Common tongue conditions in primary care. *Am Fam Physician* 2010; 81:627–634.

**Roe DA:** Riboflavin deficiency. *Semin Dermatol* 1991; 10:293.

## VITAMIN B<sub>6</sub>

### Pyridoxine deficiency

Pyridoxine (vitamin B<sub>6</sub>) deficiency may occur in patients with uremia and cirrhosis, as well as with the use of certain pharmacologic agents. Skin changes include a seborrheic dermatitis-like eruption, atrophic glossitis with ulceration, angular cheilitis, conjunctivitis, and intertrigo. Occasionally, a pellagralike eruption may occur. Neurologic symptoms include somnolence, confusion, and neuropathy.

### Pyridoxine excess

A patient who ingested large doses of pyridoxine developed a subepidermal vesicular dermatosis and sensory peripheral neuropathy. The bullous dermatosis resembled epidermolysis bullosa acquisita.

**Friedman MA, et al:** Subepidermal vesicular dermatosis and sensory peripheral neuropathy caused by pyridoxine abuse. *J Am Acad Dermatol* 1986; 14:915.

## VITAMIN B<sub>12</sub> DEFICIENCY

Vitamin B<sub>12</sub> (cyanocobalamin) is absorbed through the distal ileum after binding to gastric intrinsic factor in an acid pH. Deficiency is caused mainly by gastrointestinal (GI) abnormalities, such as a deficiency of intrinsic factor, achlorhydria (including that induced by medications), ileal diseases, and malabsorption syndromes resulting from pancreatic disease or sprue. Aggressive treatment for the eradication of *Helicobacter pylori* may cause B<sub>12</sub> deficiency, as can metformin administration and long-term antacid ingestion. In food-cobalamin malabsorption syndrome, the body is unable to release vitamin B<sub>12</sub> from food or intestinal transport proteins, especially with accompanying achlorhydria. These patients have adequate dietary vitamin B<sub>12</sub> but often have atrophic gastritis. A Schilling test will be normal. Congenital lack of transcobalamin II can also produce B<sub>12</sub> deficiency. Because of the large body stores of B<sub>12</sub> in adults, deficiency occurs 3–6 years after GI abnormalities.

Glossitis, hyperpigmentation, and canities are the main dermatologic manifestations of vitamin B<sub>12</sub> deficiency. The tongue is bright red, sore, and atrophic. Linear atrophic lesions may be an early sign. The hyperpigmentation is generalized, but more often it is accentuated in exposed areas, such as the face and hands, and in the palmar creases and flexures, resembling Addison’s disease. The nails may be pigmented. Premature gray hair may occur paradoxically. Megaloblastic anemia is often present. Weakness, paresthesias, numbness, ataxia, and other neurologic findings occur.

Parenteral replacement with IM injections of B<sub>12</sub>, 1 mg/week for 1 month, then 1 mg/month, leads to a reversal of the pigimentary changes in the skin, nails, mucous membranes, and hair. Megadose oral replacement of 1–2 mg/day may replace body stores by simple diffusion, independent of intrinsic factor. Neurologic defects may or may not improve with vitamin B<sub>12</sub> replacement.

### FOLIC ACID DEFICIENCY

Diffuse hyperpigmentation, glossitis, cheilitis, and megaloblastic anemia, identical to vitamin B<sub>12</sub> deficiency, occur in folic acid deficiency. Low folic acid is associated with neural tube defects, which are more common in light-skinned people, suggesting an association between ultraviolet (UV) light exposure and reduction in folic acid.

**De Giuseppe R, et al:** Burning mouth syndrome and vitamin B<sub>12</sub> deficiency. *J Eur Acad Dermatol Venereol* 2011; 25:868–870.

**Downham TF, et al:** Hyperpigmentation and folate deficiency. *Arch Dermatol* 1976; 112:562.

**Graells J, et al:** Glossitis with linear lesions: an early sign of vitamin B<sub>12</sub> deficiency. *J Am Acad Dermatol* 2009; 60:498.

**Pontes HA, et al:** Oral manifestations of vitamin B<sub>12</sub> deficiency. *J Can Dent Assoc* 2009; 75:533–537.

**Stabler SP:** Vitamin B<sub>12</sub> deficiency. *N Engl J Med* 2013; 368:149–160.

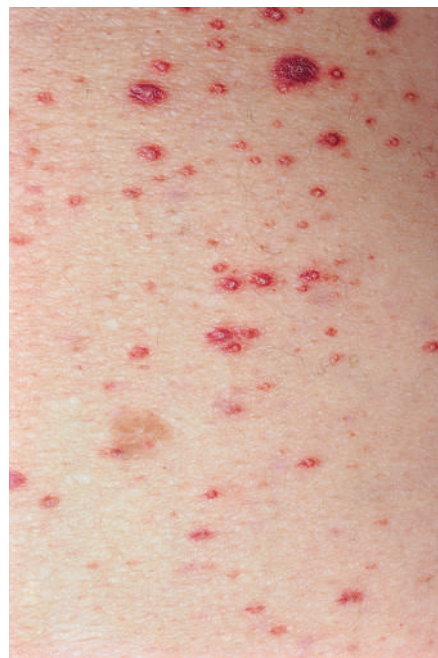**Stooper ET, et al:** Glossitis secondary to vitamin B<sub>12</sub> deficiency anemia. *CMAJ* 2013; 185:E582.

### SCURVY

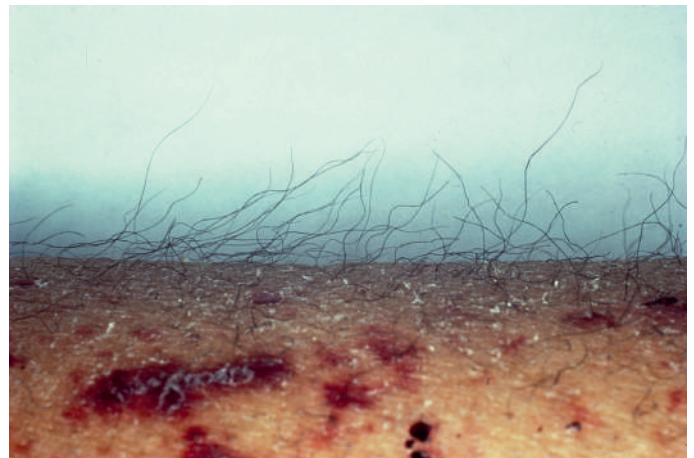Scurvy, or vitamin C deficiency, is the deficiency disease most often diagnosed by dermatologists, since cutaneous manifestations are early and prominent features. Elderly male alcoholics and psychiatric patients on restrictive diets are most frequently affected. Dialysis patients are also at risk. Smoking is a risk factor for low vitamin C levels. In the United Kingdom, up to 25% of men and 16% of women in the low-income population had vitamin C levels in the deficient range.

The “four Hs” are characteristic of scurvy: hemorrhagic signs, hyperkeratosis of the hair follicles, hypochondriasis, and hematologic abnormalities. Perifollicular petechiae are the characteristic finding (Fig. 22-2). In addition, ecchymoses of various sizes, especially on the lower extremities, are common. These may be associated with tender nodules (subcutaneous and intramuscular hemorrhage) and subperiosteal hemorrhage, leading to pseudoparalysis in children. Woody edema may be present, simulating cellulitis. Subungual, subconjunctival, intramuscular, periosteal, and intra-articular hemorrhage may also occur. The referring diagnosis is often vasculitis. Another characteristic finding is keratotic plugging of the hair follicles, chiefly on the anterior forearms, abdomen, and posterior thighs. The hair shafts are curled in follicles capped by keratotic plugs, a distinctive finding called “corkscrew hairs” (Fig. 22-3). Hemorrhagic gingivitis occurs adjacent to teeth and presents as swelling and bleeding of the gums (Fig. 22-4). The teeth are loose and the breath is foul. Gingival disease may be absent or may be the sole sign of scurvy. Edentulous areas do not develop gingivitis, and those with good oral hygiene have less prominent gingival involvement. Epistaxis, delayed wound healing, and depression may also occur. Frequently, anemia is present and may be the result of blood loss or associated deficiencies of other nutrients, such as folate.

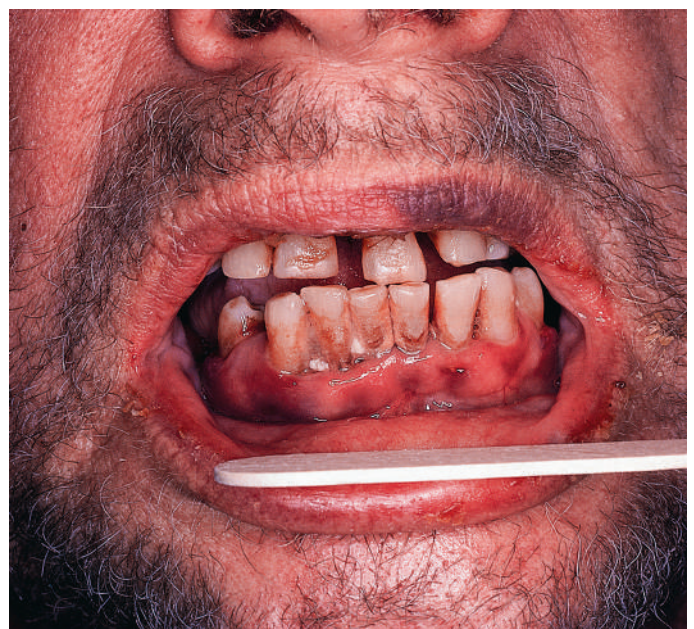The diagnosis of scurvy is usually made on clinical grounds and confirmed by a positive response to vitamin C supplementation. A biopsy will exclude vasculitis and demonstrate follicular hyperkeratosis, coiled hairs, and perifollicular



**Fig. 22-2** Scurvy, perifollicular hemorrhage and follicular hyperkeratosis.



**Fig. 22-3** Corkscrew hairs in scurvy.



**Fig. 22-4** Scurvy, gingivitis.



hemorrhage in the absence of inflammation. Serum ascorbic acid levels may be confirmatory in unusual cases. Treatment is with ascorbic acid, 1000 mg/day for a few days to 1 week, and a maintenance dose of 100 mg/day should be considered.

**Arron ST, et al:** Scurvy: a presenting sign of psychosis. *J Am Acad Dermatol* 2007; 57:S8.

**Bacci C, et al:** A rare case of scurvy in an otherwise healthy child. *Pediatr Dent* 2010; 32:536–538.

**Chisolm C, et al:** Lower extremity purpura in a woman with psychosis. *Arch Dermatol* 2010; 146:1167–1172.

**Duggan CP, et al:** Case 23-2007: a 9-year-old boy with bone pain, rash, and gingival hypertrophy. *N Engl J Med* 2009; 357:392.

**Fossitt DD, et al:** Classic skin findings of scurvy. *Mayo Clin Proc* 2014; 89:e61.

**Krutzman D, et al:** Fatigue and lower extremity ecchymosis in a 36-year-old woman. *Arch Dermatol* 2012; 148:1073–1078.

**Kocaturk E, et al:** Scurvy in a housewife manifesting as anemia and ecchymoses. *Eur J Dermatol* 2010; 20:849–850.

**Li R, et al:** Gingival hypertrophy: a solitary manifestation of scurvy. *Am J Otolaryngol* 2008; 29:426.

**Maltos AL, et al:** Scurvy in a patient with AIDS. *Rev Soc Bras Med Trop* 2011; 44:122–123.

**Singer R, et al:** High prevalence of ascorbate deficiency in an Australian peritoneal dialysis population. *Nephrology* 2008; 13:17.

**Swanson AM, et al:** Acute inpatient presentation of scurvy. *Cutis* 2010; 86:205–207.

**Woodier N, et al:** Scurvy. *Emerg Med J* 2012; 29:103.

## NIACIN DEFICIENCY (PELLAGRA)

Pellagra usually results from a deficiency of nicotinic acid (niacin, vitamin B<sub>3</sub>) or its precursor amino acid, tryptophan. It is associated classically with a diet almost entirely composed of corn, millet, or sorghum. It can occur within 60 days of dietary niacin deficiency. Malnutrition or other vitamin deficiencies, especially pyridoxine, which interfere with the conversion of tryptophan to niacin, often coexist. In developed countries, most cases of pellagra occur in alcoholics. Other possible causes of pellagra are as follows:

- Carcinoid tumors, which divert tryptophan to serotonin
- Hartnup disease (impaired absorption of tryptophan)
- Gastrointestinal disorders (e.g., Crohn's disease, GI surgery)
- Prolonged intravenous supplementation
- Psychiatric disease, including anorexia nervosa
- Restrictive diets in adult patients with atopic dermatitis concerned about "food allergy"

Pellagra can also be induced by medications, most often isoniazid, azathioprine (and its metabolite 6-mercaptopurine), 5-fluorouracil, ethionamide, prothionamide, and pyrazinamide. These medications may induce pellagra by interfering with niacin biosynthesis. The anticonvulsants, including hydantoin, phenobarbital, and carbamazepine, may rarely produce pellagra in a dose-dependent manner.

### Clinical features

Pellagra is a chronic disease affecting the GI tract, nervous system, and skin; thus the mnemonic of the "three Ds" – diarrhea, dementia, and dermatitis.

The most characteristic cutaneous finding is the photosensitive eruption, which worsens in the spring and summer. It occurs symmetrically on the face, neck, and upper chest (Casal necklace; Fig. 22-5); extensor arms; and backs of the hands. Initially, there is erythema and swelling after sun exposure, accompanied by itching and burning or pain. In severe cases,

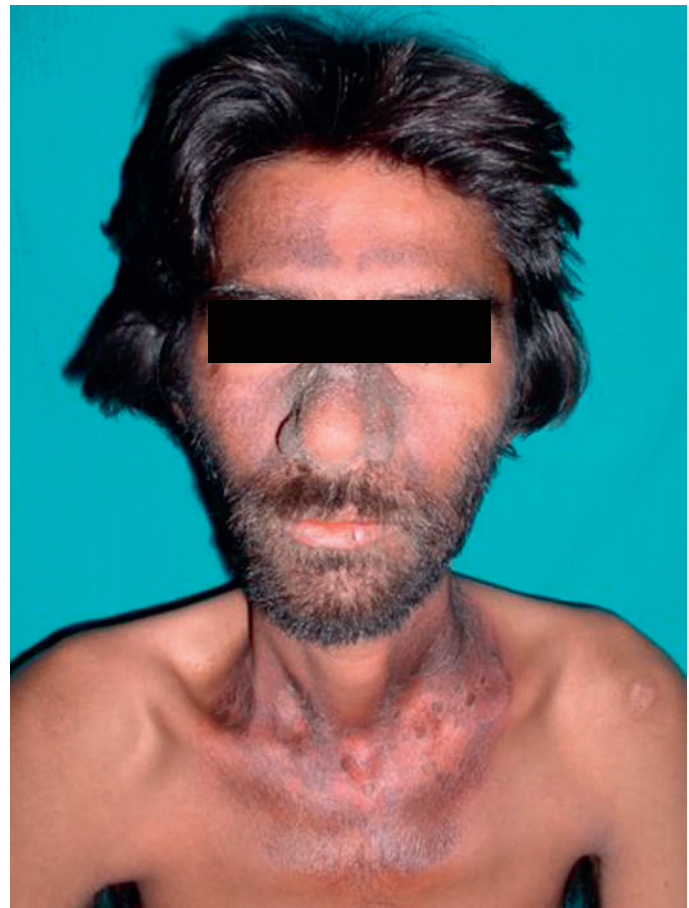

Fig. 22-5 Pellagra. (Courtesy of Shyam Verma, MD.)

the eruption may be vesicular or bullous (wet pellagra). Compared with normal sunburn, the pellagrous skin takes about four times longer to recover from the acute phototoxic injury. After several phototoxic events, thickening, scaling, and hyperpigmentation of the affected skin occur. The skin has a copper or mahogany hue. In protracted cases, the skin ultimately becomes dry, smooth, paper-thin, and glassy with a parchmentlike consistency. Scarring rarely occurs.

The nose is fairly characteristic. There is dull erythema of the bridge of the nose, with fine, yellow, powdery scales over the follicular orifices (sulfur flakes). The eruption resembles seborrheic dermatitis, except for its location. Plugs of inspissated sebum may project from dilated orifices on the nose, giving it a rough appearance.

At the onset, the patient has weakness, loss of appetite, abdominal pain, diarrhea, mental depression, and photosensitivity. Skin lesions may be the earliest sign, with phototoxicity the presenting symptom in some cases. Neurologic and GI symptoms can occur without skin changes. Delusions of parasitosis have been reported in pellagra. In the later stages, the neurologic symptoms may predominate. Apathy, depression, muscle weakness, paresthesias, headaches, and attacks of dizziness or falling are typical findings. Hallucinations, psychosis, seizures, dementia, neurologic degeneration, and coma may develop. Pellagra is progressive and can be fatal if untreated.

### Histopathology

Histologically, the findings in the skin vary according to the stage of the disease. The most characteristic finding is pallor

and vacuolar changes of the keratinocytes in a band in the upper layers of the stratum malpighii, just below the granular cell layer, which may be attenuated. If marked, a cleft may form in the upper epidermis, correlating with the blistering seen in wet pellagra.

## Diagnosis and treatment

If the characteristic skin findings are present, the diagnosis of pellagra is not difficult clinically. Dietary treatment to correct the malnutrition is essential. Animal proteins, eggs, milk, and vegetables are beneficial. Supplementation with nicotinamide, 100 mg three times daily for several weeks, should be given. Fluid and electrolyte loss from diarrhea should be replaced, and in patients with GI symptoms possibly interfering with absorption, initial IV supplementation should be considered. Within 24 h of niacin therapy initiation, the skin lesions begin to resolve, confirming the diagnosis. Alcoholism must be treated if present, and the factors that may have led to pellagra must be corrected.

**Bell HK, et al:** Cutaneous manifestations of the malignant carcinoid syndrome. *Br J Dermatol* 2005; 152:71.

**Bilgili SG, et al:** Isoniazid-induced pellagra. *Cutan Ocul Toxicol* 2011; 30:317–319.

**Desai NK, et al:** Dermatitis as one of the 3 Ds of pellagra. *Mayo Clin Proc* 2012; 87:e113.

**Frank GP, et al:** Pellegra. *Trop Doct* 2012; 42:182–184.

**Kleyn CE:** Cutaneous manifestations of the malignant carcinoid syndrome. *J Am Acad Dermatol* 2004; 50:P437.

**Ladoyanni E, et al:** Pellagra occurring in a patient with atopic dermatitis and food allergy. *J Eur Acad Dermatol Venereol* 2006; 21:394.

**Oliveira A, et al:** Azathioprine-induced pellagra. *J Dermatol* 2011; 38:1035–1037.

**Savvidou S:** Pellagra. *Clin Pract* 2014; 4:637.

**Wan P, et al:** Pellagra. *Br J Dermatol* 2011; 164:1188–1200.

## BIOTIN DEFICIENCY

Biotin is universally available and is produced by intestinal bacteria. Therefore, deficiency is rare but can occur in patients with a short gut or malabsorption. Sometimes, biotin deficiency occurs in patients taking antibiotics or receiving parenteral nutrition. Ingestion of avidin, found in raw egg white, may bind biotin, leading to deficiency. The three autosomal recessive syndromes of holocarboxylase synthetase deficiency (multiple carboxylase deficiency), biotinidase deficiency, and the rare syndrome of inability to transport biotin into cells all have similar clinical features, referred to as “multiple carboxylase deficiency.” The holocarboxylase deficiency presents earlier and is termed the “neonatal” form, whereas the biotinidase deficiency may present later and is termed the “juvenile” form. Clinical presentation is variable, with some patients manifesting only certain features.

The skin and nervous system are primarily affected. Dermatitis similar to that found in patients with zinc deficiency and essential fatty acid deficiency is seen. This periorificial dermatitis is characterized by patchy, red, eroded lesions on the face and groin. *Candida* is regularly present on the lesions. Alopecia, in some cases total, including loss of the eyebrows and eyelashes, can occur. Congenital trichorrhexis nodosa may be present, and conjunctivitis may occur. Neurologic findings are prominent; in adults these include depression, lethargy, hallucinations, and limb paresthesias, and in infants, hypotonia, lethargy, a withdrawn behavior, ataxia, seizures, deafness, and developmental delay.

The diagnosis of the inherited forms is made by detecting organic aminoaciduria of 3-hydroxyisovaleric acid. Measurement of serum biotinidase can distinguish biotinidase deficiency from holocarboxylase deficiency.

Treatment consists of 10 mg of biotin/day, but depending on the severity of the enzyme mutation, higher doses may be required. Skin lesions resolve rapidly, but the neurologic damage may be permanent; thus the importance of early diagnosis. One report suggested that valproic acid treatment in children, especially at doses of 40 mg/kg/day or higher, may lead to partial biotinidase deficiency, and that the skin lesions (seborrheic dermatitis–like rash and alopecia) improved with biotin supplementation at 10 mg/day.

**Bassi A, et al:** A 2-month-old boy with desquamative skin fold dermatitis. *J Pediatr* 2014; 164:211.

**Esparza EM, et al:** What syndrome is this? *Pediatr Dermatol* 2011; 28:333–334.

**Fleischman MH, et al:** Case report and review of congenital biotinidase deficiency. *J Am Acad Dermatol* 2004; 50:P513.

**Hove JLK, et al:** Management of a patient with holocarboxylase synthetase deficiency. *Mol Genet Metab* 2008; 95:201.

**Lunnemann L, et al:** Hair-shaft abnormality in a 7-year-old girl: trichorrhexis nodosa due to biotinidase deficiency. *JAMA Dermatol* 2013; 149:357–363.

**Rathi N, Rathi M:** Biotinidase deficiency with hypertonia as unusual feature. *Indian Pediatr* 2009; 46:65.

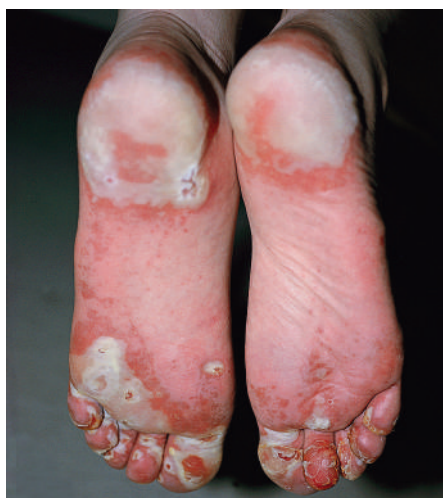**Tammachote R, et al:** Holocarboxylase synthetase deficiency. *Clin Genet* 2010; 78:88–93.

## ZINC DEFICIENCY

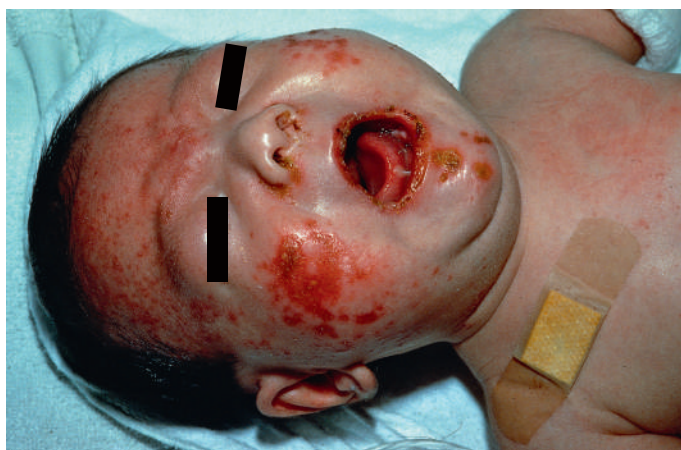Zinc deficiency may be an inherited abnormality, acrodermatitis enteropathica, or it may be acquired. Acrodermatitis enteropathica is an autosomal recessive disorder caused by mutations in the *SLC39A4* gene, which encodes the zinc transporter ZIP4. Acquired cases are termed acquired acrodermatitis enteropathica or acrodermatitis enteropathica–like syndrome. Premature infants are at particular risk because of inadequate body zinc stores, suboptimal absorption, and high zinc requirements. Normally, human breast milk has adequate zinc, and weaning classically precipitates clinical zinc deficiency in premature infants and in infants with acrodermatitis enteropathica. However, clinical zinc deficiency may occur in full-term and premature infants still breastfeeding. This results from either low maternal breast milk zinc levels or a higher zinc requirement by the infant than the breast milk can provide (even though zinc level in breast milk is normal). A rare syndrome of congenital myopathy, recurrent diarrhea, microcephaly, and deafness has been associated with a neonatal bullous eruption characteristic of nutritional deficiency. These children have required very high doses of zinc supplementation.

Parenteral nutrition without adequate zinc content may lead to zinc deficiency. Acquired zinc deficiency also occurs in alcoholics as a result of poor nutritional intake and increased urinary excretion; as a complication of malabsorption, inflammatory bowel disease (IBD), or GI surgery; and occasionally in patients with anorexia nervosa and acquired immunodeficiency syndrome (AIDS). Patients with severe erosive oral disease, such as pemphigus or graft-versus-host disease, may develop zinc deficiency from malnourishment. Zinc requirements increase during metabolic stress, so symptomatic deficiency may present during infections, after trauma or surgery, with malignancy, during pregnancy, and with renal disease. Diets containing mainly cereal grains are high in phytate, which binds zinc, and have caused endemic zinc deficiency in certain areas of the Middle East and North Africa.





**Fig. 22-6** Zinc deficiency, acquired in a patient who had severe nausea after gastric bypass procedure and was unable to eat.



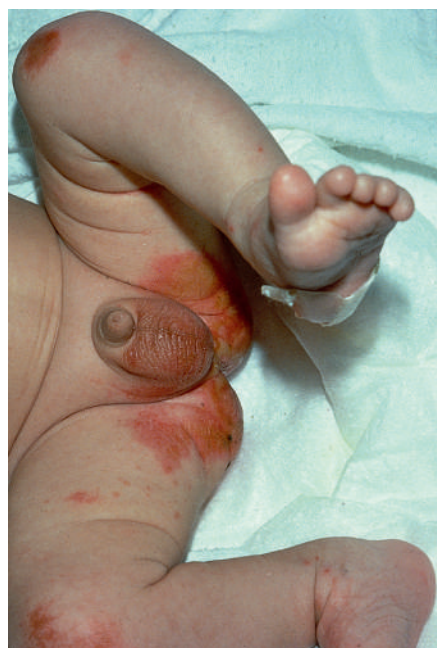**Fig. 22-7** Acrodermatitis enteropathica.

The dermatitis found in all forms of zinc deficiency is pustular and bullous, with an acral and periorificial distribution (Fig. 22-6). On the face, in the groin, and in other flexors, there is a patchy, red, dry scaling with exudation and crusting. Angular cheilitis and stomatitis may be present (Fig. 22-7). The periungual areas are erythematous and scaling and may have superficial, flaccid pustules. Nail dystrophy may result, with thinning of the nails and accentuated longitudinal ridges. Low zinc levels have been found in patients with burning mouth syndrome, and zinc supplementation may alleviate the symptoms. Chronic lesions may be more psoriasiform. Generalized alopecia may occur.

Diarrhea is present in most cases. Growth retardation, ophthalmic findings, impaired wound healing, and central nervous system manifestations occur. Patients are particularly irritable and emotionally labile.

The histopathology of acquired and hereditary zinc deficiency is identical. There is vacuolation of the keratinocytes of the upper stratum malpighii. These areas of vacuolation may become confluent, forming a subcorneal bulla. In larger lesions, there may be total epidermal necrosis with subepidermal blister formation. Neutrophils are typically present. In the late stages of acrodermatitis enteropathica, this characteristic upper epidermal pallor is frequently absent, and the biopsy demonstrates only a psoriasiform dermatitis.

The diagnosis of zinc deficiency should be suspected in at-risk individuals with acral or periorificial dermatitis. In particular, chronic diaper rash with diarrhea in an infant should lead to evaluation for zinc deficiency (Fig. 22-8). The diagnosis



**Fig. 22-8** Acrodermatitis enteropathica.

can be confirmed by low serum zinc levels. A low level of serum alkaline phosphatase, a zinc-dependent enzyme, may be a valuable adjunctive test in which the serum zinc level is normal or near-normal. In some patients, even if the zinc level is in the normal range, a trial of zinc supplementation should be considered if the skin lesions are characteristic. Replacement is with zinc sulfate, 1–2 mg/kg/day (50 mg of elemental zinc per 220 mg zinc sulfate tablet).

In acquired cases, transient treatment and addressing the underlying condition are adequate. In patients with acrodermatitis enteropathica, zinc supplementation is 3 mg/kg/day and should be lifelong. Overzealous zinc supplementation should be avoided, because it may lead to low serum copper levels.

**Afrin LB:** Fatal copper deficiency from excessive use of zinc-based denture adhesive. *Am J Med Sci* 2010; 340:164–168.

**Alhaj E, et al:** Diffuse alopecia in a child due to dietary zinc deficiency. *Skinmed* 2007; 6:199.

**Bock DE, et al:** Picture of the month. *Arch Pediatr Adolesc Med* 2009; 163:763.

**Centers for Disease Control and Prevention:** Zinc deficiency dermatitis in cholestatic extremely premature infants after a nationwide shortage of injectable zinc. *MMWR* 2013; 62:136–137.

**Cho GS, et al:** Zinc deficiency may be a cause of burning mouth syndrome as zinc replacement therapy has therapeutic effects. *J Oral Pathol Med* 2010; 39:722–727.

**Chue CD, et al:** An acrodermatitis enteropathica-like eruption secondary to acquired zinc deficiency in an exclusively breast-fed premature infant. *Int J Dermatol* 2008; 46:372.

**Corbo MD, et al:** Zinc deficiency and its management in the pediatric population. *J Am Acad Dermatol* 2013; 69:616–624.

**Cunha SF, et al:** Acrodermatitis due to zinc deficiency after combined vertical gastroplasty with jejunioileal bypass. *São Paulo Med J* 2012; 130:330–335.

**Inzinger M, et al:** Acquired zinc deficiency due to long-term tube feeding. *Eur J Dermatol* 2011; 21:633–634.

**Jensen SL, et al:** Bullous lesions in acrodermatitis enteropathica delaying diagnosis of zinc deficiency: a report of two cases and review of the literature. *J Cutan Pathol* 2008; 35:1.

**Karashima T, et al:** Oral zinc therapy for zinc deficiency-related telogen effluvium. *Dermatol Ther* 2012; 25:210–213.

**Maddonald JB, et al:** Think zinc deficiency: acquired acrodermatitis enteropathica due to poor diet and common medications. *Arch Dermatol* 2012; 148:961–963.

**Mankaney GN, et al:** Images in clinical medicine. *N Engl J Med* 2014; 371:67.

**Maverakis E, et al:** Acrodermatitis enteropathica and an overview of zinc metabolism. *J Am Acad Dermatol* 2007; 56:116.

**Salle A, et al:** Zinc deficiency: a frequent and underestimated complication after bariatric surgery. *Obes Surg* 2010; 20:1660–1670.

**Tran KT, et al:** Acquired acrodermatitis enteropathica caused by anorexia nervosa. *J Am Acad Dermatol* 2005; 53:361.

## ESSENTIAL FATTY ACID DEFICIENCY

Essential fatty acid (EFA) deficiency may develop in multiple settings, including low-birth-weight infants, cystic fibrosis, GI abnormalities (e.g., IBD, intestinal surgery), and prolonged parenteral nutrition without EFA supplementation. The resulting dermatitis is similar to that seen in zinc and biotin deficiency, although characteristically more widespread, and with less prominent periorificial, mucous membrane and nail involvement. There is a generalized xerosis because EFAs constitute up to one quarter of the fatty acids of the stratum corneum and are required for normal epidermal barrier function. Widespread erythema and an intertriginous weeping eruption are seen. The hair becomes lighter in color, and diffuse alopecia is present. Poor wound healing, growth failure, and increased risk of infection may occur. There is a decrease in linoleic acid and an increase in palmitoleic and oleic acids. A ratio of eicosatrienoic acid to arachidonic acid of more than 0.4 is diagnostic of EFA deficiency. IV lipid therapy with Intralipid 10% reverses the process. In patients who develop pancreatitis from the fat emulsion infusion, topical safflower oil emulsion or soybean oil applications may be considered as a stopgap measure, waiting for the pancreatitis to improve. Topical treatment does not maintain liver and tissue stores.

The nutrient deficiency eruption seen in children with cystic fibrosis has been termed “CF nutrient deficiency dermatitis” or CFNDD. It shares features of acrodermatitis enteropathica, kwashiorkor, and EFA deficiency. It presents at 2 weeks to 6 months of age with erythematous papules that may be annular. The diaper area and perioral/periorbital regions are initially affected. It spreads to the extremities and progresses to widespread plaques. The hair may turn gray, then repigment on supplementation. Laboratory abnormalities include anemia, hypoalbuminemia, elevated liver function tests (e.g., alkaline phosphatase), low or normal zinc, low vitamin E, and at times EFA deficiency. Biopsy shows psoriasiform dermatitis, but the upper dermal pallor may be absent. Treatment of CFNDD is general enhancement of the child’s nutrition, addressing zinc, protein, and EFA deficiencies as well as other nutritional deficits. Zinc therapy alone does not improve CFNDD.

**Bernstein ML, et al:** Cutaneous manifestations of cystic fibrosis. *Pediatr Dermatol* 2008; 25:150.

**Dalgic B, et al:** Gray hair and acrodermatitis enteropathica-like dermatitis. *Eur J Pediatr* 2011; 170:1305–1308.

**Marcason W:** Can cutaneous application of vegetable oil prevent an essential fatty acid deficiency? *J Am Diet Assoc* 2007; 107:1262.

**Peroni DG, et al:** Severe refractory dermatitis and cystic fibrosis. *Arch Dis Child* 2012; 97:205.

**Roongpisuthipong W, et al:** Essential fatty acid deficiency while a patient receiving fat regimen total parenteral nutrition. *BMJ Case Rep* 2012; Jun 14.

**Wenk KS, et al:** Cystic fibrosis presenting with dermatitis. *Arch Dermatol* 2010; 146:171–174.

## IRON DEFICIENCY

Iron deficiency is common, especially among actively menstruating women, and particularly if they have minimal red

meat in their diets and have not made an effort to replace their losses with other foods. Mucocutaneous findings include koilonychia, glossitis, angular cheilitis, pruritus, and telogen effluvium, diffuse hair loss. Plummer-Vinson syndrome is the combination of microcytic anemia, dysphagia, and glossitis, seen almost entirely in middle-age women. The lips are thin and the opening of the mouth is small and inelastic, creating a rather characteristic appearance. Smooth atrophy of the tongue is pronounced. Koilonychia is present in 40–50% of patients, and alopecia may be present. An esophageal web in the postcricoid area may occur, presenting as difficulty swallowing, or the feeling that food is stuck in the throat. The diagnosis is confirmed by measuring the serum iron level. Treatment consists of iron sulfate supplementation, 325 mg three times daily.

**Revez L, et al:** Treatments for iron-deficiency anaemia in pregnancy. *Cochrane Database Syst Rev* 2011; CD003094.

**St Pierre SA, et al:** Iron deficiency and diffuse nonscarring scalp alopecia in women. *J Am Acad Dermatol* 2010; 63:1070–1076.

## SELENIUM DEFICIENCY

Selenium deficiency occurs in patients receiving parenteral nutrition, in areas where soil selenium content is poor, and in low-birth-weight infants. Manifestations in children include hypopigmentation of the skin and hair (pseudoalbinism). Leukonychia and Terry-like nails have been reported. Cardiomyopathy, muscle pain, and weakness with elevated levels of muscle enzymes are the major features. Treatment consists of 3 µg/kg/day of selenium.

**Vinton NE, et al:** Macrocytosis and pseudoalbinism: manifestations of selenium deficiency. *J Pediatr* 1987; 111:711.

## PROTEIN-ENERGY MALNUTRITION

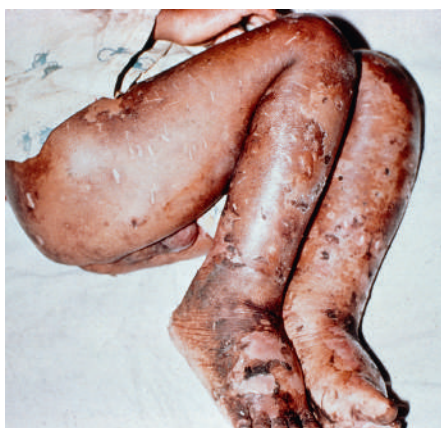Protein-energy malnutrition is a spectrum of related diseases, including marasmus, kwashiorkor, and marasmic kwashiorkor. These conditions are endemic in the developing world. Marasmus represents prolonged deficiency of protein and calories and is diagnosed in children who are below 60% of their ideal body weight without edema or hypoproteinemia. Kwashiorkor occurs with protein deficiency but a relatively adequate caloric intake and is diagnosed in children at 60–80% of their ideal body weight with edema or hypoproteinemia. Marasmic kwashiorkor shows features of both conditions and is diagnosed in children who are less than 60% of their ideal body weight with features of edema or hypoproteinemia.

These conditions are rare in developed countries, but occasionally, kwashiorkor may occur as a result of severe dietary restrictions instituted to improve infantile atopic dermatitis. In the United States, this may occur when rice beverage, which lacks protein, is substituted for cow’s milk and soy in the diets of infants surviving largely on bottle feedings. Most cases, therefore, are in infants younger than 1 year of age.

## Marasmus

In cases of marasmus, the skin is dry, wrinkled, and loose because of marked loss of subcutaneous fat. The “monkey facies,” caused by loss of the buccal fat pad, is characteristic. In contrast to kwashiorkor, there is no edema or dermatosis.





**Fig. 22-9** “Flaky paint” sign, kwashiorkor.

## Kwashiorkor

Kwashiorkor produces hair and skin changes, edema, impaired growth, and the characteristic potbelly. In diagnosed U.S. cases caused by dietary restriction or social chaos, edema has masked growth failure, delaying the diagnosis of malnutrition. The hair and skin changes are usually striking. Africans call the victims of kwashiorkor “red children.” The hair is hypopigmented, varying in color from a reddish yellow to gray or even white. The hair is dry and lusterless; curly hair becomes soft and straight; and marked scaling (crackled hair) is seen. Especially striking is the “flag sign,” affecting long, normally dark hair. The hair grown during periods of poor nutrition is pale, so that alternating bands of pale and dark hair can be seen along a single strand, indicating alternating periods of good and poor nutrition. The nails are soft and thin.

The skin lesions are hypopigmented on dark skin and erythematous or purple on fair skin. Lesions first appear in areas of friction or pressure: the flexures, groin, buttocks, and elbows. Hyperpigmented patches occur with slightly raised edges. As they progress, lesions resemble old, dark, deteriorating enamel paint with peeling or desquamation. This has been described variously as “crazy pavement,” crackled skin, mosaic skin, enamel paint, and flaky paint (Fig. 22-9). In severe cases, the peeling leaves pale, ulcerated, hypopigmented areas with hyperpigmented borders.

**Buno IJ, et al:** The enamel paint sign in the dermatologic diagnosis of early-onset kwashiorkor. *Arch Dermatol* 1998; 134:107.

- Cox JA, et al:** Flaky paint dermatosis. *JAMA Dermatol* 2014; 150:85–86.  
**Diamanti A, et al:** Iatrogenic kwashiorkor in three infants on a diet of rice beverages. *Pediatr Allerg Immunol* 2011; 22:878–879.  
**Grover Z, et al:** Protein energy malnutrition. *Pediatr Clin North Am* 2009; 56:1055–1068.  
**Heath ML, Sidbury R:** Cutaneous manifestations of nutritional deficiency. *Curr Opin Pediatr* 2006; 18:417.  
**Mann D, et al:** Cutaneous manifestations of kwashiorkor. *An Bras Dermatol* 2011; 86:1174–1177.  
**Tierney EP, et al:** Kwashiorkor from a severe dietary restriction in an 8-month infant in suburban Detroit, Michigan. *Int J Dermatol* 2010; 49:500–506.

## CAROTENEMIA AND LYCOPENEMIA

Excessive ingestion of fruits and vegetables containing large amounts of  $\beta$ -carotene and lycopene can result in a yellowish discoloration of the skin, which is especially prominent on the palms, soles, and central face (areas of high sweat gland density). The sclerae are spared. Infants are most frequently affected, perhaps since pureeing fruits and vegetables makes these pigments more available for absorption. Carotenemia may also result from excess ingestion of  $\beta$ -carotene nutritional supplements and can be seen in hypothyroidism and anorexia nervosa.

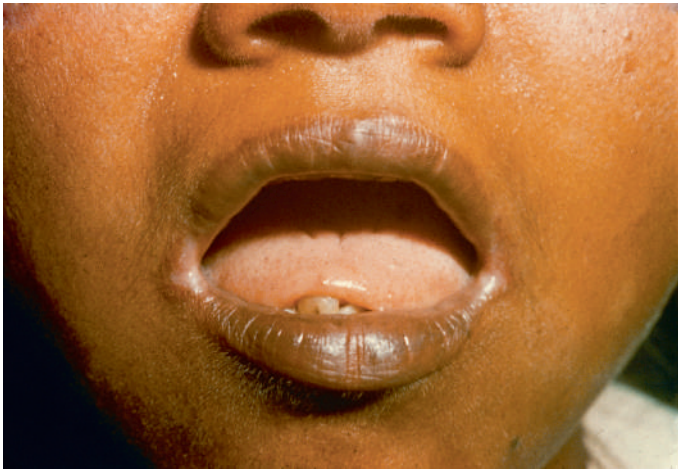- Kaimal S, et al:** Diet in dermatology. *Indian J Dermatol Venereol Leprol* 2010; 76:103–1015.  
**Sivaramakrishnan VK, et al:** Carotenemia in infancy and its association with prevalent feeding practices. *Pediatr Dermatol* 2006; 23:571.  
**Yuko T, et al:** A case of carotenemia associated with ingestion of nutrient supplements. *J Dermatol* 2006; 2:132.



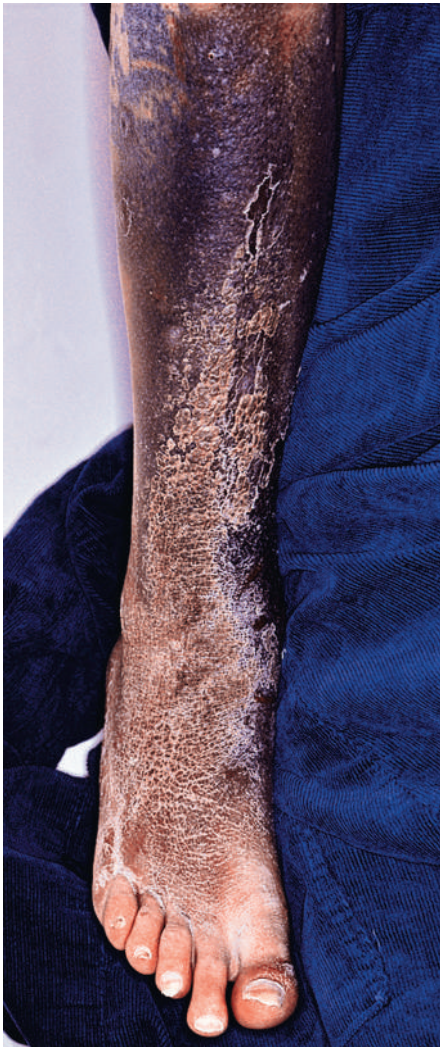Bonus images for this chapter can be found online at

[expertconsult.inkling.com](http://expertconsult.inkling.com)

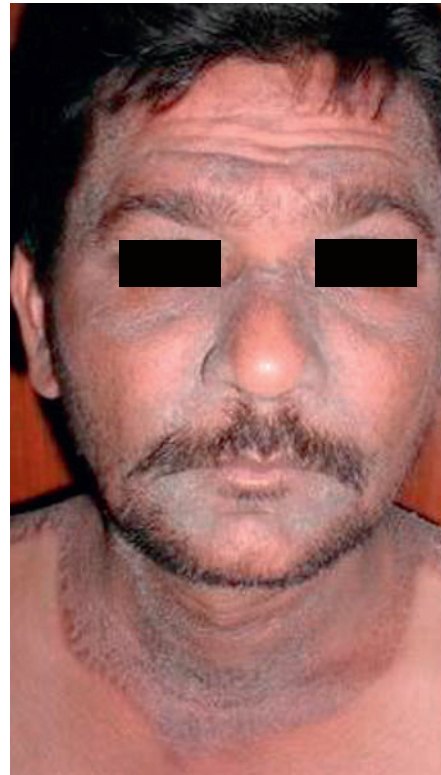- eFig. 22-1** Perlèche in riboflavin deficiency.  
**eFig. 22-2** Scurvy, large ecchymosis of the leg.  
**eFig. 22-3** Pellagra. (Courtesy of Shyam Verma, MD.)  
**eFig. 22-4** Kwashiorkor, anasarca, hypopigmentation, and scaling skin in a child who had milk allergy and was given rice milk instead.  
**eFig. 22-5** Scurvy, gingivitis.  
**eFig. 22-6** Pellagra, erosive photosensitive eruption.



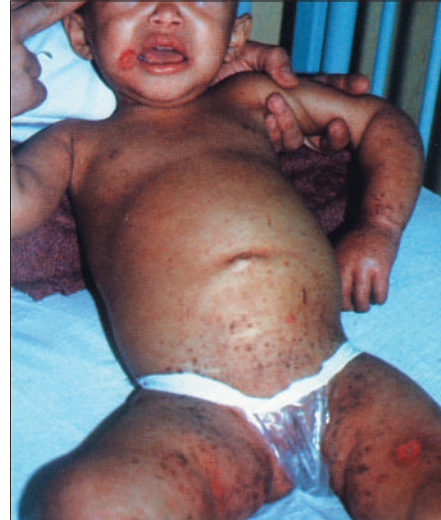**eFig. 22-1** Perlèche in riboflavin deficiency.



**eFig. 22-2** Scurvy, large ecchymosis of the leg.

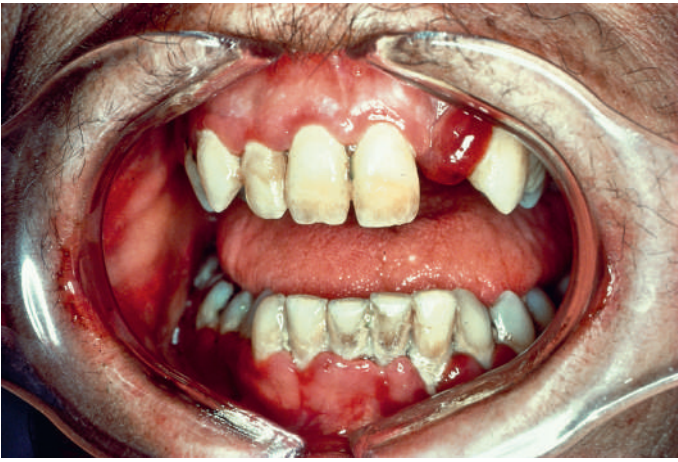

**eFig. 22-3** Pellagra. (Courtesy of Shyam Verma, MD.)

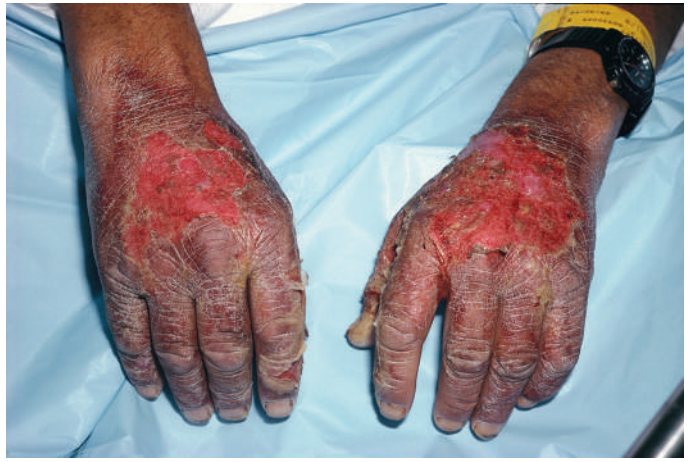

**eFig. 22-4** Kwashiorkor, anasarca, hypopigmentation, and scaling skin in a child who had milk allergy and was given rice milk instead.





**eFig. 22-5** Scurvy, gingivitis.



**eFig. 22-6** Pellagra, erosive photosensitive eruption.

# 23

## Diseases of Subcutaneous Fat

An inflammatory disorder that is primarily localized in the subcutaneous fat is termed a panniculitis. This group of disorders may be challenging for both the clinician and the dermatopathologist. Clinically, in all forms of panniculitis, lesions present as subcutaneous nodules. Histopathologically, the subcutaneous fat is a rather homogeneous tissue, and inflammatory processes may show considerable overlap. One way of classifying panniculitis is to separate erythema nodosum, as the prototypic septal panniculitis, from those processes that primarily involve the fat lobules—the lobular panniculitides. Some lobular panniculitides are caused by vasculitis (e.g., polyarteritis nodosa) and are discussed in other chapters. The remaining lobular panniculitides are categorized by their pathogenesis. Weber-Christian disease, Rothmann-Makai disease, lipomembranous or membranocystic panniculitis, and eosinophilic panniculitis are reaction patterns and are not specific entities. Neutrophilic panniculitis may be infectious or may represent a variant of Sweet syndrome with primary involvement of the panniculus.

Given the depth of lesions in the panniculus, the choice of biopsy is critical in establishing the diagnosis. An incisional or excisional biopsy, narrow at the skin surface and wider in the panniculus, is the optimal procedure. An alternative double-punch method, using a 6–8 mm punch first, followed by a 4–6 mm punch at the depth of the first punch, may be considered, but it is less ideal. Panniculitis is an area of dermatopathology where the skill of the dermatopathologist is critical in establishing good clinicopathologic correlation. If the biopsy report from an adequate specimen does not match the clinical findings, the clinician should repeat the biopsy or ask for a second opinion on the original specimen.

**Requena L:** Normal subcutaneous fat, necrosis of adipocytes and classification of the panniculitides. *Semin Cutan Med Surg* 2007; 26(2):66–70.

**Zelger B:** Panniculitides, an algorithmic approach. *G Ital Dermatol Venereol* 2013; 148(4):351–370.

### SEPTAL PANNICULITIS (ACUTE AND CHRONIC ERYTHEMA NODOSUM)

Erythema nodosum (EN) is the most common inflammatory panniculitis. It occurs in two forms: acute, which is common, and chronic, which is rare. Acute EN may occur at any age and in both genders, but most cases occur in young adult women (female/male ratio, 3:1 to 6:1). The eruption consists of bilateral, symmetric, deep, tender nodules and plaques 1–10 cm in diameter. Usually, there are up to 10 lesions, but in severe cases, many more may be found. Initially, the skin over the nodules is red, smooth, slightly elevated, and shiny (Fig. 23-1). The most common location is the pretibial area and lateral shins.

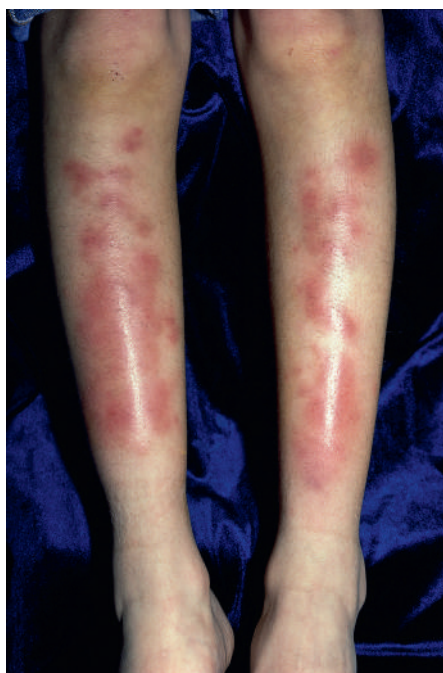In general, the lesions should be primarily anterior rather than posterior calf. Lesions may also be seen on the upper legs, extensor arms, neck, and rarely the face. The onset is acute and is frequently associated with malaise, leg edema, and arthritis or arthralgia, usually of the ankles, knees, or wrists. Fever, headache, episcleritis, conjunctivitis, and various gastrointestinal (GI) complaints may also be present. Over a few days, the lesions flatten, leaving a purple or blue-green color resembling a deep bruise (erythema contusiforme). Ulceration does not occur, and the lesions resolve without atrophy or scarring. The natural history is for the nodules to last a few days or weeks, appearing in crops, and then slowly involute. EN is much less common in children than adults and affects boys and girls equally.

Acute EN is a reactive process. It is frequently associated with a streptococcal infection, and in children, this is by far the most common precipitant. Tuberculosis (TB) remains an important cause in areas where TB is endemic. Intestinal infection with *Yersinia*, *Salmonella*, or *Shigella* may precipitate EN. Other infectious causes include systemic fungal infections (coccidioidomycosis, histoplasmosis, sporotrichosis, blastomycosis) and toxoplasmosis. EN-like lesions have been described in other infectious diseases such as *Helicobacter* septicemia, brucellosis, psittacosis, and cat-scratch fever. Because these organisms are fastidious, it has not always been possible to exclude the possibility that the EN-like lesions seen in these diseases actually represent septic foci in the panniculus. Sarcoidosis may present with fever, cough, joint pains, hilar adenopathy, and EN. This symptom complex, known as Löfgren syndrome, is especially common in Scandinavian, Irish, and Puerto Rican women. It generally responds well to therapy and runs a self-limited course. EN is frequently seen in patients with inflammatory bowel disease (IBD), more often Crohn's disease than ulcerative colitis. In IBD patients, EN is not associated with overall disease severity but is strongly associated with female gender, eye and joint involvement, and isolated colonic involvement. EN has been rarely reported in association with various hematologic malignancies, but this is less common than in patients with Sweet syndrome or pyoderma gangrenosum.

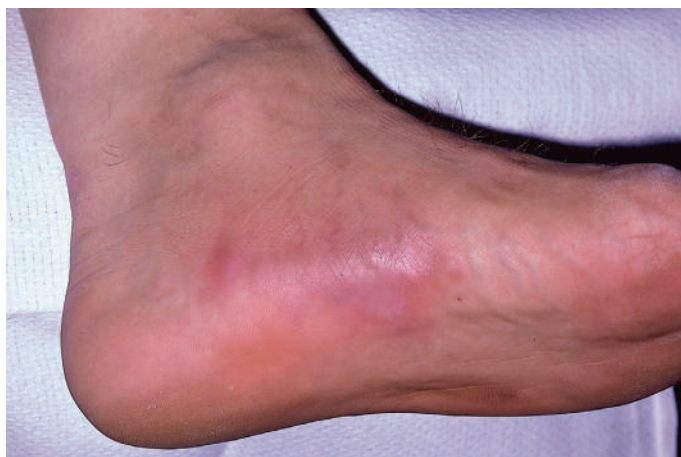Drugs may also induce EN. The bromides, iodides, and sulfonamides were once the most frequent causative agents. Currently, oral contraceptives and hormone replacement therapy are the most common medications inducing EN. This association, the predominance in young women, and the occurrence of EN in pregnancy suggest that estrogens may predispose to the development of EN. Echinacea herbal therapy and vemurafenib treatment of metastatic melanoma can also induce EN. Although infliximab has been used to treat EN associated with Crohn's disease, it has also produced EN on multiple challenges in the setting of ankylosing spondylitis.

Erythema nodosum-like lesions have been described in Behçet syndrome and Sweet syndrome and probably





**Fig. 23-1** Erythema nodosum.



**Fig. 23-2** Chronic erythema nodosum.

represent these inflammatory processes occurring in the fat, rather than the coexistence of two disorders. Histologically, the subcutaneous lesions of Behçet syndrome show features different from EN: a lobular or mixed lobular and septal pattern and, most importantly, a vasculitis that may be lymphocytic or leukocytoclastic or that may involve a small arteriole. This vasculitis is proposed to be the primary event producing the subcutaneous lesions in Behçet syndrome.

A more chronic variant of EN, called chronic EN, erythema nodosum migrans, or subacute migratory panniculitis of Vilanova and Piñol, is well described. This form of septal panniculitis is much less common than acute EN. It is distinguished from acute EN because it is unilateral, or asymmetric if bilateral (Fig. 23-2); it tends to occur in older women; and it is not associated with associated systemic symptoms except arthralgias. Additionally, the lesions in chronic EN begin as a single red nodule that tends to resolve but migrates centrifugally, forming annular plaques of subcutaneous nodules with central clearing. The lesions are painless or less tender than acute EN, and they have a prolonged course of months to years.

In the differential diagnosis of EN, other forms of panniculitis must be considered. Erythema induratum usually affects primarily the posterior calves alone and runs a more chronic course, with the possibility of ulceration and scarring. Syphilitic gummas, as well as the nodules of sporotrichosis, are generally unilateral. Subcutaneous fat necrosis associated with pancreatitis and nodular vasculitis may also occur on the shins, but associated clinicohistologic features allow the differentiation from EN. Subacute infectious processes, such as *Helicobacter* cellulitis and atypical mycobacterial infection, may closely mimic EN. In most cases, the classic picture of the acute onset of symmetric, red, tender nodules on the anterior shins of a young woman readily lead to the diagnosis of EN without a biopsy. However, if the case is atypical or does not evolve typically, a biopsy should be performed. When the diagnosis of EN has been made in error, either the clinical features were atypical and a biopsy was not performed or was inadequate (punch biopsy), or the biopsy was misinterpreted by the pathologist.

Erythema nodosum is a septal panniculitis; the inflammatory infiltrate principally involves the connective tissue septa between fat lobules throughout the evolution of the lesion. The infiltrate may be composed of either neutrophils (early) or lymphocytes and other mononuclear cells (later), or a mixture, depending on the stage at which the lesion is biopsied. In older lesions, histiocytes and multinucleate giant cells may predominate. Fat lobules are only secondarily affected by the inflammation, but some foamy histiocytes may be seen in the evolution of the lesions. Meischer radial granulomas, which are aggregates of histiocytes around stellate clefts, are characteristic but not diagnostic of EN. Leukocytoclastic vasculitis is not a histologic feature of EN. In chronic EN, septal fibrosis and septal granulomas composed of epithelioid histiocytes are seen.

The management of EN involves three components: identifying the trigger, rest and elevation of the affected extremities, and specific anti-inflammatory medications. Since streptococcus is a common trigger, throat culture and antistreptolysin O (ASO) titer are indicated. A complete history of any preceding illness will often lead to clues; for example, previous diarrhea might suggest *Yersinia* infection. A travel and exposure history is especially important when considering endemic fungal infections. Since 4% of patients with histoplasmosis present with EN, this cause should be excluded in endemic areas. Early treatment of the infectious cause does not appear to shorten the duration of the EN, although EN triggered by infections tends to last longer with a more chronic infection, and streptococcal-induced EN tends to be shorter than TB-triggered EN. Bed rest is of great value and may be all that is required in mild cases, especially in children. Gentle support hose are also helpful. Curtailing vigorous exercise during the acute attacks will shorten the course, and restriction of physical activities might prevent exacerbations and recurrences. Aspirin and nonsteroidal anti-inflammatory drugs (NSAIDs) such as indomethacin are often helpful. Potassium iodide is a safe and effective treatment. As a supersaturated solution, 5 drops three times a day, increased by 1 drop per dose per day up to 30 drops three times a day, is one easy-to-remember dose schedule. As a tablet, the dose is one 300-mg tablet three times daily. Induction of hypothyroidism by prolonged iodide therapy should be checked. Once controlled, the therapy is gradually reduced over 2–3 weeks. Intralesional corticosteroid injections will control persistent lesions. Systemic corticosteroids will result in rapid resolution of lesions, if not contraindicated by the underlying precipitating cause. In acute lesions, colchicine is often rapidly effective at a dose of 0.6 mg twice daily. For chronic EN, saturated solution of potassium iodide (SSKI) is often effective. In refractory cases, antimalarials may be tried.

The prognosis in patients with acute EN is usually good, with the attack running its course in 3–6 weeks. Recurrences do occur, especially if the underlying condition or infection is still present, or if physical activity is resumed too quickly. Chronic or atypical lesions should suggest an alternative diagnosis and require a biopsy.

**Acosta KA, et al:** Etiology and therapeutic management of erythema nodosum during pregnancy: an update. *Am J Clin Dermatol* 2013; 14(3):215–222.

**Dengen A, et al:** Erythema nodosum in a patient undergoing vemurafenib therapy for metastatic melanoma. *Eur J Dermatol* 2013; 23(1):118.

**Kisacik B, et al:** Multiclinical experiences in erythema nodosum: rheumatology clinics versus dermatology and infection diseases clinics. *Rheumatol Int* 2013; 33(2):315–318.

**Passarini B, et al:** Erythema nodosum. *G Ital Dermatol Venereol* 2013; 148(4):413–417.

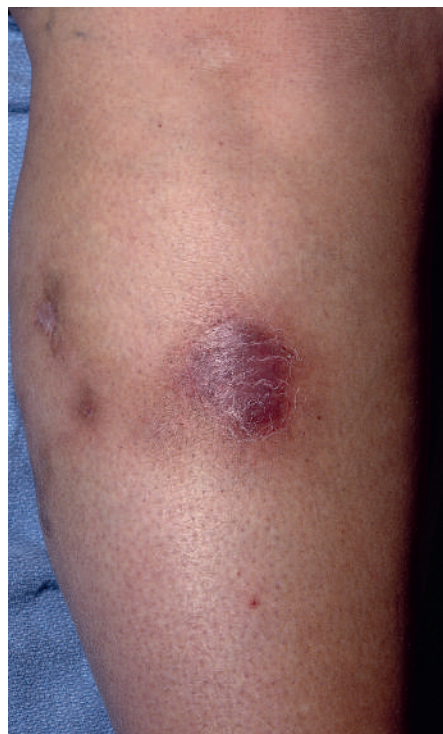## LOBULAR PANNICULITIS

### VESSEL-BASED LOBULAR PANNICULITIS

Inflammation or thrombosis of blood vessels may lead to fat necrosis caused by ischemia. This can occur in primary forms of vasculitis, such as polyarteritis nodosa and Churg-Strauss syndrome, in metabolic disorders such as oxalosis and calciphylaxis, with atheromatous emboli, with heparin and coumarin necrosis, and with various coagulopathies. These entities are discussed in other chapters.

### Nodular vasculitis and erythema induratum

Clinically and histologically, nodular vasculitis is identical to erythema induratum (EI). The two differ only by the presence of TB as a precipitating factor in EI. Nodular vasculitis presents as tender, subcutaneous nodules on the calves of middle-aged, thick-legged women (Fig. 23-3). Venous insufficiency may be present. Lesions are bilateral and less red and tender



**Fig. 23-3** Nodular vasculitis.

than EN; they often ulcerate, drain oily liquid, and recur over years.

The early lesions may show a suppurative vasculopathy, proposed by various authors to be an arteritis, a venulitis, or both. In some cases, no vasculitis is found, and despite its name, the presence of a vasculitis is not required to establish the diagnosis. Nodular vasculitis results in substantial lobular necrosis of adipocytes with suppuration. Necrosis of the lobule results in loss of the lipocyte membrane and pooling of lipid into variably sized round aggregates. As lesions evolve, the fat becomes increasingly necrotic, forming microcysts, and the disease progresses to the point where it may perforate through the epidermis, forming ulceration. Granulomatous inflammation appears adjacent to areas of fat necrosis, and eventually, lesions resolve with fibrosis.

Nontuberculous nodular vasculitis must be distinguished from EI. Because clinicopathologic features are identical, the differentiation is made by searching for tuberculous infection in the patient, applying a tuberculin skin test. If this is positive, the appropriate diagnosis is EI. Polymerase chain reaction (PCR) of the affected tissue may reveal the DNA of *Mycobacterium tuberculosis* in 50–70% of cases of EI. As a tuberculid, EI is a manifestation of cellular immunity to TB, and the purified protein derivative (PPD) test will always be positive. PCR of the tissue is not recommended in patients who are tuberculin skin test negative. It should be noted that even in areas where TB is prevalent, EI is rare, representing only 1% of cutaneous manifestations of TB in one study. When present, EI may signal serious genitourinary involvement, including tuberculous epididymo-orchitis.

Erythema induratum requires antibiotic therapy for the underlying TB. Treatment of nodular vasculitis is usually SSKI, as outlined for EN. This is effective in about half of patients. In the others, trials of colchicine, antimalarials, NSAIDs, mycophenolate mofetil (MMF), and systemic corticosteroids may be attempted. Support stockings, elevation, and treatment of associated venous insufficiency may also improve nodular vasculitis.

**Chen S, et al:** *Mycobacterium tuberculosis* infection is associated with the development of erythema nodosum and nodular vasculitis. *PLoS One* 2013; 8(5):e62653.

**Gilchrist H, et al:** Erythema nodosum and erythema induratum (nodular vasculitis): diagnosis and management. *Dermatol Ther* 2010; 23(4):320–327.

**Larsen S, et al:** Extraintestinal manifestations of inflammatory bowel disease: epidemiology, diagnosis, and management. *Ann Med* 2010; 42(2):97–114.

**Mascaró JM Jr, et al:** Erythema induratum of Bazin. *Dermatol Clin* 2008; 26(4):439–445.

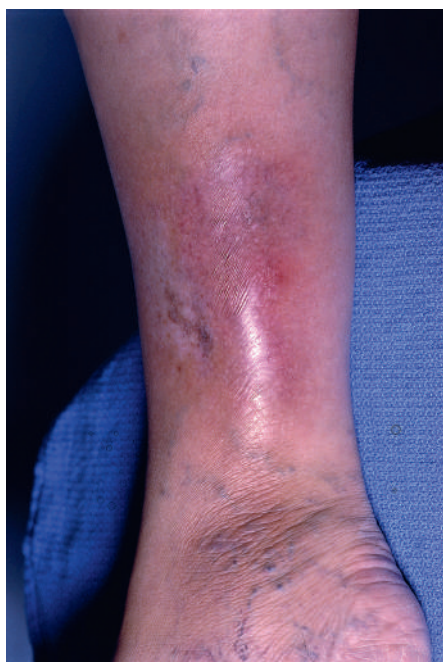**Misago N, et al:** Erythema induratum (nodular vasculitis) associated with Crohn's disease: a rare type of metastatic Crohn's disease. *Am J Dermatopathol* 2012; 34(3):325–329.

**Taverna JA, et al:** Case reports: nodular vasculitis responsive to mycophenolate mofetil. *J Drugs Dermatol* 2006; 5(10):992–993.

## Lipodermatosclerosis

Lipodermatosclerosis, or sclerosing panniculitis, occurs primarily on the medial lower third of the lower legs of women older than 40 (Fig. 23-4), with an above-average body mass index (BMI). It is often bilateral. In the acute phase, red to purple, poorly demarcated, indurated plaques are present on the lower legs. They are quite painful and may easily be misdiagnosed as cellulitis, phlebitis, EN, or inflammatory morphea. In the chronic phase, there is marked woody induration in a stocking distribution, resulting in calves that resemble inverted champagne bottles. This thick, tight, hyperpigmented skin results from fibrosis in the subcutaneous fat, which may





**Fig. 23-4**  
Lipodermatosclerosis.

occur without the primary inflammatory panniculitis ever being clinically observed. Fibrosis occurs multifocally and microscopically throughout the affected area.

It is now recognized that the etiology of lipodermatosclerosis is venous insufficiency. These patients may have venous varicosities, superficial thrombophlebitis, deep venous thrombosis, or several of these conditions. Even when venous disease is not clinically evident, evaluation of the venous system of the lower leg will frequently reveal insufficiency. Laboratory evaluation may reveal a genetic mutation in the fibrinolytic system resulting in increased thrombosis in these patients. Venous insufficiency results in hypoxia, necrosis of fat, inflammation, and eventual fibrosis. If hypoxemia is present from other causes, such as pulmonary disease, sclerosing panniculitis may be more severe. Angiosarcoma has been reported as a rare complication in the setting of postphlebotic lipodermatosclerosis.

The histologic features of sclerosing panniculitis are characteristic, but not all features may be seen on every biopsy, because the histologic features change over time within the lesion. The overlying dermis frequently shows changes of stasis with nodular proliferation of thick-walled vessels, hemosiderin deposition, fibrosis, and atrophy. In early lesions, there is ischemic necrosis in the center of the fat lobules manifested as “ghost cells”—pale cell walls with no nuclei. There is a sparse lymphocytic infiltrate in the fat septa. As the lesions evolve, the septa are thickened and fibrosed, and there is a mixed inflammatory infiltrate of lymphocytes, plasma cells, and macrophages. Foamy histiocytes are present around the areas of fat necrosis. Fat microcysts are characteristic (but not diagnostic) and appear as small cysts with feathery eosinophilic remnants of adipocytes lining the cyst cavity and resembling frost on a window, so-called lipomembranous fat necrosis. In lesions later, these microcysts collapse and are replaced by fibrosis. Despite these characteristic features, biopsy should be avoided in these patients. Biopsies heal poorly and may lead to chronic leg ulcers. The diagnosis can usually be made clinically, and noninvasive techniques such as magnetic resonance imaging (MRI) have been used to avoid poorly healing wounds related to a biopsy. If a biopsy must be performed, it should be from the most proximal edge of involvement.

This diagnosis can be clinically confirmed if a careful vascular evaluation is performed. The location on the lower medial calf is unusual for EN. Most other panniculitides favor the

posterior midcalf. The gradual progression from the ankles proximally is characteristic of sclerosing panniculitis and not other forms of lobular panniculitis.

The treatment of sclerosing panniculitis may be difficult. Fibrotic areas may be irreversible. Graded compression stockings and elevation, standard treatments for venous insufficiency, are most effective in this condition. Application of pressure dressings, such as an Unna boot, can produce dramatic, if temporary, improvement. Greater compression—Unna boot with Coban and a foam buttress (bolster material to apply extra pressure to the red inflamed area) or the Profore boot—can be beneficial. Unfortunately, some patients cannot tolerate compression because of the pain of the lesions. Intralesional triamcinolone and ultrasound therapy have been used, but this is most effective when used in conjunction with compression. Pentoxifylline, 400–800 mg three times daily, is useful, especially in patients not responding to compression and elevation alone, or in patients who are initially intolerant of compression dressings. The addition of hydroxychloroquine to pentoxifylline may provide additional improvement. Apparently, by enhancing the fibrinolytic capacity of affected patients, stanozolol, 2–5 mg, or oxandrolone, 10 mg, twice daily, may benefit some patients. This is rarely required, however, if appropriate pressure dressings are applied and the patient is able to take full doses of pentoxifylline. Stanozolol and oxandrolone may be virilizing for women and should be avoided if possible in women of childbearing age. Stanozolol may induce hepatitis. Surgical treatment of varicosities and incompetent perforators may result in dramatic improvement in some patients.

**Chan CC, et al:** Magnetic resonance imaging as a diagnostic tool for extensive lipodermatosclerosis. *J Am Acad Dermatol* 2008; 58(3):525–527.

**Choonhakarn C, et al:** Lipodermatosclerosis. *J Am Acad Dermatol* 2012; 66(6):1013–114.

**Damian DL, et al:** Ultrasound therapy for lipodermatosclerosis. *Arch Dermatol* 2009; 145(3):330–332.

**Heymann WR:** Lipodermatosclerosis. *J Am Acad Dermatol* 2009; 60(6):1022–1023.

**Huang T-M, et al:** Lipodermatosclerosis. *J Cutan Pathol* 2009; 36:453–460.

**Jeong, K-H, et al:** Refractory lipodermatosclerosis treated with intralesional platelet-rich plasma. *J Am Acad Dermatol* 65(5):e157–e158.

**Jowett AJ, et al:** Angiosarcoma in an area of lipodermatosclerosis. *Ann R Coll Surg* 2008; 90(5):W15–W16.

**Miteva M, et al:** Lipodermatosclerosis. *Dermatol Ther* 2010; 23:375–388.

**Segura S, et al:** Lipomembranous fat necrosis of the subcutaneous tissue. *Dermatol Clin* 2008; 26(4):509–517.

**Vesic S, et al:** Acute lipodermatosclerosis: an open clinical trial of stanozolol in patients unable to sustain compression therapy. *Dermatol Online J* 2008; 14(2):1.

**Walsh SN, et al:** Lipodermatosclerosis. *J Am Acad Dermatol* 2010; 62(6):1005–1012.

## PHYSICAL PANNICULITIS

The category of panniculitis includes processes in the fat that occur from physical factors. Some are characterized by the presence of needlelike clefts: sclerema neonatorum, subcutaneous fat necrosis, and poststeroid panniculitis. Infants and children are most frequently affected, and in all these disorders, metabolic differences in fat seem to be important pathogenically. Hypothermia or cold is frequently associated in some forms (cold panniculitis, sclerema, subcutaneous fat necrosis). It may be difficult in some patients to separate mild cases of sclerema neonatorum clearly from subcutaneous fat necrosis, or to differentiate cold panniculitis from subcutaneous fat

necrosis of the newborn if the lesions are at sites of cold exposure. In general, cold panniculitis refers to localized cases with a patient history of local cold exposure; sclerema refers to cases presenting in severely ill children soon after birth with a poor prognosis; and subcutaneous fat necrosis (the most common variant) refers to cases with more limited lesions occurring in the first 6 weeks of life, sometimes with associated hypercalcemia. Traumatic fat necrosis results from damage to the subcutaneous fat caused by trauma. All these conditions are treated supportively, and in all except sclerema neonatorum, spontaneous and complete recovery is expected.

### Sclerema neonatorum

Sclerema neonatorum is the severest and rarest disorder of the physical panniculitides. It affects premature neonates who are seriously ill for other reasons or have experienced profound hypothermia. Affected neonates usually die, unless the underlying diseases can be reversed. In the first few days of life, the skin begins to harden, usually initially on the buttocks or lower extremities, then rapidly spreads to involve the whole body. The skin on the palms, soles, and genitalia is spared. The skin becomes dry, livid, cold, rigid, and boardlike, limiting the mobility of the parts. The skin in the involved areas cannot be picked up. The skin of the entire body may appear half-frozen and is yellowish white. Visceral fat may also be involved. Therapy is mostly supportive, but some data suggest exchange transfusion may improve survival.

Histologically, adipocytes are enlarged and filled with needlelike clefts in a radial array. Recently, this unusual histologic finding was documented in a reaction to gemcitabine. Affected fat cells undergo necrosis. There is sparse inflammation, and histiocytes containing needlelike clefts are rare, possibly because most children die before granulomas can form.

### Subcutaneous fat necrosis of the newborn

Subcutaneous fat necrosis of the newborn (SFN) occurs during the first 4 weeks of life (half in the first week) in term or post-term infants. A history of fetal distress, birth asphyxia, and meconium aspiration is common. Maternal cocaine use, severe neonatal anemia, thrombocytopenia, and septicemia have also been associated with SFN. Widespread lesions have occurred after use of hypothermia for the treatment of hypoxic ischemic encephalopathy. Painful, firm to rubbery, erythematous nodules appear, usually on the upper back, buttocks, cheeks, or proximal extremities (Fig. 23-5). Lesions may fuse to form

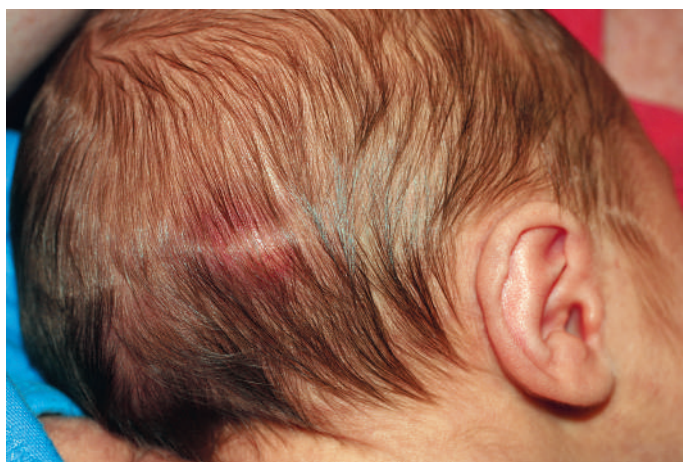

Fig. 23-5 Subcutaneous fat necrosis.

plaques and resolve spontaneously within 3 months with no scarring. In general, the infants remain well; however, hypoglycemia, thrombocytopenia, hypertriglyceridemia, lactic acidosis, and potentially life-threatening hypercalcemia may occur. Some degree of hypercalcemia occurred in more than 50% of recently reported cases and in 4 of 11 consecutive cases seen at one institution. The hypercalcemia may appear weeks to months after the appearance and resolution of the skin lesions. Periodic serial serum calcium determinations for the first 3–4 months of life have been recommended. Hypercalcemia may result in failure to thrive, irritability, apathy, hypotonia, seizures, and renal failure. The hypercalcemia is treated with hyperhydration, calcium-wasting diuretics (furosemide), and formulas low in calcium and vitamin D. Systemic corticosteroids, calcitonin, and bisphosphonates may also be effective, when other methods fail to reduce the hypercalcemia.

Histologically, SFN is a lobular panniculitis with granular necrosis of adipocytes. Needle-shaped clefts are arranged radially within histiocytes, and multinucleate foamy histiocytes are present. Degranulating eosinophils may also be present. Lesions may resolve with calcification and fibrosis. Fine-needle aspiration and touch preparations have confirmed this diagnosis, and characteristic ultrasound and MRI findings have been reported.

### Cold panniculitis

Infants and young children are particularly predisposed to cold panniculitis. It has been described in children who suck on ice, frozen teething rings, or popsicles (popsicle panniculitis); in the scrotum of prepubertal males (Fig. 23-6); and in infants treated for supraventricular tachycardia with the application of cold packs to the face. Lesions occur within a few days of the cold application and appear as slightly erythematous, nontender, firm subcutaneous nodules. Equestrian panniculitis on the upper outer thighs of women riding horses in the cold more closely resembles a form of perniosis rather than true panniculitis (see Chapter 3). Overlapping histology may occur in adults using ice packs for pain relief.

The typical patient with fat necrosis of the scrotum is a prepubertal (age 9–14) boy, who is heavyset or even obese, with scrotal swelling, usually bilateral, associated with mild to moderate pain. The gait is often guarded and broad-based.

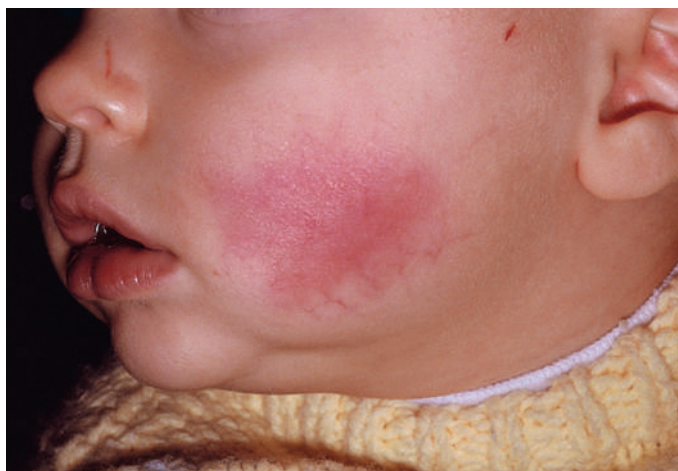

Fig. 23-6 Cold panniculitis.



There is a lack of systemic complaints and no symptoms related to voiding. The scrotal masses are bilateral and symmetric in most cases. However, the lesions may be unilateral, and there may be more than two. The masses are firm and tender and do not transmit light. The overlying scrotal skin is normal or red. Cryptorchidism may be seen. The most common location of the lesions is near the perineum, consistent with the area of greatest concentration of scrotal fat in children. The adult scrotum lacks this fatty tissue. Without treatment, lesions resolve over several days to weeks.

Histologically, there is necrosis of adipocytes within lobules of the upper subcutaneous fat adjacent to the lower dermis. A mixed inflammatory infiltrate of lymphocytes, neutrophils, and foam cells is present, and microcysts sometimes occur. This histology is not specific, and the diagnosis of cold panniculitis relies largely on obtaining a history of cold exposure.

- Akcay A, et al:** Hypercalcemia due to subcutaneous fat necrosis in a newborn after total body cooling. *Pediatr Dermatol* 2013; 30(1):120–123.
- Akin MA, et al:** Post-operative subcutaneous fat necrosis in a newborn. *Fetal Pediatr Pathol* 2011; 30(6):363–369.
- Bolotin D, et al:** Cold panniculitis following ice therapy for cardiac arrhythmia. *Pediatr Dermatol* 2011; 28(2):192–194.
- Bournas VG, et al:** Images in emergency medicine. *Ann Emerg Med* 2011; 58:216.
- Hogeling M, et al:** Extensive subcutaneous fat necrosis of the newborn associated with therapeutic hypothermia. *Pediatr Dermatol* 2012; 29(1):59–63.
- Lopez V, et al:** Usefulness of fine-needle aspiration in subcutaneous fat necrosis of the newborn diagnosis. *Pediatr Dermatol* 2010; 27(3):317–318.
- Mahé E, et al:** Subcutaneous fat necrosis of the newborn: a systematic evaluation of risk factors, clinical manifestations, complications and outcome of 16 children. *Br J Dermatol* 2007; 156(4):709–715.
- Mir-Bonafé JM, et al:** Gemcitabine-associated livedoid thrombotic microangiopathy with associated sclerema neonatorum-like microscopic changes. *J Cutan Pathol* 2012; 39(7):707–711.
- Patel AR, et al:** Circular erythematous patch in a febrile infant. *Pediatr Dermatol* 2012; 29(5):659–660.
- Pekki A, et al:** Cold panniculitis in Finnish horse riders. *Acta Derm Venereol* 2011; 91:463–490.
- Samedi VM, et al:** Neonatal hypercalcemia secondary to subcutaneous fat necrosis successfully treated with pamidronate. *AJP Rep* 2014; 4:e93–e96.
- Schubert PT, et al:** Fine-needle aspiration cytology of subcutaneous fat necrosis of the newborn. *Diagn Cytopathol* 2012; 40(3):245–247.
- Stewart CL, et al:** Equestrian pernio. *Am J Dermatopathol* 2013; 35(2):237–240.
- Vasireddy S, et al:** MRI and US findings of subcutaneous fat necrosis of the newborn. *Pediatr Radiol* 2009; 39(1):73–76.
- West SE, et al:** Ice-pack dermatosis. *JAMA Dermatol* 2013; 149(11):1314–1318.
- Zeb A, et al:** Sclerema neonatorum: a review of nomenclature, clinical presentation, histological features, differential diagnoses and management. *J Perinatol* 2008; 28(7):453–460.

## Poststeroid panniculitis

This rare form of panniculitis occurs predominantly in children treated acutely with high doses of systemic corticosteroids during rapid corticosteroid withdrawal. Substantial weight gain has usually occurred during the corticosteroid therapy. Firm subcutaneous nodules begin to appear within 1 month of tapering the corticosteroids. Areas of abundant subcutaneous fat are favored: the cheeks, trunk, and proximal extremities. Most cases resolve spontaneously within weeks, but if severe, the corticosteroids must be reinstated and tapered more slowly.

Histologically, the changes are identical to those seen in subcutaneous fat necrosis of the newborn. There is a lobular panniculitis with necrosis of adipocytes and needle-shaped

clefts in both adipocytes and histiocytes. Foamy histiocytes are also present.

**Sacchidanand SA, et al:** Post-steroid panniculitis. *Indian Dermatol Online J* 2013 Oct; 4(4): 318-320.

## Traumatic panniculitis

Accidental trauma to the skin may induce necrosis of the fat. This is most common on the trunk and breasts of women. The prior history of trauma is frequently not recalled. Lesions present similar to a lipoma, as a firm, mobile subcutaneous mass (formerly reported as mobile encapsulated lipoma). Airbag injury may induce fat necrosis. The term myospherulosis (spherulocytosis) has been used to describe subcutaneous cystic lesions induced by trauma with hemorrhage into areas of high lipid content. Many cases are caused by exogenous lipids from postoperative packing, often in parasinus tissues or subcutaneous fat. The structures resemble the sporangia of rhinosporidiosis but represent degenerated red blood cells rather than true fungal organisms. Accidental trauma to the upper anterolateral thigh from a desk or chair may result in semicircular bands of atrophy of fat called lipoatrophia semicircularis.

Histologically, there is a granulomatous lobular panniculitis with foamy histiocytes, membranous fat necrosis, and microcysts. Lesions heal with fibrosis of the septa. In myospherulosis, large round structures containing many smaller round eosinophilic bodies are noted. These represent degenerated erythrocytes.

**Boyd AS, et al:** Revision: cutaneous Munchausen syndrome. *J Cutan Pathol* 2014; 41(4):333–336.

**Grassi S, et al:** Post-surgical lipophagic panniculitis. *G Ital Dermatol Venereol* 2013; 148(4):435–441.

**Lee DJ, et al:** Traumatic panniculitis with hypertrichosis. *Eur J Dermatol* 2011; 21(2):258–259.

**Moreno A, et al:** Traumatic panniculitis. *Dermatol Clin* 2008; 26(4):481–483.

## Factitial panniculitis

Self-induced panniculitis is rarely reported, but it does occur. It may be induced by the injection of organic materials, povidone, feces, saliva, vaginal fluid, and oils. In many cases, ulceration will occur. Factitial trauma may also induce a panniculitis. Medical personnel are at risk because they have ready access to syringes and needles. Pointed, detailed questioning of the patient may identify inconsistencies in the history or the underlying cause for the behavior (e.g., attention seeking, revenge, malingering).

The clinician must have a high index of suspicion with patients in whom the clinical pattern is not characteristic of a known form of panniculitis. Inspection of early lesions for telltale healing injection sites may help confirm the diagnosis. A biopsy is often required. Culture may demonstrate a consistent pattern of fecal, oral, or vaginal flora. Biopsy demonstrates an acute lobular panniculitis with fat necrosis and a neutrophilic infiltrate. Careful evaluation of the biopsy material with polarization may identify foreign material. When the suspicion is high and no foreign material can be seen in the tissue, special evaluation by incineration and mass spectroscopy may identify the injected substance. Electron microscopy with x-ray emission spectrography can identify inorganic substances. Radiographs may demonstrate fractured needles or foreign bodies.

**Sanmartín O, et al:** Factitial panniculitis. *Dermatol Clin* 2008; 26(4):519–527.

## Sclerosing lipogranuloma

Sclerosing lipogranuloma describes the granulomatous and fibrotic reaction that occurs in the panniculus from the injection of silicone or mineral oils. In most cases, the injections are intentional and cosmetic. The time from injection to onset of symptoms may be months to more than 10 years. Topical application of an antibacterial ointment to an open wound can rarely result in the formation of lipogranuloma. Exenatide injections for type 2 diabetes may induce such changes as well.

Lesions are usually localized to the penis, scrotum, breasts, nose, and buttocks, often after an attempt to augment the area by injection. The overlying skin is hyperpigmented and erythematous. Lesions are frequently diagnosed initially as cellulitis. On palpation, the skin is indurated and cannot be picked up between the fingers. The subcutaneous tissue is indurated, thickened, and lumpy. Some patients will have focal ulceration. The injected material will frequently migrate locally, extending beyond the sites of implantation. In some cases, it is carried to other tissues, specifically the lymphoreticular system and lungs. Hepatosplenomegaly and pulmonary fibrosis may occur.

Histologically, the panniculus is replaced by the injected material, which is in various-sized vacuoles, giving the affected tissue a "Swiss cheese" appearance. Because the material is usually washed out during the tissue processing, the material itself is not seen, only the spaces it occupied in the tissue in vivo. The vacuoles are surrounded by histiocytes, many of which have ingested the material, giving their cytoplasm a vacuolated appearance. Fibrosis may be prominent. Frozen section can be used to demonstrate the lipid.

**Eun YS, et al:** A woman with a nose like an "elephant's trunk." *J Cosmet Laser Ther* 2014; 16(3):153–154.

**Foxton G, et al:** Sclerosing lipogranuloma of the penis. *Australas J Dermatol* 2011; 52(3):e12–e14.

**Nyirady P, et al:** Treatment and outcome of Vaseline-induced sclerosing lipogranuloma of the penis. *Urology* 2008; 71(6):1132–1137.

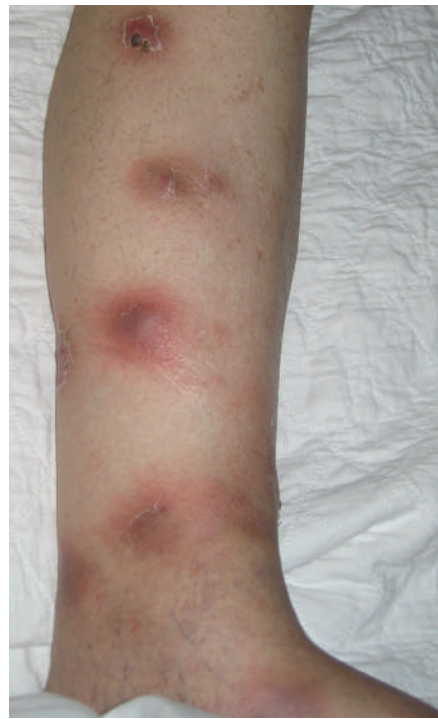**Shan SJ, et al:** Exenatide-induced eosinophilic sclerosing lipogranuloma at the injection site. *Am J Dermatopathol* 2014; 36(6):510–512.

## ENZYME-RELATED PANNICULITIS

The enzyme-related category includes panniculitis induced by enzymes that damage fat (pancreatic panniculitis) and panniculitis caused by the absence of an enzyme critical in preventing tissue inflammation after injury (alpha-1-antitrypsin).

### PANCREATIC PANNICULITIS (SUBCUTANEOUS FAT NECROSIS)

Subcutaneous fat necrosis is most often associated with pancreatitis or pancreatic carcinoma, and rarely with anatomic pancreatic abnormalities, pseudocysts, hypertriglyceridemia in association with nephrotic syndrome, endoscopic retrograde cholangiopancreatography, and drug-induced pancreatitis. Men outnumber women 2:1 in cases of pancreatitis and 7:1 in cases of pancreatic carcinoma. In cases associated with pancreatic carcinoma, acinar cell carcinoma is most common. Even metastatic pancreatic carcinoma with no residual tumor in the pancreas may induce the syndrome. In 40% of patients, the skin lesions are the first symptom of the underlying pancreatic pathology and therefore represent an important clue to the diagnosis.



**Fig. 23-7** Pancreatic fat necrosis. (Courtesy of Dr. Misha Rosenbach.)

Skin lesions appear as tender or painless, erythematous subcutaneous nodules 1–5 cm in diameter (Fig. 23-7). The lower leg is the most common location and is affected in more than 90% of cases. Subcutaneous fat elsewhere may also be affected, except rarely on the head and neck. The number of lesions is usually fewer than 10 but may reach the hundreds. In most patients, the lesions involute, leaving an atrophic scar. If the fat necrosis is severe, however, the lesion develops into a sterile abscess that may break down, draining a thick, brown, oily material.

Pancreatic panniculitis is frequently accompanied by a constellation of findings related to fat necrosis in other organs. Importantly, abdominal symptoms may be completely absent. Arthritis is found in 54–88% of patients and may be monoarticular, oligoarticular, and rarely polyarticular. The arthritis may be intermittent, migratory, or persistent and is usually in joints adjacent to the lesions of panniculitis. Examination of the joint fluid reveals the presence of free fatty acids, suggesting it is caused by fat necrosis adjacent to the joint space. Other findings are medullary fat necrosis of bone, polyserositis, and pulmonary infiltrates or embolism.

Laboratory evaluation is useful in establishing the diagnosis. In most patients, the amylase or lipase (or both) is elevated. In many cases, however, one of the tests may be normal and the other abnormal, so both tests must be performed. About 60% of patients with pancreatic carcinoma and subcutaneous fat necrosis will have a peripheral eosinophilia.

The histologic features of pancreatic panniculitis are diagnostic. These include focal areas of fat necrosis with anucleate "ghost cells"; finely stippled basophilic material, representing calcium, within the residual rim of the necrotic cells and at the periphery of the affected foci; and a dense, inflammatory polymorphous infiltrate at the periphery of the affected fat. The affected necrotic areas are relatively acellular. Several reports have suggested that the early features are those of a septal panniculitis, resembling EN. This may have represented sampling error but does indicate that if the initial sample is not diagnostic, another, perhaps more adequate, sample of a more advanced lesion should be considered. Panniculitis caused by



interferon beta injections can have a histologic appearance similar to pancreatic panniculitis.

The necrosis of fat at all affected sites is at least partly caused by the release of fat-digesting enzymes, lipases, from the affected pancreatic tissue. These lipases spread hematogenously to the affected sites.

Erythema nodosum represents the primary differential consideration, since pancreatic panniculitis may not have abdominal symptoms, also favors the lower legs, and may be accompanied by joint symptoms. The distinction can be made by skin biopsy, serum amylase, and lipase determinations, and especially if eosinophilia is present, a search for a pancreatic neoplasm.

Treatment mainly involves treating the cause of the pancreatitis. Obstruction or stenosis of ducts should be repaired, pseudocysts drained, and in the case of pancreatic carcinoma, surgery or other interventions as indicated.

**Ball, NJ, et al:** Lobular panniculitis at the site of subcutaneous interferon beta injections for the treatment of multiple sclerosis can histologically mimic pancreatic panniculitis. *J Cutan Pathol* 2009; 36:331–337.

**Hu JC, et al:** Pancreatic panniculitis after endoscopic retrograde cholangiopancreatography. *J Am Acad Dermatol* 2011; 64(5):e72–e75.

**Lueangarun S, et al:** Pancreatic panniculitis. *J Med Assoc Thai* 2011; 94(Suppl 1):S253–S257.

**Manawish K, et al:** Pancreatic panniculitis. *BMJ Case Rep* Aug 22;2014.

**Tran KT, et al:** Tender erythematous plaques on the legs. *Clin Exp Dermatol* 2010; 35:e65–366.

## ALPHA-1-ANTITRYPSIN DEFICIENCY PANNICULITIS

Alpha-1-antitrypsin is the most abundant antiprotease in circulation and a potent and irreversible inactivator of neutrophil elastase. Heterozygous deficiency of this enzyme occurs in 1 in 50 persons and homozygous deficiency in 1 in 2500 persons of European descent. Emphysema and liver disease are the most common manifestations of antitrypsin deficiency. A small percentage of patients with homozygous deficiency and the PiZZ or PiSZ phenotypes will develop panniculitis.

The panniculitis usually appears between ages 20 and 40 but can occur in childhood. Both genders are equally affected. Lesions appear after relatively minor trauma and present as painful nodules on the extremities or trunk. They may spontaneously drain an oily, brown liquid. Multiple draining sinus tracts can occur, with lesions coalescing into large, draining plaques.

The histologic findings in this form of panniculitis depend on the stage of the lesion. Early lesions show neutrophils splaying the collagen of the reticular dermis and subcutaneous septa. More fully evolved lesions show dissolution of the septa, with islands of normal fat “floating” in the spaces that represented the destroyed septa. This later finding is considered diagnostic by some. Elastic tissue stains may reveal decreased elastic tissue in the affected areas.

The clinical and histologic differential diagnosis is factitial panniculitis. This is not surprising because trauma produces both lesions, and in the case of alpha-1-antitrypsin deficiency, the inflammation-produced enzymes are simply not inactivated, leading to more pronounced lesions than would be expected from that degree of trauma.

Replacement of the deficient antitrypsin will lead to resolution of the skin lesions, but is costly. Dapsone, colchicine, and doxycycline can also be effective. These agents can reduce the requirement for enzyme replacement and should be considered as maintenance treatment in affected patients. Systemic corticosteroids may exacerbate the panniculitis. Liver

transplantation leads to normal levels of alpha-1-antitrypsin and resolution of the panniculitis. Gene therapy and stem cell therapy appear promising.

**Laureano A, et al:** Alpha-1-antitrypsin deficiency–associated panniculitis. *Dermatol Online J* 2014; 20(1):21245.

**Olson JM, et al:** Panniculitis in alpha-1 antitrypsin deficiency treated with enzyme replacement. *J Am Acad Dermatol* 2012; 66(4):e139–e141.

**Valverde R, et al:** Alpha-1-antitrypsin deficiency panniculitis. *Dermatol Clin* 2008; 26(4):447–451.

## CYTOPHAGIC HISTIOCYTIC PANNICULITIS

Cytophagic histiocytic panniculitis (CHP) is a multisystem disease characterized by widespread erythematous, painful, subcutaneous nodules, which may occasionally become ecchymotic or break down and form crusted ulcerations. There is a progressive febrile illness, with hepatosplenomegaly, pancytopenia, hypertriglyceridemia, and liver dysfunction. These result from the proliferation of benign-appearing histiocytes, which have a marked phagocytic capacity and extensively involve the reticuloendothelial system. Some patients progress to a terminal phase characterized by profound cytopenia, liver failure, and a terminal hemorrhagic diathesis. CHP represents a spectrum of disease that occurs in children and adults. Some cases are triggered by viral infections, such as Epstein-Barr virus (EBV) or human immunodeficiency virus (HIV), or viral vaccines, and others represent subcutaneous B-cell or T-cell lymphomas. The benign cases are EBV negative and the lymphoma-associated cases are EBV positive.

Histologically, there is infiltration of the lobules of subcutaneous fat by histiocytes and inflammatory cells, primarily helper T cells, with fat necrosis and hemorrhage. The characteristic cell is a “beanbag” cell: a histiocyte stuffed with phagocytized red blood cells, lymphocytes, neutrophils, platelets, or fragments of these cells. These beanbag cells are not diagnostic of CHP and can be seen infrequently in other panniculitides, especially lupus profundus. The presence of atypical lymphocytes or the detection of a clonal B-cell or T-cell proliferation supports the diagnosis of subcutaneous lymphoma in patients with CHP.

The treatment of CHP is difficult. If malignancy cannot be detected, cyclosporine has been effective in many patients, and combined treatment with high-dose corticosteroids, cyclosporine, and anakinra has been reported. Tacrolimus is another option that has improved some patients. If malignancy is detected, aggressive chemotherapy and perhaps bone marrow transplantation may be considered.

**Bader-Meunier B, et al:** Clonal cytophagic histiocytic panniculitis in children may be cured by cyclosporine A. *Pediatrics* 2013; 132:e545–e549.

**Krillis M, et al:** Cytophagic histiocytic panniculitis with haemophagocytosis in a patient with familial multiple lipomatosis and review of the literature. *Mod Rheumatol* 2012; 22:158–162.

**Miyabe Y, et al:** Successful treatment of cyclosporine-A-resistant cytophagic histiocytic panniculitis with tacrolimus. *Mod Rheumatol* 2011; 21(5):553–556.

## MISCELLANEOUS FORMS OF PANNICULITIS

### GOUTY PANNICULITIS

Uric acid crystals may deposit initially in the subcutaneous fat of patients with gouty panniculitis, leading to lesions resembling other forms of panniculitis. Histologically, there is a lobular panniculitis with necrosis of adipocytes and infiltration

of polymorphonuclear leukocytes. Feathery, needlelike crystals in sheaves are present.

**Pattanaprichakul P, et al:** Disseminated gouty panniculitis. *Dermatol Pract Concept* 2014; 4:33–35.

**Penaranda-Parada E, et al:** Gouty arthritis and panniculitis. *J Clin Rheumatol* 2012; 18(3):142–143.

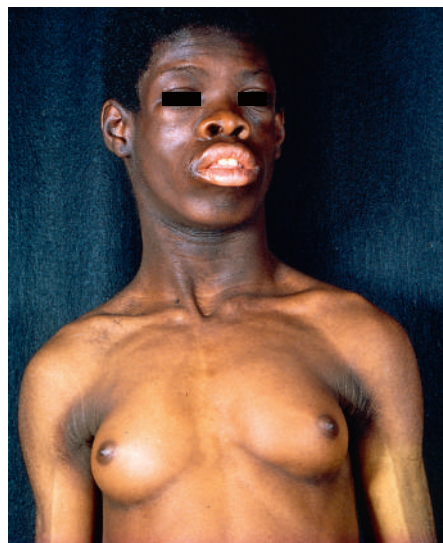
## LIPODYSTROPHY (LIPOATROPHY)

The lipodystrophies are conditions characterized by a marked reduction in subcutaneous fat. Lipodystrophies can be generalized (total), partial, or localized and may be congenital or acquired. In the congenital types, women are more frequently and more severely affected. Hypertriglyceridemia and diabetes mellitus (DM) with insulin resistance occur in many of the congenital and acquired forms of lipodystrophy. These syndromes were quite rare until the 1990s. With the advent of combination antiviral therapy for HIV infection (highly active antiretroviral therapy, HAART), acquired lipodystrophy has become common in geographic regions where HIV infection is prevalent. In addition, localized fat loss can be a consequence of therapeutic injections into the fat.

### Congenital lipodystrophies

#### Congenital generalized lipodystrophy

Congenital generalized (total) lipodystrophy, also known as Berardinelli-Seip syndrome, is a rare autosomal recessive condition. From birth, there is an extreme paucity of fat in the subcutaneous tissue and other adipose tissues, giving affected persons a generalized muscular appearance. The mechanical fat of the palms, soles, joints, orbits, and scalp is not affected in some types of this syndrome. The children have a voracious appetite. They have increased height and height velocity, advanced bone age, muscular hypertrophy, and a masculine habitus. This habitus plus enlargement of the genitalia in infancy (clitoromegaly) can lead to the misdiagnosis of precocious puberty. Scalp hair is abundant and curly, and there is generalized hypertrichosis and hyperhidrosis. The abdomen is protuberant, and the liver and spleen are enlarged. The overall appearance is acromegalic (Fig. 23-8) from enlargement of the mandible, hands, and feet. Acanthosis nigricans is invariably present and often generalized. Hyperinsulinemia,



**Fig. 23-8** Congenital generalized lipodystrophy.

insulin resistance, and DM appear often at about puberty. The DM resists insulin and oral hypoglycemic therapy, but ketoacidosis does not occur. Hypertriglyceridemia occurs and can produce eruptive xanthomas, pancreatitis, and fatty liver, which may eventuate in cirrhosis. Hypertrophic cardiomyopathy and mild mental retardation may occur. Life span is shortened, with patients frequently dying in young adulthood from complications of diabetes or from liver or heart disease.

Mutations in four genes, encoding for 1-acylglycerol 3-phosphate-*O*-acyltransferase 2 (*AGPAT2*), seipin, caveolin-1 (*CAV1*), and cavin-1, cause different subtypes of congenital generalized lipodystrophy. Type B mandibuloacral dysplasia from *ZMPSTE24* mutations, proteasome-associated autoinflammatory syndromes caused by beta subunit type 8 mutations (e.g., seemingly acquired lipodystrophies seen in Candle syndrome, and three other subtypes), glycosylation disorders, *FBNI* mutations, and *c-Fos* and *BANF1* mutations are other causes of generalized lipodystrophies that are inherited. A novel subtype with preservation of bone marrow fat, congenital muscular weakness, and cervical spine instability has also been described. Serum leptin and adiponectin levels are extremely low in various types. If leptin levels are low, leptin replacement decreases serum triglycerides and improves hyperglycemia. Some patients with congenital generalized lipodystrophy do not have mutations in these genes, suggesting there are other genetic causes.

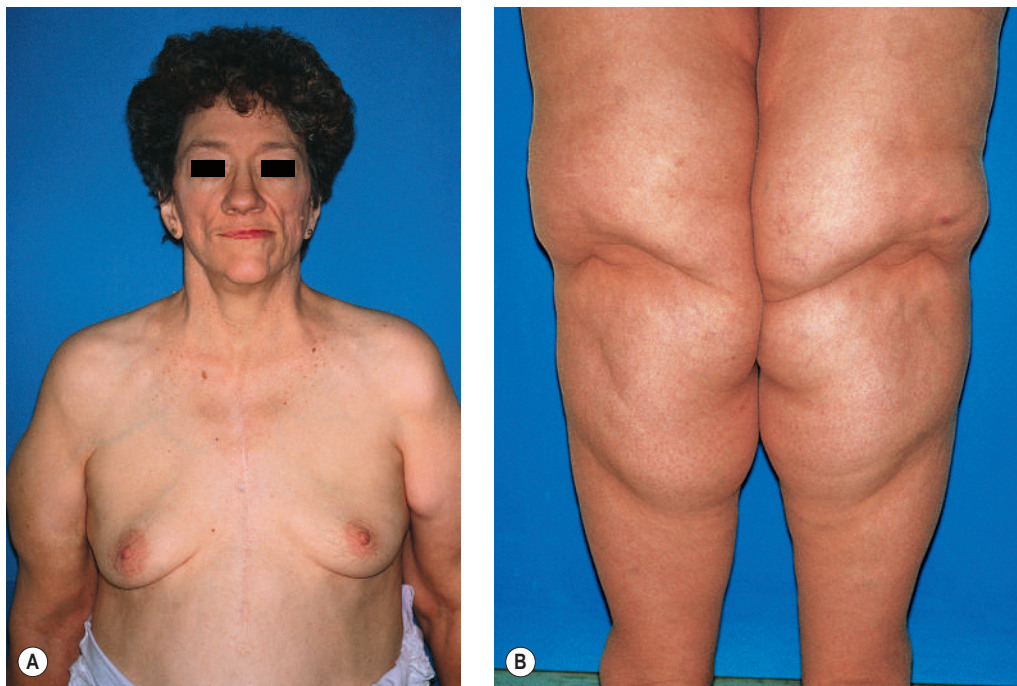#### Familial partial lipodystrophy

Familial partial lipodystrophy is a heterogeneous autosomal dominant group of disorders with distinct phenotypes. The most common variant is the Dunnigan type. Patients are normal at birth, but at about puberty, subcutaneous tissue is gradually lost from the arms and legs and variably from the chest and anterior abdomen. Fat gain occurs in the face, neck, and intra-abdominally, resulting in a cushingoid appearance. DM, hypertriglyceridemia, and atherosclerosis occur more frequently in female patients. The hypertriglyceridemia may result in pancreatitis and fatty liver, but cirrhosis has not been reported. The genetic defect in the Dunnigan variant of partial lipodystrophy is in the gene encoding lamins A and C (*LMNA*). Lamins are intermediate filaments integral to the nuclear envelope. The site of the mutation determines the phenotype expressed. Myopathy, muscular dystrophy, cardiomyopathy, and conducting system disturbances can occur in a minority of patients.

A second characterized form of familial partial lipodystrophy is related to mutations in the *PPAR-γ* gene. This rare syndrome is associated with marked loss of subcutaneous tissue of the forearms and calves, and less prominently on the upper arms and thighs. The trunk is spared, and there is no excess fat on the neck. DM, hypertriglyceridemia, hypertension, and hirsutism also occur. Other forms of familial partial lipodystrophy not associated with the previous two mutations have been described, suggesting additional genetic causes of this syndrome.

Mandibuloacral dysplasia is an extremely rare autosomal recessive condition with hypoplasia of the mandible and clavicle, acro-osteolysis, joint contractures, mottled cutaneous pigmentation, skin atrophy, alopecia, a birdlike facies, and dental anomalies. Two distinct patterns of lipodystrophy occur. Type A is characterized by loss of subcutaneous fat from the arms and legs, but normal to excess fat of the face and neck. Hyperinsulinemia, insulin resistance, DM, and hyperlipidemia occur in some patients. Mutations in the *LMNA* gene have been reported in type A patients. Mutations in the zinc metalloproteinase (*ZMPSTE24*), which is involved in the processing of prelamin A, have also been responsible for mandibuloacral





**Fig. 23-9** Partial lipodystrophy, acquired. A, Face. B, Hypertrophy of subcutaneous fat on lower half of the body.

dysplasia. Other gene mutations responsible for rarer types include those of *AKT2*, *CIDEA*, and *perilipin*. Autosomal recessive neonatal progeroid syndrome is characterized by near-total absence of fat from birth, with sparing of the sacral and gluteal areas.

### Acquired lipodystrophy

Most cases of acquired lipodystrophy are related to antiretroviral therapy, and the severity may be related to genetic variations in resistin. Lipodystrophy occurs in up to 80% of HIV-infected patients, most of whom are being treated with combination anti-HIV therapy (HAART). The fat of the face (especially buccal fat pads), buttocks, and limbs is lost. There is increased fat deposition in other areas, especially the neck, upper back (buffalo hump), and intra-abdominally. It is related to nonnucleoside reverse transcriptase inhibitors, which also inhibit the  $\gamma$ -DNA polymerase of mitochondria, leading to adipocyte apoptosis. As with the other acquired and inherited forms of lipodystrophy, patients may have hypertriglyceridemia, hypercholesterolemia, and insulin resistance, especially if a protease inhibitor is a part of their treatment. Metformin therapy, at a dose of 500–850 mg twice daily, or use of the thiazolidinediones, combined with exercise reduces the BMI and waist circumference, as well as insulin resistance. Antiretroviral-associated lipoatrophy slowly improves with prolonged rosiglitazone. Growth hormone reduces visceral fat, but the effects are short-lived, unlike with the growth hormone-releasing factor analogue tesamorelin, which has long-term benefit. Various injectable agents may provide cosmetic improvement.

Acquired lipodystrophy has several idiopathic forms, and it can be partial or generalized. In addition, hyperinsulinemia, hyperlipidemia, and DM may occur in patients with acquired lipodystrophy. Management involves controlling the hyperinsulinemia and its complications.

### Acquired partial lipodystrophy (Barraquer-Simons syndrome)

Until HAART-associated lipodystrophy appeared, the acquired partial type was the most common form of lipodystrophy. Affected females outnumber males 4:1. The syndrome presents in the first and second decades of life. This progressive fat disorder is characterized by a diffuse and progressive loss of the subcutaneous fat that usually begins in the face and scalp, progressing downward as far as the iliac crests but sparing the lower extremities. The upper half of the body looks emaciated, and the patient has sunken cheeks (Fig. 23-9, A). There is an apparent, and sometimes real, adiposity of the buttocks, thighs, and legs, especially in affected women (Fig. 23-9, B). The onset is insidious, with no discomfort or inflammation in the areas of fat loss. A few patients have developed other autoimmune diseases, including systemic lupus erythematosus and juvenile dermatomyositis.

Histologically, the skin is normal except for the absence of fat. Most patients with acquired partial lipodystrophy have reduced levels of C3 resulting from a circulating polyclonal IgG called “C3 nephritic factor.” Proteinuria caused by membranoproliferative glomerulonephritis occurs in about 20% of patients, appearing about 8 years after the onset of the lipodystrophy. C3 nephritic factor stabilizes C3b,Bb (C3 convertase), leading to unopposed activation of the alternative complement system and excessive consumption of C3.

### Acquired generalized lipodystrophy

This rare form of lipodystrophy appears during childhood or adolescence. Females with acquired generalized lipodystrophy outnumber males 3:1. The fat loss affects large areas of the body, particularly the face, arms, and legs. Mechanical fat of the palms and soles may be lost, but ocular and bone marrow fat are spared. Acanthosis nigricans is present. Hepatic steatosis and voracious appetite may be present. Cirrhosis occurs in about 20% of patients due to hepatic steatosis or

autoimmune hepatitis. DM and hypertriglyceridemia may occur.

About 25% of patients will have a preceding inflammatory panniculitis at the onset of the syndrome. These patients tend to have less severe manifestations. Another 25% of patients with acquired generalized lipodystrophy have an associated connective tissue disease, especially juvenile dermatomyositis. Half the patients give no history of panniculitis and have no connective tissue disease. Other associations include graft-versus-host disease and glucocorticoid administration.

### Centrifugal abdominal lipodystrophy

Most cases of “lipodystrophia centrifugalis abdominalis infantilis,” as described by Imamura et al., have been reported from a single region of Japan. The cause is unknown. It is almost invariably a disease of childhood; 90% of cases begin at age 3. Girls outnumber boys 2:1. It is characterized by depression of the skin caused by loss of fat in the groin (80% of patients) or axilla (20%). The atrophic area slowly enlarges centrifugally for 3–8 years in most patients, often stopping with the onset of puberty. In 80%, the depressed area was surrounded by a discrete, erythematous border with scale. One third of patients have multiple lesions, and regional lymph nodes are enlarged in 65%. The affected children are otherwise well. When the lesion stops expanding, the erythematous rim and lymphadenopathy disappear. After the progression stops, the skin returns to normal within 1 or 2 years.

### Lipoatrophia annularis (Ferreira-Marques syndrome)

Lipoatrophia annularis primarily affects women and usually involves the upper extremity. The lipoatrophy may be preceded by erythema, a bracelet-shaped swelling, and tenderness of the entire extremity. This is followed by loss of subcutaneous fat, with the arm divided into two parts by a depressed, atrophic, braceletlike constriction. The depressed band is usually about 1 cm wide and up to 2 cm in depth. Arthralgias and pain of the affected extremity precede and accompany the process. The band persists for up to 20 years. The histology shows atrophy of the subcutaneous fat. The cause is unknown.

### Localized lipodystrophy

Six months to 2 years after the initiation of insulin injections, localized atrophy of fat may develop at the sites, more

frequently in children and women than in men. Localized lipodystrophy may be a manifestation of connective tissue disease. This dystrophic change may resolve if patients are switched to human insulin. Much less often, insulin injections may result in lipohypertrophy. Rarely, injections of other medications may result in lipoatrophy, or in the case of pegvisomant, lipohypertrophy.

**Buyuktas D, et al:** Lipodystrophy during pegvisomant therapy. *Clinics* 2010; 65(9):931–933.

**Chan JL, et al:** Clinical classification and treatment of congenital and acquired lipodystrophy. *Endocr Pract* 2010; 16(2):310–323.

**De Waal R, et al:** Systematic review of antiretroviral-associated lipodystrophy. *PLoS One* 2013; 8(5):e63623, 1–15.

**Eren E, et al:** Acquired generalized lipodystrophy associated with autoimmune hepatitis and low serum C4 level. *J Clin Res Pediatr Endocrinol* 2010; 2(1):39–42.

**Florenza CG, et al:** Lipodystrophy. *Nat Rev* 2011; 7:137–150.

**Holstein A, et al:** Lipoatrophy associated with the use of insulin analogues. *Expert Opin Drug Saf* 2010; 9(2):225–231.

**Kerns MJ, et al:** Annular lipoatrophy of the ankles. *Pediatr Derm* 2011; 28(2):142–145.

**Sarni RO, et al:** Lipodystrophy in children and adolescents with acquired immunodeficiency syndrome and its relationship with the antiretroviral therapy employed. *J Pediatr* 2009; 85(4):329–334.

**Shuck J, et al:** Autologous fat grafting and injectable dermal fillers for human immunodeficiency virus-associated facial lipodystrophy. *Plast Reconstr Surg* 2013; 131(3):499–506.

**Spooner LM, et al:** Tesamorelin. *Ann Pharmacother* 2012; 46(2):240–247.

**Tierney EP, et al:** “Bullfrog neck,” a unique morphologic trait in HIV lipodystrophy. *Arch Dermatol* 2010; 146(11):1279–1282.

**Tsoukas MA, et al:** Leptin in congenital and HIV-associated lipodystrophy. *Metabolism* 2015; 64:47–59.

**Vantyghem M-C, et al:** How to diagnose a lipodystrophy syndrome. *Ann Endocrinol* 2012; 73:170–189.



Bonus images for this chapter can be found online at

[expertconsult.inkling.com](http://expertconsult.inkling.com)

**eFig. 23-1** Erythema nodosum.

**eFig. 23-2** Erythema nodosum, erythematous tender nodules on the anterior shins.

**eFig. 23-3** Chronic erythema nodosum.

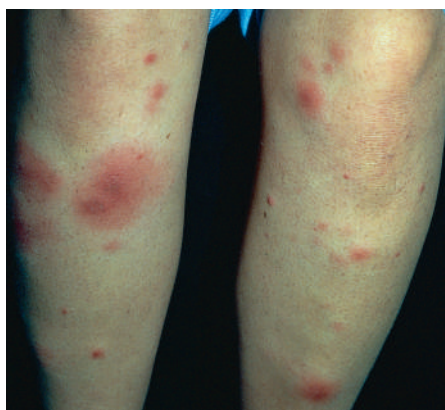
**eFig. 23-4** Cold panniculitis.

**eFig. 23-5** Pancreatic fat necrosis.

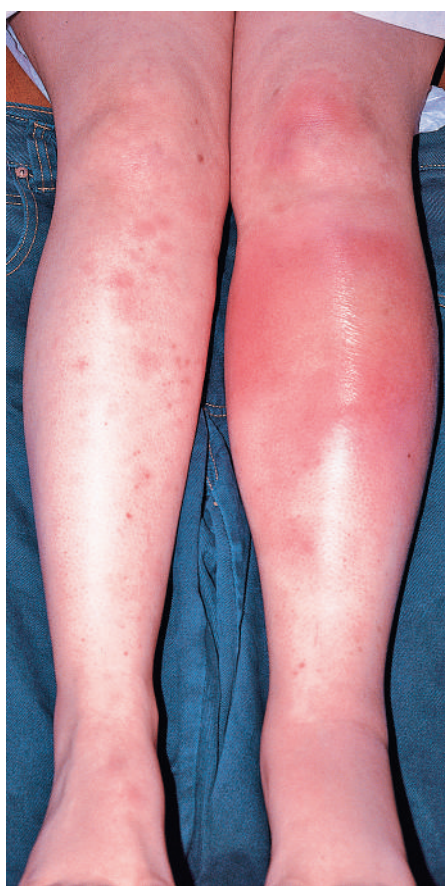**eFig. 23-6** Acquired partial lipodystrophy.

**eFig. 23-7** Insulin-induced lipohypertrophy.

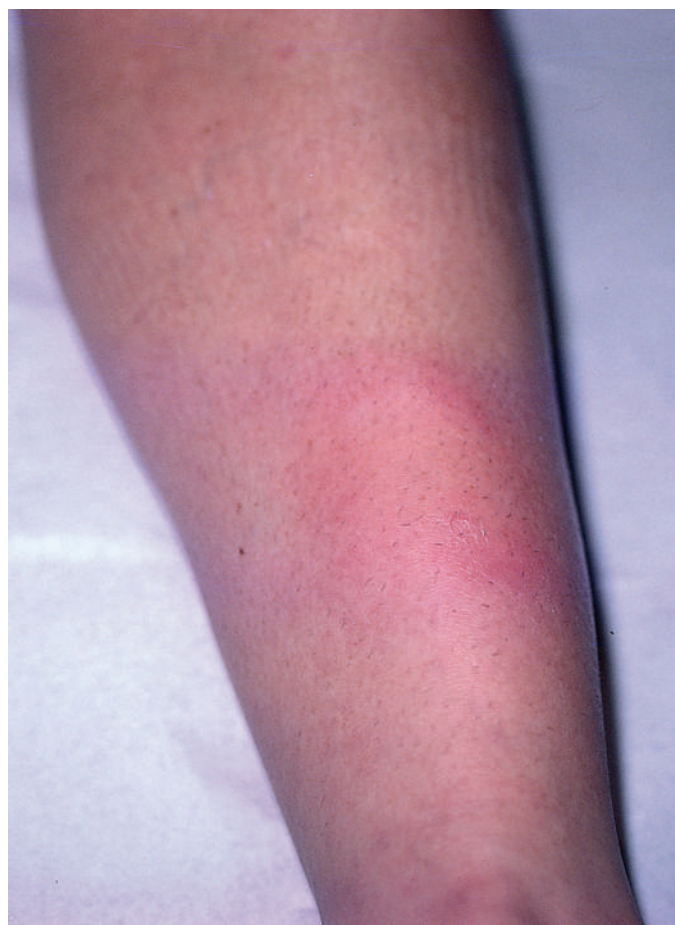



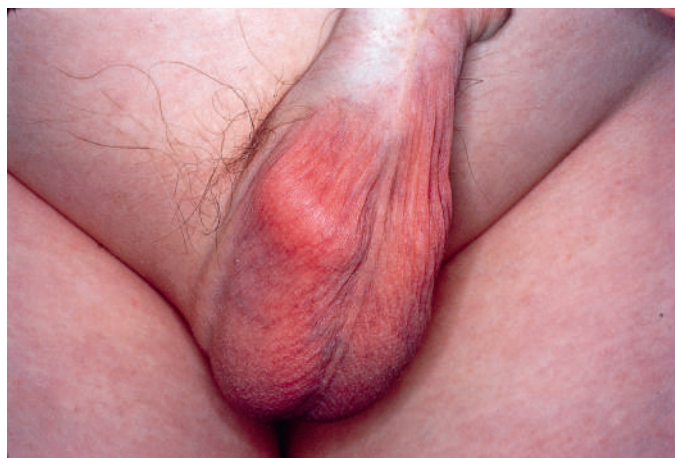**eFig. 23-1** Erythema nodosum.



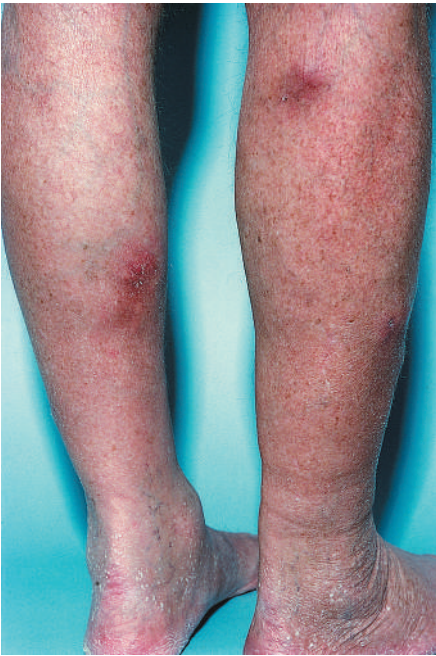
**eFig. 23-2** Erythema nodosum, erythematous tender nodules on the anterior shins.



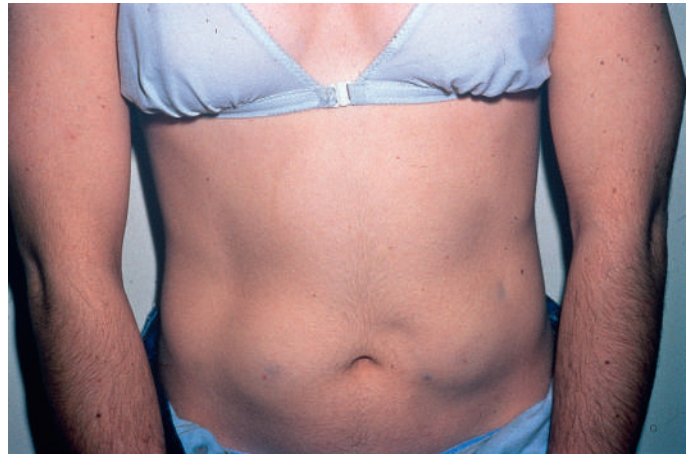
**eFig. 23-3** Chronic erythema nodosum.



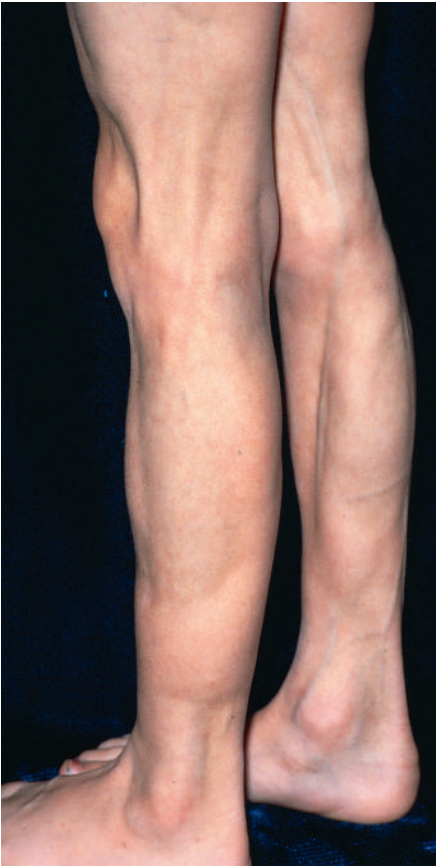**eFig. 23-4** Cold panniculitis.



**eFig. 23-5** Pancreatic fat necrosis.



**eFig. 23-7** Insulin-induced lipohypertrophy.



**eFig. 23-6** Acquired partial lipodystrophy.



The skin interacts with the endocrine system in many ways. Some of these are discussed in this chapter.

- Jabbour SA, et al:** Skin manifestations of hormone-secreting tumors. *Dermatol Ther* 2010; 23:643–650.
- Quatrano NA, et al:** Dermatologic manifestations of endocrine disorders. *Curr Opin Pediatr* 2012; 24:487–493.
- Saggini A, et al:** Skin lesions in hereditary endocrine tumor syndromes. *Endocr Pract* 2011; (Suppl 3):47–57.

### ACROMEGALY

Excess growth hormone (GH) in prepubertal children leads to gigantism, whereas once the epiphyseal growth plates close, such excess leads to acromegaly. In acromegaly, changes in the soft tissues and bones form a characteristic syndrome. In association with the well-known changes in the facial features caused by gigantic hypertrophy of the chin, nose, and supra-orbital ridges, there is thickening, reddening, and wrinkling of the forehead and exaggeration of the nasolabial grooves. The lips and tongue are thick. *Cutis verticis gyrata* is present in approximately 30% of patients. The hands and feet enlarge (Fig. 24-1), and there is gradual growth of the fingertips until they resemble drumsticks. There is diffuse hypertrophy of the skin, which is at least partly caused by deposition of colloidal iron-positive material in the papillae and reticular dermis. This increased skin thickness can be demonstrated in lateral radiographs of the heel, with reversal toward normal after treatment. Skin thickness does not correlate well with GH levels at the time of diagnosis. Skin tags are often present and the skin has an oily feel. Hypertrichosis, hyperpigmentation, and hyperhidrosis occur in many patients. The viscera also enlarge and patients may develop a variety of rheumatologic, cardiovascular, metabolic, and respiratory complications.

The clinical changes may suggest the leonine facies of Hansen's disease, as well as Paget's disease, myxedema, and pachydermoperiostosis. Acromegaloid facial appearance syndrome is an inherited condition in which only the facial changes are present, and no abnormality of growth hormone exists. Pseudoacromegaly is an acquired condition that may be seen in patients with severe insulin-resistant diabetes, which appears to be a fibroblast defect, or in patients receiving long-term minoxidil.

The cause of 98% of acromegaly is hypersecretion of GH by a pituitary adenoma. Rare cases of ectopic GH-releasing hormone (GHRH) producing tumors of the lung and pancreas have been reported. The peak age of diagnosis is in the forties. Measurement of serum insulinlike growth factor (IGF, somatomedin C), and of serum GH after a glucose load, and magnetic resonance imaging (MRI) of the pituitary are diagnostic tests. It may occur as one of the manifestations of Carney complex, McCune-Albright syndrome, or multiple endocrine neoplasia (MEN) type I.

The currently preferred treatment is a transsphenoidal microsurgical excision of the tumor. Medical therapy may be used as

a primary treatment for those unsuitable for surgery, as a pre-operative treatment, or as secondary therapy after failed surgery. Octreotide and lanreotide are potent, long-acting inhibitors of GH (somatostatin analogs) that are given as once-monthly or biweekly intramuscular (IM) depot injections. Fatigue, paresthesias, and headaches improve rapidly. With continuous treatment, soft tissue swelling and facial coarsening improve as GH levels decline in almost all patients. After 18–24 months of therapy, 50% of patients will completely normalize, with the exception of hyperhidrosis, which persists in most patients. The dopamine agonists bromocriptine and cabergoline suppress GH secretion and are used as an adjuvant medical therapy in some cases. The growth hormone receptor antagonist pegvisomant is another medical option to normalize growth hormone secretion. Radiation is generally reserved for recalcitrant cases.

- Borson-Chazot F, et al:** Acromegaly induced by ectopic secretion of GHRH. *Ann Endocrinol* 2012; 73:497–502.
- Davidovici BB, et al:** Cutaneous manifestations of pituitary gland diseases. *Clin Dermatol* 2008; 26:288.
- Jallad RS, et al:** The place of medical treatment of acromegaly. *Expert Opin Pharmacother* 2013; 14:1001–1015.
- Killinger Z et al:** Arthropathy in acromegaly. *Rheum Dis Clin North Am* 2010; 36:713–720.
- Ribeiro-Oliveira A, et al:** The changing face of acromegaly: advances in diagnosis and treatment. *Nat Rev* 2012; 8:605–611.
- Yaqub A, et al:** Insulin-mediated pseudoacromegaly. *WV Med J* 2008; 1104:12–15.
- Zen PR, et al:** Acromegaloid facial appearance and hypertrichosis: a case suggesting autosomal recessive inheritance. *Clin Dysmorphol* 2004; 13:49–50.

### CUSHING SYNDROME

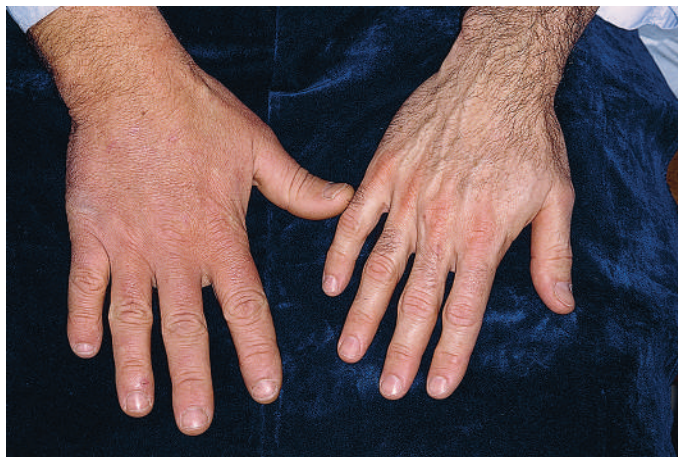Chronic excess of glucocorticoids leads to a wide variety of signs and symptoms. The most prominent features of Cushing syndrome include central obesity, affecting the face, neck, trunk, and especially the abdomen, but sparing the limbs. There is classically deposition of fat over the upper back, referred to as a buffalo hump. This may be treated with liposuction. The face becomes moon shaped, being wide and round. The peak age of onset is in the twenties and thirties.

The striking and distressing skin changes include hypertrichosis, dryness, acne, susceptibility to superficial dermatophyte and *Pityrosporon* infections, a plethora over the cheeks, anterior neck, and V of the chest, and the characteristic purplish, atrophic striae that may involve the abdomen (Fig. 24-2), buttocks, back, breasts, upper arms, and thighs. Skin fragility and thinning occur such that easy bruising and a cigarette paper-type wrinkling are present. The skin may easily pull off when adhesive tape is removed (Liddle's sign). The thinning of the skin can be demonstrated and measured in lateral radiographs of the heels. There is reversal with treatment. Women, who are affected four times more frequently than men in noniatrogenic cases, develop facial lanugo hypertrichosis,

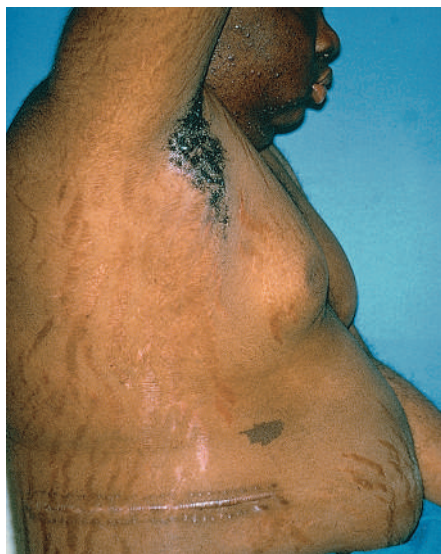with thinning of the scalp hair. Occasionally, there may be livedo reticularis, purpura, ecchymosis, or brownish pigmentation. Poikiloderma-like changes have been observed. Opportunistic fungal infections occur, either with organisms that are not normally pathogenic or as uncommon presentations of common infections.

Patients with Cushing syndrome usually have hypertension and marked generalized arteriosclerosis, with progressive weakness, prostration, and pains in the back, limbs, and abdomen; kyphosis of the dorsal spine also occurs, accentuating the buffalo hump appearance. Osteoporosis occurs, and there is generally a loss of libido. In 20% of patients, a disturbance in carbohydrate metabolism develops, with hyperglycemia, glycosuria, and diabetes mellitus.

These varied symptoms indicate a marked and widespread disturbance caused by the hyperactive adrenal cortex. When microadenomas of the pituitary gland produce these clinical findings, it is referred to as Cushing's disease; this accounts for only 10% of patients. Between 40% and 60% of additional cases are caused by increased adrenocorticotrophic hormone (ACTH, corticotropin) production by the pituitary, but no adenoma is identified. Adrenal adenomas and carcinomas, with ectopic production of ACTH by other tumors, account for the remainder of cases of noniatrogenic Cushing syndrome.



**Fig. 24-1** Acromegaly. Patient with acromegaly of hand on the left compared with normal-sized hand on the right.



**Fig. 24-2** Cushing syndrome.

Iatrogenic Cushing syndrome is usually secondary to systemic administration of corticosteroids; however, absorption from topical corticosteroids to the skin or even the gingiva may occur, especially in children. Primary pigmented nodular adrenocortical disease leading to Cushing syndrome occurs in 30% of patients with Carney complex. It is a rare feature of McCune-Albright and MEN type I syndrome. With alcohol abuse, the clinical findings of Cushing syndrome may be mimicked, producing the pseudo-Cushing syndrome.

A rapid screening test for Cushing syndrome consists of oral administration of 1 mg of dexamethasone at 11 PM, followed at 8 AM by a fluorometric determination of plasma cortisol. A cortisol level below 3 µg/dL essentially rules out Cushing syndrome, except for the iatrogenic variety, in which there is adrenocortical hypoplasia, and the serum cortisol level is very low, even without dexamethasone suppression. If this test is positive, it must be confirmed by doing a 24-hour urinary free cortisol test. A value of at least three times the upper limit of normal is 95–100% sensitive and specific. A serum ACTH is then obtained to determine if the source is the adrenal glands or if it is a pituitary tumor or an ectopic tumor (low, normal or high, and very high, respectively). Treatment is primarily surgical removal of the tumor; however, radiation, chemotherapy, or medication that blocks steroid synthesis is occasionally used.

**Besemer F, et al:** Alcohol-induced Cushing syndrome. *Neth J Med* 2011; 69(7):318–323.

**Brown RJ, et al:** Cushing syndrome in the McCune-Albright syndrome. *J Clin Endocrinol Metab* 2010; 95(4):1508–1515.

**Davidovici BB, et al:** Cutaneous manifestations of pituitary gland diseases. *Clin Dermatol* 2008; 26:288–295.

**Ejaz S, et al:** Cushing syndrome secondary to ectopic adrenocorticotrophic hormone secretion. *Cancer* 2011; 117(19):4381–4389.

**Fraser LA, et al:** Work-up for Cushing syndrome. *CMAJ* 2010; 182(6):584–587.

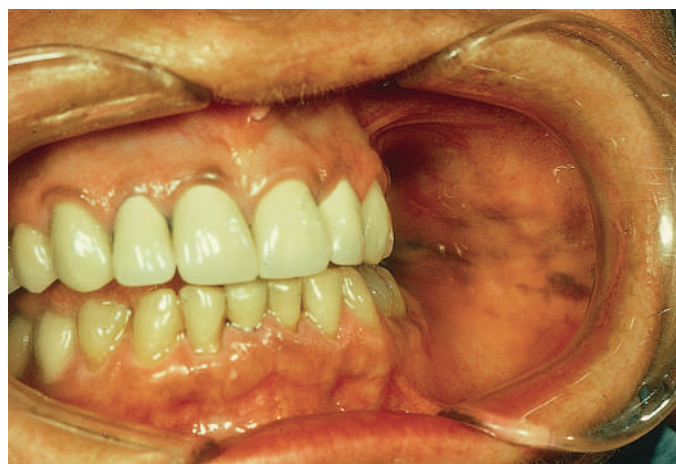**Pichardo-Lowden A, et al:** Cushing syndrome related to gingival application of a dexamethasone-containing preparation. *Endocr Pract* 2010; 16(2):336.

**Pluta RM, et al:** Cushing syndrome and Cushing disease. *JAMA* 2011; 306(24):2742.

**Starker LF, et al:** Subclinical Cushing syndrome. *Surg Clin North Am* 2014; 94(3):657–668.

## ADDISON'S DISEASE

Adrenal insufficiency is manifested in the skin primarily by hyperpigmentation (Fig. 24-3). It is diffuse but most



**Fig. 24-3** Hyperpigmentation in Addison's disease.



prominently observed in sun-exposed areas and sites exposed to recurrent trauma or pressure. The axillae, perineum, and nipples are also affected. Palmar crease darkening in patients of lighter skin type, scar hyperpigmentation, and darkening of nevi, mucous membranes, hair, and nails may all be seen. An eruptive onset of multiple new nevi may be an early sign of Addison's disease. Occasionally, pigmentation may not occur; this is referred to as white Addison's disease. Decreased axillary and pubic hair is seen in women, because their androgen production primarily occurs in the adrenals. Fibrosis and calcification of the pinnae of the ears are rare complications.

Systemic signs such as weight loss, nausea, vomiting, diarrhea, weakness, fatigue, and hypotension add specificity to the cutaneous abnormalities. Addison's disease is usually the result of autoantibody destruction of adrenocortical tissue; however, infection, hemorrhage, or infiltration may be the cause of adrenal insufficiency. In young boys suspected of having Addison's disease, adrenoleukodystrophy must be considered. Hyperpigmentation may precede neurologic signs, so very-long-chain fatty acid levels should be determined. Addison's disease may be part of polyglandular autoimmune syndrome types I, II, and IV, in which various combinations of hypoparathyroidism, chronic candidiasis, vitiligo or autoimmune thyroiditis, and diabetes may occur.

Diagnosis of Addison's disease is made by obtaining a serum cortisol, followed by stimulation with cosyntropin. Failure to see an elevation above 20 µg/dL in 1 h is diagnostic. Plasma ACTH is elevated in primary insufficiency but normal to low in patients with secondary adrenal insufficiency, in whom the damage is in the hypothalamic-pituitary axis. The adrenals should be imaged with computed tomography (CT) to exclude infiltration or infection.

Treatment of Addison's disease is replacement of the glucocorticoids and mineralocorticoids.

**Betterle C, et al:** Addison's disease. *Eur J Endocrinol* 2013; 169(6):773–784.

**Napier C, et al:** Autoimmune Addison's disease. *Autoimmune Endocr Dis* 2012; 41:e626–e635.

**Prat C, et al:** Longitudinal melanonychia as the first sign of Addison's disease. *J Am Acad Dermatol* 2008; 58:522–524.

**Vaidya B, et al:** Addison's disease. *BMJ* 2009; 339:b2385.

**Wilhelm L, et al:** Histoplasmosis associated with Addison's disease. *Rev Soc Bras Med Trop* 2013; 46(1):123.

## PANHYPOPITUITARISM AND GROWTH HORMONE DEFICIENCY

Pituitary failure results in many changes in the skin, hair, and nails because of the absence of pituitary hormone action on these sites. Pale, thin, dry skin is seen. Hypohidrosis is present. Diffuse loss of body hair occurs, with axillary, pubic, and head hair being especially thin. The nails are thin, fragile, and opaque and grow slowly. Compromise of the pituitary gland is usually caused by a pituitary tumor, although infiltration, infection, trauma, hemorrhage, or hypothalamic tumors may be the etiology. Thyroid hormone, glucocorticoids, sex steroids, and growth hormones are low and require replacement. A pituitary MRI will screen for tumors or infiltrative processes.

**Davidovici BB, et al:** Cutaneous manifestations of pituitary gland diseases. *Clin Dermatol* 2008; 26:288–295.

**De Lange TE, et al:** A case of cocaine-induced panhypopituitarism with human neutrophil elastase-specific anti-neutrophil cytoplasmic antibodies. *Eur J Endocrinol* 2009; 160(3):499–502.

**Sariguzel N, et al:** Dobraava hantavirus infection complicated by panhypopituitarism, Istanbul, Turkey, 2010. *Emerg Infect Dis* 2012; 18(7):1180–1183.

## ANDROGEN-DEPENDENT SYNDROMES

The androgen-dependent syndromes are caused by the excessive production of adrenal or gonadal androgens by adrenal adenomas, carcinoma, or hyperplasia, Leydig cell tumors in men, and arrhenoblastomas and polycystic ovarian syndrome (PCOS) in women. PCOS is defined as the association of biochemical or clinical androgenism with chronic anovulation, without specific underlying disease of the adrenal or pituitary glands.

The cutaneous signs of excessive androgen in women include acne, hirsutism, temporal balding and androgen-induced patterned scalp hair loss, seborrhea, enlargement of the clitoris, and decreased breast size. Hyperpigmentation of the skin, areolae, genitalia, palmar creases, and buccal mucosa develops in some patients. Acanthosis nigricans is common in PCOS, reflecting insulin resistance. Diabetes mellitus, cardiovascular complications, and sleep apnea are associated comorbidities of PCOS. The association of endometrial cancer is suggested but remains unproved in women. Females may also develop a deepening voice, increased muscle mass, galactorrhea, and irregular or absent periods.

In the congenital adrenogenital syndrome, excess androgen is produced by an inherited defect in any of the five enzymatic steps required to convert cholesterol to cortisol. The formation of inadequate amounts of cortisol stimulates the pituitary to secrete excessive ACTH, which leads to excess androgen production. In boys, precocious puberty results. In girls, masculinization occurs, with the prominent cutaneous signs of excess androgen production (Fig. 24-4). These signs may include acne. Acne with onset between ages 1 and 7 with physical findings suggestive of a hormonal disorder, such as sexual precocity, virilization, and growth abnormalities, should be referred to a pediatric endocrinologist. Acne that begins from ages 7 to 12 often manifests primarily as comedonal lesions in the central face. Unless there are other signs of androgen excess, these patients do not need a workup. Accelerated bone growth with early closure of the epiphyseal plates results in short stature. Early appearance of pubic and axillary hair is also seen.

Testing includes serum total testosterone and dehydroepiandrosterone sulfate (DHEA-S) levels. If the total testosterone concentration is greater than 200 ng/dL, ovarian imaging is indicated to assess for an ovarian tumor. If DHEA-S level is two to three times the upper limit, an adrenal mass should be suspected, and CT scan of the adrenals is required. In congenital adrenal hyperplasia, testing should include levels of cortisol, aldosterone, and precursor hormones, and in some

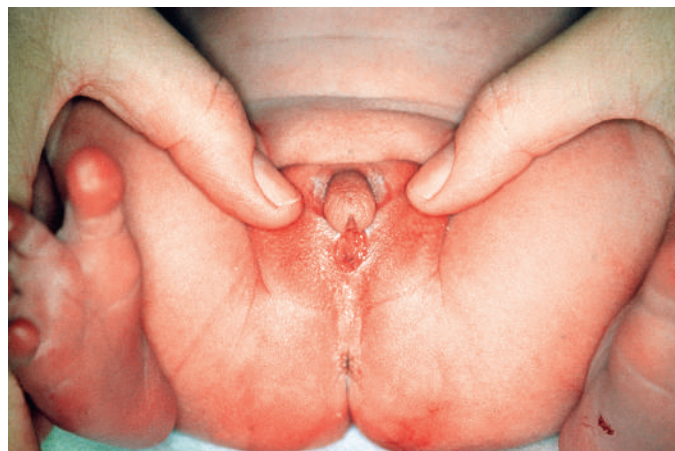

Fig. 24-4 Adrenogenital syndrome.

patients, cosyntropin (Cortrosyn) stimulation tests. Nonclassic adrenal hyperplasia is most often related to 21-hydroxylase deficiency and may present as PCOS. It is best diagnosed by a corticotropin-stimulated 17-hydroxyprogesterone (17-HP) level greater than 10 ng/mL (30.3 nmol/L). The diagnosis can be confirmed by genotyping of the *CYP21* gene. The baseline 17-HP level has been used as a screening test. Although the sensitivity and specificity of the test have been challenged, levels of 17-HP lower than 2 ng/mL (6.0 nmol/L) have a fairly good negative predictive value, and levels greater than 4 ng/mL (12.0 nmol/L) have a fairly good positive predictive value. The question remains whether treatment with corticosteroid replacement results in better outcomes than empiric androgen therapy.

Treatment of the cutaneous signs of androgen excess is successful with an oral contraceptive and often also an androgen-blocking agent such as cyproterone acetate, flutamide, or finasteride. Spironolactone, which competes for the androgen cytosol receptors, has proved useful as a systemic antiandrogen in the treatment of hirsutism and acne. Laser hair removal and standard acne therapy are also effective. Adrenal-androgenic female pattern alopecia may improve with topical minoxidil or spironolactone. Metformin is frequently used to improve insulin responsiveness. Chorionic villous biopsy may identify homozygous adrenogenital female fetuses and allow for dexamethasone therapy to prevent intrauterine virilization of the external genitalia.

**Auchus RJ et al:** Approach to the patient: the adult with congenital adrenal hyperplasia. *J Clin Endocrinol Metab* 2013; 98(7):2645–2655.

**Azziz R, et al:** The Androgen Excess and PCOS Society criteria for the polycystic ovary syndrome. *Fertil Steril* 2009; 91:456–488.

**Lee AT, et al:** Dermatologic manifestations of polycystic ovary syndrome. *Am J Clin Dermatol* 2007; 8:201–219.

**Martin KA, et al:** Evaluation and treatment of hirsutism in premenopausal women. *J Clin Endocrinol Metab* 2008; 93:1105–1120.

**Nisenblatt V, et al:** Androgens and polycystic ovary syndrome. *Curr Opin Endocrinol Diabetes Obes* 2009; 16:224–231.

**Setji TL, et al:** Polycystic ovary syndrome. *Am J Med* 2014; 127:912–919.

**Sirmans SM, et al:** Epidemiology, diagnosis, and management of polycystic ovary syndrome. *Clin Epidemiol* 2013; 18(6):1–13.

**Voutilainen R, et al:** Premature adrenarche. *J Steroid Biochem Mol Biol* 2014 Jun 9; pii: S0960-0760(14)00118-6.

## HYPOTHYROIDISM

Hypothyroidism is a deficiency of circulating thyroid hormone, or rarely, peripheral resistance to hormonal action. Deficiency may be caused by iodine deficiency, late-stage Hashimoto autoimmune thyroiditis, or pituitary or hypothalamic disease causing central hypothyroidism, or it may be iatrogenic secondary to surgery, radioactive iodine treatment, or drug therapy with lithium, interferon, multikinase inhibitors, valproic acid, or bexarotene. It may also complicate anticonvulsant and minocycline hypersensitivity syndromes, appearing approximately 2 months after the eruption has resolved. Hypothyroidism produces various clinical manifestations, depending on the age when it occurs and on its severity. Middle-age women are the adults most often affected. Patients with Turner and Down syndrome are predisposed to hypothyroidism and the production of thyroid autoantibodies. There are a wide array of immunologic conditions associated with Hashimoto thyroiditis, including polyglandular autoimmune syndrome types II and III, vitiligo, connective tissue disease, and autoimmune urticaria.

An autosomal recessive variant of ectodermal dysplasia has been described as ANOTHER syndrome: alopecia, nail dystrophy, ophthalmic complications, thyroid dysfunction,

hypohidrosis, epheles and enteropathy, and respiratory tract infections. Recent associations with hypothyroidism include lichen planopilaris and cutaneous sarcoidosis.

## Congenital hypothyroidism

Thyroid deficiency in fetal life produces the characteristic picture of cretinism at birth and in the next few months of life. Various mutations in the thyroglobulin gene, the thyroid peroxidase gene, and the thyroid-stimulating hormone (TSH) receptor may be causative. Depending on the degree of thyroid deficiency, a wide variety of signs and symptoms may be evident. The main consequence of extreme thyroid deficiency is cretinism and its attendant mental retardation, but much more prevalent are lesser degrees of intellectual and neurologic deficits seen in areas of the world where iodized salt is still not routinely available.

The person with cretinism has cool, dry, pasty-white to yellowish skin. Disturbances in the amount, texture, and distribution of the hair with patchy alopecia are common. Pigmentation is less than normal after exposure to sunlight. Sweating is greatly diminished. The lips are pale, thick, and protuberant. The tongue is usually enlarged, and there is delayed dentition. Wide-set eyes, a broad, flat nose, and periorbital puffiness characterize the face. A protuberant abdomen with umbilical hernia; acral swelling; coarse, dry, brittle nails; a clavicular fat pad; and hypothermia with cutis marmorata are also seen.

## Myxedema

When lack of secretion of thyroid hormone is severe, myxedema is produced. The skin becomes rough and dry, and in severe cases of primary myxedema, ichthyosis vulgaris may be simulated. The facial skin is puffy; the expression is often dull and flat; macroglossia, swollen lips, and a broad nose are present; and chronic periorbital infiltration secondary to deposits of mucopolysaccharides frequently develops (Fig. 24-5, A). Such infiltrate can lead to a cutis verticis gyrata appearance of the scalp. Carotenemia may cause a yellow tint in the skin that is especially prominent on the palms and soles. Diffuse hair loss is common, and the outer third of the eyebrows is shed (Fig. 24-5, B). The hair becomes coarse and brittle. The free edges of the nails break easily, and onycholysis may occur.

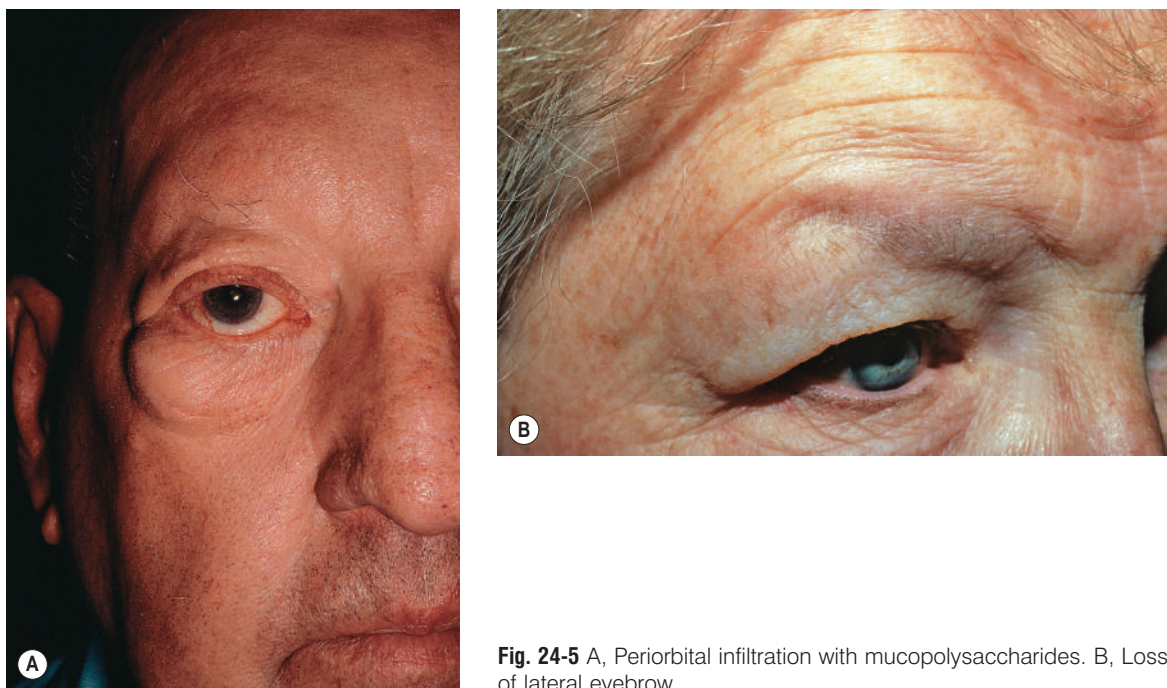
## Mild hypothyroidism

Lesser degrees of thyroid deficiency are common and much less easily diagnosed. Coldness of hands and feet in the absence of vascular disease, sensitivity to cool weather, lack of sweating, tendency to put on weight, need for extra sleep, drowsiness in the daytime, and constipation all suggest possible hypothyroidism and the need for appropriate tests. Palmoplantar keratoderma may be a sign of hypothyroidism and will resolve after thyroid hormone replacement is given.

## Diagnosis and treatment

An increased TSH test is the best diagnostic test for primary hypothyroidism. Triiodothyronine ( $T_3$ ) and thyroxine ( $T_4$ ) are low. In Hashimoto thyroiditis, the most common cause of hypothyroidism in the United States, thyroid peroxidase antibodies are present in 95% of patients and antithyroglobulin antibodies in 65%. In those with positive antibodies but normal thyroid function, hypothyroidism will develop at a rate of 5%





**Fig. 24-5** A, Periorbital infiltration with mucopolysaccharides. B, Loss of lateral eyebrow.

per year. Thyroid hormone replacement will reverse the skin findings of hypothyroidism.

**Abduljabbar MA, et al:** Congenital hypothyroidism. *J Pediatr Endocrinol Metab* 2012; 25(1-2):13–29.

**Almandoz JP, et al:** Hypothyroidism. *Med Clin North Am* 2012; 96:203–221.

**Anolik RB, et al:** Thyroid dysfunction and cutaneous sarcoidosis. *J Am Acad Dermatol* 2012; 66(1):167–168.

**Mesinkovska NA, et al:** Association of lichen planopilaris with thyroid disease. A retrospective case-control study *J Am Acad Dermatol*. 2014; 70:889–892.

**Brown RJ, et al:** Minocycline-induced drug hypersensitivity syndrome followed by multiple autoimmune sequelae. *Arch Dermatol* 2009; 145:63–66.

**Doshi DN, et al:** Cutaneous manifestations of thyroid disease. *Clin Dermatol* 2008; 26:283–287.

**Funakoshi T, et al:** Risk of hypothyroidism in patients with cancer treated with sunitinib. *Acta Oncol* 2013; 52(4):691–702.

**Persani L, et al:** Clinical review: central hypothyroidism. *J Clin Endocrinol Metab* 2012; 97(9):3068–3078.

**Persani L, et al:** Genetics and phenomics of hypothyroidism due to TSH resistance. *Mol Cell Endocrinol* 2010; 322(1-2):72–82.

**Ris-Stalpers C, et al:** Genetics and phenomics of hypothyroidism and goiter due to *TPO* mutations. *Mol Cell Endocrinol* 2010; 322(1-2):38–43.

**Targovnik HM, et al:** Thyroglobulin gene mutations in congenital hypothyroidism. *Horm Res Paediatr* 2011; 75(5):311–321.

## HYPERTHYROIDISM

Excessive quantities of circulating thyroid hormone may be caused by Graves' thyroiditis (diffuse toxic goiter), a multinodular toxic goiter (Plummer's disease), or a single, toxic thyroid nodule, early Hashimoto autoimmune thyroiditis, a TSH-secreting pituitary adenoma, pituitary resistance to thyroid hormone, metastatic thyroid cancer, or excessive human chorionic gonadotropin. The most common etiology is Graves' disease, which accounts for about 55% of cases; it is mediated by thyroid-stimulating antibodies that bind to the TSH receptor, mimic the effects of TSH, and induce hyperthyroidism. Many skin changes are common to all forms of hyperthyroidism. The cutaneous surface is warm, moist, and smooth.

Palmar erythema or facial flushing may be seen. The hair is thin and has a downy texture, and nonscarring diffuse alopecia may be observed. The skin may darken to produce a bronzed appearance or melanoderma; melasma of the cheeks is seen in some cases. Nail changes are present in approximately 5% of patients with Plummer nails, a concave contour of the plate with characteristic distal onycholysis. Hyperhidrosis may be noted.

Graves' disease has a female/male ratio of 7:1, and the peak age of onset is 20–30 years. It is the most common cause of noniatrogenic hyperthyroidism. Ophthalmopathy, pretibial myxedema, and thyroid acropachy are findings almost always limited to patients with Graves' disease (Fig. 24-6). Thyroid acropachy, seen in approximately 0.1–1% of Graves' patients, is characterized by digital clubbing, soft tissue swelling of the hands and feet, and diaphyseal proliferation of the periosteum in acral and distal long bones (tibia, fibula, ulna, radius). It usually occurs after treatment of hyperthyroidism and is frequently associated with exophthalmos and pretibial myxedema. It may, however, occasionally precede the thyrotoxicosis and has been recognized in euthyroid and hypothyroid patients. It can be confused clinically with acromegaly, pachydermoperiostosis, pulmonary osteoarthropathy, or osteoperiostitis, but the radiologic findings are pathognomonic.

Pretibial myxedema, consisting of bilateral, localized, cutaneous accumulations of glycosaminoglycans, occurs in 4% of patients who have or have had Graves' disease. The morphology may vary from a nonpitting infiltration to nodules, plaques, and even an elephantiasic form where the skin is thickened, firm, and hyperpigmented from just below the knees to the feet. It may also occur infrequently during the course of Hashimoto thyroiditis and primary hypothyroidism. Patients with pretibial myxedema regularly have associated ophthalmopathy and occasionally thyroid acropachy. Although usually not clinically apparent, approximately half of patients with Graves' disease have mucopolysaccharide deposition in the preradial area of the extensor aspects of the forearms. Lesions of the shoulder, hands, thigh, and scalp have been reported.

Improvement in the plaques of pretibial myxedema has resulted from intralesional injections of triamcinolone acetonide and with high-potency topical corticosteroids under

occlusion. Systemic corticosteroids may also be helpful. Compression stockings or complete decongestive physiotherapy, and a combination of manual lymphatic drainage, bandaging, and exercise, are useful and safe. With intravenous immune globulin (IVIG) administration, improvement of the skin, eye, and immunologic parameters has been reported in small series of patients. Pentoxifylline, octreotide, plasmapheresis, and cytotoxic drugs have all been reported to help in small numbers of patients, but negative reports also exist.

Vitiligo is present in 7% of patients with Graves' disease and occurs with an increased frequency in Hashimoto thyroiditis. Urticaria may be seen in patients with thyroid autoantibodies and may clear with the administration of thyroid hormone, even in euthyroid patients. A wide range of other autoimmune disorders may be seen in patients with Graves' disease or Hashimoto autoimmune thyroiditis.

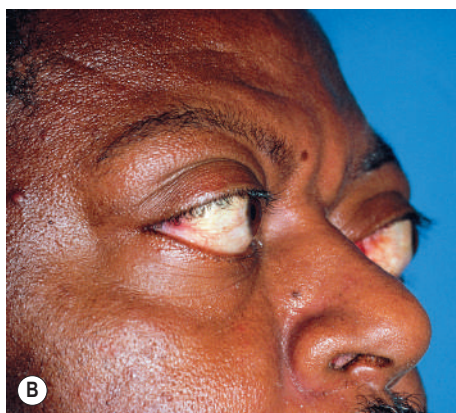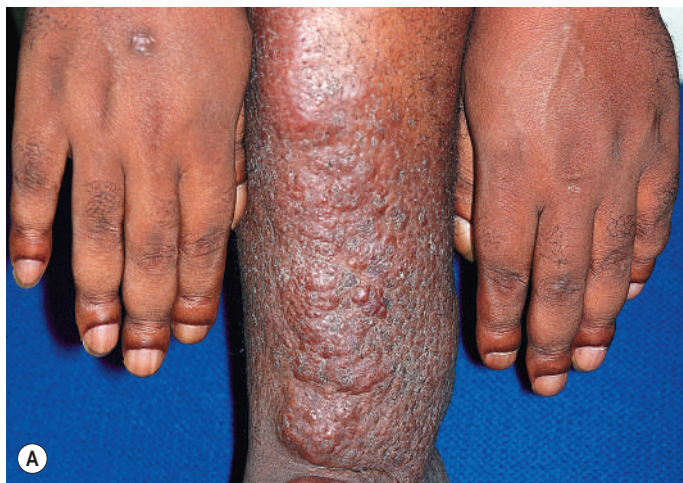The TSH level is low in all patients except those with a TSH-secreting pituitary adenoma. Free  $T_3$  and  $T_4$  are elevated. Anti-TSH antibodies are present in almost all Graves patients. A 24-hour radioiodine scan will also help define the etiology. Treatment is with radioactive iodine or antithyroid drugs such as methimazole or propylthiouracil.

**Artantas S, et al:** Skin findings in thyroid diseases. *Eur J Intern Med* 2009; 20:158.

**Brinster NS, et al:** Localized myxedema of thyroid disease. *J Am Acad Dermatol* 2013; 68(6):e189–e190.

**Heymann W (ed):** *Thyroid Disorders with Cutaneous Manifestations*. Heidelberg: Springer, 2008.

**Shirai K, et al:** Dramatic effect of low-dose oral steroid on elephantiasis pretibial myxedema. *J Dermatol* 2014; 41:941–942.



**Fig. 24-6** A, Thyroid acropachy and pretibial myxedema. B, Exophthalmos.

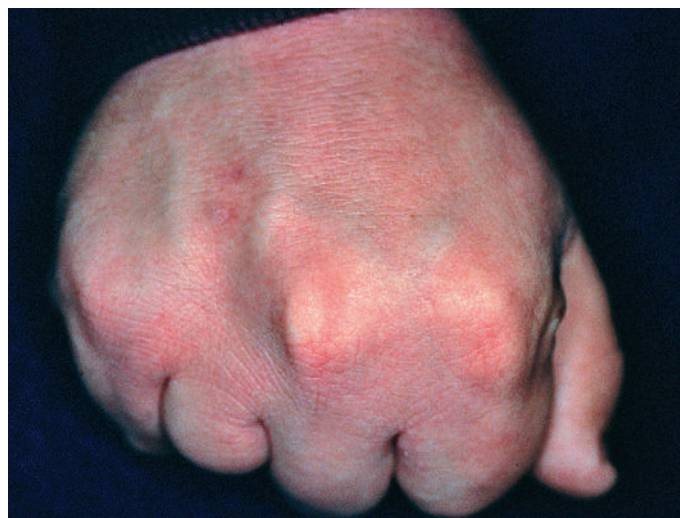**Takasu N, et al:** Treatment of pretibial myxedema (PTM) with topical steroid ointment application with sealing cover (steroid occlusive dressing technique). *Intern Med* 2010; 49:665–669.

**Vannucchi G, et al:** Treatment of pretibial myxedema with dexamethasone injected subcutaneously by mesotherapy needles. *Thyroid* 2013; 23(5):626–632.

## HYPOPARATHYROIDISM

Varied changes in the skin and its appendages may be evident in parathyroid hormone (PTH, parathormone) deficiency. Most pronounced is faulty dentition when hypoparathyroidism is present during development of the permanent teeth. The skin is dry and scaly. A diffuse scantiness of the hair and complete absence of axillary and pubic hair may be found. The nails are brittle and malformed. Onycholysis with fungal infection may be present. Of patients with idiopathic hypoparathyroidism, 15% develop mucocutaneous candidiasis. Hypoparathyroidism is the most frequent endocrine abnormality present in patients with the APECED (autoimmune polyendocrinopathy, candidiasis, ectodermal dystrophy) syndrome. In autoimmune polyendocrinopathy syndrome type I, hypoparathyroidism is present in association with Addison's disease and chronic candidiasis. Hypoparathyroidism may also occur in DiGeorge syndrome, or with parathyroid infiltration or their inadvertent surgical removal during thyroid surgery. The causative genetic defects and specific autoantibodies responsible for PTH deficiency and pseudohypoparathyroidism are well defined. Hypoparathyroidism with resultant hypocalcemia may trigger bouts of impetigo herpetiformis or pustular psoriasis.

Pseudohypoparathyroidism (PH) is an autosomal dominant or X-linked inherited disorder characterized by end-organ unresponsiveness to PTH. The PTH and phosphorus levels are high, whereas the serum calcium is low. The typical clinical findings include short stature; obesity; round face; prominent forehead; low nasal bridge; attached earlobes; short neck; short, wide nails; delayed dentition; mental deficiency; amenorrhea; blue sclerae; and cataracts. Brachycephaly, microcephaly, and shortened metacarpals or metatarsals, especially of the fourth and fifth digits, occur because of premature epiphyseal closure. This results in short, stubby fingers and toes, with dimpling over the metacarpophalangeal joints (Albright's sign; Fig. 24-7). Subcutaneous calcification and ossification occur frequently in PH, as they may in pseudopseudohypoparathyroidism (PPH), which has the same phenotype, but



**Fig. 24-7** Albright's sign in pseudohypoparathyroidism.



patients have normal serum and calcium levels. PH and PPH are two types of Albright hereditary osteodystrophy.

**Al-Azem H, et al:** Hypoparathyroidism. *Best Pract Res Clin Endocrinol Metab* 2012; 26(4):517–522.

**Bilezikian JP, et al:** Hypoparathyroidism in the adult. *J Bone Miner Res* 2011; 26(10):2317–2337.

**Brandi ML, et al:** Genetics of hypoparathyroidism and pseudohypoparathyroidism. *J Endocrinol Invest* 2011; 34(7):27–34.

**De Sanctis V, et al:** Hypoparathyroidism. *Curr Opin Endocrinol Diabetes Obes* 2012; 19: 435–442.

**Mantovani G, et al:** Clinical review: pseudohypoparathyroidism. *J Clin Endocrinol Metab* 2011; 96(10):3020–3030.

## HYPERPARATHYROIDISM

Whereas PTH regulates calcium levels, calcinosis cutis may develop from excess PTH. This can occur when the serum calcium/phosphorus product is greater than 65 mg/dL. This may manifest as large, subcutaneous nodules or white, often linearly arranged papules centered around joints. Additionally, calciphylaxis, although most common in the patient with secondary hyperparathyroidism and renal failure, may be seen occasionally in primary hyperparathyroidism.

Multiple endocrine neoplasia type I (MEN I) is characterized by tumors of the parathyroid glands, endocrine pancreas, anterior pituitary, thyroid, and adrenal glands. The most frequently observed abnormality is hypercalcemia from hypersecreting tumors of the parathyroid glands. This autosomal-dominantly inherited disease usually presents in the fourth decade of life with clinical symptoms related to hypersecretion of hormone. Patients may also manifest multiple angiofibromas, collagenomas, café au lait macules, lipomas, confetti-like hypopigmentation, and gingival macules. The angiofibromas are smaller and less numerous than those present in tuberous sclerosis. Tumors in both MEN I and tuberous sclerosis arise because of abnormalities within a tumor suppressor gene. MEN I is caused by *MEN1* mutations, and MEN type IV (or MEN 4, also called MEN X), which also has associated parathyroid tumors, is caused by mutations of *CDNK1B*.

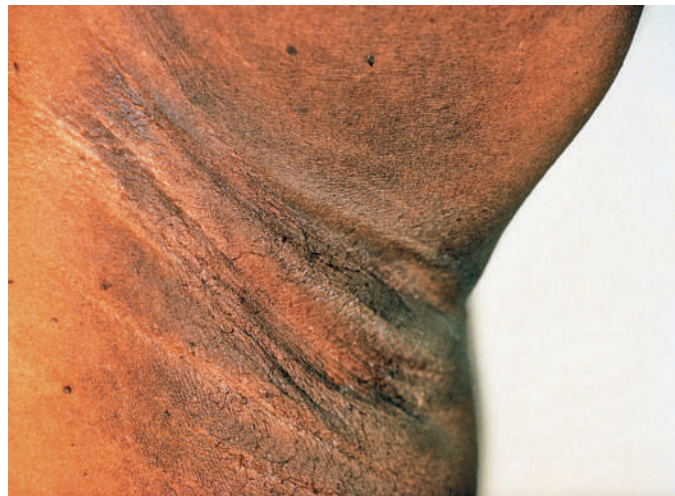**Thakker RV, et al:** Multiple endocrine neoplasia type 1 (MEN1) and type 4 (Men4). *Mol Cell Endocrinol* 2014; 386(1-2):2–15.

**Thakker RV et al:** Clinical practice guidelines for multiple endocrine neoplasia type 1 (MEN1). *J Clin Endocrinol Metab* 2012; 97(9):2990–3011.

**Vidal A, et al:** Cutaneous lesions associated to multiple endocrine neoplasia syndrome type 1. *J Eur Acad Dermatol Venereol* 2008; 22:835.

## ACANTHOSIS NIGRICANS

Acanthosis nigricans (AN) is characterized by hyperpigmentation and velvet-textured plaques, which are symmetrically distributed. The regions affected may be the face, neck, axillae (Fig. 24-8), external genitals, groin, inner aspects of the thighs, flexor and extensor surface of the elbows and knees, dorsal joints of the hands, umbilicus, and anus. With extensive involvement, lesions can be found on the areolae, conjunctivae, lips, and buccal mucosa, and around the umbilicus. Rarely, the involvement may be almost universal. The color of the patches is grayish, brownish, or black. The palms or soles may show thickening of the palmar or plantar skin with exaggeration of the dermatoglyphs. In severe cases, a rugose hypertrophy occurs and can be a sign of malignancy. Small, papillomatous, nonpigmented lesions and pigmented macules may occasionally be found in the mucous membranes of the mouth, pharynx, and vagina. Acrochordons are a frequent accompaniment in the axillae and groin. There is a clear



**Fig. 24-8** Obesity-related acanthosis nigricans.

predisposition for certain racial groups to manifest AN, with Native Americans most often affected, followed by African Americans and Hispanics, all above the rates in Caucasians. AN is obesity independent.

### Type I: acanthosis nigricans associated with malignancy

The rare type I AN may either precede (18%), accompany (60%), or follow (22%) the onset of the internal cancer. It is generally the most striking type clinically, from both the extent of involvement and the pronounced nature of the lesions (Fig. 24-9). Most cases are associated with adenocarcinoma, especially of the gastrointestinal tract (60% stomach), lung, and breast, or less often the gallbladder, pancreas, esophagus, liver, prostate, kidney, colon, rectum, uterus, and ovaries. Other types of cancer and lymphoma may be seen as well. A few cases have been observed in childhood, but most begin after puberty or in adulthood. Type I AN should be highly suspected if widespread lesions develop in a nonobese male over age 40.

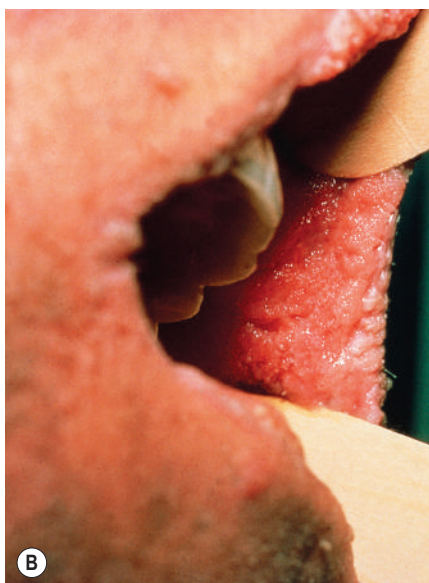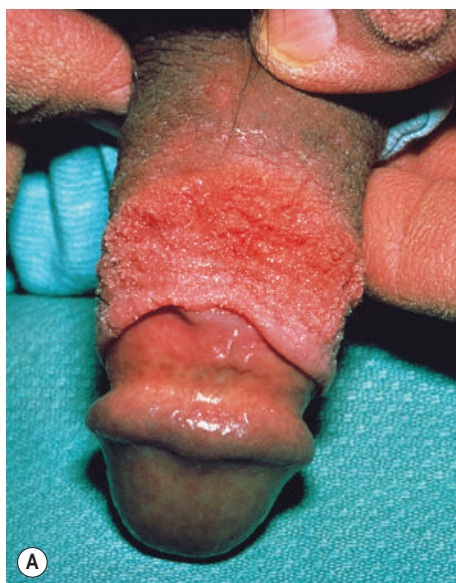Tripe palms (acanthosis palmaris) are characterized by thickened, velvety palms with pronounced dermatoglyphics; 95% occur in patients with cancer, and 77% are seen with AN (Fig. 24-10). In 40% of these patients, tripe palms are the presenting sign of an undiagnosed malignancy. If only the palms are involved, lung cancer is most common, whereas in tripe palms associated with AN, gastric cancer is most frequent.

### Type II: familial acanthosis nigricans

The exceedingly rare type II AN is present at birth or may develop during childhood. It is commonly accentuated at puberty. It is not associated with an internal cancer and is inherited in an autosomal dominant manner. Some patients will have a mutation in the fibroblast growth factor receptor 3 gene, as also occurs in Cruzon's and other syndromes with associated AN.

### Type III: acanthosis nigricans associated with insulin-resistant states and syndromes

Type III is the most common variety of AN. It presents as a grayish, velvety thickening of the skin of the sides of the neck,

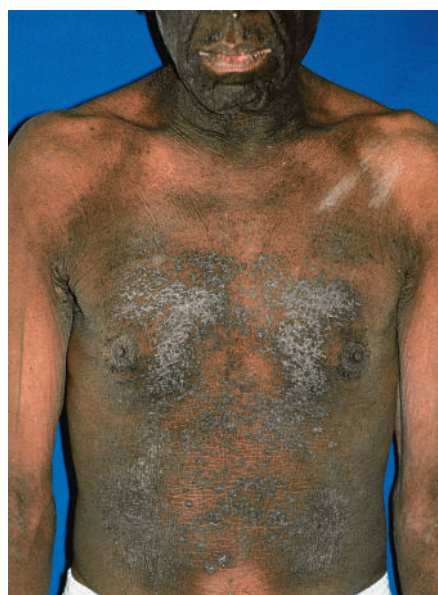

**Fig. 24-9** A and B, Extensive acanthosis nigricans in patient with stomach cancer.



**Fig. 24-10** Tripe palms.

axillae, and groins. It occurs in obese persons with or without endocrine disorders. It also occurs in acromegaly and gigantism, pseudoacromegaly, PCOS, Cushing syndrome, diabetes mellitus, MORFAN syndrome (mental retardation, overgrowth, remarkable face, and AN), Addison's disease, Prader-Willi syndrome, Alström syndrome, ataxia-telangiectasia, hyperandrogenic states, hypogonadal syndromes, and the various well-recognized insulin-resistant states. These states include lipoatrophic diabetes, leprechaunism, pinealoma (Rabson-Mendenhall syndrome), and acral hypertrophy syndrome, as well as type A syndrome, with a defect in insulin receptor and postreceptor pathways, or a lamin A mutation and type B syndrome, with the presence of autoantibodies to the insulin receptor. Whereas both type A and type B syndrome occur most often in black females, type A predominates in young children with hyperandrogenic manifestations. Many of the conditions associated with insulin resistance and AN manifest as hyperandrogenism and have been termed the HAIR-AN syndrome. In one group of women with hirsutism, obesity, and hyperandrogenism, vulvar AN was present in all patients, with other sites less frequently involved. Type B syndrome is seen in middle-age patients with autoimmune disease (Fig. 24-11). Most, if not all, patients with this type of AN may have either clinical or subclinical insulin resistance, and patients should have a glucose and insulin level drawn



**Fig. 24-11** Diffuse acanthosis nigricans in type B syndrome.

simultaneously. In adults a glucose to insulin ratio of less than 4.5 is abnormal, while in prepubertal children less than 7 is abnormal. Fasting glucose and lipoprotein profile, hemoglobin A1c, body weight, blood pressure, and an alanine transaminase (ALT) test for evaluation for fatty liver are other investigations that are useful in assessing patients with suspected insulin-resistant states.

### Diagnosis and treatment

Acanthosis nigricans may occur in fibroblast growth factor receptor defect syndromes such as Beare-Stevenson cutis gyrata syndrome, Crouzon syndrome, severe achondroplasia with developmental delay and AN (SADDAN), and thanatophoric dysplasia. Other associated syndromes that also manifest AN include Bloom syndrome, Costello syndrome, Wilson's disease, benign encephalopathy, Hirschowitz syndrome, Capozucca syndrome, Down syndrome, Hermansky-Pudlak syndrome, Kabuki syndrome, hypothyroidism, Rud syndrome, and primary biliary cirrhosis. Drugs known to induce



AN include nicotinic acid, niacinamide, somatotrophin, testosterone, triazinate, diethylstilbestrol, oral contraceptives, insulin, protease inhibitors, and glucocorticoids. Approximately 10% of renal transplant patients have AN.

The histopathology of AN shows papillomatosis without thickening of the malpighian layer. "Acanthosis" was applied here to indicate the clinical bristly thickening of the skin and not as a histologic term. Hyperkeratosis and slight hyperpigmentation of the basal layer is present in most cases; it appears, however, that the clinically observed hyperpigmentation is caused by hyperkeratosis and clinical thickening rather than by melanin.

The differential diagnosis includes intertriginous granular parakeratosis and several disorders of reticulated hyperpigmentation, including confluent and reticulated papillomatosis (Gougerot-Carteaud syndrome), Dowling-Degos' disease, Haber syndrome, and acropigmentatio reticularis of Kitamura. Granular parakeratosis presents as erythematous to brownish hyperkeratotic papules and plaques of the intertriginous regions. It is most often seen in middle-age women in the axillae; however, the inguinal folds and submammary areas may be involved. Histology reveals a thickened stratum corneum, severe compact parakeratosis with retention of keratohyalin granules, and vascular proliferation and ectasia. The cause is likely to be an irritant response to rubbing or to antiperspirants or deodorants. Dowling-Degos' disease is a familial nevoid anomaly with delayed onset in adult life. There is progressive, brown-black hyperpigmentation of flexures with associated soft fibromas and follicular hyperkeratoses. Pitted acneiform scars occur periorally.

Treatment of type I AN, associated with malignancy, consists of finding and removing the causal tumor. Early recognition and treatment may be lifesaving. AN occurring with obesity (type III) usually improves with weight loss. If there is associated endocrinopathy, it must be treated as well. One

patient with lipodystrophic diabetes improved during dietary supplementation with fish oil. Etretinate, metformin, or other medications to control insulin resistance, as well as tretinoin, calcipotriol, urea, salicylic acid, CO<sub>2</sub> laser ablation, and long-pulsed alexandrite laser therapy, have been reported as successful treatments in individual cases.

**Costa MC, et al:** Acanthosis nigricans and "tripe palm" as paraneoplastic manifestations of metastatic tumor. *An Bras Dermatol* 2012; 87(3):498–500.

**Fabroni C, et al:** Tripe palms associated with malignant acanthosis nigricans in a patient with gastric adenocarcinoma. *Dermatol Online J* 2012; 18(11):15.

**Higgins SP, et al:** Acanthosis nigricans: a practical approach to evaluation and management. *Dermatol Online J* 2008; 15:2.

**Jeong KH, et al:** Generalized acanthosis nigricans related to type B insulin resistance syndrome. *Cutis* 2010; 86(6):299–302.

**Lee AT, et al:** Dermatologic manifestations of polycystic ovary syndrome. *Am J Clin Dermatol* 2007; 8:201.

**Malek R, et al:** Treatment of type B insulin resistance. *J Clin Endocrinol Metab* 2010; 95:3641.

**Mir A, et al:** Cutaneous features of Crouzon syndrome with acanthosis nigricans. *JAMA Dermatol* 2013; 149(6):737–741.

**Rafalson L, et al:** The association between acanthosis nigricans and dysglycemia in an ethnically diverse group of eighth grade students. *Obesity* 2013; 21(3):E328–E333.

**Sinha S, et al:** Juvenile acanthosis nigricans. *J Am Acad Dermatol* 2007; 57:502.



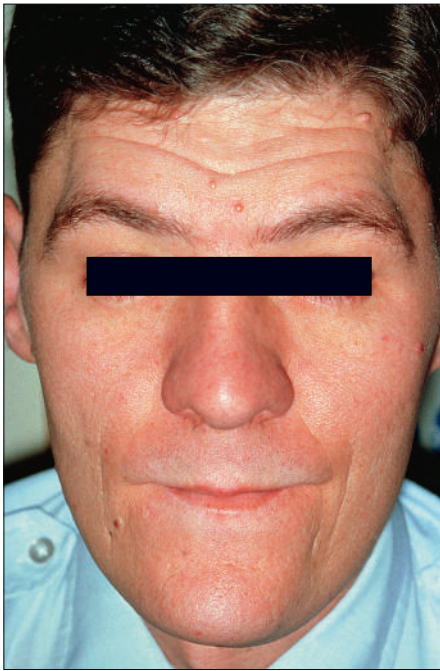
Bonus images for this chapter can be found online at

[expertconsult.inkling.com](http://expertconsult.inkling.com)

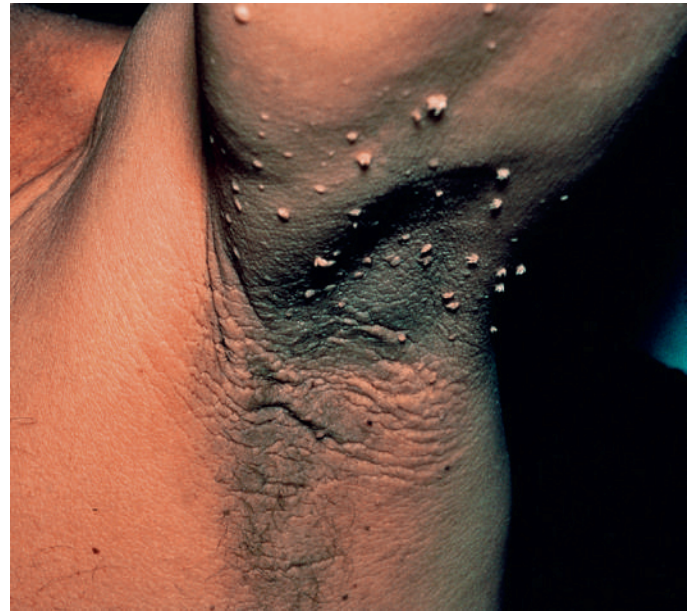**eFig. 24-1** Acromegaly.

**eFig. 24-2** Pretibial myxedema. (Courtesy of Lawrence Lieblisch, MD.)

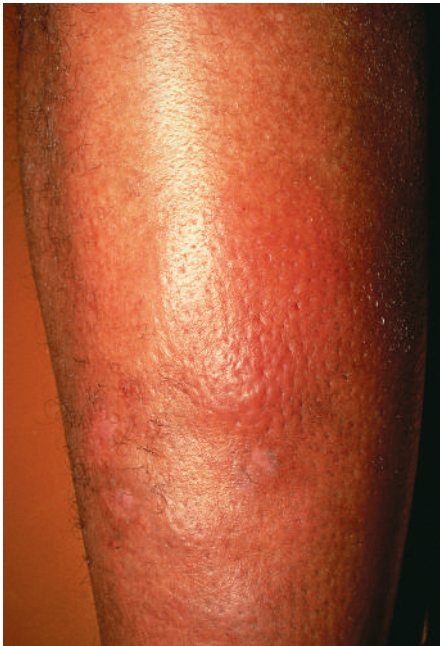**eFig. 24-3** Acanthosis nigricans.



**eFig. 24-1** Acromegaly.



**eFig. 24-3** Acanthosis nigricans.



**eFig. 24-2** Pretibial myxedema. (Courtesy of Lawrence Lieblich, MD.)



# 25

## Abnormalities of Dermal Fibrous and Elastic Tissue

### COLLAGEN

Many types of collagen have been identified in tissues of vertebrates (Table 25-1). Fibrillar collagens (types I, II, III, V, and XI) form fibrils that are among the most abundant proteins in the body. Type I collagen accounts for 60–90% of the dry weight of skin, ligaments, and demineralized bone. Type III collagen is abundant in fetal skin and blood vessels. It comprises 35% of the collagen in normal adult skin, but up to 40% in inflamed skin in the setting of contact dermatitis. Basement membrane-associated collagen is made up of types IV and VII. Fiber-associated collagens (types VIII, IX, and XIV) are found on the surface of type I and II collagens and are believed to serve as flexible spacers among fibrils. Fibril-associated collagens with interrupted triple helices (FACITs) do not form fibrils themselves but are found attached to the surfaces of preexisting fibrils of the fibril-forming collagens. FACITs are composed of types IX, XII, XIV, XVI, XIX, XX, and XXI. Network-forming collagens are sheets formed from types VIII and X. Studies on types XV, XVII, and XIX demonstrate their widespread presence in basement membranes, particularly vascular endothelium, which may represent a new subgroup of collagens associated with angiogenic and pathologic processes. Type XVII collagen is also known as BP180, and contains the target antigens for several immunobullous diseases. Type VII collagen contains the target antigens for bullous lupus and epidermolysis bullosa acquisita. Type II collagen contains the target antigens for relapsing polychondritis.

The regulation of collagen synthesis and degradation is complex. Dermal fibrosis is largely related to increases in type I collagen mediated by  $\text{pro}\alpha 1$  and  $\text{pro}\alpha 2$  collagen genes. Transforming growth factor beta (TGF- $\beta$ ) results in increased type I procollagen synthesis. Angiotensin II type 1 receptor stimulation increases collagen production and inhibits collagen degradation, whereas type 2 receptor stimulation exerts the reverse effects.

**Czarny-Ratajczak M, et al:** Collagens, the basic proteins of the human body. *J Appl Genet* 2000; 41:317.

### ELASTOSIS PERFORANS SERPIGINOSA

In 1953, Lutz described a chronic papular keratotic eruption in an arciform shape located on the sides of the nape of the neck (Fig. 25-1). The papules range from 2 to 5 mm in diameter and are grouped in a serpiginous or horseshoe-shaped arrangement. Although the lesions typically occur on the neck, other sites may be involved, such as the upper arms, face, lower extremities, and rarely the trunk. Disseminated lesions may occur in Down syndrome. Elastosis perforans serpiginosa (EPS) is most common in young adults. Men outnumber women 4:1. The disease runs a variable course, with

spontaneous resolution often occurring from 6 months to 5 years after onset. Often, atrophic scarring remains.

Approximately one third of EPS cases occur in patients with associated diseases; the most common concomitant disorder is Down syndrome. Approximately 1% of patients with Down syndrome have EPS, and the lesions are likely to be more extensive and persistent than in other patients. Progressive vaso-occlusive disease with stroke has been reported. Ehlers-Danlos syndrome, osteogenesis imperfecta, Marfan syndrome, Rothmund-Thomson syndrome, acrogeria, systemic sclerosis, morphea, XYY syndrome, and renal disease have also been associated with EPS. Reports of EPS associated with pseudo-xanthoma elasticum have occurred with penicillamine administration. Evaluation for associated disease should be driven by associated signs and symptoms.

The distinctive histopathologic changes of EPS consist of elongated, tortuous channels in the epidermis into which eosinophilic elastic fibers perforate. The fibers are extruded from the dermis. There is degeneration and alteration of the elastic tissue in the adjacent papillary dermis with an accompanying inflammatory response. In penicillamine-associated disease, the fibers may have an irregular (bramble bush) contour when examined with electron microscopy.

Treatment of EPS is difficult, but individual lesions may resolve following liquid nitrogen cryotherapy. Some cases have responded to carbon dioxide (CO<sub>2</sub>), erbium:yttrium-aluminum-garnet (Er:YAG), or pulsed dye laser therapy. Topical retinoids have been reported to be of benefit.

**Kim SW, et al:** A clinicopathologic study of thirty cases of acquired perforating dermatosis in Korea. *Ann Dermatol* 2014; 26:162–171.

**Lee SH, et al:** Elastosis perforans serpiginosa. *Ann Dermatol* 2014; 26:103–106.

**Vearrier D, et al:** What is standard of care in the evaluation of elastosis perforans serpiginosa? A survey of pediatric dermatologists. *Pediatr Dermatol* 2006; 23(3):219–224.

**Yang JH, et al:** Treatment of elastosis perforans serpiginosa with the pinhole method using a carbon dioxide laser. *Dermatol Surg* 2011; 37(4):524–526.

### REACTIVE PERFORATING COLLAGENOSIS

In 1967, Mehregan reported a rare, familial, nonpruritic skin disorder characterized by papules that grow to a diameter of 4–6 mm and develop a central area of umbilication in which keratinous material is lodged. The discrete papules may be numerous and involve sites of frequent trauma, such as the backs of the hands, the forearms, elbows, and knees. The lesion reaches a maximum size of about 6 mm in 4 weeks and then regresses spontaneously in 6–8 weeks. The lesions are broader than those of EPS, and a broad crust containing collagen fibers is extruded centrally. Koebnerization is often observed. Young children are most frequently affected. Most reports support an autosomal recessive mode of inheritance, although apparent

Table 25-1 Collagen types

Collagen type	Gene*	Chromosome	Tissue distribution
I	<i>COL1A1-2</i>	17q21.3–q22	Skin, bone, tendon
I-trimer			Tumors, cell cultures, skin, liver
II	<i>COL2A1</i>	7q21.3–q22	Cartilage, vitreous
III	<i>COL3A1</i>	12q13–q14	Fetal skin, blood vessels, intestines
IV	<i>COL4A1-6</i>	13q34, 2q35–q37, Xq22	Basement membranes
V	<i>COL5A1-3</i>	9q34.2–q34.3	Ubiquitous
VI	<i>COL6A1-3</i>	21q22.3, 2q37	Aortic intima, placenta
VII	<i>COL7A1</i>	3p21	Amnion, anchoring fibrils
VIII	<i>COL8A1-2</i>	3q12–q13.1, 1p32.3–p34.3	Endothelial cell cultures
IX	<i>COL9A1-3</i>	6q12–q14, 1p32	Cartilage, type II collagen tissue
X	<i>COL10A1</i>	6q12–q22	Cartilage
XI	<i>COL11A1-2, COL2A1</i>	1p21	Cartilage, skin
XII	<i>COL12A1</i>	6	Skin, cartilage, cornea, limbal
XIII	<i>COL13A1</i>	10q22	Ubiquitous
XIV	<i>COL14A1</i>	8q23	Ubiquitous, fetal hair follicles, basement membranes
XV	<i>COL15A1</i>	9q21–22	Skin hemidesmosomes, kidney, liver, spleen
XVI	<i>COL16A1</i>	1p34–35	Ubiquitous
XVII	<i>COL17A1</i>	10q24.3	Skin hemidesmosomes (BP180)
XVIII	<i>COL18A1</i>	21q22.3	Ubiquitous, basement membranes
XIX	<i>COL19A1</i>	6q12–q14	Ubiquitous, basement membranes
XX	<i>COL20A1</i>		Corneal epithelium, embryonic skin, sternal cartilage, tendon
XXI	<i>COL21A1</i>	6p11.2–12.3	Blood vessel walls
XXII	<i>COL22A1</i>	8q24.2	Tissue junctions such as basement membrane zone of anagen hair follicle
XXIII			Rat prostate carcinoma cells
XXIV			Fetal cornea and bone
XXV			Precursor to Alzheimer amyloid plaque component
XXVI			Testis, ovary
XXVII			Chondrocytes; developing tissues, including stomach, lung, gonad, skin, cochlea, teeth

\*A dash denotes a series of genes; e.g., *COL14A1-2* indicates both the *COL14A1* and the *COL14A2* gene.

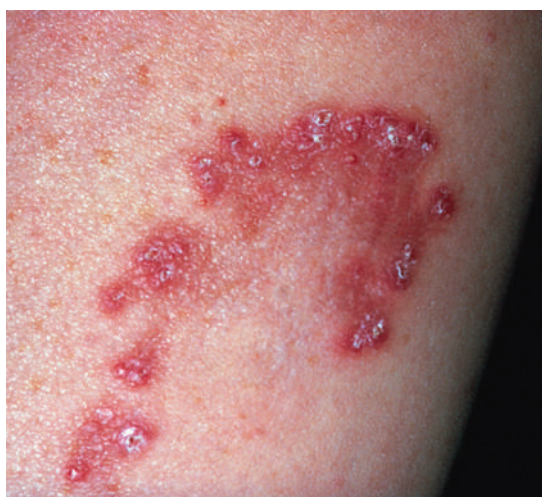

Fig. 25-1 Elastosis perforans serpiginosa.

autosomal dominant inheritance was reported in one family. Acquired reactive perforating collagenosis is discussed further in Chapter 33.

No specific treatment is typically indicated for reactive perforating collagenosis because the lesions involute spontaneously. Topical retinoids may be helpful in patients who require treatment.

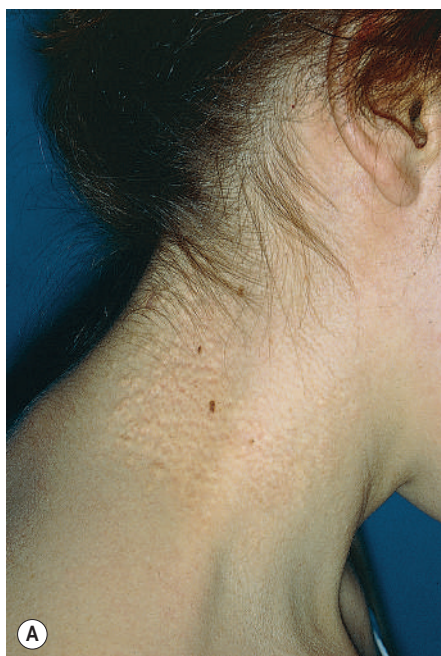**Kumar V, et al:** Familial reactive perforating collagenosis. *J Dermatol* 1998; 25:54–56.

**Ramesh V, et al:** Familial reactive perforating collagenosis: a clinical, histopathological study of 10 cases. *J Eur Acad Dermatol Venereol* 2007; 21(6):766–770.

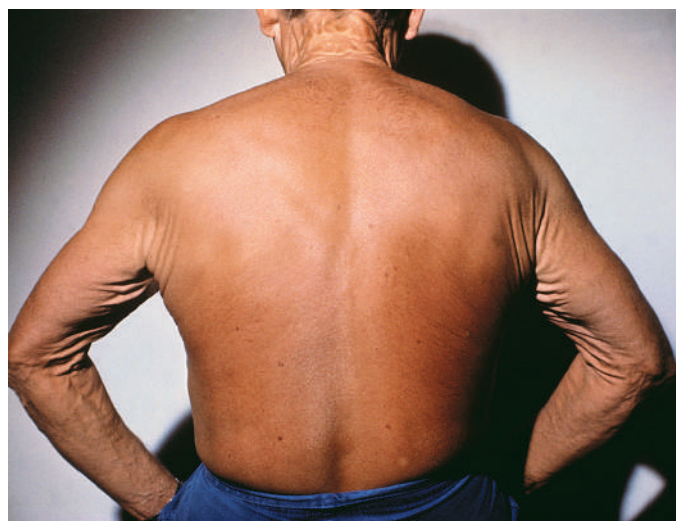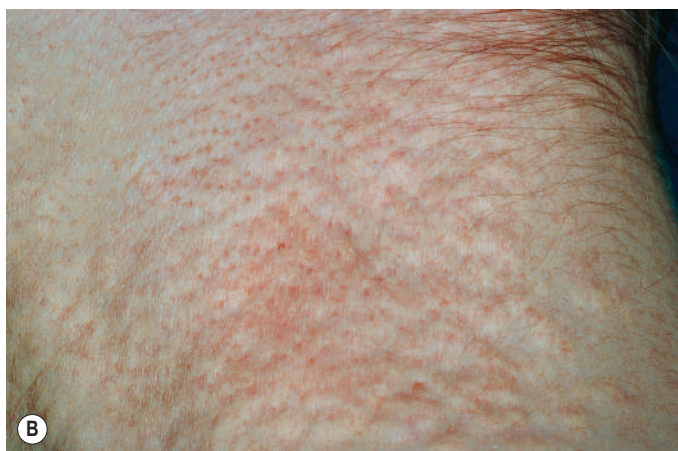## PSEUDOXANTHOMA ELASTICUM

Pseudoxanthoma elasticum (PXE) is an inherited disorder involving the connective tissue of the skin, eye, and cardiovascular system. Many cases appear to be sporadic. In familial





**Fig. 25-2** A and B, Pseudoxanthoma elasticum.



**Fig. 25-3** Pseudoxanthoma elasticum.

cases, both a recessive and a dominant inheritance pattern have been reported, with the recessive form apparently more common. The skin changes generally present as small, circumscribed, yellow to cream-colored papules on the sides of the neck and flexures, giving the skin a “plucked chicken skin” appearance (Fig. 25-2). Lax, redundant folds of skin may be present (Fig. 25-3). Nuchal comedones and milia en plaque may also be seen. Characteristic exaggerated nasolabial folds and mental creases are common. Mental creases appearing in patients under age 30 are highly suggestive of PXE. In addition, the inguinal, periumbilical, and periauricular skin, as well as the mucosa of the soft palate, inner lip, stomach, rectum, and vagina, may be involved.

The characteristic retinal change is the angioid streak, which is the result of breaks in Bruch’s elastic membrane. PXE can be demonstrated in more than half of patients with angioid streaks, and 85% of PXE patients will have retinal findings. The angioid streaks appear earlier than the skin changes, so most cases are discovered by ophthalmologists. Angioid streaks may be the only sign of the disease for years. In such patients, biopsies of the midportions of old scars may be diagnostic of PXE. The association of the skin lesions with angioid streaks is called Grönblad-Strandberg syndrome. Angioid streaks may also be seen in Ehlers-Danlos syndrome, Paget’s disease of bone, diabetes, hemochromatosis, hemolytic anemia,

hypercalcinosis, solar elastosis, neurofibromatosis, Sturge-Weber syndrome, tuberous sclerosis, myopia, sickle cell anemia, trauma, lead poisoning, hyperphosphatemia, pituitary disorders, and intracranial disorders. PXE, Paget’s disease of the bone, and sickle cell disease account for the vast majority of patients with angioid streaks.

On funduscopic examination, a reddish brown band is evident around the optic disk, from which glistening streaks extend. On fluorescent photography, early fluorescence of the angioid streaks and macular lesions is noted. In addition, there may be hemorrhages and exudates. Progressive loss of vision often starts after minor trauma to the eye. Drusenlike spots are often present and show increased autofluorescence, unlike age-related drusen.

Vascular involvement frequently leads to hemorrhage. These vascular events are caused by the degeneration of the elastic fibers in the vascular media. Gastric hemorrhage occurs in 10% of patients, and on gastroscopy, diffuse rather than focal bleeding is common. Epistaxis occurs frequently, but hematuria is rare. PXE affects the elastic tissue of the cardiac valves, myocardium, and pericardium. In one study, mitral valve prolapse was found in 71% of 14 patients examined. Hypertension occurs in many patients older than age 30. Any patient with hypertension at a young age should be examined for stigmata of PXE. Leg cramps and intermittent claudication occur prematurely, and peripheral pulses are diminished or absent. Calcification of peripheral arteries is seen in many patients over age 30 and may be detected by radiography. Accelerated coronary artery disease (CAD) can occur, especially in association with hypertension. Extensive cutaneous calcification and renal and testicular stones may occur.

Mutations in the adenosine triphosphate (ATP)-binding cassette transporter protein subfamily C member 6 gene (*ABCC6*) on the short arm of chromosome 16 have been implicated in the pathogenesis of PXE in a majority of patients, who also have a higher incidence of CAD. Although the most prominent manifestations of the disease are in the skin, eye, gut, and heart, mineralization of elastic fibers can be found in many organs.

Histologically, elastic fibers are fragmented and mineralized with calcium. The fibers stain gray-blue with hematoxylin and eosin (H&E) and are twisted, curled, and broken, suggesting “raveled wool.” Blind biopsies of scars or axillary skin in patients with a family history of PXE or with angioid streaks may show early changes of PXE. Calcium stains are helpful in identifying early disease.

The differential diagnosis includes PXE-like papillary dermal elastolysis, perforating calcific elastosis, and cutis laxa. Patients with PXE-like papillary dermal elastolysis may have cobblestoned, yellow papules on the neck, similar to PXE, but lack any retinal or vascular alterations and the typical fragmentation of elastic fibers with calcium deposition on histology. Penicillamine may induce similar clinicohistologic features in patients with Wilson's disease or homocystinuria.

No definitive therapy is available to treat the skin disease. Some data suggest that PXE patients benefit from limiting dietary calcium and phosphorus to the minimal daily requirement. Intravitreal bevacizumab has been used to treat choroidal neovascularization. Atorvastatin treatment appears promising in a mouse model.

**Finger RP, et al:** Intravitreal bevacizumab for choroidal neovascularisation associated with pseudoxanthoma elasticum. *Br J Ophthalmol* 2008; 92(4):483–487.

**Guo H, et al:** Atorvastatin counteracts aberrant soft tissue mineralization in a mouse model of pseudoxanthoma elasticum (*Abcc6*<sup>-/-</sup>). *J Mol Med (Berl)* 2013; 91(10):1177–1184.

**Hendig D, et al:** New insights into the pathogenesis of pseudoxanthoma elasticum and related soft tissue calcification disorders by identifying genetic interactions and modifiers. *Front Genet* 2013; 4:114.

**Plomp AS, et al:** Proposal for updating the pseudoxanthoma elasticum classification system and a review of the clinical findings. *Am J Med Genet* 2010; 152A(4):1049–1058.

**Uitto J, et al:** Pseudoxanthoma elasticum: diagnostic features, classification, and treatment options. *Expert Opin Orphan Drugs* 2014; 2:567–577.

## PERFORATING CALCIFIC ELASTOSIS

Also known as periumbilical perforating PXE and localized acquired cutaneous PXE, perforating calcific elastosis is an acquired, localized cutaneous disorder most frequently found in obese, multiparous, middle-age women. Lax, well-circumscribed, reticulated, or cobblestoned plaques occur in the periumbilical region with keratotic surface papules. It is a distinct disorder that shares some features of PXE. As in PXE, patients may have calcific elastosis in the middermis; however, hereditary PXE rarely causes perforating channels. None of the systemic features of PXE occurs in perforating calcific elastosis.

It is suggested that repeated trauma of pregnancy, obesity, and abdominal surgery promote elastic fiber degeneration, resulting in localized disease. PXE can cause periumbilical lesions, and in the absence of documented perforation, evaluations to exclude PXE should be performed. There is no effective therapy for perforating calcific elastosis.

**Budania A, et al:** Periumbilical perforating pseudoxanthoma elasticum: an acquired perforating disorder. *Int J Dermatol* 2012; 51(4):439–441.

## EHLERS-DANLOS SYNDROMES

Ehlers-Danlos syndromes (EDSs), also known as cutis hyperelastica, India rubber skin, and elastic skin, are a group of genetically distinct connective tissue disorders characterized by excessive stretchability and fragility of the skin (Fig. 25-4), with hyperextensibility of the joints (Fig. 25-5) and a tendency toward easy scar formation and formation of fibrous or calcified pseudotumors. Atrophic scarring on the distal fingers and wide atrophic “fish-mouth” scars are typical. Patients demonstrate reduced thickness of the dermis, as determined by high-resolution 20 MHz ultrasound. The reduction in thickness is most marked on the chest and distal lower leg. Rare oral manifestations have been reported, including supernumerary teeth and odontogenic keratocysts.

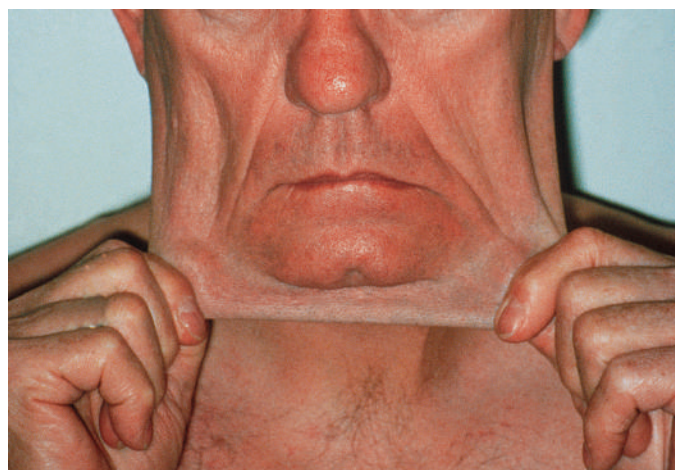

Fig. 25-4 Ehlers-Danlos syndrome.

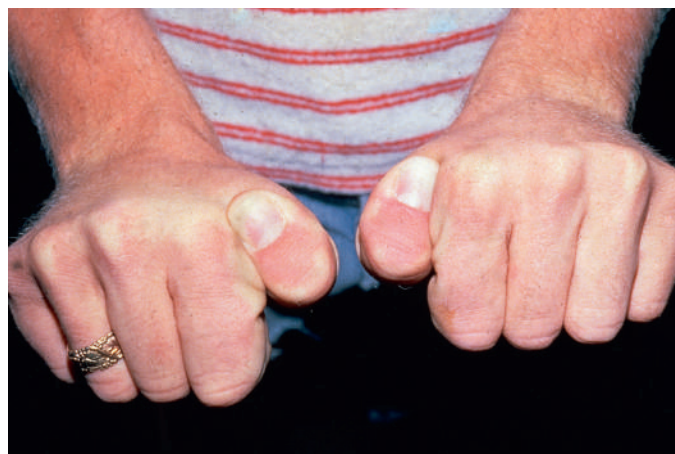

Fig. 25-5 Ehlers-Danlos syndrome, hyperextensible joints.

Classically, EDS has been divided into 10 numeric types, the salient features of which are listed in Table 25-2. Type IX EDS, an allelic variant of Menkes disease, is now reclassified as the occipital horn syndrome and is identical to X-linked cutis laxa. It is related to mutations in an X-linked gene, *ATP7A*. Patients with types I, II, III, V, VII, and VIII EDS have hyperextensible skin; the integument may be stretched like a rubber band and snaps back with equal resilience. This rubbery skin is most pronounced on the elbows, neck, and sides of the abdomen. The skin is velvety in appearance and feels like wet chamois cloth. Minor trauma may produce a gaping “fish-mouth” wound with large hematomas underneath. The subcutaneous calcifications are 2–8 mm oval nodules, mostly on the legs. Two types of nodules occur in patients with EDS. Molluscoid pseudotumors are soft, fleshy nodules seen in easily traumatized areas such as the ulnar forearms and shins. Spheroids are hard subcutaneous nodules that become calcified and probably result from fat necrosis. Trauma over the shins, knees, hands, and elbows produces cigarette paper–thin scars. Approximately 50% of these patients can touch the tip of the nose with their tongue (Gorlin's sign), compared with 10% of persons without the disorder. Aortic root dilation is seen in up to 20% of patients with EDS and is more common in types I and II than type III.

Patients with type IV EDS have thin, translucent skin, characteristic facial features, and vascular fragility. They are prone to arterial rupture and often have extensive bruising. Perforations of the intestines and uterus may occur. Atlantoaxial



**Table 25-2** Features of Ehlers–Danlos syndromes (EDSs)

Ehlers-Danlos type	Gene	Inheritance*	Molecular abnormality	Clinical features
I	<i>COL5A1–2</i> <sup>†</sup>	AD	Type V collagen	Gravis type: joint laxity, skin hyperextensibility
II	<i>COL5A1–2</i>	AD	Type V collagen	Mitis type: same as EDS type I but less severe
III	<i>TNXB</i> haploid	AD	Unknown	Hypermobility
IV	<i>COL3A1</i>	AD AR	Type III procollagen	Thin skin, bruising, ruptured blood vessels and viscera
V			Unknown	Skin hyperextensibility, easy bruising
VI	<i>LH1, PLOD</i>	AR	Lysyl hydroxylase deficiency	Severe eye defects and scoliosis
VIIA, VIIB	<i>COL1A1–2</i>	AD	Type I procollagen	Arthrochalasia, subluxations, moderate skin stretchability
VIIC		AR	Procollagen peptidase deficiency	Dermatosparaxis, severe stretchability, redundant skin
VIII	Heterogeneous, only some map to chromosome 12p13	AD	Unknown	Same as EDS types I and II, periodontitis
Old-type IX, reclassified as a variant of Menkes disease/occipital horn syndrome	<i>ATP7A</i>	X-linked	Lysyl oxidase	Abnormal facies; skeletal abnormalities, including occipital horns, chronic diarrhea, and genitourinary abnormalities
X (new-type IX)		AR	Fibronectin	Bruising
Old-type XI (new-type X)			Familial joint hypermobility syndrome	Relationship to EDS unclear
Spondylocheirodysplastic	<i>SLC39A13</i>	AR		Hyperelastic bruisable skin, joint hypermobility, contractures, tapered digits, skeletal dysplasia

\*AD, Autosomal dominant; AR, autosomal recessive.  
<sup>†</sup>*COL5A1–2* indicates both the *COL5A1* and the *COL5A2* gene.

subluxation has been noted. Protein analysis of collagen III in cultured fibroblasts usually shows a defect. Some type IV patients demonstrate no abnormalities of collagen III, although a mutation in the *COL3A1* gene is identified. Type V patients have clinical features that are similar to the gravis/mitis form, and some data suggest that more than 90% of patients who satisfy all these major criteria for the disease harbor a type V collagen (COLLV) defect. Tenascin-X haploinsufficiency causes joint hypermobility and appears to be protective against cardiovascular disease.

Patients with type VI EDS may have microcornea, retinal detachment, and glaucoma, as well as scoliosis. In normal individuals, the ratio of hydroxylysylpyridinoline (HP) to lysylpyridinoline (LP) in urine is about 10:1. In patients with type VI EDS, the HP/LP ratio is reduced, ranging from 1:3 to 1:7. The spondylocheirodysplastic form is autosomal recessive and caused by mutations in the zinc transporter gene, *SLC39A13*. This form includes hyperelastic bruisable skin, joint hypermobility, contractures, protuberant eyes, bluish sclerae, short stature, finely wrinkled palms, thenar atrophy, and tapered digits. Skeletal dysplasia includes platyspondyly, osteopenia, and widened metaphyses. The urinary HP/LP ratio is approximately 1:1.

Patients with type VIIA and VIIB EDS have marked joint hypermobility and moderate cutaneous elasticity. Dislocation of the large joints, such as the hips, is common. Type VIIC EDS, the autosomal recessive form, is referred to as dermatosparaxis; patients have severe skin fragility and sagging,

redundant skin. Type VIII EDS manifests as periodontitis as well as easy bruising. Reductions of collagen type III alone or together with a reduction in type I have been reported. When type IX EDS was redefined as a variant of Menkes syndrome, some reclassified old-type X EDS as new-type IX. It is characterized by hypermobile joints, easy bruising, fish-mouth scars, mitral valve prolapse, and platelets resistant to aggregation with collagen and adenosine diphosphate (ADP) reagents. A qualitative deficiency of fibronectin was the suggested cause, although never confirmed. Since the deletion of old-type IX, some have reclassified old-type XI as new-type X, or the familial joint hypermobility syndrome.

Because of the discovery of new types and confusion about the numbered types, an alternate classification scheme has been proposed that groups EDS by associated signs and symptoms, as well as known genetic mutations. This new classification combines numeric types I and II because they share the same mutations (Box 25-1).

Collagen fibers may appear thin. Factor XIIIa-positive dermal dendrocytes may be greatly reduced in the adventitial dermis and almost absent in the reticular dermis.

Patients must be counseled to avoid trauma. Intestinal perforations in EDS type IV have been managed with porcine small intestine submucosal grafts. Unfortunately, invasive cardiovascular procedures have generally not improved outcomes for patients with severe disease. Matrix metalloproteinase (MMP) inhibitors produce changes in connective tissue and are being evaluated as possible therapeutic agents.

### Box 25-1 New classification for Ehlers-Danlos syndrome (EDS)

1. Classic type (gravis—EDS type I, and mitis II)\*
  2. Hypermobility type (hypermobility—EDS III)
  3. Vascular types (arterial-ecchymotic—EDS type IV, Qatari EDS)<sup>†</sup>
  4. Kyphoscoliosis type (ocular-scoliotic—EDS type VI)
  5. Arthrochalasia type (arthrochalasia multiplex congenita—EDS type VIIA and VIIB)
  6. Dermatosparaxis type (human dermatosparaxis—EDS type VIIC)
  7. Miscellaneous forms (X-linked—EDS type V, periodontitis; EDS type VIII, fibronectin-deficient EDS; EDS type X, familial hypermobility syndrome [formerly EDS type XI]; progeroid EDS; and unspecified forms).
- Some progeroid EDS is related to galactosyltransferase I deficiency.

\*Mutations in the genes for collagen  $\alpha 1(V)$  chain (*COL5A1*), collagen  $\alpha 2(V)$  chain (*COL5A2*), tenascin-X (*TNX*), and collagen  $\alpha 1(I)$  chain (*COL1A1*) have been characterized in patients with classical EDS. All are autosomal dominant, except the tenascin-X-related type, which is autosomal recessive.

<sup>†</sup>A distinct vascular type of EDS was described in an extended family in Qatar. Features of the syndrome include skin hyperextensibility, joint hypermobility, tortuous systemic arteries, epicanthic folds, flat saggy cheeks, elongated facies, micrognathia, hernias, an elongated aortic arch, aortic aneurysms, bifid pulmonary artery, pulmonary stenosis, hypotonia, and arterial rupture. Linkage to the major loci of other types of EDS was excluded.

**Bergqvist D, et al:** Treatment of vascular Ehlers-Danlos syndrome: a systematic review. *Ann Surg* 2013; 258(2):257–261.

**Callewaert B, et al:** Ehlers-Danlos syndromes and Marfan syndrome. *Best Pract Res Clin Rheumatol* 2008; 22(1):165–189.

**Malfait F, De Paepe A.** The Ehlers-Danlos syndrome. *Adv Exp Med Biol* 2014; 802:129–143.

**Müller T, et al:** Loss of dermatan sulfate epimerase (DSE) function results in musculocontractural Ehlers-Danlos syndrome. *Hum Mol Genet* 2013; 22(18):3761–3772.

**Petersen JW, et al:** Tenascin-X, collagen, and Ehlers-Danlos syndrome: tenascin-X gene defects can protect against adverse cardiovascular events. *Med Hypotheses* 2013; 81(3):443–447.

**Wiesmann T, et al:** Recommendations for anesthesia and perioperative management in patients with Ehlers-Danlos syndrome(s). *Orphanet J Rare Dis* 2014; 9:109.

## MARFAN SYNDROME

Marfan syndrome is an autosomal dominant disorder of connective tissue caused by mutations in the gene encoding fibrillin-1. It is one of the more common inherited diseases, with estimated incidence rates of 1 in 10,000 in the United States. Important abnormalities include tall stature, loose-jointedness, a dolichocephalic skull, high-arched palate, arachnodactyly (Fig. 25-6), pigeon breast, pes planus, poor muscle tone, and large, deformed ears. The aorta, chordae tendineae, and aortic and mitral valves are often involved. Ascending aortic aneurysm and mitral valve prolapse are frequently seen. Ectopia lentis, extensive striae over the hips and shoulders, dental anomalies, and rarely elastosis perforans serpiginosa have been reported. Several cases document the occasional occurrence of spontaneous pneumothorax and congenital lung abnormalities.

Marfan syndrome is caused by a gene defect localized to chromosome 15 and producing abnormal elastic tissue in fibrillin 1 (aorta adventitia, suspending ligaments of lens and skin) and fibrillin 2 (elastin orientation in cartilage, aortic

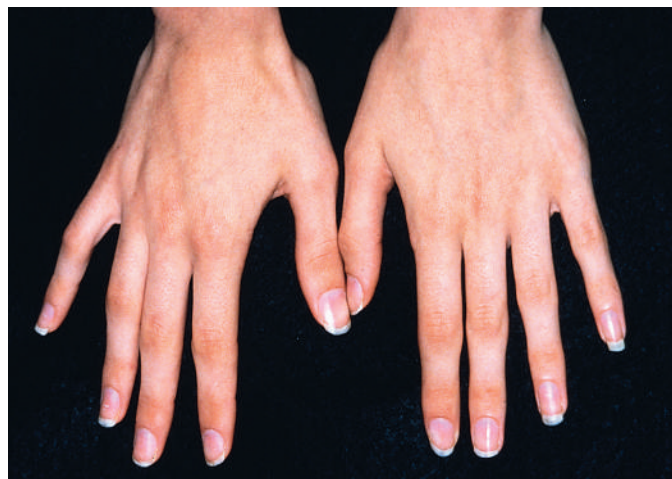

Fig. 25-6 Marfan syndrome.

media, bronchi, and all tissues rich in elastin). Gene defects include substitutions, deletions, duplication missense, frameshift, splice site, and nonsense mutations. Ectopia lentis is more common in patients whose mutations involve a cysteine substitution in the gene for fibrillin 1, and less prevalent in those with premature termination mutations. Death may result from aortic root aneurysm rupture or dissection.

Echocardiography is helpful for early detection of cardiovascular involvement. Surgical intervention may be required for aneurysms of the aortic root or for aortic dissection. Long-term administration of propranolol may significantly reduce the rate of aortic dilation, as does angiotensin II blockade with losartan. Long-term doxycycline may be helpful to inhibit MMPs. Some evidence suggests doxycycline may be more effective than atenolol in preventing progression of thoracic aortic aneurysms. Antisense ribozymes are promising for gene therapy.

**Brooke BS, et al:** Angiotensin II blockade and aortic-root dilation in Marfan's syndrome. *N Engl J Med* 2008; 358(26):2787–2795.

**Groenink M, et al:** Losartan reduces aortic dilatation rate in adults with Marfan syndrome: a randomized controlled trial. *Eur Heart J* 2013; 34(45):3491–3500.

## HOMOCYSTINURIA

Homocystinuria, an inborn error in the metabolism of methionine, is characterized by the presence of homocysteine in the urine and deficiency of the enzyme cystathionine synthase or methylenetetrahydrofolate reductase. Cystathionine  $\beta$ -synthase is a heme-containing enzyme that catalyzes pyridoxal 5'-phosphate-dependent conversion of serine and homocysteine to cystathionine. More than 130 gene mutations have been described. The defect results in increased levels of homocysteine and methionine and decreased levels of cysteine. The incidence of the disorder varies from 1 in 344,000 worldwide to 1 in 65,000 in Ireland, where homocystinuria is more common.

Signs of homocystinuria include ectopia lentis, genu valgum, kyphoscoliosis, pigeon breast deformity, and frequent fractures. Generalized osteoporosis, arterial and venous thrombosis, and mental retardation are features of homocystinuria not found in Marfan syndrome. Half of all patients will have a serious vascular event before age 30, and 25% experience a serious event before age 16. The facial skin has a characteristic flush, especially on the malar areas, and the color tends to become violaceous when the patient is reclining. Elsewhere, the skin is blotchy red, suggestive of livedo reticularis. The hair is typically fine, sparse, and blond, and the teeth are irregularly



aligned. Downward dislocation of the lens, unlike the upward displacement seen in Marfan syndrome, is a prominent feature.

Treatment with pyridoxine, folic acid, and vitamin B<sub>12</sub> produces variable results in homocystinuric patients. A methionine-restricted, cysteine-supplemented diet is generally recommended. Betaine supplementation has been shown to be effective. Wheat flour is rich in betaine, but the amounts ingested are smaller than those needed to treat the disease. Some recommend that methionine-free formulas be supplemented with 150 mg/dL of betaine. Alfalfa and bean sprouts contain ample homocysteine, and excessive amounts should be avoided. Other vegetables do not contain large amounts of homocysteine. Vitamin C ameliorates endothelial dysfunction, and the effect appears to be independent of homocysteine concentration. Some of the beneficial effects of folate are also independent of homocysteine reduction. In an animal model of homocystinuria, 5-methyltetrahydrofolate decreased mortality, but folic acid did not.

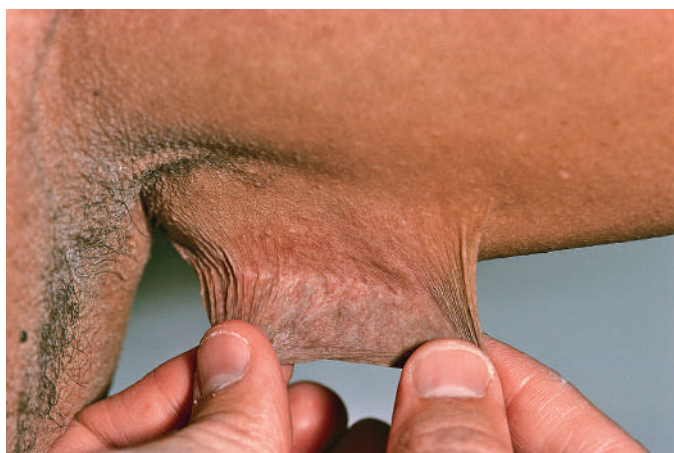**Li D, et al:** Mefolinate (5-methyltetrahydrofolate), but not folic acid, decreases mortality in an animal model of severe methylenetetrahydrofolate reductase deficiency. *J Inher Metab Dis* 2008; 31(3):403–411.

**Walter JH, et al:** Newborn screening for homocystinuria. *Cochrane Database Syst Rev* 2013; 8:CD008840.

## CUTIS LAXA (GENERALIZED ELASTOLYSIS)

Cutis laxa, also known as dermatomegaly, dermatolysis, chala-zoderma, and pachydermatocele, is characterized by inelastic loose, redundant skin. Around the eyelids, cheeks, and neck, the drooping skin produces a bloodhound-like facies. Usually, the entire integument is involved. The shoulder girdle skin may resemble that of a St. Bernard dog. The abdomen is frequently the site of large, pendulous folds. There are two well-described genetic forms of cutis laxa, the autosomal dominant and autosomal recessive types. The dominant form is primarily a cutaneous, cosmetic form, with a good prognosis. The recessive form is more common and associated with significant internal involvement, including hernias, diverticula, pulmonary emphysema, cor pulmonale, aortic aneurysm, dental caries, large fontanelles, and osteoporosis. Pulmonary emphysema, cor pulmonale, and right-sided heart failure are often seen already in infancy. Frameshift and splicing mutations in the elastin gene have been reported in autosomal dominant disease. Both homozygous and heterozygous missense mutations in the gene for fibulin 5 have been reported in some patients with the disease, especially in families with the recessive form. Gene mutations for fibulin 4 may cause autosomal recessive cutis laxa associated with emphysema, vascular tortuosity, ascending aortic aneurysm, inguinal and diaphragmatic hernia, joint laxity, and pectus excavatum. X-linked recessive cutis laxa is now known as the occipital horn syndrome (formerly type IX EDS). It is caused by a mutation in the copper-binding ion-transporting ATPase, *ATP7A*, and is allelic to another X-linked disorder, Menkes disease. Nonfamilial cases have been associated with urticaria, lupus erythematosus, glomerulonephritis, plasma cell dyscrasias, and systemic amyloidosis (Fig. 25-7). These acquired cases may have a preceding inflammatory phase with large numbers of interstitial neutrophils, eosinophils, or macrophages engulfing elastic fibers. Isolated acral disease has been associated with myeloma and rheumatoid arthritis.

The Costello syndrome is characterized by increased prenatal growth, postnatal growth retardation, coarse facies, loose skin that resembles cutis laxa, cardiomyopathy, and gregarious personality. Patients are predisposed to abdominal and pelvic rhabdomyosarcoma in childhood. The disorder appears



**Fig. 25-7** Acquired cutis laxa.

to be inherited as an autosomal dominant trait. The de Barys syndrome is associated with severe cutis laxa, mental and growth retardation, joint laxity, ocular abnormalities, and skeletal disease.

Middermal elastolysis is an acquired, noninherited condition that usually affects young women. Wide areas of skin demonstrate atrophic wrinkling. Histologically, elastic tissue is absent from the middle dermis. Many cases appear to be induced or aggravated by ultraviolet light exposure.

**Callewaert B, et al:** Comprehensive clinical and molecular analysis of 12 families with type 1 recessive cutis laxa. *Hum Mutat* 2013; 34(1):111–121.

**Mohamed M, et al:** Cutis laxa. *Adv Exp Med Biol* 2014; 802:161–184.

**Tas A, et al:** Oculoplastic approach to congenital cutis laxa syndrome. *Aesthetic Plast Surg* 2013; 37(2):417–420.

## BLEPHAROCHALASIS

In blepharochalasis, the eyelid skin becomes lax and falls in redundant folds over the lid margins. The condition may affect young adults, in whom a preceding inflammatory phase presents with episodes of lid swelling. Most cases are bilateral, but unilateral involvement may occur. Rarely, elastolysis of the earlobes may accompany blepharochalasis. It is generally sporadic, but a dominantly inherited form has been described. Biopsy shows lack of elastic fibers, and abundant IgA deposits have been demonstrated in some cases, possibly binding to fibulin and fibronectin. Sequelae include excess thin skin, fat herniation, lacrimal gland prolapse, ptosis, blepharophimosis, pseudoepicanthic fold, proptosis, conjunctival injection and cysts, entropion, and ectropion.

Ascher syndrome consists of progressive enlargement of the upper lip and blepharochalasis. The minor salivary glands of the affected areas are inflamed, resulting in superfluous folds of mucosa, giving the appearance of a double lip. There is a superficial resemblance to angioedema.

Treatment is generally by surgical correction, although successful medical treatment has been reported with systemic acetazolamide in combination with topical hydrocortisone cream. Doxycycline has also been reported as effective, presumably through MMP inhibition.

**Drummond SR, et al:** Successful medical treatment of blepharochalasis: a case series. *Orbit* 2009; 28(5):313–316.

**Karacnji T, et al:** Doxycycline for treatment of blepharochalasis via inhibition of matrix metalloproteinases. *Ophthalmol Plast Reconstr Surg* 2012; 28(3):e76–e78.

**Sacchidanand SA, et al:** Transcutaneous blepharoplasty in blepharochalasis. *J Cutan Aesthet Surg* 2012; 5(4):284–286.

## ANETODERMA (MACULAR ATROPHY)

Anetoderma is characterized by localized loss of elastic tissue resulting in herniation of subcutaneous tissue. The lesions protrude from the skin (Fig. 25-8) and on palpation have less resistance than the surrounding skin, producing the “button-hole” sign identical to a neurofibroma. The surface skin may be slightly shiny, white, and crinkly. The usual locations are the trunk, especially on the shoulders, the upper arms, and thighs. The intervening skin is normal.

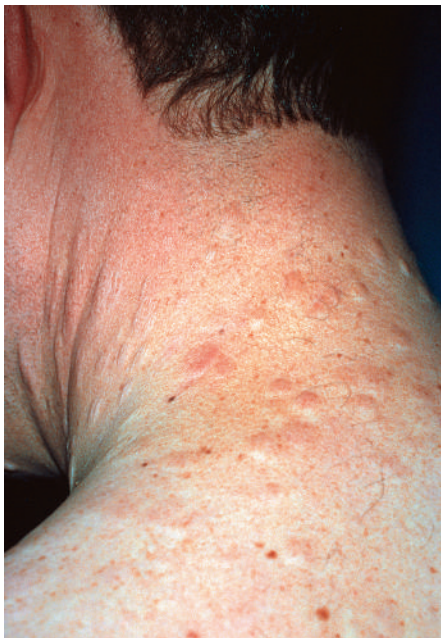Up to half of patients with anetoderma have an accompanying abnormality, such as lupus, antiphospholipid antibodies, Graves’ disease, scleroderma, hypocomplementemia, hypergammaglobulinemia, autoimmune hemolysis, or human immunodeficiency virus (HIV) infection. Screening for antiphospholipid antibodies is of particular importance because these may produce a prothrombotic state, and some patients fulfill criteria for the antiphospholipid syndrome. The antibodies may be detected as anticardiolipin antibodies, anti- $\beta$ 2-glycoprotein-I antibodies, or a lupus anticoagulant. Patients may experience recurrent fetal loss, recurrent strokes, or recurrent deep vein thrombosis. Thrombosis-associated anetoderma with ulceration has been related to antithrombin III deficiency. Some cases of anetoderma may be related to borreliosis. Rare familial cases have been noted. Secondary anetoderma may be associated with previous lesions of acne, secondary syphilis, measles, lupus erythematosus, Hansen’s disease, sarcoidosis, tuberous xanthoma, varicella, granuloma annulare, mastocytosis, and lymphoreticular malignancy.

Anetoderma of prematurity (congenital anetoderma) occurs in premature infants and may be related to pressure, adhesives, or changes in flow of ions or water under monitor leads. Intrauterine borreliosis has also been implicated.

Histologically, loss of elastic tissue is noted with special stains. In the late stage, the skin looks normal in H&E sections. In the acute stage, a neutrophilic, lymphoid, or granulomatous response may be noted. Ablative laser treatment has been reported as helpful in some patients with anetoderma.

**Clark ER, et al:** Thrombosis-induced ulcerations of the lower legs with coexistent anetoderma due to anti-thrombin III deficiency. *J Am Acad Dermatol* 2011; 65(4):880–881.

**Emer J, et al:** Generalized anetoderma after intravenous penicillin therapy for secondary syphilis in an HIV patient. *J Clin Aesthet Dermatol* 2013; 6(8):23–28.



**Fig. 25-8** Anetoderma.

**Haider M, et al:** Lupus erythematosus-associated primary and secondary anetoderma. *J Cutan Med Surg* 2012; 16(1):64–67.

**Hodak E, et al:** Primary anetoderma and antiphospholipid antibodies: review of the literature. *Clin Rev Allergy Immunol* 2007; 32(2):162–166.

## STRIAE DISTENSAE

Striae distensae are depressed lines or bands of thin, reddened skin, which later become white, smooth, shiny, and depressed. Elastotic striae have a yellow-gold iridescent appearance. Striae occur in response to changes in weight or muscle mass and skin tension, such as that induced by weightlifting. They are common on the abdomen during and after pregnancy (striae gravidarum) and on the breasts after lactation. They also occur on the buttocks and thighs, the inguinal areas, and over the knees and elbows in children during the growth spurt of puberty. Cushing syndrome, either endogenous or induced by systemic corticosteroid treatment, is a frequent cause of striae, and they may occur after application of potent topical corticosteroid preparations, especially under occlusion or in folds. Striae are common in patients with Marfan syndrome.

The histologic findings are variable and depend on the stage of development. In some early lesions, perivascular and interstitial infiltration of lymphocytes and sometimes eosinophils is noted. In older lesions, the primary changes are in the connective tissue. The collagen of the upper dermis is decreased, and thin collagen bundles lie parallel to the overlying epidermis, as in a scar. Elastic tissue often appears increased, but this may result from a loss of collagen in many cases. Dilated upper dermal vessels may be prominent.

A Cochrane review found no high-quality evidence to support the use of any topical preparation for the prevention of stretch marks during pregnancy. Over time, striae become less noticeable without treatment. Both silicone gel and placebo have demonstrated some positive effects in clinical studies, complicating interpretation of results. Topical tretinoin and vascular lasers may produce some improvement in appearance, although the benefits are more marked in the early erythematous phase. Pulsed dye lasers (585 nm) result in a moderate decrease in erythema in striae rubra. Although the total collagen per gram of dry weight increases in striae treated with pulsed dye laser, this change may not result in a clinically evident change in striae alba. Pulsed dye laser has also been used in conjunction with a radiofrequency device. Intense pulsed light has also demonstrated potential for improvement in the appearance of some striae, although with greater risk and lower efficacy in darker skin types. Some data suggest that 590-nm light is more effective than 650-nm light. Fractional photothermolysis has been used in a variety of skin types for both rubra and alba types of striae.

**Al-Dhalimi MA, et al:** A comparative study of the effectiveness of intense pulsed light wavelengths (650 nm vs 590 nm) in the treatment of striae distensae. *J Cosmet Laser Ther* 2013; 15(3):120–125.

**Brennan M, et al:** Topical preparations for preventing stretch marks in pregnancy. *Cochrane Database Syst Rev* 2012; 11:CD000066.

**Chantes A, et al:** Clinical improvement of striae distensae in Korean patients using a combination of fractionated microneedle radiofrequency and fractional carbon dioxide laser. *Dermatol Surg* 2014; 40:699.

**Kim BJ, et al:** Fractional photothermolysis for the treatment of striae distensae in Asian skin. *Am J Clin Dermatol* 2008; 9(1):33–37.

**Naeini FF, et al:** Comparison of the fractional CO<sub>2</sub> laser and the combined use of a pulsed dye laser with fractional CO<sub>2</sub> laser in striae alba treatment. *Adv Biomed Res* 2014; 3:184.

**Ud-Din S, et al:** A double-blind controlled clinical trial assessing the effect of topical gels on striae distensae (stretch marks): a non-invasive imaging, morphological and immunohistochemical study. *Arch Dermatol Res* 2013; 305(7):603–617.





**Fig. 25-9** Linear focal elastosis on lower back of elderly man.

### LINEAR FOCAL ELASTOSIS (ELASTOTIC STRIAE)

This elastosis variant presents with asymptomatic, palpable, or atrophic, yellow lines of the middle and lower back, thighs, arms, and breasts (Fig. 25-9). Linear focal elastosis is more common in males. Histologically, increased elastic fibers are seen, characterized by thin, wavy, and elongated as well as fragmented bundles. Electron microscopy reveals thin, elongated, irregularly shaped, swollen elastic fibers with degenerative changes.

**Pui JC, et al:** Linear focal elastosis: histopathologic diagnosis of an uncommon dermal elastosis. *J Drugs Dermatol* 2003; 2:79–83.

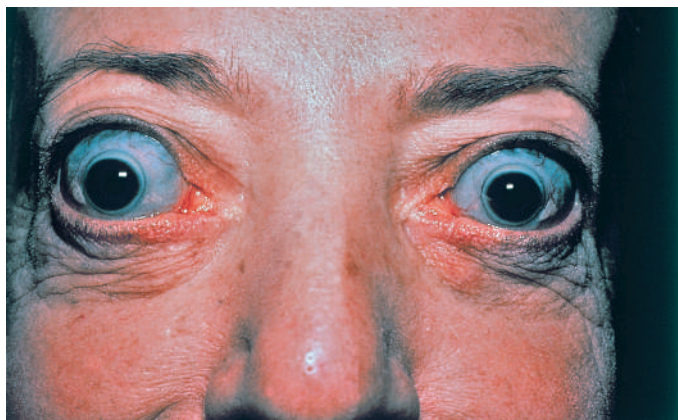### ACRODERMATITIS CHRONICA ATROPHICANS

Patients with acrodermatitis chronica atrophicans present with diffuse thinning of the skin on the extremities, sometimes associated with fibrous bands. This condition is reviewed with bacterial infections in Chapter 14, since it results from *Borrelia* infection.

### OSTEOGENESIS IMPERFECTA

Osteogenesis imperfecta (OI), also known as Lobstein syndrome, affects the bones, joints, eyes, ears, and skin. It is estimated to affect approximately 10,000 persons in the United States (4–5 in 100,000 population). There are seven recognized forms based on differences in clinical presentation and bone architecture. Types I and IV have only an autosomal dominant inheritance, whereas types II and III have both autosomal dominant and autosomal recessive forms. Fifty percent of OI patients have the type I form. The type II form is lethal, and deaths usually occur within the first week of life.

The brittle bones result from a defect in the collagenous matrix. Fractures occur early in life, sometimes in utero. Loose-jointedness may be striking, and dislocation of joints can be a problem. Blue sclerae, when present, are a valuable diagnostic clue (Fig. 25-10). Scoliosis and defective teeth may be present. Deafness develops in many patients by the second decade of life and is audiotologically indistinguishable from otosclerosis. The skin is thin and translucent, and healing wounds result in spreading atrophic scars. Elastosis perforans serpiginosa may occur. Some patients experience unusual bruiseability, probably from a structural defect in either the blood vessel wall or the supporting dermal connective tissue.



**Fig. 25-10** Blue sclerae of osteogenesis imperfecta in patient with Graves' disease. (Courtesy of Lawrence Lieblich, MD.)

The basic defect is abnormal collagen synthesis, resulting in type I collagen of abnormal structure. Most forms of OI result from mutations in the genes for the pro $\alpha$ 1 or pro $\alpha$ 2 chains of type I collagen. Types V, VI, and VII are not associated with type I collagen gene defects. In type I (blue scleral dominant) there is diminished type I collagen with a mutation of *COL1A1* gene; in type II (perinatal lethal) there is diminished type I collagen synthesis and decreased integrity of the helical domain of the  $\alpha$ 1(I) gene; in type III (progressive deforming) there is delayed secretion of type I collagen with altered mannosylation; and in type IV (white sclerae dominant) there is a defective pro $\alpha$ 1(I) gene. A distinct subset of type IV with clinical improvement over time has been mapped to chromosome 11q.

The major causes of death attributed to OI are respiratory failure secondary to severe kyphoscoliosis and head trauma, mostly observed in type III disease. Aortic dissection has also been described. Patients with type I and type IV disease have a normal life span. Brack syndrome is a combination of OI and arthrogyposis multiplex.

Treatment includes surgical intervention, such as intramedullary stabilization. Bisphosphonates and calcitriol are the most effective pharmacologic agents. Specifically, cyclic pamidronate therapy has been shown to suppress bone turnover, reduce bone pain and fracture incidence, and increase bone density and level of ambulation. Gene therapy is promising but is complicated by the genetic heterogeneity of the disease. Most of the OI mutations result in a mutant allele product that interferes with the function of the normal allele. This sort of abnormality presents greater challenges for gene therapy than simple replacement of a missing enzyme, but gene and stem cell transfer research is ongoing.

**Alcausin MB, et al:** Intravenous pamidronate treatment in children with moderate-to-severe osteogenesis imperfecta started under three years of age. *Horm Res Paediatr* 2013; 79(6):333–340.

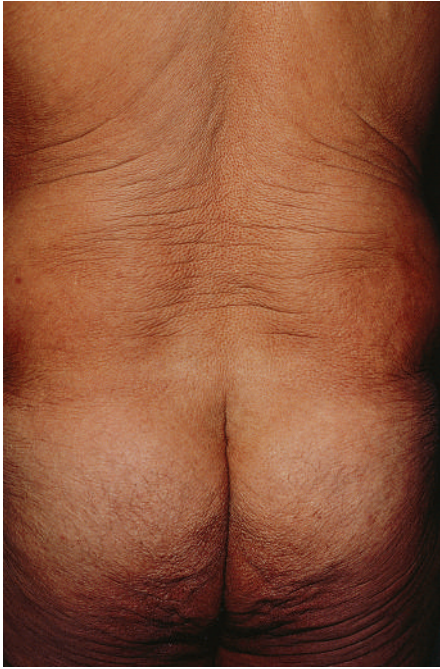**Ben Amor M, et al:** Osteogenesis imperfecta. *Pediatr Endocrinol Rev* 2013; 10(Suppl 2):397–405.

**Zhang Z, et al:** Phenotype and genotype analysis of Chinese patients with osteogenesis imperfecta type V. *PLoS One* 2013; 8(8):e72337.



Bonus images for this chapter can be found online at  
**expertconsult.inkling.com**

**eFig. 25-1** Cutis laxa.



**eFig. 25-1** Cutis laxa.



### AMYLOIDOSIS

Amyloid is a material deposited in the skin and other organs that is eosinophilic, homogeneous, and hyaline in appearance. It represents beta-pleated sheet forms of various host-synthesized molecules processed into this configuration by host cells.

Amyloidosis can be classified as systemic, localized, and hereditary types. The systemic types can deposit amyloid in multiple organs, and all are related to an overproduction of a host protein that cannot be adequately excreted or metabolized by the host. The excess protein is metabolized into amyloid precursors that interact with tissue proteoglycans/glycosaminoglycans, forming soluble amyloid oligomers. These oligomers complex with serum amyloid P (SAP), forming amyloid deposits in the affected organ. In all forms of amyloid, the pattern of deposition is characteristic, although there can be overlap between various forms. The diagnosis of a specific type of amyloid should only be made if the clinical features are characteristic and if the deposited protein is identified histochemically. Primary localized amyloidosis (also called primary cutaneous amyloidosis when the skin is affected) is very common and of importance to the dermatologist. Rare familial syndromes may be complicated by secondary systemic amyloidosis or may have genetic defects that lead to amyloid deposition (hereditary amyloidosis). Classification of cutaneous amyloidoses is as follows.

- I. Systemic amyloidosis
  - A. Primary (myeloma-associated) systemic amyloidosis
  - B. Secondary systemic amyloidosis
  - C. Dialysis-related amyloidosis
  - D. Senile systemic amyloidosis
- II. Cutaneous amyloidosis
  - A. Macular amyloidosis
  - B. Lichen amyloidosis
  - C. Nodular amyloidosis
  - D. Secondary (tumor-associated) cutaneous amyloidosis
  - E. Familial primary cutaneous amyloidosis
  - F. Pharmaceutical amyloidosis
- III. Hereditary amyloidosis

All forms of amyloid have relatively identical histologic and electron microscopic findings. The amyloid in all forms is made up of three distinct components: protein-derived amyloid fibers, amyloid P component (about 15% of amyloid), and ground substance. The protein-derived amyloid fibers are those that differ among the various forms of amyloid.

Amyloid is weakly periodic acid-Schiff (PAS) positive and diastase resistant, Congo red positive, purple with crystal violet, and positive with thioflavin T. Amyloid stained with Congo red exhibits apple-green birefringence under polarized light. Secondary systemic amyloid (AA amyloid) loses its

birefringence after treatment with potassium permanganate, whereas primary and localized cutaneous forms do not.

Amyloid stains an intense, bright orange with cotton dyes such as Dylon, Pagoda red, RIT Scarlet No. 5, or RIT Cardinal red No. 9. Ultrastructurally, amyloid has a characteristic fibrillar structure that consists of straight, nonbranching, nonanastomosing, often irregularly arranged filaments 60–100 nm in diameter. In most cases, specific antibodies against the protein component should be used to confirm the type of amyloidosis. Because amyloid substance P is present in all forms of amyloid, immunoperoxidase staining against this component will stain all forms of amyloid. In addition, since SAP is avidly bound to amyloid, radiolabeled, highly purified SAP can be used to localize amyloidosis, determine the extent of organ infiltration, study progression of disease, and determine if therapy reduces the amount of amyloid in various organs. Special centers have the capability of doing body scans (radiolabeled SAP scintigraphy) and have the reagents to identify the specific amyloid proteins immunohistochemically. In atypical cases, consulting such centers may be warranted.

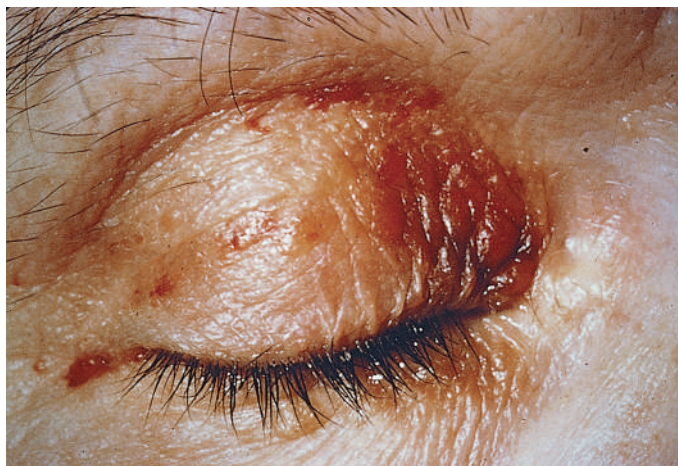### SYSTEMIC AMYLOIDOSES

#### Primary systemic amyloidosis (AL amyloidosis)

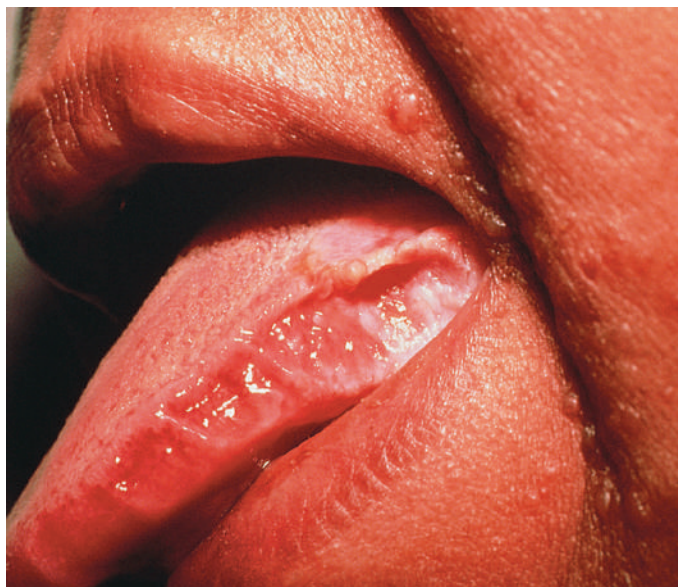Primary systemic amyloidosis typically involves the kidneys, liver, heart, gastrointestinal (GI) tract or peripheral nerve tissue, and skin. Myeloma-associated amyloidosis is included in this category. The amyloid fibril proteins in primary systemic amyloidosis are composed of the protein AL amyloid, a portion of the immunoglobulin (Ig) light chain. It is usually of the lambda ( $\lambda$ ) subtype, and certain germline Ig light-chain V chains (6aV $\lambda$ VI and 3rV $\lambda$ III) are responsible for AL amyloidosis in 40% of patients. About 90% of patients will have the Ig fragment detectable in the serum or urine; in the other 10%, the serum free light-chain assay will detect a clear excess of one of the light chains ( $\kappa$  or  $\lambda$ ), confirming the diagnosis. Also, reduction of the urine free light chains by more than 50% correlates with substantial benefit from treatment.

Cutaneous manifestations occur in approximately 40% of patients with primary systemic amyloidosis. The cutaneous eruption usually begins as shiny, smooth, firm, flat-topped, or spherical papules of waxy color that have the appearance of translucent vesicles. These lesions coalesce to form nodules and plaques of various sizes and, in some cases, bandlike lesions. The regions around the eyes, nose, mouth, and mucocutaneous junctions are frequently involved (Fig. 26-1). Vulvar lesions may resemble giant condylomata. Lesions may also be uniform small papules resembling milia or even lymphangioma. Follicular plugging may occur, resulting in milia.

Purpuric lesions and ecchymoses occur in about 15% of patients and are the most common cutaneous manifestation of



**Fig. 26-1** Systemic amyloidosis.



**Fig. 26-2** Macroglossia and translucent papules in amyloidosis. (Courtesy of Lawrence Lieblich, MD.)

primary systemic amyloidosis. There are several mechanisms by which AL amyloid leads to purpura. Amyloid may infiltrate blood vessels, making them fragile. AL amyloid may also bind factor X, contributing to the purpura. Lastly, amyloid infiltration of the liver may lead to reduced production of fibrinogen and factor X, adversely affecting clotting. Purpura chiefly involves the eyelids, limbs, and oral cavity. It typically occurs after trauma (pinch purpura) and can be reproduced by the physician by rubbing a pen or dull instrument over the skin, analogous to trying to demonstrate dermatographism. Purpuric lesions also classically appear after actions or procedures that result in increased pressure in the vessels of the face, such as after vomiting, coughing, proctoscopic examination, or pulmonary function testing.

Glossitis, with macroglossia, occurs in at least 20% of patients, may be an early symptom, and can lead to dysphagia. The tongue becomes greatly enlarged, and furrows develop (Fig. 26-2). The lateral aspects show indentations from the teeth. Papules or nodules, sometimes with hemorrhage, occur on the tongue.

Bullous amyloidosis is a rare but important clinical manifestation of amyloidosis. Skin fragility and tense, hemorrhagic or clear, noninflammatory bullae appear at areas of trauma,

usually the hands, forearms, and feet. Lesions heal with scarring and milia. The esophagus and oropharyngeal mucosae may also be involved. Histologically, the lesions are subepidermal and pauci-inflammatory. Epidermolysis bullosa acquisita and porphyria cutanea tarda are the differential diagnoses. Amyloid staining may yield negative results, and direct immunofluorescence (DIF) may be falsely positive because of AL protein deposition at the dermoepidermal junction (DEJ). The diagnosis is confirmed by evaluation of the patient's serum and urine for Ig fragments and by amyloid stains or electron microscopy of the skin biopsies, which will demonstrate the amyloid.

A diffuse or patchy alopecia, cutis verticis gyrata, and a scleroderma-like, scleromyxedema-like, or a cutis laxa-like appearance have also rarely been described. Cutis laxa-like findings may be generalized or localized to the acral parts. Lesions in the flexors and lateral neck may resemble pseudo-xanthoma elasticum (PXE). At times, lesions with cutis laxa-like or PXE-like appearance may show amyloid bound to elastic fibers. The nail matrix may be infiltrated, resulting in atrophy of the nail plate, presenting as longitudinal striae, partial onychia, splitting, and crumbling of the nail plate. Cordlike thickening along blood vessels can also occur. Bilateral stenosis of the external auditory canals has been reported. Patients with systemic amyloidosis are at increased risk for skin cancer.

Patients may present with or develop a plethora of systemic findings. Most characteristically, they develop carpal tunnel syndrome, other peripheral neuropathies, a rheumatoid arthritis (RA)-like arthropathy of the small joints, orthostatic hypotension, GI bleeding, nephrotic syndrome, and cardiac disease. Cardiac troponins are elevated and are powerful prognostic determinants in AL amyloidosis. Elevated troponins are associated with a 6-month survival. AL patients may appear to have prominent deltoid muscles as a result of deposition of amyloid in the muscles (shoulder pad sign). Cardiac arrhythmias and right-sided congestive heart failure are common causes of death.

The prognosis for patients with primary systemic amyloidosis is poor. Those presenting with neurologic findings survive longer than patients presenting with cardiac disease. Fifteen percent of patients with AL amyloidosis will have myeloma, and 15% of patients with myeloma will have AL amyloidosis.

### Secondary systemic amyloidosis (AA amyloidosis)

Secondary systemic amyloidosis is caused by a chronic infectious or inflammatory process. In these conditions, the precursor protein, serum amyloid A (SAA), an acute-phase reactant, is chronically elevated and cannot be adequately cleared from the body. It is processed to AA amyloid in affected tissues. With modern control of chronic infections (especially tuberculosis, schistosomiasis, osteomyelitis, bronchiectasis, pyelonephritis, and decubitus ulcer), infection-related AA amyloid is much less common. Most cases are now related to chronic inflammatory conditions, especially RA, juvenile idiopathic arthritis, ankylosing spondylitis, adult Still's disease, inflammatory bowel disease, and Behçet's disease. The newer and more aggressive management strategies for these inflammatory conditions have led to reduced numbers or delayed onset of AA amyloidosis in these patients. Maintaining SAA below 4 mg/L is associated with a good outcome in AA amyloidosis. The common organs involved by AA amyloidosis are the kidneys, adrenals, liver, and spleen. The skin is not involved, but biopsy of skin in patients with AA amyloidosis will detect amyloid deposits in the dermis perivascularly. Certain skin



conditions, such as hidradenitis suppurativa, stasis ulcers, psoriatic arthritis, and dystrophic epidermolysis bullosa, may be complicated by AA amyloidosis. Many inherited conditions associated with elevated SAA may be complicated by AA amyloidosis as well. These include familial Mediterranean fever, cryopyrin-associated periodic syndromes, and tumor necrosis factor (TNF) receptor-associated periodic syndrome (TRAPS).

### Dialysis-associated amyloidosis ( $\beta_2$ -microglobulin amyloidosis)

$\beta_2$ -Microglobulin is excreted primarily by the kidneys. In patients with severe renal failure on dialysis or predialysis, the excess  $\beta_2$ -microglobulin may be processed to amyloid in certain tissues. Almost 100% of patients receiving dialysis for 15 years or more will develop this form of amyloidosis. It primarily affects the synovium, causing musculoskeletal symptoms, often carpal tunnel syndrome, and less often, trigger finger, bone cysts, and spondyloarthropathy. Rarely, the skin may be involved, usually as a subcutaneous tumor, often of the buttocks overlying the sacrum. Pedunculated sacral masses, lichenoid papules, and localized hyperpigmentation can also be seen. The diagnosis is confirmed by biopsy, which demonstrates that the amyloid material is  $\beta_2$ -microglobulin on immunohistochemical stains. The treatment is high-flux dialysis or kidney transplantation.

### Senile systemic amyloidosis

Senile systemic amyloidosis is increasingly recognized as an important cause of cardiac disease in the elderly population (>70 years). Carpal tunnel syndrome can also occur. Senile systemic amyloidosis is caused by deposition of normal transthyretin, a transporter protein, in tissue. Skin lesions have not been reported, but vascular deposition has led to tongue necrosis. The diagnosis can be confirmed in about three quarters of patients with a deep abdominal fat biopsy.

## CUTANEOUS AMYLOIDOSIS

### Primary localized cutaneous amyloidosis

The primary localized cutaneous amyloidoses have been divided into four forms: macular, lichen, nodular, and familial. Macular and lichen forms of amyloidosis are also called “keratinocyte-derived” amyloidosis, frictional amyloidosis, and frictional melanosis. Some cases of these two forms of cutaneous amyloidosis are familial, but the relationship between these and cases of familial primary localized cutaneous amyloidosis is unclear. Patients with macular and lichen amyloidosis often have coexistent atopic dermatitis. Nodular and familial cases of cutaneous amyloidosis are rare and have a unique pathogenesis.

Nonfamilial macular and lichen amyloidosis have the same pathogenic basis (rubbing and friction), and overlap cases (biphasic cutaneous amyloidosis) can be seen. Individuals of Asian, Hispanic, or Middle Eastern ancestry seem to be predisposed. In Asia, the use of abrasive devices during bathing is often the precipitant. In cases of acquired macular and lichen amyloidosis, the deposited amyloid material contains keratin (primarily keratin 5) as its protein component, strongly suggesting that traumatic damage to basal keratinocytes results in the deposits. Why only certain individuals are affected is unknown. A rare form localized to the conchae has been

described. Nonfamilial macular and lichen amyloidosis may be associated with extremely pruritic skin conditions such as primary biliary cirrhosis and chronic renal failure.

The histologic picture of acquired macular and lichen amyloidosis is similar; the only difference is the size of the amyloid deposits and the extent of the overlying epidermal changes. The overlying epidermis is frequently hyperkeratotic and focally acanthotic, a result of the chronic rubbing. Focal necrotic keratinocytes may be observed in the basal cell layer. Microscopic and rarely macroscopic bullae (analogous to those in lichen planus) may be seen. Dermal papillae are expanded by amorphous deposits of amyloid that abut immediately below the epidermis. Melanin deposits are classically present in the amyloid. In all cases of postinflammatory hyperpigmentation with incontinence of pigment, the architecture of the areas of dermal melanosis should be examined carefully to exclude amyloidosis. Systemic amyloidosis is excluded by the absence of amyloid deposits around blood vessels. Special stains may be used to confirm the diagnosis, but this is rarely required if the classic histology is found. In difficult cases, immunoperoxidase for keratin will stain the amyloid deposits and confirm the diagnosis of primary cutaneous amyloidosis. DIF may demonstrate immunoglobulin (usually IgM) in a globular pattern in the keratin-derived cutaneous amyloidoses, but this is caused by passive absorption rather than specific deposition. This phenomenon is seen in all disorders with prominent apoptosis of keratinocytes.

### Macular amyloidosis

Typically, patients with macular amyloidosis exhibit moderately pruritic, brown, rippled macules characteristically located in the interscapular region of the back (Fig. 26-3). Women outnumber men by 5:1 or more. Pigmentation is generally not uniform, giving the lesions a “salt and pepper” or rippled appearance. Notalgia paresthetica is localized to the same sites, and most cases of macular amyloid between the scapulae probably result from rubbing dysesthetic areas of notalgia paresthetica. Occasionally, the thighs, shins, arms, breasts, and buttocks may be involved, and these more diffuse cases are usually associated with diffuse pruritus. Macular amyloidosis is a chronic condition.

### Lichen amyloidosis

Lichen amyloidosis is characterized by the appearance of paroxysmally itchy lichenoid papules, virtually always appearing

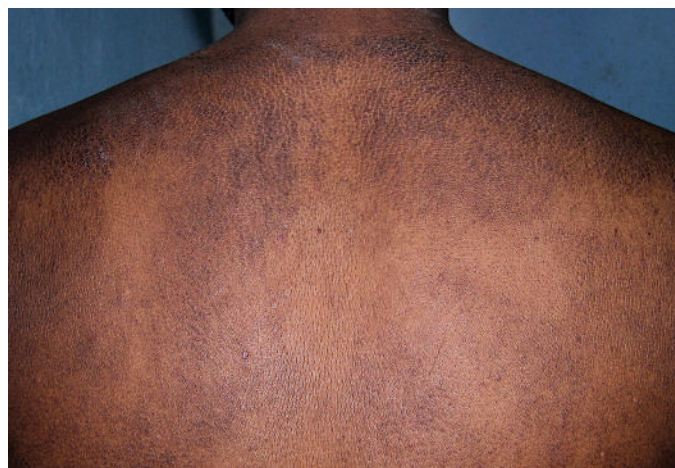
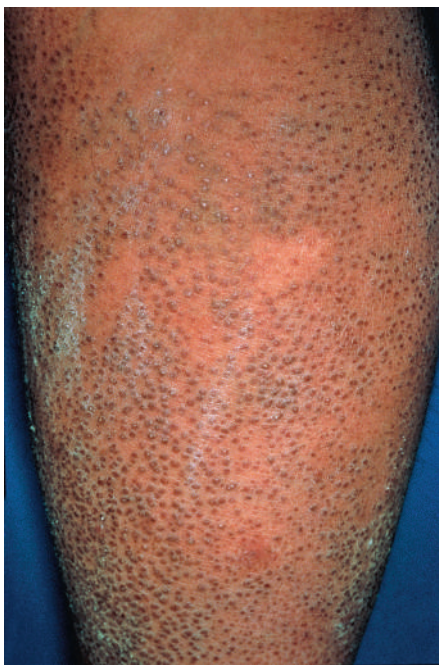
Fig. 26-3 Macular amyloid. (Courtesy of Dr. Debabrata Bandyopadhyay.)



**Fig. 26-4** Lichen amyloidosis.

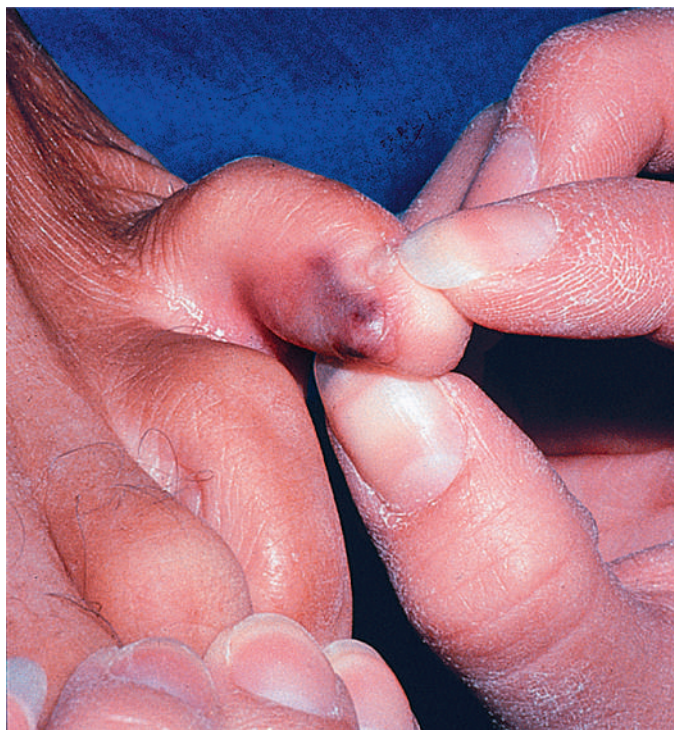bilaterally on the shins (Fig. 26-4). Some patients may deny itching. Men outnumber women 2:1. The primary lesions are small, brown, discrete, slightly scaly papules that group to form large, infiltrated plaques. Less frequently, these may occur on the thighs, forearms, face, and even the upper back.

### Treatment

Treatment of lichen and macular cutaneous amyloidosis is frequently unsatisfactory. Reducing friction is critical. Identifying the cause of the rubbing, and whether it is habit, pruritus, or neuropathy (as in *notalgia paresthetica*), directs treatment. Occlusion plays a major role, because it both enhances topical treatments and provides a physical block to prevent trauma to the skin. Administration of topical high-potency corticosteroid agents can be beneficial, as can intralesional corticosteroid therapy when small areas are involved. Topical tacrolimus 0.1% ointment, psoralen plus ultraviolet A light (PUVA) and with retinoids (Re-PUVA), ultraviolet B (UVB) light, tar, and calcipotriol benefit individual patients. Amitriptyline (for itching), oral retinoids, thalidomide, and systemic immunosuppressives, including corticosteroids, may be used in refractory cases. The pigmentation of macular amyloidosis reportedly has been improved by laser therapy, especially the 532-nm Q-switched neodymium-doped yttrium-aluminum-garnet (Nd: YAG) laser.

### Nodular amyloidosis

Nodular amyloidosis is a rare form of primary localized cutaneous amyloidosis in which single or, less often, multiple nodules or tumefactions preferentially involve the acral areas (Fig. 26-5). However, trunk, genital, or facial lesions may be seen as well. The lesions are asymptomatic, vary in size from several millimeters to several centimeters, and may grow slowly after their initial appearance. The overlying epidermis may appear atrophic, and lesions may resemble large bullae. Numerous conditions have been associated with nodular primary localized cutaneous amyloidosis (NPLCA), especially Sjögren syndrome, but also systemic sclerosis (including CREST), and RA. In Sjögren syndrome, the nodular amyloidosis typically appears about age 60, more frequently in females, and may precede the diagnosis of Sjögren syndrome by many



**Fig. 26-5** Nodular amyloidosis.

years. The dermis and subcutis may be diffusely infiltrated with amyloid. The lesions may contain numerous plasma cells and are best considered to be isolated plasmacytomas. The amyloid in these patients is Ig-derived AL, as is seen in primary systemic amyloidosis, and is unrelated to keratinocyte-related amyloid or to AA amyloid. Progression to systemic amyloidosis may occur in about 7% of cases, so they should be regularly evaluated for progression. Treatment is physical removal or destruction of the lesion with shave removal and destruction of the base.

### Secondary cutaneous amyloidosis

After PUVA therapy and in benign and malignant cutaneous neoplasms, deposits of amyloid may be found. Most frequently, the associated neoplasms are nonmelanoma skin cancers or seborrheic keratoses. Discoid lupus, dermatomyositis, and graft-versus-host disease (GVHD), as interface dermatoses with apoptosis of keratinocytes, can occasionally demonstrate amyloid in the upper dermis. In all cases, this is keratin-derived amyloid.

### Hereditary cutaneous amyloidosis syndromes

Familial primary localized cutaneous amyloidosis (FPLCA) is an autosomal dominant syndrome associated with chronic itching and cutaneous lesions resembling macular and lichen amyloidosis. It is seen most often in Japan, Brazil, China, and Taiwan. The age of onset is 5–18 years. In some families, sun exposure may be an exacerbating factor. Lesions are often widespread on the limbs, chest, and upper and lower back. The buttocks, conchae, and dorsal feet and hands may also be involved. Some patients may deny pruritus. In families from numerous countries with FPLCA, mutations in the *OSMR $\beta$*  or interleukin-31 receptor A (*IL-31RA*) genes are found. These two genes form the two subunits of the transmembrane receptor for IL-31. Affected families have only mutation of one gene,



and all mutations occur on the membrane proximal domain required for downstream signaling. IL-31 induces the secretion of monocyte chemotactic protein 1 (MCP-1), and levels of MCP-1 expression are very low in FPLCA. MCP-1 recruits monocytes to clear the cellular debris resulting from keratinocyte damage. In the absence of this signal, cellular debris accumulates, and the keratin is processed to amyloid. Rare cases of macular amyloidosis in an incontinentia pigmenti-like distribution suggest that mosaicism for FPLCA can be seen, giving this unusual cutaneous distribution. Some FPLCA cases demonstrate extensive poikilodermatous lesions, and less frequently, a patient may have multiple morphologies of lichen amyloid, poikiloderma, and dyschromia and even small bullous lesions.

Amyloidosis cutis dyschromica is a distinct type of FPLCA with onset in childhood, no pruritus, a dotted reticular hyperpigmentation with hypopigmented spots without papulation covering almost all the body, and small foci of amyloid just below the epidermis. The nature of the amyloid is unclear. Most affected families are from Japan, Taiwan, and India. UVB hypersensitivity is often reported by these patients. Multiple endocrine neoplasia type IIA (MEN-2A) syndrome and familial medullary thyroid carcinoma (FMTC) are both caused by mutations in the *RET* proto-oncogene. Cutaneous amyloidosis, most often keratin-derived macular amyloidosis, may be seen in these patients. The macular amyloid may be restricted to the upper back and also unilateral (associated with notalgia paresthetica), or it may be bilateral and more extensive. Age of onset is usually before 20. Thirty of 31 patients with MEN-2A had cutaneous amyloidosis before the diagnosis of MEN-2A was made. In a patient with macular amyloidosis of early onset (before age 20), a careful family history should be taken for endocrine neoplasias, the skin and mucosa examined for neuromas, the blood pressure taken (checking for pheochromocytoma), and the thyroid palpated. A serum calcitonin level should be ordered and, if elevated, a thyroid ultrasound performed.

### Pharmaceutical amyloidosis

When injected into the skin, insulin can create deposits of amyloid composed of the A and B subunits of insulin. This is termed AIns. Lesions present as deep subcutaneous nodules, usually on the lower abdomen. If patients inject into these sites, their glucose control may be impaired and their insulin dose may increase. Injecting into new areas or surgically removing the nodules improves glucose control. Enfuvirtide, a human immunodeficiency virus (HIV) fusion-inhibiting peptide administered subcutaneously, can produce similar lesions.

### FAMILIAL SYNDROMES ASSOCIATED WITH AMYLOIDOSIS (HEREDOFAMILIAL AMYLOIDOSIS)

Most forms of familial amyloidosis are caused by abnormal host proteins that cannot be adequately processed, resulting in their deposition in various tissues in the form of amyloid. Only 50% of patients with hereditary amyloidosis will have a positive family history. Liver, kidney, heart, eye, and nervous system may be involved. Several types of hereditary amyloidosis have been identified; some forms are caused by genetic defects in transthyretin. These are autosomal dominant syndromes, and most affected patients are heterozygotes. Others are caused by a genetic defect in apolipoprotein A-I or A-II, by a defect in gelsolin, fibrinogen A- $\alpha$ , cystatin C, or lysozyme.

These syndromes must often be diagnosed by genetic testing or immunohistochemical identification of the deposited pathogenic protein.

- Al-Niaimi F, et al:** Brown nodules and plaques on the neck. *Clin Exp Dermatol* 2013; 38:200.
- Alvarez-Ruiz SB, et al:** Unusual clinical presentation of amyloidosis: bilateral stenosis of the external auditory canal, hoarseness and a rapid course of cutaneous lesions. *Int J Dermatol* 2007; 46:503.
- An Q, et al:** Dramatic improvement of primary cutaneous amyloidosis with thalidomide. *Eur J Dermatol* 2011; 21:270.
- An Q, et al:** Thalidomide improves clinical symptoms of primary cutaneous amyloidosis: report of familial and sporadic cases. *Dermatol Ther* 2013; 26:263.
- Arnold SJ, Bowling JC:** "Shiny white streaks" in lichen amyloidosis: a clue to diagnosis. *Australas J Dermatol* 2012; 53:272.
- Bandhlish A, et al:** A clinic-epidemiological study of macular amyloidosis from North India. *Indian J Dermatol* 2012; 57:269.
- Barja J, et al:** Systemic amyloidosis with an exceptional cutaneous presentation. *Dermatol Online J* 2013; 19:11.
- Baykal C, et al:** Multiple cutaneous neuromas and macular amyloidosis associated with medullary thyroid carcinoma. *J Am Acad Dermatol* 2007; 56:S33.
- Brown AJ, et al:** Multiple lesions of primary cutaneous nodular amyloidosis in Sjögren syndrome. *J Am Acad Dermatol* 2012; 67:e267.
- Castanedo-Cazares JP:** Lichen amyloidosis improved by 0.1% topical tacrolimus. *Dermatology* 2002; 205:420.
- Chandran NS, et al:** Case of primary localized cutaneous amyloidosis with protean clinical manifestations: lichen, poikiloderma-like, dyschromic and bullous variants. *J Dermatol* 2011; 38:1066.
- Chia B, et al:** Primary localized cutaneous amyloidosis: association with atopic dermatitis. *J Eur Acad Dermatol Venereol* 2014; 28:810.
- Choi JY, et al:** Acitretin for lichen amyloidosis. *Australas J Dermatol* 2008; 49:109.
- Clos AL, et al:** Formation of immunoglobulin light chain amyloid oligomers in primary cutaneous nodular amyloidosis. *Br J Dermatol* 2011; 165:1349.
- Clos AL, et al:** Role of oligomers in the amyloidogenesis of primary cutaneous amyloidosis. *J Am Acad Dermatol* 2011; 65:1023.
- D'Souza A, et al:** Pharmaceutical amyloidosis associated with subcutaneous insulin and enfuvirtide administration. *Amyloid* 2014; 21:71.
- Funai N, et al:** Multiple milia and comedones as a skin manifestation of systemic amyloidosis. *Eur J Dermatol* 2011; 21:638.
- Gan EY, Tey HL:** Primary cutaneous nodular amyloidosis initially presenting with eczema. *Singapore Med J* 2010; 51:3158.
- Garg T, et al:** Pruritic patches on the back and papules on the legs. *Arch Dermatol* 2007; 143:255.
- Garg T, et al:** Amyloidosis cutis dyschromica: a rare pigmentary disorder. *J Cutan Pathol* 2011; 38:823.
- Grimmer J, et al:** Successful treatment of lichen amyloidosis with combined bath PUVA photochemotherapy and oral acitretin. *Clin Exp Dermatol* 2007; 32:39.
- Haemel A, et al:** Keratinocyte-derived amyloidosis as a manifestation of chronic graft-versus-host disease. *J Cutan Pathol* 2013; 40:291.
- Hanami Y, Yamamoto T:** Secondary amyloid deposition in a melanocytic nevus. *Int J Dermatol* 2013; 52:1031.
- Hemminki K, et al:** Cancer risk in amyloidosis patients in Sweden with novel findings on non-Hodgkin lymphoma and skin cancer. *Ann Oncol* 2014; 25:511.
- Ikedo SI, et al:** Diagnostic value of abdominal wall fat pad biopsy in senile systemic amyloidosis. *Amyloid* 2011; 18:211.
- Jin AGT, et al:** Comparative study of phototherapy (UVB) vs photochemotherapy (PUVA) vs topical steroids in the treatment of primary cutaneous lichen amyloidosis. *Photodermatol Photoimmunol Photomed* 2001; 17:42.
- Kalajian AH, et al:** Nodular primary localized cutaneous amyloidosis after trauma: a case report and discussion of the rate of progression to systemic amyloidosis. *J Am Acad Dermatol* 2007; 57:S26.
- Kandhari R, et al:** Asymptomatic conchal papules. *Indian J Dermatol Venereol Leprol* 2013; 79:445.
- Koh M, et al:** A rare case of primary cutaneous nodular amyloidosis of the face. *J Eur Acad Dermatol Venereol* 2008; 22:1011.
- Konopinski JC, et al:** A case of nodular cutaneous amyloidosis and review of the literature. *Dermatol Online J* 2013; 19:10.

**Kumar S, et al:** Skin involvement in primary systemic amyloidosis. *Mediterr J Hematol Infect Dis* 2013; 5:e2013005.

**Kurian SS, et al:** Amyloidosis cutis dyschromica. *Indian Dermatol Online J* 2013; 4:344.

**Lee DD, et al:** Association of primary cutaneous amyloidosis with atopic dermatitis: a nationwide population-based study in Taiwan. *Br J Dermatol* 2011; 164:148.

**Lin JR, et al:** Tongue necrosis and systemic vascular amyloidosis. *Human Pathol* 2011; 42:734.

**Love WE, et al:** The spectrum of primary cutaneous nodular amyloidosis: two illustrative cases. *J Am Acad Dermatol* 2008; 58:S33.

**Meijer JM, et al:** Sjögren's syndrome and localized nodular cutaneous amyloidosis: coincidence or a distinct clinical entity? *Arthritis Rheum* 2008; 58:1992.

**Merchand A, et al:** Cutaneous amyloid elastosis revealing multiple myeloma with systemic amyloidosis. *Acta Derm Venereol* 2013; 93:204.

**Mohty D, et al:** Cardiac amyloidosis: updates in diagnosis and management. *Arch Cardiovasc Dis* 2013; 106:528.

**Nagaste T, et al:** Insulin-derived amyloidosis and poor glycemic control: a case series. *Am J Med* 2014; 127:450.

**Ostovari N, et al:** 532-nm and 1064-nm Q-switched Nd:YAG laser therapy for reduction of pigmentation in macular amyloidosis patches. *J Eur Acad Dermatol Venereol* 2008; 22:442.

**Pardo Arranz L, et al:** Familial poikylodermic cutaneous amyloidosis. *Eur J Dermatol* 2008; 18:289.

**Park MY, Kim YC:** Macular amyloidosis with an incontinentia pigmenti-like distribution. *Eur J Dermatol* 2008; 18:477.

**Powell AM, et al:** Discoid lupus erythematosus with secondary amyloidosis. *Br J Dermatol* 2005; 153:746.

**Renker T, et al:** Systemic light-chain amyloidosis revealed by progressive nail involvement, diffuse alopecia and sicca syndrome: report of an unusual case with a review of the literature. *Dermatology* 2014; 228:97.

**Rothberg AE, et al:** Familial medullary thyroid carcinoma associated with cutaneous lichen amyloidosis. *Thyroid* 2009; 19:651.

**Sakuma TH, et al:** Familial primary localized cutaneous amyloidosis in Brazil. *Arch Dermatol* 2009; 145:695.

**Salim T, et al:** Lichen amyloidosis: a study of clinical, histopathologic and immunofluorescence findings in 30 cases. *Indian J Dermatol Venereol Leprol* 2005; 71:166.

**Shiao YM, et al:** MCP-1 as an effector of IL-31 signaling in familial primary cutaneous amyloidosis. *J Invest Dermatol* 2013; 133:1375.

**Takayama K, et al:** Dialysis-related amyloidosis on the buttocks. *Acta Derm Venereol* 2008; 88:72.

**Taniguchi Y, et al:** Cutaneous amyloidosis associated with amyopathic dermatomyositis. *J Rheumatol* 2009; 36:1088.

**Tong PL, et al:** Primary localized cutaneous nodular amyloidosis successfully treated with cyclophosphamide. *Australas J Dermatol* 2013; 54:e12.

**Wang WH, et al:** A new c.1845A→T of oncostatin M receptor-β mutation and slightly enhanced oncostatin M receptor-β expression in a Chinese family with primary localized cutaneous amyloidosis. *Eur J Dermatol* 2012; 22:29.

**Wat H, et al:** Primary systemic (amyloid light-chain) amyloidosis masquerading as pseudoxanthoma elasticum: recognizing a novel clinicopathological pattern. *JAMA Dermatol* 2014; 150:1091.

**Wettle C, et al:** Cutaneous haemorrhage induced by minimal trauma as a sign of light chain-associated amyloidosis. *B J Haematol* 2012; 159:383.

**Wey SJ, et al:** Primary Sjögren syndrome manifested as localized cutaneous nodular amyloidosis. *J Clin Rheumatol* 2011; 17:368.

**Wu JJ, et al:** Macular amyloidosis presenting in an incontinentia pigmenti-like pattern with subepidermal blister formation. *J Eur Acad Dermatol Venereol* 2008; 22:635.

**Yang W, et al:** Amyloidosis cutis dyschromica in two female siblings: cases report. *BMC Dermatol* 2011; 11:4.

**Yasuyuki F, et al:** Nail dystrophy and blisters as sole manifestations in myeloma-associated amyloidosis. *J Am Acad Dermatol* 2006; 54:712.

**Yew YW, Tey HL:** Itch in familial lichen amyloidosis: effective treatment with amitriptyline in two cases. *Dermatol Ther* 2014; 27:12.

**Yoshida A, et al:** Lichen amyloidosis induced on the upper back by long-term friction with a nylon towel. *J Dermatol* 2009; 36:56.

**Zhao JY, et al:** A case of systemic amyloidosis beginning with purpura. *Chin Med J* 2012; 125:555.

**Zuo YG, et al:** Lack of evidence for *OSMR* and *RET* gene mutations in a Chinese family with friction melanosis. *Clin Exp Dermatol* 2009; 35:282.

## PORPHYRIAS

Porphyrinogens are the building blocks of all the hemoproteins, including hemoglobin and the cytochrome enzymes, and are produced primarily in the liver and bone marrow. Each form of porphyria has now been associated with a deficiency in an enzyme in the metabolic pathway of heme synthesis. These enzyme deficiencies lead to accumulation of the precursor molecules before the mutation. The precursors are porphyrins, and the diseases are called porphyrias.

Understanding the biosynthetic pathway of heme has clarified the biochemical basis of the porphyrias. Delta-aminolevulinic acid (δALA) is synthesized in the mitochondria by δALA synthetase. From it are formed, successively, porphobilinogen, uroporphyrin III, coproporphyrin III, and protoporphyrin IX. This form reenters the mitochondrion, to be acted on by ferrochelatase to produce heme. Each step in this process is catalyzed by a specific enzyme. Heme, by negative feedback, represses the production, or activity, of δALA synthetase. If heme is inadequate, δALA synthetase activity may be increased, leading to the production of more porphyrins. Because this enzyme system is inducible, medications that increase the cytochrome drug-metabolizing system in the liver can lead to exacerbation of the porphyrias by increasing the production of the porphyrin intermediates.

The current grouping of the porphyrias is based on the primary site of increased porphyrin production, either liver or bone marrow—the hepatic or erythropoietic porphyrias, respectively. Some include a hepatoerythropoietic category. Congenital erythropoietic porphyria (CEP), X-linked dominant protoporphyria (XLDPP), and erythropoietic protoporphyria (EPP) are the erythropoietic forms. Acute intermittent porphyria (AIP), ALA dehydratase deficiency (ADP), hereditary coproporphyrin (HCP), variegate porphyria (VP), and porphyria cutanea tarda (PCT) are the hepatic forms. Hepatoerythrocytic porphyria (HEP) has been classified as either a hepatic or a hepatoerythropoietic type.

Another way to classify the porphyrias is by their symptomatology. This system divides those diseases that have acute episodes, called the acute porphyrias, and those that have skin findings, called the cutaneous porphyrias. Some conditions have both skin disease and acute episodes. The acute porphyrias are ADP, AIP, HCP, and VP. The cutaneous porphyrias are PCT, CEP, XLDPP, and EPP. VP and HCP can have both acute attacks and skin lesions. The acute attacks are induced by conditions that activate the heme biosynthesis pathway. Due to the enzymatic “blocks” as the pathway is activated, large amounts of the heme precursors (specifically, δALA and porphobilinogen) are produced by the liver and dumped into the bloodstream. These substances are neurotoxic and affect primarily the autonomic and peripheral nerves. In the cutaneous porphyrias, photosensitivity is observed. The photosensitivity is caused by the absorption of UV radiation in the Soret band (400–410 nm) by increased porphyrins, primarily in the blood vessels of the upper dermis. These activated porphyrins are unstable, and as they return to a ground state, they transfer energy to oxygen, creating reactive oxygen species. These unstable oxygen species interact with biologic systems, primarily plasma and lysosomal membranes, causing tissue damage. Mediators released from mast cells and polymorphonuclear leukocytes, acting through complement and metalloproteinase, eicosanoids, or factor XII pathways, may augment tissue effects. The skin lesions are determined by the biochemical nature of

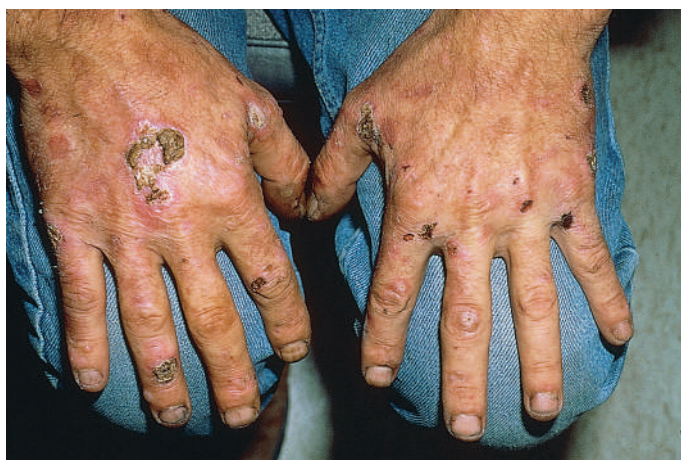

the excess porphyrin. Hydrophobic protoporphyrin has more affinity to lipid membranes, specifically endothelial cells. This correlates with acute burning and purpura exhibited in EPP, as well as the prominent reduplication of the basement membranes (seen as perivascular hyaline deposits) of the upper dermal vessels from constant repair of the phototoxic damage to the endothelial cells. The more water-soluble porphyrins (uroporphyrin and coproporphyrins) diffuse into and accumulate in the dermis and along the DEJ. The resulting skin lesions, subepidermal blisters, are caused by the phototoxic damage in this region.

The porphyrias have classically been diagnosed by identifying characteristic clinical and biochemical abnormalities, typically elevated levels of porphyrins in the urine, serum, red blood cells (RBCs), or stool. Because there is some clinical overlap, biochemical testing should be performed to confirm any diagnosis of porphyria. In the acute porphyrias, patients are often asymptomatic between attacks. During attacks, porphyrin assays will be abnormal in all forms of porphyria. Between attacks, some patients with AIP may have normal porphyrin assays. The genetic defect and the points of the most common mutations for each gene are now known for most forms of the porphyrias. Genetic testing is now recommended in most porphyrias, except PCT and EPP. This allows for the diagnosis of AIP between attacks. There is considerable clinical overlap in these rarer porphyrias; dual porphyrias exist, with mutations in two different heme synthesis genes; and low-level mutations causing atypical presentations are now well described. Accurate diagnosis in such cases requires determination of the genetic defect. This also allows for genetic counseling and prenatal diagnosis.

### PORPHYRIA CUTANEA TARDA

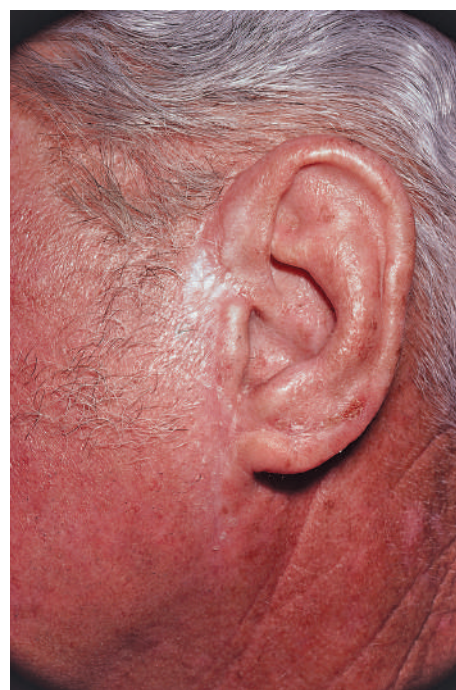Porphyria cutanea tarda is the most common type of porphyria. Patients with PCT present most often in midlife, averaging 45 years of age at disease onset. The disease is characterized by photosensitivity resulting in bullae, especially on sun-exposed parts. The dorsal hands and forearms, ears, and face are primarily affected. The bullae are noninflammatory and rupture easily to form erosions or shallow ulcers (Fig. 26-6). These heal with scarring, milia, and dyspigmentation. Lesions on the legs, especially the shins and dorsal feet, occur primarily in women. In addition, patients frequently complain of skin fragility in affected areas. There is hyperpigmentation of the skin, especially of the face, neck, and hands. Hyper-



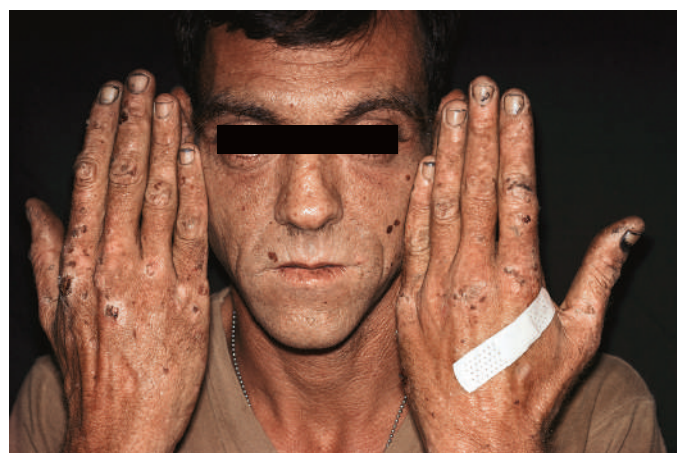**Fig. 26-6** Porphyria cutanea tarda.

trichosis of the face is seen, especially over the cheeks and temples. The face and neck, especially in the periorbital area, may show a pink to violaceous tint. Sclerodermatous thickenings may develop on the back of the neck, in the preauricular areas (Fig. 26-7), or on the thorax, fingers, and the scalp, with associated alopecia. A direct relationship between the levels of uroporphyrins in the urine and sclerodermatous changes has been reported.

Liver disease is frequently present in patients with PCT. A history of alcoholism is common. PCT is a well-recognized cutaneous complication of hepatitis C virus (HCV) infection. All PCT patients should be screened for HCV infection. Iron overload in the liver is frequently found in patients with PCT as a result of chemical or viral liver damage, or because a significant number of patients with PCT have a C282Y mutation (and a few with H63D mutation), the genetic cause of hemochromatosis (Fig. 26-8). The net result of all these liver and iron metabolism abnormalities is an increase in ferritin, with hepatic iron overload. Hepatocellular carcinoma may rarely present with PCT, and PCT patients are at 3.5 times the risk of developing hepatocellular carcinoma.



**Fig. 26-7** Porphyria cutanea tarda with sclerosis.



**Fig. 26-8** Porphyria cutanea tarda with hemochromatosis. (Courtesy of Curt Samlaska, MD.)

Porphyria cutanea tarda has been frequently associated with other diseases. It is estimated that adult-onset (type 2) diabetes mellitus occurs in 15–20% of patients with PCT. Diabetes usually occurs about a decade after the PCT diagnosis. Type 2 diabetes and the metabolic syndrome is associated with hyperferritinemia. It has been proposed that in some patients, nonalcoholic steatohepatitis (NASH) of diabetes may contribute to the development of PCT, and in one patient, weight reduction led to improvement of PCT. Antimalarial treatment of PCT leads to enhanced glucose control. Moderate smoking (>10 cigarettes/day) may lead to earlier presentation of PCT by almost a decade. Numerous cases of lupus erythematosus concomitant with PCT have been reported. Patients may have systemic and/or purely cutaneous lupus, and either disease may present initially. The pathogenesis of this association is unclear.

Porphyria cutanea tarda can occur in patients with HIV infection. This is not related only to coexistent HCV infection, which is increased in some risk groups of HIV-infected persons. Subtle porphyrin abnormalities are found in HIV disease, but the porphyrin levels are well below those capable of inducing clinical disease. Other risk factors, such as alcoholism, should be evaluated, and the existence of PCT should not be attributed to the HIV disease alone. However, effective anti-HIV therapy has led to improvement of PCT in one HIV/HCV-infected patient.

Estrogen treatment is associated with the appearance of PCT by an unknown mechanism. Before oral contraceptives were introduced, PCT cases occurred predominantly among men, but in most recent series, 60% of cases occurred in men and 40% in women. Men treated with estrogens for prostate cancer may develop PCT.

Porphyria cutanea tarda is caused by a deficiency in the enzyme uroporphyrinogen decarboxylase (UROD). Several types have been described. The most common is the sporadic, nonfamilial form, which represents about 75–80% of cases. Enzymatic activity of UROD is abnormal in the liver but normal in other tissues. This is the form associated with the cofactors previously listed. The enzyme deficiency is related to loss of enzyme activity caused by the liver damage or estrogens triggering the PCT. The enzyme UROD is inhibited by iron, so conditions that lead to iron overload in the liver (cirrhosis, alcoholism, HCV infection, type 2 diabetes, hemochromatosis) are all associated with PCT. Removal of this iron in the liver may result in improvement of PCT. With remission, the enzyme activity in the liver may return to normal.

The second, or familial, type of PCT is an autosomal dominant inherited deficiency of UROD in the liver and RBCs of patients and of clinically unaffected family members. Both the activity and the concentration of the enzyme decrease by about 50%. Multiple genetic defects have been reported that produce the same phenotype. Familial PCT tends to present at an earlier age, and development of PCT before age 20 strongly suggests familial PCT.

A third form, acquired toxic PCT, is associated with acute or chronic exposure to hepatotoxins, specifically, polyhalogenated hydrocarbons such as hexachlorobenzene and dioxin. These patients have biochemical and clinical features identical to those of patients with sporadic and familial PCT.

A diagnosis of PCT can be strongly suspected on clinical grounds. A useful confirmatory test that can be performed in the office is the characteristic pink or coral-red fluorescence of a random urine specimen under Wood's light. A 24-hour urine specimen usually contains less than 100 µg of porphyrins in a normal individual, whereas in the PCT patient it may range from 300 µg to several-thousand. The ratio of uroporphyrins to coproporphyrins in PCT is typically 3:1–5:1, distinguishing

PCT from variegate porphyria. Plasma porphyrins will also be abnormal and may be detected by peak plasma fluorescence at less than 623 nm. The diagnosis of hereditary PCT is made by demonstrating reduced UROD activity in erythrocytes.

Biopsy of a blister reveals a noninflammatory subepidermal bulla with an undulating, festooned base. PAS-positive thickening of blood vessel walls in the upper and middle dermis is present. A useful and highly characteristic, but not diagnostic, feature is the presence of the so-called caterpillar bodies. These eosinophilic, elongated, wavy structures are present in the lower and middle epidermis and lie parallel to the basement membrane zone (BMZ). They stain positively with PAS and are positive for type IV collagen and laminin, suggesting they represent BMZ material present in the epidermis. DIF of involved skin shows IgG and C3 at the DEJ and in the vessel walls in a granular-linear pattern.

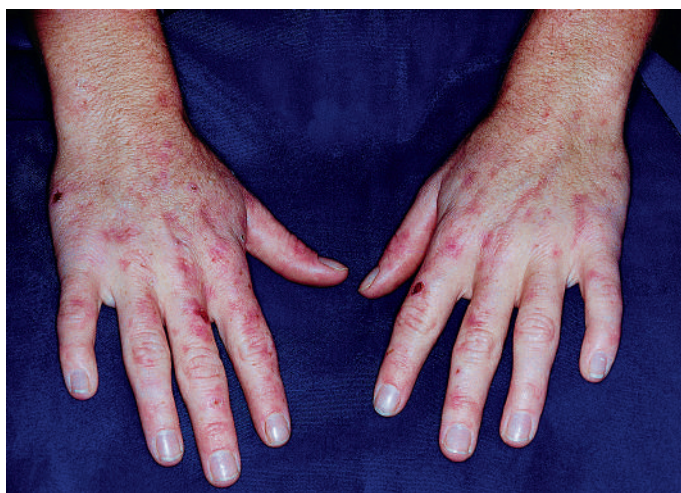Initial treatment of PCT involves removal of all precipitating environmental agents, such as alcohol and medications. This may lead to sufficient improvement so that further therapy is not required. Chemical sunscreens are of little value because they do not typically absorb radiation in the near-visible UVA range. Barrier sunscreens such as titanium dioxide and zinc oxide may be more beneficial, but physical barriers such as hats and gloves should be encouraged while therapy is initiated.

Phlebotomy is a highly effective treatment for PCT. UROD is inhibited by iron, and removal of hepatic iron may therefore lead to recovery of enzyme activity. Typically, phlebotomy of 500 mL at 2-week intervals is performed until the hemoglobin reaches 10 g/dL or the serum iron 50–60 µg/dL. Ideally, serum ferritin will become normal as well. Urinary porphyrin excretion initially increases, but gradually, 24-hour uroporphyrin levels are greatly reduced, with most patients able to achieve normal levels. This process takes several months, usually requiring a total of 6–10 phlebotomies. As the porphyrins fall, the skin lesions also involute. Initially, blistering improves, then skin fragility decreases, and finally, the cutaneous sclerosis and hypertrichosis can eventually reverse. A common error in management is coadministration of oral iron supplementation during the phlebotomies to treat the anemia.

Antimalarial therapy is an alternative to phlebotomy and may be combined with phlebotomy in difficult cases. Antimalarials complex the excess porphyrins, enhancing their excretion. Full doses of antimalarials may produce a severe hepatotoxic reaction. The initial dose is 125 mg of chloroquine or 100–200 mg of hydroxychloroquine twice weekly. Improvement is gradual and parallels the reduction in porphyrins.

The duration of treatment to reach a biochemical remission is the same for phlebotomy and antimalarial therapy, about 6–7 months. This remission may last many years. If the patient relapses, these treatments can be repeated. Alternative treatments, which are rarely required, include desferrioxamine or deferasirox (iron chelation) and erythropoietin treatment. Erythropoietin may be combined with phlebotomy. PCT in renal failure may respond to erythropoietin and low-volume phlebotomy, desferrioxamine given at the end of dialysis, or renal transplantation. If HCV infection coexists, interferon alfa treatment of the HCV infection may lead to improvement of the PCT. The management of PCT associated with hemodialysis is much more difficult. High-flux, high-efficiency hemodialysis should be instituted. N-acetylcysteine, 400 mg of powder dissolved in orange juice twice daily, can be added to augment dialysis. Erythropoietin, at times at very high dose, in combination with mini-phlebotomy can be used in anuric patients with PCT not controlled by other methods.





**Fig. 26-9** Pseudoporphyria cutanea tarda from tetracycline in a young woman.

## PSEUDOPORPHYRIA

In certain settings, patients develop blistering and skin fragility identical to PCT, with the histologic features of PCT but with normal urine and serum porphyrins. Hypertrichosis, dyspigmentation, and cutaneous sclerosis do not occur. This pseudoporphyria is most often caused by medications, typically a nonsteroidal anti-inflammatory drug (NSAID), usually naproxen. Other NSAIDs, such as nabumetone, diclofenac, and rofecoxib, as well as voriconazole, tetracycline (Fig. 26-9), tolterodine, imatinib mesylate and sunitinib, metformin, finasteride, estrogen, and multiple other medications, can cause a similar clinical picture. Tanning bed use can also produce pseudo-PCT. Some patients on hemodialysis develop a similar PCT-like picture. Less frequently, dialysis patients develop true PCT. In the anuric dialysis patient, true PCT and pseudo-PCT are distinguished by analysis of serum porphyrins in a laboratory knowledgeable in the normal porphyrin levels in patients undergoing hemodialysis. The treatment of pseudoporphyria is physical sun protection and discontinuance of any inciting medication. Ibuprofen is a safer alternative NSAID that usually does not cause pseudoporphyria. In medication-induced PCT, blistering resolves over several months once the medication is stopped. Skin fragility may persist for much longer. *N*-acetylcysteine and glutamine have been reported to improved dialysis-associated pseudo-PCT.

## HEPATOERYTHROPOIETIC PORPHYRIA

Hepatoerythropoietic porphyria (HEP) is a very rare form of porphyria that is inherited as an autosomal recessive trait. HEP is the homozygous form of PCT. It is caused by a homozygous or compound heterozygous deficiency of UROD, which is about 10% of normal in both the liver and the erythrocytes. The biochemical abnormalities are similar to but more marked than those in PCT, although the clinical features are similar to congenital erythropoietic porphyria (CEP). Dark urine is usually present from birth. In infancy, vesicles occur in sun-exposed skin, followed by sclerodermoid scarring, hypertrichosis, pigmentation, red fluorescence of the teeth under Wood's light, and nail damage. Neurologic disease has been reported. The diagnosis of HEP is confirmed by abnormal urinary uroporphyrins (as seen in PCT), elevated erythrocyte protoporphyrins, and increased coproporphyrins in the feces. In CEP, uroporphyrins are elevated in the erythrocytes, allowing

differentiation from HEP. Sun protection is necessary, but often inadequate. Bone marrow transplantation, as in CEP, may be required for HEP patients.

## VARIEGATE PORPHYRIA

Variegate porphyria (VP) is also known as mixed porphyria, South African genetic porphyria, and mixed hepatic porphyria. VP has an autosomal dominant inheritance with a high penetrance. It results from a decrease in activity of protoporphyrinogen oxidase (PPOX). Between 40% and 70% of patients with VP have skin symptoms, 27% have acute attacks, and only 14% have both acute attacks and skin symptoms. Many affected relatives have silent VP, in which there is reduced enzyme activity but no clinical lesions. Such persons should be identified and evaluated.

Variegate porphyria is characterized by the combination of the skin lesions of PCT and the acute GI and neurologic disease of acute intermittent porphyria (AIP). In 50% of VP patients, skin lesions are the presenting finding. Vesicles and bullae with erosions, especially on sun-exposed areas, are the chief manifestations. In addition, hypertrichosis is seen in the temporal area, especially in women. Hyperpigmentation of sun-exposed areas is also a feature. Facial scarring and thickening of the skin may give the patient a prematurely aged appearance.

The presence of VP should be suspected in a patient when findings indicate both PCT and AIP, especially if the patient is of South African ancestry. Fecal coproporphyrins and protoporphyrins are always elevated, and during attacks, urine porphobilinogen and ALA are elevated. Normal levels of fecal protoporphyrin in adulthood predicts freedom from both skin symptoms and acute attacks. Urinary coproporphyrins are increased over uroporphyrins, distinguishing VP from PCT. Urinary coproporphyrin level greater than 1000 nmol/day predicts increased risk for acute attacks and skin symptoms and indicates the need for preventive treatment to reduce porphyrins. A finding in the plasma of a unique fluorescence at 626 nm is characteristic of VP and distinguishes it from all other forms of porphyria. Lymphocyte PPOX can be measured, but because of the profound founder effect in this condition, genetic testing should be used to confirm the diagnosis.

Treatment of the skin lesions is symptomatic, because antimalarials and phlebotomy are not effective in modifying cutaneous disease in VP. Gonadotropin-releasing hormone (GnRH) analogs may prevent premenstrual attacks, and "hemin" and glucose loading can be used for acute attacks. VP patients, as well as those with other acute porphyrias (HCP and AIP), are at increased risk for hepatocellular carcinoma, and regular liver imaging should be performed after age 50. Education of patients and unaffected PPOX-deficient relatives is essential to avoid triggering medications.

Homozygous VP is a very rare autosomal recessive condition that presents in childhood with PCT-like acral blistering, vermiculate scarring of the cheeks, finger shortening, and developmental delay. Brain myelin is completely absent.

## HEREDITARY COPROPORPHYRIA

Hereditary coproporphyrin (HCP) is a rare, autosomal dominant porphyria resulting from a deficiency of coproporphyrinogen oxidase (CPO). About one third of patients are photosensitive, with blistering similar to but less severe than in VP. About 35% have acute attacks with GI and neurologic symptoms similar to those seen in AIP and VP. Fecal coproporphyrin III is always increased; urinary coproporphyrin, ALA,

and porphobilinogen (PBG) are increased only during attacks. Plasma fluorescence at 619 nm is seen. Mutation screening can be used to confirm the diagnosis and identify unaffected but CPO-deficient relatives. Homozygous hereditary coproporphyrin, or harderoporphyria, is caused by a homozygous defect of CPO, with patients having 10% or less of normal activity. Children present with photosensitivity, hypertrichosis, and hemolytic anemia. The biochemical findings in plasma, feces, and urine are identical to HCP, but more marked. Harderoporphyrin is the natural intermediate between coproporphyrinogen and protoporphyrinogen.

### ERYTHROPOIETIC PROTOPORPHYRIA

Erythropoietic protoporphyria (EPP) is an autosomal recessive disorder. The ferrochelatase (FECH) activity is always below 35% and usually 10–25% of normal in affected persons. This low level of enzyme activity, inherited as a pseudodominant trait (true dominant inheritance should result in only 50% reduction in enzyme activity), occurs because all affected persons are in fact compound heterozygotes. In Europe, up to 10–15% of the population carries a low-expression (hypomorphic) allele that is only 50% as active as the wild-type enzyme. If the patient also inherits a loss-of-function mutation, this combination leads to about 25% enzyme activity, below the critical 35% activity required to remain disease free. Autosomal recessive EPP results from inheritance of two genes with significant loss of function, but not a common hypomorphic allele.

Typically, EPP presents early in childhood (3 months to 2 years), although presentation late in adulthood can occur. The diagnosis of EPP in children is frequently delayed because of its rarity and the general lack of awareness of pediatricians of its existence. Older children at times are referred to psychiatrists until the diagnosis is suspected.

Unique among the more common forms of porphyria is an immediate burning of the skin on sun exposure. Because the elevated protoporphyrin IX absorbs both in the Soret band and at 500–600 nm, visible light through window glass or in the operating room may precipitate symptoms. Infants cry when exposed to sunlight. Erythema, plaquelike edema, and wheals such as those seen in solar urticaria can be seen. These lesions appear solely on sun-exposed areas. In severe cases, purpura is seen in the sun-exposed areas.

With repeated exposure, the skin develops a weather-beaten appearance. Shallow linear or elliptical scars, waxy thickening and pebbling of the skin on the nose and cheeks and over metacarpophalangeal joints, and atrophy of the rims of the ears have been described (Fig. 26-10). Perioral furrowlike scars are characteristic. The dorsal hands and face of EPP patients appear much older than their chronologic age.

About 2.5% of patients with EPP have a seasonal palmar keratoderma. It is worse in the summer and resolves in winter or with occlusion of the palm by a plaster cast. The keratoderma is waxy and may cover the whole palm or may be localized to the first web space. It is sharply demarcated at the wrist and has no red border. The thickening is moderate in severity. The nails are usually unaffected but may show minimal onycholysis. Patients with nail changes all have true autosomal recessive EPP, with lower levels of erythrocyte protoporphyrin but increased levels of fecal total porphyrin compared with pseudodominant EPP patients. In fact, their erythrocyte protoporphyrin may be near-normal. About 45% of patients with autosomal recessive EPP have this keratoderma.

Between 20% and 30% of EPP patients have liver complications because of excessive porphyrin deposits in hepatocytes. This can occur anywhere along the spectrum, from mild

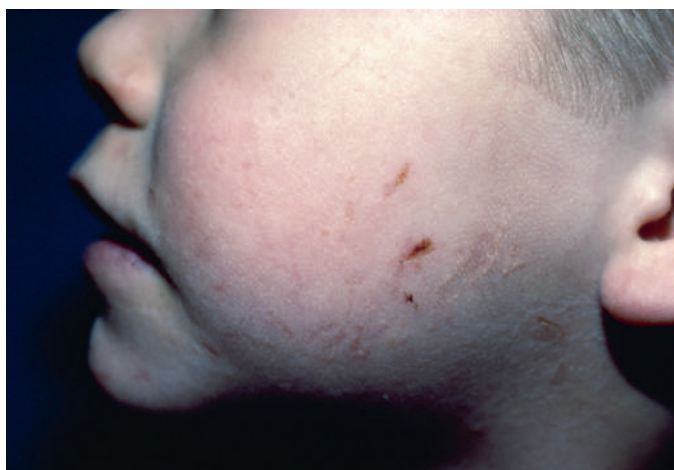

Fig. 26-10 Linear scars and erosions in erythropoietic protoporphyria.

elevation of liver function tests to cirrhosis. Only 5% of patients with EPP and liver disease develop hepatic failure, or 0.5%–1% of all EPP patients. Liver transplantation may be required. Autosomal recessive inheritance of EPP may be a risk factor for the development of liver failure. There is currently no marker for progressive liver disease (not laboratory porphyrins or genetic defect), so all patients must be monitored. Ten percent of patients develop gallstones, often in childhood. A mild microcytic anemia is present in 25% of patients with EPP, but therapy with iron should be used only if iron deficiency is detected, since it may exacerbate symptoms. Because of sun avoidance, vitamin D deficiency can occur.

The rare syndrome of EPP appearing *de novo* in adults has been reported multiple times. These cases are associated with a myeloproliferative disorder or myelodysplastic syndrome. The malignant cells in the bone marrow, caused by a translocation, lose the *FECH* gene on chromosome 18, and the patient “acquires” a *FECH* deficiency. Bone marrow transplantation is associated with resolution of this form of EPP.

Histologically, there is prominent ground-glass, PAS-positive material in the upper dermis, mostly perivascularly. This material is type IV collagen. On DIF, IgG and C3 may be found perivascularly. If an acute purpuric lesion is biopsied, the features of a leukocytoclastic vasculitis may be seen.

A diagnosis of EPP can usually be suspected on clinical grounds, especially if both the acute symptoms and the chronic skin changes are found. Because protoporphyrin IX is not water soluble, urine porphyrin levels are normal. Erythrocyte protoporphyrin is elevated and can be detected by RBC fluorescence. Erythrocyte, plasma, and fecal protoporphyrin can also be assayed to confirm the diagnosis. Erythrocyte protoporphyrin levels in affected persons may range from several hundred to several thousand micrograms per 100 mL of packed RBCs (normal values, <35 µg/100 mL of packed RBCs). Plasma fluorescence shows a peak at 634 nm.

The differential diagnosis of EPP includes hydroa vacciniforme, xeroderma pigmentosa, and solar urticaria. In infancy, before the appearance of the chronic skin changes, erythrocyte porphyrins may need to be screened to confirm the diagnosis. Once chronic changes are present, a skin biopsy will confirm the diagnosis.

The treatment of EPP patients consists of protection from exposure to sunlight with clothing and barrier sunscreens containing titanium dioxide or zinc oxide. Beta carotene, 60–180 mg/day in adults and 30–90 mg/day for children, to maintain a serum level of 600 µg/100 mL, provides some modest protection. As the child grows, the dose must be increased to maintain adequate tissue levels. Early-spring



hardening with narrow-band UVB or PUVA (wavelengths below the action spectrum of the incriminated porphyrins) is being increasingly used. Preliminary trials of colestipol, 2 g daily, and oral zinc sulfate, 600 mg daily, have led to substantial increases in light tolerance in EPP patients. Afamelanotide (Scenesse) has been demonstrated to increase light tolerance in patients with EPP, in a 20-mg sustained-release form implanted every 2 months.

### X-LINKED DOMINANT PROTOPORPHYRIA

X-linked dominant protoporphyria (XLDPP) is caused by deletions in the *dALA synthetase 2 (ALAS2)* gene. These mutations result in gain of function of the *ALAS2* gene, with increased production of protoporphyrin. Erythrocyte protoporphyrins are elevated from this overproduction of protoporphyrin, which exceeds the capacity of the ferrochelatase to incorporate the protoporphyrin into heme, resulting in excess protoporphyrin. Patients present with symptoms identical to EPP. About 10% of patients in North America with “EPP” actually have XLDPP. More severe photosensitivity and more frequent liver disease (15%) occur in XLDPP due to higher levels of protoporphyrins, about two times higher than in EPP patients. One case of late-onset XLDPP associated with myelodysplasia has been reported. Intravenous iron therapy has improved skin symptoms.

### CONGENITAL ERYTHROPOIETIC PORPHYRIA

Congenital erythropoietic porphyria (CEP) is a very rare form of porphyria s inherited as an autosomal recessive trait. It is caused by a homozygous defect of the enzyme uroporphyrinogen III synthase (UROS). The coinheritance of a gain-of-function mutation in *ALAS2* can lead to a more severe phenotype. One family with a *GATA1* mutation also developed CEP.

Congenital erythropoietic porphyria presents soon after birth with the appearance of red urine (noticeable on diapers). Severe photosensitivity occurs and may result in immediate pain and burning, so that the affected child screams when exposed to the sun. The laser used in pulse oximeters may lead to skin lesions of the nail bed. Redness, swelling, and blistering occur and result in scarring of the face, dorsal hands, and scalp (with subsequent alopecia). Ectropion can occur, with subsequent corneal damage and loss of vision. Erythrodontia of both deciduous and permanent teeth is also characteristic (Fig. 26-11). This phenomenon is demonstrated by the coral-red fluorescence of the teeth when exposed to Wood’s light. Mutilating scars, especially on the face, and hypertrichosis of the cheeks, with profuse eyebrows and long eyelashes, occur. Other features seen in CEP include growth retardation, hemolytic anemia, thrombocytopenia, porphyrin gallstones, osteopenia, and increased fracturing of bones.

A diagnosis of CEP can be easily suspected when an infant has dark urine and is severely photosensitive. There is a direct correlation among the severity of the disease, the levels of plasma porphyrins, and the residual activity of UROS. Abnormally high amounts of uroporphyrin I and coproporphyrin I are found in urine, stool, and RBCs. There is stable red fluorescence of erythrocytes. On biopsy, a subepidermal bulla is seen, identical to that in PCT.

Treatment of CEP patients is strict avoidance of sunlight and, in some cases, splenectomy for the hemolytic anemia. Oral activated charcoal is efficacious, presumably impairing the absorption of endogenous porphyrins. Repeated transfusions of packed RBCs are given at volumes sufficient to maintain the

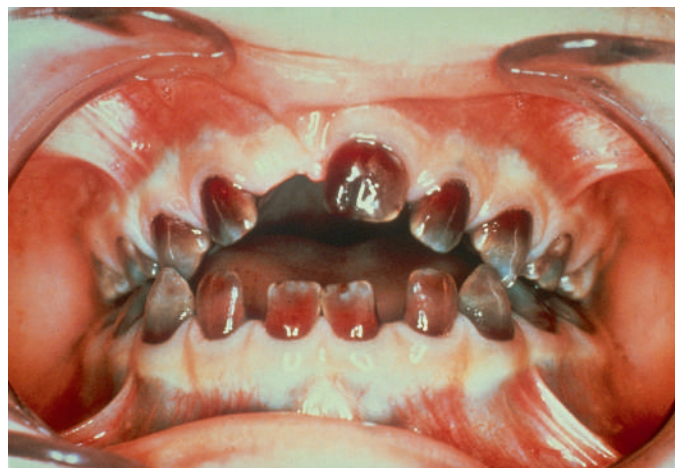

Fig. 26-11 Erythrodontia in congenital erythropoietic porphyria.

hematocrit level at 33%, turn off the demand for heme, and reduce porphyrin production. Bone marrow transplantation should be considered in severely affected children, typically those with transfusion requiring anemia or thrombocytopenia, but also those with progressive photomutilation and genotypes associated with poor outcome. Proteasome inhibitors and induced pluripotent stem cells are newer treatment opportunities.

Adult-onset CEP is extremely rare, presenting as a mild, photosensitive blistering disease resembling PCT. Usually, patients with CEP live into adulthood. Preauricular fibrosis with loss of earlobes occurs. A corticobasal syndrome resembling Parkinson’s disease can also occur.

### ACUTE INTERMITTENT PORPHYRIA

Acute intermittent porphyria (AIP), the second most common form of porphyria after PCT, is characterized by periodic attacks of abdominal pain (up to 95% of patients), GI disturbances (up to 90% of patients), pain and paresis (50–70%), seizures (10–20%), and mental symptoms (40–60%), including agitation, hallucinations, and depression. Skin lesions do not occur because the elevated porphyrin precursors are not photosensitizers. AIP is inherited as an autosomal dominant trait and is caused by a deficiency in porphobilinogen deaminase, which has 50% activity in affected persons. Only 10% of those with the genetic defect develop disease, but all may be at risk for primary liver cancer. AIP is particularly common in Scandinavia, especially Lapland. AIP usually presents after puberty in young adulthood, and women outnumber men 1.5:1–2:1.

Severe abdominal colic is most often the initial symptom of AIP. Patients usually have no abdominal wall rigidity, although tenderness and distention are present. Nausea, vomiting, and diarrhea or constipation accompany the abdominal pain. Peripheral neuropathy, mostly motor, is present. Severe pain in the extremities occurs. Optic atrophy, diaphragmatic weakness, respiratory paralysis, flaccid quadriplegia, facial palsy, and dysphagia are some of the many neurologic signs.

Attacks of AIP are triggered by certain medications and other conditions. These triggers frequently require increased hepatic heme synthesis (e.g., to make the cytochrome P450 enzymes required for metabolism of medications). Progesterone is one trigger, explaining the increased prevalence of AIP in women and the relationship to menses. Anticonvulsants, griseofulvin, rifampin, and sulfonamides are common drugs implicated in triggering AIP. The implicated medication list is constantly being modified as new drugs enter the market.

The website of the European Porphyria Initiative is the best source for an up-to-date list of both patients and health care providers ([www.porphyrria-europe.com](http://www.porphyrria-europe.com)). Crash dieting, cigarette smoking, infections, and surgery are additional triggers.

A diagnosis of AIP is established by finding elevated levels of urinary porphobilinogen and increased dALA in the plasma and urine during attacks. During remissions, the diagnosis can be confirmed in 88% of patients by detecting elevated urinary porphobilinogen. A normal test between attacks suggests less likelihood of subsequent attacks. Erythrocyte and fecal porphyrin levels are normal. AIP must be distinguished from VP, CP, and ALA dehydratase deficiency porphyria (ALAD), an autosomal recessive condition presenting in an almost identical manner to AIP. Increased dALA in the urine is found in ALAD patients and those with lead poisoning.

No specific treatment is available for AIP. It is important for the patient to avoid such precipitating factors as a wide variety of medications, including sex steroid hormones, and to maintain adequate nutrition. Glucose loading has been used extensively and appears to be beneficial in many cases. Hematin infusions, in the form of heme arginate, result in clinical improvement and a marked decrease in ALA and porphobilinogen excretion. Early treatment may ameliorate attacks. The phenothiazines (e.g., chlorpromazine) may be helpful for pain; opiates and propoxyphene are also useful for analgesia. Since 10% of patients with AIP die of hepatoma (without the development of cirrhosis), yearly ultrasound and alpha-fetoprotein determination should be undertaken in all AIP patients over age 50.

### TRANSIENT ERYTHROPORPHYRIA OF INFANCY (PURPURIC PHOTOTHERAPY-INDUCED ERUPTION)

Paller et al. reported seven infants exposed to 380–700 nm blue lights for the treatment of indirect hyperbilirubinemia who developed marked purpura in skin exposed to UV light. Extensive blistering and erosions occurred in one patient. Biopsies of the skin showed hemorrhage without epidermal changes in the cases associated with purpura, and a pauc-inflammatory, subepidermal bulla in the patient with blistering. The infants had all received transfusions. Elevated plasma coproporphyrins and protoporphyrins were found in the four infants examined. The pathogenesis is unknown.

**Allo G, et al:** Bone mineral density and vitamin D levels in erythropoietic protoporphyria. *Endocrine* 2013; 44:803.

**Arunachalam M, et al:** Scleroderma-like hands in a 16-year-old boy. *JAMA Dermatol* 2013; 149:969.

**Azak A, et al:** Pseudoporphyria in a hemodialysis patient successfully treated with oral glutamine. *Hemodial Int* 2013; 17:466.

**Badadams EL, et al:** Cascade testing of primary care blood samples with hyperferritinaemia identifies subjects with iron overload and porphyria cutanea tarda. *Ann Clin Biochem* 2014; 51:499.

**Balwani M, et al:** Erythropoietic protoporphyria, autosomal recessive. In Pagon RA, et al (eds): *GeneReview* 2013. [Epub.]

**Balwani M, et al:** Loss-of-function ferrochelatase and gain-of-function erythroid-specific 5-aminolevulinic synthase mutations causing erythropoietic protoporphyria and X-linked protoporphyria in North American patients reveal novel mutations and a high prevalence of X-linked protoporphyria. *Mol Med* 2013; 19:26.

**Bedel A, et al:** Metabolic correction of congenital erythropoietic porphyria with iPSCs free of reprogramming factors. *Am J Human Genet* 2012; 91:109.

**Bentley DP, Meek EM:** Clinical and biochemical improvement following low-dose intravenous iron therapy in a patient with erythropoietic protoporphyria. *Br J Haematol* 2013; 163:277.

**Berghoff AT, English JC:** Imatinib mesylate-induced pseudoporphyria. *J Am Acad Dermatol* 2011; 63:e14.

**Bishop DF, et al:** Molecular expression and characterization of erythroid-specific 5-aminolevulinic synthase gain-of-function mutations causing X-linked protoporphyria. *Mol Med* 2013; 19:18.

**Blouin JM, et al:** Therapeutic potential of proteasome inhibitors in congenital erythropoietic porphyria. *Proc Natl Acad Sci USA* 2013; 110:18238.

**Chan CC, Lin SJ:** Porphyria cutanea tarda. *N Engl J Med* 2011; 365:1128.

**Crawford RI, et al:** Transient erythroporphyria of infancy. *J Am Acad Dermatol* 1996; 35:833.

**DeGiovanni CV, Darley CR:** Pseudoporphyria occurring during a course of ciprofloxacin. *Clin Exp Dermatol* 2008; 33:109.

**Ergen EN, et al:** Is non-alcoholic steatohepatitis a predisposing factor to porphyria cutanea tarda? *Photodermatol Photoimmunol Photomed* 2013; 29:106.

**Erwin A, et al:** Congenital erythropoietic porphyria. In Pagon RA, et al (eds): *GeneReview* 2013. [Epub.]

**Frank J, Poblete-Gutiérrez P:** Delayed diagnosis and diminished quality of life in erythropoietic protoporphyria: results of a cross-sectional study in Sweden. *J Intern Med* 2011; 269:270.

**Frank J, et al:** Photosensitivity in the elderly—think of late-onset protoporphyria. *J Invest Dermatol* 2013; 133:1467.

**García-Martin P, et al:** Phototolerance induced by narrow-band UVB phototherapy in severe erythropoietic protoporphyria. *Photodermatol Photoimmunol Photomed* 2012; 28:261.

**Gibson GE, et al:** Coexistence of lupus erythematosus and porphyria cutanea tarda in 15 patients. *J Am Acad Dermatol* 1998; 38:569.

**Gonzalez-Estrada A, Garcia-Morillo JS:** Successful treatment of congenital erythropoietic porphyria using matched unrelated hematopoietic stem cell transplantation. *Mayo Clin Proc* 2014; 89:e11.

**Gonzalez-Estrada A, et al:** Sporadic porphyria cutanea tarda: treatment with chloroquine decreases hyperglycemia and reduces development of metabolic syndrome. *Eur J Intern Med* 2014; 25:e76.

**Graham-Brown MP, Ilchysyn A:** Development of acute phototoxic reaction during surgery in a patient with erythropoietic protoporphyria. *Clin Exp Dermatol* 2013; 38:566.

**Gyldenløve M, et al:** Pseudoporphyria: a case report. *J Eur Acad Dermatol Venereol* 2014; Mar 11. [Epub ahead of print.]

**Harms JH, et al:** An  $\alpha$ -melanocyte-stimulating hormone analogue in erythropoietic protoporphyria. *N Engl J Med* 2009; 360:306.

**Harms JH, et al:** Mitigating photosensitivity of erythropoietic protoporphyria patients by an agonistic analog of  $\alpha$ -melanocyte stimulating hormone. *Photochem Photobiol* 2009; 85:1434.

**Heithaus RE, Hogan R:** Unblinded by the lights. *N Engl J Med* 2013; 367:659.

**Hivnor C, et al:** Cyclosporine-induced pseudoporphyria. *Arch Dermatol* 2003; 139:1373.

**Holme SA, et al:** Seasonal palmar keratoderma in erythropoietic protoporphyria indicates autosomal recessive inheritance. *J Invest Dermatol* 2009; 129:599.

**Kapoor R, Johnson RA:** Porphyria cutanea tarda and hypertrichosis. *N Engl J Med* 2013; 369:1356.

**Katoulis AC, et al:** Pseudoporphyria associated with nonhemodialyzed renal insufficiency, successfully treated with oral *N*-acetylcysteine. *Case Rep Dermatol Med* 2013; 2013:271873.

**Katugampola RP, et al:** A management algorithm for congenital erythropoietic porphyria derived from a study of 29 cases. *Br J Dermatol* 2012; 167:888.

**Katugampola RP, et al:** Congenital erythropoietic porphyria: a single-observer clinical study of 29 cases. *Br J Dermatol* 2012; 167:901.

**Lenfestey A, et al:** Metformin-induced pseudoporphyria. *J Drugs Dermatol* 2012; 11:1272.

**Liu LU, et al:** Porphyria cutanea tarda, type II. In Pagon RA, et al (eds): *GeneReview* 2013. [Epub.]

**Livideanu CB, et al:** Late-onset X-linked dominant protoporphyria: an etiology of photosensitivity in the elderly. *J Invest Dermatol* 2013; 133:1688.

**Martínez Peinado C, et al:** Successful treatment of congenital erythropoietic porphyria using matched unrelated hematopoietic stem cell transplantation. *Pediatr Dermatol* 2013; 30:484.

**Massone C, et al:** Successful outcome of haemodialysis-induced pseudoporphyria after short-term oral *N*-acetylcysteine and switch to high-flux technique dialysis. *Acta Derm Venereol* 2006; 86:538.



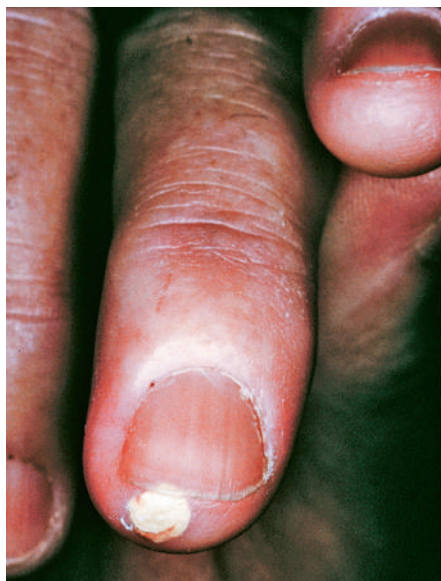- Mendez M:** A homozygous mutation in the ferrochelatase gene underlies erythropoietic protoporphyria associated with palmar keratoderma. *Br J Dermatol* 2009; 160:1330.
- Muñoz-Santos C, et al:** The association between porphyria cutanea tarda and diabetes mellitus: analysis of a long-term follow-up cohort. *Br J Dermatol* 2011; 165:486.
- Oh C, et al:** Pseudoporphyria secondary to narrowband UVB phototherapy for psoriasis. *Australas J Dermatol* 2006; 47:134.
- Okano J, et al:** Interferon treatment of PCT associated with chronic hepatitis type C. *Hepatogastroenterology* 1997; 44:525.
- Oshikawa Y, et al:** Photosensitivity and acute liver insufficiency in late-onset erythropoietic protoporphyria with a chromosome 18q abnormality. *Case Rep Dermatol* 2012; 4:144.
- Paller AS, et al:** Purpuric phototherapy-induced eruption in transfused neonates. *Pediatrics* 1997; 100:360.
- Pandya AG, et al:** Deferasirox for porphyria cutanea tarda. *Arch Dermatol* 2012; 148:898.
- Panton NA, et al:** Iron homeostasis in porphyria cutanea tarda: mutation analysis of promoter regions of *CP*, *CYBRD1*, *HAMP* and *SLC0A1*. *J Clin Pathol* 2013; 66:160.
- Pérez NO, et al:** Pseudoporphyria induced by imatinib mesylate. *Int J Dermatol* 2014; 43:e143.
- Perez-Bustillo A, et al:** Torsemide-induced pseudoporphyria. *Arch Dermatol* 2008; 144:812.
- Petersen AB, et al:** Zinc sulphate: a new concept of treatment of erythropoietic protoporphyria. *Br J Dermatol* 2012; 166:1121.
- Pham HP, et al:** Therapeutic plasma exchange in a patient with erythropoietic protoporphyria status post orthotopic liver transplantation as a bridge to hematopoietic stem cell transplantation. *J Clin Apher* 2014; 29:341.
- Pindzer VA, et al:** Homozygous variegate porphyria presenting with developmental and language delay in childhood. *Clin Exp Dermatol* 2013; 38:737.
- Quansah R, et al:** Hepatitis C- and HIV-induced porphyria cutanea tarda. *Am J Case Rep* 2014; 15:35.
- Santo Domingo D, et al:** Finasteride-induced pseudoporphyria. *Arch Dermatol* 2011; 147:747.
- Sarkany RP, et al:** Acquired erythropoietic protoporphyria as a result of myelodysplasia causing loss of chromosome 18. *Br J Dermatol* 2006; 155:464.
- Schanbacher CF, et al:** Pseudoporphyria. *Mayo Clin Proc* 2001; 76:488.
- Schneider-Yin X, et al:** Hepatocellular carcinoma in a variegate porphyria: a serious complication. *Acta Derm Venereol* 2010; 90:512.
- Schulenburg-Brand D, et al:** The cutaneous porphyrias. *Dermatol Clin* 2014; 32:369.
- Seager MJ, et al:** X-linked dominant protoporphyria: a new porphyria. *Clin Exp Dermatol* 2014; 39:35.
- Sharp MT, Horn TD:** Pseudoporphyria induced by voriconazole. *J Am Acad Dermatol* 2005; 53:341.
- Shieh S, et al:** Management of porphyria cutanea tarda in the setting of chronic renal failure: a case report and review. *J Am Acad Dermatol* 2000; 42:645.
- Sidorsky TI, et al:** Development of corticobasal syndrome in a patient with congenital erythropoietic porphyria. *Parkinsonism Relat Disord* 2014; 20:349.
- Singal AK, Anderson KE:** Variegate porphyria. In Pagon RA, et al (eds): *GeneReviews* 2013. [Epub.]
- Singal AK, et al:** Low-dose hydroxychloroquine is as effective as phlebotomy in treatment of patients with porphyria cutanea tarda. *Clin Gastroenterol Hepatol* 2012; 10:1402.
- Singal AK, et al:** Liver transplantation in the management of porphyria. *Hepatology* 2014; 60:1082.
- Sivaramkrishnan M, et al:** Narrowband ultraviolet B phototherapy in erythropoietic protoporphyria: a case series. *Br J Dermatol* 2014; 170:987.
- Spelt JM, et al:** Vitamin D deficiency in patients with erythropoietic protoporphyria. *J Inher Metab Dis* 2010; 33:S1.
- Tewari A, et al:** A case of extensive hyaline deposition in facial skin caused by erythropoietic protoporphyria. *Br J Dermatol* 2014; 171:412.
- Thom G, et al:** Leukocytoclastic vasculitis masking chronic vascular changes in previously undiagnosed erythropoietic protoporphyria. *J Cutan Pathol* 2013; 40:966.
- Tishler PV, Rosner B:** Treatment of erythropoietic protoporphyria with the oral sorbent colestipol: a proof-of-concept clinical trial. *J Am Acad Dermatol* 2013; 70:391.
- To-Figueras J, et al:** *ALAS2* acts as a modifier gene in patients with congenital erythropoietic porphyria. *Blood* 2011; 118:1443.
- Tolland JP, et al:** Voriconazole-induced pseudoporphyria. *Photodermatol Photoimmunol Photomed* 2007; 23:29.
- Tremblay J-F, et al:** Pseudoporphyria associated with hemodialysis treated with *N*-acetylcysteine. *J Am Acad Dermatol* 2003; 49:1189.
- Turnbull N, et al:** Diclofenac-induced pseudoporphyria: an under-recognized condition? *Clin Exper Dermatol* 2014; 39:348.
- Van Tuyl van Serooskerken AM, et al:** Digenic inheritance of mutations in the coproporphyrinogen oxidase and protoporphyrinogen oxidase genes in a unique type of porphyria. *J Invest Dermatol* 2011; 131:2249.
- Van Tuyl van Serooskerken AM, et al:** Extended haplotype studies in South African and Dutch variegate porphyria families carrying the recurrent *p.R59W* mutation confirm a common ancestry. *Br J Dermatol* 2012; 166:261.
- Vasconcelos P, et al:** Desferrioxamine treatment of porphyria cutanea tarda in a patient with HIV and chronic renal failure. *Dermatol Ther* 2014; 27:16.
- Verma A, et al:** Congenital erythropoietic porphyria: a case where symptoms have been precipitated by an unrelated anaemia. *Br J Dermatol* 2014; 171:422.
- Vieria FM, et al:** Precipitating factors of porphyria cutanea tarda in Brazil with emphasis on hemochromatosis gene (*HFE*) mutations: study of 60 patients. *An Bras Dermatol* 2013; 88:530.
- Wahlén S, et al:** Liver transplantation for erythropoietic protoporphyria in Europe. *Liver Transpl* 2011; 17:1021.
- Whatley SD, Badminton MN:** Role of genetic testing in the management of patients with inherited porphyria and their families. *Ann Clin Biochem* 2013; 50:204.

## CALCINOSIS CUTIS

Cutaneous calcification results from deposits of calcium and phosphorus in the skin. Calcinosis cutis is divided into five forms. Dystrophic calcinosis includes conditions in which calcification occurs in damaged tissue, usually collagen or elastic tissue. Serum calcium and phosphorus levels are normal. Dermatomyositis is a classic example of dystrophic calcinosis. Metastatic calcification refers to deposition of calcium resulting from elevated serum levels of calcium or phosphorus. Hyperparathyroidism is an example of this form of calcification. Iatrogenic and traumatic calcinosis is associated with medical procedures or occupational exposures that may involve both tissue damage and local elevated calcium concentrations. Idiopathic calcinosis cutis refers to the forms of cutaneous calcification of unknown cause with normal serum calcium. In osteoma cutis, true bone is formed in the skin. Calciophylaxis is discussed in Chapter 35.

## DYSTROPHIC CALCINOSIS CUTIS

The dystrophic type occurs in a preexisting lesion or inflammatory process. Systemic calcium metabolism is normal, and lesions affect the skin only. Dystrophic calcinosis cutis presents as small deposits of chalky granular material around the fingers and on the elbows, at areas of trauma. The deposits may spontaneously extrude from the skin. Histologically, they are localized to the dermis (or in the case of panniculitides, in the fat). The dystrophic form often occurs in limited scleroderma (the CREST syndrome: calcinosis cutis, Raynaud phenomenon, esophageal disorders, sclerodactyly, and telangiectasia) (Fig. 26-12). Pancreatic and lupus panniculitis typically demonstrate dystrophic calcification, but the process tends to remain microscopic. Patients with Werner syndrome and PCT may also develop calcifications within the scleroderma-like lesions.



**Fig. 26-12** Calcinosis cutis in CREST syndrome.

Calcinosis cutis occurs in about 10% of patients with dermatomyositis (DM), especially juvenile cases. Fingertip ulcers and disease duration are associated with calcinosis cutis. Autoantibodies to NXP-2 increase the risk for cutaneous calcinosis in DM by 15-fold. Calcification can occur in multiple forms, including: hard nodules or plaques in the subcutaneous or periarticular areas, tumors; deposits in the intermuscular fascia leading to decreased mobility; and as an exoskeleton.

Various benign and malignant neoplasms may develop calcification or ossification, with pilomatrixomas and pilar cysts most frequently reported. Nephrogenic systemic fibrosis, Hutchinson-Gilford progeria, and poikiloderma with neutropenia (Clericuzio type) may all be complicated by calcinosis cutis.

The treatment of dystrophic calcification is determined by the location, size/extent, and underlying condition. Limited surgical removal, as needed to control discomfort, can be very beneficial. Curetting out the calcium deposits around the fingers can bring dramatic relief to the patients with CREST and DM. Systemic therapies have not been consistently beneficial, with some patients having dramatic response, and the same treatment for the same disease having no effect in other patients. Bisphosphonates (alendronate, etidronate, pamidronate), diltiazem (30–180 mg/day), warfarin, anti-inflammatory agents, tumor necrosis factor (TNF) inhibitors, intravenous immune globulin (IVIG), thalidomide, and colchicine have all been used as single agents or in combination. Sodium thiosulfate, 10–25% by topical application and 12.5 mg/50 mL by injection, has reduced dystrophic calcifications in various areas. Eight patients with dystrophic calcification treated with lithotripsy had a decrease in size of the calcium deposits and a dramatic reduction in pain.

### METASTATIC CALCINOSIS CUTIS

Metastatic calcinosis cutis is a rare entity characterized by calcifications in the skin, elevated serum calcium, and sometimes hyperphosphatemia. It is often associated with bone loss or destruction, with the bone providing the source of the elevated serum calcium. Conditions associated with metastatic calcinosis include parathyroid neoplasms, primary hyperparathyroidism, chronic renal failure, hypervitaminosis D, sarcoidosis, and excessive intake of milk and alkali. Destruction of bone by osteomyelitis, leukemia, Paget's disease of the bone,

myeloma, and metastatic carcinoma may lead to elevated serum calcium and metastatic calcification. In calcinosis cutis with hyperparathyroidism, many skin manifestations are seen, with small, firm, white papules, about 1–4 mm in diameter, occurring symmetrically in the popliteal fossae, over the iliac crests, and in the posterior axillary lines. At times, metastatic calcinosis cutis localizes to areas of damaged elastic tissue (e.g., striae, solar elastosis).

The most common metabolic condition associated with metastatic calcification is renal failure. Usually, there is an elevated phosphorus level and secondary hyperparathyroidism, resulting in high calcium and phosphorus production and deposition of calcium phosphate in tissues. Less often, cutaneous calcification in renal disease can occur with normal serum calcium and phosphorus levels. Three forms of cutaneous calcification in renal disease have been described: tumoral calcinosis, calcifying panniculitis, and calciphylaxis. Tumoral calcinosis is a rare complication of renal disease. Managing the metabolic abnormalities may lead to resolution of the large deposits of calcium.

Often, calcifying panniculitis and calciphylaxis occur in the same patient at the same time, suggesting a common pathogenesis. Isolated, firm, indurated nodules, usually on the legs or thighs in the subcutaneous fat, have been called calcifying panniculitis. Usually, these are seen with the most severe complication of the abnormal calcium and phosphorus metabolism of renal disease, calciphylaxis. This life-threatening condition leads to livedo reticularis and ischemic tissue necrosis (see Chapter 35).

### IATROGENIC AND TRAUMATIC CALCINOSIS CUTIS

Medical procedures that may inadvertently introduce calcium into tissue, in association with tissue trauma, may lead to cutaneous calcification. This has been reported after extravasation of calcium chloride or calcium gluconate infusion and after electroencephalography or electromyography. The electrode paste is high in calcium, and the skin is traumatized during the procedure, leading to calcifications at the sites of electrode insertion. The most common setting is on the scalp of children. Lesions spontaneously resolve over months. Performing frequent heel sticks in neonates has led to similar lesions. Injections of low-molecular-weight calcium-containing heparins in patients with renal failure may result in calcification at the sites of injection. Frequent subcutaneous injection of interferon beta in the abdomen has resulted in localized calcification in the fat.

During liver transplantation, hypocalcemia can result from calcium chelation by the citrate in transfused blood products. Intravenous calcium infusions are regularly given. Calcifications on the upper extremities have been reported, occurring 1–3 weeks after transplantation and resolving over 6 months.

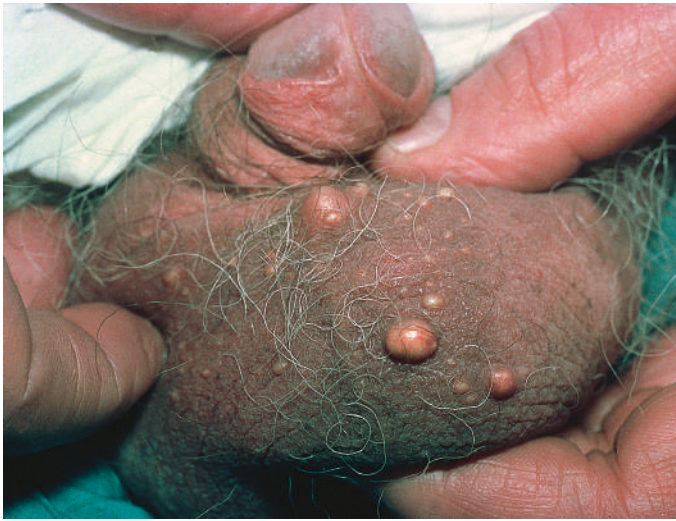Traumatic calcinosis may occur as a result of occupational exposure to calcium-containing materials, as in the cases reported in oil-field workers and coal miners. Exposure of the skin to cloth sacks of calcium chloride, limewater compresses, and refrigerant calcium chloride can all cause calcinosis cutis.

### IDIOPATHIC CALCINOSIS CUTIS

#### Idiopathic scrotal calcinosis

Idiopathic scrotal calcinosis is the most common form of idiopathic calcinosis cutis. Lesions present in young to middle-age adult men as multiple, asymptomatic, firm, round, yellow papules from several millimeters up to 1 cm in diameter





**Fig. 26-13** Scrotal calcinosis.

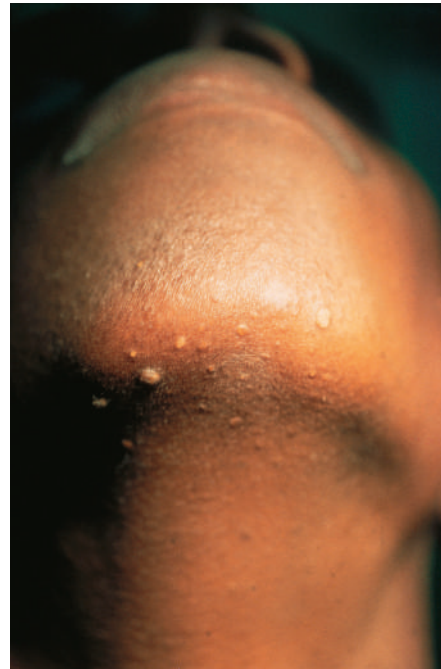(Fig. 26-13). The papules resemble infundibular follicular cysts. Similar lesions, usually 1 mm to several millimeters in size, may be seen rarely in girls or women on the labia majora. In men with scrotal lesions, similar lesions rarely will be found on the shaft of the penis, termed idiopathic calcinosis cutis of the penis. Calcinosis of the areola can have a similar appearance and is extremely rare. Histologically, localized deposits of calcium are surrounded by a foreign body reaction. At least some are calcified scrotal infundibular cysts. Why they have such a high proclivity to calcification at this anatomic location is unclear. Treatment is not required, but surgical removal cures individual lesions.

### Subepidermal calcified nodule and milia-like idiopathic calcinosis cutis

These two similar conditions are uncommon but distinct types of idiopathic calcinosis. Subepidermal calcified nodule occurs most frequently as one or a few lesions on the scalp or face of children (Fig. 26-14). Males outnumber females by almost 2:1, and the average age at onset is 7 years. Lesions present as fixed, uninfamed papules that closely resemble those of molluscum contagiosum with a central umbilication. The affected children usually do not have an underlying medical condition. A similar condition, milia-like idiopathic calcinosis cutis, has a wider distribution; eyelids, hands, feet, elbows, and knees are common sites. Two thirds of patients have Down syndrome. Treatment is not required, but surgical removal will cure any individual lesion.

### Tumoral calcinosis

Investigation of the rare cases of tumoral calcinosis, discovery of the causal genes, and development of animal models have led to improved understanding of the mechanisms of ectopic mineralization. Familial tumoral calcinosis has two genetic causes. Normophosphatemic familial tumoral calcinosis (NFTC) is seen in young adults, primarily African natives. Lesions are associated with antecedent trauma. The genetic cause is mutation in *SAMD9*. Hyperphosphatemic familial tumoral calcinosis (HFTC) is characterized by periarticular calcifications. Mutations in three genes have been described as causing this syndrome: fibroblast growth factor 23 (*FGF23*), *GALNT3*, and *KLOTHO*. Most patients present before the



**Fig. 26-14**  
Subepidermal  
calcified nodules.

second decade of life. Three quarters of these individuals have affected siblings. Multiple lesions predominate, and there is no preceding history of trauma. The serum calcium level is normal, but serum phosphorus and calcitriol levels are elevated.

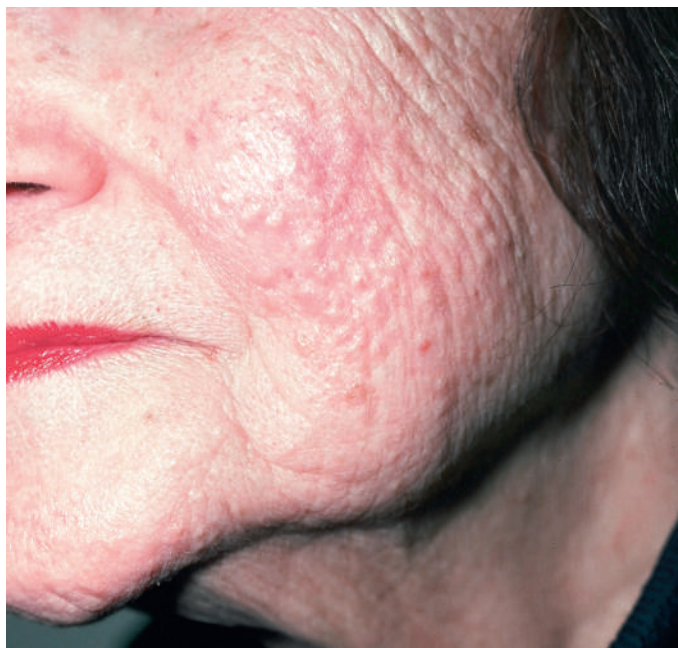Lesions in both types present as large subcutaneous masses of calcium overlying pressure areas and large joints, usually the hips, elbows, shoulders, or knees. Skin involvement, apart from the tumoral masses, is extremely rare but may occur as localized calcinosis cutis. The internal organs are not involved, and serum calcium levels are generally normal. Surgical excision has been the mainstay of therapy; however, recurrences are frequent after incomplete removal. Various dietary restrictions to lower calcium and phosphorus intake have shown some success. The combination of a phosphate binder and a carbonic anhydrase inhibitor, along with a low-phosphorus diet, led to dramatic improvement in one patient, allowing for surgical removal.

### OSTEOMA CUTIS

Bone formation within the skin may be primary, occurring in cases with no preceding lesion; metastatic, in cases associated with abnormalities of parathyroid metabolism; or dystrophic, in which ossification occurs in a pre-existing lesion or inflammatory process.

Primary osteoma cutis occurs in several clinically distinct disorders: Albright's hereditary osteodystrophy (AHO), pseudohypoparathyroidism (PHP), progressive osseous heteroplasia (POH), and widespread or single, platelike osteoma cutis (PLOC). Mutations in all four of these conditions occur in the *GNAS* gene.

Progressive osseous heteroplasia is a rare form of cutaneous ossification initially seen between birth and 6 months of age, often in the first month of life. Females are preferentially affected. Lesions begin as small papules that can coalesce to large plaques. Sometimes these plaques will have small, firm, calcified papules overlying them. Lesions are randomly distributed and may be unilateral or may involve only one anatomic area. There is no preceding trauma or inflammatory phase. Serum calcium, phosphorus, parathyroid hormone



**Fig. 26-15** Osteoma cutis. (Courtesy of Dr. Don Adler.)

(PTH), and calcitriol are normal, but alkaline phosphatase (ALP), lactate dehydrogenase (LDH), and creatine phosphokinase (CPK) may be elevated, indicating increased bone formation (ALP) or muscle destruction (CPK and LDH). Histologically, the lesions reveal intramembranous bone formation and can affect the soft tissues as well as skin. Only calcification without ossification may be found in superficial dermal biopsies, so a deep biopsy, including subcutaneous fat, may be required to confirm the diagnosis. The condition is progressive and can lead to serious sequelae, including ulceration, infection, and severe pain. Plate-like osteoma cutis occurs in newborns or young children, but also in adults. It is not associated with dysmorphic features or abnormalities of calcium or phosphorus metabolism, but shows intramembranous bone formation histologically. These disorders are most likely polar ends of a spectrum of disease; one family has been described with members having either condition. AHO is characterized by childhood development of intramembranous bone formation in the dermis and subcutaneous tissue (see Chapter 24). The cutaneous ossifications may be noted soon after birth and are usually multiple, small, superficial plaques that favor the scalp, hands, feet, periarticular regions, abdomen, and chest wall. Small lesions are of little consequence, but large subcutaneous masses may disrupt underlying structures. The patient may have characteristic dysmorphic features and pseudohypoparathyroidism or pseudopseudohypoparathyroidism. AHO also is associated with mutations of the *GNAS1* gene.

Multiple miliary osteomas of the face are clinically the most common form of osteoma cutis. These are usually seen in women (Fig. 26-15). The osteomas probably represent dystrophic ossification because they occur in patients with acne, are localized to the face, and are associated with acne scars. If oral tetracycline or minocycline is taken to treat the acne, the cutaneous osteomas may be pigmented or may fluoresce under Wood's light. Improvement with topical tretinoin, erbium:YAG laser, or incision, curettage, and primary closure has been reported.

**Aggarwal N, Shrestha S:** Images in clinical medicine. Dystrophic calcinosis cutis. *N Engl J Med* 2013; 368:e28.

**Altman JF, et al:** Treatment of primary miliary osteoma cutis with incision, curettage, and primary closure. *J Am Acad Dermatol* 2001; 44:96.

**Bair B, Fivenson D:** A novel treatment for ulcerative calcinosis cutis. *Cutis* 2011; 10:1042.

**Balin SJ, et al:** Calcinosis cutis occurring in association with autoimmune connective tissue disease. *Arch Dermatol* 2012; 148:455.

**Chabra IS, Obagi S:** Evaluation and management of multiple military osteoma cutis: case series of 11 patients and literature review. *Dermatol Surg* 2014; 40:66.

**Chantorn R, Shwayder T:** Poikiloderma with neutropenia: report of three cases including one with calcinosis cutis. *Pediatr Dermatol* 2012; 29:463.

**Chauhan NS, Sharma YP:** A child with skin nodules and extensive soft tissue calcification. *Br J Radiol* 2012; 85:193.

**Cheng PS, Lai FJ:** Sporotrichoid-like calcinosis cutis and calcifications in vessel walls and eccrine sweat glands following intravenous infusion and calcium gluconate. *Br J Dermatol* 2012; 166:892.

**Cho E, et al:** Subcorneal milia-like idiopathic calcinosis cutis: a rare presentation. *Ann Dermatol* 2013; 25:249.

**Cohen PR, Tschen JA:** Idiopathic calcinosis cutis of the penis. *J Clin Aesthet Dermatol* 2012; 5:23.

**Dominguez-Fernandez I, et al:** Calcinosis cutis following extravasation of calcium salts. *J Eur Acad Dermatol Venereol* 2008; 22:505.

**Eastham AB, et al:** Diffuse dystrophic calcinosis cutis of the scalp discoid lupus erythematosus and a systemic lupus erythematosus. *JAMA Dermatol* 2013; 149:246.

**Ehsani AH:** Calcinosis cutis complicating liver transplantation. *Dermatol Online J* 2006; 12:23.

**Elli FM, et al:** Screening for *GNAS* genetic and epigenetic alterations in progressive osseous heteroplasia: first Italian series. *Bone* 2013; 56:276.

**Falsey RR, Ackerman L:** Eruptive, hard cutaneous nodules in a 61-year-old woman. *JAMA Dermatol* 2013; 149:975.

**Fox GN, et al:** Acral milia-like idiopathic calcinosis cutis in a child with Down syndrome: report of a case, review of the literature, and description of dermoscopic findings. *Pediatr Dermatol* 2013; 30:263.

**Hershkovitz D, et al:** Functional characterization of *SAMD9*, a protein deficient in normophosphatemic familial tumoral calcinosis. *J Invest Dermatol* 2011; 131:662.

**Hoşcan MB, et al:** Massive idiopathic scrotal calcinosis. *Urology* 2012; 80:e71.

**Huh JY, et al:** Novel nonsense *GNAS* mutation in a 14-month-old boy with plate-like osteoma cutis and medulloblastoma. *J Dermatol* 2014; 41:319.

**Jang EJ, et al:** Milia-like idiopathic calcinosis cutis occurring in a toddler born as a premature baby. *Ann Dermatol* 2011; 23:490.

**Kim HS, et al:** Multiple subepidermal calcified nodules on the thigh mimicking molluscum contagiosum. *Pediatr Dermatol* 2011; 28:191.

**Kucukemre Aydin B, et al:** Osteoma cutis. *Pediatr Int* 2013; 55:257.

**Lee YW, et al:** Four cases of subepidermal calcified nodule on a child's sole. *Int J Dermatol* 2012; 51:316.

**Li Q, Uitto J:** Mineralization/anti-mineralization networks in the skin and vascular connective tissues. *Am J Pathol* 2013; 183:10.

**Lim PP, et al:** Calcinosis cutis following contact with calcium chloride solution. *Australas J Dermatol* 2012; 55:e66.

**Livingood M, Newman SA:** An unusual presentation of perforating metastatic calcinosis cutis. *Skinmed* 2013; 11:314.

**Lykoudis EG, et al:** Huge recurrent tumoral calcinosis needing extensive excision and reconstruction: report of a rare case and brief literature review. *Aesth Plast Surg* 2012; 36:1194.

**Macbeth AE, et al:** Calcified subcutaneous nodules: a long-term complication of interferon beta-1a therapy. *Br J Dermatol* 2007; 157:624.

**Martin J, et al:** Infantile osteoma cutis as a presentation of a *GNAS* mutation. *Pediatr Dermatol* 2012; 29:483.

**Myllylä RM, et al:** Multiple military osteoma cutis is a distinct disease entity: four case reports and review of the literature. *Br J Dermatol* 2011; 164:544.

**Nagai Y, et al:** Nephrogenic systemic fibrosis with multiple calcification and osseous metaplasia. *Acta Derm Venereol* 2008; 88:597.

**Nakamura S, et al:** Hutchinson-Gilford progeria syndrome with severe skin calcinosis. *Clin Exp Dermatol* 2007; 32:525.

**Nakamura Y, Muto M:** Subepidermal calcified nodule of the knee with transepidermal elimination of calcium. *J Dermatol* 2012; 39:965.



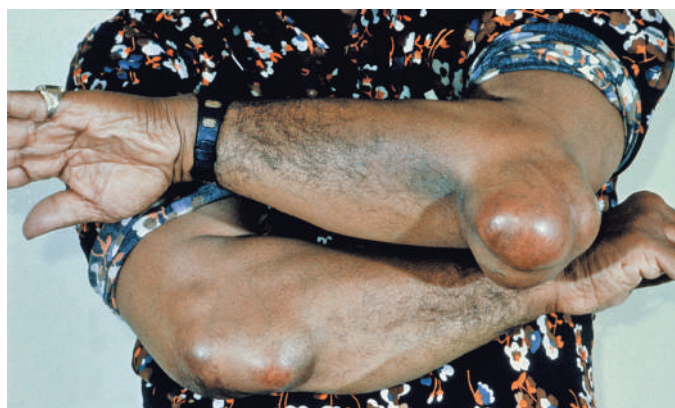- Ozuguz P, et al:** Multiple sub-epidermal calcified nodule mimicking eruptive xanthoma: a case report and review of the literature. *Indian J Dermatol* 2013; 58:406.
- Piombino L, et al:** A novel surgical approach to calcinosis cutis using a collagen-elastin matrix. *J Wound Care* 2013; 22:22.
- Reiter N, et al:** Calcinosis cutis. Part I. Diagnostic pathway. *J Am Acad Dermatol* 2011; 65:1.
- Reiter N, et al:** Calcinosis cutis. Part II. Treatment options. *J Am Acad Dermatol* 2011; 65:15.
- Riahi RR, Cohen PR:** Multiple military osteoma cutis of the face after initiation of alendronate therapy for osteoporosis. *Skinmed* 2011; 9:258.
- Schimmel RJ, et al:** GNAS-associated disorders of cutaneous ossification: two different clinical presentations. *Bone* 2010; 46:868.
- Shah V, Shet T:** Scrotal calcinosis results from calcification of cysts derived from hair follicles: a series of 20 cases evaluating the spectrum of changes resulting in scrotal calcinosis. *Am J Dermatopathol* 2007; 29:172.
- Shin BS, et al:** Recurrent milia-like idiopathic calcinosis cutis on the upper eyelid. *Ann Dermatol* 2013; 25:520.
- Shinjo SK, Souza FH:** Update on the treatment of calcinosis in dermatomyositis. *Rev Bras Reumatol* 2013; 53:211.
- Slavin RE, et al:** Tumoral calcinosis—a pathogenetic overview: a histological and ultrastructural study with a report of two new cases, one in infancy. *Int J Surg Pathol* 2012; 20:462.
- Smith GP:** Intra-dermal sodium thiosulfate for exophytic calcinosis cutis of connective tissue disease. *J Am Acad Dermatol* 2013; 69:e146.
- Sultan-Bichat N, et al:** Treatment of calcinosis cutis by extracorporeal shock-wave lithotripsy. *J Am Acad Dermatol* 2011;66:424.
- Talsania N, et al:** Platelike osteoma cutis. *J Am Acad Dermatol* 2009; 64:613.
- Tomazzini E, et al:** Vulvar calcinosis in childhood. *Int J Gynaecol Obstet* 2008; 103:263.
- Tomita H, et al:** Periorbital milia-like calcinosis. *Clin Exp Dermatol* 2012; 37:786.
- Valenzuela A, et al:** Identification of clinical features and autoantibodies associated with calcinosis in dermatomyositis. *JAMA Dermatol* 2014; 150:724.
- Vashi N, et al:** Acquired plate-like osteoma cutis. *Dermatol Online J* 2011; 17:1.
- Ward S, et al:** Three cases of osteoma cutis occurring in infancy: a brief overview of osteoma cutis and its association with pseudo-pseudohypoparathyroidism. *Australas J Dermatol* 2011; 52:127.
- Wolf EK, et al:** Topical sodium thiosulfate therapy for leg ulcers with dystrophic calcification. *Arch Dermatol* 2008; 144:1560.
- Yong AS, et al:** Vitamin D deficiency-associated calcinosis cutis, with secondary granulomatous changes. *Clin Exp Dermatol* 2013; 38:814.

## LIPID DISTURBANCES

### XANTHOMAS

Xanthomas are deposits of lipids in tissue. For the dermatologist, the important areas to look for lipid deposits are on the skin, tendon, and eyes. Xanthomas appear when abnormalities of lipid amount or processing occur in the body and thus are important markers of underlying dyslipidemia and potentially increased cardiovascular risk. The histologic features in all varieties of xanthoma are similar, characterized by the presence of numerous large, xanthoma or foam cells, which are phagocytes (fat-laden histiocytes). The cells may be multinucleated. In addition to the foam cells, giant cells of the Touton type occur. Clefts representing cholesterol and fatty acids dissolved by processing agents may be noted. Generally, a connective tissue reaction occurs around the nests of foam cells, and in old lesions, most of the foam cells are replaced with fibrosis. CD68 and adipophilin immunoperoxidase may aid in identifying foam cells.

In addition to inherited genetic defects of molecules involved in lipid homeostasis, systemic diseases (e.g., diabetes mellitus)



**Fig. 26-16** Tuberous xanthomas.

and medications (e.g., systemic retinoids) can also cause hyperlipidemias and result in xanthomas. The names of the various forms of cutaneous xanthomas are based on clinical morphology. Numerous genetic mutations have been identified, all of which result in hyperlipidemias. Several different genetic diseases may present with similar cutaneous xanthoma patterns, so referral to a “lipid” clinic is recommended for xanthoma patients with familial patterns of hyperlipidemia, as well as for those without an obvious medical cause for their dyslipidemia. The morphologies are relatively specific for the associated elevated lipid, however, with eruptive xanthomas seen with hypertriglyceridemia and other forms of xanthomas seen with increased cholesterol.

### Xanthoma tuberosum

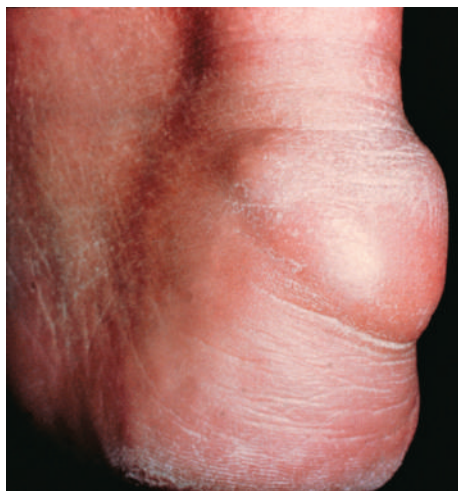Tuberous xanthomas are variously found as flat or elevated and rounded, grouped, yellowish or orange nodules located over the joints, particularly on the elbows and knees (Fig. 26-16). The lesions are indurated and tend to coalesce. They may also occur over the face, knuckles, toe joints, axillary and inguinal folds, and buttocks. Solitary lesions may be found. Early lesions are usually bright yellow or erythematous; older lesions tend to become fibrotic and lose their color. Pedunculated, fissured, and suppurative nodules may also be seen.

### Xanthoma tendinosum

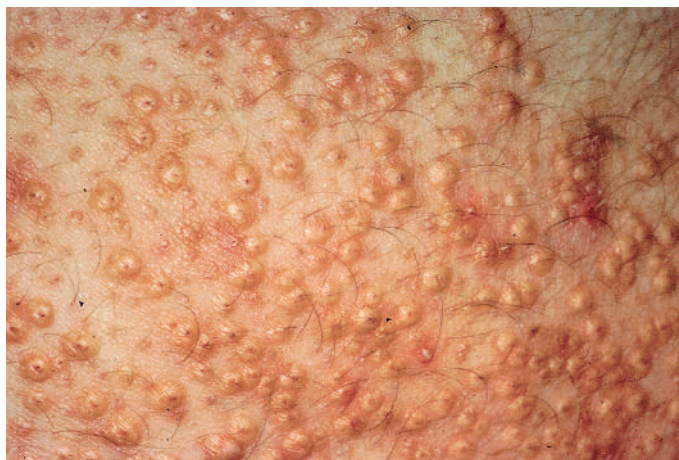Papules or nodules 5–25 mm in diameter are found in the tendons, especially in extensor tendons on the backs of the hands and dorsa of the feet and in the Achilles tendons (Fig. 26-17). These predominate in conditions with elevated low-density lipoprotein (LDL) cholesterol and can be seen in association with tuberous xanthomas and xanthelasma. The lesions also occur in obstructive liver disease, diabetes, myxedema, cerebrotendinous xanthomatosis, and phytosterolemia.

### Eruptive xanthoma

Xanthoma eruptivum consists of small, yellowish orange to reddish brown papules that appear in crops over the entire body (Fig. 26-18). The papules may be surrounded by an erythematous halo and may be grouped in various favored locations, such as the buttocks, extensor surfaces of the arms and thighs, knees, inguinal and axillary folds, and oral mucosa. Koebnerization may occur. Pruritus is variable. Eruptive xanthomas strongly suggest the presence of elevated triglyceride



**Fig. 26-17** Tendinous xanthomas.

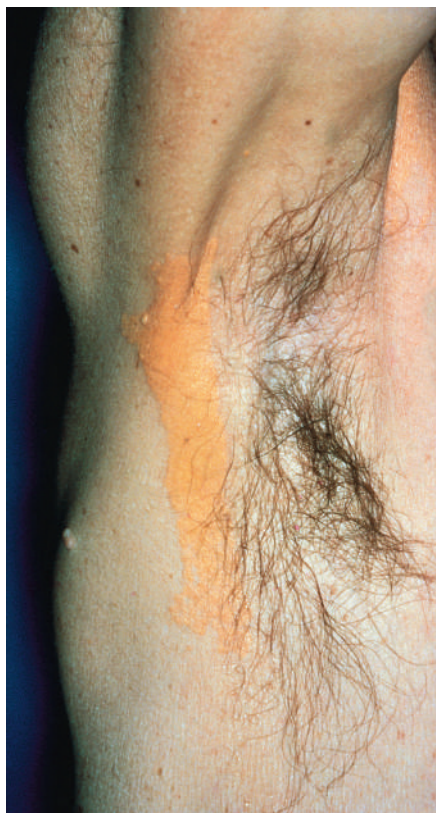

**Fig. 26-18** Eruptive xanthomas.

levels. Eruptive xanthomas are seen most often in poorly controlled type 2 diabetes mellitus but can also be seen in chronic renal failure, hypothyroidism, and treatment with estrogens, corticosteroids, or systemic retinoids.

### Xanthoma planum (plane xanthoma)

Plane xanthomas appear as flat macules or slightly elevated plaques with a yellowish tan or orange coloration of the skin spread diffusely over large areas. Characteristically, plane xanthomas may occur around the eyelids, neck, trunk, shoulders, or axillae (Fig. 26-19). These well-defined macular patches may be situated on the inner surface of the thighs and antecubital and popliteal spaces. Although these can be seen as a complication of elevated lipid levels, as in primary biliary cirrhosis, they are the one form of xanthoma that may not be associated with increased lipids. Normolipemic plane xanthomas are most frequently seen in patients with myeloma or a monoclonal gammopathy and less often in other myelodysplasias, such as mycosis fungoides, lymphoma, leukemia, and adult T-cell lymphoma/leukemia caused by human lymphotropic virus type 1 (HTLV-1). In myeloma and monoclonal gammopathy, the paraprotein complexes with LDL, and these complexes are phagocytosed by histiocytes in tissue, forming the plane xanthomas. In patients with monoclonal gammopathy-associated xanthoma, a reduced CH50 and reduced C4 (both in 80% of patients) are also usually detected, as well as a decreased C1



**Fig. 26-19** Plane xanthoma.

inhibitor level (50%) and the presence of a cryoglobulin (30%). Treatment of the underlying myelodysplasia may lead to resolution of the xanthomas.

A rare form of normolipemic xanthomatosis can occur in childhood termed normolipemic papuloeruptive xanthomatosis. Yellowish papules 2–5 mm in diameter occur on the face. They can coalesce to form large confluent plaques, especially on the face, nape of the neck, and axillae. Spontaneous involution occurs. It is unclear whether this is a rare disease in its own right or a severe variant of benign cephalic histiocytosis or papular xanthoma of childhood.

### Palmar xanthomas

Palmar xanthomas consist of nodules and irregular yellowish plaques involving the palms and flexural surfaces of the fingers (Fig. 26-20). Striated xanthomas appear as yellowish streaks that follow the distribution of creases of the palms and soles. These lesions are seen in familial dysbetalipoproteinemia, multiple myeloma, and primary biliary cirrhosis.

### Xanthelasma palpebrarum (xanthelasma)

Xanthelasma is the most common type of xanthoma. It occurs on the eyelids and is characterized by soft, chamois-colored or yellowish orange oblong plaques, usually near the inner canthi (Fig. 26-21). They usually appear between ages 40 and 60. The xanthelasmas vary from 2 to 30 mm in length and are usually symmetric. Xanthelasmas are typically seen without other forms of xanthomas and often with “normal” lipids. In 60% of xanthelasma patients, however, dyslipidemia is detected. New patients with xanthelasma should be evaluated with a full lipoprotein profile, as well as a careful history and physical examination. Consultation with a lipid clinic may be appropriate. Early (childhood) onset of xanthelasma



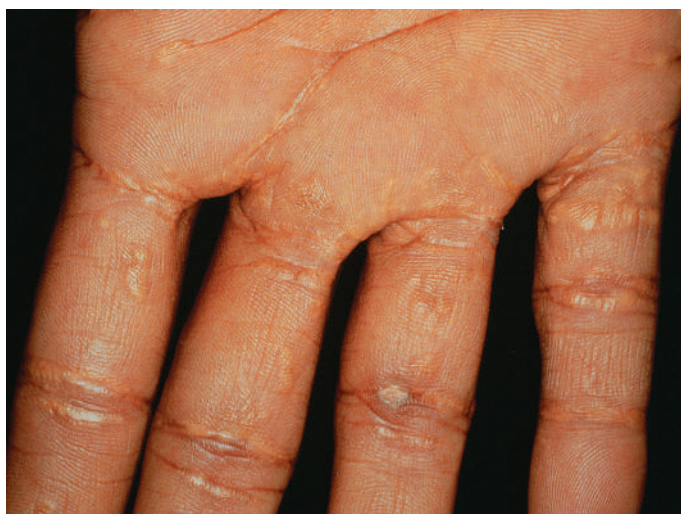

Fig. 26-20 Xanthomas of palmar striae.

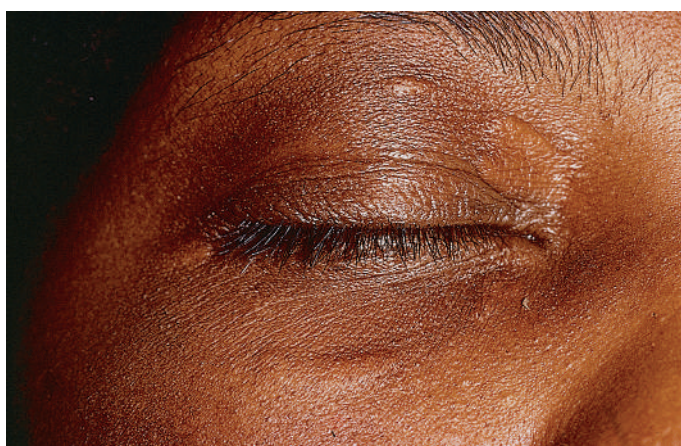

Fig. 26-21 Xanthelasma.

should suggest a hereditary lipid abnormality, especially familial hypercholesterolemia.

Treatment of xanthelasma is discussed here because of its uniqueness among the xanthomas, in that surgical therapy is often successful. The best method is surgical excision. The anesthetized lesion is grasped with mouse-tooth forceps and clipped off with scissors, and the skin edges are undermined and sutured. Excellent cosmetic results are obtained, even if the wound is not closed. Fulguration, trichloroacetic acid cauterization, and carbon dioxide (CO<sub>2</sub>), erbium:YAG, or Nd:YAG laser therapy are other methods. Complete removal of the lesions does not preclude the possibility that other new lesions will develop.

## PRIMARY HYPERLIPOPROTEINEMIAS

Frederickson classified hyperlipoproteinemias into six types on the basis of electrophoretic patterns, now called the World Health Organization International Classification of Diseases (WHO ICD) hyperlipoprotein (HLP) phenotypes, as follows.

- HLP1/type I: excess chylomicrons
- HLP2A/type IIa: excess  $\beta$ -lipoprotein
- HLP2B/type IIb: excess  $\beta$ -lipoprotein with slightly elevated very-low-density lipoproteins (VLDLs)
- HLP3/type III: increased intermediate-density (remnant) lipoproteins (IDLs)

- HLP4/type IV: increased pre- $\beta$ -lipoprotein
- HLP5/type V: increased pre- $\beta$ -lipoproteins and chylomicrons

Although this phenotypic classification has been useful for many years, advances in the understanding of lipoprotein metabolism and transport, coupled with new knowledge of molecular defects that result in these phenotypes, has led to the use of a genetic classification of lipoproteinemias. If two or more gene products are required at any point in lipoprotein metabolism, genetic deficiency of any molecule will lead to a similar phenotype. Multiple genotypes lead to the same phenotype.

Lipoprotein metabolism may be viewed according to the lipid source: an exogenous and an endogenous category. Exogenous lipids in the diet are absorbed and incorporated into triglyceride-rich chylomicrons. These are hydrolyzed by the action of lipoprotein lipase and certain cofactors, including apoprotein CII. The resulting remnants are taken up by the liver. Endogenously produced VLDLs are synthesized in the liver and, again through the action of lipoprotein lipase, are connected to cholesterol-rich IDLs and eventually into LDLs. These are then available for uptake by peripheral tissues, as well as by the liver. The uptake of LDL, IDL, and chylomicron remnants depends on specific receptors. Abnormalities of lipoprotein lipase, the apolipoproteins, cofactors, receptors, or stimulators or retarders of endogenous production or catabolism, whether on a genetic or a sporadic basis, may accelerate or block the pathway in different areas. If blockade occurs early and results in elevation of triglyceride-rich particles, eruptive xanthoma may result. If a defect occurs later in the pathway and cholesterol-rich particles accumulate, xanthelasma, tuberous xanthomas, and tendinous xanthomas should be expected, along with premature atherosclerotic cardiovascular disease.

### Lipoprotein lipase deficiency

Lipoprotein lipase deficiency causes HLP1 disease (chylomicronemia) early in life. It is rare, results from a homozygous defect, and is associated with highly elevated triglycerides. With levels above 1000 mg/dL, a high risk of pancreatitis and eruptive xanthomas exists (Fig. 26-22). As patients age, their VLDLs increase.

### Familial apoprotein CII deficiency

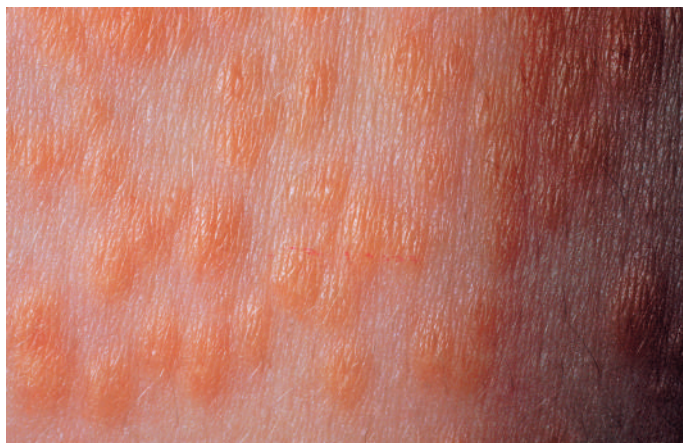Patients with the rare familial apoprotein CII deficiency lack lipoprotein lipase activator and have very high triglyceride levels, up to 10000 mg/dL. They are at risk for pancreatitis and eruptive xanthomas.

### Familial hypertriglyceridemia

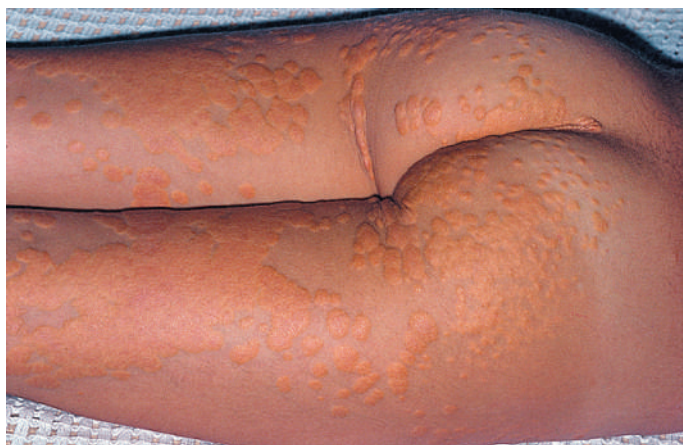In familial hypertriglyceridemia, increased hepatic production of VLDLs occurs. Eruptive xanthomas are common. Depending on the cause of this lipid pattern, the risk of atherosclerotic disease may vary.

### Familial hypercholesterolemia

Familial hypercholesterolemia (FH) has an HLP2A (Frederickson type IIa) lipid profile. It is caused by mutations in multiple genes, most often the LDL receptor. One in 500 persons carry



**Fig. 26-22** Eruptive xanthomas in lipoprotein lipase deficiency.



**Fig. 26-23** Xanthomas in homozygous familial hypercholesterolemia.

a mutation in this gene, and they present with planar, tendon, or tuberous xanthomas from age 30–60. Their LDL cholesterol is two to three times normal, and they have a twofold to threefold increase in cardiovascular disease. These persons are termed FH heterozygotes. If two FH heterozygotes marry, one in four children will be homozygous recessive for the LDL receptor and will present in childhood (teens or early twenties) with xanthomas, LDL cholesterol four to six times normal, and cardiovascular disease and aortic stenosis. Homozygous FH patients may have large xanthelasmas (xanthomatous pseudospectacles) and xanthomas of the interdigital web spaces and the gluteal cleft (Fig. 26-23).

## SECONDARY HYPERLIPOPROTEINEMIA

### Obstructive liver disease (xanthomatous biliary cirrhosis)

This type of hyperlipoproteinemia shows an increase in serum phospholipid and cholesterol levels, giving a type II lipoprotein pattern. Xanthomatous biliary cirrhosis is caused by the presence of lipoprotein X, which is secreted by the liver in cholestasis. Lipoprotein X has the ability to carry large quantities of free cholesterol and phospholipids. The triglycerides are not elevated, and the plasma is clear, showing no chylomicrons.

The xanthomatous lesions are plane xanthomas, with lesions on the face, flexor surfaces of the extremities, and trunk. Striate

palmar and plantar lesions and xanthelasmas are also seen. Tuberous xanthomas may occur. Pruritus is extremely severe. Hepatomegaly and jaundice are present. Cholestyramine can help in allaying pruritus.

Alagille syndrome is a congenital disorder characterized by intrahepatic bile ductular atresia, patent extrahepatic bile ducts, a characteristic facies (prominent forehead, deep-set eyes, straight nose, and small, pointed chin), cardiac murmur, vertebral and ocular abnormalities, low intelligence, and hypogonadism. It is an autosomal dominant inherited condition. There is persistent cholestasis early in life, with pruritus and hyperbilirubinemia. Lipid levels increase by age 2 years, and planar or papular xanthomas may occur. Alagille syndrome is a treatable condition, with cholestyramine and fat-soluble vitamins leading to long-term improvement.

## Pancreatitis

Hyperlipidemia in the hyperchylomicronemic syndromes (types I and V) may cause pancreatitis; it may be recurrent, and pancreatic necrosis and death may occur. Alternatively, pancreatitis (perhaps initiated by ethanol) may cause type I or V hyperlipoproteinemia by inducing insulin deficiency and a relative lack of lipoprotein lipase activity. A triglyceride level of 1000 mg/dL is required for pancreatitis to occur in the setting of hypertriglyceridemia. The amylase may be normal, but the lipase will be elevated.

## Medication-induced hyperlipoproteinemia

Estrogens, by decreasing lipoprotein lipase activity and increasing VLDL synthesis, may cause HLP1 or HLP5 patterns. Eruptive xanthomas may occur. Oral prednisone may induce insulin resistance and cause HLP4 or HLP5 patterns to develop. Oral retinoids, indomethacin, protease inhibitors for HIV, and olanzapine may also cause eruptive xanthomas through hypertriglyceridemia.

## Cerebrotendinous xanthomatosis

Cerebrotendinous xanthomatosis is a rare autosomal recessive disease caused by an accumulation of cholestanol in plasma lipoproteins, brain, and xanthomatous tissue. The underlying abnormality is a mutation in the sterol 27-hydroxylase gene (*CYP27A1*) in the mitochondria, leading to incomplete oxidation of cholesterol to bile acids. As a result, cholestanol, an intermediate, accumulates in tendons, brain, heart, lungs, and the lens of the eye. The disorder is characterized by prominent tendinous xanthomas, especially of the Achilles tendons (not present in all patients), macroglossia, progressive neurologic dysfunction in many forms, infantile diarrhea, developmental cataracts, and atherosclerotic coronary artery disease. Plasma cholestanol is elevated and can exceed more than 10 times normal levels. Patients with cerebrotendinous xanthomatosis are treated with chenodeoxycholic acid, and early treatment can prevent the progressive neurologic impairment.

## Sitosterolemia (phytosterolemia)

In sitosterolemia, a rare autosomal recessive disorder, plasma plant sterols are extremely elevated (>30 times normal). This disorder is caused by mutations in the genes encoding the ABCG5 and ABCG8 transporters, which are expressed only in the intestine and liver. In the intestine, they pump plant sterols



and cholesterol out of intestinal cells back into the lumen of the gut, limiting sterol and cholesterol absorption. In the liver, they pump plant sterols into the bile, aiding in their excretion. Absence of either of these genes results in increased absorption and decreased excretion of plant sterols, leading to their accumulation in the body. Patients develop tendinous xanthomas, xanthelasma, and tuberous, intertriginous, and palmar xanthomas. The diagnosis of sitosterolemia should be considered in any child or adolescent with xanthomas and a low LDL cholesterol (<130–400). It can also present as dietary-responsive hypercholesterolemia in infancy. Phytosterolemia can also mimic familial hypercholesterolemia in the adult because most patients also have type IIa hyperlipoproteinemia and accelerated atherosclerosis due to the enhanced absorption of cholesterol. Treatment is dietary restriction of plant sterols, cholesterol, and some shellfish (clam, oysters, scallops) whose sterols are also hyperabsorbed. In addition, bile sequestrants (chenodeoxycholic acid) can be used. Ezetimibe, an inhibitor of NPC1L1 (Niemann-Pick C1-like 1), inhibits absorption of plant sterols and can be effective in reducing plasma sterol levels.

### Verruciform xanthoma

Verruciform xanthoma (VX) is an uncommon lesion that occurs as a reddish orange or paler hyperkeratotic plaque or papillomatous growth with a pebbly or verrucous surface. The most common site is the oral mucosa. VX has also been reported on other mucosal surfaces, genitalia, lower extremities (Fig. 26-24), and elsewhere. On the external genitalia in men, the lesions frequently resemble condylomata acuminata and are not associated with any other condition. Disorders with damage of the papillary dermis have been associated with VX, including recessive dystrophic epidermolysis bullosa, lymphedema, and GVHD. Similarly, vulvar VX have been associated with lichen sclerosus, lichen planus, Paget's disease, and radiodermatitis. Additionally, VX has been reported in a patient with psoriatic lesions undergoing PUVA therapy and in psoriasiform skin lesions in an HIV-positive patient. Histologically, there is acanthosis without atypia, parakeratosis, and xanthoma cells in the papillary dermis. Epidermal nevus-like lesions in CHILD syndrome (congenital hemidysplasia with ichthyosiform erythroderma and limb defects) have histologic characteristics of VX. In a small percentage of VX patients, a mutation in the *NSDHL* gene ( $\beta$ -hydroxysteroid dehydrogenase) has been found. This gene is also mutated in CHILD syndrome, explaining why it and VX share the same histology. In one child, a genital VX responded to topical imiquimod treatment.

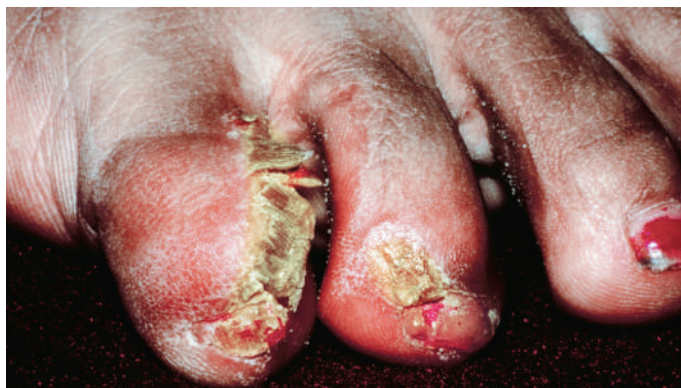

Fig. 26-24 Verruciform xanthoma.

### Familial $\alpha$ -lipoprotein deficiency (hypoalphalipoproteinemia, Tangier disease)

Tangier disease is caused by mutations in the cell membrane protein ABCA1, which mediates the secretion of excess cholesterol from cells into the HDL metabolic pathway. This results in a profound deficiency of HDL and accumulation of cholesterol in tissue macrophages. The characteristic clinical finding is enlarged yellow tonsils from accumulation of lipid in this localized area. Xanthomas do not occur, but there is diffuse accumulation of cholesterol esters in the skin as well as in the intestines, thymus, bone marrow, lymph nodes, and spleen. Peripheral neuropathy, splenomegaly (with thrombocytopenia), and premature coronary artery disease are other features of Tangier disease.

**Björkhem I:** Cerebrotendinous xanthomatosis. *Curr Opin Lipidol* 2013; 24:283.

**Blankenship DW, et al:** Verruciform xanthoma of the upper extremity in the absence of chronic skin disease or syndrome: a case report and review of the literature. *J Cutan Pathol* 2013; 40:745.

**Boyd AS, Roffwarg D:** Cutaneous verrucous xanthoma in a bone marrow transplant recipient with recessive dystrophic epidermolysis bullosa. *Pediatr Dermatol* 2013; 30:480.

**Broeshart JH, et al:** Normolipemic plane xanthoma associated with adenocarcinoma and severe itch. *J Am Acad Dermatol* 2003; 49:119.

**Brown CA, et al:** Tuberous and tendinous xanthomata secondary to ritonavir-associated hyperlipidemia. *J Am Acad Dermatol* 2005; 52:S86.

**Burnside NJ, et al:** Type III hyperlipoproteinemia with xanthomas and multiple myeloma. *J Am Acad Dermatol* 2005; 53:S281.

**Chung HG, et al:** CD 30 (Ki-1)-positive large-cell cutaneous T-cell lymphoma with secondary xanthomatous changes after radiation therapy. *J Am Acad Dermatol* 2003; 48:S28.

**D'Acunto C, et al:** Xanthelasma palpebrarum: a new adverse reaction to intradermal fillers? *Br J Dermatol* 2013; 168:437.

**Day A, et al:** Cardiovascular profile of xanthelasma palpebrarum. *Biomed Res Int* 2013; 2013:932863.

**Erkan E:** Rebuttal to "ezetimibe treatment should be considered for patients with sitosterolemia." *Pediatr Nephrol* 2014; 29:1471.

**Fite C, et al:** Vulvar verruciform xanthoma. *Arch Dermatol* 2011; 147:1087.

**Fujimoto N, et al:** Ultraviolet irradiation may generate plane xanthomas on mycosis fungoides. *Br J Dermatol* 2013; 168:213.

**Fujimoto N, et al:** Verruciform xanthoma results from epidermal apoptosis with galectin-7 overexpression. *J Eur Acad Dermatol Venereol* 2013; 27:922.

**Garcia MA, et al:** Alagille syndrome: cutaneous manifestations in 38 children. *Pediatr Dermatol* 2005; 22:11.

**Geyer AS, et al:** Eruptive xanthomas associated with protease inhibitor therapy. *Arch Dermatol* 2004; 140:617.

**Girish MP, Gupta MD:** Xanthomatous pseudospectacles in familial hypercholesterolemia. *N Engl J Med* 2005; 352:2424.

**Gregorious S, et al:** Treatment of mycosis fungoides with bexarotene results in remission of diffuse plane xanthomas. *J Cutan Med Surg* 2013; 17:52.

**Guo Y, et al:** Successful treatment of verruciform xanthomas with imiquimod. *J Am Acad Dermatol* 2013; 69:e184.

**Helm TN, et al:** Verruciform xanthomas with porokeratosis-like features but no clinically apparent lymphedema. *J Cutan Pathol* 2012; 39:887.

**Huang HY, et al:** Normolipemic papuloeruptive xanthomatosis in a child. *Pediatr Dermatol* 2009; 26:360.

**Joshi R, Ovhal A:** Verruciform xanthoma: report of five cases. *Indian J Dermatol* 2012; 57:479.

**Kose R:** Treatment of large xanthelasma palpebrarum with full-thickness skin grafts obtained by blepharoplasty. *J Cutan Med Surg* 2013; 17:197.

**Kulkarni ML, et al:** Cerebrotendinous xanthomatosis: an early diagnosis by biochemical tests. *Indian J Pediatr* 2014; 81:840.

**Kwiterovich PO:** Diagnosis and management of familial dyslipoproteinemias. *Curr Cardiol Rep* 2013; 15:371.

**Lee HY, et al:** Outcomes of surgical management of xanthelasma palpebrarum. *Arch Plast Surg* 2013; 40:380.

**Li SG:** Images in clinical medicine. Familial hypercholesterolemia. *N Engl J Med* 2009; 360:1885.

**Mehra S, et al:** A novel somatic mutation of the  $\beta$ -hydroxysteroid dehydrogenase gene in sporadic cutaneous verruciform xanthoma. *Arch Dermatol* 2005; 141:1263.

**Mignarri A, et al:** A suspicion index for early diagnosis and treatment of cerebrotendinous xanthomatosis. *J Inherit Metab Dis* 2014; 37:421.

**Park JH, et al:** Sitosterolemia presenting with severe hypercholesterolemia and intertriginous xanthomas in a breastfed infant: case report and brief review. *J Clin Endocrinol Metab* 2014; 99:1512.

**Park JS, et al:** Hepatic ABC transporters and triglyceride metabolism. *Curr Opin Lipidol* 2012; 23:196.

**Rhynne J, et al:** Multiple splice defects in *ABCA1* cause low HDL-C in a family with hypoalphalipoproteinemia and premature coronary disease. *BMC Med Genet* 2009; 10:1.

**Robinson MR, Meehan SA:** Verruciform xanthoma. *Cutis* 2013; 91:272.

**Rosmaninho A, et al:** Diffuse plane xanthomatosis associated with monoclonal gammopathy. *An Bras Dermatol* 2011; 86:S50.

**Ryu DJ, et al:** Verruciform xanthoma of the palatal gingiva: a report of two cases. *J Korean Assoc Oral Maxillofac Surg* 2013; 39:292.

**Shirdel A, et al:** Diffuse normolipaemic plane xanthomatosis associated with adult T-cell lymphoma/leukaemia. *J Eur Acad Dermatol Venereol* 2008; 22:1252.

**Sinnott BP, Mazzone T:** Tuberous xanthomas associated with olanzapine therapy and hypertriglyceridemia in the setting of a rare apolipoprotein E mutation. *Endocr Pract* 2006; 12:183.

**Sopena J, et al:** Disseminated verruciform xanthoma. *Br J Dermatol* 2004; 151:717.

**Szalat R, et al:** Pathogenesis and treatment of xanthomatosis associated with monoclonal gammopathy. *Blood* 2011; 118:3777.

**Teixeira V, et al:** Verruciform xanthomas: report of two cases. *Dermatol Online J* 2012; 18:10.

**Tsuang W:** Hypertriglyceridemic pancreatitis: presentation and management. *Am J Gastroenterol* 2009; 104:984.

**Tsubakio-Yamamoto K, et al:** Current therapy for patients with sitosterolemia: effect of ezetimibe on plant sterol metabolism. *J Atheroscler Thromb* 2010; 17:891.

**Zhao Y, et al:** 1064-nm Q-switched Nd:YAG laser in an effective and safe approach to treat xanthelasma palpebrarum in Asian population. *J Eur Acad Dermatol Venereol* 2014; Jun 9. [Epub ahead of print.]

## NIEMANN-PICK DISEASE

Niemann-Pick disease is a rare autosomal recessive condition that has three recognized subtypes. The disorder was originally described in Ashkenazi Jews. Type A and type B are both caused by mutations in the acid sphingomyelinase gene (*SMPD1*). Type A is more severe, presents in infancy with neurovisceral disease, and is often fatal. Type B is purely visceral (nonneurologic), and survival into adulthood is characteristic. Skin lesions in patients with Niemann-Pick disease types A and B include xanthomas (skin-colored to tan papules) and yellow-brown induration of the skin. Histologically, foamy histiocytes are found, which on electron microscopy have characteristic cytoplasmic inclusions. Niemann-Pick disease type C is caused by mutations in the *NPC1* and *NPC2* genes, which are involved in endosomal-lysosomal cholesterol trafficking. Type C is a neurovisceral disease with a variable age of onset and neurodegenerative course. Patients may present from the perinatal period to adulthood. Cholestatic jaundice is characteristic. Early-onset disease is often associated with severe neurologic disease and death before age 5. Patients with late-infantile and juvenile forms have neurologic disease. Patients with the adult form of type C may demonstrate visceral involvement and psychiatric and cognitive disorders. Death occurs before age 50.

**Grasko Y, et al:** A novel missense *SMPD1* gene mutation, *T460P*, and clinical findings in a patient with Niemann-Pick disease type B presenting to a lipid disorders clinic. *Ann Clin Biochem* 2014; 51(Pt 5):615.

**Neefjes J, van der Kant R:** Stuck in traffic: an emerging theme in diseases of the nervous system. *Trends Neurosci* 2014; 37:66.

**Stern G, et al:** Niemann-Pick's and Gaucher's diseases. *Parkinsonism Relat Disord* 2014; 2051:S143.

**Teixeira VB, et al:** Generalized lichen nitidus in a boy with Niemann-Pick disease type B. *An Bras Dermatol* 2013; 88:977.

## GAUCHER'S DISEASE

Although rare, Gaucher's disease is the most common lysosomal storage disease. It is an autosomal recessive disorder caused by insufficient activity of the lysosomal enzyme acid  $\beta$ -glucosidase (glucocerebrosidase, GBA, glucosylceramidase). The disease occurs most frequently among Ashkenazi Jews. Approximately 1 in 20 carry the defective gene. Lysosomal accumulation of glucosylceramide, the substrate of GBA in macrophages, causes the disease manifestations. In rare cases, Gaucher's disease is caused by mutations in the prosaposin gene, which encodes the saposin C activator protein that is necessary for optimal activity of  $\beta$ -glucosidase. Gaucher cells are identified histologically as large macrophages, 20–100  $\mu$ m in diameter, with one nucleus or a few small nuclei, and pale cytoplasm that stains faintly for fat but is PAS positive.

Gaucher's disease occurs at any age, but three types are recognized: type 1 (adult form), without neurologic involvement; type 2, the infantile form, with acute early neurologic manifestations; and type 3, the juvenile chronic neuropathic form. Some type 2 patients have congenital ichthyosis that precedes neurologic manifestations, and some are born with a collodion membrane. Epidermal ultrastructural and biochemical abnormalities occur in all type 2 patients. Hepatosplenomegaly, osteopenia/osteoporosis of the long bones, pinguiculae of the sclera, and a distinctive bronze coloration of the skin from melanin characterize the adult type. A deeper pigmentation may extend from the knees to the feet (Fig. 26-25). This is often caused by hemosiderin and may be accompanied by thrombocytopenia and splenomegaly.

The diagnosis is confirmed by DNA testing for the affected gene.

Therapy for Gaucher's disease now consists of enzyme replacement therapy (ERT) with intravenous mannose-terminated glucocerebrosidase. Only type 1 and type 3 patients are treated; ERT does not benefit type 2 patients. ERT is effective in preventing visceral disease in all type 1 and type 3 patients and reverses and prevents most symptoms in type 1 patients. Bone marrow transplantation performed before neurologic deficits occur has a high mortality rate (20–50%),

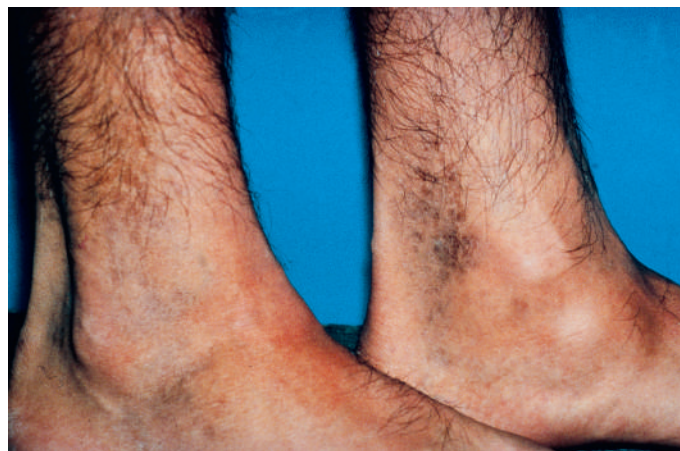

Fig. 26-25 Pigmentation of the lower leg/Dr. Gaucher's disease.



but when successful, it has halted neurologic progression. ERT is successful in treating some of the manifestations of the adult form (Gaucher's disease type 1) but is limited by cost. Substrate reduction therapy using the glycolipid synthesis inhibitor *N*-butyldeoxynojirimycin (miglustat) is also available.

The intense study of Gaucher's disease has led to two interesting findings. More than 15% of adult patients with Gaucher's disease have monoclonal gammopathy, and about 20% of these patients have an associated myelodysplasia (myeloma or lymphoma). More than 7% of adult Gaucher's disease patients will develop myeloma. Heterozygous carriers of GBA mutations are frequently found in patients with Parkinson's disease. Parkinson's disease is associated with certain "pathogenic" variant GBA mutations.

**Grabowski GA:** Phenotype, diagnosis, and treatment of Gaucher's disease. *Lancet* 2008; 372:1263.

**Grosbois B, et al:** Gaucher disease and monoclonal gammopathy: a report of 17 cases and impact of therapy. *Blood Cells Mol Dis* 2009; 43:138.

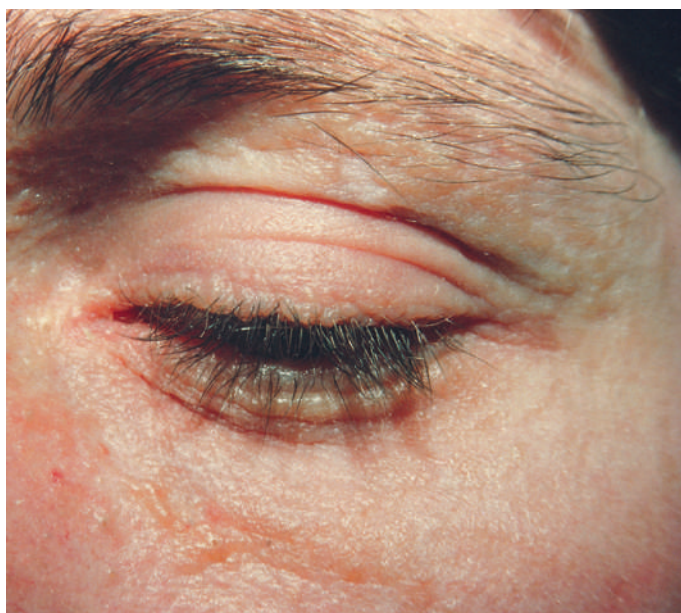**Hughes DA:** Enzyme, substrate, and myeloma in Gaucher disease. *Am J Hematol* 2009; 84:199.

**Mignot C, et al:** Gaucher disease. *Handb Clin Neurol* 2013;113:1709.

**Rosenbaum H, et al:** Hypercoagulability, Parkinsonism, and Gaucher disease. *Semin Thromb Hemost* 2013; 39:928.

## LIPOID PROTEINOSIS

Also known as Urbach-Wiethe disease and hyalinosis cutis et mucosae, lipoid proteinosis is a rare autosomal recessive condition that usually presents in infancy with a hoarse cry or voice. Mucosal lesions include yellowish white infiltrative deposits on the inner surface of the lips, undersurface of the tongue, fauces, and uvula. Inability to protrude the "woody" tongue because of frenulum shortening is characteristic. Xerostomia may occur. In childhood, beaded eyelid papules are seen. Uveitis and hyaline deposits on and in the eye may develop. Waxy, yellow papules and nodules with generalized skin thickening occur (Fig. 26-26). Mechanical friction leads to hyperkeratosis of the hands, elbows, knees, buttocks, and axillae. Acral hyperkeratotic papules occur in about 20%



**Fig. 26-26** Papules of the eyelid in lipoid proteinosis. (Courtesy of Dr. Eric Krause.)

of patients and have been described as "verrucous." In fact, in some patients, these lesions are induced by human papillomavirus (HPV). In one patient with lipoid proteinosis, epidermodysplasia verruciformis was diagnosed. Minor trauma leads to bullae that heal with pocklike or acnelike scars, especially on the face (Fig. 26-27). This may be related to the increased risk for bacterial skin infections in these patients. Scalp involvement may lead to mild loss of hair. Neurologic sequelae include epilepsy, dystonia, and cognitive impairments.

Distinctive histologic features include extreme dilation of the blood vessels, thickening of the vessel walls, progressive hyalinization of sweat glands, and infiltration of the dermis and subcutaneous tissue with extracellular hyaline deposits. Normal skin and mucous membranes also show changes of endothelial proliferation of the subpapillary vessels and a homogeneous thickening of the walls of the deeper vessels. Type IV collagen and laminin are increased around blood vessels.

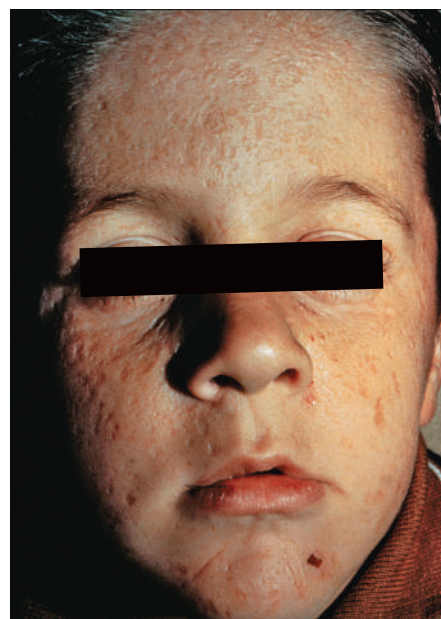Lipoid proteinosis is caused by mutations in the extracellular matrix protein 1. This protein binds to heparin sulfate proteoglycans, which are also the binding substances for HPV, perhaps explaining the frequency of HPV infection. Differentiation from erythropoietic protoporphyria may be difficult, especially histologically.

Numerous patients with lipoid proteinosis have been treated with systemic retinoids with positive results. A dose of about 0.5 mg/kg of acitretin is well tolerated and effective. Hoarseness improves in most patients, palmar and plantar hyperkeratosis is reduced, and patients may note reduction in skin blisters. Oral ulcerations improve. Earlier treatment (before age 11) was associated with a better response. Histologically, the epidermis is less thick, but the hyaline deposition is unchanged. Although death from respiratory obstruction occasionally occurs in infancy, the disease is otherwise compatible with a normal life span.

**Bakry OA, et al:** Two Egyptian cases of lipoid proteinosis successfully treated with acitretin. *J Dermatol Case Rep* 2014; 1:29.

**Dertlioğlu SB, et al:** Demographic, clinical, and radiologic signs and treatment responses of lipoid proteinosis patients: a 10-case series from Şanlıurfa. *Int J Dermatol* 2014; 53:516.

**O'Blenes C, et al:** Epidermodysplasia verruciformis in lipoid proteinosis: case report and discussion of pathophysiology. *Pediatr Dermatol* 2013; Mar 28. [Epub ahead of print.]



**Fig. 26-27** Acneiform scarring in lipoid proteinosis.

## ANGIOKERATOMA CORPORIS DIFFUSUM (FABRY DISEASE)

Fabry disease (FD) is a rare X-linked lysosomal storage disease. It is caused by mutations in the  $\alpha$ -galactosidase A gene (*GLA*), leading to a deficiency in  $\alpha$ -galactosidase A. This results in the inability to catabolize glycosphingolipids, and globotriaosylceramide accumulates in lysosomes in many tissues, including endothelial cells, erector pili muscles, dorsal root ganglion nerves, and visceral organs. Males are affected more severely and earlier. Female heterozygotes (carriers of the defective gene) can have a broad spectrum of disease, from asymptomatic to disease as severe as males, depending on which X chromosome is inactivated in which organs. This can make confirming the diagnosis of FD in a female with limited cutaneous and visceral disease quite difficult.

Skin lesions are common, and in about one quarter of male patients, a dermatologist makes the diagnosis. The most characteristic skin lesions are widespread punctate telangiectatic vascular papules that on first inspection suggest purpura, but are actually angiokeratomas. Some show hyperkeratotic tops, but these are less prominent than in other forms of angiokeratoma. Angiokeratomas occur in 66% of male and 36% of female patients with FD. The average age of onset in males is about age 20 and in females, about 10 years later. Lesions can be present as early as age 1 year. Lesions tend to occur in the "bathing trunk" area, from the umbilicus to the genitalia, where they may be present in large numbers. Smaller "macular angiomas" are seen, especially on the proximal limbs, palms, and soles, around the nailfolds of the digits, and on the vermilion border of the lips (Fig. 26-28). Telangiectasias occur in about 25% of men presenting about age 25 and in women about age 40. Vascular tortuosities of the upper eyelid are seen in 95% of FD patients, with 40% showing microaneurysms. The ophthalmologist should examine for these lesions when screening for the characteristic corneal opacities. The vascular lesions can be treated with intense pulsed light or various vascular lasers.

Other skin manifestations of FD include lower limb edema and lymphedema. Leg ulceration can occur. Hair growth is scanty. Hypohidrosis is reported by 50% or more of male and about one third of female patients, starting in their twenties.

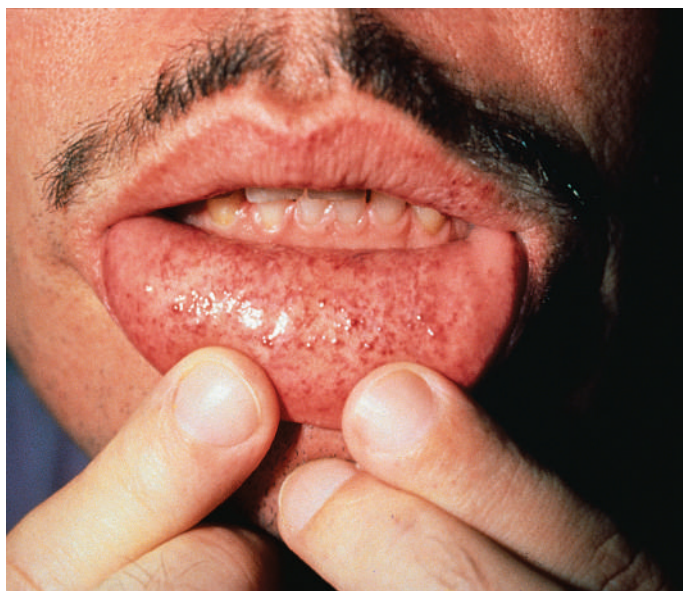


Fig. 26-28 Fabry disease.

Anhidrosis occurs in 25% of male patients. Heat intolerance can occur. About 12% of female and 6% of male patients complain of hyperhidrosis.

Visceral disease is common, especially of the kidneys, cardiovascular system, nervous system, and GI tract. Only one organ may be involved. Proteinuria followed by renal failure may begin as early as the second decade and typically presents around age 40. Cardiovascular events (myocardial infarction, arrhythmia, angina, congestive heart failure) typically appear at about age 40, contributing to premature mortality. About 5% of men and women have a cerebrovascular accident (stroke) at about age 40. About 1% of "cryptogenic" strokes are caused by undiagnosed FD. Abdominal pain, nausea, vomiting and diarrhea can all occur.

Neuropathic pain is the most common initial presentation, affecting about two thirds of FD patients. It may begin in childhood, but its nonspecific nature and the lack of physical findings delay the diagnosis, usually by more than a decade, until other stigmata appear. Thermohypesthesia is often present. The acroparesthesia or burning pain affects primarily the longest nerves and is severest on the hands and feet. It may be transient or may last for hours. Treatment is as for neuropathy, with tricyclics, gabapentin, capsaicin, and anticonvulsants. About 25% of FD patients develop carpal tunnel syndrome. Cramps and fasciculation may be the presenting neurologic symptoms. Female patients may be misdiagnosed as having multiple sclerosis.

Distinctive whorl-like opacities of the cornea occur in 90% of patients, and 50% develop characteristic spokelike cataracts in the posterior capsular location. Telangiectasias may be present on the conjunctiva and in the eye.

The diagnosis of FD may be confirmed by finding diminished levels of  $\alpha$ -galactosidase A in leukocytes, serum, fibroblasts, or amniotic fluid cells. Less than 10% enzyme activity is usually detected in affected males. In females, the diagnosis requires the identification of a genetic mutation in the *GLA* gene. This can be quite difficult if an affected male relative is not identified, since hundreds of *GLA* mutations have thus far been described that cause FD.

Histologically, there is dilation of capillaries in the papillary dermis, resulting in endothelium-lined lacunae filled with blood and surrounded by acanthotic and hyperkeratotic epidermis. Electron microscopy reveals characteristic electron-dense bodies in endothelial cells, pericytes, erector pili muscles, and fibroblasts. They are also present in normal skin of affected adults and children.

Enzyme replacement therapy is safe and can reverse substrate storage in the lysozyme. ERT leads to a reduction in neuropathic pain, relief of GI symptoms, and stabilization of cardiomyopathy; left ventricular mass decreases. Stroke and vascular coronary disease still occur, but perhaps at a lower rate. Early treatment may be more effective in preventing progression of FD.

Although widespread angiokeratomas are typical of FD, patients with other rare autosomal recessive lysosomal storage diseases, such as galactosialidosis, aspartylglycosaminuria, GM1 gangliosidosis ( $\beta$ -galactosidase deficiency, which may also manifest extensive dermal melanocytosis), and  $\alpha$ -N-acetylgalactosaminidase deficiency (Kanzaki disease), have been reported to have Fabry-like angiokeratomas. Also, several patients with no detectable enzyme deficiency have been reported, including a family with autosomal dominant inherited Fabry-like angiokeratomas associated with arteriovenous malformations. It should be emphasized that there are many normal patients who have widespread small, petechial-like lesions that erupt in adulthood, a variant of cherry angiomas.



## FUCOSIDOSIS

Angiokeratomas identical to those of Fabry disease occur in types II and III of this rare lysosomal storage disease. Fucosidosis can be distinguished clinically by the frequent presence of facial dysmorphism, severe mental retardation, weakness, spasticity, and seizures. The most severely affected patients die in childhood (type I), without the development of typical angiokeratomas. Patients with type II disease have severe spondyloepiphyseal dysplasia and normal intelligence. The adolescent type III patient can also have angiokeratomas. Fucosidosis is autosomal recessive and is caused by a deficiency in  $\alpha$ -L-fucosidase, usually detected in leukocytes.

## SIALIDOSIS

Sialidosis (mucopolipidosis type I) is an autosomal recessive lysosomal storage disease caused by mutations in the sialidase gene *NEU1*. Two types are described, the severest of which is the infantile form (type II), in which the children die within the first 2 years of life. Type I sialidosis is less severe and is characterized by mental retardation, myoclonus, cerebellar ataxia, hypotonia, skeletal abnormalities, and facial dysmorphism. Angiokeratoma can occur.

## $\beta$ -MANNOSIDASE DEFICIENCY

This rare autosomal recessive lysosomal storage disease of glycoprotein metabolism is caused by a deficiency of  $\beta$ -mannosidase that results in the accumulation of a characteristic disaccharide in the lysosomes, which may also be found in the urine. In addition to the Fabry-like angiokeratomas, mental retardation, hearing loss, aggressive behavior, peripheral neuropathy, recurrent infections, epilepsy, coarse facies, and skeletal abnormalities are often present.

- Böttcher T, et al:** Fabry disease: underestimated in the differential diagnosis of multiple sclerosis. *PLoS One* 2013; 8:e71894.
- Canafoglia L, et al:** Expanding sialidosis spectrum by genome-wide screening. *J Am Acad Neurol* 2014; 82:2003.
- Ferraz MJ, et al:** Gaucher disease and Fabry disease: new markers and insights in pathophysiology for two distinct glycosphingolipidoses. *Biochem Biophys Acta* 2014; 1841:811.
- Juan P, et al:** Fabry disease: multidisciplinary evaluation after 10 years of treatment with agalsidase beta. *JIMD Rep* 2014; 16:7.
- Kanitakis J, et al:** Fucosidosis with angiokeratoma: immunohistochemical and electron microscopic study of a new case and literature review. *J Cutan Pathol* 2005; 32:506.
- Mahmud HM:** Fabry' s disease: a comprehensive review on pathogenesis, diagnosis and treatment. *J Pak Med Assoc* 2014; 64:189.
- Michaud L:** Vascular tortuosities of the upper eyelid: a new clinical finding in Fabry patient screening. *J Ophthalmol* 2013; 2013:207573.
- Molho-Pessach V, et al:** Angiokeratoma corporis diffusum in human beta-mannosidosis: report of a new case and a novel mutation. *J Am Acad Dermatol* 2007; 57:407.
- Morais P, et al:** Angiokeratomas of Fabry successfully treated with intense pulsed light. *J Cosmet Laser Ther* 2008; 10:218.
- Nakai K, et al:** Multiple leg ulcers in a patient with Fabry disease. *J Eur Acad Dermatol Venereol* 2008; 22:382.
- Nance CS, et al:** Later-onset Fabry disease: an adult variant presenting with the cramp-fasciculation syndrome. *Arch Neurol* 2006; 63:453.
- Rombach SM, et al:** Natural course of Fabry disease and the effectiveness of enzyme replacement therapy: a systematic review and meta-analysis. *J Inherit Metab Dis* 2014; 37:341.
- Toyooka K:** Fabry disease. *Handb Clin Neurol* 2013; 113:1437.
- Tsukadaira A, et al:** Diagnosis of fucosidosis through a skin rash. *Intern Med* 2005; 44:907.

**Van der Tol L, et al:** A systematic review on screening for Fabry disease: prevalence of individuals with genetic variants of unknown significance. *J Med Genet* 2014; 51:1.

## SKIN DISORDERS IN DIABETES MELLITUS

Skin lesions are common in diabetic patients, with two-thirds or more having at least one skin finding. Xerosis appears to be particularly common, affecting 50% of those with type 1 diabetes. Keratosis pilaris is also common, affecting more than 10% of diabetic patients. Other specific cutaneous findings of diabetes are discussed next.

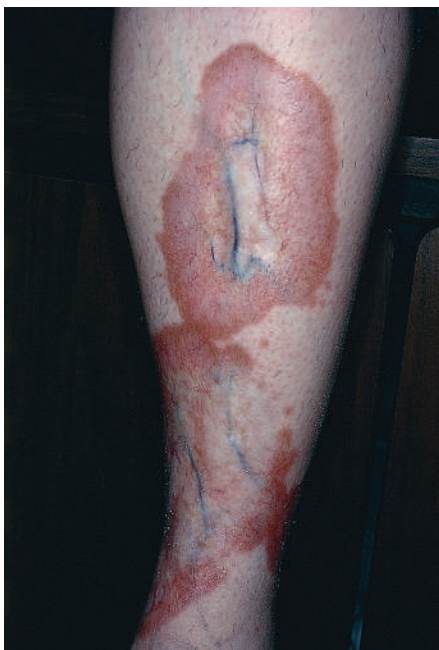## NECROBIOSIS LIPOIDICA/NECROBIOSIS LIPOIDICA DIABETICORUM

Necrobiosis lipoidica (NL) is characterized by well-circumscribed, firm, depressed, waxy, yellow-brown plaques, usually of the anterior shin. Although NL can occur in persons without diabetes mellitus, 60% of cases of NL occur in insulin-dependent (type 1) diabetic patients, and 20% occur in persons at risk for the development of diabetes (who have glucose intolerance or a family history of diabetes). If NL occurs in the setting of diabetes, it is called necrobiosis lipoidica diabetiformis (NLD). Women are affected three times more often than men; the condition usually appears between ages 20 and 40 but may occur in children or elderly people as well. The average age of onset is 34 for all diabetic patients, but 22 years, on average, in insulin-dependent patients, and 49 in non-insulin-dependent patients. Although NL is reported to affect only 0.3% of diabetic patients, the prevalence was much higher (>2%) in series of patients with type 1 diabetes. In 15%, NL precedes the onset of frank diabetes by an average of 2 years. Control of the diabetes does not influence the course of the NL.

The earliest changes are small, sharply bordered, elevated red papules that may be capped by a slight scale and that do not disappear under diascopic pressure. Later, the lesions develop into irregularly round or oval lesions with well-defined borders and a smooth, glistening (glazed) surface. The center becomes depressed and sulfur yellow, so that a firm yellowish lesion forms, surrounded at times by a violet-red or pink border. In the yellow portion, numerous telangiectases and ectatic veins are evident. Ulceration occurs in one third of NLD patients. In an unusual case, the plaques were studded with exophytic nodules resembling tuberous xanthomas. This patient had marked hyperlipidemia, perhaps contributing to the morphology. Rarely, squamous cell carcinoma may occur in chronic ulcers.

The most common location of the lesions is the shins (Fig. 26-29). Much less often, lesions will appear on the forearms, and rarely, lesions have been reported on the trunk, face, scalp, palms, and soles.

Histologically, well-developed lesions of NL demonstrate a superficial, deep, and interstitial inflammatory process that involves the whole reticular dermis and often the panniculus. Because the dermis is firm, punch biopsy specimens appear rectangular rather than tapered. The inflammatory cells include lymphocytes, histiocytes, multinucleate giant cells, and plasma cells. At low magnification, there are layered palisaded granulomas with pale-pink degenerated collagen alternating with amphophilic-staining histiocytes. In contrast to granuloma annulare, mucin is not increased in the centers of the granulomas, and there is no normal dermis in NL lesions. Between granulomas in granuloma annulare, the collagen pattern is relatively normal, although inflammatory cells



**Fig. 26-29** Necrobiosis lipoidica diabetorum.

may be present. In NL, the overlying epidermis tends to be thinned, with loss of the normal rete ridge pattern.

Treatment of NLD, after control of the diabetes is achieved, is not completely satisfactory. Pioglitazone treatment may be beneficial. Initial therapy is superpotent topical corticosteroids with occlusion. Topical calcineurin inhibitors can also be effective. Intralesional injections of triamcinolone suspension into the inflammatory papules and active advancing edges can be quite effective. Injection into the yellow center is of little benefit and may result in ulceration. It had been proposed that NLD is caused by the microangiopathy of diabetes. For this reason, agents designed to improve circulation have been used, at times with success. These include low-dose aspirin, nicotinamide, pentoxifylline, and dipyridamole. The blood flow in lesions of NLD is normal, however, suggesting that this is better considered as an inflammatory dermatosis. Phototherapy, including PUVA and UVA1, has been effective in select patients. Oral immunomodulatory therapy should be considered in patients unresponsive to topical treatment. Antimalarial treatment and thalidomide are nonimmunosuppressive options that would not alter blood sugar control. Systemic anti-inflammatories reported to be effective in select cases include systemic corticosteroids, mycophenolate mofetil (MMF), and cyclosporin A. TNF inhibitors (specifically infliximab and etanercept) have been effective in refractory cases, either systemically or by intralesional injection. However, patients being treated with TNF inhibitors for other conditions have developed NLD, similar to the paradox of patients who take TNF inhibitors developing psoriasis. Hyperbaric oxygen may be used for patients with chronic ulceration. In severe cases with persistent ulceration, excision and skin grafting have been effective, although the NLD may recur in or at the edges of the grafts. Despite initial reports of success, photodynamic therapy only improves about one third of treated patients. Pancreas-kidney transplantation led to resolution in one case, but the patient also received MMF, prednisone, and tacrolimus orally.

**Chatterjee N, et al:** An observational study of cutaneous manifestations in diabetes mellitus in a tertiary care hospital of eastern India. *Indian J Endocrinol Metab* 2014; 18:217.

**Chung CG, et al:** Necrobiosis lipoidica occurring in a patient with rheumatoid arthritis on concurrent tumor necrosis factor- $\alpha$  inhibitor. *Int J Dermatol* 2014; Apr 2. [Epub ahead of print.]

**Franklin C, et al:** Ulcerated necrobiosis lipoidica as a rare cause for chronic leg ulcers: case report series of ten patients. *Int Wound J* 2013; Oct 7. [Epub ahead of print.]

**Grillo E, et al:** Necrobiosis lipoidica. *Aust Fam Physician* 2014; 43:129.

**Kato M, et al:** Necrobiosis lipoidica with infiltration of Th17 cells into vascular lesions. *J Dermatol* 2014; 41:459.

**Kurdi AT:** Bullous diabetorum. *Lancet* 2013; 382:e31.

**Murao K:** Photodynamic therapy for necrobiosis lipoidica is an unpredictable option: three cases with different results. *Int J Dermatol* 2013; 52:1567.

**Murphy-Chutorian B, et al:** Dermatologic manifestations of diabetes mellitus: a review. *Endocrinol Metab Clin North Am* 2013; 42:869.

**Quondamatteo F:** Skin and diabetes mellitus: what do we know? *Cell Tissue Res* 2014; 355:1.

**Reid SD, et al:** Update on necrobiosis lipoidica: a review of etiology, diagnosis, and treatment options. *J Am Acad Dermatol* 2013; 69:783.

**Salazar-Nievas M, et al:** Cutaneous indurated plaque on the abdomen associated with diabetes mellitus. *Aust Fam Physician* 2013; 42:876.

**Schilling WH, et al:** Cutaneous stigmata associated with insulin resistance and increased cardiovascular risk. *Int J Dermatol* 2014; 53:1062.

**Shenavandeh S, et al:** Diabetic muscle infarction and diabetic dermopathy two manifestations of uncontrolled prolonged diabetes mellitus presenting with severe leg pain and leg skin lesions. *J Diabetes Metab Disord* 2014; 13:38.

**Uva L, et al:** Squamous cell carcinoma arising in ulcerated necrobiosis lipoidica diabetorum. *Int Wound J* 2013; Dec 26. [Epub ahead of print.]

## OTHER DIABETIC DERMADROMES

In addition to necrobiosis lipoidica, there are many cutaneous signs in this common endocrinopathy.

### Diabetic dermopathy (shin spots)

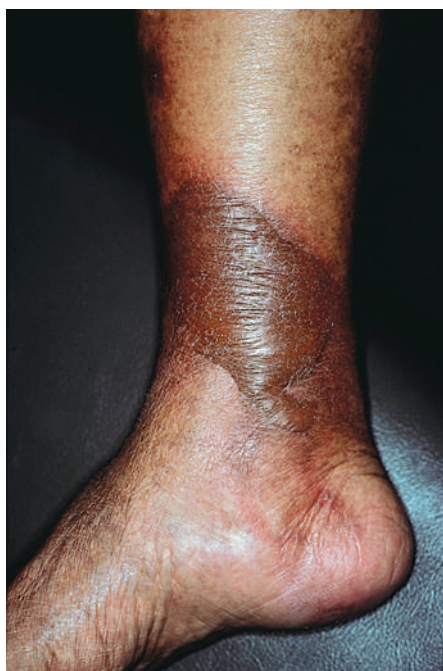Dull-red papules that progress to small, well-circumscribed, round, atrophic, hyperpigmented lesions on the shins are a common cutaneous sign of diabetes, occurring in up to 40% of diabetic patients. The lesions are twice as common in men; 70% of diabetic men over age 60 have diabetic dermopathy. Lesions begin on the lower extremities as crops of four or five dull-red macules 0.5–1 cm in diameter. As the lesions resolve, they become shallow, depressed, and hyperpigmented scars. Although shin spots occur individually in people who do not have diabetes, if four or more are present, the specificity is high for diabetes.

### Diabetic bullae

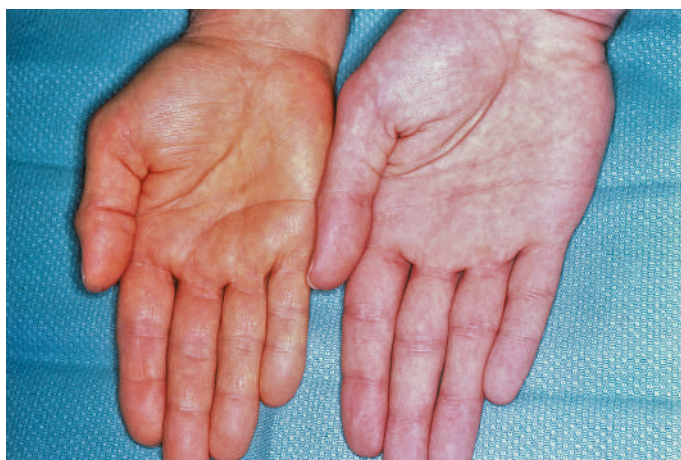Noninflammatory, spontaneous, painless blistering, most often in acral locations, is characteristic of diabetic bullae (Fig. 26-30). Lesions tend to involve the lower legs and to be 10 cm or more in diameter. The incidence is 0.16% per year. In one series of 5000 diabetic patients, 25 (0.5%) developed diabetic bullae over a 3-year period. In many cases, lesions heal spontaneously in 4–5 weeks, usually without scarring. However, lesions may be complicated at times by chronic ulceration. Aggressive and cautious management with dressings and diabetic foot care is required. Minor amputations may be needed. Lesions appear after periods of relative hypoglycemia, perhaps explaining the clinical resemblance of diabetic bullae to pressure bullae.

Lesions are subepidermal. Electron microscopic studies show separation at the lamina lucida level. DIF is negative. There is a reduced threshold to suction-induced blistering in





**Fig. 26-30** Bullous eruption of diabetes.



**Fig. 26-31** Carotenemia, yellow palm shown next to normal palm.

insulin-dependent (type 1) diabetic patients. Treatment is observation, diabetic control, aspiration of the bulla to prevent expansion by hydrostatic pressure, and aggressive wound management to optimize healing and prevent infection.

### Carotenosis

Carotenosis is a yellowish discoloration of the skin, especially of the palms and soles (Fig. 26-31), which is sometimes seen in diabetic patients.

### Limited joint mobility and waxy skin

Limited joint mobility (LJM) and waxy skin are important not only because of the 30–50% prevalence of these conditions in diabetic patients with long-standing disease, but also because they are associated with microvascular complications, such as nephropathy and retinopathy. Joint symptoms begin with limitation of joint mobility in the fifth finger at the metacarpophalangeal and proximal joints and progress radially to the

other fingers. The condition is bilateral, symmetric, and painless. Dupuytren's contractures and palmar fibrosis may be associated. Involvement of the feet also occurs and is thought to contribute to the development of chronic ulcerations. Such open sores on the neuropathic, microvascularly compromised, infection-prone diabetic foot pose a constant threat to life and limb.

### Other associated conditions in patients with diabetes

Various abnormalities associated with diabetes are erysipelas-like erythema of the legs or feet; sweating disturbances; paresthesias of the legs; mal perforans ulcerations; a predisposition to certain infections such as mucormycosis, group B streptococcal infections, nonclostridial gas gangrene, and malignant external otitis resulting from *Pseudomonas*; disseminated granuloma annulare; eruptive xanthomas; clear cell syringomas; rubeosis of the face; lipoatrophy or lipohypertrophy at sites of insulin injection; acquired perforating disorders; acanthosis nigricans; skin tags; and finger pebbling. Pruritus is common in adult diabetic patients, typically of the central trunk. It is associated with evidence of diabetic neuropathy and probably represents a form of neuropathic pruritus. Treatment is similar to that for neuropathy, starting with gabapentin.

**Bello F, et al:** Two cases of bullosis diabeticorum following long-distance journeys by road: a report of two cases. *Case Rep Endocrinol* 2012; 2012:367218.

**Kurdi AT:** Bullosis diabeticorum. *Lancet* 2013; 382:e31.

**Lopez PR, et al:** Bullosis diabeticorum associated with a prediabetic state. *South Med J* 2009; 102:643

**Sehgal VN, et al:** Noninsulin-dependent, type II diabetes mellitus-related dermatoses. Part II. *Skinmed* 2011; 9:302.

**Silverberg NB, Lee-Wong M:** Generalized yellow discoloration of the skin. The diagnosis: carotenemia. *Cutis* 2014; 93:E11.

**Weerasuriya T, et al:** Bullosis diabeticorum following carpal tunnel decompression. *BMJ Case Rep* 2012; 2012.

**Zhang AJ, et al:** Bullosis diabeticorum: case report and review. *N Z Med J* 2013; 126:91.

## OTHER METABOLIC DISORDERS

### CITRULLINEMIA

Citrullinemia occurs in two forms. Type I is caused by a deficiency of the enzyme argininosuccinic acid synthetase (*ASS1* gene). This enzyme converts citrulline and aspartic acid to argininosuccinic acid, as a part of the urea cycle. Low plasma arginine levels result, and the hypothesis is that, since keratin is 16% arginine, dermatitis may occur. Neonates who present with severe deficiencies and hyperammonemic crises may develop erosive, erythematous, scaling patches and plaques prominent in the perioral, lower abdominal, diaper, and buttock regions. This eruption clears with arginine supplementation. Short, sparse hair may also be present. Citrullinemia type II is caused by a defect in the *SCL25A13* gene and is seen primarily in East Asia, usually presenting in adolescence or adulthood.

In carbamoyl phosphate synthetase deficiency, low plasma arginine levels may also occur, and similar cutaneous findings have been reported in this second metabolic defect of the urea cycle.

Diets high in arginine will heal the skin lesions.

**Engel K, et al:** Mutations and polymorphisms in the human argininosuccinate synthetase (*ASS1*) gene. *Hum Mutat* 2009; 30:300.

**Fiermonte G, et al:** An adult with type 2 citrullinemia presenting in Europe. *N Engl J Med* 2008; 358:1408.

## HARTNUP DISEASE

Hartnup disease is an inborn error of tryptophan excretion named after the Hartnup family, in whom it was first noted. It is the second most common inherited aminoaciduria after phenylketonuria. The characteristic findings are a pellagralike dermatitis following exposure to sunlight, intermittent cerebellar ataxia, psychosis, and constant aminoaciduria.

The dermatitis occurs on exposed parts of the skin, chiefly the face, neck, hands, and legs. The erythematous scaly patches flare up into a hot, red, exudative state after exposure to sunlight, followed by hyperpigmentation. Stomatitis and vulvitis also occur. The disease becomes milder with increasing age. Rarely, an acrodermatitis enteropathica-like eruption with normal zinc levels may occur in patients with Hartnup disease.

Hartnup disease is an autosomal recessive trait. Large amounts of neutral amino acids, including tryptophan, are present in the urine, establishing the diagnosis. Hartnup disease is caused by mutations in the *SLC6A19* gene. The *SLC6A19* enzyme transports neutral amino acids across the apical membrane of epithelial cells in the gut and kidneys. The skin lesions respond to niacinamide, but the neurologic disease may not improve.

**Orbak Z, et al:** Hartnup disease masked by kwashiorkor. *J Health Popul Nutr* 2010; 28:413.

**Sander CS, et al:** Severe exfoliative erythema of malnutrition in a child with coexisting coeliac and Hartnup's disease. *Clin Exp Dermatol* 2009; 34:178.

## PROLIDASE DEFICIENCY

Prolidase deficiency (PD) is an autosomal recessive inherited inborn error of metabolism caused by mutations in the *PEPD* gene. Prolidase cleaves dipeptides containing C-terminal proline or hydroxyproline. When this enzyme is deficient, the normal recycling of proline residues obtained from collagen degradation is impaired. A buildup of iminodipeptides results, with disturbances in connective tissue metabolism and excretion of large amounts of iminodipeptides in the urine. Clinically, 85% of patients have some dermatologic manifestations. The most important cutaneous signs, which almost always appear before the affected person is 12 years old, are skin fragility; ulceration and scarring of the lower extremities; photosensitivity and telangiectasia; poliosis; scaly, erythematous, maculopapular, and purpuric lesions; and thickening of the skin with lymphedema of the legs. Some of these signs result from defective collagen metabolism in the dermis and around dermal vessels. Systemic signs and symptoms include mental deficiency, splenomegaly, and recurrent infections. An unusual facial appearance is noted at times, with low hairline, frontal bossing, and saddle nose. About 10% of patients with prolidase deficiency meet American Rheumatology Association (ARA) criteria for the diagnosis of systemic lupus erythematosus (SLE). Antinuclear antibodies (ANAs), extractable nuclear antigen (ENA), and anti-dsDNA may be positive; C3 and C4 are low; and cytopenias are present. Because C1q has a high proline content, a relative deficiency of functional C1q may explain the high frequency of lupus erythematosus (LE) in these patients.

Prolidase deficiency is confirmed by determining prolidase activity in erythrocytes, leukocytes, or fibroblasts in culture or by sequence analysis of the *PEPD* gene. In long-standing ulcerations, squamous cell carcinomas may occur.

**Butboul Aviel Y, et al:** Prolidase deficiency associated with systemic lupus erythematosus (SLE): single site experience and literature review. *Pediatr Rheumatol* 2012; 10:18.

**Dunn R, Dolianitis C:** Prolidase deficiency: the use of topical proline for treatment of leg ulcers. *Australas J Dermatol* 2008; 49:237.

**Fimiani M, et al:** Squamous cell carcinoma of the leg in a patient with prolidase deficiency. *Br J Dermatol* 1999; 140:362.

## PHENYLKETONURIA

Phenylketonuria (PKU) is an autosomal recessive disorder of phenylalanine metabolism caused by a deficiency in the enzyme phenylalanine hydroxylase. Phenylalanine is not metabolized to tyrosine. PKU is the most common form of inherited aminoaciduria, affecting 1 in 15000 live births in the United States. It is characterized by mental deficiency; epileptic seizures; pigmentary dilution of skin, hair, and eyes; pseudoscleroderma; and dermatitis (Fig. 26-32). It is most common in white persons.

Affected children are blue-eyed, with blond hair and fair skin. They are usually extremely sensitive to light, and about 50% have an eczematous dermatitis. It is clinically similar to atopic dermatitis, with a predilection for the flexures. The dermatitis is worst in the youngest patients, may improve with dietary treatment, and has been exacerbated by phenylalanine challenge in a carrier of the recessive gene. Indurations of the thighs and buttocks are present early in infancy and increase with time. After many years, the lesions soften and become atrophic.

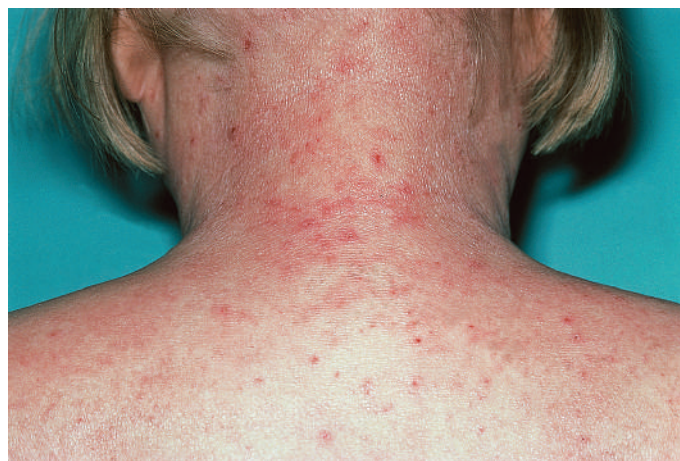Blood levels of phenylalanine are high. The presence of phenylpyruvic acid in the urine is demonstrated by a characteristic deep-green color when a few drops of ferric chloride solution are added. Green diapers occur in histidinemia as well as in PKU.

In developed countries, universal screening for PKU is practiced, so dietary therapy with phenylalanine restriction is instituted. Sapropterin dihydrochloride may also be given. This prevents the manifestations of the disease. If compliance is poor, the manifestations, including eczema, may develop at any age, followed by improvement of the skin with reinstitution of the diet.

**Al-Mayouf SM, Al-Owain MA:** Progressive sclerodermatous skin changes in a child with phenylketonuria. *Pediatr Dermatol* 2006; 23:136.

**Belloso LM, et al:** Cutaneous findings in a 51-year-old man with phenylketonuria. *J Am Acad Dermatol* 2003; 49:S190.

**Longo N, et al:** Single-dose, subcutaneous recombinant phenylalanine ammonia lyase conjugated with polyethylene glycol in adult patients



**Fig. 26-32** Light-skinned, light-haired phenylketonuria patient with dermatitis. (Courtesy of Dr. Jeff Miller.)



with phenylketonuria: an open-label, multicenter, Phase 1 dose-escalation trial. *Lancet* 2014; 384:37.

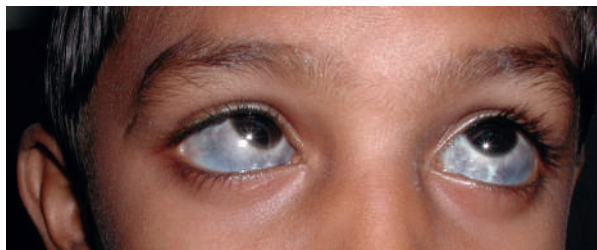**Somaraju UR, Merrin M:** Sapropterin dihydrochloride for phenylketonuria. *Cochrane Database Syst Rev* 2012; 12:CD008005.

## ALKAPTONURIA AND OCHRONOSIS

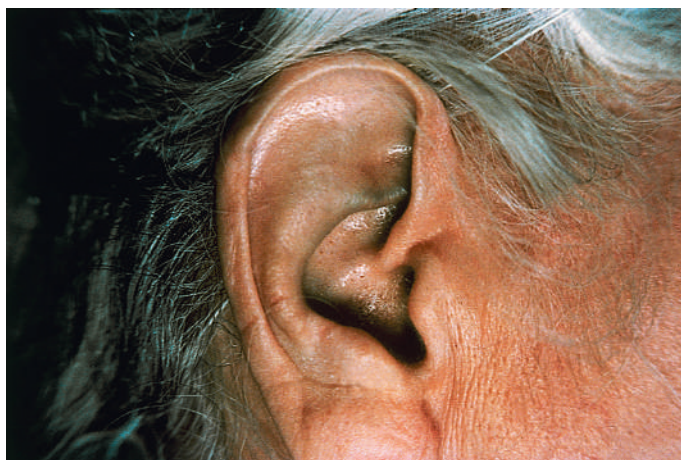Alkaptonuria, inherited as an autosomal recessive trait, is caused by the lack of renal and hepatic homogentisic acid oxidase, the enzyme necessary for the catabolism of homogentisic acid (HGA), a product of tyrosine and phenylalanine metabolism. Excess HGA is excreted in the urine and deposited in connective tissues throughout the body, especially the cartilage. The urine is dark and becomes black on standing. Men with alkaptonuria outnumber women by 2:1.

For many years, the dark urine may be the only indication of the presence of alkaptonuria. In the meantime, large amounts of HGA accumulate in the body tissues. By the third decade of life, the deposition of pigment becomes apparent. The early sign is the pigmentation of the sclera (Osler's sign; Fig. 26-33) and the cartilage of the ears (Fig. 26-34). Later, the cartilage of the nose and tendons, especially those on the hands, becomes discolored.

Blue or mottled brown macules appear on the skin. The bluish macules have a predilection for the fingers, ears, nose, genital regions, apices of the axillae, and buccal and vaginal mucosae. Palmoplantar pigmentation may occur and may be accentuated along the thenar and hypothenar eminences as pigmented pitted papules. The transradiance of the index fingers is also affected, closely resembling degenerative collagenous plaques the hand and acrokeratoelastoidosis. The apocrine sweat glands are rich in ochronotic pigment granules, and the intradermal injection of epinephrine into the skin of the axillary vault will yield brown-black sweat droplets in the follicular orifices. The cerumen is often black. Histologically,



**Fig. 26-33** Osler's sign.



**Fig. 26-34** Ochronotic pigmentation of ear cartilage.

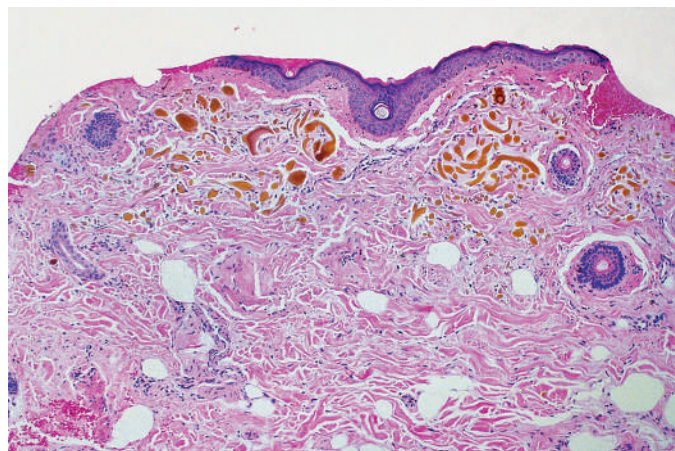
there are large, irregular ochre bodies within the reticular dermis. These represent degenerated elastic fibers with deposition of ochronotic pigment and stain black with crystal violet or methylene blue.

Ochronotic arthropathy first involves the axial spine joints, followed by the knees, shoulders, and hips. Radiographs show a characteristic appearance of early calcification of the intervertebral disk and later narrowing of the intervertebral spaces with eventual disk collapse. Tendon rupture may occur. Heart disease results from HGA deposition in the aortic and mitral valves. Renal disease is caused by HGA stones in the urinary system and can progress to renal failure.

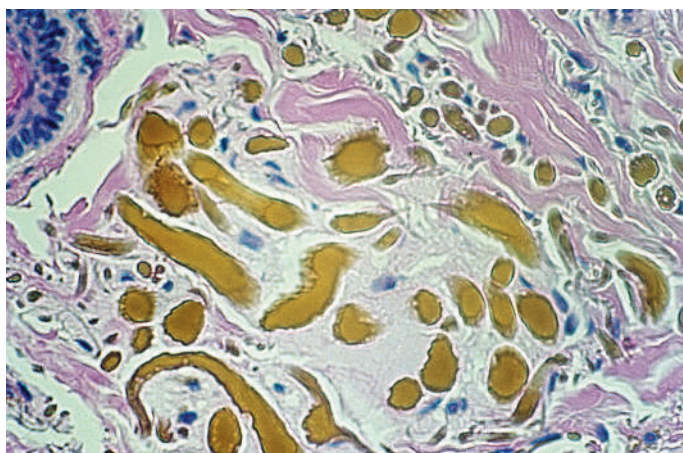
There is no effective treatment for alkaptonuria. Dietary restriction of tyrosine and phenylalanine is recommended but may not prevent progression of disease. Joint and cardiac valve replacement may be necessary. Nitisinone can greatly reduce HGA excretion but does not appear to be effective once joint disease is present. In mouse models, however, nitisinone treatment from birth prevented tissue deposition of the HGA and development of joint disease, suggesting early treatment might lead to stabilization of disease. Tyrosine keratopathy can result from nitisinone treatment. Life span is generally unaffected.

## Exogenous ochronosis

Topically applied phenolic intermediates, such as hydroquinone, carbolic acid (phenol), picric acid, and resorcinol, may produce exogenous ochronosis (Fig. 26-35). Even 2% over-the-counter hydroquinone can produce ochronosis if used regularly for a long period. Hydroquinone specifically inhibits the enzyme homogentisic acid oxidase locally, resulting in accumulation of this substance on the collagen fibers in tissues where hydroquinone is applied. All skin types can be affected, but ethnic groups with the highest prevalence of melasma and hydroquinone use are primarily reported: African Americans, Africans, and Asians. Since most patients use the hydroquinone to treat melasma, findings of melasma may overlay the skin findings of exogenous ochronosis. The typical findings are gray-brown or blue-black macules, usually over the zygomatic regions. Caviarlike, hyperchromic pinpoint papules may occur, which on dermoscopy can be seen associated with follicular openings. Confettilike depigmentation (from the hydroquinone) may be admixed with the hyperpigmentation. Histologically, exogenous ochronosis and alkaptonuria have identical changes on skin biopsy (Fig. 26-36). Treatment is less than satisfactory. Stopping the application of hydroquinone may lead



**Fig. 26-35** Exogenous ochronosis.



**Fig. 26-36** Large, ochre bodies in the dermis in exogenous ochronosis.

to improvement. Q-switched lasers has shown early, promising, but inconsistent improvement.

**Aquaron R:** Alkaptonuria: a very rare metabolic disorder. *Indian J Biochem Biophys* 2013; 50:339.

**Bellew SG, et al:** Treatment of exogenous ochronosis with a Q-switched alexandrite (755 nm) laser. *Dermatol Surg* 2004; 30:555.

**Gil I, et al:** Dermoscopic and reflectance confocal microscopic features of exogenous ochronosis. *Arch Dermatol* 2010; 146:1021.

**Introne WJ, et al:** A 3-year randomized therapeutic trial of nitisinone in alkaptonuria. *Mol Genet Metab* 2011; 103:307.

**Khaled A, et al:** Exogenous ochronosis: case report and a systematic review of the literature. *Int J Dermatol* 2011; 50:262.

**Liu WC, et al:** Exogenous ochronosis in a Chinese patient: use of dermoscopy aids early diagnosis and selection of biopsy site. *Singapore Med J* 2014; 55:e1.

**Mishra SN, et al:** Diagnostic utility of dermoscopy in hydroquinone-induced exogenous ochronosis. *Int J Dermatol* 2013; 52:413.

**Moche MJ, et al:** Cutaneous annular sarcoidosis developing on a background of exogenous ochronosis: a report of two cases and review of the literature. *Clin Exp Dermatol* 2009; 35:399.

**Preston AJ, et al:** Ochronotic osteoarthropathy in a mouse model of alkaptonuria, and its inhibition by nitisinone. *Ann Rheum Dis* 2014; 73:284.

**Ranganath LR, et al:** Natural history of alkaptonuria revisited analyses based on scoring systems. *J Inher Metab Dis* 2011; 34:1141.

**Ranganath LR, et al:** Recent advances in management of alkaptonuria. *J Clin Pathol* 2013; 66:367.

**Singh A, Ramesh V:** Exogenous ochronosis. *Indian J Med Res* 2014; 139:327.

**Tan SK:** Exogenous ochronosis in ethnic Chinese Asians: a clinicopathological study, diagnosis and treatment. *J Eur Acad Dermatol Venereol* 2011; 25:842.

**Thomas M, et al:** Acral pigmentation in alkaptonuria resembling degenerative collagenous plaques of the hands: a report of five cases. *J Am Acad Dermatol* 2010; 65:e45.

**Turgay E, et al:** Endogenous ochronosis. *Clin Exp Dermatol* 2009; 34:e865.

**Zaraa I, et al:** Endogenous ochronosis with a fatal outcome. *J Cutan Med Surg* 2012; 16:357.

## WILSON'S DISEASE (HEPATOLENTICULAR DEGENERATION)

Wilson's disease is an autosomal recessive derangement of copper transport. The disease is caused by dysfunction of a copper-transporting enzyme, P-type adenosine triphosphatase (ATP7B), which is required to excrete copper into the bile. This leads to accumulation of copper in the liver, brain, cornea, and kidney. Affected persons develop hepatomegaly, splenomegaly, and neuropsychiatric changes. Slurred speech,

a squeaky voice, salivation, dysphagia, tremors, incoordination, and spasticity may all occur. There is progressive, fatal, hepatic and central nervous system degeneration.

Azure lunulae ("sky-blue moons") of the nails occur in 10% of patients, and the smoky, greenish brown Kayser-Fleischer rings develop at the edges of the corneas. Hyperpigmentation develops on the lower extremities in most patients. A vague greenish discoloration of the skin on the face, neck, and genitalia may also be present. An idiopathic blistering eruption that ceased with treatment of Wilson's disease has been reported. Skin changes of cirrhosis (vascular spiders and palmar erythema) may occur. Low ceruloplasmin level in the serum leads to the suspected diagnosis, along with elevated 24-hour urinary copper excretion and elevated free serum copper. Ten percent of carriers for Wilson's disease have a low ceruloplasmin level, so additional tests should be performed to confirm the diagnosis.

The treatment is a low-copper diet, often with agents that bind copper and enhance its excretion from the body. D-Penicillamine, 1 or 2 g/day orally, removes copper by chelating it. Potential side effects include pemphigus, cutis laxa, and elastosis perforans serpiginosa, which has been reported repeatedly in Wilson patients receiving penicillamine. Trientine, another copper chelator, enhances copper excretion. It has less toxicity, but is somewhat less effective than D-penicillamine. Zinc supplementation leads to increased metallothionein in the gut and liver. This leads to more copper excretion in the stool. Zinc can be given at the same time as D-penicillamine. Treatment must be continued for life.

**Harada M:** Pathogenesis and management of Wilson disease. *Hepatol Res* 2014; 44:395.

## TYROSINEMIA II (RICHNER-HANHART SYNDROME)

Tyrosinemia is an autosomal recessive syndrome resulting from a deficiency of hepatic tyrosine aminotransferase, an important enzyme in the degradation of tyrosine and phenylalanine. It is caused by mutations in the *TAT* gene. The diagnosis is confirmed by identifying elevated levels of serum tyrosine. Clinical features are mild to severe keratitis and hyperkeratotic, erosive lesions of palms and soles, often with mild mental retardation. Photophobia and tearing usually occur as the keratitis begins, and ultimately, neovascularization is seen. Painful palmar and plantar hyperkeratosis may be the only manifestation. The fingertips and the hypothenar and thenar eminences are primarily affected on the palms. Initially, only the soles may be affected, with hyperkeratosis mainly over the tips of the digits and on weight-bearing surfaces. In any child presenting with palmoplantar keratoderma, the diagnosis of tyrosinemia type II must be considered. A low-tyrosine, low-phenylalanine diet may improve or prevent the eye and skin lesions, but it may or may not benefit established mental retardation.

**Meissner T, et al:** Richner-Hanhart syndrome detected by expanded newborn screening. *Pediatr Dermatol* 2008; 25:378.

**Pasternack SM, et al:** Identification of two new mutations in the *TAT* gene in a Danish family with tyrosinaemia type II. *Br J Dermatol* 2009; 160:704.

**Valikhami M, et al:** Oculocutaneous tyrosinaemia or tyrosinaemia type 2: a case report. *J Eur Acad Dermatol Venereol* 2006; 20:591.

## HURLER SYNDROME (MUCOPOLYSACCHARIDOSIS I)

Hurler syndrome, or gargoylism, is an autosomal recessive lysosomal storage disease of mucopolysaccharide metabolism.



A deficiency of  $\alpha$ -iduronidase is the causative defect. This enzyme is responsible for the breakdown of heparan sulfate and dermatan sulfate. All patients have undetectable enzyme activity by current assays, yet there is significant polymorphism in the severity and age of onset. In general, cases are divided into severe mucopolysaccharidosis (MPS-I, Hurler syndrome) and attenuated MPS-I (Hurler-Scheie syndrome, Scheie syndrome).

Hurler syndrome is characterized by mental retardation, hepatosplenomegaly, umbilical and inguinal hernia, genital infantilism, corneal opacities, and skin abnormalities. Patients with Hurler syndrome have facial dysmorphism, with a broad saddle nose, thick lips, and a large tongue. The skin is thickened, with ridges and grooves, especially on the upper half of the body. Fine lanugo hair is profusely distributed all over the body. Large, coarse hair is prominent, especially on the extremities. Dermal melanocytosis, characterized by extensive blue pigmentation with both a dorsal and a ventral distribution, indistinct borders, and a persistent or progressive course, occurs in some patients with lysosomal storage disease, including patients with Hurler syndrome, Hunter syndrome, and GM1-gangliosidosis type 1. The skeletal system is deformed, with hydrocephalus, kyphosis, and gibbus (cat-back shape). The hands are broad and have clawlike fingers. The joints are distorted.

The diagnosis of MPS-I is made by demonstrating elevated urinary glycosaminoglycan levels and deficient enzyme activity in fibroblasts, leukocytes, serum, or blood spots. Prenatal diagnosis is possible. Hematopoietic stem cell transplantation (HSCT) is the most effective treatment for Hurler syndrome. It can prevent mental deterioration if performed early enough (before age 2 and before developmental quotients fall below 70). Cardiac and joint complications are not prevented by HSCT. ERT with recombinant human  $\alpha$ -iduronidase (Aldurazyme) is an option in patients who are not candidates for HSCT.

**Ashrafi MR, et al:** Extensive mongolian spots: a clinical sign merits special attention. *Pediatr Neurol* 2006; 34:143.

**Behera B, et al:** Hurler syndrome with a tuft of hair. *Indian J Dermatol Venereol Leprol* 2006; 72:147.

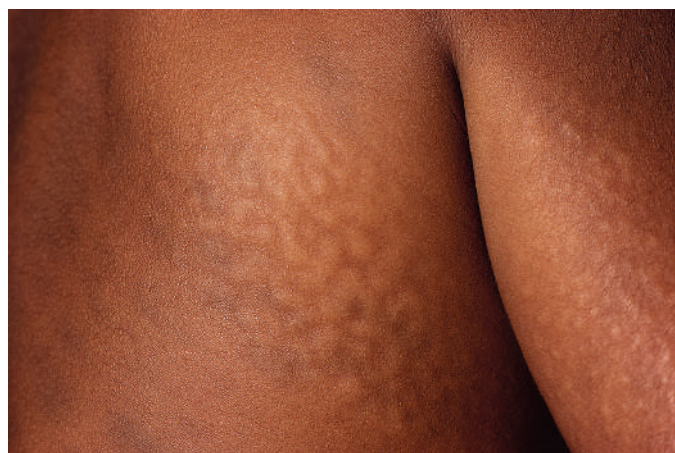**Muenzer J, et al:** Mucopolysaccharidosis I: management and treatment guidelines. *Pediatrics* 2009; 123:19.

## HUNTER SYNDROME (MUCOPOLYSACCHARIDOSIS II)

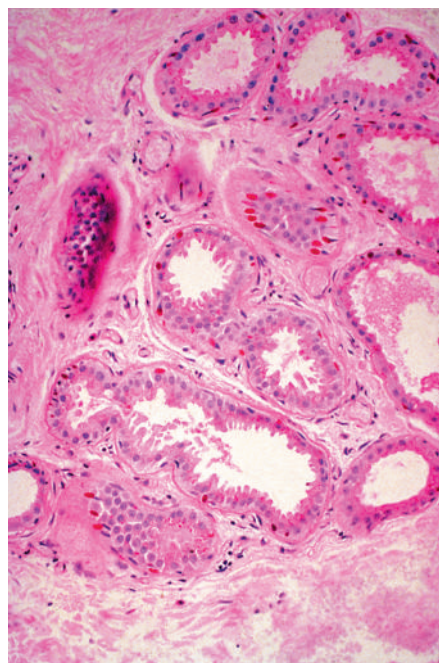
Hunter syndrome is X-linked recessive lysosomal storage disease caused by deficiency of the enzyme iduronate-2-sulfatase. The pebbly lesions of MPS-II in the skin of the upper back, neck, chest, proximal arms, or thighs represent the only diagnostic skin changes of the mucopolysaccharidoses. The lesions are firm, flesh-colored to white papules and nodules, which coalesce into a cobblestone or reticular pattern (Fig. 26-37). They generally occur at about age 10. Histologically, the lesions demonstrate increased dermal mucin and metachromatic granules in the cytoplasm of dermal fibroblasts and at times in eccrine sweat glands and epidermal keratinocytes. Additionally, the dermal melanocytosis previously described for Hurler syndrome may occur in Hunter syndrome.

Dermatan sulfate and heparan sulfate are excreted in the urine in large amounts, and the diagnosis of Hunter syndrome can be confirmed by absent iduronate-2-sulfatase in leukocytes. HSCT and ERT can be useful in appropriately evaluated patients.

**Ito K, et al:** The effect of haematopoietic stem cell transplant on papules with "pebbly" appearance in Hunter's syndrome. *Br J Dermatol* 2004; 151:207.



**Fig. 26-37** Hunter syndrome papules.



**Fig. 26-38** PAS-stained inclusions in Lafora's disease.

**Jones SA, et al:** Mortality and cause of death in mucopolysaccharidosis type II: a historical review based on data from the Hunter Outcome Survey (HOS). *J Inher Metab Dis* 2009; 32:534.

**Ochiai T, et al:** Significance of extensive mongolian spots in Hunter's syndrome. *Br J Dermatol* 2003; 148:1173.

**Sakata S, et al:** Skin rash with the histological absence of metachromatic granules as the presenting feature of Hunter syndrome in a 6-year-old boy. *Br J Dermatol* 2008; 159:249.

## LAFORA'S DISEASE

Lafora's disease is an autosomal recessive form of progressive myoclonic and tonic-clonic epilepsy beginning at puberty. It is characterized by myoclonic jerks followed by progressive ataxia, dysphagia, dysarthria, dementia, and death in early adulthood. Diagnosis is established in the proper clinical setting by demonstration of characteristic PAS-positive cytoplasmic inclusion bodies in the eccrine ducts, axillary apocrine myoepithelial cells (Fig. 26-38), and peripheral nerves. The best site to biopsy is the axilla. Other conditions in which similar polyglucosan inclusions can be seen include normal aging (amyloid bodies), double-athetosis syndrome, amyotrophic lateral sclerosis, and glycogen storage disease type IV.

Cutaneous manifestations are rare in Lafora's disease. Papulonodular lesions on the ears and indurated, thickened plaques on the arms have been reported. Large amounts of acid mucopolysaccharides were demonstrated histologically in these lesions. The disease is caused by mutations of either the *EPM2A* gene (80% of cases) or the *NHLRC1* gene, which encodes ubiquitin ligase. The products of these two genes form a complex critical to the regulation of neuronal function. This explains how mutations in either gene lead to the same phenotype.

**Karimipour D, et al:** Lafora's disease. *J Am Acad Dermatol* 1999; 41:790.

**Kecmanović M, et al:** Lafora disease: severe phenotype associated with homozygous deletion of the *NHLRC1* gene. *J Neurol Sci* 2013; 325:170.

## CADASIL SYNDROME

Cerebral autosomal dominant arteriopathy with subcortical infarcts and leukoencephalopathy (CADASIL) is a neurovascular disease of young and middle-age people. It is the most common heritable cause of stroke and vascular dementia in adults. It is caused by mutations in the gene for NOTCH3, a transmembrane protein. Children have cognitive impairment; young adults have depression and migraine with aura; and patients in their forties and fifties experience apathy, mood disturbances, and motor disability. Executive dysfunction in the late thirties to fifties is followed by dementia in the sixties and seventies. There is deposition of a granular osmophilic material (GOM) in the media of arterial walls seen on electron microscopy. This may be demonstrated by a specific immunostain. The diagnosis should be confirmed by genetic testing, which will identify most, but not all patients with CADASIL. Ultrastructural examination of skin biopsy is restricted to patients with negative genetic screening and features highly suggestive of CADASIL, or when genetic testing is not available.

**Chabriat H, et al:** CADASIL. *Lancet Neurol* 2009; 8:643.

**Lee YC, et al:** The remarkably variable expressivity of CADASIL: report of a minimally symptomatic man at an advanced age. *J Neurol* 2009; 256:1026.

**Moreton FC, et al:** Changing clinical patterns and increasing prevalence in CADASIL. *Acta Neurol Scand* 2014; 130:197.

**Morroni M, et al:** Role of electron microscopy in the diagnosis of CADASIL syndrome: a study of 32 patients. *PLoS One* 2013; 8:e65482.

**Ratzinger G, et al:** CADASIL: an unusual manifestation with prominent cutaneous involvement. *Br J Dermatol* 2005; 152:246.

**Rumbaugh JA, et al:** CADASIL. *J Am Acad Dermatol* 2000; 43:1128.

**Walsh JS, et al:** CADASIL. *J Am Acad Dermatol* 2000; 43:1125.

## FARBER DISEASE

Also known as Farber lipogranulomatosis, Farber disease is characterized by periarticular nodules; joint swelling and deformation (usually the initial presentation); a weak, hoarse cry (from laryngeal involvement); pulmonary failure; and motor and mental retardation. It is caused by deficiency of lysosomal acid ceramidase resulting from mutations in the *ASAH1* gene. Progressive accumulation of ceramide in affected tissues results in the complications.

The rubbery subcutaneous nodules have a distinct yellowish hue and are 1–2 cm in diameter. They are usually located over the joints, lumbar spine, scalp, and weight-bearing areas. Histologically, these are granulomas. Farber disease presents with a highly variable spectrum, with the most severely affected children dying by age 2 years and mildly affected children reaching their teens. There is no correlation between the

genotype or the residual ceramidase level and the phenotype. In more mildly affected cases that have not been diagnosed in infancy, the periarticular swellings and predominant joint disease, in about one third of patients, leads to the incorrect diagnosis of juvenile idiopathic arthritis. An animal model has allowed treatment strategies to be tested.

**Kostik MM, et al:** Farber lipogranulomatosis with predominant joint involvement mimicking juvenile idiopathic arthritis. *J Inherit Metab Dis* 2013; 36:1079.

**Sands MS, et al:** Farber disease: understanding a fatal childhood disorder and dissecting ceramide biology. *EMBO Mol Med* 2013; 5:799.

**Schuchman E:** A132: Farber disease explains subset of juvenile idiopathic arthritis. *Arthritis Rheumatol* 2014; 66:S173.

## ADRENOLEUKODYSTROPHY (SCHILDER'S DISEASE)

Adrenoleukodystrophy (X-ALD) is an X-linked disorder in which cerebral white matter becomes progressively demyelinated and serious adrenocortical insufficiency usually occurs. X-ALD is caused by mutations in the *ABCD1* gene. The gene defect results in impaired degradation of very-long-chain fatty acids (>22 carbons). Skin hyperpigmentation often calls attention to the adrenal disease (Addison's), and mental deterioration indicates the even graver diagnosis of ALD. A mild ichthyotic appearance to the skin of the trunk and legs and sparse hair with trichorrhexis nodosa-like features may occur. Although males are most severely affected, female heterozygote carriers can, in adulthood, develop Addison's disease and chronic myelopathy and peripheral neuropathy, often with fecal incontinence. Skin biopsies may show characteristic vacuolization of eccrine secretory coils (duct cells being spared), and biopsies of the skin and conjunctiva may show diagnostic clefts in Schwann cells surrounding myelinated axons. Lorenzo's oil and pioglitazone are potential therapies. Bone marrow transplantation may benefit a small subset of X-ALD patients.

**Berger J, et al:** Pathophysiology of X-linked adrenoleukodystrophy. *Biochimie* 2014; 98:135.

**Chen X, et al:** Adult cerebral adrenoleukodystrophy and Addison's disease in a female carrier. *Gene* 2014; 544:248.

**Engelen M, et al:** X-linked adrenoleukodystrophy in women: a cross-sectional cohort study. *Brain* 2014; 137:693.

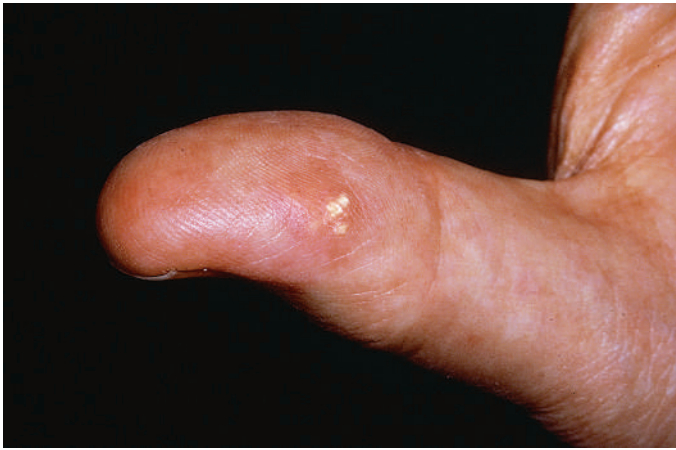**Morató L, et al:** Pioglitazone halts axonal degeneration in a mouse model of X-linked adrenoleukodystrophy. *Brain* 2013; 136:2432.

**Sassa T, et al:** Lorenzo's oil inhibits ELOVL1 and lowers the level of sphingomyelin with a saturated very long-chain fatty acid. *J Lipid Res* 2014; 55:524.

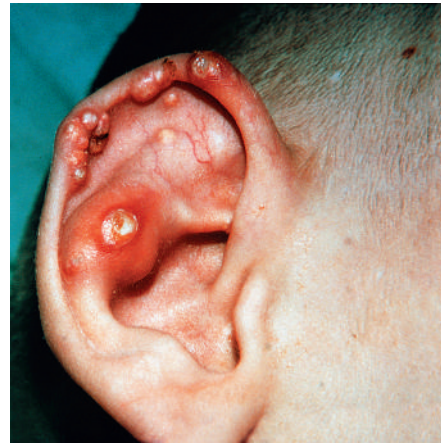## GOUT

Classic gout presents as an acute monoarthritis, usually of the great toe or knee, in a middle-age to elderly man with hyperuricemia. In such patients with chronic disease, usually present for more than 10 years, monosodium urate monohydrate may be deposited in the dermal or subcutaneous tissues, forming papules or nodules called tophi (Fig. 26-39). Rarely, tophi may be the initial presentation of gout, even with normal serum uric acid levels. Gouty tophi vary from pinhead to pea sized or rarely even baseball sized. Tophi are typically found on the pinna or outer helix of the ears and over the distal interphalangeal articulations. Tophi are of a yellow or cream color. Over time, tophi tend to break down and discharge sodium urate crystals, afterward healing and perhaps breaking down again. Atypical presentations of gout include nasal bridge





**Fig. 26-39** Gouty tophus.



**Fig. 26-40** Lesch-Nyhan syndrome.

tophi, gouty panniculitis (inflammatory subcutaneous nodules mimicking other forms of panniculitis, possibly with normal serum uric acid), and finger pad tophi. When urate crystal deposition occurs in the dermis, the lesions have been described as “pustular” or “intra-dermal” tophi.

The diagnosis of gout is verified histologically by finding the characteristic long, needle-shaped crystals of monosodium urate. Because routine processing dissolves these deposits, fixation in absolute ethanol or freezing is optimal for their demonstration, but this is rarely done because most specimens are submitted in formalin. Rather, 10- $\mu$  unstained sections from formalin-fixed specimens can demonstrate characteristic crystals under polarized light. Atypical gout occurs as a poly-articular chronic arthritis, often of the hands. It occurs equally in women and men, and there may be tophi, frequently overlying Heberden nodes, at presentation. Another risk group is organ transplant patients, of whom 10% develop gout. Treatment with certain medications has been associated with the appearance of tophi. These include diuretics, methotrexate, cyclosporine, and etanercept. Treatment with allopurinol can result in disappearance of the tophi.

## LESCH-NYHAN SYNDROME

Also known as juvenile gout, Lesch-Nyhan syndrome is a rare X-linked recessive inherited disorder characterized by childhood hyperuricemia, gout, tophi (Fig. 26-40), choreoathetosis, progressive mental retardation, and self-mutilation. The cutaneous lesions are distinctive. Massive self-mutilation of lips with the teeth occurs. The fingers are also severely chewed. The ears and nose are occasionally mutilated. An early diagnostic clue is orange crystals in the diaper. The blood uric acid is increased, and allopurinol, 200–400 mg/day, is given. There is a marked deficiency in an enzyme of purine metabolism, hypoxanthine guanine phosphoribosyltransferase (HGPRT).

**Forbess LJ, et al:** The broad spectrum of urate crystal deposition: unusual presentations of gouty tophi. *Semin Arthritis Rheum* 2012; 42:146.

**Meseguer-Yebra C, et al:** Joint destruction and presence of small papules on the palms and soles. *Clin Exp Dermatol* 2012; 37:450.

**Weaver J, et al:** Simple non-staining method to demonstrate urate crystals in formalin-fixed, paraffin-embedded skin biopsies. *J Cutan Pathol* 2009; 36:560.



Bonus images for this chapter can be found online at [expertconsult.inkling.com](http://expertconsult.inkling.com)

**eFig. 26-1** Vulvar amyloidosis.

**eFig. 26-2** Macular amyloidosis. (Courtesy of Dr. Lawrence Lieblich.)

**eFig. 26-3** Porphyria cutanea tarda.

**eFig. 26-4** Osteoma cutis. (Courtesy of Dr. Curt Samlaska.)

**eFig. 26-5** Tuberous xanthomas.

**eFig. 26-6** Tendinous xanthomas.

**eFig. 26-7** Eruptive xanthomas.

**eFig. 26-8** Eruptive xanthomas.

**eFig. 26-9** Xanthelasma.

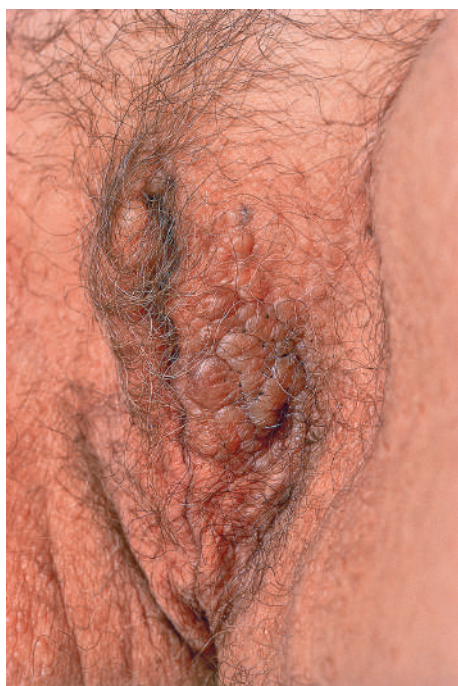**eFig. 26-10** Interdigital xanthomas in homozygous familial hypercholesterolemia.

**eFig. 26-11** Zebra bodies in Fabry disease.

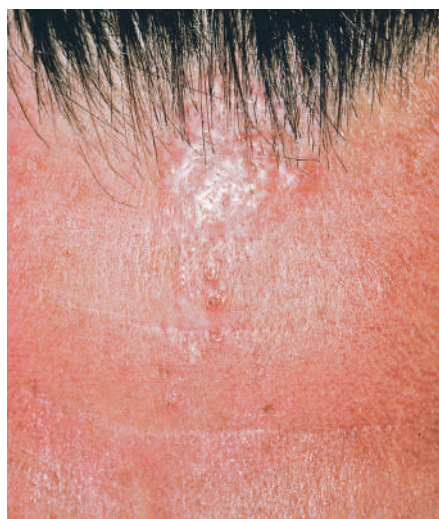**eFig. 26-12** Necrobiosis lipoidica diabetiformis.

**eFig. 26-13** Gouty tophus. (Courtesy of Dr. James Fitzpatrick.)

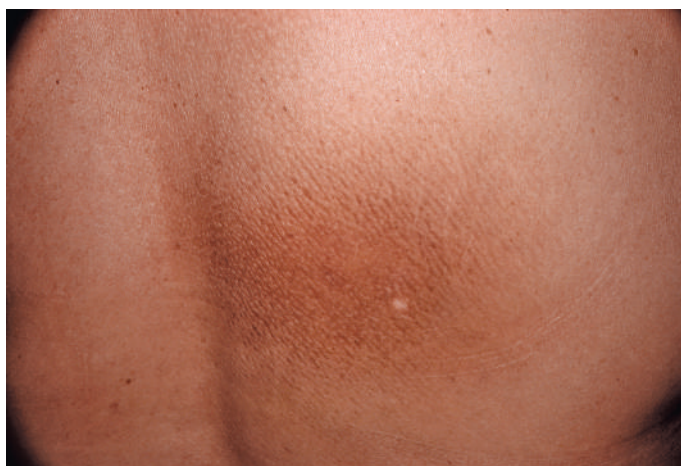



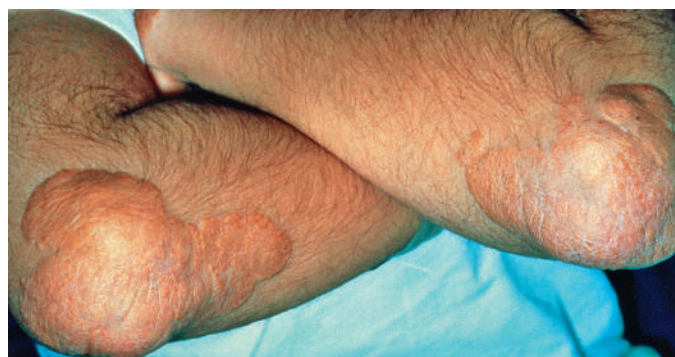**eFig. 26-1** Vulvar amyloidosis.



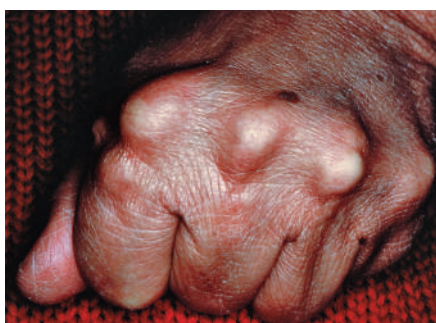**eFig. 26-4** Osteoma cutis. (Courtesy of Dr. Curt Samlaska.)



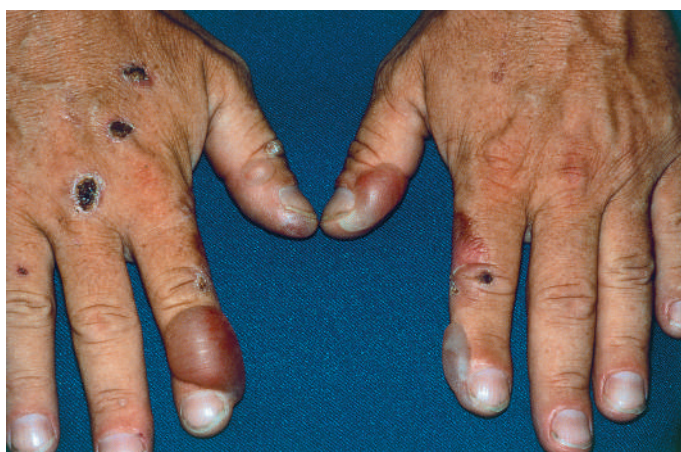**eFig. 26-2** Macular amyloidosis. (Courtesy of Dr. Lawrence Lieblich.)



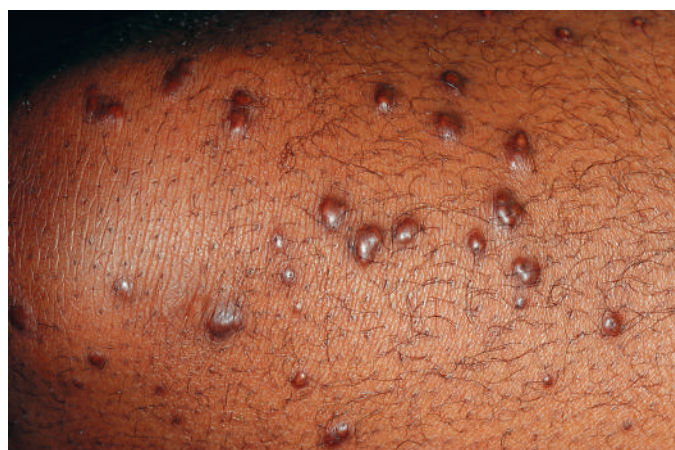**eFig. 26-5** Tuberous xanthomas.



**eFig. 26-6** Tendinous xanthomas.

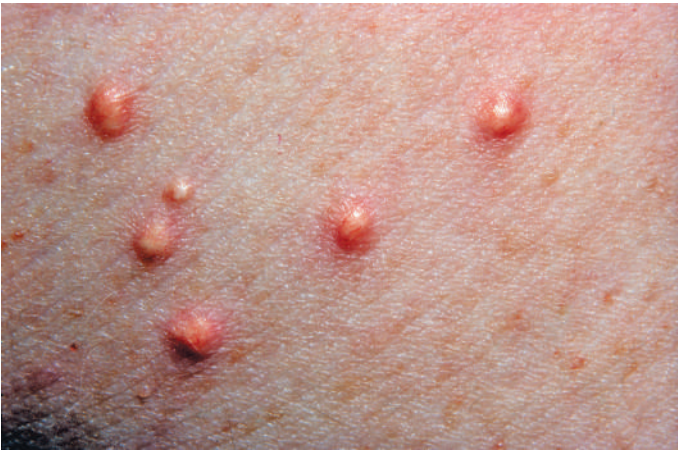

**eFig. 26-3** Porphyria cutanea tarda.

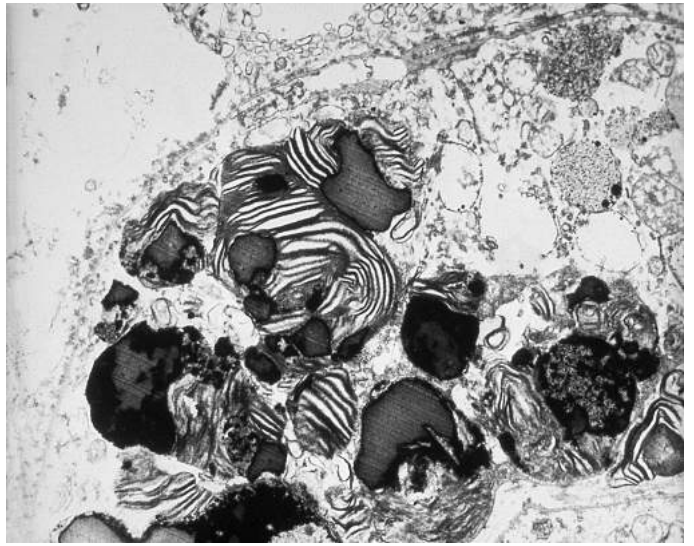


**eFig. 26-7** Eruptive xanthomas.

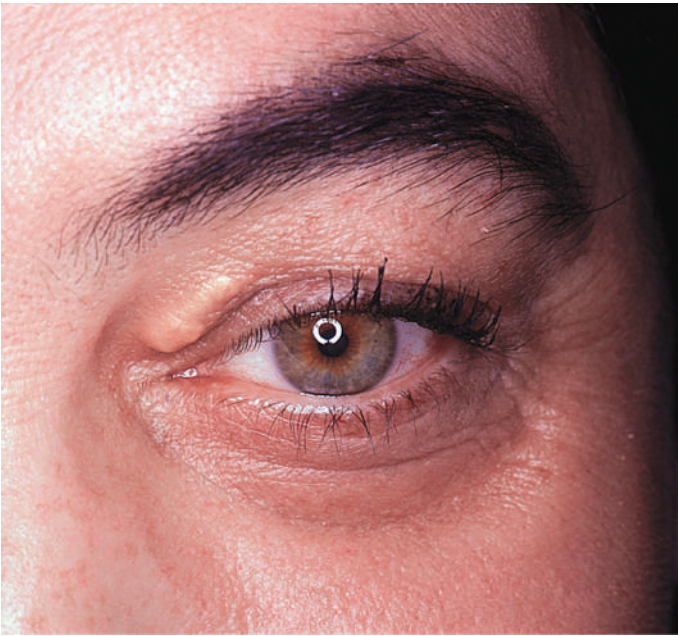




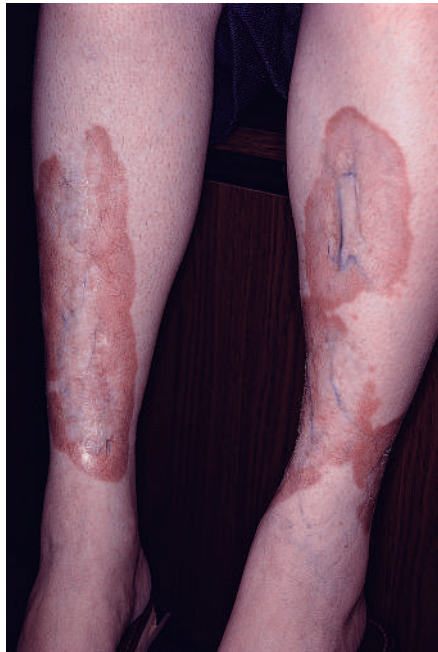**eFig. 26-8** Eruptive xanthomas.



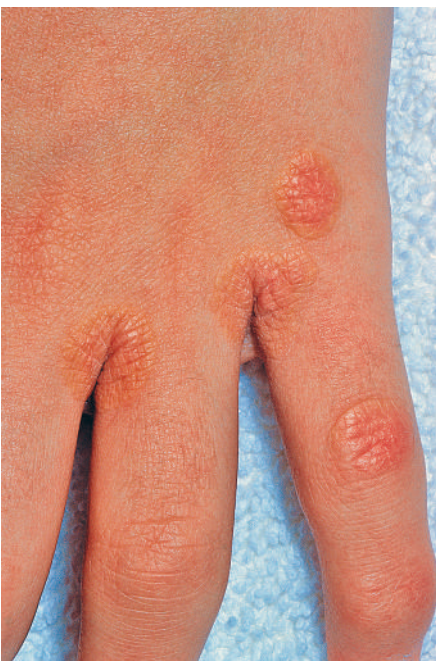**eFig. 26-11** Zebra bodies in Fabry disease.



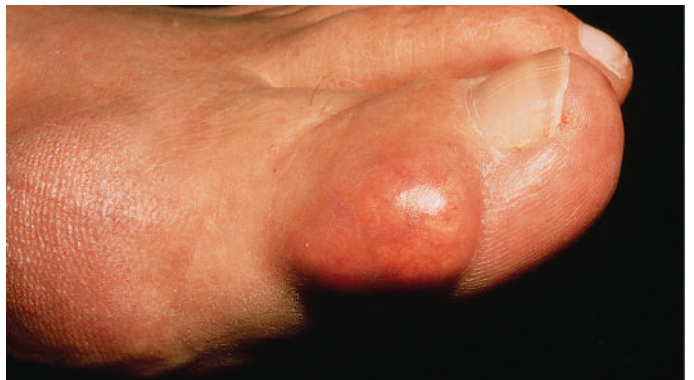**eFig. 26-9** Xanthelasma.



**eFig. 26-12**  
Necrobiosis lipoidica  
diabeticorum.



**eFig. 26-10** Interdigital  
xanthomas in  
homozygous familial  
hypercholesterolemia.



**eFig. 26-13** Gouty tophus.

# 27

## Genodermatoses and Congenital Anomalies

Genetic disorders are often grouped into three categories: chromosomal, single gene, and polygenetic. Chromosomal disorders can be numerical, such as trisomy and monosomy, or structural, resulting from translocations or deletions. Most genodermatoses show single-gene or mendelian inheritance (autosomal dominant, autosomal recessive, or X-linked recessive genes). Polygenetic syndromes often involve complex interactions of genes.

Autosomal dominant conditions require only a single gene to produce a given phenotype. Usually, the patient has one affected parent or is affected by a new mutation. The disease is transmitted from generation to generation. Autosomal recessive traits require a homozygous state to produce the abnormality. The pedigree will often reveal parental consanguinity. Parents will be clinically unaffected but often have affected relatives. X-linked conditions occur when the mutant gene is carried on the X chromosome. If a disease is X-linked recessive, the loss is evident in males (XY), who do not have a second X chromosome to express the normal allele. Therefore, X-linked recessive traits occur almost exclusively in males. They cannot transmit the disease to sons (who inherit their Y chromosome), but all their daughters will be carriers. Carrier females who are heterozygous (having one normal and one abnormal X chromosome) occasionally show some evidence of the disease. This occurs as a result of lyonization, the physiologic segmental inactivation of one of the X chromosomes. X-linked dominant disease states are usually lethal in males. Survival is possible in females who retain a normal allele. Because the mutation is lethal in many affected cell lines, females typically demonstrate loss of normal tissue in the affected segments (narrow Blaschko segments, loss of digits, microphthalmia, loss of teeth). X-linked dominant traits result in pedigrees in which more than one female is affected but no males express the disease. Rarely, males may survive, especially if they have Klinefelter syndrome (XXY).

Mosaicism is the presence of two or more genetically distinct cell lines in a single individual. It may occur as a result of physiologic inactivation of one X chromosome (lyonization) or as the result of postzygotic somatic mutation. Mosaicism often presents in a linear and whorled pattern along the lines of Blaschko. In mosaic states, genes that are detrimental to a cell population during fetal development (e.g., incontinentia pigmenti) typically result in thin segments because they are overgrown by the adjacent normal tissue. Conversely, genes that confer a growth advantage during fetal development (e.g., mutated tumor suppressor gene in segmental neurofibromatosis) may result in broad, plaque-type lesions that have grown beyond the boundaries of a typical Blaschko segment.

In autosomal dominant conditions, a normal allele remains but is not enough to prevent disease. Loss of heterozygosity (LOH) is the segmental loss of this remaining normal allele. LOH may give rise to segments of the body with an exaggerated presentation of the syndrome. The affected area

corresponds to a Blaschko segment or plaque. The forehead plaque of tuberous sclerosis is related to a mutation in a tumor suppressor gene. The loss of the tumor suppressor gene imparts a growth advantage, and loss of heterozygosity leaves no suppressor gene product in the segment. As a result, the affected segment grows beyond its Blaschko boundaries, forming a broad plaque.

When a patient presents with segmental distribution of a disorder, it is critical to determine if the disorder is a result of mosaicism or LOH. In LOH, the abnormal allele is present throughout the body, including gonadal tissue. In a patient who presents with segmental neurofibromatosis but has Lisch nodules or axillary freckling, LOH rather than mosaicism is likely to account for the segmental presentation. The risk of passing the gene to a child is about 50/50. A geneticist should be involved during discussions of risk of transmission because the mechanisms may be complex. Patients with mosaicism based on postzygotic somatic gene mutation may have gonadal mosaicism and may be capable of passing on the gene. Gonadal mosaicism is more likely when more than one segment is present on different regions of the body. Before gastrulation, when a cavity forms in the embryo, every cell is pluripotent and can give rise to an entire organism, or it can contribute to multiple sites of the body. At gastrulation, cells become dedicated to produce specific segments of the body. Blaschko segments in different regions suggest a mutation that occurred before gastrulation, when the involved cell lines could contribute to different parts of the body, including the gonads. Polygenetic disorders, such as psoriasis, may also present with limited and linear forms that may relate to segmental LOH or postzygotic mutation.

Online Mendelian Inheritance in Man (OMIM.org) contains a comprehensive database of known genetic disorders and has a search function that allows the clinician to match clinical manifestations with possible diagnoses. PubMed's clinical query function can also be used to match manifestations with syndromes, and [Genetest.org](http://Genetest.org) lists sources for genetic testing.

**Happle R:** Superimposed segmental manifestation of polygenetic skin disorders. *J Am Acad Dermatol* 2007; 57(4):690-699.

### X-LINKED, MOSAIC, AND RELATED DISORDERS

#### INCONTINENTIA PIGMENTI

Also known as Bloch-Sulzberger disease, incontinentia pigmenti is an X-linked dominant condition characterized by whorled pigmentation on the trunk, preceded by vesicular and verrucous changes. It appears in girls during the first weeks after birth (Fig. 27-1). Most lesions are evident by the time the infant is 4-6 weeks old. A vesicular phase is present in 87% of cases. This first stage begins in most individuals before 6 weeks of age and is replaced by verrucous lesions after several weeks



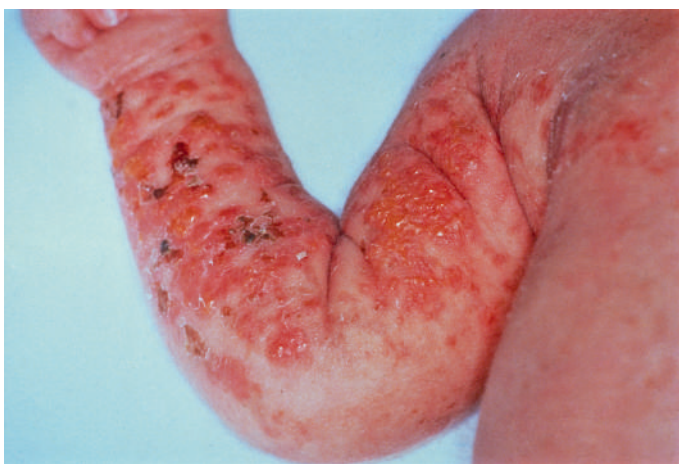

Fig. 27-1 Early incontinentia pigmenti.

to months in two thirds of patients. Although these usually resolve by 1 year of age, lesions may persist for many years. In the third, or pigmentary, phase, pigmented macules in streaks, sprays, splatters, and whorls follow the lines of Blaschko. The pigmentary stage may last for many years and then fade away, leaving no sequelae. A fourth stage may be seen in some adult women, manifesting subtle, faint, hypochromic or atrophic linear lesions, most often on the extremities.

Histologically, the vesicular stage is characterized by spongiosis with eosinophils. As the lesions mature, clusters of dyskeratotic cells appear within the epidermis. Dyskeratotic cells predominate in the verrucous stage, and pigment incontinence (dermal melanophages) predominates in hyperpigmented lesions.

Other cutaneous changes include patchy alopecia at the vertex of the scalp, atrophic changes simulating acrodermatitis chronica atrophicans on the hands, onychodystrophy, late subungual tumors that resemble subungual keratoacanthoma and may have underlying lytic bone lesions, and palmoplantar hyperhidrosis. Extracutaneous manifestations occur in 70–90% of patients. Most frequently involved are the teeth (up to 90%), bones (40%), central nervous system (CNS; 33%), and eyes (35%). Immune dysfunction with defective neutrophil chemotaxis and elevated IgE has been reported. Eosinophilia is common. Incontinentia pigmenti is an important cause of neonatal seizures and encephalopathy.

Dental abnormalities usually manifest by the time the individual is 2 years old. Dental defects include delayed eruption, partial anodontia (43%), microdontia, and cone- or peg-shaped teeth (30%). The most common CNS findings are seizures (13%), mental retardation (12%), spastic paralysis (11%), microcephaly, destructive encephalopathy, and motor impairment. The eye changes include strabismus, cataracts, retinal detachments, optic atrophy, blue sclerae, and exudative chorioretinitis. Skeletal abnormalities include syndactyly, skull deformities, dwarfism, spina bifida, clubfoot (talipes), supernumerary ribs, hemiatrophy, and shortening of the legs and arms.

Incontinentia pigmenti is caused by a mutation in the nuclear factor- $\kappa$ B (*NEMO*) gene on the X chromosome, localized to Xq28. The gene is generally lethal in male fetuses, although males with Klinefelter syndrome (47,XXY) may survive. Mosaicism may also account for some cases in males. *NEMO* mutations also cause X-linked ectodermal dysplasia with immunodeficiency, characterized by alopecia, hypohidrosis, dental anomalies, and defects in humoral immunity. Osteopetrosis and lymphedema may be present.

Incontinentia pigmenti achromians differs in that it is a “negative image,” with hypopigmentation (see section after

next). It has autosomal dominant inheritance, no vesicular or verrucous stages, and a higher incidence of CNS abnormalities. Patients with linear and whorled nevoid hypermelanosis lack the vesicular and verrucous phases.

X-linked reticulate pigmentation disorder with systemic manifestations is a rare X-linked recessive genodermatosis that mimics stage III incontinentia pigmenti. In males, cutaneous involvement is characterized by reticulate hyperpigmentation of the skin, characteristic facies, and severe systemic involvement. In the carrier females, manifestations are limited to the skin.

Mendelian susceptibility to mycobacterial disease is a rare syndrome predisposing to infection with weakly virulent mycobacteria, such as *Mycobacterium bovis*, bacille Calmette-Guérin (BCG), and environmental nontuberculous mycobacteria. The causative mutations in *NEMO* selectively affect the CD40-dependent induction of interleukin-12 (IL-12) in mononuclear cells.

Use of ruby lasers to treat pigmented lesions in infants and young children may worsen the condition. Usually, the end stage of streaks of incontinentia pigmenti starts to fade at age 2 years, and by adulthood, there may be minimal residual pigmentation.

## NAEGELI-FRANCESCHETTI-JADASSOHN SYNDROME

Also known as the chromatophore nevus of Naegeli, Naegeli-Franceschetti-Jadassohn syndrome differs from incontinentia pigmenti in that the pigmentation is reticular, with no preceding inflammatory changes, vesiculation, or verrucous lesions. Vasomotor changes and hypohidrosis are present. There is reticulate pigmentation involving the neck, flexural skin, and perioral and periorbital areas. Diffuse keratoderma and punctiform accentuation of the palms and soles may occur. Dermatoglyphics are abnormal, producing atrophic or absent ridges on fingerprints. Congenital malalignment of the great toenails may be found. Dental abnormalities are common, and many patients are edentulous. Both genders are equally affected, and the syndrome appears to be transmitted as an autosomal dominant trait related to mutations in keratin 14, causing increased susceptibility to tumor necrosis factor (TNF)- $\alpha$ -induced apoptosis. The syndrome is allelic to dermatopathia pigmentosa reticularis.

**Bustamante J, et al:** Genetic lessons learned from X-linked mendelian susceptibility to mycobacterial diseases. *Ann NY Acad Sci* 2011; 1246:92–101.

**Fusco F, et al:** Incontinentia pigmenti: report on data from 2000 to 2013. *Orphanet J Rare Dis* 2014; 9:93.

**Itin PH, et al:** Spontaneous fading of reticular pigmentation in Naegeli-Franceschetti-Jadassohn syndrome. *Dermatology* 2010; 221(2):135–136.

**Mahmoud BH, et al:** Controversies over subungual tumors in incontinentia pigmenti. *Dermatol Surg* 2014; 40:1157–1159.

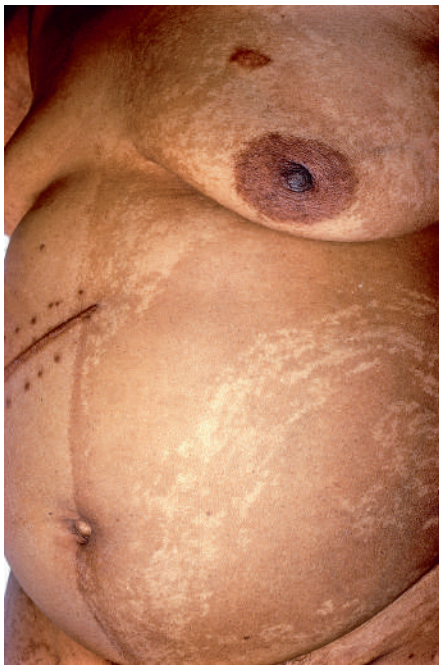**Marques GF, et al:** Incontinentia pigmenti or Bloch-Sulzberger syndrome: a rare X-linked genodermatosis. *An Bras Dermatol* 2014; 89:486–489.

**Minić S, et al:** Systematic review of central nervous system anomalies in incontinentia pigmenti. *Orphanet J Rare Dis* 2013; 8:25.

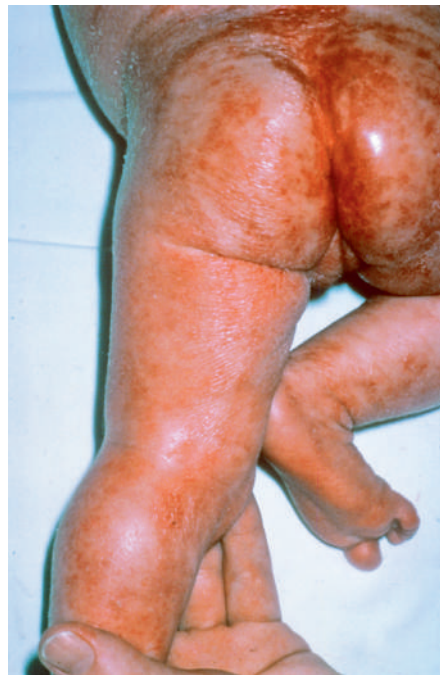**Okita M, et al:** *NEMO* gene rearrangement (exon 4-10 deletion) and genotype-phenotype relationship in Japanese patients with incontinentia pigmenti and review of published work in Japanese patients. *J Dermatol* 2013; 40(4):272–276.

**Poziomczyk CS, et al:** ncontinentia pigmenti. *An Bras Dermatol* 2014; 89:26–36.

**Zhang Y, et al:** Incontinentia pigmenti (Bloch-Siemens syndrome). *Eur J Pediatr* 2013; 172(8):1137–1138.



**Fig. 27-2** Incontinentia pigmenti achromians.



**Fig. 27-3** Chondrodysplasia punctata.

### INCONTINENTIA PIGMENTI ACHROMIANS (HYPOMELANOSIS OF ITO)

Incontinentia pigmenti achromians (IPA) is characterized by various patterns of bilateral or unilateral hypopigmentation following the lines of Blaschko (Fig. 27-2). The lesions suggest the “negative image” of incontinentia pigmenti and usually develop by the first year of life. The female/male ratio is about 2.5:1. Three quarters of affected individuals have associated anomalies of the CNS, eyes, hair, teeth, skin, nails, musculo-skeletal system, or internal organs, including polycystic kidney disease. Patients may manifest psychomotor or mental impairment, autism, microcephaly, coarse facies, and dysmorphic ears. Some patients have had associated Sturge-Weber syndrome-like leptomeningeal angiomatosis.

More than half of IPA patients have chromosomal abnormalities, with most demonstrating mosaicism for aneuploidy or unbalanced translocations. Several patients have demonstrated trisomy 13 mosaicism. No inflammatory changes or vesiculation are found before the development of the hypopigmentation. There is no treatment, but eventual repigmentation is the rule.

**Baxter LL, et al:** The etiology and molecular genetics of human pigmentation disorders. *Wiley Interdiscip Rev Dev Biol* 2013; 2(3):379–392.

### LINEAR AND WHORLED NEVOID HYPERMELANOSIS

This disorder of pigmentation develops within a few weeks of birth and progresses for 1–2 years before stabilizing. There is linear and whorled hyperpigmentation following the lines of Blaschko, without preceding bullae or verrucous lesions. Sparing of mucous membranes, eyes, palms, and soles is noted. Congenital anomalies, such as mental retardation, cerebral palsy, atrial septal defects, dextrocardia, auricular atresia, hemiatrophy, and patent ductus arteriosus may be present. Bilateral giant cerebral aneurysms have been reported. There is no sexual predilection. Biopsy of pigmented areas demonstrates increased pigmentation of the basal layer and prominence of melanocytes without incontinence of pigment.

Most cases appear to be sporadic, although familial cases have been reported. Sporadic forms have been attributed to mosaicism. Because of confusion with other pigmented disorders, such as incontinentia pigmenti, early linear epidermal nevi, hypomelanosis of Ito, and nevus depigmentosus, it is likely that linear and whorled nevoid hypermelanosis may be more common than previously appreciated.

**Cohen J 3rd, et al:** Analysis of 36 cases of Blaschkoid dyspigmentation: reading between the lines of Blaschko. *Pediatr Dermatol* 2014; 31:471–476.

**Mehta V, et al:** Linear and whorled nevoid hypermelanosis. *Int J Dermatol* 2011; 50(4):491.

**Metta AK, et al:** Linear and whorled nevoid hypermelanosis in three successive generations. *Indian J Dermatol Venereol Leprol* 2011; 77(3):403.

### CHONDRODYSPLASIA PUNCTATA

A variant of the original Conradi-Hünemann syndrome or chondrodystrophia calcificans congenita, chondrodysplasia punctata is characterized by ichthyosis of the skin similar to that of the collodion baby, followed by hyperkeratotic “whirl and swirl” patterns on erythematous skin. In addition to reddening, the waxy, shiny skin has hyperkeratotic scales of a peculiar, crushed-eggshell configuration (Fig. 27-3). As the child grows, follicular atrophoderma and pseudopelade develop. Usually, the ichthyosis clears within the first year of life but may leave behind hyperpigmentation similar to that seen in incontinentia pigmenti. An additional feature is minor nail defects, such as platonychia and onychoschizia.

There are four forms of chondrodysplasia punctata, classified by their inheritance patterns. The Conradi-Hünemann type is associated with autosomal dominant inheritance, facial dysmorphism with a low nasal bridge, short stature, mild disease, cataracts, and few skin lesions. The rhizomelic form has autosomal recessive inheritance, marked shortening of the extremities, cataracts, ichthyosis, and nasal hypoplasia; the patient dies in infancy. The X-linked recessive type has been described as part of contiguous gene deletion syndromes, with short stature, telebrachydactyly, and nasal hypoplasia. The X-linked dominant form (Happle syndrome, Conradi-Hünemann-Happle syndrome, or CDPX2) is lethal in males.



Happle syndrome (X-linked dominant chondrodysplasia punctata) has ichthyosiform erythroderma along the lines of Blaschko, cataracts, asymmetric limb shortening, and calcified stippling of the epiphyses of long bones. Follicular atrophoderma replaces the erythroderma after the first year.

The skeletal defects revealed on radiographic evaluation include irregular calcified stippling of the cartilaginous epiphyses in the long bones, costal cartilages, and vertebral diaphysis. The stippling occurs in the fetus and persists until age 3 or 4 years. The humeri and femurs may be shortened, and joint dysplasia may occur. Histologic evaluation of the ichthyotic lesions reveals a thinned, granular cell layer, calcification of keratotic follicular plugs, and focal hyperpigmentation of basal keratinocytes. The keratotic follicular plugs and calcium deposits are characteristic of chondrodysplasia punctata and helpful in establishing the diagnosis in newborns. Various types are related to defects in peroxisomal metabolism, plasmalogen, and cholesterol biosynthesis. X-linked recessive chondrodysplasia punctata (CDPX1) is caused by a defect in arylsulfatase E, located on Xp22.3. There may be an association between the rhizomelic variety and maternal autoimmunity and connective tissue disease.

**Aubourg P, et al:** Peroxisomal disorders. *Handb Clin Neurol* 2013; 113:1593–609.

**Kanungo S, et al:** Sterol metabolism disorders and neurodevelopment: an update. *Dev Disabil Res Rev* 2013; 17(3):197–210.

**Lambrecht C, et al:** Conradi-Hünermann-Happle syndrome: a novel heterozygous missense mutation, c.204G>T (p.W68C). *Pediatr Dermatol* 2014; 31:493–496.

## KLINEFELTER SYNDROME

Klinefelter syndrome, the most common sex chromosome disorder, consists of hypogonadism, gynecomastia, eunuchoidism, small or absent testicles, and elevated gonadotropins. The patient may have a low frontal hairline, sparse body hair with only a few hairs in the axillary and pubic areas, scanty or absent facial hair in men, and shortening of the fifth digit of both hands.

Thrombophlebitis and recurrent or chronic leg ulcerations may be a presenting manifestation; these may be more common than previously reported. The cause of the hypercoagulable state is believed to be an increase in plasminogen activator inhibitor 1 levels. Patients are at an increased risk of lupus erythematosus and a variety of cancers, especially male breast cancer, hematologic malignancies, and sarcomas (retinoblastoma and rhabdomyosarcoma).

Many of these patients are tall; some are obese. Dull mentality is common, and psychiatric disorders occur in about one third of patients. Klinefelter syndrome is most frequently associated with an XXY sex chromosome pattern, although other variations occur as the number of X chromosomes increases. Androgen therapy may result in improvements in appearance and function.

## XXYY GENOTYPE

The XXYY genotype is considered to be a variant of Klinefelter syndrome. In addition to the changes seen in Klinefelter, vascular changes occur in XXYY patients, such as cutaneous angiomias, acrocyanosis, and peripheral vascular disease leading to stasis dermatitis. Hypertelorism, clinodactyly, pes planus, and dental abnormalities are common. Systemic manifestations include asthma, cardiac defects, radioulnar synostosis, inguinal hernia, cryptorchidism, CNS defects, attention deficit disorder, autism, and seizures.

## TURNER SYNDROME

Turner syndrome, also known as gonadal dysgenesis, is characterized by a webbed neck, low posterior hairline margin, increased carrying angle at the elbow (cubitus valgus), congenital lymphedema, and a triangular mouth. Patients may demonstrate alopecia of the frontal area on the scalp, koilonychia, cutis laxa, cutis hyperelastica, mental retardation, short stature, infantilism, impaired sexual development, primary amenorrhea, numerous melanocytic nevi, angiokeratomas, and an increased risk of melanoma, pilomatricoma, and thyroid disease. Coarctation of the aorta is frequently found. There may be an increased incidence of alopecia areata and halo nevi in these patients.

Patients with Turner syndrome have only 45 chromosomes rather than the normal 46. An X chromosome is missing, resulting in an XO genotype. Mosaicism, structural abnormalities of the X chromosome, or a partial deficiency of one sex chromosome may account for a number of the variations in gonadal dysgenesis. Several genetic loci have been implicated, including the short-stature homeobox gene. Loss of long-arm material (Xq) can result in short stature and ovarian failure, but deletions distal to Xq21 do not appear to affect stature. Loss of the short arm (Xp) produces the full phenotype. Patients with very distal Xp deletions usually have normal ovarian function.

No specific treatment is available for Turner syndrome. Human growth hormone (hGH) has been used to treat the short stature. A review of the Cochrane Central Register of Controlled Trials determined that hGH increases short-term growth, but few data exist regarding its effects on final height.

Multiple pterygium syndrome (Escobar syndrome) is a rare autosomal recessive disorder characterized by multiple congenital joint contractures and multiple skin webs that may mimic Turner syndrome.

**Castelo-Branco C:** Management of Turner syndrome in adult life and beyond. *Maturitas* 2014; 79:471–475.

**Güven A, et al:** Multiple pterygium syndrome: mimicking the findings of Turner syndrome. *J Pediatr Endocrinol Metab* 2011; 24(11-12):1089–1093.

## NOONAN SYNDROME

Noonan syndrome is an autosomal dominant disease associated with a webbed neck that mimics Turner syndrome. Males and females are equally affected, and the chromosome number is normal. The other major features are a characteristic facies with hypertelorism, prominent ears, short stature, undescended testicles, low posterior neck hairline, cardiovascular abnormalities (e.g., pulmonary stenosis), and cubitus valgus. From 25% to 40% of patients have dermatologic findings: lymphedema, short curly hair, dystrophic nails, tendency toward keloid formation, soft elastic skin, keratosis pilaris atrophicans (ulerythema of eyebrows), multiple granular cell tumors, and abnormal dermatoglyphics. The Noonan syndrome gene, *PTPN11*, encodes the nonreceptor protein tyrosine phosphatase SHP-2, involved in the RAS/MAPK pathway. Growth hormone can help patients achieve more normal stature.

Noonan syndrome is grouped among the RASopathies—overlapping neurodevelopmental syndromes resulting from germline mutations in genes that participate in the rat sarcoma/mitogen-activated protein kinase (RAS/MAPK) pathway (*PTPN11*, *SOS1*, *RAF*, *KRAS* or *NRAS*, and *SHOC2*). Patients with Noonan syndrome may have *SOS1* mutations associated with normal cognition and stature, *RAF1* mutations

entailing a high risk of hypertrophic cardiomyopathy, specific *PTPN11* mutations predisposing to juvenile myelomonocytic leukemia, or *SHOC2* mutation (p.Ser2Gly) associated with loose anagen syndrome. Certain characteristics in early childhood suggest the diagnosis of a RASopathy, including congenital heart defects, severe feeding difficulties, and delay of developmental milestones, together with hair and skin anomalies. Feeding difficulties and developmental motor delay are the most common features with the cardiofaciocutaneous syndrome and Costello syndrome. Thin hair is common among *SHOC2* and *BRAF* mutation-positive infants. Café au lait spots are found in patients with *LS* and *PTPN11* mutations, whereas keratosis pilaris is more common in those with *SOS1*, *SHOC2*, and *BRAF* mutations. Many patients with the RASopathies appear to have an increased risk of lupus erythematosus. Legius syndrome is classified as a RASopathy, but is discussed later with the differential diagnosis of neurofibromatosis, which is traditionally classified as a phakomatosis.

### MULTIPLE LENTIGINES (LEOPARD) SYNDROME

The LEOPARD syndrome – multiple lentigines, electrocardiographic conduction abnormalities, ocular hypertelorism, pulmonary stenosis, abnormal genitalia, retardation of growth, and sensorineural deafness—is also known as multiple lentigines syndrome, cardio-cutaneous syndrome, lentiginosis profusa syndrome, or progressive cardiomyopathic lentiginosis. The lentigines are small, dark-brown, polygonal, and irregularly shaped macules, usually measuring 2–5 mm in diameter. Individual lesions may be larger, even up to 1–1.5 cm. Melanoma has been described in these patients, so atypical lesions should be biopsied.

The LEOPARD syndrome shares many clinical features with Noonan syndrome. These are allelic disorders; patients with both syndromes demonstrate mutations in the Noonan syndrome gene, *PTPN11*. Although the “R” in LEOPARD indicates growth retardation, some patients with the syndrome also exhibit mild mental retardation or speech difficulties. Many cases appear sporadically; however, inheritance as an autosomal dominant genetic trait has also been reported.

### COSTELLO SYNDROME

Costello syndrome is characterized by growth retardation; failure to thrive in infancy; coarse facies; redundant skin on the neck, palms, soles, and fingers; acanthosis nigricans; and nasal papillomata. Ventricular dilation is observed in more than 40% of cases. Hydrocephalus, brain atrophy, Chiari malformation, and syringomyelia may occur. Mild to moderate mental deficiency is frequently discovered, and most patients exhibit a characteristic sociable and friendly personality.

### CARDIOFACIOCUTANEOUS SYNDROME

Cardiofaciocutaneous (CFC) syndrome is characterized by a distinctive facial appearance, heart defects, and mental retardation. Facial characteristics include high forehead with bitemporal constriction, downslanting palpebral fissures, hypoplastic supraorbital ridges, a depressed nasal bridge, and posteriorly angulated ears with prominent helices. The heart defects include pulmonic stenosis, atrial septal defect, and hypertrophic cardiomyopathy. Patients may have ectodermal abnormalities, including sparse breakable hair, hyperkeratotic skin lesions, and a generalized ichthyosis-like condition. Most cases occur sporadically, but autosomal dominant transmission has

been reported. Various subtypes relate to different genes in the RAS/MAPK pathway, including *KRAS*, *BRAF*, and *MAP2K1/2* mutations.

The most frequent dermatologic findings in CFC patients involve the hair, which may be sparse, curly, fine or thick, woolly or brittle. In more than half of the reported cases, the patient had dry, scaly, or “hyperkeratotic,” ichthyotic skin. Other cutaneous findings include sparse or absent eyebrows and eyelashes, low posterior hairline, patchy alopecia, scant body hair, follicular hyperkeratosis, keratosis pilaris, keratosis pilaris atrophicans faciei, palmoplantar keratoderma, seborrheic dermatitis, eczema, lymphedema, hemangiomas, café au lait spots, pigmented nevi, hyperpigmented macules or stripes, cutis marmorata, and sacral dimples. Nail dystrophy, koilonychia, and dysplastic teeth have also been reported.

The differential diagnosis includes Noonan syndrome, Pallister-Killian mosaic aneuploid syndrome (mosaic tetrasomy 12p/trisomy 12p), and Costello syndrome. The difficulty often arises in assessing the facial features, which are similar in all these syndromes. Exclusion of *PTPN11* mutations in CFC syndrome and Costello syndrome confirms distinct genetic etiologies.

### EPIDERMAL NEVUS SYNDROMES

Important clues to the diagnosis of specific epidermal nevus syndromes include linear lesions with nevus sebaceus (NS) in Schimmelpenning syndrome, NS and papular nevus spilus in phacomatosis pigmentokeratotic, soft white hair in angora hair nevus syndrome (Schauder syndrome), breast hypoplasia in Becker nevus syndrome, mosaic R248 C mutation in fibroblast growth factor receptor 3 epidermal nevus (EN) syndrome (characterized by soft velvety EN and CNS abnormalities), and acral strawberry papillomatous lesions on tips of fingers or toes in CHILD syndrome. Other EN syndromes include nevus trichilemmocysticus (cysts in blaschkoid distribution), didymosis aplasticosebacea (NS with aplasia cutis congenita), SCALP syndrome (NS, CNS malformations, aplasia cutis, limbal dermoid, and pigmented nevus), Gorbello syndrome (systematized linear velvety EN with bone defects), NEVADA syndrome (nevus epidermicus verrucosus with angiodysplasia and aneurysms), and CLOVE syndrome (congenital lipomatous overgrowth, vascular malformations, and EN with nonprogressive proportionate overgrowth).

**Aoki Y, et al:** Ras/MAPK syndromes and childhood hemato-oncological diseases. *Int J Hematol* 2013; 97(1):30–36.

**Balsera AM, et al:** Distinct mechanism of formation of the 48, XXYY karyotype. *Mol Cytogenet* 2013; 6(1):25.

**Cirstea IC, et al:** Diverging gain-of-function mechanisms of two novel *KRAS* mutations associated with Noonan and cardio-facio-cutaneous syndromes. *Hum Mol Genet* 2013; 22(2):262–270.

**Dillon S, et al:** Klinefelter’s syndrome (47,XXY) among men with systemic lupus erythematosus. *Acta Paediatr* 2011; 100(6):819–823.

**Hafner C, et al:** Keratinocytic epidermal nevi are associated with mosaic *RAS* mutations. *J Med Genet* 2012; 49(4):249–253.

**Hafner C, et al:** Mosaic RASopathies. *Cell Cycle* 2013; 12(1):43–50.

**Laura FS:** Epidermal nevus syndrome. *Handb Clin Neurol* 2013; 111:349–368.

**Martínez-Quintana E, et al:** LEOPARD syndrome: clinical features and gene mutations. *Mol Syndromol* 2012; 3(4):145–157.

**Myers A, et al:** Perinatal features of the RASopathies: Noonan syndrome, cardiofaciocutaneous syndrome and Costello syndrome. *Am J Med Genet A* 2014; 164:2814–2821.

**Niemeyer CM:** RAS diseases in children. *Haematologica* 2014; 99:1653–1662.

**Rauen KA:** The RASopathies. *Annu Rev Genomics Hum Genet* 2013; 14:355–369.



Rogol AD, et al: Considerations for androgen therapy in children and adolescents with Klinefelter syndrome (47, XXY). *Pediatr Endocrinol Rev* 2010; 8(Suppl 1):145–150.

Tumurkhuu M, et al: A novel SOS1 mutation in Costello/CFC syndrome affects signaling in both RAS and PI3K pathways. *J Recept Signal Transduct Res* 2013; 33(2):124–128.

## PHAKOMATOSES

The phakomatoses are the various inherited disorders of the CNS associated with congenital retinal tumors and cutaneous involvement. These include tuberous sclerosis, von Recklinghausen's disease (neurofibromatosis), von Hippel-Lindau disease (angiomas retinae), ataxia-telangiectasia, nevoid basal cell carcinoma syndrome, nevus sebaceus, and Sturge-Weber syndrome.

## TUBEROUS SCLEROSIS (EPILOIA, BOURNEVILLE DISEASE)

Tuberous sclerosis, described by Desiree-Magloire Bourneville in 1880, is also called epiloia (*epi*, epilepsy; *loi*, low intelligence; *a*, adenoma sebaceum). This classic triad of adenoma sebaceum (Fig. 27-4), mental deficiency, and epilepsy, however, is present in only a minority of patients. Other associated features include periungual fibromas, shagreen plaques (col-

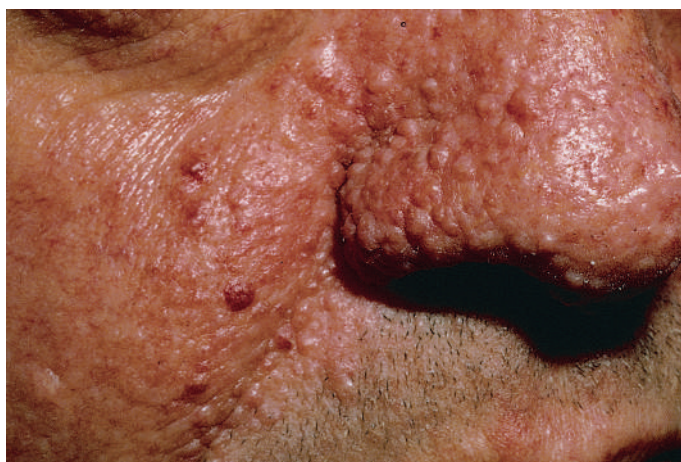

Fig. 27-4 Angiofibromas (adenoma sebaceum).

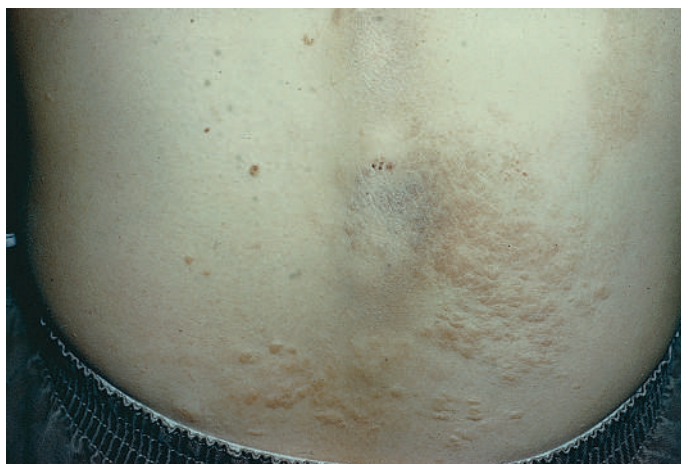


Fig. 27-5 Shagreen patch.

lagenoma), oral papillomatosis (Fig. 27-5), gingival hyperplasia, ash-leaf hypomelanotic macules (Fig. 27-6), skin fibromas, and café au lait spots.

Adenoma sebaceum lesions (angiofibromas) are 1–3 mm, yellowish red, translucent, discrete, waxy papules that are distributed symmetrically, principally over the cheeks, nose, and forehead. They have also been reported in patients with multiple endocrine neoplasia (MEN-1) and the Birt-Hogg-Dube syndrome. These lesions are present in 90% of patients older than 4 years, persist indefinitely, and may increase in number.

Shagreen plaque is named after a type of leather tanned to produce knobs on the surface, resembling shark skin. Patches of this type of “knobby” skin, varying from 1 to 8 cm in diameter, are found on the trunk, most often on the lumbosacral area. These are connective tissue nevi composed almost exclusively of collagen, occur in 40% of patients, and develop in the first decade of life.

Koenen tumors (periungual angiofibromas) occur in 50% of patients (Fig. 27-7). The tumors are small, digitate, protruding, asymptomatic, and periungual/subungual. They appear at puberty. Similar lesions may occur on the gingiva. Nails may also demonstrate longitudinal grooves, long leukonychia, and short red streaks.

Congenital white, leaf-shaped macules, also called hypomelanotic macules, are found in 85% of patients with tuberous sclerosis, ranging in number from 1 to 100. Occasional patients may not develop the macules until 6–8 years of age. These may be shaped like an ash leaf, but linear and confetti-type white

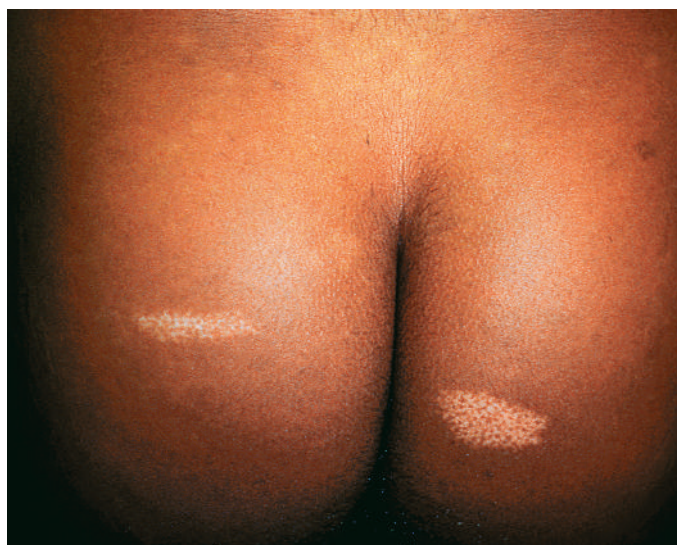

Fig. 27-6 Ash-leaf macules.

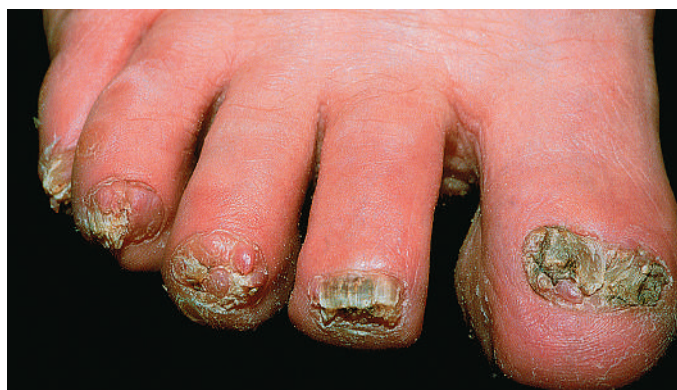

Fig. 27-7 Periungual fibromas.

macules may also be present. Wood's light examination should be performed when evaluating a patient for tuberous sclerosis. Focal poliosis (localized tufts of white hair) may be present at birth. Solitary ash-leaf macules can occur in the general population and may be confused with other hypopigmented macules, such as nevus depigmentosus.

Mental deficiency, usually appreciated early in life, is present in 40–60% of patients, varying widely in its manifestations. Epilepsy also occurs, is variable in its severity, and usually also presents early in life. Between 80% and 90% of patients have seizures or nonspecific electroencephalographic abnormalities. Hamartomatous proliferations of glial and neuronal tissue produce potato-like nodules in the cortex. X-ray evaluation will reveal these once calcified, but computed tomography (CT), cranial ultrasonography, and magnetic resonance imaging (MRI) may define these lesions as early as 6 weeks of age and thus are useful in making an early diagnosis. These brain tumors may progress to gliomas. Subependymal nodules ("candle drippings") are similar lesions in the ventricular walls. Astrocytomas may also occur. Forehead plaques may be a marker for more serious intracranial involvement.

Retinal tumors (phakomas) occur, which are optic nerve or retinal nerve hamartomas. Various ophthalmologic findings, such as pigmentary changes, nystagmus, and angioid streaks, occur in 50% of patients. Renal hamartomas (angiomyolipomas in 45%, cystic disease in 18%, fibroadenomas, or mixed tumors) and cardiac tumors (rhabdomyomas in 43%) may also occur. In the familial variety of tuberous sclerosis, 80% of patients have angiomyolipomas, which often are bilateral and cause renal failure. Women of childbearing age may present with pulmonary lymphangioleiomyomatosis with progressive respiratory failure or spontaneous pneumothorax. Newer evidence suggests that the majority of adult women with tuberous sclerosis develop at least some pulmonary manifestations of the disease. The condition is characterized by diffuse proliferation of smooth muscle cells and cystic degeneration of the pulmonary parenchyma, associated with the perivascular epithelioid cells ("PEC" cells) implicated in various PEComas. Almost half of patients with epiloia have bony abnormalities such as bone cysts and sclerosis, which can be seen on x-ray evaluation. Five or more pits in the enamel of permanent teeth are a marker for this disease.

Tuberous sclerosis is a common inherited autosomal dominant disease with highly variable penetrance. Prevalence estimates range from 1 in 5800 to 1 in 15,000. Up to 50% of cases may result from spontaneous mutations. There are two genes, the mutations of which produce indistinguishable phenotypes—9q34 (*TSC1*) and 16p13.3 (*TSC2*). *TSC1* and *TSC2* are tumor suppressor genes. *TSC2* encodes for tuberin, a putative guanosine triphosphatase (GTPase)-activating protein for rap1 and rab5. *TSC1* encodes for hamartin, a novel protein with no significant homology to tuberin or any other vertebrate protein. Hamartin and tuberin associate physically *in vivo*, suggesting that they function in the same complex rather than in separate pathways. This interaction of tuberin and hamartin explains the indistinguishable phenotypes caused by mutations in either gene. Hamartomas frequently demonstrate loss of the remaining normal allele (loss of heterozygosity).

## Diagnosis

The ash-leaf macules are usually present at birth in tuberous sclerosis patients and are most easily seen with Wood's light. If x-ray examination fails to show calcified intracranial nodules, ultrasonography, CT, or MRI should be performed. Fundoscopic examination, hand and foot x-ray evaluation, and renal ultrasonography are often rewarding in a patient with few

clinical findings; up to 31% of asymptomatic parents have been identified using these tests.

Multiple periungual fibromas are highly correlated with the syndrome, but solitary fibromas may occur in unaffected individuals. Molecular analysis for *TSC1* and *TSC2* may be the only way to identify "mildly affected" individuals.

## Treatment

Adenoma sebaceum can be treated by shaving, dermabrasion, or laser therapy. Lesions are likely to recur, requiring repeat treatment. Cranial irradiation of astrocytomas should be avoided because this may result in the subsequent development of glioblastomas. Topical and systemic mammalian target of rapamycin (mTOR) inhibitors offer a nonsurgical alternative to treatment of angiofibromas. Everolimus was the first mTOR inhibitor approved in the United States and Europe as a treatment for subependymal giant cell astrocytomas. Clinical evidence also supports the use of mTOR inhibitors, including sirolimus, in a variety of tuberous sclerosis complex-associated disease manifestations, including facial angiofibromas, renal angiomyolipoma, and epilepsy.

**Cudzilo CJ, et al:** Lymphangioleiomyomatosis screening in women with tuberous sclerosis. *Chest* 2013; 144(2):578–585.

**Curatolo P, et al:** mTOR inhibitors in tuberous sclerosis complex. *Curr Neuropharmacol* 2012; 10(4):404–415.

**Liebman JJ, et al:** Koenen tumors in tuberous sclerosis: a review and clinical considerations for treatment. *Ann Plast Surg* 2014; 73:721–722.

**Teng JM, et al:** Dermatologic and dental aspects of the 2012 International Tuberous Sclerosis Complex Consensus Statements. *JAMA Dermatol* 2014; 150:1095–1101.

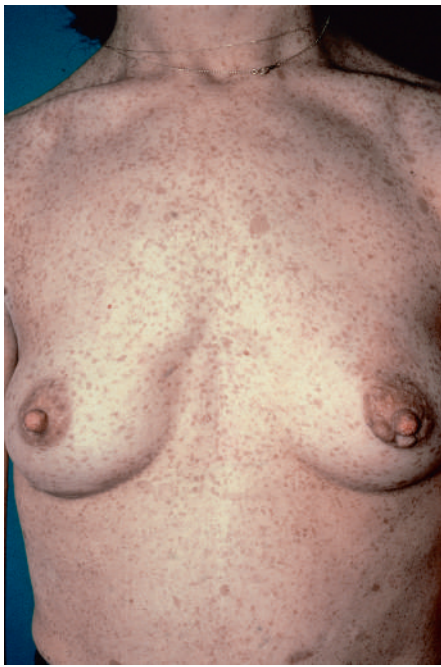**Tu J, et al:** Topical rapamycin for angiofibromas in paediatric patients with tuberous sclerosis: follow-up of a pilot study and promising future directions. *Australas J Dermatol* 2014; 55(1):63–69.

## NEUROFIBROMATOSIS (VON RECKLINGHAUSEN'S DISEASE)

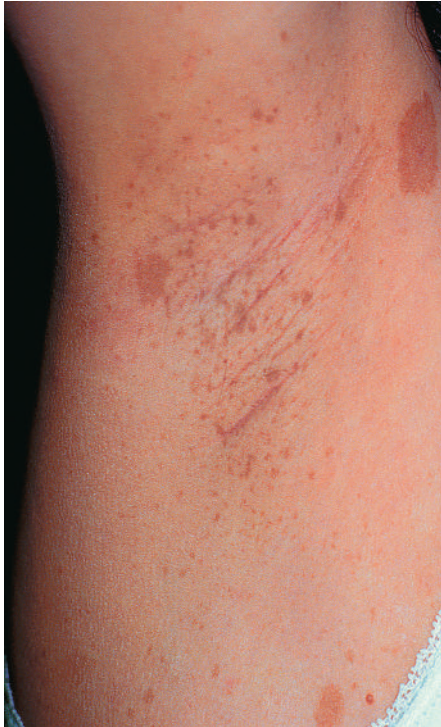Neurofibromatosis is an autosomal dominant inherited syndrome manifested by developmental changes in the nervous system, bones, and skin. In type 1 neurofibromatosis (NF-1, von Recklinghausen's disease), which includes more than 85% of cases, patients have many neurofibromas (Fig. 27-8), café au lait spots, axillary freckles (Fig. 27-9), giant pigmented hairy nevi, sacral hypertrichosis, cutis verticis gyrata, and macroglossia. Neurofibromas of the areolae occur in more than 90% of women with NF-1. Lisch nodules are found in the irides of about one quarter of patients under 6 years of age and in 94% of adult patients. Type 2 neurofibromatosis (NF-2), central or acoustic neurofibromatosis, is distinguished by bilateral acoustic neuromas, usually in the absence of cutaneous lesions, although neurofibromas and schwannomas may occur. Type 3 (mixed) and type 4 (variant) forms resemble type 2 but have cutaneous neurofibromas. Patients with these types are at greater risk for developing optic gliomas, neurilemmomas, and meningiomas. These forms are inherited as autosomal dominant traits. Segmental neurofibromatosis may arise from postzygotic somatic mutation or LOH (Fig. 27-10).

Neurofibromas are soft tumors that can be pushed down into the panniculus by light pressure with the finger ("buttonholing") and spring back when released. Histologically, these are well-circumscribed, but rarely encapsulated, spindle cell proliferations with an amphophilic myxoid stroma and many mast cells. The spindle cells have a wavy appearance. Neurofibromas result from proliferation of all supporting elements of the nerve fibers, including Schwann, perineurial,

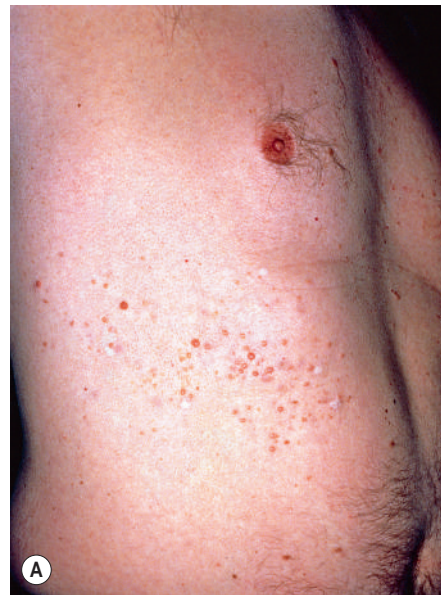



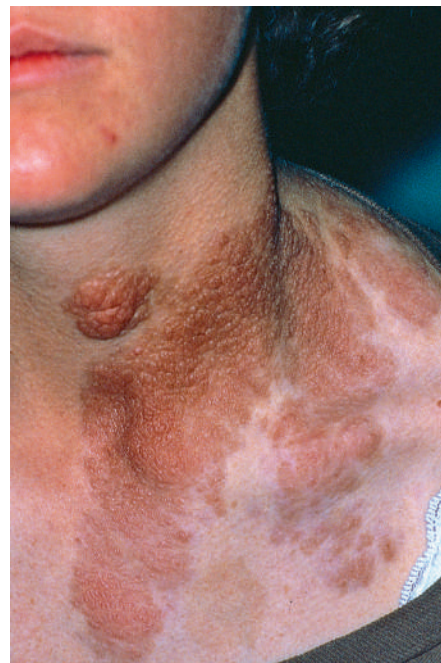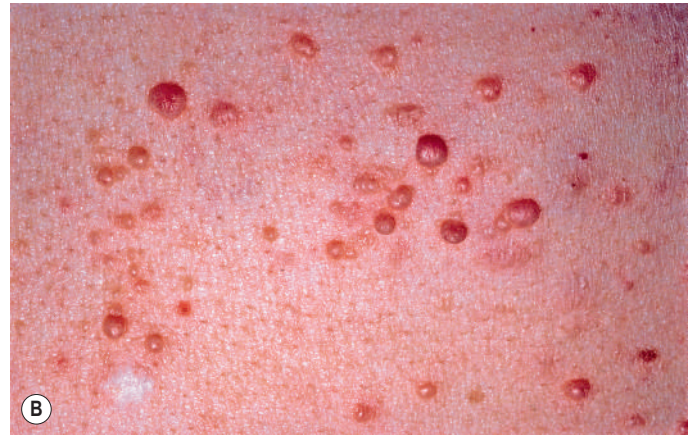
**Fig. 27-8**  
Neurofibromatosis  
type 1.



**Fig. 27-9** Axillary  
freckling.



**Fig. 27-10** A and  
B, Segmental  
neurofibromatosis.



**Fig. 27-11** Plexiform  
neurofibroma.

endoneurial, and mast cells and blood vessels. Axon stains demonstrate individual axons spread randomly throughout the tumor, in contrast to a schwannoma, where a nerve trunk is compressed at one edge of the tumor, but no axons are present within its bulk.

Subcutaneous plexiform neurofibromas are virtually pathognomonic of NF-1 and are often a manifestation of LOH. On palpation, these resemble a “bag of worms.” The overlying skin is usually hyperpigmented and may resemble a giant café au lait macule (Fig. 27-11). Histologically, they demonstrate numerous elongated encapsulated neurofibromas, often embedded in diffuse neurofibroma that involves the dermis and subcutaneous fat.

The café au lait macule is a uniformly pigmented, smooth-edged, light brown macule. Most often, these macules are

present at birth and almost always present by 1 year of age. The finding of six or more of these lesions measuring at least 1.5 cm in diameter is diagnostic, usually indicating NF-1. In children, the minimum diameter for a significant lesion is 0.5 cm. Histologically, basilar hyperpigmentation is noted, and giant melanosomes may be seen. Axillary freckling (Crowe's sign) may occur, extending to the neck and involving the inguinal, genital, and perineal areas.

Many organ systems may be involved. Acromegaly, cretinism, hyperparathyroidism, myxedema, pheochromocytoma (<1%), or precocious puberty may be present. Bone changes (usually erosive) may produce lordosis, kyphosis, and pseudoarthrosis, as well as spina bifida, dislocations, and atraumatic fractures. Neuromas of spinal nerves may cause various paralyses. Patients with NF-1 are four times more likely to develop malignancies than the general population. Cutaneous neurofibromas rarely develop into malignant, peripheral nerve sheath tumors. A growing or hardening lesion is an indication for biopsy. An increased incidence of breast carcinoma, Wilms tumor, rhabdomyosarcomas, gastrointestinal (GI) malignancies, and chronic myelogenous leukemia (CML) has also been reported. Children with NF-1 are 200–500 times more likely to develop malignant myeloid disorders than age-matched controls, and the risk for CML may be higher for those with xanthogranulomas.

Mental retardation, dementia, epilepsy, and a variety of intracranial malignancies may occur. Hypertelorism heralds a severe expression of neurofibromatosis with brain involvement. Diffuse interstitial lung disease occurs in 7% of patients.

Approximately 50% of cases of NF-1 represent new mutations. The gene for NF-1 is in the pericentric region of chromosome 17q11.2 and codes for neurofibromin, a protein that negatively regulates signals transduced by Ras proteins. There is a high rate of spontaneous postzygotic mutation of this gene. Both alleles must be affected for the individual to grow a neurofibroma. In patients with the syndrome, there is germline loss of one allele, and each neurofibroma that develops represents a late spontaneous mutation knocking out the remaining allele. Early postzygotic mutation affecting the second allele in fetal life results in LOH affecting an entire Blaschko segment. The gene for NF-2 is on the long arm of chromosome 22q11–q13 and encodes for merlin (schwannomin), a protein that links the actin cytoskeleton to cell surface glycoproteins and functions as a negative growth regulator. Germline loss-of-function mutations in the *SPRED1* gene have been associated with an NF-1-like phenotype with pigmentary changes but no neurofibromas (Legius syndrome), which is grouped with the RASopathies.

## Diagnosis

The diagnosis of NF-1 requires two or more of the following criteria to be fulfilled:

1. Six or more café au lait macules with a greatest diameter of more than 5 mm in prepubertal individuals, and a greatest diameter of more than 15 mm in postpubertal individuals
2. Two or more neurofibromas of any type or one plexiform neurofibroma
3. Freckling in the axillary or inguinal regions
4. Optic gliomas
5. Two or more Lisch nodules
6. Distinctive osseous lesion, such as a sphenoid dysplasia or thinning of the long-bone cortex with or without pseudoarthrosis

7. First-degree relative (parent, sibling, or offspring) with the disease

A diagnosis of NF-2 requires either of the following:

1. Bilateral eighth cranial nerve masses, as demonstrated on CT or MRI
2. First-degree relative with NF-2 and either unilateral eighth nerve mass or two of the following: a neurofibroma, meningioma, glioma, schwannoma, and juvenile posterior subcapsular lenticular opacity

Although not listed in the previous criteria, the presence of nevus anemicus, xanthogranuloma, and glomus tumors is strongly associated with a diagnosis of NF-1, and the prevalence is high during the first 2 years of life, when other diagnostic criteria may be absent. Nevus anemicus is usually found on the neck and upper chest, whereas the xanthogranulomas tend to be cephalic or genital.

## Screening and monitoring for complications

In one study of 93 asymptomatic patients with NF-1 who underwent cerebral imaging, 12 optic gliomas were detected, suggesting that screening MRI or CT may be of value, and fluorine-18-fluorodeoxyglucose positron emission tomography (PET) has shown some value in discriminating between benign and malignant tumors. The National Institutes of Health (NIH) consensus panel concluded that studies should be dictated by findings on clinical evaluation. It concluded that laboratory tests in asymptomatic patients are unlikely to be of value. In the majority of patients with NF-1, imaging studies should only be performed as indicated by signs or symptoms. NF-2 patients, in contrast, often require imaging studies. Screening studies should include an audiogram and brainstem auditory evoked responses. MRI is the best imaging procedure for patients with evidence of hearing impairments or abnormal evoked responses. Tests of vestibular function may be useful, because eighth cranial nerve tumors develop on the vestibular division. A screening MRI should be performed by puberty. Other tests should be performed as dictated by signs and symptoms. Pediatric patients with NF-2 have a worse prognosis, with 75% demonstrating hearing loss, 83% visual impairment, and 25% abnormal ambulation.

Trials of targeted therapy to reduce the growth of cutaneous neurofibromas are ongoing and are likely to result in better treatment options for severely affected patients.

**Blakeley J:** Development of drug treatments for neurofibromatosis type 2-associated vestibular schwannoma. *Curr Opin Otolaryngol Head Neck Surg* 2012; 20(5):372–379.

**Ferner RE, et al:** Neurofibromatosis type 1 (NF1): diagnosis and management. *Handb Clin Neurol* 2013; 115:939–955.

**Ferrari F, et al:** Juvenile xanthogranuloma and nevus anemicus in the diagnosis of neurofibromatosis type I. *JAMA Dermatol* 2014; 150:42–46.

**Gutmann DH, et al:** Optimizing biologically targeted clinical trials for neurofibromatosis. *Expert Opin Investig Drugs* 2013; 22(4):443–462.

**Harrison B, Sammer D:** Glomus tumors and neurofibromatosis: A newly recognized association. *Plast Reconstr Surg Glob Open* 2014; 2:e214.

**Madanik SA, et al:** Increased risk of breast cancer in women with NF1. *Am J Med Genet* 2012; 158A(12):3056–3060.

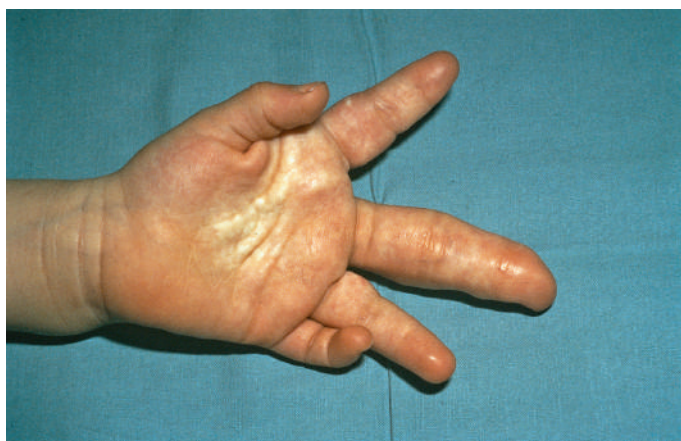**Millan MJ:** An epigenetic framework for neurodevelopmental disorders: from pathogenesis to potential therapy. *Neuropharmacology* 2013; 68:2–82.

**Pasmant E, et al:** Neurofibromatosis type 1: from genotype to phenotype. *J Med Genet* 2012; 49(8):483–489.

**Pecina-Slaus N:** Merlin, the NF2 gene product. *Pathol Oncol Res* 2013; 19(3):365–373.

**Ponti G, et al:** Cancer-associated genodermatoses: skin neoplasms as clues to hereditary tumor syndromes. *Crit Rev Oncol Hematol* 2013; 85(3):239–256.





**Fig. 27-12** Proteus syndrome.

**Treglia G, et al:** Usefulness of whole-body fluorine-18-fluorodeoxyglucose positron emission tomography in patients with neurofibromatosis type 1: a systematic review. *Radiol Res Pract* 2012; 2012:431029.

**Vranceanu AM, et al:** Quality of life among adult patients with neurofibromatosis 1, neurofibromatosis 2 and schwannomatosis: a systematic review of the literature. *J Neurooncol* 2013; 114(3):257–262.

## PROTEUS SYNDROME

Although not a phakomatosis, Proteus syndrome may be confused with neurofibromatosis. This rare sporadic disease is named after the Greek god Proteus, who could change shape. The syndrome has protean manifestations that include disproportionate, asymmetric, and distorting segmental overgrowth; cerebriform plantar hyperplasia (Fig. 27-12); epidermal nevi; patchy dermal hypoplasia; macrocephaly; hyperostosis; muscular hypoplasia; hypertrophy of long bones; vascular malformations of the capillary, venous, or lymphatic types; lipomas, lipohypoplasia; fatty overgrowth; bullous lung alterations; intellectual disability; seizures; brain malformations; and deep vein thrombosis. Germline mutations of *PTEN* cause the *PTEN* hamartoma tumor syndrome, which includes various phenotypes (Cowden, Bannayan-Riley-Ruvalcaba, Proteus, Proteus-like, and Lhermitte-Duclos syndromes).

Joseph Merrick, known as “the Elephant Man,” likely had Proteus syndrome rather than neurofibromatosis. Proteus syndrome is believed to be caused by a somatic mutation that is lethal in the nonmosaic state. Patients with a greater number of cutaneous lesions also have the most extracutaneous abnormalities. The findings of both overgrowth (pleioproteus component) and hypoplasia (elattoproteus component) in the same patient may be a manifestation of genetic twin spotting (didymosis), overexpression, and deficiency of a gene product. Linear lesions with *PTEN* mutations are now classified as segmental Cowden syndrome.

**Cohen MM Jr:** Proteus syndrome review: molecular, clinical, and pathologic features. *Clin Genet* 2014; 85(2):111–119.

**Lindhurst MJ, et al:** *AKT1* gene mutation levels are correlated with the type of dermatologic lesions in patients with Proteus syndrome. *J Invest Dermatol* 2014; 134(2):543–546.

## VON HIPPEL–LINDAU SYNDROME

Von Hippel–Lindau syndrome is an autosomal dominant disorder consisting of retinal angiomas, cerebellar medullary angioblastic tumors, pancreatic cysts, and renal tumors and

cysts. Usually, the skin is not involved, although angiomas may occur in the occipitocervical region or may be generalized. The syndrome is associated with a germline mutation of a tumor suppressor gene on the short arm of chromosome 3. From 10% to 20% of cerebellar hemangioblastomas produce erythropoietin and are accompanied by a secondary polycythemia. Ocular lesions may lead to retinal detachment. Ten percent of hypernephromas and fewer than 8% of renal cysts also produce erythropoietin. Pheochromocytoma has been associated in several kindreds with von Hippel–Lindau disease.

**Patiroglu T, et al:** Cerebellar hemangioblastoma associated with diffuse neonatal hemangiomatosis in an infant. *Childs Nerv Syst* 2012; 28(10):1801–1805.

## ATAXIA-TELANGIECTASIA

Also known as Louis-Bar syndrome, ataxia-telangiectasia consists of cerebellar ataxia, oculocutaneous telangiectasia, and sinopulmonary infection. It is familial and is usually first noted when the child begins to walk. There is awkwardness and a swaying gait, which results in the child needing to use a wheelchair by about 10 years of age. Choreic and athetoid movements and pseudopalsy of the eyes are other features. Fine telangiectases appear on the exposed surfaces of the conjunctiva at about age 3. Nystagmus is present. Telangiectases also appear later on the butterfly area of the face, inside the helix and over the backs of the ears, in the roof of the mouth, in the necklace area, in the flexures, and over the dorsa of the hands and feet. Other stigmata are café au lait patches, hypopigmented macules, melanocytic nevi, hypertrichosis, seborrheic dermatitis, premature graying and sparsity of the hair, and progeroid features.

The skin tends to be dry and coarse and over time becomes tight and inelastic, as in scleroderma. Atrophic, granulomatous, scarring plaques may occur. Early death from bronchiectasis occurs in more than half these patients, most of whom have recurrent sinus and lung infections that begin between 3 and 8 years of age.

Patients may have a marked IgA deficiency, with decreased lymphocytes and a small to absent thymus. The most common types of malignancy are lymphomas, usually of the B-cell type, and leukemias. It has been shown that homozygous patients also have a higher risk of breast cancer—100 times higher than age-matched controls. Heterozygous carriers share the defective repair of radiation-induced damage, and there is a threefold to fivefold higher risk for development of neoplasms, especially breast cancer, in heterozygotes under age 45. The ovaries and testicles do not develop normally. There is deficient thymus development, with absence of Hassall’s corpuscles and a lack of T-helper cells. Suppressor T cells are normal. In 80% of cases, IgA is absent or deficient; in 75%, absent or deficient IgE is seen; and in 50%, IgG is very low.

Ataxia-telangiectasia is transmitted as an autosomal recessive trait, and heterozygotes, although they lack clinical findings, are cancer prone. The gene has been designated *ATM* (ataxia-telangiectasia mutated gene) and is a member of a family of phosphatidylinositol-3-kinase-like enzymes involved in cell cycle control, meiotic recombination, telomere length monitoring, and DNA damage response. Affected cells are hypersensitive to ionizing radiation and are defective at the G1/S checkpoint after radiation damage. They are abnormally resistant to inhibition of DNA synthesis by ionizing radiation. The *ATM* gene is located on chromosome 11q22.3. Translocations are common in these patients, particularly for chromosomes 7 and 14. A high prevalence of *ATM* gene mutations

has also been found in a diverse array of sporadic lymphoproliferative disorders.

Early diagnosis can be difficult and the most frequent misdiagnosis is cerebral palsy. Persistently elevated levels of alpha fetoprotein (AFP) and carcinoembryonic antigen occur; these may be useful in early diagnosis. In culture, ataxia-telangiectasia fibroblasts are three times more sensitive to killing by ionizing radiation, but not ultraviolet light. Evaluations for elevated AFP and radiosensitivity of fibroblasts used to be the standard for diagnosis of this disorder, but immunoblotting the ATM protein expression is now possible.

**Greenberger S, et al:** Dermatologic manifestations of ataxia-telangiectasia syndrome. *J Am Acad Dermatol* 2013; 68(6):932–936.

**Knoch J, et al:** Rare hereditary diseases with defects in DNA-repair. *Eur J Dermatol* 2012; 22(4):443–455.

## EPIDERMOLYSIS BULLOSA

Epidermolysis bullosa (EB) is a group of rare genetic disorders that have in common the formation of blisters in response to minor physical injury. Treatment consists of prevention of trauma, decompression of large blisters, and treatment of infection. EB acquisita is an autoimmune disease and is discussed in Chapter 21. The inherited types of EB are classified as listed in [Box 27-1](#).

Internal involvement may occur in several of these subtypes of EB. Esophageal and laryngeal complications are seen primarily in recessive dystrophic EB but may be present in junctional EB (Herlitz). Pyloric atresia is reported to occur in junctional EB. Ocular lesions may be severe in dystrophic EB, and mild lesions have been reported in simplex and junctional disease.

Clinical findings and routine histologic features overlap, and accurate diagnosis depends on genetic mutation mapping, electron microscopy (EM) studies, or immunofluorescent mapping. The latter two can identify the level of the epidermal separation and also may define other defects, such as absence of anchoring fibrils or hypoplasia of hemidesmosomes. In recessive dystrophic EB, EM reveals that the cleavage is below the basal lamina, and that anchoring fibrils are diminished or absent.

Immunofluorescent mapping may define the level of the split without resorting to EM. By staining biopsy specimens for normal components of the basement membrane zone (BMZ), such as bullous pemphigoid antigen, laminin, type IV collagen, or LDA-1 antigen, the level of the split may be determined by whether the antigen localizes at the roof or base of the blister. In simplex types, all these components will be at the base; in dystrophic types, all will be at the roof; and in junctional types, bullous pemphigoid antigen will be on the roof, whereas type IV collagen and LDA-1 will be at the base. KF-1 has been found to be absent or diminished in dystrophic EB. The specific keratin abnormalities along with the abnormal genes have been identified for many of these disorders. Suprabasal forms of EB simplex are caused by defects in transglutaminase 5, plakophilin, desmoplakin, and plakoglobin. Basal forms of EB simplex are caused by defects in genes encoding for keratins 5 and 14, plectin, exophilin 5, and bullous pemphigoid antigen 1. In generalized types of junctional EB, there are defective genes encoding for laminin 332, collagen XVII,  $\alpha 6\beta 4$ -integrin, and  $\alpha 3$ -integrin. In localized types of junctional EB, there are defective genes encoding for laminin 332, collagen XVII, and  $\alpha 6\beta 4$ -integrin. Sublamina densa dystrophic forms result from mutations in type VII collagen gene *COL7A1*. Kindler syndrome represents a mixed form related to defects in kindlin 1 (fermitin family homolog 1).

### Box 27-1 Inherited types of epidermolysis bullosa (EB)

#### Intraepidermal

- EB simplex, generalized intermediate, normal keratins 5 and 14 staining, *KRT5* or *KRT14* mutation (specify type)
- EB simplex, localized, normal keratins 5 and 14 staining, *KRT5* or *KRT14* mutation (specify type)
- EB, generalized severe, normal keratins 5 and 14 staining, *KRT5* or *KRT14* mutation (specify type)
- EB simplex (Ogna)
- EB simplex–migratory circinate
- EB simplex with mottled pigmentation, normal keratin 5 staining, *KRT5* mutation (specify type)
- EB with muscular dystrophy
- EB with pyloric atresia
- EB superficialis
- Acantholytic EB simplex, *DSP* or *JUP* mutations (specify type)
- Acral peeling skin syndrome
- Skin fragility syndromes
  - Skin fragility–wooly hair syndrome (desmoplakin deficiency)
  - Skin fragility–plakoglobin deficiency
  - Skin fragility–ectodermal dysplasia syndrome (plakophilin deficiency)
- EB simplex autosomal recessive–BP230 deficiency
- EB simplex autosomal recessive–exophilin 5 deficiency
- EB simplex autosomal recessive–K14

#### Junctional (intralamina lucida)

- Junction EB (JEB), generalized severe, laminin-332 absent, *LAMA3*, *LAMB3*, or *LAMC2* mutations (specify type)
- Junction EB (JEB), generalized intermediate, laminin-332 or collagen XVII reduced staining, *LAMA3*, *LAMB3*, *LAMC2*, or *COL17A1* mutations (specify type)
- JEB localized
- JEB with pyloric atresia ( $\alpha 6\beta 4$ -integrin)
- JEB, late onset (collagen XVII)
- JEB with respiratory and renal involvement ( $\alpha 3$ -integrin subunit)
- JEB inversa

#### Dermolytic or dystrophic (sublamina densa)

##### Dominant forms

- Dystrophic EB, generalized, normal collagen VII staining, *COL7A1* mutation (specify type)
- EB pruriginosa
- Pretibial EB
- Bullous dermolysis of the newborn

##### Recessive forms

- Generalized severe, collagen VII absent, *COL7A1* mutations (specify type)
- Generalized intermediate, collagen VII reduced staining, *COL7A1* mutations (specify type)
- Bullous dermolysis of the newborn, granular intraepidermal collagen VII staining, *COL7A1* mutations (specify type)
- Localized (various types, including EB pruriginosa and pretibial EB)

### Intraepidermal forms

#### Epidermolysis bullosa simplex, generalized intermediate

The generalized type of EB simplex (EBS), dominantly inherited with complete penetrance, occurs in 1 in 500,000 births. It



is characterized by the development of vesicles, bullae, and milia over the joints of the hands, elbows, knees, and feet (Fig. 27-13), as well as other sites subject to repeated trauma. The child is affected at birth or shortly thereafter, with improvement within the first few months, but with disease recurring when the child begins crawling or later in childhood. The blistering is worse during the summer and improves during the winter. The lesions are sparse and do not lead to severe atrophy. Nikolsky's sign is negative. Usually, the mucous membranes and nails are not involved. EBS is usually milder than other forms of EB.

Inherited as an autosomal dominant trait, EBS is a disease in which keratin gene mutations cause the production of defective intermediate filaments, which lead to epidermal basal cell fragility and subsequent blistering. Gene mutations produce abnormalities in keratins 5 and 14, keratins expressed in the basal cell layer. Patients heterozygous for abnormal keratin 14 have blistering limited to the hands and feet, but homozygotes have more severe and widespread blistering of the skin and mucous membranes. Separation occurs through the basal cell layer. Rubbing skin with an eraser may lead to a subclinical lesion that demonstrates the split histologically.

### Localized epidermolysis bullosa simplex

Recurrent bullous eruption of the hands and feet is autosomal dominantly determined and appears in a chronic form in infancy or at times later in life. The Weber-Cockayne designation has been dropped in recent classification schemes. The lesions exacerbate during hot weather and when the patient is subjected to prolonged walking or marching, as in military service. Hyperhidrosis may be an associated finding. In localized EBS, the bullae are intraepidermal and suprabasal, and healing occurs without scarring.

Application of aluminum chloride hexahydrate in anhydrous ethanol (Drysol) on the normal skin of hands and feet twice a day has been shown to reduce blistering in this form of EB. After 2 weeks of daily therapy, the patient can be switched to weekly or twice-weekly applications.

### Epidermolysis bullosa simplex, generalized severe

In this autosomal dominant variant of EBS, active blisters with circinate configuration occur in infancy. Milia may develop, but there is no scarring. The oral mucosa is involved. Nails are shed but may regrow, sometimes with dystrophy. Blistering

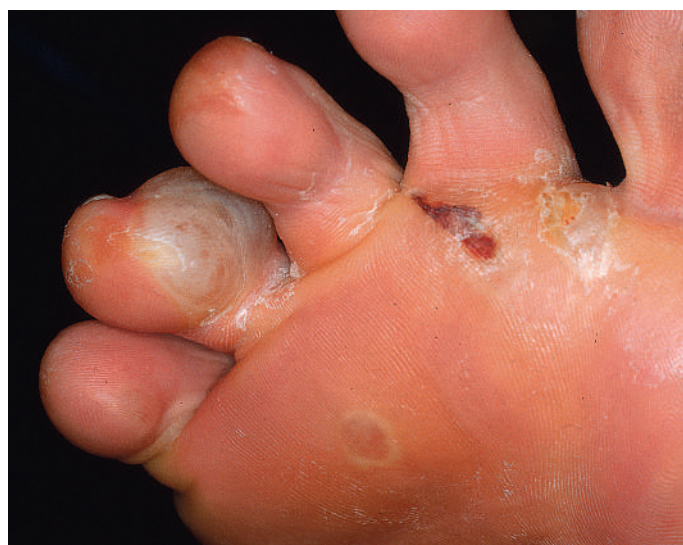

Fig. 27-13 Epidermolysis bullosa simplex.

lessens with age. Hyperkeratosis of the palms and soles may occur. Histologically, the split is through the basal layer, and tonofilaments are clumped on EM. Point mutations have been shown in keratin 5 and 14 genes.

### Epidermolysis bullosa simplex (Ogna)

Generalized bruising and hemorrhagic blisters occur. EBS is transmitted as an autosomal dominant trait. At birth, there are small, acral, traumatic sanguineous blisters. The basal keratinocytes in this syndrome do not stain with antiplectin antibodies.

### Epidermolysis bullosa simplex with mottled pigmentation

One Swedish family has been reported with autosomal dominant EBS with congenital scattered hyperpigmented and hypopigmented macules that fade slowly after birth. The remaining features are similar to those of generalized EBS. Ultrastructural studies show vacuolization of the basal cell layer.

### Epidermolysis bullosa simplex with muscular dystrophy

A form of EBS is associated with late-onset neuromuscular disease and is inherited as an autosomal recessive trait. Widespread blistering at birth is associated with scarring, milia, atrophy, nail dystrophy, dental anomalies, laryngeal webs, and urethral strictures. Progressive muscular dystrophy with weakness and wasting begins in childhood or later. This disease is caused by a mutation in the plectin gene, with affected patients having absent plectin in their skin and muscles.

### Junctional forms

#### Junctional epidermolysis bullosa, generalized severe

In junctional EB, a rare type that has autosomal recessive transmission, severe generalized blistering may be present at birth, and extensive denudation may prove fatal within a few months. There is generalized blistering (Fig. 27-14), with relative sparing of the hands, and characteristic perioral and

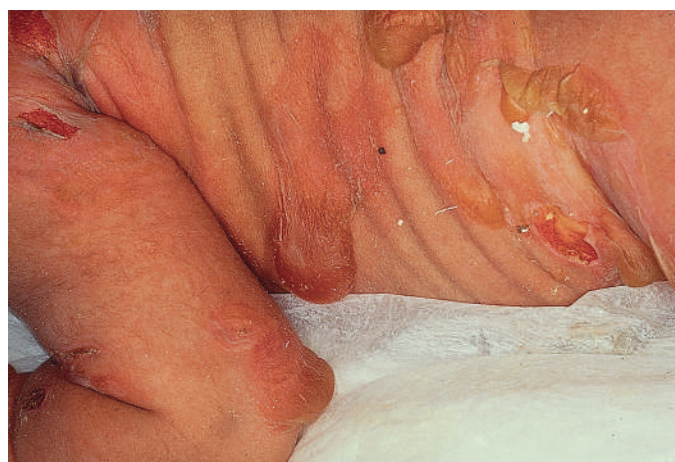

Fig. 27-14 Junctional epidermolysis bullosa.

perinasal hypertrophic granulation tissue. Eventually, the lesions heal without scarring or milia formation, but erosions may persist for years. Dysplastic teeth are common. Laryngeal and bronchial lesions may cause respiratory distress and even death. Additional systemic complications include GI tract, gallbladder, corneal, and vaginal disease. Patients who survive infancy have growth retardation and often, moderate to severe refractory anemia. Separation occurs in the lamina lucida, as shown by EM.

Herlitz junctional EB is caused by mutations in three genes: *LAMA3*, *LAMB3*, or *LAMC2*, which code for polypeptide subunits of laminin 5. In addition to good wound care and control of infection, epidermal autographs of cultured keratinocytes, isolated from clinically uninvolved skin and grown on collagen sponges, may be useful for chronic facial erosions. Complete reepithelialization can be achieved over 7–10 months.

### Junctional epidermolysis bullosa with pyloric atresia

This rare autosomal recessive inherited form of junctional EB presents at birth with severe mucocutaneous fragility and gastric outlet obstruction. Even if the pyloric atresia is repaired, the neonates may die from the severity of their skin disease. If they survive the neonatal period, the blistering diminishes. Persistent scarring of the urinary tract may occur, however, with stenosis of the ureteral-vesicular junction, requiring numerous urologic procedures. This syndrome is usually caused by a genetic mutation in either the  $\alpha 6$ - or  $\beta 4$ -integrin genes (*ITGA6* and *ITGB4*). This  $\alpha 6\beta 4$ -integrin complex is uniquely expressed on epithelial surfaces.

#### Dermolytic or dystrophic forms

The cause of dystrophic EB in both autosomal dominant and autosomal recessive inherited forms is mutation in the *COL7A1* gene encoding for type VII collagen. The anchoring fibrils in these patients are defective or deficient. Presumably, because of antigen exposure, anti-type VII collagen, anti-BP180, and anti-BP230 autoantibodies may be detected.

### Dominant dystrophic epidermolysis bullosa

On the extensor surfaces of the extremities, vesicles and bullae appear; these are most pronounced over the joints, especially over the toes, fingers, knuckles, ankles, and elbows (Fig. 27-15). Spontaneous, flesh-colored, scarlike (albopapuloid) lesions may appear on the trunk, often in adolescence, with no previous trauma. The nails may be thickened. Usually, Nikolsky's sign is present, and frequently the accumulated fluid in a bulla can be moved under the skin several centimeters away from the original site. Healing usually occurs with scarring and atrophy. Milia are often present on the rims of the ears, dorsal surfaces of the hands, and extensor surfaces of the arms and legs.

The mucous membranes are frequently involved. Bullae, vesicles, and erosions are encountered on the buccal mucosa, tongue, palate, esophagus, pharynx, and larynx. The latter involvement is manifested by persistent hoarseness in some of these patients. There may be angular contractures at the gingivolabial sulcus and dysphagia from pharyngeal scarring. Scarring on the tip of the tongue is typical. The teeth are normal. Usually, the conjunctiva is not involved.

Other changes include nail dystrophy, partial alopecia of the scalp, absence of body hair, dwarfism, and the formation of contractures and clawlike hands, with atrophy of the phalangeal bones and pseudosyndactylism. The albopapuloid type (formerly Pasini type) is now recognized as a more severe

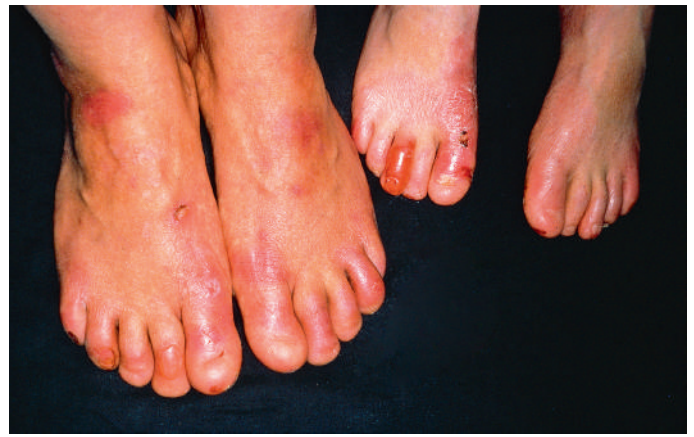

Fig. 27-15 Epidermolysis bullosa, dominant dystrophic.

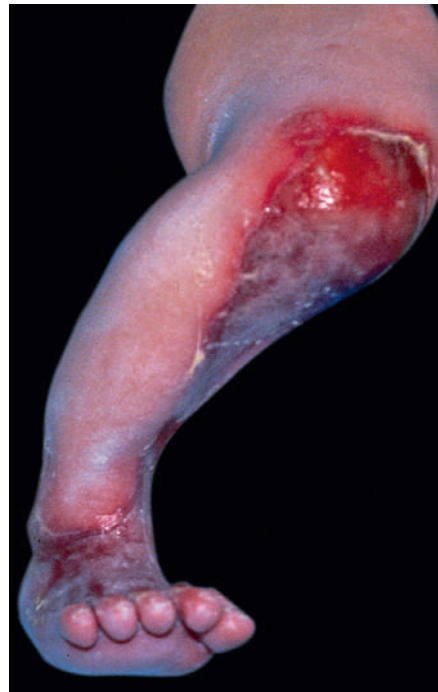

Fig. 27-16 Bart syndrome.

expression of dominant dystrophic EB. The type formerly known as Cockayne-Touraine is more limited in extent and severity, and no albopapuloid lesions are seen.

Epidermolysis bullosa pruriginosa is characterized by extreme pruritus, lichenified plaque, prurigo-like lesions, and violaceous linear scarring. Pretibial EB is characterized by recurrent blistering and scarring plaques in the pretibial area. Nail dystrophy is common. Both EB pruriginosa and pretibial EB can be inherited in either dominant or recessive fashion.

Histologically, a noninflammatory subepidermal bulla is generally present. On EM, cleavage occurs beneath the basal lamina, and anchoring fibrils are rudimentary and reduced in number. In blistered areas, these are not demonstrable.

Autologous meshed split-thickness skin grafts and allogeneic cultured keratinocytes may be used in treating nonhealing skin defects. In many patients with dominant dystrophic EB, blistering reduces over time, and only nail dystrophy may be present in adulthood.

### Bart syndrome

Bart described congenital localized defects of the skin (Fig. 27-16), mechanoblisters, and nail deformities with autosomal



dominant inheritance. Although the clinical and histologic picture of this syndrome is one of a mildly scarring mechanobullous dermatosis with a favorable prognosis, associations with mandibulofacial dysostosis, renal aplasia, and congenital abnormalities of the lower extremities have been reported. Bart syndrome is not a distinct entity but rather a clinical variant of other forms of EB, mostly dominant dystrophic EB, based on identification of a defect in the *COL7A1* gene (chromosome 3p) encoding for type VII collagen.

### Transient bullous dermolysis of the newborn

In 1985, Hashimoto et al. reported a newborn who developed blisters from every minor trauma. Separation was below the basal lamina, with degeneration of collagen and anchoring fibrils. There was rapid healing by 4 months of age. Nails were not damaged, and there was no scarring. The authors considered the following as criteria for this entity:

1. Vesiculobullous lesions present at birth or induced by friction
2. Spontaneous recovery at a few months of age
3. No dystrophic scars
4. Subepidermal blisters beginning in the dermal papillae
5. Ultrastructurally observed collagenolysis and damaged anchoring fibrils
6. Enormous dilation of rough endoplasmic reticulum, with stellate bodies of keratinocytes in their vacuoles

The cause was shown in one family to be a transversion mutation in the *COL7A1* gene encoding for type VII collagen, and it is therefore allelic with other variants of dominant or recessive dystrophic EB. The mechanism for the transient nature of reduced amounts of type VII collagen along the dermoepidermal junction remains to be defined.

### Acrokeratotic poikiloderma (Kindler syndrome, Weary-Kindler syndrome)

In 1954, Kindler reported a combination of poikiloderma congenitale and traumatic blistering of the feet from minor trauma. The disorder shares some clinical features with dominant dystrophic EB, but in the largest reported familial cluster, inheritance followed an autosomal recessive pattern. Characteristic features include skin fragility with blistering, congenital acral bullae, generalized poikiloderma with prominent atrophy, photosensitivity, acral keratoses, severe periodontal disease, and phimosis. Some patients develop intestinal dysfunction or ulcerative colitis. Pseudoainhum and sclerotic bands were reported in one case. The principal histologic change is absence of elastic fibers in the papillary dermis and fragmented fibers in the middermis. Ultrastructural studies have shown replication of the lamina densa. Acrokeratotic poikiloderma is caused by loss-of-function mutations in fermitin family homolog 1, an actin cytoskeleton-associated protein encoded by the gene *FERMT1*, which plays a role in keratinocyte adhesion, migration, and proliferation. The protein is mainly expressed in basal keratinocytes. It binds to fermitin family homolog 2, as well as  $\beta 1$  and  $\beta 3$  integrins.

### Ectodermal dysplasia/skin fragility syndrome (McGrath syndrome)

This syndrome includes trauma-induced skin fragility and defects of the hair, nails, and sweat glands. Trauma-induced blisters or skin tearing are noted on the pressure points, especially after prolonged standing or walking. Desmosomes in the

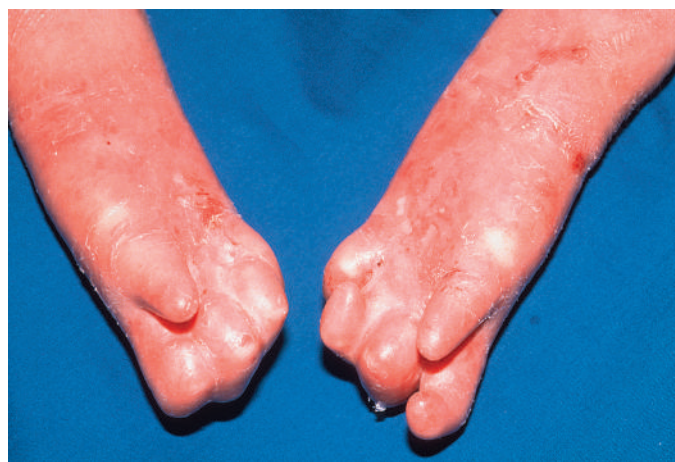

Fig. 27-17 Epidermolysis bullosa, recessive dystrophic type.

lower epidermis are small and reduced in number. The disorder is caused by mutations in the plakophilin 1 gene (*PKP1*), gene map locus 1q32.

### Recessive dystrophic epidermolysis bullosa, generalized severe

All forms of recessive dystrophic EB result from mutations in the gene encoding type VII collagen, *COL7A1*. Generalized recessive dystrophic EB in its mildest form has blisters limited primarily to the hands, feet, elbows, and knees, and limited complications. The severer variety characteristically begins at birth with generalized cutaneous and mucosal blistering. Digital fusion with encasement of the fingers and toes in scar tissues, forming a “mittenlike” deformity (Fig. 27-17), is characteristic of the severe form of recessive dystrophic EB, occurring in up to 90% of patients by age 25. Dental complications may be severe, including rampant dental caries and microstomia. Esophageal stricture may be present. Anemia and growth retardation are frequently seen in the severest cases, and progressive nutritional deficiency can result in fatal cardiomyopathy. Fatal systemic amyloidosis (AA type) has also been reported. There is a high risk of developing cutaneous squamous cell carcinomas (SCCs), with up to 50% of patients affected by age 35. These SCCs may be multiple and can metastasize and cause death. Both pretibial EB and EB pruriginosa may exhibit recessive inheritance.

Although gene therapy is promising, treatment remains primarily palliative. Gentle wound care and proper nutrition are critical. Debilitating oral lesions produce pain, scarring, and microstomia. Aggressive dental intervention is recommended. Nutritional support is of critical importance. Autologous meshed split-thickness skin grafts and allogeneic cultured keratinocytes have been useful in treating nonhealing cutaneous defects, or may be used for closure after removal of large cutaneous malignancies. A single injection of allogeneic fibroblasts at the margins can accelerate early healing of chronic recessive dystrophic EB erosions. Family education and referral to DEBRA (Dystrophic Epidermolysis Bullosa Research Association of America, 5 West 36th Street, Room 404, New York, NY 10018, [www.debra.org](http://www.debra.org)) are strongly recommended.

**Abdul-Wahab A, et al:** Gene therapies for inherited skin disorders. *Semin Cutan Med Surg* 2014; 33:83–90.

**Chu MB, et al:** Speedy simple technique for subungual blister evacuation in epidermolysis bullosa. *J Am Acad Dermatol* 2013; 69(1):e7–e8.

**Fine JD, et al:** Inherited epidermolysis bullosa: updated recommendations on diagnosis and classification. *J Am Acad Dermatol* 2014; 70:1103–1126.

**Fortuna G, et al:** The largest family of the Americas with dominant dystrophic epidermolysis bullosa pruriginosa: a 18-year longitudinal genotype-phenotype study. *J Dermatol Sci* 2013; 71(3):217–221.

**Gonzalez ME:** Evaluation and treatment of the newborn with epidermolysis bullosa. *Semin Perinatol* 2013; 37(1):32–39.

**Mahto A, et al:** Late-onset pretibial recessive dystrophic epidermolysis bullosa. *Clin Exp Dermatol* 2013; 38(6):630–632.

**Murrell DF:** The pitfalls of skin biopsies to diagnose epidermolysis bullosa. *Pediatr Dermatol* 2013; 30(2):273–275.

**Yang CS, et al:** An incompletely penetrant novel mutation in *COL7A1* causes epidermolysis bullosa pruriginosa and dominant dystrophic epidermolysis bullosa phenotypes in an extended kindred. *Pediatr Dermatol* 2012; 29(6):725–731.

## FAMILIAL BENIGN CHRONIC PEMPHIGUS (HAILEY-HAILEY DISEASE)

In 1939, Hailey and Hailey described a familial disease characterized by persistently recurrent bullous and vesicular dermatitis of the sides of the neck, axillae, and flexures. The eruption may remain localized or may become widespread. Usually, intact blisters are not evident. Instead, the lesions appear as macerated plaques with a reticulated pattern of fissuring (Fig. 27-18). Lesions may become thickly crusted and may resemble impetigo. Sometimes the center becomes dry and crusted, and an actively inflammatory border spreads peripherally, producing circinate and figurate patterns. The onset is usually in the late teens or early twenties. The condition is typically worse during the summer. Lesions tend to recur at sites of prior involvement. There may be tenderness and enlargement of the regional lymph glands caused by secondary bacterial infection. Longitudinal leukonychia may occur. Involvement of the esophagus, mouth, and labia majora is rare.

Hailey-Hailey disease is inherited in an autosomal dominant manner, and 30% of patients express new mutations. The disease is caused by a genetic defect in a calcium adenosine triphosphatase (*ATP2C1*) on chromosome 3q21.

In predisposed persons with Hailey-Hailey disease, skin trauma, bacterial or fungal infection, and dermatoses may trigger lesions. Sunburn may also exacerbate the disease. Widespread bullous lesions may occur in response to drug eruptions and may be misdiagnosed as toxic epidermal necrolysis. The histopathologic picture is unique. There is acanthosis and full-thickness acantholysis resembling a dilapidated brick

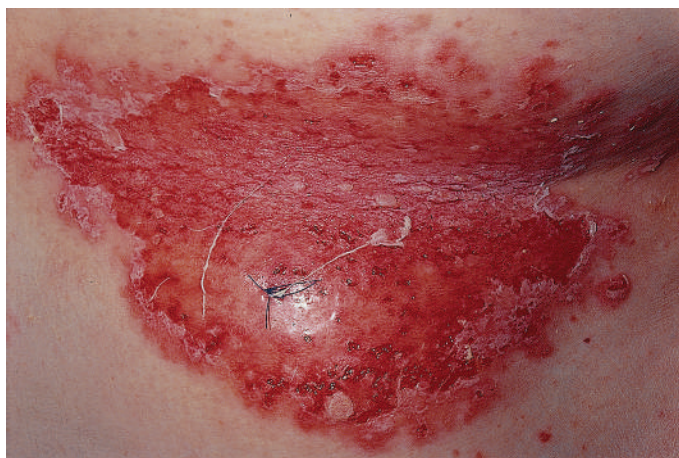

Fig. 27-18 Hailey-Hailey disease.

wall. A red band of dyskeratosis is present surrounding the nucleus, with no evidence of the blue or clear bands that occur in Darier's disease.

The treatment of Hailey-Hailey disease is difficult. Many patients improve with the use of systemic antibiotics effective against *Staphylococcus aureus*, topical clindamycin, antifungal agents, or mupirocin. Corticosteroids, administered topically, systemically, or both, have shown response. Cyclosporine, methotrexate, oral retinoids, topical calcineurin inhibitors, topical calcitriol, tacalcitol, botulinum toxin, photodynamic therapy (PDT), narrow-band ultraviolet B therapy (NB-UVB), alefacept, terbinafine, minocycline/niacinamide, and dapsone have been used in severe cases. Dermabrasion and carbon dioxide (CO<sub>2</sub>) laser vaporization have been effective in refractory disease, as the epidermis heals from uninvolved adnexal structures. Grafting and electron beam therapy have been helpful in the most severe forms of Hailey-Hailey disease.

**D'Errico A, et al:** Hailey-Hailey disease treated with methotrexate. *J Dermatol Case Rep* 2012; 6(2):49–51.

**Hamada T, et al:** Successful therapeutic use of targeted narrow-band ultraviolet B therapy for refractory Hailey-Hailey disease. *Acta Derm Venereol* 2013; 93(1):110–111.

**Vanderbeck KA, et al:** Combined therapeutic use of oral alitretinoin and narrowband ultraviolet-B therapy in the treatment of Hailey-Hailey disease. *Dermatol Reports* 2014; 6:5604.

**Varada S, et al:** Remission of refractory benign familial chronic pemphigus (Hailey-Hailey disease) with the addition of systemic cyclosporine. *J Cutan Med Surg* 2014; 18:1–4.

## DISORDERS OF CORNIFICATION (ICHTHYOSES AND ICHTHYOSIFORM SYNDROMES)

Ichthyosis is not one disease but a group of diseases in which the homeostatic mechanism of epidermal cell kinetics or differentiation is altered, resulting in the clinical appearance of scale. Because these disorders manifest as abnormal differentiation of the epidermis, the term disorders of cornification is preferred to ichthyosis.

### Treatment

A systematic review of the literature on treatment of keratinizing disorders other than ichthyosis vulgaris concluded that evidence is strongest to support the use of 5% urea, 20% propylene glycol, 5% lactic acid, calcipotriol (limited to a weekly dose of 100 g) and topical liarozole (which blocks retinoic acid metabolism). Oral liarozole was not superior to oral acitretin. Symptomatic treatment with  $\alpha$ -hydroxy acids, such as lactic acid or 12% ammonium lactate lotion, is helpful, but patients with atopic dermatitis and ichthyosis vulgaris may find that these products sting. Other compounds with hydrating and keratolytic properties are also beneficial. Creams containing 5–10% urea are effective humectants. Response to topical retinoids has been variable. Widespread use of topical salicylic acid in children may lead to salicylism, and salicylic acid products are best reserved for thicker, localized areas, when 40% urea has failed. Baths may help by hydrating the horny layer, but the water must be sealed in with an evaporation barrier such as white petrolatum. Topical calcipotriene ointment has proved effective in a variety of ichthyoses, and topical maxacalcitol, a vitamin D<sub>3</sub> analogue, has been used successfully in mosaic-type bullous congenital ichthyosiform erythroderma. Application of a 40–60% solution of propylene glycol in water under an occlusive suit removes the scales. Propylene glycol can produce renal failure and cardiac toxicity when given systemically, but few reports of adverse effects have been



noted with topical use. Many patients benefit from the use of a sauna suit, even without the use of propylene glycol, so the risk-benefit ratio of adding the propylene glycol to the regimen should be evaluated carefully. Topical tazarotene and other topical retinoids can be helpful to treat ectropion.

### Ichthyosis vulgaris

Ichthyosis vulgaris is autosomal dominant inherited and is characterized by onset in early childhood, usually between 3 and 12 months, with fine scales that appear “pasted on” over the entire body. Varying degrees of dryness of the skin may be evident. The scales are coarser on the lower extremities than on the trunk. The extensor surfaces of the extremities are most prominently involved, and the axillary and gluteal folds are usually not affected. Although the antecubital and popliteal fossae are usually spared by ichthyosis vulgaris, atopic changes may be present, because these disorders are frequently associated. Accentuated skin markings and hyperkeratosis of the palms are common features, and keratosis pilaris is frequently associated. The scalp is involved, with only slight scaling. Keratotic lesions may be found on the palmar creases (keratosis punctata). Atopy manifested as hay fever, eczema, asthma, or urticaria is often present. The course is favorable, with limited findings by the time the patient is an adult.

Histologically, there is compact eosinophilic orthokeratosis. The granular layer is reduced or absent, and keratohyalin granules may appear spongy or fragmented on EM. The spinous layer is of normal thickness. Filaggrin is reduced in involved epidermis, and profilaggrin messenger RNA is unstable in keratinocytes. This is a retention hyperkeratosis, with a normal rate of epidermal turnover. The differential diagnosis includes severe xerosis, X-linked ichthyosis, and acquired ichthyosis.

### X-linked ichthyosis

X-linked ichthyosis is transmitted only to males by heterozygous mothers as an X-linked recessive trait. This condition results from a deficiency of steroid sulfatase (arylsulfatase C), and occurs in 1:2000–5000 male births. Onset is usually before age 3 months. Cesarean birth is typical, with failure in progression of labor because of a placental sulfatase deficiency. Scales are dark, large, and prominent on the anterior neck, extensor surfaces of the extremities (Fig. 27-19), and the trunk. The sides of the neck are invariably involved, giving the child an unwashed look. The elbow and knee flexures are relatively spared, as are the face and scalp; the palms and soles are almost always spared.

The condition may be confused with ichthyosis vulgaris but typically has darker scales and demonstrates dramatic clearing during the summer months. A diagnosis of X-linked

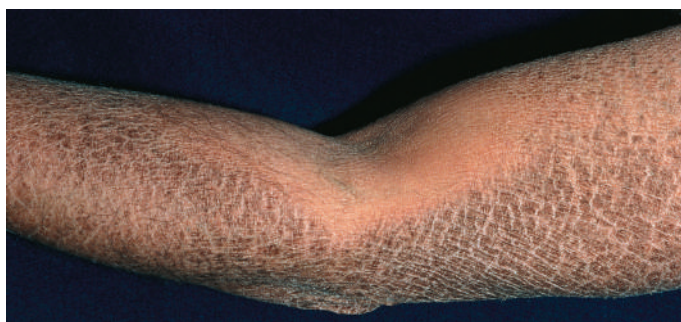

Fig. 27-19 X-linked ichthyosis.

ichthyosis is likely if the abdomen is more involved than the back, and if the ichthyosis extends down the entire dorsum of the leg. Keratosis pilaris is not present, and the incidence of atopy is not increased. Corneal opacities (which do not affect vision) are seen by slit-lamp examination on the posterior capsule or Descemet’s membrane in about 50% of affected males and female carriers. Another extracutaneous feature is a 12–15% incidence of cryptorchidism and an independently increased risk of testicular cancer. Unlike ichthyosis vulgaris, X-linked ichthyosis does not improve with age, but gradually worsens in both extent and severity.

There is usually a deletion at Xp22.3, and steroid sulfatase is lacking in fibroblasts, leukocytes, and keratinocytes. The diagnosis can be confirmed by lipoprotein electrophoresis, because the increase in cholesterol sulfate makes the low-density lipoproteins (LDLs) migrate much more rapidly, and cholesterol sulfate is elevated in serum, erythrocyte membranes, and keratin. The reduced enzyme activity can be assessed in fibroblasts, keratinocytes, leukocytes, and prenatally in amniocytes.

### Multiple sulfatase deficiency

Patients with multiple sulfatase deficiency display an overlap of steroid sulfatase deficiency, mucopolysaccharidosis, and metachromatic leukodystrophy. The scaling is sometimes milder than X-linked recessive ichthyosis. There may be developmental delay, spastic quadriparesis, and coarse facial features. Histologic examination shows hyperkeratosis with a normal granular cell layer. This autosomal recessive disorder is caused by a lack of or deficiency in all known sulfatases.

### Autosomal recessive ichthyosis

Biochemical and genetic studies have helped to define the specific ichthyotic subtypes. Clinical features often overlap, and in the past, the severity of the disease determined the classification. Identification of specific defects, such as transglutaminase 1 (TGM1) and profilaggrin/filaggrin, are important to define each disorder, and are the basis for classification of ichthyotic disorders.

### Lamellar ichthyosis

Lamellar ichthyosis is present at birth, or becomes apparent soon after, and almost always involves the entire cutaneous surface. Usually, a collodion-like membrane encases the baby at birth, then desquamates over the first 2–3 weeks of life (Fig. 27-20). The ensuing ichthyosis is characterized by large (5–15 mm), grayish brown scales, which are strikingly quadrilateral, free at the edges, and adherent in the center (Fig. 27-21). In severe cases, the scales may be so thick that they are like armor plate. Moderate hyperkeratosis of the palms and soles is frequently present. The follicles in most cases have a crateriform appearance. Ectropion is usually present and is a helpful diagnostic sign.

Lamellar ichthyosis is inherited as an autosomal recessive trait. About half the patients have decreased or absent TGM1 activity. *ALOXE3* and *ALOX12B* mutations can produce a similar appearance. Lamellar ichthyosis type 2 has been associated with mutations in the *ABCA12* gene.

In addition to the topical agents recommended for the treatment of other ichthyoses, tazarotene (Tazorac) and oral retinoids can improve symptoms. The adverse effects of prolonged retinoid therapy make their use for long-term maintenance therapy difficult.

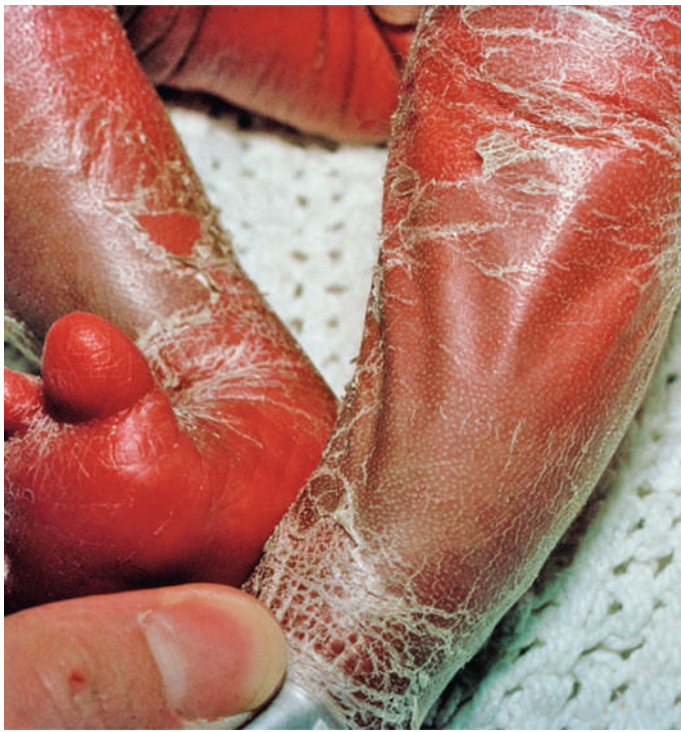

Fig. 27-20 Collodion baby.

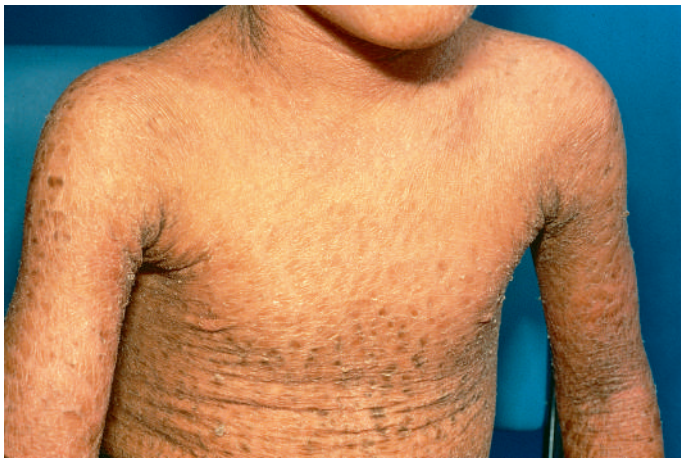

Fig. 27-21 Lamellar ichthyosis.

### Nonbullous congenital ichthyosiform erythroderma

Most infants with nonbullous congenital ichthyosiform erythroderma are born enclosed in a constricting parchmentlike or collodion-like membrane. They also have ectropion of the eyelids, which has led to confusion with lamellar ichthyosis, and at one time the term lamellar ichthyosis was used for almost all patients with nonbullous autosomal recessive ichthyoses. Because mutations in *TGM1*, *ALOXE3*, or *ALOX12B* can lead to either congenital ichthyosiform erythroderma or lamellar ichthyoses, the entities are separated largely on the basis of the clinical phenotype.

Within 24 hours of birth, fissuring and peeling begin, and large, keratinous lamellae are cast off in 10–14 days, coincident with rapid improvement. As the membrane is shed, underlying redness and scaling are apparent (Fig. 27-22). Generalized involvement is the rule, including the face, palms, soles, and flexures. Cicatricial alopecia, nail dystrophy, and some ectropion are common. Scales may be large and platelike on the legs but are likely to be fine on the trunk, face, and scalp. The

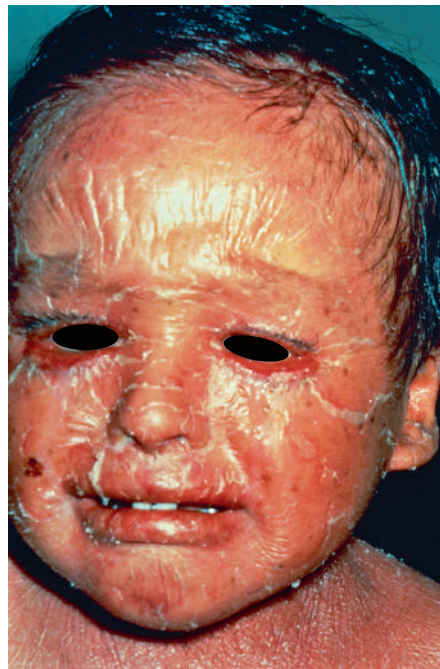

Fig. 27-22 Nonbullous congenital ichthyosiform erythroderma.

condition has been found in association with neutral lipid storage disease.

Histologically, parakeratosis and inflammation are seen more frequently in congenital ichthyosiform erythroderma than in lamellar ichthyoses. The stratum corneum is usually thicker in lamellar ichthyoses and is usually not parakeratotic.

### Harlequin fetus

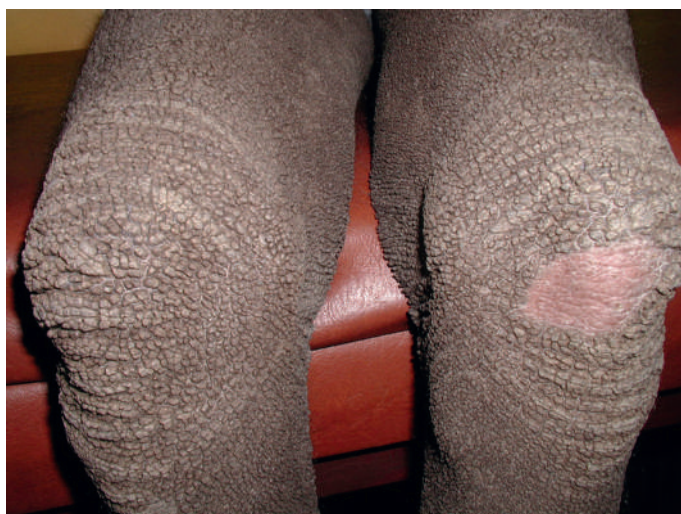Harlequin fetus is a severe disorder that affects the skin in utero, causing thick, horny, armorlike plates covering the entire surface. The ears are rudimentary or absent, and eclabium and ectropion are severe. The child is often stillborn or dies soon after delivery. With aggressive management, however, there have been long-term survivors, who develop features of congenital ichthyosiform erythroderma or lamellar ichthyosis. Absent or abnormal lamellar granules, a lack of extracellular lipid lamellae, and lipid droplets in the stratum corneum have been reported. Abnormalities of profilaggrin and keratin 6 (K6) and K16 expression have been reported. Recessive inheritance has been favored, supported by reports of consanguinity. Some reports suggest a dominant mutation with parental mosaicism.

### Epidermolytic ichthyosis

An autosomal dominant inherited disorder also known as bullous congenital ichthyosiform erythroderma or epidermolytic hyperkeratosis (EHK), epidermolytic ichthyosis is usually manifested by blisters at or shortly after birth. Later, thickened, horny, warty, or spinelike ridged scales predominate (Fig. 27-23). They are particularly prominent at the flexures. There is remarkable heterogeneity, particularly in regard to the degree of hyperkeratosis, extent of body surface involvement, presence or absence of erythroderma, and palm and sole involvement. An association with hypocalcemic vitamin D-resistant rickets has been reported. Epidermal nevi of the epidermolytic type are mosaic expressions of epidermolytic ichthyosis.

Epidermolytic ichthyosis is caused by mutations in the genes for K1 and K10. Keratin distribution patterns in





**Fig. 27-23** Epidermolytic hyperkeratosis. (Courtesy of Dr. Shyam Verma.)

keratinocytes are abnormal, suggesting an altered assembly process of cornified cell envelopes. A recessive form related to K10 mutation has been described.

Histologically, the lesional skin demonstrates compact hyperkeratosis. The granular layer is greatly thickened and contains coarse, blue and red, keratohyaline granules. Epidermal cells detach in the granular cell layer and may appear vacuolated. EM reveals the formation of perinuclear haloes. These findings allow prenatal diagnosis by fetal skin biopsy. Epidermolytic ichthyosis has been described as an incidental finding in normal skin, skin adjacent to benign and malignant epidermal tumors, and normal oral mucosa.

Short, intensive therapy with high-dose vitamin A, 750,000 U of Aquasol A daily for 2 weeks, produces modest clinical improvement. Others have tried administering systemic retinoids, with similar results; however, the patient's blistering may worsen, despite clinical improvement of the scales. Decisions regarding systemic retinoid therapy must therefore be made on a case-by-case basis. Application of 0.1% retinoic acid (Retin-A cream) has been used successfully. Pyogenic infection is a common problem, and appropriate antibiotics should be administered. A water solution of 10% glycerin and 3% lactic acid applied to wet skin can result in clinical improvement. The disease tends to become less severe with age.

### Ichthyosis bullosa of Siemens

Once classified as a subtype of epidermolytic ichthyosis (EHK), this condition is characterized by a lack of erythema, relatively mild hyperkeratosis usually limited to the flexures, and superficial molting or peeling of the skin (the "mauserung" phenomenon). Ichthyosis bullosa of Siemens is caused by mutations in the gene for keratin 2e.

### Acquired ichthyosis

Ichthyosis clinically similar to ichthyosis vulgaris may develop in patients with several systemic diseases. Acquired ichthyosis has been reported with Hodgkin disease and may be a presenting symptom. It has also occurred in non-Hodgkin lymphoma, mycosis fungoides, multiple myeloma, and carcinomatosis. In hypothyroidism, patients may develop fine scaling of the trunk and extremities, as well as carotenemia and diffuse alopecia. Characteristic ichthyosiform lesions may

develop in patients with sarcoidosis, particularly over the lower extremities. Biopsy of the lesion will often show granulomas. Ichthyosiform changes have also been reported in patients with Hansen's disease, nutritional deficiency, acquired immunodeficiency syndrome (AIDS), human T-cell lymphotropic virus infection, lupus erythematosus, and dermatomyositis. Drug-induced ichthyosis may occur with nicotinic acid, statins, triparanol, and butyrophonones.

**Abdul-Wahab A, et al:** Gene therapies for inherited skin disorders. *Semin Cutan Med Surg* 2014; 33:83–90.

**Craiglow BG, et al:** Topical tazarotene for the treatment of ectropion in ichthyosis. *JAMA Dermatol* 2013; 149(5):598–600.

**Digiovanna JJ, et al:** Systemic retinoids in the management of ichthyoses and related skin types. *Dermatol Ther* 2013; 26(1):26–38.

**Dufresne H, et al:** Importance of therapeutic patient education in ichthyosis: results of a prospective single reference center study. *Orphanet J Rare Dis* 2013; 8(1):113.

**Dyer JA, et al:** Care of the newborn with ichthyosis. *Dermatol Ther* 2013; 26(1):1–15.

**Fleckman P, et al:** Topical treatment of ichthyoses. *Dermatol Ther* 2013; 26(1):16–25.

**Hernández-Martin A, et al:** A systematic review of clinical trials of treatments for the congenital ichthyoses, excluding ichthyosis vulgaris. *J Am Acad Dermatol* 2013; 69(4):544–549.

**Lai-Cheong JE, et al:** Pathogenesis-based therapies in ichthyoses. *Dermatol Ther* 2013; 26(1):46–54.

**Madan RK, Levitt J:** A review of toxicity from topical salicylic acid preparations. *J Am Acad Dermatol* 2014; 70:788–792.

**Pan M, et al:** Urea: a comprehensive review of the clinical literature. *Dermatol Online J* 2013; 19:20392.

**Prado R, et al:** Collodion baby: an update with a focus on practical management. *J Am Acad Dermatol* 2012; 67(6):1362–1374.

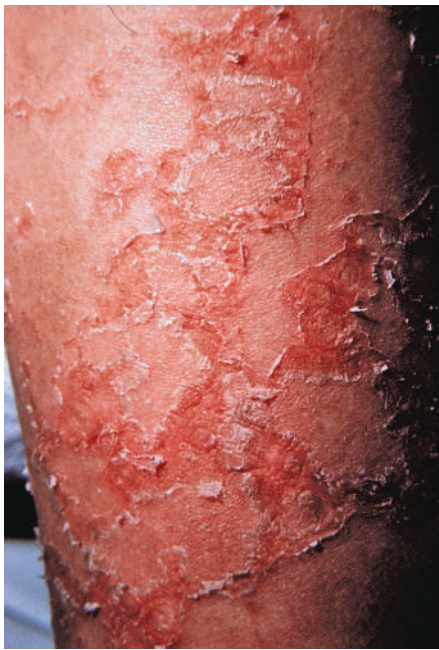**Richard G, et al:** Management of ichthyosis and related conditions, gene-based diagnosis and emerging gene-based therapy. *Dermatol Ther* 2013; 26(1):55–68.

### Restrictive dermopathy

Restrictive dermopathy is a rare, lethal, autosomal recessive inherited laminopathy characterized by abnormal facies, tight skin, sparse or absent eyelashes, and secondary joint changes. Virtually all cases are associated with polyhydramnios, reduced fetal movements, and premature delivery. Infants exhibit a fixed facial expression, with blurring of the groove between nose and cheek, sometimes described as an "Asiatic porcelain doll" appearance. Patients also exhibit micrognathia, mouth in the O position, rigid and tense skin with erosions and denudations, and multiple joint contractures. Some patients have wide cranial sutures, small pinched nose, low-set ears, microstomia, rocker-bottom feet, scaly skin, and respiratory insufficiency. Pulmonary hypoplasia, microcolon, vessel transposition, natal teeth, ectropion, submucous cleft palate, hypospadias, urethral duplication, dysplasia of clavicles, adrenal hypoplasia, and an enlarged placenta with short umbilical cord may be noted.

Histopathologic features include hyperkeratosis, parakeratosis, abnormal keratohyaline granules, and effacement of the rete ridge pattern. The dermis is attenuated with collagen fibers parallel to the epidermis, resembling a scar or tendon. Elastic fibers are absent. The subcutis demonstrates hypoplastic eccrine and sebaceous glands. The disease is usually caused by mutations in *ZMPSTE24*, causing loss of function of the encoded zinc metalloproteinase STE24 and resulting in accumulation of prelamin A at the nuclear periphery. Dominant and progeroid forms may be related to LMNA mutations.

**Starke S, et al:** Progeroid laminopathy with restrictive dermopathy-like features caused by an isodisomic LMNA mutation *p.R435C*. *Aging (Albany NY)* 2013; 5(6):445–459.



**Fig. 27-24** Ichthyosis linearis circumflexa.

### Ichthyosis linearis circumflexa

Ichthyosis linearis circumflexa is an inherited autosomal recessive disorder of cornification in which migratory annular and polycyclic patches occur (Fig. 27-24). It may first appear as severe congenital generalized exfoliative erythroderma. Later, lesions predominate on the trunk and extremities, and appear as a polycyclic serpiginous eruption characterized by constantly changing patterns. In about 1 week, the lesions attain their maximum diameter and involute, leaving no atrophy, scarring, or pigmentation. The lesions may clear almost completely during the summer. Most patients are found to have bamboo hair (trichorrhexis invaginata). The association of ichthyosiform dermatitis, hair abnormality, and atopic diathesis is called Netherton syndrome. Because of coexistent atopic dermatitis, the scalp, face, and eyebrow regions are erythematous and scaly. Hairs may fracture below the surface of the scalp, so that the patient appears bald. Mutations in *SPINK5*, which encodes the serine protease inhibitor Kazal-type 5 protein, have been identified in Netherton syndrome and result in unopposed kallikrein-related peptidase 5 (KLK5) and KLK7 activities and overactivity of elastase 2 (ELA2).

Histologic examination shows hyperkeratosis, parakeratosis, and acanthosis. The granular layer is typically absent.

Acitretin has been effective in some patients but should be avoided in erythrodermic neonates; long-term use is limited by toxicity. Topical tacrolimus has also been reported as effective, but in one report, three patients treated twice with 0.1% tacrolimus ointment were found to have significant tacrolimus blood levels. Although none of these patients developed signs or symptoms of toxic effects, monitoring of blood levels is advised if tacrolimus is used in this setting. NB-UVB has been reported as effective.

**Hovnanian A:** Netherton syndrome: skin inflammation and allergy by loss of protease inhibition. *Cell Tissue Res* 2013; 351(2):289–300.

**Maatouk I, et al:** Narrowband ultraviolet B phototherapy associated with improvement in Netherton syndrome. *Clin Exp Dermatol* 2012; 37(4):364–366.

### Neutral lipid storage disease

Dorfman-Chanarin syndrome is a rare autosomal recessive disorder characterized by an ichthyosiform eruption, myopa-

thy, and vacuolated leukocytes. Lipid vacuoles are present in all circulating granulocytes and monocytes, as well as in dermal fibroblasts, Schwann cells, smooth muscle cells, and sweat gland cells. Other organ systems, such as the CNS, liver, muscles, ears, and eyes, may also have deposits. Associated cutaneous disorders include poikiloderma atrophicum vasculare and bullous congenital ichthyosiform erythroderma. Neutral lipid storage disease is caused by a regulatory defect that alters the rates of synthesis and degradation of the major cellular phospholipids, particularly triacylglycerol-derived diacylglycerol. EM findings show electron-lucent globular inclusions in lamellar structures. Dietary intervention, with modulation of dietary fats, has been shown to aid in controlling the disease. Fibrates have also been used.

**Van de Weijer T, et al:** Effects of bezafibrate treatment in a patient and a carrier with mutations in the *PNPLA2* gene, causing neutral lipid storage disease with myopathy. *Circ Res* 2013; 112(5):e51–e54.

### Ichthyosis follicularis (ichthyosis follicularis, alopecia, and photophobia syndrome)

Ichthyosis follicularis is characterized by noncicatricial universal alopecia, severe photophobia, and generalized cutaneous follicular projections that are flesh colored and spiny. There is xerosis of nonspiny skin, and absence of sebaceous glands has been noted histologically. Hepatosplenomegaly, undescended testicles, nail dystrophy, inguinal hernia, short stature, seizures, psychomotor developmental delay, digital anomalies, and ptosis have been reported. Males outnumber females 5:1. The main considerations in the differential diagnosis are keratitis-ichthyosis-deafness (KID) syndrome and keratosis follicularis spinulosa decalvans (KFSD). Ichthyosis follicularis results from mutations in the *MBTPS2* gene impairing cholesterol homeostasis. Patients can be treated with topical keratolytics and emollients. A partial response to acitretin therapy has been noted in some patients. Intensive lubrication of the ocular surface is essential. Cardiopulmonary complications remain the major cause of death.

**Mégarbané H, et al:** Ichthyosis follicularis, alopecia, and photophobia (IFAP) syndrome. *Orphanet J Rare Dis* 2011; 6:29.

### Sjögren-Larsson syndrome

Sjögren-Larsson syndrome is characterized by ichthyosis, spastic paralysis, oligophrenia, mental retardation, and a degenerative retinitis. The ichthyosis is usually generalized, with minimal or no involvement of the scalp, hair, or nails. There is a flexural and lower abdominal accentuation. The central face is spared, ectropion is unusual, and palms and soles are involved. Mongolian spots may be present. Beginning by age 2 or 3 years, there is spastic paralysis consisting of a stiff, awkward movement of the extremities. Gluten sensitivity has been reported. EM reveals prominent Golgi apparatus and increased numbers of mitochondria in keratinocytes. Usually, a severe mental deficiency is present. The epilepsy is of the grand mal type. This syndrome is of autosomal-recessive inheritance, localized to chromosome 17p11.2. These patients have a fibroblast and leukocyte deficiency in fatty aldehyde dehydrogenase.

**Dutra LA, et al:** Sjogren-Larsson syndrome. *Adv Exp Med Biol* 2012; 724:344–350.

### Refsum syndrome

Refsum syndrome (heredopathia atactica polyneuritiformis) is an autosomal recessive inherited ichthyosis with atypical



retinitis pigmentosa, hypertrophic peripheral neuropathy, cerebellar ataxia, nerve deafness, and various electrocardiographic changes. The ichthyosis resembles ichthyosis vulgaris. It may be generalized or localized to the palms and soles. It is of delayed onset and shows lipid vacuoles in the basal layer. The epidermal cell turnover rate is increased. Biochemically, the disease is a peroxisomal disorder characterized by excessive accumulation of phytanic acid, pristanic acid, and picolinic acid in fatty tissues, myelin sheaths, heart, kidneys, and retinal tissues.

Refsum syndrome is caused by a deficiency of phytanoyl-CoA-hydroxylase. In most patients, mutations in the *PHYH* gene have been identified, and a second locus has been found on chromosome 6q22–24 with mutations in *PEX7* (a gene also associated with rhizomelic chondrodysplasia punctata type 1) and *PAHX*. Dietary restriction of phytanic acid-containing vegetables can lead to an improvement of neurologic symptoms but does not affect retinal changes. Unfortunately, in many patients, dietary restriction is not sufficient to prevent acute attacks or stabilize the progressive course. The acids are localized within very-low-density lipoprotein (VLDL), LDL, and high-density lipoprotein (HDL) particles and may be removed by extracorporeal LDL apheresis.

**Braverman NE, et al:** Peroxisome biogenesis disorders: biological, clinical and pathophysiological perspectives. *Dev Disabil Res Rev* 2013; 17(3):187–196.

### Rud syndrome

Rud syndrome is characterized by ichthyosis, hypogonadism, small stature, mental retardation, acanthosis nigricans, epilepsy, macrocytic anemia, and rarely, retinitis pigmentosa. Most kindreds have shown autosomal recessive inheritance and may be atypical variants of well-described disorders, such as Sjögren-Larsson syndrome or Refsum syndrome, rather than representing a distinct inherited disorder. Some patients have X-linked steroid sulfatase deficiency.

**Happle R:** Rud syndrome does not exist. *Eur J Dermatol* 2012; 22(1):7.

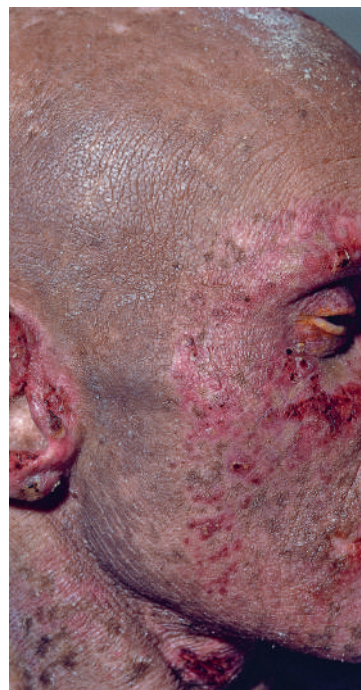### Keratitis-ichthyosis-deafness syndrome

The keratitis-ichthyosis-deafness (KID or Senter) syndrome is characterized by vascularization of the cornea, an extensive congenital ichthyosiform eruption, neurosensory deafness, reticulated hyperkeratosis of the palms and soles, hypotrichosis, partial anhidrosis, nail dystrophy, and tight heel cords. Distinctive leathery, verrucoid plaques involve the central portion of the face and ears. These changes, with absent eyebrows and eyelashes and furrows about the mouth and chin, give the children a unique facies (Fig. 27-25). Occasionally, hairs may demonstrate bright and dark bands on polarized microscopy, as seen in trichothiodystrophy. Chronic mucocutaneous candidiasis and superinfection of skin lesions is common. Benign trichilemmal tumors and SCC occur in approximately 15% of patients.

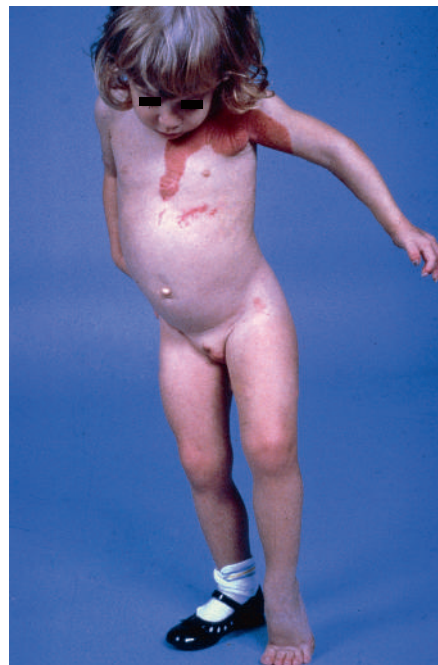Some kindreds lack deafness. The disorder is related to missense mutations in the *GJB2* gene that encodes connexin 26 (Cx26). Most cases are sporadic.

Isotretinoin treatment may exacerbate and promote corneal vascularization. Treatment with acitretin has been reported to clear the hyperkeratotic ichthyotic lesions with minimal effect on the cornea or hearing. Cyclosporin A eyedrops have been used to treat corneal neovascularization.

**Cogshall K, et al:** Keratitis, ichthyosis, and deafness syndrome: a review of infectious and neoplastic complications. *J Am Acad Dermatol* 2013; 69(1):127–134.



**Fig. 27-25** KID syndrome.



**Fig. 27-26** CHILD syndrome, left hand has a bony defect.

**Sakabe J, et al:** Connexin 26 (*GJB2*) mutations in keratitis-ichthyosis-deafness syndrome presenting with squamous cell carcinoma. *J Dermatol* 2012; 39(9):814–815.

### CHILD syndrome: congenital hemidysplasia with ichthyosiform erythroderma and limb defects

Present at birth, congenital hemidysplasia with ichthyosiform erythroderma and limb defects (CHILD) syndrome is characterized by unilateral inflammatory epidermal nevi and ipsilateral limb hypoplasia or limb defects (Fig. 27-26). Features may vary widely, from complete absence of an extremity to defects of internal organs involving the musculoskeletal, cardiovascular, or central nervous system. Biopsy may demonstrate

abnormal lamellar granules in the upper stratum spinosum. The condition is believed to be X-linked dominant and is lethal in hemizygous males. Survival in males has been reported as a result of mosaicism. In females, lyonization may produce cutaneous patterns following the lines of Blaschko, similar to incontinentia pigmenti or X-linked dominant chondrodysplasia. The pathogenesis is related to mutations in the *NSDHL* gene that is localized at Xq28 and involved in cholesterol metabolism. When unilateral epidermal nevi show features of verruciform xanthoma, CHILD syndrome should be suspected. The CHILD nevus is distinguished by ptychotropism (flexural involvement), waxy yellowish scaling, lateralization showing both diffuse and linear involvement, and the presence of foamy macrophages in the dermal papillae.

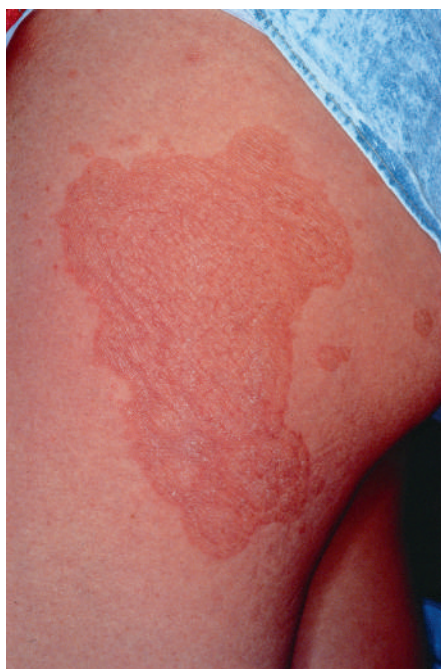
**Raychaudhury T, et al:** A novel X-chromosomal microdeletion encompassing congenital hemidysplasia with ichthyosiform erythroderma and limb defects. *Pediatr Dermatol* 2013; 30(2):250–252.

### Erythrokeratoderma variabilis

Erythrokeratoderma variabilis, also called erythrokeratoderma figurata variabilis, and Mendes da Costa-type erythrokeratoderma, is a rare autosomal dominant disorder characterized by erythematous patches and hyperkeratotic plaques of sparse but generalized distribution. The erythematous patches may assume bizarre geographic configurations that are sharply demarcated (Fig. 27-27). Over time, they change shape or size or involute completely. The keratotic plaques are reddish brown, often polycyclic, and fixed in location. The extensor surfaces of the limbs, buttocks, axillae, groins, and face are most often involved. Approximately 50% of patients display a palmoplantar keratoderma associated with peeling. Hair, nails, and mucous membranes are spared.

The onset of erythrokeratoderma variabilis is shortly after birth, or rarely at birth, or in early adult life. There may be some improvement with age, particularly after menopause. Exacerbations have been seen during pregnancy. The figurate erythematous component may be accentuated by exposure to heat, cold, or wind. Emotional upsets may also be a factor.

The gene has been mapped to 1p34–p35, the gene *GJB3* coding for a gap junction protein  $\alpha$ -4 (connexin 31). Histologi-



**Fig. 27-27**  
Erythrokeratoderma variabilis.

cally, there is hyperkeratosis and parakeratosis and a diminished granular layer. Acanthosis may occur. Ultrastructurally, epidermal keratinosomes are diminished.

Systemic retinoids such as acitretin or isotretinoin alone or combined with psoralens and ultraviolet A (UVA) therapy can restore the deficient keratinosomes and partially clear the hyperkeratotic plaques. Erythrokeratoderma variabilis often relapses when therapy is discontinued. Urea, salicylic acid, and lactic acid have proved useful for the hyperkeratotic plaques.

**Scott CA, et al:** Connexins in epidermal homeostasis and skin disease. *Biochim Biophys Acta* 2012; 1818(8):1952–1961.

**Yüksek J, et al:** Erythrokeratoderma variabilis: successful treatment with retinoid plus psoralen and ultraviolet A therapy. *J Dermatol* 2011; 38(7):725–727.

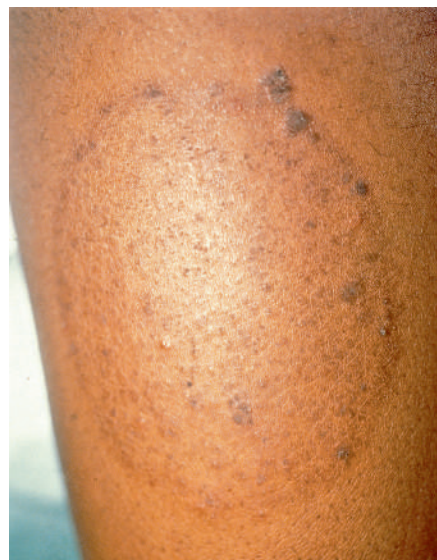### Progressive symmetric erythrokeratoderma

Progressive symmetric erythrokeratoderma (erythrokeratoderma progressiva symmetrica) is a rare, autosomal dominant inherited disorder that manifests soon after birth with erythematous, hyperkeratotic plaques that are symmetrically distributed on the extremities, buttocks, and face, sparing the trunk. Palmoplantar keratoderma may be present. The lesions may regress at puberty. Occipital alopecia, oligodontia, and severe caries have been reported. One kindred with Vohwinkel syndrome demonstrated an insertion mutation in the *Loricrin* gene, but other patients have shown no evidence of *GJB3*, *GJB4*, or *LOR* mutations. Topical treatments, including keratolytics, corticosteroids, and retinoids, have had variable success.

**Wei S, et al:** Evidence for the absence of mutations at *GJB3*, *GJB4* and *LOR* in progressive symmetrical erythrokeratoderma. *Clin Exp Dermatol* 2011; 36(4):399–405.

### PITYRIASIS ROTUNDA

Pityriasis rotunda (pityriasis circinata) manifests as perfectly circular scaly patches on the torso and proximal portions of the extremities (Fig. 27-28). The scale is adherent and resembles that of ichthyosis vulgaris. There is a strong ethnic predisposition, with a preponderance of reports in black persons, Japanese, Koreans, and Italians. Some cases are associated with systemic illnesses, especially in darker-skinned patients. Associated illnesses include tuberculosis, other pulmonary



**Fig. 27-28** Pityriasis rotunda.



disorders, liver disease, malnutrition, leukemia, lymphoma, and carcinoma of the esophagus or stomach. Familial cases with autosomal dominant transmission have also been described.

Two forms of pityriasis rotunda occur. Type I is found in black or Asian persons, usually has fewer than 30 hyperpigmented lesions, is nonfamilial, and may be associated with systemic disease. Type II disease occurs in white persons, has larger numbers of hypopigmented lesions, is often familial, and usually is not associated with internal disease.

The differential diagnosis includes tinea versicolor, tinea corporis, erythrasma, Hansen's disease, fixed drug eruptions, and pityriasis alba. Some patients note a seasonal improvement during the summer, and some respond to emollients during the winter months. Low levels of steroid sulfatase have been identified, and the profilaggrin N-terminal domain is absent in some patients. Topical and systemic retinoids have been used successfully, but pityriasis rotunda often is unresponsive unless the patient has an underlying systemic illness that can be treated.

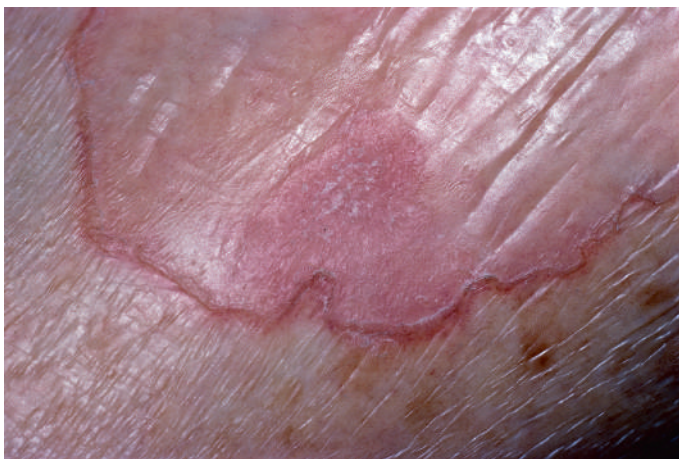**Yoneda K, et al:** The profilaggrin N-terminal domain is absent in pityriasis rotunda. *Br J Dermatol* 2012; 166(1):227-229.

**Zur RL, et al:** Pityriasis rotunda diagnosed in Canada: case presentation and review of the literature. *J Cutan Med Surg* 2013; 17(0):1-3.

## POROKERATOSIS

Porokeratosis comprises a heterogeneous group of disorders that are inherited in an autosomal dominant fashion. Except for the punctate type, they are characterized by distinct clinical findings of a keratotic ridge with a central groove that corresponds to the cornoid lamella on histology (Fig. 27-29). The groove may be accentuated by the application of gentian violet, followed by removal with alcohol. The dye remains in the groove. Povidone-iodine has been similarly used. Immunosuppression, UV exposure, and radiation therapy may exacerbate porokeratosis and promote the development of skin cancers within the lesions. The linear type has the greatest risk of malignant transformation. Segmental forms have been reported in a blaschkoid distribution and after radiation therapy.

Topical 5-fluorouracil (5-FU) can be effective in destroying individual lesions; it may need to be applied under occlusion but may result in scarring. In disseminated superficial actinic porokeratosis (DSAP), where the risk of malignant transfor-



**Fig. 27-29** Porokeratosis with keratotic ridge. (Courtesy of Dr. Curt Samlaska.)

mation is very low, the risks of treatment with 5-FU must be weighed against the generally indolent course of the lesions. PDT has been used with incubation under a heating pad to promote porphyrin conversion. Sun protection, emollients, and observation for signs of malignant degeneration may be the most suitable course of action for many patients with DSAP. Other agents that have been shown to be effective for some patients with DSAP include topical imiquimod, vitamin D<sub>3</sub> analogs, diclofenac gel, and topical retinoids, including tazarotene. Salicylic acid and  $\alpha$ -hydroxyl acids may make the lesions less noticeable. Oral retinoids have shown efficacy, but the lesions frequently recur after treatment, and long-term treatment with these agents is impractical. Combinations of oral retinoids and topical 5-FU have been effective for refractory DSAP and porokeratosis plantaris, palmaris, et disseminata, but the side effects of treatment may be considerable. Destructive modalities must extend into the dermis and produce scarring in order to prevent recurrence. Destructive modalities employed include cryotherapy, electrodesiccation and curettage, CO<sub>2</sub> laser ablation, Q-switched ruby laser, fractional photothermolysis, flashlamp-pumped pulsed dye laser, frequency-doubled neodymium-doped yttrium-aluminum-garnet (Nd:YAG) laser, dermabrasion, and grenz ray radiotherapy.

## Plaque-type porokeratosis (Mibelli)

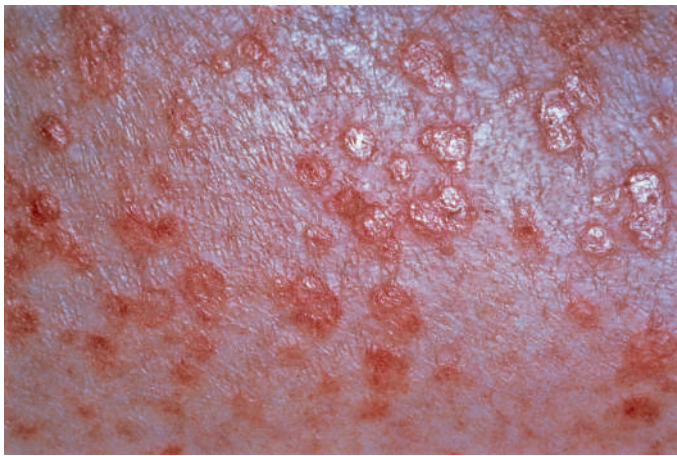Plaque-type porokeratosis is a chronic, progressive disease characterized by the formation of slightly atrophic patches surrounded by an elevated, warty border. The lesion begins as a small keratotic papule, which spreads peripherally and becomes depressed centrally. Eventually, it becomes a circinate or serpiginous, well-defined plaque surrounded by a keratotic wall or collar. This wall is grayish or brownish and frequently is surmounted by a tiny groove or linear ridge running along its summit. The enclosed central portion of the plaque consists of dry, smooth, atrophic skin; the lanugo hairs generally are absent when the patches occur in hairy areas. Linear or zosteriform distribution of the lesions may also occur. If the nail matrix is involved, nail dystrophy may develop. Lesions may appear during chemotherapy for malignancy, after renal transplantation, while on psoralen plus UVA (PUVA) treatment, and in areas of chronic sun damage or chemical exposure, such as benzylhydrochlorothiazide.

Sites of predilection are the surfaces of the hands and fingers, as well as the feet and ankles. The disease also occurs on the face and scalp (where it produces bald patches), on the buccal mucosa (where the ridge becomes macerated by moisture and appears as a milky white, raised cord), and on the glans penis (where it causes erosive balanitis).

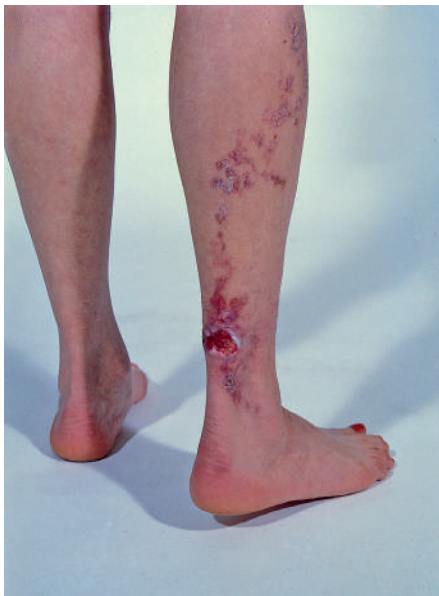
Histologically, the principal diagnostic changes are in the area of the cornoid lamella. This area demonstrates a column of parakeratotic keratin extending at about a 45-degree angle from a focus of dyskeratotic cells in the malpighian layer. The column trails behind the focus of dyskeratosis as the focus expands peripherally. The granular cell layer is absent beneath the parakeratotic column. The central portion of the lesion may demonstrate atrophy with loss of the rete ridge pattern, lichenoid dermatitis, or psoriasiform hyperplasia.

## Disseminated superficial actinic porokeratosis

Disseminated superficial actinic porokeratosis (DSAP) is characterized by numerous superficial, circinate, keratotic, brownish red macules found on sun-exposed skin (Fig. 27-30). It is more common in women. The distribution of the lesions on



**Fig. 27-30** Disseminated superficial actinic porokeratosis.

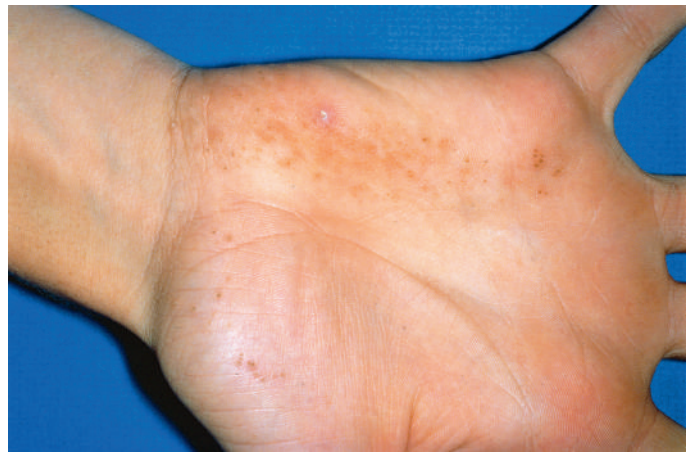

**Fig. 27-31** Linear porokeratosis with squamous cell carcinoma.

the sun-exposed areas indicates that actinic radiation is an important factor in the pathogenesis, and new lesions have been induced by exposure at commercial tanning salons. Exacerbations occur in up to two thirds of patients during summer. Immunosuppression is also well documented as exacerbating the disease. DSAP has been seen in patients with AIDS, cirrhosis, and Crohn's disease. Organ transplant patients may develop DSAP. Improvement of the immunosuppression may lead to resolution of the lesions. Gene loci have been localized to chromosomes 12q23.2-24.1 and 15q25.1-26.1, suggesting that DSAP is a genetically heterogeneous disorder.

### Linear porokeratosis

Linear porokeratosis may be segmental or generalized. It may be identified during the newborn period, and when found in the segmental pattern, may follow the lines of Blaschko. Ulcerations and erosions involving the face or extremities may delay the correct diagnosis, and linear porokeratosis should be included in the differential diagnosis of ulcerative lesions in the neonatal period. This form of porokeratosis has the highest risk of developing cutaneous malignancies, including SCC (Fig. 27-31), Bowen's disease, and basal cell carcinoma.



**Fig. 27-32** Porokeratotic eccrine ostial and dermal duct nevus.

### Porokeratosis palmaris, plantaris, et disseminata

In this distinctive form of porokeratosis, lesions first appear on the palms or soles, or more often both. Onset is frequently noted when patients are in their twenties. Slowly, the lesions may extend over the entire body. In porokeratotic eccrine ostial and dermal duct nevus, the presentation clinically appears as a nevus comedonicus of the palm or sole (Fig. 27-32), but histologic analysis reveals multiple coronoid, lamella-like, parakeratotic columns. In porokeratosis punctata, palmaris, et plantaris or punctate porokeratosis, lesions are limited to the hands and feet.

### Porokeratotic eccrine ostial and dermal duct nevus

This is a related condition that affects the eccrine ostia and typically presents with volar keratosis resembling music box spines.

**Zhang SQ, et al:** Exome sequencing identifies *MVK* mutations in disseminated superficial actinic porokeratosis. *Nat Genet* 2012; 44(10):1156-1160.

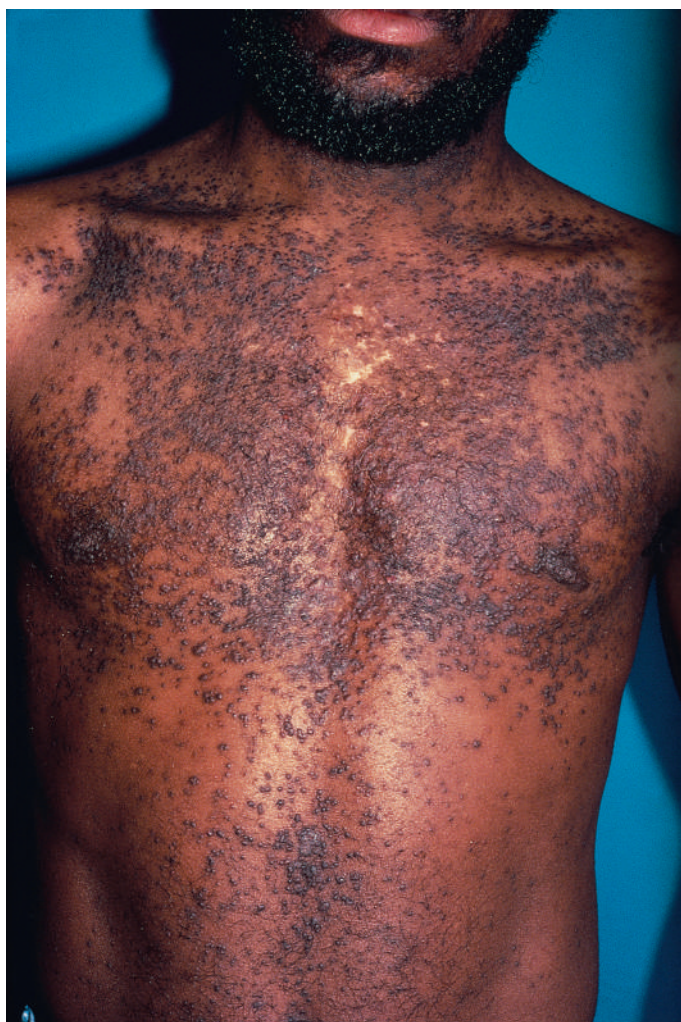### DARIER'S DISEASE (KERATOSIS FOLLICULARIS, DARIER-WHITE DISEASE)

Darier's disease is an autosomal dominant inherited skin disorder characterized by brown keratotic papules that tend to coalesce into patches in a seborrheic distribution. Early lesions are small, firm papules, almost the color of normal skin. Each papule becomes covered with a greasy, gray-brown crust that fits into a small concavity in the summit of the papule. As the lesions age, their color darkens. Over years, the papules grow and may fuse to form malodorous, papillomatous, vegetating growths.

The neck, shoulders, face, extremities, front of the chest, and midline of the back are sites of predilection for the disease. A frequent site for the earliest lesions is behind the ears. As the eruption spreads, the entire trunk, buttocks, genitals, and other parts of the skin may be involved. Usually, the eruption is symmetric and widespread, but striking unilateral or segmental involvement may also occur. Cases with segmental distribution probably represent postzygotic mutations.

Vegetations appear chiefly in the axillae, gluteal crease, and groin and behind the ears. The scalp is generally covered with greasy crusts. Lesions on the face are often prominent about





**Fig. 27-33** Darier's disease. (Courtesy of Dr. Lawrence Lieblch).

the nose. The lips may be crusted, fissured, swollen, and superficially ulcerated, and there may be a patchy keratosis with superficial erosions on the dorsum of the tongue. Small white papules or pebbling may be present on the gingiva and palate. Involvement of the oropharynx, esophagus, hypopharynx, larynx, and anorectal mucosa has been reported. Punctate keratoses are frequently noted on the palms and soles. A general horny thickening of the palms and soles may be present because of innumerable, closely set, small papules. On the dorsa of the hands and on the shins, the flat verrucous papules may resemble verrucae planae. The nails show subungual hyperkeratosis, fragility, and splintering, with longitudinal alternating white and red streaks, and triangular nicking of the free edges (Fig. 27-33). Esophageal involvement has been described.

Darier's disease is usually worse in the summer. It may begin after severe sunburn, and in some patients the lesions may be reproduced with suberythema doses of UVB light. Lithium carbonate has been shown to induce Darier's disease in some individuals. Disseminated cutaneous herpes simplex may be a complication of the disease.

Abnormal dissolution of desmosomal plaque proteins is seen, specifically desmoplakin I and II, plakoglobin, and desmoglein. Acantholysis occurs as a result of deficiency in the tonofilament/desmosome attachment. Calcium ion ( $\text{Ca}^{2+}$ )-dependent cell-cell adhesion molecules (epithelial cadherins) are greatly reduced on the acantholytic cells of patients with

Darier's disease. The Darier gene (*ATP2A2*) has been localized to 12q23–24.1 and codes for the second isoform of a calcium ATPase of the sarcoplasmic/endoplasmic reticulum (SERCA2) pump, which transports  $\text{Ca}^{2+}$  from the cytosol into the endoplasmic reticulum. Inhibition of SERCA impairs trafficking of desmoplakin to the cell surface, contributing to acantholysis.

### Histology

Darier's disease is characterized by acantholytic dyskeratosis with overlying hyperkeratosis. Round, acantholytic dyskeratotic cells (corps ronds) typically demonstrate a pale or blue halo surrounding the nucleus. Grains are flat, deeply basophilic, dyskeratotic cells, seen most frequently in the stratum granulosum and stratum corneum. Formation of a suprabasal cleft (lacuna) is noted and may involve hair follicles as well as the surface epidermis. Dermal papillae covered by a single layer of basal cells project as villi into the acantholytic space.

### Treatment

During flares, topical antibacterial agents, oral antibiotics, and short-term application of a corticosteroid may be of benefit. For localized disease, topical retinoids may be effective, but papules often occur at the periphery of the treated region. Topical diclofenac sodium has also been used. Oral retinoids are the drugs of choice for most severe cases. Cyclosporine may control severe flares, and topical sunscreens and ascorbic acid can prevent disease flares in some patients. For hypertrophic lesions, dermabrasion, laser vaporization, or excision and grafting can be considered. PDT using topical 5-aminolevulinic acid produces an initial inflammatory response that lasts 2–3 weeks. In some patients with Darier's disease, this is followed by sustained improvement. Because of the initial inflammatory response, it is only appropriate for patients who have failed most other options.

**Anuset D, et al:** Efficacy of oral alitretinoin for the treatment of Darier disease: a case report. *J Am Acad Dermatol* 2014; 71:e46–48.

**Letulé V, et al:** Treatment of Darier disease with oral alitretinoin. *Clin Exp Dermatol* 2013; 38(5):523–525.

**Millán-Parrilla F et al:** Improvement of Darier disease with diclofenac sodium 3% gel. *J Am Acad Dermatol* 2014; 70:e89–90.

**Stewart LC, et al:** Vulval Darier's disease treated successfully with ciclosporin. *J Obstet Gynaecol* 2008; 28(1):108–109.

## ACROKERATOSIS VERRUCIFORMIS

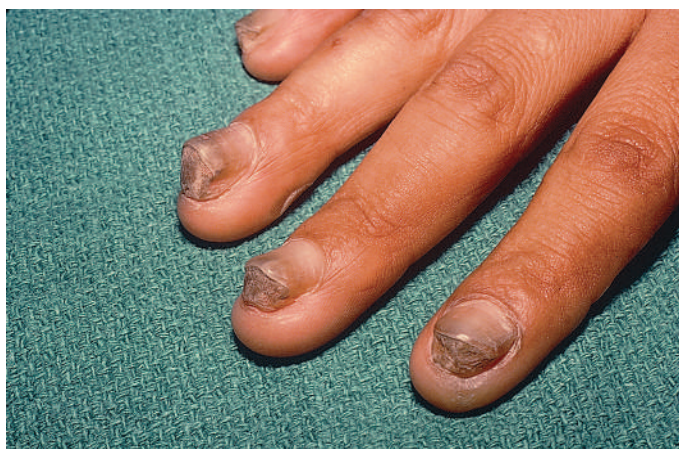This rare autosomal dominant genodermatosis is characterized by numerous flat verrucous papules occurring on the backs of the hands, insteps, knees, and elbows. The papules are closely grouped and resemble warts, except that they are flatter and more localized. The verrucous lesions are identical to those in Darier's disease, and some, but not all, cases of acrokeratosis verruciformis of Hopf are caused by mutations in the *ATP2A2* gene.

Histologically, hyperkeratosis, thickening of the granular layer, acanthosis, and church spire papillomatosis characterize the disease. Available treatments are liquid nitrogen therapy, shave excision, and  $\text{CO}_2$  laser ablation. Recurrence is common. Acitretin has been used successfully.

**DeFelice T, et al:** Acrokeratosis verruciformis. *Dermatol Online J* 2012; 18(12):12.

**Serarslan G, et al:** Acitretin treatment in acrokeratosis verruciformis of Hopf. *J Dermatolog Treat* 2007; 18(2):123–125.





**Fig. 27-34** Pachyonychia congenita.

## PACHYONYCHIA CONGENITA

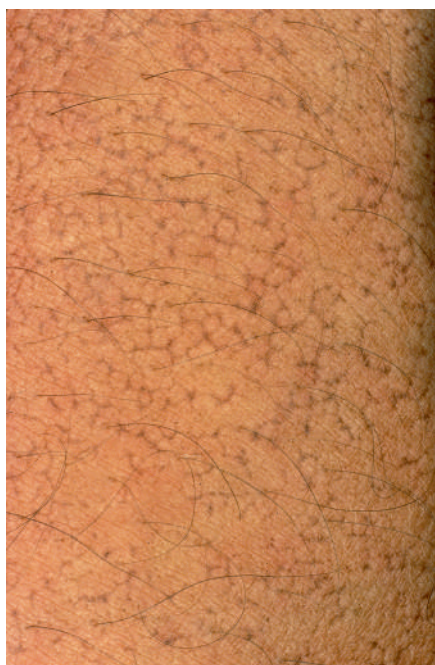In 1906, Jadassohn and Lewandowsky described a rare, often familial, anomaly of the nails that they named pachyonychia congenita. It is characterized by thickened nail beds of all fingers and toes, palmar and plantar hyperkeratosis, blistering under the callosities, palmar and plantar hyperhidrosis, spiny follicular keratoses, and benign leukokeratosis of the mucous membranes. The nail plates are extremely hard and are firmly attached to the nail beds. The nail bed is filled with yellow, horny, keratotic debris, which may cause the nail to project upward at the free edge (Fig. 27-34). Paronychia inflammation is frequently present. Delayed onset of pachyonychia in young adulthood has been described, as has acro-osteolysis.

On the extensor surfaces of the extremities, buttocks, and lumbar regions, spinelike follicular keratotic papules are found. Removal of these central cores leaves a slightly bleeding cavity. The eruption on the outer aspects of the upper and lower extremities is also follicular, resembling keratosis pilaris. This latter condition is not constant and disappears at times.

Painful friction blisters may develop on the plantar aspects of the toes or heels or along the edges of the feet, and cases have been misdiagnosed as epidermolysis bullosa. In a study of 254 patients, the triad of toenail thickening, plantar keratoderma, and plantar pain was reported by 97% of patients by age 10. Leukokeratosis of the tongue and oral mucosa, as well as occasional laryngeal involvement with hoarseness, may occur. This oral leukokeratosis resembles an oral white sponge nevus histologically and is not predisposed to the development of malignancy.

Pachyonychia congenita is divided into four types. Type I (Jadassohn-Lewandowsky syndrome) is the most common, as previously described. Type II (Jackson-Sertoli syndrome) has the same features as type I, with the additional features of natal teeth and steatocystoma multiplex. Patients with type II syndrome typically have less severe palmoplantar keratoderma, and oral lesions may be absent. Type III (Schaffer-Branauer syndrome) is similar to type I, with the addition of leukokeratosis of the corneas. Pachyonychia congenita tarda was suggested as the name for late-onset disease (type IV). Type IV disease has been described with hyperpigmentation around the neck, waist, axillae, thighs, flexures of the knees, buttocks, and abdomen. Pigmentary incontinence and amyloid deposition are seen in biopsy specimens.

Pachyonychia congenita is usually inherited as an autosomal dominant trait, although recessive forms have been reported. There is a genetic mutation of keratin 6a or 16 in type I disease, and of keratin 6b or 17 in type II disease. There is a higher likelihood of oral leukokeratosis with *KRT6A*



**Fig. 27-35** Dyskeratosis congenita. (Courtesy of Dr. Lawrence Lieblich.)

mutations, and natal teeth and cysts are strongly associated with *KRT17* mutation. Homozygous dominant missense mutation in *K17* has been associated with severe pachyonychia congenita and alopecia. Mutant-specific small inhibitory RNAs (siRNAs) and hedgehog signaling may be important in disease expression.

Avulsion of the nails brings about only temporary relief. Vigorous curettage of the matrix and nail bed is the simplest and most effective therapy. Destruction of the nail matrix with phenol may be partially effective, but recurrence of nail bed hyperkeratosis is common. The keratoderma is difficult to treat, but topical lactic acid, ammonium lactate, salicylic acid, or urea may be of some benefit. Isotretinoin has been reported to clear the keratotic papules and the oral leukokeratosis, but not the palms or soles. Acitretin has been shown to be effective in treating the late-onset form.

**Eliason MJ, et al:** A review of the clinical phenotype of 254 patients with genetically confirmed pachyonychia congenita. *J Am Acad Dermatol* 2012; 67(4):680–686.

**Irvine AD:** Double trouble: homozygous dominant mutations and hair loss in pachyonychia congenita. *J Invest Dermatol* 2012; 132(7):1757–1759.

**O'Toole EA, et al:** Pachyonychia congenita cornered: report on the 11th Annual International Pachyonychia Congenita Consortium meeting. *Br J Dermatol* 2014; 171:974–977.

**Wilson NJ, et al:** Homozygous dominant missense mutation in keratin 17 leads to alopecia in addition to severe pachyonychia congenita. *J Invest Dermatol* 2012; 132(7):1921–1924.

## DYSKERATOSIS CONGENITA (ZINSSER-COLE-ENGMAN SYNDROME)

Dyskeratosis congenita is a rare congenital syndrome characterized by cutaneous poikiloderma, nail dystrophy, and premalignant leukoplakia. Atrophy and telangiectasia are accompanied by tan-gray, mottled, hyperpigmented and hypopigmented macules or reticulated patches (Fig. 27-35). These lesions are located typically on the upper torso, neck, and face, although the extremities may also be involved.

The nails may be thin and dystrophic, although only ridging and longitudinal fissuring may be seen in mild cases. This is the first component of the syndrome to appear, becoming apparent between ages 5 and 15. The other cutaneous lesions



generally follow within 3–5 years. Leukoplakia occurs mostly on the buccal mucosa, where extensive involvement with verrucous thickening may be present. The anus, vagina, conjunctiva, and urethral meatus can be involved. Malignant neoplasms of the skin, mouth, nasopharynx, esophagus, rectum, and cervix may occur in sites of leukoplakia. Other manifestations of dyskeratosis congenita include hyperhidrosis of the palms and soles, bullous conjunctivitis, gingival disorders, dental caries, hypodontia, thin tooth enamel, periodontitis, dysphagia resulting from esophageal strictures and diverticula, skeletal abnormalities, aplastic anemia, mental deficiency, and hypersplenism. In many cases, a Fanconi type of anemia develops, beginning with leukopenia and thrombocytopenia, and progressing to severe pancytopenia. Pulmonary complications include interstitial fibrosis and *Pneumocystis jirovecii* (formerly *P. carinii*) pneumonia.

Patients with dyskeratosis congenita have short telomeres, related to mutations in genes that encode components of the telomerase complex. These include dyskerin, *TERC*, *TERT*, *NHP2*, and *NOP10*. The genetic defect for the X-linked form is located on Xq28 and associated with the *DKC1* gene for dyskerin, a protein implicated in both telomerase function and ribosomal RNA processing. The presence of short leukocyte telomeres can be helpful diagnostically. Autosomal dominant inheritance is often associated with mutations in hTR (*hTERC*), involved in the RNA component of telomerase. Some autosomal dominant cases have anemia and reticulated pigmentation following the lines of Blaschko. Of interest, some patients with idiopathic aplastic anemia or myelodysplastic syndrome without skin findings demonstrate *hTERC* mutations. Autosomal recessive inheritance of dyskeratosis congenita has also been reported.

Granulocyte colony-stimulating factor and erythropoietin may provide short-term benefits in treating bone marrow failure. Bone marrow transplantation or hematopoietic stem cell transplantation with nonmyeloablative conditioning affords the best outcomes.

Hoyeraal-Hreidarsson syndrome is characterized by intrauterine growth retardation, cerebellar hypoplasia, mental retardation, microcephaly, progressive combined immunodeficiency, and aplastic anemia. The syndrome is genetically heterogeneous. Some patients demonstrate *DKC1* gene mutations and are therefore allelic to dyskeratosis congenita.

**Ballew BJ, et al:** Updates on the biology and management of dyskeratosis congenita and related telomere biology disorders. *Expert Rev Hematol* 2013; 6(3):327–337.

**Fernández García MS, Teruya-Feldstein J:** The diagnosis and treatment of dyskeratosis congenita: a review. *J Blood Med* 2014; 5:157–167.

**Gramatges MM, et al:** Short telomeres: from dyskeratosis congenita to sporadic aplastic anemia and malignancy. *Transl Res* 2013; Jun 1. doi:pii: S1931-5244(13)00146-1. 10.1016/j.trsl.2013.05.003. [Epub ahead of print.] PMID: 23732052.

**Keeling B, et al:** Dyskeratosis congenita. *Dermatol Online J* 2014; 20:9.

## FANCONI SYNDROME

Also known as familial pancytopenia or familial panmyelophthisis, Fanconi syndrome may be associated with diffuse pigmentation of the skin (hypopigmentation, hyperpigmentation, and café au lait macules), absence of the thumbs, aplasia of the radius, severe hypoplastic anemia, thrombocytopenia, retinal hemorrhage, strabismus, generalized hyperreflexia, and testicular hypoplasia. The syndrome is associated with increased risk of myelomonocytic leukemia, SCC, and hepatic tumors. No hypersensitivity to UV light, x-rays, or chemical agents is present. Human papillomavirus DNA is often found in the SCCs. Both cutaneous and pulmonary manifestations of associated Sweet syndrome have been reported. Some patients

manifest short stature, failure to thrive, absent thumbs, short palpebral fissures, and typical skin abnormalities, but no hematologic abnormalities.

Fanconi syndrome is inherited in an autosomal recessive manner. Analysis has shown five complementation groups (FA-A, FA-B, FA-C, FA-D, and FA-E) and therefore five associated genes. The genes play an important role in hematopoiesis, and abnormal gene expression has been shown to increase apoptosis. FA-A has been localized to 16q24.3 and FA-D to 3p22.26. Chromosome patterns are frequently abnormal.

**Chatham-Stephens K, et al:** Metachronous manifestations of Sweet's syndrome in a neutropenic patient with Fanconi anemia. *Pediatr Blood Cancer* 2008; 51(1):128–130.

**Dokal I, et al:** Inherited aplastic anaemias/bone marrow failure syndromes. *Blood Rev* 2008; 22(3):141–153.

## ECTODERMAL DYSPLASIA

The ectodermal dysplasias are a clinically and genetically heterogeneous group of genodermatoses in which the cardinal features are the abnormal, absent, incomplete, or delayed development during embryogenesis of one or more of the epidermal or mucosal appendages (hair, sebaceous glands, nails, teeth, or mucosal glands). Some patients with ectodermal dysplasia also have features of mucous membrane pemphigoid with mucosal anti-BMZ BP-180 autoantibodies and severe bilateral cicatrizing conjunctivitis with blindness. Craniofacial reconstruction and dental implants can improve quality of life for patients with ectodermal dysplasia, but the failure rate of dental implants is high in this population.

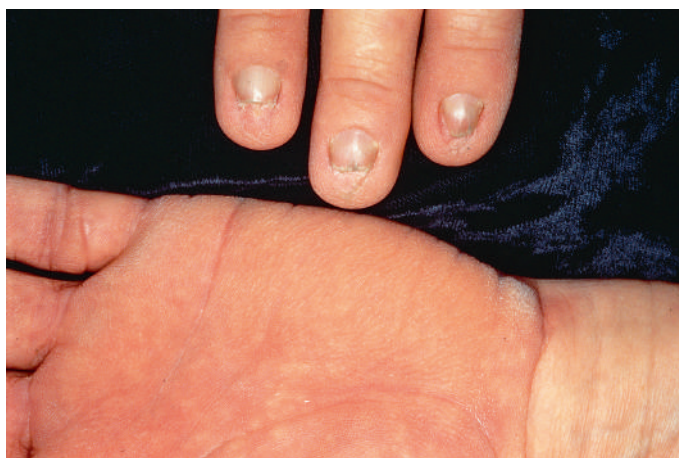### Hypohidrotic ectodermal dysplasia (anhidrotic ectodermal dysplasia, Christ-Siemens-Touraine syndrome)

The classic triad of this disorder consists of hypotrichosis, anodontia, and hypohidrosis or anhidrosis. Febrile seizures may occur in childhood. Biopsy confirms that eccrine glands are absent or rudimentary. Prenatal skin biopsy may be diagnostic.

Patients with the disorder have facies suggestive of congenital syphilis. The cheekbones are high and wide, whereas the lower half of the face is narrow. The supraorbital ridges are prominent, and the nasal bridge is depressed, forming a saddle nose. The tip of the nose is small and upturned, and the nostrils are large and conspicuous. The eyebrows are scanty, and the eyes slant upward. The lips are thickened, with the upper lip particularly protrusive. At the buccal commissures, there may be radiating furrows (pseudorhagades), and on the cheeks there may be telangiectases. Sebaceous gland hyperplasia may be noted on the cheeks and forehead. Absence of mammary glands and nipples has been reported.

Generalized hypotrichosis is present with thin, sparse hair on the scalp. The skin is soft, thin, dry, and smooth. There is partial or total anodontia, and nails may be thinned, brittle, and ridged. The teeth may be conical in shape. Mental retardation has been reported but may be a consequence of hyperthermic episodes in childhood.

The inheritance pattern is almost always X-linked recessive. Three genes, ectodysplasin (*EDA1*), EDA-receptor (*EDAR*), and EDAR-associated death domain (*EDARADD*), have been described. All are involved in nuclear factor (NF)- $\kappa$ B activation. Female carriers may have segmental expression that can be demonstrated with a starch iodide test for sweating. Both autosomal recessive and dominant modes of inheritance have



**Fig. 27-36** Hidrotic ectodermal dysplasia.

been described. The gene for autosomal dominant hypohidrotic ectodermal dysplasia has been mapped to 2q11–q13.

X-linked anhidrotic ectodermal dysplasia with immunodeficiency is caused by mutations in the gene encoding NF- $\kappa$ B modulator, *NEMO*, or inhibitor of  $\kappa$ B kinase (*IKK- $\gamma$* ). Stop codon mutations are associated with a severe phenotype with associated osteopetrosis and lymphedema. Patients may demonstrate an impaired antibody response to polysaccharides, hypogammaglobulinemia, hyper-IgM syndrome, impaired natural killer cell cytotoxicity, and various associated autoimmune diseases.

### Hidrotic ectodermal dysplasia

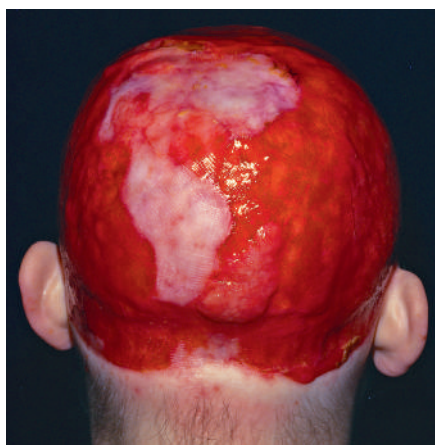The hidrotic type of congenital ectodermal dysplasia is often referred to as Clouston syndrome. Inheritance is autosomal dominant. Eccrine sweat glands function normally, and facial features are normal. Alopecia, nail dystrophy, palmoplantar hyperkeratosis (Fig. 27-36), and eye changes, such as cataracts and strabismus, are seen. Some patients have features resembling pachyonychia congenita. Widespread poromas and palmoplantar syringofibroadenomas have been described. The defective gene has been identified as *GJB6*, encoding the gap junction protein connexin 30 on the pericentromeric region of chromosome 13q (13q11–q12.1).

### AEC syndrome (Hay-Wells syndrome)

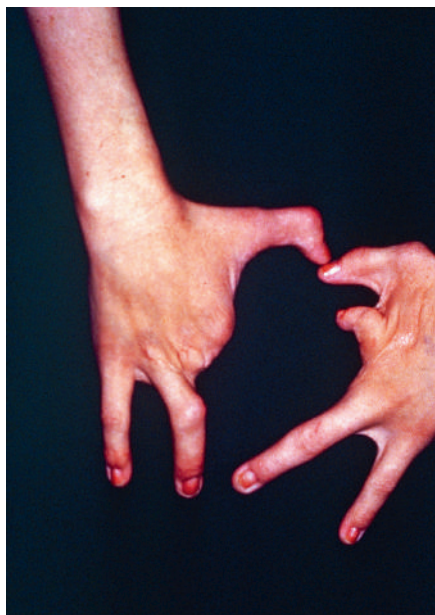Ankyloblepharon (fusion or partial fusion of the lids), ectodermal defects, and cleft lip and/or palate constitute the AEC syndrome. It has an autosomal dominant pattern of inheritance. Ankyloblepharon may be present at birth. Sparse hair, dental defects, cleft palate and lip, dystrophic nails, hypospadias, syndactyly, absent lacrimal puncta, stenotic auditory canals, and short stature may be present. An erosive scalp dermatitis is more likely to be observed in AEC than in other ectodermal disorders and occurs at an early age. The scalp dermatitis is often extensive and difficult to treat, and it persists or recurs (Fig. 27-37). Low-frequency ultrasound has been successful in treating scalp wounds unresponsive to other measures. AEC syndrome is associated with mutations in the *p63* gene.

### EEC syndrome

Ectodermal dysplasia, ectrodactyly, and cleft lip/palate are defining features of EEC syndrome. The EEC patient lacks



**Fig. 27-37** AEC syndrome with scalp dermatitis.



**Fig. 27-38** Ectrodactyly in EEC syndrome.

scalp dermatitis but has mild hypohidrosis, and ectrodactyly (congenital absence of all or part of a digit) is a prominent feature (Fig. 27-38). Folliculitis with scarring may be noted during puberty, and ocular keratitis can be a prominent feature. As with the AEC syndrome, EEC syndrome is associated with mutations in the *p63* gene.

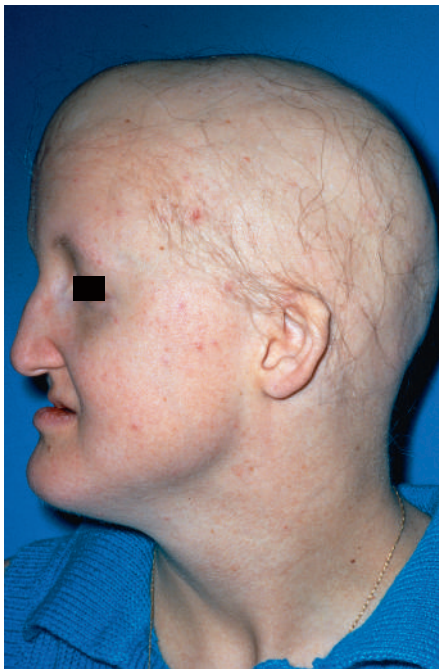
### Rapp-Hodgkin ectodermal dysplasia syndrome

Characteristic features of Rapp-Hodgkin ectodermal dysplasia syndrome include anomalies of hair (pili torti, pili canaliculi, alopecia, erosive folliculitis, thinning of eyebrows/lashes), cleft lip/palate, onychodysplasia, dental caries, hypodontia, craniofacial abnormality (Fig. 27-39), hypohidrosis, otitis media (hearing deficits), and hypospadias. It is usually inherited in an autosomal dominant manner. The syndrome is allelic to AEC and EEC, with *p63* mutations demonstrated in all three syndromes.

### Ectodermal dysplasia with corkscrew hairs

Abramovits-Ackerman et al. described this disorder in 27 patients from seven families living on Margarita Island, north-east of Venezuela. Salient features include corkscrew hairs (exaggerated pili torti), scalp keloids, follicular plugging,





**Fig. 27-39** Rapp-Hodgkin syndrome.

keratosis pilaris, xerosis, eczema, palmoplantar keratoderma, syndactyly, onychodysplasia, and conjunctival neovascularization. Typical facies, anteverted pinnae, malar hypoplasia, cleft lip/palate, and dental abnormalities may also be found. Inheritance is autosomal recessive. Anhidrosis and hypohidrosis are not features.

### Odonto-tricho-ungual-digital-palmar syndrome

First described by Mendoza et al., the salient clinical features are natal teeth, trichodystrophy, prominent interdigital folds, simianlike hands with transverse palmar creases, and unguial digital dystrophy, inherited as an autosomal dominant trait. Hypoplasia of the first metacarpal and metatarsal bones and distal phalanges of the toes may also occur.

### Lenz-Majewski syndrome

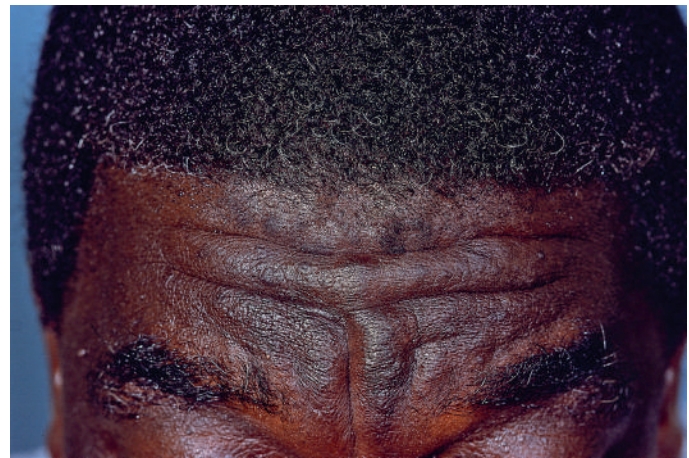Lenz-Majewski syndrome is characterized by hyperostosis, craniodiaphyseal dysplasia, dwarfism, cutis laxa, proximal symphalangism, syndactyly, brachydactyly, mental retardation, enamel hypoplasia, and hypertelorism.

### CHIME syndrome

The CHIME syndrome, a rare neuroectodermal disorder, comprises colobomas of the eye, heart defects, ichthyosiform dermatosis, mental retardation, and ear defects. Other features may include facial anomalies, epidermal nevi, developmental delay, infantile macrostomia, recurrent infections, acute lymphoblastic leukemia, and duplicated renal collecting system. The inheritance is believed to be autosomal recessive, related to mutations in the glycosylphosphatidylinositol gene *PIGL*.

### Lelis syndrome

The Lelis syndrome is a form of ectodermal dysplasia with acanthosis nigricans, palmoplantar hyperkeratosis, hypotri-



**Fig. 27-40** Pachydermoperiostosis.

chosis, hypohidrosis, nail dystrophy, early loss of adult teeth, and mental retardation.

### Nectinopathies

Cleft lip/palate—ectodermal dysplasia and ectodermal dysplasia-syndactyly syndrome are caused by recessive mutations in the *PVRL1* and *PVRL4* genes, respectively. These genes encode nectins 1 and 4, which act in cooperation with cadherins to promote cellular adhesion.

**Brancati F, et al:** Nectinopathies: an emerging group of ectodermal dysplasia syndromes. *G Ital Dermatol Venereol* 2013; 148(1):59–64.

**Felipe AF, et al:** Corneal changes in ectrodactyly-ectodermal dysplasia-cleft lip and palate syndrome: case series and literature review. *Int Ophthalmol* 2012; 32(5):475–480.

**Kawai T, et al:** Diagnosis and treatment in anhidrotic ectodermal dysplasia with immunodeficiency. *Allergol Int* 2012; 61(2):207–217.

**Knaudt B, et al:** Skin symptoms in four ectodermal dysplasia syndromes including two case reports of Rapp-Hodgkin syndrome. *Eur J Dermatol* 2012; 22(5):605–613.

**Ng BG, et al:** Mutations in the glycosylphosphatidylinositol gene *PIGL* cause CHIME syndrome. *Am J Hum Genet* 2012; 90(4):685–688.

### PACHYDERMOPERIOSTOSIS (IDIOPATHIC HYPERTROPHIC OSTEOARTHROPATHY, TOURAINE-SOLENTE-GOLE SYNDROME)

Pachydermoperiostosis is characterized by thickening of the skin in folds and accentuation of creases on the face and scalp, clubbing of the fingers, and periostosis of the long bones. The changes are especially prominent on the forehead, where the horizontal lines are deepened and the skin becomes shiny (Fig. 27-40). The eyelids, particularly the upper lids, are thickened. Likewise, there is thickening of the ears and lips, and the tongue is enlarged. The scalp may be thickened and may show cutis verticis gyrata (pachydermie vorticelle). The extremities, especially the elbows, knees, and hands, are enlarged and spade shaped. The fingers become club shaped. The palms are rough, and the thenar and hypothenar eminences are enlarged. Hyperhidrosis is common. Hyperkeratotic linear lesions of the palms and soles may be present. These lines are rippled, resembling sand of the “wind-blown desert.” Movements of the muscles may be painful. An association with gynecomastia and osteoporosis has been described.

There are inherited and acquired forms of pachydermoperiostosis. The acquired form may occur with chronic pulmonary,

mediastinal, and cardiac diseases that are associated with chronic hypoxia in peripheral tissues. Some cases have been associated with bronchogenic carcinoma. When such an association occurs, enlargement of the forehead, hands, and fingers may antedate recognition of the tumor or may develop after the tumor is identified as present. Bronchogenic carcinoma-associated pachydermoperiostosis occurs almost exclusively in men over age 40, whereas inherited Touraine-Solente-Gole syndrome usually occurs as an autosomal dominant disorder with onset in late adolescence. It is not associated with malignant disease. More prominent signs are seen in males. Autosomal recessive inheritance with cleft palate and congenital heart defects has been described. Frontal rhytidectomy has been used to treat associated leonine facies, and bone manifestations have shown some response to oral bisphosphonate therapy and arthroscopic synovectomy. *HPGD* gene mutations affecting 15-hydroxyprostaglandin dehydrogenase (15-PGDH) and mutations in the prostaglandin transporter gene *SLCO2A1* have been described.

### CUTIS VERTICIS GYRATA

Cutis verticis gyrata is characterized by folds and furrows on the scalp, usually in an anteroposterior direction. Most frequently, the vertex is involved, but other areas may have the distinctive furrowing. There may be 2–20 folds. The hair itself is normal.

Cutis verticis gyrata has been reported primarily in males, with a male/female ratio of 6:1. Onset is usually at puberty, with more than 90% of patients developing it before age 30. The condition may be familial when it occurs as a component of pachydermoperiostosis. It has been reported to result from developmental anomalies, inflammation, trauma, tumors, nevi, amyloidosis, syphilis, myxedema, Ehlers-Danlos syndrome, Turner syndrome, Klinefelter syndrome, fragile X syndrome, vemurafenib, and the insulin resistance syndrome. Biopsy findings can be normal or may show thick collagen bundles and hypertrophy of adnexal structures.

Cutis verticis gyrata is frequently found in patients with mental retardation, seizures, and schizophrenia. Rarely, a cerebriform intradermal nevus may be mistaken for this disorder. In severely involved cases, excision with grafting or scalp reduction may be indicated. Surgical excision has been used successfully to improve facial involvement.

**George L, et al:** Frontal rhytidectomy as surgical treatment for pachydermoperiostosis: a case report. *J Dermatolog Treat* 2008; 19(1):61–63.

**Harding JJ, et al:** Cutis verticis gyrata in association with vemurafenib and whole-brain radiotherapy. *J Clin Oncol* 2014; 32:e54–56.

**Sasaki T, et al:** Identification of mutations in the prostaglandin transporter gene *SLCO2A1* and its phenotype-genotype correlation in Japanese patients with pachydermoperiostosis. *J Dermatol Sci* 2012; 68(1):36–44.

**Taha HM, Orlando A:** Butterfly-shape scalp excision: a single stage surgical technique for cutis verticis gyrata. *J Plast Reconstr Aesthet Surg* 2014; 67:1747–1749.

### APLASIA CUTIS CONGENITA

Aplasia cutis congenita has a predilection for the midline of the vertex of the scalp. It presents with localized absence of skin and is rarely associated with full-thickness defects of the cranium. An association with thyroid disease and thyroid medications has been noted. Rarely, multiple symmetric defects may occur in the skin of the lower extremities. Distal radial epiphyseal dysplasia has been associated with localized aplasia cutis congenita.

The “hair collar sign” refers to a ring of long, dark hair encircling the lesion. It is often seen with membranous aplasia cutis, which may represent a forme fruste of a neural tube defect. Bullous aplasia cutis congenita demonstrates a fibrovascular or edematous stroma similar to that seen in encephalocoeles and meningoceles, suggesting it may also be related to a neural tube defect. Focal preauricular dermal dysplasia is a form of aplasia cutis congenita not typically associated with any extracutaneous anomalies. The SCALP syndrome is a nevus sebaceous syndrome with CNS malformations, aplasia cutis congenita, limbal dermoid, and a giant congenital pigmented melanocytic nevus with neurocutaneous melanosis.

### ADAMS-OLIVER SYNDROME

Features of Adams-Oliver syndrome include severe aplasia cutis congenita of the scalp, which may involve both skin and skull ossification defects, limb defects (brachydactyly, syndactyly of toes two and three, and hypoplastic toenails), extensive cutis marmorata telangiectatica congenita, cryptorchidism, and cardiac abnormalities, including dilated cardiomyopathy and heart block. Other associations include hemangiomas, retrognathia and micrognathia, strabismus, and atrial septal defect. Adams-Oliver is a rare, autosomal dominant inherited neuroectodermal syndrome.

**Atasoy HI, et al:** Unique variant of Adams-Oliver syndrome with dilated cardiomyopathy and heart block. *Pediatr Int* 2013; 55(4):508–512.

**Bakry O, et al:** Adams-Oliver syndrome: a case with isolated aplasia cutis congenita and skeletal defects. *J Dermatol Case Rep* 2012; 6(1):25–28.

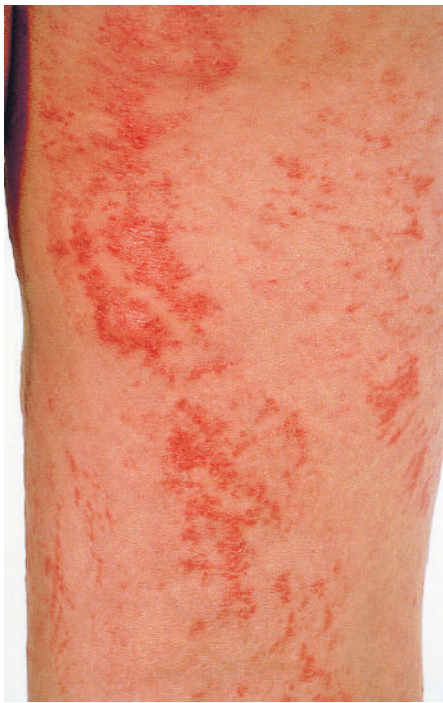**Lam J, et al:** SCALP syndrome: sebaceous nevus syndrome, CNS malformations, aplasia cutis congenita, limbal dermoid, and pigmented nevus (giant congenital melanocytic nevus) with neurocutaneous melanosis: a distinct syndromic entity. *J Am Acad Dermatol* 2008; 58(5):884–888.

### FOCAL DERMAL HYPOPLASIA (GOLTZ SYNDROME)

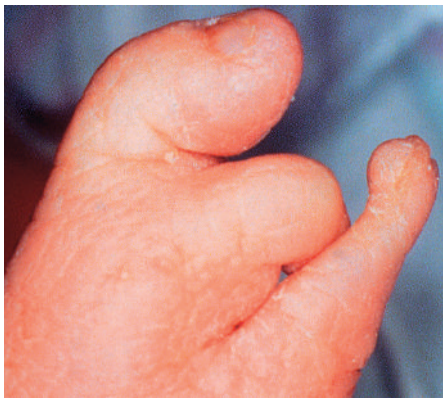Goltz syndrome is an X-linked dominant disorder characterized by malformations affecting the skin, eyes, CNS, and skeleton. Goltz syndrome is related to defects in *PORCN*, a regulator of Wnt signaling. The large majority of patients with Goltz syndrome have been female, with lethality in most male offspring. Females are protected by X-chromosome mosaicism, identical to the situation in incontinentia pigmenti. Reddish tan, atrophic, often linear or cribriform patches are frequently present on the buttocks, axillae, and thighs (Fig. 27-41). Later, lipocytes accumulate in the lesions in a nevoid fashion, resulting in yellowish brown nodules. The lesions are strikingly linear and often serpiginous, following lines of Blaschko. They are often narrower than typical Blaschko segments, suggesting that the genetic defect is lethal in many of the affected cells during development. Telangiectases are often present, and segmental presentations have been described. Papillomas may occur around the orifices of the mouth, anus, and vulva. They may be misdiagnosed as condylomata acuminata. An early inflammatory vesicular stage has been described, along with cleft lip and palate. About 80% of patients have skeletal defects. Bone changes most often involve the extremities, where there may be syndactyly, oligodactyly, and adactyly (Fig. 27-42). Scoliosis, spina bifida, and hypoplasia of the clavicle have also been reported. From 40% to 50% of patients have ocular or dental abnormalities, with coloboma being the most common ocular defect.

Van Allen-Myhre syndrome appears to represent a severe form of Goltz syndrome with split-foot and split-hand anomalies. MIDAS syndrome (microphthalmia, dermal aplasia, and





**Fig. 27-41** Goltz syndrome.



**Fig. 27-42** Goltz syndrome.

sclerocornea) is also an X-linked phenotype, but distinct from Goltz syndrome. It has been mapped to Xp22.3. Patients have bilateral microphthalmia with blepharophimosis and linear dermal aplasia, often involving the face.

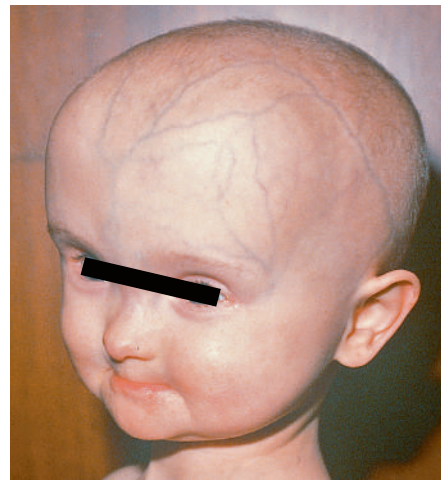Treatment of atrophic erythematous patches has been successful using a flashlamp-pumped pulsed dye laser.

**Asano M, et al:** A case of almost unilateral focal dermal hypoplasia resulting from a novel mutation in the *PORCN* gene. *Acta Derm Venereol* 2013; 93(1):120–121.

**Stevenson DA, et al:** Goltz syndrome and *PORCN* mosaicism. *Int J Dermatol* 2014; 12:1481–1484.

## WERNER SYNDROME (ADULT PROGERIA)

Werner syndrome is an autosomal recessive, premature aging syndrome characterized by many metabolic and structural abnormalities involving the skin, hair, eyes, muscles, fatty tissues, bones, blood vessels, and carbohydrate metabolism. Cells demonstrate genomic instability. Because most of these signs are not fully manifested before age 30, the diagnosis is usually made in middle age. These patients usually die before age 50 from malignant disease or vascular accidents.



**Fig. 27-43** Progeria.

The most characteristic findings are premature aging and arrest of growth at puberty, senile cataracts developing in the late twenties and thirties, premature balding and graying, and scleroderma-like lesions of the skin. A characteristic change is the loss of subcutaneous tissue and wasting of muscles, especially the extremities, so that the legs become spindly and the trunk becomes stocky. Osteoporosis and aseptic necrosis are frequently found in the small bones of the hands. The skin changes include poikiloderma, scleroderma, atrophy, hyperkeratoses, and leg ulcers. The skin has a diffuse, dark-gray or blackish pigmentation. A high-pitched voice and hypogonadism in both genders are distinctive in Werner syndrome.

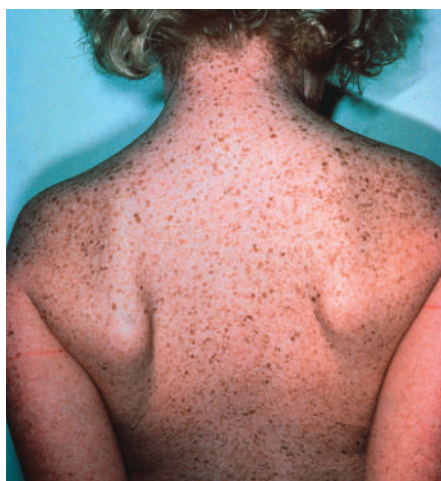Painful callosities with ulcerations may occur around the malleoli, Achilles tendons, heels, and toes. The hair thins on the eyebrows, axillae, and pubis. The skin over the cheekbones becomes taut, producing proptosis and beaking of the nose. Cataracts develop early, and the vocal cords become thickened, leading to a weak, high-pitched voice. Premature arteriosclerosis and sexual impotence are frequently observed. Diabetes is common, and areas of calcinosis circumscripta occur. Gene expression mimics normal aging.

A high rate of malignancy is associated with Werner syndrome, including a 50-fold increase in melanoma. Thyroid adenocarcinoma, hepatoma, meningioma, leukemia, carcinoma of the breast, fibrosarcoma, and a variety of sarcomas have been reported. Histologic changes in the skin may include atrophy of the epidermis and fibrosis of the dermis.

Werner syndrome is molecularly heterogeneous. The Werner protein confers adhesive properties to macromolecular proteins and is required for genomic stability. It belongs to the RecQ family of DNA helicases and appears to play a role in telomere maintenance, homologous recombination, and DNA repair. Mutant LMNA encoding nuclear lamin A/C is associated with atypical Werner syndrome with a severer phenotype. Mutations in LMNA also cause Hutchinson-Gilford progeria, Emery-Dreifuss muscular dystrophy, and dilated cardiomyopathy.

## PROGERIA (HUTCHINSON-GILFORD SYNDROME)

Progeria, or Hutchinson-Gilford syndrome, is characterized by accelerated aging, dwarfism, alopecia, generalized atrophy of the skin and muscles, enlarged head with prominent scalp veins, and a high incidence of generalized atherosclerosis, usually fatal by the second decade of life. The large, bald head and lack of eyebrows and eyelashes are distinctive (Fig. 27-43). The skin is wrinkled, pigmented, and atrophic. The nails are thin and atrophic. Most patients lack subcutaneous fat, which



**Fig. 27-44** Xeroderma pigmentosum. (Courtesy of Dr. Ken Kraemer.)

produces the appearance of premature senility. There are usually sclerodermatous plaques on the extremities. The intelligence remains intact. Arteriosclerosis, anginal attacks, and hemiplegia may occur, followed by death from coronary heart disease at an early age. Mutations in LMNA and mosaicism have been identified. Treatment is symptomatic, mainly control of diabetes mellitus and treatment of leg ulcerations.

**Coppedè F:** The epidemiology of premature aging and associated comorbidities. *Clin Interv Aging* 2013; 8:1023–1032.

**Goto M, et al:** Werner syndrome: a changing pattern of clinical manifestations in Japan (1917–2008). *Biosci Trends* 2013; 7(1):13–22.

**Kalinowski A, et al:** Interfacial binding and aggregation of lamin A tail domains associated with Hutchinson-Gilford progeria syndrome. *Biophys Chem* 2014; 195:43–48.

**Lauper JM, et al:** Spectrum and risk of neoplasia in Werner syndrome: a systematic review. *PLoS One* 2013; 8(4):e59709.

## XERODERMA PIGMENTOSUM

Xeroderma pigmentosum is an autosomal recessive disorder characterized by defective DNA thymidine dimer excision repair, extreme sun sensitivity, freckling, and skin cancer. Sun sensitivity and lentigines are early skin findings (Fig. 27-44), with median onset before age 2 years. Skin cancers often appear before age 10, and an increase in internal cancer has been noted as well. NIH data suggest a 10,000-fold increase in skin cancer before age 20. In a study of 830 patients, 45% had basal cell carcinoma or SCC, and melanoma was noted in 5%. Most of the tumors occur on the head and neck. Ocular abnormalities were found in 40% and included ectropion, corneal opacity, and neoplasms. Progressive neurologic degeneration is seen in about 20% of patients. Xeroderma pigmentosum patients in complementation group C remain free of neurologic problems. Complementation groups are defined by correction of excision repair when fibroblasts from patients in different groups are fused. A variant type with normal excision repair has also been described. Retinoids can prevent the appearance of new cancers, but side effects are significant, and a rebound in the number of cancers occurs when the drug is stopped, suggesting that the tumors are merely suppressed. Photoprotection remains essential for management. Individual tumors may be excised or destroyed with cryotherapy. Some may be treated with topical imiquimod or 5-FU. Topical application of recombinant liposomal encapsulated T4 endonuclease V repairs UV-induced cyclobutane-pyrimidine dimers and is a promising form of therapy. Gene therapy is also being pursued. Guidelines for evaluation and management from the XP Society can be found at [www.xps.org](http://www.xps.org). A

publication from the National Institutes of Health can be found at [www.cc.nih.gov/ccc/patient\\_education/pepubs/xp7\\_17.pdf](http://www.cc.nih.gov/ccc/patient_education/pepubs/xp7_17.pdf).

Xeroderma pigmentosum, Cockayne syndrome, and trichothiodystrophy are all associated with defects in nucleotide excision repair (NER). Global genome NER repairs DNA lesions throughout the genome, preventing the accumulation of mutations. Transcription-coupled NER prevents cell death caused by stalled transcription by rapidly identifying and repairing defects in the transcribed strand of DNA. Skin tumors in xeroderma pigmentosum patients have sunlight-induced mutations in *RAS*, *p53*, and *PTCH* genes. Mutations in the *XPG* gene give rise to the complementation group G form of xeroderma pigmentosum, as well as early-onset Cockayne syndrome. Prenatal diagnosis is possible with cultured chorionic villus cells or amniocytes.

The De Sanctis-Cacchione syndrome consists of xeroderma pigmentosum with mental deficiency, dwarfism, and gonadal hypoplasia. It occurs most often in patients in complementation group D. Mutations in the *ERCC6* gene, which also cause Cockayne syndrome type B, have been demonstrated as well.

## COCKAYNE SYNDROME

Cockayne syndrome is an autosomal recessive syndrome with sun sensitivity and neurologic degeneration related to mutations in five genes (*CSA*, *CSB*, *XPB*, *XPD*, and *XPG*) encoding for proteins involved in the transcription-coupled subpathway of nucleotide excision DNA repair. It differs from xeroderma pigmentosum in the lack of freckling and skin cancer and in the presence of dwarfism, beaked nose, loss of subcutaneous tissue, deafness, basal ganglia calcification, failure of brain growth, and retinopathy.

Cockayne described the syndrome as dwarfism with retinal atrophy and deafness. Dermatologic features include photodermatitis with telangiectasia, atrophy, and scarring. The hands and feet are large and cyanotic. Microcephaly, sunken eyes, severe flexion contractures, dorsal kyphosis, cryptorchidism, cataracts, growth retardation, mental retardation, hypothalamic and cerebellar dysfunction, and retinitis pigmentosa with optic atrophy may be seen. There is progressive neurologic disturbance with a shortened life span. Dermal fibroblasts and lymphoblastoid cell lines, as well as cultured amniotic fluid cells from an affected fetus, demonstrate impaired colony-forming ability and decreased DNA and RNA synthesis after UV light exposure (254 nm).

The DNA helicases unwind DNA and are important in DNA replication, DNA repair, and RNA transcription. Mutations in *XPB* or *XPD* DNA helicase can result in xeroderma pigmentosum, Cockayne syndrome, or trichothiodystrophy. The Cockayne syndrome complementation group A (*CSA*) and *CSB* genes responsible for the syndrome are associated with RNA polymerase. *CSB* protein plays a role in transcription as well as global NER. Cockayne syndrome has also been associated with mutations in *XPG*.

## XERODERMA PIGMENTOSUM/COCKAYNE SYNDROME COMPLEX

Some patients have skin features of xeroderma pigmentosum and neurologic features of Cockayne syndrome. Patients in complementation groups B, D, and G have presented with the complex. Mutations in the associated genes may give rise to clinical manifestations of xeroderma pigmentosum, Cockayne syndrome, or the xeroderma pigmentosum/Cockayne syndrome complex.



## TRICHOThIODYSTROPHY

Trichothiodystrophy is an autosomal recessive disorder characterized by photosensitivity, ichthyosis, brittle hair, intellectual impairment, decreased fertility, and short stature (PIBIDS). A review of 112 patients noted a wide spectrum of clinical features that varied from patients with only hair involvement to those with profound developmental defects. Common features included intellectual impairment (86%), short stature (73%), ichthyosis (65%), ocular abnormalities (51%), infections (46%), and photosensitivity (42%). More than half the patients had abnormal characteristics at birth, and 19 patients died before age 10.

Tay syndrome is similar to trichothiodystrophy but lacks photosensitivity. Abnormalities in NER of UV-damaged DNA are present in about 50% of Tay patients. The UV sensitivity and defective NER are similar to those of xeroderma pigmentosum patients, but these patients do not experience an increased incidence of skin cancer. Two of the three described complementation groups match xeroderma pigmentosum groups B and D, with the *XPD* gene accounting for most photosensitive trichothiodystrophy. A combined xeroderma pigmentosum/trichothiodystrophy complex has been described. Patients with trichothiodystrophy without xeroderma pigmentosum do not have an increase in skin cancer formation.

The hair, with sulfur reduced to 50% of the normal value, has distinctive features under polarizing and light microscopy and scanning EM. With light microscopy, keratin orientation alternates in a Z pattern. With polarizing microscopy, the hair shows alternating bright and dark regions that give a striking striped, or tiger tail, appearance, but the pattern may not be evident at birth, and a similar pattern of bright and dark bands has been described in the keratitis ichthyosis deafness syndrome. Hairs demonstrate heterogeneous deficiency in sulfur, with the greatest loss in areas of trichoschisis (clean fractures). Trichorrhhexis nodosa-like fractures may also be seen. In addition, the hair is extremely flattened and folds over itself like a thick ribbon. The hair shaft outline is irregular and slightly undulating, and the melanin granules are distributed in a wavy pattern. With scanning EM, the surface shows marked ridging and fluting, and the cuticle scales may be absent or greatly reduced.

**Aamann MD, et al:** Cockayne Syndrome group B protein stimulates NEIL2 DNA glycosylase activity. *Mech Ageing Dev* 2014; 135:1–14.

**DiGiovanna JJ, et al:** Shining a light on xeroderma pigmentosum. *J Invest Dermatol* 2012; 132(3 Pt 2):785–796.

**Ferrando J, et al:** Further insights in trichothiodystrophy: a clinical, microscopic, and ultrastructural study of 20 cases and literature review. *Int J Trichology* 2012; 4(3):158–163.

**Grossberg AL:** Update on pediatric photosensitivity disorders. *Curr Opin Pediatr* 2013; 25(4):474–479.

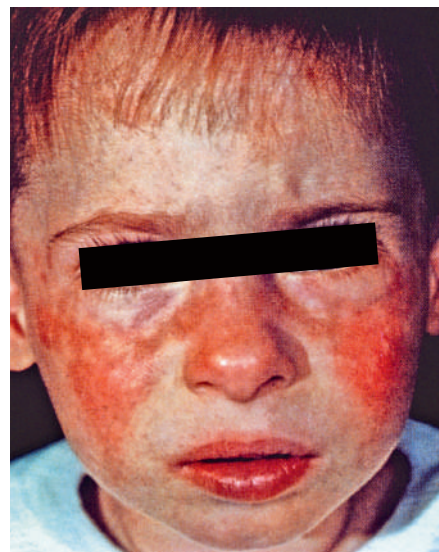**Lanzafame M, et al:** From laboratory tests to functional characterisation of Cockayne syndrome. *Mech Ageing Dev* 2013; 134(5-6):171–179.

**Lehmann AR, et al:** Xeroderma pigmentosum. *Orphanet J Rare Dis* 2011; 6:70.

**Niedernhofer LJ, et al:** Xeroderma pigmentosum and other diseases of human premature aging and DNA repair: molecules to patients. *Mech Ageing Dev* 2011; 132(6-7):340–347.

## BLOOM SYNDROME (BLOOM-TORRE-MACHACEK SYNDROME)

Bloom syndrome is transmitted as an autosomal recessive trait, chiefly among Jewish persons of Eastern European origin. It is characterized by photosensitive telangiectatic erythema in the butterfly area of the face and dwarfism. Telangiectatic



**Fig. 27-45** Bloom syndrome.

erythematous patches resembling lupus erythematosus develop in the first 2 years of life (Fig. 27-45). Bullous, crusted lesions may be present on the lips. Exacerbation of skin lesions occurs during the summer. Other changes that may be noted are café au lait spots, ichthyosis, acanthosis nigricans, syndactyly, irregular dentition, lens opacities, prominent ears, hypospadias, and cryptorchidism. The stunted growth is characterized by normal body proportions, no endocrine abnormalities (except diabetes mellitus), and low birth weight at full term. Dolichocephaly and narrow, delicate facies are present. Immune functions are abnormal, and GI and respiratory infections often occur. Cancer of all cell types and sites is increased in frequency. Leukemia, lymphoma, adenocarcinoma of the sigmoid colon, and oral and esophageal SCC, as well as other malignancies, have been associated with Bloom syndrome. About one quarter of patients under age 20 develop a neoplasm. Regular use of a broad-spectrum sunscreen, as well as photoprotection, is recommended. Testing for Bloom syndrome should be performed in children with consanguineous parents and dysmorphic features, because growth hormone treatment is contraindicated in these patients.

The gene mutated in Bloom syndrome, *BLM*, codes for a RecQ DNA helicase. *BLM* is localized to the nuclear bodies and the nucleolus and is critical for genomic stability. *BLM* interacts with *WRN*, the DNA helicase mutated in Werner syndrome, and is part of a large *BRCA-1*-containing complex containing DNA repair factors. *BLM* expression is highest during the S and G2 phases of the cell cycle. *BLM* associates with telomeres and ribosomal DNA. *BLM* interacts directly with *ATM*, the protein product of the gene mutated in ataxia-telangiectasia, and together they recognize abnormal DNA structures.

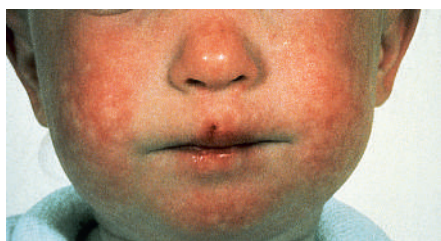**Park CJ, et al:** Solution structure of the RecQ C-terminal domain of human Bloom syndrome protein. *J Biomol NMR* 2014; 58(2):141–147.

**Renes JS, et al:** Bloom syndrome in short children born small for gestational age: a challenging diagnosis. *J Clin Endocrinol Metab* 2013; 98(10):3932–3938.

**Thomas ER, et al:** Surveillance and treatment of malignancy in Bloom syndrome. *Clin Oncol (R Coll Radiol)* 2008; 20(5):375–379.

## ROTHMUND-THOMSON SYNDROME (POIKILODERMA CONGENITALE)

Rothmund-Thomson syndrome is a rare autosomal recessive disorder. Poikiloderma begins at 3–6 months of age, with



**Fig. 27-46** Rothmund-Thomson syndrome.

tense, pink, edematous patches on the cheeks, hands, feet, and buttocks, sparing the chest, back, and abdomen (acute phase). Sensitivity to sunlight may be manifested by the development of bullae or intense erythema after brief sun exposure. This is followed by fine, reticulated or punctate atrophy associated with telangiectasia and reticulated pigmentation (chronic phase) (Fig. 27-46). Characteristically, the arms and legs are affected, with sparing of the antecubital and popliteal fossae. The skin lesions are characteristic. Otherwise, patients with Rothmund-Thomson syndrome may have a broad range of noncutaneous lesions. Short stature (two thirds of patients), small hands with radial ray defects, saddle nose, absence or sparseness of eyebrows and eyelashes (73%), alopecia of the scalp (50%), and numerous bone defects (75%) are often observed. Hypogonadism, dystrophic nails, and defective dentition are seen in a significant proportion of patients (25–60%). Cataracts occur in a small percentage of patients in childhood or young adult life, and glomerulonephritis has been reported. Associated cutaneous neoplasms include SCC, Bowen's disease, basal cell carcinoma, and melanoma, but the risk for osteosarcoma of bone is particularly high (>30%). The syndrome is related to biallelic mutations of the *RECQL4* gene. Thus, at least a subset of patients with Rothmund-Thomson syndrome has abnormal DNA helicase activity, as do patients with Werner and Bloom syndromes.

**Canger EM, et al:** Oral findings of Rothmund-Thomson syndrome. *Case Rep Dent* 2013; 2013:935716.

**Manavi S, Mahajan VK:** Rothmund-Thomson syndrome. *Indian Dermatol Online J* 2014; 5:518–519.

## HEREDITARY SCLEROSING POIKILODERMA AND MANDIBULOACRAL DYSPLASIA

Hereditary sclerosing poikiloderma is an autosomal dominant condition. The skin changes consist of generalized poikiloderma appearing in childhood (but not at birth), with hyperkeratotic and sclerotic cutaneous bands extending across the antecubital spaces, axillary vaults, and popliteal fossae. In addition, the palms and soles may show sclerosis resembling shiny scotch-grain leather. Aortic stenosis, clubbing of the fingers, and localized calcinosis of the skin have also been noted. There is no treatment. The cases described by Weary were subsequently reported later in life as mandibuloacral dysplasia, a rare autosomal recessive syndrome characterized by mandibular hypoplasia, delayed cranial suture closure, dysplastic clavicles, abbreviated club-shaped terminal phalanges, myopathy, lipodystrophy, acro-osteolysis, atrophy of the skin of the hands and feet, and typical facial changes. Mandibuloacral dysplasia must be distinguished from progeria and Werner syndrome.

A distinct subtype has been described in two generations of a South African family. The characteristics included poikiloderma, tendon contracture, and pulmonary fibrosis, with apparent autosomal dominant inheritance. Sparse, fine hairs are present on the scalp, face, and body.

**Khumalo NP, et al:** Poikiloderma, tendon contracture and pulmonary fibrosis: a new autosomal dominant syndrome? *Br J Dermatol* 2006; 155(5):1057–1061.

**Lombardi F, et al:** Compound heterozygosity for mutations in LMNA in a patient with a myopathic and lipodystrophic mandibuloacral dysplasia type A phenotype. *J Clin Endocrinol Metab* 2007; 92(11):4467–4471.

## SCLEROATROPHIC SYNDROME OF HURIEZ

Huriez syndrome, a very rare autosomal dominant disorder, is characterized by the following:

1. Scleroatrophy of the hands, with sclerodactyly
2. Ridging, clubbing, or hypoplasia of the nails
3. Lamellar keratoderma of the hands and, to a lesser extent, the soles

Patients with Huriez syndrome may also have multiple telangiectasias of the lips and face and flexion contractures of the little finger. Aggressive SCCs occur in the scleroatrophic skin, including that of the palms and soles (13% lifetime risk, 5% mortality in affected persons). Affected patients have reduced Langerhans cells in affected skin, but normal dermal dendritic cells.

## FRANCESCHETTI-KLEIN SYNDROME (MANDIBULOFACIAL DYSOSTOSIS)

This syndrome includes palpebral antimongoloid fissures, hypoplasia of the facial bones, macrostomia, vaulted palate, malformations of both the external and internal ear, buccal-auricular fistula, abnormal development of the neck with stretching of the cheeks, accessory facial fissures, and skeletal deformities. Patients who have the complete syndrome usually die in infancy, but patients with the abortive type may live to an old age. Franceschetti-Klein syndrome is allelic to the Treacher Collins syndrome and caused by the Treacher Collins-Franceschetti (*TCOF1*) gene.

## TREACHER COLLINS SYNDROME

Treacher Collins syndrome includes midface hypoplasia with micrognathia, microtia, conductive hearing loss, and cleft palate. It is inherited as an autosomal dominant trait and caused by mutations in the *TCOF1* gene, which encodes a protein called treacle.

## OCULOauriculofrontonasal SYNDROME

This syndrome is sporadic in nature, although autosomal recessive inheritance has been suggested by some authors. Features include hemifacial microsomia, microtia, ocular hypertelorism, upper palpebral colobomata, preauricular tags, lateral face clefting, and nasal clefting.

## POPLITEAL PTERYGIUM SYNDROME

Pterygia or skinfolds may extend from the thigh down to the heel and thus prevent extension or rotation of the legs. Crural pterygia, cryptorchidism, bifid scrotum, agenesis of the labia majora, cleft lip and palate, adhesions between the eyelids, syndactyly, and talipes equinovarus may be present. Autosomal dominant inheritance has been described, and



popliteal pterygium syndrome is allelic to the van der Woude syndrome.

## VAN DER WOUDE SYNDROME

The van der Woude syndrome is an autosomal dominant craniofacial disorder characterized by hypodontia, pits of the lower lip, and cleft palate. It is associated with mutations in the *IRF6* gene. Other reported associations include natal teeth, ankyloglossia, syndactyly, equinovarus foot deformity, and congenital heart disease. Lower lip pits may be found in other congenital disorders, such as popliteal pterygium syndrome, and occasionally in orofaciogigital syndrome type I (oral frenula and clefts, hypoplasia of alae nasi, and digital asymmetry). Surgical correction is the treatment of choice.

## APERT SYNDROME (ACROCEPHALOSYNDACTYLY)

Apert syndrome is autosomal dominant inherited and is characterized by craniosynostosis and fusion of the digits (syndactyly). Patients present with synostosis of the feet, hands, carpi, tarsi, cervical vertebrae, and skull. The facial features are distorted and the second, third, and fourth fingers are fused into a bony mass with a single nail. Neurologic defects may be caused in part by brain compression by the abnormal skull. Oculocutaneous albinism and severe acne vulgaris have been reported with Apert syndrome, although some of the acneiform lesions actually represent follicular hamartomas. Mutations in the fibroblast growth factor receptor (*FGFR2*) gene are responsible for Apert, Crouzon, and Pfeiffer syndromes.

## PFEIFFER SYNDROME

Pfeiffer syndrome is autosomal dominant inherited and consists of osteochondrodysplasia and craniosynostosis. Type 1 patients have normal intelligence and generally a good outcome. Types 2 and 3 are associated with severe neurologic compromise, a poor prognosis, and sporadic occurrence. Respiratory compromise may occur as a result of tracheal stenosis and fibrous cartilaginous rings.

## CROUZON SYNDROME

Crouzon syndrome includes craniosynostosis and acanthosis nigricans. It is associated with mutations in the *FGFR2* gene. The crouzonodermoskeletal syndrome with choanal atresia and hydrocephalus is caused by mutations in *FGFR3*, a gene associated with achondroplastic dwarfism.

## CARPENTER SYNDROME

Carpenter syndrome is an acrocephalopolysyndactyly syndrome with an autosomal recessive pattern of inheritance. Patients present with craniosynostosis and acral deformities that include syndactyly.

## WHISTLING FACE SYNDROME

In this rare disorder, also known as craniocarpotarsal syndrome, Freeman-Sheldon syndrome, Windmill-Vane-Hand syndrome, and distal arthrogyposis type 2, the child appears

to be whistling all the time. This configuration is the result of microstomia, deep-set eyes, flattened midface, coloboma, contracted joint muscles of the fingers and hands, and alterations of the nostrils. Ulnar deviation of the fingers, kyphoscoliosis, and talipes equinovarus may be present. Brain anomalies have also been reported. Autosomal dominant, autosomal recessive, and sporadic variants have been reported. Prenatal diagnosis can be made on ultrasound. Surgical intervention may be required for some patients.

**Herman TE, et al:** Crouzon-dermo-skeletal syndrome, Crouzon syndrome with acanthosis nigricans syndrome. *J Perinatol* 2014; 34(2):164–165.

**Raposo-Amaral CE, et al:** Patient-reported quality of life in highest-functioning Apert and Crouzon syndromes: a comparative study. *Plast Reconstr Surg* 2014; 133(2):182e–191e.

**Roscioli T, et al:** Genotype and clinical care correlations in craniosynostosis: findings from a cohort of 630 Australian and New Zealand patients. *Am J Med Genet C Semin Med Genet* 2013; 163(4):259–270.

## OTHER SYNDROMES THAT INCLUDE HAIR ABNORMALITIES

### Hallerman-Streiff syndrome

Hallerman-Streiff syndrome includes characteristic “bird facies,” congenital cataracts, microphthalmia, mandibular hypoplasia, hypotrichosis, and dental abnormalities. The nose is thin, sharp, and hooked, and the chin is absent. The hair is diffusely sparse and brittle. Baldness may occur frontally or at the scalp margins, but sutural alopecia—hair loss following the lines of the cranial sutures—is characteristic of this syndrome. The small face is in sharp contrast with a disproportionately large-appearing head. The lips are thin; some of the teeth may be absent while others are dystrophic, resulting in malocclusion. Nystagmus, strabismus, and other ocular abnormalities occur. Cleft palate and syndactyly may be present, representing overlap with oculodentodigital dysplasia associated with *GJA1* gene mutation.

### Polyostotic fibrous dysplasia (Albright’s disease)

Polyostotic fibrous dysplasia may present as slowly progressive, lifelong unilateral hair loss (scalp, pubic, axillary, and palpebral). Sickle cell disease is often characterized by scantiness of body and facial hair.

### Cronkhite-Canada syndrome

Cronkhite-Canada syndrome is characterized by alopecia, skin pigmentation, onychodystrophy, malabsorption, and generalized GI polyposis.

### Marinesco-Sjögren syndrome

Marinesco-Sjögren syndrome consists of cerebellar ataxia, mental retardation, congenital cataracts, inability to chew food, thin brittle fingernails, and sparse hair. The dystrophic hairs do not have the normal layers (cortex, cuticle, medulla), and 30% of the hair shafts show narrow bands of abnormal, incomplete keratinization. There is an autosomal recessive type of inheritance in this syndrome, and the gene has been mapped to chromosome 5q31.

## Generalized trichoepitheliomas

Generalized trichoepitheliomas, alopecia, and myasthenia gravis may be a variant of the generalized hair follicle hamartoma syndrome. There is a report of a localized variant of this syndrome. Histologically, there is replacement of the hair follicles by trichoepithelioma-like epithelial proliferations associated with hyperplastic sebaceous glands.

## Crow-Fukase (POEMS) syndrome

This acquired syndrome is characterized by polyneuropathy, organomegaly, endocrinopathy, M-protein, and skin changes (POEMS) such as diffuse hyperpigmentation, dependent edema, skin thickening, hyperhidrosis, and hypertrichosis.

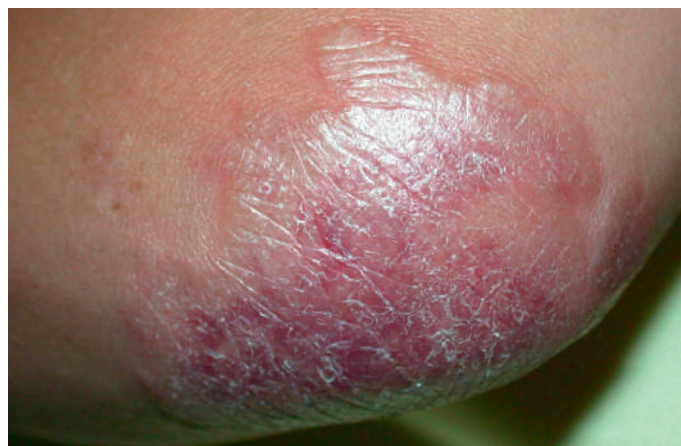## Cartilage-hair hypoplasia (McKusick-type metaphyseal chondrodysplasia)

Cartilage-hair hypoplasia encompasses short-limbed dwarfism and abnormally fine and sparse hair in children. These children are especially susceptible to viral infections and recurrent respiratory infections. A high incidence of non-Hodgkin lymphoma, leukemia, SCC, and basal cell carcinoma has been reported. A functional defect of small lymphocytes, with impaired cell-mediated immunity, may occur (Fig. 27-47). Most patients are anergic to skin-test panels and have increased numbers of natural killer cells. The major mutation involves the *RMRP* gene, which encodes a component of mitochondrial RNA-processing endoribonuclease.

Cartilage-hair hypoplasia has been associated with Omenn syndrome, a variant of severe combined immunodeficiency disease (SCID), which includes erythroderma, eosinophilia, and susceptibility to various pathogens. Mutations in recombination-activating genes 1 and 2 (*RAG1/RAG2*) or Artemis have been associated with Omenn syndrome. Artemis deficiency causes inability to repair DNA double-strand breaks and is one of the causes of radiosensitive SCID.

## Trichorhinophalangeal syndrome

This genetic disorder consists of fine and sparse scalp hair, thin nails, pear-shaped broad nose, and cone-shaped epiphyses of the middle phalanges of some fingers and toes. Supernumerary teeth have been reported. There is an autosomal dominant



**Fig. 27-47** Noninfectious granuloma in cartilage-hair hypoplasia. (Courtesy of Drs. James Treat and Albert Yan.)

and also a recessive inheritance type. Trichorhinophalangeal syndrome can result from single base-pair mutations or deletion of the *TRPS1* gene, which encodes a GATA zinc-finger transcription factor located on chromosomal band 8q24.1. Type II (Langer-Giedion syndrome) includes mental retardation and multiple exostoses and is a contiguous gene syndrome caused by a one-copy deletion in the chromosome 8q23-q24 region, spanning the genes *TRPS1* and *EXT1*. Type III resembles a severe form of type I with short stature.

## Papillon-Lefèvre syndrome

Papillon-Lefèvre syndrome is characterized by hyperkeratosis palmaris et plantaris, periodontitis, and sparsity of the hair. Hyperhidrosis and other signs and symptoms begin early in life. Inheritance of this disease is of an autosomal recessive type.

## Klippel-Feil syndrome

Klippel-Feil syndrome consists of a low posterior scalp hairline extending onto the shoulders, with a short neck, limiting movement of the neck and suggestive of webbing. The cervical vertebrae are fused. This syndrome is caused by faulty segmentation of the mesodermal somites between the third and seventh weeks in utero. Strabismus, nystagmus, cleft palate, bifid uvula, and high palate are other features. Ear abnormalities include microtia, external ear canal stenosis, and chronic ear inflammation. Klippel-Feil syndrome occurs mostly in girls.

## McKusick syndrome

Features of McKusick syndrome include short-limbed dwarfism and fine, sparse, hypoplastic, and dysmorphic hair.

## Atrichia with papules

This rare autosomal recessive disorder is characterized by loss of hair beginning shortly after birth and the development of cutaneous cystic papules. Mutations in the hairless gene have been identified in both humans and mice, but a similar phenotype has also been reported with a normal hairless gene but with vitamin D-resistant rickets type IIA and mutations in the vitamin D receptor gene. The cyst epithelium demonstrates keratins 15 and 17, suggesting derivation from the follicular bulge and the presence of stem cells. Both the hairless gene and the vitamin D receptor gene produce zinc-finger proteins and may have overlapping functions.

**Bansal M, et al:** Atrichia with papular lesions. *Int J Trichology* 2011; 3(2):112-114.

**Candamourty R, et al:** Trichorhinophalangeal syndrome type 1: a case report with literature review. *J Nat Sci Biol Med* 2012; 3(2):209-211.

**David D, et al:** Co-segregation of trichorhinophalangeal syndrome with a t(8;13)(q23.3;q21.31) familial translocation that appears to increase *TRPS1* gene expression. *Hum Genet* 2013; 132(11):1287-1299.

**Min BJ, et al:** An interstitial, apparently-balanced chromosomal insertion in the etiology of Langer-Giedion syndrome in an Asian family. *Eur J Med Genet* 2013; 56(10):561-565.

**Nickles K, et al:** Long-term results after treatment of periodontitis in patients with Papillon-Lefèvre syndrome: success and failure. *J Clin Periodontol* 2013; 40(8):789-798.

**Wang S, et al:** Atrichia with papular lesions in a Chinese family caused by novel compound heterozygous mutations and literature review. *Dermatology* 2013; 226(1):68-74.



## KERATOSIS PILARIS

Keratosis pilaris may be limited in mild cases to the posterior upper arms and manifests as a horny plug in each hair follicle. The thighs are the next most common site, but lesions may occur on the face, forearms, buttocks, trunk, and legs. Facial involvement may be mistaken for acne vulgaris and may leave small, pitted scars, even when the condition does not scar elsewhere. Variants of keratosis pilaris with more prominent scarring are included under the heading of keratosis pilaris atrophicans.

The individual lesions are small, acuminate, follicular papules. They may or may not be erythematous. Sometimes, the keratotic plugs are the most prominent feature of the eruption, whereas at other times, most of the lesions are punctate erythematous papules. Occasionally, inflammatory acneiform pustules and papules may appear.

Forcible removal of one of the plugs leaves a minute, cup-shaped depression at the apex of the papule, which is soon filled by new keratotic material. The lesions tend to be arranged in poorly defined groups, dotting the otherwise normal skin in a fairly regular pattern. They are prone to appear in xerotic or atopic patients. Autosomal dominant inheritance has been described.

Other conditions associated with keratosis pilaris are ichthyosis follicularis, atrichia with papular lesions, mucoepidermal dysplasia, cardiofaciocutaneous syndrome (keratosis pilaris, curly hair, sparse hair with pulmonary valve stenosis, hypertrophic cardiomyopathy, or atrial septal defect), ectodermal dysplasia with corkscrew hairs, and KID syndrome. Keratosis pilaris rubra has prominent erythema and widespread areas of skin involvement, but no atrophy or hyperpigmentation.

Treatment is difficult, but some patients respond to topical retinoids. Ammonium lactate 12% can produce some smoothing of the lesions but seldom results in improvement of the erythema. Topical calcipotriene is effective in some patients. Pulsed dye laser has been used for erythematous variants.

## ERYTHROMELANOSIS FOLLICULARIS FACIEI ET COLLI

Patients with this condition present with well-demarcated erythema, follicular papules, and hyperpigmentation. Itching and photosensitivity may be prominent.

## FOLLICULAR ATROPHODERMA

Follicular atrophoderma consists of follicular indentations without hairs, notably occurring on extensor surfaces of the hands, legs, and arms. Scrotal (fissured) tongue may also be found. It has been described repeatedly in association with other genetically determined abnormalities, including X-linked dominant chondrodysplasia punctata, Bazex syndrome (follicular atrophoderma type), and keratosis palmoplantar disseminata. Bazex (Bazex-Dupré-Christol) syndrome is characterized by congenital hypotrichosis, follicular atrophoderma, multiple milia, hypohidrosis, and basal cell carcinomas. Both trichorhexis nodosa and pili bifurcati have been described in patients with the syndrome.

## KERATOSIS PILARIS ATROPHICANS

Keratosis pilaris atrophicans is seen in three syndromes: keratosis pilaris atrophicans faciei, atrophoderma vermiculata,

and keratosis pilaris follicularis spinulosa decalvans. Keratosis pilaris atrophicans has been reported as being associated with woolly hair and Noonan syndrome. Overlap between the three entities may occur.

Response to therapy is often limited, but some success has been noted with keratolytics and retinoids. Pulsed dye laser therapy has led to improvement in erythema, but not skin roughness.

## Keratosis pilaris atrophicans faciei and ulerythema ophryogenes

Keratosis pilaris atrophicans faciei is characterized by persistent erythema and small, horny, follicular papules with onset during childhood. On involution, these leave pitted scars and atrophy, with resulting alopecia. The disorder involves the eyebrows, from which it may rarely spread to the neighboring skin and even to the scalp. The term ulerythema ophryogenes is used to describe cases with involvement limited to the lateral third of the eyebrows.

Lesions may also begin on the cheeks or temples, rather than the eyebrows. The follicles become reddened (Fig. 27-48), then develop papules, and finally follicular atrophy. In keratosis pilaris atrophicans faciei, the follicular involvement extends to the cheeks and forehead.

Histologically, follicular hyperkeratosis of the upper third of the hair follicle is seen. A small, depressed scar forms when the lesion heals. It may occur with atopy or woolly hair and may be seen in Noonan syndrome and the cardiofaciocutaneous syndrome. Transmission is autosomal dominant.

## Atrophoderma vermiculata

Atrophoderma vermiculata is also known as atrophoderma vermiculata, atrophoderma ulerythematosum, folliculitis ulerythematosum reticulata, and honeycomb atrophy. It is characterized by symmetric involvement of the face by numerous small, closely crowded areas of atrophy separated by narrow ridges, producing a cribriform or honeycomb surface. This worm-eaten (vermiculate) appearance results from atrophy of the follicles and surrounding skin. Each atrophic area is an abrupt, pitlike depression 1–3 mm in diameter. Among the ridges, a few milia may be seen.

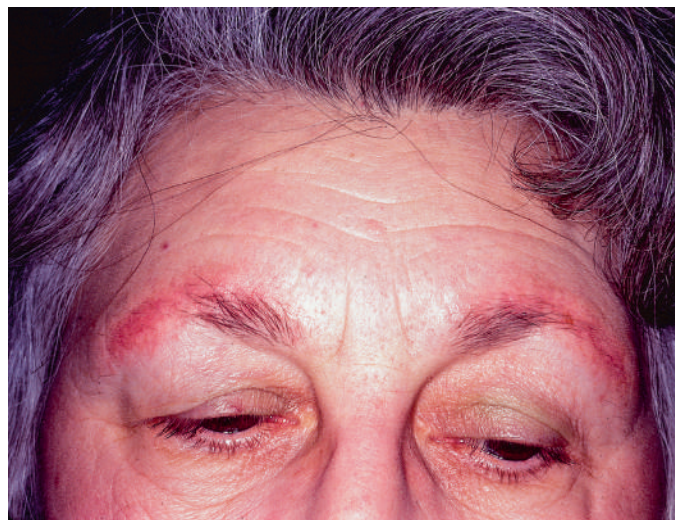

Fig. 27-48 Ulerythema ophryogenes.

The skin covering the ridges is even with the normal skin but contrasts with it by being somewhat waxy, firmer, and apparently stretched. The cause of the disease is undetermined, but familial occurrence has been noted, and it may be associated with other diseases, such as congenital heart block, other cardiac anomalies, neurofibromatosis, oligophrenia, or Down syndrome.

Histologically, the epidermis is slightly atrophic, with diminution in size of the interpapillary projections. In the dermis, the capillaries are dilated, and the vessels have a moderate lymphocytic perivascular infiltration. Follicles may be enlarged, tortuous, dilated, and hyperkeratotic.

### Rombo syndrome

Rombo syndrome is a rare disorder characterized by atrophoderma vermiculata, cyanosis of the hands and feet, milia, telangiectases, hypotrichosis, multiple basal cell carcinomas, and trichoepitheliomas. The associated vermicular atrophoderma produces a coarse, grainy skin texture. Rombo syndrome is inherited in an autosomal dominant manner. It must be distinguished from Bazex syndrome, Rasmussen syndrome (milia, trichoepithelioma, cylindroma), and multiple trichoepitheliomas.

### Keratosis follicularis spinulosa decalvans (Siemens-1 syndrome)

In keratosis follicularis spinulosa decalvans, keratosis pilaris begins on the face and progresses to involve the scalp, limbs, and trunk. There is hyperkeratosis of the palms and soles. Cicatricial alopecia of the scalp and eyebrows is characteristic. Atopy, photophobia, and corneal abnormalities are frequently associated. Deafness, physical and mental retardation, recurrent infections, nail abnormalities, acne keloidalis nuchae, tufted hair folliculitis, and aminoaciduria have also been purported associations. The disorder is genetically heterogeneous. Although inheritance in large kindreds has been X-linked recessive, X-linked dominant and autosomal dominant inheritance have also been suggested. In one X-linked form, the defective genetic site is on Xp22.13–p22.2 in the region of the gene for spermidine/spermine N(1)-acetyltransferase.

**Alcántara González J, et al:** Keratosis pilaris rubra and keratosis pilaris atrophicans faciei treated with pulsed dye laser: report of 10 cases. *J Eur Acad Dermatol Venereol* 2011; 25(6):710–714.

**Janjua SA, et al:** Keratosis follicularis spinulosa decalvans associated with acne keloidalis nuchae and tufted hair folliculitis. *Am J Clin Dermatol* 2008; 9(2):137–140.

**Marqueling AL, et al:** Keratosis pilaris rubra: a common but underrecognized condition. *Arch Dermatol* 2006; 142(12):1611–1616.

## H SYNDROME

The “H syndrome” is an inherited syndrome characterized by hyperpigmentation, hypertrichosis, and indurated patches of skin involving the lower two thirds of the body, with hearing loss, hypogonadism, hepatosplenomegaly, short stature, cardiac anomalies, and scrotal masses. The patients exhibit growth hormone deficiency and hypergonadotropic hypogonadism with azoospermia. Biopsies of involved skin

demonstrate acanthosis with dermal and subcutaneous infiltration by histiocytes, plasma cells, and mast cells.

**Molho-Pessach V, et al:** The H syndrome: a genodermatosis characterized by indurated, hyperpigmented, and hypertrichotic skin with systemic manifestations. *J Am Acad Dermatol* 2008; 59(1):79–85.

## MELAS SYNDROME

The MELAS syndrome (mitochondrial myopathy, encephalopathy, lactic acidosis, stroke-like episodes) is a rare neurodegenerative mitochondrial disorder inherited in the maternal line. Caution is required during anesthesia for procedures, because severe acidosis, neurologic deterioration, and cardiorespiratory compromise may occur with a single dose of propofol. Diffuse erythema with reticular pigmentation may occur. EM of the skin may reveal abnormal mitochondria.

**Hämäläinen RH, et al:** Tissue- and cell-type-specific manifestations of heteroplasmic mtDNA 3243A>G mutation in human induced pluripotent stem cell–derived disease model. *Proc Natl Acad Sci USA* 2013; 110(38):E3622–3630.

**Kubota Y, et al:** Skin manifestations of a patient with MELAS syndrome. *J Am Acad Dermatol* 1999; 41:469–473.

**Potesio CP, Check JH, et al:** Improvement in symptoms of the syndrome of mitochondrial encephalopathy, lactic acidosis, and stroke-like symptoms (MELAS) following treatment with sympathomimetic amines—possible implications for improving fecundity in women of advanced reproductive age. *Clin Exp Obstet Gynecol* 2014; 41:343–345.

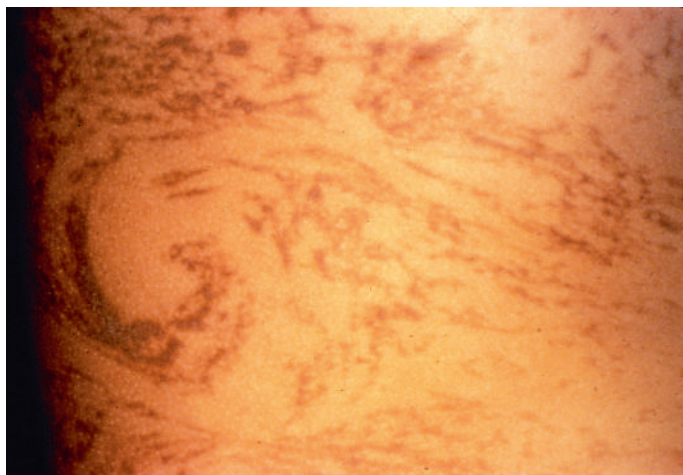


Bonus images for this chapter can be found online at

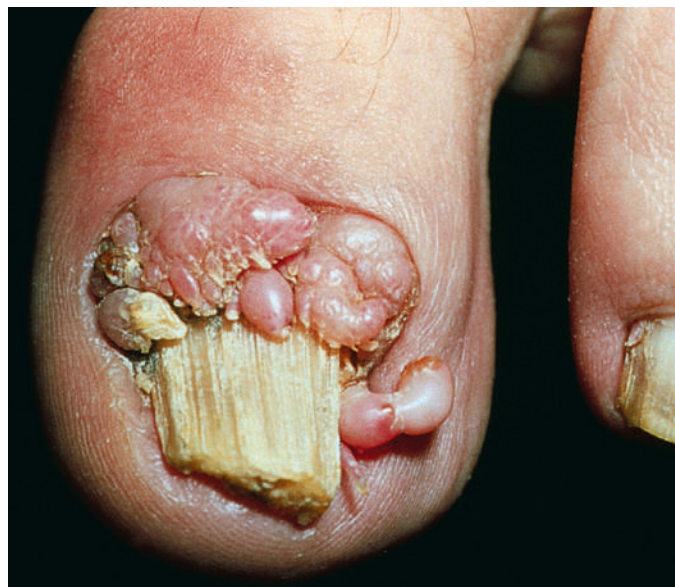[expertconsult.inkling.com](http://expertconsult.inkling.com)

- eFig. 27-1 Late pigmentary incontinentia pigmenti.
- eFig. 27-2 Angiofibromas.
- eFig. 27-3 Oral papillomas in tuberous sclerosis.
- eFig. 27-4 Periungual fibromas.
- eFig. 27-5 Café au lait macules.
- eFig. 27-6 Proteus syndrome. (Courtesy of Dr. Michelle Maroon.)
- eFig. 27-7 Ataxia-telangiectasia.
- eFig. 27-8 Epidermolysis bullosa simplex.
- eFig. 27-9 Junctional epidermolysis bullosa.
- eFig. 27-10 Benign familial pemphigus.
- eFig. 27-11 Hailey-Hailey disease.
- eFig. 27-12 X-linked ichthyosis.
- eFig. 27-13 Porokeratosis.
- eFig. 27-14 Darier's disease. (Courtesy of Dr. Lawrence Lieblch.)
- eFig. 27-15 Pachyonychia congenita.
- eFig. 27-16 Pachyonychia congenita.
- eFig. 27-17 Pachyonychia congenita.
- eFig. 27-18 Pachyonychia congenita.
- eFig. 27-19 Hypohidrotic ectodermal dysplasia. (Courtesy of James Fitzpatrick, MD.)
- eFig. 27-20 Cutis verticis gyrata.
- eFig. 27-21 Goltz syndrome.
- eFig. 27-22 Sclerodermatous legs in progeria.
- eFig. 27-23 Ocular squamous cell carcinoma in xeroderma pigmentosum.
- eFig. 27-24 Rothmund-Thomson syndrome.

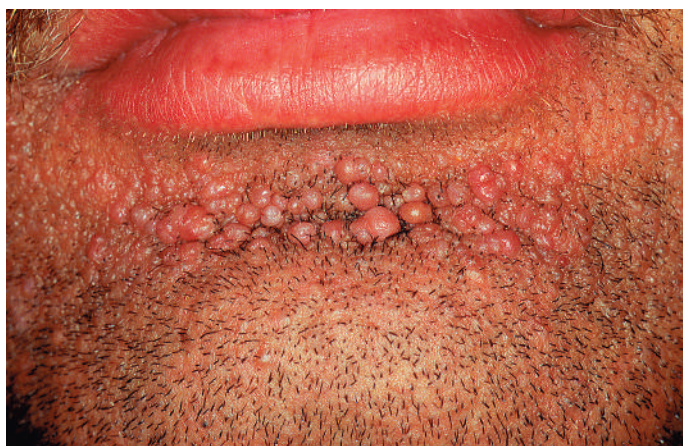



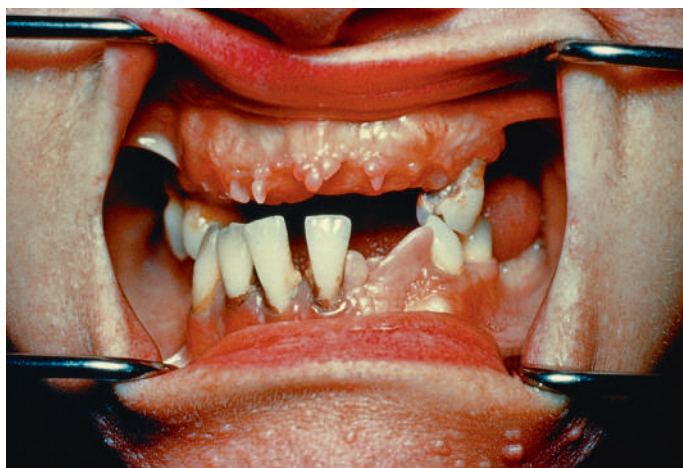eFig. 27-1 Late pigmentation in incontinentia pigmenti.



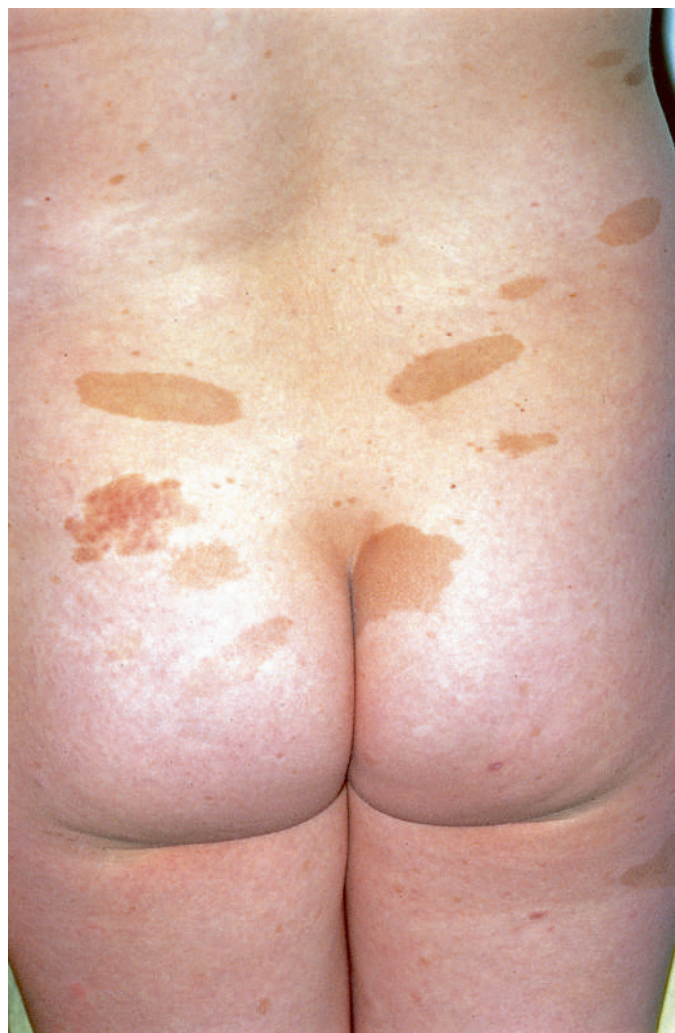eFig. 27-4 Periungual fibromas.



eFig. 27-2 Angiofibromas.

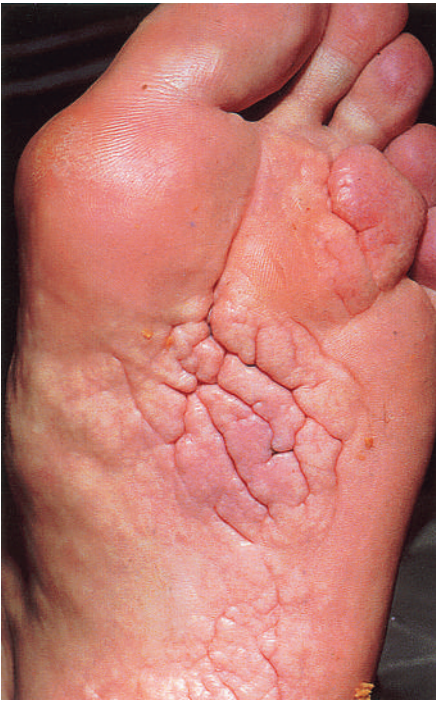

eFig. 27-3 Oral papillomas in tuberous sclerosis.

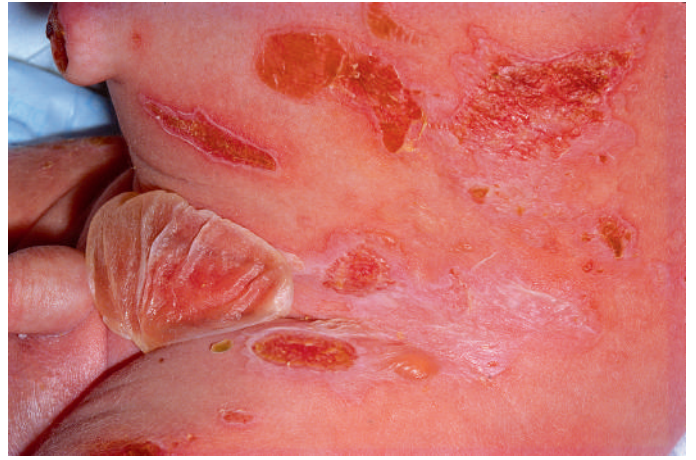

eFig. 27-5 Café au lait macules.

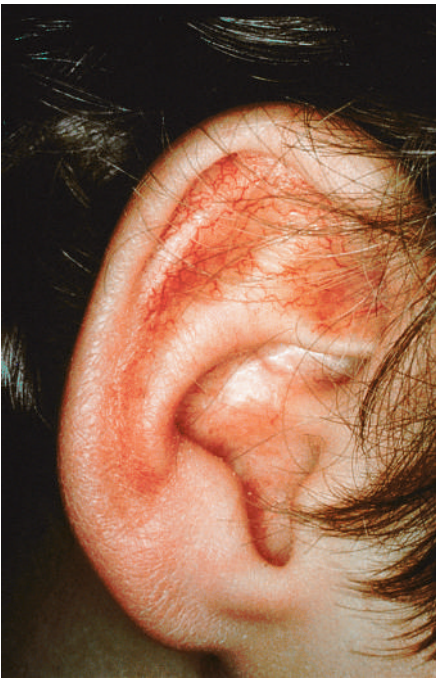



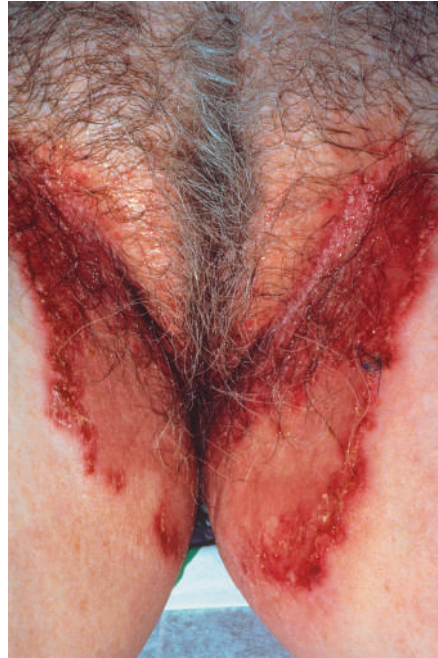**eFig. 27-6** Proteus syndrome. (Courtesy of Dr. Michelle Maroon.)



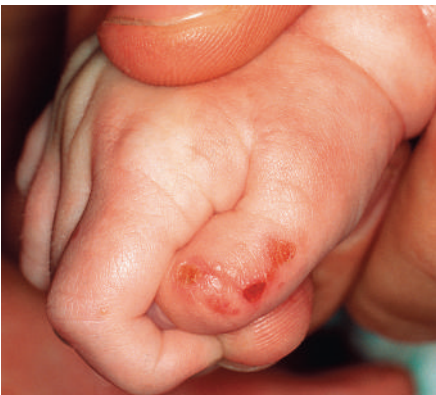**eFig. 27-9** Junctional epidermolysis bullosa.



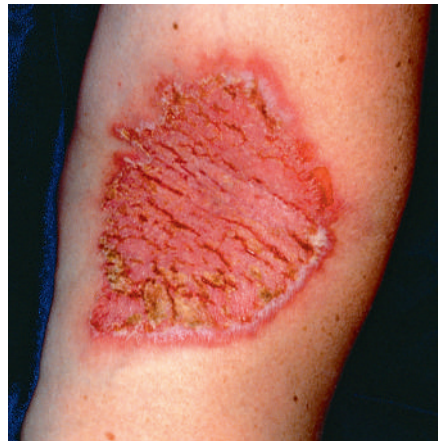**eFig. 27-7**  
Ataxia-telangiectasia.



**eFig. 27-10** Benign familial pemphigus.

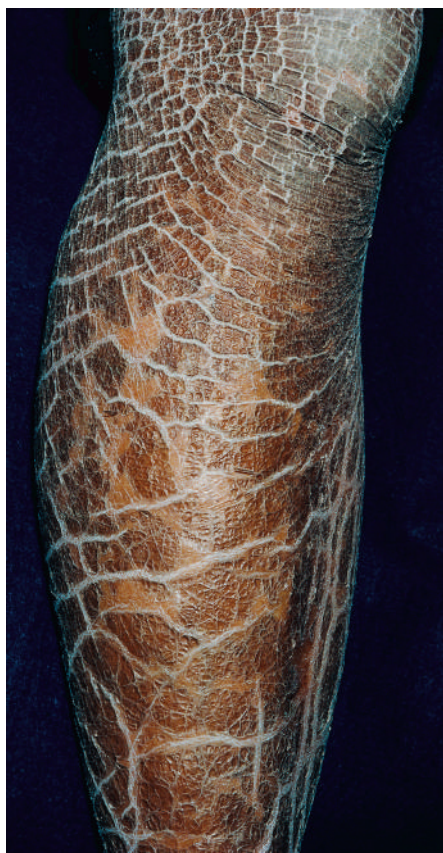

**eFig. 27-8**  
Epidermolysis bullosa simplex.

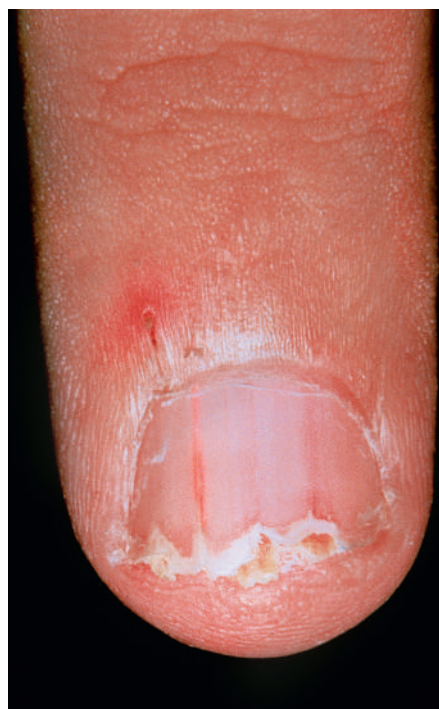

**eFig. 27-11** Hailey-Hailey disease.

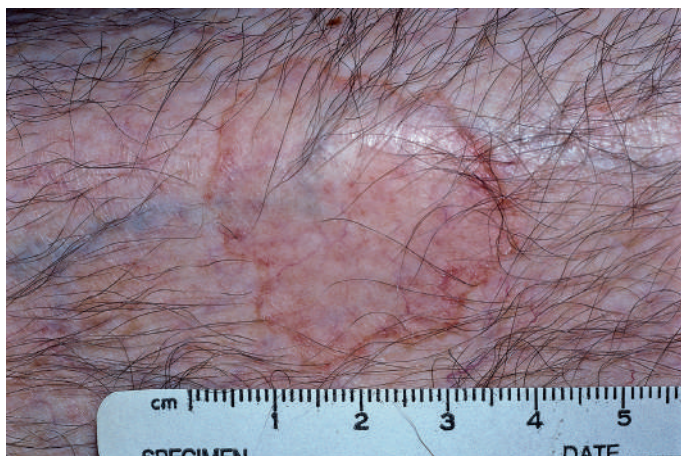




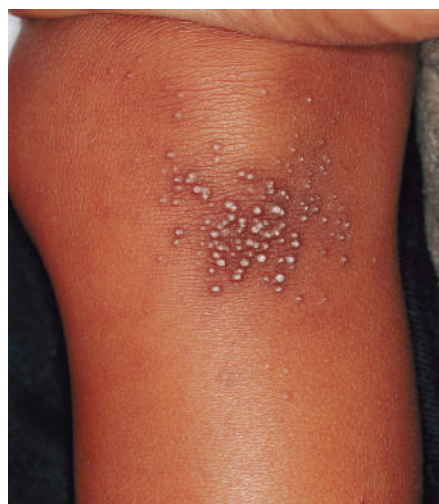**eFig. 27-12** X-linked ichthyosis.



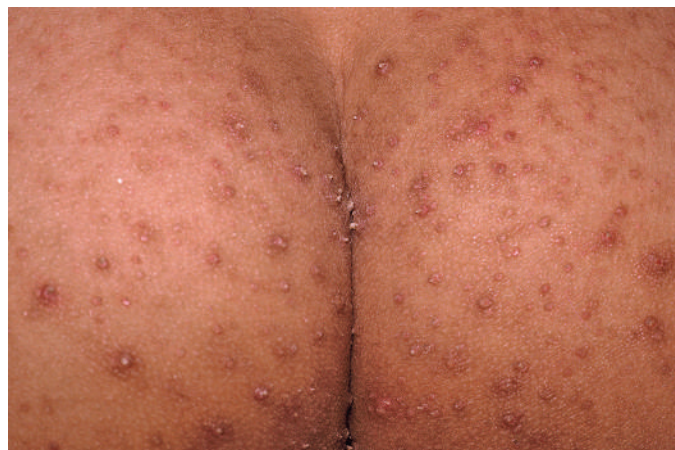**eFig. 27-14** Darier's disease. (Courtesy of Dr. Lawrence Lieblich.)



**eFig. 27-13** Porokeratosis.

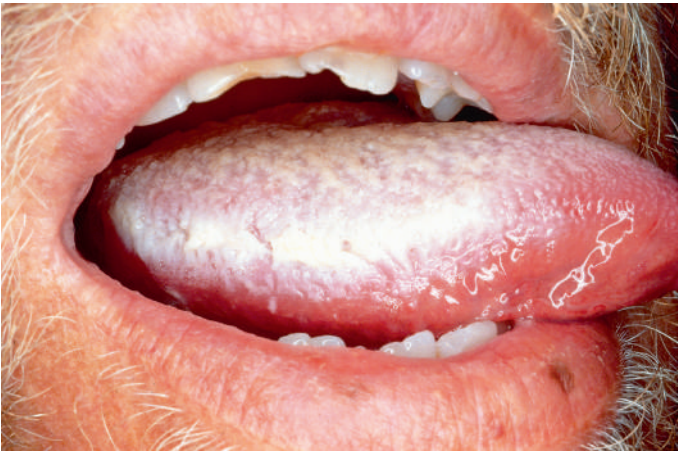

**eFig. 27-15** Pachyonychia congenita.

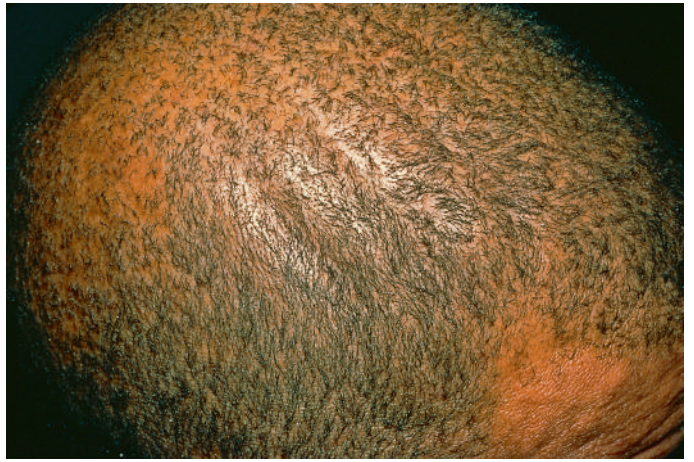


**eFig. 27-16** Pachyonychia congenita.

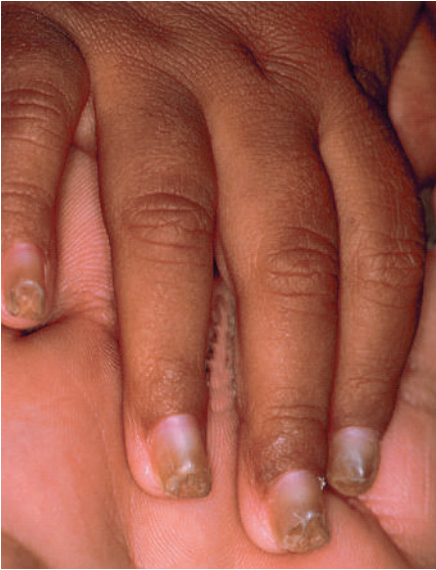



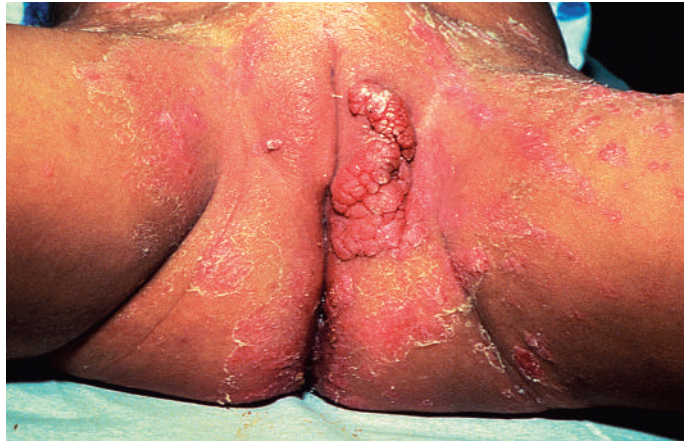eFig. 27-17 Pachyonychia congenita.



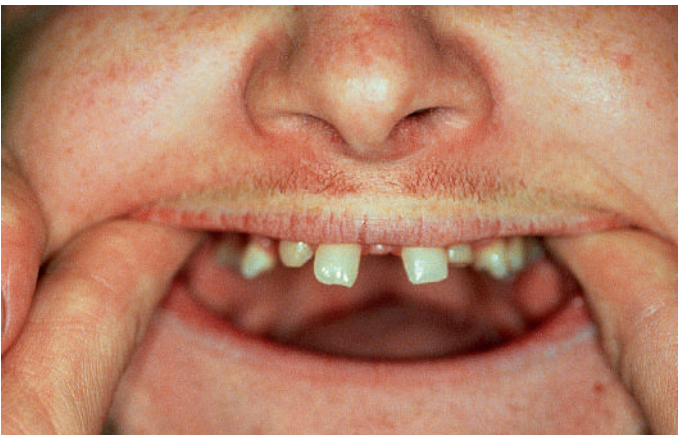eFig. 27-20 Cutis verticis gyrata.



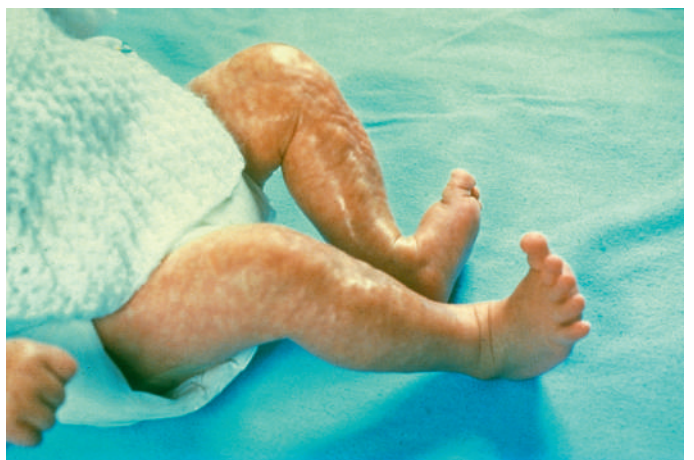eFig. 27-18  
Pachyonychia  
congenita.



eFig. 27-21 Goltz syndrome.

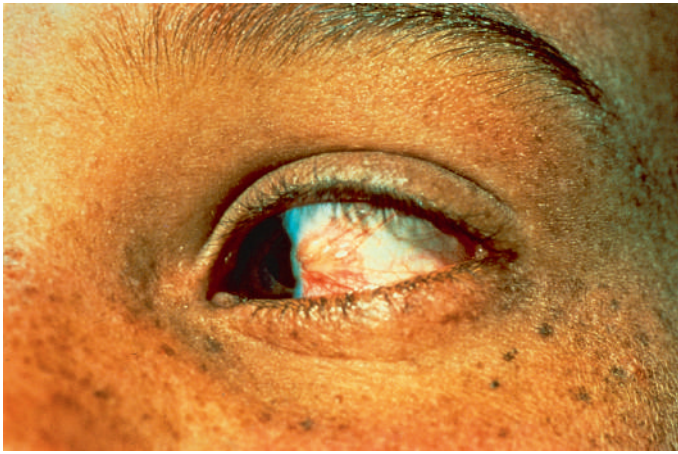


eFig. 27-19 Hypohidrotic ectodermal dysplasia.

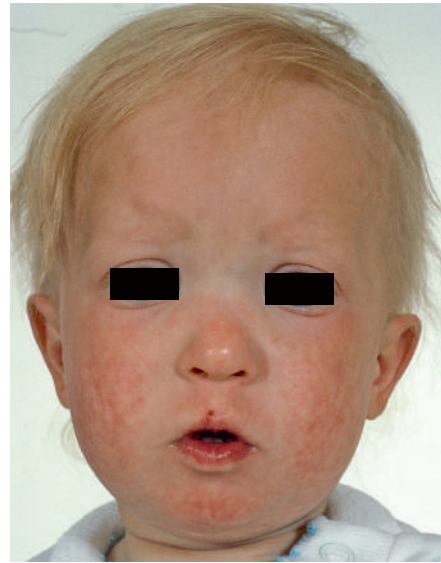

eFig. 27-22 Sclerodermatous legs in progeria.





**eFig. 27-23** Ocular squamous cell carcinoma in xeroderma pigmentosum.



**eFig. 27-24** Rothmund-Thomson syndrome.

## Dermal and Subcutaneous Tumors

In this chapter, proliferations derived from vascular endothelial cells, fibroblasts, myofibroblasts, smooth muscle cells, Schwann cells, and lipocytes are reviewed. Also discussed are several neoplasms of cells invading or aberrantly present in the dermis, such as metastatic cancer, endometriosis, and meningioma.

### CUTANEOUS VASCULAR ANOMALIES

Differentiation between infantile hemangiomas and vascular malformations is helpful when planning therapy, because infantile hemangiomas involute spontaneously while vascular malformations are persistent. Blie et al. reported six kindreds in which infantile hemangiomas and vascular malformations occurred in various family members in an autosomal dominant manner, linking the two disorders.

**Garzon MC, et al:** Vascular malformations. Part I. *J Am Acad Dermatol* 2007; 56(3):353–370.

**Garzon MC, et al:** Vascular malformations. Part II. Associated syndromes. *J Am Acad Dermatol* 2007; 56(4):541–564.

**Kumar S, et al:** Management strategy for facial venous malformations. *Natl J Maxillofac Surg* 2014; 5(1):93–96.

### Hamartomas

Hamartomas are characterized by an abnormal arrangement of tissues normally present in a given site. This is in contrast to a nevus, which has an increase in tissue normally present at a given site, but in an orderly “normal” arrangement.

### Phakomatosis pigmentovascularis

Patients with a combination of vascular malformations and melanocytic or epidermal nevi are grouped into this disorder, and these are manifestations of genetic twin spotting. The revised classification includes only four types: phakomatosis cesioflammea (blue nevus/dermal melanosis and nevus flammeus), phakomatosis spilorosa (nevus spilus and a pale-pink vascular spot), phakomatosis cesiomarmorata (blue spots and cutis marmorata telangiectatica congenita), and unclassifiable cases not corresponding to the previous patterns. Associated systemic findings may include intracranial and visceral vascular anomalies, ocular abnormalities, choroidal melanoma, and hemihypertrophy of the limbs. Phakomatosis cesioflammea is the most common type (85%), and half of patients with this type have serious manifestations, such as Klippel-Trenaunay-Parkes-Weber syndrome or Sturge-Weber syndrome. Bilateral deafness and malignant hypertension have also been described. Some authors have suggested that particularly extensive and aberrant mongolian spots may be a marker for more severe systemic involvement. Phakomatosis spilorosa has been associated with multiple granular cell tumors. Most patients are

Asian. Phakomatosis pigmentokeratocica is now classified separately as a syndrome that includes pigmented and epidermal nevi, but it has been described with connective tissue nevus and pinhead-sized angioma-like lesions superimposed on a speckled lentiginous nevus.

**Arnold AW, et al:** Phakomatosis melanorosea without extracutaneous features: an unusual type of phakomatosis pigmentovascularis. *Eur J Dermatol* 2012; 22(4):473–475.

### Eccrine angiomatous hamartoma

Eccrine angiomatous hamartoma usually appears as a solitary nodular lesion on the acral areas of the extremities, particularly the palms and soles, but identical lesions also occur on areas of the body that normally have few eccrine glands. This lesion appears at birth or in early childhood and is often associated with pain and hyperhidrosis. The lesion is a dome-shaped, tender, bluish nodule. Hypertrichosis may be present. When it is stroked or pinched, drops or beaded rings of perspiration may be seen.

Histologically, there is a combination of lobules of mature eccrine glands and ducts with thin-walled blood vessels. Excessive mucin, fat, smooth muscle, nerve infiltration, and terminal hairs may be present. The lesion has been associated with spindle cell hemangioma, arteriovenous malformation (AVM), and verrucous hemangioma. Excision may be necessary because of pain.

**Halder C, et al:** Eccrine angiomatous hamartoma: late onset facial presentation. *Indian J Dermatol* 2014; 59(4):403–405.

**Shin J, et al:** Eccrine angiomatous hamartoma: a review of ten cases. *Ann Dermatol* 2013; 25(2):208–212.

### Malformations

Malformations are abnormal structures that result from an aberration in embryonic development or trauma. The abnormality may be caused by an anatomic malformation or a functional alteration (as in nevus anemicus). Anatomic malformations are subdivided according to the type of vessel involved: capillary, venous, arterial, lymphatic, or combined. The term “capillary malformation” is sometimes used as a synonym for nevus flammeus, but it is best used as a term encompassing a variety of entities, including salmon patch, nevus anemicus, and cutis marmorata telangiectatica congenita.

Diffuse capillary malformation with overgrowth has been characterized as a distinct syndrome that differs from Klippel-Trenaunay-Parkes-Weber syndrome (KTPW) by prominent subcutaneous veins rather than persistent embryologic vessels and other vascular malformations. KTPW requires venous and lymphatic as well as capillary malformation. Cutis marmorata telangiectatica congenita is differentiated by reticulated atrophy and limb hypoplasia; the macrocephaly capillary malformation syndrome by hypotonia, hydrocephalus,



developmental delay, and digital syndactyly, and CLOVES (congenital lipomatous asymmetric overgrowth of the trunk, lymphatic, capillary, venous, and combined-type vascular malformations, epidermal nevi, skeletal and spinal anomalies) syndrome by overgrowth with triangular feet, dysmorphic toes, and truncal lymphatic, venous, and capillary malformations. The macrocephaly capillary malformation syndrome often demonstrates a reticulated capillary malformation and may include syndactyly and as well as asymmetry. The *PIK3CA*-associated segmental overgrowth syndromes include *megalencephaly-capillary malformation (MCAP) syndrome*, *hemimegalencephaly*), and *segmental body overgrowth syndromes*, including CLOVES syndrome.

**Happle R:** What is a capillary malformation? *J Am Acad Dermatol* 2008; 59(6):1077–1079.

**Lee MS, et al:** Diffuse capillary malformation with overgrowth: a clinical subtype of vascular anomalies with overgrowth. *J Am Acad Dermatol* 2013; 69:589–594.

## Nevus anemicus

Nevus anemicus is a congenital disorder characterized by macules of varying size and shape that are paler than the surrounding skin and cannot be made red by trauma, cold, or heat. The nevus resembles vitiligo, but there is a normal amount of melanin. Wood's light does not accentuate it, and diascopy causes it to merge into the surrounding blanched skin. The patches are usually well defined with irregular edges. It may occur on the neck and trunk of young children with neurofibromatosis when other features have not yet developed. Nevus anemicus can also be found in tuberous sclerosis or as one component of phakomatosis pigmentovascularis. In nevus anemicus, the triple response of Lewis lacks a flare, but outside the nevus, a flare does develop after rubbing the skin. The underlying defect is an increased sensitivity of the blood vessels to catecholamines. On biopsy and with confocal microscopy, lesional skin resembles normal skin.

## Nevus oligemicus

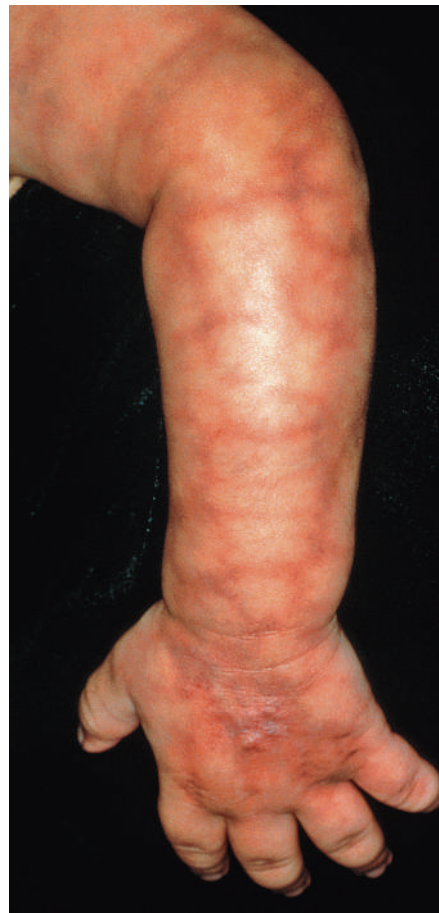Nevus oligemicus presents as a patch of livid skin that is cooler than the normal skin as a result of decreased blood flow. Vasoconstriction of deep vessels is thought to be the underlying defect.

**Ferrari F, et al:** Juvenile xanthogranuloma and nevus anemicus in the diagnosis of neurofibromatosis type 1. *JAMA Dermatol* 2014; 150(1):42–46.

**Marque M, et al:** Nevus anemicus in neurofibromatosis type 1: a potential new diagnostic criterion. *J Am Acad Dermatol* 2013; 69(5):768–775.

## Cutis marmorata telangiectatica congenita (congenital phlebectasia, van Lohuizen syndrome)

Cutis marmorata telangiectatica congenita is characterized by the presence of a purplish, reticulated, vascular network with a segmental distribution, usually involving the extremities (Fig. 28-1). The mottling is pronounced and is made more distinct by crying, vigorous activity, and cold. At birth, it may resemble a port wine stain, and lesions usually improve by 2 years of age but may remain stable. The condition occurs sporadically, and there is a female preponderance. The segmental distribution suggests mosaicism, and occasional familial occurrence could be explained by parandominant inheritance, where heterozygous individuals are phenotypically normal and the mutation is transmitted unperceived, only becoming manifest when a postzygotic mutation gives rise to loss of heterozygosity.



**Fig. 28-1** Cutis marmorata telangiectatica congenita. (Courtesy of Brooke Army Medical Center Teaching File.)

Associated anomalies occur in more than half of patients. Common anomalies include varicosities, nevus flammeus, ulceration, macrocephaly, and hypoplasia and hypertrophy of soft tissue and bone. Unusual associations include generalized congenital fibromatosis, premature ovarian failure, Chiari I malformation, and rectal and genital anomalies. These lesions are associated with phakomatosis pigmentovascularis and the Adams-Oliver syndrome (limb abnormalities, scalp defects, skull ossification defects). High copper levels and increased elastolysis have been described.

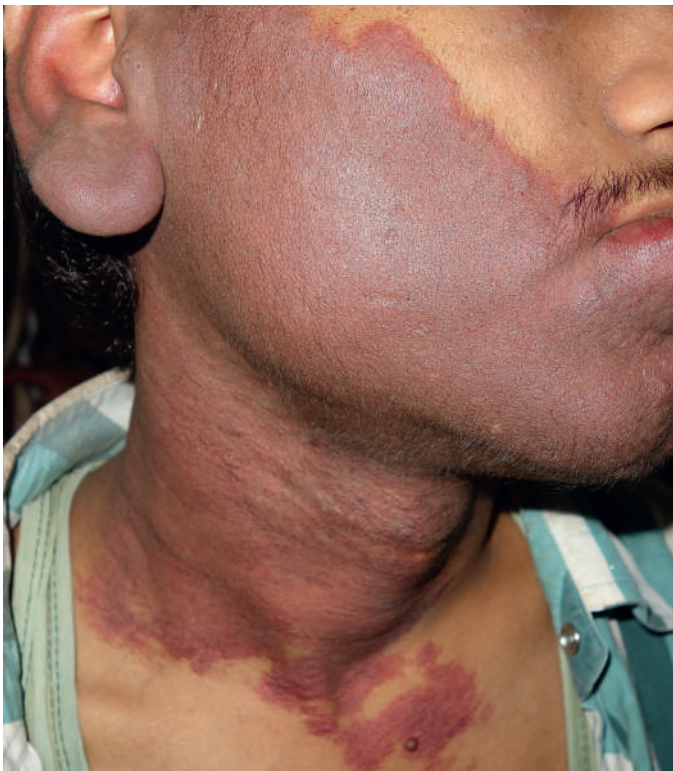The differential diagnosis includes residual vascular lesions from neonatal lupus and Bockenheimer syndrome. Bockenheimer syndrome appears in childhood and shows progressive development of large venous ectasias involving one limb. No treatment is required for cutis marmorata telangiectatica congenita. Many of the lesions will become less noticeable with time.

**Memarzadeh A, et al:** Limb length discrepancy in cutis marmorata telangiectatica congenita: an audit of assessment and management in a multidisciplinary setting. *Br J Dermatol* 2014; 170(3):681–686.

**Pleimes M, et al:** Characteristic congenital reticular erythema: cutis marmorata telangiectatica congenita. *J Pediatr* 2013; 163(2):604–604.e1.

## Nevus flammeus (port wine stain)

Nevus flammeus nuchae (“stork bite”) is a congenital capillary malformation present in 25% of newborns. It may persist in at least 5% of the population. It usually is a pink-red macule situated on the posterior midline between the occipital protuberance and the tip of the spine of the fifth cervical vertebra. The long axis is usually up and down. A similar-appearing midline nevus flammeus (salmon patch, nevus simplex, or “angel’s



**Fig. 28-2** Port wine stain. (Courtesy Dr. Debarbrata Bandyopadhyay.)

kiss”) on the glabellar region or on one upper eyelid is present in approximately 15% of newborns. It tends to fade during childhood and is rarely associated with Beckwith-Wiedemann or MCAP syndrome.

Other port wine stains occur in an estimated 3:1000 children. The stains are present at birth and vary in color from pink to dark or bluish red. The lesions are usually unilateral and located on the face and neck (Fig. 28-2), although they may be widespread and involve as much as half the body. The most common site is a unilateral distribution on the face. The mucous membrane of the mouth may be involved. Although the surface of a nevus flammeus is usually smooth, small vascular nodular outgrowths or warty excrescences may develop over time. These lesions often become more bluish or purple with age. Several reports document multiple basal cell carcinomas occurring in adult life over sites of long-standing nevus flammeus. Rarely, nevus flammeus may appear as an acquired condition, usually with onset after trauma.

Nevus flammeus in the area supplied by the ophthalmic division of the trigeminal cranial nerve is a component of the Sturge-Weber syndrome (encephalotrigeminal angiomatosis), but the leptomenigeal component is present in only 10% of patients, with all or most of the V1 branch of the trigeminal nerve involved. Leptomenigeal angiomatosis may clinically manifest as epilepsy, mental retardation, hemiplegia, hemisensory defects, and homonymous hemianopsia. Characteristic calcifications are present in the outer layers of the cerebral cortex; these consist of double-contoured “tram tracks” that follow the brain convolutions. Ocular abnormalities, such as glaucoma, buphthalmos (infantile glaucoma, related to abnormal development of angle formed by cornea and iris), retinal detachment, and blindness, affect approximately 50% of patients. These may be present without leptomenigeal involvement. The syndrome results from the persistence of the primitive embryonal vascular plexus that develops during the sixth fetal week around the cephalic neural tube and in the region destined to become facial skin. Normally, the plexus

regresses during the ninth week, but in the Sturge-Weber syndrome it persists. Fibronectin gene expression is increased in lesional fibroblasts.

Overgrowth of soft tissue and underlying bone may occur in an affected extremity, giving rise to the Klippel-Trenaunay-Parkes-Weber syndrome. The Klippel-Trenaunay syndrome is characterized by port wine malformations, and the Parkes-Weber syndrome by deep AVMs.

Port wine stains are components of many rare congenital disorders. Occasionally, nevus flammeus may be a manifestation of phakomatosis pigmentovascularis. The Beckwith-Wiedemann syndrome may comprise facial port wine stain, macroglossia, omphalocele, visceral hyperplasia, occasionally hemihypertrophy, and hypoglycemia. Cobb syndrome (cutaneous meningospinal angiomatosis) is a nonfamilial disorder characterized by a port wine hemangioma or other vascular malformation in a dermatome supplied by a segment of the spinal cord containing a venous malformation or AVM. Kyphoscoliosis is common, and multiple neurologic, gastrointestinal (GI), urologic, and skeletal abnormalities may also be present. Proteus syndrome is characterized by vascular malformations that include nevus flammeus, hemihypertrophy, macrodactyly, verrucous epidermal nevus, soft tissue subcutaneous masses, and cerebriform overgrowth of the plantar surface. Roberts syndrome consists of a facial port wine stain and hypomelia, hypotrichosis, growth retardation, and cleft lip. The Wyburn-Mason syndrome consists of unilateral retinal AVM associated with ipsilateral port wine stain near the affected eye. This may be present in association with Sturge-Weber syndrome. The TAR syndrome is defined by congenital thrombocytopenia, bilateral absence or hypoplasia of the radius, and port wine stain. Coats’ disease manifests with retinal telangiectasia and ipsilateral facial port wine stain. The capillary malformation–arteriovenous malformation (CM-AVM) syndrome is an autosomal dominant disorder caused by heterozygous *RASA1* mutations and resulting in multifocal capillary malformations and high risk for fast-flow lesions.

Lesional skin in nevus flammeus demonstrates overexpression of vascular endothelial growth factor (VEGF) and its receptor (VEGF-R2). Occasional familial segregation of port wine stains has been noted, and a large associated gene locus, *CMC1*, has been identified on chromosome 5q. *RASA1*, a gene encoding p120-RasGAP, is found within this region, and heterozygous inactivating *RASA1* mutations have been found in affected families. Somatic mutations in *GNAQ* have been described in Sturge-Weber syndrome and port wine stains.

Histologically, port wine stains demonstrate dilation of capillaries in the subpapillary network. Laser therapy has been used with satisfactory results, but a number of treatments are required, and recurrence is common. The flashlamp pulsed dye laser has the best record of safety and efficacy. Typically, a pulse duration of 0.45 ms is used. A study of cryogen spray-cooled laser treatment at wavelengths of 585 versus 595 nm, both with 7-mm spot size in a range of 7–10 J/cm<sup>2</sup>, demonstrated better blanching at 585 nm. In another study, purple lesions responded best to 585 nm at 0.5 ms, whereas red and pink lesions showed similar results with either 585 nm at 0.5 ms or 595 nm for 20 ms. In this study, 595 nm at 0.5 ms was less effective than the other settings. Optical-thermal models predict that for vessel diameters of 40, 80, and 120 μm, effective pulse durations should be approximately 1.5, 6, and 20 ms, respectively. Cryospray cooling and fluence can be varied to produce optimal results. For darker-skinned patients, multiple pulse stacking with multiple cryogen spurts provides better epidermal protection. Intense pulsed light has been effective in some patients resistant to multiple pulsed dye laser treatments. Long-pulse pulsed alexandrite lasers work best for hypertrophic, purple lesions, whereas pulsed dye lasers work



best for flat, pink lesions. The variable-pulse pulsed dye laser may be effective in lesions refractory to standard pulse dye laser treatment. A frequency-doubled (532-nm) neodymium-doped yttrium-aluminum-garnet (Nd:YAG) laser that allows for shorter pulse widths, large spot sizes, and high fluences resulted in up to 75% improvement in color at 1 month after a single treatment. Other studied modalities include 810-nm diode and 1064-nm Nd:YAG lasers, as well as intense pulse light systems. Photodynamic therapy and use of antiangiogenic agents after laser irradiation show promise.

**Cerrati EW, et al:** Surgical treatment of head and neck port-wine stains by means of a staged zonal approach. *Plast Reconstr Surg* 2014; 134(5):1003–1012.

**Jagtap S, et al:** Sturge-Weber syndrome: clinical spectrum, disease course, and outcome of 30 patients. *J Child Neurol* 2013; 28(6):725–731.

**Laquer VT, et al:** Microarray analysis of port wine stains before and after pulsed dye laser treatment. *Lasers Surg Med* 2013; 45(2):67–75.

**Lian CG, et al:** Novel genetic mutations in a sporadic port-wine stain. *JAMA Dermatol* 2014; 150(12):1336–1340.

**Ortiz AE, et al:** Port-wine stain laser treatments and novel approaches. *Facial Plast Surg* 2012; 28(6):611–620.

**Reddy KK, et al:** Treatment of port-wine stains with a short pulse width 532-nm Nd:YAG laser. *J Drugs Dermatol* 2013; 12(1):66–71.

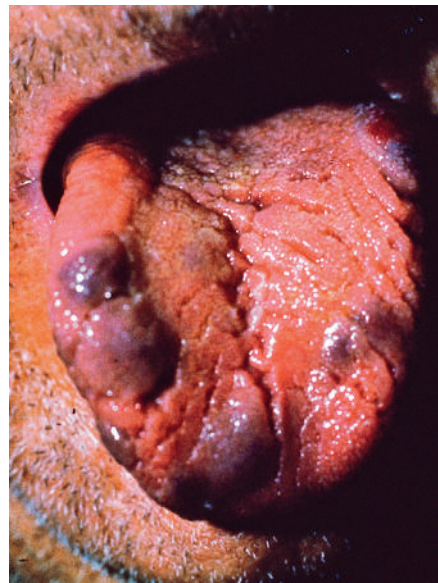**Shirley MD, et al:** Sturge-Weber syndrome and port-wine stains caused by somatic mutation in *GNAQ*. *N Engl J Med* 2013; 368(21):1971–1979.

## Deep venous malformations including cavernous venous malformation

Cavernous venous malformations present as rounded, bright-red or deep-purple, spongy nodules. They occur chiefly on the head and neck and may involve both the skin and the mucous membranes. There is usually a deep component with a connection to the venous circulation. Calcified phleboliths and localized hyperhidrosis may occasionally be present, but the lesions are generally asymptomatic. The deep components are not amenable to laser therapy. Results of surgical resection are generally poor. Compression may be helpful. Customized, snug-fitting garments are preferable to elastic bandages.

Several syndromes are associated with venous malformations. The Bannayan-Riley-Ruvalcaba syndrome is described later in this chapter. Maffucci syndrome, also known as dyschondroplasia with hemangiomas, is characterized by multiple vascular malformations with dyschondroplasia. The dyschondroplasia is manifested by uneven bone growth as a result of the defects of ossification, with enchondromatosis that results in multiple and frequent fractures in the period of bone growth. During the prepubertal years, 1–2 cm nodules appear on the small bones of the hand or foot. Later, larger nodules, the enchondromas, appear on the long bones. Much later, similar lesions appear on the trunk. Sarcomatous degeneration occurs in 50% of patients. The distribution of the lesions is mostly unilateral. Multiple venous malformations of the skin and mucous membranes are present in this nonhereditary mesodermal dysplasia disorder. Lymphangiomas may also occur. Pigmentary changes, such as vitiligo and café au lait macules, have been noted. In Ollier disease, the enchondromatosis is present without the cutaneous abnormalities. Human enchondromatosis has been associated with abnormalities in parathyroid hormone-related protein (PTHrP), its receptor, and the Indian hedgehog (*IHH*) gene. PTHrP delays differentiation of proliferating chondrocytes, whereas *IHH* promotes proliferation.

The blue rubber bleb nevus syndrome is characterized by cutaneous and GI venous malformations. The skin lesions have a cyanotic, bluish appearance with a soft, elevated, nipplelike center, but deeper lesions may also occur. They can be



**Fig. 28-3** Blue rubber bleb nevus syndrome.

emptied by firm pressure, leaving them flaccid. The lesions are located predominantly on the trunk and arms. Nocturnal pain may occur and is a characteristic symptom. Gastrointestinal hemangiomas are found throughout the GI tract (Fig. 28-3) but are numerous in the small intestine. Rupture of a lesion may produce melena. Occasionally, other organs may express venous malformations, and symptomatic central nervous system (CNS) lesions have been described. This syndrome generally occurs as a sporadic condition. It may be present as an autosomal dominant familial trait. Treatment of bleeding or painful lesions is destruction or excision. Minimally invasive surgical techniques are well suited to the treatment of numerous lesions. For patients who continue to have bleeding episodes that require blood transfusions, octreotide, a somatostatin analog known to decrease splanchnic blood flow, may be effective.  $\epsilon$ -Aminocaproic acid has also been used.

Gorham's disease (Gorham's sign) is characterized by cutaneous and osseous venous and lymphatic malformations associated with massive osteolysis or "disappearing bones." Although multiple areas of the skeletal system may be involved, usually only a single bone is destroyed. The bone is completely or partially replaced with fibrous tissue. The cutaneous malformation may be the initial sign of the disease, which typically appears in young children, usually in areas adjacent to involved bones.

Sinusoidal hemangioma is a vascular malformation that usually presents in adults as a bluish purple nodule, less than 4 cm in diameter, on the trunk or breasts. Multiple lesions may occur, and a facial location has also been reported. Histologically, it appears as a lobular, circumscribed mass with dilated, interconnected vascular channels filled with blood.

A familial condition of multiple cutaneous and mucosal venous malformations with abnormal venous channels and decreased or absent smooth muscle was shown to result from an activating mutation in the receptor tyrosine kinase *TIE-2* endothelial gene. It is located on chromosome 9p and is the result of a single amino acid substitution in the kinase domain of the *TIE-2* receptor.

Cerebral cavernomas are vascular malformations that may be inherited in an autosomal dominant manner. The gene, *CCM1*, has been mapped to chromosome 7. Cutaneous malformations are sometimes present, including hyperkeratotic cutaneous capillary venous malformations.

Venous malformation (VM) should be distinguished from glomuvenous malformation (GM, glomangioma). VMs are

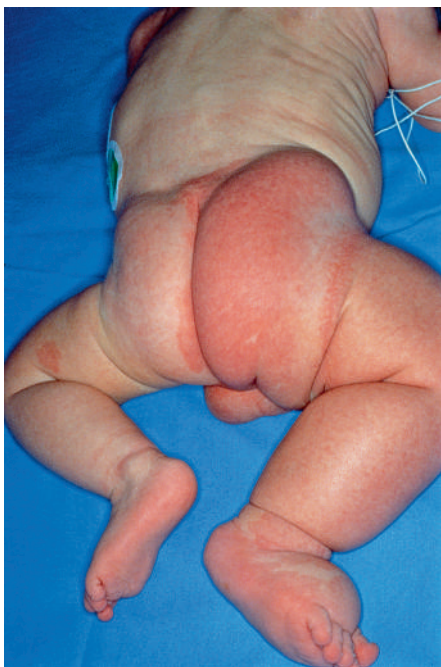usually sporadic, whereas GMs are frequently inherited. VM is linked to chromosome 9p21; GM is linked to 1p21 and loss-of-function mutations in glomulin. GM can be pink at initial presentation but evolves to blue-black with a cobblestone appearance and minimal hyperkeratosis. Involvement of an extremity is typical, and the GMs are often painful if compressed. VM is an isolated, mucosal or subcutaneous blue lesion that may involve muscle. The lesion often shrinks with external pressure and is typically painful in the morning due to congestion. Increased pain may be noted at puberty, during menstruation, with pregnancy, or with oral contraceptives. VM may be associated with intravascular coagulopathy. Sclerotherapy is more effective in VM than in GM. Ethanolamine oleate has been reported as a novel sclerotherapy agent. Both soft tissue injury and neuropathy have been reported after various forms of embolization or sclerotherapy. Absence of deeper tissue involvement noted with magnetic resonance imaging (MRI) is associated with a higher rate of skin necrosis and alcohol embolization.

**Fayad LM, et al:** Venous malformations: MR imaging features that predict skin burns after percutaneous alcohol embolization procedures. *Skeletal Radiol* 2008; 37(10):895–901.

### Klippel-Trenaunay syndrome (hemangiectatic hypertrophy, angio-osteohypertrophy syndrome)

Klippel-Trenaunay syndrome (KTS) is characterized as a triad of nevus flammeus, venous and lymphatic malformations, and soft tissue hypertrophy of the affected extremity (Fig. 28-4). The lower limb is affected in approximately 95% of patients. When there is an associated arteriovenous (AV) fistula, Parkes-Weber is appended to the diagnosis.

The earliest and most common presenting sign is a nevus flammeus that is confined to the skin of an extremity. The port wine stain often stops abruptly at the midline with a sharp, linear border, but it may be patchy and extend over the buttocks and trunk and may occasionally be seen with a bilateral or generalized distribution. Varicose veins may be present. The deeper VM in this sporadic syndrome may be confined to the skin, but it often extends to muscle and bone. Venous



**Fig. 28-4** Klippel-Trenaunay syndrome.

thromboembolism has been reported, with an incidence as high as 22%. In other patients, the deep venous system is hypoplastic.

The involved limb is usually larger and longer than normal. Other, less frequent features include intermittent claudication, venous ulcers, increased skin temperature, diffuse hair loss, hypertrichosis, lymphedema, altered sweating, lacrimation, or salivation. Gait abnormalities are common. Hemihypertrophy of the face; cutaneous lymphangioma; varicose pulmonary, bladder, and colonic veins; and recurrent pulmonary emboli have been reported. Intradural spinal cord AVMs, epidural hemangioma, and epidural angiomyolipoma have been reported to occur at the same segmental level as cutaneous lesions of KTS. Clinical evaluation consists of color duplex ultrasonography to evaluate the patency of the deep venous system, MRI for visualization of hypertrophic muscle and bone, arteriography when an AV fistula is suspected, and conventional radiography of both extremities. Early venography may be performed, if the deep venous system is not hypoplastic, to determine whether there are defects that might be amenable to surgical correction. Thick-slice dynamic magnetic resonance projection angiography (MRPA) and intra-arterial digital subtraction angiography can be used to detect AV shunting in Parkes-Weber syndrome. Mutations associated with the angiogenic factor VG5Q have been described in KTS. A balanced translocation involving chromosomes 8q22.3 and 14q13 has also been reported.

Flashlamp-pumped pulsed dye laser treatments may be used for the nevus flammeus component. The varicosities and malformations may respond to microfoam sclerosis, endovenous thermal ablation, or surgical stripping. Edema is managed through elevation, graded compression pumps, fitted garments, and diuretics. Surgery may be performed to correct the inequality in limb length, to relieve deep venous obstruction, or to correct an associated AV fistula. Skin ulcers have responded to sunitinib. The Klippel-Trenaunay Support Group website can be found at [www.k-t.org](http://www.k-t.org).

**Lacerda Lda S, et al:** Differential diagnoses of overgrowth syndromes: the most important clinical and radiological disease manifestations. *Radiol Res Pract* 2014; 2014:947451.

**Nguyen S, et al:** Skin ulcers in Klippel-Trenaunay syndrome respond to sunitinib. *Transl Res* 2008; 151(4):194–196.

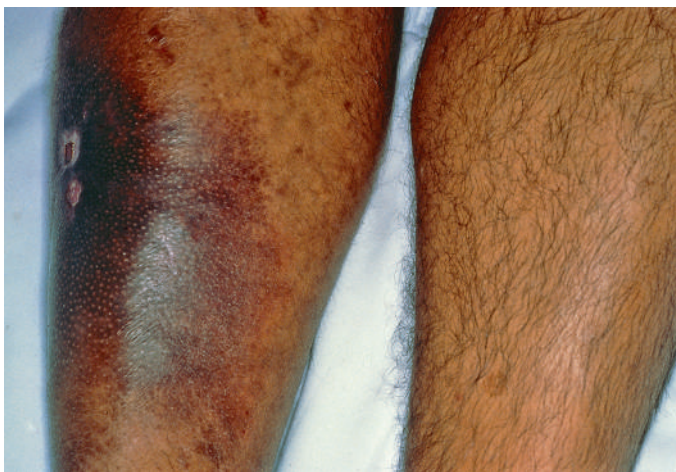**Redondo P, et al:** Microfoam treatment of Klippel-Trenaunay syndrome and vascular malformations. *J Am Acad Dermatol* 2008; 59(2):355–356.

### Arteriovenous fistulas

An arteriovenous fistula is a route from artery to vein, bypassing the capillary bed. AV fistulas may be congenital or acquired. Congenital AV fistulas occur mostly on the extremities and may be recognized, or at least suspected, in the presence of varicose veins, ulcerations, hemangiomas, and nevus flammeus. They may occur internally as a component of Osler-Weber-Rendu disease (hereditary hemorrhagic telangiectasia). Acquired AV fistulas are usually the result of trauma (Fig. 28-5) but may be created intentionally for hemodialysis access.

The skin over AV fistulas is warmer, hair may grow faster, and the affected limb may be larger than the other; thrills and bruits may be discerned in some cases. Changes may result from stasis, a vascular steal syndrome, edema, a vascular mass, increased sweating, or paresthesias. At times, reddish purple nodules or a plaque may be present with a clinical resemblance to Kaposi sarcoma; this has been called pseudo-Kaposi sarcoma (Stewart-Bluefarb syndrome). It may occur because of congenital malformations, in which case a unilateral purplish discoloration of the skin over or distal to the AV anomaly begins to appear in the second or third decade of life.





**Fig. 28-5** Stasislike changes below acquired arteriovenous fistula.

This type accounts for 80% of cases; the remainder are secondary to fistulas caused by trauma. Iatrogenic AV fistulas, such as those produced to facilitate hemodialysis, may also bring about skin changes, including reactive angioendotheliomatosis. Histologically, there is an increase in thick-walled vessels lined by plump endothelial cells, extravasated erythrocytes, and deposits of hemosiderin. Proliferating endothelial cells may occlude the lumen.

Cirroid aneurysms (angioma arteriale racemosum) are uncommon congenital AV fistulas of the scalp or face. They may appear on the skin as a pulsating mass that may extend over the neck and scalp and may penetrate into the cranium, or they may simply manifest as a solitary blue or red papule in the midadult period. Abdominal AV fistulas may be associated with lower extremity edema, cyanosis, pulsatile varicose veins, and scrotal edema.

Diagnosis of an AV fistula is established by plethysmography, thermography, determination of oxygen saturation of venous blood, or arteriography.

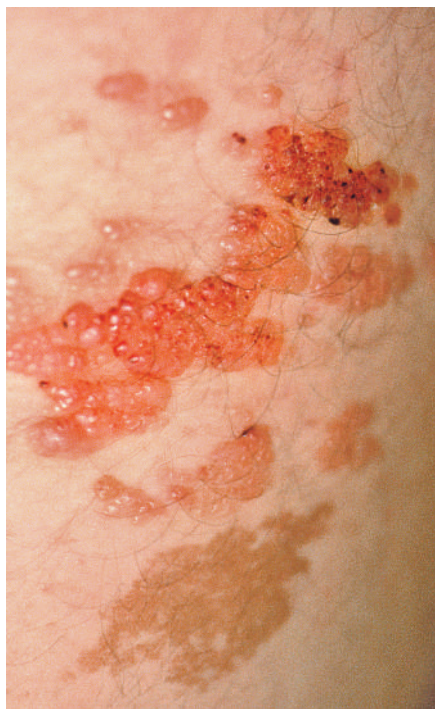Treatment of traumatically induced AV fistulas by excision is curative. Because the congenital malformation variety consists of multiple small distal lesions, surgical intervention is not feasible in many patients. Color echo-Doppler ultrasonography-guided sclerotherapy with polidocanol microfoam has been used successfully in this setting. Sodium tetradecyl sulfate and ethanolamine oleate have both been used as sclerosants in various forms of AV malformation. Pressure and elevation as supportive measures may limit ulceration, infection, and other secondary complications.

**Rutherford RB:** Noninvasive evaluation for congenital arteriovenous fistulas and malformations. *Semin Vasc Surg* 2012; 25(1):49–57.

**Scruggs J, et al:** Cutaneous manifestations of abdominal arteriovenous fistulas. *Cutis* 2011; 87(6):284–286.

### Prominent inferior labial artery

The arteries supplying the lips are normally tortuous to accommodate the movements of the mouth. Howell and Freeman reported a potentially troublesome arterial anomaly of the lower lip characterized by the appearance of a pulsating papule in the lower vermilion, 1 or 2 cm from the oral commissure, formed by an especially tortuous segment of the inferior labial artery. A similar anomaly may involve the upper lip. Caliber-persistent labial artery may be misdiagnosed as squamous cell carcinoma, and the biopsy may produce significant bleeding. On the lip, it is best to “palpate for pulsation prior to puncture.”



**Fig. 28-6** Superficial lymphatic malformation adjacent to café au lait macule.

### Acral arteriolar ectasia

Paslin and Heaton reported a man with purple serpiginous ectatic arterioles on the backs of his fingers, which appeared in the fifth decade of life.

**Howell JB, Freeman RG:** The potential peril from caliber-persistent arteries of the lips. *J Am Acad Dermatol* 2002; 46:256.

**Paslin DA, Heaton CL:** Acral arteriolar ectasia. *Arch Dermatol* 1972; 106:906.

### Superficial lymphatic malformation (lymphangioma circumscriptum)

The old term for superficial lymphatic malformation was lymphangioma circumscriptum; however, this is not a tumor but rather a congenital malformation of the superficial lymphatics. A superficial lymphatic malformation presents as groups of deep-seated, vesiclelike papules (Fig. 28-6), resembling frog spawn, at birth or shortly thereafter. The lesions are usually yellowish but may be pink, red, or dark. When the papules are punctured, they exude clear, colorless lymph. The papules are arranged irregularly in groups that may be interconnected by sparsely scattered lymph cysts. The entire process, however, as a rule is localized to one region. The sites of predilection are the abdomen, axillae, genitalia, and mouth, particularly the tongue. The scrotum is subject to multifocal lymphatic malformations presenting as clear, thick-walled, vesiclelike lesions. At times, the surface is verrucous, in which case the color may be brownish, and the lesions may be mistaken for warts. Lesions resembling molluscum contagiosum have also been described.

Frequently, the lesions consist of a combination of blood and lymph elements, so that purple areas are sometimes seen scattered within the vesiclelike papules. The lesions are also frequently associated with a deep component that occupies the subcutaneous tissues and muscles. Over time, these lymphatic malformations show only slight changes.

As with angiokeratomas, lymphangiomas may be seen adjacent to café au lait macules. This may represent a twin spotting phenomenon. Acquired lesions occur in the setting of chronic

lymphedema. Lesions occurring after radiation therapy overlap with atypical vascular lesion (AVL). A peculiar penicillamine-induced dermatopathy may result from damage to the underlying supporting structures of the dermis and allow dilation of lymph vessels within areas of trauma, such as the dorsal hands and knees. Central facial involvement may be seen in variegate porphyria, and sites of chronic high-potency steroid application may develop lymphangiectasia.

Excision and grafting, fulguration, or coagulation is frequently unsatisfactory because of recurrences resulting from vascular connections between the surface lesions and deep-seated lymphatic cisterns. The deeper component should be evaluated by MRI or other suitable radiologic imaging to delineate the extent of deep involvement before planned procedures. Vaporization with the carbon dioxide (CO<sub>2</sub>) laser may be successful if deeper components are not present. Pulsed dye laser, intense pulse light systems, sclerosants, and electro-surgical techniques have also been reported as effective. Keloid formation has been described after laser vaporization of genital lymphangiomas. Sclerotherapy has been reported as successful, and radiotherapy has been used successfully in select refractory cases.

**Emer J, et al:** A case of lymphangioma circumscriptum successfully treated with electrodesiccation following failure of pulsed dye laser. *Dermatol Online J* 2013; 19(3):2.

**Kupetsky EA, Pugliano-Mauro M:** Lymphangioma circumscriptum: sodium tetradecyl sulfate 0.1% versus hypertonic saline. *Dermatol Surg* 2014; 40(8):928–930.

**Yang X, et al:** Highly selective electrocoagulation therapy: an innovative treatment for lymphangioma circumscriptum. *Dermatol Surg* 2014; 40(8):899–905.

## Cystic lymphatic malformation

Cystic lymphatic malformations are deep-seated, typically multilobular, poorly defined, soft tissue masses that are painless and covered by normal skin. They are most common in the oral cavity and on the extremities and have been described in Mafucci syndrome. Cystic hygromas are clinically better circumscribed, occurring usually in the neck (Fig. 28-7), axilla, or groin. The posterior neck lesions may be associated with Turner syndrome, other chromosomal aneuploidy conditions, hydrops fetalis, or other congenital abnormalities. Cytogenetic analysis of children born with cystic hygromas is indicated, because aneuploidy may recur in subsequent pregnancies. Transabdominal or transvaginal sonography can visualize these lesions

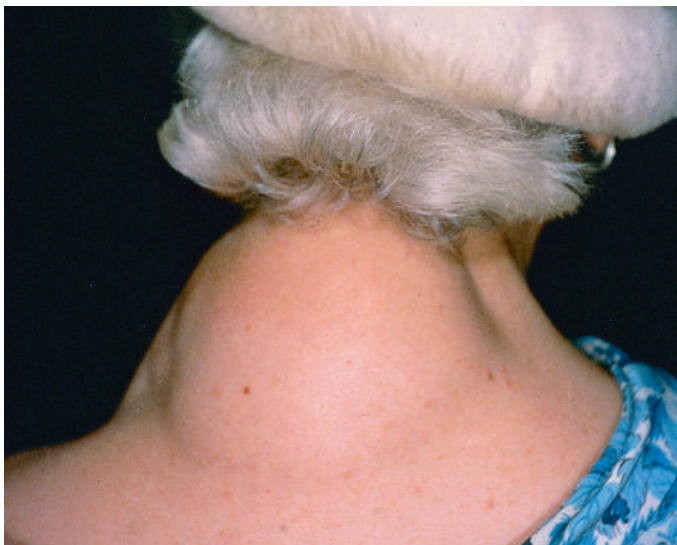

Fig. 28-7 Cystic hygroma.

in utero. Usually, the lesions will recur after surgical treatment because of their depth, but injection sclerotherapy with agents such as OK-432 (picibanil) may result in regression. Sildenafil has been reported as an effective nonsurgical treatment in the setting of pediatric orbital lymphangioma.

**Gandhi NG, et al:** Sildenafil for pediatric orbital lymphangioma. *JAMA Ophthalmol* 2013; 131(9):1228–1230.

**Guruprasad Y, et al:** Cervical cystic hygroma. *J Maxillofac Oral Surg* 2012; 11(3):333–336.

## Lymphangiomatosis

Diffuse or multifocal dilated lymphatic channels involving the skin, soft tissues, bone, and parenchymal organs are a rare congenital condition. If an extremity is affected, the prognosis is good; however, when vital internal organs are involved, the prognosis is poor. Skin lesions are presenting signs in 7% of patients with thoracic lymphangiomatosis. These patients have a high incidence of complications, including chylothorax (49%), pulmonary infiltrates (45%), bone lesions (39%), splenic lesions (19%), cervical involvement (15%), and disseminated intravascular coagulation (9%). Splenic lymphangiomatosis has been associated with Proteus syndrome. Diffuse pulmonary lymphangiomatosis has been successfully treated with bevacizumab.

## Gorham-Stout syndrome

Gorham-Stout syndrome is characterized by lymphangiomatosis and chylous effusions, with osteolytic changes resulting in “vanishing bones.” Response to pegylated interferon (IFN) alfa-2b was noted in a 9-year-old boy with systemic disease. Response to bisphosphonates has also been noted.

**Al-Jamali J, et al:** Gorham-Stout syndrome of the facial bones: a review of pathogenesis and treatment modalities and report of a case with a rare cutaneous manifestations. *Oral Surg Oral Med Oral Pathol Oral Radiol* 2012; 114(6):e23–e29.

**Aman J, et al:** Successful treatment of diffuse pulmonary lymphangiomatosis with bevacizumab. *Ann Intern Med* 2012; 156(11):839–840.

**Nikolaou VS, et al:** Vanishing bone disease (Gorham-Stout syndrome): a review of a rare entity. *World J Orthop* 2014; 5(5):694–698.

## Dilation of preexisting vessels

### Spider angioma (vascular spider, spider nevus, nevus araneus)

The lesion of spider angioma is suggestive of a red spider. The ascending central arteriole represents the “body” of the spider, and the radiating fine vessels suggest the multiple legs. These small telangiectases occur singly or severally, most frequently on the face and neck, with decreasing frequency on the upper trunk and upper extremities. In young children, the sites of predilection are the backs of the hands and forearms and the face.

Young children and pregnant women show these lesions most frequently. In pregnant women, palmar erythema is usually present with the vascular spiders. The presence of vascular spiders in otherwise healthy children is common.

Vascular spiders also occur in patients with cirrhosis, hepatitis C, malignant disease of the liver, and other hepatic dysfunctions. The common denominator has been shown to be an elevated blood estrogen level. Elevations in VEGF and basic fibroblastic growth factor are also significant predictors for spider angiomas in cirrhotic patients. When vascular spiders occur with palmar erythema and pallid nails with distal



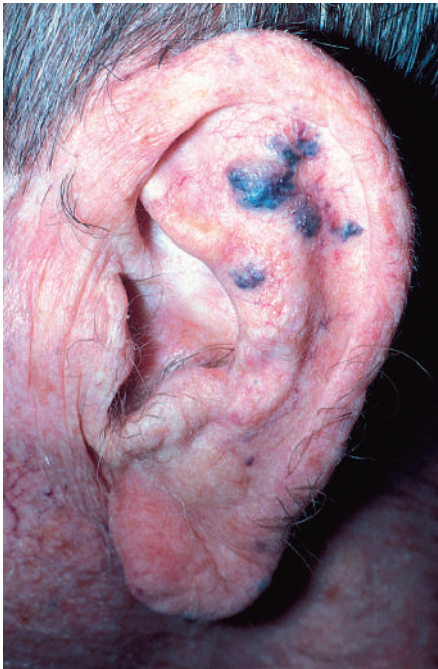

Fig. 28-8 Venous lake.

hyperemic bands, cirrhosis of the liver should be considered. AV hemangioma has also been reported to be associated with chronic liver disease.

The vascular spiders of childhood usually involute without treatment, although several years may elapse before this occurs. In pregnant women, most lesions will involute soon after delivery. If active therapy will be performed, either obliteration by electrodesiccation of the central punctum or laser treatment can produce good results.

### Venous lakes

Venous lakes (phlebectases) are small, dark-blue, slightly elevated blebs (Fig. 28-8). They are easily compressed and are located on the face, ears, lips, neck, forearms, and backs of the hands. These manifestations of chronic sun damage are extremely dilated, blood-filled spaces lined with thin, elongated endothelial cells and usually surrounded by prominent solar elastosis. Venous lakes may be treated by light electrocautery, laser ablation, fulguration, infrared coagulation, intralesional injection of 1% polidocanol, and cryotherapy.

### Capillary aneurysms

These flesh-colored solitary lesions, resembling an intradermal nevus, may suddenly grow larger and darker and become blue-black or black as a result of thrombosis. Capillary aneurysms are surrounded by a zone of erythema. The lesions may be clinically indistinguishable from malignant melanoma. Histologically, these are thrombotic, dilated capillaries lying just below the epidermis. Shave excision in stages will expose the clot and eliminate the uncertainty.

### Telangiectasia

Telangiectases are fine, linear vessels coursing on the surface of the skin; collectively, they are named telangiectasia. Telangiectasia may occur in normal skin at any age, in both genders, and anywhere on the skin and mucous membranes. Fine telangiectases may be seen on the alae nasi of most adults. They are prominent in areas of chronic actinic damage seen in fair-skinned persons. Persons long exposed to wind, cold, or heat are also subject to telangiectasia.

Telangiectases can be found in such conditions as radiodermatitis, xeroderma pigmentosum, lupus erythematosus (LE), dermatomyositis, scleroderma and the CREST syndrome, rosacea, cirrhosis of the liver, acquired immunodeficiency syndrome (AIDS), poikiloderma, basal cell carcinoma, necrobiosis lipoidica diabetorum, sarcoid, lupus vulgaris, adenoma sebaceum, keloid, angioma serpiginosum, angiokeratoma corporis diffusum, ataxia-telangiectasia, pregnancy, Osler-Weber-Rendu disease, and Bloom syndrome. These entities are discussed in other sections with the disease states in which they occur.

Altered capillary patterns on the fingernail folds (cuticular telangiectases) are indicative of collagen vascular disease, such as LE, scleroderma, or dermatomyositis. Tortuous glomeruloid loops are characteristic of LE, whereas dilated loops and avascular areas are typical of scleroderma and dermatomyositis. Reticular telangiectatic erythema may occur overlying implantable cardioverter-defibrillators.

Electrodesiccation and laser ablation can be effective. Pulsed dye laser and other vascular lasers, such as the 532-nm Nd:YAG laser, are usually well tolerated and associated with a low risk of scarring. Larger vessels require a longer pulse duration. Contact or cryospray cooling can reduce the incidence of complications. Pulse stacking (multiple pulses of low fluences) has been used to reduce the incidence of side effects, such as purpura, hyperpigmentation, hypopigmentation, and scar formation.

### Generalized essential telangiectasia

Generalized essential telangiectasia (GET) is characterized by the dilation of veins and capillaries over a large segment of the body without preceding or coexisting skin lesions. The telangiectases may be distributed over the entire body or localized to some large area, such as the legs, arms, and trunk. The lesions may be discrete or confluent. Distribution along the course of the cutaneous nerves may occur. This type of telangiectasia is rarely associated with systemic disease, although patients with a similar appearance may have autoimmune disease. One report documented GI bleeding from a "watermelon" stomach in a woman with GET.

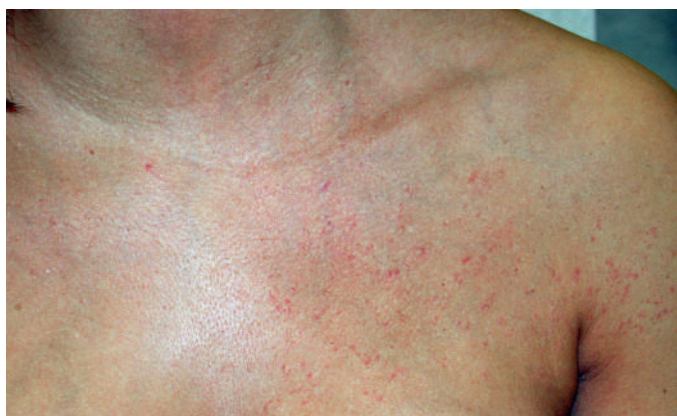Most frequently, GET develops in women in their forties and fifties. The initial onset is on the lower legs and then spreads to the upper legs, abdomen, and arms. The dilations persist indefinitely. Generally, this is a sporadic condition, although it has been described in families as an autosomal dominant trait, in which case it has been termed hereditary benign telangiectasia.

It has been reported that GET may be differentiated from telangiectasia associated with systemic disease by assessing alkaline phosphatase activity. Telangiectatic vessels in GET do not have alkaline phosphatase activity in the endothelium of the terminal arteriole and the arterial portion of the capillary loops.

Individual areas may be treated with laser ablation. High-energy, high-frequency, long-pulse Nd:YAG laser and the 585 nm flashlamp-pumped pulsed dye laser have been reported to produce good results. Tetracycline, ketoconazole, and treatment of a chronic sinus infection have led to involution in individual reports.

### Universal angiomas

Universal angiomas, called "generalized telangiectasia" by Bean, is a bleeding disease that affects the blood vessels of the skin and mucous membranes, as well as other parts of the body. Bean and Rather reported a 13-year-old boy who had frequent nosebleeds and ear and upper respiratory infections.



**Fig. 28-9** Unilateral nevoid telangiectasia.

He had mottled skin, with redness that blanched on pressure. Finely dilated blood vessels were universal, suggesting the term “pink man.” Some irregular white patches were also present. Continual bleeding into the skin was evident despite normal coagulation of the blood. This type of angiomas differs from generalized telangiectasia because of its hemorrhagic tendency, especially epistaxis.

### Unilateral nevoid telangiectasia

In unilateral nevoid telangiectasia, fine, threadlike telangiectasias develop in a unilateral, sometimes dermatomal, distribution (Fig. 28-9). The areas most often involved are the trigeminal and C3 and C4 or adjacent areas, with the right side involved slightly more often than the left. In some cases the condition is congenital, but more often it is acquired. Increased estrogen appears to play a role in the onset of acquired cases (e.g., pregnancy, puberty in women, adrenarche in men), and hepatitis/alcohol-related cases have been reported. Lesions have responded to pulse dye laser treatment.

### Angiokeratomas

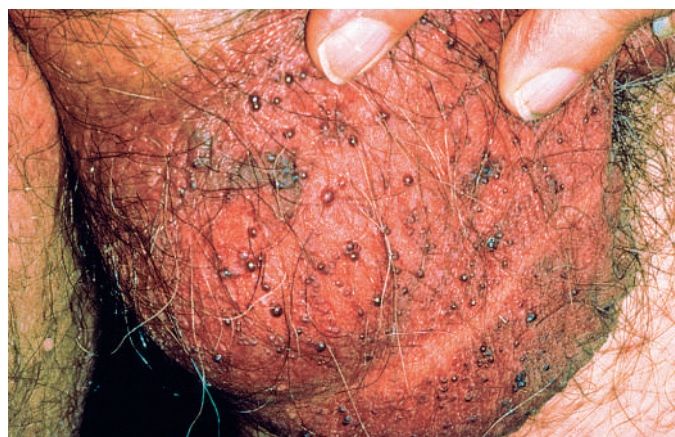Angiokeratomas are essentially telangiectases that have an overlying hyperkeratotic surface. Angiokeratoma corporis diffusum is discussed in Chapter 26.

### Angiokeratoma circumscriptum

Angiokeratoma circumscriptum is a malformation of dermal and subcutaneous capillaries and veins and is variably classified as a capillary or venous malformation. The vascular malformation is congenital. Over time, a verrucous component appears. The lesions are bluish red and well defined and occur mainly on the lower extremities, but also on the chest or forearm. Linear segmental lesions have been described. Associated spinal lesions (Cobb syndrome) have been reported. Klippel-Trenaunay syndrome has also been reported in association with verrucous vascular malformation. Superficial ablative therapy is typically followed by recurrence, regardless of whether ablation is performed by excision, laser, cryotherapy, or electrocautery. In contrast, full-thickness excision is generally effective and may be used in combination with laser therapy.

### Angiokeratoma of Mibelli

The lesions of angiokeratoma of Mibelli consist of 1–5 mm red vascular papules, the surfaces of which become hyperkeratotic



**Fig. 28-10** Fordyce angiokeratomas.

over time. The papules are dull red or purplish black, verrucous, and rounded and are usually situated on the dorsum of the fingers and toes, the elbows, and the knees. Frequently, these are called telangiectatic warts. The patient often has cold, cyanotic hands and feet. Autosomal dominant inheritance has been described, and an association with chilblains is common. The condition is most frequently discovered in prepubertal children.

Histologically, hyperkeratosis, increased thickness of the granular layer, and dilation of the subpapillary vessels to form lacunae are the chief features.

The differential diagnosis of angiokeratomas of the dorsal hands in children includes acral pseudolymphomatous angiokeratoma in children (APACHE). However, APACHE is unilateral and sporadic in nature, without associated cold sensitivity; histologic examination reveals a dense, nodular, lymphohistiocytic infiltrate with occasional plasma cells, eosinophils, and multinucleated giant cells. It is a variant of pseudolymphoma and not primarily a vascular lesion. Similar lesions may occur in adolescents and adults, and the terms acral angiokeratoma-like pseudolymphoma and T-cell-rich angiomatoid polypoid pseudolymphoma of the skin have been used to describe these varied presentations.

Angiokeratoma may be treated with electrocautery, fulguration, CO<sub>2</sub> laser ablation, long-pulse vascular laser therapy, or cryotherapy, with fairly good results.

### Angiokeratoma of the scrotum (Fordyce)

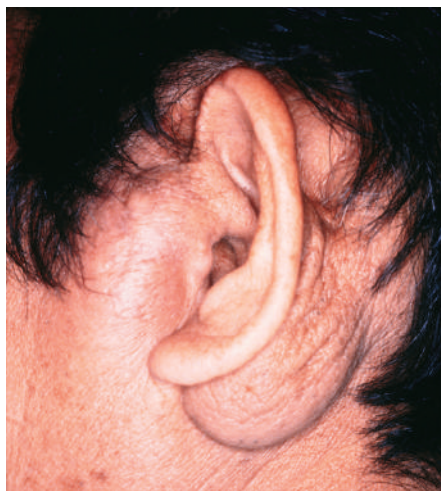The angiomas are multiple small vascular papules that stud the scrotum (Fig. 28-10) and sometimes the vulva in middle-age and elderly individuals. There is often a diffuse redness of the involved area that may be a source of concern to the patient. Urethral or clitoral lesions may also be seen. Infrequently, the keratotic part may be involuntarily scratched off to produce considerable bleeding. Rarely, the lesions may bleed spontaneously. Histologically, the many communicating lacunae in the subpapillary layer are lined with endothelium and connected underneath by dilated veins. Treatment is best accomplished by shave excision, cautery, laser ablation, or fulguration of troublesome lesions. The primary therapy is reassurance.

**Brown KR, et al:** Superficial venous disease. *Surg Clin North Am* 2013; 93(4):963–982.

**Dayrit JF, et al:** T-cell-rich angiomatoid polypoid pseudolymphoma of the skin: a clinicopathologic study of 17 cases and a proposed nomenclature. *J Cutan Pathol* 2011; 38(6):475–482.

**Turan H, et al:** Acquired unilateral nevoid telangiectasia syndrome accompanied by chronic hepatitis B virus infection. *Acta Dermatovenerol Croat* 2013; 21(2):133–134.





**Fig. 28-11** Kimura's disease. (Courtesy of Department of Dermatology, Keio University School of Medicine.)

**Wang L, et al:** Solitary angiokeratoma on palms and soles: a clinicopathological analysis of 21 cases. *J Dermatol* 2013; 40(8):653–656.

**Zeng Y, et al:** Treatment of angiokeratoma of Mibelli alone or in combination with pulsed dye laser and long-pulsed Nd:YAG laser. *Dermatol Ther* 2014; 27(6):348–351.

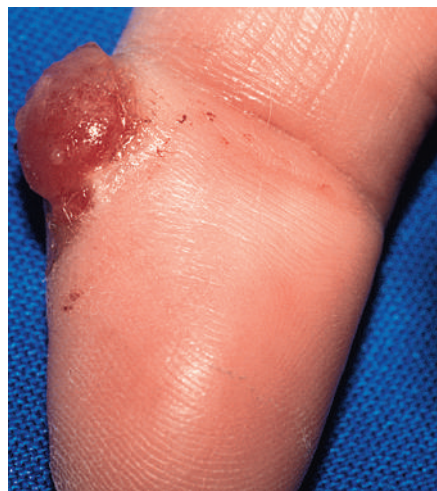## Hyperplasias

### Angiolymphoid hyperplasia with eosinophilia

Patients with angiolymphoid hyperplasia with eosinophilia (ALHE) usually present with pink to red-brown, dome-shaped, dermal papules or nodules of the head or neck, especially in the retroauricular area and elsewhere on the scalp. ALHE may also occur in the mouth and on the trunk, extremities, penis, and vulva. Grouped lesions merge to form plaques or grape-like clusters. There is a female preponderance, and the average age of onset is 32 years. Symptoms can include pain or pruritus, which may occur after trauma. An underlying AV shunt is present as a result of damage to and repair of an artery or vein. Histologically, central thick-walled vessels with hobnail endothelium are noted. Surrounding hyperplasia of smaller vessels and nodular lymphoid aggregates with eosinophils are present.

Lesions do not spontaneously regress. Treatment with surgical excision is successful in 65% of cases. The lesions may recur if the underlying AV shunt is not excised. Intralesional corticosteroids, pulsed dye laser therapy with conventional or ultralong pulsed systems, Nd:YAG laser, cryotherapy, pentoxifylline, indomethacin, imiquimod, and electrodesiccation have been successful in some patients. Difficult cases have been controlled with IFN alfa-2b, isotretinoin, or vinblastine, and partial responses to intralesional bleomycin have been reported.

It is important to distinguish ALHE from Kimura's disease (Fig. 28-11). Kimura's disease is an inflammatory disorder that presents as massive subcutaneous swelling in the periauricular and submandibular region in young Asian men. Histologically, prominent germinal centers with eosinophils are present in the subcutaneous tissue. Although blood vessels are abundant, changes are less prominent than in ALHE. Additionally, Kimura's disease is associated with allergic conditions such as asthma, rhinitis, and eczema, and it is frequently accompanied by lymphadenopathy, peripheral blood eosinophilia, and elevated IgE level. Although clonal T-cell gene rearrangement has been reported in both ALHE and Kimura's disease, heteroduplex polymerase chain reaction (PCR) has disproved



**Fig. 28-12** Pyogenic granuloma.

clonality in some cases positive on conventional PCR. Coexistence of ALHE and peripheral T-cell lymphoma has been reported.

**Akdeniz N, et al:** Intralesional bleomycin for angiolymphoid hyperplasia. *Arch Dermatol* 2007; 143(7):841–844.

**Carlesimo M, et al:** Angiolymphoid hyperplasia with eosinophilia treated with isotretinoin. *Eur J Dermatol* 2007; 17(6):554–555.

**Choi JE, et al:** Successful treatment of Kimura's disease with a 595-nm ultra-long pulsed dye laser. *Acta Derm Venereol* 2008; 88(3):315–316.

**Griauzde J, Srinivasan A:** Imaging of vascular lesions of the head and neck. *Radiol Clin North Am* 2015; 53(1):197–213.

**Hoff SR, et al:** Head and neck vascular lesions. *Otolaryngol Clin North Am* 2015; 48(1):29–45.

## Pyogenic granuloma

A pyogenic granuloma is a small, eruptive, usually solitary, sessile or pedunculated, friable papule (Fig. 28-12). The lesion is common in children but may occur at any age. It occurs most often on an exposed surface: on the hands, forearms, or face, or at sites of trauma. The lesion also occurs in the mouth, especially on the gingiva, most often in pregnant women (granuloma gravidarum). On the sole of the foot or nail bed, it may be mistaken for a melanoma. Pyogenic granulomas bleed easily on the slightest trauma and, if cut off superficially, promptly recur. Recurring lesions may have one or many satellite lesions.

Pyogenic granulomas may be seen in patients treated with isotretinoin, capecitabine, vemurafenib, or indinavir. Isotretinoin treatment of acne vulgaris can be complicated by numerous exuberant pyogenic granuloma-like lesions of the trunk or periungual lesions. Some data suggest that patients with pyogenic granuloma have a statistically higher prevalence of *Bartonella* seropositivity compared with controls, but a definite etiologic role has not been established.

Histologically, pyogenic granuloma is a lobular capillary hemangioma, with lobules separated by connective tissue septa. With time, the epidermis becomes thinned, then eroded. Heavy secondary staphylococcal colonization is common. Intravascular pyogenic granuloma appears as a lobular capillary proliferation within a vein.

Treatment is by curettage or shave excision, followed by destruction of the base by fulguration or silver nitrate. Silver nitrate alone may be sufficient to treat smaller lesions. Topical timolol, imiquimod under occlusion, and sclerotherapy with monoethanolamine oleate or sodium tetra decyl sulfate have been used successfully. At times, a recalcitrant lesion may require excision or laser ablation. The drug-induced variety

will regress after lowering of the dose or discontinuation of the medication. Systemic corticosteroids have been used to treat recurrent giant pyogenic granulomas.

**Samatha Y, et al:** Management of oral pyogenic granuloma with sodium tetra decyl sulphate: a case series. *NY State Dent J* 2013; 79(4):55–57.

**Sammot SJ, et al:** Pyogenic granuloma as a cutaneous adverse effect of vemurafenib. *N Engl J Med* 2014; 371(13):1265–1267.

### Intravascular papillary endothelial hyperplasia

Masson described this intravascular papillary proliferation that may mimic angiosarcoma. The lesions appear as red or purplish, 5-mm to 5-cm papules or deep nodules on the head, neck, or upper extremities. The condition represents recanalization of a thrombosed vessel. Histologic examination reveals intravascular papillary projections lined by endothelial cells. Thrombi may still be present, and the papillary projections may have a fibrinous or hyaline core. High-resolution ultrasound imaging may be useful in establishing the diagnosis, although the diagnosis is usually made by biopsy. Excision is curative.

**Kim TH, et al:** Intravascular papillary endothelial hyperplasia (Masson's tumour) in the vulva. *Eur J Obstet Gynecol Reprod Biol* 2013; 169(2):413–414.

### Angioma serpiginosum

Angioma serpiginosum, first described by Hutchinson in 1889, is characterized by minute, copper-colored to bright-red angiomatous puncta that tend to become papular. These puncta occur in groups, which enlarge through the constant formulation of new points at the periphery, whereas those at the center fade. In this manner, linear arrays, small rings, or serpiginous patterns are formed. No purpura is present, but a netlike or diffuse erythema forms the background. In the areas undergoing involution, a delicate tracery of rings and lines, a fine desquamation, and at times a semblance of atrophy are seen. Slight lichenification and scaling may be evident in the papular lesions. The eruption predominates on the lower extremities. Although it affects both genders at all ages, 90% of cases occur in girls under 16. It is usually slowly progressive and chronic, and although involution may occur, it is probably never complete. Treatment with a pulsed dye laser will improve or eliminate such lesions. Angioma serpiginosum following Blaschko's lines, with associated esophageal papillomatosis, has been reported as an X-linked dominant condition with mild features of Goltz-Gorlin syndrome, including hair and nail dystrophy. The condition maps to Xp11.3–Xq12.

Angioma serpiginosum must be differentiated from the progressive pigmentary disease of Schamberg. In the latter, pinpoint areas of purpura, the so-called cayenne pepper spots, form macules that tend to coalesce and form diffusely pigmented patches. The pigment is hemosiderin. Purpura annularis telangiectodes (Majocchi) is often bilateral and is characterized by acute outbreaks of telangiectatic points that spread peripherally and form small rings. In lichenoid purpuric and pigmentary dermatosis of Gougerot and Blum, the primary lesion is a minute, lichenoid, reddish brown papule that is sometimes hemorrhagic. It has a tendency toward central involution and residual pigmentation.

In angioma serpiginosum, the most important histologic finding is dilated and tortuous capillaries in the dermal papillae and the upper dermis. No inflammatory infiltrate or extravasation of red blood cells is observed. The dilated capillaries show no alkaline phosphatase activity, in contrast to normal capillaries.

**Blinkenberg EO, et al:** Angioma serpiginosum with oesophageal papillomatosis is an X-linked dominant condition that maps to Xp11.3–Xq12. *Eur J Hum Genet* 2007; 15(5):543–547.

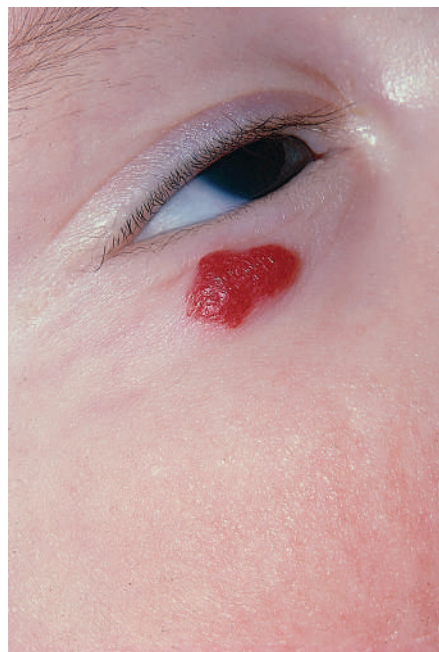**Marks V, et al:** Reflectance confocal microscopy features of angioma serpiginosum. *Arch Dermatol* 2011; 147(7):878.

## Benign neoplasms

### Infantile hemangioma (strawberry hemangioma)

Strawberry (capillary) hemangiomas, the most common benign tumors of childhood, are present at birth in one third of cases. The remainder appear shortly thereafter. Sixty percent are on the head and neck, but they may occur anywhere. The dome-shaped lesion is dull to bright red, and when involution begins, streaks or islands of white appear in the lesion as it flattens. The lesions have sharp borders; they are soft and easily compressed (Fig. 28-13). Generally, they tend to grow over the first year or so, remain stable for a period of months, and then slowly involute spontaneously. The period of greatest growth is the first 5 months. Ulceration occurs in almost 16% of lesions, usually by 4 months of age. Approximately 30% resolve by the third year, 50% by age 5, and 70% by 7 years of age. The skin may appear normal after involution, but more often, atrophy, telangiectasia, or anetoderma-type redundancy is present.

The majority of these lesions occur sporadically, but kindreds with autosomal dominant inheritance of infantile hemangiomas and/or vascular malformations have been described. Large segmental hemangiomas of the skin may be associated with visceral hemangiomatosis involving the liver, GI tract, lung, brain, and mediastinum. Facial segmental hemangiomas are associated with PHACE syndrome; proposed by Frieden et al. in 1996, PHACE denotes the association of posterior fossa brain malformations (primarily the Dandy-Walker malformation), hemangiomas, arterial anomalies, coarctation of the aorta and other cardiac defects, and eye abnormalities. When sternal clefting and abdominal raphae are present, the designation PHACES is used. The hemangiomas frequently involve more than one dermatome. Flat, lumbar hemangiomas are often associated with occult spinal dysraphism. The acronym LUMBAR syndrome has been used to describe the association of lower body hemangioma, urogenital anomalies, myelopathy, bony deformities, anorectal malformations, arterial anomalies, and renal anomalies.



**Fig. 28-13** Infantile hemangioma.



Multiple hemangiomas, usually 1–10 mm in size, may appear in the first few weeks to months of life and in large numbers. If purely cutaneous, they generally involute without sequelae, and the term benign neonatal hemangiomatosis is applied. However, visceral lesions may be present in the CNS, lungs, liver, or other organs. When internal lesions are present, complications may occur, such as GI or CNS bleeding, high-output cardiac failure, obstructive jaundice, and respiratory failure; this results in high mortality among untreated patients. Preliminary screening includes stool guaiac test for occult blood (Hemoccult) and imaging of the liver. If either of these is positive, more extensive studies are indicated, with special attention to the thyroid and heart.

The pathogenesis of infantile hemangiomas is complex. CD133+ stem cells within the hemangioma differentiate into mature blood vessels that express GLUT-1, a glucose transporter normally restricted to endothelial cells with blood-tissue barrier function, as in brain and placenta. The vessels proliferate, then involute. Some suggest the stem cells could originate from placental trophoblast. Histologically, strawberry marks are composed of primitive endothelial cells similar to those found before the embryonic development of true venous channels. Ultrastructurally, they lack typical Weibel-Palade bodies but do have crystalloid inclusions typical of embryonic endothelium and stain for GLUT-1. They also stain for Fc- $\gamma$ -R2, Lewis Y antigen (LeY), and merosin. Young hemangiomas show evidence of endothelial progenitor cells that stain with CD133 and CD34. In late stages, the endothelium flattens, and the lumina are more apparent because of increased blood flow. In time, fibrosis becomes pronounced as involution progresses.

Simple observation may be appropriate for many hemangiomas, allowing the lesions to regress spontaneously. The so-called Cyrano defect, a hemangioma that causes the end of the nose to become bulbous, may be successfully approached surgically in many cases before the patient begins school. Additionally, surgical intervention in small, pedunculated hemangiomas and eyelid tumors may also be an excellent option. Compressive wraps may improve extremity hemangiomas.

Indications for pharmacologic intervention include severe hemorrhage, thrombocytopenia, threatened cardiovascular compromise from high-output cardiac failure, nasal or auditory canal obstruction, hepatic hemangiomatosis, skin ulceration, or threatened interference with vital functions, such as feeding, respiration, passage of urine or stool, limb function, tissue destruction, or vision. There is a risk of occlusion amblyopia, astigmatism, and myopia from periorbital hemangiomas. Additionally, strong consideration should be given to treatment of hemangiomas that may lead to permanent disfigurement or long-term psychological consequences, such as large hemangiomas of the ear, nose, glabellar area, or lips.

Beta blockers are used most frequently, but systemic treatment can be complicated by bradycardia or hypoglycemia, and regular feedings are critical before and during treatment. Rebound is common after discontinuation of  $\beta$ -blockers, and longer courses are now usually employed. Some hemangiomas respond to topical  $\beta$ -blockers. Intralesional corticosteroid treatment has been used but carries some risk of embolization and occlusion of ocular vessels. Injection regularly produces pressures exceeding the systemic arterial pressure, leading to possible embolization.

Oral prednisone at a dose of 2–4 mg/kg/day has also been used for infantile hemangioma. In the 30% of patients who respond well to treatment, the enlarging hemangioma stops growing in 3–21 days. Ulcerations will heal within 2 weeks. The lesion will usually shrink if treatment is continued for 30–90 days. Laryngeal involvement and stridor, if present, are

usually dramatically relieved by treatment. Repeated courses of treatment may be undertaken if rebound of growth occurs on discontinuation of the steroidal agent. Some experts recommend prolonged low-dose oral corticosteroids over a 12-month period to prevent this rebound phenomenon. Treatment with recombinant interferon is rarely used because of the risk of spastic diplegia. Topical imiquimod, low-frequency ultrasound, and selective arterial embolization have also been used. Both Nd:YAG and potassium titanyl phosphate (KTP) lasers have been used to deliver intralesional therapy.

**Burne R, Taylor R:** Monitoring propranolol treatment in periocular infantile haemangioma. *Eye (Lond)* 2014; 28(11):1281–1285.

**Chamlin SL, et al:** Multicenter prospective study of ulcerated hemangiomas. *J Pediatr* 2007; 151(6):684–689; 689.e1.

**Hochman M:** Infantile hemangiomas: current management. *Facial Plast Surg Clin North Am* 2014; 22(4):509–521.

**Hoff SR, et al:** Head and neck vascular lesions. *Otolaryngol Clin North Am* 2015; 48(1):29–45.

**Iacobas I, et al:** LUMBAR: association between cutaneous infantile hemangiomas of the lower body and regional congenital anomalies. *J Pediatr* 2010; 157(5):795–801.e1–e7.

**McCuaig CC, et al:** Therapy of ulcerated hemangiomas. *J Cutan Med Surg* 2013; 17(4):233–242.

**Pope E, et al:** Oral versus high-dose pulse corticosteroids for problematic infantile hemangiomas: a randomized, controlled trial. *Pediatrics* 2007; 119(6):e1239–e1247.

**Shehata N, et al:** Late rebound of infantile hemangioma after cessation of oral propranolol. *Pediatr Dermatol* 2013; 30(5):587–591.

## Rapidly involuting congenital hemangioma and noninvoluting congenital hemangioma

Rapidly involuting congenital hemangioma (RICH) and noninvoluting congenital hemangioma (NICH) are rare GLUT-1-negative vascular tumors that present fully grown at birth and either involute rapidly or fail to involute. Whereas smooth muscle actin (SMA)-positive cells are common in the walls of infantile hemangiomas, they are rare in RICH. Children with RICH or NICH coexisting with infantile hemangioma have been described, as have children with partially involuting congenital hemangioma.

## Cherry angiomas (senile angiomas, de Morgan spots)

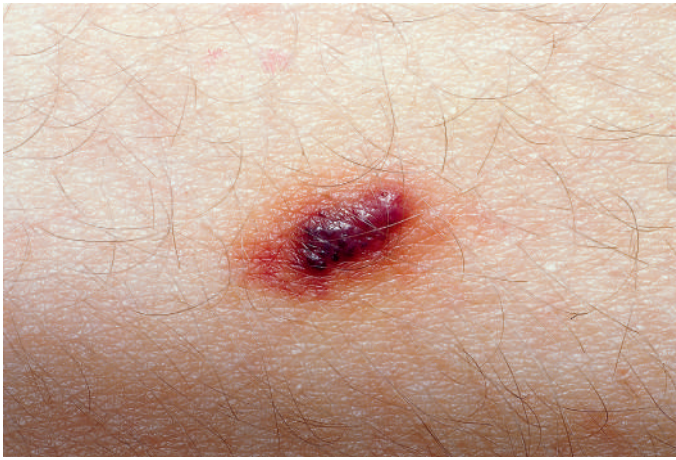These round, slightly elevated, ruby-red papules 0.5–6 mm in diameter are the most common vascular anomalies. It is a rare 30-year-old person who does not have a few, and the number increases with age. Probably every 70-year-old person has some senile angiomas. Most are on the trunk; they are rarely seen on the hands, feet, or face. Early lesions may mimic petechiae. When lesions are surrounded by a purpuric halo, amyloidosis should be suspected. Eruptive lesions have been described after nitrogen mustard therapy. Light electrodesiccation or laser ablation with intense pulsed light (IPL) and long-pulse Nd:YAG laser systems can be effective. Shave excision can also be performed, but most patients accept reassurance and do not request removal.

**Fodor L, et al:** A side-by-side prospective study of intense pulsed light and Nd:YAG laser treatment for vascular lesions. *Ann Plast Surg* 2006; 56(2):164–170.

**Ma HJ, et al:** Eruptive cherry angiomas associated with vitiligo: provoked by topical nitrogen mustard? *J Dermatol* 2006; 33(12):877–879.

## Targetoid hemosiderotic hemangioma

In 1988, Santa Cruz and Aronberg described a lesion characterized by a central brown or violaceous papule surrounded by



**Fig. 28-14** Targetoid hemosiderotic hemangioma.

an ecchymotic halo (Fig. 28-14). The term hobnail hemangioma has been proposed because many lesions are not targetoid. These acquired hemangiomas occur in the young to middle-age individuals and are present on the trunk or extremities. They likely represent trauma to a preexisting hemangioma, with thrombosis and subsequent recanalization. Histologically, a biphasic growth pattern is seen, with central, superficial, dilated vascular structures lined by prominent hobnail endothelial cells, and collagen-dissecting, narrow vessels in deeper parts of the lesion. The endothelial cells commonly stain for CD31, but not CD34. D2-40 staining suggests lymph-angiomatous proliferation.

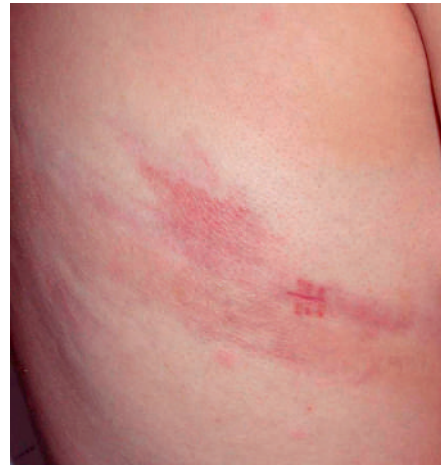**Gutte RM, Joshi A:** Targetoid hemosiderotic hemangioma. *Indian Dermatol Online J* 2014; 5(4):559–560.

### Glomeruloid hemangioma

Glomeruloid hemangioma is a distinctive benign vascular neoplasm first described in 1990 and reported in patients with POEMS (Crow-Fukase) syndrome and Castleman's disease. Some have also been associated with idiopathic thrombocytopenic purpura and Sjögren syndrome. Similar lesions have been reported in patients who are otherwise healthy.

The POEMS syndrome consists of polyneuropathy (severe sensorimotor), organomegaly (heart, spleen, kidneys), endocrinopathy, M component (M protein, monoclonal gammopathy), and skin changes (hyperpigmentation, hypertrichosis, thickening, sweating, clubbed nails, leukonychia, angiomas). Small, firm, red to violaceous papules appear on the trunk and proximal extremities in approximately one third of patients. Histologically, the lesions may be microvenular hemangiomas, cherry angiomas, multinucleated cell angiohistiocytes, or glomeruloid hemangiomas. The latter consist of ectatic vascular structures containing aggregates of capillary loops within a dilated lumen, simulating the appearance of a renal glomerulus. Sequestered degenerating red blood cells are a characteristic finding. Two types of endothelial cell have been noted within the lesions: a capillary-type endothelium with large vesicular nuclei, open chromatin pattern, and a large amount of cytoplasm; and sinusoidal endothelium with small basal nuclei, dense chromatin, and scant cytoplasm. Lesions associated with POEMS syndrome demonstrate increased expression of VEGF and its receptor, Flt-1.

**Jacobson-Dunlop E, et al:** Glomeruloid hemangiomas in the absence of POEMS syndrome. *J Cutan Pathol* 2012; 39(4):402–403.



**Fig. 28-15** Tufted angioma.

### Microvenular hemangioma

The recently described microvenular hemangioma is an acquired, benign vascular neoplasm that presents as an asymptomatic, slowly growing, 0.5–2.0 cm, reddish lesion on the forearms or other sites of young to middle-age adults. Multiple and eruptive variants have been described. Dermoscopic examination reveals multiple, well-demarcated, red globules. Monomorphous, elongated blood vessels with small lumina involve the entire reticular dermis. In many areas, the endothelial cells are surrounded by pericytes. The endothelial cells are podoplanin (D2-40) negative. GLUT-1 may be focally positive. The main differential diagnosis is Kaposi sarcoma. Along with glomeruloid hemangioma, microvenular hemangioma may sometimes be present in POEMS syndrome.

**Linos K, et al:** Microvenular hemangioma presenting with numerous bilateral macules, patches, and plaques: a case report and review of the literature. *Am J Dermatopathol* 2013; 35(1):98–101.

**Trindade F, et al:** Microvenular hemangioma: an immunohistochemical study of 9 cases. *Am J Dermatopathol* 2012; 34(8):810–812.

### Tufted angioma (angioblastoma)

The tufted angioma lesion usually develops in infancy or early childhood on the neck and upper trunk. Adult onset has also been described. The lesions present as poorly defined, dull-red macules with a mottled appearance, varying from 2 to 5 cm in diameter. Some show clusters of smaller angiomatous papules superimposed on the main macular area (Fig. 28-15), and associated hypertrichosis has been noted. The lesions are usually sporadic, although familial cases have been reported. Histologic examination reveals small, circumscribed angiomatous tufts and lobules scattered in the dermis in a so-called cannonball pattern. Tumors with features of both tufted angioma and kaposiform hemangioendothelioma (KHE) have been described, and transformation between the tumors has also been noted. Immunostaining can be helpful in distinguishing these tumors. Tufted angioma is characterized by a proliferation of CD34+ endothelial cells with few actin-positive cells. KHE shows CD34 staining only in the luminal endothelial cells. In infantile hemangiomas, actin-positive cells outnumber CD34+ cells.

Most lesions slowly extend with time, being progressive but benign in nature. Occasional spontaneous regression is documented; however, treatment with low-dose aspirin, pulsed dye laser, IPL, excision, high-dose corticosteroids, radiation,



vincristine, and propranolol has been successful. Lesions associated with Kasabach-Merritt syndrome have also been treated with embolization, prednisone, and vincristine.

The term angioblastoma has also been used for a rare pediatric tumor often associated with destruction of regional structures, including bone. Basic fibroblast growth factor has been reported to be elevated, and some patients have responded to treatment with IFN alfa-2b.

**Fahrtash F, et al:** Successful treatment of kaposiform hemangioendothelioma and tufted angioma with vincristine. *J Pediatr Hematol Oncol* 2010; 32(6):506–510.

**Jawaji S, et al:** Response of tufted angiomas to low-dose aspirin. *Pediatr Dermatol* 2013; 30(1):124–127.

**Sabharwal A, et al:** Acquired tufted angioma of upper lip: case report and review of the literature. *Head Neck Pathol* 2013; 7(3):291–294.

**Wang L, et al:** Congenital disseminated tufted angioma. *J Cutan Pathol* 2013; 40(4):405–408.

**Yamamoto Y, et al:** Successful treatment of tufted angioma with propranolol. *J Dermatol* 2014; 41(12):1120–1122.

## Kaposiform hemangioendothelioma

Kaposiform hemangioendothelioma (KHE) is an uncommon vascular tumor that affects infants and young children. Rare cases have been reported in adults. It was first designated KHE in 1993. Although it frequently occurs in the retroperitoneum, KHE may present as multinodular soft tissue masses, purpuric macules, plaques, and multiple telangiectatic papules. The lesions extend locally and usually involve the skin, soft tissues, and even bone. The cutaneous variant may be associated with lymphangiomas. KHE is locally aggressive and may be complicated by platelet trapping and consumptive coagulopathy (Kasabach-Merritt syndrome), but distant metastases have not yet been reported. It has also been reported in association with Milroy-Nonne disease (primary hereditary lymphedema).

Histologically, there are combined features of cellular infantile hemangioma and Kaposi sarcoma. Additionally, in some tumors, lymphangiomas is seen sharply separated from the vascular lesion. There is a multilobular appearance that closely resembles that of tufted angioma, but in KHE, lesions are larger and less circumscribed and involve the deep soft tissue and even bone. Transition between these tumors has been described. The transcription factor Prox-1 has been shown to induce proliferation and deep extension in a mouse model of the disease.

The prognosis depends on the depth and location of the lesion. Significant morbidity and mortality may result from compression and invasion of surrounding structures. If localized to the skin, lesions may be successfully excised. However, because of their tendency for deep and infiltrative growth, this is usually not possible. A response to  $\beta$ -blockers has been noted in only about one third of patients, and a combination of systemic corticosteroids and vincristine, either agent alone, or rapamycin is often necessary. Low-dose radiation and alcohol injection have also been used for KHE patients, and the combination of vincristine, aspirin, and ticlopidine has been given in the setting of Kasabach-Merritt syndrome.

## Kasabach-Merritt syndrome (hemangioma with thrombocytopenia)

Kasabach-Merritt syndrome (KMS) is seen in infants at an average age of 7 weeks. Before the onset of the acute event, the infant will often have a reddish or bluish plaque or tumor on the limb or trunk, or in rare instances, no visible lesion at all. The lesions usually have an associated lymphatic component, and most are KHEs. KMS also occurs in tufted angiomas

and multifocal lymphangioendotheliomatosis, lesions that both demonstrate lymphatic differentiation. KMS is rarely reported in association with capillary hemangiomas or angiosarcoma. Some patients with venous malformations will have a chronic low-grade consumptive coagulopathy that occurs throughout life, and this should not be confused with KMS.

Infants with KMS suddenly develop a painful violaceous mass in association with purpura and thrombocytopenia. The most striking sign is the bleeding tendency, especially in the hemangioma itself or into the chest or abdominal cavities. The spleen may be enlarged. Hemoglobin, platelets, fibrinogen, and factors II, V, and VIII are all reduced. Prothrombin time and partial thromboplastin time are prolonged, and fibrin split products may be elevated. Cases of microangiopathic hemolytic anemia have also been described. Repeated episodes of bleeding may occur, and although these may be spontaneous, bleeding can be precipitated by surgery, directed either at the hemangioma or elsewhere. The mortality may be as high as 30%, with most deaths secondary to bleeding complications.

Because KMS may be a self-limited disorder, expectant observation may be the best approach initially. Systemic corticosteroids, IFN alfa-2a, vincristine, vinblastine, cyclophosphamide, actinomycin D, embolization,  $\epsilon$ -aminocaproic acid, antiplatelet agents, irradiation, excision, and compression therapy have been used, alone or in combination. Treatment is often difficult, however, and some KMS patients respond poorly to all attempted modalities.

**Chiu YE, et al:** Variable response to propranolol treatment of kaposiform hemangioendothelioma, tufted angioma, and Kasabach-Merritt phenomenon. *Pediatr Blood Cancer* 2012; 59(5):934–938.

**Drolet BA, et al:** Consensus-derived practice standards plan for complicated kaposiform hemangioendothelioma. *J Pediatr* 2013; 163(1):285–291.

**Fernandez-Pineda I, et al:** Long-term outcome of vincristine-aspirin-ticlopidine (VAT) therapy for vascular tumors associated with Kasabach-Merritt phenomenon. *Pediatr Blood Cancer* 2013; 60(9):1478–1481.

**Margolin JF, et al:** Medical therapy for pediatric vascular anomalies. *Semin Plast Surg* 2014; 28(2):79–86.

**Shen W, et al:** Treating kaposiform hemangioendothelioma with Kasabach-Merritt phenomenon by intralesional injection of absolute ethanol. *J Craniofac Surg* 2014; 25(6):2188–2191.

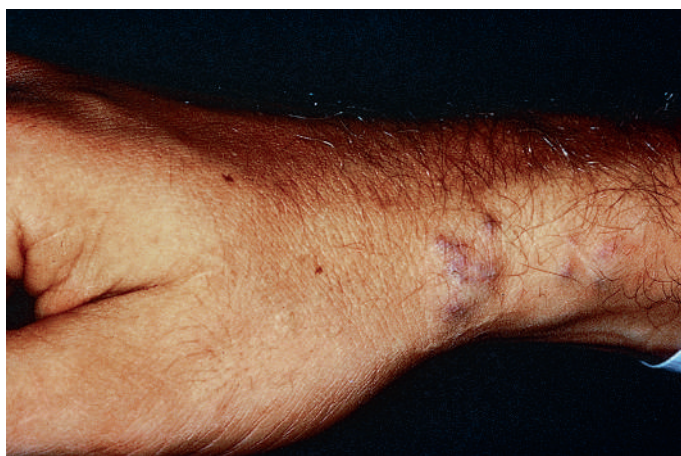## Multifocal lymphangioendotheliomatosis

Patients with multifocal lymphangioendotheliomatosis present at birth with hundreds of red-brown plaques as large as several centimeters. Similar lesions may occur in the GI tract and are associated with severe bleeding. Severe thrombocytopenic coagulopathy (Kasabach-Merritt syndrome) occurs in affected children. Treatment with corticosteroids and/or IFN alfa results in little to no improvement. The histology is distinctive, with delicate, thin-walled vessels lined by hobnailed endothelium with papillary tufting. The endothelial cells demonstrate a high proliferative fraction with Ki-67 staining and are reactive with LYVE-1, suggesting lymphatic differentiation.

**Yeung J, et al:** Multifocal lymphangioendotheliomatosis with thrombocytopenia. *J Am Acad Dermatol* 2006; 54(5 Suppl):S214–S217.

## Acquired progressive lymphangioma (benign lymphangioendothelioma)

Wilson-Jones introduced the term acquired progressive lymphangioma in 1976 to designate a group of lymphangiomas that occur anywhere in young individuals, grow slowly, and present as bruise-like lesions or erythematous macules.



**Fig. 28-16** Multiple glomangiomas.

Rarely, the lesion is yellow or alopecic. The histologic appearance is that of delicate, endothelium-lined spaces dissecting between collagen bundles. A similarity to the plaque stage of Kaposi sarcoma may be striking. Simple excision is curative. Prednisone has caused some extensive lesions to regress.

**Kim HS, et al:** Acquired progressive lymphangioma. *J Eur Acad Dermatol Venereol* 2007; 21(3):416–417.

## Glomus tumor and glomangiomas

The solitary glomus or neuromyoarterial tumor is most frequently a skin-colored or slightly dusky blue, firm nodule 1–20 mm in diameter. Subungual tumors show a bluish tinge through the translucent nail plate. The tumor is usually extremely tender, and paroxysmal pain occurs frequently. Sensitivity is likely to be present constantly, and when touched, the tumor responds with severe radiating pain. However, nontender glomus tumors are encountered. The characteristic location is subungual, but tumor may occur on the fingers and arms, or elsewhere. Digital lesions are more common in women, and there is a male predominance of nondigital lesions. There appears to be an association between glomus tumor and neurofibromatosis. High-resolution MRI, high-resolution ultrasonography (5–9 MHz), and color duplex sonography may be used to define the limits of the tumor before surgery is undertaken. Progressive growth may lead to ulceration.

Multiple glomangiomas are usually nontender and are generally widely distributed over the body. These may be inherited as an autosomal dominant trait and can be congenital. Clinically, they may resemble lesions of blue rubber bleb nevus (Fig. 28-16). When grouped in one area, they may appear as a confluent mass. Hereditary multiple glomus tumors may represent an autosomal dominant mosaic trait and may be congenital. The glomus coccygeum is a normal structure that may be seen in pilonidal sinus excision specimens.

Histologically, glomus tumors contain numerous vascular lumina lined by a single layer of flattened endothelial cells. Peripheral to the endothelial cells are layers of glomus cells. Generally, these are round and arranged in distinct rows resembling strings of black pearls. Rarely, the cells have a somewhat spindled morphology. Multiple glomangiomas tend to have only one or two layers of glomus cells. Glomangiomyomas have a prominent muscularis media in addition to one or two layers of glomus cells. Both solitary and multiple glomus tumors are related to the arterial segment of the cutaneous glomus, the Sucquet-Hoyer canal. The glomus cells

are modified vascular smooth muscle cells and stain with vimentin rather than desmin. Smooth muscle actin is often positive.

Treatment of solitary glomus tumors is best carried out by complete excision, which immediately produces relief from pain. The subungual tumors are most difficult to locate and eradicate because they are usually small, seldom more than a few millimeters in diameter.

Rare reports of glomangiosarcomas describe large, deeply located extremity lesions that consist of sarcomatous areas intermingled with areas of benign glomus tumor.

**Ham KW, et al:** Glomus tumors: symptom variations and magnetic resonance imaging for diagnosis. *Arch Plast Surg* 2013; 40(4):392–396.

**Harrison B, Sammer D:** Glomus tumors and neurofibromatosis: a newly recognized association. *Plast Reconstr Surg Glob Open* 2014; 2(9):e214.

**Yanai T, et al:** Immunohistochemical demonstration of cyclooxygenase-2 in glomus tumors. *J Bone Joint Surg Am* 2013; 95(8):725–728.

## Hemangiopericytoma

True hemangiopericytomas are rare. The term is now reserved for lesions that demonstrate differentiation toward pericytes and cannot be otherwise classified. Most lesions formerly classified as hemangiopericytomas are now classified as examples of solitary fibrous tumor or giant cell angiofibroma. Remaining lesions can often be classified as glomangiopericytoma/myopericytoma or infantile myofibromatosis.

Clinically, the typical lesion is a nontender, bluish red tumor that occurs on the skin or in the subcutaneous tissues on any part of the body. The firm, usually solitary nodule may be up to 10 cm in diameter. Histologically, the tumor is composed of endothelium-lined vessels that are filled with blood and surrounded by cells with oval or spindle-shaped nuclei (pericytes). The pericytes often form a concentric perivascular pattern. Staghornlike ectatic spaces are often encountered. Wide local excision is the treatment of choice, but radiation therapy may produce excellent palliation.

## Lesions formerly classified as hemangiopericytomas

Various soft tissue tumors can present with a hemangiopericytoma-like staghorn vascular pattern, the most common being solitary fibrous tumor. Solitary fibrous tumor is usually CD34+ and has a wide distribution in the skin, mucosa, and viscera. When excision cannot be accomplished, targeted therapy, including imatinib, may be helpful. Myofibromas demonstrate nodular, pale-blue, hypocellular zones with surrounding hypercellular zones that contain staghorn vessels. Some examples lack the hypocellular zones and present only with a hemangiopericytoma-like pattern. Myopericytoma is a rare mesenchymal neoplasm that typically involves the extremities. The tumor demonstrates concentric perivascular spindle cells with myoid differentiation. Glomangiopericytoma is a closely related tumor composed of perivascular spindle cells with myoid differentiation; it combines features of glomus tumors and a hemangiopericytoma-like vascular pattern.

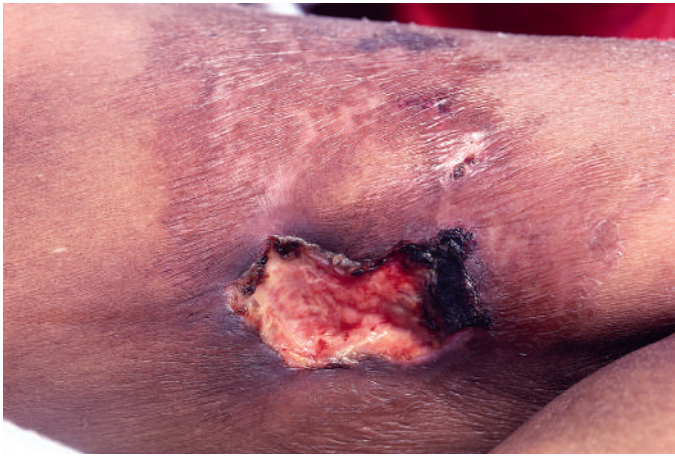**Stacchiotti S, et al:** Targeted therapies in rare sarcomas: IMT, ASPS, SFT, PEComa, and CCS. *Hematol Oncol Clin North Am* 2013; 27(5):1049–1061.

**Watanabe K, et al.** CD34-negative solitary fibrous tumour resistant to imatinib. *BMJ Case Rep* 2013; Jul 5.

## Proliferating angioendotheliomatosis

Diseases designated angioendotheliomatosis have historically been divided into two groups: a reactive, involuting type and





**Fig. 28-17** Diffuse dermal angiomatosis.

a malignant, rapidly fatal type. “Malignant angioendotheliomatosis” has been shown to be intravascular (angiotropic) lymphoma rather than a true vascular lesion.

The reactive type of angioendotheliomatosis is uncommon. It occurs in patients who have subacute bacterial endocarditis, Chagas’ disease, pulmonary tuberculosis, cryoproteinemia, severe atherosclerotic disease, periodontal disease, and antiphospholipid antibodies, as well as in patients with no identifiable underlying process. Patients present with red-purple patches, plaques, nodules, petechiae, and ecchymoses, usually of the lower extremities. Some may present with a livedoid pattern or lesions resembling atrophie blanche. Diffuse dermal angiomatosis is a variant associated with ischemia or atherosclerosis. The lesion occurs most often on the thigh, breast, or pannus in areas of vascular insufficiency (Fig. 28-17) and may clear with revascularization. It has also been described in association with an AV fistula and with anticardiolipin antibodies.

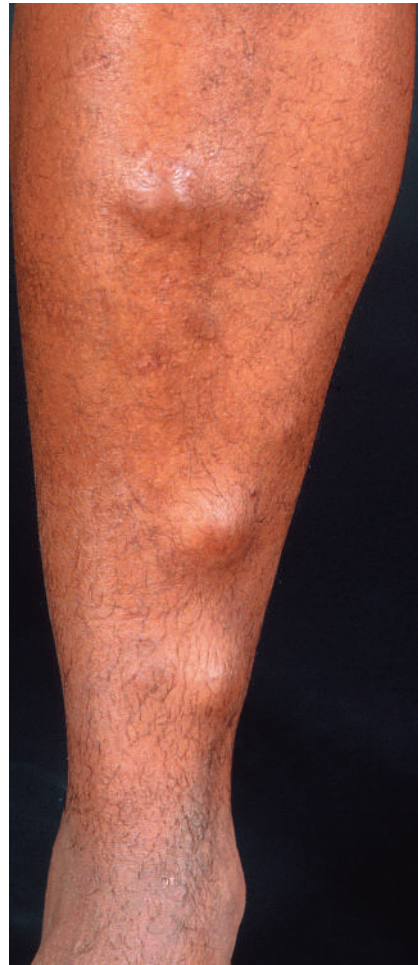Histologically, the vessels in benign reactive angioendotheliomatosis are dilated and are filled with proliferating endothelial cells, usually without atypia. Some cases demonstrate a proliferation of capillaries in the dermis, with diffuse, lobular, or mixed patterns. Fibrin microthrombi are common, and some cases show amyloid deposits or positive immunohistochemical staining for human herpesvirus 8 (HHV-8) in lesional endothelial cell nuclei. The course in this type is characterized by involution over 1–2 years. Therapy for the underlying condition has been considered as hastening involution.

The malignant type of “angioendotheliomatosis” is actually a large-cell, intravascular lymphoma and is discussed in Chapter 32.

**Kawaoka J, et al:** Coexistence of diffuse reactive angioendotheliomatosis and neutrophilic dermatosis heralding primary antiphospholipid syndrome. *Acta Derm Venereol* 2008; 88(4):402–403.

## Hemangioendotheliomas

Hemangioendotheliomas (HEs) are a group of tumors that span the spectrum from benign to low-grade malignancy. Kaposiform HEs are associated with tufted angiomas and Kasabach-Merritt syndrome and are discussed with those entities. Composite HEs may have epithelioid or retiform features and behave as borderline malignant tumors. Immunoreactivity for Prox-1 suggests lymphatic differentiation.



**Fig. 28-18** Spindle cell hemangioendotheliomas. (Courtesy of Dr. Timothy Gardner.)

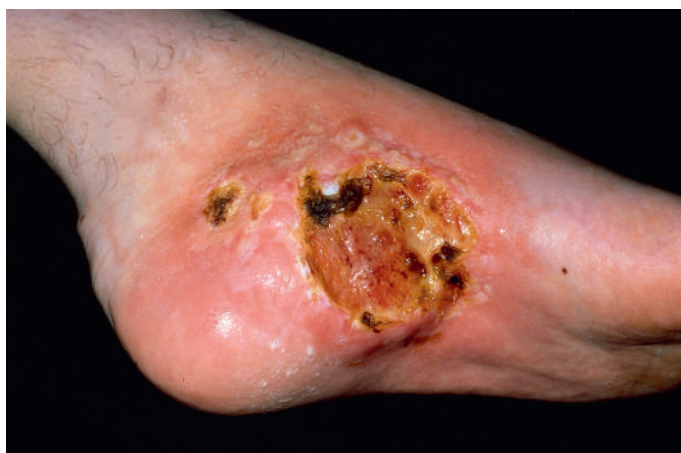### Spindle cell hemangioma (spindle cell hemangioendothelioma)

Spindle cell hemangioma is a vascular tumor that was first described in 1986. The condition typically presents in a child or young adult who develops blue nodules of firm consistency on a distal extremity (Fig. 28-18). Usually, multifocal lesions occur within an anatomic region. Histologically, a well-circumscribed dermal nodule will contain dilated vascular spaces with fascicles of spindle cells between them. Areas of the tumor will have an open alveolar pattern resembling hemorrhagic lung tissue. Phleboliths are common. A thrombosed, large, adjacent vessel with recanalization may be identified. The lesions appear to represent benign vascular proliferations in response to trauma to a larger vessel. They may recur after excision.

## Low-grade malignancies

### Epithelioid hemangioendothelioma

Epithelioid hemangioendothelioma usually presents as a solitary, slow-growing papule or nodule on a distal area of an extremity and behaves as a low-grade malignancy (Fig. 28-19). There is a male preponderance, and onset is frequently before the individual is 25 years of age. Histologically, there are two components: dilated vascular channels and solid epithelioid and spindle-cell elements with intracytoplasmic lumina. Wide excision is recommended with evaluation of regional lymph nodes, which are the usual site of metastases. In the minority of cases in which distant metastatic lesions develop, chemotherapy, radiation, or both may be employed.



**Fig. 28-19** Large, ulcerated epithelioid hemangioendothelioma.

### Retiform hemangioendothelioma

Retiform hemangioendothelioma is another form of low-grade malignancy that presents as a slow-growing exophytic mass, dermal plaque, or subcutaneous nodule on the upper or lower extremities of young adults. Histologically, there are arborizing blood vessels reminiscent of normal rete testis architecture. HHV-8 DNA sequences have been reported in this tumor. Wide excision is recommended, although local recurrences are common. To date, no widespread metastases have occurred, although regional lymph nodes may develop tumor infiltrates.

### Epithelioid sarcomalike (pseudomyogenic) hemangioendothelioma

The epithelioid sarcomalike variant demonstrates sheets of spindle, epithelioid, and rhabdomyoblastic cells. This variant also behaves as a low-grade malignancy.

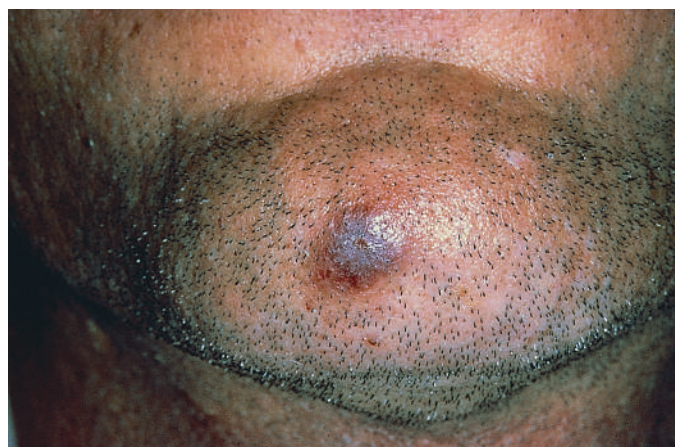### Endovascular papillary angioendothelioma (Dabska tumor)

Endovascular papillary angioendothelioma, a rare low-grade angiosarcoma, presents as a slow-growing tumor on the head, neck, or extremity of infants or young children. It shows multiple vascular channels with papillary plugs of endothelial cells surrounding central, hyalinized cores that project into the lumina, sometimes forming a glomeruloid pattern. The entity is controversial; similar histologic features have been observed in other vascular tumors, such as angiosarcoma, retiform hemangioendothelioma, and glomeruloid hemangioma. The tumor may be a distinct entity or may demonstrate a histologic pattern seen in other vascular tumors. Wide excision and excision of the regional lymph nodes, when involved, are usually curative.

**Liau JY, et al:** Composite hemangioendothelioma presenting as a scalp nodule with alopecia. *J Am Acad Dermatol* 2013; 69(2): e98–e99.

**McNab PM, et al:** Composite hemangioendothelioma and its classification as a low-grade malignancy. *Am J Dermatopathol* 2013; 35(4):517–522.

**Requena L, et al:** Cutaneous epithelioid sarcomalike (pseudomyogenic) hemangioendothelioma: a little-known low-grade cutaneous vascular neoplasm. *JAMA Dermatol* 2013; 149(4):459–465.



**Fig. 28-20** Kaposi sarcoma.

## Malignant neoplasms

### Kaposi sarcoma

Moritz Kaposi described this vascular neoplasm in 1872 and called it “multiple benign pigmented idiopathic hemorrhagic sarcoma.” Since his description, the disease has been reported in five separate clinical settings, with different presentations, epidemiology, and prognoses, as follows:

1. Classic Kaposi sarcoma (KS), an indolent disease seen chiefly in middle-age men of Southern and Eastern European origin
2. African cutaneous KS, a locally aggressive process affecting middle-age Africans in tropical Africa
3. African lymphadenopathic KS, an aggressive disease of young patients, primarily children under age 10
4. Kaposi sarcoma in patients immunosuppressed by AIDS
5. Lymphoma or immunosuppressive therapy

#### Clinical features

##### Classic Kaposi sarcoma

The early lesions appear most often on the toes or soles as reddish, violaceous, or bluish black macules and patches that spread and coalesce to form nodules or plaques (Fig. 28-20). These have a rubbery consistency. There may be brawny edema of the affected leg. Macules or nodules may appear, usually much later, on the arms and hands, and rarely may extend to the face, ears, trunk, genitalia, or buccal cavity, especially the soft palate. The course is slowly progressive and may lead to great enlargement of the lower extremities as a result of lymphedema. However, there may be periods of remission, particularly in the early stages of the disease, when nodules may undergo spontaneous involution. After involution, there may be an atrophic and hyperpigmented scar.

##### African cutaneous Kaposi sarcoma

Nodular, infiltrating, vascular masses occur on the extremities, mostly of men between ages 20 and 50. This form of KS is endemic in tropical Africa and has a locally aggressive but systemically indolent course.

##### African lymphadenopathic Kaposi sarcoma

Lymph node involvement, with or without skin lesions, may occur in children under age 10. The course is aggressive, often terminating fatally within 2 years of onset.



## AIDS-associated Kaposi sarcoma

Cutaneous lesions begin as one or several red to purple-red macules, rapidly progressing to papules, nodules, and plaques. There is a predilection for the head, neck, trunk, and mucous membranes. A fulminant, progressive course with nodal and systemic involvement is expected. KS may be the presenting manifestation of human immunodeficiency virus (HIV) infection.

## Immunosuppression-associated Kaposi sarcoma

The lesion's morphology resembles that of classic KS; however, the site of presentation is more variable.

### Internal involvement

The GI tract is the most frequent site of internal involvement in classic KS. The small intestine is probably the viscus most often involved. In addition, the lungs, heart, liver, conjunctiva, adrenal glands, and lymph nodes of the abdomen may be affected. Skeletal changes are characteristic and diagnostic. Bone involvement is always an indication of widespread disease. Changes noted are rarefaction, cysts, and cortical erosion.

African cutaneous KS is frequently accompanied by massive edema of the legs and frequent bone involvement.

African lymphadenopathic KS has been reported among Bantu children, who develop massive involvement of the lymph nodes, especially the cervical nodes, preceding the appearance of skin lesions. The children also develop lesions on the eyelids and conjunctiva, from which masses of hemorrhagic tissue hang down. Eye involvement is often associated with swelling of the lacrimal, parotid, and submandibular glands, with a picture similar to Mikulicz syndrome.

In AIDS-associated KS, 25% of patients have cutaneous involvement alone, whereas 29% have visceral lesions only. The most frequent sites of visceral involvement are the lungs (37%), GI tract (50%), and lymph nodes (50%). Visceral involvement ultimately occurs in more than 70% of patients with AIDS-associated KS. Other immunosuppressed patients with KS may have visceral involvement in a variable percentage of cases.

### Epidemiology

Kaposi sarcoma is worldwide in distribution. In Europe, there are foci of classic KS in Galicia, near the Polish-Russian border, and extending southward to Austria and Italy. In New York City, KS has occurred mostly in elderly Galician Jewish and southern Italian men. In Africa, KS occurs largely south of the Sahara Desert. Northeast Congo and Rwanda-Burundi areas have the highest prevalence, and to a lesser extent, West and South Africa.

The prevalence of AIDS-related KS has decreased since the 1980s. Most cases are in men who have sex with men (MSM). Very few reports have documented the exceptional occurrence of KS in patients with AIDS who acquired their infection from intravenous drug use, or in Haitians, children, or people with hemophilia. Patients at risk for developing KS associated with other causes of immunosuppression include those with iatrogenic suppression from oral prednisone or other chronic immunosuppressive therapies, as may be given to transplant patients. Endemic disease in southern Europe is strongly associated with oral corticosteroid use and diabetes and is inversely associated with cigarette smoking.

Kaposi sarcoma is associated with an increased risk of developing second malignancies, such as malignant lymphomas (Hodgkin disease, T-cell lymphoma, non-Hodgkin lymphoma), leukemia, and myeloma. The risk of lymphoreticular malignancy is about 20 times greater in KS patients than in the general population.

## Etiopathogenesis

Kaposi sarcoma is formed by proliferation of abnormal vascular endothelial cells. HHV-8 is found in KS lesional tissue irrespective of clinical type. Primary effusion lymphoma, solid lymphoma, and Castleman's disease are other confirmed associations with HHV-8 infection.

### Histology

Histopathology of KS varies considerably according to the stage of the disease. Early lesions demonstrate irregularly shaped, ectatic vessels with scattered lymphocytes and plasma cells. The endothelial cells of the capillaries are large and protrude into the lumen, resembling buds. Later lesions show proliferation of vessels around preexisting vessels and adnexal structures. The preexisting structure may jut into the vascular space, forming a promontory sign. Dull-pink globules, extravasated erythrocytes, and hemosiderin are present. Nodular lesions are composed of spindle cells with erythrocytes that appear to line up between spindle cells with no apparent vascular space.

### Treatment

All types of KS are radiosensitive. Radiation therapy has been used with considerable success, whether in small fractionated doses, in larger single doses to limited or extended fields, or by electron beam radiation. Local excision, cryotherapy, alitretinoin gel (Panretin), locally injected chemotherapy or IFN, and laser ablation have been used for troublesome, localized lesions.

Vincristine solution, 0.1 mg/mL injected intralesionally, not more than 3 mL at one time and at intervals of 2 weeks, produces involution of tumors, some for as long as 8 months. These studies indicate that adequate control of KS lesions may be achieved, at least for periods of 6–12 months. The development of resistance to medication seems to be inevitable.

Many other agents have been found to be effective; among the best are IFN, vinblastine, and actinomycin D. The response rate initially is high, but recurrent lesions, which are common, are generally less responsive. Systemic therapy is usually needed if more than 10 new KS lesions develop in 1 month, or if there is symptomatic lymphedema, symptomatic pulmonary disease, or symptomatic visceral involvement.

In the setting of HIV, protease inhibitors have been shown to have antiangiogenic effects; however, the results of non-nucleoside reverse transcriptase inhibitor-based regimens are not inferior to protease inhibitor-based therapy in the prevention of KS. This suggests that regression of KS is mediated by an overall improvement in immune function and not by the effects of specific antiretrovirals. Liposomal anthracyclines and paclitaxel have been approved by the U.S. Food and Drug Administration (FDA) as first-line and second-line monotherapy, respectively, for advanced KS.

Rapamycin (sirolimus), an inhibitor of the mammalian target of rapamycin (mTOR), is an effective immunosuppressant for the prevention of transplant rejection, with benefits as a treatment for KS. Dual inhibition of PI3K $\alpha$  and mTOR by PI-103 appears promising.

### Course

Classic KS progresses slowly, with rare lymph node or visceral involvement. Death usually occurs years later from unrelated causes. African cutaneous KS is aggressive, with early nodal involvement, and death from KS is expected within 1–2 years. AIDS-related KS, although widespread, is almost never fatal; almost all patients die of intercurrent infection. The course of the disease is variable in patients who develop immunosuppression-related KS from causes other than AIDS. Removal of the immunosuppression may result in resolution

of the KS without therapy. Among transplant patients, a change from a calcineurin inhibitor to sirolimus often results in regression of KS lesions.

**Chang Y, Moore P:** Twenty years of KSHV. *Viruses* 2014; 6(11):4258–4264.

**Donato V, et al:** Radiation therapy in the treatment of HIV-related Kaposi's sarcoma. *Anticancer Res* 2013; 33(5):2153–2157.

**La Ferla L, et al:** Kaposi's sarcoma in HIV-positive patients: the state of art in the HAART-era. *Eur Rev Med Pharmacol Sci* 2013; 17(17):2354–2365.

**Yaich S, et al:** Sirolimus for the treatment of Kaposi sarcoma after renal transplantation: a series of 10 cases. *Transplant Proc* 2012; 44(9):2824–2826.

## Atypical vascular lesion

Atypical vascular lesion (AVL) occurs after mastectomy and radiation. Staghornlike, thin-walled vessels are present, but endothelial atypia is minimal. Lesions may represent a precursor to malignancy. *MYC* amplification is noted in postirradiation angiosarcomas but not in primary cutaneous angiosarcoma or in other radiation-associated vascular proliferations, such as AVL.

**Feller JK, et al:** c-myc and cutaneous vascular neoplasms. *Am J Dermatopathol* 2013; 35(3):364–369.

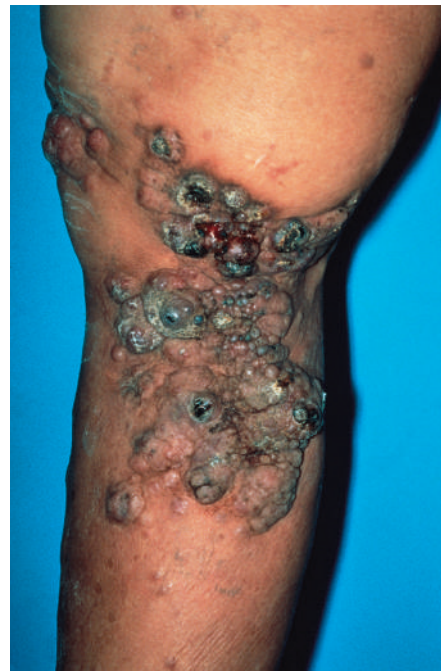## Angiosarcoma

Angiosarcomas of the skin occur in four clinical settings. First and most common are those that occur in the head and neck of elderly people. The male/female ratio is 2:1. The lesion often begins as a poorly defined bluish macule that may be mistaken for a bruise. Distinguishing features are the frequent occurrence of a peripheral erythematous ring, satellite nodules, presence of intratumoral hemorrhage, and the lesion's tendency to bleed spontaneously or after minimal trauma. The tumor progressively enlarges asymmetrically, often becomes multicentric, and develops indurated bluish nodules and plaques. The sudden development of thrombocytopenia may herald metastatic disease or an enlarging primary tumor.

Solid sheets of atypical epithelioid cells may be present, but more often, the pattern is that of subtle infiltration in the dermis, producing the appearance of cracks between collagen bundles. The spaces are lined by hyperchromatic nuclei. Immunoperoxidase staining for endothelial markers such as CD31, CD34, and *Ulex europaeus* lectin aids in the diagnosis, and most malignant vascular tumors are positive for podoplanin (D2-40).

Early diagnosis and complete surgical excision, followed by moderate-dose, very-wide-field radiotherapy, offer the best prognosis for limited disease. Chemotherapy and radiation therapy for extensive disease are often only palliative, especially when dealing with scalp lesions and high-grade lesions. Doxorubicin-ifosfamide chemotherapy produces a modest response rate. Paclitaxel is now often used as a first-line palliative systemic therapy, achieving an objective response rate of 56%. Sirolimus and IFN both show promise for scalp and facial angiosarcomas. Because of the multicentricity of lesions, the frequent occurrence on the face or scalp, and the rapid growth with early metastasis, death occurs in most patients within 2 years. A dramatic response was reported in a 77-year-old man with recurrent angiosarcoma of the face and scalp after combination treatment with IFN alfa-2a and 13-*cis*-retinoic acid.

The second classic clinical situation in which angiosarcoma develops is in chronic lymphedematous areas, as occurs in the upper arm after mastectomy, the so-called Stewart-Treves syndrome (Fig. 28-21). This tumor appears approximately 11–12 years after surgery in an estimated 0.45% of patients. The



**Fig. 28-21** Stewart-Treves syndrome.

prognosis is poor for these patients, with a mean survival of 19–31 months and 5-year survival of 6–14%. Metastases to the lungs are the most frequent cause of death. Early amputation offers the best hope.

A third setting includes tumors that develop in previously irradiated sites. If the condition for which radiation therapy was given was a benign one, the average interval between radiation and development of angiosarcoma is 23 years. If the preceding illness was a malignant condition, the interval is shortened to 12 years. Again, the prognosis is poor, with survival generally between 6 months and 2 years after diagnosis. Many patients with the Stewart-Treves syndrome received radiation, and radiation may play a pathogenic role.

Angiosarcomas develop in settings other than those previously described, and this small miscellaneous subset comprises the fourth category. An angiosarcoma producing granulocyte colony-stimulating factor was associated with prominent peripheral leukocytosis.

**Dettenborn T, et al:** Prognostic features in angiosarcoma of the head and neck: a retrospective monocenter study. *J Craniomaxillofac Surg* 2014; 42(8):1623–1628.

**Du W, et al:** Vascular tumors have increased p70 S6-kinase activation and are inhibited by topical rapamycin. *Lab Invest* 2013; 93(10):1115–1127.

**Farid M, et al:** Cutaneous versus non-cutaneous angiosarcoma: clinicopathologic features and treatment outcomes in 60 patients at a single Asian cancer centre. *Oncology* 2013; 85(3):182–190.

**Hung J, et al:** Sporadic versus radiation-associated angiosarcoma: a comparative clinicopathologic and molecular analysis of 48 cases. *Sarcoma* 2013; 2013:798403.

**Patel AM, et al:** The horizon for treating cutaneous vascular lesions. *Semin Cutan Med Surg* 2012; 31(2):98–104.

**Vora R, et al:** Cutaneous angiosarcoma of head and neck. *Indian J Dermatol* 2014; 59(6):632.

## FIBROUS TISSUE ABNORMALITIES

### Keloid

A keloid is a firm, irregularly shaped, fibrous, hyperpigmented, pink or red excrescence. The growth usually arises as the result of a cut, laceration, or burn—or less often an acne



pustule on the chest or upper back—and spreads beyond the limits of the original injury, often sending out clawlike (cheloid) prolongations. The overlying epidermis is smooth, glossy, and thinned from pressure. The early, growing lesion is red and tender and has the consistency of rubber. It is often surrounded by an erythematous halo, and the keloid may be telangiectatic. Lesions may be tender, painful, and pruritic and may rarely ulcerate or develop draining sinus tracts.

Keloids are often multiple. They may be as tiny as pinheads or as large as an orange. Those that follow burns and scalds are large. Lesions are often linear, frequently having bulbous expansions at each end. The surface may be larger than the base, so that the edges are overhanging. The most common location is the sternal region, but keloids also occur frequently on the neck, ears, extremities, or trunk and rarely on the face, palms, or soles. The earlobes are often involved as a result of ear piercing, but involvement of the central face is rare. Keloids are much more common and grow to larger dimensions in black persons than others.

Why certain individuals develop keloids remains unsolved. Trauma is usually the immediate causative factor, but this induces keloids only in those with a predisposition for their development. There is also a regional predisposition.

Histologically, a keloid is a dense and sharply defined nodular growth of myofibroblasts and collagen with a whorl-like arrangement resembling hypertrophic scar. Centrally, thick hyalinized bundles of collagen are present and distinguish keloids from hypertrophic scars. Elastic tissue is scanty, as in a scar. Through pressure, the tumor causes thinning of the normal papillary dermis and atrophy of adjacent appendages, which it pushes aside. Mucopolysaccharides are increased, and often there are numerous mast cells.

Keloids are usually distinctive. They may be distinguished from hypertrophic scars by their clawlike projections (Fig. 28-22), which are absent in the hypertrophic scar; the extension of the keloid beyond the confines of the original injury; and the presence of thick, hyalinized collagen bundles histologically. Frequently, spontaneous improvement of the hypertrophic scar occurs over months, but not in the keloid. Atypical lesions should be biopsied because carcinoma en cuirasse may mimic keloid.

Initial treatment is usually by means of intralesional injection of triamcinolone suspension alone or in combination with 5-fluorouracil (5-FU). Using a 30-gauge needle on a 1-mL tuberculin Luer syringe, triamcinolone suspension is injected into various parts of the lesion; 40 mg/mL is generally used for initial treatment, although as the lesion softens, 10–20 mg/mL may be sufficient to produce involution with less risk of

surrounding hypopigmentation and atrophy related to lymphatic spread of the corticosteroid. Injections are repeated at intervals of 6–8 weeks, as required. Flattening and cessation of itching are reliably achieved by this approach and in some cases may even be achieved with topical corticosteroids. The lesions are never made narrower, however, and hyperpigmentation generally persists. 5-FU can produce responses in refractory keloids but is associated with a somewhat higher risk of hyperpigmentation, pain, and ulceration after injection. Bleomycin is being investigated alone and in combination with triamcinolone. Transforming growth factor (TGF)- $\beta$  is known to be involved in keloid formation, and triamcinolone acetamide-induced decreases in cellular proliferation and collagen production are associated with a statistically significant decrease in the level of TGF- $\beta$ 1 in both normal and keloid fibroblast cell lines. Anti-TGF- $\beta$ 1 therapy looks promising, as does nuclear factor (NF)- $\kappa$ B inhibition and green tea polyphenol epigallocatechin-3-gallate.

Other approaches to treatment include flashlamp pulsed dye laser treatment, which is also associated with reduced expression of TGF- $\beta$ 1. Cryosurgery (including contact, intralesional needle cryoprobe, and spray), intralesional etanercept, and calcium channel-blockers have some demonstrated efficacy in the treatment of keloids. Fibroblasts derived from the central part of keloids grow faster than peripheral keloid and nonkeloid fibroblasts. Verapamil has been shown to decrease interleukin-6 (IL-6) and VEGF in these cultured cells and to inhibit cell growth.

If surgical removal by excision is feasible, and if narrowing of the keloid is a vitally important goal, the keloid may be excised. After the excision, intralesional injection of triamcinolone or IFN alfa-2b may be combined with postoperative x-ray irradiation or topical application of imiquimod. Silicone sheeting and pressure are other adjunctive methods used to limit recurrences. Results with these modalities have been mixed, and a Cochrane review concluded that the quality of evidence supporting silicone sheeting is generally poor. Keloids demonstrate an increased number of mast cells, and silicone gel-sheet treatment has been shown to reduce lesional mast cell numbers and decrease itching. Banding at the base of the keloid with a suture ligature for 5 weeks has been used successfully to treat pedunculated lesions.

Pierced-ear keloids occur with considerable frequency. When the keloid is young, intralesional injection of triamcinolone is frequently sufficient to control the problem. In old keloids, excision of the lesion using lidocaine with triamcinolone, followed by injections at 2-week intervals, produces good results. CO<sub>2</sub> laser excision has also been successful in old, mature keloids in this site.

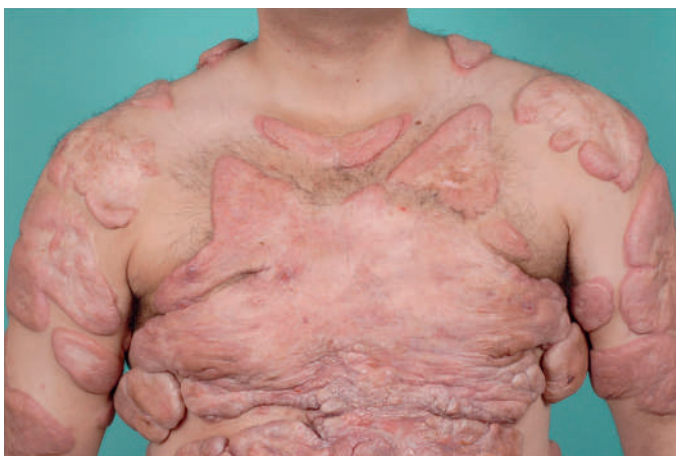

Fig. 28-22 Extensive keloids.

**Camacho-Martínez FM, et al:** Results of a combination of bleomycin and triamcinolone acetamide in the treatment of keloids and hypertrophic scars. *An Bras Dermatol* 2013; 88(3):387–394.

**Chopinard M, et al:** Intralesional cryosurgery to treat keloid scars: results from a retrospective study. *Dermatology* 2014; 229(3):263–270.

**Goldenberg G, et al:** Use of intralesional cryosurgery as an innovative therapy for keloid scars and a review of current treatments. *J Clin Aesthet Dermatol* 2013; 6(7):23–26.

**Huang C, et al:** Pharmacological treatment for keloids. *Expert Opin Pharmacother* 2013; 14(15):2087–2100.

**Huang L, et al:** A study of the combination of triamcinolone and 5-fluorouracil in modulating keloid fibroblasts in vitro. *J Plast Reconstr Aesthet Surg* 2013; 66(9):e251–e259.

**O'Brien L, et al:** Silicone gel sheeting for preventing and treating hypertrophic and keloid scars. *Cochrane Database Syst Rev* 2013; 9:CD003826.

**Saha AK, et al:** A comparative clinical study on role of 5-fluorouracil versus triamcinolone in the treatment of keloids. *Indian J Surg* 2012; 74(4):326–329.

**Trisliana Perdanasari A, et al:** Recent developments in the use of intralesional injections in keloid treatment. *Arch Plast Surg* 2014; 41(6):620–629.

## Dupuytren contracture

Dupuytren contracture is a fibromatosis of the palmar aponeurosis. The lesion arises most frequently in men between ages 30 and 50 as multiple firm nodules in the palm. Usually, three to five nodules about 1 cm in diameter develop, proximal to the fourth finger. Later, the fibromatosis produces contractures, which may be disabling. The condition occurs at times with alcoholic cirrhosis, diabetes mellitus, muscular dystrophy and chronic epilepsy. It is also associated with Peyronie's disease, plantar fibromatosis, and knuckle pads. In some cases, there is a familial predisposition. The fibrous nodules are composed of myofibroblasts that express androgen receptors. 5 $\alpha$ -Dihydrotestosterone induces an increase in Dupuytren fibroblast proliferation. In contrast to deep fibromatoses, which behave more aggressively, superficial fibromatoses lack  $\beta$ -catenin and adenomatous polyposis coli (APC) gene mutations.

Early disease may respond well to intralesional triamcinolone or collagenase, but surgical excision of the involved palmar fascia may be the only way to liberate severely contracted fingers. Androgen blockade represents a potential avenue of pharmacologic therapy. As with keloids, TGF- $\beta$ 2 inhibition appears promising.

## Plantar fibromatosis

The plantar analog of Dupuytren contracture, plantar fibromatosis (Ledderhose's disease), occurs as slowly enlarging nodules on the soles that ultimately cause difficulty in walking or even weight bearing. The diagnosis is usually made clinically, but both biopsy and MRI can be used to confirm the diagnosis. The usual surgical treatment is wide excision of the plantar fascia. Subtotal excision is associated with a high rate of recurrence. Although adjuvant radiotherapy is effective in decreasing the recurrence rate, it has a significant complication rate, with functional impairment. As with other forms of fibromatosis, intralesional injection of triamcinolone acetate or collagenase may represent nonsurgical alternatives.

**Baltzer H, et al:** Cost-effectiveness in the management of Dupuytren's contracture: a Canadian cost-utility analysis of current and future management strategies. *Bone Joint J* 2013; 95B(8):1094–1100.

**Denkler K.** Collagenase for recurrent Dupuytren contracture with skin grafts. *J Hand Surg Am* 2013; 38(6):1264.

**Dias JJ, et al:** Patterns of recontracture after surgical correction of Dupuytren disease. *J Hand Surg Am* 2013; 38(10):1987–1993.

**Peimer CA, et al:** Dupuytren contracture recurrence following treatment with collagenase *Clostridium histolyticum* (CORDLESS study): 3-year data. *J Hand Surg Am* 2013; 38(1):12–22.

**Schulze SM, Tursi JP:** Postapproval clinical experience in the treatment of Dupuytren's contracture with collagenase *Clostridium histolyticum* (CCH): the first 1000 days. *Hand (NY)* 2014; 9(4):447–458.

## Peyronie's disease

Plastic induration of the penis is a fibrous infiltration of the intercavernous septum of the penis. This fibrosis results in the formation of nodules or plaques. As a result of these plaques, a fibrous chordae is produced, and curvature of the penis occurs on erection, sometimes so severe as to make intromission difficult or impossible. In some patients, pain may be

severe. The association of Peyronie's disease with Dupuytren contracture has been recognized.

Injection of IFN alfa-2b, verapamil, or collagenase has been used. Intralesional triamcinolone suspension injected or iontophoresed into the plaques and nodules has shown mixed results. Oral therapies include tocopherol (vitamin E), para-aminobenzoate, colchicine, tamoxifen, and acetyl-L-carnitine, but data supporting oral therapy are weak. Surgical correction tailored to the degree of deformity is often successful. Extracorporeal shock wave therapy may reduce penile pain but may worsen curvature.

**Garaffa G, et al:** Understanding the course of Peyronie's disease. *Int J Clin Pract* 2013; 67(8):781–788.

**Lopes I, et al:** Penile corporoplasty with Yachia's technique for Peyronie's disease: single center experience with 117 patients. *Urol Ann* 2013; 5(3):167–171.

## Lipofibromatosis

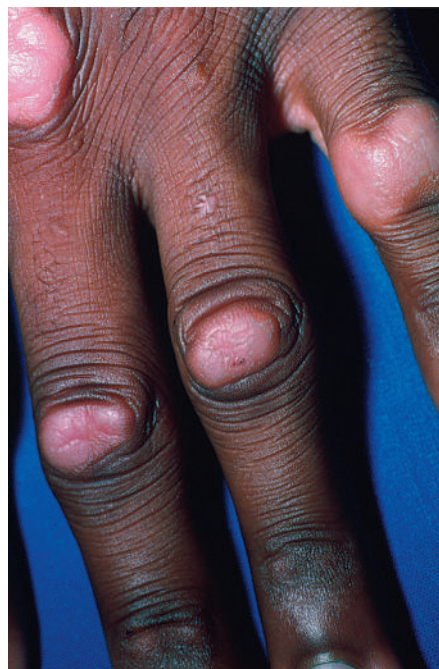Lipofibromatosis is a rare tumor of infancy that typically presents as a poorly demarcated, slow-growing soft tissue mass on an extremity. It is sometimes associated with other defects, such as syndactyly, cleft lip and palate, trigonocephaly, and atrial septal defect. Histologically, mature fat is separated by collagenous septa containing fibroblasts and myofibroblasts. A subtle honeycomb pattern of fibrosis may be noted at the edge of the fat lobule.

**Boos MD, et al:** Lipofibromatosis: an institutional and literature review of an uncommon entity. *Pediatr Dermatol* 2014; 31:298–304.

**Costa Dias S, et al:** Lipofibromatosis of the knee in a 19-month-old child. *J Pediatr Surg* 2012; 47(5):1028–1031.

## Knuckle pads

Knuckle pads (heloderma) are well-defined, round, plaque-like, fibrous thickenings that develop on the extensor aspects of the proximal interphalangeal joints of the toes and fingers (Fig. 28-23), including the thumbs. They develop at any age and grow to about 10–15 mm in diameter over a few weeks or months, then persist permanently. They are flesh colored or



**Fig. 28-23** Knuckle pads.



somewhat brown, with normal or slightly hyperkeratotic epidermis overlying and adherent to them. They are a part of the skin and are freely movable over underlying structures.

Knuckle pads are sometimes associated with Dupuytren contracture, clubbing, or camptodactyly (irreducible flexion contracture of one or more fingers). Some cases are familial, and some are related to trauma or frequent knuckle cracking. Autosomal dominant associations of knuckle pads, mixed hearing loss, keratoderma, and leukonychia have been reported, including Bart-Pumphrey syndrome (*GJB2* mutations). Knuckle pads have also been associated with autosomal dominant epidermolytic palmoplantar keratoderma with a mutation in keratin 9.

Histologically, the lesions are fibromas. They are differentiated clinically from the nodular type of neurodermatitis and from the small, hemispherical pitted papules that may develop over the knuckles after frostbite or in acrocyanosis, and from rheumatic nodules. Treatment with intralesional injection of corticosteroids may be beneficial. As with keloids, intralesional 5-FU may be beneficial.

**Chen LH, et al:** G59A mutation in the *GJB2* gene in a Taiwanese family with knuckle pads, palmoplantar keratoderma and sensorineural hearing loss. *Clin Exp Dermatol* 2012; 37(3):300–301.

**Du ZF, et al:** A novel mutation within the 2B rod domain of keratin 9 in a Chinese pedigree with epidermolytic palmoplantar keratoderma combined with knuckle pads and camptodactyly. *Eur J Dermatol* 2011; 21(5):675–679.

**Hyman CH, et al:** Report of a family with idiopathic knuckle pads and review of idiopathic and disease-associated knuckle pads. *Dermatol Online J* 2013; 19(5):18177.

## Pachydermodactyly

Pachydermodactyly represents a benign fibromatosis of the fingers. There is a fullness of the medial and lateral digit just proximal to the proximal interphalangeal joint. This asymptomatic process most often is first noted in adolescence and usually involves multiple fingers. It can be misdiagnosed as juvenile idiopathic arthritis. Five types have been described: classic, localized, transgrediens (abnormality extends to metacarpophalangeal areas), familial, and pachydermodactyly associated with tuberous sclerosis. Some cases may result from repetitive ticlike obsessive-compulsive behaviors. Increased collagen or mucin accounts for the swelling. Patients with pachydermodactyly associated with repetitive tics respond to treatment for the obsessive-compulsive disorder.

**El-Hallak M, et al:** Pachydermodactyly mimicking juvenile idiopathic arthritis. *Arthritis Rheum* 2013; 65(10):2736.

## Desmoid tumor

Desmoid tumors occur as large, deep-seated, well-circumscribed masses arising from the muscular aponeurosis. They most frequently occur on the abdominal wall, especially in women during or soon after pregnancy. Desmoid tumors have been divided into five types: abdominal wall, extra-abdominal, intra-abdominal, multiple, and those occurring in Gardner syndrome/familial adenomatous polyposis. They recur locally and can kill if they invade, surround, or compress vital structures. The most dangerous desmoid tumors are therefore those at the root of the neck and the intra-abdominal type. MRI will aid in the evaluation of soft tissue extension and recurrence after treatment. Mutations in the  $\beta$ -catenin gene correlate with local recurrence. Treatment may be with wide local excision, radiotherapy, or hormonal manipulation. High-dose tamoxifen in combination with sulindac has been effective. Mesenteric desmoid tumors have been treated with

antiangiogenic therapy with toremifene and IFN alfa-2b. Imatinib mesylate appears promising.

**Devata S, et al:** Desmoid tumors: a comprehensive review of the evolving biology, unpredictable behavior, and myriad of management options. *Hematol Oncol Clin North Am* 2013; 27(5):989–1005.

## Collagenous fibroma (desmoplastic fibroblastoma)

This slow-growing, deep-set, benign fibrous tumor is usually located in the deep subcutis, fascia, aponeurosis, or skeletal muscle of the extremities, limb girdles, or head and neck regions. It is characterized by hypocellularity and dense bands of hyalinized collagen that may infiltrate into skeletal muscle. Despite this, no tumors have been reported to metastasize or recur after excision. Chromosomal translocation (2;11)(q31; q12) as well as trisomy 8 have been reported. Tumor cells stain for vimentin and may stain for actin, but have been negative for CD34, S-100 protein, keratin, CD68, desmin, and  $\beta$ -catenin.

**Nishio J, et al:** Translocation t(2;11) is characteristic of collagenous fibroma (desmoplastic fibroblastoma). *Cancer Genet* 2011; 204(10):569–571.

**Stacy RC, et al:** Collagenous fibroma (desmoplastic fibroblastoma) of the orbital rim. *Ophthal Plast Reconstr Surg* 2013; 29(4):e101–e104.

## Aponeurotic fibroma

Aponeurotic fibroma has also been called juvenile aponeurotic fibroma (calcifying fibroma). It is a tumorlike proliferation characterized by the appearance of slow-growing, cystlike masses that occur on the limbs, especially the hands and feet. Histologically, the distinctive lesions are sharply demarcated and composed of collagenous stroma showing acid mucopolysaccharides infiltrated by plump mesenchymal cells with oval nuclei. Hyalinized areas are also present, suggesting chondroid or osteoid metaplasia. An aid to the diagnosis is stippled calcification, readily seen on radiographs. Surgical excision is the treatment of choice and can be guided by MRI.

**Schonauer F, et al:** Calcifying aponeurotic fibroma of the distal phalanx. *J Plast Reconstr Aesthet Surg* 2013; 66(2):e47–e49.

## Infantile myofibromatosis

Infantile myofibromatosis is the most common fibrous tumor of infancy. Eighty percent of patients have solitary lesions, with half of these occurring on the head and neck. About 60% are present at or soon after birth.

Congenital generalized fibromatosis is an uncommon condition that presents at birth or soon after. It is characterized by multiple, firm, dermal and subcutaneous nodules. Skeletal lesions, primarily of the metaphyseal regions of the long bones, occur in 50% of patients. If only the skin and bones develop fibromas, the prognosis is excellent, with spontaneous resolution of the lesions and with no complications expected in the first 1–2 years of life. Some refer to this limited disease as “congenital multiple fibromatosis.” Females more frequently contract the generalized disease.

The fibromas may involve the viscera, including the GI tract, breast, lungs, liver, pancreas, tongue, serosal surfaces, lymph nodes, or kidney. Autosomal dominant inheritance has been reported, and mutations in *PDGFRB* and *NOTCH3* have been described. Histologically, fascicles of spindle cells occur in a whorled pattern. These nodules are composed of myofibroblasts.

Mortality in the more widespread subset is high; 80% die from obstruction or compression of vital organs. Patients who survive past 4 months have spontaneous regression of their disease. Some life-threatening cases have responded to low-dose chemotherapy.

### Diffuse infantile fibromatosis

This process occurs within the first 3 years of life and is usually confined to the muscles of the arms, neck, and shoulder area. There is multicentric infiltration of muscle fibers with fibroblasts resembling those in aponeurotic fibromas. Calcification does not occur. Recurrence after excision occurs in about one third of patients.

### Aggressive infantile fibromatosis

The clinical presentation of this locally recurring, nonmetastasizing lesion involves single or multiple, fast-growing masses that are present at birth or that occur within the first year of life. Infantile fibromatosis may be seen in any location, although the arms, legs, and trunk are the usual sites. Histologically, it is hypercellular and mimics malignancy.

**Ferrari A, et al:** Fibroblastic tumors of intermediate malignancy in childhood. *Expert Rev Anticancer Ther* 2013; 13(2):225–236.

**Lee J:** Mutations in *PDGFRB* and *NOTCH3* are the first genetic causes identified for autosomal dominant infantile myofibromatosis. *Clin Genet* 2013; 84(4):340–341.

**Ruparelia MS, et al:** Infantile fibromatosis: a case report and review of the literature. *Br J Oral Maxillofac Surg* 2011; 49(6):e30–e32.

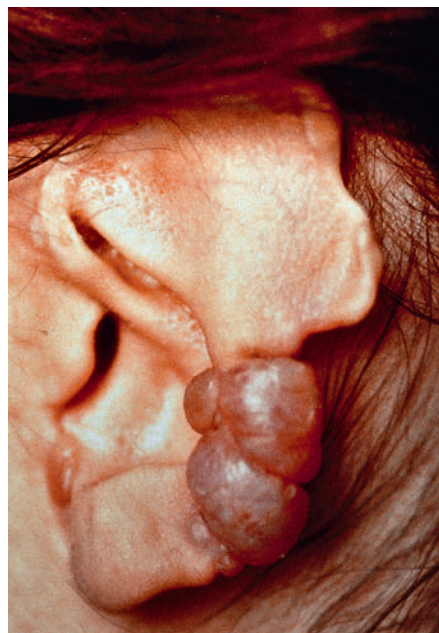### Juvenile hyaline fibromatosis and infantile systemic hyalinosis

Juvenile hyaline fibromatosis and infantile systemic hyalinosis are allelic autosomal recessive conditions characterized by multiple subcutaneous skin nodules, hyaline deposition, gingival hypertrophy, osteolytic bone lesions, and joint contractures. Nodular tumors of the scalp, face, and extremities usually appear in early childhood. Pink confluent papules may occur on the paranasal folds, periauricular area (Fig. 28-24), and perianal region. The gene has been mapped to chromosome 4q21, with at least 15 different mutations in the gene encoding capillary morphogenesis protein 2, a transmembrane protein induced during capillary morphogenesis and that binds laminin and collagen IV. Histologically, fibroblasts with fine, intracytoplasmic eosinophilic granules are embedded in a homogeneous eosinophilic dermal ground substance. Ultrastructurally, the fibroblasts demonstrate defective synthesis of collagen, deposited as fibrillogranular material.

**Denadai R, et al:** Systemic hyalinosis: new terminology, severity grading system, and surgical approach. *J Pediatr* 2012; 161(1):173; author reply 173–174.

### Infantile digital fibromatosis (infantile digital myofibroblastoma, inclusion body fibroma)

Infantile digital fibromatosis is a rare neoplasm of infancy and childhood that usually occurs on the dorsal or lateral aspects of the distal phalanges of the toes and fingers. The thumb and great toe are usually spared. These asymptomatic, firm, red, smooth nodules occur during the first year of life, 47% in the



**Fig. 28-24** Juvenile hyaline fibromatosis.

first month. Rare congenital lesions have been noted. The lesions do not metastasize but may infiltrate deeply. Histologically, the epidermis is normal, but the dermis is infiltrated with proliferating myofibroblasts and collagen bundles. Eosinophilic cytoplasmic inclusions in many of the fibroblasts are characteristic. Treatment by surgical excision has a high risk of recurrence, and conservative, nonsurgical management is often appropriate. Spontaneous regression is generally noted, but the lesion may cause functional impairment and may infiltrate deeply before regression occurs. Mohs micrographic surgery has been performed successfully using both trichrome staining and smooth muscle actin staining to demonstrate the inclusion bodies within tumor cells.

**Laskin WB, et al:** Infantile digital fibroma/fibromatosis: a clinicopathologic and immunohistochemical study of 69 tumors from 57 patients with long-term follow-up. *Am J Surg Pathol* 2009; 33(1):1–13.

**Spingardi O, et al:** Infantile digital fibromatosis: our experience and long-term results. *Chir Main* 2011; 30(1):62–65.

### Fibrous hamartoma of infancy

Fibrous hamartoma of infancy is a single dermal or subcutaneous firm nodule of the upper trunk that is present at birth or shortly thereafter. Overlying skin changes are uncommon but may include increased hair, alteration in pigmentation, and eccrine gland hyperplasia with hyperhidrosis. Most cases are solitary, but multiple tumors have been reported; 91% of lesions are noted within the first year of life, and 23% are congenital. The male/female ratio is 2.4:1. Most lesions occur in the axillary region, upper arm, upper trunk, inguinal region, and external genital area. An association with Williams syndrome has been reported. Biopsy shows an organoid pattern with different types of tissue organized in whorls or bands. In early lesions, lobules of mature fat are interspersed between myxoid and fibrous areas. Myxoid zones have primitive mesenchymal cells with stellate nuclei. Fibrosing areas demonstrate delicate collagen bundles and many elongated fibroblast nuclei. The overlying skin may demonstrate abortive hair follicles, and many eccrine units may be present. Complex chromosomal translocations have been reported. Over time, both the myxoid and the fibrosing areas develop into cell-poor fibrous areas with thick collagen bundles. There is no recurrence after excision.



**F-Eire P, et al:** Cutaneous changes in fibrous hamartoma of infancy. *Indian J Dermatol* 2013; 58(2):160.

**Seguier-Lipszyc E, et al:** Fibrous hamartoma of infancy. *J Pediatr Surg* 2011; 46(4):753–755.

**Takahashi E, et al:** Atrophic fibrous hamartoma of infancy with epidermal and adnexal changes. *J Dermatol* 2013; 40(3):212–214.

### Fibromatosis colli

In fibromatosis colli, there is a fibrous tissue proliferation infiltrating the lower third of the sternocleidomastoid muscle at birth. Fine-needle aspiration is useful to confirm the diagnosis. Spontaneous remission occurs within a few months. Occasionally, some patients are left with a wryneck deformity; however, this complication is amenable to surgery.

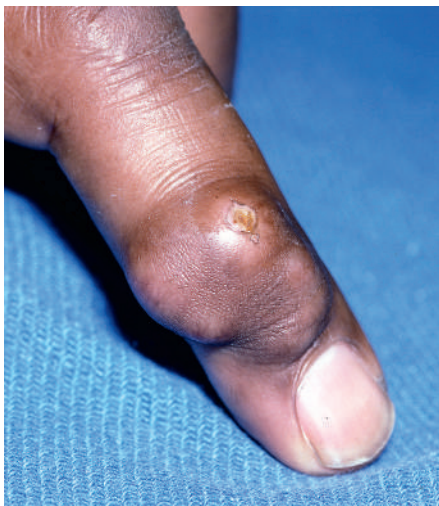**Lowry KC, et al:** The presentation and management of fibromatosis colli. *Ear Nose Throat J* 2010; 89(9):E4–E8.

### Giant cell tumor of the tendon sheath

This giant cell tumor is most frequently attached to the tendons of the fingers (Fig. 28-25), hands, and wrists and has a predilection for the flexor surfaces. It is firm, 1–3 cm in diameter, and does not spontaneously involute. It recurs after excision in approximately 25% of cases. Fibroma of the tendon sheath represents a variant of the giant cell tumor that lacks giant cells. The fibroma tends to occur more in younger men (average age at onset 30) than the giant cell variety. When a proliferation similar to giant cell tumor of the tendon sheath occurs in deeper tissues, it is referred to as pigmented villonodular tenosynovitis. The pigment is hemosiderin.

Histologically, the giant cell tumor consists of lobules of densely hyalinized collagen. The characteristic osteoclast-like giant cells have deeply eosinophilic cytoplasm that molds to adjacent cells. Oval gray fibroblast nuclei are present throughout the lesion. Lipophages and siderophages may be numerous, and hemosiderin deposition may impart a brown color to the lesions on gross examination. The fibroma of the tendon sheath generally lacks lipophages and siderophages as well as giant cells, with the lobules composed of dense, fibrocollagenous tissue with oval gray fibroblast nuclei.

The rate of recurrence depends on the presence or absence of a pseudocapsule, lobulation of the tumor, extra-articular location, and presence of satellite lesions. Local recurrence has been treated with more extensive surgery, and imaging studies can define the extent of the tumor. Radiation therapy has been reported anecdotally.



**Fig. 28-25** Giant cell tumor of the tendon sheath.

**Adams EL, et al:** Giant cell tumor of the tendon sheath: experience with 65 cases. *Eplasty* 2012; 12:e50.

**Garner HW, et al:** Benign synovial tumors and proliferative processes. *Semin Musculoskelet Radiol* 2013; 17(2):177–178.

### Ainhum

Ainhum is also known as dactylolysis spontanea, bankokerend, and sukhapakla. It is a disease affecting the toes, especially the fifth toe, characterized by a linear constriction around the affected digit that ultimately leads to the spontaneous amputation of the distal part. It occurs chiefly among black men in Africa. Usually, ainhum is unilateral but may be bilateral.

The disease begins with a transverse groove in the skin on the flexor surface of the toe, usually beneath the first interphalangeal articulation. The furrow is produced by a ringlike fibrosis and an induration of the dermis. It deepens and extends laterally around the toe until the two ends meet, so that the digit becomes constricted, as if in a ligature. The constricted part becomes swollen, soft, and after a time, greatly distended. Ulceration may result in a malodorous discharge, with pain and gangrene. The course of the disease is slow, but in 5–10 years, spontaneous amputation occurs, generally at a joint.

The cause is unknown. The condition may result from chronic trauma and exposure to the elements by walking barefoot in the tropics. Fissuring followed by chronic inflammation and fibrosis may then result.

Treatment in early cases by cutting the constricting band is unsuccessful. In advanced cases, amputation of the affected member is advisable. Surgical correction by Z-plasty has produced good results. Intralesional injection of betamethasone (15 injections total) has also been successful.

### Pseudo-ainhum

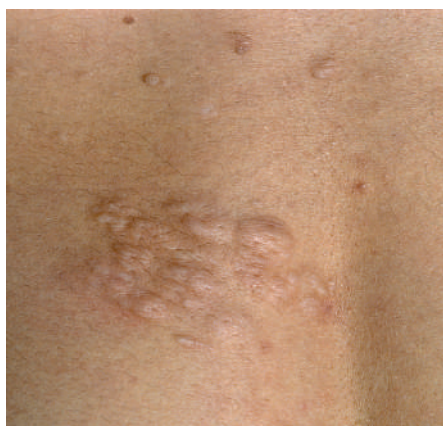Pseudo-ainhum has been a term used in connection with certain hereditary and nonhereditary diseases in which annular constriction of digits occurs. Hereditary disorders include hereditary palmoplantar keratodermas, especially Vohwinkel syndrome and mal de Meleda, pachyonychia congenita, Ehlers-Danlos syndrome, erythropoietic protoporphyria, and keratoderma with universal atrichia. Nonhereditary disorders associated with constriction of digits include ainhum, Hansen's disease, cholera, ancylostomiasis, scleroderma, Raynaud syndrome, pityriasis rubra pilaris, psoriasis, Olmsted syndrome, Reynold syndrome (scleroderma and primary biliary cirrhosis with antimitochondrial antibodies), syringomyelia, ergot poisoning, gout, and spinal cord tumors. Factitial pseudo-ainhum may be produced by self-application of a rubber band, string, or other ligature. Congenital cases have been reported that may affect digits or limbs. Pseudo-ainhum may occur as a familial condition or may be secondary to amniotic bands. Treatment includes surgery or intralesional injection of corticosteroids, as in ainhum. Retinoids may be used in responsive diseases.

**Bassetto F, et al:** Vohwinkel syndrome: treatment of pseudo-ainhum. *Int J Dermatol* 2010; 49(1):79–82.

**De Araujo DB, et al:** Ainhum (dactylolysis spontanea): a case with hands and feet involvement. *J Clin Rheumatol* 2013; 19(5):277–279.

### Connective tissue nevi

Connective tissue nevi are uncommon lesions that may present as acquired isolated plaques, as multiple lesions



**Fig. 28-26** Connective tissue nevus.

(acquired or congenital), or as one finding in a more generalized disease. Biopsy findings include abnormal collagen bundles and altered amounts elastin. These lesions characteristically occur on the trunk, most often in the lumbosacral area (Fig. 28-26). Although solitary lesions occur, they are often multiple and may show a linear or zosteriform arrangement. Individual lesions are slightly elevated plaques 1–15 cm in diameter, varying in color from light yellow to orange, with a surface texture resembling shagreen leather. In Proteus syndrome, the connective tissue nevi are present as plantar, or occasionally palmar, masses with a cerebriform surface. Connective tissue nevi of the acquired type have been classified as eruptive collagenomas, isolated collagenomas, or isolated elastomas, depending on the number of lesions and the predominant dermal fibers present. They cannot be differentiated clinically.

Hereditary types of connective tissue nevi include dermatofibrosis lenticularis disseminata in the Buschke-Ollendorff syndrome, familial cutaneous collagenoma, and the shagreen patches seen in tuberous sclerosis. Buschke-Ollendorff syndrome is an autosomal dominant inherited disorder in which widespread dermal papules and plaques develop asymmetrically over the trunk and limbs. Elastic fiber thickening, highly variable fiber diameter, and desmosine increases threefold to sevenfold above normal have been described in these patients. The associated feature of osteopoikilosis is asymptomatic but is diagnostic of the syndrome in x-ray evaluation. Focal sclerotic densities are seen, primarily in the long bones, pelvis, and hands. Buschke-Ollendorff syndrome is highly variable, and familial inheritance of elastic tissue nevi without evidence of osteopoikilosis has been reported.

Papular elastorrhexis is characterized by multiple white, evenly scattered papules, usually occurring on the trunk. Elastic fibers are decreased and may appear thin and fragmented. Most reported cases are sporadic, but familial occurrence has been described.

Patients with familial cutaneous collagenomas may present with numerous symmetric, asymptomatic dermal nodules on the back. The age of onset is usually in the middle to late teens. In patients with the inherited disease, multiple endocrine neoplasia type I (MEN-I) multiple collagenomas were reported in 23 of 32 patients. These were less than 3 mm in diameter and were on the upper torso, neck, and shoulders. They occurred in association with many other cutaneous findings, including angiofibromas, café au lait macules, and lipomas. Atrioseptal defect has also been reported in association with familial collagenomas.

The collagenomas of tuberous sclerosis are associated with adenoma sebaceum, periungual fibromas, and ash-leaf macules. Because at least half the cases of tuberous sclerosis result from new mutations, all patients with connective tissue

nevi should be carefully studied for evidence of tuberous sclerosis, even in the absence of a family history of the disease. Isolated plantar collagenoma may exhibit a cerebriform appearance and resemble plantar fibromas of Proteus syndrome.

Eruptive collagenomas may be widespread or localized. They have rarely been associated with infectious diseases such as syphilis.

Mucinous nevus is a form of connective tissue nevus characterized by increased ground substance without increases in collagen or elastin. Histologically, collagen bundles are widely separated by mucin and may be attenuated. Overlying follicular induction similar to that seen in dermatofibromas may be present.

**Batra P, et al:** Eruptive collagenomas. *Dermatol Online J* 2010; 16(11):3.

**Choi Y, et al:** Papular elastorrhexis: a case and differential diagnosis. *Ann Dermatol* 2011; 23(Suppl 1):S53–S56.

**De Feraudy S, et al:** Fibroblastic connective tissue nevus: a rare cutaneous lesion analyzed in a series of 25 cases. *Am J Surg Pathol* 2012; 36(10):1509–1515.

**McCuaig CC, et al:** Connective tissue nevi in children: institutional experience and review. *J Am Acad Dermatol* 2012; 67(5):890–897.

### Elastofibroma dorsi

Elastofibroma dorsi is a benign tumor usually located in the deep soft tissues in the subscapular region, but sometimes at other sites. The tumor is firm and unencapsulated and measures up to several centimeters in diameter. It is believed to represent an unusual response to repeated trauma. Histologically, the tumor consists of abundant compact sclerotic collagen mixed with large, swollen, irregular elastic fibers, often appearing as globules of elastic tissue. It usually appears on nuclear medicine scans, suggesting it is not as uncommon as once believed. Computed tomography (CT) and MRI can define the extent of the lesion, and excision is curative.

**Lococo F, et al:** Elastofibroma dorsi: clinicopathological analysis of 71 cases. *Thorac Cardiovasc Surg* 2013; 61(3):215–222.

### Angiofibromas

These skin-colored to reddish papules show fibroplasia and varying degrees of vascular proliferation in the upper dermis. Angiofibromas may occur as a solitary nonhereditary form, the fibrous papule of the nose; as multiple nonhereditary lesions, the pearly penile papules; or as multiple hereditary forms, as in tuberous sclerosis, Birt-Hogg-Dube syndrome (in combination with the specific lesion, the fibrofolliculoma), and MEN-I. Reports of agminated or segmental angiofibromas may represent a segmental form of tuberous sclerosis. The multiple hereditary types may respond to rapamycin and are discussed in other chapters.

Cellular angiofibroma typically occurs in the genital region of older women. It consists of small spindle cells arranged in short fascicles and relatively abundant, small, rounded vessels. Cellular angiofibromas may express estrogen and progesterone receptors as well as CD34.

### Fibrous papule of nose (fibrous papule of face, benign solitary fibrous papule)

These lesions occur in adults as dome-shaped, sessile, skin-colored, white or reddish papules, 3–6 mm in diameter, on or near the nose (Fig. 28-27). Fibrous papule is usually solitary, but a few lesions can occur. It may be confused with a nevocytic nevus, neurofibroma, granuloma pyogenicum, or a basal



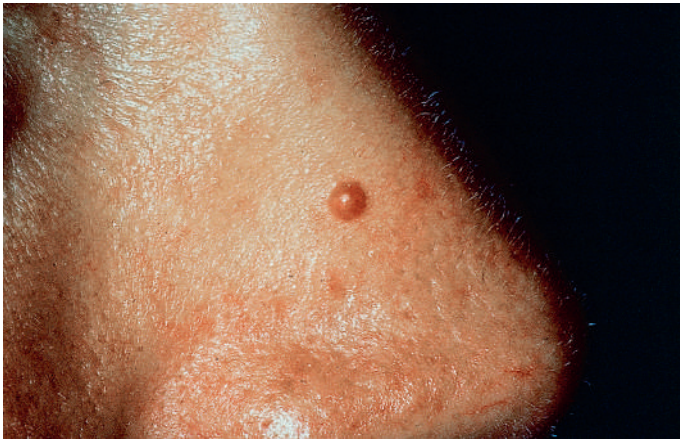

Fig. 28-27 Fibrous papule.

cell carcinoma. As with other angiofibromas, fibrous papules demonstrate concentric fibrosis surrounding vessels and adnexal structures. Stellate dermal dendrocytes are often prominent. Clear cell, granular, and epithelioid variants have been described. They stain for factor XIIIa. Large, pyramidal, junctional melanocytes are often noted overlying the lesion, and a superficial shave biopsy may be mistaken for a melanocytic lesion. Conservative excision is curative; recurrence is rare. Multiple lesions should prompt a search for other stigmata of tuberous sclerosis.

### Pearly penile papules

This is the term given to pearly-white, dome-shaped angiofibromas occurring circumferentially on the coronal margin and sulcus of the glans penis. The lesions may be firm or soft and filiform. Occasionally, lesions are also present on the penile shaft. Pearly penile papules are not uncommon. Patients usually present at age 20–30, concerned that these are condylomata, or are referred as having treatment-resistant venereal warts. These lesions should be distinguished from papillomas, hypertrophic sebaceous glands, and condyloma acuminatum. No treatment is necessary, only reassurance. If treatment is desired, laser ablation or shave excision is effective.

### Acral fibrokeratoma

Acral fibrokeratoma, often called acquired digital fibrokeratoma, is characterized by a pinkish, hyperkeratotic, hornlike projection occurring on a finger, toe, palm, or sole. The projection usually emerges from a collarette of elevated skin. The average age of the patient is 40. The lesion resembles a rudimentary supernumerary digit, cutaneous horn, or neuroma. Onset during immunosuppressive therapy has been reported, and grouped lesions may occur. Multiple periungual lesions are associated with tuberous sclerosis.

Histologic sections show a central core of thick collagen bundles interwoven closely in a vertical position. This is surrounded by capillaries and a fine network of reticulum fibers. Stellate dermal dendrocytes may be present, as in fibrous papule. Simple surgical excision or laser ablation at the level of the skin surface is effective. The term acquired reactive digital fibroma has been proposed for a unique form of posttraumatic dermal nodular fibrous proliferation present on the digits. The lesions are composed of haphazard fascicles of spindle cells that express vimentin and occasionally CD34.

**Frydman AF, et al:** Acquired fibrokeratoma presenting as multiple plantar nodules. *Dermatol Online J* 2010; 16(10):5.

**Plaza JA, et al:** Acquired reactive digital fibroma: a clinicopathologic report of 5 cases of a new entity. *J Am Acad Dermatol* 2013; 69(4):603–608.

**Wheless JW, et al:** A novel topical rapamycin cream for the treatment of facial angiofibromas in tuberous sclerosis complex. *J Child Neurol* 2013; 28(7):933–936.

### Familial myxovascular fibromas

Multiple verrucous papules on the palms and fingers have been described that on biopsy show focal neovascularization and mucinlike changes in the papillary dermis. Clinically, these lesions closely resemble warts. They have been reported in several family members, with a probable autosomal dominant inheritance.

### Superficial acral fibromyxoma (digital fibromyxoma)

Superficial acral fibromyxoma typically appears in the superficial soft tissues of the acral extremity of an adult. Most are painless. Histologically, they are characterized by a moderately cellular proliferation of bland, spindled and stellate fibroblasts with a loose storiform or fascicular growth pattern. Mucin and small blood vessels are prominent. Spindle cells typically express CD34, CD99, and epithelial membrane antigen. CD10 and nestin expression have also been reported.

**Hollmann TJ, et al:** Digital fibromyxoma (superficial acral fibromyxoma): a detailed characterization of 124 cases. *Am J Surg Pathol* 2012; 36(6):789–798.

### Subungual exostosis

Subungual exostosis is closely related to solitary osteochondroma, and both are found beneath the distal edge of the nail, most frequently of the great toe. Rarely, the terminal phalanges of other toes, particularly the little toe, or even the fingers, may be involved. The exostosis is seen mainly in women between ages 12 and 30. The first appearance is a small pinkish growth projecting slightly beyond the inner free edge of the nail. The overlying nail becomes brittle and either breaks or is removed, after which the tumor, being released, mushrooms upward and distally above the level of the nail. It grows slowly to a maximum diameter of about 8 mm. Pressure of the shoe on the lesion causes great pain.

Subungual exostosis must be differentiated from pyogenic granuloma, verruca vulgaris, pterygium invernium unguis, ingrowing nail, and glomus tumor. If subungual exostosis is suspected, the diagnosis can be confirmed by radiographic examination. Complete excision or curettage is the proper method of treatment. Secondary intention healing is generally good. Vacuum-assisted closure has been used for large wounds.

**Dacambra MP, et al:** A novel management strategy for subungual exostosis. *BMJ Case Rep* 2013; Aug 30.

**Starnes A, et al:** Subungual exostosis: a simple surgical technique. *Dermatol Surg* 2012; 38(2):258–260.

### Chondrodermatitis nodularis chronica helicis

This small, nodular, tender, chronic inflammatory lesion occurs on the helix of the ear. Most patients are men. The lesions are not uncommon, and sometimes as many as 12

nodules may arrange themselves along the edge of the upper helix. The lesions are 2–4 mm in diameter, well defined, slightly reddish, and extremely tender. At times, the surface is covered by an adherent scale or a shallow ulcer. After the masses have reached a certain size, growth ceases, but the lesions persist unchanged for years. There is no tendency to malignant change. Similar lesions may occur on the anthelix, predominantly in women.

Chondrodermatitis nodularis chronica heliis is produced by ischemic necrosis of the dermis and generally occurs on the side the patient favors during sleep. The patient may have a history of frostbite, chronic trauma, or chronic actinic exposure with concomitant actinically induced lesions of the face and dorsal hands.

Histologically, a zone of eosinophilic necrosis of collagen is flanked by granulation tissue. Overlying acanthosis and hyperkeratosis and central ulceration may be present. The histologic changes resemble those of a decubitus ulcer, but on a smaller scale. Occasionally, bizarre reactive fibroblasts are noted, as in atypical decubital fibroplasia.

Topical nitroglycerin is effective in some patients with chondrodermatitis nodularis chronica heliis, and pressure-induced ischemia can be reduced with the use of a self-adhering foam before sleep. Refractory lesions may be removed by shave technique, or the underlying cartilage may be excised or fenestrated to reduce pressure on the overlying skin during sleep. The patient may be encouraged to change sleeping positions, but many find this difficult. Pillows with an ear slot are also available.

**Cognetta AB Jr, et al:** Triangular window technique: a novel approach for the surgical treatment of chondrodermatitis nodularis heliis. *Dermatol Surg* 2012; 38(11):1859–1862.

**Flynn VR, et al:** Topical nitroglycerin: a promising treatment option for chondrodermatitis nodularis heliis. *J Am Acad Dermatol* 2011; 65(3):531–536.

**Garrido Colmenero C, et al:** Nitroglycerin patch for the treatment of chondrodermatitis nodularis heliis: a new therapeutic option. *Dermatol Ther* 2014; 27(5):278–280.

**Travelute CR:** Self-adhering foam: a simple method for pressure relief during sleep in patients with chondrodermatitis nodularis heliis. *Dermatol Surg* 2013; 39(2):317–319.

**Yaneza MM, et al:** Chondrodermatitis nodularis chronica heliis excision and reconstruction. *J Laryngol Otol* 2013; 127(1):63–64.

## Oral submucous fibrosis

A distinctive fibrosis of the oral mucosa has become common in the western Pacific basin and South Asia among persons whose diet is heavily seasoned with chili or who chew betel, a compound of the nut of the areca palm, the leaf of the betel pepper, and lime. The irritation produced first causes a thickening of the palate, tonsillar pillars, and fauces secondary to dermal and muscular fibrosis (Fig. 28-28). As the disease progresses, opening of the mouth and protrusion of the tongue develop, such that eating, swallowing, and speech are impaired. Later, ulceration and leukoplakic areas occur, and finally, in approximately 7% of patients, malignant transformation to squamous cell carcinoma develops. Treatment consists of the intralesional injection of triamcinolone or dexamethasone alone or with hyaluronidase or the antioxidant spirulina. In advanced cases, surgical excision and grafting or laser ablation has been used. Discontinuance of the offending substance and physical therapy are also needed.

**Ameer NT, et al:** A cross sectional study of oral submucous fibrosis in central India and the effect of local triamcinolone therapy. *Indian J Otolaryngol Head Neck Surg* 2012; 64(3): 240–243.

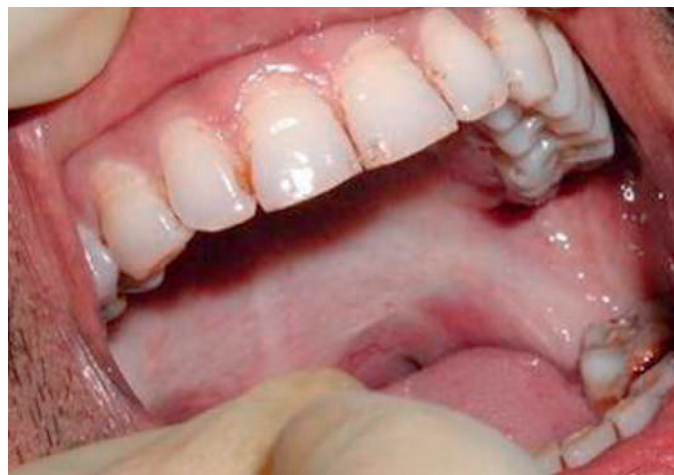

Fig. 28-28 Oral submucous fibrosis. (Courtesy of Dr. Shyam Verma.)

**Shetty P, et al:** Efficacy of spirulina as an antioxidant adjuvant to corticosteroid injection in management of oral submucous fibrosis. *Indian J Dent Res* 2013; 24(3):347–350.

**Yoithaprabhunath TR, et al:** Pathogenesis and therapeutic intervention of oral submucous fibrosis. *J Pharm Bioallied Sci* 2013; 5(Suppl 1): S85–S88.

## Fascial hernia

Evanescent herniations in the form of nodules appear in the skin where the deep and superficial veins meet as they go through the fascia. These herniated nodules, seen most frequently on the lower extremities, become prominent when the underlying muscles contract, and pain may occur with prolonged exertion. Treatment is not indicated unless the area is chronically painful. Light compression may be effective.

**Harrington AC, et al:** Hernias of the anterior tibialis muscle. *J Am Acad Dermatol* 1990; 22:123.

## Perineal skin tag (infantile perianal pyramidal protrusion)

Perineal skin tags may be congenital or acquired. They are generally asymptomatic but may require surgical intervention if inflamed or traumatized. A similar appearance may occur as a manifestation of lichen sclerosus.

## Cutaneous pseudosarcomatous polyp and umbilical polyp

Cutaneous pseudosarcomatous polyps and umbilical pseudosarcomatous polyps are benign proliferations with a taglike configuration but also dramatic cytologic atypia and pleomorphism. The cells stain positive for vimentin and variably for CD34 and factor XIIIa. Their clinical behavior is benign.

**Bord A, et al:** Prenatal sonographic diagnosis of congenital perineal skin tag: case report and review of the literature. *Prenat Diagn* 2006; 26(11):1065–1067.

**Cathro HP, et al:** Cutaneous pseudosarcomatous polyp: a recently described lesion. *Ann Diagn Pathol* 2008; 12(6):440–444.

## Acrochordon (fibroepithelial papilloma, skin tag)

Small, flesh-colored to dark-brown, pinhead-sized and larger, sessile and pedunculated papillomas commonly occur on the



neck, often in association with small seborrheic keratoses. These tags are also seen frequently in the axillae and on the eyelids and less often on the trunk and groins, where the soft, pedunculated growths often hang on thin stalks. These flesh-colored, teardrop-shaped tags feel like small bags. Occasionally, as a result of twisting of the pedicle, one will become inflamed, tender, and even gangrenous. Both genders have the same incidence, with almost 60% of individuals acquiring acrochordons by age 69. Skin tags often increase in number when the patient is gaining weight or during pregnancy and may be related to the growth hormone–like activity of insulin. They may be associated with diabetes mellitus. In patients preselected for GI complaints, skin tags appear to be more prevalent in those with colonic polyps. This association has not been proved for the general population.

Histologically, acrochordons are characterized by epidermis enclosing a dermal fibrovascular stalk. Smaller lesions often demonstrate seborrheic keratosis–like acanthosis and horn cysts.

Small lesions can be clipped off at the base with little or no anesthesia. Aluminum chloride may be applied for hemostasis if needed. Light electrodesiccation can also be effective. For larger lesions, anesthesia and snip excision are preferred.

An entity that is frequently reported as perianal acrochordons or skinfolds has now been named infantile perianal pyramidal protrusions. This occurs in young children, usually girls, in the midline anterior to the anus. It reduces with time, and no treatment is necessary. Child abuse, genital warts, hemorrhoids, granulomatous lesions of inflammatory bowel disease, or rectal prolapse must be considered in the differential diagnosis of these lesions.

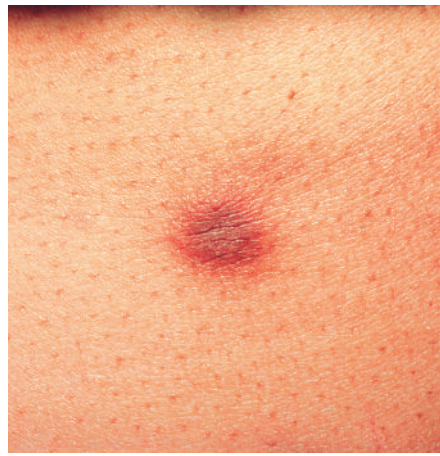Skin tag–like basal cell carcinomas in childhood should suggest a diagnosis of nevoid basal cell carcinoma syndrome (NBCCS). Biopsy should be performed on acrochordons in children because the lesions are uncommon in this age group and may be the presenting sign of NBCCS.

### Dermatofibroma (fibrous histiocytoma)

This common skin lesion's appearance is usually sufficiently characteristic to permit clinical diagnosis. Dermatofibroma is generally a single, round or ovoid papule or nodule, about 0.5–1 cm in diameter, that is reddish brown, sometimes with a yellowish hue. The sharply circumscribed nodule is more evident on palpation than expected from inspection. The larger lesions may present an abrupt elevation at the border to form an exteriorized tumor resting on a sessile base.

Dermatofibroma may be elevated or slightly depressed. The hard lesion is adherent to the overlying epidermis, which may be thinner from pressure or even indented, so that there is a dell-like depression over the nodule (Fig. 28-29). In such cases, only the depression is seen, but on palpation, the true nature of the lesion is found. Fitzpatrick proposed the term “dimple sign” for the depression created over a dermatofibroma when it is grasped gently between thumb and forefinger.

Dermatofibromas seldom occur in children and are encountered mostly in middle-age adults. Their size generally varies from 4 to 20 mm, although giant lesions greater than 5 cm occur. After they reach this size, growth ceases, and the harmless lump remains stationary. The principal locations are on the lower extremities, above the elbows, or on the sides of the trunk. Systemic lupus erythematosus, treatment with prednisone or immunosuppressive drugs, chronic myelogenous leukemia, and HIV infection have been associated with the development of multiple dermatofibromas. It is suspected that many dermatofibromas are initiated by injuries to the skin, such as insect bites or blunt trauma.



**Fig. 28-29**  
Dermatofibroma.  
(Courtesy of Dr.  
Lawrence Lieblich.)

Histologic examination reveals a dermal mass composed of close whorls of fibrous tissue in which there are numerous spindle or histiocytic cells. The cells have features of fibroblasts and myofibroblasts but are probably of primitive mesenchymal origin. Immunohistochemical studies show that most cells are positive for factor XIIIa and CD10, and negative for MAC387, S-100, and CD34. The tumor is not well circumscribed and may extend into adjacent structures and surround individual collagen bundles at the periphery (collagen trapping). Overlying acanthosis is typical, and induction of primitive epithelial germs or mature follicular structures may be noted. Basal cell carcinoma–like changes often overlie dermatofibromas, but true basal cell carcinoma is quite rare.

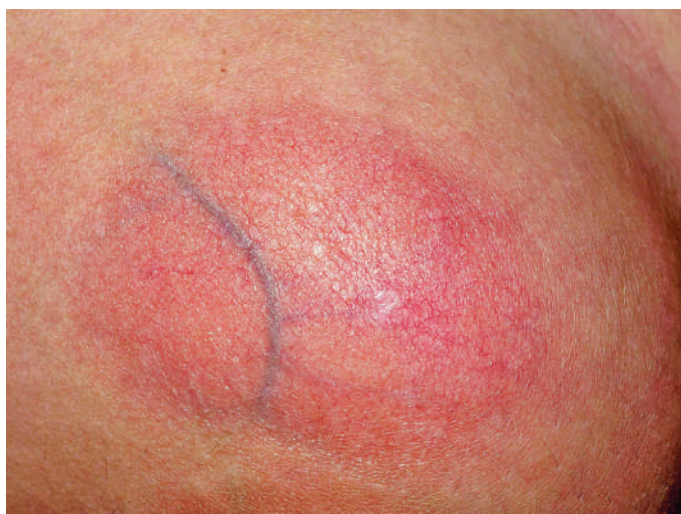At times, large histiocytic cells within the lesion are strikingly atypical (“monster cells”). Occasionally, granular cytoplasm may predominate. Hemosiderin may be present, and foam cells and lipid deposits may be seen. The presence of Touton giant cells containing hemosiderin is pathognomonic of dermatofibroma. There is a great variation in the vascular components. Rarely, the vascularization is pronounced and suggests a form of hemangioma (sclerosing hemangioma). Deep, penetrating dermatofibromas may grow into the subcutaneous tissue through the fibrous septa or with a pushing front of tumor. They lack the extensive lacy and lamellar infiltrative growth pattern of dermatofibrosarcoma protuberans. Deep, fascial, fibrous histiocytomas may involve the fat or muscle at times. Signet ring and plaque-type variants have been described. A pigmented variant has shown histologic overlap with Bednar tumor (pigmented dermatofibrosarcoma protuberans). The lesion stained positive for CD34, a marker usually absent in dermatofibromas.

The clinical appearance of the lesion and its location, chiefly on the lower extremities, are distinctive. Clinically, granular cell tumor, dermatofibrosis lenticularis disseminata, clear cell acanthoma, and melanoma are some of the lesions to be considered. At times, only a biopsy can differentiate these. Progressive enlargement beyond 2 or 3 cm in diameter suggests a malignant fibrous histiocytoma or dermatofibrosarcoma protuberans, and excisional biopsy is indicated.

These lesions usually are asymptomatic and do not require treatment. Involution may occur after many years if the lesion is left alone. Simple reassurance is suggested.

### Epithelioid cell histiocytoma

Usually solitary but occasionally multiple, these lesions appear as dome-shaped papules composed of bland epithelioid cells. These histiocytomas typically stain for factor XIIIa, and many consider them to be closely related to dermatofibromas.



**Fig. 28-30** Dermal dendrocyte hamartoma.

**Gómez-Mateo Mdel C, et al:** Nonepithelial skin tumors with multinucleated giant cells. *Semin Diagn Pathol* 2013; 30(1):58–72.

**Shaheen B, et al:** Multiple clustered dermatofibromas (fibrous histiocytomas): an atypical clinical variant of dermatofibroma. *Clin Exp Dermatol* 2013; 39(1):88–90.

### Dermal dendrocyte hamartoma

Dendrocyte hamartoma presents as a rounded, medallion-like lesion on the upper trunk; it is composed of fusiform CD34, factor XIIIa-positive cells in the middle and reticular dermis. The lesions are asymptomatic, brown or erythematous in color, and may have a slightly atrophic, wrinkled surface (Fig. 28-30). The major differential diagnosis is congenital atrophic dermatofibrosarcoma protuberans (DFSP), but to date there has been no evidence of chromosomal abnormalities, such as the t(17; 22)(q22; q13) translocation with the DFSP fusion gene *COL1A1-PDGFB*.

**Marque M, et al:** Medallion-like dermal dendrocyte hamartoma: the main diagnostic pitfall is congenital atrophic dermatofibrosarcoma. *Br J Dermatol* 2009; 160(1):190–193.

### Nodular fasciitis (nodular pseudosarcomatous fasciitis)

Also known as subcutaneous pseudosarcomatous fibromatosis, this benign mesenchymal neoplasm occurs most often on the arms. Clinically, a firm, solitary, sometimes tender nodule develops in the deep fascia and often extends into the subcutaneous tissue. It usually measures 1–4 cm in diameter. The lesion appears suddenly over a few weeks, without apparent cause, in normal, healthy persons. Gender distribution is equal, and the average age at onset is 40.

Microscopic findings consist of well-defined, loose nodules of stellate and spindle cells that may have a myxoid “tissue culture” appearance. Capillary proliferation is typical, and erythrocyte extravasation between spindle cells is common. Nodular lymphoid infiltrates are often noted within the lesion. On electron microscopic examination, the component cells in the neoplasm have proved to be myofibroblasts. A characteristic t(17; 22)(p13; q13), balanced translocation has been described resulting in *MYH9-USP6* gene fusion.

Dermal, intravascular, and infiltrative variants with ganglionlike cells (proliferative fasciitis) have been described. These are designated when the nodular masses arise in the dermis, in intimate association with blood vessels, or show

ganglionlike giant cells and infiltration of collagen. The proper treatment is complete excision. Recurrence is rare, and the prognosis is excellent. A rapid response to intralesional corticosteroids has been reported in one case.

Cranial fasciitis of childhood is an uncommon variant of nodular fasciitis, manifesting as a rapidly enlarging mass in the subcutaneous tissue of the scalp, which may invade the cranium. It occurs in infants and children, resembles nodular fasciitis histologically, and usually does not recur after surgical excision. Some lesions have demonstrated dysregulation of the Wnt/ $\beta$ -catenin pathway.

Proliferative fasciitis and proliferative myositis are closely related entities. Proliferative fasciitis demonstrates irregular extension into the fibrous septa with collagen trapping and ganglionlike nuclei. Proliferative myositis has a similar appearance but extends into adjacent muscle.

Pseudosarcomatous ischemic fasciitis (atypical decubital fibroplasia) is a manifestation of pressure-induced necrosis. The histologic appearance is similar to that of chondrodermatitis nodularis of the ear, only on a much larger scale. A wide zone of fibrinoid necrosis is bordered by granulation tissue and large, atypical fibroblast nuclei that resemble radiation fibroblasts.

**Amary MF, et al:** Detection of USP6 gene rearrangement in nodular fasciitis: an important diagnostic tool. *Virchows Arch* 2013; 463(1):97–98.

**Khuu A, et al:** Nodular fasciitis: characteristic imaging features on sonography and magnetic resonance imaging. *J Ultrasound Med* 2014; 33(4):565–573.

### Solitary fibrous tumor

Solitary fibrous tumors occur in the mediastinum but may also be found in many other parts of the body. They have a diffuse, “patternless” growth pattern and stain strongly positive for CD34. Some express progesterone receptor. Their behavior is unpredictable, and complete excision is recommended. Spindle cell lipomas with few or no lipocytes (“low-fat” and “nonfat” spindle cell lipomas) may be misinterpreted as solitary fibrous tumors because they are also CD34 positive.

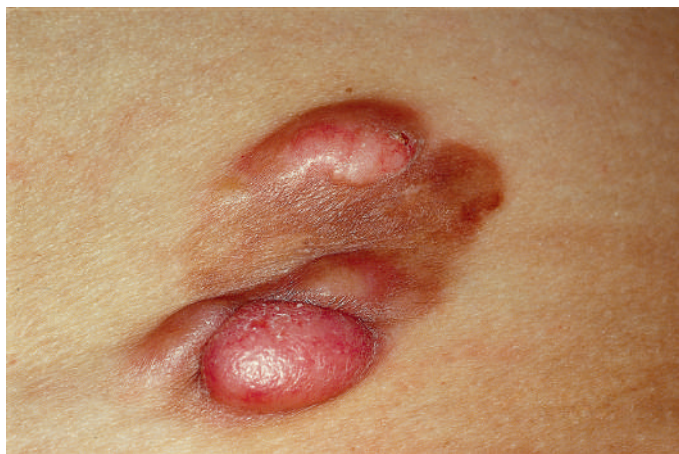**Insabato L, et al:** Extrapleural solitary fibrous tumor: a clinicopathologic study of 19 cases. *Int J Surg Pathol* 2009; 17(3):250–254.

### Plexiform fibrohistiocytic tumor

The rare plexiform fibrohistiocytic tumor arises primarily on the upper extremities of children and young adults. There is a strong female predisposition. It presents as a slowly growing, painless growth in the subcutaneous tissue. There is usually extension into the dermis or the underlying skeletal muscle. Histologically, it is a distinctly biphasic tumor, with a fibroblastic component mixed with aggregates of mononuclear histiocyte-like cells and multinucleated osteoclast-like cells. The multinucleated cells label for vimentin and CD68, whereas the spindle cells express smooth muscle actin but not factor XIIIa. There is considerable histologic overlap with cellular neurothekeoma. Both tumors are uniformly positive for NKIC3 and CD10. MiTF is strongly and diffusely positive in cellular neurothekeoma but negative in the plexiform fibrohistiocytic tumor, suggesting that the two are distinct. Although most patients are cured with excisional surgery, some tumors will recur locally, and infrequently, regional and systemic metastases can occur.

**Fox MD, et al:** Expression of MiTF may be helpful in differentiating cellular neurothekeoma from plexiform fibrohistiocytic tumor (histiocytoid predominant) in a partial biopsy specimen. *Am J Dermatopathol* 2012; 34(2):157–160.





**Fig. 28-31** Recurrent dermatofibrosarcoma protuberans.

**Lynnhtun K, et al:** Plexiform fibrohistiocytic tumour: morphological changes and challenges in assessment of recurrent and metastatic lesions. *Histopathology* 2012; 60(7):1156–1158.

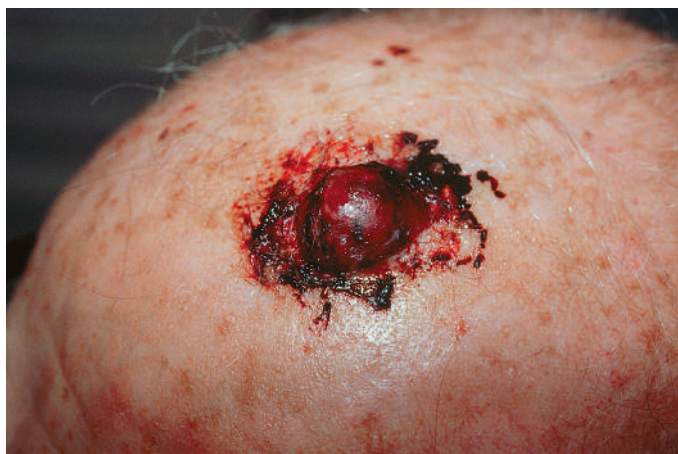### Dermatofibrosarcoma protuberans

Dermatofibrosarcoma protuberans (DFSP) is characterized by bulky, protuberant, neoplastic masses. Between 50% and 60% occur on the trunk, with less common involvement of the proximal extremities and the head and neck. The disease begins with one or multiple elevated, erythematous, firm nodules or plaques, often associated with a purulent exudate or with ulceration. Patients, usually middle-age, complain of a firm, painless lump in the skin that has been slowly increasing in size for several years. The course is slowly progressive, with pain becoming prominent as the lesion grows, and frequent recurrence after initial conservative surgical intervention (Fig. 28-31). In untreated patients, severe pain and contractures may result. There is minimal tendency to metastasize, although wide dissemination has been reported.

Histologically, DFSP shows a subepidermal fibrotic plaque with uniform spindle cells and variable vascular spaces. In many cases, there is a pronounced matlike woven pattern of spindle cells. Cytogenetic studies demonstrate a t(17;22)(22; q13) fusion involving the *COL1A1* gene on chromosome 17 and the *PDGFB* gene on chromosome 22. Giant cells may be present in small numbers. Pigmented DFSPs, in which the cells contain melanin, predominantly affect persons of color and are called Bednar tumors. CD34 and nestin positivity are characteristic and serve as markers to distinguish DFSP from dermatofibroma. Nestin expression correlates with the degree of invasion. S-100 is negative and may be used to separate spindle cell melanoma from a Bednar tumor. Recurrent DFSP can be myxoid and resembles the diffuse type of neurofibroma histologically. A juvenile variant, called giant cell fibroblastoma, is characterized by a loose arrangement of spindle cells and by multinucleated giant cells adjacent to dilated spaces that resemble dilated lymphatic vessels.

The differential diagnosis, especially in the early stage, is that of keloid, large dermatofibroma, or medallion-like dermal dendrocytoma. CD34+ myxoid dermatofibrohistiocytoma of the skin occurs as an indolent posttraumatic tumor. It resembles myxoid DFSP.

Mohs surgical excision technique is the treatment of choice for DFSP. In a series of 50 patients, recurrence rate was 2%; with wide local excision, recurrence is 11–50%. A preoperative MRI may assist in planning successful clearance. Imatinib mesylate has been effective in some unresectable tumors, but resistance may occur.



**Fig. 28-32** Atypical fibroxanthoma. (Courtesy of Dr. Daniel Loo.)

**Cheon M, et al:** Medallion-like dermal dendrocyte hamartoma: differential diagnosis with congenital atrophic dermatofibrosarcoma protuberans. *Ann Dermatol* 2013; 25(3):382–384.

**Hong JY, et al:** Genetic aberrations in imatinib-resistant dermatofibrosarcoma protuberans revealed by whole genome sequencing. *PLoS One* 2013; 8(7):e69752.

**Serra-Guillén C, et al:** High immunohistochemical nestin expression is associated with greater depth of infiltration in dermatofibrosarcoma protuberans: a study of 71 cases. *J Cutan Pathol* 2013; 40(10): 871–878.

### Atypical fibroxanthoma

Atypical fibroxanthoma (AFX) of the skin is a low-grade malignancy that occurs chiefly on the sun-exposed parts of the head or neck in white persons over age 50. Most cases appear to be related to undifferentiated pleomorphic sarcoma (malignant fibrous histiocytoma), which AFX resembles histologically. Its smaller size and more superficial location account largely for its more favorable prognosis. Some cases probably represent spindled or anaplastic squamous cell carcinoma (SCC) that has lost the ability to express keratin. Clinically, the tumor begins as a small, firm nodule, often with an eroded or crusted surface without characteristic morphologic features (Fig. 28-32). A distinct clinical variant has a different presentation as a slowly enlarging tumor on a covered area, in patients with an average age of 39. This variant accounts for 25% of cases.

The lesion develops in the dermis and is separated from the epidermis by a thin band of collagen. The tumor consists of bizarre spindle cells mingled with atypical histiocytic cells. The cytoplasm may be vacuolated and resembles the xanthoma cell. Mitotic figures, prominent eosinophilic nucleoli, and the presence of a biphasic tumor cell population are characteristic findings, but purely spindle cell variants also occur. S-100 staining decorates colonizing dendritic cells, but not the tumor cells, and prekeratin staining is negative; this helps to distinguish AFX from SCC. Variants with clear cells, granular cells, and osteoclast-type cells have been described. Tumor cells stain for CD10, S-100A6, and procollagen I, but none of these markers is specific for AFX.

The treatment of choice is complete surgical excision. Mohs microsurgery results in fewer recurrences and smaller defects than conventional excision. Although the prognosis is excellent, local recurrence after inadequate excision is common, and cases of metastasizing AFX have been reported.

**Gru AA, et al:** Atypical fibroxanthoma: a selective review. *Semin Diagn Pathol* 2013; 30(1):4–12.

## Undifferentiated pleomorphic sarcoma (malignant fibrous histiocytoma)

The undifferentiated pleomorphic type is the most common soft tissue sarcoma of middle and late adulthood. It arises deeply and is more likely to appear in deep fascial planes than in subcutaneous tissue. One third occur on the thigh or buttock. Peak incidence is in the seventh decade. These sarcomas sometimes arise in an area of radiodermatitis or in a chronic ulceration.

Several histologic variants have been described, including myxoid, inflammatory, and giant cell types. Gene expression profiling is now being used to define subtypes of pleomorphic sarcoma. Cell staining is positive for vimentin and factor XIIIa. Pleomorphic cellular elements and bizarre mitotic figures are characteristic. AFXs are smaller and more superficial tumors of the dermis, compared with the deeper location of undifferentiated pleomorphic sarcoma (UPS). Epithelioid sarcoma lacks the large, bizarre, multinucleated cells often seen in UPS.

The prognosis in UPS is related to the site; deeper and more proximally located tumors have a poorer prognosis. The myxoid variant is less likely to metastasize. An especially poor prognosis attends tumors arising in sites of radiodermatitis. Local recurrence after excision occurs in 25%, 35% metastasize, and overall survival is 50%. Mohs surgical removal may result in fewer recurrences.

The angiomatoid type may have a different presentation on the extremities of children, as a slowly growing dermal or subcutaneous mass. It has been separated because it has a relatively good prognosis.

## Cutaneous myxofibrosarcoma

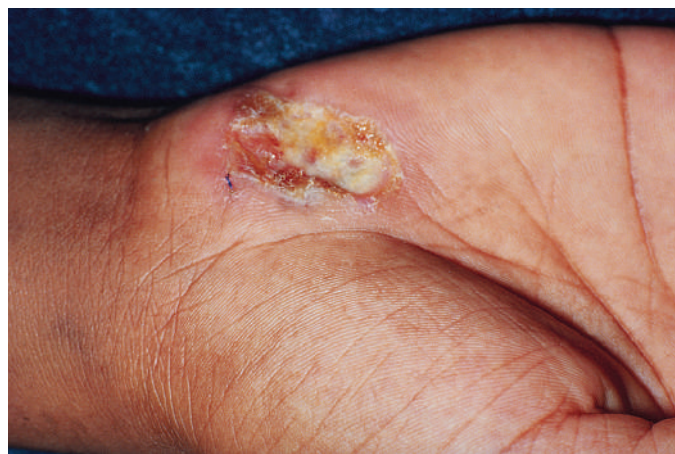Myxofibrosarcoma is the term used for myxoid variants of UPS. The diagnosis of cutaneous myxofibrosarcoma is often delayed because the tumor may appear indolent clinically and may mimic an interstitial granuloma histologically. Areas of atypical spindle cells within a prominent myxoid stroma and pleomorphic multinucleated cells suggest the diagnosis. The main differential diagnosis is myxoid liposarcoma. The margins are often poorly defined, and preoperative MRI can be helpful in surgical planning.

**Riouallon G, et al:** Superficial myxofibrosarcoma: assessment of recurrence risk according to the surgical margin following resection: a series of 21 patients. *Orthop Traumatol Surg Res* 2013; 99(4): 473–477.

## Epithelioid sarcoma

Epithelioid sarcoma occurs chiefly in young adults, with onset usually from ages 20 to 40. Two thirds of cases are in men. Almost all lesions are on the extremities, with half on the hands or wrists (Fig. 28-33). They have been reported from a wide variety of locations, however, including the genital region (“proximal type”).

The tumor grows slowly among fascial structures and tendons, often with central necrosis of the tumor nodules and ulceration of the overlying skin. Initial clinical diagnoses may include granuloma annulare, rheumatoid nodule, or ganglion cyst. Histologically, irregular nodular masses of large, deeply acidophilic, polygonal cells merge with spindle cells in a biphasic pattern. Central necrosis within masses of epithelioid cells may give the impression of a palisaded granuloma. Absence of staining for CD68 (KP-1) and coexpression of keratins and vimentin confirm the diagnosis. Loss of INI1



**Fig. 28-33** Epithelioid sarcoma.

expression is also helpful diagnostically, but has no prognostic implications.

Wide local excision of small, early lesions may achieve a cure. Recurrence after attempted excision is seen in three of four patients, and late metastasis in 45%. There is a propensity for lymph node and lung metastases, and in one series of eight patients, 5-year and 10-year survival rates of 25% were reported. Women have a more favorable prognosis; the proximal lesions have a worse prognosis.

**Chbani L, et al:** Epithelioid sarcoma: a clinicopathologic and immunohistochemical analysis of 106 cases from the French sarcoma group. *Am J Clin Pathol* 2009; 131(2):222–227.

## Myxomas

Cutaneous myxomas may be solitary and may appear as flesh-colored nodules on the face, trunk, or extremities. They may also occur as part of Carney complex. This has also been reported under the acronyms NAME (nevi, atrial myxoma, myxoid neurofibromas, ephelides) and LAMB (lentiginos, atrial myxoma, mucocutaneous myxomas, blue nevi) and simply as cutaneous lentiginosis with atrial myxoma.

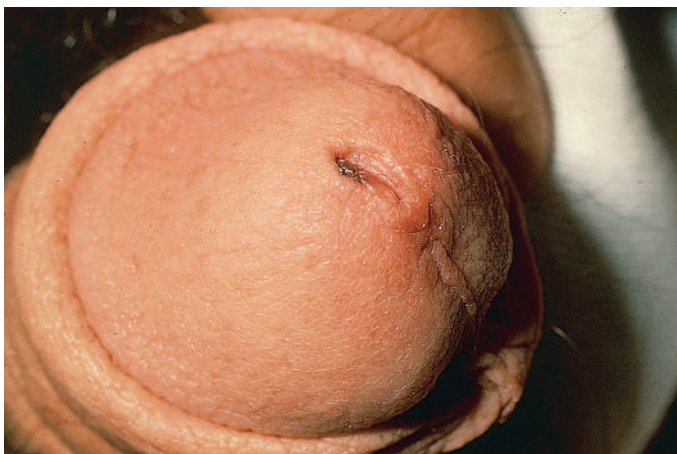
The Carney complex consists of patients who have two or more of the following:

1. Cardiac myxomas (79%)
2. Cutaneous myxomas (not myxoid neurofibromas) (45%)
3. Mammary myxoid fibromas (30%)
4. Spotty mucocutaneous pigmentation, including lentiginos (not ephelides) and blue nevi, often of a distinctive epithelioid variety (65%)
5. Adrenocortical adenoma/primary pigmented nodular adrenocortical disease (45%), which results in Cushing syndrome
6. Testicular tumors (56% of male patients)
7. Pituitary growth hormone-secreting tumors (10%).

A peculiar type of schwannoma featuring melanin and psammoma bodies may also be present.

The cutaneous myxomas occur as small (<1 cm), multiple, skin-colored papules with a predilection for development by a mean age of 18 years, and a tendency to occur on the ears, eyelids, and nipples. The lentiginos are prominent on the face, lips, conjunctival mucosa, rectal mucosa and genital mucosa (Fig. 28-34). Cardiac myxomas may occur in any of the four chambers of the heart and are recurrent in 20%. They may embolize to the skin, producing acral necrotic lesions.





**Fig. 28-34** Characteristic pigmentation on the penile mucosa in Carney syndrome.

Recognition of this syndrome, with diagnosis and removal of the atrial myxomas, can be lifesaving. The first-degree family members should be examined because this is an autosomal dominant inherited condition. The disease has been mapped to two loci, and a third is likely. Mutations in the gene coding for the protein kinase A type Ia regulatory subunit (*PPKAR1A*) on chromosome 17 have been documented in about half the families.

A malignant counterpart, the myxosarcoma, is a tumor that arises in the subcutaneous fat and underlying soft tissues. There is a tendency for local recurrence after wide and deep excision. Metastases are rare.

**Carney JA, et al:** Adrenal cortical adenoma: the fourth component of the Carney triad and an association with subclinical Cushing syndrome. *Am J Surg Pathol* 2013; 37(8):1140–1149.

**Mateus C, et al:** Heterogeneity of skin manifestations in patients with Carney complex. *J Am Acad Dermatol* 2008; 59(5):801–810.

### Aggressive angiomyxoma

Aggressive angiomyxoma is an uncommon soft tissue neoplasm that usually involves the vulvoperineal and pelvic regions of young women. Any angiomyxoid tumor in this area is suspect for aggressive behavior. The tumor is mucinous and deeply infiltrative but does not demonstrate nuclear atypia or mitosis. The rate of local recurrence is high despite wide surgical resection, and MRI can be helpful in preoperative planning.

**Bai HM, et al:** Individualized managing strategies of aggressive angiomyxoma of female genital tract and pelvis. *Eur J Surg Oncol* 2013; 39(10):1101–1108.

### MASTOCYTOSIS

Mastocytosis is a general term applied to local and systemic accumulations of mast cells. Mast cells are bone marrow-derived CD34+ cells. These cells carry preformed mediators, such as histamine, heparin, and various cytokines, which, when released, may cause symptoms such as flushing, urticaria, diarrhea, abdominal pain, headache, dyspnea, syncope, and palpitations.

Mastocytosis is divided into childhood-onset and adult-onset disease. The condition varies in these two age groups, in terms of clinical presentation, prognosis, and pathogenic factors. Studies have revealed mutations in the *c-KIT*

### Box 28-1 Classification of mastocytosis

#### Cutaneous and systemic mastocytosis

1. Indolent systemic mastocytosis (ISM)
  - Isolated bone marrow mastocytosis
  - Smoldering systemic mastocytosis (SSM)
2. Systemic mastocytosis with associated hematopoietic disease (SM-AHD, AHNMD [*associated* hematologic non–mast cell disorder]): systemic mastocytosis with leukemia, myelodysplastic syndrome/disease, or non-Hodgkin lymphoma
3. Aggressive systemic mastocytosis (ASM)
4. Mast cell leukemia
5. Mast cell sarcoma
6. Extracutaneous mastocytoma

proto-oncogene in many adult-onset cases. Its protein product is the transmembrane tyrosine kinase KIT receptor (CD117), whose ligand is stem cell factor (also known as mast cell growth factor). Both clonality studies and mutational analysis indicate that many adult cases of mastocytosis result from a neoplastic proliferation of mast cells, with a mutation at codon 816 in the *c-KIT* gene. This mutation is activating, resulting in the proliferation of mast cells. A second mutation, a chromosomal deletion on 4q12, results in the juxtaposition of platelet-derived growth factor receptor- $\alpha$  and FIP1L1. This fusion gene activates hematopoietic cells and is pathogenic in a subset of patients with systemic mastocytosis and eosinophilia. This subset of patients has also been considered as having a type of “hyper eosinophilic syndrome.” Thus, the vast majority of adults with mastocytosis have systemic disease that may be viewed as a fundamentally myelodysplastic disorder.

Children often do not express any *c-KIT* mutation; nor do the uncommon familial cases. The disease in the latter is usually transmitted by autosomal dominant inheritance with reduced expressivity, although other patterns may occur. The mutations leading to familial disease have not been defined. It appears that spontaneous childhood disease may occur from cytokine-derived hyperplasias, from mutations other than the activating 816 type, or from mutations yet to be described. Some pediatric cases, however, are known to have inactivating mutations of *c-KIT*, and a few have the adult-type activating mutations. Childhood disease is defined as occurring before age 15. The majority of children develop their disease before age 2, and in most of them, the condition spontaneously involutes.

### Clinical classification

Mast cell disease is divided into two broad categories—cutaneous and systemic. Cutaneous mastocytosis describes cases with involvement of only the skin and includes most cases of childhood mastocytosis and infrequent adult cases. Childhood cases usually fall into one of three categories of cutaneous mastocytosis. The most common (60–80% of patients) is urticaria pigmentosa or so-called “maculopapular” cutaneous mastocytosis; fewer (10–35%) patients present with solitary mastocytosis; the remainder have the rare forms of diffuse cutaneous mastocytosis or the telangiectatic type. A classification has been proposed by Akin and Metcalfe, which incorporates the World Health Organization (WHO) criteria (Box 28-1).

The vast majority of adult patients with mastocytosis are classified as having systemic mastocytosis, since they typically have clonal proliferation of the bone marrow–derived mast cells. Of adult patients with systemic mastocytosis not associated with hematopoietic disease, 60% have indolent mastocytosis and 40% have aggressive mastocytosis. Patients with aggressive systemic mastocytosis usually lack skin lesions. Mast cell leukemia and sarcoma are very rare. Many patients who present to the dermatologist with only skin lesions will have the indolent variety. Symptoms and signs of systemic disease are classified as those related to organ infiltration by mast cells and those caused by mediator release from mast cells. Direct organ involvement is most frequently bone pain from lytic bone lesions, hepatosplenomegaly, lymphadenopathy, or cytopenia from bone marrow involvement. For the dermatologist, the most important symptoms are those related to mediator release, usually acting on the GI tract, respiratory tree, or blood vessels. These include pruritus, flushing, urticaria, angioedema, headache, nausea, vomiting, abdominal cramps, diarrhea, gastric/duodenal ulcer, malabsorption, asthmalike symptoms, presyncope, syncope, and anaphylaxis. These may occur spontaneously or may result from massive histamine release after ingestion of known mast cell degranulators, such as alcohol, morphine, codeine, or extended rubbing of the skin. *Hymenoptera* stings may induce anaphylaxis. Mast cells also produce heparin, which may result in hematemesis, epistaxis, melena, and ecchymoses. Osteoporosis may also occur from chronic heparin release, resulting in fractures.

### Cutaneous mastocytosis

Cutaneous mastocytosis is relatively common, representing about 1 in 500 initial consultations to pediatric dermatologists.

#### Solitary mastocytoma

About 10–40% of childhood mastocytosis presents as the solitary lesion, which may be present at birth or may develop during the first weeks of life. It originates as a brown macule that urticates on stroking. It may develop into a papule, a raised round or oval plaque, or a tumor. The size is usually less than 1 cm, but occasionally it may reach two or three times this diameter. The surface is usually smooth but may have a peau d'orange appearance. Although the mastocytoma may occur anywhere on the body, it favors the dorsum of the hand near the wrist. Edema, urtication, vesiculation, and even bulla formation may be observed in the lesion. Even a solitary lesion may produce systemic symptoms, usually flushing.

Although the generalized form may begin with a single lesion, dissemination usually occurs within 3 months of its appearance. Most solitary mastocytomas involute spontaneously by age 10 or earlier. They also respond favorably to excision or to the application of a hydrocolloid dressing to prevent the rubbing that triggers mediator release and symptomatology. Progression to malignant disease does not occur.

#### Generalized eruption, childhood type (urticaria pigmentosa)

The generalized form of cutaneous mastocytosis represents 60–90% of childhood cases. In this type, the eruption usually begins during the first weeks of life, presenting with rose-colored, pruritic, urticarial, slightly pigmented macules, papules, or nodules. The lesions are oval or round and vary in diameter between 5 and 15 mm and may coalesce. The color varies from yellowish brown to yellowish red. Occasionally,

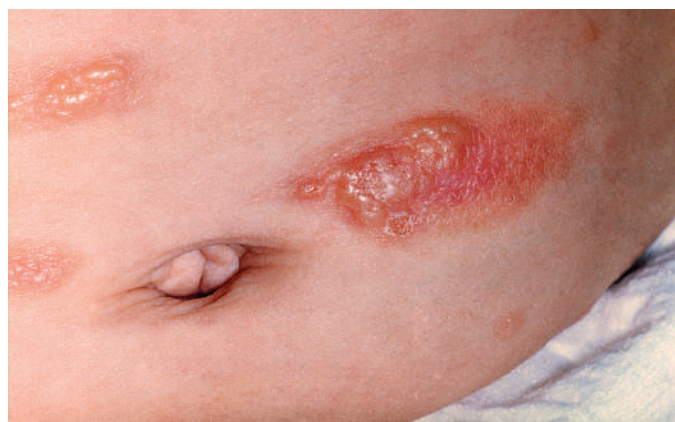


Fig. 28-35 Bullous mastocytosis.

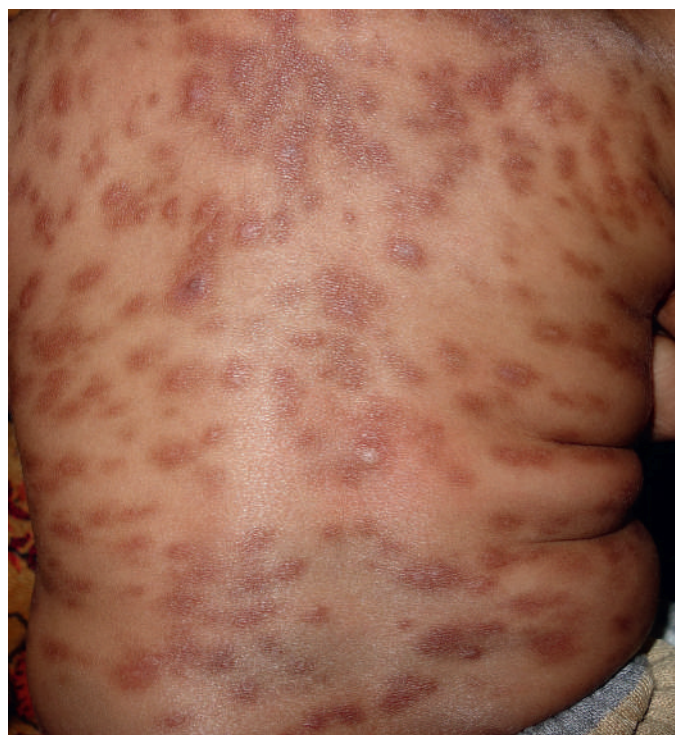

Fig. 28-36 Urticaria pigmentosa.

the lesions are a pale-yellow color, and this has been called xanthelasma. Vesicle and bulla formation is a frequent prominent feature early in the disease (Fig. 28-35). Indeed, vesicles and bullae may be the initial presenting signs, but they usually persist no longer than 3 years. In the older age groups, vesiculation rarely occurs.

At their onset, lesions are similar to urticaria, except that they are not evanescent. The lesions persist and gradually become chamois or slate colored (Fig. 28-36). When they are firmly stroked or vigorously rubbed, urticaria with a surrounding erythematous flare (Darier's sign) usually develops. Dermatographism of clinically uninvolved skin is present in one third to one half of patients. For many years, the brown, waxy skin lesions may persist before they begin to involute. Pigmentation and all evidence of the disease usually disappear within a few years, generally before puberty. The eruption, however, may infrequently persist into adult life. Although systemic involvement is possible, malignant systemic disease is extremely rare.



## Diffuse cutaneous mastocytosis

In this rare form with diffuse involvement, the entire integument may be thickened and infiltrated with mast cells to produce a peculiar orange color, giving rise to the term “homme orange.” There is an infiltrated doughy or boggy consistency to the skin, and lichenification may be present. In the neonatal period, diffuse cutaneous blistering may occur, leading to the diagnosis of epidermolysis bullosa or some other primary bullous disorder. This is termed “bullous mastocytosis.”

### Systemic mastocytosis

Systemic mastocytosis is diagnosed by fulfilling the one major criterion and one minor criterion, or three minor criteria. The major criterion is the finding of dense infiltrates of mast cells (aggregates of 15 or more) in bone marrow or other extracutaneous tissues. The four minor criteria are as follows:

1. Atypical mast cell morphology
2. Aberrant mast cell surface phenotype (CD25 or CD2)
3. Serum/plasma tryptase greater than 20 ng/mL
4. A codon 816 *c-KIT* mutation in peripheral blood, bone marrow, or lesional tissue

Patients with a history of *Hymenoptera*-induced anaphylaxis and an elevated tryptase level should be evaluated for systemic mastocytosis.

The most common type of systemic mastocytosis in adults is indolent systemic mastocytosis. These patients lack evidence of an associated non-mast cell hematologic disorder; lack end-organ dysfunction such as ascites, malabsorption, cytopenias, and pathologic fractures; and lack mast cell leukemia. The disorder is then diagnosed through physical and histopathologic examination of skin lesions. Several different patterns of cutaneous involvement have been described.

### Generalized eruption, adult type

The generalized eruption is the most common pattern of mastocytosis presenting to the dermatologist. The most common lesions are macules, papules, or nodules disseminated over most of the body, but especially on the upper arms, legs, and trunk. The upper arms and upper inner thighs may be the only areas involved on presentation. These may be reddish purple (Fig. 28-37), rust colored, or brown. The brown lesions may closely resemble common nevi. They may urticate on rubbing, as seen in children with urticaria pigmentosa.

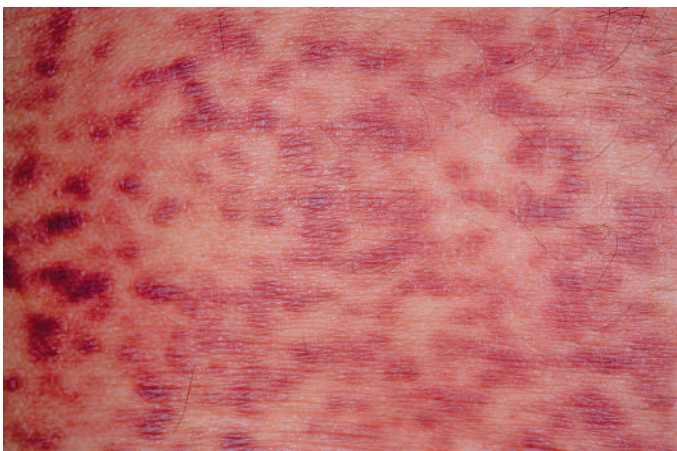


Fig. 28-37 Adult generalized mastocytosis.

### Erythrodermic mastocytosis

There is generalized erythroderma, and the skin has a leather-grain appearance. Urtication can be produced over the entire surface.

### Telangiectasia macularis eruptiva perstans

This is a persistent, pigmented, asymptomatic eruption of macules usually less than 0.5 cm in diameter, with a slightly reddish brown tinge. Despite the name, little or no telangiectasia may be evident. Darier's sign may not be demonstrable, because the number of mast cells in the skin may not be greatly increased.

### Classification and prognosis in adult systemic mastocytosis

The 2008 WHO classification includes indolent systemic mastocytosis (SM), aggressive SM, SM associated with a clonal non-mast cell lineage disease, and mast cell leukemia. Patients with systemic mastocytosis with an associated hematologic non-mast cell lineage disorder (SM-AHNMD) are typically older adults with signs and symptoms of systemic disease. A variety of associated non-mast cell hematologic conditions, including polycythemia vera, hypereosinophilic syndrome, chronic myelogenous or monocytic leukemia, lymphocytic leukemia, primary myelofibrosis, and Hodgkin disease, may be seen. Typically, this type does not have skin lesions. The prognosis in these patients is that of their underlying hematologic condition. Smoldering SM is characterized by a slow progression and lack of end-organ dysfunction from mast cell infiltration. It describes patients with 30% or more infiltration of the bone marrow cavity by mast cells, a serum tryptase level greater than 200 ng/mL, and hepatosplenomegaly. Aggressive SM has a more fulminant course and describes the condition of patients with end-organ dysfunction caused by mast cell infiltration: bone marrow failure, liver dysfunction, splenomegaly with hypersplenism, pathologic fractures, and GI involvement with malabsorption and weight loss. This group of patients has a poor prognosis. Mast cell leukemia occurs when the atypical mast cells (multilobular or multiple nuclei) represent 10% of circulating cells or 20% of bone marrow cells. The prognosis is poor.

### Mast cell sarcoma and extracutaneous mastocytoma

These are rare findings of isolated tumors of either atypical mast cells in mast cell sarcoma or benign-appearing mast cells in extracutaneous mastocytoma. They occur in sites other than the skin or bone marrow. Mast cell sarcomas are aggressive, locally destructive lesions, in contrast to the benign mastocytomas, which carry a good prognosis.

### Biochemical studies

Mast cells produce tryptase. Serum tryptase has become the preferred laboratory test to demonstrate evidence of increased mast cell burden, replacing urinary histamine and urinary histamine metabolites. The test is of prognostic significance in some patients. Tryptase is measured as a total serum tryptase level. This should be obtained when the patient is in a normal state of health, because anaphylaxis will increase tryptase transiently. Mastocytosis patients may have a

persistently and significantly elevated tryptase level. Results above 20 ng/mL are a minor criterion for the diagnosis of systemic mastocytosis.

## Histopathology

The typical skin lesion shows a dense dermal aggregate of mononuclear cells with abundant amphophilic cytoplasm. When these large mononuclear cells are stained with Giemsa or toluidine blue, the metachromatic granules are observed. A Leder stain will stain the cells diffusely red. When blisters are present, the roof of the vesicle or bulla is subepidermal. The mast cells collect in a band below the vesicle. Infiltration of local anesthetic adjacent to the lesion rather than directly into it and the use of anesthetic without epinephrine may help to avoid mast cell degranulation. Monoclonal antibodies against tryptase and CD117 (KIT) are available and are very sensitive.

## Diagnosis

The typical case of cutaneous mastocytosis is easily diagnosed by the presence of solitary or multiple pigmented macules, papules, or nodules that urticate when irritated by stroking or scratching. The diagnosis is confirmed by biopsy of the lesion with demonstration of increased numbers of mast cells. The bullous and vesicular lesions may be more difficult to diagnose clinically; however, scrapings from the base of the bulla when stained with Giemsa or Wright stain will show mast cells in profusion.

Once the diagnosis of skin lesions of mastocytosis is made, the decision to assess for bone marrow involvement is key. Although therapy to reduce the disease burden of proliferating clonal mast cells is not effective, bone marrow examination will provide information about the extent of the disease and the presence or absence of a non-mast cell hematologic disorder, and it will assist in the counseling on prognosis. All adult patients and children with the unexplained presence of an abnormal complete blood count (CBC), hepatomegaly, splenomegaly, lymphadenopathy, or serum baseline tryptase of greater than 20 ng/mL should be offered a bone marrow examination. Both serum tryptase levels and markers of bone turnover, including C-telopeptide and osteoprotegerin, are associated with extent of disease.

In asymptomatic adults whose only sign or symptom of mastocytosis is skin lesions, and who choose not to have a bone marrow examination, serum tryptase and CBC should be repeated at least yearly during a complete history and physical examination. Elevation of the tryptase level, a drop in the platelet count or hemoglobin, a rise in the monocytes, or the onset of organomegaly should trigger a bone marrow examination. In children with early-onset disease, the prognosis is good; usually, tryptase evaluation or mutational analysis is reserved for those with the findings just listed, or with persistent localized bone pain, severe GI symptoms, or biochemical evidence of hepatic insufficiency.

## Differential diagnosis

Clinically, a small solitary mastocytoma most frequently resembles a pigmented nevus or juvenile xanthogranuloma. Urtication establishes the diagnosis. The disseminated lesions are also distinctive enough to cause little or no difficulty in the diagnosis. The nodular form may resemble xanthomas; however, the presence of urtication is distinctive. The vesicular and bullous lesions are to be distinguished from various

hereditary and nonhereditary bullous diseases. The main histologic similarity is to Langerhans cell histiocytosis.

## Prognosis

Most cases of early-onset, skin-limited disease in children clear completely. The solitary mastocytoma involutes spontaneously, usually within 3 years of onset. In children and adults with indolent systemic mastocytosis, the prognosis is also good. This is the most common category of patients presenting for diagnosis in the dermatology clinic. Patients with AHNMD have the prognosis of the associated disease. In the newly described patients with smoldering systemic mastocytosis, the prognosis is intermediate and not yet well defined. Patients with aggressive systemic mastocytosis, mast cell leukemia, or mast cell sarcoma have a poor prognosis.

## Treatment

Symptomatic relief of histamine-mediated symptoms may be achieved in many cases by the use of antihistamines. Both H1 and H2 blockers and antiserotonin drugs, such as cyproheptadine, may alleviate urtication, pruritus, and flushing. Nifedipine, 10 mg three times daily, may also be effective in isolated cases. Psoralen with ultraviolet A (PUVA) or medium-dose UVA1 therapy alone produces excellent clearing of the skin in most cases. Most patients will have sustained benefit for at least 6 months after treatment. Approximately 25% will have a remission lasting longer than 5 years, and in others the frequency of phototherapy may be tapered to once or twice a month, and patients still remain clear. Intralesional triamcinolone or potent topical corticosteroids under occlusion may also clear cutaneous lesions; however, the lesions do recur after discontinuance. Also, concern about local atrophy, striae, and systemic absorption limits the utility of this treatment.

The importance of avoiding physical stimuli such as extremes of temperature, pressure/friction, and chemical degranulators of mast cells cannot be overemphasized. The application of a hydrocolloid dressing over an isolated mastocytoma in an infant may reduce the flushing it produces. The chemicals that patients with mastocytosis must avoid include opiates, aspirin, alcohol, quinine, scopolamine, gallamine, decamethonium, reserpine, amphotericin B, polymyxin B, and D-tubocurarine. *Hymenoptera* stings may induce anaphylaxis; the patient (and parents of an affected child) should be taught to recognize the signs of anaphylactic shock, given a premeasured dose of epinephrine (EpiPen) for emergency use, and educated on its use. After such an event, it is prudent to treat for several days with 20–40 mg of prednisone to avoid recurrent attacks.

Control of diarrhea in systemic mastocytosis may be achieved by orally administered disodium cromoglycate. GI ulcers may be treated with proton pump inhibitors and H2 antagonists. The treatment of systemic mast cell disease is of limited efficacy. For patients with indolent systemic mastocytosis and severe osteoporosis, IFN alfa may be considered. In patients with smoldering systemic mastocytosis, watchful waiting is recommended, although IFN alfa, with or without glucocorticoids, may be considered for progressive “B” findings. In aggressive systemic mastocytosis, IFN alfa may also be used, with or without glucocorticoids. 2-Chlorodeoxyadenosine (as used in Langerhans cell histiocytosis) can also be effective in aggressive systemic mastocytosis. A gain-of-function D816V point mutation in the transmembrane receptor KIT kinase domain is found in the majority of patients with systemic mastocytosis. Patients with the mutation do not generally respond to imatinib mesylate. Patients with systemic mastocytosis who



have the *FIP1L1-PDGFR* translocation, who lack the *c-KIT* mutation, or who have novel mutations may respond to imatinib, and it may even prove helpful in patients with associated leukemia. CD1a-positive familial cutaneous mastocytosis without germline or somatic mutations in *c-kit* has been described. Cladribine (an adenosine deaminase inhibitor) has been used successfully for cytoreductive therapy in the setting of systemic mastocytosis. Bone marrow transplantation for the most severely affected patients with systemic mastocytosis is being investigated.

**Bennett M, et al:** Response of urticaria pigmentosa to cladribine in a patient with systemic mastocytosis. *Br J Haematol* 2013; 160(4):420.

**Cardet JC, et al:** Mastocytosis: update on pharmacotherapy and future directions. *Expert Opin Pharmacother* 2013; 14(15):2033–2045.

**D'Arena G, et al:** Darier sign and cutaneous involvement in mastocytosis. *Br J Haematol* 2014; 167(4):440.

**Fuller SJ:** New insights into the pathogenesis, diagnosis, and management of mastocytosis. *Hematol Oncol Clin North Am* 2012; 26(6):1143–1168.

**Ishida M, et al:** Cutaneous mastocytosis with abundant eosinophilic infiltration: a case report with review of the literature. *Int J Clin Exp Pathol* 2014; 7(5):2695–7.

**Neri I, et al:** Diffuse cutaneous mastocytosis: a heterogeneous disease. *Arch Dis Child* 2013; 98(8):607.

**Torrel A, et al:** Childhood mastocytosis. *Curr Opin Pediatr* 2012; 24(4):480–486.

**Valent P, et al:** Proposed diagnostic algorithm for patients with suspected mastocytosis: a proposal of the European Competence Network on Mastocytosis. *Allergy* 2014; 69(10):1267–1274.

**Vannorsdall EJ, et al:** Symptomatic response to imatinib mesylate in cutaneous mastocytosis associated with chronic myelomonocytic leukemia. *Curr Oncol* 2013; 20(4):e349–e353.

## ABNORMALITIES OF NEURAL TISSUE

### Solitary neurofibroma

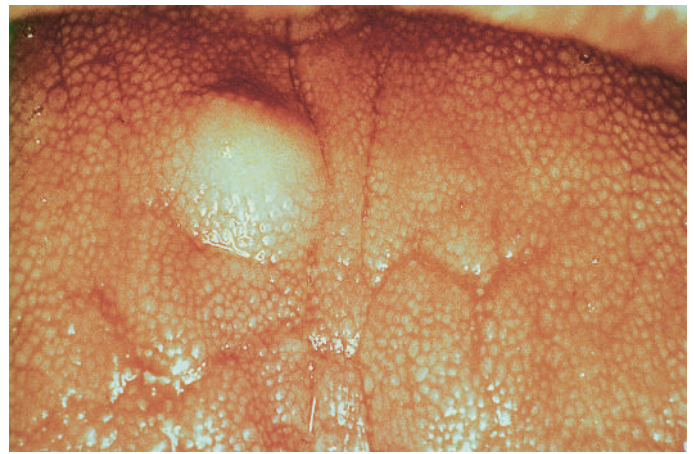
The typical solitary cutaneous neurofibroma is usually 3–6 mm in diameter. It is soft, flaccid, translucent, and pinkish white. Frequently, the soft small tumor can be invaginated, as if through a ring in the skin, by pressure with the finger (this is called “buttonholing”).

When only one or two lesions are present, they are typically spontaneous tumors without internal manifestations. When three or more are present, a diagnosis of neurofibromatosis should be considered. Infrequently, large pendulous masses occur, in which numerous, tortuous, thickened nerves can be felt; this has been likened to a “bag of worms.” These plexiform neurofibromas, which often have overlying pigmentation, usually occur in neurofibromatosis (see Chapter 27).

Histologically, the lesion demonstrates wavy spindled nuclei and fine collagen fibers. The stroma is often myxoid and contains many mast cells. Cholinesterase activity is markedly positive in the neurofibromas; the Schwann cells are S-100 positive; neurofilament protein staining demonstrates scattered axons; and CD34 demonstrates a characteristic fingerprint pattern. Shave removal is usually adequate therapy for symptomatic lesions.

### Granular cell tumor

About one third of reported granular cell tumors occur on the tongue (Fig. 28-38), one third involve the skin, and one third occur in the internal organs. The tumor is usually a well-circumscribed, solitary, firm nodule ranging from 5 to 30 mm, with a brownish red or flesh tint, depending on nearness to the surface. Its surface is often rough or verrucous, corresponding to pseudoepitheliomatous hyperplasia overlying the



**Fig. 28-38** Granular cell tumor of the tongue.

tumor. Rarely, the lesions may ulcerate. They are multiple in 10–15% of cases.

The solitary lesion may be located anywhere on the body, but almost half of all tumors appear on the head or neck. Usually, patients are in their third to fifth decade. About two thirds of patients are black, and two thirds are women. In most cases, the tumor grows very slowly, and when completely removed, does not usually recur. However, local or multicentric recurrence may at times cause confusion in determining if a granular cell tumor is malignant.

The histologic picture is distinctive. The cells are large, pale, and irregularly polygonal, with a poorly defined cellular membrane, and contain coarsely granular cytoplasm with scattered giant lysosomal granules. Some of the cells are multinucleated or contain vacuoles or small pyknotic or eosinophilic inclusions. At times, the arrangement is in cords or sheets, in irregular alveolar masses, or even organoid. Pseudoepitheliomatous hyperplasia is a regular feature. The cells stain positively with vimentin, neuron-specific enolase, S-100, myelin protein, p75 nerve growth factor, calretinin, NKI/C3, and PGP9.5. Hybrid forms that overlap with perineurioma have been described.

Malignant granular cell tumor is uncommon. Most are much larger than the benign granular cell tumors, with an average diameter of 9 cm; benign lesions average less than 2 cm. Most malignant granular cell tumors demonstrate cytologic atypia, but some are quite bland cytologically. Other factors that correlate with malignant behavior are an infiltrative growth pattern, history of local recurrence, older patient age, presence of necrosis, increased mitotic activity, spindling of tumor cells, and nuclear staining with the proliferation marker Ki67 (MIB 1) in more than 10% of tumor nuclei. Mutant p53 protein has been identified in more than half of malignant granular cell tumors studied. About one third are aneuploid, one third hyperdiploid, and one third diploid. In contrast, almost all benign tumors are diploid.

Because of the difficulties in distinguishing benign from some malignant granular cell tumors, complete excision is advisable whenever possible. Malignant granular cell tumors often have an infiltrative growth pattern and perineural extension. Mohs micrographic surgery may be helpful in ensuring complete excision.

**Arcot R, et al:** Peripheral and cranial nerve sheath tumors—a clinical spectrum. *Indian J Surg* 2012; 74(5):371–375.

**Paul SP, et al:** An unusual granular cell tumour of the buttock and a review of granular cell tumours. *Case Rep Dermatol Med* 2013; 2013:109308.

## Perineurioma

The normal perineurium is composed of flattened cells that surround the nerve. Perineuriomas are derived from these cells. Cutaneous lesions appear as nondescript papules clinically. Sclerosing perineuriomas demonstrate concentric lamellar fibrosis and are EMA positive. Reticular, granular, and lipomatous variants have been described.

**Hayashi T, et al:** Hybrid schwannoma/perineurioma of the spinal nerve: multifocal occurrence, and recurrence as an intraneural perineurioma. *Pathol Int* 2013; 63(7):368–373.

**Piña-Oviedo S, et al:** The normal and neoplastic perineurium: a review. *Adv Anat Pathol* 2008; 15(3):147–164.

## Neuroma cutis

Cutaneous neuromas include traumatic neuromas, multiple mucosal neuromas, and solitary palisaded encapsulated neuromas. Segmental neuromas have also been described.

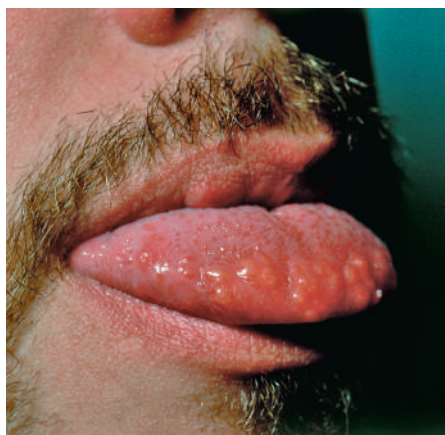
Traumatic neuromas result from the overgrowth of nerve fibers in the severed ends of peripheral nerves. The lesion may be tender or painful, and when scarring has occurred or the distal stump has been removed, a phantom limb syndrome may result. These often occur on the fingers, at sites of amputation of supernumerary digits, or on the sole, usually at the third metatarsal space.

Multiple mucosal neuromas occur as part of the autosomal dominant inherited, multiple mucosal neuroma syndrome (MEN-2b). These patients have a marfanoid habitus, thickened protruding lips, and multiple neuromas of the oral mucosa (lips, tongue, gingiva), conjunctiva, and sometimes sclera (Fig. 28-39). A few have multiple cutaneous neuromas, usually limited to the face. There is a strong association with medullary carcinoma of the thyroid, bilateral pheochromocytomas, and diffuse GI tract ganglioneuromatosis. Disease is caused by a mutation in the *RET* proto-oncogene. Infants at risk should be screened for this mutation and total thyroidectomy performed if positive.

The palisaded, encapsulated neuroma of the skin is a solitary, large, encapsulated tumor, usually of the face. It is a slow-growing, flesh-colored, dome-shaped, firm lesion, usually appearing around the mouth or nose. It closely resembles a basal cell carcinoma or an intradermal nevus.

**Brau-Javier CN, et al:** Acquired segmental neuromas. *PR Health Sci J* 2013; 32(2):101–103.

**Rodríguez-Peralto JL, et al:** Benign cutaneous neural tumors. *Semin Diagn Pathol* 2013; 30(1):45–57.



**Fig. 28-39** Multiple mucosal neuromas.

## Neurothekeoma (nerve sheath myxoma)

Neurothekeoma refers to a tumor of the nerve sheath and is composed of cords and nests of large cells packed among collagen bundles close to small nerves. Mitotic figures and nuclear atypia are sometimes seen, but the tumor is benign. These benign intradermal or subcutaneous tumors are divided histologically into two distinct subtypes: the classic or myxoid variant and the cellular type. An intermediate or mixed variety is also recognized. The myxoid variant (nerve sheath myxoma) is characterized by islands of stellate and spindled cells in a mucinous matrix. The cells stain strongly for S-100 protein. Myxoid neurothekeoma occurs in middle-age adults, primarily on the head, neck, and upper extremities. It is twice as common in women. The cellular type occurs in childhood, with a high female preponderance, and has a predilection for the head, neck, or shoulders. The cellular type does not stain for S-100 protein but does stain for S-100A6, PGP9.5, MiTF, and NK1C3. It is unclear if these tumors really demonstrate nerve sheath differentiation, but for now, they are grouped with the myxoid neurothekeomas. Examples of cellular neurothekeoma with high mitotic rate and atypia mimic malignant spindle cell tumors. They have a significant rate of recurrence but at this point are not known to have a clear metastatic potential.

**Cardoso J, et al:** Cellular neurothekeoma with perineural extension: a potential diagnostic pitfall. *J Cutan Pathol* 2012; 39(6):662–664.

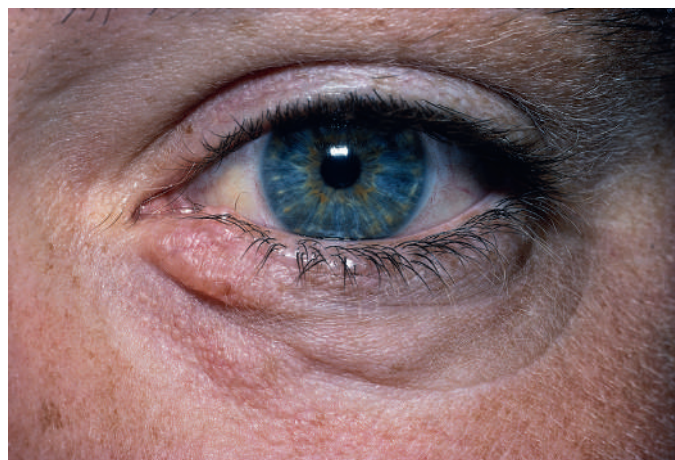
**El Kehdy J, et al:** Solitary nodule on the base of the nose in an adolescent girl: cellular neurothekeoma. *Pediatr Dermatol* 2012; 29(5):659–660.

**Fetsch JF, et al:** Neurothekeoma: an analysis of 178 tumors with detailed immunohistochemical data and long-term patient follow-up information. *Am J Surg Pathol* 2007; 31(7):1103–1114.

**Hornick JL, et al:** Cellular neurothekeoma: detailed characterization in a series of 133 cases. *Am J Surg Pathol* 2007; 31(3):329–340.

## Schwannoma (neurilemmoma)

Peripheral schwannomas are usually solitary nerve sheath tumors, most often seen in women. They occur almost exclusively in deep tissues, along the main nerve trunks of the extremities, especially the flexor surface of the arms, wrists, and knees. They are also seen on the scalp, sides of the neck, and tongue. The solitary tumor is a nodule of 3–30 mm in diameter (Fig. 28-40). It is soft or firm and pale pink or



**Fig. 28-40** Schwannoma. (Courtesy of Dr. Curt Samlaska.)



yellowish; it may or may not be painful. Schwannomas involve many other organs, and brain tumors such as meningiomas, gliomas, and astrocytomas may occur.

In some cases, the tumors are multiple, and these may be seen with neurofibromatosis type 1 (NF-1) or more often NF-2, or as an entity independent of neurofibromatosis. The independent type may be congenital or may have a delayed onset. It may be sporadic or familial. Three clinical patterns are described: elevated, dome-shaped nodules; pale-brown, indurated macules; and multiple papules coalescing into plaques 2–100 mm in diameter, with a predilection for the trunk. Cases have occurred that appeared to be unassociated with NF-2, but on further investigation of the individual or family, revealed other signs of NF-2 and the gene abnormality on chromosome 22.

Plexiform schwannomas may occur as single or multiple lesions, localized to a single anatomic site or more generalized, and arise in the dermis or subcutaneous tissue. They may occur as a solitary lesion or may be associated with NF-1, NF-2, or multiple schwannomas. Another subtype of schwannoma is the melanotic psammomatous type seen in association with Carney syndrome, featuring spotty pigmentation, myxomas, and endocrine overactivity. Plexiform melanocytic schwannoma may demonstrate mitotic figures and pleomorphic nuclei and must be differentiated from malignant melanoma. Important clues include the presence of focal Verocay bodies as well as an EMA-positive capsule derived from perineurium.

Histologically, the classic forms are well encapsulated with characteristic subcapsular edema and two types of tissue, referred to as Antoni types A and B. Hard schwannomas are firm on gross examination and are composed of Antoni A tissue—palisades of basophilic Schwann cell nuclei separated by brightly eosinophilic zones (Verocay bodies). Soft schwannomas are diffusely edematous. They are composed mostly of Antoni B tissue, a degenerative change characterized by loose, edematous connective tissue and ectatic blood vessels. S-100, vimentin, and myelin basic protein stains are positive in hard schwannomas. Staining is variable in soft schwannomas. A Bodian or neurofilament protein stain reveals very few or no nerve fibers within the bulk of the tumor, although a compressed nerve may be present at one edge of the mass in a subcapsular location. “Ancient schwannomas” may demonstrate remarkable nuclear atypia, which represents a benign degenerative change. Mitoses are absent. Ancient schwannomas should not be confused with malignant peripheral nerve sheath tumor (“malignant schwannoma”), a tumor that arises in long-standing neurofibromas in the setting of NF-1. Excision is almost invariably curative, except in the malignant variety, for which combined wide resection and radiotherapy is needed.

**Yeh I, et al:** Plexiform melanocytic schwannoma: a mimic of melanoma. *J Cutan Pathol* 2012; 39(5):521–525.

### Infantile neuroblastoma

Neuroblastoma is the most common malignant tumor of early childhood. Cutaneous nodules are most often seen in younger patients, being present in 32% of infants with the disease. These occur as multiple, 2–20 mm, firm, blue nodules that, when rubbed, blanch and form a halo of erythema. The blanching persists for 1–2 h and is followed by a refractory period of several hours. Biopsy shows clusters of basophilic cells with a high nuclear/cytoplasmic ratio, surrounded by eosinophilic, fine fibrillar material. Elongated nuclei are often noted focally. Two other findings that may be present are periorbital ecchymoses (the so-called raccoon eyes) and heterochromia of the irises.

For infants with skin involvement, the prognosis is generally good, with either spontaneous remission or spontaneous transformation into benign ganglioneuromas expected. Prognostic factors other than age, based on molecular genetic characteristics such as the status of the oncogene *MYCN* and chromosome 1p deletion, are helping to stratify prognosis and therapeutic recommendations.

**Monclair T, et al:** The International Neuroblastoma Risk Group (INRG) staging system: an INRG Task Force report. *J Clin Oncol* 2009; 27(2):298–303.

### Ganglioneuroma

Ganglioneuroma has only rarely been described in the skin as an isolated entity. These tumors are composed of mature ganglion cells comingled with fascicles of spindle cells. They arise most often in von Recklinghausen neurofibromatosis or with neuroblastomas and usually occur in childhood. The tissue stains positively for both argyrophilic and argentaffin granules.

**Furmanczyk PS, et al:** Cutaneous ganglioneuroma associated with overlying hyperkeratotic epidermal changes: a report of 2 cases. *Am J Dermatopathol* 2008; 30(6):600–603.

**Murphy M, et al:** Cutaneous ganglioneuroma. *Int J Dermatol* 2007; 46(8):861–863.

### Nasal glioma (cephalic brainlike heterotopias)

Nasal gliomas are rare, benign, congenital tumors. When they occur extranasally, they are easily confused with hemangiomas. The tumor is usually a firm, incompressible (unlike hemangioma and encephalocele), reddish blue to purple lesion occurring on the nasal bridge or midline near the root. It does not transilluminate or enlarge with crying, unlike some encephaloceles. It may also occur intranasally.

Nasal gliomas differ from encephaloceles in that the latter are connected to the subarachnoid space by a sinus tract, whereas the former usually lose this connection before birth. Clinically, these cannot be absolutely differentiated, so a biopsy should not be performed. Skull radiographs, MRI, ultrasound, and Doppler flow studies may be performed, to help define the lesion and detect possible skull involvement. Neurosurgical consultation is advisable.

Histologically, the nodule consists of glial tissue associated with glial giant cells, fibrous tissue, and numerous blood vessels. It is unencapsulated. The lesion does not involute spontaneously.

**Bellet JS:** Developmental anomalies of the skin. *Semin Perinatol* 2013; 37(1):20–25.

**Gnagi SH, Schraff SA:** Nasal obstruction in newborns. *Pediatr Clin North Am* 2013; 60(4):903–922.

### Cutaneous meningioma

Primary cutaneous meningioma represents a continuum with rudimentary meningocele. It results from the presence of meningocytes outside the calvarium. If actual brain remnants are present, the lesion is called a rudimentary cephalocele. Small, hard, fibrous, calcified nodules occur along the spine, in the scalp, on the forehead, or rarely in the external ear canal. Most occur over the scalp, and some have an underlying connection to the CNS or an underlying bony abnormality. They usually come to medical attention in the first year of life. On the scalp, they may present with a dark tuft of hair or an alopecic area surrounded by a dark collar of hair (hair collar sign).

Type I lesions present at birth and develop from ectopic arachnoid cells. Type II lesions usually present in adults and demonstrate arachnoid cells surrounding nerve bundles. Type III lesions are caused by direct extension or metastasis from dural neoplasms. Cutaneous meningiomas may develop in the scalp secondary to an intracranial meningioma, either through erosion of the skull or by extension through an operative defect of the skull. Lastly, they may also arise from cranial or spinal nerves. Clinically, these lesions have no distinctive appearance. They are firm subcutaneous nodules adherent to the skin.

Diagnosis is made by histologic examination. The tumors consist of vascularlike anastomosing spaces with spindle cells forming whorls around collagen bundles. Lamellar, calcified psammoma bodies are often present. Psammoma bodies are not specific for meningiomas and may also be found in intradermal nevi, juvenile xanthogranuloma, pituitary of the fetus and newborn, schwannomas associated with Carney syndrome, meninges, choroid plexus, pineal gland, papillary carcinoma of thyroid, ovarian neoplasms, and mammary intraductal papilloma. Meningiomas are usually EMA and p63 positive, creating the potential for confusion with epithelial lesions.

**Fox MD, et al:** Cutaneous meningioma: a potential diagnostic pitfall in p63 positive cutaneous neoplasms. *J Cutan Pathol* 2013; 40(10):891–895.

## Encephalocele and meningocele

Primary defects in the neural tube may lead to encephaloceles, meningoceles, or meningomyeloceles. They present in infancy along the midline of the face, scalp, neck, or back as soft, compressible masses that may transilluminate or enlarge with crying. Tufts of long, dark hair or alopecia with a surrounding collar of dark hair may overlie them.

Many cutaneous lesions of the midline of the back, most frequently at the base of the spine, suggest that malformations of the spinal cord and associated structures are present. Cutaneous manifestations of spinal dysraphism include depressed or polypoid lesions; dyschromic or hairy lesions; dermal or subcutaneous lesions; vascular malformations; or neoplasms of many types. Midline masses require intensive radiologic and neurosurgical evaluation before biopsy because of the possible connection to the CNS. MRI is the imaging modality of choice. Approximately 10% of patients will have evidence of occult spinal dysraphism if one abnormality is present, whereas the majority will have dysraphism if two or more abnormalities are present.

## Chordomas, parachordomas, and myoepitheliomas

Parachordomas are closely related to myoepitheliomas and mixed tumor of skin and salivary gland. They generally occur as an isolated neoplasm. Both benign and malignant parachordomas occur in skin and can be differentiated by the degree of cellularity, atypia, and number of mitoses. Chordomas are soft tissue neoplasms that present as firm, smooth nodules in the sacrococcygeal region or at the base of the skull in middle-age patients. They arise from notochord remnants. The pathologic appearance for each of these tumors is that of an incompletely encapsulated tumor with nests and cords of large epithelioid cells with multivacuolated physaliferous cells. Chordomas may metastasize late in their course to various sites, including the skin. Wide excision with postoperative radiation therapy is the treatment of choice.

**Ali S, et al:** Parachordoma/myoepithelioma. *Skeletal Radiol* 2013; 42(3):431, 457–458.

**Rekhi B, et al:** Histopathological, immunohistochemical and molecular spectrum of myoepithelial tumours of soft tissues. *Virchows Arch* 2012; 461(6):687–697.

## ABNORMALITIES OF FAT TISSUE

### Lipomas

Lipomas, subcutaneous tumors composed of fat tissue, may occur as a solitary sporadic lesion or as multiple lesions with or without a familial component. There are multiple histologic subtypes, and these frequently have an associated clinical correlation. Most have specific chromosomal alterations that help in their identification in difficult cases. Protease inhibitors given for HIV disease may induce lipomas, angiolipomas, or benign symmetric lipomatosis, as well as lipodystrophy.

Lipomas are most often found on the trunk. They also occur frequently on the neck, forearms, and axillae. They are soft, single or multiple, small or large, lobulated, compressible growths, over which the skin on traction often becomes dimpled, although otherwise unchanged. Lipomas usually stop growing after attaining a certain size, then remain stationary indefinitely. Frontalis-associated lipomas of the forehead are relatively large lesions arising either within or deep to the frontalis muscle.

A lipoma located in the midline of the sacral region may be a marker for spinal dysraphism or other embryologic malformation. Other midline lesions, such as tufts of hair (“fawn’s tail”), hemangiomas (Cobb syndrome), skin tags, sinuses, or pigmented lesions, should also raise suspicion for occult embryologic malformations. MRI is the most sensitive imaging modality. If spinal dysraphism is diagnosed, early treatment may be possible before irreversible damage has occurred. Do not attempt to biopsy a sacrococcygeal lipoma; call a neurosurgeon into consultation. It may be a lipomeningocele with communicating sinuses to the dura.

Histologically, the lipoma is an encapsulated, lobulated tumor containing normal fat cells held together by strands of connective tissue. Occasionally, eccrine sweat glands may be associated, and then they are called adenolipomas. Alterations in chromosomes 12q13–15 and chromosomes 13q12–22 may be detected in benign lipomas.

Lipomas may be left untreated, unless they are large enough to be objectionable. They may be excised, removed with liposuction, extruded through a 3-mm incision after being freed with a cutting curette, or segmentally extracted through a stab incision. More advanced surgical technique is necessary to remove the deep lesions on the forehead, which may lie below the fascial plane. Injection with phosphatidylcholine has also been reported as successful.

Multiple lipomas may occur in groups of two to hundreds of confluent painless tumors of various sizes over any part of the body (Fig. 28-41). These lesions are sometimes painful when growing rapidly. When present in certain patterns, special designations are applied. Madelung’s disease (benign symmetric lipomatosis or multiple symmetric lipomatosis) occurs most often in middle-age men, who may develop multiple, large, painless, coalescent lipomas around the neck, shoulders, and upper arms. Familial multiple lipomatosis is a dominantly inherited syndrome in which multiple asymptomatic lipomas of the forearms and thighs appear in the third decade of life. The shoulders and neck are spared, and the lipomas are encapsulated and movable. Diffuse lipomatosis is characterized by an early age of onset, usually before 2 years; diffuse infiltration of muscle by an unencapsulated mass of



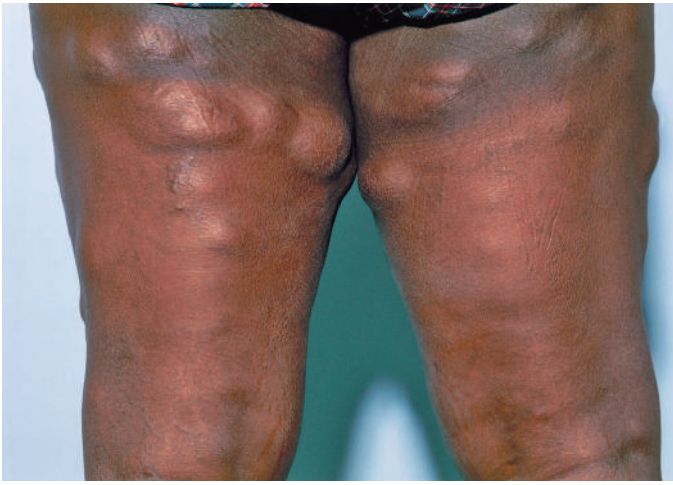

Fig. 28-41 Multiple lipomas.

histologically mature lipocytes; and progressive enlargement and extension of the tumor mass. It usually involves a large portion of the trunk or an extremity. Some cases are associated with distant lipomas or hemangiomas or with hypertrophy of underlying bone.

Dercum's disease (*adiposis dolorosa*) is seen most often in obese or corpulent menopausal women who develop symmetric, tender, circumscribed fatty lesions. These are often accompanied by weakness and psychiatric disturbances. Relief of pain lasting for weeks after intravenous infusions of lidocaine, 1.3 g/day for 4 days, has been reported.

Several other conditions are characterized by multiple abnormalities, including lipomas. Encephalocraniocutaneous lipomatosis is a rare neurocutaneous syndrome characterized by unilateral porencephalic cysts with cortical atrophy, ipsilateral facial and scalp lesions, ocular abnormalities, cranial asymmetry, and neurologic complications. The skin changes consist of unilateral lipomatous scalp tumors with overlying alopecia and connective tissue nevi. Ipsilateral lipodermoids, choristomas, and calcifications are the eye findings. CNS abnormalities include unilateral cerebral atrophy, dilated ventricles, porencephaly, cerebral calcifications, and lipomas of the leptomeninges. Seizures and mental retardation may occur. Some patients may have overlapping features of Proteus syndrome: multiple lipomas, epidermal nevi, cerebriform lesions of the plantar surfaces, vascular malformations, macrodactyly, hemihypertrophy, exostoses, and scoliosis.

Bannayan-Riley-Ruvalcaba syndrome is characterized by multiple subcutaneous lipomas and vascular malformations, lentiginosities of the penis and vulva, verrucae, and acanthosis nigricans. There is overlap in some of these cases with Cowden syndrome. Both syndromes have been associated with allelic mutations of the *PTEN* gene.

Multiple endocrine neoplasia type I has been associated with skin lesions consisting of multiple facial angiofibromas, collagenomas, café au lait spots, lipomas, confetti-like hypopigmented macules, and multiple gingival papules, in addition to the tumors of the parathyroid glands, endocrine pancreas, and anterior pituitary.

Fröhlich syndrome consists of multiple lipomas, obesity, and sexual infantilism.

Gardner syndrome consists of multiple osteomas, fibromas, desmoid tumors, lipomas, fibrosarcomas, epidermal inclusion cysts, and leiomyomas, associated with intestinal polyposis exclusively in the colon and rectum. The coexistence of cutaneous cysts, leiomyomas, and osteomas (mostly on the skull) with intestinal polyposis is frequently not recognized

until malignant degeneration of one of the polyps occurs and surgical removal brings the syndrome to notice. Half of such patients develop carcinoma of the colon before age 30, and almost all these patients die before age 50, unless they have surgical treatment. In general, total colectomy is advised. Bony exostoses occur in 50% of patients and usually involve the membranous bones of the face and head. Cysts occur in 63% of patients and again, most frequently involve the face and scalp. These are epidermal inclusion cysts; two thirds have within them foci of pilomatrical differentiation. Pigmented lesions of the ocular fundus occurred in 90% of 41 patients with Gardner syndrome and 46% of 43 first-degree relatives. They are usually multiple and bilateral and, having been seen in a 3-month-old infant, are probably congenital. Gardner syndrome is transmitted as an autosomal dominant disease. The defect is a mutation in the *APC* gene located at chromosome 5q21. In some families, polyposis and carcinoma may occur without the skin and bone tumors. Lipomas have also been noted in the Carney complex, along with myxomas and pigmented lesions.

## Subtypes

Angiolipomas present as painful subcutaneous nodules, having all the other features of a typical lipoma. Multiple subcutaneous angiolipomas are common and have no invasive or metastatic potential. They may be associated with capillary malformations and may be induced by protease inhibitor therapy of HIV disease.

The angiolipoleiomyoma (angiomyolipoma of the skin) affects the acral skin of middle-age men. No signs of tuberous sclerosis or renal angiomyolipoma are present. Mature adipocytes, thick-walled blood vessels, and smooth muscle cells in fascicles around blood vessels are present.

Neural fibrolipoma is an overgrowth of fibrofatty tissue along a nerve trunk that often leads to nerve compression. Patients are usually age 30 or younger and note a slowly enlarging subcutaneous mass with associated tenderness, decreased sensation, or paresthesia. The median nerve is most often involved. At times, macrodactyly appears, with elongation and splaying of the phalanges. MRI will provide the diagnosis, but unfortunately, there is no effective treatment.

Chondroid lipomas are deep-seated, firm, yellow tumors that characteristically occur on the legs of women. Histologically, there is a thin capsule around mature lipocytes that have a single large vacuole and multivacuolated, S-100/vimentin-positive cells within a chondromyxoid matrix.

The spindle cell lipoma is an asymptomatic, slow-growing subcutaneous tumor that has a predilection for the posterior back, neck, and shoulders of older patients. It is usually solitary, although multiple lesions may occur. Some patients have a familial background of similar lesions. The neoplasm consists of lobulated masses of mature adipose tissue with areas of spindle cell proliferation. The spindle cells stain positive for CD34. Abnormalities of chromosomes 16 and 13 have been reported. The spindled component of young spindle cell lipomas may be myxoid or cellular. The nuclei may be wavy and accompanied by mast cells, as in a neurofibroma. Examples with minimal fat may be misdiagnosed as solitary fibrous tumors. In old spindle cell lipomas (fibrolipomas), the spindle cell component has matured into dense collagen bundles.

Pleomorphic lipomas, as with spindle cell lipomas, occur mostly on the back or neck of older individuals. There are floret giant cells with overlapping nuclei. Occasional lipoblast-like cells and atypical nuclei may be present and require differentiation from a liposarcoma. There is loss of chromosome 16q material. Despite this alarming appearance, the lesions behave in a perfectly benign manner. Pleomorphic lipomas

lack the size, depth, infiltrative growth, and arborizing vascular pattern of liposarcoma. The term “atypical lipomatous tumor” is used to describe well-differentiated, low-grade liposarcoma. Extensive or deeply infiltrating tumors should be reviewed by a clinician experienced in soft tissue pathology.

The intradermal spindle cell/pleomorphic lipoma is distinct in that it most often affects women and has a wide distribution, occurring with relatively equal frequency on the head and neck, trunk, and the upper and lower extremities. Histologically, these lesions are unencapsulated and have infiltrative margins. Again, the spindle cells stain positive for CD34.

Hibernoma (lipoma of brown fat) is a form of lipoma composed of finely vacuolated fat cells of embryonic type. Hibernomas have a distinctive brownish color and a firm consistency and usually occur singly. These tumors are benign. They occur chiefly in the mediastinum and the interscapular region of the back, but they also occur on the scalp, sternal region, and legs. They are usually about 3–12 cm in breadth, and the onset is most often in adult life. Abnormalities of chromosomes 10 and 11 have been reported in the lesions. Epidural lipomatosis, collections of fat in the epidural space, may cause acute chord compression in the course of systemic corticosteroid treatment. A case of this distinctive, uncommon side effect proved to be the result of deposits of brown fat.

**Dalal KM, et al:** Diagnosis and management of lipomatous tumors. *J Surg Oncol* 2008; 97(4):298–313.

**Karoui S, et al:** Adenolipoma of the skin. *Pathologica* 2011; 103(6):343–345.

### Nevus lipomatosus superficialis

Soft, yellowish papules or cerebriform plaques, usually of the buttock or thigh, less often of the ear or scalp, with a wrinkled rather than warty surface, characterize nevus lipomatosus superficialis. The distribution may be either zonal (as in the multiple lesions reported by Hoffmann and Zurhelle) or solitary. Solitary lesions appear as plaque, or linear array, but some resemble broad, fatty acrochordons. Onset before age 20 is the rule. Most do not require treatment, but diagnostic biopsy is sometimes performed, and intralesional phosphatidylcholine has been reported as successful.

**Sendhil Kumaran M, et al:** Nevus lipomatosus superficialis unseen or unrecognized: a report of eight cases. *J Cutan Med Surg* 2013; 17(5):335–339.

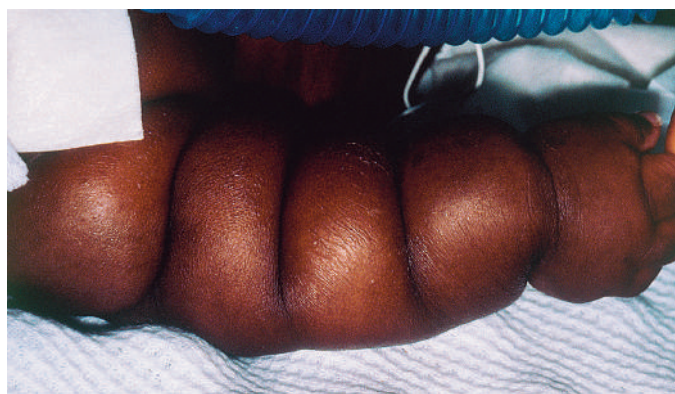### Folded skin with scarring (“Michelin tire baby” syndrome)

In this rare syndrome, the infant has numerous deep, conspicuous, symmetric, ringed creases around the extremities, resembling stacked tires (Fig. 28-42). The underlying skin may manifest a smooth muscle hamartoma, a nevus lipomatosus, or elastic tissue abnormalities. It may occur as an autosomal dominant or recessive trait, as a sporadic condition, as an isolated finding or in association with congenital facial and limb abnormalities, or with severe neurologic defects.

**Ulucan H, et al:** Circumferential skin folds and multiple anomalies: confirmation of a distinct autosomal recessive Michelin tire baby syndrome. *Clin Dysmorphol* 2013; 22(2):87–90.

### Benign lipoblastoma

Frequently confused with a liposarcoma, benign lipoblastoma affects infants and young children exclusively, with approximately 90% of cases occurring before 3 years of age. It most



**Fig. 28-42** “Michelin tire baby.”

often involves the soft tissues of the upper and lower extremities. A circumscribed and a diffuse form can be distinguished. The circumscribed form is superficially located and clinically comparable to a lipoma. The diffuse form is more deeply situated and is analogous to diffuse lipomatosis. Microscopically, both forms consist of lobulated immature adipose tissue composed of lipoblasts, a plexiform capillary pattern, and a richly myxoid stroma. Cytogenetic studies for rearrangements of chromosome 8q11–q13 or fluorescence in situ hybridization (FISH) analysis for the *PLAG1-HAS2* fusion gene help to distinguish this tumor from liposarcoma, a distinction that can be difficult histologically. Complete local excision is the treatment of choice; however, recurrences may occur in as many as one quarter of patients.

**Choi HJ, et al:** Pediatric lipoblastoma of the neck. *J Craniofac Surg* 2013; 24(3):e507–e510.

**Deen M, et al:** A novel *PLAG1-RAD51L1* gene fusion resulting from a t(8;14)(q12;q24) in a case of lipoblastoma. *Cancer Genet* 2013; 206(6):233–237.

### Liposarcoma

Liposarcomas are the most common soft tissue sarcoma. They usually arise from the intermuscular fascia, and only rarely from the subcutaneous fat. They do not arise from preexisting lipomas. The usual course is an inconspicuous swelling of the soft tissue that undergoes an imperceptibly gradual enlargement. When a fatty tumor becomes larger than 10 cm in diameter, liposarcoma should be seriously considered. The upper thigh is the most common site. Other frequent sites are the buttocks, groin, and upper extremities. Adult males are mainly affected.

Liposarcomas may be well differentiated; subtypes include the adipocytic, sclerosing, inflammatory, spindle cell, and dedifferentiated variants. In this category, there are aberrations of chromosome 12. Myxoid and round cell-variant liposarcoma often shows poorly differentiated histology. In most cases, there is a reciprocal translocation t(12; 16)(q13; q11). The third major class is pleomorphic liposarcoma. Dermal lesions may resemble pleomorphic lipoma but are S100 positive and contain lipoblasts.

Treatment is adequate radical excision of the lesion. In patients with well-differentiated superficial lesions, the prognosis is good; for deeper, high-grade lesions, the extension between fascial planes and presence of small satellite nodules require carefully planned surgery, which may be assisted by MRI guidance. For metastatic liposarcomas, radiation therapy may be effective.

**Al-Zaid T, et al:** Dermal pleomorphic liposarcoma resembling pleomorphic fibroma: report of a case and review of the literature. *J Cutan Pathol* 2013; 40(8):734–739.



## ABNORMALITIES OF SMOOTH MUSCLE

### Leiomyoma

Cutaneous leiomyomas are smooth muscle tumors characterized by painful nodules that occur singly or multiply. They may be separated conveniently into solitary and multiple cutaneous leiomyomas arising from arrectores pilorum muscles (piloleiomyomas); solitary genital leiomyomas arising from the dartoic, vulvar, or mammillary muscle; and solitary angioliomyomas arising from the muscles of veins.

#### Solitary cutaneous leiomyoma

The typical lesion is a deeply circumscribed, rounded nodule 2–15 mm in diameter. It is freely movable. The overlying skin may have a reddish or violaceous tint. Although the lesion is insensitive at first, painful paroxysms may occur. Once pain commences, it tends to intensify.

#### Multiple cutaneous leiomyomas

These brownish, grouped, papular lesions vary from 2 to 23 mm in diameter and are the most common variety of leiomyoma (Fig. 28-43). Two or more sites of the skin surface may be involved. The firm, smooth, superficial, sometimes translucent, and freely movable nodules are located most frequently on the trunk and extremities. They often form linear or dermatomal patterns, either alone or with scattered isolated non-segmental lesions elsewhere. These leiomyomas may occur on the tongue or, less often, elsewhere in the mouth as well. The usual age at onset is the teens to the fourth decade. Eruptive lesions have been described in chronic lymphocytic leukemia.

Multiple leiomyomas are inherited in an autosomal dominant manner as part of Reed syndrome. Women with this inherited type often have uterine leiomyomas as well. This is part of an inherited syndrome in which some patients also have a predisposition to type II papillary renal carcinomas or renal collecting duct cancer. Mutations in the fumarate hydratase gene are present in 75% of patients with Reed syndrome; these mutations may also be inherited in an autosomal recessive manner. Fully affected children have severe neurologic impairment. The adult carriers may develop leiomyomas. Sporadic leiomyoma, leiomyosarcomas, renal cancers, and uterine

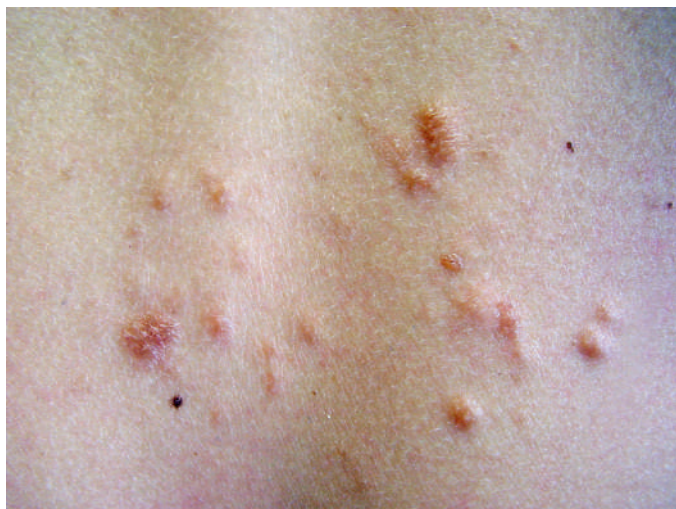

Fig. 28-43 Multiple leiomyomas.

leiomyomas have a very low frequency of fumarate hydratase gene mutations.

### Genital leiomyomas

These lesions are located on the scrotum, on the labia majora, or rarely on the nipples. They may be intracutaneous or subcutaneous in location. Most genital leiomyomas are painless and solitary. Alport syndrome is an X-linked dominant syndrome consisting of hematuric nephropathy, deafness, and maculopathy caused by mutations in type IV collagen. Some of these patients will have diffuse leiomyomatosis, which may affect the esophagus, tracheobronchial tree, perirectal area, and genital tract and vulva. Bilateral nipple leiomyomas have been associated with *BRAF* inhibition therapy.

### Angioliomyoma (vascular leiomyoma)

Angioliomyoma arises from the muscle of veins. Pain, either spontaneous or provoked by pressure or cold, occurs in about half the cases. Vascular leiomyoma is found mostly on the lower leg in middle-age women. Solid tumors occur three times more frequently in women, and cavernous tumors occur four times more often in men. Solid lesions on the extremities are usually painful; tumors of the head are rarely painful. In AIDS patients, multiple skin and visceral angioliomyomas may occur. These tumors cells possess the Epstein-Barr virus genome.

Histologically, the leiomyoma is made up of bundles and masses of smooth muscle fibers. Varying amounts of collagen are intermingled. The smooth muscle cells are finely fibrillated and contain a glycogen vacuole adjacent to the nucleus. The nuclei are typically long, thin, and cigar shaped.

### Angiolipoleiomyoma

Fitzpatrick et al. reported eight patients with acquired, solitary, asymptomatic acral nodules. Seven were men, and all were adults. Histologically, they had well-circumscribed subcutaneous tumors composed of smooth muscle cells, blood vessels, connective tissue, and fat.

### Treatment

Leiomyomas are benign. Solitary painful lesions may be excised. When they are multiple and familial, monitoring for renal cell or collecting duct carcinoma is important. When multiple lesions are present and painful, as may occur especially in the winter, relief of pain may be achieved by giving doxazosin, an oral  $\alpha$ 1-adrenoceptor antagonist. This is better tolerated than phenoxybenzamine, an  $\alpha$ -adrenergic blocker, which also has been reported to provide pain relief. Nifedipine (10 mg three times daily), amlodipine, gabapentin, oral nitroglycerin, and  $\alpha$ -blockers have also had variable success. An ice cube applied over the lesions often induces pain, and the effectiveness of therapy may be assessed by the length of time it takes for the ice cube to cause pain. Botulinum toxin type A (Botox) injection has also been reported as effective.

**Aggarwal S, et al:** Disseminated cutaneous leiomyomatosis treated with oral amlodipine. *Indian J Dermatol Venereol Leprol* 2013; 79(1):136.

**Kontochristopoulos G, et al:** A case of Reed's syndrome: an underdiagnosed tumor disorder. *Case Rep Dermatol* 2014; 6(2):189–193.

**Stewart L, et al:** Association of germline mutations in the fumarate hydratase gene and uterine fibroids in women with hereditary leiomyomatosis and renal cell cancer. *Arch Dermatol* 2008; 144(12):1584–1592.

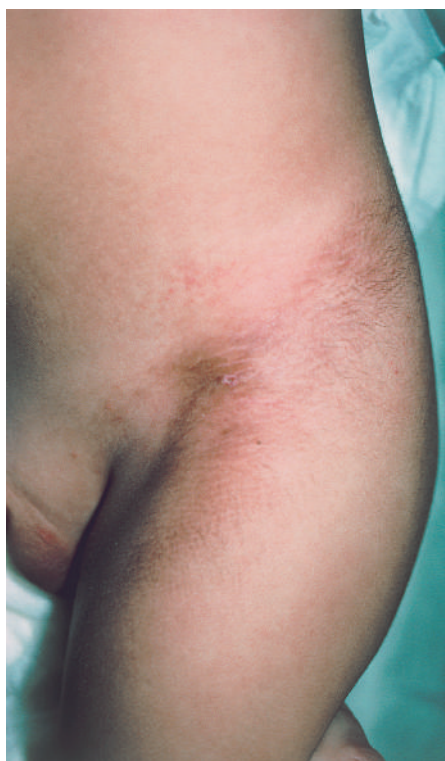
## Congenital smooth muscle hamartoma

Congenital smooth muscle hamartoma is typically a skin-colored or lightly pigmented patch or plaque with hypertrichosis (Fig. 28-44). It is often present at birth, usually on the trunk, with the lumbosacral area involved in two thirds of patients. Older patients may have perifollicular papules. They vary in size from 2 × 3 to 10 × 10 cm. The “Michelin tire baby” syndrome may result from a diffuse smooth muscle hamartoma. One patient presented with a linear reddish purple plaque. The incidence is approximately 1 in 2600 newborns. Transient elevation on rubbing may be seen (pseudo-Darier’s sign) in 80% of patients. An association with multiple adult myofibromas has been reported, as has association with congenital melanocytic nevus.

Histologically, numerous thick, long, well-defined bundles of smooth muscle are seen in the dermis at various angles of orientation. There may be an increase in hair follicles, and some cases have been associated with congenital or blue nevi.

In some patients, there is clinical and histologic overlap with Becker nevus. Classically, Becker nevus is a unilateral (rarely bilateral) acquired hyperpigmentation, usually beginning as a tan macule on the shoulder or pectoral area of a teenage male. Over time, hypertrichosis develops within it. Biopsy of such lesions shows acanthosis, papillomatosis, and increased basal cell pigmentation. Occasional congenital lesions manifesting hyperpigmentation and hypertrichosis have shown biopsy findings consistent with those of a Becker nevus (no smooth muscle proliferation), and lesions with a typical late-onset history compatible with Becker nevus have occasionally shown smooth muscle hamartoma-like changes in the dermis. Other cases of late-onset smooth muscle hamartomas are occasionally reported that are not hyperpigmented or hypertrichotic. No treatment is necessary.

**Tzu J, et al:** Combined blue nevus–smooth muscle hamartoma: a series of 12 cases. *J Cutan Pathol* 2013; 40(10):879–883.



**Fig. 28-44** Smooth muscle hamartomas.

## Leiomyosarcoma

Superficial leiomyosarcomas, originating in the dermis or subcutaneous tissue, account for approximately 2% of all soft tissue sarcomas. Occasionally, a lesion may present in the skin that is a metastasis from an internal source. The cutaneous leiomyosarcoma appears in the dermis as a solitary nodule. It may originate from the arrector pili or genital dartos muscle. This has a good prognosis. Recurrence rates with Mohs surgery are approximately 15%, with metastases a rare event. Subcutaneous leiomyosarcomas, on the contrary, have a guarded prognosis, since hematogenous metastases occur in approximately 35% of patients. These prove fatal in about one third of patients. Lung metastases are common, so chest imaging is an important part of monitoring these patients.

The clinical appearance of leiomyosarcomas is not distinctive, and thus the diagnosis is established by the histopathologic findings. These differ from the leiomyoma by dense cellularity, nuclear pleomorphism, numerous mitotic figures, and disarray of the smooth muscle bundles. Collagen is found only in the septa. Desmin, smooth muscle actin, and h-caldesmon are helpful in differentiating leiomyosarcoma from other spindle cell or pleomorphic tumors.

The preferred method of treatment is wide local excision with a 1-cm margin. The Mohs surgical approach is useful in limiting recurrences and sparing tissue. Radiation therapy and chemotherapy are generally not effective.

**Deneve JL, et al:** Cutaneous leiomyosarcoma: treatment and outcomes with a standardized margin of resection. *Cancer Control* 2013; 20(4):307–312.

## MISCELLANEOUS TUMORS AND TUMOR-ASSOCIATED CONDITIONS

### Cutaneous endometriosis

Endometriosis of the skin is characterized by the appearance of brownish papules at the umbilicus or in lower abdominal scars after gynecologic surgery in middle-age women. The usually solitary tumor ranges from a few to 60 mm (average 5 mm) in diameter. The tender or painful lesion is bluish black from the bleeding that occurs cyclically in many patients. Histopathologic findings are glandular structures with a columnar epithelium and a surrounding fibromyxoid stroma typically containing extravasated red blood cells and hemosiderin. Decidualized endometriosis demonstrates glassy-pink epithelioid cells surrounding contracted lumina. Treatment of choice is surgical excision. Preoperative treatment with danazol or leuprolide may reduce its size.

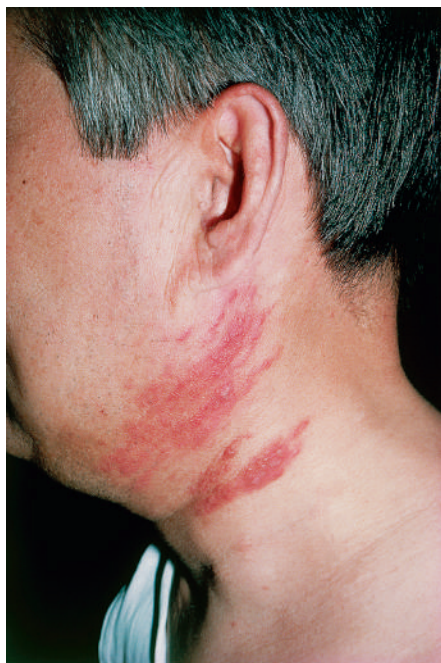**DeClerck BK, et al:** Cutaneous decidualized endometriosis in a nonpregnant female: a potential pseudomalignancy. *Am J Dermatopathol* 2012; 34(5):541–543.

### Teratoma

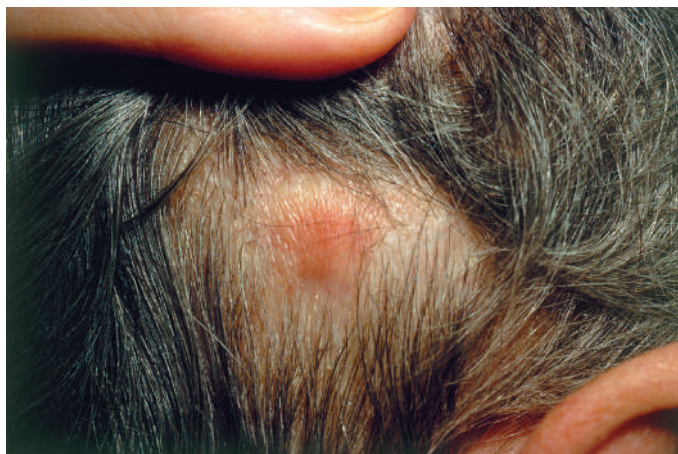Teratomas may develop in the skin but are most common in the ovaries or testes. Occurrence with a myelomeningocele has been reported. They have no characteristic clinical features, but on microscopic examination, many types of tissue, representative of all three germ layers, are present. Hair, teeth, and functioning thyroid tissue are examples of fully differentiated tissues that may develop. Occasionally, malignancy may occur.

**Bellet JS:** Developmental anomalies of the skin. *Semin Perinatol* 2013; 37(1):20–25.





**Fig. 28-45** Metastatic rectal cancer presenting as inflammatory carcinoma.



**Fig. 28-46** Alopecia neoplastica secondary to breast carcinoma.

### Metastatic carcinoma

Malignant tumors are able to grow at sites distant from the primary site of origin; thus, dissemination to the skin may occur with any malignant neoplasm. These infiltrates may result from direct invasion of the skin from underlying tumors, may extend by lymphatic or hematogenous spread, or may be introduced by therapeutic procedures.

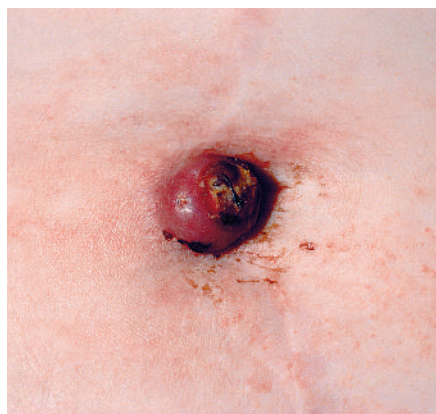From 5% to 10% of patients with cancer develop skin metastases. The reported incidence figures vary widely according to the type of study undertaken and the site of primary tumor studied. The frequency of involvement of the skin is low when other sites are considered, such as the lung, liver, lymph nodes, and brain.

Usually, metastases occur as numerous firm, hard, or rubbery masses, with a predilection for the chest, abdomen, or scalp, in an adult over age 40 who has had a previously diagnosed carcinoma. However, many variations exist in morphology, number of lesions, site of growth, age at onset, and timing of metastases. They are most often intradermal papules, nodules, or tumors that are firm, skin colored to reddish, purplish, black, or brown; may be fixed to underlying tissues; and rarely ulcerate.

Several unusual morphologic patterns occur. Carcinoma en cuirasse is a diffuse infiltration of the skin that imparts an indurated and hidebound leathery quality to skin. This sclerodermoid change, also referred to as scirrhus carcinoma, is produced by fibrosis and single rows of tumor cells. This type primarily occurs with breast carcinoma. Carcinoma telangiectaticum is another unusual type of cutaneous metastasis from breast carcinoma that presents as small, pink to purplish papules, pseudovesicles, and telangiectases.

Inflammatory carcinoma (carcinoma erysipelatoides) is characterized by erythema, edema, warmth, and a well-defined leading edge, similar to erysipelas in appearance (Fig. 28-45). This is usually caused by breast carcinoma but has been reported with many other primary tumors. Histologically, there is minimal to no inflammation, but rather neoplastic cells within dilated superficial dermal vessels.

Alopecia neoplastica may present as a cicatricial localized area of hair loss (Fig. 28-46). On biopsy, it is usually seen to be caused by breast metastases in women and by lung or kidney



**Fig. 28-47** Sister Mary Joseph nodule.

carcinoma in men. Metastatic breast cancer may be darkly pigmented, as may Paget's disease of the breast.

The so-called Sister Mary Joseph nodule is formed by localization of metastatic tumors to the umbilicus (Fig. 28-47). The most common primary sites are the stomach, large bowel, ovary, and pancreas. Zosteriform, linear, or chancroidal ulcerations of the genitalia and verrucous nodules of the legs are other, rarely reported clinical presentations.

The primary tumor is usually diagnosed before the appearance of metastases, and dissemination to the skin is often a late finding. Metastases to other, more frequently involved organs, such as the lung and liver, have usually occurred. A poor prognosis is thus the rule. Skin infiltrates may, however, be the first harbinger of a malignant visceral neoplasm and are often the first clinically apparent metastatic site.

The principal anatomic sites to which metastases localize are the chest, abdomen, and scalp, with the back and extremities being relatively uncommon areas. Involvement of the skin is likely to be near the area of the primary tumor. Thus, chest lesions are usually caused by breast carcinoma in women and lung carcinoma in men, abdominal or perineal lesions by colonic carcinoma, and the face by squamous cell carcinoma of the oral cavity. Extremity lesions, when they occur, are most often caused by melanoma.

Because of its overall high prevalence, breast cancer is the type most frequently metastatic to the skin in women, and melanoma, followed by lung cancer, is the type seen most often in men. Colon carcinoma is also common because of its high incidence in both genders. Renal cell carcinoma, although less common, has a predilection for scalp metastases. Metastatic lesions are uncommon in children, but when they do

occur, neuroblastoma and leukemia are the most frequent causes.

Lymphangiosarcoma (Stewart-Treves syndrome) develops in a site of chronic lymphedema, such as in breast cancer patients who have had lymph node resection. Antikeratin antibodies are useful in identifying metastatic breast carcinoma, whereas CD34, CD31, and *Ulex europaeus* lectin are positive in Stewart-Treves angiosarcoma. Differential staining with keratins 7 and 20 can help suggest the site of origin in cases of cutaneous metastatic adenocarcinoma.

**Sittart JA, et al:** Cutaneous metastasis from internal carcinomas: a review of 45 years. *An Bras Dermatol* 2013; 88(4):541–544.

## Paraneoplastic syndromes

Some cancers produce findings in the skin indicating that an underlying internal malignancy may be present. These may range from a specific eruption characteristic of a particular type of cancer, such as necrolytic migratory erythema, to a nonspecific cutaneous reaction pattern, such as that caused by an internal malignancy. Although many of these syndromes are discussed in other chapters, a few are mentioned here as illustrative examples of this phenomenon.

Bazex syndrome, or acrokeratosis paraneoplastica, is characterized by violaceous erythema and scaling of the fingers, toes, nose, and aural helices. Nail dystrophy and palmoplantar keratoderma may be seen. These cases are secondary to primary malignant neoplasms of the upper aerodigestive tract or metastatic cancer to lymph nodes, often in the cervical region.

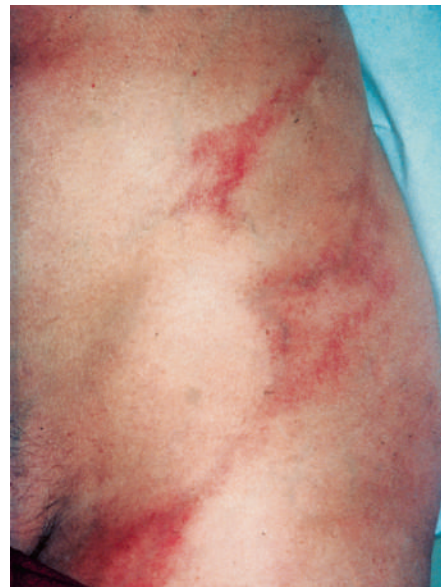The glucagonoma syndrome is characterized by weight loss, glucose intolerance, anemia, glossitis, and necrolytic migratory erythema. Erythematous patches with bullae and light-brown papules with scales involving the face, groin, and abdomen characterize the skin eruption. This is seen with glucagon-secreting tumors of the pancreas.

Erythema gyratum repens is a gyrate serpiginous erythema with characteristic wood grain-pattern scales; it is almost always associated with an underlying malignancy. Hypertrichosis lanuginosa acquisita, or malignant down, is the sudden growth of profuse, soft, nonmedullated, nonpigmented, downy hair in an adult. The most common sites of associated carcinoma reported were the lung and colon.

The sign of Leser-Trélat is the sudden appearance of multiple pruritic seborrheic keratoses, associated with an internal malignancy. Trousseau's sign, or migratory thrombophlebitis (Fig. 28-48), is usually associated with pancreatic carcinoma. A form of pemphigus, paraneoplastic pemphigus, is most frequently associated with lymphoma, chronic lymphocytic leukemia, and Castleman's disease.

Several cutaneous diseases that are not associated with internal malignancy with the frequency of the previous conditions, but that may be a sign of internal malignancy in some cases, are exfoliative erythroderma (lymphoproliferative disease), acanthosis nigricans (adenocarcinoma), multicentric reticulohistiocytosis, Sweet syndrome (acute myelogenous leukemia), nodular fat necrosis (pancreatic carcinoma), Paget's disease (underlying adnexal or breast carcinoma, or adenocarcinoma of genitourinary tract or colon), dermatomyositis in patients over age 40, palmar fasciitis and polyarthritides syndrome, and acquired ichthyosis (lymphoproliferative).

A variant of acquired ichthyosis, pityriasis rotunda, manifests circular, brown, scaly patches from 1 to 28 cm in diameter and varying in number from 1 to 20. They may occur on the trunk or extremities. These symptomless patches may be a clue to the diagnosis of hepatocellular carcinoma in South African black patients. Tripe palms, considered by some to be



**Fig. 28-48** Superficial migratory thrombophlebitis secondary to breast cancer.

acanthosis nigricans of the palms, are associated with carcinoma in more than 90% of cases. Filiform hyperkeratosis of the palms may present in patients who develop cancer.

**Abreu Velez AM, et al:** Diagnosis and treatment of cutaneous paraneoplastic disorders. *Dermatol Ther* 2010; 23(6):662–675.

**Da Silva JA, et al:** Paraneoplastic cutaneous manifestations: concepts and updates. *An Bras Dermatol* 2013; 88(1):9–22.

**Moore RL, et al:** Epidermal manifestations of internal malignancy. *Dermatol Clin* 2008; 26(1):17–29.

**Pipkin CA, et al:** Cutaneous manifestations of internal malignancies: an overview. *Dermatol Clin* 2008; 26(1):1–15.

**Shah A, et al:** Neoplastic/paraneoplastic dermatitis, fasciitis, and panniculitis. *Rheum Dis Clin North Am* 2011; 37(4):573–592.

**Steele HA, et al:** Mucocutaneous paraneoplastic syndromes associated with hematologic malignancies. *Oncology (Williston Park)* 2011; 25(11):1076–1083.

## Carcinoid

Carcinoid involves the lungs, heart, and GI tract, as well as the skin. The outstanding feature of the skin is flushing, usually lasting 5–10 min. It most prominently involves the head and neck, but also produces a diffuse, scarlet color, with mottled red patches on the thorax and abdomen. Striking color changes may occur, with salmon red, bluish white, and other colors appearing simultaneously on various portions of the skin. Cyanosis may also be present. As the episodic flushing continues over months to years, telangiectases and plethora appear, as though the patient has polycythemia vera. Gyrate and serpiginous patches of erythema and cyanosis flare up and subside, not only on the face, but also on all parts of the body and extremities.

Pellagroid changes may appear as a result of shunting of dietary tryptophan away from the kynurenine-niacin pathway and into the 5-hydroxyindole pathway. Periorbital swelling, edema of the face, neck, and feet, and sclerodermatous changes may occur. Disseminated deep dermal and subcutaneous metastatic nodules from a primary bronchial carcinoid tumor have been documented. The clinical features of the carcinoid syndrome become evident only after hepatic metastases have occurred, or when the primary tumor is a bronchial carcinoid, or if the carcinoid arises in an ovarian teratoma, where the venous drainage bypasses the hepatic circulation.



The release of excessive amounts of serotonin and bradykinin into the circulation produces attacks of flushing of the skin, weakness, abdominal pain, nausea, vomiting, sweating, bronchoconstriction, palpitation, diarrhea, and collapse. These attacks may last a few hours. Right-sided cardiac valvular fibrosis occurs in 60% of chronically affected patients. Symptoms may be induced in these patients by the injection of epinephrine, at which time kinin peptide is released. Alcohol, hot beverages, exercise, and certain foods, among other factors, may induce flushing. The patient will provide the relevant triggers by history.

### Etiologic factors

Carcinoid, also called argentaffinoma, is a tumor that arises from the argentaffin Kulchitsky chromaffin cells in the appendix or terminal ileum, as well as in other parts of the GI tract, from the lungs as bronchial adenomas, and rarely from ovarian or testicular teratomas. Some of these produce large amounts of serotonin (5-hydroxytryptamine), a derivative of tryptophan, and others do not. The primary lesion is more active in the production of serotonin than are the metastases. The tumor frequently metastasizes to the draining lymph glands or to neighboring organs, especially the liver, and rarely to more distal sites.

### Laboratory findings

The diagnosis may be established by finding a high level of 5-hydroxyindolacetic acid (5-HIAA) in the urine. The normal urinary excretion of 5-HIAA is 3–8 mg/day, but in the presence of carcinoid, it may reach 300 mg. Urinary values greater

than 25 mg/day are diagnostic of carcinoid. Any value above the normal output is considered suspicious. The ingestion of bananas may cause significant elevations of 5-HIAA in the urine within a few hours, because banana pulp contains serotonin (4 mg/banana) and catecholamines. Tomatoes, red plums, pineapples, avocados, and eggplants also contain serotonin, but in much smaller amounts.

A screening test for 5-HIAA is the addition of nitrosonaphthol to the urine. A purple color is produced when 40 mg/day of 5-HIAA is excreted. Other serotonin metabolites besides 5-HIAA are found in the urine. The blood also contains serotonin in amounts of 0.2–0.4 mg%. In the presence of carcinoid, the amount may be 10 times normal.


Metastatic carcinoid may appear in the skin. A high index of suspicion is needed, because metastatic carcinoid has been reported to mimic apocrine poroma on shave biopsy.

### Treatment

In the rare cases where there is only a primary tumor without metastases, this should be removed. Excision of metastatic lesions in the liver may also be considered. If this is impossible, long-acting somatostatin analogs provide good long-term symptomatic control of the flushing and diarrhea. Injections are given monthly. Vitamin supplementation with niacin and avoidance of known trigger factors to flushing are recommended. Restriction of tryptophan-containing foods for short periods may limit serotonin production.

**Jabbour SA:** Skin manifestations of hormone-secreting tumors. *Dermatol Ther* 2010; 23(6):643–650.

**Shah KR, et al:** Cutaneous manifestations of gastrointestinal disease. Part I. *J Am Acad Dermatol* 2013; 68(2):189.e1–e21

 Bonus images for this chapter can be found online at [expertconsult.inkling.com](http://expertconsult.inkling.com)

**eFig. 28-1** Nevus anemicus.

**eFig. 28-2** Port wine stain.

**eFig. 28-3** Port wine stain.

**eFig. 28-4** Arteriovenous fistula, caused by mortar explosion in popliteal fossa.

**eFig. 28-5** Superficial lymphatic malformation.

**eFig. 28-6** Spider angioma.

**eFig. 28-7** Venous lake.

**eFig. 28-8** Angiokeratoma circumscriptum.

**eFig. 28-9** Pyogenic granuloma.

**eFig. 28-10** Cherry angiomas.

**eFig. 28-11** Infantile hemangioma.

**eFig. 28-12** Subungual glomus tumor.

**eFig. 28-13** Intravascular lymphoma.

**eFig. 28-14** Angiosarcoma.

**eFig. 28-15** Angiosarcoma after radiation therapy.

**eFig. 28-16** Stewart-Treves tumor.

**eFig. 28-17** Keloid.

**eFig. 28-18** Dupuytren contracture.

**eFig. 28-19** Fibroma of the tendon sheath.

**eFig. 28-20** Connective tissue nevus of Proteus.

**eFig. 28-21** Pearly penile papules.

**eFig. 28-22** Acquired digital fibrokeratoma.

**eFig. 28-23** Dermatofibroma. (Courtesy of Dr. Lawrence Lieblch.)

**eFig. 28-24** Recurrent dermatobromasarcoma protuberans.

**eFig. 28-25** Malignant fibrous histiocytosis at the site of radiation dermatitis.

**eFig. 28-26** Adult generalized mastocytosis.

**eFig. 28-27** Urticaria pigmentosa.

**eFig. 28-28** Traumatic neuroma.

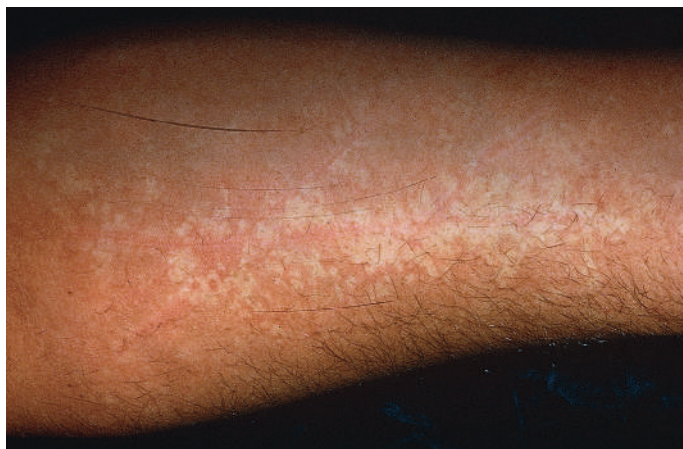**eFig. 28-29** Neurilemmoma.

**eFig. 28-30** Frontalis-associated lipoma of the forehead.

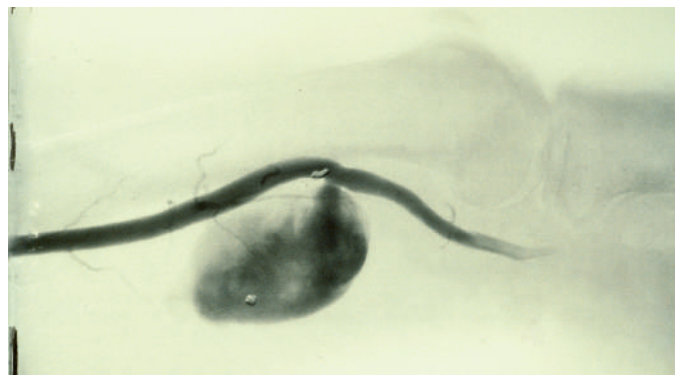
**eFig. 28-31** Multiple leiomyomas.

**eFig. 28-32** Erythema gyratum repens secondary to ovarian cancer.

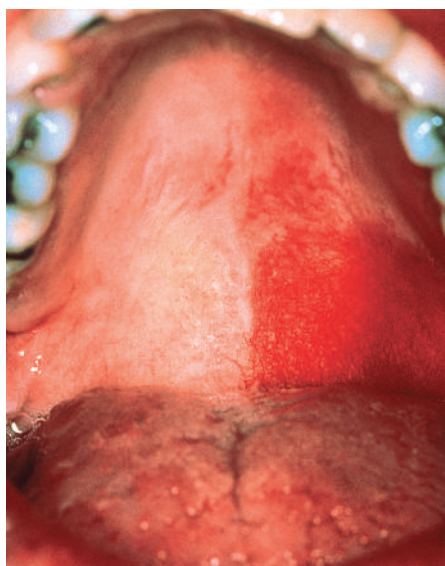
**eFig. 28-33** Acanthosis nigricans from gastrointestinal carcinoma.



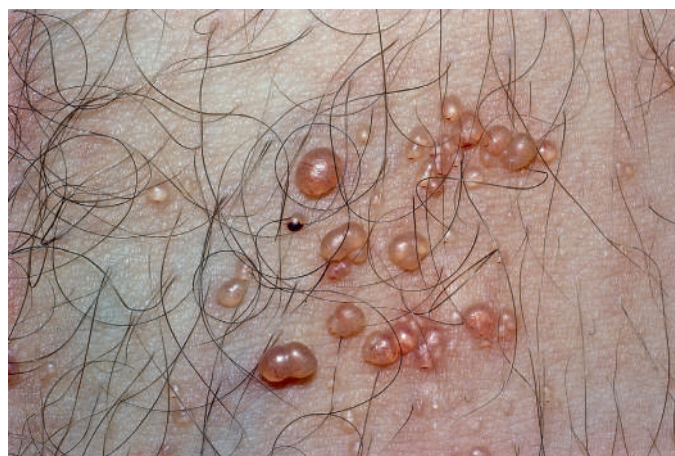eFig. 28-1 Nevus anemicus.



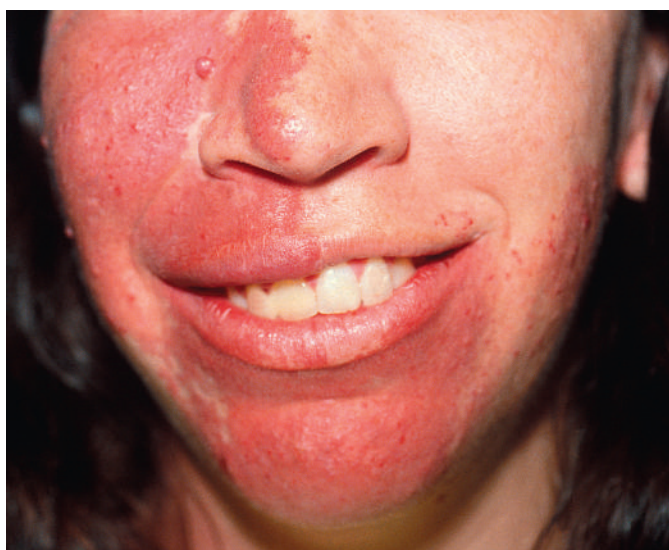eFig. 28-4 Arteriovenous fistula, caused by mortar explosion in popliteal fossa.



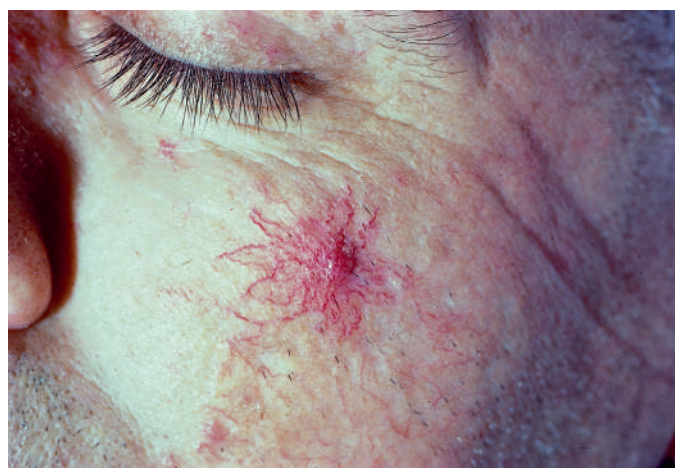eFig. 28-2 Port wine stain.



eFig. 28-5 Superficial lymphatic malformation.

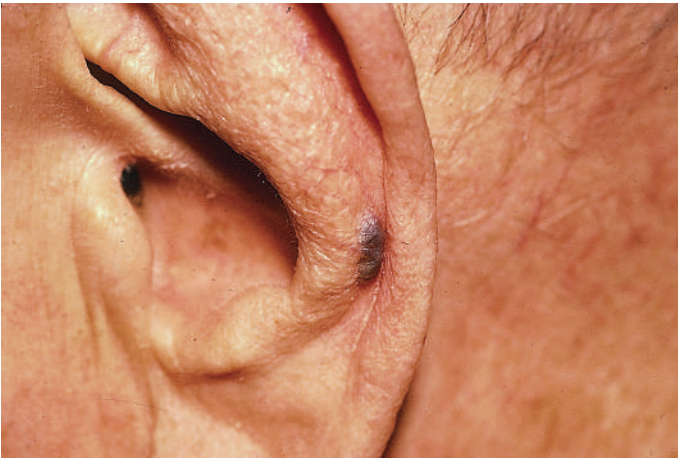

eFig. 28-3 Port wine stain.

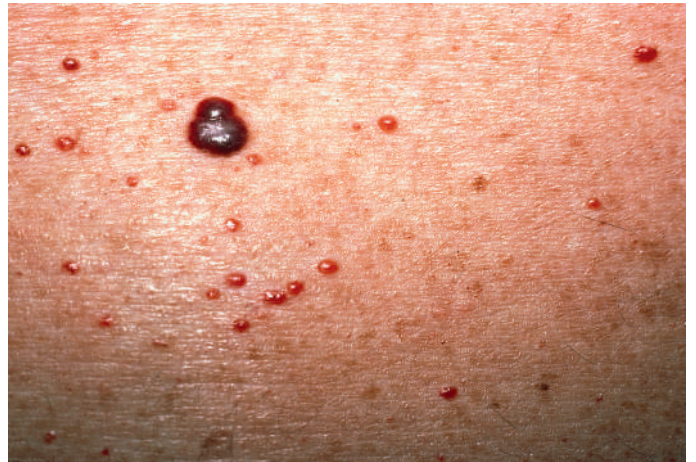

eFig. 28-6 Spider angioma.

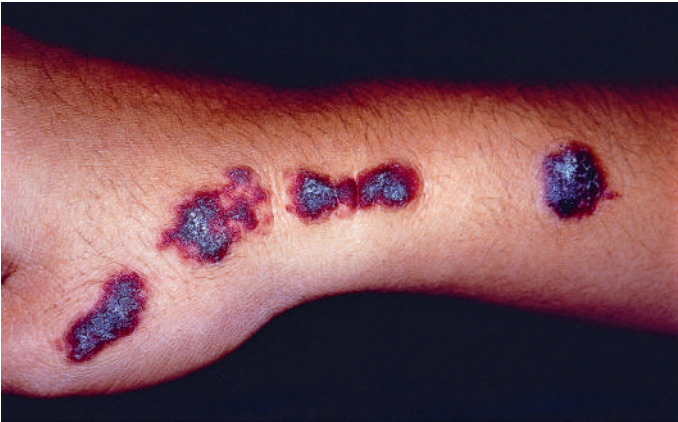



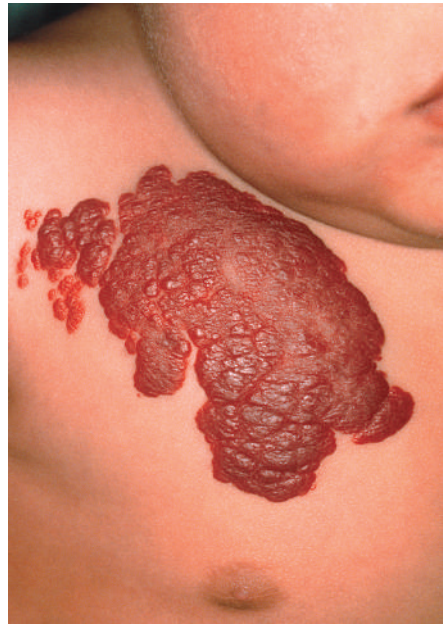**eFig. 28-7** Venous lake.



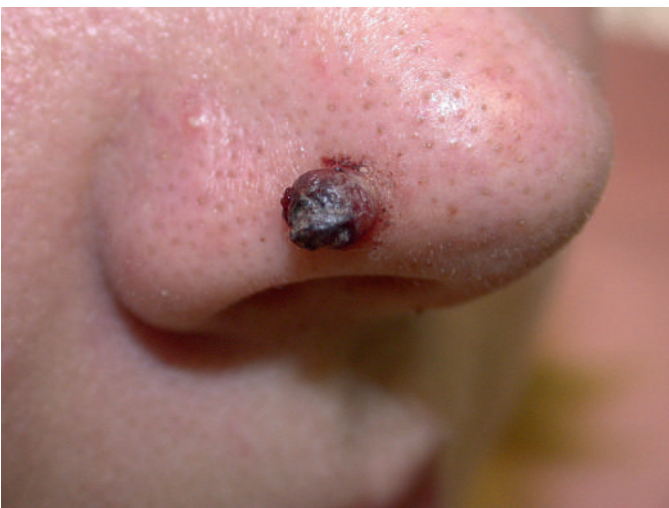**eFig. 28-10** Cherry angiomas.



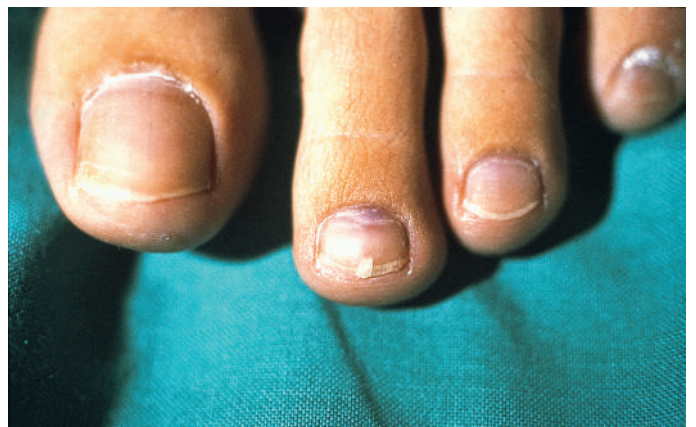**eFig. 28-8** Angiokeratoma circumscriptum.



**eFig. 28-11** Infantile hemangioma.

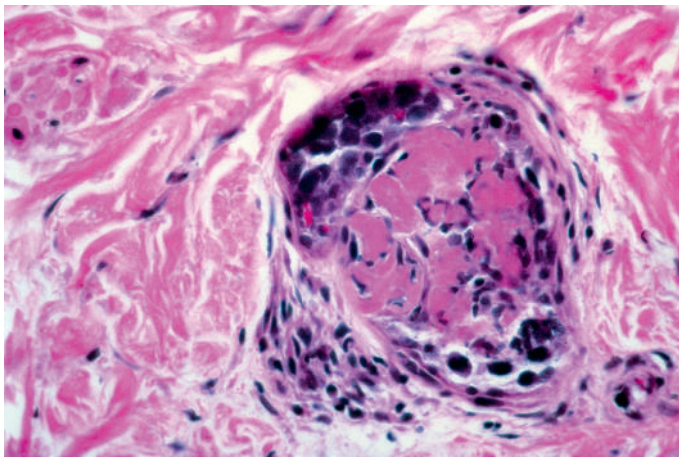


**eFig. 28-9** Pyogenic granuloma.

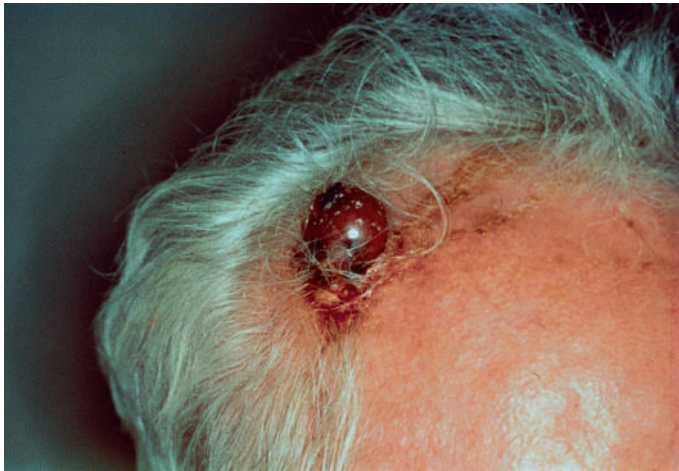

**eFig. 28-12** Subungual glomus tumor.

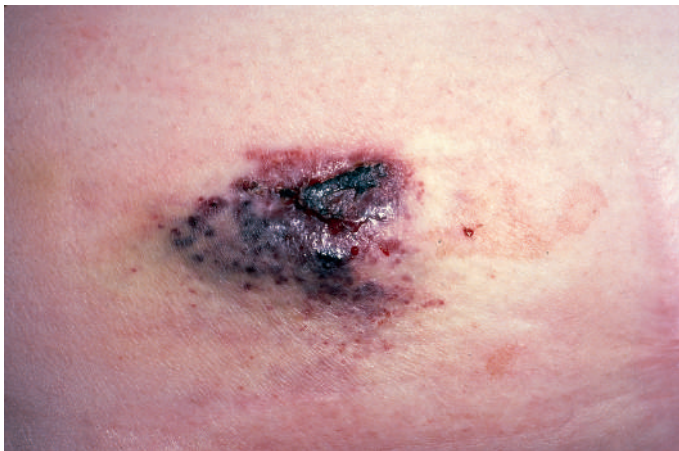




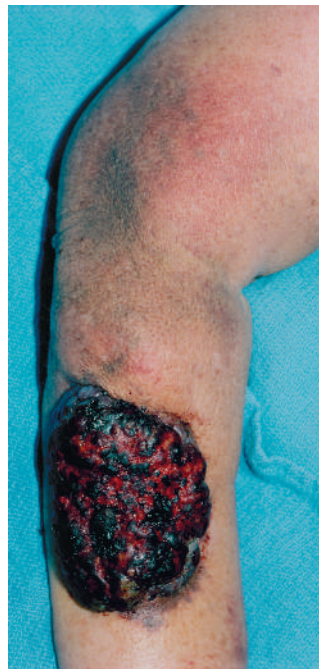eFig. 28-13 Intravascular lymphoma.



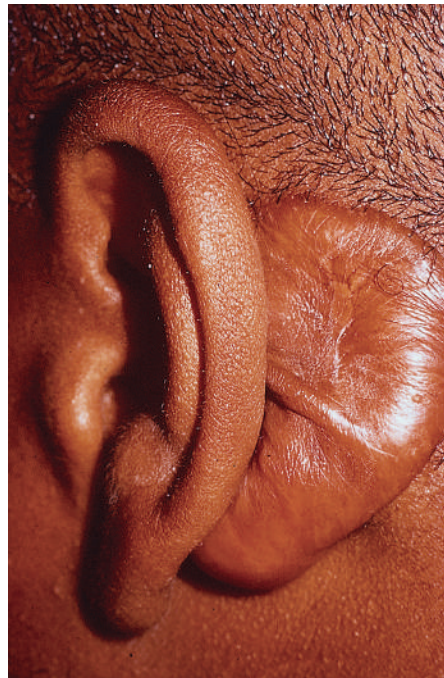eFig. 28-14 Angiosarcoma.



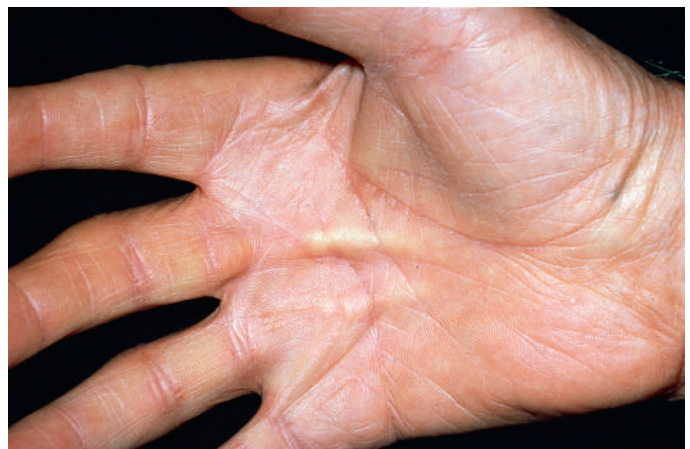eFig. 28-15 Angiosarcoma after radiation therapy.



eFig. 28-16 Stewart-Treves tumor.

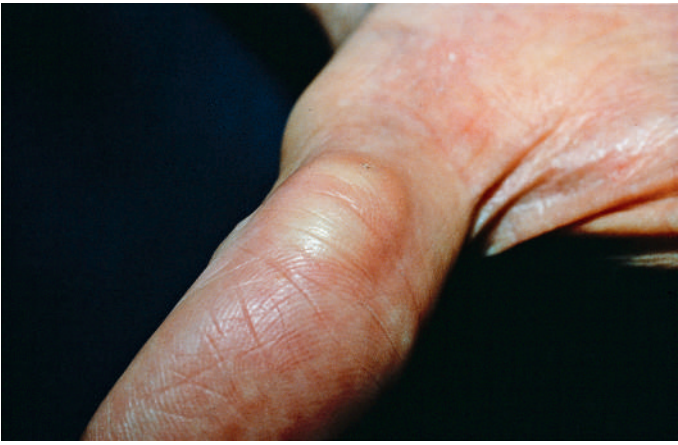

eFig. 28-17 Keloid.

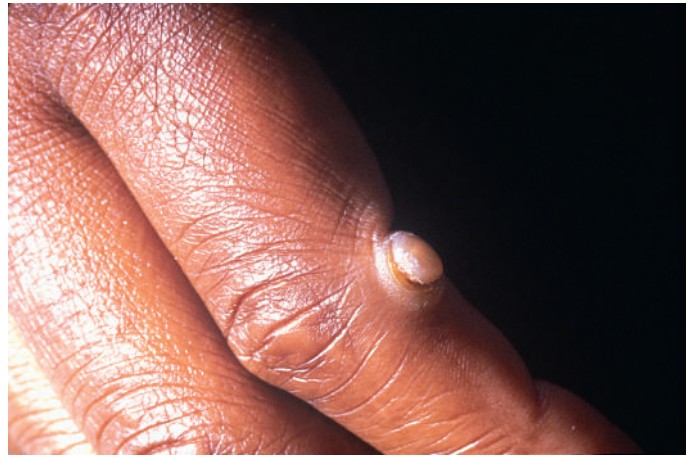

eFig. 28-18 Dupuytren contracture.

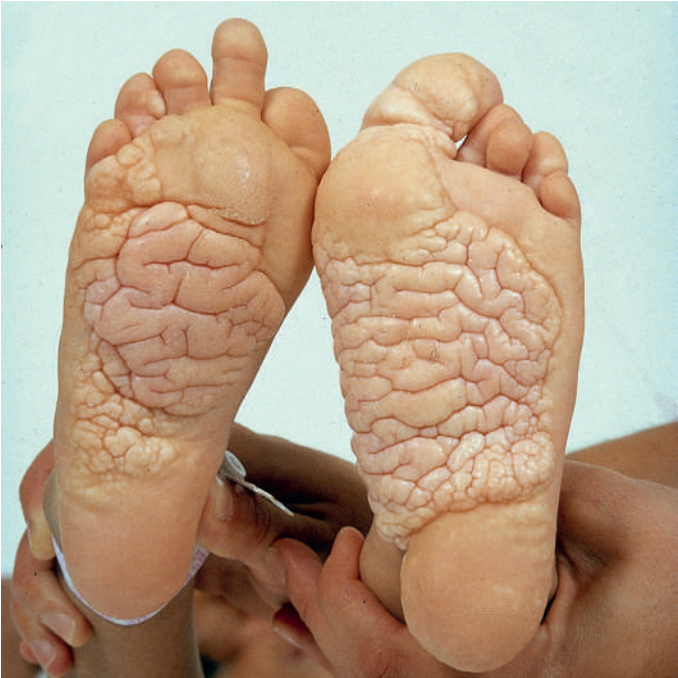



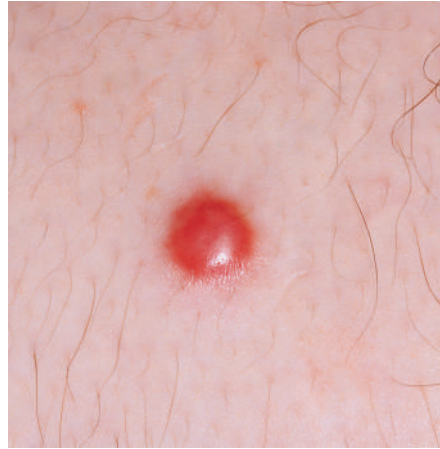**eFig. 28-19** Fibroma of the tendon sheath.



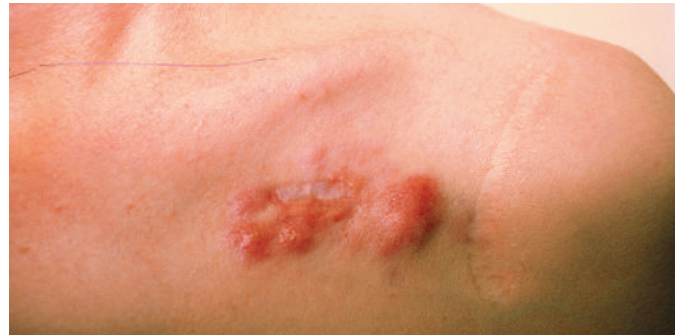**eFig. 28-22** Acquired digital fibrokeratoma.



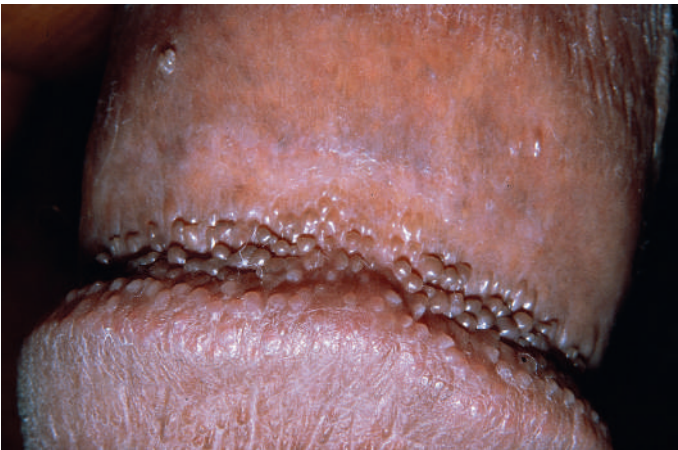**eFig. 28-20** Connective tissue nevus of Proteus.



**eFig. 28-23**  
Dermatofibroma.  
(Courtesy of Dr.  
Lawrence Lieblich.)

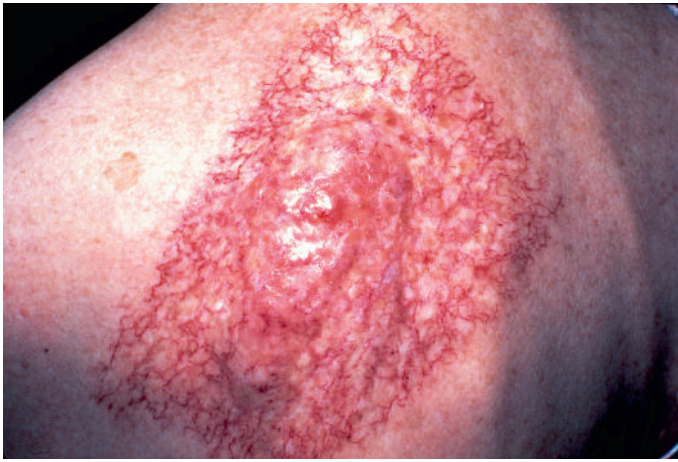

**eFig. 28-24** Recurrent dermatobromasarcoma protuberans.

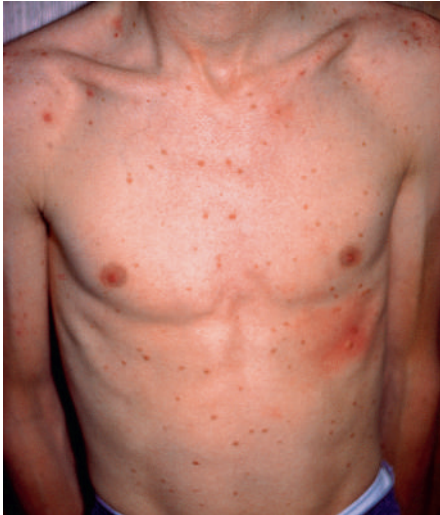

**eFig. 28-21** Pearly penile papules.

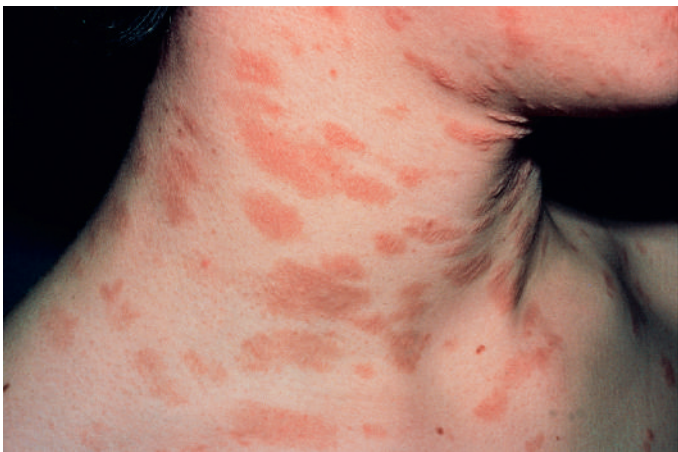



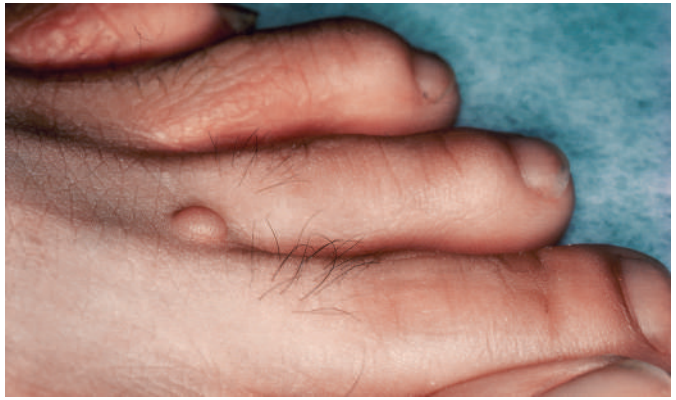**eFig. 28-25** Malignant fibrous histiocytosis at the site of radiation dermatitis.



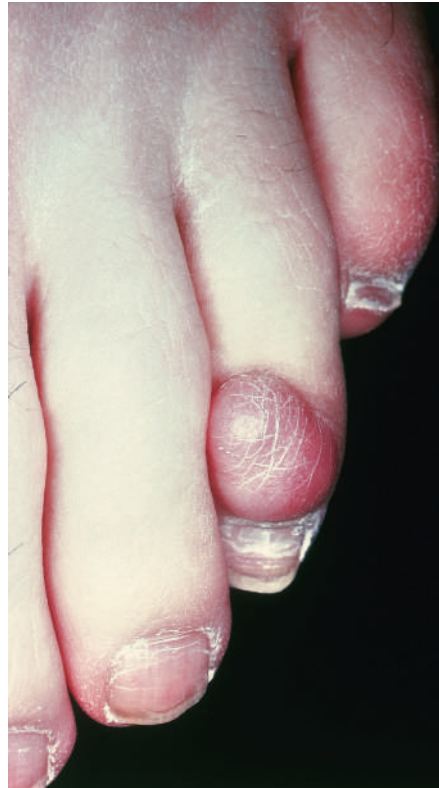**eFig. 28-26** Adult generalized mastocytosis.



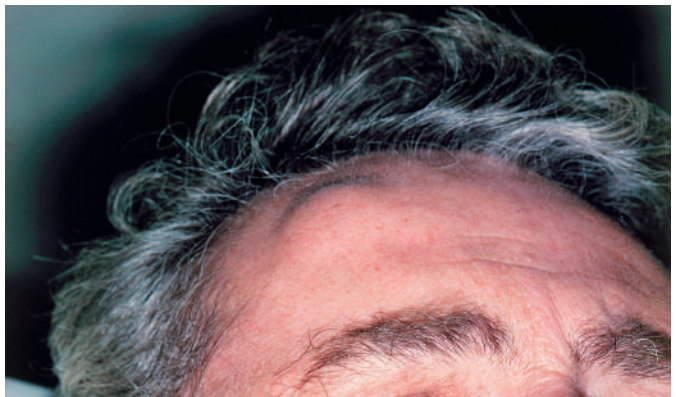**eFig. 28-27** Urticaria pigmentosa.



**eFig. 28-28** Traumatic neuroma.

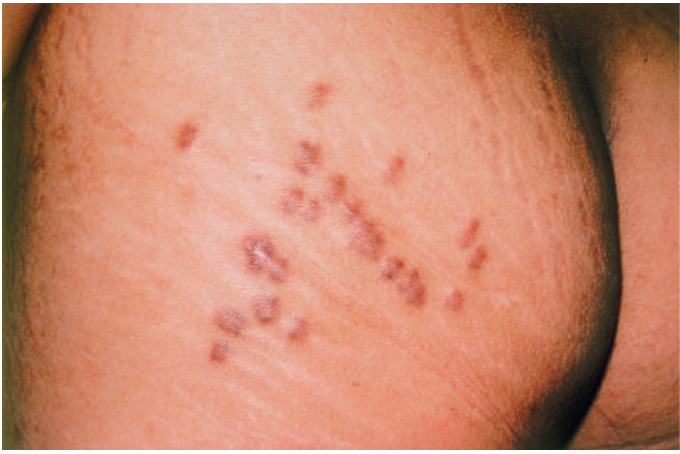


**eFig. 28-29** Neurilemmoma.

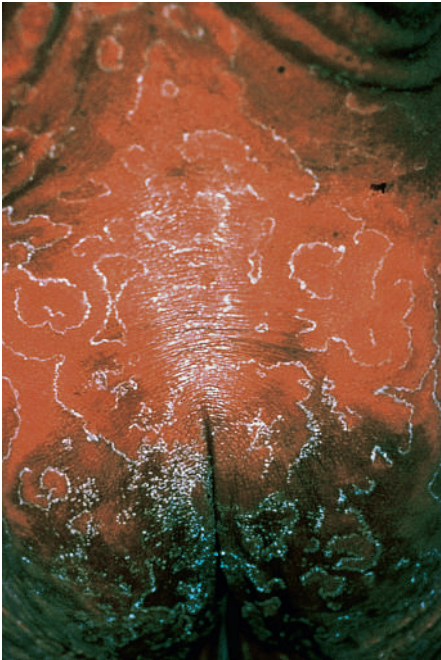


**eFig. 28-30** Frontalis-associated lipoma of the forehead.

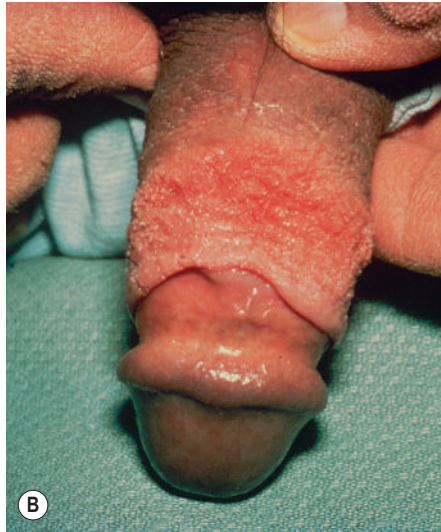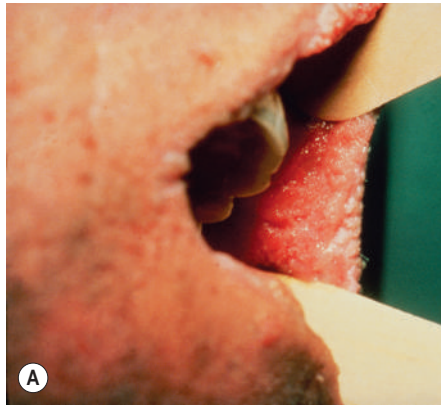




**eFig. 28-31** Multiple leiomyomas.



**eFig. 28-32** Erythema gyratum repens secondary to ovarian cancer.



**eFig. 28-33 A and B,** Acanthosis nigricans from gastrointestinal carcinoma.

## Epidermal Nevi, Neoplasms, and Cysts

### EPIDERMAL NEVI

Epidermal nevi are hamartomatous growths of the epidermis that are present at birth in about half of patients or develop early in childhood. The term “epidermal nevus” includes several entities, including keratinocytic epidermal nevi, nevus sebaceus, and nevus comedonicus, depending on which epidermal cell or structure comprises the lesion. Although it is usually possible to classify epidermal nevi into one type, it is not uncommon to find local elements of various types within the same epidermal nevus. The epidermal nevus should be classified by its predominant histologic and clinical feature: keratinocytic, comedonal, or sebaceous. Some syndromes have also been included in this classification, such as Proteus, CHILD, and phakomatosis pigmentokeratocytica, since localized lesions and widespread systematized presentations are caused by the same genetic mutations. This suggests that all “epidermal nevi” should be classified according to their histologic phenotype. Epidermal nevi of all types are considered an expression of cutaneous mosaicism with genetic mutation in the affected skin, but sparing the unaffected skin in widespread lesions; much less frequently, the mutation is found not only in the skin, but also in other tissues. Lesions follow the lines of Blaschko, suggesting that they represent postzygotic mutations. In general, larger lesions, more widespread lesions, and lesions of the head and neck are more likely to have associated internal complications. The combination of an epidermal nevus and an associated internal problem is called “epidermal nevus syndrome.” For each histologic type, the frequency and nature of associated systemic problems may be characteristic. Overall, about 1 in 1000 children have an epidermal nevus of some type.

### Keratinocytic epidermal nevi

Keratinizing epidermal nevi are the most common type of epidermal nevus and are described by a great variety of terms, such as linear epidermal nevus, hard nevus of Unna, soft epidermal nevus, and nevus verrucosus (verrucous nevus). If the lesion is widespread on half the body, the term nevus unius lateris has been used. The term ichthyosis hystris is used if the lesions are bilateral and widespread.

The most common pattern of keratinocytic epidermal nevus is linear epidermal nevus. The individual lesions are verrucous, skin-colored, dirty-gray, or brown papules, which coalesce to form a serpiginous plaque (Fig. 29-1). Interspersed in the localized patch may be horny excrescences and rarely comedones. The age of onset of epidermal nevi is generally at birth, but they may also develop within the first 10 years of life. They follow the lines of Blaschko.

The histologic changes in the epidermis are hyperplastic and affect chiefly the stratum corneum and stratum malpighii.

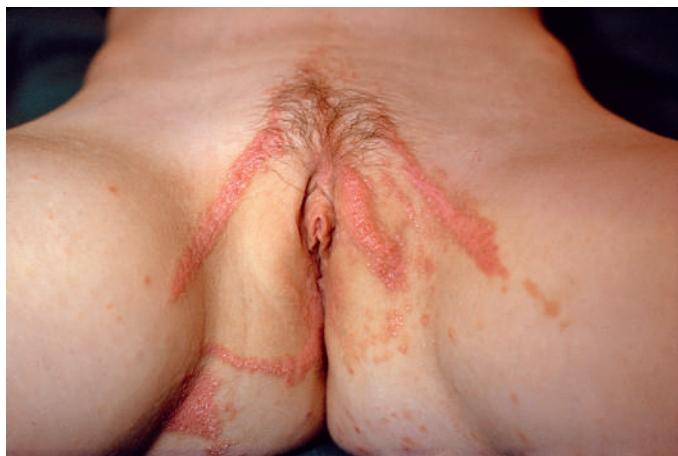There is variable hyperkeratosis, acanthosis, and papillomatosis. Up to 62% of biopsies of epidermal nevi have this pattern, so-called nonepidermolytic hyperkeratosis (NONEEN). About 16% show epidermolytic hyperkeratosis. At times, other histologic patterns may be found, including a psoriatic type, an acrokeratosis verruciformis-like type, and a Darier’s disease-like type. It is assumed that each of these types would be associated with a specific mutation in the affected skin that, if widespread, would give rise to the cutaneous disorder with the same histology. For example, epidermal nevi that show epidermolytic hyperkeratosis would have the same gene mutation as the disorder of cornification, bullous congenital ichthyosiform erythroderma (i.e., keratins K1 and K10). In fact, patients with this type of epidermal nevus may have gonadal mosaicism that can result in offspring with the full-blown disorder. In a significant portion of the classic and common keratinocytic epidermal nevi that simply shows hyperkeratosis, papillomatosis, and acanthosis histologically, there is an activating gene mutation in fibroblast growth factor receptor 3 (*FGFR3*), *HRAS*, or *PIK3CA*, a downstream effector of FGFR signaling. *FOXP1* is highly expressed in these lesions. The same gene mutations are found in sporadic seborrheic keratoses, which, not surprisingly, have the same histology.

Keratinocytic epidermal nevi, as a part of an “epidermal nevus syndrome,” may be associated with internal manifestations, including primarily skeletal abnormalities and, less often, central nervous system (CNS) manifestations. Various abnormalities of the bones, vessels, and brain are associated with these clinical findings. CNS manifestations appear to be more common when the lesions are large and located on the head and neck. Large keratinocytic epidermal nevi of the trunk and extremities are more frequently associated with skeletal abnormalities. Since both nevus sebaceus and keratinocytic epidermal nevi were included in the original and large reports of epidermal nevus syndrome, the precise characterization of the “keratinocytic epidermal nevus syndrome” remains to be defined.

Both Proteus syndrome and CLOVE syndrome (congenital lipomatous overgrowth, vascular malformations, and epidermal nevi) can have skin lesions of epidermal nevus. CLOVE is distinguished from Proteus syndrome by congenital overgrowth of a ballooning nature, which grows proportionately with the patient and typically affects the feet.

The CHILD syndrome and verruciform xanthoma are both characterized by the presence histologically of elongated and widened dermal papillae filled with xanthomalike cells. Epidermal hyperplasia, with acanthosis, papillomatosis, parakeratosis, and hyperkeratosis, is also present (the features of a keratinocytic epidermal nevus). In rare cases, instead of half the body being affected, large quadrants of the body, favoring folds, are the sites of the epidermal growths (ptychotropism). CHILD and verruciform xanthoma (in some cases) contain mutations in the *NSDHL* gene, located on the X chromosome and required for cholesterol biosynthesis.





**Fig. 29-1** Linear epidermal nevus.

Epidermal nevus syndrome associated with *FGFR3* mutation is characterized by widespread epidermal nevus and developmental brain defects. Epidermal nevus syndrome may also be associated with vitamin D-resistant hypophosphatemic rickets, perhaps from circulating fibroblast growth factor 23 acting as a phosphaturic.

Rarely, keratinocytic and adnexal malignancies occur in keratinocytic epidermal nevi. Any newly appearing lesion within a stable epidermal nevus should be biopsied to exclude this possibility. Management of keratinocytic epidermal nevi is difficult because, unless the treatment extends into the dermis (and thus may cause scarring), the lesion recurs. The use of a combination of 5% 5-fluorouracil (5-FU) plus 0.1% tretinoin creams once daily may be beneficial, and the response may be enhanced by occlusion. Cryotherapy can be quite effective, with good cosmetic results. Combination topical corticosteroids and calcipotriene may be beneficial. Carbon dioxide (CO<sub>2</sub>) and erbium:yttrium-aluminum-garnet (Er:YAG) laser treatment may also be effective. If the lesion is small, simple excision can be considered.

**Akhyani M, et al:** Bullous ichthyosiform erythroderma in a child born to a parent with systematized linear epidermolitic hyperkeratosis. *Int J Dermatol* 2009; 48:215.

**Avgerinou GP, et al:** CHILD syndrome: the *NSDHL* gene and its role in CHILD syndrome, a rare hereditary syndrome. *J Eur Acad Dermatol Venereol* 2010; 24(6):733–736.

**Brandling-Bennett HA, et al:** Epidermal nevi. *Pediatr Clin North Am* 2010; 57:1177.

**De D, et al:** Basal cell carcinoma developing in verrucous epidermal nevus. *Indian J Dermatol Venereol Leprol* 2007; 73:127.

**Gantner S, et al:** CHILD syndrome with mild skin lesions: histopathologic clues for the diagnosis. *J Cutan Pathol* 2014; 41(10):787–790.

**Garcia-Vargas A, et al:** An epidermal nevus syndrome with cerebral involvement caused by a mosaic *FGFR3* mutation. *Am J Med Genet* 2008; 146A:2275.

**Gucev ZS, et al:** Congenital lipomatous overgrowth, vascular malformations, and epidermal nevi (CLOVE) syndrome: CNS malformations and seizures may be a component of this disorder. *Am J Med Genet* 2008; 146A:2688.

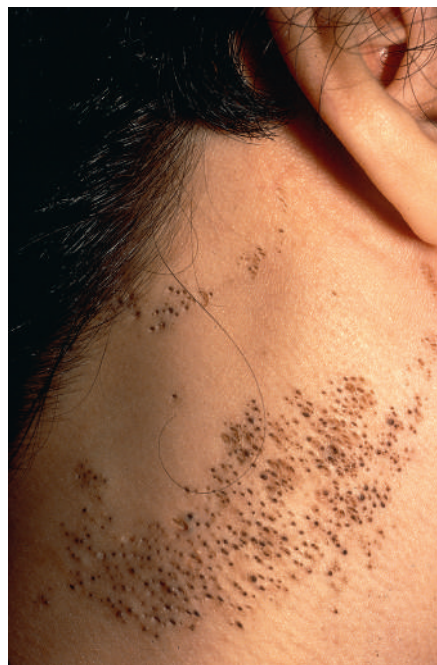**Hafner C, et al:** Mosaicism of activating *FGFR3* mutations in human skin causes epidermal nevi. *J Clin Invest* 2006; 116:2201.

**Hafner C, et al:** Oncogenic *PIK3CA* mutations occur in epidermal nevi and seborrheic keratoses with a characteristic mutation pattern. *Proc Natl Acad Sci USA* 2007; 104:13450.

**Hamanaka S, et al:** Multiple malignant eccrine poroma and a linear epidermal nevus. *J Dermatol* 1996; 23:469.

**Koh MJ, et al:** Systematized epidermal nevus with epidermolitic hyperkeratosis improving with topical calcipotriol/betametasone dipropionate combination ointment. *Pediatr Dermatol* 2013; 30:370.

**Masood Q, Narayan D:** Squamous cell carcinoma in a linear epidermal nevus. *J Plast Reconstr Aesthet Surg* 2009; 62:693.



**Fig. 29-2** Nevus comedonicus.

**Mehra S, et al:** A novel somatic mutation of the 3 $\beta$ -hydroxysteroid dehydrogenase gene in sporadic cutaneous verruciform xanthoma. *Arch Dermatol* 2005; 141:1263.

**Moreira Al, et al:** Epidermal nevus syndrome associated with hypophosphatemic rickets. *Dermatol Online J* 2010; 16:14.

**Narazaki R, et al:** Linear nevus sebaceous syndrome with hypophosphatemic rickets with elevated FGF-23. *Pediatr Nephrol* 2012; 27:861.

**Panagiotopoulos A, et al:** Assessment of cryotherapy for the treatment of verrucous epidermal naevi. *Acta Derm Venereol* 2009; 89:292.

**Paradela S, et al:** Epidermal nevi treated by carbon dioxide laser vaporization: a series of 25 patients. *J Dermatolog Treat* 2007; 18:169.

## Nevus comedonicus

Nevus comedonicus is characterized by closely arranged, grouped, often linear papules that have at their center dilated follicular openings with keratinous plugs resembling comedones. Cysts, abscesses, fistulas, and scars develop in about half the cases, which have been described as “inflammatory” nevus comedonicus. As with other epidermal nevi, lesions may be localized to a small area or may have an extensive distribution. They are most frequently unilateral, although bilateral cases are also seen. Lesions occur mostly on the trunk and follow the lines of Blaschko. The lesions may develop any time from birth to age 15 but are usually present by age 10. Follicular tumors, including trichofolliculoma and pilar sheath acanthoma, can appear within the lesion. An “epidermal nevus syndrome” or “nevus comedonicus syndrome” has been reported with electroencephalogram (EEG) abnormalities, ipsilateral cataract, corneal changes, and skeletal anomalies (hemivertebrae, scoliosis, and absence of fifth ray of hand).

The pilosebaceous follicles are dilated and filled with keratinous plugs (Fig. 29-2). On the palms, pseudocomedones are present. Histologic examination reveals large dilated follicles filled with orthokeratotic horny material and lined by atrophic squamous epithelium. The interfollicular epidermis is papillomatous, as seen in typical epidermal nevi. Hair follicle differentiation, well-formed follicular structures, and normal sebaceous glands are not common in well-formed lesions.

Apert syndrome is characterized by skeletal anomalies and acne. It is caused by a mutation in *FGFR2*. A mutation has also

been found in *FGFR2* in at least one case of nevus comedonicus, suggesting that nevus comedonicus may be a mosaic form of Apert syndrome.

Treatment of lesions not complicated by inflammatory cysts and nodules is primarily cosmetic. Pore-removing cosmetic strips and comedone expression may improve the cosmetic appearance. Topical tretinoin may be beneficial, as may Er:YAG or CO<sub>2</sub> laser. Patients with inflammatory lesions are much more difficult to manage. If the area affected is limited, surgical excision may be considered. Oral isotretinoin, chronically at the minimum effective dose (0.5 mg/kg/day, or less if possible), may partially suppress the formation of cysts and inflammatory nodules; however, many cases of nevus comedonicus fail to respond. The comedonal lesions do not improve with oral isotretinoin.

**Caers SJ, et al:** Successful treatment of nevus comedonicus with the use of the erbium YAG laser. *J Eur Acad Dermatol Venereol* 2008; 22(3):375–377.

**Ferrari B, et al:** Nevus comedonicus: a case series. *Pediatr Dermatol* 2014; Dec 29 [Epub ahead of print].

**Milburn S, et al:** The treatment of naevus comedonicus. *Br J Plast Surg* 2004; 57:805.

**Munro CS, Wilkie A:** Epidermal mosaicism producing localised acne: somatic mutation in *FGFR2*. *Lancet* 1998; 352:704.

**Pavithra S, et al:** Nevus comedonicus syndrome. *Indian J Dermatol* 2011; 56(6):771–772.

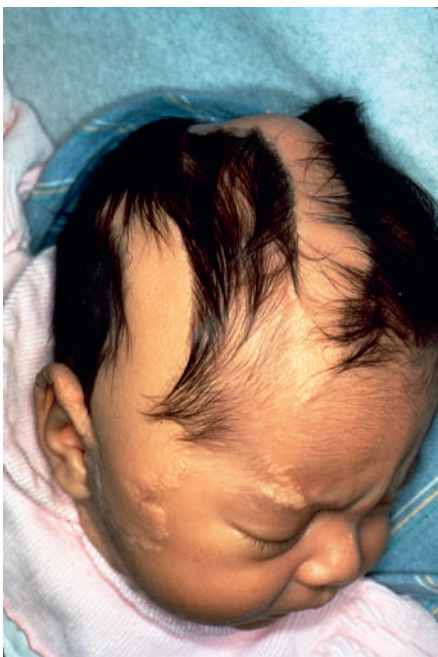**Sardana K, Garg V:** Successful treatment of nevus comedonicus with ultrapulse CO<sub>2</sub> laser. *Indian J Dermatol Venereol Leprol* 2009; 75(5):534–535.

**Tchernev G, et al:** Nevus comedonicus: an updated review. *Dermatol Ther (Heidelb)* 2013; 3(1):33–40.

## Epidermal nevus syndrome

Epidermal nevus syndrome does not represent a single entity, but rather multiple syndromes characterized by keratinocytic or organoid nevi, at times associated with internal organ involvement. Each variant has characteristic cutaneous findings and at times relatively specific internal findings. There are at least five variants of organoid epidermal nevus syndrome, as follows:

1. Schimmelpenning syndrome (Fig. 29-3). Nevus sebaceus coexists with cerebral, ocular, and skeletal defects.



**Fig. 29-3**  
Schimmelpenning syndrome.

Lesions of the head and neck may lack prominent sebaceous hyperplasia. Coloboma and lipodermoid of the conjunctiva can occur. Vitamin D-resistant hypophosphatemic rickets may be present.

2. Phacomatosis pigmentokeratotica. Nevus sebaceus and papular nevus spilus coexist. The nevus sebaceus may have a flat, erythematous central area with an elevated margin showing features of a nonorganoid epidermal nevus. Multiple angiomas may be found in the nevus spilus component. True basal cell carcinomas develop in the nevus sebaceus of this syndrome. CNS complications can occur, along with hyperhidrosis, weakness, and sensory or motor neuropathy. Vitamin D-resistant rickets may also be present.
3. Nevus comedonicus syndrome. Nevus comedonicus with ipsilateral ocular, skeletal, or neurologic defects defines this syndrome.
4. Angora hair nevus syndrome. A linear epidermal nevus is covered with long, white hair growing from dilated follicular pores. CNS, eye, and skeletal abnormalities may be found.
5. Becker nevus syndrome. Becker nevus is associated with ipsilateral hypoplasia of the breast.

Keratinocytic nevi are seen in at least four epidermal nevus syndromes, as follows:

1. Proteus syndrome
2. Type 2 segmental Cowden's disease. A linear soft, thick, papillomatous keratinocytic nevus in the absence of cerebriform hyperplasia of the palms and soles, but with segmental glomerulosclerosis. It is caused by loss of heterozygosity in an embryo carrying a *PTEN* germline mutation. Associated anomalies include lipomas, connective tissue nevi, vascular nevi, hemihypertrophy, seizures, hydrocephalus, and gastrointestinal (GI) polyps.
3. CHILD syndrome. X-linked dominant, male lethal trait. It is caused by a mutation in *NSDHL*. Chondrodysplasia punctata is characteristic. There is a marked affinity of the nevus for the body folds (ptychotropism). There is a tendency to spontaneous involution.
4. Fibroblast growth factor receptor 3 epidermal nevus syndrome (Garcia-Hafner-Happle syndrome). A velvety-type nonepidermolytic epidermal nevus and cerebral defects identify this syndrome.

Less well-defined syndromes include the following:

1. Nevus trichilemmocysticus. Multiple trichilemmal cysts along Blaschko's lines are associated with osteomalacia and fractures.
2. Didymosis aplasticosebacea. Sebaceous nevus coexists with aplasia cutis, usually in close proximity to each other.
3. SCALP syndrome. Sebaceous nevus, CNS malformations, aplasia cutis congenital, limbal dermoid, and pigmented nevus. It is a combination of didymosis aplasticosebacea and a large melanocytic nevus.
4. Gobellos syndrome. Systematized, linear, velvety, orthokeratotic nevus with hypertrichosis and follicular hyperkeratosis. Multiple bony defects are present.
5. Bafverstedt syndrome. Horny excrescences in a linear pattern with mental retardation and seizures. Diffuse ichthyosis-like hyperkeratosis covers the entire body, including the palms and soles.
6. NEVADA syndrome. Keratinocytic, verrucous nevus with angiodyplasia.
7. CLOVE syndrome. Congenital lipomatous overgrowth, vascular malformation, and epidermal nevus. Extensive



truncal vascular malformations and overgrown feet are characteristic.

**Happle R:** The group of epidermal nevus syndromes. *J Am Acad Dermatol* 2010; 63:1, 25.

### Inflammatory linear verrucous epidermal nevus

The term inflammatory linear verrucous epidermal nevus (ILVEN) may encompass as many as four separate conditions. The most common form is the classic ILVEN, or “dermatitic” epidermal nevus. At least three quarters of these cases appear before age 5 years, most before age 6 months. Later onset in adulthood has been reported. ILVEN is characteristically pruritic and pursues a chronic course. Lesions follow the lines of Blaschko. The individual lesions comprising the affected region are erythematous papules and plaques with fine scale (Fig. 29-4). The lesions are morphologically nondescript and, if the distribution is not recognized, could be easily overlooked as an area of dermatitis or psoriasis. Multiple, widely separated areas may be affected, usually on only one side of the body; this may also be bilateral, analogous to other epidermal nevi. Familial cases have been reported. Rarely, systemic involvement, with musculoskeletal and neurologic sequelae (developmental delay, epilepsy), has been reported.

Histologically, classic ILVEN demonstrates abruptly alternating areas of hypergranulosis with orthokeratosis, and parakeratosis with agranulosis. An inflammatory infiltrate of lymphocytes is present in the upper dermis. At times, the histology may simply be that of a subacute dermatitis. Although the histologic diagnosis of psoriasis can be considered, the correct diagnosis can be established if the dermatopathologist is made aware of ILVEN as a consideration. If there is a question, the presence of involucrin expression in the parakeratotic areas can distinguish ILVEN from psoriasis.

Three other types of inflammatory nevus have been included in this group. Some cases of “linear” lichen planus have been considered as “epidermal nevi,” because they typically follow lines of Blaschko. CHILD syndrome, also considered a type of “inflammatory” epidermal nevus, is usually clinically distinct, demonstrating its characteristic hemidysplasia. The most

confusing entity has been the “nevroid” or “linear” psoriasis. These cases are of two types. The first type is a child with a family history of psoriasis who has a nevroid lesion at or near birth. The child later develops psoriasis that “koebnerizes” into the ILVEN lesion, suggesting it is a “locus minoris resistentiae” for psoriasis. Treatment of the psoriasis clears the psoriasis overlying the ILVEN, but not the ILVEN. Arthritis developed in one such patient. In the second type, psoriasis initially presents in one band or area. Histologically, it resembles psoriasis. Most of these patients develop typical psoriasis later in life, suggesting a mosaicism that allowed expression of the psoriasis earlier in the initially affected area.

Inflammatory LVEN is differentiated from other epidermal nevi by the presence of erythema and pruritus clinically and by histologic features. Lichen striatus can be distinguished by its histology and natural history. Topical corticosteroids and topical retinoids appear to have limited benefit in ILVEN. However, topical vitamin D (calcipotriol and calcitriol) and topical anthralin have been beneficial. Surgical modalities include excision, cryotherapy, and laser. In cases of “nevroid,” “linear,” or “blaschkolinear” psoriasis, acitretin, narrow-band (NB) ultraviolet (UV) B therapy, and calcipotriene have been beneficial, but etanercept has failed.

**Agarwal US, et al:** Inflammatory linear verrucous epidermal nevus with psoriasiform histology. *Indian J Dermatol* 2014; 59(2):211.

**Behera B, et al:** Giant inflammatory linear verrucous epidermal nevus: successfully treated with full thickness excision and skin grafting. *Indian J Dermatol* 2013; 58(6):461–463.

**Burnett CT, Kouba DJ:** Inflammatory linear verrucous epidermal nevus of the digits treated with surgical excision and skin grafting. *Dermatol Surg* 2012; 38(12):2022–2024.

**Conti R, et al:** Inflammatory linear verrucous epidermal nevus: why a combined laser therapy. *J Cosmet Laser Ther* 2013; 15(4):242–245.

**Ferreira FR, et al:** Involucrin in the differential diagnosis between linear psoriasis and inflammatory linear verrucous epidermal nevus: a report of one case. *An Bras Dermatol* 2013; 88(4):604–607.

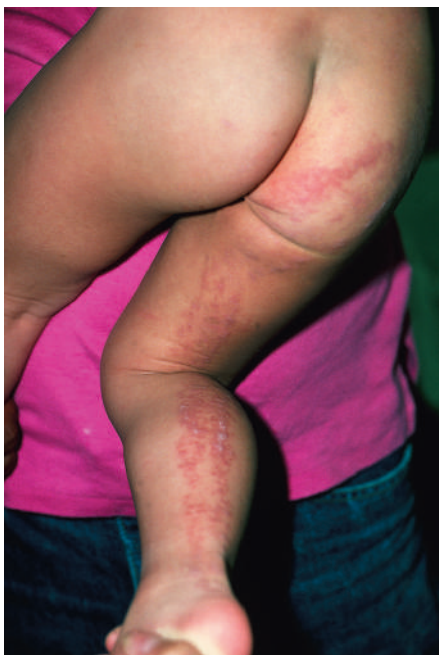**Hammami Ghorbel H, et al:** Treatment of inflammatory linear verrucous epidermal nevus with 2940 nm erbium fractional laser. *J Eur Acad Dermatol Venereol* 2014; 28(6):824–825.

**Le K, et al:** Vulval and perianal inflammatory linear verrucous epidermal naevus. *Australas J Dermatol* 2009; 50:115.

**Lee SH, Rogers M:** Inflammatory linear verrucous epidermal naevi: a review of 23 cases. *Australas J Dermatol* 2001; 42:252.

**Mazereeuw-Hautier J, et al:** Familial inflammatory linear verrucous epidermal naevus in a father and daughter. *Australas J Dermatol* 2009; 50:115.

**Renner R, et al:** Acitretin treatment of a systematized inflammatory linear verrucous epidermal naevus. *Acta Derm Venereol* 2005; 85:348.



**Fig. 29-4** Inflammatory linear verrucous epidermal nevus.

### HYPERKERATOSIS OF THE NIPPLE AND AREOLA

Hyperkeratosis of the nipple and areola (HNA) is an uncommon, benign, asymptomatic, acquired condition of unknown pathogenesis. Women represent 80% of cases, and HNA presents in their second or third decade. In men, the time of presentation is variable. Most cases are bilateral, although unilateral cases can occur. In about half the cases, both the areola and the nipple are involved. Breastfeeding is usually not affected. Clinically, there is verrucous thickening and brownish discoloration of the nipple and/or areola. Histologically, orthokeratotic hyperkeratosis occurs, with occasional keratinous cysts in the filiform acanthotic epidermis. The course is chronic. Treatment with cryotherapy, electrosurgical superficial removal of hyperkeratosis, excision and reconstruction, low-dose acitretin, topical steroids, and calcipotriol have benefitted some patients. A similar clinical manifestation has been seen in graft-versus-host disease (GVHD), malignant acanthosis nigricans, and candidiasis of the nipple associated with mucocutaneous candidiasis. Painful areolar hyperkeratosis

may be seen as a complication of sorafenib therapy. HNA must be distinguished from acanthosis nigricans, pregnancy-associated hyperkeratosis of the nipple, nipple eczema with lichenification, and Darier's disease. Isolated papules or small plaques in this location probably represent seborrheic keratoses affecting the nipple or areola. The relationship of HNA and areolar melanosis is unclear; these conditions have significant clinical similarity, except for the absence of hyperkeratosis in those lesions described as areolar melanosis.

**Boussofara L, et al:** Bilateral idiopathic hyperkeratosis of the nipple and areola. *Acta Dermatovenerol Alp Panonica Adriat* 2011; 20(1):41–43.

**Foustanos A, et al:** Surgical approach for nevoid hyperkeratosis of the areola. *J Cutan Aesthet Surg* 2012; 5(1):40–42.

**Frigerio M, et al:** Hyperkeratosis of nipple skin during sorafenib treatment. *Dig Liver Dis* 2009; 41:611.

**Ghanadian A, et al:** Nevoid hyperkeratosis of the nipple and/or areola: treatment with topical steroid. *Indian J Dermatol* 2013; (58(5):408.

**Guevara-Gutierrez E, et al:** Unilateral nevoid hyperkeratosis of the nipple and areola treated with topical calcitriol. *Actas Dermosifiliogr* 2008; 99(6):500–501.

**Higgins HW, et al:** Pregnancy-associated hyperkeratosis of the nipple: a report of 25 cases. *JAMA Dermatol* 2013; 149(6):722–726.

**Kartal Durmazlar SP, et al:** Hyperkeratosis of the nipple and areola: 2 years of remission with low-dose acitretin and topical calcipotriol therapy. *J Dermatolog Treat* 2008; 19:337.

**Lee HW, et al:** Hyperkeratosis of the nipple and areola as a sign of malignant acanthosis nigricans. *Clin Exp Dermatol* 2005; 30:721.

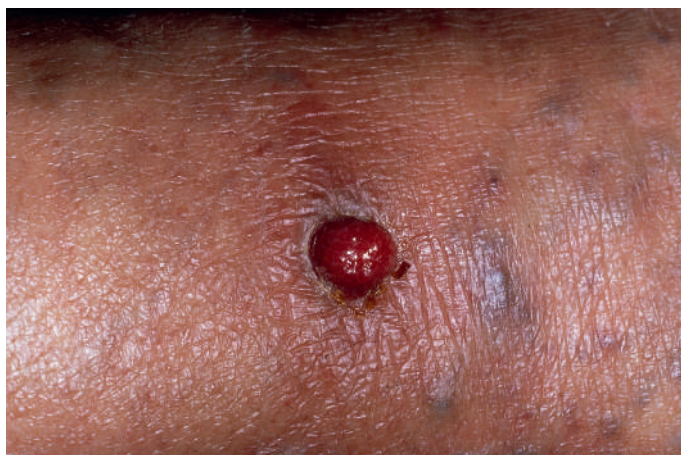**Mikhail M, et al:** Four views of areolar melanosis: clinical appearance, dermoscopy, confocal microscopy, and histopathology. *Dermatol Surg* 2008; 34:1101.

**Sceppa JA, et al:** Melanosis of the areola and nipple. *J Am Acad Dermatol* 2008; 59:S33.

**Verma P, et al:** Unilateral nevoid/primary hyperkeratosis of nipple and areola successfully treated with radiofrequency ablation. *J Cutan Aesthet Surg* 2011; 4(3):214–215.

## CLEAR CELL ACANTHOMA (PALE CELL ACANTHOMA)

Clear cell acanthoma is also known as Degos acanthoma. The typical lesion is a circumscribed, red, moist, shiny nodule with some crusting and peripheral scale (Fig. 29-5); it is usually about 1–2 cm in diameter. A collarette of scale is usually observed, and there may be pigmented variants. Exophytic nodules have been reported. The favorite site is on the shin, calf, or occasionally the thigh, although other sites (e.g., abdomen, scrotum) have been reported. The lesion is asymptomatic and slow growing and can occur in either gender,



**Fig. 29-5** Clear cell acanthoma.

usually after age 40. Solitary lesions are most common, but multiple nodules have been described. Rarely, an eruptive form of the disease occurs, producing up to 400 lesions. Squamous cell carcinoma (SCC) arising from clear cell acanthoma has also been reported. Lesions occurring in plaques of psoriasis on the buttocks have been described, and clear cell acanthoma on the nipple has been associated with chronic eczema, suggesting a possible inflammatory etiology.

The acanthotic epidermis consists of pale, edematous cells and is sharply demarcated. The basal cell layer is normal. Neutrophils are scattered within the acanthoma and in groups below and within the stratum corneum, a finding similar to the micropustules of psoriasis. The dermal blood vessels are dilated and tortuous, as seen in psoriasis. The clear keratinocytes abound in glycogen, staining positive with periodic acid–Schiff (PAS). Several centers have reported identification of human papillomavirus (HPV) in clear cell acanthomas, making distinction of these lesions from warts difficult. Clear cell acanthoma must be differentiated from eccrine poroma, which appears most frequently on the hair-free part of the foot, and from clear cell hidradenoma, which occurs most often on the head, especially the face and eyelids. Treatment is surgical, with cryotherapy, CO<sub>2</sub> laser, or excision.

**Finch TM, Tan CY:** Clear cell acanthoma developing on a psoriatic plaque: further evidence of an inflammatory aetiology? *Br J Dermatol* 2000; 142:842.

**Kang IJ, et al:** Clear cell acanthoma on the axilla successfully treated with carbon dioxide laser. *Clin Exp Dermatol* 2014; Dec 16. [Epub ahead of print].

**Monari P, et al:** Multiple eruptive clear cell acanthoma. *J Dermatol Case Rep* 2010; 4(2):25–27.

**Nazzaro G, et al:** A 26-year-old man with an eczematous lesion on the nipple. *Arch Dermatol* 2012; 148(5):641–646.

**Shirai A, et al:** Multiple clear cell acanthoma associated with multiple Bowen's disease. *Int J Dermatol* 2014; 53(8):e386–388.

**Tempark T, Shwayder T:** Clear cell acanthoma. *Clin Exp Dermatol* 2012; 37(8):831–837.

## WAXY KERATOSES OF CHILDHOOD (KERINOKERATOSIS PAPULOSA)

Waxy keratoses of childhood is a genodermatosis that is either sporadic or familial. It may be generalized or segmental. Clinically, the lesions are keratotic, flesh-colored papules that affect the trunk and extremities. They appear before age 3 years. Histologically, there is papillomatosis with focal “church-spire” tenting of the epidermis and marked hyperkeratosis. The natural history of this rare disorder is unknown. Clinically and histologically, the lesions must be distinguished from warts.

**Gönül M, et al:** A case of waxy keratoses of childhood. *Dermatology* 2008; 217:143.

**Happle R, et al:** Kerinokeratosis papulosa with a type 2 segmental manifestation. *J Am Acad Dermatol* 2004; 50:S84.

**Mehrabi D, et al:** Waxy keratoses of childhood in a segmental distribution. *Pediatr Dermatol* 2001; 18:415.

## MULTIPLE MINUTE DIGITATE HYPERKERATOSIS

Multiple minute digitate hyperkeratosis (MMDH) is a rare disorder. About half of cases are familial, inherited in an autosomal dominant manner, and the other half are sporadic. This condition has also been called digitate keratoses, disseminated spiked hyperkeratosis, minute aggregate keratosis, and familial disseminated piliform hyperkeratosis. Clinically, hundreds of tiny, asymptomatic digitate keratotic papules appear on the



trunk and proximal extremities. They are not associated with follicular structures. Histologically, each lesion represents a spiked, digitate, or tented area of acanthotic epidermis with overlying orthohyperkeratosis. Similar lesions can be seen after inflammation and radiation therapy. The relationship of the familial/sporadic cases and the postinflammatory condition is unclear. In some adult patients, an underlying malignancy is found.

**Caccetta TP, et al:** Multiple minute digitate hyperkeratosis: a proposed algorithm for the digitate keratoses. *J Am Acad Dermatol* 2012; 67(1):e49–e55.

**Pimentel CL, et al:** Multiple minute digitate hyperkeratosis. *J Eur Acad Dermatol Venerol* 2002; 16:422.

### ACANTHOLYTIC ACANTHOMA, EPIDERMOLYTIC ACANTHOMA, ACANTHOLYTIC DYSKERATOTIC ACANTHOMA

These three acanthomas represent benign, usually solitary, but at times multiple papules that are nondescript and may be mistaken for basal cell carcinoma (BCC), SCC, or HPV infection. Histologic examination shows epidermal hyperplasia with acantholysis resembling pemphigus vulgaris, pemphigus foliaceus, or Hailey-Hailey disease. The condition multiple epidermolytic acanthoma usually occurs in the genital area and histologically resembles Hailey-Hailey disease. This probably represents a localized variant of that condition.

**Hijazi MM, et al:** Multiple localized epidermolytic acanthomas of the vulva associated with vulvar pruritus: a case report. *Am J Dermatopathol* 2014; Jul 21. [Epub ahead of print.]

**Jang BS, et al:** Multiple scrotal epidermolytic acanthomas successfully treated with topical imiquimod. *J Dermatol* 2007; 34:267.

**Kazlouskaya V, et al:** Solitary epidermolytic acanthoma. *J Cutan Pathol* 2013; 40(8):701–707.

**Ko CJ, et al:** Acantholytic dyskeratotic acanthoma: a variant of a benign keratosis. *J Cutan Pathol* 2008; 35:298.

**Minakawa S, et al:** Acantholysis caused repeated hemorrhagic bullae in a case of acantholytic acanthoma. *J Dermatol* 2012; 39(12):1107–1108.

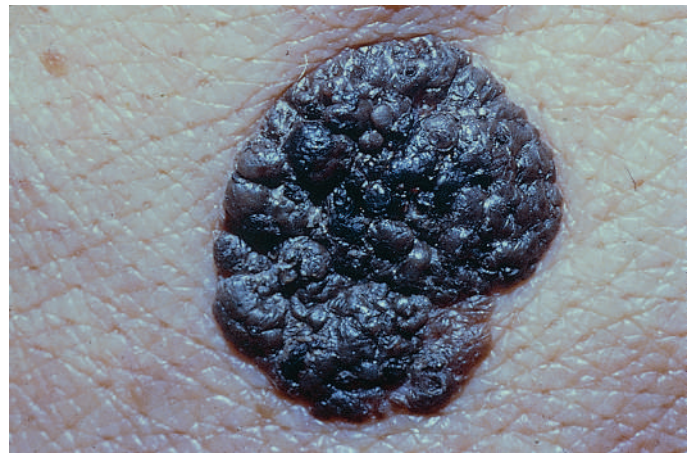
**Sass U, et al:** Acantholytic tumor of the nail: acantholytic dyskeratotic acanthoma. *J Cutan Pathol* 2009; 36:1308.

### WARTY DYSKERATOMA

Warty dyskeratomas are usually solitary and are found on the head and neck (70%), trunk (20%), or extremities. Rare oral lesions occur. The lesion is a brown-red papule or nodule with a soft, yellow, central keratotic plug. Histologically, a cuplike depression filled with a keratotic plug is most common. The epithelium lining the invagination shows the features of Darier's disease, with intraepidermal clefts, acantholytic cells, and pseudovilli. Keratin pearls, corps ronds, and grains may be seen. Cystic lesions with prominent keratinous cysts can occur. Cutaneous lesions appear to originate from a hair follicle. Warty dyskeratoma must be distinguished histologically from keratoacanthoma and acantholytic SCC. Acantholytic acanthoma has a similar histology, but dyskeratosis is absent, distinguishing it from warty dyskeratoma. Treatment is surgical.

**Kaddu S, et al:** Warty dyskeratoma—"follicular dyskeratoma": analysis of clinicopathologic features of a distinctive follicular adnexal neoplasm. *J Am Acad Dermatol* 2002; 47:423.

**Martorell-Calatayud A, et al:** Numerous umbilicated papules on the trunk: multiple warty dyskeratoma. *Am J Dermatopathol* 2012; 34(6):674–675.



**Fig. 29-6** Seborrheic keratosis.

### SEBORRHEIC KERATOSIS

Seborrheic keratoses are incredibly common and usually multiple. They present as oval, slightly raised, tan or light-brown to black, sharply demarcated papules or plaques, rarely more than 3 cm in diameter (Fig. 29-6). They appear "stuck on" the skin, as if they could be removed with the flick of a fingernail. They are located mostly on the chest and back but also frequently involve the scalp, face, neck, and extremities. An inframammary accumulation is common. Occasionally, genital lesions are seen. The palms and soles are spared; "seborrheic keratoses" in these areas are usually eccrine poromas. The surface of the warty lesions often becomes crumbly, resembling a loosely attached crust. When this is removed, a raw, moist base is revealed. Seborrheic keratoses may be associated with itching. Some patients have hundreds of these lesions on the trunk. Although it had been thought that the age of onset is generally in the fourth to fifth decade, in Australia the prevalence of seborrheic keratoses was 20% in males and 25% in females age 15–25. Typical lesions of the trunk are much more common in white persons; however, the "dermatosis papulosa nigra" variant of the central face is common in African Americans and Asians.

The pathogenesis of seborrheic keratoses is unknown. Clinically, they usually originate de novo or appear initially as a lentigo. A sudden eruption of many seborrheic keratoses may follow an exfoliative erythroderma, erythrodermic psoriasis, or an erythrodermic drug eruption. These lesions may be transient. Seborrheic keratoses are more common in areas of sun exposure, including favoring the driver's side in truck drivers. In about one third or more of cases, solar lentigines and seborrheic keratoses both have gain-of-function mutations in *FGFR3* and *PIK3CA*, the genes mutated in keratinocytic epidermal nevi. This supports the concept that some seborrheic keratoses begin as flat lesions that cannot be distinguished from solar lentigines.

Histologically, most seborrheic keratoses demonstrate acanthosis, varying degrees of papillomatosis, hyperkeratosis, and at times, keratin accumulations within the acanthotic epidermis (pseudo-horn cysts). The epidermal cells lack cytologic atypia, except at times in the irritated variant, where typical mitoses may occur. Six histologic types are distinguished: hyperkeratotic, acanthotic, adenoid or reticulated, clonal, irritated, and melanoacanthoma. Poor correlation exists between the clinical appearance and the observed histology, unlike for inverted follicular keratosis, dermatosis papulosa nigra, and stucco keratosis, where the histologic features are characteristic and match the clinical lesion. Melanoacanthoma differs

from regular seborrheic keratosis by the presence of numerous dendritic melanocytes within the acanthotic epidermis. Oral melanoacanthoma, which has also been called melanoacanthosis, is clinically a reactive pigmented lesion seen primarily in young black patients (see Chapter 34). Many cases of inverted follicular keratosis represent irritated seborrheic keratoses. Some view granular parakeratotic acanthomas a variant of irritated seborrheic keratosis, and others see it as a separate entity.

The differential diagnosis usually poses no problems in most cases, but clinically atypical lesions can be a challenge. The most difficult, especially for the nondermatologist, is to differentiate the solitary black seborrheic keratosis from melanoma. The regularly shaped verrucous lesion is often different from the smooth-surfaced and slightly infiltrating pattern of melanoma. Dermoscopy can so metimes be of great value; at other times, however, seborrheic keratoses may demonstrate dermatoscopic features typical of melanocytic lesions, and the presence of horn cysts does not exclude a melanocytic lesion. Actinic keratoses are usually erythematous, more sharply rough, and slightly scaly. The edges are not sharply demarcated, and they occur most often on the face, bald scalp, and backs of the hands. Nevi may be closely simulated. Clonal seborrheic keratoses demonstrate intraepidermal nests suggestive of intraepidermal epithelioma of Jadassohn. Rarely, Bowen's disease, SCC, BCC, trichilemmal carcinoma, or melanoma arises within typical-appearing seborrheic keratosis. Some of these may represent collision lesions, not cancers arising from seborrheic keratoses. It is prudent to biopsy any lesion that appears atypical, since even the most seasoned dermatologist has been humbled by the occasional diagnosis of melanoma in low-suspect lesions.

Seborrheic keratoses are easily removed with liquid nitrogen, curettage, or both, to avoid the need for local anesthesia to perform the curettage. The spray freezes the lesion to make it brittle enough for easy removal with the curette. Scarring is not produced by this method. Light freezing with liquid nitrogen alone is also effective, and most patients prefer it to simple curettage with local anesthesia mainly because of decreased wound care. Light fulguration and shave removal are other acceptable methods. A novel topical agent is in clinical trials.

## SIGN OF LESER-TRÉLAT

The sudden appearance of numerous seborrheic keratoses in an adult may be a cutaneous sign of internal malignancy. Sixty percent of the neoplasms have been adenocarcinomas, primarily of the GI tract. Other common malignancies are lymphoma, breast cancer, and SCC of the lung, but many other types have been reported. To be considered a case of Leser-Trélat, the keratoses should begin at approximately the same time as the development of the cancer, have a rapid onset, and run a parallel course in regard to growth and remission. The lesions are often pruritic, and acanthosis nigricans and tripe palms may accompany the appearance of the seborrheic keratoses of Leser-Trélat.

**Al Ghazal P, et al:** Leser-Trélat sign and breast cancer. *Lancet* 2013; 381(9878):1653.

**Da Rosa AC, et al:** Three simultaneous paraneoplastic manifestations (ichthyosis acquisita, Bazex syndrome, and Leser-Trélat sign) with prostate adenocarcinoma. *J Am Acad Dermatol* 2009; 61:538.

**Gill D, et al:** The prevalence of seborrheic keratoses in people aged 15 to 30 years. *Arch Dermatol* 2000; 136:759.

**Hafner C, et al:** *FGFR3* and *PIK3CA* mutations are involved in the molecular pathogenesis of solar lentigo. *Br J Dermatol* 2009; 160:546.

**Hirata SH, et al:** "Globulelike" dermatoscopic structures in pigmented seborrheic keratosis. *Arch Dermatol* 2004; 140:128.

**Husain Z, et al:** Sign and pseudo-sign of Leser-Trélat: case reports and a review of the literature. *J Drugs Dermatol* 2013; 12(5):e79–e87.

**Kluger N, Guillot B:** Sign of Leser-Trélat with an adenocarcinoma of the prostate: a case report. *Cases J* 2009; 2:8868.

**Levy-Nissenbaum E, et al:** Seborrheic keratosis removal in multi-center phase I/II clinical trial using a novel topical formulation (BL-5010). *Br J Dermatol* 2014; Dec 18 [Epub ahead of print.]

**Lin J, et al:** Evaluation of dermatoscopic algorithm for seborrheic keratosis: a prospective study in 412 patients. *J Eur Acad Dermatol Venereol* 2014; 28(7):957–962.

**Oyama N, Kaneko F:** Trichilemmal carcinoma arising in seborrheic keratosis: a case report and published work review. *J Dermatol* 2008; 35:782.

**Tay YK, Tan SK:** A study comparing the efficacy and risk of adverse events using two techniques of electrocautery for the treatment of seborrheic keratoses. *Dermatol Surg* 2013; 39(5):810–813.

**Tomich CE, et al:** Melanoacanthosis (melanoacanthoma) of the oral mucosa. *J Dermatol Surg Oncol* 1990; 16:231.

**Wood LD, et al:** Effectiveness of cryosurgery vs curettage in the treatment of seborrheic keratoses. *JAMA Dermatol* 2013; 149(1):108–109.

**Zabel RJ, et al:** Malignant melanoma arising in a seborrheic keratosis. *J Am Acad Dermatol* 2000; 42:831.

**Zhang N, et al:** Acanthosis nigricans, tripe palms, and sign of Leser-Trélat in a patient with gastric adenocarcinoma: case report and literature review in China. *Int J Dermatol* 2013; May 15. [Epub ahead of print.]

## DERMATOSIS PAPULOSA NIGRA

Dermatosis papulosa nigra occurs in about 35% of black persons and is also relatively common in Asians. It usually begins in adolescence, appearing first as minute, round, skin-colored or hyperpigmented macules or papules that develop singly or in sparse numbers on the malar regions or on the cheeks below the eyes (Fig. 29-7). It has been described in patients as young as age 3. The lesions increase in number and size over time, so that over the course of years, the patient may have hundreds of lesions. These are distributed over the periorbital regions initially but may occur on the rest of the face as well as the neck and upper chest. Lesions do not spontaneously resolve. They closely simulate seborrheic keratoses. The lesions are asymptomatic and do not develop scaling, crusting, or ulceration.

Microscopically, the chief alterations are in the epidermis. Irregular acanthosis, papillomatosis, and deposits of uncommonly large amounts of pigment throughout the rete, particularly in the basal layer, are characteristic. Many believe this to be a form of seborrheic keratosis. This concept is supported by the finding of *FGFR3* mutations in the lesions of dermatosis

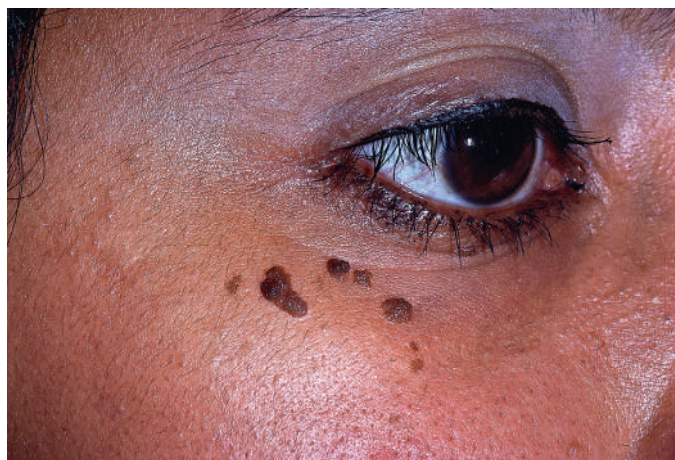


Fig. 29-7 Dermatitis papulosa nigra.



papulosis nigra, similar to those found in seborrheic keratoses.

Treatment is made difficult by the tendency for the development of dyspigmentation. Light curettage with or without anesthesia; light, superficial liquid nitrogen application; and light electrodesiccation are effective but may result in hyperpigmentation or hypopigmentation. KTP, CO<sub>2</sub>, and Nd:YAG lasers have been reported effective but not superior to simple electrodesiccation. Aggressive treatment should be avoided to minimize dyspigmentation and scarring.

## STUCCO KERATOSIS

Stucco keratoses have been described as “stuck on” lesions occurring on the lower legs, especially in the vicinity of the Achilles tendon. They are also seen on the dorsa of the feet, forearms, and dorsal hands. The palms, soles, trunk, and head are never affected. Varying in diameter from 1 to 5 mm, the lesions are loosely attached and thus can easily be scratched off. They vary in number from a few to more than 50. Stucco keratoses are common in the United States and Australia. They occur mostly in men over 40 years old. Histologically, the picture is that of a hyperkeratotic type of seborrheic keratosis, with no hypergranulosis and no wart particles seen on electron microscopy. The presence of *PIK3CA* mutations in stucco keratoses suggests they are a variant of seborrheic keratosis. The treatment, if required, consists of emollients, which soften the skin and cause the scaly lesions to fall off. Ammonium lactate 12% lotion may be effective in improving the appearance of the lesions. Stucco keratoses must be distinguished from Flegel’s disease.

**Babapour R, et al:** Dermatitis papulosa nigra in a young child. *Pediatr Dermatol* 1993; 10:356.

**Bruscino N, et al:** Dermatitis papulosa nigra and 10,600-nm CO<sub>2</sub> laser, a good choice. *J Cosmet Laser Ther* 2014; 16(3):114–116.

**Garcia MS, et al:** Treatment of dermatitis papulosa nigra in 10 patients: a comparison trial of electrodesiccation, pulsed dye laser, and curettage. *Dermatol Surg* 2010; 36(12):1968–1972.

**Hafner C, et al:** *FGFR3* and *PIK3CA* mutations in stucco keratosis and dermatitis papulosa nigra. *Br J Dermatol* 2010; 162(3):508–512.

**Katz TM, et al:** Dermatitis papulosa nigra treatment with fractional photothermolysis. *Dermatol Surg* 2009; 35:1840.

**Kundu RV, et al:** Comparison of electrodesiccation and potassium-titanyl-phosphate laser for treatment of dermatitis papulosa nigra. *Dermatol Surg* 2009; 35:1079.

**Schweiger ES, et al:** Treatment of dermatitis papulosa nigra with a 1064 nm Nd:YAG laser: report of two cases. *J Cosmet Laser Ther* 2008; 10:120.

**Taylor SC, et al:** Postprocedural wound-healing efficacy following removal of dermatitis papulosa nigra lesions in an African American population: a comparison of a skin protectant ointment and a topical antibiotic. *J Am Acad Dermatol* 2011; 64(3 Suppl):S30–S35.

## HYPERKERATOSIS LENTICULARIS PERSTANS (FLEGEL’S DISEASE)

Rough, yellow-brown, keratotic, flat-topped papules 2–5 mm in diameter and found primarily on the dorsal feet and lower legs are characteristic. The palms, soles, and oral mucosa may rarely be involved. Familial cases have been reported.

The histologic findings are distinctive, with hyperkeratosis and parakeratosis overlying a thinned epidermis and irregular acanthosis at the periphery. A bandlike inflammatory infiltrate occurs in the papillary dermis. Topical emollients, topical keratolytics, topical corticosteroids, zinc bandages, topical 5-FU, and psoralen plus ultraviolet A (PUVA) therapy have been reported useful. Oral retinoids may result in improvement but

are difficult to justify in this chronic, asymptomatic condition except in rare severe cases. Both benefit and failure with topical vitamin D analogs have been reported. The lesions do not recur after shallow shave excision.

**Bayramgurler D, et al:** Flegel’s disease: treatment with topical calcipotriol. *Clin Exp Dermatol* 2002; 27:161.

**Cooper SM, George S:** Flegel’s disease treated with psoralen ultraviolet A. *Br J Dermatol* 2000; 142:340.

**Krishnan A, Kar S:** Hyperkeratosis lenticularis perstans (Flegel’s disease) with unusual clinical presentation: response to isotretinoin therapy (photoletter to the editor). *J Dermatol Case Rep* 2012; 6(3):93–95.

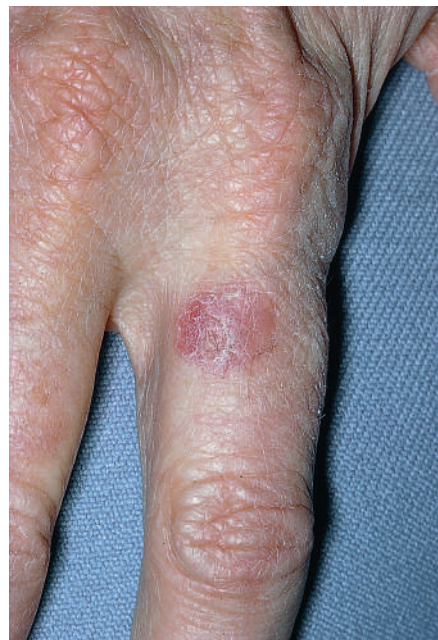**Patel KB:** Hyperkeratosis lenticularis perstans: case report of a rare entity. *Indian J Dermatol* 2013; 58(2):161.

**Sterneberg-Vos H, et al:** Hyperkeratosis lenticularis perstans (Flegel’s disease)—successful treatment with topical corticosteroids. *Int J Dermatol* 2008; 47:38.

## BENIGN LICHENOID KERATOSES (LICHEN PLANUS–LIKE KERATOSIS)

Benign lichenoid keratoses are usually solitary, dusky-red to violaceous, papular lesions up to 1 cm in diameter and at times larger (Fig. 29-8). They occur most often on the distal forearms, hands, or chest of middle-age white women. The lesions are typically biopsied because the clinical features are identical to those of a superficial BCC. A slight violaceous hue or the presence of an adjacent solar lentigo can raise the suspicion of lichen planus–like keratosis. Multiple lesions may simulate a photodermatitis, such as lupus erythematosus (LE). Evolution from preexisting solar lentigines is often noted histologically or by history, and the presence of the same underlying genetic mutations (*FGFR3*, *PIK3CA*, and *RAS*) supports this concept.

Histologically, the lesion may be indistinguishable from idiopathic lichen planus. Whereas idiopathic lichen planus rarely demonstrates parakeratosis, plasma cells, or eosinophils, these may be present in lichen planus–like keratosis. The remnants of a solar lentigo may be seen at the periphery. These features, plus the clinical information that this represents a solitary lesion, suggest the correct diagnosis. Clinical correlation is essential because similar histologic findings may



**Fig. 29-8** Lichen planus–like keratosis.

be seen in lichenoid drug eruptions, acral LE, and lichenoid regression of melanoma. Direct immunofluorescence is positive, with clumped deposits of IgM in a lichen planus-like pattern at the dermoepidermal junction (DEJ). This differs from the continuous granular immunoglobulin deposition of acral LE. Cryotherapy with liquid nitrogen is effective.

**Abdulla FR, Mutasim DF:** Multiple benign lichenoid keratoses. *J Am Acad Dermatol* 2010; 62(5):900–901.

**Groesser L, et al:** *FGFR3*, *PIK3CA* and *RAS* mutations in benign lichenoid keratosis. *Br J Dermatol* 2012; 166(4):784–788.

**Jang K, et al:** Lichenoid keratosis: a clinicopathologic study of 17 patients. *J Am Acad Dermatol* 2000; 43:511.

**Kim HS, et al:** Clinical and histopathologic study of benign lichenoid keratosis on the face. *Am J Dermatopathol* 2013; 35(7):738–741.

## ARSENICAL KERATOSES

Arsenical keratoses are keratotic, pointed, 2–4 mm, wartlike lesions on the palms, soles, and sometimes ears of persons who have a history of drinking contaminated well water or taking medications containing arsenic trioxide, usually for asthma (e.g., Fowler’s solution, Bell’s Asthma Mixture), atopic dermatitis, or psoriasis, often years previously (Fig. 29-9). These lesions resemble palmar pits but may have a central hyperkeratosis. When the keratosis is picked off with the fingernails, a small, dell-like depression is seen.

Bowen’s disease and invasive arsenical SCC may be present, with the latent period being 10 and 20 years, respectively. The profound increase in Bowen’s disease and SCC appears to be characteristic of patients with arsenic exposure from well water. In patients exposed to arsenic through elixirs, BCCs are more characteristically seen. The latency period for development of BCC is also 20 years. Lesions are most common on the scalp and trunk. Arsenical keratoses may be a marker for increased lung and urothelial carcinoma.

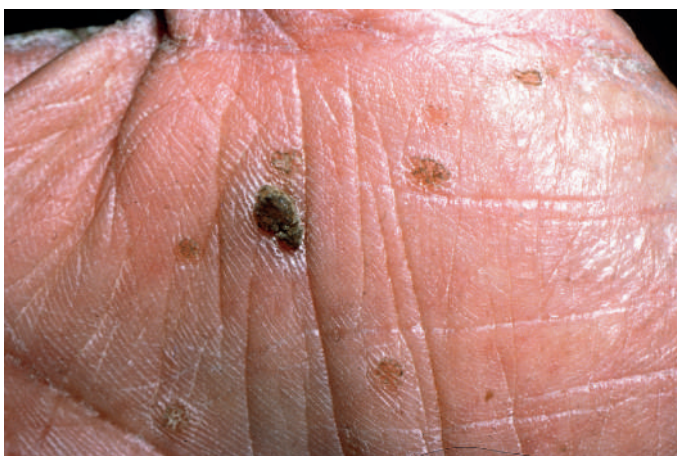
**Boonchai W, et al:** Basal cell carcinoma in chronic arsenicism occurring in Queensland, Australia, after ingestion of an asthma medication. *J Am Acad Dermatol* 2000; 43:664.

**Elmariah SB, et al:** Invasive squamous-cell carcinoma and arsenical keratoses. *Dermatol Online J* 2008; 14:24.

**Hsu LI, et al:** Use of arsenic-induced palmoplantar hyperkeratosis and skin cancers to predict risk of subsequent internal malignancy. *Am J Epidemiol* 2013; 177(3):202–212.

**Khandpur S, et al:** Chronic arsenic toxicity from Ayurvedic medicines. *Int J Dermatol* 2008; 47:618.

**Ruiz de Luzuriaga AM, et al:** Arsenical keratoses in Bangladesh: update and prevention strategies. *Dermatol Clin* 2011; 29(1):45–51.

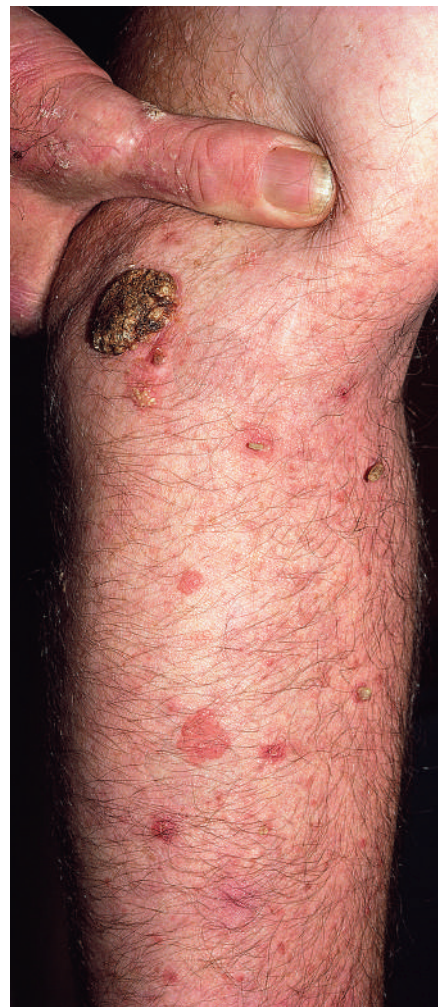

**Fig. 29-9** Arsenical keratosis of the palm.

**Son SB, et al:** Successful treatment of palmoplantar arsenical keratosis with a combination of keratolytics and low-dose acitretin. *Clin Exp Dermatol* 2008; 33:202.

## NONMELANOMA SKIN CANCERS AND THEIR PRECURSORS

More nonmelanoma skin cancers (NMSCs) are diagnosed annually in the United States than all other cancers combined. In 2006, more than 3.5 million new NMSC cases were estimated to occur, and the incidence is rising. One in two men and one in three women in the United States will develop NMSC in their lifetime, usually after age 55. Although these result in only about 2000–2500 deaths annually, because of their sheer numbers, NMSCs represent about 5% of all Medicare cancer expenditures. Those at risk for skin cancer are fair-skinned individuals who tan poorly and who have had significant chronic or intermittent sun exposure. Red hair phenotype with loss-of-function mutations in the melanocortin-1 receptor may be a risk factor as well. Additional risk factors include a history of skin cancer, prior radiation therapy, PUVA treatment, arsenic exposure, and systemic immunosuppression (Fig. 29-10). Once an individual has developed an NMSC, the risk for a second is increased 10-fold. Over the 3-year period following the initial NMSC diagnosis, more than 40% of BCC and SCC patients develop a BCC, and 18% of SCC patients develop another SCC. By 5 years, as many as 50% of women and 70% of men will develop a second NMSC. The



**Fig. 29-10** Actinic keratosis/Bowen’s disease in transplant recipient.



rate of developing NMSCs is no different 3 years or 10 years after the initial NMSC diagnosis. Patients with a history of NMSC should be examined regularly for NMSCs.

Ultraviolet radiation (UVR) is the major cause of nongenital NMSCs and actinic keratoses. The effect of UVR appears to be mediated through mutation of the *p53* gene, which is found mutated in a substantial percentage of NMSCs and actinic keratoses. Most skin cancers are highly immunogenic, but the immune response is suppressed by continued actinic exposure. Both chronic sun exposure and intermittent intense exposure are risk factors for the development of NMSCs. It is believed that avoiding sun exposure reduces the risk for NMSC. The use of sunscreens in the prevention of NMSCs has been controversial; they may inadvertently lead to prolonged intentional sun exposure, negating their possible beneficial effect. Nonetheless, dermatologists and their societies recommend a program of sunscreen use together with sun avoidance to patients at risk for skin cancer. This includes avoiding midday sun, seeking shade, wearing protective clothing, and regularly applying a sunblock of sun protection factor (SPF) 15–30 with both UVB and UVA coverage. This program was pioneered in Australia and has led to improvements in some skin cancer rates there.

**Centers for Disease Control and Prevention:** Preventing skin cancer: findings of the task force on community preventive services on reducing exposure to ultraviolet light. *Arch Dermatol* 2004; 140:251.

**Chuang T, Brashear R:** Risk factors of non-melanoma skin cancer in United States veteran patients: a pilot study and review of literature. *J Eur Acad Dermatol Venerol* 1999; 12:126.

**Czarnecki C, Czarnecki D:** Patients who have multiple skin cancers develop new skin cancers at a constant rate. *Arch Dermatol* 2002; 138:125.

**Dieppen TL, Mahler V:** The epidemiology of skin cancer. *Br J Dermatol* 2002; 146:1.

**Lewis KG, Weinstock MA:** Nonmelanoma skin cancer mortality (1988–2000). *Arch Dermatol* 2004; 140:837.

**Marcil I, Stern RS:** Risk of developing a subsequent nonmelanoma skin cancer in patients with a history of nonmelanoma skin cancer. *Arch Dermatol* 2000; 136:1524.

**Olsen, CM, et al:** Turning the tide? Changes in treatment rates for keratinocytic cancers in Australia 2000 through 2011. *J Am Acad Dermatol* 2014; 71:21–26.e1.

**Rogers, HW, et al:** Incidence estimate of nonmelanoma skin cancer in the United States, 2006. *Arch Dermatol* 2010; 146:283–287.

**Schaffer JV, Bolognia JL:** The melanocortin-1 receptor: red hair and beyond. *Arch Dermatol* 2001; 137:1477.

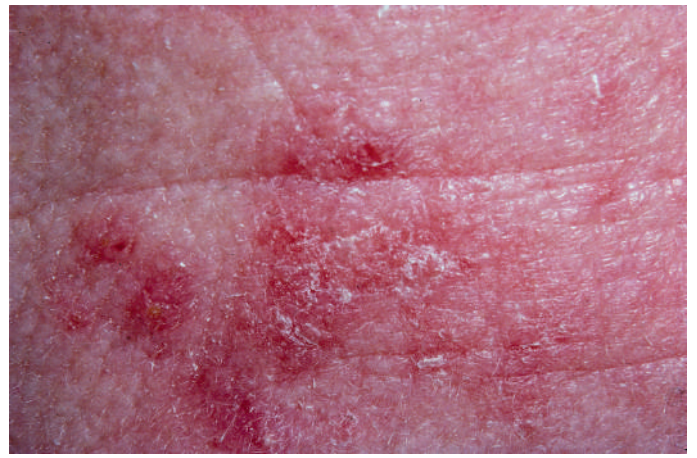
**Siegel, R, et al:** Cancer statistics, 2014. *CA Cancer J Clin* 2014; 64:9–29.

**Wegner MR, et al:** Timing of subsequent new tumors in patients who present with basal cell carcinoma or cutaneous squamous cell carcinoma. *JAMA Dermatol* 2015; Jan 14 [Epub ahead of print.]

**Wysong, A, et al:** Nonmelanoma skin cancer visits and procedure patterns in a nationally representative sample: National Ambulatory Medical Care Survey 1995–2007. *Dermatol Surg* 2013; 39:596–602.

## ACTINIC KERATOSIS (SOLAR KERATOSIS)

Actinic keratoses represent in situ dysplasias resulting from sun exposure. They are found chiefly on the chronically sun-exposed surfaces of the face (Fig. 29-11), ears, balding scalp, dorsal hands, and forearms. They are usually multiple, discrete, flat or elevated, verrucous or keratotic, red, pigmented, or skin colored. Usually, the surface is covered by an adherent scale, but sometimes it is smooth and shiny. On palpation, the surface is rough, like sandpaper, and at times lesions are more easily felt than seen. The patient may complain of tenderness when the lesion is rubbed or shaved over with a razor. The lesions are usually relatively small, measuring 3 mm to 1 cm in diameter, most being less than 6 mm. Rarely, lesions may reach 2 cm in size, but a lesion larger than 6 mm should be



**Fig. 29-11** Actinic keratosis.

considered an actinic keratosis only if confirmed by biopsy or if it completely resolves with therapy. The hypertrophic type, which may lead to cutaneous horn formation, is most frequently present on the dorsal forearms and hands.

Actinic keratoses are the most common epithelial precancerous lesions. Although lesions typically appear in persons over age 50, actinic keratoses may occur in the twenties or thirties in patients who live in areas of high solar irradiation and have fair skin. Patients with actinic keratoses have a propensity for the development of nonmelanoma cutaneous malignancies. Actinic keratoses can be prevented by the regular application of sunscreen and by a low-fat diet. Beta carotene is of no benefit in preventing actinic keratoses.

Six types of actinic keratosis can be recognized histologically: hypertrophic, atrophic, bowenoid, acantholytic, pigmented, and lichenoid. The epidermis may be acanthotic or atrophic. Keratinocyte maturation may be disordered, with overlying parakeratosis sometimes present. The basal cells are most frequently dysplastic, although in more advanced lesions, dysplasia may be seen throughout the epidermis, simulating Bowen's disease (bowenoid actinic keratosis).

The clinical diagnosis of actinic keratosis is usually straightforward. Early lesions of chronic cutaneous LE, erosive and pustular dermatosis of the scalp, and pemphigus foliaceus are sometimes confused with actinic keratoses. Seborrheic keratoses, even when lacking pigmentation, are usually more "stuck on" in appearance and more sharply marginated than actinic keratoses. Dermoscopy may aid in this distinction. It is difficult to distinguish hypertrophic actinic keratoses from early SCC, and a low threshold for biopsy is recommended. Similarly, actinic keratoses, which present as red patches, cannot easily be distinguished from Bowen's disease or superficial BCC. If there is a palpable dermal component, or if on stretching the lesion there is a pearly quality, a biopsy should be considered. Any lesion larger than 6 mm, and any lesion that has failed to resolve with appropriate therapy for actinic keratosis, should also be carefully evaluated for biopsy.

Since some percentage of actinic keratoses will progress to NMSC, their treatment is indicated. There are many effective therapeutic modalities. Cryotherapy with liquid nitrogen is most effective and practical when there are a limited number of lesions. A bulky cotton applicator dipped into liquid nitrogen or a handheld nitrogen spray device can be used. If the cotton-tipped applicator method is used, the liquid nitrogen into which the applicator is dipped should be used for only one patient, because there is a theoretic risk of cross-contamination from one patient to another. Infectious agents are not killed by freezing, so many dermatologists now use the spray devices. We recommend using a small-opening tip with

continuous bursts of nitrogen spray in a circular motion, depending on the size of the lesion, attempting an even frosting. Only the lesion should be frosted, and the duration of cryotherapy must be carefully controlled. A long freeze that results in significant epidermal-dermal injury produces white scars, which are easily seen on the fair skin of those at risk for actinic keratoses. When correctly performed, healing usually occurs within 1 week on the face, but may require up to 4 weeks on the arms and legs. Caution should be exercised when treating below the knee, because wound healing in these regions is particularly poor, and a chronic ulcer can result. Also, caution is required in persons at risk for having a cryoprotein, such as hepatitis C virus-infected patients and those with connective tissue disease or lymphoid neoplasia, who may have an excessive reaction to cryotherapy. It is better on the first visit to “undertreat” until the tolerance of a patient’s skin to cryotherapy is known. Application of 0.5% 5-FU for 1 week before cryotherapy improves the response.

For extensive, broad, or numerous lesions, topical chemotherapy is recommended. Any lesion that could represent an NMSC should be biopsied before beginning topical chemotherapy for actinic keratoses. Self-treatment with 5-FU without a physician’s supervision should be discouraged. The diagnosis of NMSC may be delayed by ineffective topical chemotherapy. The two agents most frequently used are 5-FU cream, 0.5–5%, or imiquimod 5% cream. Topical tretinoin and adapalene do not have the efficacy of these two agents but can be used for prolonged periods and represent an option for patients with a few early lesions. Also, 3% diclofenac in 2.5% hyaluronan gel can be effective when used for 60 days for actinic keratoses. Topical resiquimod and ingenol mebutate are newer and less frequently used topical therapeutic options.

The frequency and duration of treatment are determined by the individual’s reaction and the anatomic site of application. 5-FU is applied once daily in most cases. For the face, 0.5% 5-FU tends to give a predictable response, which is slightly less severe than that produced by the 1–5% concentrations. Some patients prefer the stronger concentration for a briefer period, while others favor a slower onset of the reaction and a more prolonged course. For the 5% cream, treatment duration rarely needs to exceed 2–3 weeks. For the 0.5% cream, the treatment course is typically 3–6 weeks. Usually, the central face will respond more briskly than the temples and forehead, which may require a longer duration of treatment. If the reaction is brisk, the treatment can be stopped and restarted at a lower concentration. Depending on the individual’s sensitivity, an erythematous burning reaction will occur within several days. Treatment is stopped when a peak response occurs, characterized by a change in color from bright to dusky red, reepithelialization, and crust formation. Healing usually occurs within another 2 weeks of stopping treatment, depending on the treatment site. Certain areas of the face are prone to intense irritant dermatitis when exposed to 5-FU, and tolerance can be improved if the patient avoids application to the glabella, melolabial folds, and chin. For the scalp, the 0.5% concentration may be adequate, but prolonged or multiple treatment courses often are required if this low concentration is used. The 5% cream produces a more predictable, although brisk, reaction. A thick cutaneous horn can prevent penetration of 5-FU, and hypertrophic actinic keratoses on the scalp, dorsal hand, and forearm may respond poorly unless the area is pretreated with an agent to remove excessive keratin overlying the lesions. Pretreatment with tretinoin for 2–3 weeks can improve efficacy and shorten the duration of subsequent 5-FU treatment. It has been observed that 5-FU “seeks out” lesions that may not be clinically apparent. The use of topical 5-FU to the face can also reverse photoaging. Clinically inapparent BCCs may be detected during or on completion of the

treatment. Rarely, patients who have had multiple courses of 5-FU topical chemotherapy will develop a true allergic contact dermatitis to the 5-FU. This is manifested by the redness, edema, or vesiculation extending beyond the area of application and by the patient developing pruritus rather than tenderness of the treated areas. Patch testing can be confirmatory.

Imiquimod is an interferon (IFN) inducer and eradicates actinic keratoses by producing a local immunologic reaction against the lesions. The ideal protocol for application of imiquimod may not yet be determined. About 80% of patients respond to imiquimod, and 20% may not respond at all, perhaps because that they lack some genetic component required to induce an inflammatory cascade when imiquimod is applied. If it is applied three times a week, patients develop an inflammatory reaction similar to that seen with daily application of 5-FU. The severity of the reaction is somewhat unpredictable, with a small subset of patients, especially fair-skinned women, developing a severe burning and crusting reaction after only one or a few applications. In others, no reaction at all occurs. With twice-weekly application, the treatment course is prolonged, up to 16 weeks. Severe erythema occurs in 17.7% and scabbing/crusting in 8.4% of patients so treated. The median percentage reduction in actinic keratoses is 83.3% with this treatment protocol. However, only 7% of patients treating actinic keratoses on the arms and hands with imiquimod three times per week achieved complete clearance. Applying it more frequently leads to increased toxicity. Overall, although the reaction is less predictable with imiquimod, it is also typically less severe than with high-concentration 5-FU. The adverse event rates are similar to those with low-concentration (0.5%) 5-FU. Another regimen is to apply imiquimod for long periods at a reduced frequency, once or twice weekly. Applications can be in alternating 1-month cycles or continuous for many months. This may allow management of some patients who require treatment but cannot tolerate any significant changes in appearance. Ultimately, the choice between topical 5-FU and imiquimod will be based on patient preference, prior physician and patient experience with the modalities, and the cost. Imiquimod is significantly more expensive per gram than any form of 5-FU. A meta-analysis comparing efficacy studies of the two agents dosed in various concentrations and regimens suggested imiquimod may have higher efficacy for actinic keratosis on the face and scalp. A recent Cochrane review concluded that 5-FU, imiquimod, ingenol mebutate, and diclofenac are similarly efficacious but have different adverse events and cosmetic outcomes. Direct comparative trials between these agents would be of great value in determining the optimal and most cost-effective strategy for the treatment of extensive actinic keratoses.

Surgical management of actinic keratoses with chemical peels, laser resurfacing, and photodynamic therapy is discussed in Chapters 37 and 38.

**Anderson L, et al:** Randomized, double-blind, double-dummy, vehicle-controlled study of ingenol mebutate gel 0.025% and 0.05% for actinic keratosis. *J Am Acad Dermatol* 2009; 60:934.

**Askew DA, et al:** Effectiveness of 5-fluorouracil treatment for actinic keratosis—a systematic review of randomized controlled trials. *Int J Dermatol* 2009; 48:453.

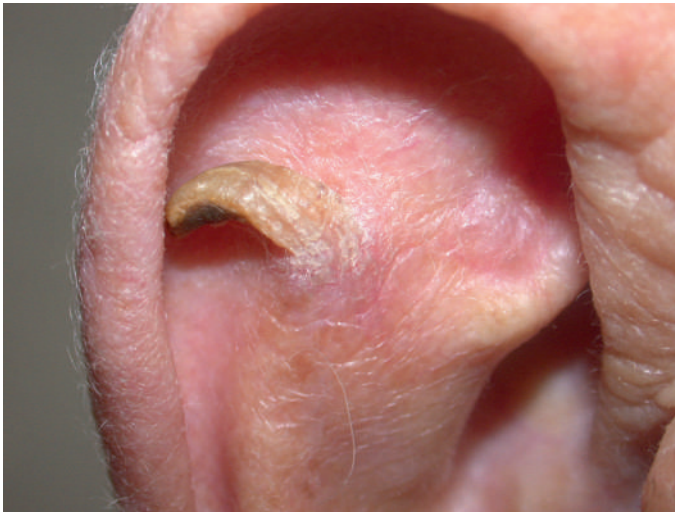**Bagatin E, et al:** 5-Fluorouracil superficial peel for multiple actinic keratoses. *Int J Dermatol* 2009; 48:902.

**Gupta AK, et al:** Evaluation of the effectiveness of imiquimod and 5-fluorouracil for the treatment of actinic keratosis: critical review and meta-analysis of efficacy studies. *J Cutan Med Surg* 2005; 9:209–214.

**Gupta AK, et al:** Interventions for actinic keratoses. *Cochrane Database Syst Rev* 2012; 12:CD004415.

**Hanke CW, et al:** Imiquimod 2.5% and 3.75% for the treatment of actinic keratoses: results of two placebo-controlled studies of daily application to the face and balding scalp for two 3-week cycles. *J Am Acad Dermatol* 2010; 62(4):573–581.





**Fig. 29-12** Cutaneous horn of the ear.

**Hughes MC, et al:** Food intake, dietary patterns, and actinic keratoses of the skin: a longitudinal study. *Am J Clin Nutr* 2009; 89:1246.

**Kose O, et al:** Comparison of the efficacy and tolerability of 3% diclofenac sodium gel and 5% imiquimod cream in the treatment of actinic keratosis. *J Dermatolog Treat* 2008; 19:159.

**Lebwohl M, et al:** Ingenol mebutate gel for actinic keratosis. *N Engl J Med* 2012; 366(11):1010–1019.

**Micali G, et al:** Topical pharmacotherapy for skin cancer. Part II. Clinical applications. *J Am Acad Dermatol* 2014; 70(6):979.e1–e12; quiz 9912.

**Park MY, et al:** Photorejuvenation induced by 5-aminolevulinic acid photodynamic therapy in patients with actinic keratosis: a histologic analysis. *J Am Acad Dermatol* 2010; 62:85.

**Philipp-Dormston WG:** Field cancerization: from molecular basis to selective field-directed management of actinic keratosis. *Curr Probl Dermatol* 2015; 46:115–121.

**Sotiriou E, et al:** Intra-individual, right-left comparison of topical 5-aminolevulinic acid photodynamic therapy vs. 5% imiquimod cream for actinic keratoses on the upper extremities. *J Eur Acad Dermatol Venereol* 2009; 23:1061.

**Szeimies RM, et al:** Long-term follow-up of photodynamic therapy with a self-adhesive 5-aminolaevulinic acid patch: 12 months data. *Br J Dermatol* 2010; 162(2):410–414.

**Vaccaro M, et al:** Erosive pustular dermatosis of the scalp following treatment with topical imiquimod for actinic keratosis. *Arch Dermatol* 2009; 145:1340.

## CUTANEOUS HORN (CORNU CUTANEUM)

Cutaneous horns are encountered most frequently on the dorsal hands and scalp. Lesions may also occur on the hands, penis (Fig. 29-12), and eyelids. They are skin-colored, horny excrescences 2–60 mm long, sometimes divided into several antlerlike projections.

These lesions are most often benign, with the hyperkeratosis being superimposed on an underlying seborrheic keratosis, verruca vulgaris, angiokeratoma, molluscum contagiosum, or trichilemmoma in about 60% of cases. However, 20–30% may overlie premalignant keratosis, and 20% may overlie SCCs or BCCs. The risk for a cutaneous horn overlying a malignancy is much higher in fair-complexioned elderly persons. Hyperkeratotic actinic plaques less than 1 cm in diameter on the dorsum of the hand, wrist, or forearms in white patients have been shown to have a malignancy rate of 50%. One third of penile horns are associated with underlying malignancies. Excisional biopsy with histologic examination of the base is necessary to determine the best therapy, which would be dictated by the diagnosis of the underlying lesion and by the apparent adequacy of removal.

**Mantese SA, et al:** Cutaneous horn: a retrospective histopathological study of 222 cases. *An Bras Dermatol* 2010; 85(2):157–163.

**Sullivan GA, et al:** Cutaneous horn of the penis: its association with squamous cell carcinoma and HPV-16 infection. *J Am Acad Dermatol* 1990; 23:269.

**Yu RC, et al:** A histopathological study of 643 cutaneous horns. *Br J Dermatol* 1991; 124:449.

## KERATOACANTHOMA

### Clinical features

There are four types of keratoacanthoma: solitary, multiple, eruptive, and keratoacanthoma centrifugum marginatum. The exact biologic behavior of keratoacanthoma remains controversial. In the past, it had been considered a reactive condition or pseudomalignancy that could be treated expectantly. Now, the favored view is that keratoacanthomas are low-grade SCCs, which in many cases will regress. The regression may be partially mediated by immunity but takes the form of terminal differentiation. The course of these tumors is unpredictable. Even those that ultimately involute can cause considerable destruction before they regress. Any lesions that have the histologic features of keratoacanthoma and appear in an immunosuppressed host should be managed as an SCC, with complete eradication.

Sunlight appears to play an important role in the etiology, especially in the solitary types, with light-skinned persons being predominantly affected. Cases of keratoacanthoma after trauma, hypertrophic lichen planus, discoid LE, tattoos, fractional thermolysis, and imiquimod erosions, and along the distal ends of surgical excisions, suggest that an isomorphic phenomenon is common. The keratoacanthomas appear about 1 month after the traumatic injury. All these associated conditions result in damage to the dermis, especially along the DEJ, and necessitate wound healing. The biologic behavior of these lesions is unknown, but they have added to the controversy of keratoacanthoma as a reactive versus a malignant process. Eruptive keratoacanthomas and SCCs have appeared during treatment for metastatic melanoma with the *BRAF* inhibitor vemurafenib. In Muir-Torre syndrome, sebaceous tumors and keratoacanthomas occur in association with multiple internal malignancies. A second, less common cancer scenario is the keratoacanthoma–visceral carcinoma syndrome (KAVCS); only a handful of cases have been reported. Patients have multiple or large keratoacanthomas that appear at the same time as an internal malignancy, always of the genitourinary tract. The relationship of Muir-Torre syndrome to KAVCS awaits identification of the genetic basis of both syndromes.

### Solitary keratoacanthoma

The solitary keratoacanthoma is a rapidly growing papule that enlarges from a 1-mm macule or papule to as large as 25 mm in 3–8 weeks. When fully developed, it is a hemispheric, dome-shaped, skin-colored nodule that has a smooth crater filled with a central keratin plug (Fig. 29-13). The smooth shiny lesion is sharply demarcated from its surroundings. Telangiectases may run through the lesion. Subungual keratoacanthomas are tender subungual tumors that usually cause significant nail dystrophy. Subungual lesions often do not regress spontaneously and induce early underlying bony destruction, characterized on radiograph as a crescent-shaped lytic defect without accompanying sclerosis or periosteal reaction.

The solitary keratoacanthoma occurs mostly on sun-exposed skin, with the central portion of the face, backs of the hands,

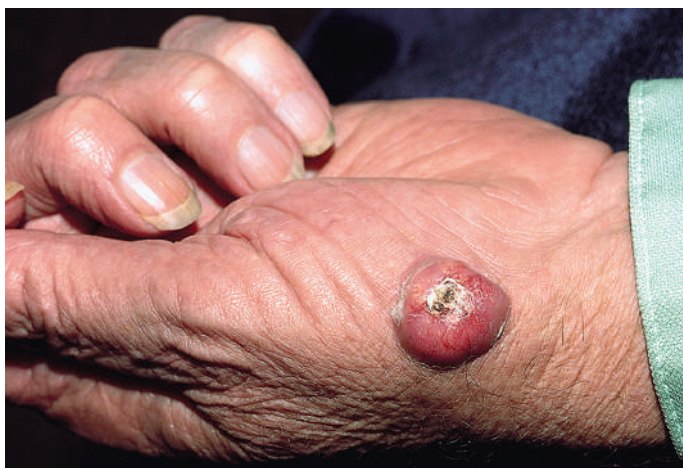

Fig. 29-13 Keratoacanthoma.

and arms most often involved. Less frequently, other sites are involved, such as the buttocks, thighs, penis, ears, and scalp. Elderly fair-skinned individuals most frequently develop keratoacanthomas. Lesions of the dorsal hands are more common in men, and keratoacanthomas of the lower legs are more common in women. The most interesting feature of this disease is the rapid growth for 2–6 weeks, followed by a stationary period for another 2–6 weeks, and finally a spontaneous involution over another 2–6 weeks, leaving a slightly depressed scar. The stationary period and involuting phase are variable; some lesions may take 6 months to 1 year to resolve completely. An estimated 5% of treated lesions recur. Invasion along nerve trunks has been documented and may result in recurrence after a seemingly adequate excision.

### Histopathology

The histologic findings of keratoacanthoma and a low-grade SCC are so similar that it is frequently difficult to make a definite diagnosis on the histologic findings alone. When a properly sectioned specimen is examined under low magnification, the center of the lesion shows a crater filled with eosinophilic keratin. Over the sides of the crater, which seems to have been formed by invagination of the epidermis, a “lip” or “marginal buttress” of epithelium extends over the keratin-filled crater. At the base and sides of the crater, the epithelium is acanthotic and composed of keratinocytes, which are highly keratinized and have an eosinophilic, glassy cytoplasm. Surrounding the keratinocyte proliferation, a dense inflammatory infiltrate is frequently seen. Neutrophilic microabscesses are common within the tumor, and trapping of elastic fibers is often identified at the periphery of the tumor. These features favor a diagnosis of keratoacanthoma. The most definitive histologic feature is evidence of terminal differentiation, where the scalloped outer border of the tumor has lost its infiltrative character and is reduced to a thin rim of keratinizing cells lining a large, keratin-filled crater. The presence of acantholysis within the tumor is incompatible with a diagnosis of keratoacanthoma. It is also important to distinguish keratoacanthoma from marked pseudoepitheliomatous hyperplasia, as seen in prurigo nodularis. Unfortunately, histology does not completely correlate with biologic behavior. The diagnosis of benign-behaving keratoacanthoma versus a potentially aggressive SCC may not always be possible. Even if the classic histologic features of keratoacanthoma are seen, the diagnosis of SCC should be considered if the lesion does not behave as expected.

### Treatment

Although keratoacanthomas spontaneously involute, it is impossible to predict how long this will take. The patient may be faced with destructive growth of a tumor for as long as 1 year. More importantly, SCC cannot always be excluded clinically. Therefore, excisional biopsy of the typical keratoacanthoma of less than 2 cm in diameter should be considered in most cases. If the history is characteristic, or multiple lesions have appeared simultaneously, less aggressive interventions may be considered. Nonsurgical therapy may also be considered in certain sites to preserve function or improve cosmetic outcome.

Intralesional injections of 5-FU solution, 50 mg/mL (undiluted from ampule) at weekly intervals; bleomycin, 0.5 mg/mL; or methotrexate, 25 mg/mL, can be effective. For a typical lesion, four injections along the base at each pole are recommended. Low-dose systemic methotrexate can be considered if multiple lesions are present and there is no contraindication. For clinically typical lesions, these modalities may be tried before resorting to surgical removal, especially if the latter presents any problem. Excision is recommended if there is not at least 50% involution of the lesion after 3 weeks. Radiation therapy may also be used on giant keratoacanthomas when surgical excision or electrosurgical methods are not feasible.

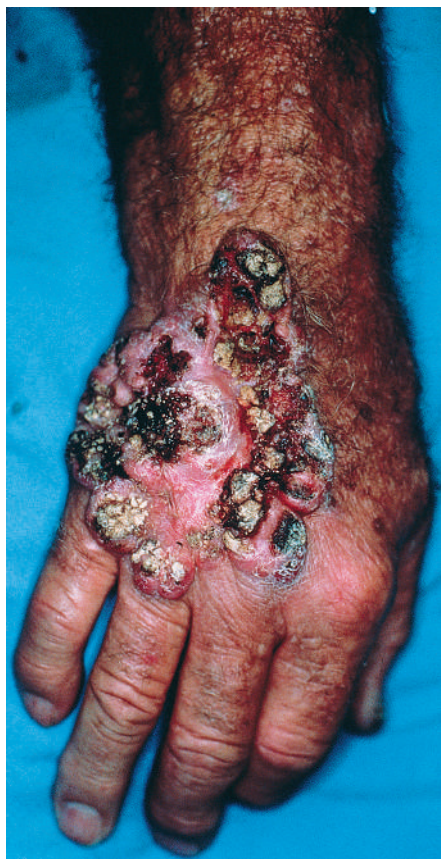### Multiple keratoacanthomas (Ferguson Smith type)

This type of keratoacanthoma is frequently referred to as the Ferguson Smith type of multiple self-healing keratoacanthoma. These lesions are identical clinically and histologically to the solitary type. There is frequently a family history of similar lesions. The condition has been traced to two large Scottish kindreds. Affected families from other countries have also been reported. Beginning on average at about age 25, but possibly as early as the second decade, patients develop crops of keratoacanthomas that begin as small red macules and rapidly become papules that evolve to typical keratoacanthomas. Lesions may number from a few to hundreds, but generally only 3–10 lesions are noted at any one time. Sun-exposed sites are favored, especially the ears and nose, and in most cases scalp lesions occur. In addition, these patients typically develop keratoacanthomas at sites of trauma, often at the ends of surgical excisions. Lesions grow over 2–4 weeks, reaching a size of 2–3 cm, then remain stable for 1–2 months before slowly involuting. They leave a prominent crateriform scar. If the early lesions are aggressively treated with cryotherapy, shave removal, or curettage, the scar may be less marked than that induced by spontaneous involution. Treatment with an oral retinoid can be effective in stopping the appearance of new lesions and causing involution of existing ones.

### Generalized eruptive keratoacanthomas (Grzybowski variant)

The generalized eruptive keratoacanthoma is very rare and sporadic, with most patients having no affected family members. The usual age of onset is between 40 and 60. The patients are usually in good health and are not immunosuppressed. The cause of this condition is unknown. HPV has not been detected in most patients in whom it was sought. The clinical features are characteristic and unique. The Grzybowski type of multiple keratoacanthoma is characterized by a generalized eruption of numerous dome-shaped, skin-colored papules 2–7 mm in diameter. Multiple larger typical keratoacanthomas may also appear. Thousands of lesions may develop.





**Fig. 29-14**  
Keratoacanthoma centrifugum marginatum.

The eruption is usually generalized, but spares the palms and soles. The oral mucous membranes and larynx can be involved. Severe pruritus may be a feature. Clinically, pityriasis rubra pilaris or widespread lichen planopilaris are often considered. Bilateral ectropion, narrowing of the oral aperture, and severe facial disfigurement can result. Linear arrangement of some lesions, especially over the shoulders and arms, has also been noted. Despite the multiplicity of lesions, no case of “metastasis” from a skin lesion or increased risk of internal malignancy has been reported in the Grzybowski variant of keratoacanthoma. Dr. Grzybowski’s original patient died of a myocardial infarction 16 years after diagnosis. Oral treatment with retinoids, methotrexate, and cyclophosphamide can prove effective.

### Keratoacanthoma centrifugum marginatum

This uncommon variant of keratoacanthoma is usually solitary, although multiple lesions can occur. Keratoacanthoma centrifugum marginatum is characterized by progressive peripheral expansion and concomitant central healing, leaving atrophy. Spontaneous involution, as may be seen in other variants of keratoacanthoma, does not occur. Lesions range from 5 to 30 cm in diameter (Fig. 29-14). The dorsum of the hands and pretibial regions are favored sites. Oral treatment with etretinate and methotrexate with prednisone has been effective in isolated cases.

**Alloo A, et al:** Photodynamic therapy for multiple eruptive keratoacanthomas associated with vemurafenib treatment for metastatic melanoma. *Arch Dermatol* 2012; 148(3):363–366.

**Annest NM, et al:** Intralesional methotrexate treatment for keratoacanthoma tumors: a retrospective study and review of the literature. *J Am Acad Dermatol* 2007; 56(6):989–993.

**Anzalone CL, Cohen PR:** Generalized eruptive keratoacanthomas of Grzybowski. *Int J Dermatol* 2014; 53(2):131–136.

**Bogner PN, et al:** Giant keratoacanthoma: case report and review of the English literature. *Am J Dermatopathol* 2014; 36(3):252–257.

**Chandrakumar SF, Yeung J:** Cutaneous adverse events during vemurafenib therapy. *J Cutan Med Surg* 2014; 18(4):223–228.

**Chorny JA, et al:** Eruptive keratoacanthomas in a new tattoo. *Arch Dermatol* 2007; 143:1457.

**Esser AC, et al:** Acute development of multiple keratoacanthomas and squamous cell carcinomas after treatment with infliximab. *J Am Acad Dermatol* 2004; 50:S75.

**Goldenberg G, et al:** Eruptive squamous cell carcinomas, keratoacanthoma type, arising in a multicolor tattoo. *J Cutan Pathol* 2008; 35:62.

**Kato N, et al:** Ferguson Smith type multiple keratoacanthomas and a keratoacanthoma centrifugum marginatum in a woman from Japan. *J Am Acad Dermatol* 2003; 49:741.

**Magalhães RF, et al:** Diagnosis and follow-up of keratoacanthoma-like lesions: clinical-histologic study of 43 cases. *J Cutan Med Surg* 2008; 12(4):163–173.

**Mangas C, et al:** A case of multiple keratoacanthoma centrifugum marginatum. *Dermatol Surg* 2004; 30:803.

**Ming ME:** Multiple hyperkeratotic nodules on the arms—diagnosis: keratoacanthoma visceral carcinoma syndrome (KAVCS). *Arch Dermatol* 2003; 139:1363.

**Oakley A, Ng S:** Grzybowski’s generalized eruptive keratoacanthoma: remission with cyclophosphamide. *Australas J Dermatol* 2005; 46:118.

**Obed J, et al:** A pathergic response to fractional CO<sub>2</sub>. *J Drugs Dermatol* 2012; 11(9):1122–1123.

**Ogasawara Y, et al:** A case of multiple keratoacanthoma centrifugum marginatum: response to oral etretinate. *J Am Acad Dermatol* 2003; 48:282.

**Pattee SF, Silvis NG:** Keratoacanthoma developing in sites of previous trauma: a report of two cases and review of the literature. *J Am Acad Dermatol* 2003; 48:S35.

**Savage JA, Maize JC Sr:** Keratoacanthoma clinical behavior: a systematic review. *Am J Dermatopathol* 2014; 36(5):422–429.

**Vandergriff T, et al:** Generalized eruptive keratoacanthomas of Grzybowski treated with isotretinoin. *J Drugs Dermatol* 2008; 7:1069.

**Wieland U, et al:** No evidence for a causal role of Merkel cell polyomavirus in keratoacanthoma. *J Am Acad Dermatol* 2012; 67(1):41–46.

**Wu TP, et al:** Keratoacanthomas arising in association with pruritic nodules in pruritic, actinically damaged skin. *J Am Acad Dermatol* 2013; 69(3):426–430.

**Zaraa I, Cogrel O:** Images in clinical medicine. Subungual tumor of the thumb. *N Engl J Med* 2012; 367(23):2240.

## BASAL CELL CARCINOMA

Basal cell carcinoma (BCC) is the most common cancer in the United States, Australia, New Zealand, and many other countries with a largely white, fair-skinned population with moderate sun exposure. In Hawaii, the incidence of BCC is 14-fold higher in persons of European ancestry (especially Celtic) than in Japanese, and 34-fold higher than in Filipinos. Still, persons of color can develop BCCs, especially fair-skinned Asians and Hispanics who have accumulated significant lifetime sun exposure from occupational sources, usually farm work. White Hispanics have less skin cancer awareness, use sun protection less frequently, and are more likely to use tanning beds than darker-skinned Hispanics. They represent a prevalent at-risk population for skin cancer over the next decades.

Intermittent intense sun exposure, as identified by prior sunburns; radiation therapy; a positive family history of BCC; immunosuppression; a fair complexion, especially red hair; easy sunburning (skin types I or II); and blistering sunburns in childhood are risk factors for the development of BCC. Indoor tanning is a strong risk factor for early-onset BCC, particularly among women. Of interest, actinic elastosis and wrinkling are not risk factors for the development of BCC. In fact, BCCs are relatively rare on the dorsal hand, where sun exposure is high, whereas actinic keratoses and SCCs abound.

SCC is three times more common than BCC on the dorsum of the hand. These findings suggest that the mechanism by which UVR induces BCC is not related solely to the total amount of UVR received. The regular use of sunscreens cannot be proved to reduce the risk for BCC, in contrast to actinic keratoses and SCCs, which are clearly related to the amount of lifetime sun exposure. The ratio of BCC to SCC decreases as one moves from northern (~10) to southern (~2) United States. Once a person has had a BCC, their risk for a subsequent BCC is high: 44% in the next 3 years.

Many clinical morphologies of BCC exist. Clinical diagnosis depends on the clinician being aware of the many forms BCC may take. Because these clinical types may also have different biologic behavior, histologic classification of the type of BCC may also influence the therapy chosen.

### Nodular basal cell carcinoma (classic basal cell carcinoma)

The classic or nodular BCC constitutes 50–80% of all BCCs. Nodular BCC is composed of one or a few small, waxy, semi-translucent nodules forming around a central depression that may or may not be ulcerated, crusted, and bleeding. The edge of larger lesions has a characteristic rolled border. Telangiectases course through the lesion. Bleeding on slight injury is a common sign. As growth progresses, crusting appears over a central erosion or ulcer, and when the crust is knocked or picked off, bleeding occurs, and the ulcer becomes apparent. This ulcer is characterized by chronicity and gradual enlargement over time. The lesions are asymptomatic, and bleeding is the only difficulty encountered. The lesions are most frequently found on the face (85–90% on head and neck) and especially on the nose (25–30%). The forehead, ears (Fig. 29-15), periocular areas, and cheeks are also favored sites. However, any part of the body may be involved.

### Cystic basal cell carcinoma

These dome-shaped, blue-gray cystic nodules are clinically similar to eccrine and apocrine hidrocystomas (Fig. 29-16).

### Morpheic, morpheaform, or cicatricial basal cell carcinoma

This type of BCC presents as a white sclerotic plaque, and 95% of these occur on the head and neck. Ulceration, a pearly rolled

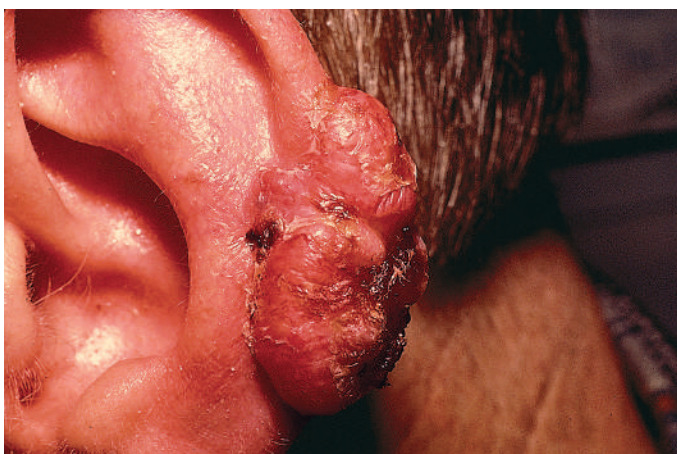

Fig. 29-15 Basal cell carcinoma, nodular type.

border, and crusting are usually absent. Telangiectasia is variably present. Therefore, the lesion is often missed or misdiagnosed for some time. The differential diagnosis includes desmoplastic trichoepithelioma, a scar, microcystic adnexal carcinoma, and desmoplastic melanoma. The unique histologic feature is the strands of basal cells interspersed amid densely packed, hypocellular connective tissue. Morpheic BCCs constitute 2–6% of all BCCs. Data suggest use of fluorouracil may be a risk factor for morpheaform versus nonmorpheaform BCC.

### Infiltrative basal cell carcinoma

Infiltrative BCC is an aggressive subtype characterized by deep infiltration of spiky islands of basaloid epithelium in a fibroblast-rich stroma. Clinically, it lacks the scarlike appearance of morpheic BCC. Histologically, the stroma is hypercellular, the islands are jagged in outline, and squamous differentiation is common.

### Micronodular basal cell carcinoma

These tumors are not clinically distinctive, but the micronodular growth pattern makes them less amenable to curettage.

### Superficial basal cell carcinoma

Superficial BCC is also termed superficial multicentric BCC. This is a very common form of BCC, comprising at least 15% of the total. It favors the trunk (45%) or distal extremities (14%). Only 40% occur on the head and neck. The multicentricity is merely a histologic illusion created by the passing of the plane of section through the branches of a single, multiply branching lesion.

This type of BCC most frequently presents as a dry, psoriasiform, scaly lesion. It is usually a superficial flat growth, which in many cases exhibits little tendency to invade or ulcerate. The lesions enlarge very slowly and may be misdiagnosed as patches of eczema or psoriasis. They may grow to be 10–15 cm in diameter. Close examination of the edges of the lesion will show a threadlike raised border. These erythematous plaques with telangiectasia may occasionally show atrophy or scarring. Some lesions may develop an infiltrative component in their deeper aspect and grow into the deeper dermis. When this occurs, they may induce dermal fibrosis and multifocal ulceration, forming a “field of fire” type of large

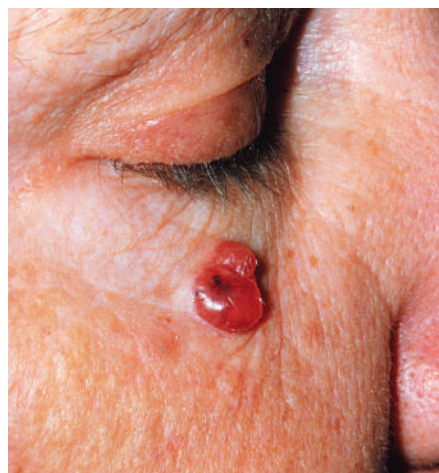
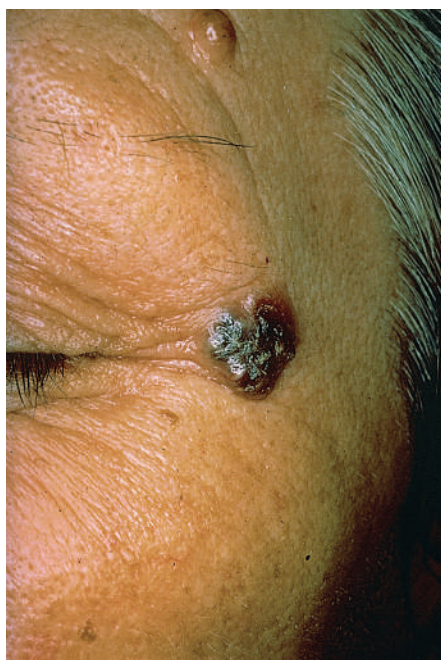
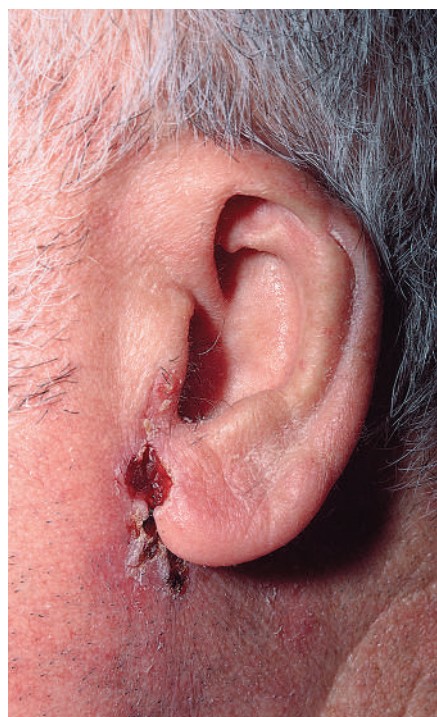

Fig. 29-16 Basal cell carcinoma, cystic.





**Fig. 29-17** Basal cell carcinoma, pigmented.



**Fig. 29-18** Basal cell carcinoma, rodent ulcer.

BCC. Sometimes the lesion will heal at one place with a white atrophic scar and then spread actively to the neighboring skin. A patient can have several of these lesions simultaneously or over time. This form of BCC is the most common pattern seen in patients with human immunodeficiency virus (HIV) infection and BCC.

### Pigmented basal cell carcinoma

This variety has all the features of nodular BCC, but in addition, brown or black pigmentation is present (Fig. 29-17). When dark-complexioned persons, such as Latin Americans, Hispanics, or Asians, develop BCC, this is the type they tend to develop. Pigmented BCCs make up 6% of all BCCs. In the management of these lesions, it should be known that, if ionizing radiation therapy is chosen, the pigmentation remains at the site of the lesion.

### Rodent ulcer

Also known as Jacobi ulcer, rodent ulcer is a neglected BCC that has formed an ulceration (Fig. 29-18). The pearly border of the lesion may not be recognized. If it occurs on the lower extremity, it may be misdiagnosed as a vascular ulceration.

### Fibroepithelioma of Pinkus

First described by Pinkus as premalignant fibroepithelial tumor, this is usually an elevated, skin-colored, sessile lesion on the lower trunk, lumbosacral area, groin, or thigh and may be as large as 7 cm. The lesion is superficial and resembles a fibroma or papilloma. Histologically, interlacing basocellular sheets extend downward from the surface to form an epithelial meshwork enclosing a hyperplastic mesodermal stroma. As with infundibulocystic BCC, fibroepithelioma is composed of pink epithelial strands with blue basaloid buds. Fibroepithelioma has a more prominent fibromucinous stroma and lacks the horn cysts characteristic of infundibulocystic BCC.

Fibroepithelioma often demonstrates sweat ducts within the pink epithelial strands. A slight inflammatory infiltrate may also be present. Simple removal by excision or electrosurgery is the treatment of choice.

### Polypoid basal cell carcinoma

The polypoid BCCs present as exophytic nodules of the head and neck.

### Porelike basal cell carcinoma

Patients with thick sebaceous skin of the central face may develop a BCC that resembles an enlarged pore or stellate pit. The lesions virtually always occur on the nose, melolabial fold, or lower forehead. Affected patients are generally men, and the majority are smokers. Many years pass from the appearance of the lesion until a diagnostic biopsy is taken, because the lesion is considered inconsequential.

### Aberrant basal cell carcinoma

Even in the absence of any apparent carcinogenic factor, such as arsenic, radiation, or chronic ulceration, BCC may occur in odd sites, such as the scrotum, vulva, perineum, nipple, and axilla.

### Solitary basal cell carcinoma in young persons

These curious lesions are typically located in the region of embryonal clefts in the face and are often deeply invasive. Complete surgical excision is much safer than curettage for their removal. Cases in children and teenagers, unassociated with the basal cell nevus syndrome or nevus sebaceus, are well documented.

## Natural history

Basal cell carcinomas run a chronic course as the lesion slowly enlarges and tends to become more ulcerative. As a rule, the lesions tend to bleed without pain or other symptoms. Some tend to heal spontaneously and form scar tissue as they extend. Peripheral spreading may produce configurate, somewhat ser-piginous patches. The ulceration may burrow deep into the subcutaneous tissues or even into cartilage and bone, causing extensive destruction and mutilation. At least half the deaths that occur from BCC result from direct extension into a vital structure rather than metastases.

## Metastasis

Metastasis is extremely rare, occurring in 0.0028–0.55% of BCCs. This low rate is believed to occur because the tumor cells require supporting stroma to survive. The following criteria are now widely accepted for the diagnosis of metastatic BCC:

1. The primary tumor must arise in the skin.
2. Metastases must be demonstrated at a site distant from the primary tumor and must not be related to simple extension.
3. Histologic similarity must exist between the primary tumor and the metastases.
4. The metastases must not be mixed with SCC.

Metastatic BCC is twice as common in men as in women. Immunosuppression does not appear to increase the risk of metastasis of BCC. Most BCCs that metastasize arise on the head and neck and tend to be large tumors that have recurred despite multiple surgical procedures or radiation therapy. The histologic finding of perineural or intravascular BCC increases the risk for metastasis. The regional lymph nodes are the most common site of metastasis, followed by the lung, bone, skin, liver, and pleura. Spread is equally distributed between hematogenous and lymphatic. An average of 9 years elapses between the diagnosis of the primary tumor and metastatic disease, but the interval for metastasis ranges from less than 1 year to 45 years. Although the primary tumor may be present for many years before it metastasizes, once metastases occur, the course is rapidly downhill. After metastasis, fewer than 20% of patients survive 1 year, and fewer than 10% will live for more than 5 years.

## Association with internal malignancies

Frisch et al. reported a series of 37,674 patients with BCCs followed over 14 years. Comparison of cancer rates for the general population was remarkable, with 3663 new cancers versus 3245 in the control population. Malignant melanoma and lip cancers were most frequently found; however, internal malignancies were also noted to be excessive, involving the salivary glands, larynx, lung, breast, kidney, and lymphatics (non-Hodgkin lymphoma). The rate of non-Hodgkin lymphoma was particularly high. Patients receiving the diagnosis of BCC before age 60 had a higher rate of breast cancer, testicular cancer, and non-Hodgkin lymphoma.

## Immunosuppression

Immunosuppression for organ transplantation increases the risk for the development of BCC by about 10-fold. Some increased risk for BCC is also thought to occur in HIV-infected patients and in those receiving immunosuppressive medications for other reasons. Patients with chronic lymphocytic

leukemia are also at increased risk for BCC. In the immunosuppressed population, a history of blistering sunburns in childhood is a strong risk factor for the development of BCC after immunosuppression.

## Etiology and pathogenesis

It appears that BCCs arise from immature pluripotential cells associated with the hair follicle. Mutations that activate the hedgehog signaling pathway, which controls cell growth, are found in most BCCs. The affected genes are those for sonic hedgehog, patched 1, and smoothened (*SMO*). Inactivation of patched 1 is most common, and *SMO* mutations are associated with 10–20% of sporadic BCCs.

## Histopathology

The general belief is that a correlation exists between histologic subtype of BCC and biologic behavior. BCCs are considered as being of low risk or high risk, depending on their probability of causing problems in the future: subclinical extension, incomplete removal, aggressive local invasive behavior, and local recurrence. Therefore, the dermatopathology report of a BCC should include a subtype descriptor when possible. Unfortunately, many shave biopsy specimens do not allow for accurate typing, and the presence of an indolent growth pattern superficially does not exclude the possibility of a deeper, more aggressive growth pattern. The common histologic patterns are nodular, superficial, infiltrative, morpheic, micronodular, and mixed. The nodular type is a low-risk type. High-risk types include the infiltrative, morpheic, and micronodular patterns, because of aggressive local invasive behavior and a tendency to recur. Superficial BCC is prone to increased recurrence due to inadequate removal. When evaluating the histologic margin of superficial BCC, tumor stroma involving the margin should be considered a positive margin.

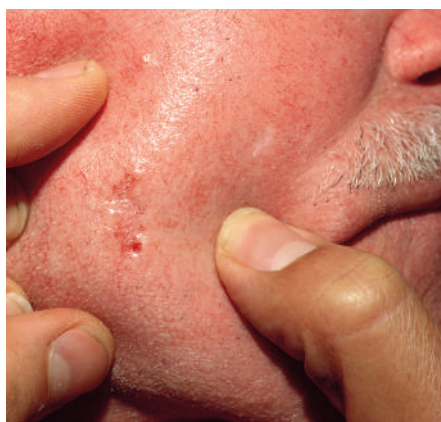The early lesion shows small, dark-staining, polyhedral cells resembling those of the basal cell layer of the epidermis, with large nuclei and small nucleoli. These occur within the epidermis as thickenings or immediately beneath the epidermis as downgrowths connected with it. After the growth has progressed, regular compact columns of these cells fill the tissue spaces of the dermis, and a connection with the epidermis may be difficult to demonstrate. At the periphery of the masses of cells, the columnar cells may be characteristically arranged like fence posts (palisading). This may be absent when the tumor cells are in cord arrangement or in small nests. Cysts may form. The interlacing strands of tumor cells may present a latticelike pattern. The dermal stroma is an integral and important part of the BCC. The stroma is loose and fibromyxoid, with a sparse lymphoid infiltrate often present. The stroma can be highlighted by metachromatic toluidine blue staining, which can be useful during Mohs surgery.

## Differential diagnosis

Distinguishing between small BCCs and small SCCs is largely an intellectual exercise. Both are caused chiefly by sunlight, neither is likely to metastasize, and both will require removal, usually by simple surgical excision or curettage. A biopsy is always indicated but may be performed at the definitive procedure, when the likelihood of the diagnosis of NMSC is high and the patient is fully informed and gives consent.

A waxy, nodular, rolled edge is fairly characteristic of BCC (Fig. 29-19). The SCC is a dome-shaped, elevated, hard, and





**Fig. 29-19** Basal cell carcinoma, accentuation of pearly border when skin is stretched.

infiltrated lesion. The early BCC may easily be confused with sebaceous hyperplasia, which has a depressed center with yellowish small nodules surrounding the lesion. However, these lesions never bleed and do not become crusted.

Bowen's disease, Paget's disease, amelanotic melanoma, and actinic and seborrheic keratoses may also simulate BCC. Ulcerated BCC on the shins is frequently misdiagnosed as a stasis ulcer, and a biopsy may be the only way to differentiate the two. Pigmented BCC is frequently misdiagnosed as melanoma or as a pigmented nevus. The superficial BCC is easily mistaken for psoriasis or eczema. The careful search for the rolled edge of the peripheral nodules is important in differentiating BCC from all other lesions.

## Treatment

Each lesion of BCC must be thoroughly evaluated individually. Age and gender of the patient as well as the size, site, and type of lesion are important factors to be considered when choosing the proper method of treatment. No single treatment method is ideal for all lesions or all patients. The choice of treatment will also be influenced by the experience and ability of the treating physician in the various treatment modalities. A biopsy should be performed in all patients with suspected BCC to determine the histologic subtype and confirm the diagnosis.

The aim of treatment is for a permanent cure with the best cosmetic results. This is important because the most common location of BCC is the face. Recurrences result from inadequate treatment and are usually seen during the first 4–12 months after treatment. A minimum 5-year follow-up is indicated, however, to continue a search for new lesions, since the development of a second BCC is common.

Treatment of BCC is usually surgical (see Chapter 37), but some forms of BCC are amenable to medical treatment or radiation therapy. Vismodegib, an orally active, small-molecule inhibitor of smoothed that targets the hedgehog pathway, has antitumor activity and clinically meaningful response in locally advanced or metastatic BCC.

## Topical therapy

Topical therapy appears to be most effective in the treatment of superficial BCC. For nodular BCCs, the cure rates are only 65%, which is unacceptable given the other options available. On the other hand, superficial BCCs may be cured 80% of the time with topical treatment. Topical 5-FU applied twice daily for at least 6 weeks can yield acceptable results in properly selected (i.e., thin) tumors but is not otherwise very effective, with high recurrence rates. Imiquimod applied three times a

week with occlusion, or five times a week without occlusion, is the favored form of topical, patient-applied treatment for superficial BCC. Duration of treatment is 6 weeks but may be extended if the lesion does not appear to have been eradicated. Cosmetic results are excellent, especially for lesions of the anterior chest and upper back, where significant scarring usually results from surgical procedures. Photodynamic therapy (PDT) has also emerged as a treatment option for BCC. A randomized controlled trial (RCT) found imiquimod to be superior, and 5-FU not to be inferior, to PDT for superficial BCC. Cure rates are higher with surgical excision than with topical therapy.

- Arits AH, et al:** Photodynamic therapy versus topical imiquimod versus topical fluorouracil for treatment of superficial basal-cell carcinoma: a single blind, non-inferiority, randomised controlled trial. *Lancet Oncol* 2013; 14(7):647–654.
- Basset-Seguín N, et al:** Efficacy of Hedgehog pathway inhibitors in basal cell carcinoma. *Mol Cancer Ther* 2015; Jan 13 [Epub ahead of print.]
- Benedetto AV, et al:** Basal cell carcinoma presenting as a large pore. *J Am Acad Dermatol* 2002; 47:727.
- Brooke RCC, et al:** Discordance between facial wrinkling and the presence of basal cell carcinoma. *Arch Dermatol* 2001; 137:751.
- Byrd-Miles K, et al:** Skin cancer in individuals of African, Asian, Latin-American, and American-Indian descent: differences in incidence, clinical presentation, and survival compared to Caucasians. *J Drugs Dermatol* 2007; 6:10.
- Caccialanza M, et al:** Radiotherapy of morphea-type basal cell carcinoma: results of 127 cases. *J Eur Acad Dermatol Venereol* 2014; 28(12):1751–1755.
- Cho M, et al:** Utility of radiotherapy for treatment of basal cell carcinoma: review. *Br J Dermatol* 2014; 171(5):968–973.
- Dreno B, et al:** Clinical benefit assessment of vismodegib therapy in patients with advanced basal cell carcinoma. *Oncologist* 2014; 19(8):790–796.
- Esquivias Gomez JJ, et al:** Basal cell carcinoma of the scrotum. *Australas J Dermatol* 1999; 40:141.
- Ferrucci LM, et al:** Indoor tanning and risk of early-onset basal cell carcinoma. *J Am Acad Dermatol* 2012; 67(4):552–562.
- Gloster HM Jr, Neal K:** Skin cancer in skin of color. *J Am Acad Dermatol* 2006; 55:741.
- Goldberg LH:** Basal-cell carcinoma as a predictor of other cancers. *Lancet* 1997; 349:664.
- Kahn HS, et al:** Increased cancer mortality following a history of non-melanoma skin cancer. *JAMA* 1998; 280:910.
- Ma F, et al:** Skin cancer awareness and sun protection behaviors in white Hispanic and white non-Hispanic high school students in Miami, Florida. *Arch Dermatol* 2007; 143:983.
- McCormack CJ, et al:** Differences in age and body site distribution of the histological subtypes of basal cell carcinoma: a possible indicator of differing causes. *Arch Dermatol* 1997; 133:593.
- Mosterd K, et al:** Fractionated 5-aminolaevulinic acid–photodynamic therapy vs. surgical excision in the treatment of nodular basal cell carcinoma: results of a randomized controlled trial. *Br J Dermatol* 2008; 159(4):864–870.
- Naldi L, et al:** Host-related and environmental risk factors for cutaneous basal cell carcinoma: evidence from an Italian case-control study. *J Am Acad Dermatol* 2000; 42:446.
- Pranteda G, et al:** Basal cell carcinoma: differences according to anatomic location and clinical-pathological subtypes. *G Ital Dermatol Venereol* 2014; 149(4):423–426.
- Robinson JK, et al:** Basal cell carcinoma with pulmonary and lymph node metastasis causing death. *Arch Dermatol* 2003; 139:643.
- Rosso S, et al:** The multicentre South European study “Helios.” II: different sun exposure patterns in the aetiology of basal cell and squamous cell carcinomas of the skin. *Br J Cancer (Scot)* 1996; 73:1447.
- Saldanha G, et al:** Basal cell carcinoma: a dermatopathological and molecular biological update. *Br J Dermatol* 2003; 148:195.
- Scrivener Y, et al:** Variations of basal cell carcinomas according to gender, age, location and histopathological subtype. *Br J Dermatol* 2002; 147:41.
- Tilli CMLJ, et al:** Molecular aetiology and pathogenesis of basal cell carcinoma. *Br J Dermatol* 2005; 152:1108.

Von Hoff DD, et al: Inhibition of the hedgehog pathway in advanced basal-cell carcinoma. *N Engl J Med* 2009; 361(12):1164–1172.

Xiong MY, et al: Fluorouracil and other predictors of morpheiform basal cell carcinoma among high-risk patients: the Veterans Affairs Topical Tretinoin Chemoprevention Trial. *JAMA Dermatol* 2014; 150(3):332–334.

## NEVOID BASAL CELL CARCINOMA SYNDROME (GORLIN SYNDROME)

### Clinical features

The nevoid BCC syndrome (NBCCS) or basal cell nevus syndrome is an autosomal dominant inherited disorder. The major diagnostic criteria for NBCCS include the following:

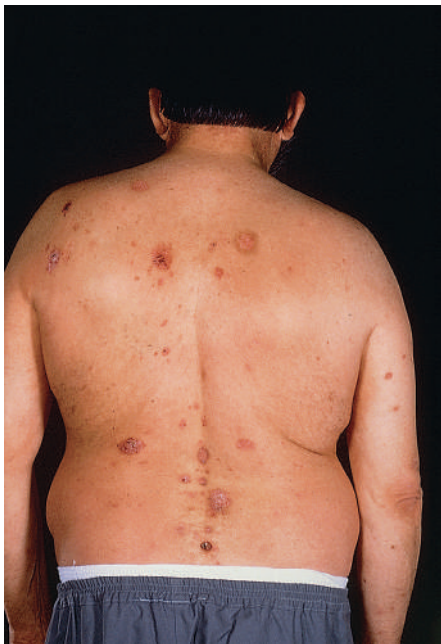1. Development of multiple BCCs (>5) or a BCC before age 30 (Fig. 29-20)
2. Odontogenic keratocysts of the jaws
3. Pitted depressions on the hands and feet (palmar/plantar pits) (two or more)
4. Lamellar calcification of the falx under age 20
5. First-degree relative with NBCCS.

Minor criteria are as follows:

1. Childhood medulloblastoma
2. Lympho-mesenteric or pleural cysts
3. Macrocephaly (97th percentile)
4. Cleft lip/palate
5. Vertebral/rib abnormalities
6. Preaxial or postaxial polydactyly
7. Ovarian/cardiac fibromas
8. Ocular abnormalities

The diagnosis of NBCCS is made if the affected individual has two major criteria and one minor criterion, or one major criterion and three minor criteria. Genetic testing has revealed that some persons carrying the genetic mutation do not meet the diagnostic criteria.

Essentially, all cases of NBCCS are caused by mutations in the *PTCH* (or *PTCH1*) gene. One family with a mutation in the *SUFU* gene has been reported. *SUFU* mutations have been reported with medulloblastoma susceptibility. Mutations occur



**Fig. 29-20** Multiple basal cell carcinomas in nevoid basal cell carcinoma syndrome.

throughout the *PTCH* gene, and no correlation appears to exist between the site of the mutation and the clinical phenotype. Most mutations result in premature termination and production of shortened gene product. Loss of the *PTCH* gene can also occur by deletions of part of the long arm of chromosome 9, where the *PTCH* gene is located (region q22). This represents about 6% of NBCCS patients.

The clinical findings seen with NBCCS depend on two characteristics: the race of the patient and the form of mutation (nucleotide point mutation or chromosome deletion). Of 105 patients reported in one series, 80% were white. The first tumor developed by the mean age of 23 years for white patients. Palmar pits were seen in 87%. Jaw cysts were found in 74%, with 80% manifested by age 20. The total number of cysts ranged from 1 to 28. Medulloblastomas developed in four patients, and three had cleft lip or palate. Physical findings in this series included “coarse face” (54%), macrocephaly (50%), hypertelorism (42%), frontal bossing (27%), pectus deformity (13%), and Sprengel deformity (11%). In Japanese and African American patients with NBCCS, palmar and plantar pits, odontogenic keratocysts, and skeletal abnormalities are most common, with BCCs not appearing until much later in life. Those patients with NBCCS caused by deletions of chromosome 9q22 have all the stigmata of typical NBCCS patients, and in addition often have severe mental retardation, hyperactivity, overfriendliness with strangers, short stature, and less often, neonatal hypotonia, epicanthic folds, short neck, pectus, scoliosis, and epilepsy.

### Skin tumors

The BCCs occur at an early age or any time thereafter as multiple lesions, usually numerous. The usual age of appearance is 17–35 years. Although any area of the body may be affected, there is a marked tendency toward involvement of the central facial area, especially the eyelids, periorbital area, nose, upper lip, and cheeks. Persons with fair skin (type 1) and prior excessive UV exposure are particularly prone to develop many BCCs. Lesions typically appear as 1–10 mm, hyperpigmented or skin-colored, dome-shaped papules. They have a striking resemblance to typical compound or intradermal nevi. Polypoid BCC or acrochordon-like BCC is a more unusual variant that tends to occur in NBCCS patients in childhood. Among the many BCCs that an NBCCS patient may have, some sit indolently and others may grow more aggressively.

### Jaw cysts

Jaw cysts occur in approximately 90% of patients. They occur as early as age 5 years and rarely after age 30. Both the mandible and the maxilla may show cystic defects on x-ray, with mandibular involvement occurring twice as often. Jaw cysts most commonly present as painless swelling. They usually have a keratinized lining (keratocysts) but uncommonly a cyst may be an ameloblastoma.

### Pits of palms and soles

An unusual pitting of palms and soles is a distinguishing feature of the disease. This usually becomes apparent in the second decade of life. Up to 87% of patients with NBCCS will have pits. Histologically, they show basaloid proliferation, but the lesions do not progress or behave as a BCC.

### Skeletal defects/birth defects

Most NBCCS patients have skeletal anomalies that are easily detected on radiographs. Macrocephaly is the first feature



observed and explains the high rate of cesarean delivery of NBCCS-affected neonates. Other skeletal defects include bifid, fused, missing, or splayed ribs; scoliosis; and kyphosis. Radiographic evidence of multiple lesions is highly suggestive of this syndrome; and since most are present congenitally, radiology may be useful in diagnosing this syndrome in patients too young to manifest other abnormalities. Cleft lip/palate is seen in 5% of patients; lamellar calcification of the falx will be evident in 90% of patients by age 20; and polydactyly also occurs. Numerous ocular findings have been reported, and if NBCCS is suspected or confirmed, an ophthalmologic evaluation should be performed. Spina bifida is, fortunately, uncommon.

### Histopathology

The histology of BCCs arising in syndromic patients is identical to that arising in nonsyndromic patients, with the solid and superficial types being most common.

### Differential diagnosis

Several other unique types of BCC presentation should not be confused with NBCCS. One type is the linear unilateral BCC syndrome, in which a linear arrangement of close-set papules, sometimes interspersed with comedones, is present at birth. Biopsy reveals BCCs, but they do not increase in size with the age of the patient. A second type, referred to as Bazex syndrome, is an X-linked dominant inherited disease comprising follicular atrophoderma of the extremities, localized or generalized hypohidrosis, hypotrichosis, and multiple BCCs of the face, which often arise at an early age. A third type consists of multiple hereditary infundibulocystic BCCs and is an autosomal dominant syndrome. It is distinguished from NBCCS by the absence of palmar pits and jaw cysts in most cases. Clinically, patients appear to have multiple trichoepitheliomas. Numerous skin-colored pearly papules affect the central face, accentuated in the nasolabial folds. The generalized basaloid follicular hamartoma syndrome differs from NBCCS by having basaloid follicular hamartomas instead of BCCs. It is reported from a large kindred in the southeastern United States (see later). Tiny palmar pits are present. Histologically, infundibulocystic BCC and basaloid follicular hamartoma may be indistinguishable, so the two familial syndromes may be difficult to separate. Rombo syndrome, reported in one large Swedish family, has multiple BCCs, vermiculate atrophoderma, and hypotrichosis. A patient with multiple BCCs and myotonic dystrophy has been reported, suggesting yet another genodermatosis associated with multiple BCCs.

### Treatment

Genetic counseling is essential. Strict sun avoidance and maximum sun protection, as recommended for xeroderma pigmentosum patients, is advised. Avoidance of ionizing radiation is also paramount, because NBCCS patients are particularly sensitive to radiation; multiple BCCs may appear in the distribution of radiation therapy used to treat medulloblastoma or BCC or other cancers. Treatment involves very regular monitoring and biopsy of suspicious lesions. Topical therapy with tazarotene and imiquimod may be of some use in preventing and treating the superficial tumors. Oral retinoid therapy may reduce the frequency of new BCCs appearing and may slow the growth of existing small BCCs. However, once the oral retinoids are stopped, the lesions again begin to

grow. Vismodegib, the hedgehog pathway inhibitor, reduces BCC tumor burden and prevents growth of new BCCs in those with NBCCS; however, poor tolerability of the medication leads to a high rate of discontinuation (~50%). A topical formulation of a smoothed inhibitor appears to be effective and better tolerated, leading to BCC regression. Surgical treatments are used for most lesions, either curettage and desiccation or excision. At times, megasections, with removal of multiple tumors under general anesthesia in the operating room, are needed to keep up with the large number of BCCs these patients develop. PDT appears to be particularly beneficial when used to treat areas that have had multiple BCCs in the past.

**Ally MS, et al:** The use of vismodegib to shrink keratocystic odontogenic tumors in patients with basal cell nevus syndrome. *JAMA Dermatol* 2014; 150(5):542–545.

**Bañuls J, et al:** Tissue and tumor mosaicism of the myotonin protein kinase gene trinucleotide repeat in a patient with multiple basal cell carcinomas associated with myotonic dystrophy. *J Am Acad Dermatol* 2004; 50:S1.

**Chang AL, et al:** Surgical excision after neoadjuvant therapy with vismodegib for a locally advanced basal cell carcinoma and resistant basal carcinomas in Gorlin syndrome. *JAMA Dermatol* 2013; 149(5):639–641.

**Dalati T, Zhou H:** Gorlin syndrome with ameloblastoma: a case report and review of the literature. *Cancer Invest* 2008; 26:975.

**Endo M, et al:** Nationwide survey of nevoid basal cell carcinoma syndrome in Japan revealing the low frequency of basal cell carcinoma. *Am J Med Genet* 2012; 158A(2):351–357.

**Gilchrist BA, et al:** Photodynamic therapy for patients with basal cell nevus syndrome. *Dermatol Surg* 2009; 35:1576.

**Glaessl A, et al:** Sporadic Bazex-Dupré-Christol-like syndrome: early onset basal cell carcinoma, hypohidrosis, hypotrichosis, prominent milia. *Dermatol Surg* 2000; 26:152.

**Griner D, et al:** Surgical management of Gorlin syndrome: a 4-decade experience using local excision technique. *Ann Plast Surg* 2014; Jan 7. [Epub ahead of print.]

**Kimonis VE, et al:** Clinical manifestations in 105 persons with nevoid basal cell carcinoma syndrome. *Am J Med Genet* 1997; 69:299.

**Kimonis VE, et al:** Clinical and radiological features in young individuals with nevoid basal cell carcinoma syndrome. *Genet Med* 2013; 15(1):79–83.

**Mathias SD, et al:** Assessing health-related quality of life for advanced basal cell carcinoma and basal cell carcinoma nevus syndrome: development of the first disease-specific patient-reported outcome questionnaires. *JAMA Dermatol* 2014; 150(2):169–176.

**Micali G, et al:** The use of imiquimod 5% cream for the treatment of basal cell carcinoma as observed in Gorlin's syndrome. *Clin Exp Dermatol* 2003; 28:19.

**Pastorino L, et al:** Identification of a *SUFU* germline mutation in a family with Gorlin syndrome. *Am J Med Genet* 2009; 149A:1539.

**Requena L, et al:** Multiple hereditary infundibulocystic basal cell carcinomas. *Arch Dermatol* 1999; 135:1227.

**Skvara H, et al:** Topical treatment of basal cell carcinomas in nevoid basal cell carcinoma syndrome with a smoothed inhibitor. *J Invest Dermatol* 2011; 131(8):1735–1744.

**Tang JY, et al:** Inhibiting the hedgehog pathway in patients with the basal-cell nevus syndrome. *N Engl J Med* 2012; 366(23):2180–2188.

**Titinchi F, et al:** Nevoid basal cell carcinoma syndrome: a 40-year study in the South African population. *J Oral Pathol Med* 2013; 42(2):162–165.

**Vered M, et al:** The immunoprofile of odontogenic keratocyst (keratocystic odontogenic tumor) that includes expression of *PTCH*, *SMO*, *GLI-1* and *bcl-2* is similar to ameloblastoma but different from odontogenic cysts. *J Oral Pathol Med* 2009; 38:597.

**Wolfe CM, et al:** A possible chemopreventive role for photodynamic therapy in Gorlin syndrome: a report of basal cell carcinoma reduction and review of literature. *Australas J Dermatol* 2013; 54(1):64–68.

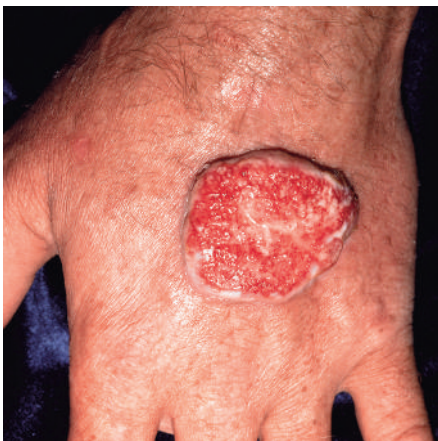## SQUAMOUS CELL CARCINOMA

Squamous cell carcinoma (SCC) is the second most common form of skin cancer. Most cases of SCC of the skin are induced

by UVR. Chronic, long-term sun exposure is the major risk factor, and areas that have had such exposure (face, scalp, neck, dorsal hands) are favored locations. SCC becomes relatively more common as the annual amount of UVR increases, so SCC is more common in Texas than in Minnesota, for example. Immunosuppression greatly enhances the risk for the development of SCC, approximately 65-fold to 250-fold among organ transplant recipients, with azathioprine exposure especially associated with greater risk for development of cutaneous SCC. Sorafenib and possibly the tumor necrosis factor (TNF) inhibitors may be associated with increased risk of cutaneous SCC. High-risk genital HPVs, primarily 16, 18, 31, and 35, play a role in SCCs that develop on the genitalia and periungually. Chronic ulcers, hidradenitis suppurativa, recessive dystrophic epidermolysis bullosa, lesions of discoid LE, erosive lichen planus, prior radiation exposure, and PUVA therapy also appear to enhance the risk for SCC development. Metastasis, with mortality of 18%, is very uncommon for SCCs arising at sites of chronic sun damage, whereas it is relatively high (20–30%) in SCCs occurring in the various scarring processes. In recessive dystrophic epidermolysis bullosa, metastatic SCC is the most common cause of death in adulthood. Patients with epidermodysplasia verruciformis (EDV) also develop SCCs on sun-exposed sites, associated with unique HPV types. These unique EDV HPV types (e.g., HPV-5, HPV-8) may also play a role in SCCs that develop in immunosuppressed persons. SCC of the oral mucosa is discussed in Chapter 34. Because the vast majority of cutaneous SCCs are induced by UVR, sun protection, with avoidance of the midday sun, protective clothing, and the regular application of a sun-block of SPF 30 or higher, is recommended. Some researchers have suggested that smoking is also a risk factor for cutaneous SCC, but this is controversial.

### Clinical features

Frequently, SCC begins at the site of actinic keratosis on sun-exposed areas such as the face and backs of the hands. BCCs far outnumber SCCs on facial skin, but SCCs on the hand occur three times more frequently than BCCs. The lesion may be superficial, discrete, and hard and arises from an indurated, rounded, elevated base. It is dull red and contains telangiectases. In the course of a few months, the lesion becomes larger, deeply nodular, and ulcerated. The ulcer is at first superficial and hidden by a crust. When the crust is removed, a well-defined papillary base is seen (Fig. 29-21), and on palpation, a discrete hard disk is felt. In the early phases, this tumor is localized, elevated, and freely mobile over underlying



**Fig. 29-21** Squamous cell carcinoma.

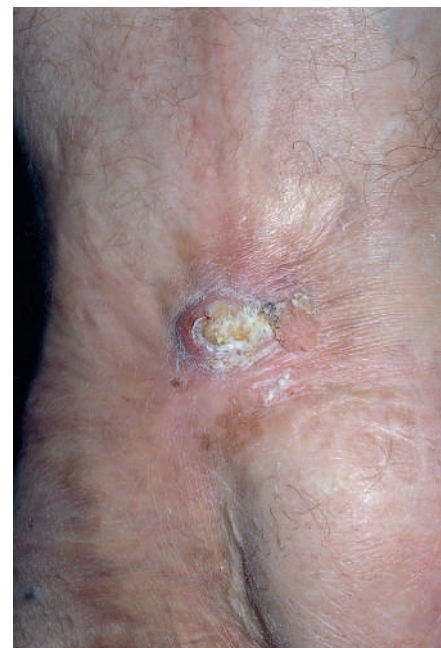
structures; later it gradually becomes diffuse, more or less depressed, and fixed. The growth eventually invades the underlying tissues. The tumor above the level of the skin may be dome shaped, with a corelike center that later ulcerates. The surface in advanced lesions may be cauliflower-like, composed of densely packed, filamentous projections, between which are clefts filled with a viscous, purulent, malodorous exudate.

In black patients, SCCs are 20% more common than BCCs. The most favored sites are the face and lower extremities, with involvement of non-sun-exposed areas more common. Elderly women (mean age 77) are primarily affected in cases involving the lower legs. Prior direct heat exposure from open fireplaces may be the predisposing factor. In contrast, the most frequently found predisposing conditions in white patients are scarring processes, such as burns (Fig. 29-22), leg ulcers, and hidradenitis suppurativa.

On the lower lip, SCC often develops on actinic cheilitis. From repeated sunburn, the vermilion surface becomes dry, scaly, and fissured. At the beginning, only a local thickening is noticeable. This then becomes a firm nodule. It may grow outward as a sizable tumor or inward with destructive ulceration. A history of smoking is also a frequent and significant predisposing factor. Lower lip lesions far outnumber upper lip lesions; men greatly outnumber women (12:1); and the median age is the late sixties. SCCs occurring on the lower lip metastasize in 10–15% of cases. SCC of the lip may also occur in areas of discoid LE in black patients. Neoplastic transformation into SCC may develop in 0.3–3% of patients with discoid LE of the lip.

Periungual SCC frequently presents with signs of erythema and scaling, which can superficially resemble a wart. The patient may even have periungual warts on other digits. Early on, pain and ulceration are uncommon. Radiographs show that 50% have changes in the terminal phalanx. There is a low rate of metastases (3%), but local excision with Mohs microsurgery is recommended, as it reduces the risk of recurrence. Periungual SCC is strongly associated with genital HPV types, primarily 16, 18, 31, and 35.

Given the numerous presentations of SCC on the skin, there should be a low threshold for biopsy of any suspicious keratotic, ulcerated, or nodular lesion, especially on the background of chronic sun exposure.



**Fig. 29-22** Squamous cell carcinoma in a burn scar. (Courtesy of Dr. Curt Samlaska.)



## Histopathology

Squamous cell carcinoma is characterized by irregular nests, cords, or sheets of neoplastic keratinocytes invading the dermis to various depths. Thickness is an important risk factor for metastasis, with thickness >2 mm associated with a metastatic rate of 4% and >6 mm with a rate of 16%. Less than 5% of patients with metastatic SCC had a primary cutaneous SCC <2 mm in thickness. Immunosuppression, location on the ear, and increased horizontal size all increase the risk of metastasis by twofold to fourfold. Desmoplasia and tumor thickness also increase local recurrence risk, by 16 and 6 times, respectively. Although histologic differentiation should be reported, it seems less important than these other tumor features in predicting prognosis. In tumors that are poorly differentiated or of primary clear cell morphology, other types of neoplasm must be excluded, such as melanoma. Immunoperoxidase staining for keratins is very useful in this setting. Desmoplastic SCCs by light microscopy have prominent trabecular growth patterns, narrow columns of atypical epithelial cells, and marked desmoplastic stromal reaction. These tumors tend to recur. Acantholytic SCC is a recognized histologic subtype but is of no prognostic importance. The finding of perineural or vascular invasion and recurrence are poor prognostic features.

## Differential diagnosis

The differentiation of SCC from keratoacanthoma is of academic interest in most cases, because simple surgical excision is performed on most of these lesions. However, if nonsurgical modalities are contemplated, a biopsy confirming the diagnosis of keratoacanthoma is recommended. In the setting of immunosuppression, keratoacanthoma-like lesions should be managed as SCCs. The rapid growth and presence of a rolled border with a keratotic central plug suggest the diagnosis of keratoacanthoma, as does explosive growth. An early SCC may be confused with a hypertrophic actinic keratosis, and indeed, the two may be indistinguishable clinically. Biopsy to include the base of the lesion is necessary to make the diagnosis.

Pseudoepitheliomatous hyperplasia (PEH) must be distinguished histologically from true SCC. Marked PEH may be seen in granular cell tumor, bromoderma, blastomycosis, granuloma inguinale, and chronic pyoderma. It is frequently mistaken for SCC in chronic stasis ulcers, ulcerations occurring in thermal burns, lupus vulgaris, leishmaniasis, and even sporotrichosis. PEH arises from adnexal structures, as well as the surface epidermis. Hyperkeratosis and hypergranulosis of adjacent hair follicles are often present. Strands of epidermal cells may extend into the reticular dermis and usually trap elastic fibers, a finding also seen in keratoacanthoma but rarely in conventional SCCs. A potential diagnostic pitfall is the presence of benign PEH adjacent to and overlying invasive SCC. This is particularly common in lesions that have been picked or scratched.

## Metastases

The rate of SCC metastasis from all skin sites ranges from 0.5% to 5.2%. Lesions at elevated risk of metastasis (and recurrence) are those on the lip, ear, or anogenital skin; those occurring at the site of chronic scar or irradiation; those 2 cm or more in diameter; those more than 4 mm thick; those that are recurrent, have poor histologic differentiation, or perineural invasion; and those occurring in patients with organ transplantation or hematologic malignancy. Such patients may be considered

for more aggressive surgical management and adjuvant radiotherapy. Careful attention should be paid to regional lymph nodes draining the site of the SCC. These should be examined at the initial evaluation when the suspicious lesion is identified and at the regular visits that follow the treatment of the SCC.

Patients with SCC are at increased risk of developing other malignancies, such as cancers of the respiratory organs, buccal cavity, pharynx, and small intestine (in men) as well as non-Hodgkin lymphoma and leukemia.

## Prevention/treatment

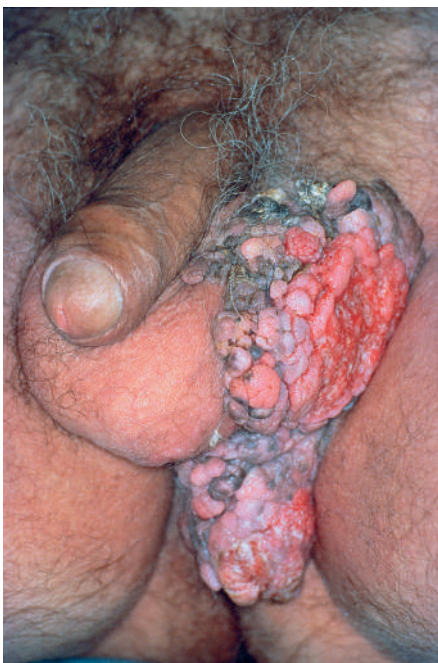The primary treatment of SCC of the skin is surgical (see Chapter 37). Oral retinoids may be useful as a preventive strategy in patients with immunosuppression who develop frequent cancers. PDT might be beneficial to reduce the number of SCCs occurring in areas of prior UV damage where SCCs have already occurred. Organ transplant recipients should be educated about sun protection and skin cancer risk, ideally *before* their transplantation, and should have regular skin examinations by a trained dermatologist. The use of sirolimus instead of other immunosuppressives appears to reduce the prevalence of SCCs in organ transplant recipients. Immunosuppressed patients receiving voriconazole for treatment or prophylaxis of invasive fungal infections should be made aware of its role in photocarcinogenesis and its link to increased SCC incidence and should be similarly educated about sun protection measures.

- Brantsch KD, et al:** Analysis of risk factors determining prognosis of cutaneous squamous-cell carcinoma: a prospective study. *Lancet Oncol* 2008; 9(8):713–720.
- Breuninger H, et al:** Desmoplastic squamous cell carcinoma of skin and vermilion surface: a highly malignant subtype of skin cancer. *Cancer* 1997; 79:915.
- Brougham ND, et al:** The incidence of metastasis from cutaneous squamous cell carcinoma and the impact of its risk factors. *J Surg Oncol* 2012; 106(7):811–815.
- Campistol JM:** Minimizing the risk of posttransplant malignancy. *Transplantation* 2009; 87:S19.
- Clayman GL, et al:** Mortality risk from squamous cell skin cancer. *J Clin Oncol* 2005; 23(4):759–765.
- Dinehart SM, et al:** Metastatic cutaneous squamous cell carcinoma derived from actinic keratosis. *Cancer* 1997; 79:920.
- Dubauskas Z, et al:** Cutaneous squamous cell carcinoma and inflammation of actinic keratoses associated with sorafenib. *Clin Genitourin Cancer* 2009; 7:20.
- Farasat S, et al:** A new American Joint Committee on Cancer staging system for cutaneous squamous cell carcinoma: creation and rationale for inclusion of tumor (T) characteristics. *J Am Acad Dermatol* 2011; 64(6):1051.
- Fine JD, et al:** Epidermolysis bullosa and the risk of life-threatening cancers: the National EB Registry experience, 1986–2006. *J Am Acad Dermatol* 2009; 60(2):203–211.
- Fritsch A, et al:** New primary cancers after squamous cell skin cancer. *Am J Epidemiol* 1995; 141:916.
- Harper JG et al:** Squamous cell carcinoma in an African American with discoid lupus erythematosus: a case report and review of the literature. *South Med J* 2010; 103(3):256–259.
- Harwood CA, et al:** Low dose retinoids in the prevention of cutaneous squamous cell carcinomas in organ transplant recipients. *Arch Dermatol* 2005; 141:456.
- Herschel S, et al:** Squamous cell carcinoma arising in hidradenitis suppurativa. *J Dtsch Dermatol Ges* 2014; 12(5):417–419.
- Hofbauer GL, et al:** Swiss clinical practice guidelines for skin cancer in organ transplant recipients. *Swiss Med Wkly* 2009; 139:407.
- Ingvar A, et al:** Immunosuppressive treatment after solid organ transplantation and risk of post-transplant cutaneous squamous cell carcinoma. *Nephrol Dial Transplant* 2010; 25(8):2764–2771.
- Kerbleski JF, Gottlieb AB:** Dermatological complications and safety of anti-TNF treatments. *Gut* 2009; 58:1033.

- Koch A, et al:** Polydactylous Bowen's disease. *J Eur Acad Dermatol Venereol* 2003; 17:213.
- Kowal-Vern A, Criswell BK:** Burn scar neoplasms: a literature review and statistical analysis. *Burns* 2005; 31(4):403–413.
- McCall CO, Chen SC:** Squamous cell carcinoma of the legs in African Americans. *J Am Acad Dermatol* 2002; 47:524.
- McQuillan RF, et al:** The effect of switching from calcineurin inhibitor to sirolimus on the incidence of skin cancers in kidney transplant recipients. *J Eur Acad Dermatol Venereol* 2009; 23:330.
- Motley R, Lawrence C:** Multiprofessional guidelines for the management of the patient with primary cutaneous squamous cell carcinoma. *Br J Dermatol* 2002; 146:18.
- Nijsten TEC, Stern RS:** Oral retinoid use reduces cutaneous squamous cell carcinoma risk in patients with psoriasis treated with psoralen-UVA: a nested cohort study. *J Am Acad Dermatol* 2003; 49:644.
- Schmults CD, et al:** Factors predictive of recurrence and death from cutaneous squamous cell carcinoma: a 10-year, single-institution cohort study. *JAMA Dermatol* 2013; 149(5):541.
- Sheppard J, et al:** Skin cancer in psoriatic arthritis treated with anti-TNF therapy. *Rheumatology (Oxford)* 2007; 46:1622.
- Takeda H, et al:** Multiple squamous cell carcinomas in situ in vitiligo lesions after long-term PUVA therapy. *J Am Acad Dermatol* 1998; 38:268.
- Wennberg AM, et al:** Photodynamic therapy with methyl aminolevulinate for prevention of new skin lesions in transplant recipients: a randomized study. *Transplantation* 2008; 86:423.
- Wisgerhof HC, et al:** Trends of skin diseases in organ-transplant recipients transplanted between 1966 and 2006: a cohort study with follow-up between 1994 and 2006. *Br J Dermatol* 2010; 162(2):390–396.

## VERRUCOUS CARCINOMA (CARCINOMA CUNICULATUM)

Verrucous carcinoma is a distinct, well-differentiated, low-grade SCC. It affects mostly elderly men. The primary characteristic of these lesions is their close resemblance, clinically and histologically, to a wart. The lesions present as a bulbous mass with a soft consistency and often multiple sinuses opening to the surface, resembling “rabbit burrows.” Lesions of this type are most common on the sole but also occur in the genital area (Fig. 29-23) (giant condyloma of Buschke and Lowenstein) and on the oral mucosa. In some cases, as in the



**Fig. 29-23** Giant condyloma of Buschke and Lowenstein.

Buschke-Lowenstein tumor, verrucous carcinomas are induced by HPV. These HPVs may be of the “low-risk” types, such as HPV-6 or HPV-11, or the high-risk types, such as HPV-16 or HPV-18. In other cases, no HPV can be found, and pressure or other factors (but not UV light) are thought to play a role. The natural history is of a slow-growing mass that over years may invade the bones beneath the tumor.

Histologically, the lesion shows a characteristic picture of bulbous rete ridges topped by an undulating keratinized mass. The squamous epithelium is well differentiated, and cytologic atypia is minimal. The cytoplasm is often apple-pink and may have a glassy appearance. The tumor border is smooth and pushing, rather than spiky and infiltrative.

Excision is the best treatment, and Mohs microsurgery may be a helpful technique. Radiotherapy has been reported to induce anaplastic transformation, and although the risk appears to be low, it is best avoided if other treatment options exist. Lymph node metastasis is rare, and the prognosis is favorable when complete excision is accomplished. Other treatments used for cutaneous verrucous carcinomas with variable success include topical or systemic chemotherapy (bleomycin, 5-FU, cisplatin, methotrexate), CO<sub>2</sub> laser, intralesional IFN alfa, imiquimod, and PDT.

- Abbas MA:** Wide local excision for Buschke-Löwenstein tumor or circumferential carcinoma in situ. *Tech Coloproctol* 2011; 15(3):313–318.
- Assaf C, et al:** Verrucous carcinoma of the axilla: case report and review. *J Cutan Pathol* 2004; 31:199.
- Bhushan M, et al:** Carcinoma cuniculatum of the foot assessed by magnetic resonance scanning. *Clin Exp Dermatol* 2001; 26:419.
- Cassarino DS, et al:** Cutaneous squamous cell carcinoma: a comprehensive clinicopathologic classification. Part One. *J Cutan Pathol* 2006; 33:191.
- D’Aniello C, et al:** Verrucous “cuniculatum” carcinoma of the sacral region. *Br J Dermatol* 2000; 143:459.
- Ghosh S, et al:** Squamous cell carcinoma developing in a cutaneous lichen planus lesion: a rare case. *Case Rep Dermatol Med* 2014; 2014:205638.
- Gordon DK, et al:** Verrucous carcinoma of the foot, not your typical plantar wart: a case study. *Foot (Edinb)* 2014; 24(2):94–98.
- Huang SH, et al:** Truths and myths about radiotherapy for verrucous carcinoma of larynx. *Int J Radiat Oncol Biol Phys* 2009; 73(4):1110–1115.
- Kanik AB, et al:** Penile verrucous carcinoma in a 37-year-old circumcised man. *J Am Acad Dermatol* 1997; 37:329.
- Koch H, et al:** Verrucous carcinoma of the skin: long-term follow-up results following surgical therapy. *Dermatol Surg* 2004; 30:1124.
- Narayana GP, Sandhya I:** Verrucous carcinoma of the finger: a rare site of occurrence. *Indian Dermatol Online J* 2014; 5(2):218–219.
- Walvekar RR, et al:** Verrucous carcinoma of the oral cavity: a clinical and pathological study of 101 cases. *Oral Oncol* 2009; 45(1):47–51.

## BOWEN'S DISEASE (SQUAMOUS CELL CARCINOMA IN SITU)

Bowen's disease (BD) is intraepidermal SCC. Multiple possible agents can induce BD, including HPV of certain types, arsenic exposure, and sun exposure. An association with the Merkel cell polyomavirus has been reported in immunosuppressed patients. The origin of the cells developing into BD is unknown but might be a pluripotential epidermal cell. BD may ultimately become invasive. When it does, it may have an aggressive biologic behavior.

### Clinical features

Bowen's disease may be found on any part of the body as an erythematous, slightly scaly and crusted, noninfiltrated



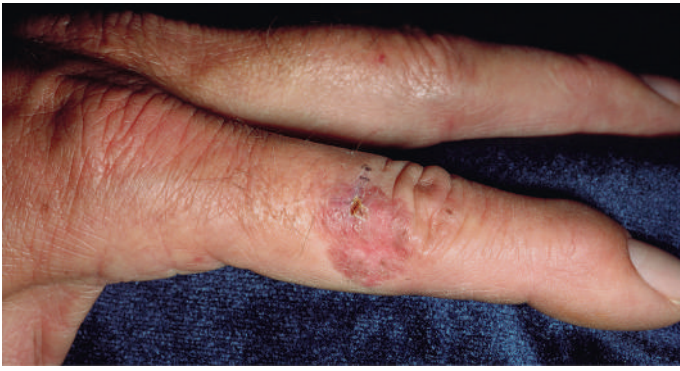

Fig. 29-24 Bowen's disease.

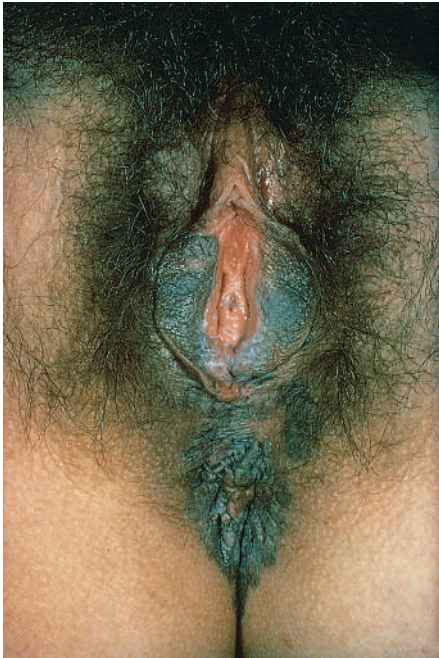


Fig. 29-25 Bowen's disease.

patch from a few millimeters to many centimeters in diameter (Fig. 29-24). The lesion is sharply defined. The scale may be pronounced enough for the lesion to be mistaken for psoriasis, or the plaque may have a stuck-on appearance and be mistaken for a broad, sessile seborrheic keratosis. Papillated keratotic lesions can occur. When BD occurs on the vulvar skin, vaginal mucosa, or perianal areas, it may be deeply pigmented (Fig. 29-25). Infrequently, BD may be pigmented elsewhere. Invasion is often indicated by the development of an exophytic, endophytic, or ulcerative component. A rare but particularly difficult clinical scenario is the elderly female patient with multicentric BD of the shins.

As the lesion slowly enlarges, spontaneous cicatrization may develop in portions of the lesion. When the intraepithelial growth becomes invasive, the lesion may appear ulcerated and fungating. The squamous carcinoma that evolves from BD tends to be more aggressive than SCC arising in actinic keratosis. When SCC in situ occurs as a velvety plaque on the glans penis, it is referred to as erythroplasia of Queyrat (see later discussion).

Around or beneath the nail, BD can be difficult to diagnose. It can present as a red (erythronychia) or black/brown (melanonychia) longitudinal band of several millimeters in width. HPV may be associated with these lesions, which should be biopsied.

## Histopathology

The atypical keratinocytes may invade the adjacent epidermis in a buckshot or clonal nested pattern. With time, they may replace the entire epidermis, often with deep, full-thickness involvement of adnexal structures, especially the hair follicles. The epidermis shows hyperkeratosis, parakeratosis, and broad acanthosis or anastomosis of adjacent rete ridges. Epidermal maturation is absent, so the epidermis appears disorganized, and individually keratinizing cells and atypical cells are seen at all levels of the epidermis. There is, however, a sharp delineation between dermis and epidermis, and the basement membrane is intact. The upper dermis usually shows a chronic inflammatory infiltrate. Although the cells tend to be anaplastic with a high nuclear/cytoplasmic ratio, variants with smaller nuclei and abundant cytoplasm exist, and transitional areas between the patterns may be seen. Invasive lesions of BD tend to have a squamoid to basaloid appearance, with central necrosis. Adnexal differentiation may be present.

## Differential diagnosis

Frequently, BD is misdiagnosed as psoriasis, superficial multicentric BCC, tinea corporis, nummular eczema, seborrheic keratosis, or actinic keratosis. Paget's disease, especially the extramammary type, may mimic BD not only clinically but also histologically. There is no dyskeratosis in Paget's disease, and the intervening nonvacuolated epidermal cells are not atypical. Stains for mucin and carcinoembryonic antigen (CEA) are positive in Paget's disease and negative in pagetoid BD. BD may be heavily pigmented, especially when occurring in the anogenital region. Lesions of bowenoid papulosis show a histologic spectrum from genital warts with buckshot atypia to full-thickness atypia indistinguishable from BD. If the lesions are multicentric and behave as genital warts, the term bowenoid papulosis may be applied. Treatment is guided completely by the clinical pattern. Genital SCC is induced by high-risk HPV, so bowenoid papulosis represents the initial clinical lesion in the progression from HPV infection to carcinoma. There is no clear boundary where bowenoid papulosis stops and SCC in situ begins.

## Treatment

Topical treatment of SCC in situ with cryotherapy and topical 5-FU has been disappointing because of a high recurrence rate. Imiquimod 5% cream, applied once daily for up to 16 weeks, seems to be effective enough to be recommended as a therapeutic option. Response rates have been as high as 90%. It may allow treatment of large lesions that might be difficult to approach surgically. Combination treatment with imiquimod 5% cream, three times a week, and 5% 5-FU, twice daily (except at the times of the imiquimod application), has also been reported effective. Tazarotene could be added to this treatment for hyperkeratotic lesions or to enhance penetration. PDT can be considered.

Simple excision of small lesions is a reasonable treatment option. Large, poorly defined lesions, or lesions in which preservation of normal tissue is critical, are indications for Mohs microsurgery. Other surgical techniques to treat SCC in situ are described in Chapter 37. Curettage and desiccation may also be performed, but recurrence may occur if extension down the follicles is not eradicated. Lesions of the lower legs are particularly problematic, because they are often multiple and in elderly persons are often found in conjunction with significant venous insufficiency. Any form of therapy may

result in chronic leg ulceration in this setting. Using a compression bandage should be considered after surgery, similar to that applied to a chronic leg ulcer, to help prevent ulceration.

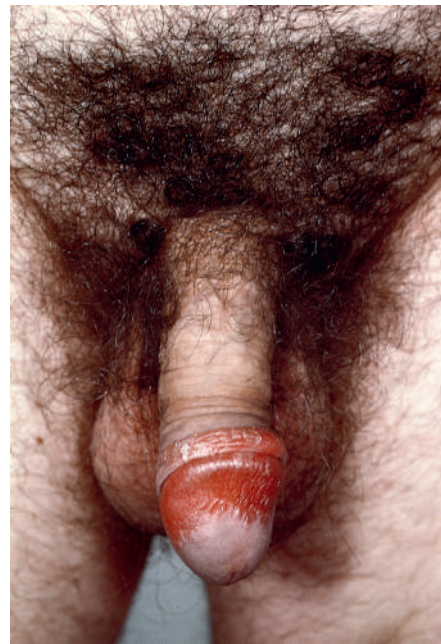- Alessi SS, et al:** Treatment of cutaneous tumors with topical 5% imiquimod cream. *Clinics (Sao Paulo)* 2009; 64(10):961–966.
- Ball SB, et al:** Treatment of cutaneous Bowen's disease with particular emphasis on the problem of lower leg lesions. *Australas J Dermatol* 1998; 39:63.
- Chen S, et al:** Immunohistochemical analysis of the mammalian target of rapamycin signalling pathway in extramammary Paget's disease. *Br J Dermatol* 2009; 161:357.
- Christensen E, et al:** Guidelines for practical use of MAL-PDT in non-melanoma skin cancer. *J Eur Acad Dermatol Venereol* 2010; 24(5):505–512.
- De Berker DA, et al:** Localized longitudinal erythronychia: diagnostic significance and physical explanation. *Arch Dermatol* 2004; 140:1253.
- Gonzalez-Perez R, et al:** Metastatic squamous cell carcinoma arising in Bowen's disease of the palm. *J Am Acad Dermatol* 1997; 36:635.
- Leibovitch I, et al:** Cutaneous squamous carcinoma in situ (Bowen's disease): treatment with Mohs micrographic surgery. *J Am Acad Dermatol* 2005; 52(6):997–1002.
- Maury G, et al:** Multiple Bowen disease of the lower limbs in elderly women: a rare clinical subset involving therapeutic difficulties. *Ann Dermatol Venereol* 2009; 136(6-7):508–512.
- Modi G, et al:** Combination therapy with imiquimod, 5-fluorouracil, and tazarotene in the treatment of extensive radiation-induced Bowen's disease of the hands. *Dermatol Surg* 2010; 36(5):694–700.
- Morton CA, et al:** British Association of Dermatologists' guidelines for the management of squamous cell carcinoma in situ (Bowen's disease) 2014. *Br J Dermatol* 2014; 170(2):245–260.
- Neubert T, Lehmann P:** Bowen's disease: a review of newer treatment options. *Ther Clin Risk Manag* 2008; 4(5):1085–1095.
- Saito T, et al:** Subungual Bowen disease revealed by longitudinal melanonychia. *J Am Acad Dermatol* 2012; 67(5):e240–e241.
- Shimizu A, et al:** Human papillomavirus type 56-associated Bowen disease. *Br J Dermatol* 2012; 167(5):1161–1164.
- Truchuelo M, et al:** Effectiveness of photodynamic therapy in Bowen's disease: an observational and descriptive study in 51 lesions. *J Eur Acad Dermatol Venereol* 2012; 26(7):868–874.
- Westers-Attema A, et al:** Photodynamic therapy in Bowen's disease: influence of histological features and clinical characteristics on its success. *Dermatology* 2014; Nov 13 [Epub ahead of print.]

## ERYTHROPLASIA OF QUEYRAT

Erythroplasia of Queyrat is SCC in situ of the glans penis or prepuce. SCC in situ on the penile shaft also occurs. Both conditions are caused by high-risk HPV types (16, 18, 31, 35). Clinically, erythroplasia of Queyrat is characterized by single or multiple, fixed, well-circumscribed, erythematous, moist, velvety or smooth, red-surfaced plaques on the glans penis (Fig. 29-26). Uncircumcised men, usually over age 40, are most often affected, and when SCC in situ affects the penile shaft, it is usually distally under the foreskin. The differential diagnosis includes Zoon balanitis, candidiasis, penile psoriasis, irritant balanitis, and extramammary Paget's disease. A biopsy is usually indicated to confirm the diagnosis. The intensity of the inflammatory infiltrate under lesions of erythroplasia of Queyrat can be great, and plasma cells can be numerous. This may lead to the histologic misdiagnosis of both erythroplasia and Zoon balanitis occurring simultaneously or sequentially.

Since red lesions on the glans of elderly uncircumcised men are common, the following factors suggest that a biopsy is indicated:

1. The lesion is fixed (does not move or resolve).
2. The patient lacks other stigmata of psoriasis or another skin disease that could affect the glans penis.
3. The patient's sexual partner has cervical dysplasia.
4. The lesion does not resolve with effective topical therapy for irritant balanitis, candidiasis, or psoriasis.



**Fig. 29-26**  
Erythroplasia of Queyrat.

Once the diagnosis of SCC in situ of the penis is made, the patient's sex partner(s) should be referred for evaluation. Sexual partners of men with SCC of the penis are more likely to develop preinvasive and invasive cancer of the cervix or anus.

Progression to invasive SCC is more common in erythroplasia of Queyrat than in BD of the nongenital skin, and the resulting SCCs are more aggressive and tend to metastasize earlier than those that develop in BD of the nongenital skin. There is no evidence of an increase in internal malignancy in patients with erythroplasia.

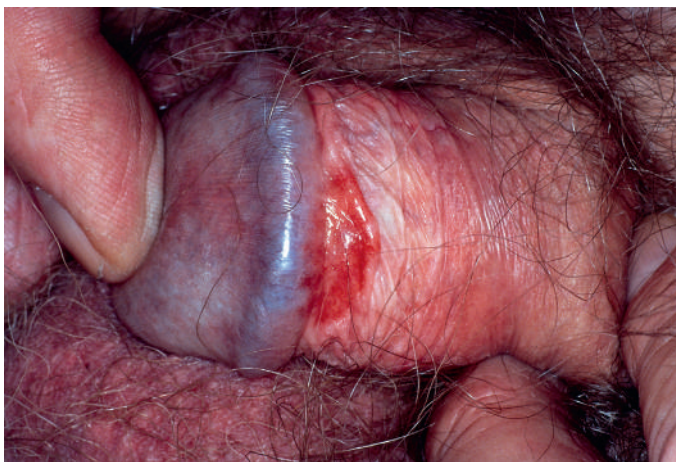Topical therapy can be effective in the treatment of erythroplasia of Queyrat and has the advantage that it can identify and treat areas not visible clinically. Topical 5% 5-FU cream applied once daily under occlusion (with the foreskin or a condom) can be effective. It will induce a brisk reaction and superficial erosion, which can be uncomfortable. Treatment is continued for 3–12 weeks, depending on the response. Imiquimod cream 5%, applied between once daily and three times weekly will similarly induce a significant reaction and may clear the lesion after 3–12 weeks. Careful follow-up is required, especially for the first few years. Surgical modalities such as excision, laser therapy, and PDT are reserved for patients failing topical treatments. Radiation therapy can also be effective.

- Arlette JP:** Treatment of Bowen's disease and erythroplasia of Queyrat. *Br J Dermatol* 2003; 149:43.
- Divakaruni AK, et al:** Erythroplasia of Queyrat with Zoon's balanitis: a diagnostic dilemma. *Int J STD AIDS* 2008; 19:861.
- Fai D, et al:** Methyl-aminolevulinic photodynamic therapy for the treatment of erythroplasia of Queyrat in 23 patients. *J Dermatolog Treat* 2012; 23(5):330–332.
- Micali G, et al:** Erythroplasia of Queyrat treated with imiquimod 5% cream. *J Am Acad Dermatol* 2006; 55(5):901–903.
- Schmitz L, et al:** Optical coherence tomography imaging of erythroplasia of Queyrat and treatment with imiquimod 5% cream: a case report. *Dermatology* 2014; 228(1):24–26.

## BALANITIS PLASMACELLULARIS (ZOON BALANITIS)

Balanitis plasmacellularis is also known as balanoposthitis chronica circumscripta plasmacellularis or Zoon balanitis.





**Fig. 29-27** Zoon balanitis.

Zoon balanitis represents about 7% of persistent genital lesions biopsied for diagnosis. It is a benign inflammatory lesion of the glans penis, which histologically demonstrates a plasma cell–rich infiltrate. The plasma cell infiltrate, while characteristic, may not be present in all lesions of this type, and in fact, some researchers believe there is a spectrum of histology in idiopathic, benign, nonscarring balanitis, from lesions containing few plasma cells to lesions containing many plasma cells. Clinically, Zoon balanitis is characterized by a red patch, which is usually sharply demarcated and usually on the inner surface of the prepuce or the glans penis (Fig. 29-27). The lesion is erythematous, moist, and shiny. It occurs as a single lesion but may consist of several confluent macules. It is asymptomatic and does not produce inguinal adenopathy. Uncircumcised men from ages 24 to 85 are most often affected. As with erythroplasia of Queyrat, presence of the foreskin constitutes a significant risk factor, and the disease is rarely seen in circumcised men.

Vulvitis chronica plasmacellularis is the counterpart of balanitis in women. The vulva shows a striking, lacquerlike luster. Erosions, punctate hemorrhage, synechia, and a slate to ochre pigmentation may supervene.

Plasmacytosis circumorificialis is the same disease on the oral mucosa, lips, cheeks, and tongue. The differential diagnosis of Zoon balanitis is penile psoriasis, lichen planus, lichen sclerosus, and SCC in situ. Histologically, the epidermis is atrophic, with flattened diamond-shaped keratinocytes and mild spongiosis. In the papillary dermis, a band of infiltrate consisting almost exclusively of plasma cells is present. Dilated vessels are also seen. This picture is strikingly different from that of the main clinical differential diagnosis, erythroplasia of Queyrat, in which the epidermis is principally involved, with atypia of keratinocytes throughout the entire epithelium. HPV has not been detected.

Topical corticosteroids, alone or in combination with anti-candidal treatment, are helpful in patients with Zoon balanitis. Potent topical steroids, pimecrolimus cream 1%, tacrolimus ointment 0.1%, and imiquimod cream 5% have all been reported effective in select cases. Circumcision may be curative. Laser ablation and photodynamic therapy can also be effective.

**Alessi E, et al:** Review of 120 biopsies performed on the balanopreputial sac: from Zoon's balanitis to the concept of a wider spectrum of inflammatory non-cicatricial balanoposthitis. *Dermatology* 2004; 208:120.

**Bardazzi F, et al:** Two cases of Zoon's balanitis treated with pimecrolimus 1% cream. *Int J Dermatol* 2008; 47:198.

**Fernández-Aceñero MJ, Córdova S:** Zoon's vulvitis (vulvitis circumscripta plasmacellularis). *Arch Gynecol Obstet* 2010; 282(3):351–352.

**Kumar B, et al:** Plasma cell balanitis: clinicopathologic study of 112 cases and treatment modalities. *J Cutan Med Surg* 2006; 10(1):11–15.

**Mallon E, et al:** Circumcision and genital dermatoses. *Arch Dermatol* 2000; 136(3):350–354.

**Marconi B, et al:** Zoon's balanitis treated with imiquimod 5% cream. *Eur J Dermatol* 2010; 20:134.

**Retamar RA, et al:** Zoon's balanitis: presentation of 15 patients, five treated with a carbon dioxide laser. *Int J Dermatol* 2003; 42:305.

**Tang A, et al:** Plasma cell balanitis of Zoon: response to Trimovate cream. *Int J STD AIDS* 2001; 12:75.

**Toker SC, et al:** Zoon's balanitis in a circumcised man. *J Am Acad Dermatol* 2007; 57(2 Suppl):S6–S7.

**Torchia D, Cappugi P:** Photodynamic therapy for Zoon balanitis. *Eur J Dermatol* 2014; Oct 21 [Epub ahead of print.]

**Wollina U:** Ablative erbium:YAG laser treatment of idiopathic chronic inflammatory non-cicatricial balanoposthitis (Zoon's disease): a series of 20 patients with long-term outcome. *J Cosmet Laser Ther* 2010; 12:120–123.

## PSEUDOEPITHELIOMATOUS KERATOTIC AND MICACEOUS BALANITIS

Pseudoepitheliomatous keratotic and micaceous balanitis was described by Lortat-Jacob and Civatte in 1966. The lesions occurring on the glans penis are verrucous excrescences with scaling. Ulcerations, cracking, and fissuring on the surface of the glans are frequently present. The keratotic scale is usually micaceous and resembles psoriasis. Most patients are over age 50 and frequently have been circumcised for phimosis in adult life. Histologically, there is marked hyperkeratosis and parakeratosis, as well as pseudoepitheliomatous hyperplasia. Acanthotic masses give rise to a craterlike configuration. HPV has not been detected. This lesion is probably best considered as a form of verrucous carcinoma. The treatment is usually surgical and might include Mohs microsurgery. Topical 5-FU has been effective, but the hyperkeratotic scale may make penetration suboptimal. If topical chemotherapy is used, post-treatment biopsies are recommended.

**Hanumaiah B, et al:** Pseudoepitheliomatous keratotic and micaceous balanitis: a rare condition successfully treated with topical 5-fluorouracil. *Indian J Dermatol* 2013; 58(6):492.

**Murthy PS, et al:** Pseudoepitheliomatous, keratotic, and micaceous balanitis. *Indian J Dermatol* 2010; 55(2):190–191.

**Perry D, et al:** Pseudoepitheliomatous, keratotic, and micaceous balanitis: case report and review of the literature. *Dermatol Nurs* 2008; 20:117.

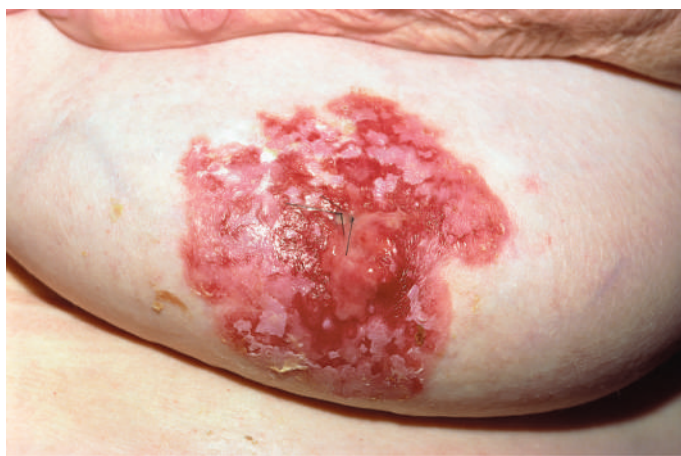**Sardesai VR, et al:** Pseudoepitheliomatous keratotic and micaceous balanitis with malignant transformation. *Indian J Sex Transm Dis* 2013; 34(1):38–40.

**Zhu H et al:** Treatment of pseudoepitheliomatous, keratotic, and micaceous balanitis with topical photodynamic therapy. *Int J Dermatol* 2014; Sep 30 [Epub ahead of print.]

## PAGET'S DISEASE OF THE BREAST

### Clinical features

Page's disease (PD) of the nipple affects women primarily (there are very rare male cases). Between 1% and 4% of breast carcinomas present with PD. It is characterized by a unilateral, sharply marginated, erythematous, and at times crusted patch or plaque affecting the nipple and occasionally the areola (Fig. 29-28). At times, it may be hyperpigmented and may mimic melanoma. As the lesion grows, it may spread to the areola, and even beyond, making the areolae appear asymmetric. Over months or years, it may become eroded. The nipple may or may not be retracted. In advanced cases, a subadjacent mass and ipsilateral axillary adenopathy may be palpable. About



**Fig. 29-28** Paget's disease of the breast.

5% of patients have PD without confirmed evidence of underlying carcinoma, and the remaining 95% have either an invasive or an intraductal carcinoma in proportions of 35–65%, depending on the reporting center. In rare cases, even when no underlying carcinoma is found on surgical removal, the sentinel node may be positive.

## Histopathology

Paget's disease is characterized by the presence of Paget cells: large, round, pale-staining cells with large nuclei. Intercellular bridges are absent. The cells appear singly or in small nests between the squamous cells. Usually, acanthosis is present, but the granular layer is preserved, and there is no parakeratosis, but atypical cells may be "spat out" into the stratum corneum. Frequently, a layer of basal cells separates the Paget cells from the basement membrane and is seen crushed beneath the nests of Paget cells. This histologic feature helps to distinguish PD from pagetoid melanoma and Bowen's disease. In the dermis, an inflammatory reaction is often present. Unusual variants include PD with marked intraepidermal melanin and an acantholytic anaplastic form.

The Paget cell is PAS positive, diastase resistant, almost always HER-2/neu positive, and EMA positive; it stains with CAM 5.2 and CK 7. This staining profile and negativity for S-100 and cytokeratins 5/6 allow clear distinction from pagetoid melanoma and pagetoid Bowen's disease. CEA positivity is variable in PD of the breast, being positive in 0–50% of PD cases compared with virtually 100% of extramammary PD cases. The Toker cell, a normal clear cell of the breast, stains similarly but is HER-2/neu negative. It has been proposed as the precursor cell of PD and may be so for some cases of PD with no underlying breast cancer.

## Diagnosis

The presence of unilateral eczema of the nipple recalcitrant to simple treatment should lead to suspicion of PD, and the lesion should be biopsied. The presence of bilateral lesions suggests a benign process, usually atopic dermatitis. Papillary adenoma of the nipple clinically resembles PD, but on biopsy it shows a papillary and adenomatous growth in the dermis with connection to the surface. There is a lining of apocrine-type secretory epithelium. Hyperkeratosis of the nipple and areola may occasionally be unilateral but histologically reveals only hyperkeratosis, acanthosis, and papillomatosis.

## Treatment

Patients with PD of the breast should be referred to a center with expertise in the management of breast cancer. Prognosis depends on the presence of an underlying invasive ductal carcinoma or nodal metastases. Patients presenting with a palpable breast mass typically have more advanced disease and lower 5-year survival. Some data suggest PD itself may be an independent marker of worse prognosis of invasive breast carcinoma (IBC) compared with IBC of similar stage and characteristics without PD.

**Bernardi M, et al:** Paget disease in a man. *Arch Dermatol* 2008; 144:1660.

**Brummer O, et al:** HER-2/neu expression in Paget's disease of the vulva and the female breast. *Gynecol Oncol* 2004; 95:336.

**Caliskan M, et al:** Paget's disease of the breast: the experience of the European Institute of Oncology and review of the literature. *Breast Cancer Res Treat* 2008; 112:513.

**Garijo MF, et al:** An overview of the pale and clear cells of the nipple epidermis. *Histol Histopathol* 2009; 24:367.

**Hida T, et al:** Pigmented mammary Paget's disease mimicking melanoma: report of three cases. *Eur J Dermatol* 2012; 22(1):121–124.

**Lester T, et al:** Different panels of markers should be used to predict mammary Paget's disease associated with in situ or invasive ductal carcinoma of the breast. *Ann Clin Lab Sci* 2009; 39:17.

**Ling H, et al:** Patients with nipple-areola Paget's disease and underlying invasive breast carcinoma have very poor survival: a matched cohort study. *PLoS One* 2013; 8(4):e61455.

**Liu W, et al:** Mammary Paget's disease and extra-mammary Paget's disease: two morphologically similar but biologically different diseases. *J Cutan Pathol* 2010; 37(11):1145–1149.

**Miller L, et al:** Erosive adenomatosis of the nipple: a benign imitator of malignant breast disease. *Cutis* 1997; 59:91.

**Montemarano AD, et al:** Superficial papillary adenomatosis of the nipple: a case report and review of the literature. *J Am Acad Dermatol* 1997; 36:871.

**Nofech-Mozes S, Hanna W:** Toker cells revisited. *Breast J* 2009; 15:394.

**Sandoval-Leon AC, et al:** Paget's disease of the nipple. *Breast Cancer Res Treat* 2013; 141(1):1–12.

**Tanaka VD, et al:** Mammary and extramammary Paget's disease: a study of 14 cases and the associated therapeutic difficulties. *Clinics (Sao Paulo)* 2009; 64:599.

**Trebska-McGowan K, et al:** Update on the surgical management of Paget's disease. *Gland Surg* 2013; 2(3).

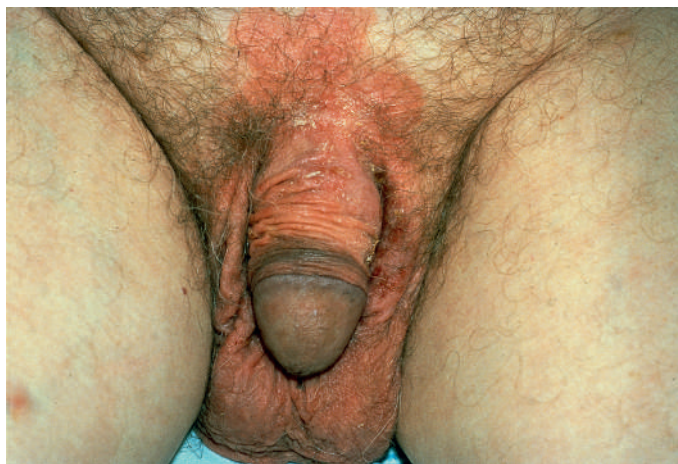**Wang CC, et al:** Pigmented mammary Paget's disease presenting as an enlarged areola. *Breast J* 2009; 15:421.

**Zhao L, et al:** Diagnostic role of immunohistochemistry in the evaluation of breast pathology specimens. *Arch Pathol Lab Med* 2014; 138(1):16–24.

## EXTRAMAMMARY PAGET'S DISEASE

Extramammary Paget's disease (EMPD) is much less common than PD. It affects adults, usually between 65 and 70 years of age. The vulva is the most common location, except perhaps in China, where penoscrotal EMPD is reported in large numbers. Penoscrotal EMPD is uncommon in black persons. EMPD presents most often as a unifocal process, but multifocal lesions may occur, including cases involving as many as four anatomic locations simultaneously. Axillary lesions typically appear with or after genital lesions and are more frequent in men. Lesions typically affect apocrine sites, including the groin (vulva, scrotum, perianal area, penis, inguinal folds) (Fig. 29-29) and axilla, but rare cases can affect other anatomic locations. The lesions of EMPD are typically erythematous, well-demarcated plaques measuring several centimeters in diameter. They may involve any region of the genitalia, including the penis, scrotum, vulva, or perianal skin. The condition often goes undiagnosed for months to years, as the misdiagnoses of pruritus ani, a fungal infection, contact dermatitis,





**Fig. 29-29** Extramammary Paget's disease.

lichen sclerosus, or intertrigo are made. A nonhealing banal eczematous patch persisting in the anogenital or axillary region should raise concern about EMPD and trigger a biopsy. Intense pruritus is common. Bleeding, nodularity, and induration are late signs. Underpants erythema, or redness in the whole genital area, may be indicative of widespread lymphatic involvement in the pelvic basin and is a poor prognostic sign. Lesions may be hyperpigmented or hypopigmented.

Extramammary PD can be divided into the following four forms:

1. Primary EMPD (arising intraepidermally), with or without invasion
2. EMPD associated with an underlying apocrine carcinoma
3. EMPD associated with an underlying adjacent malignancy
4. EMPD associated with an underlying distant carcinoma

The majority of patients with EMPD do not have underlying carcinoma, and the process apparently begins as an intraepidermal neoplasm, which can then invade (invasive EMPD). The clinical appearance of all types of EMPD is identical. The location of the EMPD determines the percentage of patients who have other associated malignancies. In vulvar EMPD, 4–17% have an associated adnexal neoplasm, and 11–20% have a distant carcinoma of the breast, cervix, vagina, bladder, colon, rectum, ovary, liver, gallbladder, or skin. In perianal EMPD, an underlying adnexal carcinoma occurs in 7–10% of cases, and a distant carcinoma of the rectum, stomach, breast, or ureter is present in 15–45%. Penoscrotal EMPD has an associated carcinoma of the prostate, bladder, testicles, ureter, or kidney in 11% of cases. In a large series from The Netherlands, underlying malignancy was found in 35% of patients with EMPD. In all patients with EMPD, an extensive and targeted cancer workup should be undertaken, depending on the histologic staining pattern (see next) and the location. Prolonged follow-up and malignancy screening should be considered, because EMPD patients have an increased risk of secondary malignancy at these sites even years after the initial EMPD diagnosis.

Histologically, the findings are similar to those found in mammary PD: acanthosis, hyperkeratosis, parakeratosis, and pale, vacuolated Paget cells in suprabasilar levels of the epithelium. Signet ring Paget cells are present in a small minority of cases. Paget cells can form nests that compress basal keratinocytes. Conventional histopathologic findings are similar in both primary cutaneous EMPD and most cases in which EMPD is caused by an underlying malignancy. Mucin,

stainable by alcian blue or colloidal iron, is present in the majority of cases. The finding of cytoplasmic mucin makes a urothelial origin unlikely.

Significant effort has been put into developing a series of stains that would clearly distinguish PD from EMPD and identify patients who have underlying carcinomas, either local apocrine cancers or distant neoplasms. This involves examining the expression of various cytokeratins, mucins, and other products specific to certain organ systems. RCAS1 may be very sensitive for EMPD cells, and measurement of serum levels of this marker can be used to monitor patients with invasive disease, analogous to following prostate-specific antigen (PSA) in patients with treated prostate cancer. In vulvar and perianal EMPD, two distinct staining patterns have been defined. CK7+/CK20-/GCDFP15 negative is called the type I or endodermal pattern and is associated with EMPD and distant cancers. Ectodermal or cutaneous pattern (type II) stains the atypical cells CD7+/CK20-/GCDFP15 positive. This is associated with a cutaneous origin for the EMPD. In addition, tissue-specific markers may at times identify the distant tumor responsible for the EMPD. Immunohistochemical studies can provide some guidance in distinguishing between these possibilities, largely through identifying antigens that are not found on the cells of primary cutaneous EMPD. The specificity of these studies is limited, but a positive finding of an immunoprofile that differs from that of typical primary EMPD should lead to a thorough investigation. Primary cutaneous EMPD has an immunophenotype similar to that of apocrine epithelium: cytokeratin 7 positive, cytokeratin 20 negative, and CEA positive. Cases caused by spread from an underlying bladder carcinoma are typically uroplakin and p63 positive. Those caused by rectal carcinoma are usually CK7 negative, CDX2 positive, and CK20 positive. Prostatic adenocarcinoma can also result in EMPD and can be identified by staining for PSA or the marker P504S. Unfortunately, PSA positivity can be seen in female patients with EMPD, and not all males with PSA positivity of the EMPD cells have underlying prostate cancer. The p63 staining in vulvar EMPD suggests an underlying urothelial carcinoma. Staining with AKT, CDK2, mTOR, and other proteins in the mTOR pathway suggests that this pathway may be important in the pathogenesis of EMPD.

Extramammary PD can remain within the epithelium or “invade” the dermis. “Invasive” EMPD has a high rate of metastasis and a very poor prognosis. Sentinel node examination of patients with “invasive” EMPD should be considered because it predicts the risk for metastasis.

Surgical removal is the treatment of choice, with Mohs microsurgery having a better outcome than fixed surgical margins. Despite what appears to be adequate clinical margins, recurrence rates are high because of the discontinuous and microscopic wide extension of EMPD. The recurrence rate after micrographic surgery is about 12% and more than 30% for standard 2-cm margins. Positive KI67 and PAS staining of surgical margins may suggest the need for wider excision. Imiquimod has been used with success in multiple reports, but follow-up is limited. Topical 5-FU, radiation therapy, PDT, and laser therapy have also been used. Intralesional IFN alfa-2b was beneficial in one case. Some cases of genital EMPD are HER-2/neu positive and have responded to trastuzumab, a monoclonal antibody directed against HER-2.

**Abe S, et al:** Quadruple extra-mammary Paget's disease. *Acta Derm Venereol* 2007; 87:80.

**Bae JM, et al:** Mohs micrographic surgery for extramammary Paget disease: a pooled analysis of individual patient data. *J Am Acad Dermatol* 2013; 68(4):632–637.

**Bagby CM, MacLennan GT:** Extramammary Paget's disease of the penis and scrotum. *J Urol* 2009; 182:2908.

**Challenor R, et al:** Multidisciplinary treatment of vulval extramammary Paget's disease to maintain sexual function: an imiquimod success story. *J Obstet Gynaecol* 2009; 29:252.

**Chen S, et al:** Immunohistochemical analysis of the mammalian target of rapamycin signalling pathway in extramammary Paget's disease. *Br J Dermatol* 2009; 161:357.

**Dai B, et al:** Primary invasive carcinoma associated with penoscrotal extramammary Paget's disease: a clinicopathologic analysis of 56 cases. *BJU Int* 2015; 115(1):153–160.

**Edey KA, et al:** Interventions for the treatment of Paget's disease of the vulva. *Cochrane Database Syst Rev* 2013; 10:CD009245.

**Feng CC, et al:** Positive Ki67 and periodic acid-Schiff mandates wider range of excision in scrotal extramammary Paget's disease. *Dermatol Surg* 2013; 39(3 Pt 1):381–386.

**Fujisawa Y, et al:** Penile preservation surgery in a case of extramammary Paget's disease involving the glans penis and distal urethra. *Dermatol Surg* 2008; 34:823.

**Fukui T, et al:** Photodynamic therapy following carbon dioxide laser enhances efficacy in the treatment of extramammary Paget's disease. *Acta Derm Venereol* 2009; 89:150.

**Hata M, et al:** Postoperative radiation therapy for extramammary Paget's disease. *Br J Dermatol* 2014; Aug 19 [Epub ahead of print.]

**Hatta N, et al:** Extramammary Paget's disease: treatment, prognostic factors and outcome in 76 patients. *Br J Dermatol* 2008; 158:313.

**Hendi A, et al:** Unifocality of extramammary Paget disease. *J Am Acad Dermatol* 2008; 59:811.

**Hilliard NJ, et al:** Pigmented extramammary Paget's disease of the axilla mimicking melanoma: case report and review of the literature. *J Cutan Pathol* 2009; 36:995.

**Im M, et al:** Extramammary Paget's disease of the scrotum with adenocarcinoma of the stomach. *J Am Acad Dermatol* 2007; 57:S43.

**Karam A, Dorigo O:** Increased risk and pattern of secondary malignancies in patients with invasive extramammary Paget disease. *Br J Dermatol* 2014; 170(3):661–671.

**Liegl B, et al:** Mammary and extramammary Paget's disease: an immunohistochemical study of 83 cases. *Histopathology* 2007; 50:439.

**Luyten A, et al:** Treatment of extramammary Paget disease of the vulva with imiquimod: a retrospective, multicenter study by the German Colposcopy Network. *J Am Acad Dermatol* 2014; 70(4):644–650.

**Minicozzi A, et al:** Perianal Paget's disease: presentation of six cases and literature review. *Int J Colorectal Dis* 2010; 25:1.

**Miyamoto T, et al:** Axillary apocrine carcinoma with Paget's disease and apocrine naevus. *Clin Exp Dermatol* 2009; 34:e110.

**Murata Y, Kumano K:** Multicentricity of extramammary Paget's disease. *Eur J Dermatol* 2007; 17:164.

**Murata Y, et al:** Underpants-pattern erythema. *J Am Acad Dermatol* 1999; 40:949.

**Panasiti V, et al:** Intralesional interferon alfa-2b as neoadjuvant treatment for perianal extramammary Paget's disease. *J Eur Acad Dermatol Venereol* 2008; 22:522.

**Pascual JC, et al:** Extramammary Paget's disease of the groin with underlying carcinoma and fatal outcome. *Clin Exp Dermatol* 2008; 33:595.

**Perez DR, et al:** Management and outcome of perianal Paget's disease: a 6-decade institutional experience. *Dis Colon Rectum* 2014; 57(6):747–751.

**Perrotto J, et al:** The role of immunohistochemistry in discriminating primary from secondary extramammary Paget Disease. *Am J Dermatopathol* 2010; 32(2):137–143.

**Sanderson P, et al:** Imiquimod therapy for extramammary Paget's disease of the vulva: a viable non-surgical alternative. *J Obstet Gynaecol* 2013; 33(5):479–483.

**Spiliopoulos D, et al:** Vulvar and breast Paget's disease with synchronous underlying cancer: a unique association. *Arch Gynecol Obstet* 2009; 280:313.

**Wang HW, et al:** A prospective pilot study to evaluate combined topical photodynamic therapy and surgery for extramammary Paget's disease. *Lasers Surg Med* 2013; 45(5):296–301.

**Wang Z, et al:** Penile and scrotal Paget's disease: 130 Chinese patients with long-term follow-up. *BJU Int* 2008; 102:485.

**Zhu Y, et al:** Clinicopathological characteristics, management and outcome of metastatic penoscrotal extramammary Paget's disease. *Br J Dermatol* 2009; 161:577.

## CLEAR CELL PAPULOSIS

Clear cell papulosis is an uncommon disorder that presents with multiple, minimally elevated, hypopigmented papules. Most cases have been reported in Asian or Hispanic children. Onset is usually before age 6 and may be as soon as 4 months of age. The eruption favors the pubic region, lower abdomen, and along the milk lines. Histology demonstrates mild acanthosis, decreased epidermal pigmentation, and the presence of single or small clusters of large clear cells in the basal and occasionally suprabasal layers of the epidermis. The cells are positive for EMA, CEA, and CD7, identical to Toker cells.

**Farley-Loftus R, et al:** Clear cell papulosis. *Dermatol Online J* 2008; 14:19.

**Sim JH, et al:** Clear cell papulosis of the skin: acquired hypomelanosis. *Arch Dermatol* 2011; 147(1):128–129.

**Tseng FW, et al:** Long-term follow-up study of clear cell papulosis. *J Am Acad Dermatol* 2010; 63(2):266–273.

**Wysong A, et al:** Clear-cell papulosis: a rare entity that may be misconstrued pathologically as normal skin. *Pediatr Dermatol* 2012; 29(2):195–198.

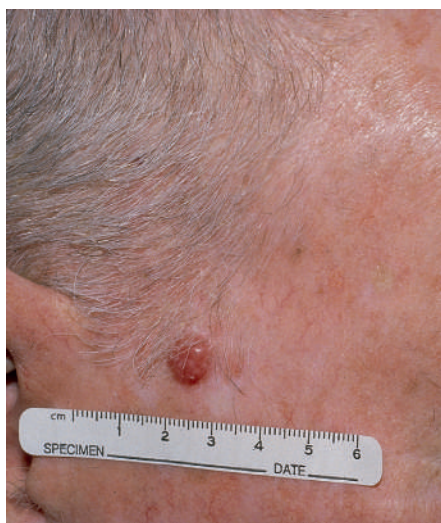**Yu Y, et al:** Clear cell papulosis: a connection of clear cells to Toker cells or Paget disease. *Arch Dermatol* 2009; 145:1066.

## MERKEL CELL CARCINOMA (TRABECULAR CARCINOMA)

Merkel cell carcinoma (MCC) was first described by Toker in 1972. The cell of origin is the Merkel cell, a slow-acting mechanoreceptor in the basal layer of the epidermis. Although still a rare tumor occurring at an incidence of about 0.44 per 100,000 population, MCC recently increased threefold over 15 years, an increased incidence of 8% per year. Melanoma, by comparison, increased at a rate of only 3% per year over the same period. More than 1500 MCCs occur yearly in the United States. This is a tumor of the elderly population, with 90% of cases found in persons older than 50, 76% in those over 65, and 72% in those over 70. The mean age is 76 in women and 74 in men. About 60% of MCC patients are men, and 95% occur in white people. There is strong evidence that MCC is induced by sun exposure. About 90% of cases occur on sun-exposed sites, with 27% of cases on the face, 9% on the scalp and neck (or 36% on the head and neck), 22% on the upper extremity, 15% on the lower extremity (37% on the extremities), and only 11% on the trunk. About 3% occur on the ear, eyelid, or lip. PUVA therapy is associated with an increased risk for MCC. Immunosuppression by organ transplantation, chronic lymphocytic leukemia, and HIV infection all substantially increase the risk for developing MCC, so that in some series, 8–15% of patients with MCC have some form of immune impairment.

Clinically, this tumor presents as a rapidly growing, nontender, red to violaceous nodule with a shiny surface (Fig. 29-30) and overlying telangiectasia. Most cases are *not* considered malignant by the dermatologist at biopsy. The acronym AEIOU has been suggested: asymptomatic/lack of tenderness, expanding rapidly, immune suppression, older than 50 years, and ultraviolet-exposed site on a person with fair skin. MCC is an aggressive tumor with a propensity for local recurrence and nodal and distant metastases. At presentation, about one third of cases have regional node involvement, and hematogenous spread will eventuate in at least one third of patients. Spontaneous remissions have been reported, primarily in women with head and neck tumors; this is most often associated with reduction of iatrogenic immunosuppression. The regression is rapid, but the MCC can recur after "spontaneous resolution." MCC can present as a metastatic disease without





**Fig. 29-30** Merkel cell carcinoma.

an evident primary tumor; such patients have a significantly better prognosis than those of the same stage with a known primary.

Approximately 80% of MCCs in North America and 25% of MCCs in Australia are associated with a virus, the Merkel cell polyomavirus (MCPyV). The virus is found integrated into the genome of the MCC when present, and all progenitor cells have the same viral genome, suggesting that the viral infection began at the time the neoplasia was developing, or before. MCC patients are more likely to be seropositive for MCPyV. Infection with this virus is widespread, with seroprevalence increasing from 30% in children younger than 5 to almost 80% in persons older than 50. Lymphoid tissue, especially the tonsils, seems to be the reservoir. The virus may behave similar to HPV, with increasing seroprevalence with exposure over time and spontaneous clearance in most adults. MCPyV can be recovered from about 4% of immunocompetent persons and 36% of immunosuppressed patients. This may explain the high risk for MCC with immunosuppression, analogous to the high risk of HPV-related neoplasia in immunosuppressed patients. MCPyV has also been reported in NMSCs in both immunocompetent and immunosuppressed patients. Bowen's disease, BCC, and SCC have been associated with viral infection in up to 40% of cases in some laboratories, but these results have not been reproduced and may represent laboratory overidentification. At the University of California, San Francisco, the rate is less than 1%. Normal skin infection has also been reported, and the viral copies in these NMSCs are much fewer than in MCC. The pathogenic role of MCPyV in NMSCs other than MCC is speculative. Visceral tumors and other small cell neuroendocrine tumors of other organ systems do *not* contain MCPyV, substantiating its role in the development of MCC.

Staging predicts prognosis and guides therapy. Sentinel lymph node biopsy (SLNB) should be performed at definitive excision of the primary tumor. One third of patients with no palpable adenopathy have a positive SLNB. The SLNB sample must be stained with CK20 (if the primary tumor is positive) to detect micrometastases. Computed tomography (CT) will detect metastatic disease in only 20% of MCC patients. Whether tumors less than 1 cm in diameter require SLNB is controversial, but even in small tumors, lymph node metastases can be found; in one study, 14% of those with 0.5-cm tumors had regional nodal involvement. Imaging with CT, magnetic resonance imaging (MRI), or positron emission tomography (PET) may be used to search for metastatic disease. Palpable lymph nodes must be sampled to exclude the presence of metastatic

disease. MCC patients who harbor MCPyV have a better prognosis (45% vs. 15% 5-year survival), and the MCC is more likely to present on an extremity. MCC should be treated expeditiously; patients have developed metastatic disease in the weeks awaiting definitive surgery.

The treatment of MCC should be directed by persons with expertise in managing this rare tumor. Therapy may need to be individualized, depending on various risk factors present. Many of these patients are elderly and may not be able to tolerate some of the recommended treatments. The goal of therapy for patients with only local disease or regional nodal metastases is cure and local control. This involves the combined use of surgery and radiation therapy in most cases. Radiation therapy alone can be efficacious and is recommended for patients unable to tolerate surgery. Radiation therapy is directed at both the primary site and the draining and/or regional lymph node basins in most cases and should be considered even if the sentinel lymph nodes are negative. Recurrence is seen in 46–76% of untreated lymph nodes. Even after Mohs surgery, radiation therapy reduces the local recurrence rate from 16% to near 0%. Prophylactic lymph node dissection enhances local control but does not improve survival. It is gradually being replaced with radiation therapy of the affected nodal basin. Locoregional recurrence remains a substantial problem in patients with MCC and is a poor prognostic sign. Therefore, the emerging consensus is that addressing the regional lymph nodes is crucial in therapy. Adjuvant chemotherapy has been disappointing because it does not prevent later development of metastatic, regional, or local disease; thus it is not recommended. MCC may be initially responsive to chemotherapy, but disease progression occurs. In the setting of metastatic MCC, chemotherapy would be considered palliative. Partial response was seen with use of a multikinase inhibitor, pazopanib.

Histologically, MCC is a dermal tumor that may extend into the subcutaneous tissue. The cells are about 15  $\mu$ m in diameter and have very scant cytoplasm and hyperchromatic nuclei with a distinctive smudged chromatin pattern. Mitoses and apoptotic cells are numerous. The cells are arranged in sheets and cords. Depth of invasion, lymphovascular involvement, and mitotic index may be poor prognostic histologic features. MCC must be distinguished from small cell lung cancer, lymphoma, neuroblastoma, small cell endocrine carcinoma, Ewing sarcoma, melanoma, and even BCC. Immunoperoxidase confirmation of the diagnosis and exclusion of other small cell tumors is required to establish the diagnosis. The tumor should be CK20 positive and thyroid transcription factor 1 (TTF-1) negative. CK20 staining is of the "perinuclear dot pattern." CK7 tends to stain small cell lung cancer and not MCC. MCC is negative for S-100 and leukocyte common antigen (LCA).

**Albores-Saavedra J, et al:** Merkel cell carcinoma demographics, morphology, and survival based on 3870 cases: a population based study. *J Cutan Pathol* 2010; 37(1):20–27.

**Andres C, et al:** Prevalence of MCPyV in Merkel cell carcinoma and non-MCC tumors. *J Cutan Pathol* 2010; 37(1):28–34.

**Assouline A, et al:** Clinical and therapeutic aspects in elderly patients with Merkel cell carcinoma: special focus on radiotherapy. *J Am Geriatr Soc* 2009; 57:1946.

**Boyer JD, et al:** Local control of primary Merkel cell carcinoma: review of 45 cases treated with Mohs micrographic surgery with and without adjuvant radiation. *J Am Acad Dermatol* 2002; 47:885.

**Carter JJ, et al:** Association of Merkel cell polyomavirus-specific antibodies with Merkel cell carcinoma. *J Natl Cancer Inst* 2009; 101:1510.

**Clarke CA, et al:** Risk of Merkel cell carcinoma after solid organ transplantation. *J Natl Cancer Inst* 2015; 107(2).

**Connelly T:** Regarding complete spontaneous regression of Merkel cell carcinoma. *Dermatol Surg* 2009; 35:721.

**Dauids M, et al:** Response to a novel multitargeted tyrosine kinase inhibitor pazopanib in metastatic Merkel cell carcinoma. *J Clin Oncol* 2009; 27:e97.

**DeCaprio JA:** Does detection of Merkel cell polyomavirus in Merkel cell carcinoma provide prognostic information? *J Natl Cancer Inst* 2009; 101:905.

**Faust H, et al:** Prospective study of Merkel cell polyomavirus and risk of Merkel cell carcinoma. *Int J Cancer* 2014; 134(4):844–848.

**Fields RC, et al:** Five hundred patients with Merkel cell carcinoma evaluated at a single institution. *Ann Surg* 2011; 254(3):465–475.

**Foote M, et al:** Merkel cell carcinoma: the prognostic implications of an occult primary in stage IIIB (nodal) disease. *J Am Acad Dermatol* 2012; 67:395.

**Gass JK, et al:** Multiple primary malignancies in patients with Merkel cell carcinoma. *J Eur Acad Dermatol Venereol* 2010; 24(5):601–603.

**Grotz TE, et al:** Natural history of Merkel cell carcinoma following locoregional recurrence. *Ann Surg Oncol* 2012; 19:2556.

**Heath M, et al:** Clinical characteristics of Merkel cell carcinoma at diagnosis in 195 patients: the AEIOU features. *J Am Acad Dermatol* 2008; 58:375.

**Howle J, Veness M:** Sentinel lymph node biopsy in patients with Merkel cell carcinoma: an emerging role and the Westmead hospital experience. *Australas J Dermatol* 2012; 53:26.

**Howle JR, et al:** Merkel cell carcinoma: an Australian perspective and the importance of addressing the regional lymph nodes in clinically node-negative patients. *J Am Acad Dermatol* 2012; 67:33.

**Hruby G, et al:** The important role of radiation treatment in the management of Merkel cell carcinoma. *Br J Dermatol* 2013; 169:975.

**Iyer JG, et al:** Relationships among primary tumor size, number of involved nodes, and survival for 8044 cases of Merkel cell carcinoma. *J Am Acad Dermatol* 2014; 70:637.

**Jouary T, et al:** Adjuvant prophylactic regional radiotherapy versus observation in stage I Merkel cell carcinoma: a multicentric prospective randomized study. *Ann Oncol* 2012; 23:1074.

**Kim JA, Choi AH:** Effect of radiation therapy on survival in patients with resected Merkel cell carcinoma: a propensity score surveillance, epidemiology, and end results database analysis. *JAMA Dermatol* 2013; 149(7):831–838.

**Koljonen V, et al:** Chronic lymphocytic leukaemia patients have a high risk of Merkel-cell polyomavirus DNA-positive Merkel-cell carcinoma. *Br J Cancer* 2009; 101:1444.

**Lemos BD, et al:** Pathologic nodal evaluation improves prognostic accuracy in Merkel cell carcinoma: analysis of 5823 cases as the basis of the first consensus staging system. *J Am Acad Dermatol* 2010; 63:751.

**Pape E, et al:** Radiotherapy alone for Merkel cell carcinoma: a comparative and retrospective study of 25 patients. *J Am Acad Dermatol* 2011; 65:983.

**Poulsen M, et al:** Factors influencing relapse-free survival in Merkel cell carcinoma of the lower limb: a review of 60 cases. *Int J Radiat Oncol Biol Phys* 2010; 76(2):393–397.

**Schwartz JL, et al:** Features predicting sentinel lymph node positivity in Merkel cell carcinoma. *J Clin Oncol* 2011; 29:1036.

**Shuda M, et al:** Human Merkel cell polyomavirus infection I. MCV T antigen expression in Merkel cell carcinoma, lymphoid tissues and lymphoid tumors. *Int J Cancer* 2009; 125:1243.

**Sihto H, et al:** Clinical factors associated with Merkel cell polyomavirus infection in Merkel cell carcinoma. *J Natl Cancer Inst* 2009; 101:938.

**Soltani AM, et al:** Merkel cell carcinoma of the hand and upper extremity: current trends and outcomes. *J Plast Reconstr Aesthet Surg* 2014; 67(3):e71–e77.

**Tai P, et al:** Management of Merkel cell carcinoma with emphasis on small primary tumors: a case series and review of the current literature. *J Drugs Dermatol* 2010; 9:105.

**Tarantola TI, et al:** Unknown primary Merkel cell carcinoma: 23 new cases and a review. *J Am Acad Dermatol* 2013; 68:433.

**Tolstov YL, et al:** Human Merkel cell polyomavirus infection. II. MCV is a common human infection that can be detected by conformational capsid epitope immunoassays. *Int J Cancer* 2009; 125:1250.

**Treglia G, et al:** Diagnostic performance of fluorine-18-fluorodeoxyglucose positron emission tomography in patients with Merkel cell carcinoma: a systematic review and meta-analysis. *Am J Clin Dermatol* 2013; 14:437.

**Turk T, et al:** Spontaneous regression of Merkel cell carcinoma in a patient with chronic lymphocytic leukemia: a case report. *J Med Case Rep* 2009; 3:7270.

**Veness M, et al:** The role of radiotherapy alone in patients with Merkel cell carcinoma: reporting the Australian experience of 43 patients. *Int J Radiat Oncol Biol Phys* 2010; 78(3):703–709.

**Warnick M, et al:** Merkel cell carcinoma presenting as lymphadenopathy without a primary cutaneous lesion: a report of 2 cases. *Arch Dermatol* 2008; 144:1397.

**Xie H, et al:** MicroRNA Expression patterns related to Merkel cell polyomavirus infection in human Merkel cell carcinoma. *J Invest Dermatol* 2014; 134(2):507–517.

## SEBACEOUS NEVI AND TUMORS

### Nevus sebaceus (organoid nevus)

Nevus sebaceus of Jadassohn presents as a sharply circumscribed, yellow-orange hamartoma, varying from a few millimeters to several centimeters in size. These lesions are usually solitary, congenital, and linear in configuration. The scalp is the most common location (50%), but other areas of the head and neck (45%) are also common. The trunk is involved in 5% or less of cases. The lesions persist throughout life and are usually alopecic. In childhood, they are only slightly papillated or velvety (Fig. 29-31), but in adulthood, with hyperplasia of the sebaceous elements, the lesions become more elevated and cerebriform. Large, pedunculated lesions presenting as exophytic tumors at birth are an unusual phenotype. Recent work has shown that somatic *HRAS* and *KRAS* mutations give rise to nevus sebaceus.

Numerous neoplasms, most of them adnexal, have been described arising in nevus sebaceus. The most common tumors are trichoblastoma and syringocystadenoma papilliferum, each occurring in about 5% of nevus sebaceus. Both these tumors present as new, often pigmented papules or nodules arising in the nevus sebaceus. BCC is uncommon, occurring in less than 1% of lesions. Many cases previously diagnosed as BCC are actually trichoblastomas. Many of the tumors are difficult to classify precisely. Development of benign tumors occurs in less than 5% of nevus sebaceus before age 16, and malignant tumors are rare in childhood or adolescence. The risk for tumor development increases with age. Rarely, aggressive malignant adnexal neoplasms may arise, usually in older adults. Familial cases have been described.

Nevus sebaceus may be associated with multiple internal abnormalities, making it one of the cutaneous abnormalities to be included within the epidermal nevus syndrome (see

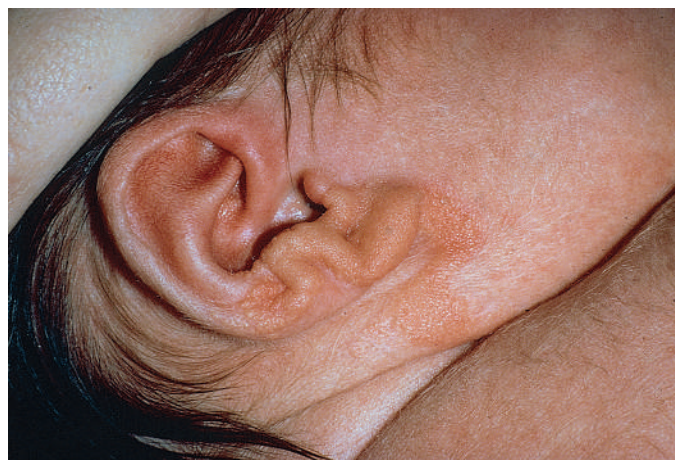

Fig. 29-31 Nevus sebaceus.



earlier). Schimmelpenning syndrome is a synonym for sebaceous nevus syndrome (SNS). In cases of SNS, the nevus sebaceous is usually on the scalp and is linear and large ( $\geq 10$  cm). The sebaceous nevi usually occupy more than one dermatome. Ocular colobomas and choristomas are characteristic. Neurologic findings are present in 7% of all patients with nevus sebaceous and up to two thirds of patients with SNS. Epilepsy is seen in about two thirds of cases, usually beginning in the first year of life. Mental retardation can occur. Although numerous anatomic abnormalities of the brain have been described in SNS, CT and MRI are frequently normal in children with seizures and mental retardation. Urologic and cardiovascular defects have also been reported. A rare variant of SNS is the SCALP syndrome: sebaceous nevus syndrome, CNS malformations, aplasia cutis congenita, limbal dermoid, and pigmented nevus (giant congenital melanocytic nevus). The aplasia cutis and sebaceous nevus are adjacent and on the scalp. SCALP syndrome is also called didymosis aplasticosebacea.

A rare but frequently reported association is that of nevus sebaceous and hypophosphatemic rickets. Most patients have large sebaceous nevi and evidence of "SNS." If the rickets goes unrecognized, permanent bone loss and orthopedic injury result. Serum phosphate is low, and there is excess phosphate in the urine. Serum calcium is normal. It is now clear that the nevus sebaceous itself secretes a factor responsible for phosphorus wasting. Fibroblast growth factor 23 (FGF-23) and matrix extracellular phosphoglycoprotein (MEPE) are both elevated in the blood of patients with this syndrome, and the levels of these substances parallel the hypophosphatemia. Surgical removal of the nevus sebaceous is the treatment of choice. When the nevus sebaceous is removed, the metabolic abnormalities normalize, and FGF-23 and MEPE levels return to normal. Partial removal can ameliorate the condition. Octreotide can also be used if surgical removal is not possible.

Histologically, in prepubertal lesions, the epithelium is acanthotic and papillomatous. Pilosebaceous structures are immature and resemble the fetal pilar germ. After puberty, the epidermis is more hyperplastic and at times papillomatous. It may resemble a seborrheic keratosis or acanthosis nigricans or may have features of an epidermal nevus. Sebaceous glands are usually abundant, placed high in the dermis, and connect directly to the epidermal surface. Follicular structures, if present, are usually vellous or partially formed. Apocrine glands are present in about half the lesions. The dermis is thickened, with increased vascularity and fibrous connective tissue. Mature lesions have been described as broad, bald, bumpy (papillomatous), and bubbly (sebaceous). The finding of epidermodysplasia verruciformis (EDV)-associated and genital-mucosal HPV DNA in nevus sebaceous is of unclear significance.

Although the risk of development of malignancy exists, it is small, and virtually always occurs after adolescence. For this reason, surgical removal can be delayed until adulthood, when the patient can make an informed decision regarding removal. If the lesion leads to disfigurement, stigmatization, or symptomatology, it may be removed at any age.

**Boger LD, et al:** Sebaceous nevus syndrome: a case report of a child with nevus sebaceous, mental retardation, seizures, and mucosal and ocular abnormalities. *Dermatol Online J* 2012; 18(9):5.

**Cribier B, et al:** Tumors arising in nevus sebaceous: a study of 596 cases. *J Am Acad Dermatol* 2000; 42:263.

**Dalle S, et al:** Apocrine carcinoma developed in nevus sebaceous of Jadassohn. *Eur J Dermatol* 2003; 13:487.

**Demerdjjeva Z, et al:** Epidermal nevus syndrome and didymosis aplasticosebacea. *Pediatr Dermatol* 2007; 24:514.

**Duncan A, et al:** Squamous cell carcinoma developing in a naevus sebaceous of Jadassohn. *Am J Dermatopathol* 2008; 30:269.

**Guhan B, Duncan RD:** Linear sebaceous naevus syndrome and resistant rickets. *J Bone Joint Surg Br* 2004; 86:151.

**Hoffman WH, et al:** Elevated fibroblast growth factor-23 in hypophosphatemic linear nevus sebaceous syndrome. *Am J Med Genet* 2005; 134A:233.

**Idriss MH, Elston DM:** Secondary neoplasms associated with nevus sebaceous of Jadassohn: a study of 707 cases. *J Am Acad Dermatol* 2014; 70(2):332–337.

**Lam J, et al:** SCALP syndrome: sebaceous nevus syndrome, CNS malformations, aplasia cutis congenita, limbal dermoid, and pigmented nevus (giant congenital melanocytic nevus) with neurocutaneous melanosis: a distinct syndromic entity. *J Am Acad Dermatol* 2008; 58:884.

**Levinsohn JL, et al:** Whole-exome sequencing reveals somatic mutations in *HRAS* and *KRAS*, which cause nevus sebaceous. *J Invest Dermatol* 2013; 133(3):827–830.

**Sakanoue M, et al:** Microcystic adnexal carcinoma arising in a nevus sebaceous. *Indian J Dermatol* 2013; 58(3):247.

**Santibanez-Gallerani A, et al:** Should nevus sebaceous of Jadassohn in children be excised? A study of 757 cases, and literature review. *J Craniofac Surg* 2003; 14:658.

**Wang E, et al:** A rare combination of sebaceoma with carcinomatous change (sebaceous carcinoma), trichoblastoma, and poroma arising from a nevus sebaceous. *J Cutan Pathol* 2013; 40(7):676–682.

**West C, et al:** Autosomal dominant transmission of nevus sebaceous of Jadassohn. *Dermatol Online J* 2012; 18(11):17.

**Wiedemeyer K, et al:** Trichoblastomas with Merkel cell proliferation in nevi sebacei in Schimmelpenning-Feuerstein-Mims syndrome: histological differentiation between trichoblastomas and basal cell carcinomas. *J Dtsch Dermatol Ges* 2009; 7:612.

**Zutt M, et al:** Schimmelpenning-Feuerstein-Mims syndrome with hypophosphatemic rickets. *Dermatology* 2003; 207:72.

## Sebaceous hyperplasia

Onset of sebaceous hyperplasia is usually after age 40, and the prevalence increases with age. The areas of predilection are the forehead, infraorbital regions, and temples. The lesions are small, cream-colored or yellowish, umbilicated papules 2–6 mm in diameter. Dermoscopy can be helpful in confirming the diagnosis and identifies the central crater, the yellow lobules, and the associated telangiectasia. Unusual sites may be affected, such as the areolae, nipples, penis, neck, and chest, where disease occurs as solitary lesions, clustered papules, or beaded lines. Prominent sebaceous hyperplasia occurs in 15% of patients taking cyclosporine and may involve ectopic sites such as the oral mucosa. It often appears many years after the cyclosporine is begun. Histologically, sebaceous hyperplasia demonstrates hyperplasia of one sebaceous gland, with normal-sized surrounding glands. The glands are multilobulated, each dividing into smaller lobules to produce a cluster resembling a bunch of grapes. Clinically, they may mimic an early BCC.

Premature sebaceous hyperplasia, also known as familial presenile sebaceous hyperplasia, presents with extensive sebaceous hyperplasia with onset at puberty and worsening with age. Familial patterns have been reported, inherited in an autosomal dominant manner. It involves the face, neck, and upper thorax but spares the periorificial regions.

Treatment is solely for cosmetic purposes and employs electrosurgery, laser therapy, PDT, or even shallow shave biopsy. Isotretinoin will reduce lesions, but they immediately recur when the drug is stopped, so isotretinoin is probably not indicated for this condition. Long-term successful therapy with isotretinoin requires low-dose maintenance therapy.

**Boonchai W, et al:** Familial presenile sebaceous gland hyperplasia. *J Am Acad Dermatol* 1997; 36:120.

**Boschnakow A, et al:** Cyclosporin A-induced sebaceous gland hyperplasia. *Br J Dermatol* 2003; 149:193.

**Errichetti E, et al:** Areolar sebaceous hyperplasia associated with oral and genital Fordyce spots. *J Dermatol* 2013; 40(8):670.

**Kim HS, et al:** Sebaceous hyperplasia of the scrotum and penile shaft. *Ann Dermatol* 2011; 23(Suppl 3):S341–S342.

**McDonald SK, et al:** Successful treatment of cyclosporine-induced sebaceous hyperplasia with oral isotretinoin in two renal transplant recipients. *Australas J Dermatol* 2011; 52(3):227–230.

**Noh S, et al:** A case of sebaceous hyperplasia maintained on low-dose isotretinoin after carbon dioxide laser treatment. *Int J Dermatol* 2014; 53(2):e151–e153.

**Perrett CM, et al:** Topical photodynamic therapy with methyl aminolevulinic acid to treat sebaceous hyperplasia in an organ transplant recipient. *Arch Dermatol* 2006; 142:781.

**Wang Q, et al:** Premature sebaceous hyperplasia in an adolescent boy. *Pediatr Dermatol* 2011; 28(2):198–200.

## Sebaceous adenoma

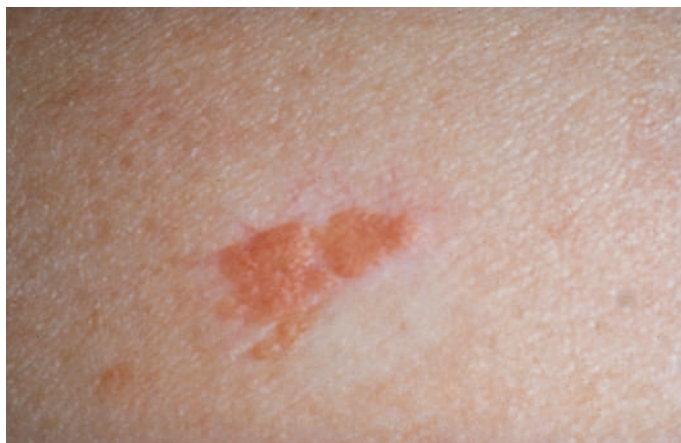This slow-growing tumor usually presents as a pink, flesh-colored, or yellow papule or nodule. Sebaceous adenoma occurs primarily on the head and neck (70%) in elderly persons (mean age 60). Histologically, the tumor is composed of multiple, sharply marginated, sebaceous lobules. Each lobule has a basal layer of darker germinative cells, but the maturation is not as well developed as in a normal sebaceous gland. The basaloid cells occupy more than the typical one to two cell layers seen in the normal sebaceous gland or in sebaceous hyperplasia. Multiple openings directly to the overlying epidermis may be found. Sebaceous adenoma may be a cutaneous marker of the Muir-Torre syndrome.

## Sebaceoma (sebaceous epithelioma)

Clinically, sebaceomas have the same morphologic characteristics as BCCs. They appear as yellow or orange papules, nodules, or plaques (Fig. 29-32), usually on the scalp, face, and neck. Sebaceous epitheliomas also may be associated with Muir-Torre syndrome. Histologically, the tumor consists of oval nests of irregularly shaped basaloid cells with differentiation toward sebaceous cells. The basaloid cells should outnumber the differentiated sebocytes in a sebaceoma. Also, there may be cystic spaces containing vacuolated, amorphous material.

## Reticulated acanthoma with sebaceous differentiation

This rare tumor presents as an enlarging, erythematous to brown plaque, often on the back. Histologically, the tumor has



**Fig. 29-32** Sebaceoma.

a reticulated seborrheic keratosis–like pattern, being broad and well circumscribed. There are clusters of sebocytes at the bases of the rete ridges. Sebaceous ducts may also be seen. These ductal elements are EMA positive and CEA negative. This tumor can also be associated with Muir-Torre syndrome.

## Sebaceous carcinoma

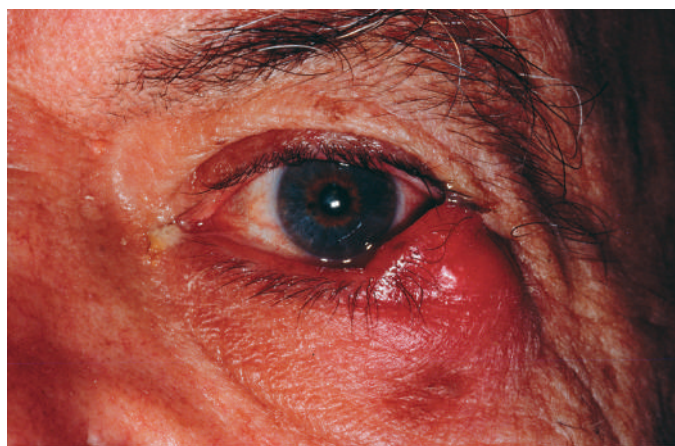Sebaceous carcinoma is a rare neoplasm, and 75% of cases occur on the eyelid or around the eye. It most frequently arises on the eyelids from the meibomian or Zeis glands. It usually appears in the tarsal region of the upper eyelids (75%) and represents 1% or more of eyelid malignancies. It is frequently misdiagnosed as a chalazion, delaying appropriate treatment. The scalp, other areas of the face, and the trunk are the next most common areas involved. Lesions present as a painless subcutaneous nodule or less often a pedunculated growth. Rarely, sebaceous carcinoma has been reported to involve the feet, external genitalia, and oral mucosa. Fatal metastatic disease occurs in 9–50% of cases (30% of eyelid cases), and 5-year survival for this tumor is 80%. Sebaceous carcinomas arising in nonocular locations can also metastasize, usually to regional lymph nodes. Sebaceous carcinoma may be seen in Muir-Torre syndrome (Fig. 29-33).

Histologically, the tumor is composed of lobules or sheets of cells that extend deeply into the dermis, subcutaneous fat, or muscle. The tumor cells are pleomorphic and show various degrees of sebaceous differentiation, manifested by a vacuolated rather than clear cytoplasm. Undifferentiated cells with mitotic figures can be found. The cells vary greatly in size and shape. A characteristic feature in ocular tumors is pagetoid or bowenoid spread of the tumor onto the overlying conjunctiva or skin. Sebaceous differentiation may be minimal in this in situ component, leading to the misdiagnosis of SCC in situ.

Treatment is surgical, with Mohs micrographic surgery having the best results; there is an 11% recurrence rate after Mohs and 30% after standard excision. Given the extent of sebaceous carcinomas, oculoplastic reconstruction is usually required. In extraocular cases, complete excision, as for an adnexal carcinoma, and careful follow-up are recommended.

## Muir-Torre syndrome

Sebaceous tumors of the skin were first reported by Muir in 1967 and Torre in 1968 as being associated with the



**Fig. 29-33** Sebaceous carcinoma in patient with Muir-Torre syndrome.



development of internal malignancy, a combination that has been called the Muir-Torre syndrome (MTS). The cutaneous lesions may be sebaceous adenomas, sebaceomas, or sebaceous carcinomas. In MTS, these tumors occur more often on the trunk than they do in the general population, in whom sebaceous tumors favor the head and neck. Keratoacanthomas (KAs) are also common and multiple. The KAs may show sebaceous differentiation. The combination of a sebaceous tumor and a KA should be highly suggestive of MTS. The recognition of the association of sebaceous neoplasms and MTS is highlighted by one report, in which 42% of persons with a sebaceous neoplasm had MTS. Between 22% and 32% of patients with MTS present with the sebaceous neoplasm before development of the internal malignancy. About 60% have already had an internal malignancy by the time the sebaceous neoplasm occurs. Because the mean age of presentation of the sebaceous neoplasm is 63 years, the confirmation of MTS becomes important for genetic counseling of the patient's children. MTS is inherited in an autosomal dominant manner in about 60% of cases; penetrance is high, but expression is variable.

Muir-Torre syndrome is now recognized to be a subset of the Lynch syndrome, or hereditary nonpolyposis colorectal cancer syndrome (HNPCC). HNPCC and MTS are caused by mutations in mismatch repair (MMR) genes (*MLH1*, *MSH2*, and *MSH6* for MTS and Lynch syndrome, and *PMS2* only in Lynch syndrome). *MSH2* mutations are responsible for 90% of MTS families. The most common malignancy is colonic adenocarcinoma (47%), usually proximal to the splenic flexor. Multiple polyps are not present. Genitourinary tumors (21%), breast cancer (12%), and hematologic disorders (9%) are also common.

The absence of an MMR enzyme results in microsatellite instability (MSI). MMR enzymes (or their absence) can be detected fairly inexpensively and with a high degree of sensitivity and specificity using immunohistochemistry for *MSH-2*, *MLH-1*, and *MSH-6* on routinely processed paraffin-embedded pathology specimens. Lack of expression of one of these enzymes prompts further testing for MSI using polymerase chain reaction (PCR)-based techniques. MSI is found in about 60% of sebaceous neoplasms, and more than half of those patients will have MTS. This allows for suspicion of MTS to be raised during the pathologic evaluation of a sebaceous neoplasm. Any pathology report regarding a sebaceous tumor should include this information, because it is essential for directing further evaluation and care of the patient. The visceral tumors of MTS also contain MSI. The finding of MSI on a biopsy should lead to germline testing of the patient and subsequently of the family if the patient has the mutation. Hypermethylations of *MLH1* promoter and *BRAF-600E* mutations can lead to immunohistochemical results suggesting *MLH1* deficiency and should be screened for before undertaking genetic testing of the patient who shows *MLH1* deficiency on biopsy. Once the diagnosis is confirmed, the patient and genetically related family members should be appropriately screened for underlying malignancies of the GI and genitourinary systems. This screening should begin at a much younger age than is standard: 20–25 years for colonoscopy and 30–35 years for transvaginal ultrasound. Other organs are screened if the affected family has such cancers; screening might include upper endoscopy, urine cytology, or abdominal ultrasound. The value of screening for noncolonic carcinomas has not been demonstrated. Genetic counseling should be provided.

**Abbas O, Mahalingam M:** Cutaneous sebaceous neoplasms as markers of Muir-Torre syndrome: a diagnostic algorithm. *J Cutan Pathol* 2009; 36:613.

**Bassetto F, et al:** Biological behavior of the sebaceous carcinoma of the head. *Dermatol Surg* 2004; 30:472.

**Dores GM, et al:** Incidence of cutaneous sebaceous carcinoma and risk of associated neoplasms: insight into Muir-Torre syndrome. *Cancer* 2008; 113(12):3372–3381.

**Eisen DB, Michael DJ:** Sebaceous lesions and their associated syndromes. Part I. *J Am Acad Dermatol* 2009; 61:549.

**Eisen DB, Michael DJ:** Sebaceous lesions and their associated syndromes. Part II. *J Am Acad Dermatol* 2009; 61:563.

**Harrington CR, et al:** Extraocular sebaceous carcinoma in a patient with Muir-Torre syndrome. *Dermatol Surg* 2004; 30:817.

**Ingram JR, et al:** All patients with sebaceous gland neoplasms should be screened for Muir-Torre syndrome. *Clin Exp Dermatol* 2009; 34(2):264–266.

**Jagan L, et al:** Sebaceous adenomas of the eyelid and Muir-Torre syndrome. *Br J Ophthalmol* 2015; Jan 16 [Epub ahead of print.]

**Kacerovska D, et al:** *MSH6* mutation in a family affected by Muir-Torre syndrome. *Am J Dermatopathol* 2012; 34(6):648–662.

**Landis MN, et al:** Immunosuppression and sebaceous tumors: a confirmed diagnosis of Muir-Torre syndrome unmasked by immunosuppressive therapy. *J Am Acad Dermatol* 2011; 65(5):1054–1058.e1.

**Lee BA, et al:** Sebaceous neoplasms with mismatch repair protein expressions and the frequency of co-existing visceral tumors. *J Am Acad Dermatol* 2012; 67(6):1228–1234.

**Mangold E, et al:** A genotype-phenotype correlation in HNPCC: strong predominance of *MSH2* mutations in 41 patients with Muir-Torre syndrome. *J Med Genet* 2004; 41:567.

**Mathiak M, et al:** Loss of DNA mismatch repair proteins in skin tumors from patients with Muir-Torre syndrome and *MSH2* or *MLH1* germline mutations: establishment of immunohistochemical analysis as a screening test. *Am J Surg Pathol* 2002; 26(3):338–343.

**Ponti G, et al:** Identification of Muir-Torre syndrome among patients with sebaceous tumors and keratoacanthomas: role of clinical features, microsatellite instability, and immunohistochemistry. *Cancer* 2005; 103(5):1018–1025.

**Robert ME, et al:** A clinical scoring system to identify patients with sebaceous neoplasms at risk for the Muir-Torre variant of Lynch syndrome. *Genet Med* 2014; 16(9):711–746.

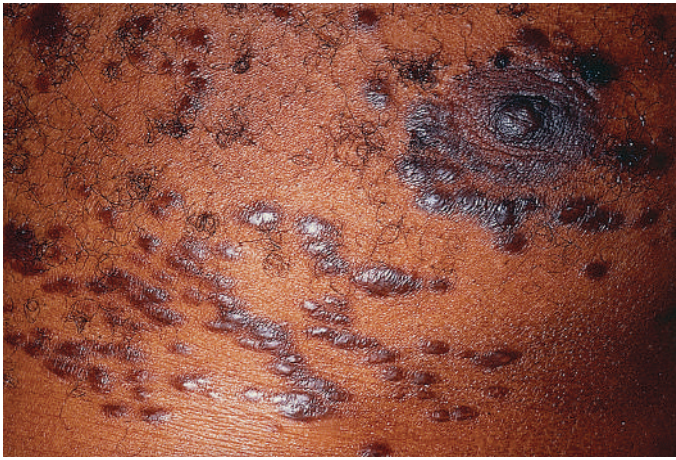
## SWEAT GLAND TUMORS

### Syringoma

Syringomas are common neoplasms demonstrating sweat duct differentiation. They present as small papules 1–3 mm in diameter and may be yellow, brown, or pink. They are virtually always multiple and most frequently occur on the eyelids and upper cheeks (Fig. 29-34). Syringomas are disproportionately common in these sites in Japanese women. Other sites of involvement include the axillae, abdomen, forehead, penis, and vulva. Genital syringomas may cause genital pruritus and may be mistaken for genital warts. Rarely, they may be unilateral or linear. Symmetric distal extremity involvement has

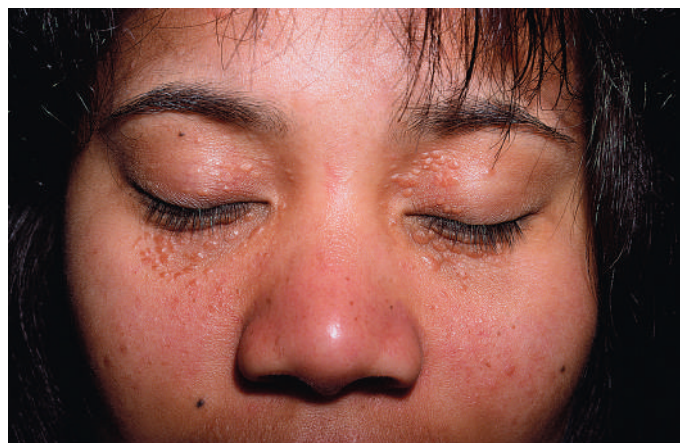

Fig. 29-34 Syringomas.



**Fig. 29-35** Syringomas.

also been reported. Eruptive syringomas are histologically identical to syringomas of the eyelid but appear suddenly as numerous lesions on the neck, chest (Fig. 29-35), axillae, upper arms, and periumbilically, usually in young persons. Some have suggested that eruptive syringomas represent a proliferative process of inflamed normal eccrine glands, analogous to traumatic neuroma being a proliferation of normal peripheral nerve. The fact that numerous lesions appear after “waxing” in the pubic areas supports this hypothesis. Many individual case reports document unusual clinical variants of syringomas. These include types limited to the scalp, associated with alopecia; a unilateral linear or nevoid distribution; those limited to the vulva or penis; those limited to the distal extremities; and the lichen planus-like and milia-like types. Syringomas may calcify and may be mistaken for subepidermal calcified nodules. The rare “plaque-type” syringoma may be mistaken for a microcystic adnexal carcinoma.

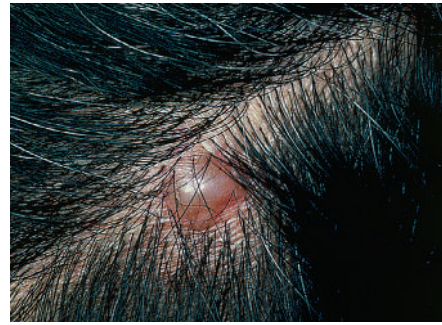Familial cases of syringomas occur. In general, except in eruptive cases, syringomas develop slowly and persist indefinitely without symptoms. Acral lesions are often present. Syringomas occur in 18% of adults with Down syndrome, particularly females. This is approximately 30 times the frequency seen in patients with other syndromes.

Histologically, syringomas are characterized by dilated cystic spaces lined by two layers of cuboidal cells and epithelial strands of similar cells. Some of the cysts have small, comalike tails, which produce a distinctive picture, resembling tadpoles or the pattern of a paisley tie. There is a dense fibrous stroma. At times, the cells of the syringoma have abundant clear cytoplasm, which represents accumulated glycogen. This has been called “clear cell syringoma.” Syringomas stain positive for keratins 5, 6, 14, 6, 16, 19, and 77 on the inner cell layer, and K5 and K14 on the outer cell layer, in a pattern identical to the intraglandular eccrine duct. The microscopic differential diagnosis of “paisley tie” epithelial islands embedded in a sclerotic stroma includes microcystic adnexal carcinoma (sclerosing sweat duct carcinoma), desmoplastic trichoepithelioma, and morpheaform BCC.

Treatment is difficult, but many lesions respond to very light electrodesiccation or shave removal. For larger lesions, surgical removal may be considered. CO<sub>2</sub> laser treatment by the pinhole method or by fractional thermolysis has been reported as effective.

**Akita H, et al:** Syringoma of the face treated with fractional photothermolysis. *J Cosmet Laser Ther* 2009; 11:216.

**Ceulen RP, et al:** Multiple unilateral skin tumors suggest type 1 segmental manifestation of familial syringoma. *Eur J Dermatol* 2008; 18:285.



**Fig. 29-36**  
Hydrocystoma.

**Cho SB, et al:** Treatment of syringoma using an ablative 10,600-nm carbon dioxide fractional laser: a prospective analysis of 35 patients. *Dermatol Surg* 2011; 37(4):433–438.

**Cohen PR et al:** Penile syringoma: reports and review of patients with syringoma located on the penis. *J Clin Aesthet Dermatol* 2013; 6(6):38–42.

**Ghanadan A, Khosravi M:** Cutaneous syringoma: a clinicopathologic study of 34 new cases and review of the literature. *Indian J Dermatol* 2013; 58(4):326.

**Huang YH, et al:** Vulvar syringoma: a clinicopathologic and immunohistologic study of 18 patients and results of treatment. *J Am Acad Dermatol* 2003; 48:735.

**Jamalipour M, et al:** Generalized eruptive syringomas. *Indian J Dermatol* 2009; 54(1):65–67.

**Marzano AV, et al:** Familial syringoma: report of two cases with a published work review and the unique association with steatocystoma multiplex. *J Dermatol* 2009; 36:154.

**Nosrati N, et al:** Axillary syringomas. *Dermatol Online J* 2008; 14:13.

**Olson JM, et al:** Multiple penile syringomas. *J Am Acad Dermatol* 2008; 59:S46.

**Park HJ, et al:** The treatment of syringomas by CO<sub>2</sub> laser using a multiple-drilling method. *Dermatol Surg* 2007; 33:310.

**Seo SH, et al:** A case of milium-like syringoma with focal calcification in Down syndrome. *Br J Dermatol* 2007; 157:612.

**Soler-Carrillo J, et al:** Eruptive syringoma: 27 new cases and review of the literature. *J Eur Acad Dermatol Venereol* 2001; 15:242.

## Hydrocystomas

Hydrocystomas, which may be of eccrine or apocrine differentiation, are 1–3 mm translucent cystic papules that occasionally have a bluish tint. They usually are solitary, occur on the face or scalp, and are more common in women. In some patients, multiple lesions may be present (Fig. 29-36), and they may be pigmented. They may become more prominent during hot weather. They most often occur periorcularly. Multiple hydrocystomas with apocrine secretion on the eyelids are the hallmark of Schopf-Schulz-Passarge syndrome (SSPS), an adult-onset autosomal recessive form of ectodermal dysplasia associated with *WNT10A* mutations. Other features include hypodontia, hypotrichosis, nail dystrophy, and palmoplantar keratoderma. Multiple palmoplantar syringofibroadenomas are present in most cases of SSPS and can present as a palmoplantar keratoderma. Up to 44% of patients have other adnexal tumors. Skin and visceral malignancies are not increased in SSPS.

Microscopically, a single cystic cavity is lined by two layers of small, cuboidal epithelial cells. Apocrine differentiation in the form of decapitation secretion is common. Lesions with papillary proliferations of the lining are classified as cystadenomas. Treatment, if desired, is by excision for solitary lesions. Laser treatment may be effective, both with CO<sub>2</sub> and pulsed dye laser. Topical atropine ointment 1% or scopolamine cream 0.01% (1.2 mL of 0.25% scopolamine eyedrops in 30 g of Eucerin), once daily, has been used with variable success in patients with multiple lesions. Pupil size may increase with



these agents. Oral glycopyrrolate, 1 mg twice daily, may be useful in suppressing exercise-induced and hot weather-induced enlargement. Botulinum toxin may also be effective, either injected or applied topically.

**Castori M, et al:** Schopf-Schulz-Passarge syndrome: further delineation of the phenotype and genetic considerations. *Acta Derm Venereol* 2008; 88:607.

**Couto Júnior Ade S, et al:** Hidrocystoma: surgical management of cystic lesions of the eyelid. *An Bras Dermatol* 2010; 85(3):368–371.

**Gandhi V, et al:** Eccrine hidrocystoma successfully treated with topical synthetic botulinum peptide. *J Cutan Aesthet Surg* 2011; 4(2):154–155.

**Jabbar AS, et al:** Eccrine hidrocystomas presenting as multiple papules on the cheeks. *Dermatol Online J* 2013; 19(8):19269.

**Jakobiec FA, Zakka FR:** A reappraisal of eyelid eccrine and apocrine hidrocystomas: microanatomic and immunohistochemical studies of 40 lesions. *Am J Ophthalmol* 2011; 151(2):358–374.e2.

**Lee HW, et al:** Multiple eccrine hidrocystomas: successful treatment with the 595 nm long-pulsed dye laser. *Dermatol Surg* 2006; 32:296.

**Madan V, et al:** Multiple eccrine hidrocystomas: response to treatment with carbon dioxide and pulsed dye lasers. *Dermatol Surg* 2009; 35:1015.

**Mahnaz Jamalipour, et al:** Generalized eruptive syringomas. *Indian J Dermatol* 2009; 54(1):65–67.

**Ozkan Z:** Multiple eccrine hidrocystomas of the vulva. *Int J Gynaecol Obstet* 2009; 105:65.

**Park HC, et al:** Treatment of multiple eccrine hidrocystomas with isotretinoin followed by carbon dioxide laser. *J Dermatol* 2013; 40(5):414–415.

**Tziotzios C, et al:** Clinical features and *WNT10A* mutations in 7 unrelated cases of Schöpf-Schulz-Passarge syndrome. *Br J Dermatol* 2014; 171(5):1211–1214.

**Vani D, et al:** Multiple apocrine hidrocystomas: a case report. *J Clin Diagn Res* 2013; 7(1):171–172.

**Woolery-Lloyd H, et al:** Treatment for multiple periorbital eccrine hidrocystomas: botulinum toxin A. *J Drugs Dermatol* 2009; 8:71.

### Acrospiromas (poroma, hidroacanthoma simplex, dermal duct tumor, nodular hidradenoma, clear cell hidradenoma)

Acrospiromas are benign tumors with acrosyringial differentiation. A poroma presents as a slow-growing, 2–12 mm, slightly protruding, sessile, soft, reddish tumor that occurs most often on the sole (Fig. 29-37) or side of the foot. Palmar lesions may also occur, and more rarely, lesions appear wherever sweat glands are found. The lesion will bleed on slight trauma. A distinctive finding is the cup-shaped shallow depression from which the tumor grows and protrudes. Poromas tend to occur singly, but multiple lesions may also occur. A rare variant is called eccrine poromatosis, in which

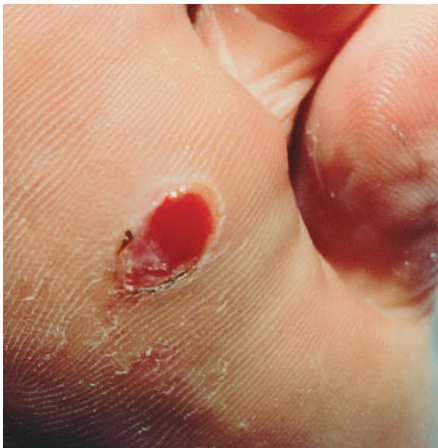

Fig. 29-37 Poroma.

more than 100 lesions may involve the palms and soles and may be associated with hidrotic ectodermal dysplasia, immunosuppression, or chemotherapy. These may represent acrosyringial nevi. Dermal duct tumors present deep nodules that may involve any part of the body. Nodular and clear cell hidradenomas are larger nodules that often involve the head or neck but may occur anywhere. Hybrid combinations of different patterns of acrospiroma are very common.

Histologically, poromas demonstrate solid masses of uniform, cuboidal epithelial cells with ample cytoplasm and focal duct differentiation. The cells are smaller than those in the contiguous epidermis and tend to arrange themselves in cords and broad columns extending downward from the normal epidermis. Areas of clear cell and cystic degeneration may be present, and an underlying dermal duct tumor or hidradenoma may be present. Melanocytes may be dispersed throughout the tumor and may be clinically hyperpigmented. The surrounding stroma is highly vascular, with telangiectatic vessels. Hidroacanthoma simplex represents an intraepidermal eccrine poroma. These lesions resemble clonal seborrheic keratoses, except for the presence of focal duct differentiation. Dermal duct tumors are composed of the same small acrosyringial cells as other acrospiromas. The cells form small dermal islands with ductal differentiation. When the cells form a large nodule, the tumor is referred to as a nodular hidradenoma. When clear cells and cystic degeneration are prominent, the tumor is referred to as a clear cell hidradenoma. A distinctive feature of the latter two tumors is the presence of areas of eosinophilic hyalized stroma. All the cells in a poroma, except entrapped ducts, stain with K5/14. Focally, they are K1/10 positive and uniformly K77 negative. This is the staining pattern of the sweat duct ridge and acrosyringium (intraepidermal portions of sweat duct). The clinical differential diagnosis includes porocarcinoma, pyogenic granuloma, melanoma (amelanotic and melanotic), Kaposi sarcoma, BCC, and seborrheic keratosis. The lesions are benign but often recur following inadequate excision. Malignant degeneration may occur, and atypia is sometimes minimal within tumors that have metastasized. For these reasons, simple complete excision is recommended when feasible.

### Malignant acrospiroma (malignant poroma, porocarcinoma)

This represents the most common form of sweat duct carcinoma. Most malignant acrospiromas appear clinically similar to poromas but may also manifest as a blue or black nodule, plaque, or ulcerated tumor. Porocarcinoma affects men and women equally at an average age of 70 years. The most frequent sites of involvement are the legs (30%), feet (20%), face (12%), thighs (8%), and arms (7%). Of interest is the rare involvement of the palms and soles, despite these having the greatest concentration of sweat glands. The average age from onset to treatment is 4–8 years. These tumors are of intermediate aggressiveness, with metastases usually occurring to regional lymph nodes and, less often, hematogenously.

Histologically, the tumor may be seen adjoining benign acrospiroma. Atypia may be marked or minimal, with pleomorphic or monomorphic nuclei and abundant or scant eosinophilic cytoplasm. Most frequently, the cells are smaller and more basophilic than those in benign acrospiromas with a high mitotic rate. Focal squamous or sarcomatous differentiation may be present. Pagetoid spread within the adjacent epidermis may be seen. As in benign acrospiromas, clear cell and cystic degeneration may be present. The degree of ductal differentiation is variable. The tumors can be deeply infiltrative. Perineural and lymphovascular involvement by

the tumor can be present and should be noted on the dermatopathology report. The epidermis may be invaded by metastatic porocarcinoma. Mohs surgery can be a valuable technique, particularly on the face. As with other cutaneous neoplasms, margins should be free of tumor islands and tumor stroma to be considered negative. Local recurrence approaches 20%, and lymph node metastases occur in about 20% of patients. SNLB could be considered. Distant metastases occur in 10% of cases, often at a distant skin site.

**Aaribi I, et al:** Successful management of metastatic eccrine porocarcinoma. *Case Rep Oncol Med* 2013; 2013:282536.

**Battistella M, et al:** From hidroacanthoma simplex to poroid hidradenoma: clinicopathologic and immunohistochemical study of poroid neoplasms and reappraisal of their histogenesis. *Am J Dermatopathol* 2010; 32(5):459–468.

**Chang O, et al:** Eccrine porocarcinoma of the lower extremity: a case report and review of literature. *World J Surg Oncol* 2011; 9:94.

**Deckelbaum S, et al:** Eccrine poromatosis: case report and review of the literature. *Int J Dermatol* 2014; 53(5):543–548.

**Gerber PA, et al:** Eccrine porocarcinoma of the head: an important differential diagnosis in the elderly patient. *Dermatology* 2008; 216:229.

**Ishida M, Okabe H:** Expression profiles of mTOR pathway proteins in porocarcinoma: a provisional immunohistochemical study. *Biomed Rep* 2013; 1(1):28–30.

**Kurashige Y, et al:** Eccrine porocarcinoma: clinical and pathological report of eight cases. *Case Rep Dermatol* 2013; 5(3):259–266.

**Minagawa A, Koga H:** Dermoscopy of pigmented poromas. *Dermatology* 2010; 221(1):78–83.

**Nguyen A, Nguyen AV:** Eccrine porocarcinoma: a report of 2 cases and review of the literature. *Cutis* 2014; 93(1):43–46.

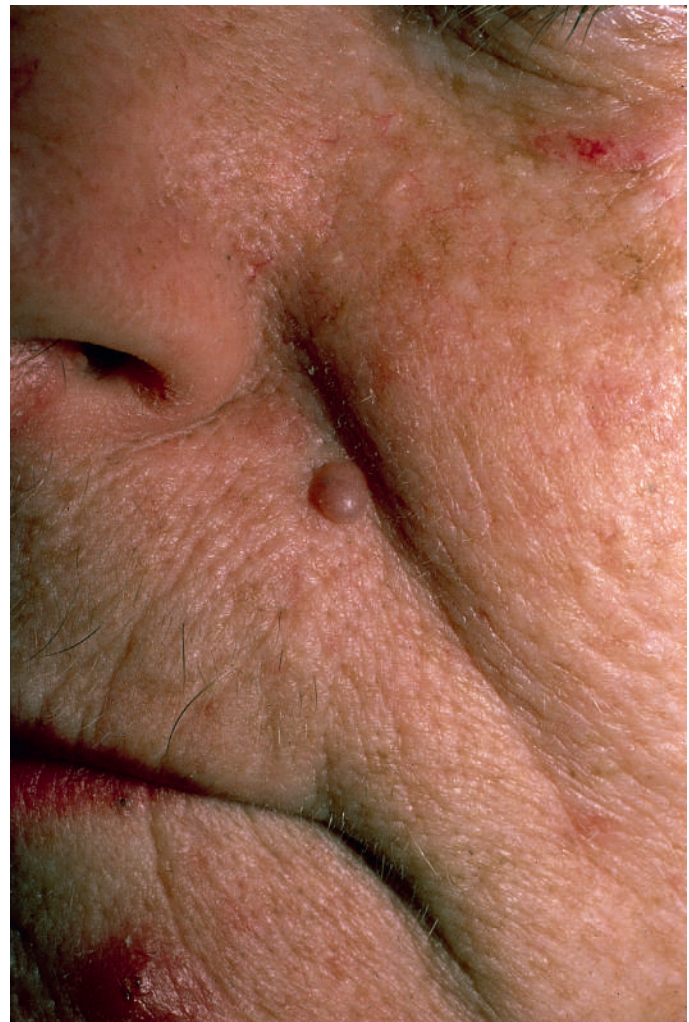**Nguyen BT, et al:** Multiple poromas in a bone marrow transplant recipient: a case report. *Dermatol Online J* 2012; 18(7):9.

**Sawaya JL, Khachemoune A:** Poroma: a review of eccrine, apocrine, and malignant forms. *Int J Dermatol* 2014; 53(9):1053–1061.

**Shin HT, et al:** Clear cell hidradenoma on the palm. *Ann Dermatol* 2014; 26(3):403–404.

**Skowron F, et al:** Primary eccrine porocarcinoma: a clinicopathological study of 50 cases. *Ann Dermatol Venereol* 2014; 141(4):258–2564.

**Urso C, et al:** Carcinomas of sweat glands: report of 60 cases. *Arch Pathol Lab Med* 2001; 125:498.



**Fig. 29-38** Spiradenoma.

## Spiradenoma

Spiradenoma presents clinically as a solitary, 1-cm, deep-seated nodule, occurring most frequently on the ventral surface of the body, especially over the upper half. Normal-appearing skin covers the nodule, which may be skin colored, blue, or pink (Fig. 29-38). Occasionally, multiple lesions may be present and may occur in a linear or segmental pattern. Giant lesions that are very vascular are rarely seen. Lesions may be painful, but not universally. Spiradenoma has a generally benign clinical course and occurs most frequently between ages 15 and 35, although it has also been reported in infancy and childhood. Familial cases have been described. Rarely, malignant transformation occurs, and the subsequent tumor may also have features of a cylindroma (spiradenocylindrocarcinoma).

Microscopically, spiradenoma demonstrates either a single nodule or multiple basophilic nodules within the dermis. Tumor cells have minimal to no visible cytoplasm. They are often arranged in characteristic small rosettes. Three cell types are present: cells with large, pale-gray nuclei; those with smaller, darker-gray nuclei; and jet-black lymphocytes peppered throughout the nodule. Ductlike structures are often present, as are large, pink hyaline globules that resemble the bright-red hyaline basement membrane material that outlines the islands of cylindromas. In fact, spiradenomas and cylindromas often occur together in the same patient, and hybrid collision tumors are quite common. These have historically been thought to be of eccrine lineage, but both tumors may instead originate from the hair follicle bulge.

When painful, eccrine spiradenoma may be mistaken for leiomyoma, glomus tumor, neuroma, and angioliipoma. Treatment is simple excision. Spiradenocylindrocarcinoma presents as a solitary nodule that may have experienced an abrupt change in size. Histologically, these lesions have focal areas of atypia, mitoses, and invasion. They may metastasize to regional lymph nodes or hematogenously. Local recurrence occurs with inadequate surgical control.

**Apostolou G, et al:** Spiradenocylindrocarcinoma: report of a case with a low-grade component of spiradenocarcinoma and an immunohistochemical study. *Am J Dermatopathol* 2009; 31(6):594–598.

**Ben Brahim E, et al:** Malignant eccrine spiradenoma: a new case report. *J Cutan Pathol* 2010; 37(4):478–481.

**Bumgardner AC, et al:** Trichoepitheliomas and eccrine spiradenomas with spiradenoma/cylindroma overlap. *Int J Dermatol* 2005; 44:415.

**Chow W, Griffiths M:** A malignant eccrine spiradenoma of the scalp. *BMJ Case Rep* 2014; doi:10.1136/bcr-2013-202524.

**Dai B, et al:** Spiradenocarcinoma, cylindrocarcinoma and spiradenocylindrocarcinoma: a clinicopathologic study of 9 cases. *Histopathology* 2014; 65(5):658–666.

**Englander L, et al:** A rare case of multiple segmental eccrine spiradenomas. *J Clin Aesthet Dermatol* 2011; 4(4):38–44.

**Gordon S, et al:** Pediatric segmental eccrine spiradenomas: a case report and review of the literature. *Pediatr Dermatol* 2013; 30(6):e285–e286.

**Jariwala A, et al:** Not all stubbed toes are innocuous: a case report of rare malignant eccrine spiradenoma (spiradenocarcinoma) of the toe. *Foot Ankle Surg* 2010; 16(2):e32–e33.

**Kazakov DV, et al:** Morphologic diversity of malignant neoplasms arising in preexisting spiradenoma, cylindroma, and spiradenocylindroma



based on the study of 24 cases, sporadic or occurring in the setting of Brooke-Spiegler syndrome. *Am J Surg Pathol* 2009; 33:705.

**Sellheyer K:** Spiradenoma and cylindroma originate from the hair follicle bulge and not from the eccrine sweat gland: an immunohistochemical study with CD200 and other stem cell markers. *J Cutan Pathol* 2014; Oct 29 [Epub ahead of print.]

**Tanese K, et al:** Malignant eccrine spiradenoma: case report and review of the literature, including 15 Japanese cases. *Clin Exp Dermatol* 2010; 35:51.

**Tiradogonzalez M, et al:** Neonatal spiradenoma. *Pediatr Dermatol* 2013; 30(6):e228–e229.

**Tran K, et al:** Spiradenomas. *Dermatol Online J* 2012; 18(12):15.

## Cylindroma

Cutaneous cylindroma occurs predominantly on the scalp and face as a solitary lesion. The tumor is firm but rubberlike and pink-blue; it ranges in size from a few millimeters to several centimeters (Fig. 29-39). The solitary cylindroma is considered to be nonhereditary and at times may be found in areas other than the head and neck. Women are affected more than men.

The dominantly inherited form, Brooke-Spiegler syndrome (BSS), appears soon after puberty as numerous rounded masses of various sizes on the scalp. The lesions resemble bunches of grapes or small tomatoes. Lesions appear in the second or third decade of life. Sometimes they cover the entire scalp like a turban. BSS is characterized by the presence of multiple adnexal neoplasms, including cylindroma, trichoepitheliomas, spiradenomas, trichoblastomas, follicular cysts, and milia. Familial cylindroma is now considered a variant of BSS because it harbors the same mutation. There is no genotypic/phenotypic correlation in these two syndromes. BSS is caused by a mutation in the *CYLD* tumor suppressor gene.

Histologically, these are cylindrical masses of epithelial cells surrounded and segmented by thick bands of a hyaline material. Cylindroma may be mistaken for pilar cyst, but the distinctive appearance and consistency make diagnosis easy, especially in the multiple type. Treatment is surgical; success using ablative laser therapy has also been reported.

**Chaer RA, Lipnick S:** Images in clinical medicine: cylindroma. *N Engl J Med* 2004; 351:2530.

**Chen M, et al:** Brooke-Spiegler syndrome associated with cylindroma, trichoepithelioma and eccrine spiradenoma. *Int J Dermatol* 2013; 52(12):1602–1604.

**Grossmann P, et al:** Novel and recurrent germline and somatic mutations in a cohort of 67 patients from 48 families with Brooke-Spiegler syndrome including the phenotypic variant of multiple familial trichoepitheliomas and correlation with the histopathologic findings in 379 biopsy specimens. *Am J Dermatopathol* 2013; 35(1):34–44.

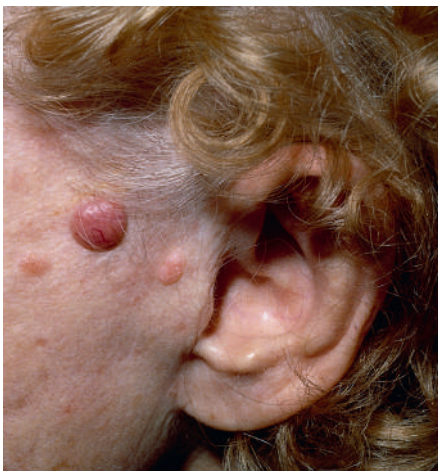

Fig. 29-39 Cylindroma.

**Rajan N, et al:** Transition from cylindroma to spiradenoma in *CYLD*-defective tumours is associated with reduced *DKK2* expression. *J Pathol* 2011; 3:309–321.

**Richard A, et al:** CO<sub>2</sub> laser treatment of skin cylindromas in Brooke-Spiegler syndrome. *Ann Dermatol Venereol* 2014; 141(5):346–353.

**Sima R, et al:** Brooke-Spiegler syndrome: report of 10 patients from 8 families with novel germline mutations: evidence of diverse somatic mutations in the same patient regardless of tumor type. *Diagn Mol Pathol* 2010; 19(2):83–91.

**Tarstedt M, Molin L:** Nd:YAG laser for effective treatment of multiple cylindroma of the scalp. *J Cosmet Laser Ther* 2004; 6:41.

**Trufant J, et al:** Brooke-Spiegler syndrome. *Dermatol Online J* 2012; 18(12):16.

## Mixed tumor (chondroid syringoma)

Cutaneous mixed tumor is an uncommon skin tumor, representing about 1 in 1000 skin lesions removed electively. It favors men between ages 25 and 65. Mixed tumor presents clinically as a firm, intradermal or subcutaneous nodule, virtually always located on the head or neck. These tumors are usually asymptomatic and measure 5–30 mm in diameter, but may be much larger.

Histologically, nests of cuboidal or polygonal epithelial cells in the dermis give rise to tubuloalveolar and ductal structures and occasionally, keratinous cysts. These structures are embedded in a matrix varying from a faint-blue chondroid substance to an acidophilic hyaline material. Myoepithelial and lipomatous elements may also be found in the tumor in addition to the chondroid stroma. Ossification may occur. The treatment is surgical. Mixed tumors may also occur in other organs, especially salivary glands, where they are also known as pleomorphic adenomas. In salivary and rarely in cutaneous chondroid syringoma, tyrosine crystals may be seen in the tumor. Tumors with only focal glandular elements, or with no epithelial elements, have been called “cutaneous myoepitheliomas.” They are tumors of the myoepithelial cells; these cells surround the sweat glands and, by their contraction, help deliver the product of the glands to the surface. Both cutaneous mixed tumors and cutaneous myoepitheliomas stain positively with SOX-10, supporting the notion that these tumors exist on a spectrum.

## Malignant mixed tumor (malignant chondroid syringoma)

The rare malignant mixed tumor favors the trunk and extremities, whereas the benign mixed tumor of the skin favors the head and neck. At presentation, the masses range from 1 to 10 cm, with a median size of 4 cm. They often grow rapidly. The chance of metastasis is greater than 50%, with a predilection for visceral spread. Metastases usually take the form of an adenocarcinoma, and the chondroid stroma found in primary lesions is often not found. Histologic features that distinguish malignant mixed tumor from chondroid syringoma include cytologic atypia, pleomorphism, increased mitotic activity, and focal necrosis. Treatment is surgical.

**Hafezi-Bakhtiari S, et al:** Benign mixed tumor of the skin, hypercellular variant: a case report. *J Cutan Patol* 2010; 37(9):e46–e49.

**Kakitsubata Y, et al:** Giant chondroid syringoma presenting as a growing subcutaneous mass in the upper arm: MRI findings with pathologic correlation. *Joint Bone Spine* 2009; 76:711.

**Laxmisha C, et al:** Chondroid syringoma of the ear lobe. *J Cutan Pathol* 2009; Jul 10.

**Malik R, et al:** A rare case of malignant chondroid syringoma of scalp. *Indian Dermatol Online J* 2013; 4(3):236–238.

- Nangia A, et al:** Chondroid syringoma with extensive osseous differentiation: a rare finding. *Indian J Pathol Microbiol* 2014; 57(2):344–345.
- Naujokas A, et al:** SOX-10 expression in cutaneous myoepitheliomas and mixed tumors. *J Cutan Pathol* 2014; 41(4):353–363.
- Sivamani R, et al:** Chondroid syringoma: case report and review of the literature. *Dermatol Online J* 2006; 12:8.

## Ceruminoma

Ceruminous glands, modified apocrine glands of the external ear, may give rise to both benign and malignant tumors. Distinguishing these may be difficult; thus, both the malignant and the benign tumors have been termed ceruminomas. The tumors present as a firm papule or nodule in the external auditory canal. Ulceration and crusting may occur, and continued growth may obstruct the meatus, resulting in hearing loss. Histologically, glands and cysts are present, lined by a tuboglandular proliferation with two layers: an inner layer of ceruminous cells (containing cerumen and with decapitation secretion) and a basal spindled or cuboidal myoepithelial layer. Treatment is excision, which is curative if margins are clear.

- Crain N, et al:** Ceruminous gland carcinomas: a clinicopathologic and immunophenotypic study of 17 cases. *Head Neck Pathol* 2009; 3(1):1–17.
- Giuseppe M, et al:** Adenoma of the ceruminous gland (ceruminoma). *Otol Neurotol* 2011; 32(2):e14–e15.
- Jan JC, et al:** Ceruminous adenocarcinoma with extensive parotid, cervical, and distant metastases: case report and review of literature. *Arch Otolaryngol Head Neck Surg* 2008; 134(6):663–666.
- Thompson LD, et al:** Ceruminous adenomas: a clinicopathologic study of 41 cases with a review of the literature. *Am J Surg Pathol* 2004; 28:308.

## Hidradenoma papilliferum

Hidradenoma papilliferum is a benign adenoma that arises from anogenital mammary-like glands and is located almost exclusively in the vulvar and perianal areas. The tumor is covered by normal skin. On palpation, it is a firm papule less than 1 cm in diameter. Malignant transformation is rare and can resemble a focus of ductal carcinoma in situ. Microscopically, hidradenoma papilliferum is encapsulated and lies in the dermis, having no connection with the epidermis. There is a cystlike cavity lined with villi. The walls of the cavity and the villi are lined, occasionally with a single layer but usually with a double layer of cells: luminal secretory cells and myoepithelial cells. This is a benign lesion, and the diagnosis and treatment are accomplished by excisional biopsy.

- Duhan N, et al:** Hidradenoma papilliferum of the vulva: case report and review of literature. *Arch Gynecol Obstet* 2011; 284(4):1015–1017.
- Hama M, et al:** Ulcerated hidradenoma papilliferum. *Int J Dermatol* 2013; 52(2):198–199.
- Kazakov DV, et al:** Lesions of anogenital mammary-like glands: an update. *Adv Anat Pathol* 2011; 18(1):1–28.
- Kurashige Y, et al:** Hidradenoma papilliferum of the vulva in association with an anogenital mammary-like gland. *J Dermatol* 2014; 41(5):411–413.
- Moon JW, et al:** Giant ectopic hidradenoma papilliferum on the scalp. *J Dermatol* 2009; 36:545.
- Veeranna S, et al:** Solitary nodule over the labia majora: hidradenoma papilliferum. *Indian J Dermatol Venereol Leprol* 2009; 75:327.

## Syringadenoma papilliferum (syringocystadenoma papilliferum)

This lesion develops in a nevus sebaceus of Jadassohn on the scalp or face in about one third of patients. Around half are

present at birth, while approximately 25% arise on the trunk and genital and inguinal regions during adolescence. The lesions are rose-red papules of firm consistency; they vary from 1 to 3 mm and may occur in groups. Vesicle-like inclusions are seen, pinpoint to pinhead in size, filled with clear fluid. Some of the papules may be umbilicated and simulate molluscum contagiosum. Extensive verrucous or papillary plaques may also be present.

Histologically, the tumor shows ductlike structures that extend from the surface epithelium. Numerous papillary projections may extend into the lumina, which may be cystic. The papillary projections are lined by glandular epithelium, often consisting of two rows of cells. The tumor cells stain positive for CEA. The dermal stroma contains numerous plasma cells. Rarely, malignant transformation may occur. Excision is recommended.

- Chauhan A, et al:** Linear syringocystadenoma papilliferum: a case report with review of literature. *Indian J Dermatol* 2013; 58(5):409.
- Chi CC, et al:** Syringocystadenocarcinoma papilliferum: successfully treated with Mohs micrographic surgery. *Dermatol Surg* 2004; 30:468.
- Dufrechou L, et al:** Syringocystadenoma papilliferum arising on the scrotum. *Pediatr Dermatol* 2013; 30(3):e12–e13.
- Ghazeri G, Abbas O:** Syringocystadenoma papilliferum developing over hyperkeratosis of the nipple in a pregnant woman. *J Am Acad Dermatol* 2014; 70(4):e84–e85.
- Hoekzema R, et al:** Syringocystadenocarcinoma papilliferum in a linear nevus verrucosus. *J Cutan Pathol* 2009.
- Idriss MH, Elston DM:** Secondary neoplasms associated with nevus sebaceus of Jadassohn: a study of 707 cases. *J Am Acad Dermatol* 2014; 70(2):332–337.
- Khurana VK, et al:** A case of syringocystadenocarcinoma papilliferum on lower leg: a rare location. *Indian J Dermatol* 2013; 58(5):405.
- Monticciolo NL, et al:** Verrucous carcinoma arising within syringocystadenoma papilliferum. *Ann Clin Lab Sci* 2002; 32:434.
- Mundi JP, et al:** Syringocystadenoma. *Dermatol Online J* 2013; 19(12):20722.
- Ogunrinade K, et al:** Agminated syringocystadenoma papilliferum: a new clinical presentation of a rare benign adnexal neoplasm. *Dermatol Online J* 2013; 19(8):19270.
- Sangma MM, et al:** Syringocystadenoma papilliferum of the scalp in an adult male: a case report. *J Clin Diagn Res* 2013; 7(4):742–743.
- Satter E, et al:** Syringocystadenocarcinoma papilliferum with locoregional metastases. *Dermatol Online J* 2014; 20(4):22335.
- Schaffer JV, et al:** Syringocystadenoma papilliferum in a patient with focal dermal hypoplasia due to a novel *PORCN* mutation. *Arch Dermatol* 2009; 145:218.
- Steshenko O, et al:** Syringocystadenoma papilliferum of the vulva: a rarity in gynecology. *BMJ Case Rep* 2014; May 28.

## Papillary eccrine adenoma (tubular apocrine adenoma)

This uncommon benign sweat gland neoplasm presents clinically as dermal nodules located primarily on the extremities of black patients, especially on the dorsal hand or foot. Histologic findings consist of a well-circumscribed, dermal, unencapsulated growth composed of dilated ductlike structures lined by two or more layers of cells. Intraluminal papillations may project into the cystic spaces. Because this lesion tends to recur locally, complete surgical excision with clear margins is recommended. Hybrid or overlapping lesions with a superficial component resembling syringocystadenoma papilliferum and a deep component resembling tubular adenoma can occur.

- Kazakov DV, et al:** Tubular adenoma and syringocystadenoma papilliferum: a reappraisal of their relationship. An interobserver study of a series, by a panel of dermatopathologists. *Am J Dermatopathol* 2007; 29:256.



**Kim MS, et al:** a case of tubular apocrine adenoma with syringocystadenoma papilliferum that developed in a nevus sebaceus. *Ann Dermatol* 2010; 22(3):319–322.

**Lee HJ, et al:** Syringocystadenoma papilliferum of the back combined with a tubular apocrine adenoma. *Ann Dermatol* 2011; 23(Suppl 2):S151–S154.

**Martinelli PT, et al:** Mohs micrographic surgery for tubular apocrine adenoma. *Int J Dermatol* 2006; 45(11):1377–1378.

## Syringofibroadenoma (acrosyringal nevus of Weedon and Lewis)

First described by Mascaro in 1963, five variants of eccrine syringofibroadenoma are now recognized:

1. Solitary
2. Multiple, in Schopf syndrome
3. Multiple, without other skin manifestations
4. Nonfamilial unilateral linear
5. Reactive

The solitary type presents frequently as a hyperkeratotic nodule or plaque involving the extremities. The linear type may be linear, blaschkoid, or zosteriform in appearance, and some cases may represent an acrosyringal nevus. Multiple lesions have been termed eccrine syringofibroadenomatosis (ESFA) and occur in both variants of hidrotic ectodermal dysplasia, Schopf syndrome, and Clouston syndrome. The multiple ESFAs may appear in a mosaic pattern. In Clouston syndrome (due to mutation in the *GJB6* gene), HPV-10 has been detected in the tumors. Multiple lesions have also been reported without other associated cutaneous findings. Many cases represent a reactive epithelial proliferation, whereas others represent a true neoplasm of acrosyringal cells. Histologically, the strands resemble those of the fibroepithelial tumor of Pinkus, but with broader anastomosing cords without the basaloid buds. “Reactive eccrine syringofibroadenoma” most often occurs on the lower leg and may show adjacent changes of an associated dermatosis. Carcinomatous transformation of ESFA has been reported.

**Castori M, et al:** Schöpf-Schulz-Passarge syndrome: further delineation of the phenotype and genetic considerations. *Acta Derm Venereol*. 2008; 88(6):607–612.

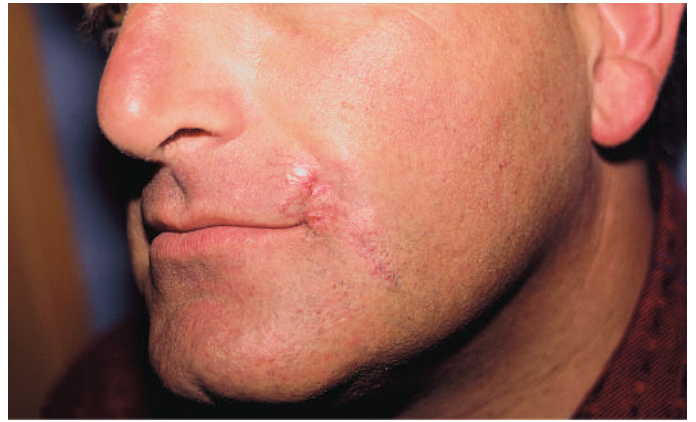**De Andrade AC, et al:** Clouston syndrome associated with eccrine syringofibroadenoma. *An Bras Dermatol* 2014; 89(3):504–506.

**Husein-ElAhmed H, et al:** Solitary eccrine syringofibroadenoma arising on the toe. *J Dtsch Dermatol Ges* 2014; 12(2):148–150.

**Xu XL, et al:** A case of multiple eccrine syringofibroadenoma mimicking verruca vulgaris. *J Dermatol* 2013; 40(8):665–666.

## Microcystic adnexal carcinoma (sclerosing sweat duct carcinoma)

This tumor generally presents as a very slow-growing plaque or nodule. It occurs most frequently on the head and neck (87%), face (73%), and scalp (10%). Lesions favor the midface and periorbital area, with a predilection for the left side. The upper lip (Fig. 29-40) is involved nine times more often than the lower lip. Given their propensity for sun-exposed sites, long-term sun exposure may play a role in the pathogenesis of microcystic adnexal carcinomas; they have also occurred at sites of prior therapeutic radiation. The lesions are locally aggressive, with local recurrences in 50% of cases. Metastasis rarely occurs. Microcystic adnexal carcinoma occurs most often in Caucasians (90%) but also is reported in Japanese Americans and in African Americans, in whom it may be



**Fig. 29-40** Microcystic adnexal carcinoma.

found in atypical locations. Histologically, the superficial part of the tumor is composed of ducts, keratinous cysts, and small cords of cells, superficially resembling a syringoma. The deeper component consists of nests and strands in a dense stroma. Perineural invasion is common and may be extensive. This explains the frequent recurrence after initial excision. Specific immunohistochemical markers have been proposed to distinguish microcystic adnexal carcinoma from infiltrative BCC, desmoplastic trichoepithelioma, and SCC. Mohs microsurgery is the treatment of choice. Radiation treatment of the tumor is controversial; it may be useful as adjuvant therapy but appears to be inadequate as monotherapy, with potential for recurrence and more aggressive behavior of the tumor.

**Baxi S, et al:** Microcystic adnexal carcinoma of the skin: the role of adjuvant radiotherapy. *J Med Imaging Radiat Oncol* 2010; 54(5):477–482.

**Gabillot-Carre M, et al:** Microcystic adnexal carcinoma: report of seven cases including one with lung metastasis. *Dermatology* 2006; 212:221.

**Hansen T, et al:** Extrafacial microcystic adnexal carcinoma: case report and review of the literature. *Dermatol Surg* 2009; 35:1835.

**Leibovitch I, et al:** Microcystic adnexal carcinoma: treatment with Mohs micrographic surgery. *J Am Dermatol* 2005; 52:295.

**Nadiminti H, et al:** Microcystic adnexal carcinoma in African-Americans. *Dermatol Surg* 2007; 33:1384.

**Ohtsuka H, Nagamatsu S:** Microcystic adnexal carcinoma: review of 51 Japanese patients. *Dermatology* 2002; 204:190.

**Pugh TJ, et al:** Microcystic adnexal carcinoma of the face treated with radiation therapy: a case report and review of the literature. *Head Neck* 2012; 34(7):1045–1050.

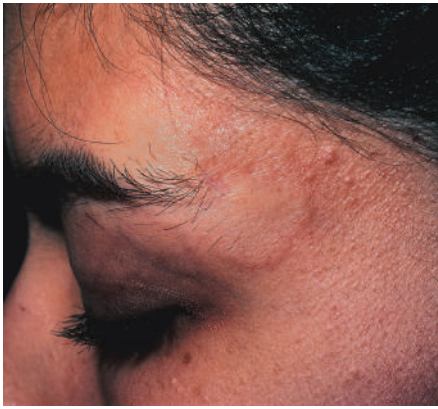
**Smart DR, et al:** Microcystic adnexal carcinoma: the first reported congenital case. *Pediatr Dermatol* 2011; 28(1):35–38.

**Vidal CI, et al:** p63 Immunohistochemistry is a useful adjunct in distinguishing sclerosing cutaneous tumors. *Am J Dermatopathol* 2010; 32(3):257–261.

**Yu JB, et al:** Surveillance, epidemiology, and end results (SEER) database analysis of microcystic adnexal carcinoma (sclerosing sweat duct carcinoma) of the skin. *Am J Clin Oncol* 2010; 33(2):125–127.

## Eccrine carcinoma (syringoid carcinoma)

Eccrine carcinoma is rare and presents as a plaque or nodule on the scalp (Fig. 29-41), trunk, or extremities. Local recurrence is common, but metastases are rare. It is composed of ducts and tubules with atypical basaloid cells. A more cellular tumor with numerous tubules and ducts has been termed polymorphous sweat gland carcinoma. Overlap features with microcystic adnexal carcinoma occur, but in general, eccrine carcinoma has a less desmoplastic stroma.



**Fig. 29-41** Eccrine carcinoma.

## Mucinous carcinoma

Mucinous carcinoma is typically a round, elevated, reddish, and sometimes ulcerated mass, usually located on the head and neck (75%). Forty percent occur on the eyelid. It grows slowly and is usually asymptomatic. Local recurrence is seen in 36%, but the rate of metastasis and widespread dissemination is low (15%). Rare tumors on the eyelid (derived from glands of Moll) may express estrogen and progesterone receptors, analogous to mucinous carcinoma of the breast. Mucinous gut carcinomas may also metastasize to skin and must be excluded before diagnosing a primary cutaneous mucinous carcinoma.

Histologically, tumors are characterized by the presence of large areas of mucin, in which small islands of basophilic epithelial cells are embedded (blue islands floating in a sea of mucus). Basaloid cells in a cribriform pattern, with ductlike structures, are typical. The recommended treatment is surgical excision; Mohs surgery leads to lower rates of recurrence when compared to those treated with traditional surgical excision (13% vs. 34%).

**Frances L, et al:** Secondary mucinous carcinoma of the skin. *Dermatol Online J* 2014; 20(4):22361.

**Kamalpour L, et al:** Primary cutaneous mucinous carcinoma: a systematic review and meta-analysis of outcomes after surgery. *JAMA Dermatol* 2014; 150(4):380–384.

**Marra DE, et al:** Mohs micrographic surgery of primary cutaneous mucinous carcinoma using immunohistochemistry for margin control. *Dermatol Surg* 2004; 30:799.

**Wako M, et al:** Mucinous carcinoma of the skin with apocrine-type differentiation: immunohistochemical studies. *Am J Dermatopathol* 2003; 25:66.

## Aggressive digital papillary adenocarcinoma (digital papillary adenocarcinoma)

This aggressive malignancy involves the digit between the nail bed and the distal interphalangeal joint spaces in most cases, or occurs just proximal to this region. It presents as a solitary cystic nodule. Ulceration and bleeding can occur, and rarely the malignancy may be fixed to underlying tissues. Most patients are men in their fifties. The tumor is locally aggressive, with a 50% local recurrence rate. Metastases, particularly pulmonary, occur in about 15% of cases. The tumor is poorly circumscribed and is composed of tubuloalveolar and ductal structures with areas of papillary projections. The tumor is positive for S-100, and the cystic contents are positive for CEA and EMA. Complete excision is the treatment of choice. Cases previously called aggressive digital papillary “adenoma” are best regarded as adenocarcinoma.

**Chen S, Asgari M:** Papillary adenocarcinoma in situ of the skin: report of four cases. *Dermatol Pract Concept* 2014; 4(2):23–28.

**Hsu HC, et al:** Aggressive digital papillary adenocarcinoma: a review. *Clin Exp Dermatol* 2010; 35(2):113–119.

**Suchak R, et al:** Cutaneous digital papillary adenocarcinoma: a clinicopathologic study of 31 cases of a rare neoplasm with new observations. *Am J Surg Pathol* 2012; 36(12):1883–1891.

## Primary cutaneous adenoid cystic carcinoma

This rare cutaneous tumor usually presents on the chest, scalp, or vulva of middle-age to older persons. It is similar histologically to adenoid cystic carcinoma of the salivary gland, with a proliferation of small, ductlike islands and larger islands with a “Swiss cheese” or cribriform pattern. Detection of HPV and overexpression of p16 (a tumor suppressor protein also called CDKN2A) has been demonstrated in many of these lesions. Adenoid cystic carcinoma may recur locally or rarely metastasizes. Surgical excision, perhaps with Mohs micrographic surgery, is the treatment of choice.

**Boland JM, et al:** Detection of human papilloma virus and p16 expression in high-grade adenoid cystic carcinoma of the head and neck. *Mod Pathol* 2012; 25(4):529–536.

**Dores GM, et al:** Primary cutaneous adenoid cystic carcinoma in the United States: incidence, survival, and associated cancers, 1976 to 2005. *J Am Acad Dermatol* 2010; 63(1):71–78.

**Maybury CM, et al:** A nodule in the groin: primary cutaneous adenoid cystic carcinoma (pcACC). *JAMA Dermatol* 2013; 149(11):1343–1344.

**Ramakrishnan R, et al:** Primary cutaneous adenoid cystic carcinoma: a clinicopathologic and immunohistochemical study of 27 cases. *Am J Surg Pathol* 2013; 37(10):1603–1611.

**Xu YG, et al:** Cutaneous adenoid cystic carcinoma with perineural invasion treated by Mohs micrographic surgery: a case report with literature review. *J Oncol* 2010; 2010:469049.

## Apocrine gland carcinoma

Apocrine gland carcinoma unrelated to Paget’s disease is rare. The axilla or anogenital region is the most common site, but occasionally, other areas with apocrine glands may be involved. Lesions present as a mass. Widespread metastases occur in at least 40% of cases.

**Figueira EC, et al:** Apocrine adenocarcinoma of the eyelid: case series and review. *Ophthalm Plast Reconstr Surg* 2013; 29(6):417–423.

**Goldstein R, et al:** Advanced vulvar apocrine carcinoma expressing estrogen receptors that responds to tamoxifen therapy. *Future Oncol* 2012; 8(9):1199–1203.

**Hollowell KL, et al:** Cutaneous apocrine adenocarcinoma: defining epidemiology, outcomes, and optimal therapy for a rare neoplasm. *J Surg Oncol* 2012; 105(4):415–419.

**Kajal B, et al:** Apocrine adenocarcinoma of the vulva. *Rare Tumors* 2013; 5(3):e40.

**Singh H, et al:** Apocrine sweat gland carcinoma: initial evaluation, staging, and response monitoring using 18F-FDG PET/CT. *Clin Nucl Med* 2013; 38(5):e223–e225.

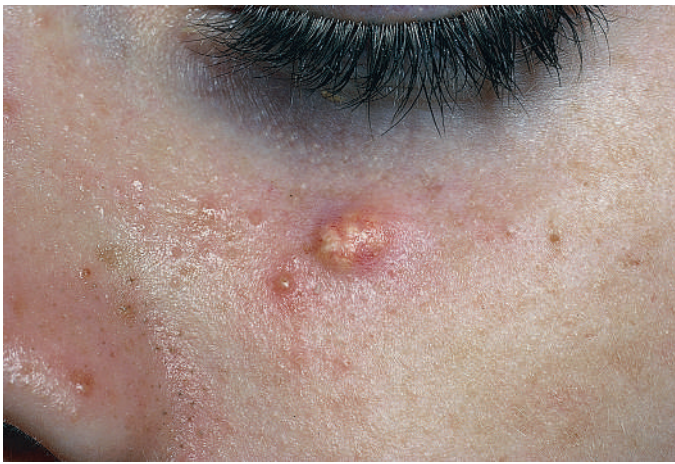**Terada T, et al:** Apocrine carcinoma of the scrotum with extramammary Paget’s disease. *Int J Dermatol* 2013; 52(4):504–506.

## HAIR FOLLICLE NEVI AND TUMORS

### Pilomatricoma (calcifying epithelioma of Malherbe)

Also known as Malherbe calcifying epithelioma and pilomatricoma, this benign tumor is derived from hair matrix cells. It usually occurs as a single lesion, which is most often found on the face, neck, or proximal upper extremity. Lesions may also be located on the scalp, trunk, and lower extremities.





**Fig. 29-42** Pilomatricoma, larger lesion with yellow tint.

Pilomatricoma is an asymptomatic, deeply seated, 0.5–7 cm, firm nodule covered by normal or pink skin. On stretching, it may show the “tent sign,” with multiple facets and angles (Fig. 29-42); on gentle pinching, it may show the “skin crease sign,” with a central longitudinal crease. Overlying epidermal atrophy is common, leading to an appearance that may resemble anetoderma or striae. “Giant” and “bullous” presentations have been described. In a review of 239 patients, the youngest was 1 year and the oldest, 83 years. There is a bimodal age distribution, in the first and sixth decades. Females are more often affected than males.

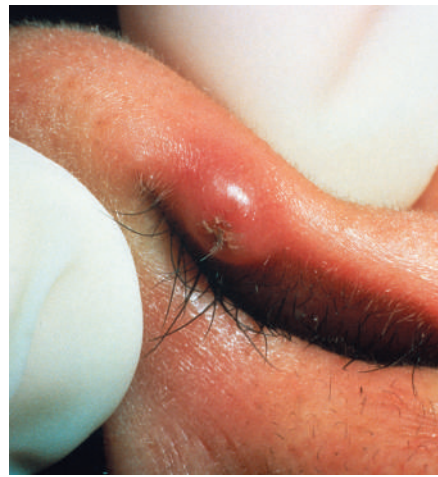Multiple pilomatricomas are uncommon. They are usually seen in association with myotonic dystrophy–Steinert syndrome. They may also occur in Rubinstein-Taybi syndrome, trisomy 9, and Turner syndrome. Patients with Gardner syndrome have epidermoid cysts with focal areas of pilomatricoma-like changes. Rarely, multiple pilomatricomas will be inherited in an autosomal dominant pattern with no other association.

The histopathology shows an encapsulated mass. Basophilic cells with minimal cytoplasm resemble those of the hair matrix. They evolve into eosinophilic “shadow” cells. Calcification occurs frequently. Ossification, melanin deposits, and foreign body reaction with giant cells may all be present. Activating mutations in  $\beta$ -catenin are present in the majority of pilomatricomas. It is expressed in the basophilic but not the shadow cells. “Melanocytic matricoma” is a rare lesion presenting as a small papule, which histologically is composed of matrical cells, some shadow cells, and numerous dendritic melanocytes containing melanin. It appears to be a fairly common variant in the Japanese population.

Clinical differential diagnosis is usually impossible in the adult, but in children, since epidermoid cysts are rare, this diagnosis should be considered for any firm cystic mass of the face and upper body. When palpated, pilomatricomas are firmer and more faceted than epidermoid and pilar cysts. Fine-needle aspiration has led to misdiagnosis, with the basophilic cells being interpreted as carcinoma. Treatment is surgical excision.

### Malignant pilomatricoma (pilomatrix carcinoma, pilomatrical carcinoma)

Malignant pilomatricomas are rare tumors. Described as being locally aggressive, but with limited metastatic potential, many cases labeled “malignant” may actually have been “proliferating” pilomatricomas. Metastases to regional lymph nodes are most common. Mohs micrographic surgery may be considered to obtain clear margins.



**Fig. 29-43**  
Trichofolliculoma.

- Belliappa P, et al:** Bullous pilomatricoma: a rare variant resembling bouncy ball. *Int J Trichology* 2013; 5(1):32–34.
- Berberian BJ, et al:** Multiple pilomatricomas in association with myotonic dystrophy and a family history of melanoma. *J Am Acad Dermatol* 1997; 37:268.
- Blaya B, et al:** Multiple pilomatricomas in association with trisomy 9. *Pediatr Dermatol* 2009; 26:482.
- Chattopadhyay M, et al:** Anetodermic pilomatricoma in a patient with hypermobility syndrome. *Clin Exp Dermatol* 2014; 39(2):218–220.
- Cornejo KM, Deng A:** Pilomatrix carcinoma: a case report and review of the literature. *Am J Dermatopathol* 2013; 35(3):389–394.
- Gupta M, et al:** Aggressive pilomatrixoma: a diagnostic dilemma on fine-needle aspiration cytology with review of literature. *Diagn Cytopathol* 2014; 42(10):906–911.
- Handler MZ, et al:** Prevalence of pilomatricoma in Turner syndrome: findings from a multicenter study. *JAMA Dermatol* 2013; 149(5):559–564.
- Hernández-Núñez A, et al:** Retrospective study of pilomatricoma: 261 tumors in 239 patients. *Actas Dermosifiliogr* 2014; 105(7):699–705.
- Herrmann JL, et al:** Pilomatrix carcinoma: 13 new cases and review of the literature with emphasis on predictors of metastasis. *J Am Acad Dermatol* 2014; 71(1):38–43.e2.
- Ieni A, et al:** Limits of fine-needle aspiration cytology in diagnosing pilomatrixoma: a series of 25 cases with clinico-pathologic correlations. *Indian J Dermatol* 2012; 57(2):152–155.
- Ishida M, Okabe H:** Pigmented pilomatricoma: an underrecognized variant. *Int J Clin Exp Pathol* 2013; 6(9):1890–1893.
- Julian CG, et al:** A clinical review of 209 pilomatricomas. *J Am Acad Dermatol* 1998; 39:191.
- Kim IH, Lee SG:** The skin crease sign: a diagnostic sign of pilomatricoma. *J Am Acad Dermatol* 2012; 67(5):e197–e198.
- Kwon D, et al:** Characteristics of pilomatrixoma in children: a review of 137 patients. *Int J Pediatr Otorhinolaryngol* 2014; 78(8):1337–1341.
- Niiyama S, et al:** Proliferating pilomatricoma. *Eur J Dermatol* 2009; 19:188.
- Sable D, Snow SN:** Pilomatrix carcinoma of the back treated by Mohs micrographic surgery. *Dermatol Surg* 2004; 30:1174.
- Sherrod QJ, et al:** Multiple pilomatricomas: cutaneous marker for myotonic dystrophy. *Dermatol Online J* 2008; 14:22.
- Souto MP, et al:** An unusual presentation of giant pilomatrixoma in an adult patient. *J Dermatol Case Rep* 2013; 7(2):56–59.

### Trichofolliculoma

Trichofolliculoma is a benign, highly structured tumor of the pilosebaceous unit, characterized by a small, dome-shaped nodule about 5 mm in diameter on the face or scalp. From the center of the flesh-colored nodule, a small wisp of fine, vellus hairs protrudes through a central pore (Fig. 29-43). It may occur at any age but mostly affects adults. Mouse studies suggest that dysregulation of bone morphogenic protein sig-

naling in hair follicle progenitors may contribute to trichofolliculoma formation.

Histologically, the tumor consists of one or more large follicles with smaller, radiating, secondary follicular structures, sometimes referred to as “the mother follicle with her babies.” The secondary follicles range from an immature rudimentary matrix to well-formed follicles with papillae, matrix, trichohyaline, and fine hairs (“fingers of fully formed follicles forming fiber”). The tumor may have little stroma or may be embedded in a fibrous orb. Sebaceous glands may be prominent, a variant termed sebaceous trichofolliculoma. The follicular structures in trichofolliculomas transition through phases of the hair cycle. In telogen, they may resemble fibrofolliculomas. The presence of hair shafts helps distinguish the two. Folliculosebaceous cystic hamartoma may closely resemble a sebaceous trichofolliculoma. Treatment is surgical removal.

**Kan L, et al:** Inhibition of BMP signaling in P-cadherin positive hair progenitor cells leads to trichofolliculoma-like hair follicle neoplasias. *J Biomed Sci* 2011; 18:92.

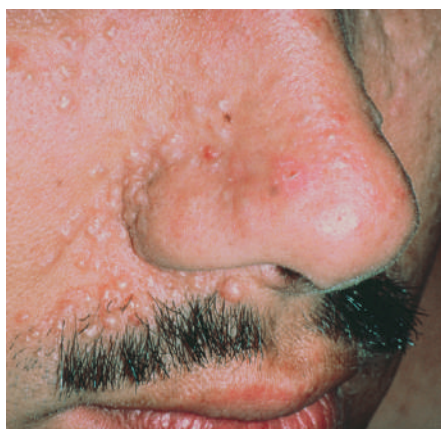**Misago N, et al:** A reevaluation of trichofolliculoma: the histopathological and immunohistochemical features. *Am J Dermatopathol* 2010; 32(1):35–43.

**Tanimura S, et al:** Two cases of folliculosebaceous cystic hamartoma. *Clin Exp Dermatol* 2006; 31:68.

**Wu YH:** Folliculosebaceous cystic hamartoma or trichofolliculoma? A spectrum of hamartomatous changes induced by perifollicular stroma in the follicular epithelium. *J Cutan Pathol* 2008; 35(9):843–848.

### Brooke-Spiegler syndrome (multiple familial trichoepithelioma, epithelioma adenoides cysticum)

This autosomal dominant condition usually presents in childhood or around puberty. Familial cylindroma, multiple familial trichoepithelioma, and Brooke-Spiegler syndrome are all variants of the same condition. The favored term is Brooke-Spiegler syndrome (BSS). There is a variable phenotypic expression among and within families and patients. The multiple trichoepitheliomas present as multiple cystic and solid papules on the face, favoring the upper lip, nasolabial folds, and eyelids. The individual lesions are small, round, smooth, shiny, slightly translucent, firm, circumscribed papules or nodules. The individual lesions average 2–4 mm in diameter. The center may be slightly depressed. Most frequently, the lesions are grouped but discrete. On the face, they are often symmetric (Fig. 29-44). Other sites may be the scalp, neck, and trunk. Multiple linear and dermatomal trichoepitheliomas may rarely be seen. Multiple cylindromas and spiradenomas, epidermoid cysts, and milia may occur in association with



**Fig. 29-44**  
Trichoepitheliomas.

multiple trichoepitheliomas. BSS is caused by mutations in *CYLD*, which functions as a tumor suppressor gene. It has a critical role in deubiquinating proteins, which is important in controlling their biologic function. Some individuals in these families have primarily trichoepitheliomas, others have primarily cylindromas, and others have a panoply of adnexal tumors, including cylindromas, trichoepitheliomas, and spiradenomas. BSS patients seem to be at particular risk for degeneration of their cylindromas and spiradenomas to carcinomas.

### Solitary trichoepithelioma

The singly occurring trichoepithelioma is nonhereditary and mostly favors the face. However, it may also be found on the scalp, neck, trunk, and proximal extremities. It presents as a firm dermal papule or nodule and must be distinguished from BCC.

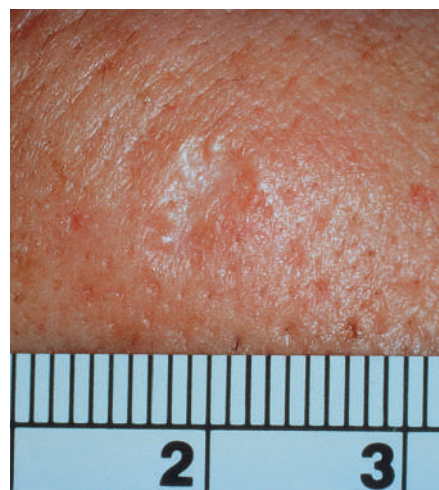
### Giant solitary trichoepithelioma

The lesions may be several centimeters in diameter, occurring most frequently on the thigh or perianal regions. They are found in older adults.

### Desmoplastic trichoepithelioma

This lesion, which is difficult to differentiate from morpheiform BCC histologically, occurs as solitary or multiple lesions on the face. Desmoplastic trichoepitheliomas are firm and slightly indented (central dell sign), with a raised, annular border (Fig. 29-45). Young women are most often affected, and familial solitary and multiple desmoplastic trichoepitheliomas have been described.

Trichoepitheliomas are dermal tumors with multiple nests of basaloid cells, some of which show abortive follicular differentiation. Keratinous cysts, calcification, and amyloid may all be seen. The stroma in most trichoepitheliomas resembles the fibrous sheath of a normal hair follicle. It contains many fine collagen fibers and fibroblasts that surround the tumor islands in a concentric array. Clusters of plump nuclei resembling the cells of the follicular papilla (papillary mesenchymal bodies) are common. In the desmoplastic variety, the tumor is composed of small cords of epithelium embedded in a dense eosinophilic stroma with fewer fibroblasts. The islands often



**Fig. 29-45**  
Trichoepithelioma, desmoplastic type.



present a “paisley tie” appearance, and the microscopic differential diagnosis includes morpheaform BCC, syringoma, and microcystic adnexal carcinoma. The clinical features may distinguish these entities. Focal calcification, horn cysts, and a central dell favor trichoepithelioma. In desmoplastic trichoepithelioma, clefts form between collagen fibers in the stroma, whereas in BCC, clefts form between the tumor islands and stroma. Trichoepitheliomas are best classified as benign tumors of the hair germ. As such, they may be considered variants of trichoblastoma. Histologically, trichoepithelioma must be differentiated from keratotic BCC, with which it is frequently confused.

Solitary lesions can be treated by surgical excision. Multiple lesions can be smoothed down by resurfacing the skin with laser surgery, dermabrasion, or electrosurgery. This procedure must be repeated at regular intervals, as the lesions gradually recur.

### Trichoblastoma

These benign neoplasms of follicular germinative cells usually present as asymptomatic nodules 0.5–1 cm in size in the deep dermis or subcutaneous tissue. The scalp is the most common location, especially if associated with nevus sebaceus of Jadassohn. Trichoblastomas usually occur in adult men and women, but children can also develop them. The lesions may be pigmented. Trichoblastomas arise in organoid nevi and represent the majority of basaloid neoplasms described as “basal cell carcinomas” in nevus sebaceus. The rare Curry-Jones syndrome, with cutaneous streaky hypopigmentation, hyperpigmented linear atrophic lines on the soles, and many other musculoskeletal, ocular, and GI defects, can feature multiple trichoblastomas. Histologically, trichoblastoma is a dermal or subcutaneous tumor composed of basaloid cells with areas of follicular differentiation. The islands may connect with the overlying epidermis, especially in the setting of an organoid nevus. The stroma is identical to that seen in trichoepithelioma and typically contains papillary mesenchymal bodies. Merkel cells may be prominent within the tumor, and amyloid can be found. Cutaneous lymphadenoma is a variant of trichoblastoma with extensive infiltration of the tumor islands by lymphocytes and histiocytes. The stroma resembles that of other trichoblastomas. A single or double row of basaloid tumor cells is seen at the periphery of each island, whereas the center is composed of histiocytes and lymphocytes. Surgical excision is curative.

**Blake PW, Toro JR:** Update of cylindromatosis gene (*CYLD*) mutations in Brooke-Spiegler syndrome: novel insights into the role of deubiquitination in cell signaling. *Hum Mutat* 2009; 30:1025.

**Chen M, et al:** Brooke-Spiegler syndrome associated with cylindroma, trichoepithelioma and eccrine spiradenoma. *Int J Dermatol* 2013; 52(12):1602–1604.

**Grange DK, et al:** Two new patients with Curry-Jones syndrome with trichoblastoma and medulloblastoma suggest an etiologic role of the sonic hedgehog-patched-GLI pathway. *Am J Med Genet* 2008; 146A:2589.

**Grossmann P, et al:** Novel and recurrent germline and somatic mutations in a cohort of 67 patients from 48 families with Brooke-Spiegler syndrome including the phenotypic variant of multiple familial trichoepitheliomas and correlation with the histopathologic findings in 379 biopsy specimens. *Am J Dermatopathol* 2013; 35(1):34–44.

**Hochwalt PC, et al:** Numerous facial lesions in a 47-year-old woman. *JAMA Dermatol* 2013; 149(2):223.

**Kang TW, et al:** Trichoblastoma in a child. *Pediatr Dermatol* 2009; 26:476.

**Kirby JS, et al:** Trichoblastic carcinoma associated with multiple familial trichoepithelioma. *Dermatol Surg* 2012; 38(12):2018–2021.

**Koay JL, et al:** Asymptomatic annular plaque of the chin: desmoplastic trichoepithelioma. *Arch Dermatol* 2002; 138:1091.

**LoPiccolo MC, et al:** Comparing ablative fractionated resurfacing, photodynamic therapy, and topical imiquimod in the treatment of trichoblastomas of Brooke-Spiegler syndrome: a case study. *Dermatol Surg* 2011; 37(7):1047.

**Mollet PU, Muñoz JF:** False-negative tumor-free margins following Mohs surgery for aggressive trichoblastoma. *Am J Dermatopathol* 2012; 34(3):255–258.

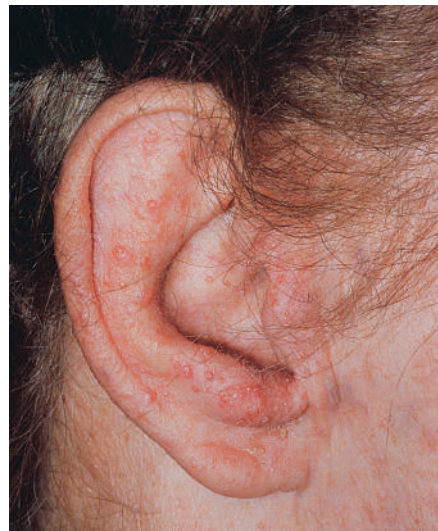**Ponti G, et al:** Brooke-Spiegler syndrome: report of two cases not associated with a mutation in the *CYLD* and *PTCH* tumor-suppressor genes. *J Cutan Pathol* 2012; 39:366.

**Samaka RM, et al:** Multiple familial trichoepithelioma with malignant transformation. *Indian J Dermatol* 2013; 58(5):409.

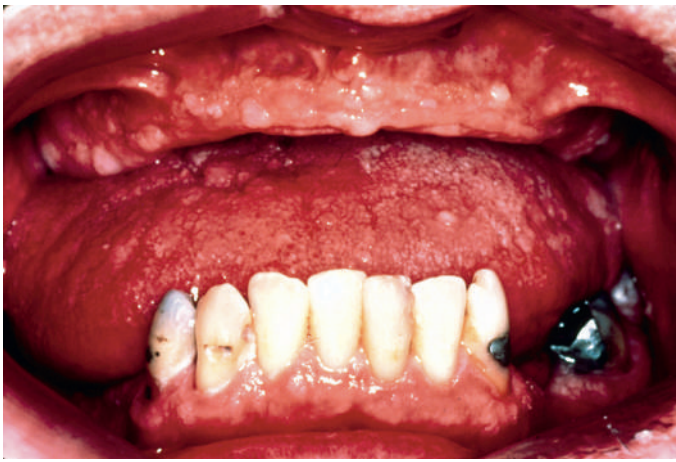### Trichilemmoma and Cowden syndrome (Cowden's disease, multiple hamartoma syndrome)

Trichilemmoma is a benign neoplasm that differentiates toward cells of the outer root sheath. It usually occurs as a small, solitary papule on the face, particularly the nose and cheeks. Sporadic tumors are often caused by activating *HRAS* mutations. Most lesions are clinically misdiagnosed as BCC or benign keratosis.

Trichilemmomas may also occur as multiple facial lesions. When they do, this is a specific cutaneous marker for Cowden syndrome (CS), an autosomal dominant inherited condition. The prevalence of CS is 1 in /200,000–250,000. The penetrance is almost complete, with 90% of affected patients having stigmata by age 20. Diagnostic criteria for CS have been established, and certain mucocutaneous manifestations are considered pathognomonic, including trichilemmomas of the face, acral keratoses, papillomatous papules (Figs 29-46 and 29-47), and mucosal lesions. The trichilemmomas, or “facial papules,” are present in 86% of CS patients and appear on average at age 22 but can appear at any age from childhood to advanced age (75 years). Trichilemmomas are generally limited to the head and neck, especially the central face, around the orifices; however, other sites may be involved (e.g., ears). Because not all facial papules have characteristic histology, the presence of “papillomatous” lesions is a diagnostic criterion. The other pathognomonic mucocutaneous benign features are acral keratoses, which present as either verrucous hyperkeratosis on the extensor extremities, or palmoplantar translucent keratoses, in 28% and 20% of CS patients, respectively. Acral neuromatosis may present as translucent papules on the backs and sides of the fingers. The mucous membranes are involved in more than 80% of patients and usually in multiple anatomic locations, favoring the buccal and gingival



**Fig. 29-46** Cowden syndrome.



**Fig. 29-47** Oral papillomas in Cowden syndrome.

mucosa. They can coalesce and form the characteristic cobblestone pattern seen in 40% of CS patients. Involvement of the respiratory mucosa can occur, with an acanthosis nigricans-like appearance. The mucosal lesions develop after the cutaneous lesions and have a persistent but benign course. Other cutaneous lesions include lipomas, hemangiomas, xanthomas, acanthosis nigricans, and various hyperpigmented macules. Macrocephaly with head circumference of greater than 97% is a major criterion for the diagnosis.

Malignancies develop in up to 40% of patients with CS. They are major criteria for the diagnosis and include breast, endometrial, and thyroid carcinoma. Breast cancer occurs in 25–50% of female patients and has been reported in male patients with CS. For breast cancer, the average age at diagnosis is 36 years. About 75% of affected females have fibrocystic disease of the breast. Endometrial cancer occurs in 6% of women with CS and has appeared as early as adolescence. Although not criteria for the diagnosis, multiple GI polyps (in 70–85%) and GI malignancies also occur. Minor criteria include thyroid lesions (including adenomas or goiter, and thyroiditis, in two thirds of patients), mental retardation, lipomas, fibromas (multiple sclerotic fibromas or storiform collagenomas), and genitourinary tumors. Multiple lipomatosis of the testicles is a common manifestation. The adult form of Lhermitte-Duclos disease, or dysplastic gangliocytoma of the cerebellum, represents the neurologic manifestation of CS. Lhermitte-Duclos disease is another pathognomonic criterion for the diagnosis of CS. A number of mucocutaneous malignancies have been found in patients with CS, including melanoma, BCC, SCC, MCC, and trichilemmal carcinoma.

Mutations in the tumor suppressor gene *PTEN* are responsible for the majority of CS. Patients who do not have a mutation in *PTEN* have mutations in the promoter region for *PTEN* or have methylation and downregulation of *KILLIN*, another tumor suppressor, with resultant rates of breast and renal cancer higher than those seen with *PTEN* mutation. In 10% of cases, the mutation is not in *PTEN* or the promoter and may be in the succinate dehydrogenase genes. Another disorder caused in 65% of cases by mutations in *PTEN* is Bannayan-Riley-Ruvalcaba syndrome (BRRS): autosomal dominant inherited macrocephaly, genital lentiginosities, motor and speech delay, mental retardation, hamartomatous polyps, myopathies, lipomas, and hemangiomas. BRRS is now considered a variant of CS that presents earlier in life, and patients having overlap syndromes with features of both CS and BRRS have been described. Some patients with a Proteus-like syndrome also have mutations in *PTEN*. These diseases have been called the “*PTEN* hamartoma tumor syndrome.”

Microscopically, trichilemmomas show variable hyperkeratosis and parakeratosis. Tumor lobules extend downward from the epidermis and demonstrate glycogen-rich clear cells, peripheral palisading, and a thick, hyalinized basement membrane.

Facial papillomas can be removed with surgical procedures, but new lesions continue to appear throughout life. Some patients achieve satisfactory cosmetic results from dermabrasion or CO<sub>2</sub> laser. Regular cancer screening and genetic counseling are paramount in CS. Rapamycin prevents the development of mucocutaneous lesions and premature death in the animal model for CS, suggesting that the mTOR pathway is involved in the development of the cutaneous lesions and the later complications of CS.

- Al-Daraji WI, et al:** Storiform collagenoma as a clue for Cowden disease or *PTEN* hamartoma tumour syndrome. *J Clin Pathol* 2007; 60:840.
- Bennett KL, et al:** Germline epigenetic regulation of *KILLIN* in Cowden and Cowden-like syndrome. *JAMA* 2010; 304(24):2724–2731.
- Blumenthal GM, Dennis PA:** *PTEN* hamartoma tumor syndromes. *Eur J Hum Genet* 2008; 16:1289.
- Caux F, et al:** Segmental overgrowth, lipomatosis, arteriovenous malformation and epidermal nevus (SOLAMEN) syndrome is related to mosaic *PTEN* nullizygosity. *Eur J Hum Genet* 2007; 15:767.
- Farooq A, et al:** Cowden syndrome. *Cancer Treat Rev* 2010; 36(8):577–583.
- Ferran M, et al:** Acral papular neuromatosis: an early manifestation of Cowden syndrome. *Br J Dermatol* 2008; 158:174.
- Ferran M, et al:** Bilateral and symmetrical palmoplantar punctate keratoses in childhood: a possible clinical clue for an early diagnosis of *PTEN* hamartoma-tumour syndrome. *Clin Exp Dermatol* 2009; 34:e28.
- Flores IL, et al:** Oral presentation of 10 patients with Cowden syndrome. *Oral Surg Oral Med Oral Pathol Oral Radiol* 2014; 117(4):e301–e310.
- Lachlan KL, et al:** Cowden syndrome and Bannayan-Riley-Ruvalcaba syndrome represent one condition with variable expression and age-related penetrance: results of a clinical study of *PTEN* mutation carriers. *J Med Genet* 2007; 4:579.
- Ngeow J, et al:** Second malignant neoplasms in patients with Cowden syndrome with underlying germline *PTEN* mutations. *J Clin Oncol* 2014; 32(17):1818–1824.
- Ni Y, et al:** Germline mutations and variants in the succinate dehydrogenase genes in Cowden and Cowden-like syndromes. *Am J Hum Genet* 2008; 83:261.
- Orloff MS, Eng C:** Genetic and phenotypic heterogeneity in the *PTEN* hamartoma tumour syndrome. *Oncogene* 2008; 27:5387.
- Orloff MS, et al:** Germline *PIK3CA* and *AKT1* mutations in Cowden and Cowden-like syndromes. *Am J Hum Genet* 2013; 92(1):76–80.
- Pilarski R, et al:** Cowden syndrome and the *PTEN* hamartoma tumor syndrome: systematic review and revised diagnostic criteria. *J Natl Cancer Inst* 2013; 105(21):1607–1616.
- Robinson S, Cohen AR:** Cowden disease and Lhermitte-Duclos disease: an update—case report and review of the literature. *Neurosurg Focus* 2006; 20(1):E6.
- Squarize CH, et al:** Chemoprevention and treatment of experimental Cowden's disease by mTOR inhibition with rapamycin. *Cancer Res* 2008; 68:7066.
- Stathopoulos P, et al:** Cowden syndrome: mucocutaneous lesions as precursors of internal malignancy. *Oral Maxillofac Surg* 2014; 18(2):229–235.
- Tan MH, et al:** A clinical scoring system for selection of patients for *PTEN* mutation testing is proposed on the basis of a prospective study of 3042 probands. *Am J Hum Genet* 2011; 88(1):42–56.
- Tan MH, et al:** Lifetime cancer risks in individuals with germline *PTEN* mutations. *Clin Cancer Res* 2012; 18(2):400–407.
- Tsai JH, et al:** Frequent activating *HRAS* mutations in trichilemmoma. *Br J Dermatol* 2014; 171(5):1073–1077.
- Umemura K, et al:** Gastrointestinal polyposis with esophageal polyposis is useful for early diagnosis of Cowden's disease. *World J Gastroenterol* 2008; 14:5755.
- Woodhouse J, Ferguson MM:** Multiple hyperechoic testicular lesions are a common finding on ultrasound in Cowden disease and represent lipomatosis of the testis. *Br J Radiol* 2006; 79:801.



## Trichilemmal carcinoma

Trichilemmal carcinomas are reported to arise on sun-exposed areas, most often the face and ears. They present as a slow-growing papule, indurated plaque, or nodule with a tendency to ulcerate. They may arise in the association of immunosuppression. It may be difficult to distinguish trichilemmal carcinoma from invasive Bowen's disease (which often shows adnexal differentiation) or a clear cell SCC. Surgical removal is recommended; Mohs micrographic surgery has been used successfully. Local recurrence and metastasis have occurred.

**Hamman MS, Brian Jiang SI:** Management of trichilemmal carcinoma: an update and comprehensive review of the literature. *Dermatol Surg* 2014; 40(7):711–717.

**Kulahci Y, et al:** Multiple recurrence of trichilemmal carcinoma of the scalp in a young adult. *Dermatol Surg* 2010; 36(4):551–554.

**Tolkachjov SN, et al:** Mohs micrographic surgery in the treatment of trichilemmal carcinoma: The Mayo Clinic experience. *J Am Acad Dermatol* 2015; 72(1):195–196.

**Wilkie MD, et al:** Trichilemmal carcinoma: an unusual presentation of a rare cutaneous lesion. *BMJ Case Rep* 2013; Apr 18.

**Yi HS, et al:** Recurrent and metastatic trichilemmal carcinoma of the skin over the thigh: a case report. *Cancer Res Treat* 2010; 42(3):176–179.

**Zhuang SM, et al:** Survival study and clinicopathological evaluation of trichilemmal carcinoma. *Mol Clin Oncol* 2013; 1(3):499–502.

## Trichodiscoma, fibrofolliculoma, perifollicular fibromas, mantleomas, and Birt-Hogg-Dubé syndrome

These benign tumors form a spectrum of neoplasms combining a follicular element and the specialized periadventitial dermis of the upper portion of the hair follicle. They may represent variations of the same tumor cut in different planes of section. All these lesions clinically appear as 2–4 mm, asymptomatic, skin-colored, dermal papules affecting the face and upper trunk. They may be single but are frequently multiple. When multiple, they are often numerous and are a marker for Birt-Hogg-Dubé syndrome (BHD) (Fig. 29-48). The histomorphology of these hair follicle tumors is identical in patients with BHD and in cases unassociated with BHD. Fibrofolliculoma demonstrates cords and strands of two-cell to four-cell epithelium emanating from a follicular structure. The epithelial elements may anastomose, and sebaceous elements may be present. This follicular structure is surrounded by a collagenous or fibromucinous orb. Trichodiscomas represent a sectioning artifact that demonstrates only the tumor stroma.

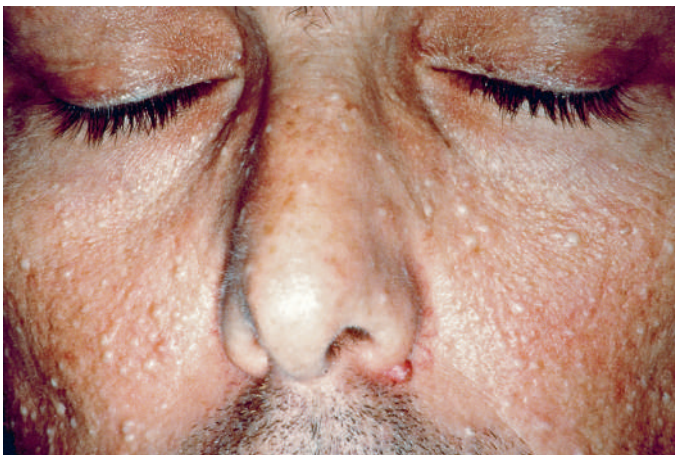

Fig. 29-48 Birt-Hogg-Dubé syndrome.

The BHD syndrome is inherited in an autosomal dominant manner. It is caused by a mutation in the gene *folliculin (FLCN)*, which is located on chromosome 17p. Many of the mutations occur in a hypermutable region of the gene. This gene is conserved in many species and expressed in many tissues, but its exact function is unknown. Recently, it has been linked to numerous cell pathways important in cancer biology, including cell growth, metabolism, adhesion, motility, kinesis, and survival. Homozygous loss of function of the *folliculin* gene is embryonically lethal, suggesting that *FLCN* may indeed play a broad and important role in the cell. Cutaneous lesions are common in patients with BHD, affecting more than 80% of persons 30 years or older. The fibrofolliculomas appear in adulthood and usually precede other stigmata but can be quite subtle. In the vast majority of cases, they are multiple and often very numerous. They can be widespread but always affect the nose, paranasal area, back of the pinna, and behind the ear. Comedolike papules with keratinous plugs may be seen. Lesions can coalesce into plaques and be grouped. Multiple epidermoid cysts can occur. Hyperseborrhea may be seen, with numerous facial fibrofolliculomas. Skin tags are present in 100% of patients, most often in the axillae. Small, discrete, soft, mucosa-colored or white papules of the lips, gingiva, tongue, and buccal mucosa are present in about 40% of patients and families with BHD. Biopsies of the oral lesions reveal an acanthotic epithelium overlying a fibrotic process.

In addition to the cutaneous lesions previously noted, patients are at risk for the development of renal tumors and spontaneous pneumothorax. The renal tumor risk is seven times that of the general population and especially affects men (at twice the risk) and those over 40. At least 30% of patients with BHD develop renal tumors, and these can appear after age 20. Renal tumors may be multiple and bilateral, a clinical scenario that should suggest the diagnosis of BHD. Patients with BHD develop renal oncocytomas and chromophobe renal carcinomas, or a mixed type that is characteristic of BHD. These are otherwise rare histologic variants of renal cell carcinoma. Multiple renal cysts may also occur.

Patients with BHD have greater than 30 times the risk of developing a spontaneous pneumothorax than unaffected persons—a lifetime risk of 24%. Pneumothorax can occur at a young age in BHD; 17% of BHD patients under 40 will have a spontaneous pneumothorax. Median age of pneumothorax occurrence is 38 years. Spontaneous pneumothorax results from multiple pulmonary cysts, which affect 83% of BHD patients. The cysts are at the lung base and subpleural. Recurrent pneumothorax is common and should suggest BHD. Patients do not seem to have progressive pulmonary failure, and severe chronic obstructive pulmonary disease (COPD) is not associated with *FLCN* mutations. Colonic polyps and neoplasms, which were initially reported to be associated with BHD syndrome, do *not* appear to be increased in BHD syndrome. Thyroid nodules are seen in 90% of affected families and 65% of BHD patients. BHD must be differentiated from familial multiple discoid fibroma, which presents similarly with facial papules but is histologically distinct, lacks systemic complications, and does not involve the *FLCN* gene.

The treatment of the fibrofolliculomas is surgical debulking. In most patients, the lesions are small and can be cosmetically removed by shave removal, curettage, or resurfacing if the lesions are numerous. Smoking is proscribed because it may worsen lung complications. Renal imaging should be periodically performed, but the best method is unclear. CT is more accurate than ultrasound, especially for smaller lesions, but repeat scans lead to unacceptable radiation exposure. MRI is expensive but diagnostically most accurate. Although there is no genotype/phenotype correlation known at this time for *FLCN* mutations, certain families seem to be predisposed to

certain complications of BHD. In those families, more aggressive screening for the particularly prevalent complication seems warranted. Since the *FLCN* gene seems to interact with the mTOR pathway, it has been suggested that the use of rapamycin has potential benefit in BHD; however, an RCT showed no benefit.

**Cocciolone RA, et al:** Multiple desmoplastic melanomas in Birt-Hogg-Dubé syndrome and a proposed signaling link between folliculin, the mTOR pathway, and melanoma susceptibility. *Arch Dermatol* 2010; 146(11):1316–1318.

**Diamond JM, Kotloff RM:** Recurrent spontaneous pneumothorax as the presenting sign of the Birt-Hogg-Dubé syndrome. *Ann Intern Med* 2009; 150:289.

**Farrant PB, Emerson R:** Hyfrecation and curettage as a treatment for fibrofolliculomas in Birt-Hogg-Dubé syndrome. *Dermatol Surg* 2007; 33:1287.

**Furuya M, Nakatani Y:** Birt-Hogg-Dubé syndrome: clinicopathological features of the lung. *J Clin Pathol* 2013; 66(3):178–186.

**Gaur K, et al:** The Birt-Hogg-Dubé tumor suppressor folliculin negatively regulates ribosomal RNA synthesis. *Hum Mol Genet* 2013; 22(2):284–299.

**Gijzen LM, et al:** Topical rapamycin as a treatment for fibrofolliculomas in Birt-Hogg-Dubé syndrome: a double-blind placebo-controlled randomized split-face trial. *PLoS One* 2014; 9(6):e99071.

**Houweling AC, et al:** Renal cancer and pneumothorax risk in Birt-Hogg-Dubé syndrome; an analysis of 115 *FLCN* mutation carriers from 35 BHD families. *Br J Cancer* 2011; 105(12):1912–1919.

**Imada K, et al:** Birt-Hogg-Dubé syndrome with clear-cell and oncocytic renal tumour and trichoblastoma associated with a novel *FLCN* mutation. *Br J Dermatol* 2009; 160:1350.

**Jacob CI, Dover JS:** Birt-Hogg-Dubé syndrome: treatment of cutaneous manifestations with laser skin resurfacing. *Arch Dermatol* 2001; 137:98.

**Mallipeddi R, et al:** Birt-Hogg-Dubé syndrome with a renal angiomyolipoma: further evidence of a relationship between Birt-Hogg-Dubé syndrome and tuberous sclerosis complex. *Byrne Australas J Dermatol* 2012; 53(2):151–154.

**Medvetz DA, et al:** Folliculin, the product of the Birt-Hogg-Dubé tumor suppressor gene, interacts with the adherens junction protein p0071 to regulate cell-cell adhesion. *PLoS One* 2012; 7(11).

**Menko FH, et al:** Birt-Hogg-Dubé syndrome: diagnosis and management. *Lancet Oncol* 2009; 10:1199.

**Nishii T, et al:** Unique mutation, accelerated mTOR signaling and angiogenesis in the pulmonary cysts of Birt-Hogg-Dubé syndrome. *Pathol Int* 2013; 63(1):45–55.

**Pritchard SE, et al:** Successful treatment of facial papules with electrodesiccation in a patient with Birt-Hogg-Dubé syndrome. *Dermatol Online J* 2014; 20(7).

**Reiman A, et al:** Gene expression and protein array studies of folliculin-regulated pathways. *Anticancer Res* 2012; 32(11):4663–4670.

**Spring P, et al:** Syndrome of Birt-Hogg-Dubé, a histopathological pitfall with similarities to tuberous sclerosis: a report of three cases. *Am J Dermatopathol* 2013; 35(2):241–245.

**Starink TM, et al:** Familial multiple discoid fibromas: a look-alike of Birt-Hogg-Dubé syndrome not linked to the *FLCN* locus. *J Am Acad Dermatol* 2012; 66(2):259.e1–e9.

**Tee AR, Pause A:** Birt-Hogg-Dubé: tumour suppressor function and signalling dynamics central to folliculin. *Fam Cancer* 2013; 12(3):367–372.

**Toro JR, et al:** *BHD* mutations, clinical and molecular genetic investigations of Birt-Hogg-Dubé syndrome: a new series of 50 families and a review of published reports. *J Med Genet* 2008; 45:321.

**Vincent A, et al:** Birt-Hogg-Dubé syndrome: a review of the literature and the differential diagnosis of firm facial papules. *J Am Acad Dermatol* 2003; 49:698.

pore lined by outer root sheath epithelium. Multiple short, bulbous, acanthotic projections extend from the central infundibulum-like pore.

## Pilar sheath acanthoma

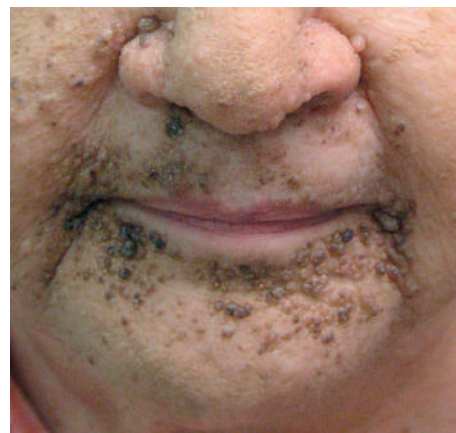Pilar sheath acanthoma is most often found on the face, particularly above the upper lip in adults. Patients present with a solitary, 5–10 mm, skin-colored nodule with a central keratinous plug. Histologically, pilar sheath acanthoma differs from a dilated pore by having larger tumor lobules radiating from the central infundibulum-like pore.

## Trichoadenoma

Presenting as a solitary growth ranging from 3 to 15 mm in diameter, this lesion may be clinically mistaken for a seborrheic keratosis, having a vegetative or verrucous appearance. Although most frequently found on the face, it may occur at other sites, especially the buttock, which is the second most common location. Trichoadenomas also differentiate toward the follicular infundibulum. Histologically, they are quite distinctive, being composed of a collection of ringlike eosinophilic structures that often occur in pairs (resembling eyeglasses). No hair shafts are present.

## Basaloid follicular hamartoma

Basaloid follicular hamartoma (BFH) is a distinctive benign adnexal tumor that has four described variants: solitary papule, localized plaque of alopecia, linear or blaschkoid unilateral plaque, and generalized papules. Generalized BFH form has also been termed generalized hair follicle hamartoma. Most often affecting the skin of the face and scalp, BFHs are solitary or multiple, skin-colored, 2–3 mm papules (Fig. 29-49) or infiltrating plaques associated with progressive hair loss in the affected areas. Congenital and adult appearance has been described. In some generalized cases, there is an association with alopecia, myasthenia gravis, or circulating autoantibodies (antinuclear and antiacetylcholine receptor antibodies). Cystic fibrosis and generalized follicular hamartomas have been reported in three siblings, suggesting a possible genetic linkage. A familial, autosomal dominant form has been described, with numerous milia; comedolike lesions; hyperpigmented papules of the face, scalp, ears, neck, and trunk; hypotrichosis; hypohidrosis; and pinpoint palmar pits. It presents in early childhood. Happle-Tinschert syndrome is segmentally arranged BFH, linear atrophoderma with hypo/hyperpigmentation, enamel defects, ipsilateral hypertrichosis, and skeletal and cerebral anomalies.



**Fig. 29-49** Basaloid follicular hamartoma. (Courtesy of Dr. J. English.)

## Other hair follicle tumors

### Dilated pore (of Winer)

This lesion typically presents as a solitary, prominent, open comedo on the face or upper trunk of an elderly individual. Histologically, it is composed of a greatly dilated follicular



Histologically, BFH may be indistinguishable from infundibulocystic BCC. Lesions are characterized by thin, branching eosinophilic strands and thick cords with associated basaloid buds and keratin cysts. Unlike most other pilar tumors, the stroma is loose, fibrillar, or mucinous. In nevoid and generalized forms, apparently normal skin may also demonstrate small islands of basaloid cells. Trichoblastomas may occur within nevoid lesions. *PTCH* gene signaling is upregulated in the cells contacting the dermis in BFH. Generalized BFH syndrome must be distinguished from Bazex-Dupr -Christol syndrome, Brown-Crounse syndrome, Rombo syndrome, basal cell nevus syndrome, and Brooke-Spiegler syndrome. Its differentiation from multiple hereditary infundibulocystic basal cell carcinoma syndrome may be difficult. Treatment essentially consists of recognition of the correct diagnosis, avoidance of unnecessary surgery, and periodic monitoring (malignant growths may arise within BFH, if not transform from it). Oral and topical retinoids and PDT have been reported effective for widespread BFH.

### Folliculosebaceous cystic hamartoma

Folliculosebaceous cystic hamartoma is a benign hamartoma of epithelial and mesenchymal elements. It presents as a solitary, 0.5–1.5 cm papule or nodule virtually always on the head, with two-thirds occurring on or adjacent to the nose. Rare giant lesions up to 15 cm in diameter have been reported. Age of onset ranges from infancy to the sixth decade. Histologically, the lesion is composed of three elements: an intradermal cystic structure lined by squamous epithelium identical to that of the infundibulum; numerous sebaceous lobules radiating from the cystic structure; and a surrounding stroma with fibrous, adipose, vascular, and neural tissues. Stromal spindle cells are positive for CD34. The tumor may represent a sebaceous trichofolliculoma biopsied during telogen phase.

### Tumors of the follicular infundibulum

These flat, keratotic papules, and sometimes hypopigmented macules, of the head and neck are usually solitary but may be multiple. They appear in adulthood. The terms eruptive infundibulomas and infundibulomatosis have been used to describe cases with multiple lesions. In the rare generalized cases, there is a strong clinical resemblance to Darier's disease, with accentuation on the neck, central chest, groin, and axillae. Histologically, the solitary and multiple cases are identical. There is a platelike proliferation of epidermal cells growing parallel to the epidermis and connecting to it at multiple sites. Clear, glycogenated cells similar to those of a trichilemmoma, sebaceous differentiation, cystic and ductal structures, and papillary mesenchymal bodies may be seen.

**Alomari A, et al:** Solitary and multiple tumors of follicular infundibulum: a review of 168 cases with emphasis on staining patterns and clinical variants. *J Cutan Pathol* 2013; 40(6):532–537.

**Ansai S, et al:** A clinicopathologic study of folliculosebaceous cystic hamartoma. *Am J Dermatopathol* 2010; 32(8):815–820.

**Bavikar RR, et al:** Postauricular pilar sheath acanthoma. *Int J Trichology* 2011; 3(1):39–40.

**Bruscino N, et al:** Pilar sheath acanthoma simulating basal cell carcinoma. *G Ital Dermatol Venereol* 2014; 149(1):155–156.

**Gumaste P, et al:** Generalized basaloid follicular hamartoma syndrome: a case report and review of the literature. *Am J Dermatopathol* 2014; Apr 2. [Epub ahead of print.]

**Itin PH:** Happle-Tinschert syndrome: segmentally arranged basaloid follicular hamartomas, linear atrophoderma with hypo- and hyperpigmentation, enamel defects, ipsilateral hypertrichosis, and skeletal and cerebral anomalies. *Dermatology* 2009; 218:221.

**Kubba A, et al:** Tumor of follicular infundibulum: an unsuspected cause of macular hypopigmentation. *Indian J Dermatol Venereol Leprol* 2014; 80(2):141–144.

**Lee MW, et al:** Linear basaloid follicular hamartoma on the Blaschko's line of the face. *Clin Exp Dermatol* 2005; 30:30.

**Lee WS, et al:** Congenital trichoadenoma with an unusual clinical manifestation. *J Am Acad Dermatol* 2007; 57:905.

**Lo CS, et al:** Unilateral segmentally arranged basaloid follicular hamartomas with osteoma cutis and hypodontia: a case of Happle-Tinschert syndrome. *Clin Exp Dermatol* 2013; 38(8):862–865.

**Miller CJ, et al:** Sebaceous carcinoma, basal cell carcinoma, trichoadenoma, trichoblastoma, and syringocystadenoma papilliferum arising within a nevus sebaceus. *Dermatol Surg* 2004; 30:1546.

**Mills O, Thomas LB:** Basaloid follicular hamartoma. *Arch Pathol Lab Med* 2010; 134(8):1215–1219.

**Misago N, et al:** A reevaluation of folliculosebaceous cystic hamartoma: the histopathological and immunohistochemical features. *Am J Dermatopathol* 2010; 32(2):154–161.

**Oseroff A, et al:** Treatment of diffuse basal cell carcinomas and basaloid follicular hamartomas in nevoid basal cell carcinoma syndrome by wide-area 5-aminolevulinic acid photodynamic therapy. *Arch Dermatol* 2005; 141(1):60–67.

**Shimanovich I, et al:** Trichoadenoma of Nikolowski is a distinct neoplasm within the spectrum of follicular tumors. *J Am Acad Dermatol* 2010; 62(2):277–283.

**Steffen C:** Winer's dilated pore: the infundibuloma. *Am J Dermatopathol* 2001; 23:246.

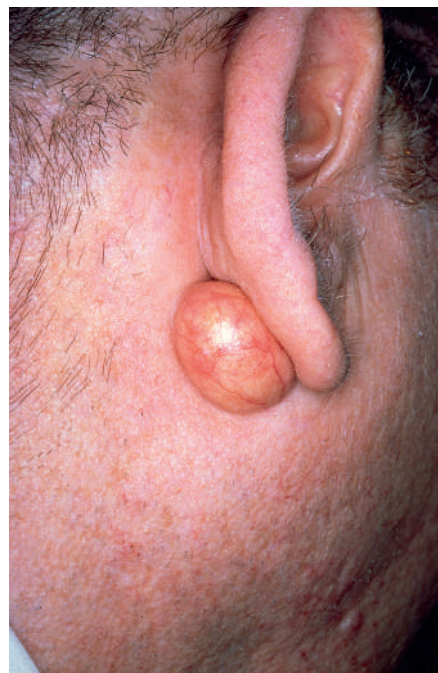**Sturtz DE, et al:** Giant folliculosebaceous cystic hamartoma of the upper extremity. *J Cutan Pathol* 2004; 31:287.

**Waxweiler WT, et al:** A novel phenotype with features of basal cell nevus syndrome and basaloid follicular hamartoma syndrome. *J Am Acad Dermatol* 2011; 65(1):e17–e19.

## EPITHELIAL CYSTS AND SINUSES

### Epidermal cyst (epidermal inclusion cyst, infundibular cyst)

Epidermal inclusion cyst is one of the most common benign skin tumors. It presents as a compressible, but not fluctuant, cystic mass from 0.5 to several centimeters in diameter (Fig. 29-50). The surface of the overlying skin is usually smooth



**Fig. 29-50** Epidermal inclusion cyst.

and shiny from the upward pressure. These nodules are freely movable over underlying tissue and are attached to the normal skin above them by a comedolike central infundibular structure or punctum. The pasty contents of the cysts are formed mostly of macerated keratin, which has a cheesy consistency and pungent odor. Epidermal inclusion cysts occur most often on the face, neck, and trunk but may be found in almost any location. They frequently result from plugging of the follicular orifice, often in association with acne vulgaris. They may also occur by epidermal implantation. Deep penetrating injuries, such as with a sewing machine needle or stapler, or even with nail biting, may result in epidermoid cysts growing within bone. In persons with dark pigment, the lining of the epidermoid cyst and its contents may be pigmented. Epidermoid cysts rarely appear before puberty, and earlier onset should suggest an alternative diagnosis (e.g., pilomatricoma, dermoid cyst, Gardner syndrome). Lesions of the scalp are usually trichilemmal cysts. Rare cysts of the soles are caused by infection by HPV-60.

Epidermoid cysts may rupture and induce a vigorous foreign body inflammatory response, after which they are firmly adherent to surrounding structures and are more difficult to remove. Rupture is associated with the sudden onset of redness, pain, swelling, and local heat, simulating an abscess. Incision and drainage will confirm the diagnosis of inflamed cyst, when the smelly, cheesy material is evacuated. This will also lead to rapid resolution of symptoms. These episodes are often misdiagnosed as “infection” of the cyst, but cultures are usually negative, and antibiotic treatment is not required. Intralesional triamcinolone may hasten resolution of the symptoms. Rarely, malignancies such as SCC, BCC, and melanoma have arisen within epidermoid cysts. Rapidly enlarging cysts should be considered for excision, and histology should be reviewed carefully.

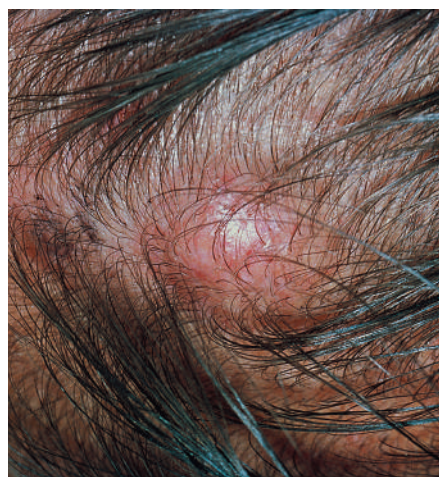
The epidermoid cyst is a keratinizing cyst, the wall of which is stratified squamous epithelium containing keratohyalin granules. It is differentiated from the pilar cyst by the different pattern of keratinization, although hybrid cysts with infundibular, trichilemmal, and even pilomatric differentiation can be seen. Idiopathic scrotal calcinosis is the end stage of calcification of epidermoid cysts of the scrotum. Pilomatric differentiation within an epidermoid cyst should suggest Gardner syndrome.

Surgical excision is curative, but the complete cyst and any associated “daughter” cysts must be removed. Enucleation of the cyst through a small incision or a hole made with a 4-mm biopsy punch or a laser may be attempted. A curette may be used to scrape out and snag all the fragments of the cyst wall. Alternatively, the lining of the cyst can be eradicated by cauterizing it with 20% trichloroacetic acid. Inflamed cysts may also be treated in this way, but the inflammation makes complete removal of the cyst more difficult. If any fragment of the cyst wall is left behind, the cyst may recur.

### Proliferating epidermoid cyst

These tumors, derived from epidermoid cysts, occur more often in men (64%), and the most frequent sites are the pelvic/anogenital areas (36%), scalp (21%), upper extremities (18%), and trunk (15%). In rare cases, carcinomatous changes can be seen on histology, with anaplasia, high mitotic rate, and deep invasion. Proliferating epidermoid cysts are locally aggressive, but distant metastasis is rare. Malignant onycholemmal cyst may describe a rare slow-growing tumor arising from a subungual keratinous cyst.

**Baek SO, et al:** Giant epidermal inclusion facial cyst. *J Craniofac Surg* 2011; 22(3):1149–1151.



**Fig. 29-51** Pilar cyst.

**Bajoghli A, et al:** Melanoma arising from an epidermal inclusion cyst. *J Am Acad Dermatol* 2013; 68(1):e6–e7.

**Ghigliotti G et al:** Usefulness of dermoscopy for the diagnosis of epidermal cyst: the “pore” sign. *Clin Exp Dermatol* 2014; 39(5):649–650.

**Jayalakshmy PS, et al:** Pigmented epidermal cyst with dense collection of melanin: a rare entity—report of a case with review of the literature. *Indian Dermatol Online J* 2012; 3(2):131–134.

**Sau P, et al:** Proliferating epithelial cysts: clinicopathological analysis of 96 cases. *J Cutan Pathol* 1995; 22:394.

**Smoot EC:** Removal of large inclusion cysts with minimal incisional scars. *Plast Reconstr Surg* 2007; 119:1395.

**Song SW, et al:** Minimally invasive excision of epidermal cysts through a small hole made by a CO<sub>2</sub> laser. *Arch Plast Surg* 2014; 41(1):85–88.

### Pilar cyst (trichilemmal cyst, isthmus-catagen cyst)

The trichilemmal cyst, also known as a wen, is similar clinically to the epidermoid cyst, except that about 90% of pilar cysts occur on the scalp (Fig. 29-51). Women over age 60 are predominantly affected. The cyst may be found rarely on the face, trunk, and extremities. An overlying punctum is not present, and lesions tend to be more mobile and firmer than epidermoid cysts. Hereditary trichilemmal cysts (autosomal dominant) link to the short arm of chromosome 3 but not to  $\beta$ -catenin or MLH1.

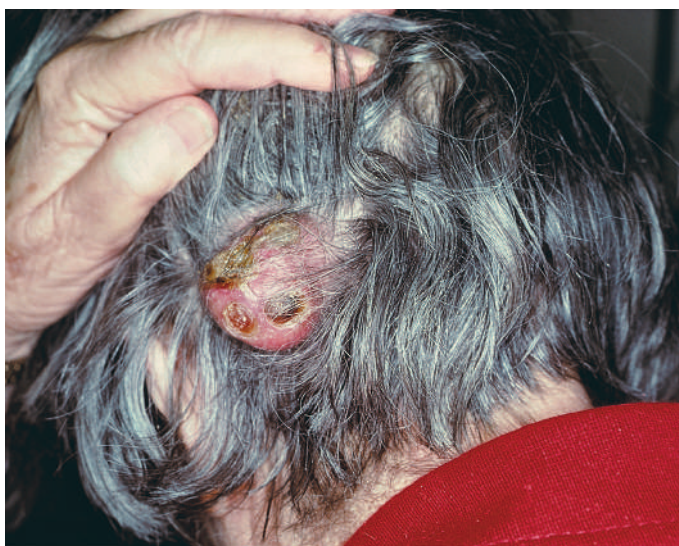The trichilemmal cyst is lined by stratified squamous epithelium, which is derived from the outer root sheath. The lining cells demonstrate trichilemmal keratinization, increasing in size as they approach the cyst cavity and abruptly keratinizing without forming a granular cell layer. The cyst contents are homogeneous; they usually calcify and rarely ossify. Hybrid cysts with features of both an epidermoid cyst and a pilar cyst can be seen.

Treatment is the same as for the epidermoid cyst. Pilar cysts are much more easily enucleated, so more limited incision is required to remove the lesion.

### Proliferating trichilemmal cyst/malignant trichilemmal cyst

A spectrum of lesions ranges from typical pilar cysts with focal areas of epithelial proliferation to solid proliferating growths with atypia that are best considered SCCs. The typical proliferating pilar cyst or proliferating pilar tumor is a large (up to 25 cm) exophytic neoplasm confined almost exclusively to the scalp and back of the neck. These lesions are approximately five times more common in women, and the mean age of





**Fig. 29-52** Pilar cyst, proliferating type.

patients is 65 years. They gradually enlarge and may ulcerate (Fig. 29-52). The vast majority of lesions are cured by local excision. Some lesions may recur and, less often, they may be locally aggressive. Focal areas of atypia and mitoses may be seen in benign-behaving, proliferating pilar tumors. In uncommon cases, there are focal areas that show frank SCC. These lesions should be called “malignant proliferating pilar tumor.” Areas of SCC are characterized by increased cellularity, atypia, frequent mitoses, and most importantly, invasion of the surrounding stroma. These tumors may behave aggressively. The clinical features that should suggest potential aggressive behavior are nonscalp location, recent rapid growth, size greater than 5 cm, and an infiltrative growth pattern clinically and histologically. In KID (keratosis, ichthyosis, deafness) syndrome, the development of malignant proliferating pilar tumor may occur in young adulthood and may be fatal.

Proliferating trichilemmal cysts are composed of proliferations of squamous cells with trichilemmal differentiation, forming scroll-like structures or small cysts. Lesions are usually well circumscribed. Focal cellular atypia, mitoses, and necrosis may be present and do not necessarily predict aggressive behavior. Cases with aggressive growth and metastases usually have cytologic atypia, as well as an invasive growth pattern. The presence of a clearly benign component and a second anaplastic component growing outward suggests the development of a carcinoma. Proliferating pilar cysts and their malignant counterparts express hair cytokeratins (cytokeratin 7), and malignant trichilemmal tumors express CD34, suggesting fetal hair root phenotype and trichilemmal differentiation.

**Aneiros-Fernandez J, et al:** Giant proliferating trichilemmal malignant tumor. *Indian J Dermatol Venereol Leprol* 2011; 77(6):730.

**Chaichamnan K, et al:** Malignant proliferating trichilemmal tumors with CD34 expression. *J Med Assoc Thai* 2010; 93(Suppl 6):S28–S34.

**Dewanda NK, Midya M:** Baker's dozen on the scalp: an interesting case of multiple trichilemmal cyst. *J Cutan Aesthet Surg* 2014; 7(1):67–68.

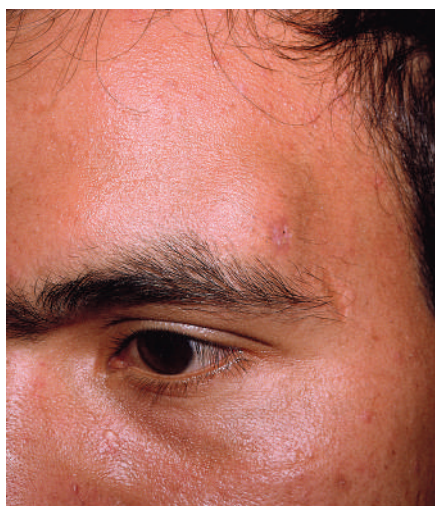
**Eiberg H, et al:** Mapping of hereditary trichilemmal cyst (*TRICY1*) to chromosome 3p24–p21.2 and exclusion of  $\beta$ -catenin and MLH1. *Am J Med Genet* 2005; 133A:44.

**Eskander A, et al:** Squamous cell carcinoma arising in a proliferating pilar (trichilemmal) cyst with nodal and distant metastases. *J Otolaryngol Head Neck Surg* 2010; 39(5):E63–E67.

**Goyal S, et al:** Malignant proliferating trichilemmal tumor. *Indian J Dermatol* 2012; 57(1):50–52.

**Khaled A, et al:** Malignant proliferating trichilemmal cyst of the scalp: histological aspects and nosology. *Pathologica* 2011; 103(3):73–76.

**Nyquist GG, et al:** Malignant proliferating pilar tumors arising in KID syndrome: a report of two patients. *Am J Med Genet* 2007; 143A:734.



**Fig. 29-53** Dermoid, cystic nodule of the lateral eyebrow.

**Pusiol T, et al:** Ossifying trichilemmal cyst. *Am J Dermatopathol* 2011; 33(8):867–868.

**Rangel-Gamboa L, et al:** Proliferating trichilemmal cyst: the value of Ki67 immunostaining. *Int J Trichology* 2013; 5(3):115–117.

**Seidenari S, et al:** Hereditary trichilemmal cysts: a proposal for the assessment of diagnostic clinical criteria. *Clin Genet* 2013; 84(1):65–69.

## Dermoid cyst

Cutaneous dermoid cysts, also called congenital inclusion dermoid cysts, result from local anomalies in embryonic development and occur along embryonic closure zones. On the face, they occur above the lateral end of the eyebrow (external angular dermoid) (Fig. 29-53), at the nasal root, along the midline of the forehead, over the mastoid process, on the floor of the mouth, and anywhere along the midline of the scalp from the frontal to the occipital region. Dermoid cysts may also be found on the chest, back, abdomen, and perianal area. Nasal and external angular dermoids may be seen in multiple members of a family, suggesting a genetic component. Lesions usually present within the first year of life, although only 70% of lesions have been identified by age 5 years. The typical lesion is a few millimeters to several centimeters in diameter and located in the subcutaneous fat. A tethering to the underlying tissues and an underlying bony defect may be noted. They are nonpulsatile, firm, and cystic, and they do not transilluminate. A punctum or opening to the skin surface may be present, but dermoid cysts are not usually attached to the overlying skin. A tuft of hair may project from a pit, signifying the presence of an underlying sinus or cyst. Inflammation of the cyst caused by rupture (with extrusion of hair and a foreign body reaction) or infection may first bring the patient to the physician. Because the dermoid may connect to underlying structures, including the pleura and CNS, infection may spread to the CNS or lungs, with potentially serious consequences. Patients with spina bifida frequently develop dermoid cysts of the repaired portion of their spinal column. Dermoids overlying the lower spine may be associated with tethered cord and late development of ambulatory difficulties. At times, dermoids may be on the lateral buttocks. Dermal sinuses/dermoids may be associated with other findings of occult spinal dysraphism, including hyperpigmented patches, “skin tags,” hemangiomas, and hairy nevi.

Histologically, the cyst wall is lined with keratinizing stratified squamous epithelium containing skin appendages, including lanugo hair. Portions of the cyst lining may demonstrate

a wavy eosinophilic (shark tooth) pattern resembling that of a steatocystoma.

In a child, attempts at surgical removal or biopsy of a cyst over cleavage planes (including along the midline of the back) should not be attempted without proper assessment to rule out an intraspinal or intracranial communication. CT or MRI is required. Any underlying bony changes detected by CT scan should be followed up with an MRI scan; cranial penetration by the cyst at times may be difficult to identify by CT. If an intracranial connection is detected, the patient should be referred to a neurosurgeon.

- Ackerman LL, et al:** Cervical and thoracic dermal sinus tracts: a case series and review of the literature. *Pediatr Neurosurg* 2002; 37:137.
- Bodkin PA, et al:** Beware of the midline scalp lump. *J R Soc Med* 2004; 97:239.
- Guruprasad Y, Chauhan DS:** Midline nasal dermoid cyst with Tessier's 0 cleft. *J Nat Sci Biol Med* 2014; 5(2):479–482.
- Ikwueke I, et al:** Congenital dermal sinus tract in the lateral buttock: unusual presentation of a typically midline lesion. *J Pediatr Surg* 2008; 43:1200.
- Madke B, et al:** Nasal dermoid sinus cyst in a young female. *Indian Dermatol Online J* 2013; 4(4):380–381.
- Maurice SM, Burstein FD:** Disappearing dermoid: fact or fiction? *J Craniofac Surg* 2012; 23(1):e31–e33.
- Mazzola CA, et al:** Dermoid inclusion cysts and early spinal cord tethering after fetal surgery for myelomeningocele. *N Engl J Med* 2002; 347:256.
- Vega RA, et al:** Intradiploic dermoid cyst of the lateral frontotemporal skull: case report and review of the literature. *Pediatr Neurosurg* 2013; 49(4):232–235.

## Pilonidal sinus

Pilonidal cyst or sinus occurs in the midline sacral region at the upper end of the cleft of the buttocks. A pit may be all that is visible before puberty. Pilonidal cysts/sinuses usually become symptomatic during adolescence. The lesion becomes inflamed from rupture or less frequently infection. Pilonidal sinus/cyst often occurs with nodulocystic acne, dissecting cellulitis, and hidradenitis suppurativa (the acne tetrad). Histologically, the cyst/sinus is lined by stratified squamous epithelium of the type seen in normal epidermis or follicular infundibulum. Some pilonidal cysts/sinuses are composed of epithelium, which keratinizes without formation of a granular cell layer, analogous to the outer root sheath. Referral to a general surgeon is recommended, because recurrences may follow simple cystectomy and marsupialization. SCCs have been reported to arise from chronic inflammatory pilonidal disease.

- Doll D, et al:** Surgery for asymptomatic pilonidal sinus disease. *Int J Colorectal Dis* 2008; 23(9):839–844.
- Eryilmaz R, et al:** Recurrent squamous cell carcinoma arising in a neglected pilonidal sinus: report of a case and literature review. *Int J Clin Exp Med* 2014; 7(2):446–450.
- Muzi MG, et al:** Long-term results of pilonidal sinus disease with modified primary closure: new technique on 450 patients. *Am Surg* 2014; 80(5):484–488.

## Steatocystoma simplex

Solitary steatocystoma (simple sebaceous duct cyst, steatocystoma simplex) occurs with equal frequency in adult women and men and occurs on the face, trunk, or extremities. The oral mucosa may also be involved. It is not familial, and solitary lesions are much less common than multiple ones. The cysts are usually 0.5–1.5 cm in size, although rarely, solitary steatocystomas more than 8 cm have been reported. The cyst contains an oily, yellow fluid and may contain vellus hairs. Histologically, the cyst is lined by stratified squamous

epithelium. Small, mature, sebaceous lobules are present along the cyst wall and empty into the cyst. The luminal surface of the cyst is eosinophilic, wavy (shark tooth pattern), and ribbonlike, analogous to the sebaceous duct. “Hybrid” cysts may have portions of their lining of the steatocystoma type, with the other portions resembling pilar cyst, epidermoid cyst, or even pilomatricoma. Simple excision is curative.

- Monshizadeh R, et al:** Perforating follicular hybrid cyst of the tarsus. *J Am Acad Dermatol* 2003; 48:S33.
- Sunohara M, et al:** Two cases of steatocystoma simplex in infants. *Dermatol Online J* 2012; 18(7):2.
- Yonekura K, et al:** Giant steatocystoma simplex. *J Dermatol* 2005; 32(4):309.

## Steatocystoma multiplex

Steatocystoma multiplex (SM) consists of multiple, uniform, yellowish, cystic papules usually 2–6 mm in diameter (Fig. 29-54), located principally on the upper anterior portion of the trunk, upper arms, axillae, and thighs. The lesions lack a punctum. The majority of patients present with dermal lesions, but multiple subcutaneous masses resembling multiple lipomas can occur. Lesions usually appear in adolescence or early adulthood, when sebaceous activity is at its peak. Development of SM can first occur in late adulthood. In severe cases, the lesions may be generalized, with sparing only of the palms and soles. At times, the lesions may be limited to the face or scalp, a distinct form termed the facial papular variant. Lesions limited to the genital area have also been reported. Congenital and adolescent-onset linear lesions are rare. Steatocystoma may be larger (up to 2 cm) and prone to rupture and suppuration (steatocystoma multiplex suppurativum). If these lesions are widespread, the condition can be very disfiguring. Steatocystomas contain a syrupy, yellowish, odorless, oily material. In the suppurative type, colonization with bacteria can occur, leading to foul odor and social isolation.

Histologically, the lining of the cyst is stratified squamous epithelium, with the cyst lining containing mature sebaceous glands. The epithelial lining is identical to the sebaceous duct. The luminal surface is wavy and eosinophilic and may stain with calretinin (perhaps only in the late-onset facial type). The granular layer is absent, but large basophilic granules may be seen focally in the epithelial cells in the upper layers of the cyst lining. In some cases, hair follicles occur in the cyst wall, and vellus hairs may be present in the cavity. A relationship with eruptive vellus hair cysts has been suggested because of a similar clinical appearance, time of onset, and overlapping histologic features. It has been proposed that these clinical entities are a spectrum of the same disease process and should be classified as “multiple pilosebaceous cysts.”

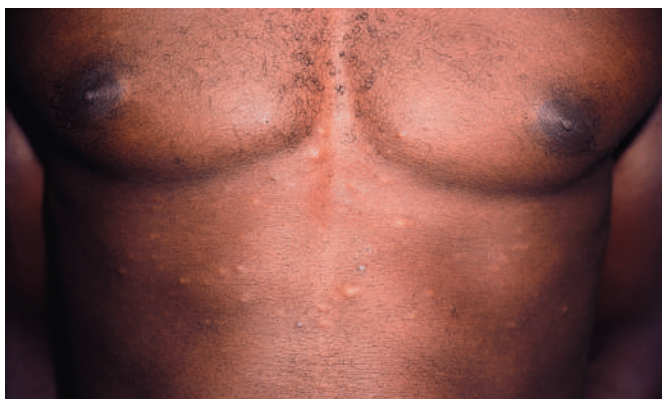

Fig. 29-54 Steatocystoma multiplex.



Often familial, SM demonstrates an autosomal dominant mode of inheritance. Sporadic cases, however, can occur. Keratin 17 missense mutations occur in familial (but not sporadic) SM, usually in a hypermutable site of exon 1 of the gene (the helix initiation motif). K17 is expressed in the nail bed, hair follicles, and sebaceous glands. This same genetic mutation also causes pachyonychia congenita type 2 (PC-2). Patients with PC-2 have milder keratoderma, but also natal teeth, pili torti, angular cheilosis, and hoarseness. These patients have multiple cysts, some of which are steatocystomas and some eruptive vellus hair cysts. Milia, flexural abscesses identical to hidradenitis, and scrotal and vulvar cysts can also be seen in these kindreds. Hybrid cysts may occur. It is unclear why patients with hereditary SM and K17 mutations identical to those seen in PC-2 have no other stigmata of PC-2. Oligodontia and partial persistent primary dentition can be seen in some kindreds with SM and K17 mutations.

The definitive treatment of individual lesions is removal. This may be accomplished with small incisions and gentle extraction. However, the sheer number of the cysts usually precludes this type of treatment, and the location on the chest makes healing with cosmetically acceptable scars an issue. Laser incision of the cysts may also be effective. They may remain clinically improved for many months; however, eventual recurrence is the rule. Oral isotretinoin, 0.75–1 mg/kg/day, has been reported to benefit the suppurative variant of steatocystoma. Long-term follow-up has not been reported.

**Apaydin R, et al:** Steatocystoma multiplex suppurativum: oral isotretinoin treatment combined with cryotherapy. *Australas J Dermatol* 2000; 41:98.

**Bakkour W, Madan V:** Carbon dioxide laser perforation and extirpation of steatocystoma multiplex. *Dermatol Surg* 2014; 40(6):658–662.

**Choudhary S, et al:** A modified surgical technique for steatocystoma multiplex. *J Cutan Aesthet Surg* 2010; 3(1):25–28.

**Gass JK, et al:** Steatocystoma multiplex, oligodontia and partial persistent primary dentition associated with a novel keratin 17 mutation. *Br J Dermatol* 2009; 161:1396.

**Hollmig T, Menter A:** Familial coincidence of hidradenitis suppurativa and steatocystoma multiplex. *Clin Exp Dermatol* 2010; 35(4):e151–e152.

**Jain M, et al:** Acral steatocystoma multiplex. *Indian Dermatol Online J* 2013; 4(2):156–157.

**Kanda M, et al:** Morphological and genetic analysis of steatocystoma multiplex in an Asian family with pachyonychia congenita type 2 harbouring a *KRT17* missense mutation. *Br J Dermatol* 2009; 160:465.

**Lee D, et al:** Steatocystoma multiplex confined to the scalp with concurrent alopecia. *Ann Dermatol* 2011; 23(Suppl 2):S258–S260.

**Lee SJ, et al:** The vein hook successfully used for eradication of steatocystoma multiplex. *Dermatol Surg* 2008; 33:82–84.

**Moody MN, et al:** 1450-nm Diode laser in combination with the 1550-nm fractionated erbium-doped fiber laser for the treatment of steatocystoma multiplex: a case report. *Dermatol Surg* 2012; 38(7 Pt 1):1104–1106.

**Ofaiche J, et al:** Familial pachyonychia congenita with steatocystoma multiplex and multiple abscesses of the scalp due to the *p.Asn92Ser* mutation in keratin 17. *Br J Dermatol* 2014; 171(6):1565–1567.

**Papakonstantinou E, et al:** Facial steatocystoma multiplex combined with eruptive vellus hair cysts: a hybrid? *J Eur Acad Dermatol Venereol* 2014; Jul 30. [Epub ahead of print.]

**Park J, et al:** Late onset localized steatocystoma multiplex of the vulva. *Indian J Dermatol Venereol Leprol* 2014; 80(1):89–90.

**Torchia D et al:** Eruptive vellus hair cysts: a systematic review. *Am J Clin Dermatol* 2012; 13(1):19–28.

**Varshney M, et al:** Steatocystoma multiplex. *BMJ Case Rep* 2011; Sep 26.

## Eruptive vellus hair cysts

Eruptive vellus hair cysts (EVHCs) appear as multiple (up to hundreds), 1–4 mm, skin-colored or hyperpigmented,

dome-shaped papules of the midchest and proximal upper extremities. They may be congenital but usually have their onset between ages 4 and 18 (in the first and second decades). Disseminated lesions have been reported. A unilateral distribution can occur. Facial lesions can be distinctly hyperpigmented and simulate a primary melanocytic disorder, such as nevus of Ota. The pinna of the ear may rarely be affected. Hidrotic and anhidrotic ectodermal dysplasia and Lowe syndrome have been associated with EVHC. Onset in later adulthood with chronic renal failure has been reported in multiple cases. Clinically, EVHCs tend to be smaller than steatocystomas and may have an area of central hyperkeratosis or umbilication, a feature lacking in steatocystoma. Acne is distinguished by the lack of inflammatory lesions.

Histologically, the cystic epithelium is of the stratified squamous type; the cyst contents are composed of laminated keratin and multiple vellus hairs, and follicle-like invaginations may be present in the cyst wall. Steatocystoma may at times have vellus hairs, and EVHCs may have sebaceous glands in their lining. About 25% of EVHC lesions spontaneously resolve by transepidermal elimination. Topical tazarotene has been effective, but with no long-term follow-up. Similarly, lactic acid 12% and topical tretinoin can lead to improvement. Most treatments are surgical, including extraction, and CO<sub>2</sub> laser. Er:YAG laser is inferior to tazarotene and is associated with recurrence.

**Alfaro-Castellon P, et al:** Dermoscopy distinction of eruptive vellus hair cysts with molluscum contagiosum and acne lesions. *Pediatr Dermatol* 2012; 29(6):772–773.

**Chan KH, et al:** Eruptive vellus hair cysts presenting as bluish-grey facial discoloration masquerading as naevus of Ota. *Br J Dermatol* 2007; 157:188.

**Helbig D, et al:** Comparative treatment of multiple vellus hair cysts with the 2940 nm Er:YAG and 1540 nm Er:Glass laser. *J Cosmet Laser Ther* 2011; 13(5):223–226.

**Köse O, et al:** Anhidrotic ectodermal dysplasia with eruptive vellus hair cysts. *Int J Dermatol* 2001; 40:401.

**Park JH, et al:** A case of eruptive vellus hair cysts that developed on the labium major. *Ann Dermatol* 2009; 21(3):294–296.

**Rodgers SA, et al:** Familial eruptive vellus hair cysts. *Pediatr Dermatol* 2012; 29(3):367–369.

**Saks K, Levitt JO:** Tazarotene 0.1 percent cream fares better than erbium:YAG laser or incision and drainage in a patient with eruptive vellus hair cysts. *Dermatol Online J* 2006; 12:7.

**Torchia D, et al:** Eruptive vellus hair cysts: a systematic review. *Am J Clin Dermatol* 2012; 13(1):19–28.

## Milia

Milia are keratinous cysts 1–4 mm in diameter. They are white and easily seen as cystic through the overlying attenuated skin. Milia are common, and multiple clinical patterns of milia have been described. Milia can be considered primary, appearing spontaneously, or secondary, caused by trauma, skin disease, or medication.

Primary milia occur congenitally (or shortly after birth in preterm neonates) in up to 50% of newborns. They favor the face, especially the nose, scalp, upper trunk, and proximal extremities of all races and both genders. They resolve over weeks. Rare kindreds with an autosomal dominant inheritance have profuse, essentially confluent, congenital milia on the face. These also spontaneously resolve. Adults and children frequently develop milia, especially on the cheeks, eyelids, forehead, and genitalia. In infants, milia localized to the areola may be seen. These milia tend to persist. Multiple eruptive milia is a term applied to lesions that occur spontaneously in too large a number to be considered benign primary milia of children and adults. Cases favor the head and erupt over

weeks to months. This can be idiopathic or familial. Nasal crease milia appear in a horizontal row in the nasal crease in nonatopic persons. Some cases are congenital. Pseudoacne of the nasal crease may be related. Milia en plaque describes a rare disorder characterized by an erythematous plaque containing numerous milia. These lesions are usually on the head and neck, especially the periauricular or periorbital regions. They are most common in middle-age females. One 3-year-old child had widespread depigmented macules and patches with numerous milia in the depigmented areas, termed generalized milia with nevus depigmentosus.

Secondary milia can develop as a result of blistering skin diseases, such as epidermolysis bullosa, pemphigus, bullous pemphigoid, porphyria cutanea tarda, herpes zoster, polymorphous light eruption, lupus erythematosus, Stevens-Johnson syndrome, contact dermatitis, and many other conditions. They also tend to occur after trauma, such as dermabrasion, chemical peel, ablative laser therapy, skin grafts, and radiotherapy. Long-term topical corticosteroid therapy and use of occlusive moisturizers may result in the appearance of milia. Cyclosporine and 5-FU have been associated with the development of milia.

Multiple milia have been reported in a number of genodermatoses, such as congenital ectodermal defect; reticular pigmented genodermatosis with milia (Naegeli-Franceschetti-Jadassohn syndrome); congenital absence of dermal ridges, syndactyly, and facial milia; generalized basaloid follicular hamartoma syndrome; basal cell nevus syndrome; atrichia with papular lesions; pachyonychia congenita type 2; Rombo syndrome; Brooke-Spiegler syndrome; Loey-Pictz syndrome; and Bazex syndrome.

Primary milia are small epidermoid cysts, derived from the infundibulum of the vellus hair (Fig. 29-55). As with epidermoid cysts, primary milia are fixed and persistent. Secondary milia may be derived from eccrine ducts or hair follicles as they attempt to reepithelialize eroded epidermis. They are often transient and spontaneously disappear. Milia must be distinguished from milialike idiopathic calcinosis cutis, miliary osteomas, syringomas with milialike structures, trichoepitheliomas, comedonal acne, flat warts, and xanthelasma. Lesions of cutaneous T-cell lymphoma with prominent follicular mucinosis may have many milia. Treatment is incision and expression of the contents with a beveled cutting tipped hypodermic needle, 11 blade, or comedo extractor. No anesthesia is needed

for most patients. Topical tretinoin (Retin-A) has been reported effective in treating milia en plaque and more generalized forms of milia involving the face. Minocycline has also been used to treat milia en plaque.

**Belhadjali H, et al:** Milia en plaque and discoid lupus erythematosus. *Clin Exp Dermatol* 2009; 34:e356.

**Berk DR, Bayliss SJ:** Milia: a review and classification. *J Am Acad Dermatol* 2008; 59:1050.

**Berk DR, Bayliss SJ:** Milium of the areola: a novel regional variant of primary milia. *Pediatr Dermatol* 2009; 26:485.

**Connolly T:** Eruptive milia and rapid response to topical tretinoin. *Arch Dermatol* 2008; 144:816.

**Ishiura N, et al:** A case of milia en plaque successfully treated with oral etretinate. *Br J Dermatol* 2007; 157(6):1287-1289.

**Miller LM, et al:** Milia: a unique reaction to tattoos. *Cutis* 2011; 87(4):195-196.

**Nambudiri VE, et al:** Milia en plaque of the nose: report of a case and successful treatment with topical tretinoin. *Pediatrics* 2014; 133(5):e1373-1376.

**Risma KA, Lucky AW:** Pseudoacne of the nasal crease: a new entity? *Pediatr Dermatol* 2004; 21:427.

**Rutter KJ, Judge MR:** Profuse congenital milia in a family. *Pediatr Dermatol* 2009; 26:62.

**Sambrano BL, et al:** Eruptive milia secondary to vemurafenib. *J Am Acad Dermatol* 2013; 69(5):e258-e260.

**Tzermias C, et al:** Reticular pigmented genodermatosis with milia: special form of Naegeli-Franceschetti-Jadassohn syndrome or a new entity? *Clin Exp Dermatol* 1995; 20:331.

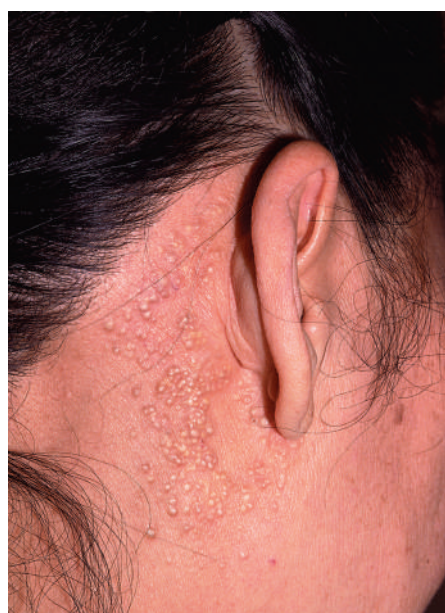**Voth H, Reinhard G:** Periocular milia en plaque successfully treated by erbium:YAG laser ablation. *J Cosmet Laser Ther* 2011; 13(1):35-37.

## Verrucous cysts (cystic papillomas)

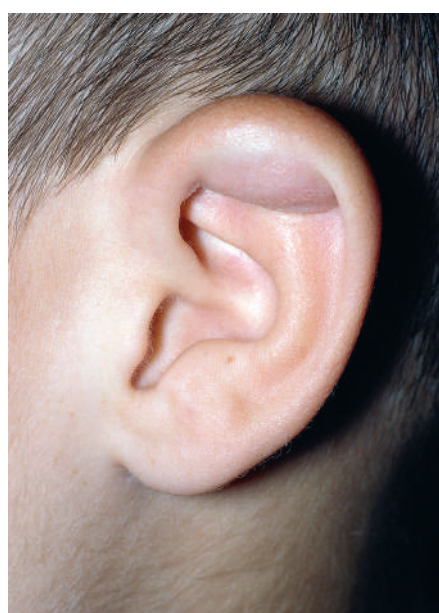Verrucous cysts resemble epidermoid cysts, except that the lining demonstrates papillomatosis and coarse hypergranulosis. Koilocytes may be present. On the sole, red granules resembling those in myrmecia are often seen. They have been shown to contain HPV and probably form as a result of HPV infection of a follicular unit or sweat duct (see Chapter 19).

## Pseudocyst of the auricle (auricular endochondral pseudocyst)

Pseudocyst of the auricle presents clinically as a fluctuant, tense, noninflammatory swelling on the upper half of the ear



**Fig. 29-55** Milia en plaque.



**Fig. 29-56** Pseudocyst of the auricle.



(Fig. 29-56). Most affected persons are between ages 20 and 45, and up to 90% are male. Pruritic disorders such as atopic dermatitis and systemic lymphoma, hard pillows in China, carrying heavy objects on the shoulder, helmet and earphone wearing, and a slap to the side of the head have all been associated with auricular pseudocysts. This strongly suggests that trauma plays a role, although patients will frequently deny trauma. The fluid collection is between the two layers of the bilaminar cartilage of the pinna. There is no cyst lining, with the affected cartilage showing focal degeneration and granulation tissue. Needle aspiration yields serous or bloody fluid. Simple aspiration is ineffective. Aspiration or drainage, followed by the application of a bolster or pressure dressing for several weeks, is usually effective. Since application of pressure for several weeks is required, a sutured-on bolster with buttons or gauze is easier for the patient than an externally applied dressing. Intracystic injections of corticosteroids, fibrin glue, or minocycline have been used in recurrent cases. Surgical intervention involves removal of the inner anterior portion of the cyst.

**Kallini JR, Cohen PR:** Rugby injury-associated pseudocyst of the auricle: report and review of sports-associated dermatoses of the ear. *Dermatol Online J* 2013; 19(2):11.

**Kanotra SP, Lateef M:** Pseudocyst of pinna: a recurrence-free approach. *Am J Otolaryngol* 2009; 30:73.

**Kim H, et al:** Human papillomavirus type 59 identified in a verrucous cyst of the flank. *Eur J Dermatol* 2006; 16(3):254–257.

**Kim TY, et al:** Treatment of a recurrent auricular pseudocyst with intralesional steroid injection and clip compression dressing. *Dermatol Surg* 2009; 35:245.

**Lee JY, et al:** Successful treatment of a pseudocyst of the auricle using intralesional sodium tetradecyl sulfate injection. *Dermatol Surg* 2013; 39(12):1938–1940.

**Patigaroo SA, et al:** Clinical characteristics and comparative study of different modalities of treatment of pseudocyst pinna. *Eur Arch Otorhinolaryngol* 2012; 269(7):1747–1754.

**Pusiol T, et al:** Invasive squamous cell carcinoma arising from a human papillomavirus genotype 16-associated verrucous cyst. *Int J Infect Dis* 2010; 14(Suppl 3):e378.

**Salgado CJ, et al:** Treatment of auricular pseudocyst with aspiration and local pressure. *J Plast Reconstr Aesthet Surg* 2006; 59:1450.

## Cutaneous columnar cysts

Five types of cyst that occur in the skin are lined by columnar epithelium, as described next.

### Bronchogenic cysts

These small, solitary cysts or sinuses are most often located in the region of the suprasternal notch or over the manubrium sterni. Bronchogenic cysts can also occur on the chin, neck, and abdominal wall. A scapular location is rarely described. Boys are affected four times more often than girls. Lesions are typically subcutaneous and rarely connect to deeper structures. Histologically, the cyst is composed of a wall lined by respiratory epithelium and may contain seromucinous glands and underlying fibromuscular connective tissue or cartilage. Gastric mucosa may also be seen.

### Branchial cleft cysts

These present as cysts, sinuses, or skin tags along the anterior border of the sternocleidomastoid muscle or near the angle of the mandible (Fig. 29-57). Branchial cysts are lined primarily with stratified squamous epithelium. Lymphoid follicles are often present, and smooth muscle is absent, distinguishing branchial cleft from bronchogenic cysts, although some evidence suggests that these cysts are related.

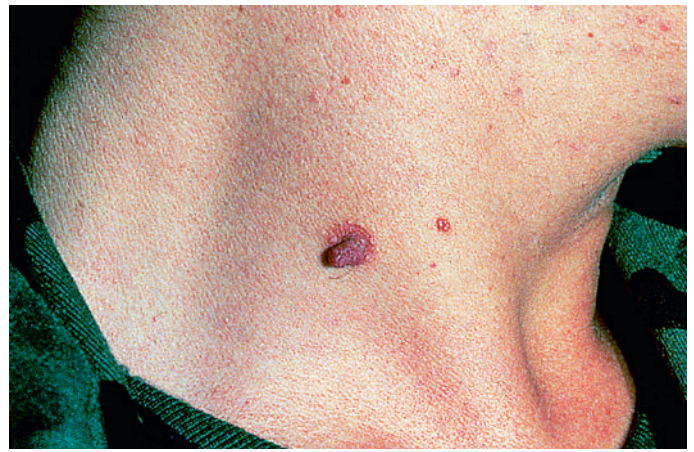

Fig. 29-57 Branchial cleft cyst.

### Thyroglossal duct cysts

Thyroglossal duct cysts virtually always occur on the anterior portion of the neck, near the hyoid bone. They present as a sinus, cyst, or recurrent abscess of the neck. Thyroglossal duct cysts are the most common cause of congenital neck anomalies in childhood. Presentation in adult life can occur. Malignancies (papillary adenocarcinoma, follicular adenocarcinoma, mixed papillary/follicular adenocarcinoma, adenocarcinoma, SCCs) arising from cysts have been reported in 1% of cases. Clinically, thyroglossal duct cysts are deep to subcutaneous tissue and usually are not managed by dermatologists.

### Cutaneous ciliated cysts

Cutaneous ciliated cysts are usually solitary and located on the legs of females. Men account for only 10% of cases. These cysts have also been described in the perineum and vulva (vulvar ciliated cysts). The epithelium lining the cysts is cuboidal to columnar, with pseudostratified areas. Cilia are seen, and the lining cells stain strongly for dynein. This histology is similar to the normal fallopian tube, suggesting that the cysts are of müllerian origin. Ciliated metaplasia of the eccrine duct has been proposed for lesions occurring on the upper half of the body and in men. As with the median raphe cyst, the cavity is often filled with debris.

### Median raphe cysts

Median raphe cysts of the penis are developmental defects lying in the ventral midline of the perineum from the anus to the urethra, most often on the distal shaft near the glans. They most frequently present as dermal lesions of less than 1 cm in young men and may appear suddenly after sexual intercourse-associated trauma. These cysts may appear as a cord or a series of beads (termed canal-like). They are lined by pseudostratified columnar epithelium with focal areas of mucin-secreting epithelium present. Ciliated cells may be present and, as with ciliated cysts in females, the cavity is typically filled with debris. Melanocytes may occasionally be present in the cyst wall, giving the cysts a pigmented appearance. Median raphe cysts do not stain with human milk fat globulin 1, distinguishing them from apocrine cystadenomas. Median raphe cysts do not connect with the urethra and can be treated with surgical excision.

## CONGENITAL PREAURICULAR FISTULA

This anomaly occurs as a pit in the preauricular region, often in several members and generations of a family. On each side,

just anterior to the external ear, there is a small dimple, pore, or fistulous opening that may extend as far as the middle ear. Most congenital preauricular fistulas are benign and do not require surgery. Complications of surgery are common, and complete excision of both the pit and the sinus tract should be the goal if surgery is attempted.

**Chong SJ, et al:** Cutaneous ciliated cyst in a 16-year-old girl. *J Am Acad Dermatol* 2007; 56(1):159–160.

**Geller KA, et al:** Thyroglossal duct cyst and sinuses: a 20-year Los Angeles experience and lessons learned. *Int J Pediatr Otorhinolaryngol* 2014; 78(2):264–267.

**Huang XY, et al:** Preauricular sinus: clinical course and associations. *Arch Otolaryngol Head Neck Surg* 2007; 133(1):65–68.

**Joehlin-Price AS, et al:** PAX-8 expression in cutaneous ciliated cysts: evidence for müllerian origin. *Am J Dermatopathol* 2014; 36(2):167–170.

**Kawaguchi Y, et al:** Infected bronchogenic cyst treated with drainage followed by resection. *Ann Thorac Surg* 2014; 98(1):332–334.

**Krauel L, et al:** Median raphe cysts of the perineum in children. *Urology* 2008; 71:830.

**LaCarrubba F, et al:** Canal versus cysts of the penile median raphe: advancing diagnostic methods using videodermatoscopy. *Pediatr Dermatol* 2010; 27(6):667–669.

**Lee DK, et al:** Efficacy of ethanol ablation for thyroglossal duct cyst. *Ann Otol Rhinol Laryngol* 2015; 124(1):62–67.

**Mattingly JK, et al:** Cervical bronchogenic cysts: case report and review of the literature. *Am J Otolaryngol* 2014; 35(5):655–657.

**Nishida H, et al:** Pigmented median raphe cyst of the penis. *J Cutan Pathol* 2012; 39(8):808–810.

**Park CO, et al:** Median raphe cyst on the scrotum and perineum. *J Am Acad Dermatol* 2006; 55:S114.

**Pastore V, Bartoli F:** “Extended” Sistrunk procedure in the treatment of recurrent thyroglossal duct cysts: a 10-year experience. *Int J Pediatr Otorhinolaryngol* 2014; 78(9):1534–1536.

**Pradeep KE:** Cutaneous bronchogenic cyst: an under-recognised clinicopathological entity. *J Clin Pathol* 2009; 62:384.

**Proia G, et al:** Papillary carcinoma on a thyroglossal duct cyst: diagnostic problems and therapeutic dilemma—a case report. *Acta Otorhinolaryngol Ital* 2014; 34(3):215–217.

**Reserva JL, et al:** Cutaneous ciliated cyst of the scalp: a case report of a cutaneous ciliated eccrine cyst and a brief review of the literature. *Am J Dermatopathol* 2014; 36(8):679–682.

**Rohof D, et al:** Recurrences after thyroglossal duct cyst surgery: results in 207 consecutive cases and review of the literature. *Head Neck* 2014; Jul 1. [Epub ahead of print.]

**Turkylmaz Z, et al:** Management of thyroglossal duct cysts in children. *Pediatr Int* 2004; 46:77.

**Verma SB:** Canal-like median raphe cysts: an unusual presentation of an unusual condition. *Clin Exp Dermatol* 2009; 34:e857.

**Vlodavsky E, et al:** Gastric mucosa in a bronchogenic cutaneous cyst in a child: case report and review of literature. *Am J Dermatopathol* 2005; 27:145.



Bonus images for this chapter can be found online at [expertconsult.inkling.com](http://expertconsult.inkling.com)

**eFig. 29-1** Verrucous linear epidermal nevus.

**eFig. 29-2** Nevus comedonicus.

**eFig. 29-3** Nevus sebaceus syndrome with lipodermoid of the conjunctiva.

**eFig. 29-4** Hyperkeratosis of the nipple.

**eFig. 29-5** Seborrheic keratosis.

**eFig. 29-6** Stucco keratoses.

**eFig. 29-7** Benign lichenoid keratosis.

**eFig. 29-8** Arsenical keratosis in patient exposed to arsenic in drinking water.

**eFig. 29-9** Hyperkeratotic actinic keratosis of arms and hands.

**eFig. 29-10** Cutaneous horn of penis overlying HPV-positive squamous cell carcinoma.

**eFig. 29-11** Basal cell carcinoma.

**eFig. 29-12** Basal cell carcinoma.

**eFig. 29-13** Squamous cell carcinoma, preauricular ulceration in patient with AIDS.

**eFig. 29-14** Bowen's disease.

**eFig. 29-15** Erythroplasia of Queyrat.

**eFig. 29-16** Zoon balanitis, fixed red papule on glans penis indistinguishable from erythroplasia of Queyrat.

**eFig. 29-17** Paget's disease of the breast.

**eFig. 29-18** Merkel cell carcinoma.

**eFig. 29-19** Nevus sebaceus.

**eFig. 29-20** Syringomas.

**eFig. 29-21** Hidrocystomas.

**eFig. 29-22** Trichoepithelioma.

**eFig. 29-23** Trichoblastoma.

**eFig. 29-24** Birt-Hogg-Dubé syndrome.

**eFig. 29-25** Dilated pore of Winer.

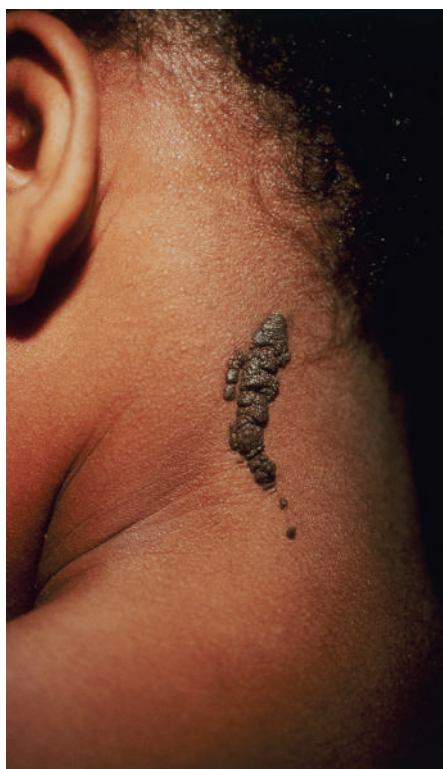**eFig. 29-26** Pilonidal sinus.

**eFig. 29-27** Extramammary Paget's disease.

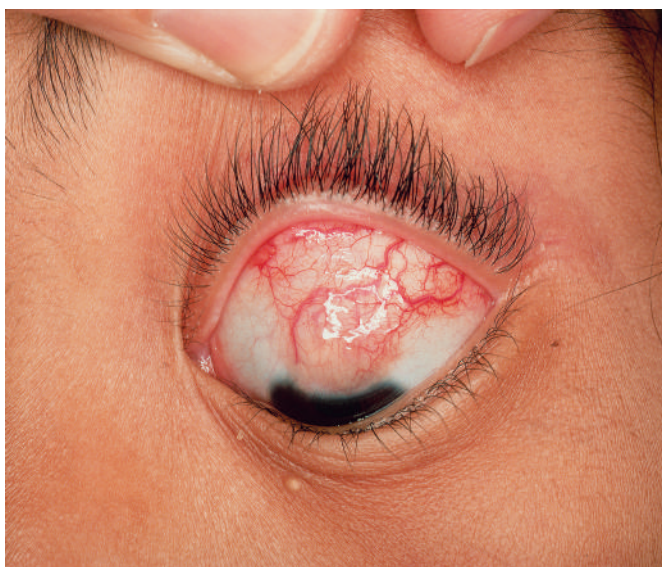**eFig. 29-28** Epidermal inclusion cyst.

**eFig. 29-29** Steatocystoma multiplex.

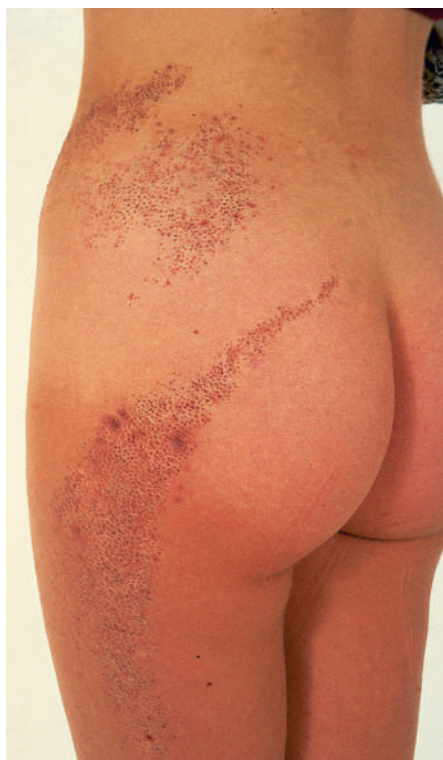



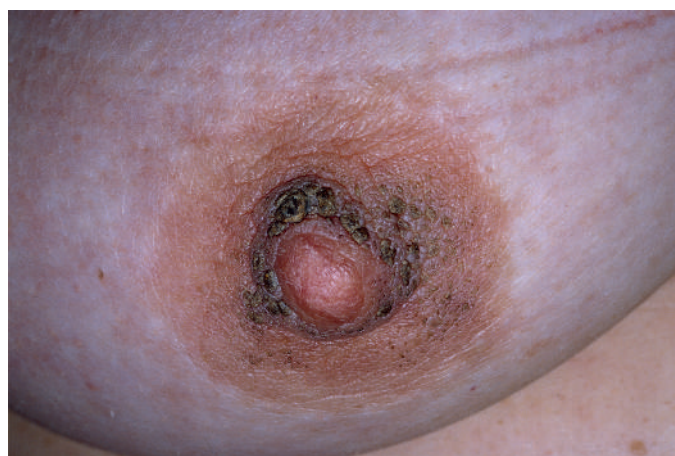**eFig. 29-1** Verrucous linear epidermal nevus.



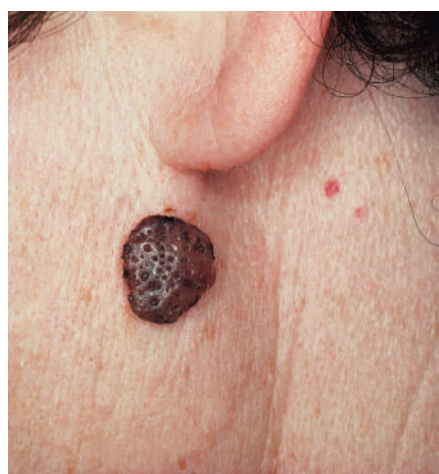**eFig. 29-3** Nevus sebaceus syndrome with lipodermoid of the conjunctiva.



**eFig. 29-2** Nevus comedonicus.

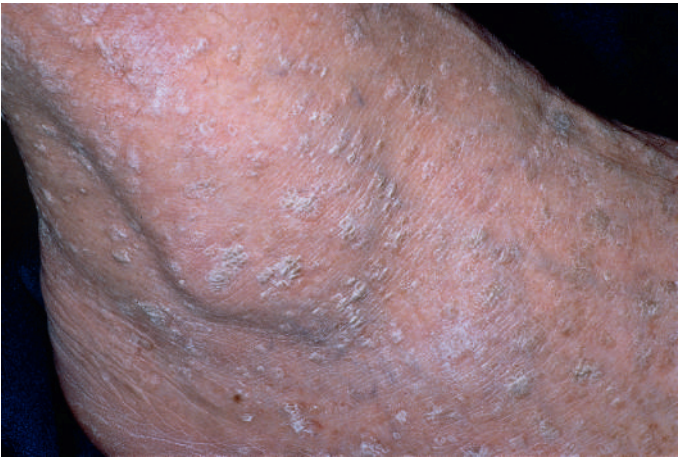


**eFig. 29-4** Hyperkeratosis of the nipple.

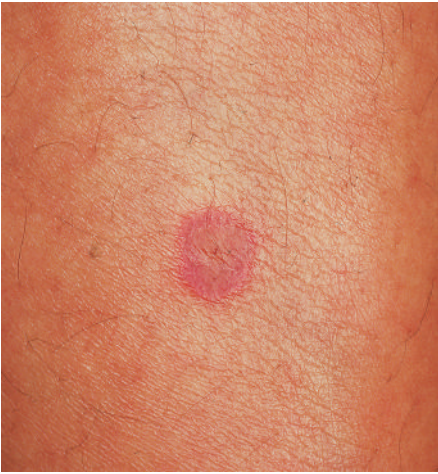

**eFig. 29-5** Seborrheic keratosis.

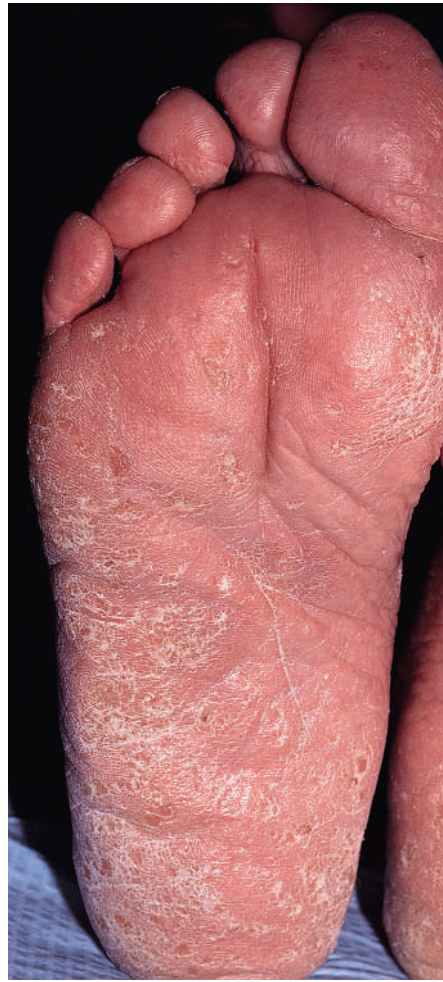



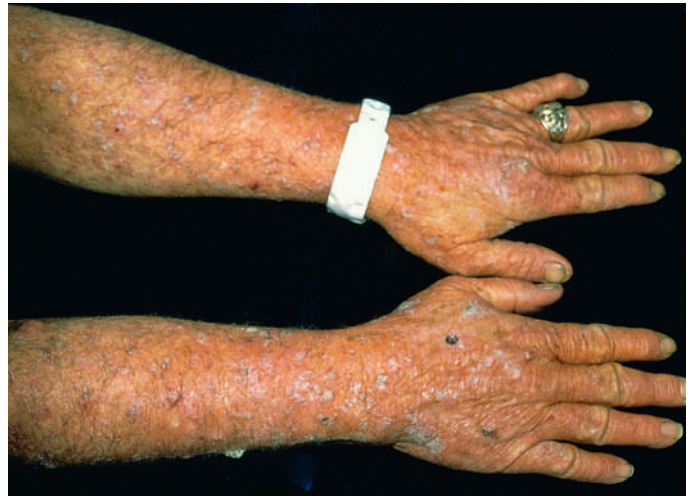**eFig. 29-6** Stucco keratoses.



**eFig. 29-7** Benign lichenoid keratosis.

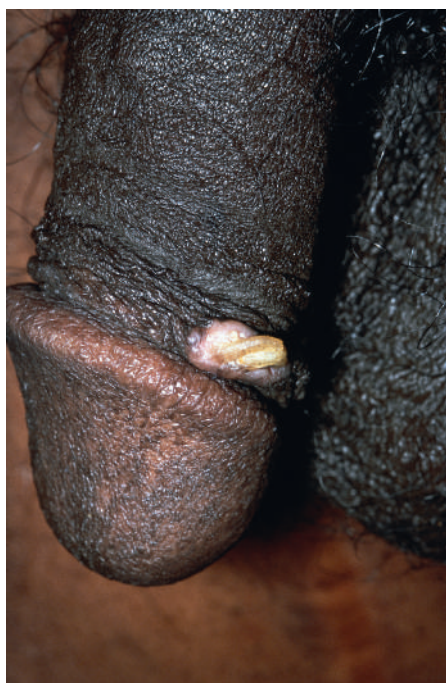

**eFig. 29-8** Arsenical keratosis in patient exposed to arsenic in drinking water.

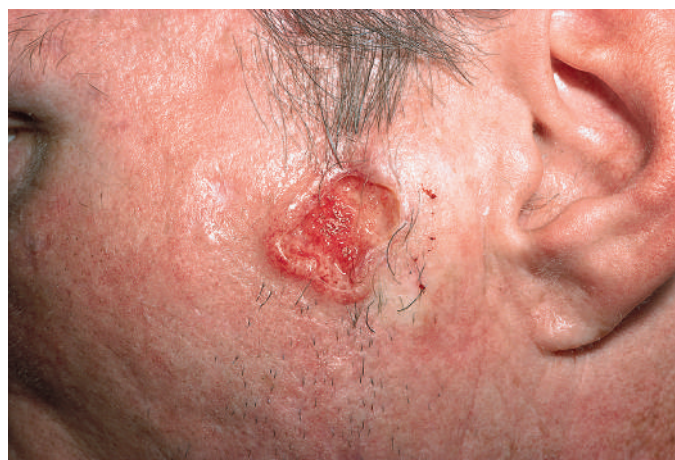

**eFig. 29-9** Hyperkeratotic actinic keratosis of arms and hands.

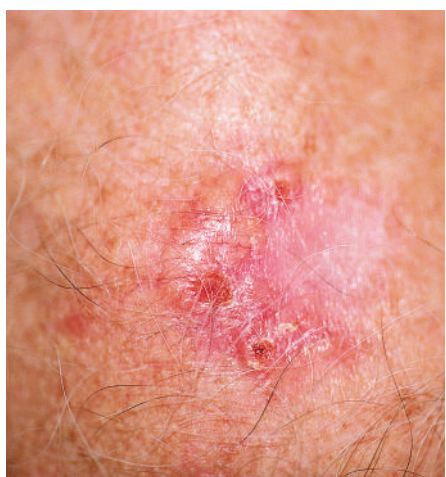



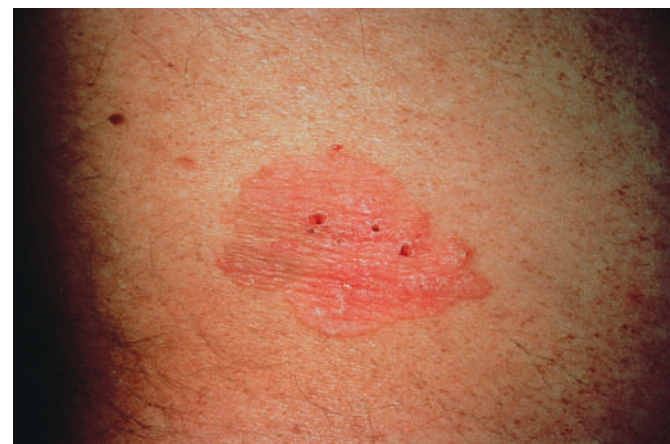**eFig. 29-10** Cutaneous horn of penis overlying HPV-positive squamous cell carcinoma.



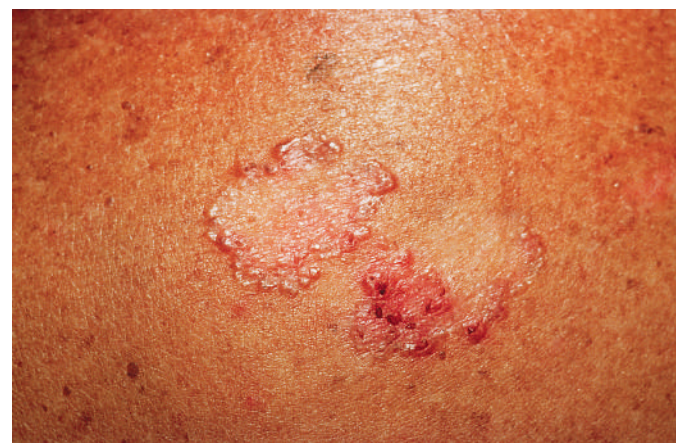**eFig. 29-13** Squamous cell carcinoma, preauricular ulceration in patient with AIDS.



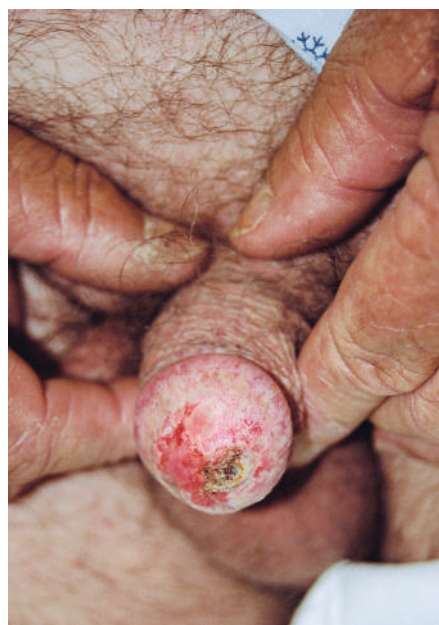**eFig. 29-11** Basal cell carcinoma.



**eFig. 29-14** Bowen's disease.

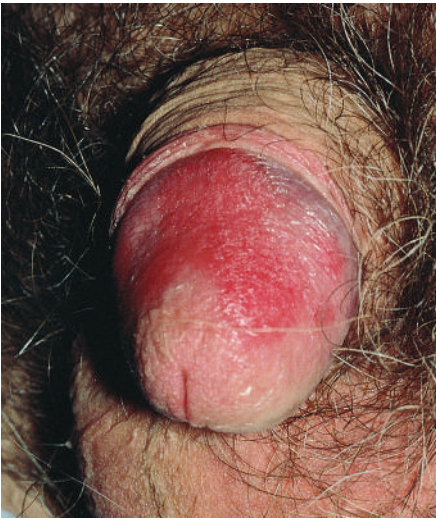

**eFig. 29-12** Basal cell carcinoma.

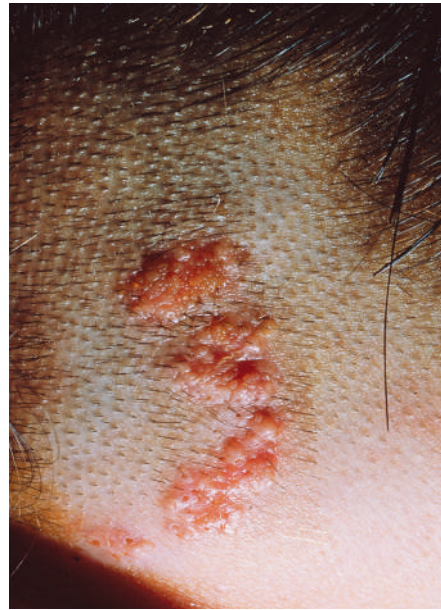

**eFig. 29-15** Erythroplasia of Queyrat.

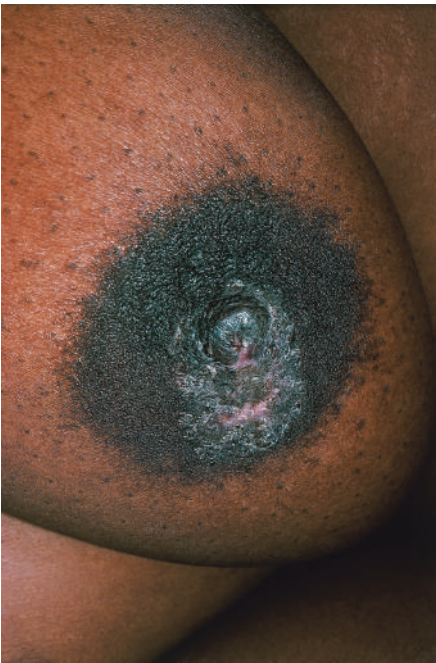



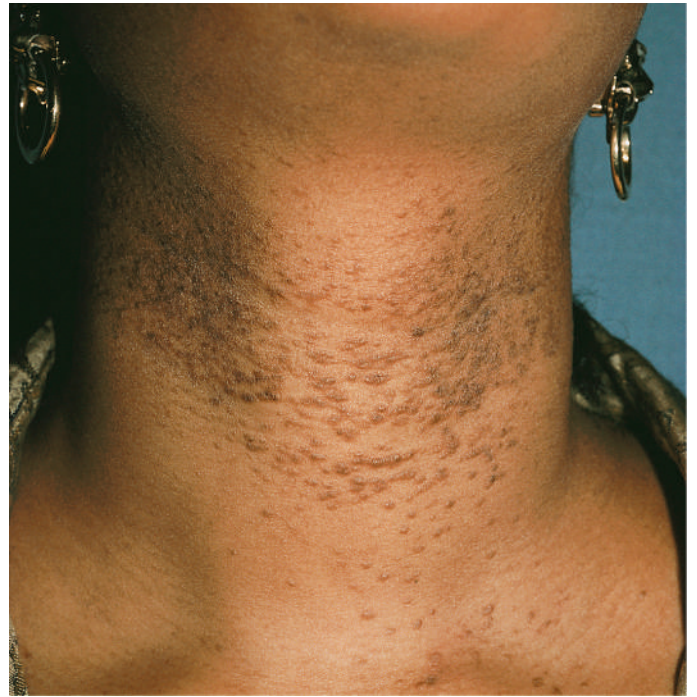**eFig. 29-16** Zoon balanitis, fixed red papule on glans penis indistinguishable from erythroplasia of Queyrat.



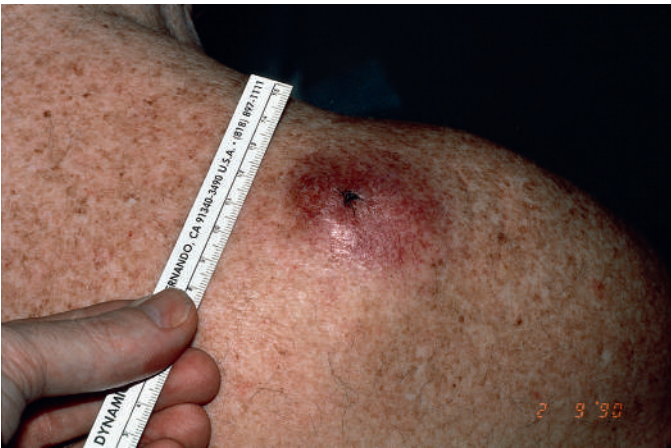**eFig. 29-19** Nevus sebaceus.



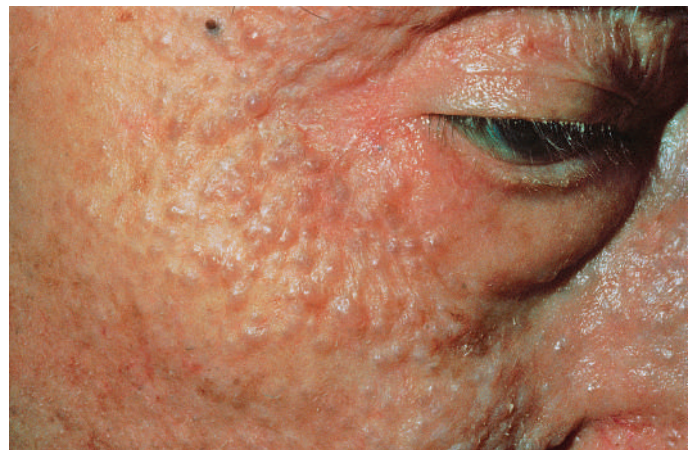
**eFig. 29-17** Paget's disease of the breast.



**eFig. 29-20** Syringomas.

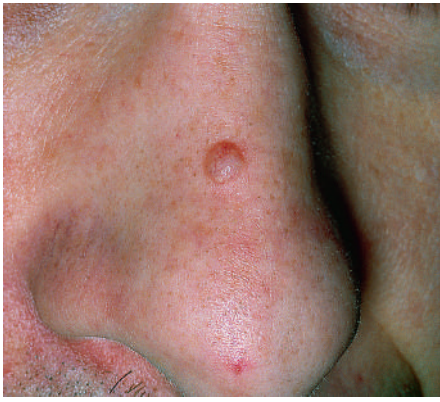

**eFig. 29-18** Merkel cell carcinoma.

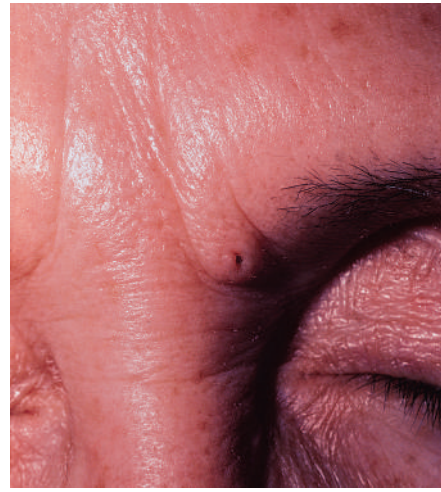

**eFig. 29-21** Hidrocystomas.

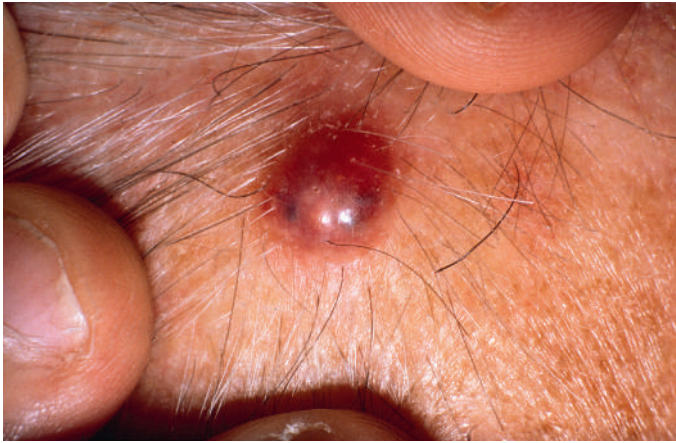




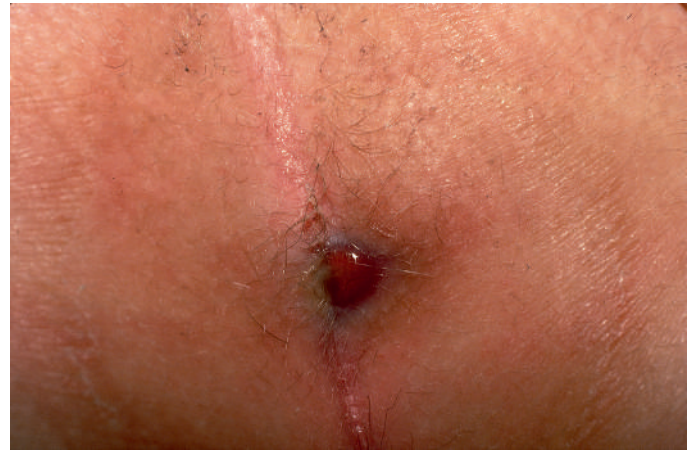**eFig. 29-22**  
Trichoepithelioma.



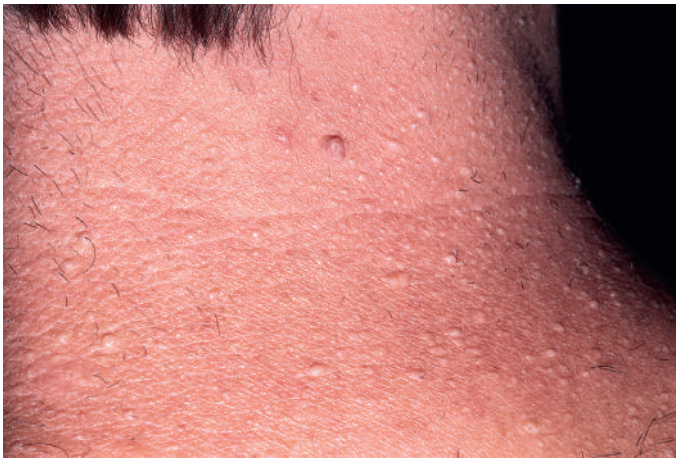**eFig. 29-25** Dilated  
pore of Winer.



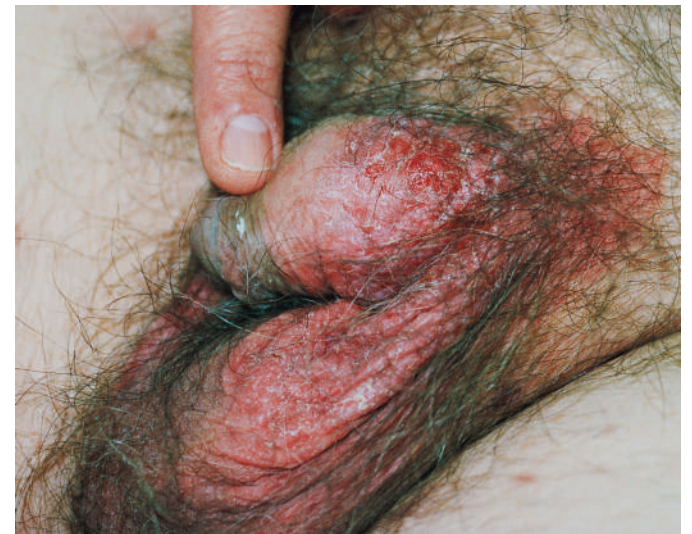**eFig. 29-23** Trichoblastoma.



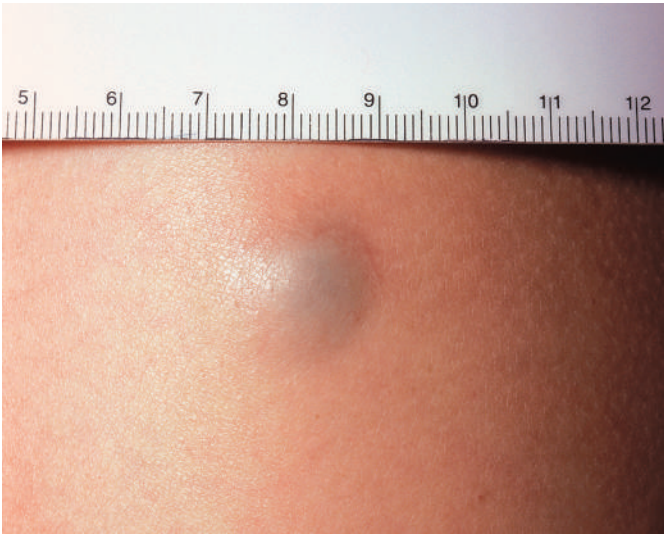
**eFig. 29-26** Pilonidal sinus.



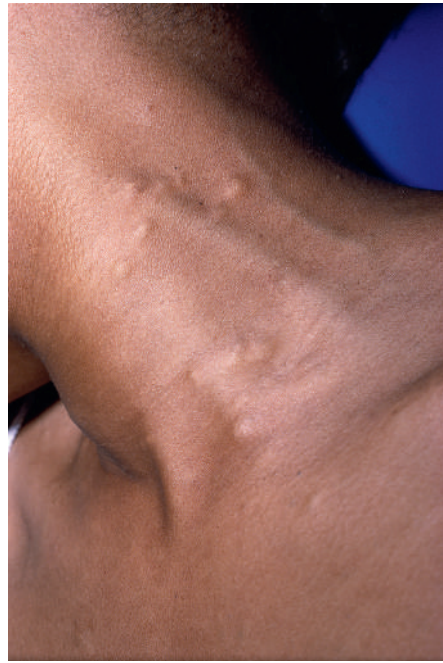**eFig. 29-24** Birt-Hogg-Dubé syndrome.



**eFig. 29-27** Extramammary Paget's disease.



**eFig. 29-28** Epidermal inclusion cyst.



**eFig. 29-29**  
Steatocystoma  
multiplex.



# 30

## Melanocytic Nevi and Neoplasms

Melanocytes originate in the embryonal neural crest and migrate to the epidermis, dermis, leptomeninges, retina, mucous membrane epithelium, inner ear, cochlea, and vestibular system. Nevus cells are a form of melanocyte with a tendency to aggregate into clusters of cells. Nevus cells lack dendritic processes but are otherwise similar to other melanocytes.

### EPIDERMAL MELANOCYTIC LESIONS

The melanocytes occurring at the dermoepidermal junction (DEJ) are dendritic cells that supply melanin to the skin. These cells contain pigment granules (melanosomes). Melanocytes stain with the dopa reaction and silver stains because they contain melanin. Immunohistochemical stains, such as S-100, HMB-45, MelanA/Mart-1, MITF, and SOX-10, do not depend on the presence of melanin. These stains have largely replaced silver stains for the identification of melanocytes in biopsy specimens. Melanocytes of the epidermis transfer melanosomes through their thin, dendritic processes, where they are actively taken up by keratinocytes. Melanocyte numbers vary by anatomic site and are increased in sun-damaged skin, but they vary little among racial groups. The type, number, size, dispersion, and degree of melanization of the melanosomes determine the pigmentation of the skin and hair.

Treatment of epidermal pigmented lesions can be directed at pigmented keratinocytes, melanocytes, or melanosomes. Q-switched (QS) lasers target the melanosome. Lasers with a longer pulse duration lasting milliseconds (ms) result in melanocyte destruction. Laser treatment produces consistent lightening of ephelides, but the response is variable for café au lait macules, Becker nevus, and nevus spilus.

### Ephelis

The common freckle occurs in light-skinned individuals in response to sun exposure. Histologically, freckles demonstrate pigmented basilar keratinocytes, and a mild increase in the number of melanocytes.

### Nevus spilus

Nevus spilus (speckled lentiginous nevus) presents as a light-brown or tan macule, speckled with smaller, darker macules or papules (Fig. 30-1). It frequently occurs on the trunk and lower extremities, tends to follow Blaschko lines, and is noted in approximately 2% of the population. The nevus spilus may be small, measuring less than 1 cm in diameter, or may be quite large and follow a segmental distribution, referred to as a “zosteriform” lentigo. Multiple sites may be involved in the same individual and may be widely separated by normal skin.

Happle has suggested dividing the entity into two forms, a macular type and a papular type. The dark speckles in the macular type are more evenly distributed and represent junctional lentiginous nevi; malignant melanoma has been reported more frequently in this type. Nevus spilus maculosus is consistently found in phacomatosis spilorosea, whereas nevus spilus papulosus demonstrates compound or intradermal nevi and is seen in phacomatosis pigmentokeratocica.

Nevus spilus in combination with a nevus flammeus is called phacomatosis pigmentovascularis (see Chapter 28). Phacomatosis pigmentokeratocica includes a speckled lentiginous nevus, organoid nevus, hemiatrophy, and neurologic findings such as muscular weakness. Generalized nevus spilus has been associated with nevus anemicus and primary lymphedema. Nevus spilus has also been reported in association with nevus depigmentosus and with bilateral nevus of Ito.

Histologically, the flat, tan background may show only basilar hyperpigmentation, such as is present in a café au lait spot, or lentiginous proliferation of the epidermis with bulbous rete ridges. The darker speckles usually contain nevus cells and may occasionally demonstrate blue nevi or Spitz nevi.

Because nevus cells are often present in the dark speckles, melanoma may rarely arise in them. A changing lesion should be biopsied. Removal by QS ruby laser or QS alexandrite laser has been reported as effective but may require many sessions for acceptable results.

**Arnold AW, et al:** Phacomatosis melanorosea without extracutaneous features: an unusual type of phacomatosis pigmentovascularis. *Eur J Dermatol* 2012; 22(4):473–475.

**Hanayama H, et al:** Congenital melanocytic nevi and nevus spilus have a tendency to follow the lines of Blaschko: an examination of 200 cases. *J Dermatol* 2007; 34(3):159–163.

**Happle R:** Nevus spilus maculosus vs. partial unilateral lentiginosis. *J Acad Dermatol Venereol* 2007; 21(5):713.

**Happle R:** Speckled lentiginous naevus: which of the two disorders do you mean? *Clin Exp Dermatol* 2009; 34(2):133–135.

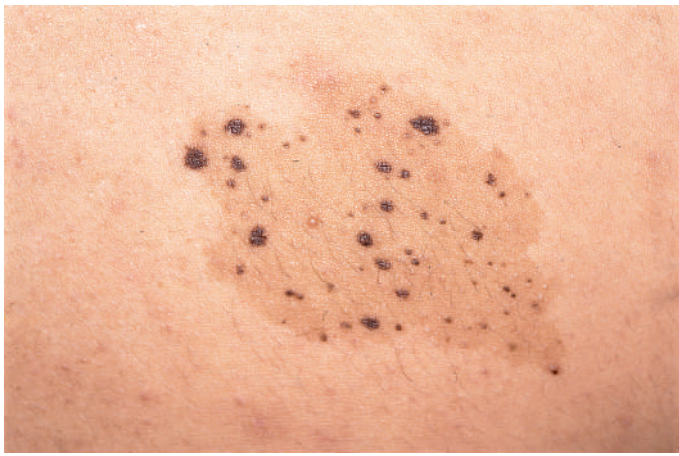
**Kar H, et al:** Treatment of nevus spilus with Q switched Nd:YAG laser. *Indian J Dermatol Venereol Leprol* 2013; 79(2):243–245.

**Tavoloni Braga JC, et al:** Early detection of melanoma arising within nevus spilus. *J Am Acad Dermatol* 2014; 70(2):e31–e32.

### Lentigo

#### Lentigo simplex

These lesions occur as sharply defined, round to oval, brown or black macules. Lentigines usually arise in childhood but may appear at any age. There is no predilection for areas of sun exposure. Multiple lentigines may appear after clearing of plaques of psoriasis, including during biologic therapy. Histologically, lentigo simplex shows hyperpigmentation of basilar keratinocytes and an increase in the number of melanocytes in the basal layer. Melanophages are usually present in the upper dermis.



**Fig. 30-1** Nevus spilus. (Courtesy of Dr. Rui Tavares-Bello.)

### Solar lentigo (lentigo senilis)

Solar lentigines are commonly known as “liver spots.” They are persistent, benign, discrete, hyperpigmented, round to oval macules occurring on sun-damaged skin. The backs of the hands, cheeks, and forehead are favorite sites in the typical older patient. Red-haired, light-skinned individuals, especially those with high solar exposure, may develop many of these on the shoulders and central upper chest, even at an early age. Solar lentigines may be accompanied by depigmented macules, actinic purpura, and other chronic actinic degenerative changes in the skin. They may evolve into benign lichenoid keratoses and reticulated seborrheic keratoses.

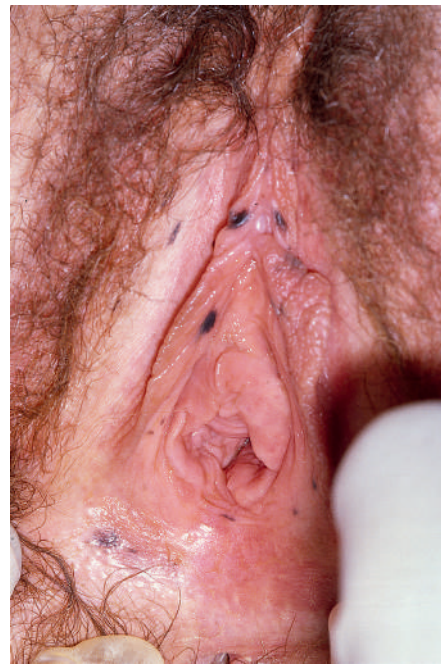Histologically, the rete ridges appear club shaped or show narrow, budlike extensions. There is a marked increase in pigmentation in the basal cell layer, especially at the tips of the bulbous rete. The number of melanocytes is slightly increased, and the upper dermis often contains melanophages.

Application of liquid nitrogen with a cotton-tipped applicator or cryospray unit is often an effective destructive modality. Argon, QS neodymium-yttrium-aluminum-garnet (Nd:YAG), frequency-doubled Nd:YAG, QS and long-pulse alexandrite, QS ruby, and Er:YAG lasers have been reported as effective. Intense pulsed light has also been used. Postinflammatory pigment alteration is the major complication seen with destructive modalities. Sun protection will reduce the number of new lesions. Bleaching creams containing 4% or 5% hydroquinone, used over several months, will induce temporary lightening. Hydroquinone-cyclodextrin (2%), 4-hydroxyanisole (4-HA), chemical peels, local dermabrasion, topical tretinoin, and adapalene are other treatment options. The combination of 2% 4-HA and 0.01% tretinoin is superior to either active component alone, and a commercial preparation containing these two ingredients plus 2% mequinol has been shown to lighten lesions.

Early lesions of lentigo maligna (melanoma in situ) may be light to medium brown and may mimic solar lentigines. When in doubt, a biopsy is appropriate. Lentigo maligna, benign solar lentigo, and pigmented actinic keratosis all occur on sun-damaged skin, and collision lesions are common. If a lesion is not homogeneous clinically, representative biopsies should be taken from each color or shade of brown within the lesion.

### PUVA lentigines

Individuals receiving oral methoxsalen photochemotherapy (psoralen plus ultraviolet A, PUVA), may develop persistent pigmented macules with possible melanocytic atypia. These



**Fig. 30-2** Vulvar melanosis.

lesions may occur on sites that are normally protected from sunlight. High-dose single exposures to radiation may result in similar radiation lentigines in exposed skin.

### Ink spot lentigo (sunburn lentigo)

Sunburn lentigines typically occur on the shoulders as small, extremely irregular, reticulated, dark-gray to black macules resembling spots of ink on the skin. Histologically, there is a mild increase in the number of melanocytes and increased melanin in both the basilar keratinocytes and the stratum corneum.

### Labial, penile, and vulvar melanosis (melanotic macules, mucosal lentigines)

Melanotic macules are usually light brown on the oral labial mucosa but may be strikingly irregular and darkly pigmented in the genitalia. In females, the labia minora are most often affected (Fig. 30-2), and in males, the glans and prepuce. Histologically, these lesions demonstrate broad, “boxcar” rete ridges with prominent basilar hyperpigmentation and a normal to slightly increased number of melanocytes. The melanocytes are usually morphologically normal.

### Multiple lentigines syndrome

The lesions appear shortly after birth and develop a distinctive speckled appearance that has given rise to the designation LEOPARD syndrome. LEOPARD is Gorlin’s mnemonic acronym for lentigines, electrocardiographic abnormalities, ocular hypertelorism, pulmonary stenosis, abnormalities of genitalia, retardation of growth, and deafness. Inheritance is autosomal dominant. Multiple lentigines occur mainly on the trunk, but other areas may also be involved, such as the palms and soles, buccal mucosa, genitalia, and scalp. *PTPN11* gene mutations are seen in both LEOPARD syndrome and Noonan syndrome. Café noir spots noted in these patients are larger and darker than café au lait spots. Histologically, some are melanocytic nevi, whereas others demonstrate histologic features of lentigo simplex.



## Moynahan syndrome

Moynahan syndrome consists of multiple lentigines, congenital mitral stenosis, dwarfism, genital hypoplasia, and mental deficiency.

## Generalized lentiginosis

An occasional patient will have generalized lentiginosis without associated abnormalities.

## Centrofacial lentiginosis

Centrofacial lentiginosis is characterized by lentigines on the nose and adjacent cheeks, variously associated with status dysraphicus, multiple skeletal anomalies, and central nervous system (CNS) disorders. Mucous membranes are spared. Onset is in the first years of life. Lentigines of the central face are also typical of Carney complex.

## Carney complex

Carney complex is also known as NAME syndrome and LAMB syndrome. This designation comprises cardiocutaneous myxomas, lentigines, blue nevi, and endocrine abnormalities. It is discussed in more detail with myxomas in Chapter 28.

## Inherited patterned lentiginosis in black persons

O'Neill and James reported 10 light-complexioned black patients with autosomal dominant lentigines beginning in infancy or early childhood, but no internal abnormalities (Fig. 30-3). The lentigines were distributed over the central face and lips, with variable involvement of the dorsal hands and feet, elbows, and buttocks. The mucous membranes were spared.

## Partial unilateral lentiginosis

Partial unilateral lentiginosis is a rare disorder of cutaneous pigmentation characterized by the presence of multiple simple lentigines, wholly or partially involving half the body. Conjunctival involvement has been reported. Agminated lentiginosis appears to be a similar if not identical entity.

## Peutz-Jeghers syndrome

Peutz-Jeghers syndrome is an autosomal dominant syndrome consisting of pigmented macules on the lips, oral mucosa, and

perioral and acral areas. Gastrointestinal polyps, especially prominent in the jejunum, are frequently associated. It is discussed further in Chapter 36.

**Bujaldón AR:** LEOPARD syndrome: what are café noir spots? *Pediatr Dermatol* 2008; 25(4):444–448.

**Piérard-Franchimont C, et al:** Analytic quantification of the bleaching effect of a 4-hydroxyanisole-tretinoin combination on actinic lentigines. *J Drugs Dermatol* 2008; 7(9):873–878.

**Raziee M, et al:** Efficacy and safety of cryotherapy vs. trichloroacetic acid in the treatment of solar lentigo. *J Eur Acad Dermatol Venereol* 2008; 22(3):316–319.

**Sadighha A, et al:** Efficacy and adverse effects of Q-switched ruby laser on solar lentigines: a prospective study of 91 patients with Fitzpatrick skin type II, III, and IV. *Dermatol Surg* 2008; 34(11):1465–1468.

**Trafeli JP, et al:** Use of a long-pulse alexandrite laser in the treatment of superficial pigmented lesions. *Dermatol Surg* 2007; 33(12):1477–1482.

## Becker nevus

Becker nevus presents as a hyperpigmented, hypertrichotic patch on the upper trunk (Fig. 30-4) or proximal upper extremity. The lesion usually begins before puberty, and almost all patients are males. The lesion is typically associated with a smooth muscle hamartoma histologically. Usually, the lesion is asymptomatic and of little consequence, but some lesions have also been associated with connective tissue nevus, inflammatory linear verrucous epidermal nevus, basal cell carcinoma (BCC), phakomatosis pigmentovascularis, or abnormalities of underlying bone or of vascular, neural, or other soft tissue structures (Becker nevus syndrome). The pathogenesis may be related to increased expression of androgen receptors within lesional skin. Treatment may not be necessary, but some patients desire removal of pigment or terminal hair associated with the lesion. Ablative 10,600-nm fractional laser therapy has been used with partial success. Topical flutamide has also been used.

**Dasegowda SB, et al:** Becker's nevus syndrome. *Indian J Dermatol* 2014; 59(4):421.

**Meesters AA, et al:** Ablative fractional laser therapy as treatment for Becker nevus: a randomized controlled pilot study. *J Am Acad Dermatol* 2011; 65(6):1173–1179.

**Patrizi A, et al:** Clinical characteristics of Becker's nevus in children: report of 118 cases from Italy. *Pediatr Dermatol* 2012; 29(5):571–574.

**Taheri A, et al:** Treatment of Becker nevus with topical flutamide. *J Am Acad Dermatol* 2013; 69(3):e147–e148.

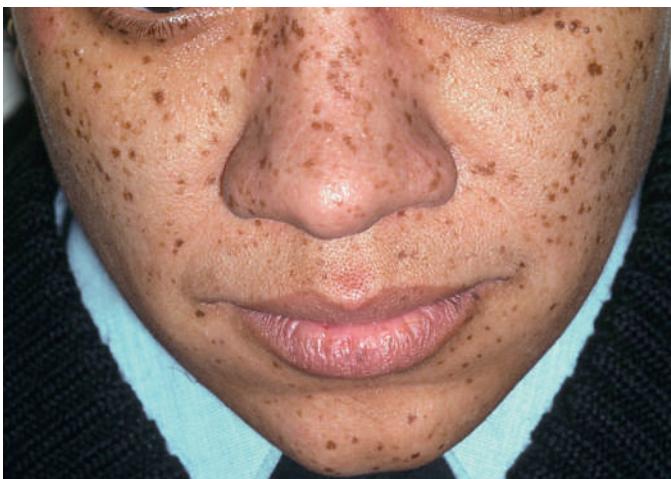


Fig. 30-3 Inherited patterned lentiginosis.

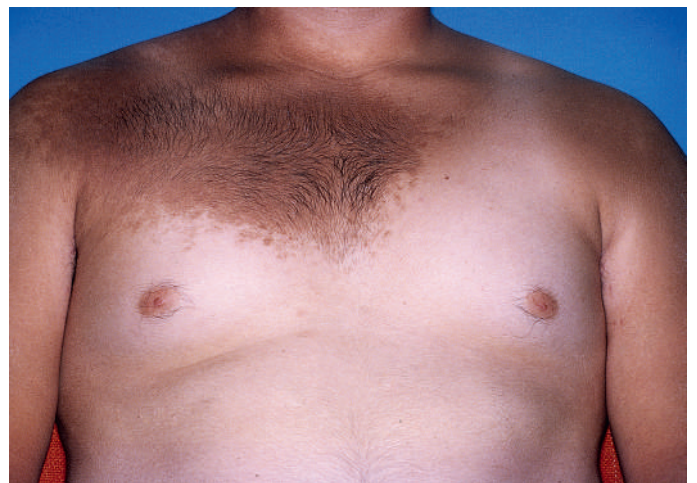
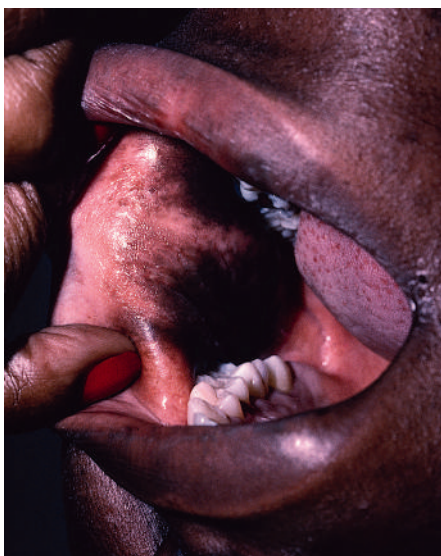
Fig. 30-4 Becker nevus.



**Fig. 30-5**  
Melanoacanthoma.

## MELANOACANTHOMA

Cutaneous melanoacanthoma is an uncommon lesion first described by Bloch. Clinically, it resembles a pigmented seborrheic keratosis or pigmented BCC and tends to occur in older white men. Histologically, it is a benign epidermal neoplasm composed of keratinocytes and dendritic melanocytes. It is best considered a form of seborrheic keratosis. The starburst dermatoscopic appearance can be confused with that of Spitz nevus. Grouped and ulcerated lesions rarely occur.

Oral melanoacanthoma is also a proliferation of two cell types, melanocytes and epithelial cells, but appears to be a reactive lesion. It occurs as a macular or slightly raised pigmented area on the buccal mucosa, predominantly in young adult black women (Fig. 30-5). Rapid onset and spontaneous resolution are typical.

**Geetha T, et al:** Bilateral oral melanoacanthoma in an Indian boy. *Indian J Dermatol Venereol Leprol* 2011; 77(2):210–212.

**Jain S, et al:** Multifocal cutaneous melanoacanthoma with ulceration: a case report with review of literature. *Indian J Dermatol Venereol Leprol* 2011; 77(6):699–702.

## BENIGN MELANOCYTIC NEVI

Common moles, also known as nevocytic nevi or banal nevi, tend to increase in number during the first three decades of life. They are less common in doubly covered areas, such as the buttocks. They typically begin as sharply defined macular lesions, become papular, then gradually become soft and lose their pigment.

Sun exposure increases the number of moles in the exposed skin. Australians have more moles than Europeans. White persons have more than black persons, and individuals with a light complexion have more nevi than those with a dark complexion. Women have more total nevi and more nevi on the legs. Men have more on the trunk. Black persons have more nevi on the palms, soles, conjunctivae, and nail beds. A study of young British women showed an association of holidays overseas with an increased nevus count. The association was greatest in anatomic sites intermittently exposed to sunlight.

Eruptive nevi may occur in association with bullous diseases, severe sunburn, immunosuppression, or sulfur mustard gas exposure. The cheetah phenotype refers to patients with more than 100 uniform, dark-brown to black pigmented macules 4 mm or smaller. The evaluation of these patients can

be challenging, because similar-appearing lesions range from junctional nevi to melanoma histologically.

Melanocytic lesions with a junctional component are more often removed during the summer months, whereas excision of intradermal nevi is relatively constant during the year. This suggests that some change in these lesions draws more attention during the summer months. Nevi may darken during pregnancy, but other changes should prompt consideration of a biopsy.

## Clinical and histologic features

Features of benign nevi include a diameter of 6 mm or less, perfectly uniform pigmentation, flaccid epidermis, smooth, uniform border, and an unchanging size and color. Benign nevi tend to be round to oval and undergo a predictable course of maturation.

Junctional nevi are sharply circumscribed brown macules, varying in diameter from 1 to 6 mm. They usually appear between 3 and 18 years of age. During adolescence and adulthood, some become compound or intradermal. Small, well-nested junctional melanocytic proliferations are almost invariably benign. Benign junctional nevi associated with bulbous hyperplasia of the rete ridges are referred to as junctional lentiginous nevi. Lentigo maligna can appear well nested with an appearance similar to that of junctional lentiginous nevi. Any broad junctional melanocytic lesion on sun-damaged skin should be viewed with suspicion.

Compound nevi demonstrate both junctional and intradermal melanocytes. Benign compound nevi are well nested at the junction, with dispersion of individual melanocytes at the base of the lesion. They demonstrate bilateral symmetry but are not symmetric from top to bottom. Instead, with descent into the dermis, the melanocytes become smaller and spindle in appearance. Nests at the junction tend to be round to oval and are about equidistant from one another. Dermal nests are generally smaller than the junctional nests and become progressively smaller deeper in the dermis. Individual cells rather than nests are present at the base. Pigment is most prominent at the junction and becomes progressively less prominent deeper in the dermis. Intradermal nevi look similar to compound nevi, without the junctional nests.

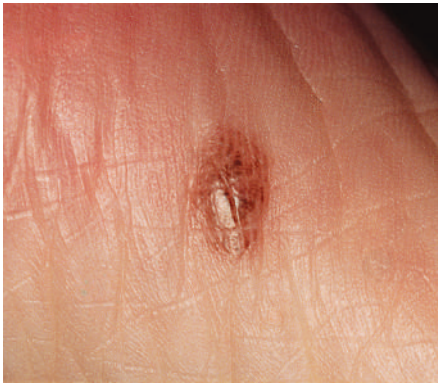
In most benign nevi, there are no melanocytes above the DEJ. Individual melanocytes in a “buckshot” scatter throughout the epidermis are typical of superficial spreading melanoma. Sunburned benign nevi may also demonstrate buckshot intraepidermal scatter of melanocytes, and buckshot scatter may be seen in the central portion of acral nevi and Spitz nevi. Genital nevi often demonstrate large, poorly cohesive nests. They may also resemble dysplastic nevi histologically. A histologic resemblance to dysplastic nevi is also common in nevi from the scalp, ears, dorsal foot, and breast, even in patients with no other evidence of the dysplastic nevus syndrome.

On the palms and soles, the rete pattern follows the dermatoglyphs (Fig. 30-6). Nests in these locations tend to run along the rete ridges. If a benign palmar nevus is bisected across the dermatoglyphs, the nests will appear round to oval. If the same lesion is sectioned parallel to the dermatoglyphs, the nests will appear elongated and may mimic those of melanoma as an artifact of sectioning. Careful communication with the pathologist is essential when submitting an acral melanocytic lesion to the laboratory.

## Malignant degeneration

Almost half of melanomas occur in preexisting nevi, and an increased number of nevi represents a risk factor for





**Fig. 30-6** Acral nevus.

melanoma. The signs of malignant transformation in pigmented nevi are recent enlargement, an irregular or scalloped border, asymmetry, changes or variegation in color (especially red, white, or blue), surface changes (scaling, erosion, oozing, crusting, ulceration, or bleeding), development of a palpable thickening, signs of inflammation, or the appearance of satellite pigmentation. Symptoms may include development of pain, itch, or tenderness. The “ugly duckling” sign refers to nevi in an individual generally tending to share a similar appearance. Any mole that does not share the same characteristics should be considered for biopsy. Moles with dark areas that do not lie entirely within the lesion, but produce an extension beyond the border, may represent melanoma arising in association with a preexisting nevus. The clinician should alert the pathologist to the presence of these areas and the pathologist should section through the appropriate area. Perifollicular hypopigmentation is a common finding in benign nevi. When it occurs at the edge of the nevus, it may give the lesion a notched appearance. Dermatoscopic examination may be of value in this setting. Lesions with changing clinical or dermatoscopic features should be biopsied.

Nevi frequently darken with pregnancy or with oral contraceptive use. Nevi from normal persons have no estrogen or progesterone receptors, but there may be positive estrogen receptor binding in nevi from pregnant women, as is also found in malignant melanoma. The development of what appears to be a new pigmented nevus in a patient over age 35 should alert the physician to possible melanoma, because patients without the dysplastic nevus syndrome usually do not develop new nevi at this age.

## Treatment

Acquired nevi should be removed if they show signs of malignant transformation. Nevi of the neckline, beltline, or other areas that are irritated may be removed to relieve the patient of the irritation. Nevi may also be removed if they are in a location where it is impractical to observe them. If a solitary, darkly pigmented lesion is present on the oral or genital mucous membrane, a biopsy should be performed, because nevi are uncommon in these locations. Nail matrix nevi and lentiginos produce a pigmented nail band. The proximal matrix gives rise to the dorsal nail plate, and the distal matrix gives rise to the ventral nail plate. When the nail is observed end-on, the level of the pigment may be evident and indicates the location of the pigmented lesion in the matrix. A widening band indicates a matrix lesion increasing in diameter. Biopsy of a solitary, expanding, acquired longitudinal pigmented band in an adult is typically necessary to ascertain the cause. Hutchinson’s sign (pigmentation of the nailfold) is an

indicator of melanoma. Nail matrix melanoma in children is exceptional.

Conjunctival nevi occur, and most can be followed serially if the lesion has been present since childhood or has shown no evidence of growth. Changing pigmented lesions and those acquired after childhood are best evaluated in conjunction with an ophthalmologist. Most conjunctival nevi occur on the bulbar conjunctiva and often about the nasal or temporal corneoscleral limbus. Suspicion of melanoma should arise if a pigmented lesion occurs in the palpebral or forniceal conjunctiva, if lesions are not hinged at the limbus and are immovable, if they extend into the cornea, if there is canalicular obstruction that leads to tearing, or if adjacent dilated vessels are noted.

Combined melanocytic nevi are common. They consist of a banal nevus together with a blue nevus, Spitz nevus, or deep penetrating nevus. Two or more distinct populations of melanocytes are evident.

Melanocytic nevi may occur in lymph nodes and are present in about 10% of sentinel node biopsies. Nodal nevi typically occur in the capsule, in contrast to melanoma metastases, which are typically subcapsular. Nodal nevi are frequently associated with cutaneous nevi in the draining basin, especially nevi with congenital features.

**Barnhill RL, et al:** State of the art, nomenclature, and points of consensus and controversy concerning benign melanocytic lesions: outcome of an international workshop. *Adv Anat Pathol* 2010; 17(2):73–90.

**Choi JW, et al:** Differentiation of benign pigmented skin lesions with the aid of computer image analysis: a novel approach. *Ann Dermatol* 2013; 25(3):340–347.

**Fernandes NC:** The risk of cutaneous melanoma in melanocytic nevi. *An Bras Dermatol* 2013; 88(2):314–315.

**Flores A:** Eponyms, morphology, and pathogenesis of some less mentioned types of melanocytic nevi. *Am J Dermatopathol* 2012; 34(6):607–618.

## Pseudomelanoma (recurrent nevus)

Melanotic lesions clinically resembling a superficial spreading melanoma may occur at the site of a recent shave removal of a melanocytic nevus. Melanocytic nevi occurring in areas of lichen sclerosis or bullous disease often have similar features. On dermatoscopic examination, a regular network and the presence of streaks suggest reactive pigmentation. Any truly suspicious lesion should be removed. Histologically, the junctional component often demonstrates a predominance of non-nested melanocytes, confluence of nests, and nests that vary in size and shape. The presence of a superficial dermal scar with remnants of the original nevus beneath this zone of fibrosis is an important clue to the correct diagnosis. Although atypical in appearance, the junctional proliferation remains entirely confined to the area overlying the scar.

Recurrent Spitz nevus is a particular problem because many of the histologic features of benign Spitz nevi overlap with those of melanoma. In benign recurrent Spitz nevi, the dermal component typically retains cytologic maturation, dispersion at the base of the lesion, and an immunostaining pattern typical for benign nevi. Recurrent blue nevi also present special difficulties. High cellularity, cellular pleomorphism, mitotic figures, and a lymphoid host response may be present. In the absence of marked cytologic atypia, frequent mitotic figures or necrosis en masse, the lesions are likely to be benign. Because of the special problems posed by recurrent Spitz and blue nevi, the initial biopsy of these lesions should be a complete excisional biopsy whenever possible. Congenital nevi have a higher rate of recurrence when surgery is done at a younger age.

**Botella-Estrada R, et al:** Clinical, dermoscopy and histological correlation study of melanotic pigmentations in excision scars of melanocytic tumours. *Br J Dermatol* 2006; 154(3):478–484.

**Mérigou D, et al:** Management of congenital nevi at a dermatologic surgical paediatric outpatient clinic: consequences of an audit survey 1990–1997. *Dermatology* 2009; 218(2):126–133.

## Balloon cell nevus

Clinically, balloon cell nevi are indistinguishable from ordinary nevi. Histologically, they are composed of large, pale, polyhedral balloon cells. Generally, foci of ordinary nevus cells are also evident. Rarely, the lesions are composed entirely of balloon cells. Balloon cell change has been reported in cellular blue nevus as well. Balloon cell melanoma does exist, but the nuclei are large and pleomorphic, and the architecture of the lesion is that of melanoma. Balloon cell nodal nevi may be seen in sentinel node specimens.

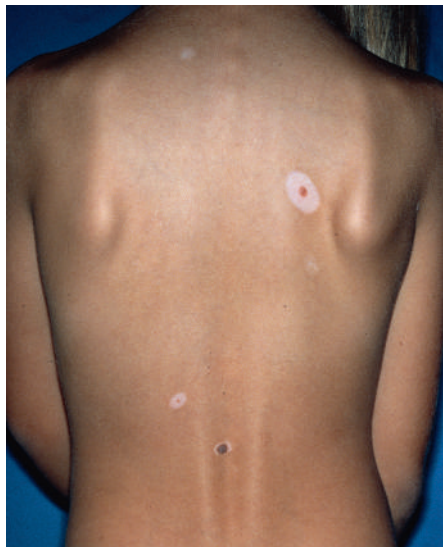**Cagnano E, et al:** Compound nevus with congenital features and balloon cell changes: an immunohistochemical study. *Ann Diagn Pathol* 2008; 12(5):362–364.

**Urso C:** Nodal melanocytic nevus with balloon-cell change (nodal balloon-cell nevus). *J Cutan Pathol* 2008; 35(7):672–676.

## Halo nevus

Halo nevus is also known as Sutton nevus, perinevoid vitiligo, and leukoderma acquisitum centrifugum. The lesions are characterized by a pigmented nevus with a surrounding depigmented zone (Fig. 30-7). Halo nevi tend to be multiple and occur most frequently on the trunk, mostly in teenagers. The central nevus gradually loses its pigmentation, turns pink, and then disappears, leaving a round to oval area of depigmentation. Over time, the area repigments. Darkening of the central nevus rather than lightening has also been reported in association with the halo phenomenon. Halo nevi have been reported during infliximab therapy. Targetlike pigmented nevi present with the appearance of an inverse halo nevus phenomenon.

The infiltrate contains many cytotoxic T cells and may represent immunologically induced rejection. The peripheral blood has been shown to contain activated adhesive lymphocytes that disappear when the lesion is excised. Patients also demonstrate antibodies to melanocytes and cell-mediated



**Fig. 30-7** Halo nevus.

immunity to melanoma cells. There may be associated vitiligo.

Regressing melanoma may also have associated leukoderma, but the pattern is usually haphazard and confined to the pigmented lesion. Other lesions that may also have a surrounding zone of leukoderma include blue nevi and neurofibromas.

Histologically, halo nevi demonstrate a band of lymphocytes that extends throughout the lesion, intimately mingling with the melanocytes. In contrast, the lymphoid infiltrate associated with melanoma tends to aggregate at the periphery of the lesion. In early halo nevi, amelanotic melanocytes may be found in the leukodermic halo. Later, melanocytes are absent until repigmentation occurs. A granulomatous infiltrate may rarely be present. The term Myerson's nevus has been applied to eczematous change associated with a nevus. Hypopigmentation may be present.

A full mucocutaneous examination at diagnosis is indicated to exclude a concurrent melanoma, but this is rarely found. The decision to remove the nevus at the center of the halo is based on its morphologic features, as with any other nevus.

**Denianke KS, et al:** Granulomatous inflammation in nevi undergoing regression (halo phenomenon): a report of 6 cases. *Am J Dermatopathol* 2008; 30(3):233–235.

**Loh J:** Meyerson phenomenon. *J Cutan Med Surg* 2010; 14(1):30–32.

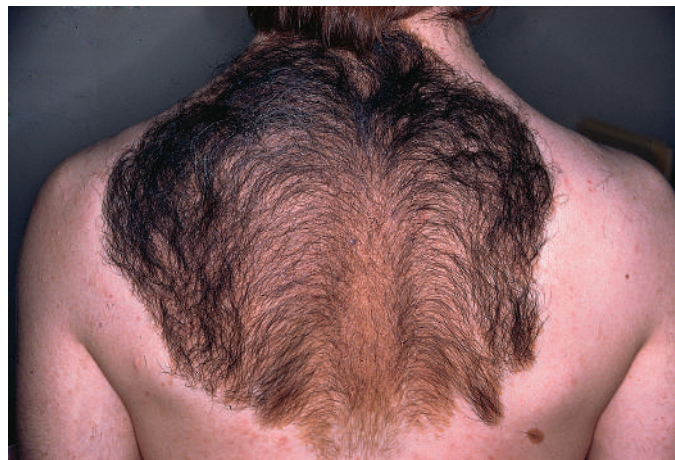**Nashan D, et al:** Multiple target-like pigmented nevi: an inverse halo-nevus phenomenon. *J Eur Acad Dermatol Venereol* 2010; 24(1):104–105.

## Congenital melanocytic nevus

### Giant pigmented nevus (giant hairy nevus, bathing trunk nevus)

Giant pigmented nevi appear as large, darkly pigmented hairy patches in which smaller, darker patches may be interspersed or present as small satellite lesions. The skin may be thickened and verrucous. The trunk is a favored site, especially the upper or lower parts of the back (Fig. 30-8). Giant hairy nevi are present at birth and grow proportionally with the body. Widespread congenital dermal nevus with large nodules may affect the entire body, including the palms, soles, and oral mucous membrane. Some congenital melanocytic nevi have associated placental infiltration by benign melanocytes.

The incidence of melanomas developing in giant congenital pigmented nevi is between 2% and 15%. Approximately 60%



**Fig. 30-8** Giant hairy nevus.



of these melanomas appear within the first decade of life, and the majority arise in the dermis or subjacent tissue, rather than at the DEJ. About 40% of the malignant melanomas seen in children occur in large congenital nevi. The risk is greatest for axial lesions and those larger than 40 cm. In one study, 94% of large congenital nevi that gave rise to melanoma had satellite nevi.

Large axial lesions may be associated with neurocutaneous melanocytosis. The risk is greatest for large axial lesions with many satellite lesions, and almost half of patients with symptomatic neurocutaneous melanosis develop leptomeningeal melanoma. Neurocutaneous melanosis can be detected by magnetic resonance imaging (MRI).

Histologically, giant congenital nevi extend into the deep dermis and may involve the subcutis, fascia, muscle, and other underlying structures. Nevus cells are found in a patchy perivascular distribution and often extend in a patchy, single-file fashion between collagen bundles. Nests are often seen in association with adnexal structures or nerves. Extensive desmoplasia has been described. Estrogen and progesterone binding has been noted in congenital nevi. These receptors are generally absent from common acquired nevi.

Benign “proliferative” nodules within giant congenital nevi may be confused histologically with malignant change. Features useful in distinguishing the two include lack of high-grade atypia, lack of necrosis, rarity of mitoses, a lack of Ki-67 expression, evidence of transition between the cells of the nodule and those of the adjacent nevus, and lack of compressive expansile growth. Comparative genomic hybridization has demonstrated chromosomal aberrations in atypical nodular proliferations in congenital nevi, but many of these are numerical aberrations of whole chromosomes, suggesting a mitotic spindle defect. These differ from the chromosomal aberrations seen in melanoma.

Treatment decisions must be individualized. Half of all melanomas in giant congenital nevi occur in deep structures. Extensive surgery to remove the upper portions of the lesion reduces, but does not eliminate, the risk of melanoma. In patients with leptomeningeal melanosis, the risk of melanoma remains high. Satellite lesions and extremity lesions have a lower incidence of neoplastic conversion than large axial lesions, and the risk-benefit ratio of extensive surgery on these lesions differs accordingly. Some lesions are not amenable to excision because they involve functionally critical areas.

Serial excision is the method of choice whenever possible. Tissue expansion, cultured autologous cultured skin substitutes, and flap closure are especially useful in the head and neck region. Alternative approaches to treatment, such as dermabrasion, curettage, carbon dioxide (CO<sub>2</sub>) laser ablation or treatment with QS Nd:YAG, ruby, and alexandrite lasers can lead to improvement in appearance. Therapy may also eliminate some nevus cells, with theoretic lowering of the melanoma risk. It is important to emphasize that most melanomas in giant congenital nevi occur in the dermal component rather than at the DEJ. Any treatment that alters the surface may alter detection of deep melanoma. Malignant transformation has been reported 20 years after dermabrasion. Regardless of the method of choice, lifelong periodic cutaneous examination and general medical evaluation are indicated.

### Small and medium-sized congenital nevocytic nevus

Small, congenital nevocytic nevi are generally defined as less than 2 cm in greatest diameter, and medium-sized lesions measure more than 2 cm but less than 20 cm. They are found in about 1% of newborns. About half eventually become hairy. Histologically, they share many features with giant congenital nevi but usually do not extend into the subcutaneous tissue.

Many of the histologic features associated with congenital nevi also occur in acquired nevi. The risk of melanoma in small to medium-sized congenital nevi is extremely low; it may be no greater or only slightly greater than the risk of melanoma arising in ordinary acquired nevi. One important difference is that malignant degeneration may occur in the deep dermal component of small congenital nevi, rather than at the DEJ. Most of the melanomas that do occur do so after puberty. Excision is recommended for changing lesions and may be considered for those of cosmetic concern and in areas difficult to observe.

**Green MC, et al:** Management considerations for giant congenital melanocytic nevi in adults. *Mil Med* 2014; 179(4):e463–e465.

**Ibrahimi OA, et al:** Congenital melanocytic nevi: where are we now? Part II. Treatment options and approach to treatment. *J Am Acad Dermatol* 2012; 67(4):515.e1–e13.

**Kovalyshyn I, et al:** Congenital melanocytic naevi. *Australas J Dermatol* 2009; 50(4):231–240.

**Krengel S, et al:** New recommendations for the categorization of cutaneous features of congenital melanocytic nevi. *J Am Acad Dermatol* 2013; 68(3):441–451.

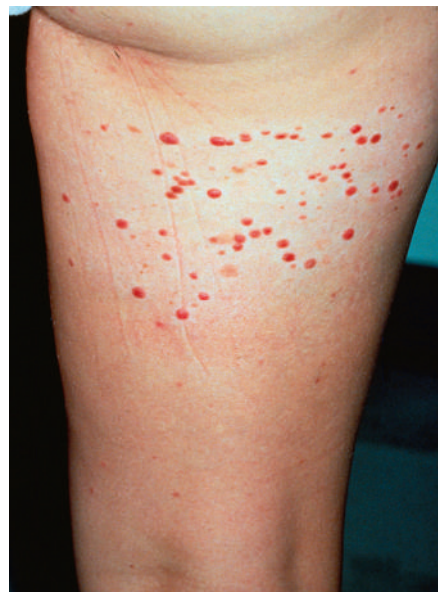**Margulis A, et al:** Congenital melanocytic nevi of the eyelids and periorbital region. *Plast Reconstr Surg* 2009; 124(4):1273–1283.

**Vourc’h-Jourdain M, et al:** Large congenital melanocytic nevi: therapeutic management and melanoma risk—a systematic review. *J Am Acad Dermatol* 2013; 68(3):493–498.e1–e14.

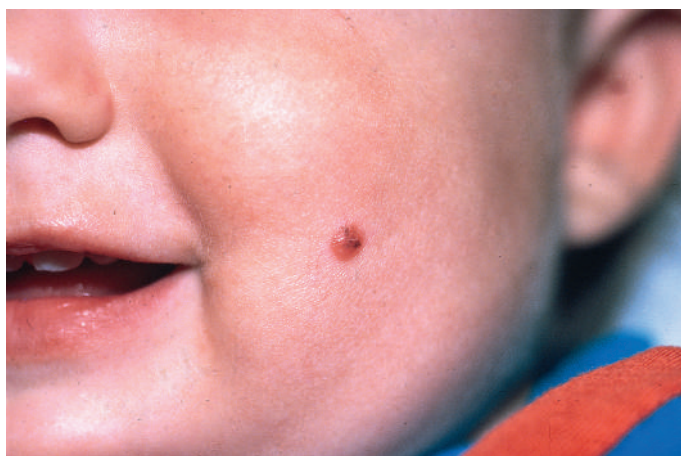### Spindle and epithelioid cell nevus (Spitz nevus)

Spitz nevi typically appear as pink, smooth-surfaced, raised, round, firm papules. Most frequently, Spitz nevi occur during the first two decades of life, although they occur in adulthood in about one third of cases. Infrequently, multiple lesions present as agminate (clustered) (Fig. 30-9) or disseminated lesions in children and adults. Although they usually contain no visible pigment, some lesions are pigmented. Occasionally, Spitz nevi can be blue-black in color (Fig. 30-10). A starburst pattern is characteristic on dermatoscopic examination. Although dermoscopy and confocal microscopy are being used in this setting, both false-positive and false-negative studies occur, and histologic examination remains the “gold standard” for evaluation of suspicious lesions.

As with other nevi, Spitz nevi may be junctional, compound, or intradermal. Compound nevi are most common and are



**Fig. 30-9** Agminated Spitz nevi. (Courtesy of Brooke Army Medical Center Teaching File.)



**Fig. 30-10** Spitz nevus. (Courtesy of Brooke Army Medical Center Teaching File.)

characterized by compact hyperkeratosis, hypergranulosis, and pseudoepitheliomatous hyperplasia. The cells are large, with round to spindled nuclei. Epithelioid cells have large vesicular nuclei with prominent nucleoli and ample pink cytoplasm. Adjacent to the nucleus, the cytoplasm typically has a more amphophilic hue, giving it a characteristic two-tone appearance, similar to the cytoplasm of the cells in reticulohistiocytic granuloma. The nests tend to be oval and oriented in a vertical direction, as are the nuclei within the nests, so that they appear to be “raining down” the adjacent rete ridges. Clefts are typically present adjacent to some of the nests, and superficial vascular ectasia is characteristic. Dull-pink globules (Kamino bodies) are seen within the epidermis. These represent trapped basement membrane zone material and stain similar to collagen with a trichrome stain as well as with immunostains for type IV collagen. Buckshot scatter of melanocytes may be noted within the epidermis overlying the center of the lesion, but the lesion is sharply circumscribed, and cells disperse as individual units between collagen bundles at the base of the lesion. Rosettelike structures may occur. In a review of 349 Spitz nevi, the presence of epithelioid and spindled cells was the only feature present in 100% of cases. Other findings, in descending order, included maturation (72%), inflammatory infiltrate (70%), epidermal hyperplasia (66%), melanin (50%), telangiectasias (40%), Kamino bodies (34%), desmoplastic stroma (26%), mitosis (23%), pagetoid extension (13%), and hyalinization of the stroma (8%).

Melanomas may have many of the previous features, but generally lack Kamino bodies, and often demonstrate broad lateral extension, deep mitoses, and large nests at the base of the lesion. In questionable cases, adjunctive studies may be of value. S-100A6 shows strong and diffuse expression in Spitz nevi. Other melanocytic nevi often express S-100A6 weakly or not at all. Melanomas may express S-100A6, but the expression tends to be weak and patchy in the dermal component and is often negative in the junctional component. HMB-45 typically stains Spitz nevi in a top-heavy fashion, while melanomas stain uniformly top to bottom. MIB-1 (Ki-67), a proliferation marker, may also be helpful as an adjunct to the histopathologic diagnosis of Spitz nevi. MIB-1-positive nuclei are rare in the deep portion of a Spitz nevus, whereas they are often numerous in melanoma. Comparative genomic hybridization demonstrates chromosomal aberrations in the majority of melanomas, but most Spitz nevi show no aberrations. A minority of Spitz nevi show an isolated gain of chromosome 11p, the site of *HRAS*, but this aberration is not observed in melanoma. Specific gains or losses can be demonstrated with fluorescent

in situ hybridization (FISH) probes. Studies of the mitogen-activated protein kinase (MAPK) pathway and genomic gains and losses may also prove helpful in this setting.

Junctional Spitz nevi usually show some degree of buckshot scatter of melanocytes and share many histologic features with melanoma. Lesions that lack sharp lateral circumscription are more likely to represent melanoma. Intradermal Spitz nevi lack overlying hyperkeratosis, hypergranulosis, or pseudoepitheliomatous hyperplasia, but the cells disperse as individual units at the deep margin. Dermal spitzoid lesions that remain nested at the deep margin are likely to represent melanoma. Desmoplastic Spitz nevi may be compound or intradermal, and are characterized by a dense, hypocellular collagenous stroma.

Pigmented spindle cell nevus is regarded by many as a variant of Spitz nevus. The lesions tend to be pigmented macules on the legs of young women. The cells are smaller and uniformly spindled, but other histologic features are similar to those of Spitz nevi. In contrast to Spitz nevi, they stain poorly with S-100A6. Desmoplastic Spitz nevi are moderately to strongly positive for p16, whereas most desmoplastic melanomas are negative, but studies have produced conflicting results regarding the usefulness of this antibody. Neuropilin-2 looks promising as an adjunctive study. Both Spitz nevi and spitzoid melanoma have a lower incidence of *BRAF* and *NRAS* mutations than common acquired nevi and conventional melanomas. *HRAS* mutations are typical of Spitz nevi but are rare to absent in spitzoid melanoma. *HRAS*-duplicated Spitz nevi are large, with large nuclei. *BAP1*-mutated nevi (Wiesner nevi) are composed of dermal nests of large epithelioid melanocytes with pleomorphism and lack of maturation, simulating melanoma. Immunoperoxidase staining for *BAP1* is negative, whereas staining for VE1 (V600E) *BRAF* mutation is positive. *BAP1* mutation is associated with the familial uveal melanoma syndrome, which includes large numbers of Wiesner nevi, mesothelioma, and renal cell carcinoma. *BAP1* mutation can also be seen in melanoma, so lack of *BAP1* staining alone is not sufficient to prove that the lesion is benign.

Although new molecular techniques may allow better differentiation, because of the histologic overlap with melanoma, the biopsy technique for suspected Spitz nevi should be complete excision whenever possible. Critical differentiating histologic features include sharp lateral circumscription and dispersion at the base of the lesion. An incomplete excision will fail to demonstrate either the lateral or the deep aspect of the tumor, and these diagnostic features will not be evident. When a lesion is incompletely excised, most authorities recommend reexcision of the site to ensure complete removal. At times, however, the dogma that all Spitz nevi should be completely excised must be tempered in the patient's best interest. An otherwise typical Spitz nevus that extends to the deep margin on a young child's nose may be difficult to excise without disfigurement. The risks of anesthesia must also be weighed against the likelihood that the lesion is anything but a benign Spitz nevus. Data suggest that children and teenagers with atypical spitzoid neoplasms and positive sentinel nodes have a less aggressive clinical course than those with unambiguous melanoma, but this may merely reflect mixed outcomes of benign and malignant lesions that were classified together.

**Busam KJ, et al:** Multiple epithelioid Spitz nevi or tumors with loss of *BAP1* expression: a clue to a hereditary tumor syndrome. *JAMA Dermatol* 2013; 149(3):335–339.

**Diaconeasa A, et al:** Histopathologic features of spitzoid lesions in different age groups. *Rom J Morphol Embryol* 2013; 54(1):51–62.

**Gerami P, et al K:** Risk assessment for atypical spitzoid melanocytic neoplasms using FISH to identify chromosomal copy number aberrations. *Am J Surg Pathol* 2013; 37(5):676–684.



**Hilliard NJ, et al:** p16 Expression differentiates between desmoplastic Spitz nevus and desmoplastic melanoma. *J Cutan Pathol* 2009; 36(7):753–759.

**Lott JP, et al:** Clinical characteristics associated with Spitz nevi and Spitzoid malignant melanomas: The Yale University Spitzoid Neoplasm Repository experience, 1991 to 2008. *J Am Acad Dermatol* 2014; 71(6):1077–1082.

**Luo S, et al:** Spitz nevi and other spitzoid lesions. Part I. Background and diagnoses. *J Am Acad Dermatol* 2011; 65(6):1073–1084.

**Luo S, et al:** Spitz nevi and other spitzoid lesions. Part II. Natural history and management. *J Am Acad Dermatol* 2011; 65(6):1087–1092.

**Marghoob AA:** Practice gaps. Underuse of dermoscopy in assessing Spitz nevi in children : comment on “Spitz nevi: beliefs, behaviors, and experiences of pediatric dermatologists.” *JAMA Dermatol* 2013; 149(3):291–292.

**Mason A, et al:** Expression of p16 alone does not differentiate between Spitz nevi and spitzoid melanoma. *J Cutan Pathol* 2012; 39(12):1062–1074.

**Massi D, et al:** Atypical Spitz tumors in patients younger than 18 years. *J Am Acad Dermatol* 2015; 72(1):37–46.

**Murali R, et al:** Tumours associated with *BAP1* mutations. *Pathology* 2013; 45(2):116–126.

**Requena C, et al:** Spitz nevus: a clinicopathological study of 349 cases. *Am J Dermatopathol* 2009; 31(2):107–116.

**Shahbain H, et al:** Molecular diagnostics for ambiguous melanocytic tumors. *Semin Cutan Med Surg* 2012; 31(4):274–278.

**Witiisuwannakul J, et al:** Neuropilin-2 as a useful marker in the differentiation between spitzoid malignant melanoma and Spitz nevus. *J Am Acad Dermatol* 2013; 68(1):129–137.

**Zalaudek I, et al:** “White” network in Spitz nevi and early melanomas lacking significant pigmentation. *J Am Acad Dermatol* 2013; 69(1):56–60.

## Dysplastic nevus

In 1978, Clark et al. described families with unusual nevi and multiple inherited melanomas, a condition they referred to as the “B-K mole syndrome” (after Family B and Family K). About the same time, Lynch et al. recognized similar findings in other families and designated this the “familial atypical multiple mole–melanoma” (FAMM) syndrome. The most widely accepted term for the marker lesions is dysplastic nevus, with the patient’s condition called the dysplastic nevus syndrome (DNS). The lesions may also be referred to as atypical nevi, Clark’s nevi, or nevi with architectural disorder. Patients with dysplastic nevi who have at least two blood relatives with dysplastic nevi and melanoma have the worst prognosis for development of melanoma. These individuals may have a 100% lifetime risk of melanoma. An associated increased risk of developing pancreatic carcinoma is present in some families. Some studies have indicated that ocular melanomas may occur in these patients.

The genetic basis for familial melanoma is being elucidated. One quarter to one third of patients have germline mutations on chromosome 9p in the *CDKN2A* tumor-suppressor gene (also known as *p16*, *MTS1*, and *p16INK4A*). It encodes for an inhibitor of a cyclin-dependent kinase 4 (CDK4), which functions to suppress proliferation. Patients with mutations that impair the function of the p16 suppressor protein, referred to as the p16M alleles, have a concomitant predisposition to pancreatic cancer. In other families in whom this is not present and who have 16W alleles, the predisposition to melanoma does not correlate with an elevated risk of pancreatic cancer. Mutations in the *CDK4* gene have also been found to be responsible for a lesser number of cases of familial melanomas. The products of this gene interact with the same cell growth cycle process as p16.

Moles with a histology similar to dysplastic nevi also occur frequently in patients without a personal or family history of melanoma, with 5–20% of patients having at least one

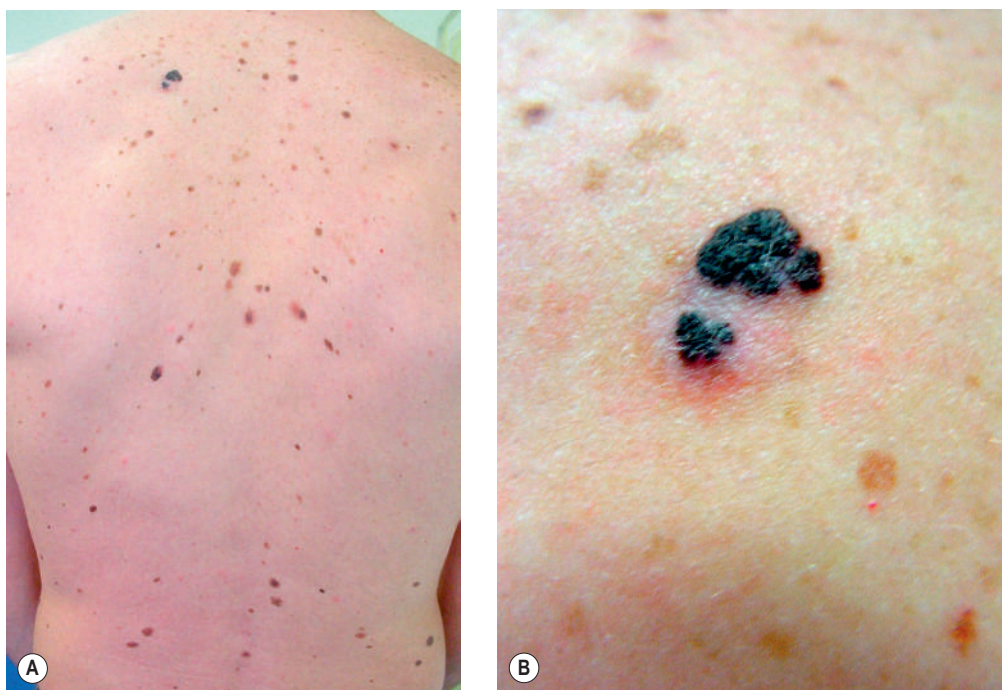
clinically dysplastic nevus, depending on the criteria used. During the growth phase, many nevi demonstrate junctional extension beyond the dermal component. This “shouldering” phenomenon is also one of the criteria for dysplastic nevi, and many growing nevi will have some histologic features of dysplastic nevi. The same is true for many congenital nevi, genital nevi, and those on the breast, dorsal foot, and scalp, none of which appears to be a marker for DNS.

Dysplastic nevi differ from common acquired nevi in several respects. Clinically, dysplastic nevi are characterized by a variegated tan, brown, and pink coloration, with the pink hues seen mainly in the macular portion of the nevus. A macular component is always present and may comprise the entire lesion but frequently surrounds a papular center. The nevi are larger than common nevi, usually 5–12 mm in diameter (common nevi usually measure 6 mm or less). The shape of dysplastic nevi is often irregular, with indistinct borders. Atypical nevi are most often seen on the back (Fig. 30-11), and exposure to sun promotes the development of these lesions in individuals with DNS.

The lesions appear to be precursors for melanoma, as well as serving as a marker for an increased risk of de novo melanoma. Most of the melanomas that occur in these patients will arise in normal-appearing skin. Nuclear minichromosome maintenance protein expression is low in banal nevi (~1%), higher in dysplastic nevi (~6%), and highest in cutaneous melanomas (~50% of cells). Survivin is present in 85.2% of dysplastic nevi. Criteria for histologic diagnosis of dysplastic nevi vary. The U.S. National Institutes for Health (NIH) consensus conference published the following as characteristic histologic features: basilar melanocytic hyperplasia with bulbous elongation of the rete ridges; spindle-shaped or epithelioid melanocytes arranged horizontally and aggregating in nests that fuse with adjacent rete ridges; lamellar and concentric superficial dermal fibrosis; and cytologic atypia (usually present but not essential for diagnosis). In compound dysplastic nevi, the junctional component generally extends at least three rete ridges beyond the dermal component. Grading of atypia is variable from one observer to another. Much of the atypia is focal and localized to the periphery (shoulder region) of the lesion. Atypia that extends throughout the lesion is more significant, and lesions with high-grade atypia may be difficult to distinguish from melanoma. Lesions with the architecture of a dysplastic (Clark) nevus but cytologic features of a Spitz nevus have been referred to as “spark” nevus (Spitz/Clark), “spastic” nevus (Spitz/dysplastic), or “ditz” (dysplastic/Spitz).

When a patient with clinically dysplastic nevi is seen, initial examination should include a total body inspection, including the scalp. A family history should be obtained with special attention paid to items such as moles, skin cancer, and melanoma. In general, excision of individual atypical nevi should be limited to those suspicious for melanoma. There should be prudent sun avoidance and sunscreen use. Patients should be educated in self-examination and encouraged to examine themselves monthly. Physician examination every year is also prudent. Baseline dermatologic photography may aid surveillance examinations. This is particularly helpful for detecting new lesions. Digital epiluminescence microscopic surveillance of atypical nevi may also be of value. Indications for removal of a lesion include an increase in diameter, focal enlargement, radial streaming, peripheral black dots, and clumping within the pigment network. Individual patients often demonstrate a consistent nevus phenotype clinically and on dermatoscopic examination. Lesions that differ from this “signature pattern” should generally be removed for histologic examination.

In patients with dysplastic nevi and a positive family or personal history of melanoma, physician examination every



**Fig. 30-11** A, Dysplastic nevi, “ugly duckling” sign, left shoulder. B, Close-up of left shoulder lesion, superficial spreading melanoma.

3–6 months is recommended, with excision of nevi that change in clinical appearance and new lesions suspicious for melanoma.

Narrow excisional biopsies of dysplastic nevi often fail to remove the subclinical junctional component of the lesion. The pathologist is left to comment on a specimen with melanocytic atypia at a positive margin. When the lesions recur, they often appear atypical both clinically and histologically. Recurrent lesions may easily be misinterpreted as melanoma by someone unfamiliar with the preceding lesion. In general, the most appropriate biopsy technique for a dysplastic nevus is a broad saucerization that extends 0.5–2 mm beyond the clinically evident border of the lesion. After wound contraction, the added margin results in little difference in the appearance of the final scar, and the risk of a recurrent lesion is much lower. Especially on the upper shoulders and limb girdle area, saucerized biopsies often result in scars with a better appearance than those produced by suture closure. When faced with a positive lateral margin, it is best to reexcise lesions with significant atypia. The reexcision may take the form of a wider saucerization. Data suggest that the risk of recurrence of a low-grade dysplastic nevus approaching a margin is low. When a lesion with low-grade atypia extends to a lateral margin, it is reasonable to observe the lesion for signs of recurrence.

**Duffy K, et al:** The dysplastic nevus: from historical perspective to management in the modern era. Part I. Historical, histologic, and clinical aspects. *J Am Acad Dermatol* 2012; 67(1):1.e1–e16.

**Duffy K, et al:** The dysplastic nevus: from historical perspective to management in the modern era. Part II. Molecular aspects and clinical management. *J Am Acad Dermatol* 2012; 67(1):19.e1–e12.

**Elston D, et al:** Histologically dysplastic nevi that extend to a specimen border. *J Am Acad Dermatol* 2013; 68(4):682–683.

**Hocker TL, et al:** Favorable long-term outcomes in patients with histologically dysplastic nevi that approach a specimen border. *J Am Acad Dermatol* 2013; 68(4):545–551.

**Moloney FJ, et al:** Detection of primary melanoma in individuals at extreme high risk: a prospective 5-year follow-up study. *JAMA Dermatol* 2014; 150(8):819–827.

**Reddy KK, et al:** Atypical (dysplastic) nevi: outcomes of surgical excision and association with melanoma. *JAMA Dermatol* 2013; 149(8):928–934.

**Strazzula L, et al:** The utility of re-excising mildly and moderately dysplastic nevi: a retrospective analysis. *J Am Acad Dermatol* 2014; 71(6):1071–1076.

### Epidermolysis bullosa–associated nevus

Patients with epidermolysis bullosa (EB) may develop eruptive nevi and large, acquired melanocytic nevi with a clinical and dermoscopic appearance that resembles melanoma. Long-term follow-up suggests benign behavior. Biopsy findings with EB-associated nevus can be similar to those of a persistent/recurrent nevus.

**Cash SH, et al:** Epidermolysis bullosa nevus: an exception to the clinical and dermoscopic criteria for melanoma. *Arch Dermatol* 2007; 143(9):1164–1167.

**Lattouf C, et al:** Epidermolysis bullosa simplex, Dowling-Meara type with eruptive nevi. *Int J Dermatol* 2012; 51(9):1094–1096.

### MELANOMA (MALIGNANT MELANOMA)

Except in the setting of giant congenital nevi, melanomas typically originate from melanocytes at the DEJ. Almost half will develop in preexisting nevi, but the rest will develop on previously normal-appearing skin. Usually, there is a prolonged, noninvasive, radially oriented growth phase in which the lesion enlarges asymmetrically. Eventually, a tumor nodule develops, reflecting a vertical growth phase. Although the presence of a vertical growth phase may represent an independent risk factor for metastasis, the single greatest risk factor is the depth of invasion.

The “ABCD” criteria for melanoma are imperfect but are simple for lay individuals to understand and have proved helpful for the detection of melanoma. The letters stand for asymmetry, border irregularity, color variegation, and a large diameter (>6 mm). Epiluminescence microscopy is a noninvasive technique for examining pigmented lesions that makes subsurface structures visible. In the hands of experienced users, it can be a helpful technique.



The incidence of melanoma has increased in light-skinned people. Melanoma is not usually encountered in the darker races, and acral lesions account for a greater share of melanomas in dark-skinned individuals. The lowest incidence is found among Asians. The incidence of melanoma is low until after puberty. Children rarely manifest congenital or acquired melanoma. Congenital melanoma may occur because of transplacental transmission from an affected mother, as a primary intrauterine lesion, as a melanoma that occurs on a congenital nevus in utero, or as prenatal metastatic lesions from neurocutaneous melanosis. All these have a poor prognosis. In children, melanomas occur at least half the time from preexisting normal skin, where the clues to diagnosis are the same as in adults, but recognition is often delayed because of the overall low incidence in the pediatric population. Melanomas may also develop in preexisting nevi, most importantly deep within giant congenital nevi.

During pregnancy, pigmented nevi often become uniformly darker and may enlarge symmetrically. Estrogen and progesterone receptors develop on the melanocytes, and these changes are likely to be hormonally induced. If, however, changes occur that would normally incite worry about melanoma, such as irregular pigmentation or asymmetric growth, a biopsy should be performed. Women who develop melanoma during pregnancy have a shorter disease-free interval after excision; however, there is no adverse survival effect.

### Etiologic factors

A light complexion, light eyes, blond or red hair, the occurrence of blistering sunburns in childhood, heavy freckling, and a tendency to tan poorly and sunburn easily indicate increased risk for melanoma. Large numbers of common nevi, the presence of large nevi, and the presence of clinically dysplastic lesions all increase the risk of melanoma. Axial giant congenital nevi or mutations in the p16 *CDK4* gene are potent risk factors. The risk of developing multiple primary melanomas is elevated if the patient has a family history of melanoma, has clinically or histologically atypical nevi, has more than 50 benign nevi, and does not use sunscreen. Sunscreens should be applied daily to sun-exposed areas, but must be used in conjunction with sun avoidance. Mutations of the *BRAF* gene are frequent in melanomas on nonchronically sun-exposed skin in Caucasians. Acral and mucosal lentiginous melanomas are associated with mutations of the *KIT* gene and amplifications of the gene for cyclin D1 or the *CDK4* gene. Amplifications of the gene for cyclin D1 are also detected in normal-looking melanocytes adjacent to these melanomas, suggesting field cancerization, as has been postulated for head and neck carcinomas in which early mutations impart a selective growth advantage, leading to expansion of the population of cells and creating a field of cells ripe for secondary mutations.

Other implicated factors include PUVA, tanning lamps, xeroderma pigmentosum, burn scars, and immunodeficiency. An association between administration of levodopa therapy for Parkinson's disease and the onset of melanoma remains unproved.

### Melanoma types

Clinicopathologic types of melanoma include lentigo maligna, superficial spreading melanoma, acral-lentiginous melanoma, nodular melanoma, desmoplastic melanoma, mucosal melanoma, ocular melanoma, primary CNS melanoma, and primary soft tissue malignant melanoma. Clinically, melanomas may be pedunculated, polypoid, amelanotic, or hyper-

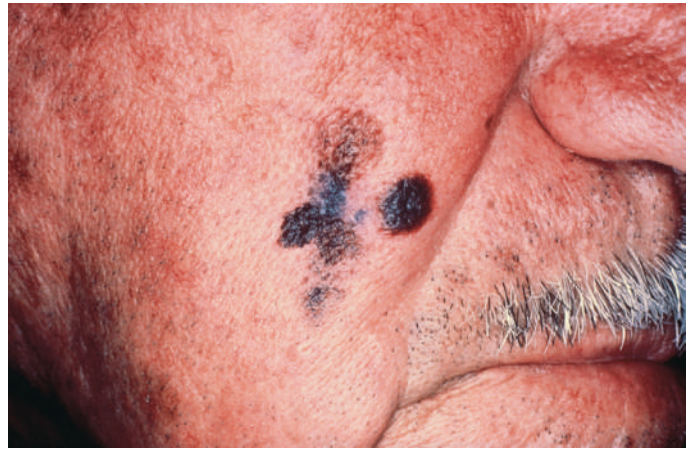

Fig. 30-12 Lentigo maligna melanoma.

keratotic. Some authors recognize animal-type melanoma as a distinct subtype. It resembles dendritic melanoma seen in horses and demonstrates low nuclear expression of glutathione *S*-transferase.

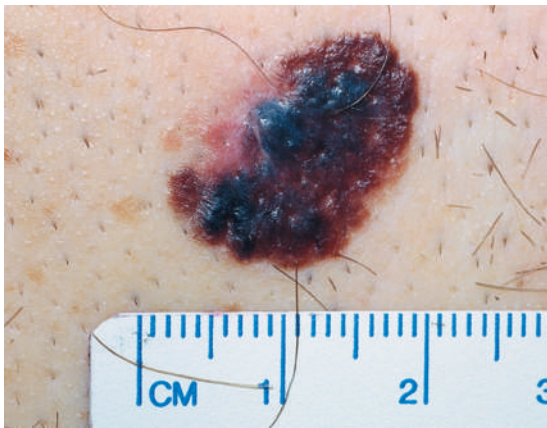
### Lentigo maligna (lentiginous melanoma on sun-damaged skin)

Lentigo maligna begins as a tan macule that extends peripherally, with gradual, uneven darkening over years. It is more common in older patients with heavily sun-damaged skin and in sunny climates. It appears to be increasing in frequency, and some data suggest it is now the most common form of melanoma. The spread and darkening are usually so slow that the patient pays little attention to this insidious lesion. After a radial growth period of 5–20 years, a vertical growth phase of invasive melanoma can develop (Fig. 30-12). The lesion is then referred to as lentigo maligna melanoma. A palpable nodule within the original macular lesion is the best evidence that this has occurred, although there may be darkening or bleeding as well. Lentiginous types of melanoma also give rise to desmoplastic melanoma, which may appear as a papule, firm plaque, or inconspicuous area of induration.

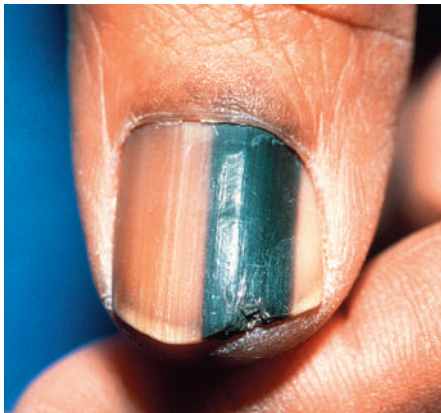The lentiginous melanomas (lentigo maligna and acral-lentiginous melanoma) proliferate principally at the DEJ, with little buckshot scatter into the overlying epidermis. Because the junctional involvement is often only one cell thick, lentiginous melanomas often extend laterally far beyond the clinically apparent margin. The lateral subclinical extension frequently exceeds the “standard” 5-mm margin for in situ melanoma, and asymmetric growth is common.

### Superficial spreading melanoma

Superficially spreading melanoma once was the most common form of melanoma and affects adults of all ages, with the median age in the fifth decade. Unlike lentigo maligna, it occurs most often on intermittently exposed skin. The upper back in both genders and the legs in women are the most common sites. There is a tendency to multicoloration, not just with different shades of tan, but variegated black, red, brown, blue, and white (Fig. 30-13). Lesions may arise de novo or in association with a preexisting nevus. Areas of color change within a nevus, especially dark areas that extend beyond the border of the remainder of the lesion, are suspicious for melanoma arising in a nevus. As a vertical growth phase develops, a papule or nodule usually appears. Skin markings disappear as the lesion expands. Regression may appear as variation in



**Fig. 30-13** Superficial spreading malignant melanoma.



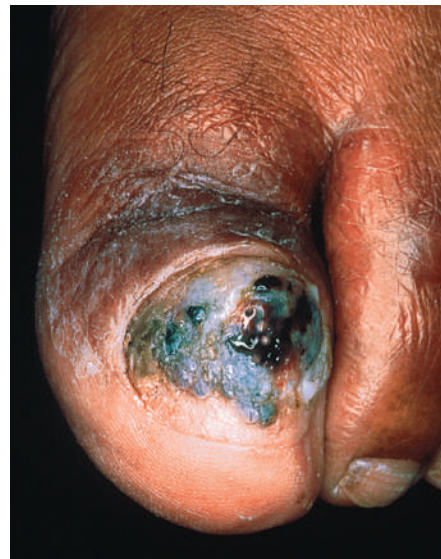**Fig. 30-14** Malignant melanoma.

pigmentation or a scalloped margin. The radial growth phase is characterized by buckshot scatter of melanocytes throughout the epidermis. Because of this, the borders tend to be more sharply defined than those of lentiginous types of melanoma.

### Acral-lentiginous melanoma

Acral-lentiginous melanoma is the most common type of melanoma in dark-skinned and Asian populations. This is because the frequency of the other types is low in these patients, not because the incidence of acral-lentiginous melanoma is any higher than in white persons. The median age of patients is 50 years, with equal gender distribution. The most common site of melanoma in black persons is the foot, with 60% of patients having subungual or plantar lesions. All lentiginous melanomas demonstrate a junctional growth pattern and tend to have indistinct margins. Over time, a vertical growth phase develops. Periungual hyperpigmentation and Hutchinson's sign may be seen; a black discoloration of the proximal nailfold at the end of a pigmented streak (melanonychia striata) is an ominous sign suggesting melanoma in the matrix of the nail (Fig. 30-14).

The early changes of acral-lentiginous melanoma may be light brown and uniformly pigmented. The thumb and hallux are more frequently involved than the other digits. In time, the lesion becomes darker and nodular and may ulcerate. Metastases to the epitrochlear and axillary nodes are common, because diagnosis is often delayed. Subungual melanoma (Fig. 30-15) may be misdiagnosed as onychomycosis, verruca vulgaris, chronic paronychia, subungual hyperkeratosis, pyogenic granuloma, Kaposi sarcoma, glomus tumor, or subungual hematoma. Nests in acral nevi tend to follow



**Fig. 30-15** Malignant melanoma.

dermatoglyphs. If ink is applied to an acral melanocytic lesion and then wiped off (leaving ink in the furrows), the presence of pigment between the inked furrows suggests the possibility of melanoma. A biopsy demonstrating large dendritic melanocytes with dendrites that vary in diameter in an acral location suggests acral-lentiginous melanoma, even in the absence of irregular junctional nests or confluent melanocytic growth.

### Mucosal melanoma

Primary melanoma of the mucous membranes is rare and typically demonstrates a lentiginous (junctional) growth pattern. In the mouth, especially the palate, the lesion is usually pigmented and may be ulcerated. It may occur in the nasal mucosa as a polypoid tumor. On the lip, it is apt to be an indolent ulcer. Melanoma of the vulva is manifested by a tumor and is often ulcerated, with bleeding and pruritus. It is most often detected after metastasis to the groin has occurred.

### Nodular melanoma

These lesions arise without a clinically apparent radial growth phase, but usually, large atypical melanocytes can be found in the epidermis beyond the region of vertical growth. Primary dermal melanomas in congenital nevi are also nodular and lack a radial growth phase. Nodular melanoma constitutes about 15% of all melanomas. It occurs twice as often in men as in women, primarily on sun-exposed areas of the head, neck, and trunk. The tumors may be smooth and dome shaped, fungating, friable, or ulcerated. Bleeding is usually a late sign.

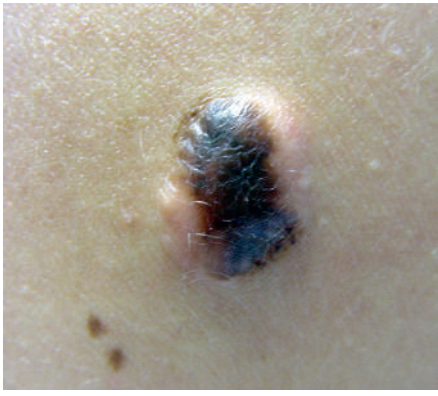
### Polypoid melanoma

This is a variant of nodular melanoma, presenting as a pedunculated tumor. At its base, the polypoid melanoma does not appear to descend for any appreciable distance into the dermis. Nevertheless, the 5-year survival rate is only 42%, compared with 57% for other nodular melanomas. The prognosis relates to the thickness (a measure of the volume of the tumor) and the presence of a vertical growth phase.

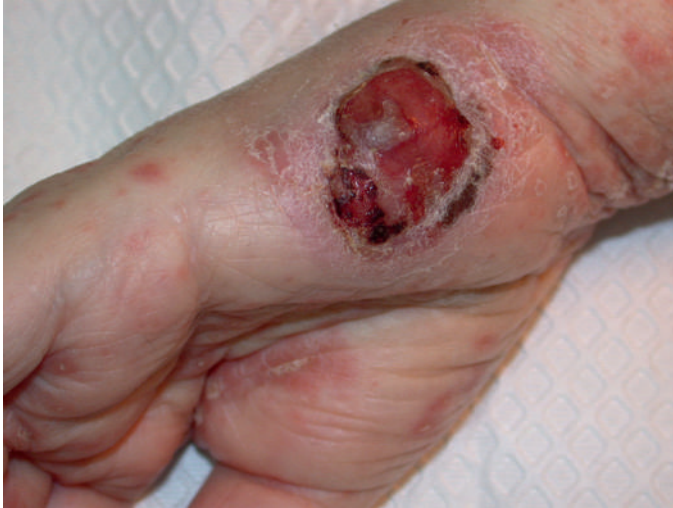### Desmoplastic melanoma

This deeply infiltrating type of melanoma usually has a spindle cell pattern histologically in which collagen fibers extend between the tumor cells. Desmoplastic melanoma most often





**Fig. 30-16**  
Desmoplastic melanoma.



**Fig. 30-17** Amelanotic malignant melanoma.

occurs on the head or neck of older men (Fig. 30-16), often within a subtle lentigo maligna. The lesions may also occur on the digits, in association with a subtle acral-lentiginous melanoma. One third of cases present with only a palpable dermal irregularity and are amelanotic. The biopsy demonstrates a spindle cell proliferation with a dense fibrous stroma. Atypia is variable. The lesions are typically neurotropic and demonstrate extensive growth along the perineurium beyond the bulk of the tumor. Nodular lymphoid aggregates are frequently present and are an important clue to the diagnosis. S-100 protein and SOX-10 are the most reliable immunostains. HMB-45 and Mart-1 are usually negative. Pure desmoplastic melanomas have a low risk of metastasis, but hybrid tumors carry a much greater risk.

### Amelanotic melanoma

Nonpigmented melanoma differs from other melanomas only in its lack of pigment. The lesion is pink (Fig. 30-17), erythematous, or flesh colored, and often mimics BCC or granuloma pyogenicum. Amelanotic melanoma is the typical variant seen in albino persons. Dermatoscopic features may still be of diagnostic value, even in amelanotic melanomas.

### Soft tissue melanoma and clear cell sarcoma

Primary soft tissue melanoma is rare and distinguished from clear cell sarcoma by the presence of *BRAF* mutations and

the absence of the characteristic t(12; 22)(q12; q12) translocation that is seen in clear cell sarcoma. As with melanoma, clear cell sarcoma contains melanosomes and stains positively for S-100 and HMB-45. It occurs most frequently on the lower extremities of young people. The average age at onset is 27. The history is of an enlarging, often painful mass on an extremity, with the foot or ankle involved 43% of the time. The tumors arise in and are bound to the aponeuroses, tendons, or fascia and only infrequently invade the overlying skin. Histologically, there are compact nests and fascicles of polygonal or fusiform cells, with a clear cytoplasm present between dense fibrous tissue septa that connect with tendinous or aponeurotic tissue. Multinucleated cells are common. Frequently, there are translocations of chromosomes 12 and 22. Metastases are often present at first diagnosis, and the prognosis is poor. Local recurrence or distant metastases after the initial excision are frequent and result in death in more than 50% of reported cases. Treatment is with wide excision and lymph node dissection. Radiotherapy and chemotherapy are used as an adjunct in some cases. The lesion appears to arise from neural crest cells.

### Differential diagnosis

Melanoma may clinically simulate a wide variety of lesions, including pigmented BCC, darkly pigmented seborrheic keratosis, pyogenic granuloma, and Kaposi sarcoma. Melanomas may appear pearly, may contain horn cysts, and may exhibit a collarette, and none of these is sufficient to forego a biopsy. Other melanoma-simulating lesions include subungual traumatic hematoma, cherry angioma, pigmented Bowen's disease, and pigmented Paget's disease.

### Biopsy

Complete removal with a 1-3 mm margin of skin is the preferred method of biopsy for a lesion suspected to be melanoma. Saucerization technique is frequently used for macular lesions. Although the National Comprehensive Cancer Network (NCCN) recommends avoiding wider margins to permit accurate lymphatic mapping for sentinel node biopsy, some evidence suggests that accurate mapping is usually still possible even after wide excision.

In lesions too large for simple excision, an incisional or punch biopsy, deep enough to permit measurement of thickness, has no effect on prognosis. When melanoma is suspected in a giant pigmented nevus, an incisional biopsy should be performed. Biopsy of lentigo maligna is problematic because the lesions tend to be quite large and arise in cosmetically sensitive areas. Skip areas are common in these lesions and may lead to misdiagnosis. Areas of the tumor may undergo lichenoid regression and resemble benign lichenoid keratosis. Collision with other pigmented lesions, such as benign solar lentigo, pigmented large cell acanthoma, and pigmented actinic keratosis, is common. Because of the potential for sampling error, small biopsies frequently result in misdiagnosis. If the lesion is heterogeneous, multiple areas may need to be sampled.

### Histopathology

Biopsies should be read by a dermatopathologist or other pathologist experienced in pigmented lesions. The report should include thickness and an assessment of the deep and

peripheral margins. The presence of ulceration should be noted. Several studies demonstrate that concordance for assessment of Clark's level is poor, and reporting of Clark's level has largely been replaced by reporting of the mitotic rate. The presence of satellite metastasis is a powerful adverse prognostic indicator and should be noted in the report. Other factors that may be important to note include regression, tumor-infiltrating lymphocytes, vertical growth phase, angiolymphatic invasion, neurotropism, and histologic subtype.

Whereas benign nevi are well nested at the DEJ, melanomas usually demonstrate junctional areas where nonnested melanocytes predominate. Benign nevi demonstrate dispersion of individual melanocytes at the base of the lesion, whereas melanomas remain nested at the base. Melanomas are typically asymmetric, whereas metastatic and nodular melanomas may present as perfectly symmetric spheres. Benign nevi demonstrate bilateral symmetry and show maturation (smaller, more neuroid cells) with descent into the dermis. Most melanomas lack bilateral symmetry and show minimal maturation with descent into the dermis. In nevi, nests at the DEJ tend to be round to oval, situated at the tips and sides of rete ridges, and are about equidistant from one another. In melanoma, junctional nests are often elongated or have irregular shapes. They are randomly distributed and often involve the arches over the dermal papillae, as well as the tips and sites of the rete ridges. Confluent runs of melanocytes are frequently seen at the DEJ and often continue down the adnexal structures. In nevi, dermal nests are generally smaller than the junctional nests and become progressively smaller deeper in the dermis. In melanoma, dermal nests generally fail to become smaller in the deeper dermis. In nevi, pigment is most prominent at the junction and becomes progressively less prominent deeper in the dermis. Melanomas often retain pigment deep in the lesion. In superficial spreading melanoma, individual melanocytes are present in buckshot scatter throughout the epidermis. Lentiginous types of melanoma tend to proliferate at the DEJ with little associated buckshot scatter. Invasive melanoma is often associated with a lymphoid infiltrate that forms a band at the periphery of the lesion. Plasma cells may be numerous. A vertical growth phase is identified by the presence of dermal mitoses, a dermal nest larger than the largest junctional nest, or invasion of the reticular dermis or solar elastotic band. Melanoma depth is measured from the granular layer or base of the ulcer. If invasion has occurred from follicular extension of the tumor, the lesion is measured from the inner root sheath. Rare variants of melanoma include balloon cell melanoma and dendritic "equine-type" melanoma.

Some types of benign nevus mimic individual features of melanoma. Sunburned nevi, acral nevi, and Spitz nevi may demonstrate buckshot intraepidermal scatter of melanocytes. Blue nevi typically are pigmented to the base of the lesion and extend into the dermis as a bulbous projection with minimal maturation and no dispersion of cells at the base. The silhouette, sclerotic stroma, and bland cytology are key to the diagnosis.

Comparative genomic hybridization has shown that chromosomal aberrations are common in melanoma. They occur earlier in the progression of acral melanoma than in melanomas on the trunk. In general, melanomas tend to have abnormalities involving chromosomes 9, 10, 7, and 6. Acral melanomas are more likely to have aberrations involving chromosomes 5p, 11q, 12q, and 15, and many amplifications are found at the cyclin D1 locus. Lentigo maligna melanomas are more likely to show losses of chromosomes 17p and 13q. Chromosomal aberrations are rare in benign banal nevi. A minority

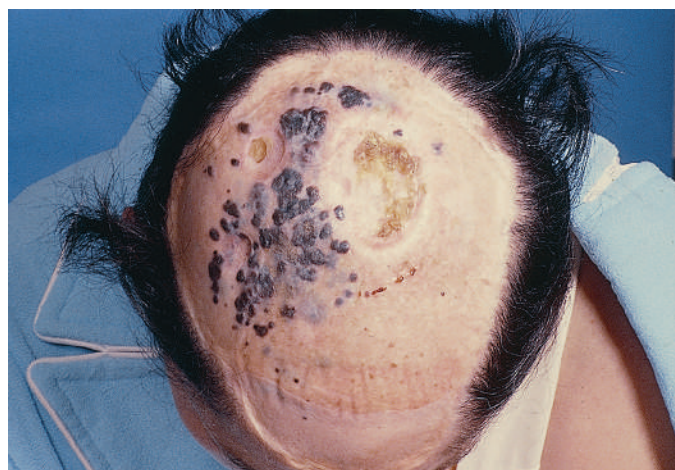

Fig. 30-18 Metastatic malignant melanoma.

of Spitz nevi may show an isolated gain involving the entire short arm of chromosome 11.

## Metastasis

Early metastases typically occur by way of the lymphatic channels, and regional lymphadenopathy may be the first sign. Satellite metastases appear as pigmented nodules around the site of the excision (Fig. 30-18). Later, metastases occur through the bloodstream and may become widespread. The chief site for metastatic melanoma is the skin, but all other organs are at risk. CNS metastasis is the most common cause of death. Although most metastatic spread occurs in the first 5 years after diagnosis, late-onset metastases occur, especially in premenopausal women. Melanemia, melanuria, and cachexia are likely to occur in terminal disease. In extreme cases, the entire integument may become deeply pigmented (generalized melanosis), with melanin in melanophages, endothelial cells, and tissue histiocytes. Occasionally, patients present with metastatic melanoma from an unknown source. Full-body skin examination may reveal a depigmented or irregularly pigmented atrophic patch consistent with a regressed primary lesion. Such patients are estimated to have a 40% chance of 5-year survival. Estrogen receptors may play a role in melanoma progression and metastasis, with lower levels of expression of receptors in thicker lesions.

## Staging

The American Joint Committee on Cancer (AJCC) developed a staging system for cutaneous melanoma. The system's categories depend on definitions for primary tumors, lymph node involvement, and distant metastases (Box 30-1; [www.cancerstaging.net](http://www.cancerstaging.net)). The American Academy of Dermatology (AAD) guideline regarding management and follow-up of melanoma can be found at [www.aad.org](http://www.aad.org).

## Prognosis

The prognosis for a patient with stage I melanoma is primarily related to tumor thickness. Cure rates by stage are as follows:

- Stage I (T1 or T2a, N0, M0): >80%
- Stage II (T2b-4, N0, M0): 60-80%



**Box 30-1** Summary of American Joint Committee on Cancer melanoma staging

T0: No evidence of primary tumor  
 Tis: Melanoma in situ  
 T1: Up to 1.0 mm in thickness

- T1a: No ulceration or dermal mitoses
- T1b: At least one dermal mitosis or ulceration

T2: 1.01–2.0 mm in thickness

- T2a: No ulceration
- T2b: Ulceration

T3: 2.01–4.0 mm in thickness

- T3a: No ulceration
- T3b: Ulceration

T4: >4.0 mm in thickness

- T4a: No ulceration
- T4b: Ulceration

N0: No regional lymph node metastasis  
 N1: Metastasis in one lymph node

- N1a: Clinically occult
- N1b: Clinically apparent or grossly involving a lymph node

N2: Two to three regional nodes or in-transit metastasis

- N2a: Clinically occult
- N2b: Clinically apparent
- N2c: Satellite or in-transit metastases

N3: Four or more nodes, matted nodes or in-transit metastasis with positive nodes  
 M0: No distant metastases  
 M1: Distant metastases

- M1a: Skin or nodes
- M1b: Lung
- M1c: All other viscera or any distant metastases with elevated lactic acid dehydrogenase (LDH)

- Stage III (N1–3, M0): 10–60%
- Stage IV (M1): <10%

Many variables have been reported to influence survival, including the following:

- Presence of tumor-infiltrating lymphocytes; a brisk response is best.
- Mitotic rate; 0 is best, and >6/mm<sup>2</sup> is worst.
- Ulceration has an adverse effect.
- Location; hair-bearing limbs yield a better prognosis than when lesions are present on the trunk, head, neck, palm, or sole.
- Gender; women have a better prognosis than men.
- Age; younger patients have a better prognosis.
- Presence of leukoderma at distal sites improves the prognosis.
- Regression is associated with a poorer prognosis.

Multivariate analysis shows that some factors are not independently predictive and others are of variable significance in different series. Pregnancy does not have an adverse effect on survival in patients with clinically localized melanoma. Tumor thickness, ulceration, and lymph node involvement have the greatest predictive value and are used to determine therapy.

The presence or absence of melanoma in regional lymph nodes is the single most important prognostic factor for melanoma. Sentinel lymph node dissection using lymphoscintigraphy with <sup>99m</sup>Tc-labeled colloids is widely used for the staging of clinically node-negative melanomas. The success rate in localizing the sentinel lymph node approaches 98% at centers

experienced in the technique. When combined with the vital blue dye technique, the success rate can approach 99%. About 20% of patients with melanoma between 1.5 and 4 mm in depth will have metastasis in their sentinel node(s). For desmoplastic and neurotropic melanoma (mean Breslow depth, 4.0 mm; median, 2.8 mm), published data suggest that up to 12% have at least one positive sentinel lymph node, although recent data suggest those with metastases are likely to be hybrid tumors rather than pure desmoplastic melanomas. Tumor thickness and ulceration are the major independent predictors of sentinel lymph node metastases. Age and axial tumor location are also significant. Patients with larger metastases to the sentinel node (metastatic deposits >2 mm in diameter) have significantly decreased survival.

Local recurrence related to a positive margin should not be equated with local recurrence representing dermal in-transit lymphatic metastasis. The latter is associated with a poor prognosis, whereas the former may be cured in many cases by reexcision.

### Workup and follow-up

There is no definite proof that any routine laboratory work or imaging study affects longevity, and no routine laboratory or imaging studies should be done for stage 0 or 1a melanoma. Some advocate only ordering studies as prompted by signs or symptoms regardless of stage. Other guidelines recommend limited studies varying by stage. The AAD guideline states that baseline laboratory tests and imaging studies are generally not recommended in asymptomatic patients with a new diagnosis of primary melanoma regardless of thickness. It also notes that surveillance laboratory tests and imaging studies in asymptomatic patients have a low yield but are associated with relatively high false-positive rates.

A pelvic computed tomography (CT) scan should be performed in those with palpable inguinofemoral lymphadenopathy. The highest yield for CT scans is in the area adjacent to nodal disease. As glucose metabolism is increased in malignant tumors, positron emission tomography (PET) using the glucose analog fluorine-18-fluorodeoxyglucose (F18-FDG) can be used to detect metastases in patients with signs or symptoms. Although evidence supporting any routine imaging studies in the absence of signs or symptoms is scant, some authorities consider them for the first few years in patients with very-high-risk disease.

Periodic skin examinations are important to detect second primary tumors as well as metastatic disease. The AAD guideline notes that no clear data regarding follow-up interval exist but recommends at least annual history and physical examination, and that patient self-examination remains the most important means of detecting recurrent disease or a new primary melanoma. Because tumor recurrence occurs sooner in patients with thick melanomas than those with thin melanomas, some authors have suggested follow-up schedules based on AJCC staging, to include annual examinations for patients with stage I disease, examinations every 6 months for 2 years and then annually for those with stage IIa disease, and examinations every 4 months for 2 years, every 6 months in the third year, and annually thereafter for those with stage IIb-stage IIc disease. A palpable node is an indication for fine-needle aspiration (FNA).

### Treatment

Early excision remains the most important determinant of outcome. Most published guidelines are based on data that

relate largely to superficial spreading melanoma and may not be applicable to all melanomas. For any melanoma, simple complete excision should be performed. Wider margins reduce the risk of local recurrence, but scant evidence suggests that they affect mortality, which is more closely related to distant metastasis than to local/regional recurrence. A margin of 0.5 cm is currently recommended for excision of a melanoma in situ, although narrower margins may be performed in the interest of sparing vital tissue. A 1.0-cm margin is recommended for superficial spreading melanomas 1.0 mm or less in thickness, a 1–2 cm margin for those 2 mm or less, and a 2-cm margin for those thicker than 2.0 mm. In the case of lentigo maligna, mucosal, and acral-lentiginous melanoma, subclinical extension of the in situ tumor usually exceeds 0.5 cm, and asymmetric growth is common. In such cases, a symmetric “standard” margin may do a disservice to the patient. It may result in a positive lateral margin and difficult closure because excessive uninvolved skin was sacrificed. Mohs micrographic surgery may be useful in this setting. Although hematoxylin-eosin (H&E)-stained frozen sections have been used, immunostains such as MelanA, MITF, or SOX-10 are easier to interpret. Staged excision with permanent sections is another option. In patients who are poor surgical candidates, nonsurgical treatments such as topical imiquimod and radiotherapy may be used. Nail apparatus melanoma may necessitate amputation of a digit or skin grafting. This is another setting where Mohs micrographic surgery may be considered as a tissue-sparing technique. It may also be helpful in the management of desmoplastic melanoma, especially when neurotropism is present.

Sentinel node biopsy (SNB) should be discussed with patients whose melanomas are 1 mm or greater in thickness. SNB should be considered for thinner lesions in patients who have ulceration, dermal mitosis, or other features of a vertical growth phase, Clark level IV or V invasion, regression, or a positive deep margin on initial biopsy. Dual-basin drainage from the trunk is not independently associated with an increased risk of nodal metastases, but each basin must be identified and sampled. Those with a positive SNB or nodal metastasis confirmed by FNA should receive counseling regarding dissection of the remainder of the nodal basin. An analysis of SNB results in 422 Swedish patients with a mean thickness of 3.2 mm suggests that SN-negative patients have better disease-free survival ( $p < 0.0001$ ), but the false-negative rate may be as high as 14%.

Ipilimumab blocks the CTLA-4 protein, reducing tumor tolerance. It has shown impressive results in some patients with melanoma, and trials of ipilimumab with other immunomodulating drugs and vaccines are ongoing. The RAS-RAF-MEK-ERK pathway is a critical signal transduction pathway in melanoma, and alterations in this pathway, including *BRAF* and *NRAS* mutations, are important drivers of melanomagenesis. *BRAF* inhibition with vemurafenib can produce time-limited responses. The mechanism of action of vemurafenib involves selective inhibition of mutated-*BRAF* V600E kinase, leading to reduced signaling through the aberrant MAPK pathway. Trametinib, a selective MEK inhibitor, has been shown to have a survival benefit over cytotoxic chemotherapy in patients with V600 *BRAF*-mutant metastatic melanoma. MEK inhibitors also have potential in the treatment of advanced melanoma harboring other genetic mutations, such as *NRAS* and *GNAQ/GNA11*. Combinations of inhibitors have the potential to overcome tumor resistance. Side effects of therapy can be significant. Typical vemurafenib side effects include arthralgia, fatigue, alopecia, photosensitivity, pruritus, hand-foot syndrome, eruptive benign and malignant squamous proliferations, and panniculitis. Oncogenic mutations in *KIT* occur in mucosal and acral melanomas, as well as those

on chronically sun-damaged skin. Imatinib may have a role in treating tumors in these sites.

For in-transit metastases, surgical excision, interferon (IFN), hyperthermic isolated limb perfusion with melphalan, CO<sub>2</sub> laser ablation, and intralesional bacille Calmette-Guérin (BCG) are used. Dinitrochlorobenzene in the setting of in-transit melanoma metastases has been reported to induce local remission but did not prevent metastatic lymph node and liver involvement. For stage IV disease, treatment options include resection, radiation, dacarbazine, temozolomide, interleukin-2, paclitaxel, and combination chemotherapy.

Adjuvant therapy should be discussed with patients who have positive nodes or node-negative melanoma that is 4 mm thick, ulcerated, or Clark’s level IV or V. IFN alfa-2b is U.S. Food and Drug Administration (FDA) approved as adjuvant therapy. Although meta-analysis suggests that IFN therapy may increase relapse-free survival, an advantage for overall survival is uncertain. Systemic symptoms may require discontinuation of therapy in some patients, and lipodystrophy has been reported with IFN therapy. The results of trials have been mixed. Reports of long-term survival after resection of distant melanoma metastases suggest that cytoreductive surgery may play a role in select patients.

Clinical vaccine trials are ongoing, and some have shown promising results. However, despite numerous trials, only a few patients have been shown to exhibit strong antigen-specific cellular responses. CD137 is a promising target for immunotherapy. Antiangiogenic agents also show promise when used in combination with cytotoxic agents.

**Bourgeois AC, et al:** Positron emission tomography/computed tomography in melanoma. *Radiol Clin North Am* 2013; 51(5):865–879.

**Bowen GM:** Surgical management of melanoma. *Facial Plast Surg* 2013; 29(5):365–372.

**Carlson JA:** On the cusp of a revolution: melanoma molecular diagnostics. *J Am Acad Dermatol* 2013; 69(4):646–647.

**Chakraborty R, et al:** Molecular targeted therapies in metastatic melanoma. *Pharmacogenomics Pers Med* 2013; 6:49–56.

**Erickson C, et al:** Treatment options in melanoma in situ: topical and radiation therapy, excision and Mohs surgery. *Int J Dermatol* 2010; 49(5):482–491.

**Hodi FS, et al:** Improved survival with ipilimumab in patients with metastatic melanoma. *N Engl J Med* 2010; 363:711–723.

**Ito T, et al:** Acral lentiginous melanoma: who benefits from sentinel lymph node biopsy? *J Am Acad Dermatol* 2015; 72(1):71–77.

**Ji AL, et al:** Ambulatory melanoma care patterns in the United States. *J Skin Cancer* 2013; 2013:689261.

**Li SY, et al:** Immunotherapy of melanoma with the immune costimulatory monoclonal antibodies targeting CD137. *Clin Pharmacol* 2013; 5(Suppl 1):47–53.

**Lo JA, Fisher DE:** The melanoma revolution: from UV carcinogenesis to a new era in therapeutics. *Science* 2014; 346(6212):945–949.

**Maldonado-Seral C, et al:** Vemurafenib-associated neutrophilic panniculitis: an emergent adverse effect of variable severity. *Dermatol Online J* 2013; 19(4):18187.

**Mansfield AS, et al:** Inhibition of angiogenesis for the treatment of metastatic melanoma. *Curr Oncol Rep* 2013; 15(5):492–499.

**Nguyen JT, et al:** Surgical management of subungual melanoma: Mayo Clinic experience of 124 cases. *Ann Plast Surg* 2013; 71(4):346–354.

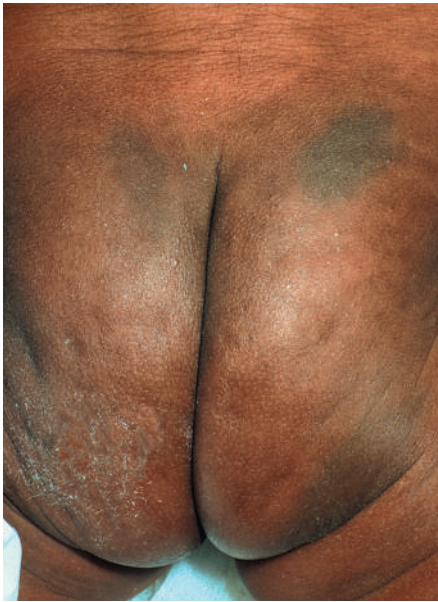**Rastrelli M, et al:** Melanoma: epidemiology, risk factors, pathogenesis, diagnosis and classification. *In Vivo* 2014; 28(6):1005–1011.

**Ray M, et al:** Translational research in melanoma. *Surg Oncol Clin North Am* 2013; 22(4):785–804.

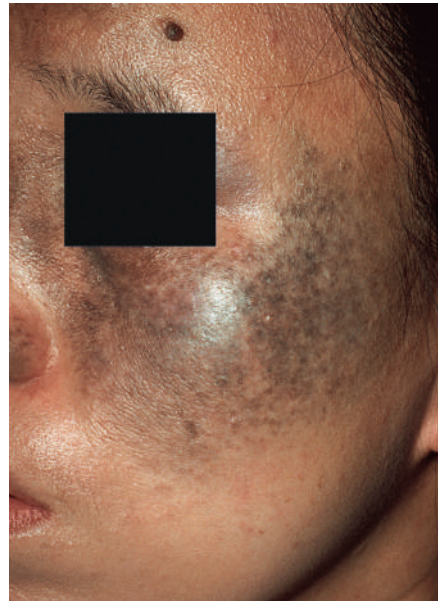
**Salama AK, et al:** MEK inhibition in the treatment of advanced melanoma. *Curr Oncol Rep* 2013; 15(5):473–482.

**Salama AK:** Evolving pharmacotherapies for the treatment of metastatic melanoma. *Clin Med Insights Oncol* 2013; 7:137–149.





**Fig. 30-19** Mongolian spot.



**Fig. 30-20** Nevus of Ota.

## DERMAL MELANOCYTIC LESIONS

### Mongolian spot

The mongolian spot is a bluish gray macule that varies in diameter from 2 to 8 cm. It occurs typically in the sacral region of the newborn (Fig. 30-19), in 80–90% of Asian, southern European, American black, and Native American persons. The Mayan Indians uniquely take great pride in it as an indicator of pure Mayan inheritance. The mongolian spot may be situated in other locations. Multiple spots may occur in a widespread distribution, and overlapping spots have been described. These have been called generalized dermal melanocytosis or dermal melanocytic hamartomas. They may occur in phakomatosis pigmentovascularis types II, IV, and V and have been described in the setting of Sjögren-Larsson syndrome. Extensive mongolian spots have been associated with Hunter syndrome and trisomy 20 mosaicism.

Histologically, the mongolian spot shows elongated dendritic dermal melanocytes, widely scattered among normal collagen bundles in the deep dermis. It usually disappears during childhood, although rarely, it may persist into adulthood. QS ruby and Nd:YAG lasers have been used to treat mongolian spots. Application of bleaching creams should be considered before treatment to reduce overlying pigmentation. The outcome of laser treatment tends to be better for lesions treated before age 20.

**Kagami S, et al:** Laser treatment of 26 Japanese patients with mongolian spots. *Dermatol Surg* 2008; 34(12):1689–1694.

**Leung AK, et al:** Superimposed mongolian spots. *Pediatr Dermatol* 2008; 25(2):233–235.

### Nevus of Ota (oculodermal melanocytosis)

The nevus of Ota is also known as nevus fuscoceruleus ophthalmomaxillaris. It is usually present at birth in the two thirds of patients who have ocular involvement. Other lesions may not appear until the teen years. The conjunctiva and skin around the eye supplied by the first and second branch of the trigeminal nerve may be involved, as well as the sclera, ocular muscles, retrobulbar fat, periosteum, and buccal mucosa. On the skin, brown, slate-gray, or blue-black macules slowly grow larger and deeper in color (Fig. 30-20). Nevus of Ota persists

throughout life; 80% occur in females, and 5% are bilateral. Glaucoma or ipsilateral sensorineural hypoacusia may also occasionally complicate nevus of Ota. Malignant melanoma rarely occurs, and malignant degeneration occurs more frequently in white patients. The most common site of malignancy is the choroid.

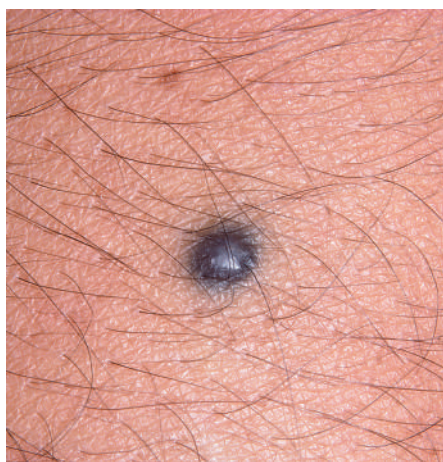
Histologically, elongated dendritic dermal melanocytes are seen scattered in the upper portion of the dermis. Acquired unilateral nevus of Ota-like macules are known as “sun nevus.” Some express hormone receptors. QS lasers have been used successfully to treat nevus of Ota. Nd:YAG laser at 1064 nm is suitable for use in a wide range of skin types. Acquired dermal melanocytosis (acquired bilateral nevus of Ota-like macules or Hori nevus) is recalcitrant to laser therapy compared with nevus of Ota. Good results have been reported after treatment with QS ruby laser. Initial topical bleaching with 0.1% tretinoin and 5% hydroquinone ointment containing 7% lactic acid can be used to reduce epidermal melanin before laser treatment. Epidermal cooling has been advocated in the past, but some data suggest an increased incidence of hyperpigmentation with epidermal cooling. QS ruby laser has also been used after epidermal ablation using a scanned CO<sub>2</sub> laser. Lesions of phakomatosis pigmentovascularis have been treated successfully with QS ruby and alexandrite lasers, with flashlamp-pumped pulsed dye laser for the vascular component. Intense pulse light systems have been combined with the QS ruby laser for complex dyspigmentation among Asian patients. Fractional photothermolysis using a fractionated 1440-nm Nd:YAG laser has also been reported as successful.

### Nevus of Ito

Also known as nevus fuscoceruleus acromiodeltoideus, the nevus of Ito has the same features as nevus of Ota, except that nevus of Ito occurs in the distribution of the posterior supraclavicular and lateral cutaneous brachial nerves, to involve the shoulder, side of the neck, and supraclavicular areas.

**Kouba DJ, et al:** Nevus of Ota successfully treated by fractional photothermolysis using a fractionated 1440-nm Nd:YAG laser. *Arch Dermatol* 2008; 144(2):156–158.

**Manuskiatti W, et al:** Effect of cold air cooling on the incidence of postinflammatory hyperpigmentation after Q-switched Nd:YAG laser treatment of acquired bilateral nevus of Ota-like macules. *Arch Dermatol* 2007; 143(9):1139–1143.



**Fig. 30-21** Blue nevus.

## Blue nevus

Blue nevi appear as well-defined blue papules or nodules (Fig. 30-21). Histologically, they share the silhouette of a bulbous fingerlike or wedge-shaped protrusion into the dermis. All variants show minimal maturation and no dispersion of melanocytes in the deep portion of the lesion. All except epithelioid blue nevi and some cellular blue nevi are associated with a dense sclerotic stroma. They usually occur as combined nevi: combinations of various types of blue nevus, blue nevus combined with banal nevus, or blue nevus combined with Spitz nevus.

### Blue nevus of Jadassohn-Tiche (common blue nevus, *nevus ceruleus*)

The typical lesion is a steel-blue papule or nodule that begins in early life. Some may be large and congenital. The slowly growing lesion is rarely more than 2–10 mm in diameter and occurs most frequently on the dorsal hands, feet, and face. Histologically, the lesion is composed of dendritic dermal melanocytes and melanophages. The sclerotic stroma is particularly prominent in this variant.

### Cellular blue nevus

Usually, a cellular blue nevus is a large, firm, blue or blue-black nodule. It is most frequently seen on the buttock and sacrococcygeal region and occasionally is present at birth. Women have cellular blue nevus 2.5 times more often than men, and the average age of the patient seen with this lesion is 40 years. Infrequently, these lesions may invade underlying structures, such as the skull in scalp lesions. Occasionally, cellular blue nevi may occur on the eyelids. Histologically, in addition to deeply pigmented melanophages, islands of cells are observed with large, fusiform vesicular nuclei, prominent nucleoli, and abundant pale cytoplasm. The cellular islands contain little or no pigment or stroma. Important diagnostic criteria for benign blue nevi include a low mitotic rate, absence of necrosis, low Ki-67–positive proliferative fraction, and uniform HMB-45 labeling. Cytologic atypia may be present in benign blue nevi, but mitotic figures should not be seen. Such “ancient” blue nevi frequently demonstrate edematous stromal areas and hyaline changes in vessels, suggesting a degenerative phenomenon.

### Epithelioid blue nevus

Epithelioid blue nevi are mostly seen in patients with the Carney complex (myxomas, spotty skin pigmentation,

endocrine overactivity, and schwannomas). They occur on the extremities and trunk and less frequently on the head and neck. They may also be noted in the absence of Carney complex and may occur on the genital mucosa. The lesions are composed of large polygonal and epithelioid melanocytes often laden with melanin. These cells are admixed with heavily pigmented dendritic melanocytes, spindled melanocytes, and melanophages. Some melanocytes are situated among the dermal collagen bundles singly, in short rows, and small groups. The nuclei are vesicular with very pale chromatin and a single, prominent nucleolus. They may demonstrate moderate pleomorphism and rare mitotic figures. In contrast to other blue nevi, they lack the usual sclerotic stroma. Some authors have grouped epithelioid blue nevi with dendritic (equine-type) and epithelioid melanomas under the designation “pigmented epithelioid melanocytoma,” which they regard as a borderline malignancy or low-grade melanoma. One problem with this designation is the lack of data suggesting that the lesions in patients with the Carney complex behave in a malignant manner. More than 50% of patients with Carney complex harbor mutations in the protein kinase A regulatory subunit 1 $\alpha$  (*PRKARIA*) gene, and the protein kinase is absent in the associated epithelioid blue nevi. Some evidence suggests that molecular studies could be useful to classify these lesions more accurately in regard to biologic behavior.

### Deep penetrating nevus

This unique type of nevus is frequently seen in combination with other forms of blue nevus. The fascicles of cells have small, hyperchromatic nuclei with a smudged chromatin pattern and inconspicuous nucleoli. Adjacent melanophages are noted with deep penetrating nevus.

### Amelanotic blue nevus (hypomelanotic blue nevus, “gray nevus”)

In the amelanotic or hypomelanotic variant of cellular blue nevus, mild cytologic atypia and pleomorphism may be present. Mitotic activity (up to 3 mitoses/mm) may also be observed. It is important to recognize the amelanotic blue nevus so as not to confuse it with a malignant lesion.

### “Malignant blue nevus”

The term “malignant blue nevus” has been used to refer to melanomas arising in a blue nevus, usually a cellular blue nevus. It has also been used for de novo melanoma resembling a cellular blue nevus. When melanoma occurs in a blue nevus, an abrupt transition can be seen between the nevus and the melanoma. The melanoma demonstrates a sheet-like growth pattern, mitoses, necrosis, and nuclear atypia.

### Treatment

Excision is the mainstay of treatment for blue nevi. Successful results have been reported with the QS ruby laser. Treatment of the malignant variety is the same as for a malignant melanoma. Intratumoral therapy with IFN beta has also been used.

**Barnhill RL, et al:** State of the art, nomenclature, and points of consensus and controversy concerning benign melanocytic lesions: outcome of an international workshop. *Adv Anat Pathol* 2010; 17(2):73–90.

**Battistella M, et al:** Two congenital cases of pigmented epithelioid melanocytoma studied by fluorescent in situ hybridization for melanocytic tumors: case reports and review of these recent topics. *Dermatology* 2010; 221(2):97–106.



**Cheung WL, et al:** Dermatopathology updates on melanocytic lesions. *Dermatol Clin* 2012; 30(4):617–622.

**Fleming MG:** Pigmented lesion pathology: what you should expect from your pathologist, and what your pathologist should expect from you. *Clin Plast Surg* 2010; 37(1):1–20.

**Gavriilidis P, et al:** Pigmented epithelioid melanocytoma: a new concept encompassing animal-type melanoma and epithelioid blue nevus. *BMJ Case Rep* 2013; Mar 22.

**Murali R, et al:** Blue nevi and related lesions: a review highlighting atypical and newly described variants, distinguishing features and diagnostic pitfalls. *Adv Anat Pathol* 2009; 16(6):365–382.

**Wang Q, et al:** Cellular blue nevi of the eyelid: a possible diagnostic pitfall. *J Am Acad Dermatol* 2008; 58(2):257–260.



Bonus images for this chapter can be found online at [expertconsult.inkling.com](http://expertconsult.inkling.com)

**eFig. 30-1** Solar lentigines.

**eFig. 30-2** Inherited patterned lentiginosis of black persons.

**eFig. 30-3** Nevus spilus.

**eFig. 30-4** Becker nevus.

**eFig. 30-5** Benign nevi.

**eFig. 30-6** Medium-sized congenital nevus.

**eFig. 30-7** Spitz nevus. (Courtesy of Brooke Army Medical Center Teaching File.)

**eFig. 30-8** Spitz nevus.

**eFig. 30-9** Halo nevus.

**eFig. 30-10** Multiple spindle cell nevi.

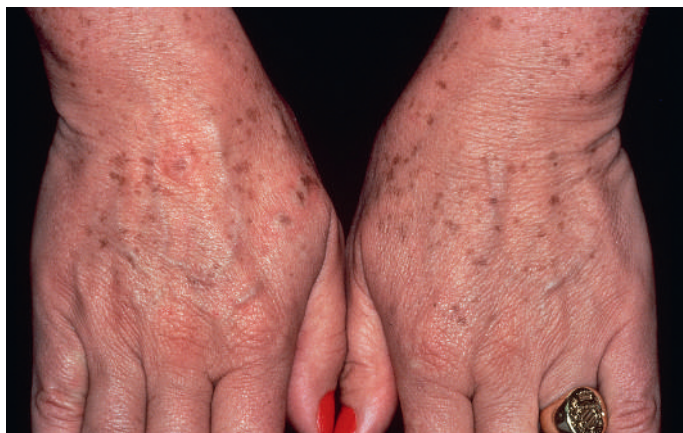**eFig. 30-11** Fried-egg appearance of dysplastic nevus.

**eFig. 30-12** Melanoma.

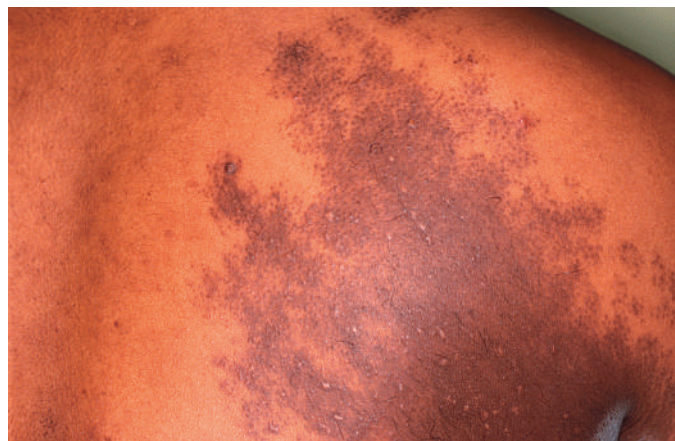**eFig. 30-13** Palatal melanoma.

**eFig. 30-14** Amelanotic malignant melanoma.

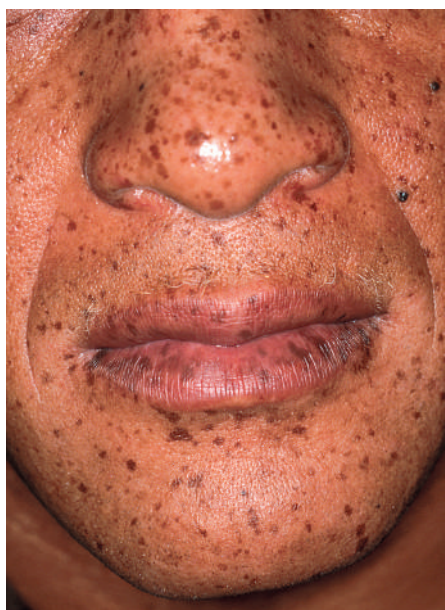**eFig. 30-15** Metastatic malignant melanoma. (Courtesy of Brooke Army Medical Center Teaching File.)



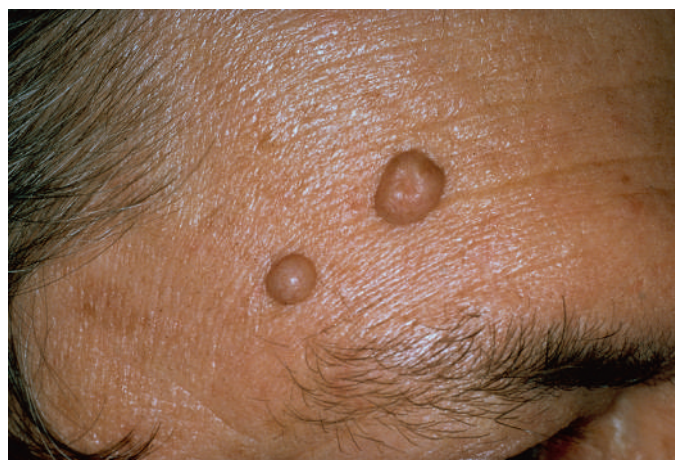eFig. 30-1 Solar lentigines.



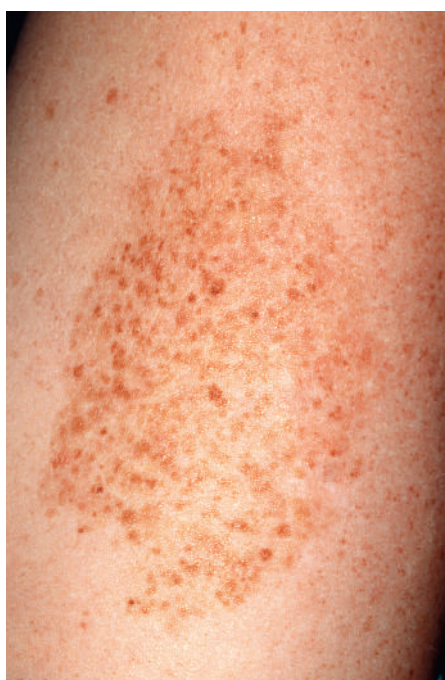eFig. 30-4 Becker nevus.



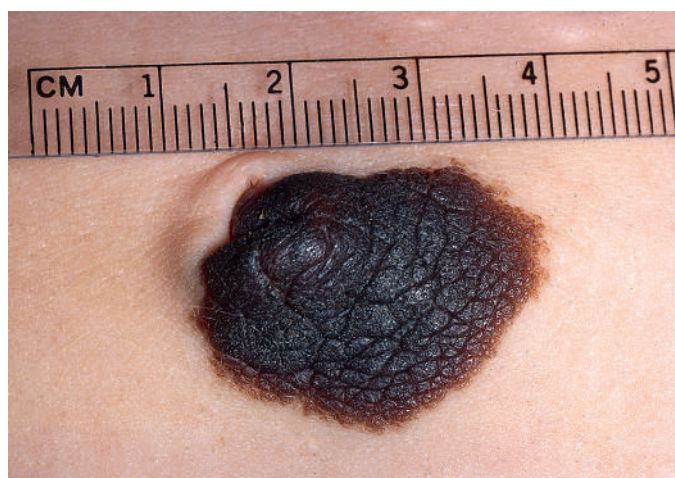eFig. 30-2 Inherited patterned lentiginosis of black persons.



eFig. 30-5 Benign nevi.

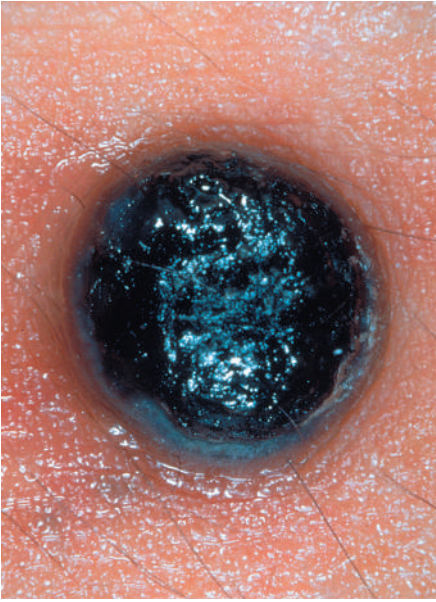


eFig. 30-3 Nevus spilus.

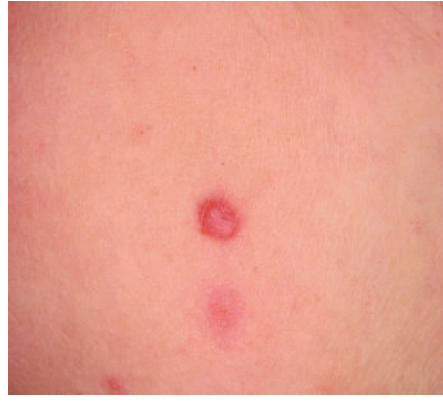

eFig. 30-6 Medium-sized congenital nevus.

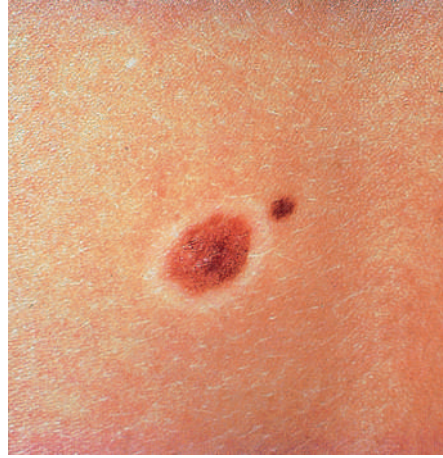



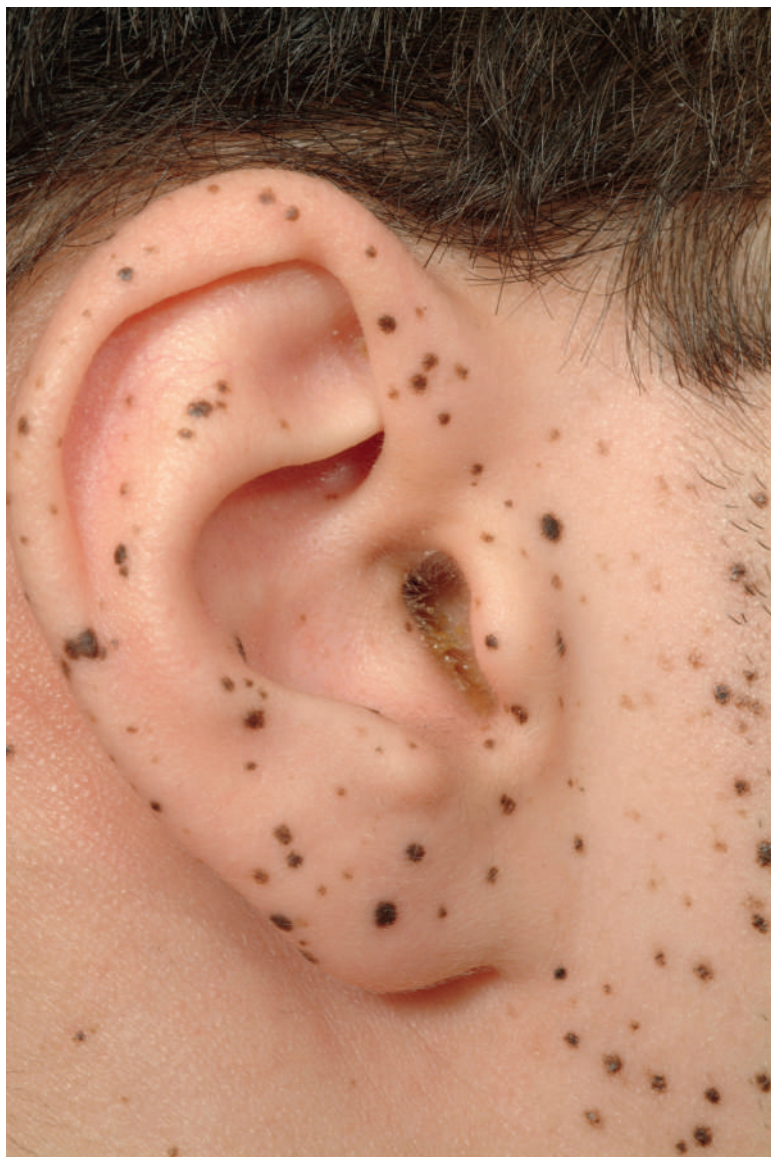**eFig. 30-7** Spitz nevus.  
(Courtesy of Brooke Army Medical Center Teaching File.)



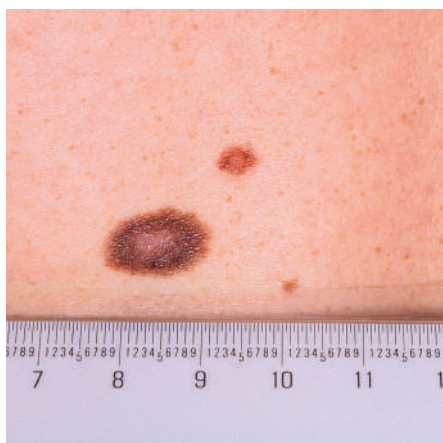
**eFig. 30-8** Spitz nevus.



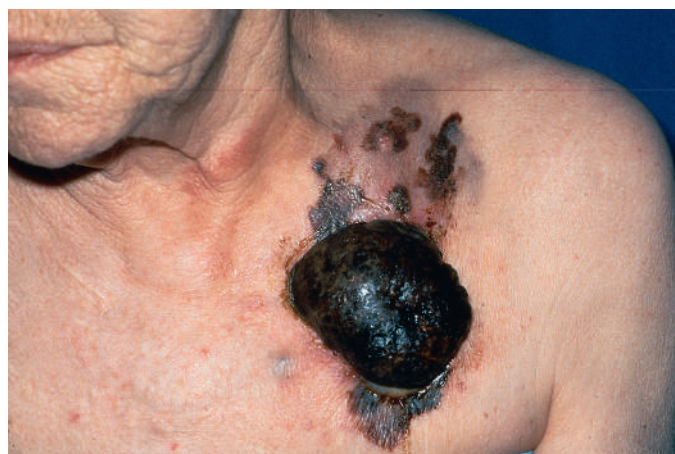**eFig. 30-9** Halo nevus.



eFig. 30-10 Multiple spindle cell nevi.

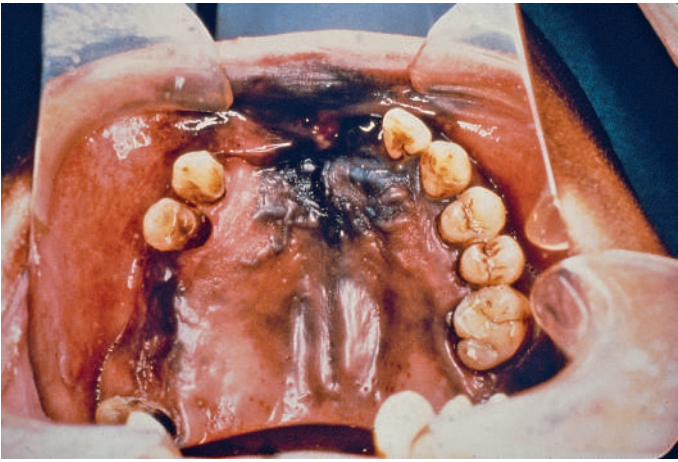


eFig. 30-11 Fried-egg appearance of dysplastic nevus.

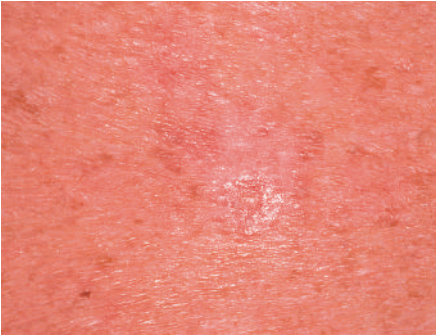


eFig. 30-12 Melanoma.

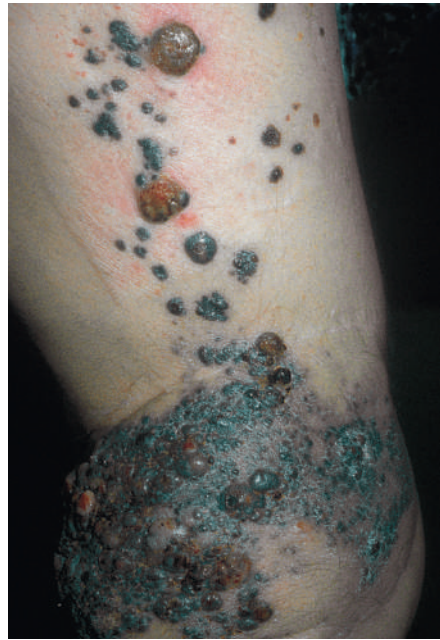



**eFig. 30-13** Palatal melanoma.



**eFig. 30-14** Amelanotic malignant melanoma.



**eFig. 30-15** Metastatic malignant melanoma. (Courtesy of Brooke Army Medical Center Teaching File.)

## Macrophage/Monocyte Disorders

### PALISADED GRANULOMATOUS DERMATOSES

#### Granuloma annulare

Granuloma annulare (GA) is a relatively common idiopathic disorder of the dermis and subcutaneous tissue. It occurs in all races and at all ages but affects women twice as often as men. GA may exhibit the isomorphic response of Koebner, affect healed areas of herpes zoster, and may be restricted to sun-exposed areas. Most cases spontaneously resolve, leaving entirely normal skin, but loss of elastic tissue may occur, leaving atrophic lesions resembling middermal elastolysis or anetoderma. GA lesions will sometimes spontaneously resolve when biopsied. Long-term follow-up of at least 20 years in patients with GA reveals that lesions usually heal, and that the patients remain healthy and do not develop unusual diseases. Case reports of associations as described here demonstrate that GA can be a reactive condition associated with a variety of underlying disorders and medications. In most patients, however, GA is a benign, self-limited (although not soon enough for the dermatologist or patient) condition affecting only the skin. Histologic variants in the GA spectrum have distinct names and warrant consideration as separate entities if they are specifically associated with a distinct clinical morphology or underlying condition.

Many clinical morphologies of GA exist. Usually, patients exhibit primarily one clinical type during the course of their illness, except in the subcutaneous form, in which typical papular or localized GA may also occur.

#### Localized granuloma annulare

The localized form of GA tends to affect children and young to middle-age adults. Usually, only one or a few lesions are present at any one time. Localized GA usually appears on the lateral or dorsal surfaces of the fingers or hands, elbows, dorsal feet, and ankles (Figs. 31-1 to 31-3). Rarely, the eyelid or even a Becker nevus may be affected. Lesions are erythematous, fawn colored or violaceous, thinly bordered plaques or papules that slowly spread peripherally while undergoing central involution, so that roughly annular lesions are formed. The overlying skin usually remains completely normal. Lesions may coalesce and sometimes form scalloped patterns or firm plaques. The lesions never ulcerate and on resolving, virtually always leave no residua. They develop slowly and often involute spontaneously. Although more than 50% of patients clear within 2 years, lesions will recur in 40%. Autoimmune thyroiditis may be present in women with localized GA.

#### Generalized granuloma annulare

Disseminated GA describes patients with more than 10 lesions and generalized GA patients with multiple lesions involving

the trunk and upper/lower extremities. Generalized GA affects mostly women in the fifth and sixth decades but is also a common pattern in adolescents and children. The association of generalized GA with diabetes mellitus has been questioned, although in some childhood cases, diabetes and GA appeared at the same time. This may be related to the association of dyslipidemia (elevated cholesterol, triglycerides, or LDL cholesterol) with generalized GA. The eruption of generalized GA presents as a diffuse but symmetric, papular or annular eruption. Lesions may number in the hundreds. Lesions favor the nape of the neck, upper trunk, and proximal upper extremities and rarely exceed 5 cm in diameter (Fig. 31-4). The palms, soles, and eyelids may be affected. The face and genital area are usually spared. In some cases, sun exposure seems to be a trigger (see actinic granuloma later, under Annular elastolytic giant cell granuloma). Some patients are completely asymptomatic, whereas others complain of severe pruritus. Spontaneous clearing usually occurs but at variable times. The average duration is 3–4 years but may be as short as 4 months or longer than 10 years.

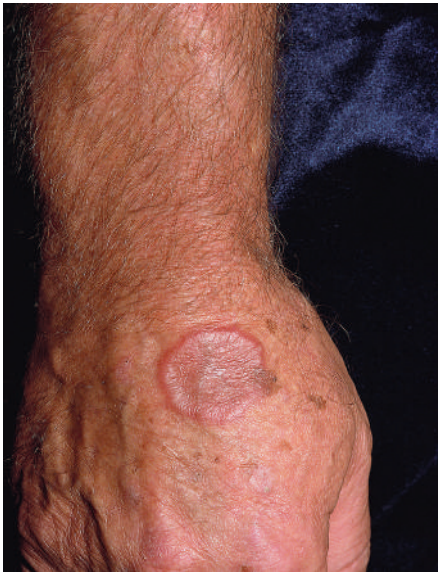#### Patch-type or macular granuloma annulare

Macular GA is significantly more common in women, usually at age 30–70. Flat or only slightly palpable erythematous or red-brown lesions occur, especially on the upper medial thighs and in bathing-trunk distribution. Lesions may closely simulate cutaneous T-cell lymphoma or morphea. Individual lesions average at least several centimeters in diameter but may be much larger. On careful palpation, small papules can be felt in some patients, and on stretching the skin the papules or small annular lesions can be seen. Such papules are the most fruitful sites for biopsies. Both well-formed necrobiotic granulomas and the interstitial pattern of GA may be seen on biopsy.

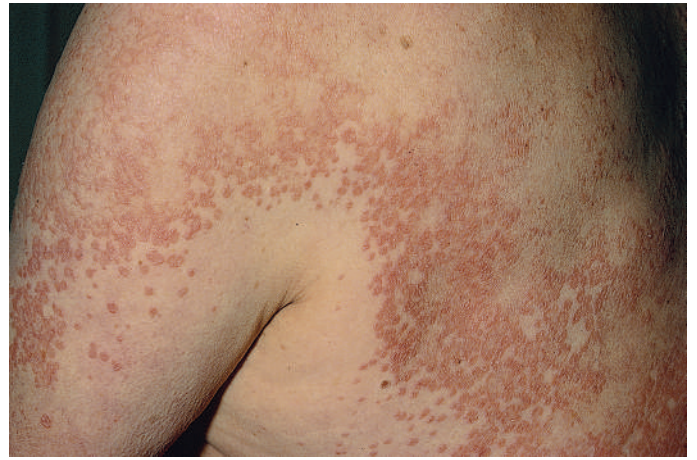#### Subcutaneous granuloma annulare (deep granuloma annulare, pseudorheumatoid nodule)

Subcutaneous GA is most common in children, with boys affected twice as frequently as girls. Childhood cases appear at any age from 1 year to adolescence, with one congenital case reported. Lesions tend to occur on the lower legs, especially the dorsal foot, but may also occur on the distal upper extremity or scalp. Multiple lesions are usually present. There is often a history of trauma to the affected area preceding the appearance of a lesion. Typically, lesions are skin-colored, deep dermal or subcutaneous nodules up to several centimeters in diameter (Fig. 31-5). Superficial papular lesions are present in about one quarter of patients with subcutaneous GA. Lesions in general are asymptomatic and resolve over a few years. The major clinical problem occurs when the initial pathologic interpretation is “rheumatoid nodule” and an unnecessary extensive rheumatologic workup is performed. An unusual variant

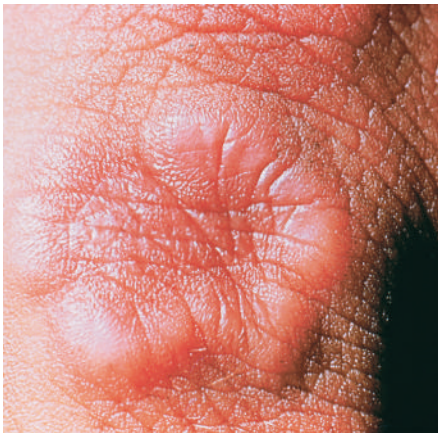



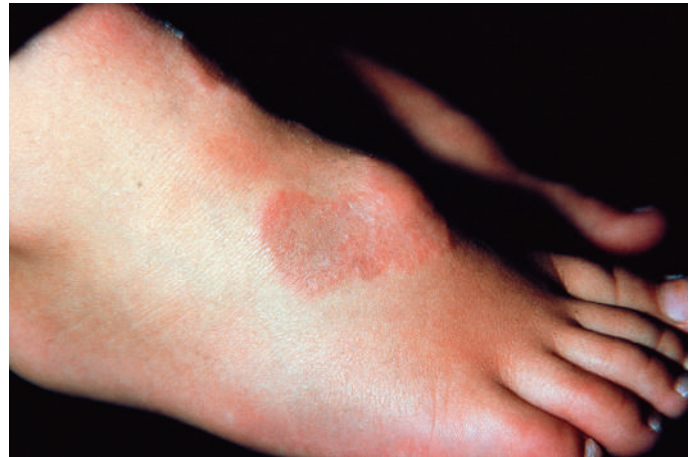**Fig. 31-1** Granuloma annulare, annular, localized type.



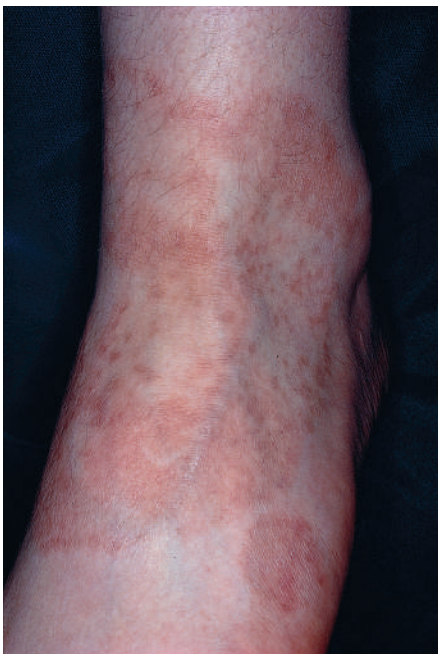
**Fig. 31-4** Generalized granuloma annulare.



**Fig. 31-2** Granuloma annulare, annular plaque composed of coalescing papules.



**Fig. 31-5** Granuloma annulare, subcutaneous and dermal lesion.



**Fig. 31-3** Granuloma annulare on the dorsal foot.

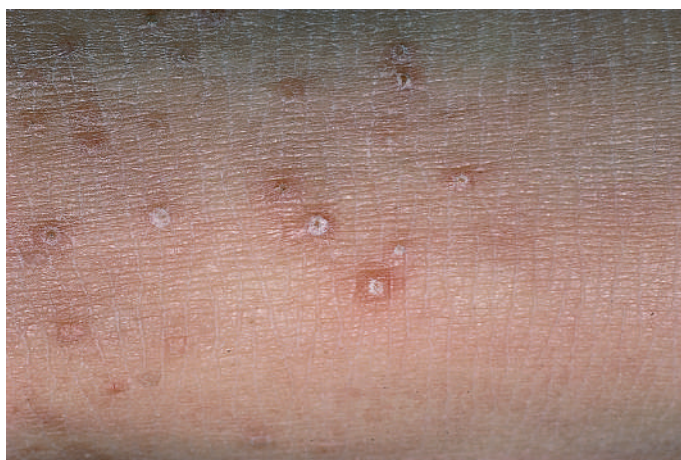remains localized to the penis or scrotum, an atypical location for GA in general. Adult women without rheumatoid arthritis may develop similar lesions around the joints.

### **Perforating granuloma annulare**

Perforating GA usually appears on the dorsal hands and presents as papules with a central keratotic core (Fig. 31-6). This core represents transepidermal elimination of the degenerated material in the center of GA lesions and clinically can resemble a pustule.

### **Palmar granuloma annulare/acute-onset painful acral granuloma annulare**

This clinical variant of GA does not resemble other forms of the disease, and the diagnosis is often missed clinically. Palmar or acral GA can be chronic but is often acute. Males and females present with the sudden onset of painful lesions on the hands and feet and a scattering of lesions at other sites. The lateral, dorsal, and marginal hands and, to less extent, the feet are affected. Lesions are tender to palpation and, when present on the palms, are dusky and may vaguely resemble erythema multiforme. Patients may have associated arthralgias and diarrhea, and they feel feverish, features of a "cytokine storm." The erythrocyte sedimentation rate (ESR) may be elevated, even above 50 mm/hr. Lesions resolve over months,



**Fig. 31-6** Perforating granuloma annulare.

at times after systemic corticosteroid or hydroxychloroquine therapy. The authors have seen one such case associated with Hodgkin disease.

### Granuloma annulare in HIV disease

Granuloma annulare may occur in persons with human immunodeficiency virus (HIV) infection at all stages of disease. Lesions are typically papular, and generalized GA is more common (60%) than localized GA (40%). Photodistributed and perforating lesions may also occur. The histology is identical to GA in the normal host. The natural history of GA in HIV patients is unknown.

### Granuloma annulare and malignant neoplasms

The occurrence of GA and a cancer in the same patient is rare, but it has been reported many times. Most of these patients are age 35–75. Half the cases occur in lymphoma/leukemia patients and half in those with solid tumors. The diagnosis of the neoplasm usually predates the diagnosis of GA but can precede it. In some cases, lesions are described as “atypical” in that they may be painful (see earlier).

### Other conditions associated with granuloma annulare

Granuloma annulare may occur after a bee sting, after waxing induced pseudofolliculitis in a patient, and after injections at a medical spa for mesotherapy or bacille Calmette-Guérin (BCG) immunization. Two groups of infectious diseases have been described as having GA-like lesions either histologically or clinically: borreliosis and tuberculosis (TB). Both Lyme disease in the United States and *Borrelia* infections in Europe have been described rarely as demonstrating interstitial granulomatous inflammation; clinically, however, at least in Europe, the lesions resemble morphea rather than GA. Despite laboratory evidence of infection, treatment of the patient with appropriate antibiotics may not lead to resolution of the skin lesions. A tuberculid can closely resemble disseminated GA, although histologically, caseous necrosis may be seen in the center of the granulomas. Treatment for TB leads to resolution of the skin lesions. In the appropriate patient, evaluation for TB and antituberculous treatment may be indicated. Medications can trigger interstitial granulomatous cutaneous reactions, at times resembling GA (see Interstitial granulomatous drug reaction).

## Granuloma annulare and eye disease

Anterior and chronic intermediate uveitis has been described in patients with localized GA. The uveitis can be unilateral or bilateral, may be mild and may respond to topical therapy, or may be aggressive, resulting in visual impairment. The frequency of uveitis in patients with GA seems to be too low to recommend that all patients with GA be screened by an ophthalmologist. However, GA patients should be questioned about visual symptoms, including reduced visual acuity. If these are present, ophthalmologic evaluation would be appropriate.

### Histology

Because there are many clinical patterns of GA, skin biopsies are often performed to confirm the diagnosis. In general, two histopathologic patterns often coexist in the same patient. The classic pattern of GA is a palisading granuloma characterized by histiocytes and epithelioid cells surrounding a central zone of altered collagen. In well-developed lesions, there is mucin deposition within the foci of altered collagen. Fibrin and nuclear dust may also be present in the degenerated foci. Lesions are most often located in the upper and middle reticular dermis but may involve the deep dermis or subcutaneous tissue. At the periphery of lesions, a leukocytoclastic vasculitis may rarely be found. IgM and C3 in the blood vessels of the skin lesions are found in about half of patients.

In the second pattern of GA, the interstitial, lesions may be entirely interstitial, or an interstitial pattern may be seen adjacent to well-formed palisaded lesions. A patchy dermal infiltrate of histiocytes and other mononuclear cells with occasional neutrophils is interspersed between collagen bundles. The patchy distribution within the dermis is best appreciated at scanning magnification. Interstitial mucin is often present in the affected areas, and is best demonstrated with a colloidal iron stain. Although these features are sufficient to confirm the diagnosis of GA, further sectioning may reveal typical palisaded granulomas. If the number of histiocytes in the infiltrate is small and lymphocytes predominate, the diagnosis of interstitial cutaneous T-cell lymphoma should be considered.

### Treatment

Patients regularly report that a biopsy of the lesion will cause its involution. Because the lesions are often asymptomatic and spontaneous involution occurs, no treatment is required in many mild cases. Numerous modalities have been reported to improve GA, suggesting that no one treatment is uniformly efficacious and the “treatment of choice.” It is best to develop a therapeutic ladder for both localized and generalized cases of GA. For localized cases, the intralesional injection of triamcinolone suspension is effective and is a reasonable initial treatment. Most patients relapse within 3–7 months. Superpotent topical corticosteroids or topical calcineurin inhibitors, or imiquimod, may be effective in some patients, especially those with more macular lesions. Phototherapy in the form of pulsed dye laser, high-intensity ultraviolet (UV) therapy with a laser designed to treat psoriasis (excimer), psoralen plus UVA (PUVA), and photodynamic therapy (PDT) can all be efficacious.

Generalized GA patients represent a major therapeutic challenge. Although systemic corticosteroids may be very effective, the high doses required and the usual immediate relapse as the steroids are tapered make this approach untenable in most situations. In addition, because dyslipidemia or metabolic syndrome may be present, systemic corticosteroids may be relatively contraindicated. Many systemic agents have been



reported as effective, but few have been tested in large numbers of patients or in blinded or controlled trials. For any treatment, 3–6 months of therapy appears necessary for efficacy or failure to be demonstrated. With all treatments, the GA may clear, only to recur when therapy is stopped. Antibiotics such as doxycycline; the combination of rifampin, ofloxacin, and minocycline, once monthly; pentoxiphylline, 400 mg three times daily; or high-dose nicotinamide, potassium iodide, oral calcitriol, or dapsone, 100 mg/day, can be effective. Fumaric acid esters over 1–18 months have also shown efficacy. Oral retinoids, especially isotretinoin, can be considered at a dose of 0.5 mg/kg or slightly more. Hydroxychloroquine and chloroquine in standard doses can be effective, and in very high doses (hydroxychloroquine at 9 mg/kg) probably will give a higher rate of response, although at potentially a greater risk of toxicity. Phototherapy in the form of narrow-band (NB) UVB, PUVA, or UVA1 can be effective in select patients. About half of patients clear with phototherapy but may relapse or may require maintenance. The combination of fumaric acid esters with PUVA appears to give the highest level of response with phototherapy. For patients with severe disease, tumor necrosis factor (TNF) inhibitors can be considered. Etanercept, infliximab, and adalimumab have all been reported to be effective. It is of interest that these medications can also cause GA. Systemic agents, such as cyclosporine, interferon (IFN) gamma, and hydroxyurea, have been reported to be effective in small series of patients. The potential toxicity of these medications limits their use to patients with significant GA.

**Adams DC, Hogan DJ:** Improvement of chronic generalized granuloma annulare with isotretinoin. *Arch Dermatol* 2002; 138:1518.

**Agrawal AK, et al:** An unusual presentation of subcutaneous granuloma annulare in associated with juvenile on-set diabetes: case report and literature review. *Pediatr Dermatol* 2012; 29:202.

**Amy de la Breteque M, et al:** Infliximab in recalcitrant granuloma annulare. *Int J Dermatol* 2014; Jun 25. [Epub ahead of print.]

**Asano Y, et al:** Generalized granuloma annulare treated with short-term administration of etretinate. *J Am Acad Dermatol* 2006; 54:S245.

**Badavanis G, et al:** Successful treatment of granuloma annulare with imiquimod cream 5%: a report of four cases. *Acta Derm Venereol* 2005; 85:547.

**Balin SJ, et al:** Myelodysplastic syndrome presenting as generalized granulomatous dermatitis. *Arch Dermatol* 2011; 147:331.

**Barzilai A, et al:** Pseudorheumatoid nodules in adults: a juxta-articular form of nodular granuloma annulare. *Am J Dermatopathol* 2005; 27:1.

**Baskan EB, et al:** A case of granuloma annulare in a child following tetanus and diphtheria toxoid vaccination. *J Eur Acad Dermatol Venereol* 2005; 19:639.

**Baskan EB, et al:** A case of generalized granuloma annulare with myelodysplastic syndrome: successful treatment with systemic isotretinoin and topical pimecrolimus 1% cream. *J Eur Acad Dermatol Venereol* 2007; 21:693.

**Brey NV, et al:** Acute-onset, painful acral granuloma annulare: a report of 4 cases and a discussion of the clinical and histologic spectrum of the disease. *Arch Dermatol* 2006; 142:49.

**Brey NV, et al:** Association of inflammatory eye disease with granuloma annulare? *Arch Dermatol* 2008; 144:803.

**Bronfenbrener R, et al:** Granuloma annulare treated with excimer laser. *J Clin Aesthet Dermatol* 2012; 5:43.

**Boyd AS:** Granuloma annulare responsive to oral calcitriol. *Int J Dermatol* 2012; 51:115.

**Cannistraci C, et al:** Treatment of generalized granuloma annulare with hydroxychloroquine. *Dermatology* 2005; 211:167.

**Chiang K, et al:** Periocular granuloma annulare: a case report and review of the literature. *Pediatr Dermatol* 2014; 31:722.

**Cho YS, et al:** Auricular granuloma annulare in a child. *Int J Dermatol* 2014; 53:e158.

**Cornejo KM, et al:** A cutaneous interstitial granulomatous dermatitis-like eruption arising in myelodysplasias with leukemic progression. *Am J Dermatopathol* 2013; 35:e26.

**Czarnecki DB, et al:** The response of generalized granuloma annulare to dapsone. *Acta Dermatol Venereol (Stockh)* 1986; 66:82.

**Dadban A, et al:** Widespread granuloma annulare and Hodgkin's disease. *Clin Exp Dermatol* 2008; 33:465.

**Dahl MV:** Granuloma annulare: long-term follow-up. *Arch Dermatol* 2007; 143:946.

**Dahl MV:** Testing lipid levels in granuloma annulare. *Arch Dermatol* 2012; 148:1136.

**De Aloe G, et al:** Congenital subcutaneous granuloma annulare. *Pediatr Dermatol* 2005; 22:234.

**Duarte AF, et al:** Generalized granuloma annulare: response to doxycycline. *J Eur Acad Dermatol Venereol* 2009; 23:84.

**Fang KS, et al:** Papules on the hands: granuloma annulare. *Arch Dermatol* 2011; 137:1647.

**Fathi K, et al:** Subcutaneous granuloma annulare of the penis associated with a urethral anomaly: case report and review of the literature. *Pediatr Dermatol* 2014; 31:e100.

**Forman SB, et al:** Penile granuloma annulare of an adolescent male: case report and review of the literature. *Pediatr Dermatol* 2008; 25:260.

**Frigerio E, et al:** Multiple localized granuloma annulare: ultraviolet A1 phototherapy. *Clin Exp Dermatol* 2007; 32:762.

**Garg S, Baveja S:** Generalized granuloma annulare treated with monthly rifampicin, ofloxacin and minocycline combination therapy. *Indian J Dermatol* 2013; 58:197.

**Goldminz AM, Gottlieb AB:** Noninfectious granulomatous dermatitides: a review of 8 disorders. Part 1 of 3. *Semin Cutan Med Surg* 2013; 32:177.

**Grundmann-Kollmann M, et al:** Cream psoralen plus ultraviolet A therapy for granuloma annulare. *Br J Dermatol* 2001; 144:996.

**Gualco F, et al:** Interstitial granuloma annulare and borreliosis: a new case. *J Eur Acad Dermatol Venereol* 2007; 21:1117.

**Gutte R, et al:** Granuloma annulare on the palms: a clinicopathological study of seven cases. *Indian J Dermatol Venereol Leprol* 2012; 78:468.

**Hall CS, et al:** Treatment of recalcitrant disseminated granuloma annulare with hydroxyurea. *J Am Acad Dermatol* 2008; 58:525.

**Herron MD, Florell SR:** Disseminated granuloma annulare accompanying *Mycobacterium tuberculosis* lymphadenitis. *Int J Dermatol* 2004; 43:961.

**Hinckley MR, et al:** Generalized granuloma annulare as an initial manifestation of chronic myelomonocytic leukemia: a report of 2 cases. *Am J Dermatopathol* 2008; 30:274.

**Hu SW, et al:** Trauma-related papular granuloma annular. *Dermatol Online J* 2013; 19:20719.

**Inui S, et al:** Disseminated granuloma annulare responsive to narrowband ultraviolet B therapy. *J Am Acad Dermatol* 2005; 53:533.

**Kang HS, et al:** Anetoderma developing in generalized granuloma annulare in an infant. *Ann Dermatol* 2014; 26 :283.

**Karsai S, et al:** Fractional photothermolysis for the treatment of granuloma annulare: a case report. *Lasers Surg Med* 2008; 40:319.

**Kawakami T, et al:** Granuloma annulare-like skin lesions as an initial manifestation in a Japanese patient with adult T-cell leukemia/lymphoma. *J Am Acad Dermatol* 2009; 60:848.

**Kiremitci U, et al:** Generalized granuloma annulare resolving to anetoderma. *Dermatol Online J* 2006; 12:16.

**Klein A, et al:** Off-label use of fumarate therapy for granulomatous and inflammatory skin diseases other than psoriasis vulgaris: a retrospective study. *J Eur Acad Dermatol Venereol* 2012; 26:1400.

**Knoell KA:** Efficacy of adalimumab in the treatment of generalized granuloma annulare in monozygotic twins carrying the 8.1 ancestral haplotype. *Arch Dermatol* 2009; 145:610.

**Kozic H, Webster GF:** Treatment of widespread granuloma annulare with adalimumab. *J Clin Aesthet Dermatol* 2011; 4:42.

**Lai JH, et al:** Evolution of granuloma annulare to mid-dermal elastolysis: report of a case and review of the literature. *J Cutan Pathol* 2014; 41:462.

**Lee SW, et al:** Generalized granuloma annular in infancy following bacille Calmette-Guérin vaccination. *Ann Dermatol* 2011; 23:S319.

**Levin NA, et al:** Resolution of patch-type granuloma annulare lesions after biopsy. *J Am Acad Dermatol* 2002; 46:426.

**Ma A, et al:** Response of generalized granuloma annulare to high-dose niacinamide. *Arch Dermatol* 1983; 119:836.

**Marcus DV, et al:** Granuloma annulare treated with rifampin, ofloxacin, and minocycline combination therapy. *Arch Dermatol* 2009; 145:787.

**Moyana Almagro B, et al:** Interstitial granulomatous dermatitis and arthritis revealing oesophageal carcinoma. *Clin Exp Dermatol* 2013; 38:501.

**Nebesio CL, et al:** Lack of an association between granuloma annulare and type 2 diabetes mellitus. *Br J Dermatol* 2002; 146:122.

**Neto Pimentel DR, et al:** Multiple deep granuloma annulare limited to the cephalic segment in childhood. *Pediatr Dermatol* 2008; 25:407.

**Pasmatzis E, et al:** Temporary remission of disseminated granuloma annulare under oral isotretinoin therapy. *Int J Dermatol* 2005; 44:169.

**Passeron T, et al:** Treatment of granuloma annulare with the 595-nm pulsed dye laser, a multicenter retrospective study with long-term follow-up. *J Eur Acad Dermatol Venereol* 2013; 27:785.

**Piaserico S, et al:** Generalized granuloma annulare treated with methylaminolevulinic acid photodynamic therapy. *Dermatology* 2009; 218:282.

**Reddy HS, et al:** Granuloma annulare anterior uveitis. *Ocul Immunol Inflamm* 2008; 16:55.

**Schnopp C, et al:** UVA1 phototherapy for disseminated granuloma annulare. *Photodermatol Photoimmunol Photomed* 2005; 21:68.

**Shimizu S, et al:** Atypical generalized granuloma annulare associated with two visceral cancers. *J Am Acad Dermatol* 2006; 54:S236.

**Shupack J, Siu K:** Resolving granuloma annulare with etanercept. *Arch Dermatol* 2006; 142:394.

**Sidwell RU, et al:** Subcutaneous granuloma annulare of the penis in 2 adolescents. *J Pediatr Surg* 2005; 40:1329.

**Simon M, et al:** Antimalarials for control of disseminated granuloma annulare in children. *J Am Acad Dermatol* 1994; 31:1064.

**Sliger BN, et al:** Treatment of granuloma annulare with the 595 nm pulsed dye laser in a pediatric patient. *Pediatr Dermatol* 2008; 25:196.

**Smith JB, et al:** Potassium iodide in the treatment of disseminated granuloma annulare. *J Am Acad Dermatol* 1994; 30:791.

**Sokumbi O, et al:** Granuloma annulare-like eruption associated with B-cell chronic lymphocytic leukemia. *J Cutan Pathol* 2012; 39:996.

**Sonthalia S, et al:** Papular granuloma annulare of palms and soles: case report of a rare presentation. *F1000Research* 2014; 3:32.

**Spadino S, et al:** Disseminated granuloma annulare: efficacy of cyclosporine therapy. *Int J Immunopathol Pharmacol* 2006; 19:433.

**Spicuzza L, et al:** Granuloma annulare as first clinical manifestation of diabetes mellitus in children: a case report. *Diabetes Res Clin Pract* 2012; 95:e55.

**Strahan JE, et al:** Granuloma annulare as a complication of mesotherapy: a case report. *Dermatol Surg* 2008; 34:836.

**Takayama K, et al:** Papular granuloma annulare with subcutaneous granulomatous reaction induced by a bee sting. *Acta Derm Venereol* 2008; 88:519.

**Thornsberry LA, English JC 3rd:** Etiology, diagnosis and therapeutic management of granuloma annulare: an update. *Am J Clin Dermatol* 2013; 14:279.

**Toepfer NJ, et al:** Three cases of subcutaneous granuloma annulare of the penis: a rare presentation of a common disease. *Urology* 2011; 78:508.

**Toro JR, et al:** Granuloma annulare and human immunodeficiency virus infection. *Arch Dermatol* 1999; 135:1341.

**Tsai J, et al:** Cutaneous tuberculid clinically resembling generalized granuloma annulare. *Clin Exp Dermatol* 2007; 32:450.

**Vázquez-López F, et al:** Localized granuloma annulare and autoimmune thyroiditis in adult women: a case-control study. *J Am Acad Dermatol* 2003; 48:517.

**Villegas RG, et al:** Pustular generalized perforating granuloma annulare. *Br J Dermatol* 2003; 149:866.

**Wanat KA, et al:** Granuloma annulare associated with cutaneous marginal zone lymphoma: a case linking a hematologic malignancy with granulomatous dermatitis. *Am J Dermatopathol* 2012; 34:844.

**Wat M, et al:** Granuloma annulare mimicking multicentric reticulohistiocytosis. *Dermatol Online J* 2013; 19:20400.

**Watanabe S, et al:** Remission of generalized erythematous granuloma annulare after improvement of hyperlipidemia and review of the Japanese literature. *Dermatol Pract Concept* 2014; 4:171.

**Webber HO, et al:** Treatment of disseminated granuloma annulare with low-dose fumaric acid. *Acta Derm Venereol* 2009; 89:295.

**Weinberg JM, et al:** Granuloma annulare restricted to Becker's nevus. *Br J Dermatol* 2004; 151:245.

**Weisenseel P, et al:** Photodynamic therapy for granuloma annulare: more than a shot in the dark. *Dermatology* 2008; 217:329.

**Wollina U, Langner D:** Treatment of disseminated granuloma annulare recalcitrant to topical therapy: a retrospective 10-year analysis with comparison of photochemotherapy alone versus photochemotherapy

plus oral fumaric acid esters. *J Eur Acad Dermatol Venereol* 2012; 26:1319.

**Wu W, et al:** Dyslipidemia in granuloma annulare. *Arch Dermatol* 2012; 148:1131.

**Yoon NY, et al:** Generalized granuloma annulare after bacille Calmette-Guérin vaccination, clinically resembling papular tuberculid. *J Dermatol* 2014; 41:109.

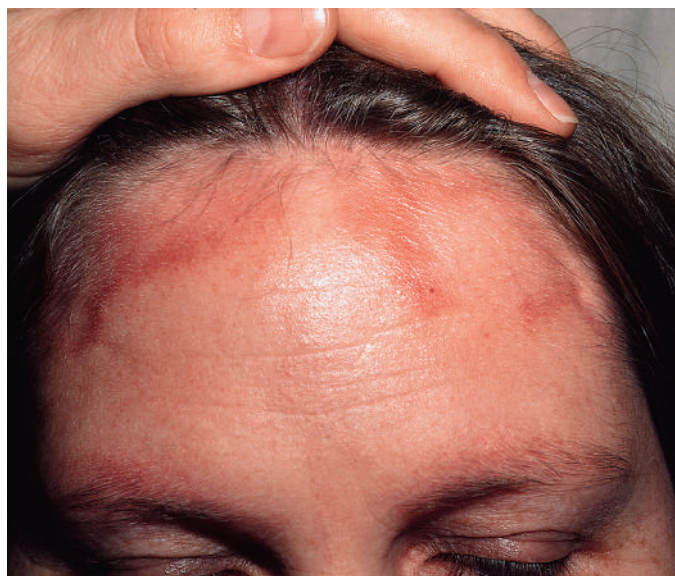**Young HS, Coulson IH:** Granuloma annulare following waxing induced pseudofolliculitis: resolution with isotretinoin. *Clin Exp Dermatol* 2000; 25:274.

**Ziemer M, et al:** Granuloma annulare: a manifestation of infection with *Borrelia*? *J Cutan Pathol* 2008; 35:1050.

### Annular elastolytic giant cell granuloma (Meischer's), annular elastolytic granuloma, and actinic granuloma (O'Brien)

Annular elastolytic giant cell granuloma (AEGCG) and actinic granuloma are unified by their histopathologic appearance. Annular elastolytic granuloma has been proposed as an alternative term to describe this spectrum of cases. Perhaps some cases called facial annular sarcoidosis and non-diabetes-associated necrobiosis lipoidica of the face can be included in this category. It is currently unclear whether these simply represent variants of GA, occurring most frequently on sun-damaged skin, or are distinct diseases.

Two patterns of AEGCG have been reported. The first is a single, asymptomatic, atrophic-appearing, yellow, thin plaque on the forehead (Meischer's granuloma) (Fig. 31-7). Fine wrinkling and loss of elasticity characterize the skin within the ring. Clinically, this pattern resembles facial necrobiosis lipoidica more than GA. The second variant consists of multiple extensor upper extremity and sometimes trunk lesions, occurs more frequently in women, and favors sun-exposed areas. In these cases, the lesions have an active erythematous border with central clearing. A papular variant has been described. Although the vast majority of cases occur in adults, children and even an infant have been affected. Except for temporal arteritis, as described later, most patients are otherwise well. However, AEGCG has been described in association with acute myelogenous leukemia (which resolved with remission and recurred with relapse of the leukemia) and pleomorphic cutaneous T-cell lymphoma. At times, as in GA, the lesions of



**Fig. 31-7** Annular elastolytic giant cell granuloma (Meischer), atrophic annular plaque.



AEGCG may heal with loss of elastic tissue and clinical features of skin laxity and anetoderma. The condition is chronic.

Actinic granuloma, as described by O'Brien, may represent the same disorder as AEGCG. It presents as papules and plaques on sun-exposed skin. Lesions are frequently numerous and may coalesce to cover much of the exposed skin. A history of onset after significant sun exposure and the distribution on physical examination should lead to suspicion of the diagnosis. A few lesions may occur on sun-protected sites or may spill over from affected areas to more photoprotected sites. Rarely, open comedones, scarring, and milia formation may be present clinically. Actinic granuloma may be associated with transepidermal elimination of damaged connective tissue or loss of elastic tissue surrounding the follicular ostia, leading to a Favre-Racouchot-like appearance. This condition affects older adults (usually over age 50) and can be intensely pruritic. Actinic granuloma is not associated with diabetes mellitus, but in numerous reports, it occurred in patients with temporal arteritis. It is speculated that the vasculitis is also caused by actinic injury to the connective tissue surrounding the temporal artery. Conjunctival involvement has been reported.

Histologically, all these conditions show a characteristic histology. The dermal infiltrate of macrophages is largely interstitial, and well-formed palisaded granulomas are uncommon. Multinucleated giant cells, often quite large, are numerous. Mucin is scant or lacking. The macrophages characteristically contain fragments of actinically damaged elastic tissue (elastophagocytosis). When this typical histology is seen in concert with the classic clinical features previously noted, it may be reasonable to make these specific diagnoses. These conditions cannot, however, be diagnosed on clinical or histologic grounds alone. Some cases with the clinical features of AEGCG or actinic granuloma will show histology more characteristic of typical GA or even sarcoidosis, suggesting a spectrum of both clinical and histologic features in these patients.

Treatment of AEGCG (annular elastolytic granuloma) and actinic granuloma has been difficult. Aggressive sun protection should be encouraged for patients with lesions primarily on sun-exposed skin. Topical and intralesion corticosteroids and topical calcineurin inhibitors can be used for individual lesions. Many patients respond to systemic corticosteroids, but relapse immediately when the steroids are tapered or discontinued. Oral antimalarials are at times effective. Insulin improved diabetic control and the actinic granuloma in one patient. Other anecdotal treatments include oral retinoids, fumaric acid, PUVA, pentoxifylline, tranilast, dapsone, cyclosporine, and methotrexate.

Neutrophilic sebaceous adenitis presents with asymptomatic annular plaques on the face of men more than women. Fewer than 10 cases have been reported. It may be photosensitive. The condition resolves spontaneously after weeks to months without scarring. Histologically, in early lesions there is a neutrophilic, multifocal infiltrate around sebaceous glands with necrosis of some sebocytes. In later lesions the inflammation is primarily lymphohistiocytic. In addition to granuloma annulare/annular elastolytic giant cell granuloma, tinea faciei, pemphigus foliaceus, a gyrate erythema, and lupus erythematosus are in the clinical differential diagnosis.

**Andreu-Barasoain M, et al:** Long-lasting interstitial generalized granuloma annulare on sun-exposed areas. *Photoderm Photoimmunol Photomed* 2012; 28:216.

**Berliner JG, et al:** The sarcoidal variant of annular elastolytic granuloma. *J Cutan Pathol* 2013; 40:917.

**Boussault P, et al:** Primary cutaneous CD4+ small/medium-sized pleomorphic T-cell lymphoma associated with an annular elastolytic giant cell granuloma. *Br J Dermatol* 2009; 160:1126.

**De Oliveira FL, et al:** Hybrid clinical and histopathological pattern in annular lesions: an overlap between annular elastolytic giant cell

granuloma and granuloma annulare. *Case Rep Dermatol Med* 2012; 2012:102915.

**Coelho R, et al:** Annular lesions on the forehead of a 44-year-old woman. *Clin Exp Dermatol* 2010; 35:e48.

**Gallagher MJ, et al:** Actinic granuloma of the conjunctiva. *Br J Ophthalmol* 2003; 87:1044.

**Garg A, et al:** Annular elastolytic giant cell granuloma heralding onset and recurrence of acute myelogenous leukemia. *Arch Dermatol* 2006; 142:532.

**Gass JK, et al:** Generalized granuloma annulare in a photosensitive distribution resolving with scarring and milia formation. *Clin Exp Dermatol* 2009; 34:e53.

**Goldminz AM, Gottlieb AB:** Noninfectious granulomatous dermatitides: a review of 8 disorders. Part 2 of 3. *Semin Cutan Med Surg* 2013; 32:e1.

**Klemke CD, et al:** Generalized annular elastolytic giant cell granuloma. *Dermatology* 2003; 207:420.

**Lee HW, et al:** Annular elastolytic giant cell granuloma in an infant: improvement after treatment with oral tranilast and topical pimecrolimus. *J Am Acad Dermatol* 2005; 53:S244.

**Marmon S, et al:** Papular variant of annular elastolytic giant-cell granuloma. *Dermatol Online J* 2012; 18:23.

**Morita K, et al:** Papular elastolytic giant cell granuloma: a clinical variant of annular elastolytic giant cell granuloma or generalized granuloma annulare? *Eur J Dermatol* 1999; 9:647.

**Muller FB, Groth W:** Annular elastolytic giant cell granuloma: a prodromal stage of mid-dermal elastolysis? *Br J Dermatol* 2007; 156:1377.

**Özkaya-Bayazit E, et al:** Annular elastolytic giant cell granuloma: sparing of a burn scar and successful treatment with chloroquine. *Br J Dermatol* 1999; 140:525.

**Sniezek PJ, et al:** Annular atrophic plaques on the arms of a 57-year-old woman. *Arch Dermatol* 2006; 142:775.

**Stein JA, et al:** Actinic granuloma. *Dermatol Online J* 2007; 13:19.

**Sudy E, et al:** Open comedones overlying granuloma annulare in a photoexposed area. *Photodermatol Photoimmunol Photomed* 2006; 22:273.

**Terui T, et al:** Annular elastolytic sarcoidosis of the face. *Eur J Dermatol* 1998; 8:127.

**Ventura F, et al:** Two cases of annular elastolytic giant cell granuloma: different response to the treatment. *Dermatol Online J* 2010; 16:11.

## Interstitial granulomatous drug reaction

Interstitial granulomatous drug reaction (IGDR) is an uncommon but increasingly recognized pattern of adverse reactions to medication. Cases reported as GA induced by a medication often have an "interstitial" pattern, and some of the same medications cause both IGDR and "GA," so medication-induced granuloma annulare and IGDR are considered together here. Although it may occur within a few days of starting the medication, most patients with IGDR have been taking the medication for months to years. A wide variety of medications have been implicated, including calcium channel blockers (most common cause reported), lipid-lowering agents, angiotensin-converting enzyme (ACE) inhibitors, diuretics, nonsteroidal anti-inflammatory drugs (NSAIDs), antihistamines, anticonvulsants, antidepressants, allopurinol, darifenacin, sorafenib, ganciclovir, trastuzumab, strontium ranelate, sennoside (common over-the-counter laxative), Chinese herbs, and even soy. Immunomodulatory medications, including thalidomide, lenalidomide, anakinra, IFNs alpha and beta, and TNF inhibitors have been implicated in causing IGDR in many cases. At times, drug-induced hypersensitivity syndrome (DIHS/DRESS) cutaneous eruptions will have the histology of IGDR.

Clinically, the lesions are erythematous annular plaques with an indurated border and sometimes a tendency to central clearing. Lesions favor the creases (groin, axillae, popliteal fossae) but may also affect the trunk, proximal extremities, palms, and soles. Lesions may be photodistributed, affecting the face and dorsal extensor forearm and hands. Pruritus is minimal or absent. Mucous membranes are spared.

Histologically, there is a diffuse deep dermal infiltrate that is perivascular but has a prominent interstitial component. The inflammatory infiltrate is centered in the lower two thirds of the dermis; it contains neutrophils, eosinophils, histiocytes, and multinucleated giant cells. Degenerated collagen bundles may be surrounded by histiocytes, neutrophils, and eosinophils, forming “Churg-Strauss” granulomas, and mucin is usually scant or absent. Necrobiotic granulomas are usually incomplete but at times have been reported to resemble those seen in GA. Unique features that should suggest IGDR over GA include an interface component and “atypical” lymphocytes in the infiltrate. The histologic differential diagnosis includes interstitial granulomatous dermatitis associated with arthritis, palisaded neutrophilic granulomatous dermatitis, papular eruption of methotrexate, and interstitial GA. Lesions resolve over months once the offending ingested is stopped.

**Alvarez-Perez A, et al:** Granuloma annulare photoinduced by paroxetine. *Photoderm Photoimmunol Photomed* 2012; 28:47.

**Cassone G, Tumati B:** Granuloma annulare as a possible new adverse effect of topiramate. *Int J Dermatol* 2014; 53:259.

**Chen YC, et al:** Interstitial granulomatous drug reaction presenting as erythroderma: remission after discontinuation of enalapril maleate. *Br J Dermatol* 2008; 158:1143.

**Deng A, et al:** Interstitial granulomatous dermatitis associated with the use of tumor necrosis factor alpha inhibitors. *Arch Dermatol* 2006; 142:198.

**Du XF, et al:** Interstitial granulomatous drug reaction to a Chinese herb extract. *Eur J Dermatol* 2012; 22:419.

**Dyson SW, et al:** Interstitial granulomatous dermatitis secondary to soy. *J Am Acad Dermatol* 2004; 51:S105.

**Fernando SL, et al:** Drug-induced hypersensitivity syndrome with superficial granulomatous dermatitis—a novel finding. *Am J Dermatopathol* 2009; 31:611.

**Fujita Y, et al:** A case of interstitial granulomatous drug reaction due to sennoside. *Br J Dermatol* 2004; 150:1028.

**Goldminz AM, Gottlieb AB:** Noninfectious granulomatous dermatitides: a review of 8 disorders. Part 3 of 3. *Semin Cutan Med Surg* 2013; 32:e7.

**Groves C, et al:** Interstitial granulomatous reaction to strontium ranelate. *Arch Dermatol* 2008; 144:268.

**Kim MS, et al:** Allopurinol-induced DRESS syndrome with a histologic pattern consistent with interstitial granulomatous drug reaction. *Am J Dermatopathol* 2014; 36:193.

**Lim AC, et al:** A granuloma annulare-like eruption associated with the use of amlodipine. *Australas J Dermatol* 2002; 45:24.

**Marcollo Pini A, et al:** Interstitial granulomatous drug reaction following intravenous ganciclovir. *Br J Dermatol* 2008; 158:1391.

**Martin G, et al:** Interstitial granulomatous dermatitis with arthritis associated with trastuzumab. *J Eur Acad Dermatol Venereol* 2010; 24:493.

**Martinez-Moran C, et al:** Interstitial granulomatous drug reaction to sorafenib. *Arch Dermatol* 2011; 147:1118.

**Martorell-Calatayud A, et al:** Interstitial granulomatous drug reaction to adalimumab. *Am J Dermatopathol* 2010; 32:408.

**Mason HR, et al:** Interstitial granulomatous dermatitis associated with darifenacin. *J Drugs Dermatol* 2008; 7:895.

**Ratnarathorn M, et al:** Disseminated granuloma annulare: a cutaneous adverse effect of anti-TNF agents. *Indian J Dermatol* 2011; 56:752.

**Regula CG, et al:** Interstitial granulomatous drug reaction to anakinra. *J Am Acad Dermatol* 2008; 59:S25.

**Voulgari PV, et al:** Granuloma annulare induced by anti-tumour necrosis factor therapy. *Ann Rheum Dis* 2008; 67:567.

**Yazganoglu KD, et al:** Interstitial granulomatous drug reaction due to thalidomide. *J Eur Acad Dermatol Venereol* 2009; 23:490.

## Granuloma multiforme (Leiker)

Granuloma multiforme (GM) is seen most frequently in central Africa, where it is a common disorder, and rarely elsewhere. It affects adults over age 40 and is more common in women. Lesions are most frequently found on the upper trunk and arms and in sun-exposed areas. GM begins as small papules

that evolve within 1 year into round or oval plaques up to 15 cm in diameter. The active edge of lesions may be elevated to as much as 4 mm in height and the center slightly depressed and hypopigmented. Pruritus can occur, and coalescing lesions may form unusual polycyclic shapes. The course is chronic. GM is, most importantly, separated from tuberculoid leprosy. Histologically, GM resembles GA, but multinucleated giant cells are prominent. Giant cells typically contain phagocytosed connective tissue, and elastic tissue is decreased in the areas affected by the granulomas. GM shares many features with AEGCG and actinic granuloma, or GA of sun-exposed skin, and in fact may be considered identical to these disorders.

**Kumari R, et al:** Granuloma multiforme: a report from India. *Indian J Dermatol Venereol Leprol* 2009; 75:296.

## Necrobiotic xanthogranuloma

Necrobiotic xanthogranuloma (NXG) is an uncommon multi-system disease with prominent skin findings. The cause is unknown. Some consider it to exist along a spectrum of “adult orbital xanthogranulomatous disease” (AOXGD), which also includes adult-onset xanthogranuloma (AOX), and adult-onset asthma with periocular xanthogranuloma (AAPOX). NXG is gradually progressive, affecting men and women equally, and beginning on average at about age 50 (range 25–80 or older). The most common site affected is the periorbital area (>80% of patients). Multicentric involvement is typical. Lesions may be localized or initially present in scars. The characteristic skin lesions are yellow (xanthomatous) plaques and nodules. Periorbitally, they may be mistaken for xanthelasma, but they are deep, firm, and indurated and may extend into the orbit. The trunk and proximal extremities may have orange-red plaques with an active red border and an atrophic center with superficial telangiectasias (Fig. 31-8). These plaques may grow to 25 cm in diameter. The skin lesions ulcerate in 50% of cases, leading to atrophic scarring. Acral nodules may also occur, some localized solely to the subcutaneous tissue. Extracutaneous involvement most often affects the eyes. Patients may complain of burning, itching, or pain around or in the eyes. Diplopia and inflammation in various compartments of the eye can occur, including conjunctivitis, keratitis, scleritis, uveitis, iritis, ectropion, or proptosis. Ulceration and scarring of the plaques and distortion of the eye may lead to visual occlusion. Blindness may result. Lymphadenopathy, hepatosplenomegaly, and mucosal, myocardial, and pulmonary lesions may occur. There is a monoclonal IgG (usually  $\kappa$ ) paraproteinemia in 80% of cases and rarely an IgA

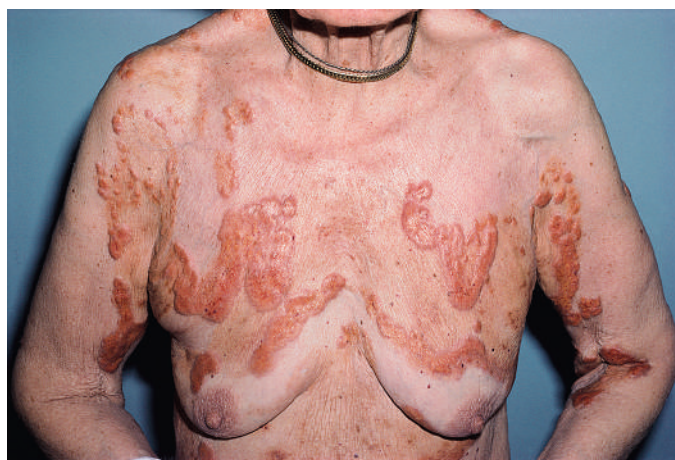

Fig. 31-8 Necrobiotic xanthogranuloma.



paraproteinemia. Thrombocytopenia, neutrophilia, neutropenia, and eosinophilia may be present. The bone marrow may show leukopenia, plasmacytosis (25–50% of patients), or frank myeloma (10–20%). In some patients, a myelodysplastic syndrome may be present or may develop (chronic lymphocytic lymphoma, Hodgkin or non-Hodgkin lymphoma). The NXG predates the development of the myeloma or myelodysplastic syndrome by an average of 2.5 years, but as long as 20 years.

Histologically, there are extensive zones of degenerated collagen surrounded by palisaded macrophages. These macrophages are of various forms: foamy, Touton cells, epithelioid, and giant cells, sometimes with more than 50 nuclei. Atypical multinucleated giant cells with multiple nuclei clustered at one end of the cell (polarized nuclei) are seen in 80% or more of cases. The process extends into the fat, obliterating fat lobules. Cholesterol clefts and extracellular lipid deposits are prominent, but not universally present. Within this process is a perivascular and interstitial infiltrate of lymphocytes and plasma cells. Lymphoid follicles are present. In the skin, the lymphoid aggregates are polytypic. The histologic differential diagnosis includes necrobiosis lipoidica and other histiocytoses. NXG has more atypical and Touton giant cells, lymphoid nodules, and cholesterol clefts. As in plane xanthomas seen with paraproteinemia, the associated monoclonal gammopathy of undetermined significance (MGUS) appears to enhance the intracellular accumulation of cholesterol within the macrophages/histiocytes.

The treatment is usually directed at the paraprotein or underlying malignancy. Treatment of the malignancy may lead to resolution of the NXG lesions. Other treatments have included systemic corticosteroids, IFN alpha, alkylating agents (e.g., chlorambucil, cyclophosphamide, melphalan), plasmapheresis, or local radiation therapy (for eye lesions). Numerous reports have documented response to high-dose intravenous immunoglobulin. In addition, extracorporeal photopheresis and thalidomide have induced remissions. Simple excision is an option, but lesions may recur.

**Efebera Y, et al:** Complete response to thalidomide and dexamethasone in a patient with necrobiotic xanthogranuloma associated with monoclonal gammopathy: a case report and review of the literature. *Clin Lymphoma Myeloma Leuk* 2011; 11:298.

**Ghiasi N, et al:** Necrobiotic xanthogranuloma as an unusual cause of refractive chronic bilateral leg ulceration. *Int J Low Extrem Wounds* 2012; 11:293.

**Hallerman C, et al:** Successful treatment of necrobiotic xanthogranuloma with intravenous immunoglobulin. *Arch Dermatol* 2010; 146:957.

**Hashemi P, et al:** Necrobiotic xanthogranuloma of the extremities with paraproteinemia and without periorbital involvement at presentation. *Cutis* 2012; 89:41.

**Kadakia S, et al:** Spectacular skin nodules: cutaneous necrobiotic xanthogranuloma without paraproteinemia. *Indian J Dermatol* 2012; 57:396.

**Khan M, et al:** An unusual subcutaneous lump. *Clin Exp Dermatol* 2012; 37:808.

**Koch PS, et al:** Erythematous papules, plaques and nodular lesions on the trunk and within preexisting scars. *JAMA Dermatol* 2013; 149:1103.

**Lam K, et al:** Bilateral necrobiotic xanthogranuloma of the eyelids followed by a diagnosis of multiple myeloma 20 years later. *Ophthalmol Plast Reconstr Surg* 2013; 29:e118.

**Lisewski W, et al:** Treatment of refractory necrobiotic xanthogranulomas with extracorporeal photopheresis and intravenous immunoglobulin. *Dermatol Ther* 2014; 27(5):268–271.

**Meyer S, et al:** Cyclophosphamide-dexamethasone pulsed therapy for treatment of recalcitrant necrobiotic xanthogranuloma with paraproteinemia and ocular involvement. *Br J Dermatol* 2005; 153:443.

**Minami-Hori M, et al:** Adult orbital xanthogranulomatous disease: adult-onset xanthogranuloma of periorbital location. *Clin Exp Dermatol* 2011; 36:628.

**Naghashpour M, et al:** Nonnecrobiotic necrobiotic xanthogranuloma as an initial manifestation of paraproteinemia and small lymphocytic

lymphoma in a patient with Sjögren syndrome. *Am J Dermatopathol* 2011; 33:855.

**Peyman A, et al:** Necrobiotic xanthogranuloma associated with necrotizing scleritis. *Am J Dermatopathol* 2012; 34:644.

**Rose A, et al:** Necrobiotic xanthogranuloma. *Dermatol Online J* 2012; 18:30.

**Ryan E, et al:** Necrobiotic xanthogranuloma: response to chlorambucil. *Australas J Dermatol* 2012; 55:e23.

**Santosaputri E, et al:** A multisystem granulomatous disease: necrobiotic xanthogranuloma with hepatic involvement. *Med J Aust* 2014; 200:490.

**Sutton L, et al:** Treatment of necrobiotic xanthogranuloma with 2-chlorodeoxyadenosine. *SKINmed* 2013; 11:121.

**Wood AJ, et al:** Necrobiotic xanthogranuloma: a review of 17 cases with emphasis on clinical and pathologic correlation. *Arch Dermatol* 2009; 145:279.

**Yasukawa K, et al:** Necrobiotic xanthogranuloma: isolated skeletal muscle involvement and unusual changes. *J Am Acad Dermatol* 2005; 52:729.

## SARCOIDOSIS

Sarcoidosis is a chronic multisystem inflammatory disease characterized by granuloma formation in most affected tissues. Sarcoidosis occurs worldwide. In Europe, it is most prevalent in Scandinavia, especially in Sweden, with a prevalence of 64 per 100,000 population. In the United Kingdom, the rate is 20 per 100,000, and in France and Germany, about 10 in 100,000, with lower rates in Spain and Japan of 1.4 in 100,000. In the United States, the southeastern states and certain urban centers (New York City, Detroit, Washington, DC) show the highest prevalence, and there is a marked racial variation, with a rate of 10.9 per 100,000 for white persons and 35.5 per 100,000 for African Americans. Women are affected slightly more often than men, with the highest incidence in African American women between ages 30 and 39. The lifetime risk for the development of sarcoidosis is 0.85% for white and 2.4% for black U.S. residents. The disease begins most frequently between ages 20 and 40, with a second peak at ages 65–69. Patients with late-onset sarcoidosis are five times more frequently women than men, have uveitis, and have specific skin lesions in one third of cases.

Interleukin-2 (IL-2)- and IFN- $\gamma$ -secreting CD4+ helper T (Th) cells are important in causing lesions, as are other Th1 and Th17 cytokines. Several genetic associations have been made with sarcoidosis, but the underlying cause still remains a mystery. HLA-DQB1\*0201 and HLA-DRB1\*0301 are strongly associated with acute disease and a good prognosis. Mutations in the promoter region of TNF are associated with erythema nodosum (EN) in sarcoidosis in Caucasians, and a variant in intron 1 of the lymphotoxin alpha (*LTA*) gene is associated with EN in female Caucasian sarcoidosis patients. Polymorphisms in the IL-23 receptor are associated with sarcoidal uveitis.

Cutaneous involvement is present in 25–30% of patients with sarcoidosis and may be classified as specific, which reveals granulomas on biopsy, or nonspecific, which is mainly reactive, such as EN. In about 20% of patients, the skin lesions appear before the systemic disease; in 50%, the skin and systemic lesions appear simultaneously; and in 30%, the skin lesions appear up to 10 years after the systemic disease has occurred. This is often coincidental with the tapering of systemic corticosteroids for pulmonary sarcoidosis. The cutaneous manifestations of sarcoidosis are varied, and numerous morphologic lesion types have been described, including: papules, nodules, plaques, subcutaneous nodules, scar sarcoidosis, erythroderma, and ulcerations. The lesions may be verrucous, ichthyosiform, hypomelanotic, psoriasiform, or alopecic. They are usually multiple, firm, and elastic when palpated. They extend to involve the entire thickness of the dermis. The overlying epidermis may be slightly

thinned, discolored, telangiectatic, or scaly. The color is faint, showing dull tints of red, purple, brown, or yellow, according to the stage of development. Usually, the lesions are asymptomatic, but approximately 10–15% of patients itch. There is a racial difference in the frequency of cutaneous lesions in sarcoidosis. Among white patients, EN is as common as the specific cutaneous manifestations, and both types of cutaneous involvement occur in about 10% of white patients with sarcoidosis. In black patients, EN is much less common; however, specific cutaneous manifestations occur in 50% or more of patients. The skin lesions in general do not correlate with the extent or nature of systemic involvement or with prognosis. The exceptions are EN, which is associated with a good prognosis, and subcutaneous sarcoidosis and lupus pernio. The morphologic types of sarcoidosis are discussed next, and when possible, the relationship to systemic sarcoidosis.

### Erythema nodosum in sarcoidosis

Erythema nodosum is the most common nonspecific cutaneous finding in sarcoidosis. EN rarely occurs in sarcoidosis beginning after age 65. Sarcoidosis may first appear with fever, polyarthralgias, uveitis, bilateral hilar adenopathy, fatigue, and erythema nodosum. This combination, known as Löfgren syndrome, occurs frequently in Scandinavian whites and is uncommon in American blacks. The typical red, warm, and tender subcutaneous nodules of the anterior shins are distinctive and are most frequently seen in young women. The face, upper back, and extensor surfaces of the upper extremities may less frequently be involved. There is a strikingly elevated ESR, frequently above 50 mm/hr. EN is associated with a good prognosis, with the sarcoidosis involuting within 2 years of onset in 80% of patients. Conversely, the absence of EN is a risk factor for persistent disease activity. Sweet syndrome may also rarely be seen in association with sarcoidosis as a nonspecific finding.

### Papular sarcoid

Papules are the most common morphology of cutaneous sarcoidosis and are usually less than 1 cm in diameter. Lesions may be localized or generalized, in which case small papules predominate (Fig. 31-9). This is also known as miliary sarcoid. The papules are especially numerous over the face, eyelids, neck, and shoulders. Plaques may occur by the expansion or

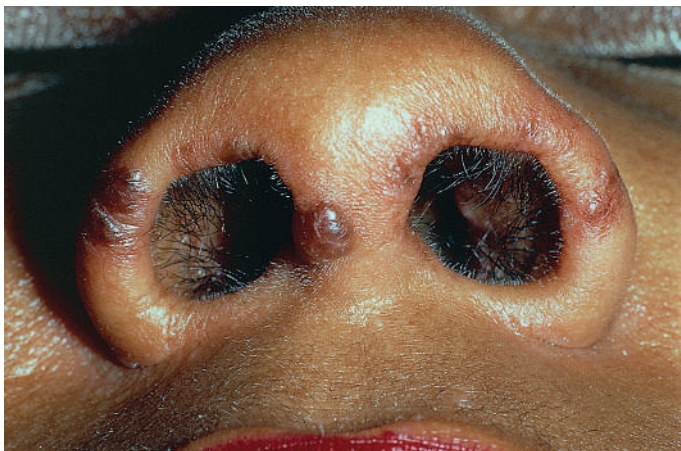

Fig. 31-9 Sarcoidosis, characteristic papules on the nares.

coalescence of papules. In time, the lesions involute to faint macules. Hyperkeratosis may rarely be prominent, giving the lesions a verrucous appearance. “Papular sarcoidosis of the knee” is distinctive, in that disease is often limited to this site. In this region, the sarcoidal granulomas often contain foreign bodies. In Caucasians, it often occurs in the context of Löfgren syndrome (see earlier) and has a good prognosis. Papular lesions along the alar rim in African Americans, in contrast, may be the first evidence of lupus pernio (see later) and portend a poor prognosis.

### Annular sarcoidosis

Papular lesions may coalesce or be arranged in annular patterns, usually with a red-brown hue (Fig. 31-10). On palpation, the lesions are indurated. Central clearing with hypopigmentation, atrophy, and scarring may occur. Lesions favor the head and neck and are usually associated with chronic sarcoidosis. Alopecia may result in the center of the lesion. Annular plaques of sarcoidosis can preferentially develop in sun-exposed areas.

### Hypopigmented sarcoidosis

Hypopigmentation may be the earliest sign of sarcoidosis and is usually diagnosed in darkly pigmented races. Lesions vary from a few millimeters to more than 1 cm in diameter and favor the extremities. Although they appear macular, a dermal or subcutaneous component is often palpable.

### Lupus pernio

Lesions typically are brown to violaceous, smooth, shiny plaques on the head and neck, especially the nose (Fig. 31-11), cheeks, lips, forehead, and ears. They can be very disfiguring. Involvement of the nasal mucosa and underlying bone may occur and lead to nasal perforation and collapse of the nasal bridge. Upper aerodigestive tract involvement is also common. Ear, nose, and throat (ENT) evaluation is recommended. In three quarters of lupus pernio patients, chronic fibrotic respiratory tract involvement is found. In 43%, lupus pernio is associated with granulomas in the bones (punched-out cysts), most often of the fingers. Chronic ocular lesions occur in 37% of patients. Sarcoid involving the sinus is associated with lupus pernio in 50% of cases. Lupus pernio is typically seen in women in their fourth or fifth decade. The skin lesions rarely involute spontaneously. At times, lupus pernio may resemble rhinophyma. It is important to make the correct diagnosis,

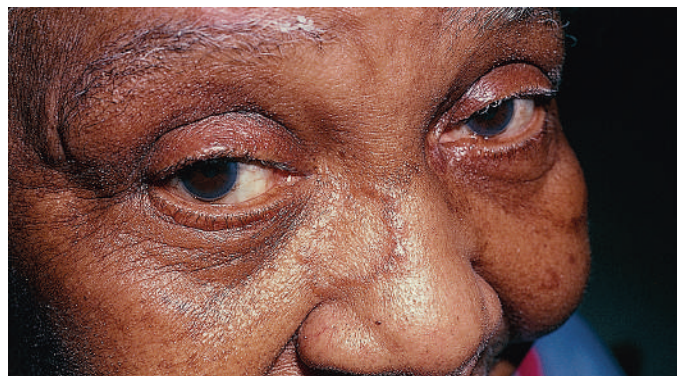
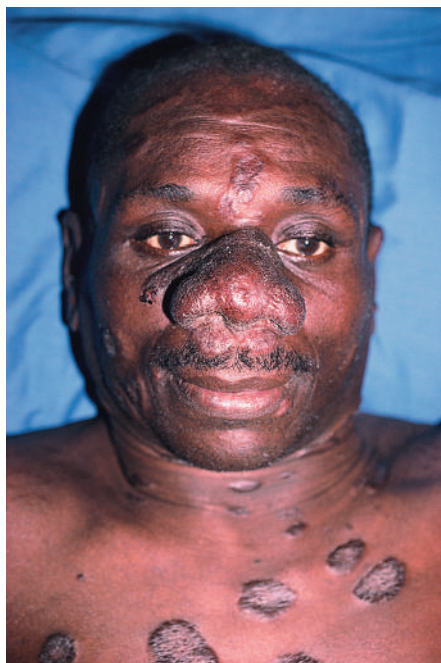
Fig. 31-10 Sarcoidosis, annular plaque.





**Fig. 31-11** Sarcoidosis, lupus pernio with rhinophymatous nasal changes.

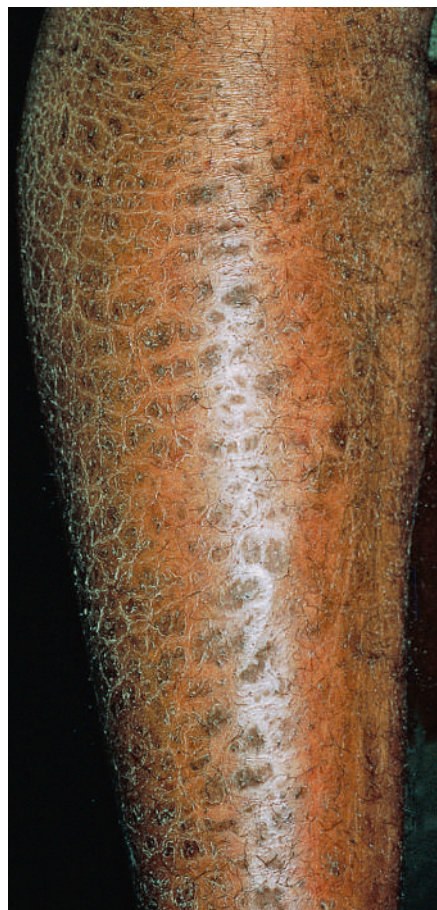because ulceration of sarcoidal lesions may occur with laser treatment, even with pulsed dye laser.

### Ulcerative sarcoidosis

Ulcerative sarcoidosis is very rare, affecting about 0.5% of patients with sarcoidosis. It affects primarily blacks, but it is also well recognized in Japanese. It is two to three times more common in women than men. In one third of cases, it is the presenting finding of sarcoidosis, except in Japan, where it is usually a late finding in patients with known sarcoidosis. The ulcerations may occur *de novo* or in sarcoidal plaques. Lesions favor the lower extremities, but most patients have lesions in more than one anatomic region. Trauma may be the inciting event. The clinical appearance may not be specific, but skin biopsies are diagnostic. Lupus pernio may also be present. Many patients have multisystem sarcoidosis, although infrequently, no other evidence of sarcoidosis is found. Biopsies may show necrosis in the center of sarcoidal granulomas. Methotrexate, which can be therapeutic in sarcoidosis, may also lead to ulceration in sarcoidosis patients.

### Subcutaneous sarcoidosis

Subcutaneous sarcoidosis is also known as Darier-Roussy sarcoïd and consists of a few to numerous 0.5–3 cm, deep-seated nodules on the trunk and extremities; only rarely do they appear on the face. The overlying epidermis may be normal (30%), erythematous (50%), or slightly violaceous (10%). The lesions are usually asymptomatic. About 90% of patients will have multiple lesions, and the upper extremity is most frequently affected (virtually 100% of patients). Lesions on the upper extremity have a tendency to form indurated linear bands from the elbow to the hand on the cubital side of the forearm. The amount of subcutaneous involvement in the upper extremity may be so extensive as to simulate chronic cellulitis. A biopsy is usually required to confirm the diagnosis. About 90% of patients also will have systemic involvement, usually bilateral hilar adenopathy. Overall, however, the prognosis is good.



**Fig. 31-12** Sarcoidosis, ichthyosiform type; biopsy showed noncaseating granuloma, although there was no palpable dermal component to the lesions.

### Plaques

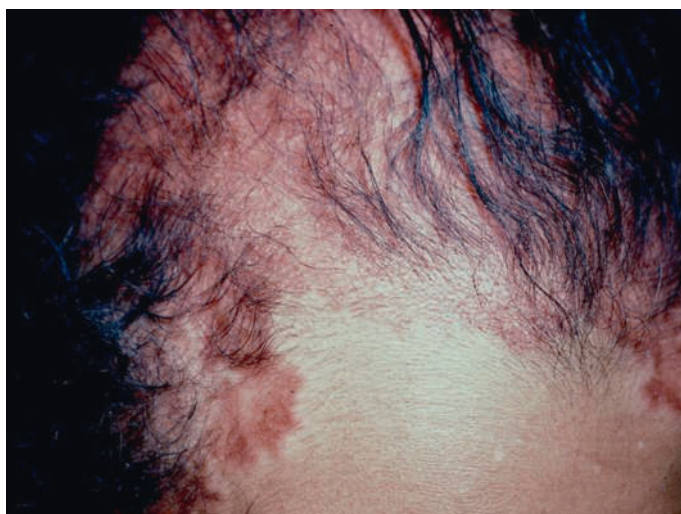
These distinctive lesions are flat-surfaced, slightly elevated plaques that appear with greatest frequency on the cheeks, limbs, and trunk symmetrically. Superficial nodules may be superimposed, and coalescence of plaques may lead to serpiginous lesions. Involvement of the scalp may lead to permanent alopecia. The finding of alopecia in an annular plaque with a raised border should raise the diagnostic consideration of sarcoidosis.

### Erythrodermic sarcoidosis

Erythrodermic sarcoidosis is an extremely rare form of sarcoidosis. A diffuse infiltrative erythroderma of the skin usually begins as erythematous, scaling patches that merge to involve large portions of the body. A biopsy is confirmatory, but the diagnosis can be clinically suspected if small, “apple jelly” papules are seen on diascopy throughout the erythroderma.

### Ichthyosiform sarcoidosis

Ichthyosiform sarcoidosis resembles ichthyosis vulgaris or acquired ichthyosis, with fine scaling usually on the distal extremities (Fig. 31-12). It is virtually always seen in nonwhite persons, especially African Americans. Almost all patients have or will develop systemic disease. In 75% of patients, the skin lesions follow or occur at the same time as the diagnosis of systemic sarcoidosis. Although the lesions have no palpable component, a biopsy will reveal dermal noncaseating granulomas.



**Fig. 31-13** Sarcoidosis, scarring alopecia of scalp.

### Alopecia

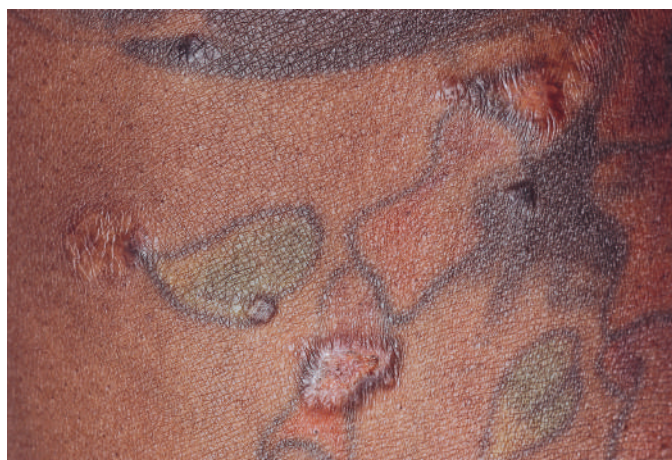Alopecia on the scalp caused by sarcoidosis can have multiple morphologies. Plaques may extend into and involve the scalp, leading to scarring hair loss (Fig. 31-13). More rarely, macular lesions from one to several centimeters in diameter appear on the scalp and closely resemble alopecia areata. This form may be permanent or reversible. Diffuse alopecia, scaly plaques resembling seborrheic dermatitis, and cicatricial lesions resembling discoid lupus erythematosus or pseudopelade may also occur. A biopsy of all forms of alopecic sarcoid will reveal dermal granulomas and sometimes loss of follicular structures. Scalp sarcoidosis is virtually always seen in African or African American women. In cases where sarcoidosis affects the scalp, causing alopecia, the patient almost always has other cutaneous lesions, and the vast majority of cases will demonstrate systemic involvement. Syringotropic involvement may lead to hypohidrosis.

### Morpheaform sarcoidosis

Extremely rarely, specific cutaneous lesions of sarcoidosis may be accompanied by substantial fibrosis and simulate morphea. Less than 10 cases have been described to date. Most often, the lesions are localized and resemble linear morphea. Skin biopsy will demonstrate noncaseating granulomas. African American women are most frequently affected. This form of sarcoidosis responds favorably to antimalarial therapy.

### Sarcoidosis in scars (scar sarcoid)

Infiltration and elevation of tattoos and old, flat scars are two variants of scar sarcoid. Previously flat scars become raised and may become erythematous or violaceous. These lesions may be confused with hypertrophic scars. Infiltration of tattoos may be the first manifestation of sarcoidosis and can be confused with a granulomatous hypersensitivity reaction to the tattoo pigment (Fig. 31-14). Cosmetic tattooing, as may be performed in a dermatology office, may result in sarcoidal granulomas in patients with pulmonary sarcoidosis. Hyaluronic acid injections can also be complicated by the development of sarcoidal lesions in patients with sarcoidosis. As noted later, patients with hepatitis C virus (HCV) infection receiving IFN therapy are at high risk for developing sarcoidosis and



**Fig. 31-14** Sarcoidosis, papules and plaques arising in a tattoo.

can develop disfiguring sarcoidal reactions after cosmetic filler injections. Similar granulomatous reactions may occur in the earlobe after ear piercing and represent granulomatous allergic dermatitis to metals introduced by the procedure or the earring. Titanium, nickel, cobalt, zinc, gold, and palladium can all be the allergen.

From 22% to 77% of biopsies from patients with cutaneous sarcoidosis will contain polarizable foreign material, suggesting that scar sarcoidosis is very common. The foreign material seems to be a nidus that favors the development of sarcoidal granulomas. Scar sarcoid sometimes occurs in patients with acute disease and EN, especially if the lesions are small papules on the knees. It may also occur in patients with chronic sarcoidosis. The presence of polarizable material in a granulomatous process does not confirm the diagnosis of "foreign body granuloma," but rather should result in evaluation of the patient for evidence of systemic sarcoidosis. When foreign material is found, infection must be carefully excluded if no other features of sarcoidosis are found.

### Nail sarcoidosis

Sarcoidosis of the nail can affect any compartment of the nail, causing onycholysis, subungual hyperkeratosis (nail bed involvement), brittle nails, pitting, ridging, or rough nails (trachyonychia), distal matrix involvement, and even pterygium (nail matrix destruction). Nails may be hyperpigmented. Sarcoidal dactylitis and phalangeal bone disease as well as intrathoracic sarcoidosis often accompany nail sarcoidosis. Drumstick dactylitis is associated with lupus pernio.

### Mucosal sarcoidosis

The lesions in the mouth are characterized by pinhead-sized papules that may be grouped and fused together to form a flat plaque. The hard palate, tongue, buccal mucosa, or posterior pharynx may be involved. They may simulate Fordyce spots. In lupus pernio, the nasal mucosa is frequently involved. Rarely, in ulcerative sarcoidosis, the oral mucosa may be involved. Sarcoidosis may also infiltrate the gingiva, causing "strawberry gums" that simulate Wegener's granulomatosis.

### Systemic sarcoidosis

Sarcoidosis may involve virtually every internal organ, and its presentations are protean. Many cases of sarcoidosis are



asymptomatic, and only when routine radiographs of the chest reveal some abnormality is sarcoidosis suspected. Fever may be the only symptom of the disease or may be accompanied by weight loss, fatigue, and malaise.

Intrathoracic lesions, including parenchymal lung lesions and hilar adenopathy, are the most common manifestation of the disease, occurring in 90% of cases of sarcoidosis. All patients with cutaneous sarcoidosis, even without any respiratory symptoms, should be evaluated with chest radiograph and pulmonary function tests. Pulmonary radiograph changes are staged as follows:

- Stage 0: normal
- Stage I: bilateral hilar and/or paratracheal adenopathy
- Stage II: adenopathy with pulmonary infiltrates
- Stage III: pulmonary infiltrates only
- Stage IV: pulmonary fibrosis.

The panda sign correlates with gallium uptake in the nasopharynx and lacrimal and parotid glands; the lambda sign correlates with uptake in the paratracheal lymph nodes. These characteristic findings, plus a skin biopsy demonstrating typical sarcoidal granulomas, can be used as presumptive evidence for sarcoidosis. Lymphadenopathy, especially of the mediastinal and hilar nodes, and generalized adenopathy, or adenopathy confined to the cervical or axillary areas, may be an initial sign of sarcoidosis or may occur during the course of the disease. Polyarthralgias may be seen with acute sarcoidosis or as a component of chronic disease. Chronic arthritis may occur (Fig. 31-15). Osseous involvement is often present in chronic disease. The most characteristic changes are found radiographically in the bones of the hands and feet, particularly in the phalanges. These consist of round, punched-out, lytic, cystic lesions. These are seen frequently in patients with lupus pernio. The bone lesions represent epithelioid granulomas.

Ocular involvement is present in 30–50% of patients, so all patients with sarcoidosis, even if asymptomatic, should have routine ophthalmologic examinations. Any eye findings should be treated because even asymptomatic ocular sarcoidosis can lead to blindness. Anterior uveitis is the most common ocular manifestation. The lacrimal gland may be involved unilaterally or bilaterally by painless nodular swellings. Lesions

of the iris are nodular and painless. There may also be lesions of the retina, choroid, sclera, and optic nerve. Optic neuritis with vision or color vision loss is an emergency. Ophthalmic disease is highly correlated with systemic involvement. Conjunctival biopsy is positive in about 50% of patients with sarcoidosis, making it an easy site to sample and confirm the diagnosis.

Parotid gland and lacrimal gland enlargement with uveitis and fever may occur in sarcoidosis; this is known as uveoparotid fever or Heerfordt syndrome and usually lasts 2–6 months if not treated. Facial nerve palsy and central nervous system (CNS) disease are frequently seen in Heerfordt syndrome. Mikulicz syndrome is bilateral sarcoidosis of the parotid, submandibular, sublingual, and lacrimal glands.

Clinically apparent hepatic involvement occurs in about 20% of patients; however, a blind liver biopsy will reveal granulomas in 60% of cases. Hepatomegaly with elevation of serum alkaline phosphatase, biliary cirrhosis with hypercholesterolemia, and portal hypertension with esophageal varices are some of the manifestations. Liver biopsy showing hepatic granulomas is an excellent means of confirming the diagnosis of sarcoidosis.

Renal disease may be caused by direct involvement with granulomas or secondary to hypercalcemia. Hypercalcemia results from the macrophage in the granuloma having large amounts of 25-hydroxyvitamin D-1 $\alpha$ -hydroxylase, which converts 25-hydroxyvitamin D to the more active 1,25-dihydroxyvitamin D. Nephrolithiasis may result. Cardiac involvement occurs in 5% of cases, but in a higher percentage of autopsy cases. Baseline cardiac evaluation with a detailed cardiac history and electrocardiogram is recommended. Fatal arrhythmias and heart failure can develop.

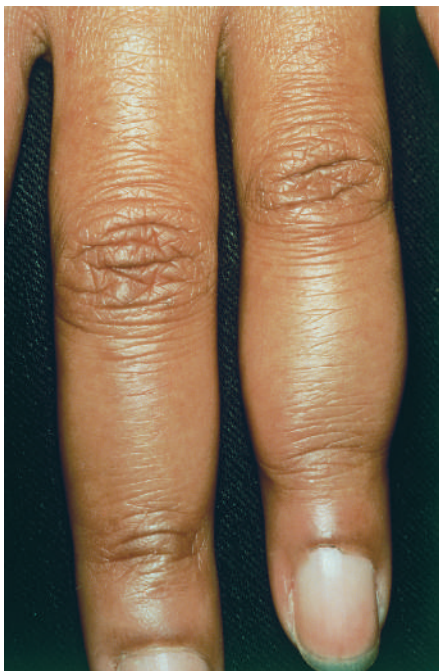Neurosarcoidosis occurs in 5–10% of patients. It can present in numerous ways, from focal cranial nerve involvement (most often facial nerve palsy) to aseptic meningitis, seizures, psychiatric changes, stroke, and space-occupying lesions. Neurosarcoidosis tends to be chronic and relapsing, with a higher mortality rate. Vision loss in sarcoidosis after heat exposure is called the Uhthoff phenomenon. Magnetic resonance imaging (MRI) with or without gadolinium is useful for detecting CNS lesions of sarcoidosis and following therapy.

Measuring ACE levels in sarcoidosis patients has little utility. ACE levels may be elevated in all granulomatous diseases, including infectious granulomatous disorders. An elevated ACE level is suggestive of, but not diagnostic for, granulomatous inflammation. A normal ACE level cannot be used to rule out sarcoidosis, and an elevated level does not necessarily indicate the presence of multisystem involvement. The use of 18F-fluorodeoxyglucose (FDG) positron emission tomography (PET) is more accurate in identifying extent of involvement and monitoring response to treatment.

### Pediatric sarcoidosis

Childhood sarcoidosis is rare. The clinical features are very age dependent. Older children, age 10–15, typically have lung, lymph node, and eye involvement. Calcium abnormalities are present in 30% of children with sarcoidosis. Older children develop specific sarcoidal skin lesions at the same rate as adults, about 30% of the time. One presentation resembles granulomatous periorificial dermatitis.

Blau syndrome is caused by mutations in the *NOD2* gene and is associated with early-onset sarcoidosis (age <5 years). It is more common in white patients. The triad of skin, joint, and eye involvement is characteristic and often confused with juvenile rheumatoid arthritis. Skin lesions are typically small papules and are the first clinical feature in more than half of patients, starting at a median age of 1 year. The skin lesions



**Fig. 31-15** Sarcoidosis, fusiform swelling of digits.

are often generalized and may be flat topped, giving them a lichenoid appearance. They are red-brown to tan and can occur in clusters or linear arrays. The face may have confluent lesions.

## Histopathology

The histology of sarcoidosis in all affected tissues is identical. The characteristic finding is that of the “naked tubercle,” composed of collections of large, pale-staining, epithelioid histiocytes. There may be small foci of necrosis in the center of the granulomas, and multinucleate giant cells, sometimes with inclusions (asteroid bodies, Schaumann bodies), may be present. Although classically there are few lymphocytes around the granulomas, they may be numerous. The granulomas may be nodular, diffuse, or tubular along neurovascular structures. Perifollicular and other periadnexal involvement can be seen in sarcoidosis.

The histologic differential diagnosis is broad, and the diagnosis of sarcoidosis cannot be definitively made histologically. Allergic granulomas caused by metals are histologically identical to sarcoidosis. Other foreign body granulomas (especially as a result of silica), granulomatous rosacea, granulomatous secondary syphilis, tuberculoid leprosy, atypical mycobacterial infections, and leishmaniasis may closely simulate sarcoidosis.

The diagnosis of sarcoidosis is established by the demonstration of involvement consistent with sarcoidosis in two different organ systems. This is usually done histologically, or by characteristic findings with radiologic techniques, including gallium scans, PET, and MRI. If cutaneous sarcoidal granulomas are identified in a patient with no prior history of sarcoidosis, the first diagnostic test should be a chest radiograph. If this is abnormal, further pulmonary evaluation is indicated. Ophthalmologic evaluation and conjunctival biopsy may be useful. Since many patients with sarcoidosis may develop ocular involvement that may be asymptomatic, every patient should see an ophthalmologist. Blind biopsy of the minor salivary glands may demonstrate sarcoidal granulomas in about 50% of patients with systemic sarcoidosis. Otherwise, histologic evaluation of any involved tissue may be considered. The site for biopsy may be guided by PET scans, which, if characteristic, can be used to support the diagnosis.

## Sarcoidosis in the setting of immunologic abnormalities

Numerous reports document sarcoidosis occurring in patients with various forms of spontaneous or iatrogenic immunologic aberrations. Patients with ataxia-telangiectasia, severe combined immunodeficiency, and common variable immunodeficiency—three primary immunodeficiencies with both B-cell and T-cell defects—are predisposed to sarcoidal granulomas in the skin. Histologically, these have a low CD4/CD8 ratio, in contrast to classic sarcoidosis, which is rich in CD4+ T cells. Sarcoidosis may be associated with lymphoma, especially Hodgkin disease (sarcoidosis-lymphoma syndrome). B-cell lymphoma, chronic myeloid and lymphoid leukemia, and mucosa-associated lymphoid tissue (MALT) lymphoma have all been described in patients with sarcoidosis. Sarcoidosis patients are about 40–60% more likely to develop malignancy, including solid tumors such as nonmelanoma skin cancers (threefold risk), renal cancer, and nonthyroid endocrine tumors. In addition, adenopathy in patients with lymphoma or solid tumors may demonstrate sarcoidal granulomas without tumor. This is important to know when

a patient with a cancer develops an enlarged node, and sampling of the node becomes important to avoid unnecessary therapy. Sézary syndrome with extensive cutaneous granulomas has been described.

Alteration of the immune system with medications can lead to the development of systemic sarcoidosis. These typically cause a constellation of pulmonary and cutaneous disease. Etanercept, adalimumab, and infliximab (the TNF inhibitors) have all been reported to trigger sarcoidosis. This is ironic, since they are also often therapeutic in sarcoidosis (analogous to the situation with TNF inhibitors and psoriasis). Numerous reports document the appearance of sarcoidosis in association with IFN alfa therapy, usually for the treatment of HCV infection. HCV alone may also trigger sarcoidosis. Cutaneous lesions (60% of patients), pulmonary findings (75%), or both, as well as other features of sarcoidosis, occur in 5% of patients treated with IFN alfa for HCV. The addition of ribavirin may increase the risk. In more than 80% of patients, the sarcoidosis resolves after the treatment is discontinued. Treatment of HIV infection with highly active antiretroviral therapy (HAART) has led to the appearance of sarcoidosis or tattoo granulomas, apparently by enhancing the number and function of Th cells. Sarcoidosis is now well recognized as a feature of immune reconstitution syndrome (IRIS). Hematopoietic stem cell transplantation (HSCT), both allogenic or autologous, has been associated with the appearance of pulmonary sarcoidosis. If HSCT is performed for malignant disease, the presence of hilar adenopathy may be interpreted as recurrent or metastatic disease, and inappropriate treatment may be given. Other medications causing sarcoidosis include alemtuzumab (anti-CD52 monoclonal antibody for CTCL), vemurafenib (*BRAF* inhibitor), and ipilimumab (anti-CTLA4 monoclonal antibody for malignant melanoma).

Patients with sarcoidosis are at increased risk to develop other immune-mediated and chronic inflammatory diseases, including systemic lupus erythematosus, autoimmune chronic hepatitis, multiple sclerosis, coeliac disease, thyroid disease, and ulcerative colitis (but not Crohn’s disease).

## Differential diagnosis

Granulomatous secondary syphilis may closely simulate sarcoidosis both clinically and histologically. Blau syndrome, an autosomal dominant granulomatous disease, is similar to childhood sarcoidosis (see earlier). It can be distinguished from sarcoidosis by the lack of pulmonary involvement. Granulomatous cutaneous T-cell lymphoma (CTCL) can usually be distinguished histologically and by the presence of pulmonary involvement in sarcoidosis.

## Treatment

Numerous therapies have been reported as beneficial in cutaneous sarcoidosis, usually after anecdotal observation. Virtually no information exists regarding what types of therapy are best for which of the various cutaneous manifestations. The cutaneous disease may spontaneously remit without treatment. Because most skin lesions are asymptomatic, the major indication for treatment is cosmetic. Treatment begins by evaluating the patient for systemic disease. If found, the treatment of the systemic disease may clear the skin lesions. Otherwise, a stepwise approach to management based on extent, severity, and rapidity of progression can be considered.

Systemic corticosteroids are almost always beneficial in cutaneous sarcoidosis. Unfortunately, the doses required to control cutaneous disease may be too high (usually in excess of 15 mg/



day) to be ideal for long-term use. For limited skin disease, intralesional injection of 2.5–5.0 mg/mL of triamcinolone acetonide suspension is very effective. For thinner lesions, superpotent topical corticosteroids, topical tacrolimus, and UVA1 phototherapy may be effective. Antibiotic treatment with a single agent (usually minocycline or doxycycline, 100 mg twice daily) may be considered in patients with skin lesions in whom systemic disease does not require treatment. About one quarter of patients have complete resolution of their skin lesions, and more than half have a partial remission. A more aggressive antibiotic regimen called CLEAR—combined levofloxacin, 500 mg/day; ethambutol, 25 mg/kg/day, up to 1200 mg; azithromycin, 250 mg/day; and rifampin, 10 mg/kg/day, or up to 300 mg/day—is also effective. Maximum response occurs after several months of therapy.

Local surgical procedures can be beneficial for some forms of sarcoidosis. Pulsed dye laser, used repeatedly, PDT, and even CO<sub>2</sub> laser remodeling may be effective in the appropriate cases. In severe lupus pernio, nasal skin excision followed by flap reconstruction can lead to dramatic improvement.

Systemic corticosteroid therapy is indicated for acute systemic involvement with fever and weight loss, in active eye disease, for sarcoidal involvement of the myocardium, in active pulmonary disease with functional disability, in hypersplenism, in hypercalcemia, and for symptomatic CNS involvement.

Antimalarials, both chloroquine and hydroxychloroquine, have been used to treat extensive cutaneous sarcoidosis, in doses of 250 mg/day or 200–400 mg/day, respectively. About three quarters of patients appear to respond partially or completely. In some cases, the associated CNS disease or hypercalcemia also improves. These agents may also be used to reduce the dose of systemic steroids required. Antimalarial therapy can be combined with antibiotic treatment.

Methotrexate, in doses of 15–25 mg/week, is also efficacious and seems to help patients with severe lupus pernio or ulcerative sarcoidosis who are otherwise difficult to treat. Methotrexate-induced hepatitis occurs in 15% of patients with sarcoidosis treated. Leflunomide may be given similar to methotrexate and may be used in patients with gastrointestinal intolerance for methotrexate. Response rates are about 75%. The retinoids, principally isotretinoin, have been reported as beneficial in some patients, usually at doses of 0.5–1.0 mg/kg. Response is only seen after 6 weeks or more. Thalidomide, 50–200 mg/day, has led to improvement of the skin lesions after several months. It should not be used to treat pregnant patients, however, because of possible teratogenic effects on the fetus. Venous thrombosis may complicate thalidomide therapy, especially if doses above 100 mg/day are used. Thalidomide is an option when methotrexate is contraindicated. Azathioprine and cyclophosphamide had been used for refractory disease, and mycophenolate mofetil has shown efficacy in mucocutaneous disease and may be considered an effective form of rescue and steroid-sparing therapy. The combination of thalidomide, an immunosuppressive agent, with an antimalarial may be effective when these agents fail individually. TNF is an important cytokine in the formation of granulomas. Not surprisingly, TNF inhibitors, including infliximab, etanercept, and adalimumab, can be effective in refractory cutaneous and systemic sarcoidosis. Infliximab appears to be particularly beneficial in controlling severe lupus pernio. Combination therapy with thalidomide, an immunosuppressive agent, a TNF inhibitor, and an antimalarial may be used in severe, refractory cutaneous disease. Fumaric acid esters and apremilast (PDE-4 inhibitor) both have improved cutaneous sarcoidosis and may be considered when other agents fail.

**Adam A, et al:** Sarcoidosis associated with vemurafenib. *Br J Dermatol* 2013; 169:181.

**Ahmed I, Harshad SR:** Subcutaneous sarcoidosis: is it a specific subset of cutaneous sarcoidosis frequently associated with systemic disease? *J Am Acad Dermatol* 2006; 54:55.

**Arostequi JI, et al:** *NOD2* gene-associated pediatric granulomatous arthritis: clinical diversity, novel and recurrent mutations, and evidence of clinical improvement with interleukin-1 blockade in a Spanish cohort. *Arthritis Rheum* 2007; 56:3805.

**Assmann T, et al:** Cutaneous sarcoidal granuloma after botulinum toxin type A injection. *J Am Acad Dermatol* 2013; 69:e247.

**Baughman RP, et al:** Efficacy and safety of apremilast in chronic cutaneous sarcoidosis. *Arch Dermatol* 2012; 148:262.

**Bhagat R, et al:** Pulmonary sarcoidosis following stem cell transplantation: is it more than a chance occurrence? *Chest* 2004; 126:642.

**Bohelay G, et al:** Striking leflunomide efficacy against refractory cutaneous sarcoidosis. *J Am Acad Dermatol* 2013; 70:e111.

**Buss G, et al:** Two cases of interferon-alpha-induced sarcoidosis koebnerized along venous drainage lines: new pathogenic insights and review of the literature of interferon-induced sarcoidosis. *Dermatol* 2013; 226:289.

**Caras WE, et al:** Coexistence of sarcoidosis and malignancy. *South Med J* 2003; 96:918.

**Cardoso JC, et al:** Cutaneous sarcoidosis: a histopathological study. *J Eur Acad Dermatol Venereol* 2009; 23:678.

**Chakravarty SD, et al:** Sarcoidosis triggered by interferon-beta treatment of multiple sclerosis: a case report and focused literature review. *Semin Arthritis Rheum* 2012; 42:206.

**Choi HJ, et al:** Papular sarcoidosis limited to the knees: a clue for systemic sarcoidosis. *Int J Dermatol* 2006; 45:169.

**Coto-Segura P, et al:** A sporadic case of early-onset sarcoidosis resembling Blau syndrome due to the recurrent R334W missense mutation on the *NOD2* gene. *Br J Dermatol* 2007; 157:1257.

**Dadban A, et al:** Association of Sweet's syndrome and acute sarcoidosis: report of a case and review of the literature. *Clin Exp Dermatol* 2009; 34:189.

**Dal Sacco D, et al:** Scar sarcoidosis after hyaluronic acid injection. *Int J Dermatol* 2005; 44:411.

**Darlington P, et al:** HLA-alleles associated with increased risk for extra-pulmonary involvement in sarcoidosis. *Tissue Antigens* 2014; 83:267.

**DeFelice T, et al:** Verrucous and macular sarcoidosis. *Dermatol Online J* 2012; 18:10.

**Descamps V, et al:** Facial cosmetic filler injections as possible target for systemic sarcoidosis in patients treated with interferon for chronic hepatitis C: two cases. *Dermatology* 2008; 217:81.

**Drake WP, et al:** Oral antimycobacterial therapy in chronic cutaneous sarcoidosis: a randomized, single-masked, placebo-controlled study. *JAMA Dermatol* 2013; 149:1040.

**Eckert A, et al:** Anti-CTLA4 monoclonal antibody induced sarcoidosis in a metastatic melanoma patient. *Dermatology* 2009; 218:69.

**El Sayed F, et al:** Childhood sarcoidosis: diagnostic issues. *Dermatol Online J* 2013; 19:20037.

**Fazzi P, et al:** Thalidomide for improving cutaneous and pulmonary sarcoidosis in patients resistant or with contraindications to corticosteroids. *Biomed Pharmacother* 2012; 66:300.

**Fok KC, et al:** Cutaneous sarcoidosis in a patient with ulcerative colitis on infliximab. *J Crohns Colitis* 2012; 6:708.

**Ghosh UC, et al:** Ichthyosiform sarcoidosis revisited. *Indian J Dermatol Venereol Leprol* 2013; 79:795.

**Ginarte M, et al:** Morpheaform sarcoidosis. *Acta Derm Venereol* 2006; 86:264.

**Goossens A, et al:** Allergic contact granuloma due to palladium following ear piercing. *Contact Dermatitis* 2006; 55:338.

**Green JJ, Lawrence N:** Generalized ulcerative sarcoidosis induced by therapy with the flashlamp-pumped pulsed dye laser. *Arch Dermatol* 2000; 137:507.

**Gregg PJ, et al:** Sarcoidal tissue reaction in Sézary syndrome. *J Am Acad Dermatol* 2000; 43:372.

**Haimovic A, et al:** Sarcoidosis: a comprehensive review and update for the dermatologist. Part I. Cutaneous disease. *J Am Acad Dermatol* 2012; 66:699.e1.

**Haimovic A, et al:** Sarcoidosis: a comprehensive review and update for the dermatologist. Part II. Extracutaneous disease. *J Am Acad Dermatol* 2012; 66:719.e1.

- Haimovic A, et al:** Reply to: monogenic early-onset sarcoidosis is no longer a variant of "idiopathic" sarcoidosis. *J Am Acad Dermatol* 2013; 69:165.
- Hayakawa J, et al:** A syringotropic variant of cutaneous sarcoidosis: presentation of 3 cases exhibiting defective sweating responses. *J Am Acad Dermatol* 2013; 68:1016.
- High WA, et al:** Granulomatous reaction to titanium alloy: an unusual reaction to ear piercing. *J Am Acad Dermatol* 2006; 55:716.
- Hunt RD, et al:** Ulcerative sarcoidosis. *Dermatol Online J* 2012; 18:29.
- Hurst EA, Mauro T:** Sarcoidosis associated with pegylated interferon alfa and ribavirin treatment for chronic hepatitis C: a case report and review of the literature. *Arch Dermatol* 2005; 141:865.
- Ichiki Y, Kitajima Y:** Ulcerative sarcoidosis: a case report and review of the Japanese literature. *Acta Derm Venereol* 2008; 88:526.
- Ikeda S, et al:** A case of sarcoidosis with severe acute renal failure requiring dialysis. *Clin Nephrol* 2014; 82(4):273-277.
- Isshiki T, et al:** Usefulness of low-dose methotrexate monotherapy for treating sarcoidosis. *Intern Med* 2013; 52:2727.
- Jamilloux Y, et al:** Elderly-onset sarcoidosis: prevalence, clinical course, and treatment. *Drugs Aging* 2013; 30:969.
- Ji J, et al:** Cancer risk in hospitalized sarcoidosis patients: a follow-up study in Sweden. *Ann Oncol* 2009; 20:1121.
- Kalajian AH, et al:** Sarcoidal anemia and leucopenia treated with methotrexate and mycophenolate mofetil. *Arch Dermatol* 2009; 145:905.
- Kanazawa N, et al:** Monogenic early-onset sarcoidosis is no longer a variant of "idiopathic" sarcoidosis. *J Am Acad Dermatol* 2013; 69:164.
- Kapoor S:** Cutaneous and systemic malignancies in patients with sarcoidosis: a close association. *Ann Acad Med Singapore* 2009; 38:179.
- Katoh N, et al:** Cutaneous sarcoidosis successfully treated with topical tacrolimus. *Br J Dermatol* 2002; 147:154.
- Katta R, et al:** Sarcoidosis of the scalp: a case series and review of the literature. *J Am Acad Dermatol* 2000; 42:690.
- Kluger N:** Sarcoidosis on tattoos: a review of the literature from 1939 to 2011. *Sarcoidosis Vasc Diffuse Lung Dis* 2013; 30:86.
- Kluger N, et al:** Leg ulcers revealing systemic sarcoidosis with splenomegaly and thrombocytopenia. *Int J Dermatol* 2013; 52:1398.
- Kouba DJ, et al:** Mycophenolate mofetil may serve as a steroid-sparing agent for sarcoidosis. *Br J Dermatol* 2003; 148:147.
- Kowalczyk JP, et al:** "Strawberry gums" in sarcoidosis. *J Am Acad Dermatol* 2008; 59:S118.
- Kwon EJ, et al:** Interstitial granulomatous lesions as part of the spectrum of presenting cutaneous signs in pediatric sarcoidosis. *Pediatr Dermatol* 2007; 24:517.
- Lamrock E, Brown P:** Development of cutaneous sarcoidosis during treatment with tumour necrosis alpha factor antagonists. *Australas J Dermatol* 2012; 53:e87.
- Mahnke N, et al:** Cutaneous sarcoidosis treated with medium-dose UVA1. *J Am Acad Dermatol* 2004; 50:978.
- Maña J, Marcoval J:** Skin manifestations of sarcoidosis. *Presse Med* 2012; 41:e355.
- Maña J, et al:** Granulomatous cutaneous sarcoidosis: diagnosis, relationship to systemic disease, prognosis and treatment. *Sarcoidosis Vasc Diffuse Lung Dis* 2013; 30:268.
- Marcoval J, et al:** Subcutaneous sarcoidosis: clinicopathological study of 10 cases. *Br J Dermatol* 2005; 153:790.
- McDougal KE, et al:** Variation in the lymphotoxin-alpha/tumor necrosis factor locus modifies risk of erythema nodosum in sarcoidosis. *J Invest Dermatol* 2009; 129:1921.
- Milman N, et al:** Favourable effect of TNF-alpha inhibitor (infliximab) on Blau syndrome in monozygotic twins with a de novo *CARD15* mutation. *APMIS* 2006; 114:912.
- Mortimer NJ, et al:** Childhood sarcoidosis presenting with extensive cutaneous lesion, bilateral hilar lymphadenopathy and severe hypercalcaemia. *Australas J Dermatol* 2007; 48:233.
- Moss J, et al:** Mycobacterial infection masquerading as cutaneous sarcoidosis. *Clin Exp Dermatol* 2009; 34:e199.
- Nazemi MJ, et al:** A case of sarcoidosis mimicking Wegener's granulomatosis. *Int J Dermatol* 2013; 52:1288.
- Nguyen YT, et al:** Treatment of cutaneous sarcoidosis with thalidomide. *J Am Acad Dermatol* 2004; 50:235.
- Nureki S, et al:** Interventricular septal thickening as an early manifestation of cardiac sarcoidosis. *Int Heart J* 2014; 55:181.
- O'Donoghue NB, Barlow RJ:** Laser remodeling of nodular nasal lupus pernio. *Clin Exp Dermatol* 2006; 31:27.
- Osawa R, et al:** Chain saw blade granuloma: reaction to a deeply embedded metal fragment. *Arch Dermatol* 2006; 142:1079.
- O'Shea SJ, et al:** Cutaneous sarcoid resulting in scarring. *Clin Exp Dermatol* 2012; 37:585.
- Papadavid E, et al:** Subcutaneous sarcoidosis masquerading as cellulitis. *Dermatology* 2008; 217:212.
- Pariser RJ:** A double-blind, randomized, placebo-controlled trial of adalimumab in the treatment of cutaneous sarcoidosis. *J Am Acad Dermatol* 2013; 68:765.
- Pariser RJ:** A response to "comment on" a double-blind, randomized, placebo-controlled trial of adalimumab in the treatment of cutaneous sarcoidosis. *J Am Acad Dermatol* 2013; 70:951.
- Pascual JC, et al:** Sarcoidosis after highly active antiretroviral therapy in a patient with AIDS. *Clin Exp Dermatol* 2004; 29:156.
- Rajoriya N, et al:** Immune-mediated and chronic inflammatory disease in people with sarcoidosis: disease associations in a large UK database. *Postgrad Med J* 2009; 85:233.
- Ramos-Casals M, et al:** Sarcoidosis in patients with chronic hepatitis C virus infection: analysis of 68 cases. *Medicine (Baltimore)* 2005; 84:69.
- Reich JM:** Concurrent sarcoidosis and lung cancer. *Chest* 2009; 136:943.
- Roos S, et al:** Successful treatment of cutaneous sarcoidosis lesions with the flashlamp pumped pulsed dye laser: a case report. *Dermatol Surg* 2009; 35:1139.
- Rosen T, Doherty C:** Successful long-term management of refractory cutaneous and upper airway sarcoidosis with periodic infliximab infusion. *Dermatol Online J* 2007; 13:14.
- Rosenbach M:** The dermatologist's role in sarcoidosis. *JAMA Dermatol* 2013; 149:760.
- Rosenbach M, et al:** Reliability and convergent validity of the cutaneous sarcoidosis activity and morphology instrument for assessing cutaneous sarcoidosis. *JAMA Dermatol* 2013; 149:550.
- Rosenberg B:** Ichthyosiform sarcoidosis. *Dermatol Online J* 2005; 11:15.
- Sahraian MA, et al:** Cutaneous and pulmonary sarcoidosis following treatment of multiple sclerosis with interferon- $\beta$ -1b: a case report. *J Med Case Rep* 2013; 7:270.
- Santos G, et al:** Exacerbation of recalcitrant cutaneous sarcoidosis with adalimumab: a paradoxical effect? A case report. *An Bras Dermatol* 2013; 88:S26.
- Sauder MB, et al:** "Comment on" a double-blind, randomized, placebo-controlled trial of adalimumab in the treatment of cutaneous sarcoidosis. *J Am Acad Dermatol* 2014; 70:950.
- Schaffter JV, et al:** Widespread granulomatous dermatitis of infancy: an early sign of Blau syndrome. *Arch Dermatol* 2007; 143:386.
- Sehgal VN, et al:** Sarcoidosis as a systemic disease. *Clin Dermatol* 2014; 32:351.
- Shigemitsu H, et al:** Is sarcoidosis frequent in patients with cancer? *Curr Opin Pulm Med* 2008; 14:478.
- Shinya C, et al:** Cutaneous sarcoidosis presenting with pinhead-sized papules. *Eur J Dermatol* 2008; 18:191.
- Smith R, et al:** Improving cosmesis of lupus pernio by excision and forehead flap reconstruction. *Clin Exp Dermatol* 2009; 34:e25.
- Stagaki E, et al:** The treatment of lupus pernio: results of 116 treatment courses in 54 patients. *Chest* 2009; 135:468.
- Steen T, English JC:** Oral minocycline in treatment of cutaneous sarcoidosis. *JAMA Dermatol* 2013; 149:758.
- Stockman DL, et al:** Verrucous cutaneous sarcoidosis: case report and review of this unusual variant of cutaneous sarcoidosis. *Am J Dermatopathol* 2013; 35:273.
- Thachil J, et al:** The development of sarcoidosis with the use of alemtuzumab: clues to T-cell immune reconstitution. *Br J Haematol* 2007; 138:559.
- Torres LK, Faiz SA:** Tattoos and sarcoidosis. *N Engl J Med* 2014; 370:e34.
- Trevenzoli M, et al:** Sarcoidosis and HIV infection: a case report and a review of the literature. *Postgrad Med J* 2003; 79:535.
- Trien R, et al:** Interferon-alpha-induced sarcoidosis in a patient being treated for hepatitis C. *Am J Case Rep* 2014; 15:235.
- Tu J, Chan J:** Cutaneous sarcoidosis and infliximab: evidence for efficacy in refractory disease. *Australas J Dermatol* 2014; 55:279.
- Varron L, et al:** Late-onset sarcoidosis: a comparative study. *Medicine* 2012; 91:137.



**Wanat KA, Rosenbach M:** Case series demonstrating improvement in chronic cutaneous sarcoidosis following treatment with TNF inhibitors. *Arch Dermatol* 2012; 149:1097.

**Wanat KA, Rosenbach M:** A practical approach to cutaneous sarcoidosis. *Am J Clin Dermatol* 2014; 15:283.

**Wilsman-Theis D, et al:** Photodynamic therapy as an alternative treatment for cutaneous sarcoidosis. *Dermatology* 2008; 217:343.

**Yanardag H, et al:** Diagnosis of cutaneous sarcoidosis: clinical and the prognostic significance of skin lesions. *Multidiscip Respir Med* 2013; 8:26.

**Zouboulis CC, et al:** Multi-organ sarcoidosis treatment with fumaric acid esters: a case report and review of the literature. *Dermatol* 2014; 228:202.

## HISTIOCYTOSIS

These disorders are characterized by infiltrates that contain either Langerhans cells (the X-type histiocytoses) or infiltrates of non-Langerhans cell histiocytes (the non-X histiocytoses).

### Non-X histiocytoses

Zelger and Burgdorf proposed classifying this group of disorders as the "xanthogranuloma family." Their classification scheme relies on the morphology of the monocyte/macrophage composing the lesion. Weitzman and Jaffe refined this concept and outlined the immunohistochemical features of the cells involved. These classification schemas are useful for this uncommon group of disorders. However, since the histiocytes within any disorder can change their appearance, no one specific morphologic cell type absolutely characterizes these disorders. There are three large families of histiocytoses based on these classification schemas: X-type histiocytosis or Langerhans cell histiocytosis (LCH); non-LCH histiocytoses of the juvenile xanthogranuloma (JXG) family (which have the phenotype of dermal dendritic cells, being positive for factor XIIIa, fascin, MS-1, and CD68); and multicentric reticulohistiocytosis and

sinus histiocytosis with massive lymphadenopathy (SHML; Rosai-Dorfman disease), which are thought not to be in the JXG family of non-X histiocytoses. In the end, the final diagnosis is established by typical clinical features, a compatible histology, and an evolution typical for that disorder (Fig. 31-16).

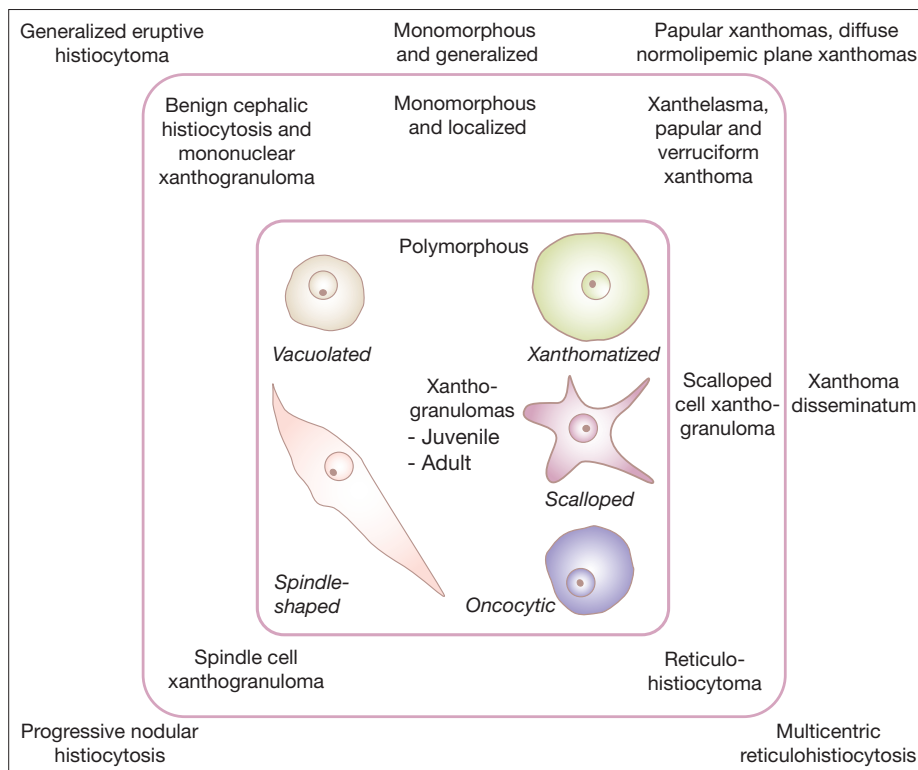
The non-X histiocytoses are divided clinically into three groups: those involving primarily or only the skin (JXG); those that affect the skin but have a major systemic component (Erdheim-Chester disease); and those that are primarily a systemic disease with occasional skin lesions as a part of the disease (SHML). At any level of differentiation or appearance of the histiocyte, there may be a disease in any category. Conceptually, this allows one to think of the JXG group of non-X histiocytoses as lying along a spectrum: benign cephalic histiocytosis, JXG, Erdheim-Chester disease, generalized eruptive histiocytosis, xanthoma disseminatum, and progressive nodular histiocytosis. Most diseases at the beginning of the spectrum are localized, benign disorders; as one progresses through the diseases, they tend to become more generalized but are still benign; at the end of the spectrum lie diseases that are less likely to involute and may have visceral involvement. This parallels the histologic appearance of the infiltrating histiocyte, which progresses from scalloped to vacuolated to xanthomatized and finally spindled. In any disease, however, many morphologies of the histiocyte may be seen.

**Weitzman S, Jaffe R:** Review: uncommon histiocytic disorders. The non-Langerhans cell histiocytoses. *Pediatr Blood Cancer* 2005; 45:256.

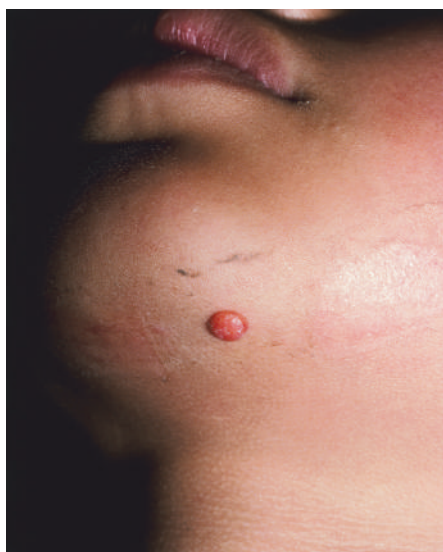**Zelger B, Burgdorf WHC:** The cutaneous "histiocytoses." In *Advances in Dermatology*. St Louis: Mosby, 2001.

### Juvenile xanthogranuloma

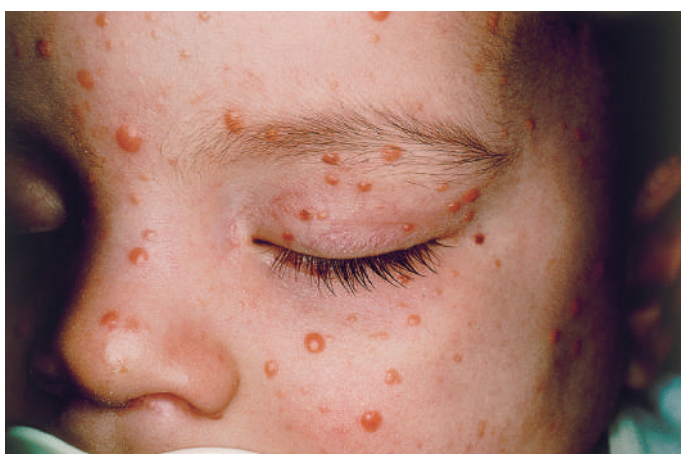Juvenile xanthogranuloma is the most common non-LCH. Between 20% and 35% of lesions are congenital. The vast majority of lesions (70%) are diagnosed within the first year of life. The mean age of onset is 22 months, and the median, 5



**Fig. 31-16** Schematic drawing of unifying concept of non-X histiocytoses.



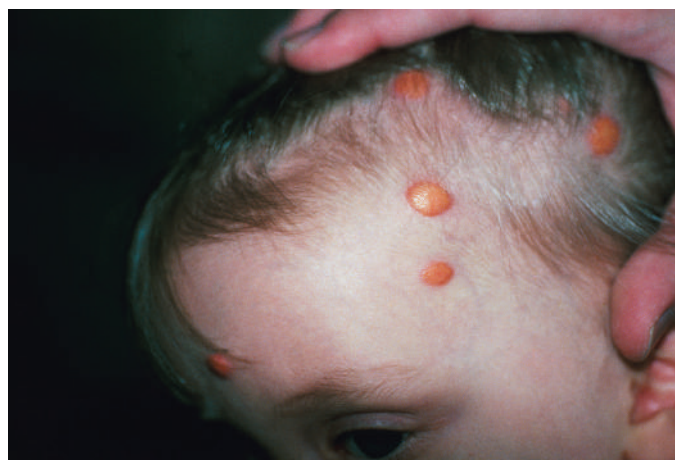**Fig. 31-17** Juvenile xanthogranuloma, solitary.



**Fig. 31-18** Juvenile xanthogranuloma, multiple small papules.

months, demonstrating the proclivity for early onset. About 80% of cases are solitary (Fig. 31-17). Boys are more often affected than girls. In adults, lesions tend to occur in the late twenties to early thirties, and the gender distribution is equal. JXG is 10 times more common in white than in black persons, but it occurs in all races. Multiple cutaneous lesions affect male children much more frequently (12:1).

The JXGs begin as well-demarcated, firm, rubbery, round to oval dermal papules or nodules 5–10 mm in diameter. Early lesions are pink to red with a yellow tinge and become tan-brown over time. On dermoscopy, the lesions have an orange-yellow background, a subtle erythematous border with branched and linear vessels running from the edge to the center of the lesion, and “clouds” of paler yellow areas representing areas of xanthomatized histiocytes. Most lesions are asymptomatic. The head and neck are the most common locations, followed by the upper trunk and upper extremities. Lesions have been divided into three types: small nodular (2–5 mm; Fig. 31-18); large nodular (5–20 mm; Fig. 31-19); and giant xanthogranuloma (>20 mm). The small-type lesions are more numerous than the large type. Often, however, one patient will have both types of lesion, and the proposed increased risk for ocular involvement in the micronodular type and other internal involvement in the macronodular type has been refuted. Skin lesions regress spontaneously within 3–6 years in children. In adults, lesions are usually persistent.



**Fig. 31-19** Juvenile xanthogranuloma, multiple nodules.

Hyperpigmentation, atrophy, or anetoderma may remain after lesions resolve.

Multiple atypical presentations have been described. These include hyperkeratotic nodules; macronodular tumors 2–10 cm in diameter; clustered (agminated) forms; linear lesions; flat, plaque-like lesions; and pedunculated or cylindrical exophytic lesions. Atypical sites of involvement include the genitalia, lips, palms, soles, earlobes, and fingers. The most common location for JXGs after the dermis is the subcutaneous tissue, again most often on the head and neck. About 15% of JXGs present in this manner, usually as a solitary mobile mass up to 3 cm in diameter. Subcutaneous JXG typically appears before age 1 and often before age 3 months. Oral JXG may develop in infancy or childhood and is most frequently a solitary lesion of the tongue, lip, or palate.

Extracutaneous JXG is uncommon and occurs as visceral involvement, in association with either multiple cutaneous lesions or a solitary extracutaneous lesion. Visceral disease of both types accounts for only 4% of childhood JXGs and for 5–10% of all JXG cases. Ocular involvement occurs in about 0.3–0.4% of children with multiple JXGs, and 41% of children with ocular JXGs have skin lesions. Skin lesions appear after eye lesions in 45% of cases. In 92%, eye lesions occur during the first 2 years of life. The most common location is the iris, where JXG can present as a tumor, unilateral glaucoma, unilateral uveitis with spontaneous hyphema, or as heterochromia iridis. The eyelid or posterior eye may also be involved. Ocular screening is recommended for all children with multiple cutaneous lesions before age 2 years.

Mass lesions of the nasal, orbital, and paranasal sinus region can occur and cause erosion of the orbit and extend to the skull. Other extracutaneous sites and their presentations, in order of frequency, include the lung (respiratory distress and nodular opacities on chest radiograph), liver (hepatomegaly and, rarely, fatal giant cell hepatitis), testis (mass), and rarely, the CNS, kidney, spleen, and retroperitoneum. Other evaluations for extracutaneous JXGs are not indicated unless there are symptoms or findings suggesting their presence. Extracutaneous lesions also spontaneously regress. If surgical intervention is required, extracutaneous lesions tend not to recur, even if they are incompletely excised. Rarely, the burden of visceral JXGs may be so great that the patient's life is threatened. These cases have been called disseminated JXG, systemic JXG, or systemic xanthogranuloma. In 25% of these patients, no skin lesions are found, or the skin lesions may appear after the systemic disease is identified. Progressive CNS, liver, or bone marrow involvement usually mandates aggressive therapy and is usually managed with the protocols used to



treat LCH. Bone marrow involvement can also produce hemophagocytic lymphohistiocytosis syndrome with profound cytopenias. Locally aggressive tumors may be radiated.

The JXGs have been reported in association with neurofibromatosis (NF-1) and juvenile myelomonocytic leukemia (JMML). Patients with NF-1 and JXG were reported to be 20–32 times more likely to develop JMML, but this association has recently been questioned. Since JMML occurs in infancy or early childhood, café au lait macules often are the only findings of NF-1 at the time. Sometimes, all three conditions affect the same patient, with males having a 3:1 predominance and usually a maternal history of NF-1. Children with JXG should be examined for stigmata of NF-1. If these stigmata are found, especially in a boy with a maternal history of NF-1, the pediatrician should be alert to the possible, although uncommon, occurrence of JMML. Nevus anemicus may be seen in children with JXG and NF-1. The presence of nevus anemicus in a young infant with JXG should put the health care team on alert that this patient may have NF-1. Rarely, JXG in childhood may be associated with mastocytosis or childhood acute lymphoblastic leukemia. The leukemia and the JXG can have the same clonality, and the JXG lesions may occur after the treatment of the leukemia or less often, concurrently. Similarly, Wiskott-Aldrich syndrome has been reported with multiple JXGs. Multiple xanthogranulomas are rare in adults, and it is quite unusual for them to occur in an eruptive manner. At least six cases have been associated with hematologic malignancy (chronic lymphocytic leukemia, essential thrombocytosis, large B-cell lymphoma, adult T-cell lymphoma/leukemia, and monoclonal gammopathy). Systemic involvement with JXG in adults is also rare and usually requires histologic confirmation.

Lesions appear histologically as nonencapsulated but circumscribed proliferations in the upper and middle reticular dermis and may extend more deeply into the subcutaneous tissue or abut directly on the epidermis with no grenz zone. Epidermotropism does not occur. As classically proposed, the histopathology varies in accordance with the age of the lesion. Very early lesions are composed of mononuclear cells with abundant amphophilic cytoplasm that is poorly lipidized or vacuolated. Later, the cells become more vacuolated and multinucleated forms appear. In mature lesions, foam cells, multinucleated foam cells (Touton giant cells) and foreign body giant cells are present. Touton giant cells are characteristic of JXG but not specific for it. The inflammatory infiltrate consists of lymphocytes, eosinophils, and neutrophils and lacks plasma cells. Fibrosis occurs in the older lesions. The histology just described is characteristic of cutaneous JXGs. Soft tissue and visceral JXGs present with more monomorphous cytology, and can have a prominent spindle cell appearance. Immunohistochemistry is especially valuable in confirming the diagnosis of extracutaneous JXG. The cells of JXG of all anatomic locations stain with factor XIIIa, vimentin, fascin, MS-1, and CD68, but not with CD1a, S-100, or other specific markers for Langerhans cells.

The treatment for most cases of JXG is observation. By age 6 years, most lesions have resolved, often leaving normal or only slightly hyperpigmented skin. In adults, spontaneous involution is slower, and local removal with surgery could be considered. Injection of bevacizumab intravitreally may be used to treat JXG of the iris.

It is noteworthy that the patterns of involvement by JXG and LCH are similar, with childhood onset and primary cutaneous involvement; when visceral disease occurs, the liver, bone, and lungs are usually involved. Without histologic confirmation, isolated JXG of the bone would be most likely diagnosed as isolated LCH, a much more common condition. These clinical

similarities between JXG and LCH may occur because both diseases are caused by antigen-presenting dendritic cells. JXG is a proliferation of dermal dendrocytes, and LCH is a proliferation of Langerhans cells. The clinical features favoring JXG include lack of crusting or scale and the distribution and uniformity of size of lesions. Histologic evaluation is definitive in difficult cases, because JXGs are negative for the Langerhans cell marker CD1a. Unlike LCH, JXGs are usually negative for S-100, although a few S-100-positive cells may be seen in a JXG. JXG may appear in a patient who also has LCH. Benign cephalic histiocytosis may be difficult to distinguish both clinically and histologically, although its lesions tend to be flatter and are mainly on the head and neck. Papular xanthoma can be distinguished histologically. Clinically, mastocytosis will urticate when scratched (Darier's sign) and can be distinguished histologically. Solitary JXG appearing in a child must be distinguished from a Spitz nevus, which usually requires a biopsy.

- Aparicio G, et al:** Eruptive juvenile xanthogranuloma associated with relapsing acute lymphoblastic leukemia. *Pediatr Dermatol* 2008; 25:487.
- Arribas MP, et al:** Giant cutaneous horn on the forearm of a neonate. *Pediatr Dermatol* 2013; 30:261.
- Ashkenazy N, et al:** Successful treatment of juvenile xanthogranuloma using bevacizumab. *J AAPOS* 2014; 18:295.
- Azorin D, et al:** Systemic juvenile xanthogranuloma with fatal outcome. *Pediatr Dermatol* 2009; 26:709.
- Berti S, et al:** Giant congenital juvenile xanthogranuloma. *Arch Dis Child* 2013; 98:317.
- Bowling JC, et al:** Solitary anogenital xanthogranuloma. *Clin Exp Dermatol* 2005; 30:716.
- Chantorn R, et al:** Severe congenital systemic juvenile xanthogranuloma in monozygotic twins. *Pediatr Dermatol* 2008; 25:470.
- Chiba K, et al:** Diagnostic and management difficulties in a case of multiple intracranial juvenile xanthogranuloma. *Childs Nerv Syst* 2013; 29:1039.
- De Oliveria Rocha B, et al:** Erythematous yellowish plaque on the face of a child. *Int J Dermatol* 2013; 52:295.
- Dehner LP:** Juvenile xanthogranulomas in the first two decades of life: a clinicopathologic study of 174 cases with cutaneous and extracutaneous manifestations. *Am J Surg Pathol* 2003; 27:579.
- Ferrari F, et al:** Juvenile xanthogranuloma and nevus anemicus in the diagnosis of neurofibromatosis type 1. *JAMA Dermatol* 2014; 150:42.
- Gressot LV, et al:** Disseminated intracranial juvenile xanthogranulomatosis in a neonate without cutaneous lesions. *J Neurosurg Pediatr* 2013; 12:187.
- Gruber R, et al:** Concomitant juvenile xanthogranuloma and cutaneous mastocytosis in a 3-year-old Swedish girl: case report and review of the literature. *Int J Dermatol* 2011; 50:611.
- Gunson TH, Birchall NM:** Symmetrical giant facial plaque-type juvenile xanthogranuloma. *J Am Acad Dermatol* 2008; 59:S56.
- Hara T, et al:** Prolonged severe pancytopenia preceding the cutaneous lesions of juvenile xanthogranuloma. *Pediatr Blood Cancer* 2006; 47:103.
- Haughton AM, et al:** Disseminated juvenile xanthogranulomatosis in a newborn resulting in liver transplantation. *J Am Acad Dermatol* 2008; 58:S12.
- Hirata M, et al:** A case of adult limbal xanthogranuloma. *Jpn J Ophthalmol* 2007; 51:302.
- Jesenak M, et al:** Wiskott-Aldrich syndrome caused by a new mutation associated with multifocal dermal juvenile xanthogranulomas. *Pediatr Dermatol* 2013; 30:91.
- Kaur MR, et al:** Disseminated clustered juvenile xanthogranuloma: an unusual morphological variant of a common condition. *Clin Exp Dermatol* 2008; 33:575.
- Kim CR, et al:** A case of congenital spindle cell xanthogranuloma. *Am J Dermatopathol* 2012; 34:672.
- Kiopelidou D, et al:** Linear-agminated juvenile xanthogranulomas. *Int J Dermatol* 2008; 47:387.
- Lehrke HD, et al:** Intracardiac juvenile xanthogranuloma with presentation in adulthood. *Cardiovasc Pathol* 2014; 23:54.

- Mallory M, et al:** Café-au-lait macules and enlarging papules on the face. *J Am Acad Dermatol* 2013; 68:348.
- Matcham NJ, et al:** Systemic juvenile xanthogranulomatosis imitating a malignant abdominal wall tumor with lung metastases. *J Pediatr Hematol Oncol* 2007; 29:72.
- Messeguer F, et al:** Clustered juvenile xanthogranuloma. *Pediatr Dermatol* 2013; 30:e295.
- Murphy JT, et al:** Juvenile xanthogranuloma: diverse presentations of noncutaneous disease. *J Pediatr Hematol Oncol* 2014; 36(8):641–645.
- Ng SY:** Segmental juvenile xanthogranuloma. *Pediatr Dermatol* 2014; 31:615.
- Ngendahayo P, de Saint Aubain N:** Mitotically active xanthogranuloma: a case report with review of the literature. *Am J Dermatopathol* 2012; 34:e27.
- Papadakis V, et al:** A rare case of neonatal systemic xanthogranulomatosis with severe hepatic disease and metachronous skin involvement. *J Pediatr Hematol Oncol* 2012; 34:226.
- Perez-Becker R, et al:** An aggressive juvenile xanthogranuloma clonally related to a preceding T-cell acute lymphoblastic leukemia. *Pediatr Blood Cancer* 2010; 56:859.
- Pinto C, et al:** Giant congenital juvenile xanthogranuloma presenting as a yellowish atrophic plaque. *J Dermatol* 2014; 41:647.
- Savasan S, et al:** Successful bone marrow transplantation for life-threatening xanthogranuloma disseminatum in neurofibromatosis type-1. *Pediatr Transplant* 2005; 9:534.
- Shoo BA, et al:** Xanthogranulomas associated with hematologic malignancy in adulthood. *J Am Acad Dermatol* 2008; 59:488.
- Sivapirabu G, et al:** Juvenile xanthogranuloma: challenges in complicated cases. *Australas J Dermatol* 2011; 52:284.
- Song M, et al:** Structural correlations between dermoscopic and histopathological features of juvenile xanthogranuloma. *J Eur Acad Dermatol Venereol* 2011; 25:259.
- Strehl JD, et al:** Juvenile xanthogranulomas developing after treatment of Langerhans cell histiocytosis: case report and literature review. *Int J Clin Exp Pathol* 2012; 5:720.
- Sugiura K, et al:** Symmetrical giant facial plaque-type juvenile xanthogranuloma persisting beyond 10 years of age. *Acta Derm Venereol* 2014; 94:465.
- Weiss VL, et al:** Juvenile xanthogranuloma: an unusual cause of intratesticular mass in childhood. *Urology* 2014; 83:1173.

## Benign cephalic histiocytosis

Benign cephalic histiocytosis (BCH) is a rare condition affecting boys and girls of all races equally. The onset is between 2 and 34 months of age (rarely up to 5 years), with 50% of cases beginning between 5 and 12 months. The disease begins initially on the head in virtually all cases, often the cheeks, eyelids, forehead, and ears. Lesions may later appear on the neck and upper trunk and less often, more caudad. There are always multiple lesions, but often few in number (5–20), although they can number more than 100. Individual lesions are slightly raised, reddish-yellow papules 2–4 mm in diameter. Lesions may coalesce to give a reticulate appearance. The lesions cause no symptoms. The mucosa and viscera are not involved. Lesions spontaneously involute over 2–8 years, leaving behind hyperpigmented macules. Some cases of BCH have evolved to become XGs, and one patient later developed generalized eruptive histiocytoma many years after the involution of BCH. This supports the concept outlined earlier that these conditions lie along a spectrum, and all derive from the same cell type, a dermal dendritic cell. Histologically, there is a diffuse dermal infiltration of monomorphous macrophages, which stain positive for CD68 and factor XIIIa and negative with S-100 and CD1a.

- Koca R, et al:** Benign cephalic histiocytosis: a case report. *Ann Dermatol* 2011; 23:508.
- Patsatsi A, et al:** Benign cephalic histiocytosis: case report and review of the literature. *Pediatr Dermatol* 2014; 31:547.

## Generalized eruptive histiocytoma (generalized eruptive histiocytosis)

Generalized eruptive histiocytosis (GEH) is a very rare disease, usually presenting in young adulthood. The diagnostic criteria follow:

1. Widespread, erythematous, essentially symmetric papules, especially involving the trunk and proximal extremities, sparing the flexors, and rarely involving the mucous membranes (there is no visceral involvement)
2. Progressive development of new lesions, often in crops, over several years with eventual spontaneous involution to hyperpigmented macules
3. Benign histologic picture of monomorphous, vacuolated macrophages

Lesions appear in crops and may be grouped or clustered. (Since Winkelmann's initial report of this entity, several cases with grouped lesions have been reported, so finding grouped lesions does not exclude the diagnosis of GEH.) They are skin-colored, brown, or violaceous. GEH is rare in childhood, if indeed it is a separate condition. In adults and children, GEH may suddenly appear several weeks after a bacterial or viral illness; in adults it may be associated with underlying malignancy, usually leukemia or lymphoma. GEH is distinguished from xanthoma disseminatum by the lack of visceral disease, the benign course, and by the scalloped appearance of the macrophages in xanthoma disseminatum. Histologically, there is a dermal infiltrate of monomorphous vacuolated macrophages and mononuclear histiocytes. The GEH cells stain positive for vimentin, CD68, and usually factor XIIIa, and negative for S-100, and CD1a. The natural history of GEH is unpredictable, with complete resolution in some cases and persistence in others. Some cases have progressed to widespread xanthogranulomas, xanthoma disseminatum, or progressive nodular histiocytosis, again supporting the concept that these diseases all fall along a spectrum and derive from the same cell type. In childhood, no treatment may be required. In adulthood, treatment with PUVA or isotretinoin could be considered.

- Attia A, et al:** Generalized eruptive histiocytoma. *J Dermatol Case Rep* 2011; 3:53.
- Chern E, et al:** Generalized eruptive histiocytosis in an infant. *Acta Derm Venereol* 2010; 90:204.
- Klemke C, et al:** Atypical generalized eruptive histiocytosis associated with acute monocytic leukemia. *J Am Acad Dermatol* 2003; 49:233.
- Seward JL, et al:** Generalized eruptive histiocytosis. *J Am Acad Dermatol* 2004; 50:116.
- Sharath Kumar BC, et al:** Generalized eruptive histiocytosis mimicking leprosy. *Indian J Dermatol Venereol Leprol* 2011; 77:498.
- Tamiya H, et al:** Generalized eruptive histiocytoma with rapid progression and resolution following exanthema subitum. *Clin Exp Dermatol* 2005; 30:300.

## Xanthoma disseminatum (Montgomery syndrome)

Xanthoma disseminatum (XD) is a very rare, potentially progressive non-LCH that preferentially affects males in childhood or young adulthood (2:1 male/female ratio). XD is characterized by the insidious onset of small, yellowish red to brown papules and nodules that are discrete and disseminated. They characteristically involve the eyelids and flexural areas of the axillary and inguinal folds and the antecubital and popliteal fossae. Over years, the lesions increase in number, forming coalescent xanthomatous plaques and nodules. About 30–50% of cases have mucous membrane involvement, most often of the oropharynx (causing dysphagia), larynx (causing



dysphonia and airway obstruction), and conjunctiva and cornea (causing blindness). Diabetes insipidus, usually transient, occurs in 40% (30% at presentation). CNS involvement, with epilepsy, hydrocephalus, and ataxia, can occur. Synovitis and osteolytic bone lesions have been described. The natural history of the disease is variable. About one third of XD patients undergo spontaneous complete remission, one-third have partial remission, and one-third have persistent or progressive disease. Patients who have a spontaneous complete remission do not have evidence of systemic disease other than diabetes insipidus. Spontaneous remission often leaves areas of atrophy or anetoderma, caused by local loss of elastic tissue.

The serum lipids are abnormal in 20% of XD cases, which may lead to confusion with hyperlipidemic xanthomatosis. Histologic examination of early lesions shows surprisingly nonfoamy, scalloped macrophages. Later, lesions show xanthoma cells, Touton giant cells, and frequently a mild inflammatory cell infiltrate of lymphocytes, plasma cells, and neutrophils. The macrophages stain with CD68 and factor XIIIa.

Disseminated xanthosiderohistiocytosis is a variant of XD in which the lesions have a keloidal consistency; they have annular borders, a cephalad distribution, and extensive iron and lipid deposition in the macrophages and connective tissue.

Progressive XD can produce considerable morbidity and can even be fatal. Therefore, aggressive therapy may be indicated. Lipid-lowering therapy has improved lesions in a few patients. 2-Chlorodeoxyadenosine, 0.14 mg/kg/day for 5 days every month for five to eight cycles, resulted in substantial improvement in five eighths of patients with limited toxicity. 18F-FDG PET or computed tomography (CT) can be useful in defining extent of disease and response to treatment of visceral lesions.

**Attia AM, et al:** Xanthoma disseminatum: a progressive case with multisystem involvement. *J Postgrad Med* 2014; 60:69.

**Jin S, et al:** A case of xanthoma disseminatum: evaluation and monitoring by 18F-fluorodeoxyglucose positron emission tomography/computed tomography/computed tomography. *Br J Dermatol* 2014; 170:1177.

**Khezri F, et al:** Xanthoma disseminatum: effective therapy with 2-chlorodeoxyadenosine in a case series. *Arch Dermatol* 2011; 147:459.

**Kim WJ, et al:** Successful treatment of xanthoma disseminatum with combined lipid lowering agents. *Ann Dermatol* 2012; 24:380.

**Lee EH, et al:** Successful treatment of xanthoma disseminatum with simvastatin. *J Dermatol* 2011; 38:1015.

**Lee HC, et al:** Unusual flexural papules in a male patient with diabetes. *Clin Exp Dermatol* 2012; 37:931.

**Park HY, et al:** A case of xanthoma disseminatum with spontaneous resolution over 10 years: review of the literature on long-term follow-up. *Dermatology* 2011; 222:236.

**Toberer F, et al:** Intertriginous orange-to brownish papules and plaques: a quiz. *Acta Derm Venereol* 2013; 93:493.

## Progressive nodular histiocytosis

Progressive nodular histiocytosis (PNH) is a very rare disorder that affects men and women equally and usually begins between ages 40 and 60 years. The characteristic clinical feature is the development of two types of lesion: superficial papules and deeper, larger, subcutaneous nodules. The superficial lesions are small xanthomatous papules up to 5 mm in diameter. They are diffusely distributed on the body, but spare the flexors (unlike xanthoma disseminatum, which favors the flexors). The larger deep lesions can be up to 5 cm in diameter and are associated with pain, ulceration, and disfigurement. Smaller lesions may evolve to the larger lesions over time. On the face, lesions may coalesce, giving the patient a leonine facies and creating ectropion. New lesions progressively appear, and spontaneous resolution of individual lesions can be seen, but general involution of all the lesions does not occur.

Mucosal lesions are unusual but can involve the conjunctiva and larynx. Iron deficiency anemia can occur because the histiocytes in the nodules may accumulate iron, reducing available body iron stores. Histologically, the superficial lesions show foamy macrophages, and the deeper lesions show a densely cellular proliferation of spindle-shaped histiocytes with multinucleated giant cells. It is the development of these deep lesions composed of primarily spindled histiocytes that is the diagnostic feature of PNH. Local excision may be used for symptomatic lesions.

**Amin SM, et al:** Progressive nodular histiocytosis with normal karyotypic analysis. *Dermatol Online J* 2013; 19:18577.

**Chapman LW, et al:** Reddish-brown nodules and papules in an elderly man. *JAMA Dermatol* 2013; 149:1229.

**Glavin FL, et al:** Progressive nodular histiocytosis: a case report with literature review, and discussion of differential diagnosis and classification. *J Cutan Pathol* 2009; 36:1286.

**Hilker O, et al:** Progressive nodular histiocytosis. *J Dtsch Dermatol Ges* 2013; 11:301.

**Nofal A, et al:** Progressive nodular histiocytosis: a case report and literature review. *Int J Dermatol* 2011; 50:1546.

## Papular xanthoma

Papular xanthoma (PX) is a rare form of non-LCH that is poorly defined. The disease can occur at any age, but usually appears in early childhood or after adolescence. PX usually presents as a solitary lesion favoring men 4:1 over women. The primary lesion is a small, yellow papule 1–10 mm in diameter. If multiple, lesions are generalized, not grouped, and do not favor the flexors. No abnormalities are found on lipid profile examination. Erosive arthritis (resembling multicentric reticulohistiocytosis) has been reported in one child and one adult. Histologically, there are aggregates of xanthomatized foamy macrophages in the dermis, with Touton giant cells. Inflammatory cells are scant or absent. Cells stain positive for markers of monocytes/macrophages such as CD68, but are negative for factor XIIIa. The differential diagnosis includes normolipemic plane xanthomas and normolipemic papuloeruptive xanthomatosis. In infants, the natural history is for spontaneous involution. In one adult patient, treatment with doxycycline was effective.

**Andrew R, et al:** Papular xanthomas with destructive arthritis. *J Am Acad Dermatol* 2013; 69:e309.

**Aubert O, et al:** Favorable radiological outcome of skeletal Erdheim-Chester disease involvement with anakinra. *Joint Bone Spine* 2013; 80:206.

**Breier F, et al:** Papular xanthoma: a clinicopathological study of 10 cases. *J Cutan Pathol* 2002; 29:200.

**Matiz C, et al:** Papular xanthomas and erosive arthritis in a 3 year old girl: is this a new MRH variant? *Pediatr Rheumatol* 2009; 7:15.

## Erdheim-Chester disease

A rare non-LCH, Erdheim-Chester disease (ECD) is primarily a visceral disorder with cutaneous lesions in 20–30% of patients (half at presentation). ECD can begin at any age from childhood to the ninth decade. The characteristic feature is bilateral and symmetric sclerosis of the metaphyseal and diaphyseal regions of the long bones. These radiologic findings are considered pathognomonic. Diabetes insipidus may occur, from involvement of the pituitary and retroperitoneal fibrosis affecting the kidneys. Despite a normal gross appearance, many internal organs are affected. The course is progressive with infiltration of many visceral organs, followed by fibrosis. This is often fatal, usually from pulmonary fibrosis and cardiac failure; 1-year and 5-year survival are 96% and 68%, respectively. Skin lesions typically present as red-brown or

xanthomatous, 2–15 mm papules or nodules. Lesions favor the eyelids (as with xanthomas), axilla, groin, neck, trunk (inframammary areas), and face (similar to lesions seen in XD). As in LCH, a significant percentage of patients (~50%) have the *BRAF* V600E mutation. Some patients have simultaneously both LCH and ECD (called mixed histiocytosis), apparently driven by these mutations. Less often, patients have had *NRAS* mutations. Initial treatment is with IFN alfa; in unresponsive patients, anakinra or infliximab (cytokine blockade) may be beneficial. In patients who progress despite these treatments, a *BRAF* inhibitor (vemurafenib) or *NRAS* inhibitor (if a mutation is detected) could be considered. Cladribine and imatinib are options if no mutation is detected.

**Aitken SJ, et al:** An *NRAS* mutation in a case of Erdheim-Chester disease. *Histopathology* 2015; 66(2):316–319.

**Cangi MG, et al:** *BRAF*<sup>V600E</sup> mutation is invariably present and associated to oncogene-induced senescence in Erdheim-Chester disease. *Ann Rheum Dis* 2014; Mar 26. [Epub ahead of print.]

**Cavalli G, et al:** The multifaceted clinical presentations and manifestations of Erdheim-Chester disease: comprehensive review of the literature and of 10 new cases. *Ann Rheum Dis* 2013; 72:1691.

**Dagna L, et al:** Tumor necrosis factor  $\alpha$  as a master regulator of inflammation in Erdheim-Chester disease: rationale for the treatment of patients with infliximab. *J Clin Oncol* 2012; 30:e286.

**Diamond EL, et al:** Consensus guidelines for the diagnosis and clinical management of Erdheim-Chester disease. *Blood* 2014; 124:483.

**Diamond EL, et al:** Detection of an *NRAS* mutation in Erdheim-Chester disease. *Blood* 2013; 122:1089.

**Ferreiro E, et al:** TNF- $\alpha$  Erdheim-Chester disease pericardial effusion promotes endothelial leakage in vitro and is neutralized by infliximab. *Rheumatology* 2014; 53:198.

**Haroche J, et al:** High prevalence of *BRAF* V600E mutations in Erdheim-Chester disease but not in other non-Langerhans cell histiocytosis. *Blood* 2012; 120:2700.

**Hervier B, et al:** Association of both Langerhans cell histiocytosis and Erdheim-Chester disease linked to the *BRAF*-V600E mutation: a multicenter study of 23 cases. *Blood* 2014; 124:1119.

**Hervier B, et al:** Treatment of Erdheim-Chester disease with long-term high-dose interferon alfa. *Semin Arthritis Rheum* 2012; 41:907.

**Killu AM, et al:** Erdheim-Chester disease with cardiac involvement successfully treated with anakinra. *Int J Cardiol* 2013; 167:e115.

**Kornik RI, et al:** Diabetes insipidus, bone lesions, and new-onset red-brown papules in a 42-year-old man. *J Am Acad Dermatol* 2013; 68:1034.

**Munoz J, et al:** Erdheim-Chester disease: characteristics and management. *Mayo Clin Proc* 2014; 89:985.

## Progressive mucinous histiocytosis in women

Progressive mucinous histiocytosis is a rare autosomal dominant or X-linked hereditary disorder described primarily in women. The skin lesions consist of a few to numerous skin-colored to red-brown papules, ranging from pinhead to pea sized, which tend to appear on the face, arms, forearms, hands, and legs. Onset is in the second decade of life, with slow progression and no tendency to spontaneous involution. Visceral and mucosal lesions have not been reported. Histologically, in the middermis there is a proliferation of spindle-shaped and epithelioid monocytes. Superficial telangiectatic vessels and increased mast cells are found. Abundant mucin is demonstrated by alcian blue staining, indicating the presence of acid mucopolysaccharides. This condition can be distinguished from the other non-Langerhans cell histiocytoses by its familial pattern, lack of lipidized and multinucleated cells, and presence of mucin. Immunoperoxidase studies most consistently show positivity for CD68 and negativity for CD1a, S-100, and CD34.

**Schlegel C, et al:** Hereditary progressive mucinous histiocytosis: first report in a male patient. *Acta Derm Venereol* 2010; 90:65.

## Reticulohistiocytosis

Two distinct forms of reticulohistiocytosis occur: reticulohistiocytoma and multicentric reticulohistiocytosis (MRH). The two forms have identical histology but distinct clinical manifestations.

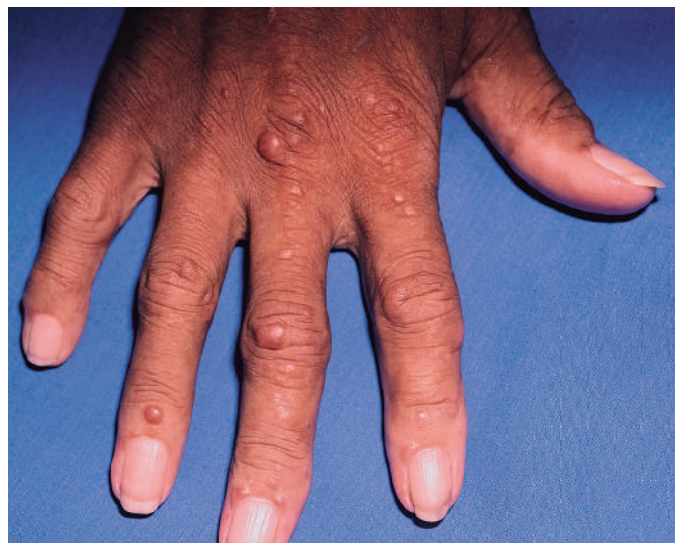### Reticulohistiocytoma

Reticulohistiocytoma usually occurs as a solitary, firm dermal lesion less than 1 cm in diameter. Lesions favor the trunk and extremities. Solitary lesions and multiple lesions without systemic involvement, in contrast to MRH, have been described, mainly in adult men and rarely in children.

### Multicentric reticulohistiocytosis

A multisystem disease, MRH usually begins about age 50 (range 6–86 years). It is twice as common in women as men and affects all races. The primary manifestations are skin lesions and a potentially destructive arthritis. In 40% of cases the joint disease occurs first, in 30% the skin lesions precede the joint symptoms, and in 40% the joint and skin disease appear simultaneously.

Clinically, there may be a few to a few hundred firm, skin-colored to red-brown papules and nodules, mostly 2–10 mm in diameter, but some reaching several centimeters in size (Fig. 31-20). These occur most frequently on the fingers and hands, with a tendency to cause paronychia lesions. In about half of MRH patients, lesions will be arranged around nailfolds, giving a “coral bead” appearance, which may be associated with nail dystrophy. The upper half of the body, including the arms, scalp, face, ears, and neck, are also common sites. About 90% of patients have lesions on the face and hands. Nodular and papular involvement of the pinnae and a symmetric distribution of the lesions, especially over joints, are characteristic. The nodules on the arms, elbows, and knees may resemble rheumatoid nodules. Diffuse erythematous lesions can occur, at times simulating erythroderma. Patients may present initially with macular or minimally infiltrated erythema on sun-exposed sites, simulating a photodermatitis or dermatomyositis. Small papules are often present, which are useful in confirming the diagnosis of MRH. Lesions may ulcerate. Xanthelasma occurs in 30% of patients. Atypical patchy areas of hypopigmentation over the face and upper limbs have been noted. About 10% of MRH patients may complain of pruritus. The itching is not localized to the skin lesions and may precede their appearance.



**Fig. 31-20** Multicentric reticulohistiocytosis.



Mucous membrane involvement is seen in one third of MRH patients and is most common on the lips and tongue; other sites are the gingiva, palate, buccal mucosa, nasopharynx, larynx, and sclera. Lesions of the esophagus can lead to dysphagia. One-third have hypercholesterolemia and xanthelasma. Rheumatoid factor is usually negative.

Osteoarticular changes are the most important aspect of MRH. No association exists between the extent, size, or severity of the skin eruption and the course of the joint disease. The associated arthropathy is an inflammatory, symmetric, polyarticular arthritis that can affect many joints, including the hands, knees, shoulders, wrists, hips, ankles, elbows, feet, and spine. The arthritis can be rapidly destructive and mutilating, with absorption and telescopic shortening of the phalanges and digits—doigts en lorgnette (opera-glass fingers). In earlier reports, at least 50% of cases developed arthritis mutilans, but this has been reduced to about 11%. The infiltrating cells in the skin and joints are identical on microscopic examination and immunophenotypic evaluation. The clinical course varies. In many cases, there is complete involution after about 8 years. The joint destruction is permanent, however, and is a cause of severe disability. The joint involvement may resemble rheumatoid arthritis and psoriatic arthritis. Weight loss and fever occur in one third of patients.

About 15% of patients with MRH have associated autoimmune disorders. Thyroiditis, Sjögren syndrome, ulcerative colitis, and vitiligo have all been reported. About 25% of reported cases have had an associated malignancy. Given this high rate of malignancy, every patient with MRH should have a careful history and physical examination and a complete age-appropriate cancer screening, repeated at regular intervals (similar to the protocol followed for patients with dermatomyositis). No specific tumor type has been associated; cancers reported with MRH include breast, gastrointestinal tract, genitourinary tract, and melanoma, as well as leukemia and lymphoma. The skin lesions usually appear before diagnosis of the malignancy, but synchronous behavior of the skin lesions and underlying malignancy is only occasionally reported. In one case, tuberculosis was identified, and treatment of the TB led to resolution of the MRH.

Other organs and tissues may be involved, such as bone, muscle, lymph nodes, liver, myocardium, pericardium, lungs, pleura, and stomach. Myocardial involvement may be fatal. Usual interstitial pneumonia or typical MRH cells may be seen in pulmonary lesions.

Histologically, the skin lesions are usually centered in the middermis and tend to occupy much or all of the dermis. The infiltrating cells are mononuclear and multinucleate monocytes/macrophages. The giant cells are most characteristic, with an abundant smooth or slightly granular, eosinophilic or amphophilic, “ground-glass” cytoplasm. Their cytoplasm is darker in the center than at the periphery. These cells stain positive for periodic acid–Schiff (PAS) after diastase digestion. The overlying epidermis may be thinned but is usually separated from the dermal process by a narrow zone of collagen (grenz zone). Characteristically, there is a polymorphous infiltrate of lymphocytes, neutrophils, eosinophils, and plasma cells within the lesions. On immunohistochemistry, monocyte/macrophage cells stain positive for CD68, vimentin, and CD163. In MRH, the cells in the skin and joints stain positive for acid phosphatase that is tartrate resistant (TRAP) and cathepsin K, markers for osteoclasts. This may explain the response of MRH to bisphosphonates, which cause apoptosis of osteoclasts and are taken up by cells in the reticuloendothelial system.

Given the aggressive nature of the arthritis, early and adequate treatment should be considered. However, associated malignancy is common and can be worsened by immunosup-

pressive therapy. The same would be true if the patient had underlying asymptomatic TB. Initially, the patient should be screened for these two conditions, and these should be adequately treated if found. In patients free of neoplasia and TB, the treatment is individualized. Spontaneous remissions are common, making efficacy of treatment difficult to determine. The major goal of treatment is to prevent the destruction of the joints that are the cause of disability. If systemic therapy is considered, two approaches can be taken. One is the use of the combination of systemic corticosteroids, methotrexate (or leflunomide), and a TNF inhibitor. Of the TNF inhibitors, infliximab has proved more effective than etanercept and should probably be the initial agent used. The other approach is to use a combination of immunosuppressives and a bisphosphonate. The infiltrating cells in MRH seem phenotypically to be osteoclastic in behavior, so this therapy is logical and appears to be joint sparing. In refractory cases, use of a bisphosphonate and TNF inhibitor with methotrexate and systemic corticosteroids could be considered. For patients with skin lesions only, therapy is not required. PUVA, antimalarials, topical nitrogen mustard, and low-dose methotrexate, a bisphosphonate, or a TNF inhibitor could be considered if symptoms are severe.

**Arai S, et al:** Multicentric reticulohistiocytosis presenting with the cutaneous features of photosensitivity dermatitis. *J Dermatol* 2012; 39:180.

**Bennassar A, et al:** Multicentric reticulohistiocytosis with elevated cytokine serum levels. *J Dermatol* 2011; 38:905.

**Codriansky KA, et al:** Multicentric reticulohistiocytosis: a systemic osteoclastic disease? *Arthritis Rheum* 2008; 59:444.

**Cyrułnik AA, et al:** Multicentric reticulohistiocytosis: contrasting presentations in 2 Hispanic patients. *Cutis* 2014; 93:243.

**Goto H, et al:** Successful treatment of multicentric reticulohistiocytosis with alendronate. *Arthritis Rheum* 2003; 48:3538.

**Ho SG, Yu RC:** A case of multicentric reticulohistiocytosis with multiple lytic skull lesions. *Clin Exp Dermatol* 2005; 30:515.

**Hsiung SH, et al:** Multicentric reticulohistiocytosis presenting with clinical features of dermatomyositis. *J Am Acad Dermatol* 2003; 48:S11.

**Kalajian AH, Callen JP:** Multicentric reticulohistiocytosis successfully treated with infliximab: an illustrative case and evaluation of cytokine expression supporting anti-tumor necrosis factor therapy. *Arch Dermatol* 2008; 144:1350.

**Kamata Y, Minota S:** Progressive multicentric reticulohistiocytosis. *Intern Med* 2012; 51:687.

**Liu YU, Fang K:** Multicentric reticulohistiocytosis with generalized systemic involvement. *Clin Exp Dermatol* 2004; 29:373.

**Lonsdale-Eccles AA, et al:** Successful treatment of multicentric reticulohistiocytosis with leflunomide. *Br J Dermatol* 2009; 161:470.

**Lovelace K, et al:** Etanercept and the treatment of multicentric reticulohistiocytosis. *Arch Dermatol* 2005; 141:1167.

**Macia-Villa CC, Zea-Mendoza A:** Multicentric reticulohistiocytosis: case report with response to infliximab and review of treatment options. *Clin Rheumatol* 2014. [Epub ahead of print.]

**Mavragani CP, et al:** Alleviation of polyarticular syndrome in multicentric reticulohistiocytosis with intravenous zoledronate. *Ann Rheum Dis* 2005; 64:1521.

**McIlwain KL, et al:** Multicentric reticulohistiocytosis with prominent cutaneous lesions and proximal muscle weakness masquerading as dermatomyositis. *J Rheumatol* 2005; 32:193.

**Miettinen M, Fetsch JF:** Reticulohistiocytoma (solitary epithelioid histiocytoma): a clinicopathologic and immunohistochemical study of 44 cases. *Am J Surg Pathol* 2006; 30:521.

**Millar A, et al:** Multicentric reticulohistiocytosis: a lesson in screening for malignancy. *Rheumatology (Oxford)* 2008; 47:1102.

**Rentsch JL, et al:** Prolonged response of multicentric reticulohistiocytosis to low dose methotrexate. *J Rheumatol* 1998; 25:1012.

**Rudd A, et al:** A case of multicentric reticulohistiocytosis responsive to azathioprine in a patient with no underlying malignancy. *Australas J Dermatol* 2011; 52:202.

**SantaLucia P, Helm MF:** What is your diagnosis? Diagnosis: multicentric reticulohistiocytosis with dermatomyositislike features. *Cutis* 2009; 84:272.

**Satoh M, et al:** Treatment trial of multicentric reticulohistiocytosis with a combination of prednisolone, methotrexate and alendronate. *J Dermatol* 2008; 35:168.

**Tan BH, et al:** Multicentric reticulohistiocytosis and urologic carcinomas: a possible paraneoplastic association. *J Cutan Pathol* 2011; 38:43.

**Taniguchi T, et al:** Ultraviolet light-induced Köbner phenomenon contributes to the development of skin eruptions in multicentric reticulohistiocytosis. *Acta Derm Venereol* 2011; 91:160.

**Webb-Detiege T, et al:** Infiltration of histiocytes and multinucleated giant cells in the myocardium of a patient with multicentric reticulohistiocytosis. *J Clin Rheumatol* 2009; 15:25.

**West KL, et al:** Multicentric reticulohistiocytosis: a unique case with pulmonary fibrosis. *Arch Dermatol* 2012; 148:228.

**Yang HJ, et al:** Multicentric reticulohistiocytosis with lungs and liver involved. *Clin Exp Dermatol* 2009; 34:183.

## Indeterminate cell histiocytosis

Indeterminate cell histiocytosis (ICH) is a rare histiocytosis composed of cells that stain variably with markers for Langerhans cells (S-100 and CD1a) but are negative for langerin (CD207) and do not demonstrate Langerhans cell granules on electron microscopy. The cells may be CD68 positive, suggesting a monocyte/macrophage lineage. The exact origin of these cells is unclear. ICH affects both children and adults. Solitary and multiple lesions may occur, and the color of lesions varies from yellow to red-brown. Lesions may be papules, plaques, or nodules 3 mm to 10 cm in size. These clinical features are not specific and resemble the papular lesions seen in many forms of non-LCH. Conjunctival involvement has been reported. Solitary malignant tumors with similar immunohistochemistry have been described, clinically resembling atypical fibroxanthoma. ICH seems to have a benign course in the vast majority of patients, and no therapy is required. UVB, PUVA, and total-skin electron beam therapy have resulted in clearing of skin lesions. Pravastatin, thalidomide (alone or with isotretinoin), and methotrexate have been effective. Many patients have been treated with numerous chemotherapeutic agents similar to those used for LCH, but therapeutic response has been equivocal. Acute myelogenous leukemia has followed some of these courses of chemotherapy. Solitary lesions with malignant histology should be managed with surgical excision, ensuring adequate margins. The utility of adjunctive therapy and sentinel lymph node sampling is not known. Post-scabietic nodules and rarely post-pityriasis rosea lesions may contain a proliferation of cells that are immunohistologically identical to indeterminate cells.

**Bakry OA, et al:** Indeterminate cell histiocytosis with naïve cells. *Rare Tumors* 2013; 5:e13.

**Bard S, et al:** S100-negative indeterminate cell histiocytosis in an African American child responsive to narrowband ultraviolet B. *Pediatr Dermatol* 2011; 28:524.

**Burns MV, et al:** Treatment of indeterminate cell histiocytosis with pravastatin. *J Am Acad Dermatol* 2010; 64:e85.

**Caputo R, et al:** Chemotherapeutic experience in indeterminate cell histiocytosis. *Br J Dermatol* 2005; 153:206.

**Ferran M, et al:** Acquired mucosal indeterminate cell histiocytoma. *Pediatr Dermatol* 2007; 24:253.

**Fournier J, et al:** Successful treatment of indeterminate cell histiocytosis with low-dose methotrexate. *J Dermatol* 2011; 38:937.

**Frater JL, et al:** Histiocytic sarcoma with secondary involvement of the skin and expression of CD1a: evidence of indeterminate cell differentiation? *J Cutan Pathol* 2006; 33:437.

**Hashimoto K, et al:** Post-scabietic nodules: a lymphohistiocytic reaction rich in indeterminate cells. *J Dermatol* 2000; 27:181.

**Logemann N, et al:** Indeterminate cell histiocytosis successfully treated with narrowband UVB. *Dermatol Online J* 2013; 19:20031.

**Malhomme de la Roche H, et al:** Indeterminate cell histiocytosis responding to total skin electron beam therapy. *Br J Dermatol* 2008; 158:838.

**Tardío JC, et al:** Self-regressing S100-negative CD1a-positive cutaneous histiocytosis. *Am J Dermatopathol* 2013; 35:e57.

**Tóth B, et al:** Indeterminate cell histiocytosis in a pediatric patient: successful treatment with thalidomide. *Pathol Oncol Res* 2012; 18:535.

**Vener C, et al:** Indeterminate cell histiocytosis in association with later occurrence of acute myeloblastic leukaemia. *Br J Dermatol* 2007; 156:1357.

**Ventarola DJ, et al:** S-100-negative, CD1a-positive histiocytosis: a new variant with features of both indeterminate cells and interstitial dermal dendrocytes. *Arch Dermatol* 2011; 147:995.

**Wollenberg A, et al:** Long-lasting "Christmas tree rash" in an adolescent: isotopic response of indeterminate cell histiocytosis in pityriasis rosea? *Acta Derm Venereol* 2002; 82:288.

**Yin R, et al:** Recurrent generalized indeterminate cell histiocytosis: a case report. *J Am Acad Dermatol* 2010; 63:e3.

## Sea-blue histiocytosis

Sea-blue histiocytosis may occur as a familial inherited syndrome or as an acquired secondary or systemic infiltrative process. The characteristic and diagnostic cell is a histiocytic cell containing cytoplasmic granules that stain blue-green with Giemsa and blue with May-Gruenwald stain. The disorder is characterized by infiltration of these cells into the marrow, spleen, liver, lymph nodes, and lungs, as well as the skin in some patients. Skin lesions include papules or nodules, facial waxy plaques, eyelid swelling, and patchy-gray pigmentation of the face and upper trunk. Similar histologic findings have occurred in patients with myelogenous leukemia, light-chain deposition disease, adult Niemann-Pick disease (type B), sphingomyelinase deficiency, or mutations in the apolipoprotein E gene, and following the prolonged use of intravenous fat supplementation or liposomal amphotericin B. The unifying feature in all these conditions is an abnormal lipid metabolism by the infiltrating histiocytes. This condition has been seen in the infiltrate of a patient with CTCL.

**Bigorgne C, et al:** Sea-blue histiocyte syndrome in the bone marrow secondary to total parenteral nutrition. *Leukemia Lymphoma* 1998; 28:523.

**Caputo R, et al:** Unusual variants of non-Langerhans cell histiocytosis. *J Am Acad Dermatol* 2007; 57:1031.

**Michot JM, et al:** Very prolonged liposomal amphotericin B use leading to a lysosomal storage disease. *Int J Antimicrob Agents* 2014; 43:566.

**Naghashpour M, Cualing H:** Splenomegaly with sea-blue histiocytosis, dyslipidemia, and nephropathy in a patient with lecithin-cholesterol acyltransferase deficiency: a clinicopathologic correlation. *Metabolism* 2009; 58:1459.

**Newman B, et al:** Aggressive histiocytic disorders that can involve the skin. *J Am Acad Dermatol* 2007; 56:302.

## X-type histiocytoses (Langerhans cell histiocytosis)

The X-type group of histiocytoses is caused by infiltration of the skin, and in some cases, other organs, by Langerhans cells. The spectrum of disease is broad, with solitary, usually benign and autoinvoluting lesions at one end and multicentric, multiorgan visceral and skin disease at the other. Most cases of LCH demonstrate clonality and telomere shortening. In addition, *BRAF* and *ARAF* mutations have been detected in a majority of cases. All these features would suggest LCH as a "neoplastic" condition. Adult patients with LCH may have myeloid and solid cancers supporting a "neoplastic" phenotype. In the case of associated leukemias, the leukemic cells may share the same surface markers and may be clonally related. However, preliminary evidence shows that IL-17A is elevated, and IL-17A receptor status determines extent of disease. This suggests that LCH represents a "hybrid" condition with features of both neoplasia and immunologic



dysregulation. This helps to explain the variable outcome from spontaneous involution to progressive and fatal disease.

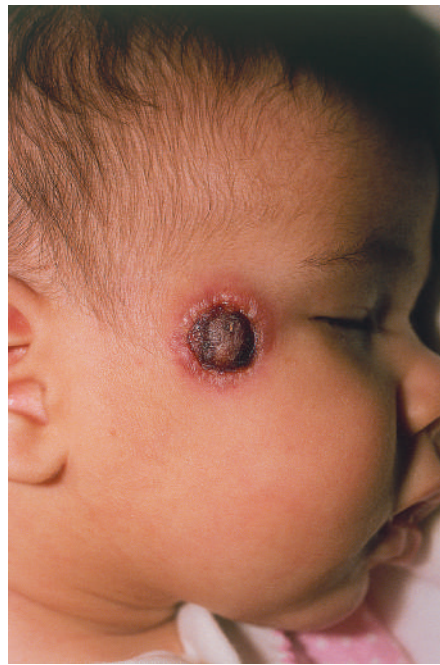Histologically, in all cases of LCH in the skin, there is a dense dermal infiltrate of Langerhans cells. This can be superficial and immediately below the epidermis (usually corresponding to small papules or scaly patches clinically), folliculocentric, or deep and diffuse (in papular and nodular lesions). The Langerhans cells are recognized by their abundant, amphophilic cytoplasm and eccentric round or kidney bean-shaped nucleus. There is frequently exocytosis of the abnormal cells into the overlying epidermis. If this is extensive, macroscopic vesicles can be seen, and erosion can occur secondarily. The dermal infiltrate is accompanied by many other inflammatory cells, including neutrophils, eosinophils, lymphocytes, and plasma cells. Dermal edema and hemorrhage are characteristically present. In larger and older lesions, the infiltrating histiocytic cells become foamy, and fibrosis may be present. These older lesions may lack immunoreactivity for specific Langerhans cell markers and can resemble JXG. The histologic features of the Langerhans cells, such as nuclear atypia and mitotic indices, do not predict prognosis and are not reproducible. Histology is not predictive of biologic behavior. Immunohistochemistry is useful in confirming the diagnosis. The infiltrating cells in LCH are positive for S-100 and CD1a. Langerin is a protein expressed in the Birbeck granule and stained with CD207. Electron microscopy is rarely required to diagnose LCH because of this panel of Langerhans cell, "characteristic" markers.

### Congenital self-healing reticulohistiocytosis (Hashimoto-Pritzker disease)

Congenital self-healing reticulohistiocytosis (CSHR) is an autoinvoluting, self-limited form of LCH. It can be considered as one end of the spectrum of LCH, and although cases continue to be described, it is best approached as a variant of LCH, not a separate entity. CSHR is usually present at birth or appears very soon thereafter, although a case in an 8-year-old child has been reported. CSHR has been described in two forms: a solitary and a multinodular variant. Solitary or generalized lesions can affect any part of the cutaneous surface. Lesions range from 0.2 to 2.5 cm in diameter (Fig. 31-21). Lesions may grow postnatally. Exceptionally large tumors up to 8 cm in diameter can occur. At presentation, the lesions can be papules or nodules, with or without erosion or ulceration. Individual lesions are red, brown, pink, or dusky. Lesions may rarely appear as hemorrhagic bullae. Lesions greater than 1 cm characteristically ulcerate as they resolve. Lesions are asymptomatic and spontaneously involute over 8–24 weeks, leaving atrophic scarring from the ulcerated nodules. Internal involvement has been reported on the mucosa and even in the lungs (which also have spontaneously involuted), making distinction of CSHR and autoinvoluting LCH difficult to separate. Histologically, the skin lesions are composed of Langerhans cells, and no histologic features identify this variant of LCH. Because LCH with systemic involvement may present in identical fashion, systemic evaluation is recommended, including a physical examination, complete blood count, liver function tests, and radiologic evaluation of the bones. The affected child must be followed regularly because, as in other forms of LCH, late recurrences can occur in about 10% of cases.

**Aggarwal V, et al:** Congenital Langerhans cell histiocytosis with skin and lung involvement: spontaneous regression. *Indian J Pediatr* 2010; 77:811.

**Kansal R, et al:** Identification of the V600D mutation in exon 15 of the *BRAF* oncogene in congenital, benign Langerhans cell histiocytosis. *Genes Chromosomes Cancer* 2013; 52:99.



**Fig. 31-21** Congenital self-healing reticulohistiocytosis, solitary lesion.

**Kapur P, et al:** Congenital self-healing reticulohistiocytosis (Hashimoto-Pritzker disease): ten-year experience at Dallas Children's Medical Center. *J Am Acad Dermatol* 2007; 56:290.

**Kim JE, et al:** Solitary congenital erosion in a newborn: report of a solitary congenital self-healing reticulohistiocytosis. *Ann Dermatol* 2014; 26:250.

**Larsen L, et al:** Congenital self-healing reticulohistiocytosis: concern for a poor prognosis. *Dermatology Online J* 2012; 18:2.

**Nakashima T, et al:** Congenital self-healing LCH: a case with lung lesions and review of the literature. *Pediatr Int* 2010; 52:e224.

**Slott Jensen ML, et al:** Congenital self-healing reticulohistiocytosis: an important diagnostic challenge. *Acta Paediatr* 2011; 100:784.

**Wheller L, et al:** Unilesional self-limited Langerhans cell histiocytosis: a case report and review of the literature. *J Cutan Pathol* 2013; 40:595.

**Yurkovich M, et al:** Solitary congenital self-healing Langerhans cell histiocytosis: a benign variant of Langerhans cell histiocytosis? *Dermatol Online J* 2013; 19:3.

### Langerhans cell histiocytosis

A rare disease, LCH is characterized by proliferation of Langerhans cells. Many organs can be affected. International standardization of terminology and treatment protocols has resulted in improved management of patients and has allowed for investigational protocols rapidly to determine efficacy of treatments identified by recent scientific advancements, such as use of vemurafenib with the identification of *BRAF* V600E mutations.

Age of onset is an important determinant of the natural history of the disease, and therefore childhood and adult forms of LCH are considered separately. Adults are more likely to have mucocutaneous lesions, twice as likely to reactivate (63% vs. 37%), and more likely to die of their disease (24% vs. 11%). It is also quite clear that patients may begin with any pattern of disease and evolve or relapse to another pattern. This is especially true of younger children. Up to 50% of children under age 1 year diagnosed with skin-limited LCH progress to have multisystem disease. Repeated evaluation and close follow-up are required.

#### Childhood Langerhans cell histiocytosis

In childhood LCH, boys are slightly more often affected than girls. The incidence in children is about 2.6 cases per 1 million,

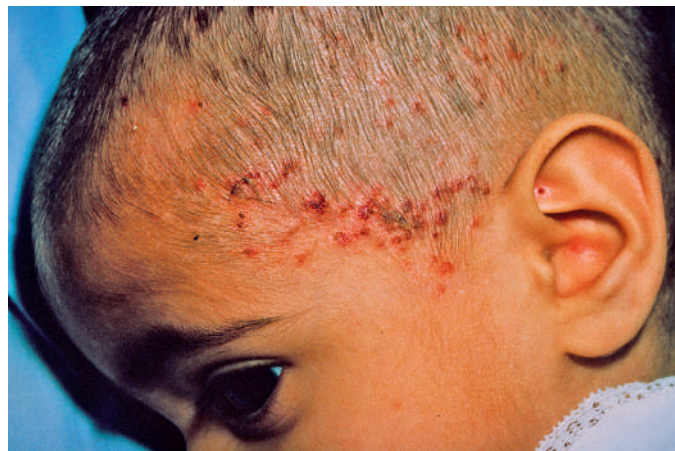with a greater rate in children under 1 year of age (7 per 1 million), 2 cases per 1 million in ages 1–4, and about 1 case per 1 million in ages 5–14. Children conceived through in vitro fertilization (IVF) before 2002 appear to have increased risk for development of LCH. Neonatal disease occurs in 6% of cases but at times is unrecognized, especially if involving an internal organ asymptotically but not affecting its function. Thus, many of the neonatal cases have predominantly cutaneous lesions. Overall, in childhood LCH, bone lesions represent about two thirds of cases and skin disease about one third. Only 10% of cases have neither skin nor bone involvement. In children under 1 year of age, the skin is involved in three quarters of cases, with ear and bone being involved in about one third. Two thirds of children under 1 year have multisystem disease, with half having involvement of liver, lungs, or bone marrow. In children age 1–4, bone disease is most common, but two-thirds or more have multisystem disease. In children age 5–14, bone disease is almost always seen, and multisystem disease is seen in less than 20%.

### Skin lesions

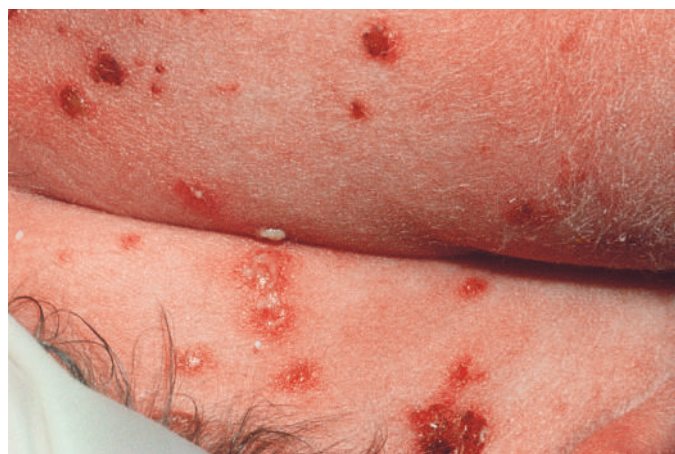About 10% of children have single-organ disease involving only the skin, and 50% of children with multisystem LCH have skin involvement, making skin the second most commonly involved organ in childhood LCH. Almost 90% of children less than 1 year old with multisystem LCH have skin lesions. The pattern of skin disease does not predict the presence or extent of systemic disease. The most common form of skin disease in children is that described in Abt-Letterer-Siwe disease. The skin lesions are tiny red, red-brown, or yellow papules that are widespread but favor the intertriginous areas, behind the ears, and the scalp (Figs. 31-22 and 31-23). There is a superficial resemblance to seborrheic dermatitis, but on careful inspection, the lesions are individual papules with focal hemorrhage. The papules are often folliculocentric. Lesions may erode or weep. In children, this pattern is frequently associated with multisystem disease. In a rare variant of this LCH pattern, vesicles appear (Fig. 31-24), usually in infants. The vesicles rupture easily, resulting in widespread erosions. This presentation may be confused with other bullous diseases, especially congenital candidiasis, herpesvirus infections, bullous impetigo, bullous mastocytosis, primary immunobullous diseases, and epidermolysis bullosa. The vesicles result from large intraepidermal collections of Langerhans cells, and a Tzanck smear may lead one to suspect the diagnosis. A less common presentation is with slightly larger papules, up to 1 cm in diameter. These lesions tend to be yellow-red and resemble xanthomas or xanthogranulomas (Fig. 31-25). They can be

numerous and widespread. A rare variant resembling lichen planopilaris has been reported. Congenital lesions with hemorrhage have been reported as resembling “blueberry muffin” babies, but the biopsies show typical LCH.

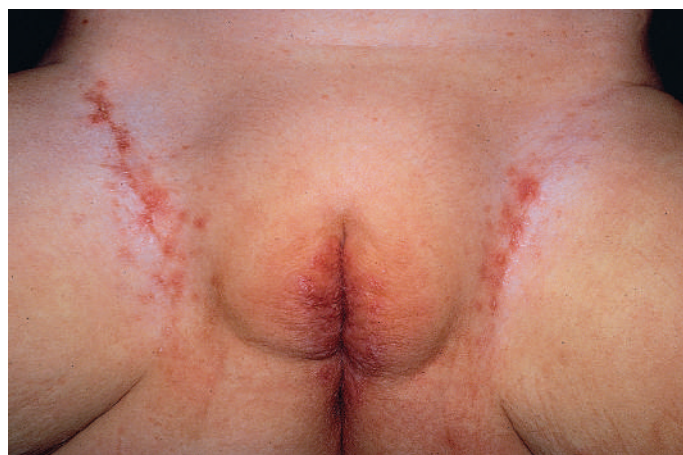Although uncommon, nail changes can occur, including nail dystrophy, nail bed purpura, loss of the nail plate, and paronychia. Both fingernails and toenails may be affected. Most patients with nail involvement have multisystem disease. LCH restricted to the genitalia is rare, but vulvar, inguinal, and perianal disease may be the initial manifestation of LCH. It tends to be painful and ulcerative and may simulate hidradenitis suppurativa or cutaneous Crohn’s disease, because axillary and scalp involvement may also be present.



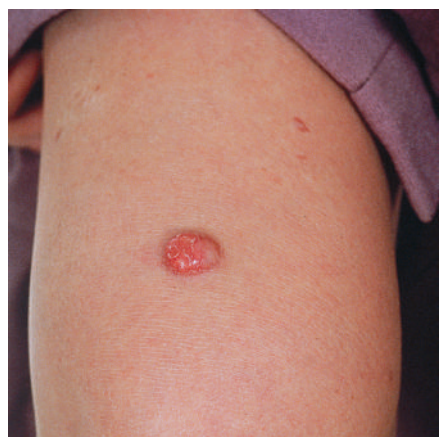**Fig. 31-23** Langerhans cell histiocytosis, seborrheic dermatitis-like eruption with hemorrhage.



**Fig. 31-24** Langerhans cell histiocytosis, bullous lesions.

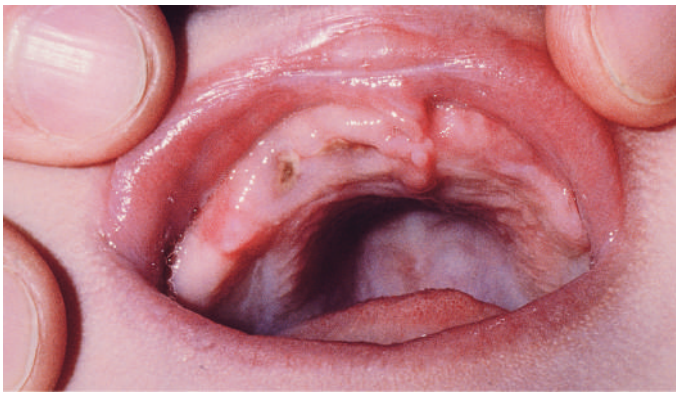


**Fig. 31-22** Langerhans cell histiocytosis, pink and purpuric eruption of the inguinal and genital areas.

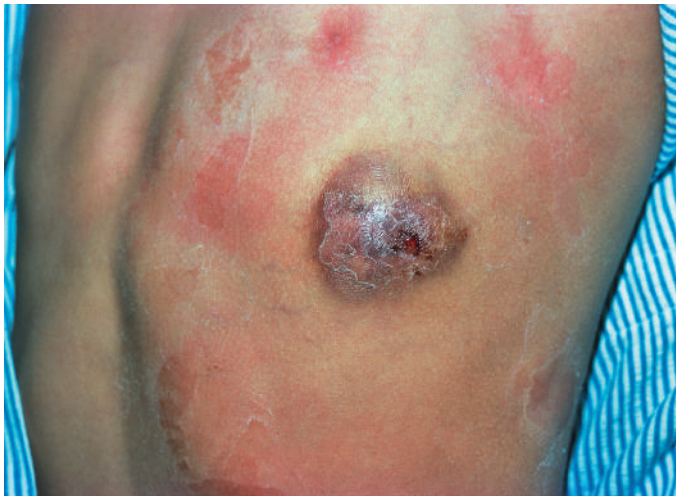

**Fig. 31-25** Langerhans cell histiocytosis, xanthomatous nodule in patient with diabetes insipidus.





**Fig. 31-26** Langerhans cell histiocytosis, gingival lesions.



**Fig. 31-27** Langerhans cell histiocytosis, eosinophilic granuloma of rib that eroded through to the skin.

### Oral mucosa lesions

The oral mucosa may be involved in children with LCH. Lesions may be mucosal ulcerations that are painful and inflamed. They affect primarily the buccal mucosa. Most oral disease is caused by alveolar bone lesions. These osteolytic lesions can lead to significant periodontitis. Gingival ulceration can result (Fig. 31-26). Teeth detach from the underlying bone and on x-ray films appear to be “floating.” Palpable masses and gingival lesions should be sought and a dental evaluation completed in all patients. Cervical adenopathy is common. Bilateral parotid swelling may occur.

### Visceral involvement

The most commonly involved organ in LCH children is the bone (Fig. 31-27). The lesions may be asymptomatic or may cause pain. The skull is most often involved, followed by the long bones, then the flat bones. Bony lesions tend to occur in older children and young adults. Lesions are treated with curettage, intralesional corticosteroids, or radiation. Endocrine dysfunction occurs, usually in the form of diabetes insipidus, which is more common in patients with bone disease of the skull and in those with extensive disease. Diabetes insipidus is one of the common long-term sequelae of children recovering from LCH.

The bone marrow may be affected, resulting in cytopenias. This may present as purpura in the skin. The liver may be involved directly by infiltration with Langerhans cells or may be affected indirectly by enlarged nodes in the porta hepatis, leading to obstructive disease. Either pattern can lead to biliary

cirrhosis. Pulmonary disease with diffuse micronodular infiltrates and cysts occurs less frequently in children than in adults with LCH.

### Adult Langerhans cell histiocytosis

In adults, the peak age of presentation is between 20 and 35 years, with multisystem disease in one third to two thirds of adults with LCH. Bones are the most common organ involved, and 12% of adult LCH patients have disease limited to one or several bones. Skin and mucosal involvement is the second most common manifestation in adults. Diabetes insipidus occurs in 20% of patients, and other endocrine abnormalities can result from hypothalamic-pituitary involvement. These remain a problem after the LCH is treated and require constant monitoring. In the skin, lesions can be papular or diffuse, sometimes with both forms of lesion present at different sites. Acneiform lesions of the chest and back, identical clinically to acne vulgaris, can occur. Xanthomatous lesions may be seen. A pattern repeatedly reported in the skin of adults with LCH is a red, erosive, intertriginous eruption, with a close resemblance to deficiency dermatitis. It favors the groin and inframammary areas, especially in elderly women. Pulmonary LCH occurs on average at age 33 years. A diffuse micronodular pattern on chest radiograph may progress to cyst formation (honeycomb lung), large bullae, and pneumothorax. More than 90% of adults with pulmonary LCH are tobacco or marijuana smokers. Pneumothorax occurs in 25% of cases. High-resolution CT is useful for diagnosis. Five-year survival is 88%. Lung transplantation may be required. It is unclear if isolated pulmonary LCH is a reactive process or a variant of LCH.

### Treatment and prognosis

In childhood LCH, outcome is determined by the extent of involvement and, more importantly, the function of affected organs. Children younger than 1 year with multisystem disease have the worst prognosis, with mortality approaching 50%, children age 1–4 years have a 30% or lower mortality, and mortality is only 6% in children 5 years or older. Involvement of the ear and lung is a poor prognostic finding in patients with multisystem disease. Early initial response to multidrug chemotherapy in childhood multisystem LCH is an important predictor of survival, with survival of 92% of responders and 11% of nonresponders after 6 weeks of treatment. Baseline and repeated evaluation is important. Lesions in one organ system may resolve while disease progresses in another organ. Skin lesions may spontaneously resolve, only for the disease to recur, even years later, so patients must be followed regularly.

For treatment and prognosis, patients are classified as having single-system LCH or multisystem LCH. Those with multisystem LCH are further stratified into those with involvement of high-risk “organs” (bone marrow, liver, spleen, and CNS) and those without involvement of these organ systems. Patients with multisystem disease should be referred to a center for evaluation and treatment recommendations and potentially, new investigational treatment protocols. Most often, vinblastine and a corticosteroid are used as initial treatment, but reactivation remains a problem. Patients with localized skin disease can be managed by the dermatologist. Topical nitrogen mustard, PUVA, NB-UVB (or excimer laser), thalidomide (100 mg/day), methotrexate (20 mg/wk), and azathioprine can be considered, depending on the extent of skin disease. Also, 5% imiquimod may be effective for limited skin lesions. Oral retinoids (acetrein and isotretinoin) can be used adjunctively with other treatments.

Associated lymphomas, solid tumors, and myelodysplasias have occurred in patients with LCH, with acute lymphoblastic leukemia and myelodysplastic syndrome preceding the

appearance of LCH, and acute myelogenous leukemia and acute lymphoblastic leukemia following it. In some cases of cutaneous and systemic lymphomas, aggregates of Langerhans cells are seen in the tissue affected by the lymphoma. Whether this represents the coexistence of LCH and lymphoma, or a reactive proliferation of Langerhans cells within the tissue affected by the lymphoma, is unknown.

### Differential diagnosis

The diffuse, small papular form of LCH is frequently misdiagnosed as seborrheic dermatitis. The yellow color of the lesions and the presence of hemorrhage in the small papules, if present, should suggest the diagnosis of LCH. Nodular lesions of scabies can closely simulate LCH. This includes the finding of Langerhans or indeterminate cells in the dermal infiltrate on electron microscopy and S-100 and CD1a staining. The larger papules resemble JXG and xanthomas. Erosive genital disease may simulate deficiency dermatitis and cutaneous Crohn's disease.

- Åkefeldt SO, et al:** Langerhans cell histiocytosis in children born 1982–2005 after in vitro fertilization. *Acta Paediatrica* 2012; 101:1151.
- Bechan GI, et al:** Telomere length shortening in Langerhans cell histiocytosis. *Br J Haematol* 2008; 140:420.
- Black A, et al:** Seventy-nine-year-old man with Langerhans cell histiocytosis treated with cladribine. *J Am Acad Dermatol* 2010; 65:681.
- Brown NA, et al:** High prevalence of somatic MAP2K1 mutations in BRAF V600E negative Langerhans cell histiocytosis. *Blood* 2014; 124:1655.
- Campanati A, et al:** Purely cutaneous Langerhans' cell histiocytosis in an adult woman. *Acta Derm Venereol* 2009; 89:299.
- Chander R, et al:** Pulmonary disease with striking nail involvement in a child. *Pediatr Dermatol* 2008; 25:633.
- Christie LJ, et al:** Lesions resembling Langerhans cell histiocytosis in association with other lymphoproliferative disorders: a reactive or neoplastic phenomenon? *Hum Pathol* 2006; 37:32.
- Delprat C, Aricó M:** Blood spotlight on Langerhans cell histiocytosis. *Blood* 2014; 124:867.
- Edelbroek JR, et al:** Langerhans cell histiocytosis first presenting in the skin of adults: frequent association with a second haematological malignancy. *Br J Dermatol* 2012; 167:1287.
- Fahrner B, et al:** Long-term outcome of hypothalamic pituitary tumors in Langerhans cell histiocytosis. *Pediatr Blood Cancer* 2012; 58:606.
- Fernandes LB, et al:** Langerhans cells histiocytosis with vulvar involvement and responding to thalidomide therapy: case report. *An Bras Dermatol* 2011; 86:S78.
- Fieta-Asin B, et al:** Progressive cutaneous lesions in an elderly woman with systemic failure. *Int J Dermatol* 2012; 51:1175.
- Girschikofsky M, et al:** Management of adult patients with Langerhans cell histiocytosis: recommendations from an expert panel on behalf of Euro-Histio-Net. *Orphanet J Rare Dis* 2013; 8:72.
- Golpanian S, et al:** Pediatric histiocytosis in the United States: incidence and outcomes. *J Surg Res* 2014; 190:221.
- Hancox JG, et al:** Adult onset folliculocentric Langerhans cell histiocytosis confined to the scalp. *Am J Dermatopathol* 2004; 26:123.
- Haroche J, et al:** Dramatic efficacy of vemurafenib in both multisystemic and refractory Erdheim-Chester disease and Langerhans cell histiocytosis harboring the BRAF V600E mutation. *Blood* 2013; 121:1495.
- Haupt R, et al:** Langerhans cell histiocytosis (LCH): guidelines for diagnosis, clinical work-up and treatment for patients till the age of 18 years. *Pediatr Blood Cancer* 2013; 60:175.
- Hoang MT, et al:** Recurrent perianal red plaque with superficial erosions and pustular exudate in a 16-month-old boy. *Clin Exp Dermatol* 2012; 38:203.
- Huang JT, et al:** Langerhans cell histiocytosis mimicking molluscum contagiosum. *J Am Acad Dermatol* 2011; 67:e117.
- Ibler K, et al:** Recurrent boils of the axilla and groin: a quiz. *Acta Derm Venereol* 2012; 92:109.
- Kartono F, et al:** Crusted Norwegian scabies in an adult with Langerhans cell histiocytosis: mishaps leading to systemic chemotherapy. *Arch Dermatol* 2007; 143:626.
- Kim BE, et al:** Clinical features and treatment outcomes of Langerhans cell histiocytosis: a nationwide survey from Korea histiocytosis working party. *J Pediatr Hematol Oncol* 2014; 36:125.

- Kurt S, et al:** Diagnosis of primary Langerhans cell histiocytosis of the vulva in a postmenopausal woman. *Case Rep Obstet Gynecol* 2013; 2013:962670.
- Lindahl LM, et al:** Topical nitrogen mustard therapy in patients with Langerhans cell histiocytosis. *Br J Dermatol* 2012; 166:642.
- Lourda M, et al:** Detection of IL-17A-producing peripheral blood monocytes in Langerhans cell histiocytosis patients. *Clin Immunol* 2014; 153:112.
- Maia RC, et al:** Langerhans cell histiocytosis: differences and similarities in long-term outcome of paediatric and adult patients at a single institutional centre. *Hematology* 2014; May 29. [Epub ahead of print.]
- Mataix J, et al:** Nail changes in Langerhans cell histiocytosis: a possible marker of multisystem disease. *Pediatr Dermatol* 2008; 25:247.
- Mir A, et al:** Perifollicular Langerhans cell histiocytosis. *Dermatol Online J* 2012; 18:6.
- Morimoto A, et al:** Recent advances in Langerhans cell histiocytosis. *Pediatr Int* 2014; 56:451.
- Murakami I, et al:** IL-17A receptor expression differs between subclasses of Langerhans cell histiocytosis, which might settle the IL-17A controversy. *Virchows Arch* 2013; 462:219.
- O'Kane D, et al:** Langerhans cell histiocytosis associated with breast carcinoma successfully treated with topical imiquimod. *Clin Exp Dermatol* 2009; 34:e829.
- Oliveira A, et al:** Langerhans cell histiocytosis: two clinical presentations in the same patient. *Dermatol Online J* 2012; 18:8.
- Pedrosa AF, et al:** Primary Langerhans cell histiocytosis of the vulva: acitretin as a glucocorticoid-sparing agent. *Int J Dermatol* 2014; 53:e240.
- Podjasek JO, et al:** Adult-onset systemic Langerhans cell histiocytosis mimicking inflammatory bowel disease: the value of skin biopsy and review of cases of Langerhans cell histiocytosis with cutaneous involvement seen at the Mayo Clinic. *Int J Dermatol* 2014; 53:305.
- Querings K, et al:** Clinical spectrum of cutaneous Langerhans' cell histiocytosis mimicking various diseases. *Acta Derm Venereol* 2006; 86:39.
- Ruiz-Villaverde R, et al:** Erythroderma as an initial presentation of Langerhans cell histiocytosis involving the sinus. *Actas Dermosifiliogr* 2014; 105:630.
- Sahm F, et al:** BRAFV600E mutant protein is expressed in cells of variable maturation in Langerhans cell histiocytosis. *Blood* 2012; 120:e28.
- Satter EK, et al:** Diffuse xanthogranulomatous dermatitis and systemic Langerhans cell histiocytosis: a novel case that demonstrates bridging between non-Langerhans cell histiocytosis and Langerhans cell histiocytosis. *J Am Acad Dermatol* 2009; 60:841.
- Shaffer MP, et al:** Langerhans cell histiocytosis presenting as blueberry muffin baby. *J Am Acad Dermatol* 2005; 53:S143.
- Shannon K, Hermiston M:** A(nother) RAF mutation in LCH. *Blood* 2014; 123:3063.
- Szturz P, et al:** Lenalidomide proved effective in multisystem Langerhans cell histiocytosis. *Acta Oncol* 2012; 51:412.
- Vogel CA, et al:** Excimer laser as adjuvant therapy for adult cutaneous Langerhans cell histiocytosis. *Arch Dermatol* 2008; 144:1287.
- Von Steub E, et al:** Successful treatment of adult multisystemic Langerhans cell histiocytosis with psoralen-UV-A, prednisone, mercaptopurine, and vinblastine. *Arch Dermatol* 2008; 144:649.
- Wang P, et al:** Extensive cutaneous Langerhans cell histiocytosis in an elderly woman. *J Dermatol* 2011; 38:794.
- Yazc N, et al:** Langerhans cell histiocytosis with involvement of nails and lungs in an adolescent. *J Pediatr Hematol Oncol* 2008; 30:77.
- Yoje SL, et al:** Langerhans cell histiocytosis in acute leukemias of ambiguous or myeloid lineage in adult patients: support for a possible clonal relationship. *Mod Pathol* 2014; 27:651.



Bonus images for this chapter can be found online at

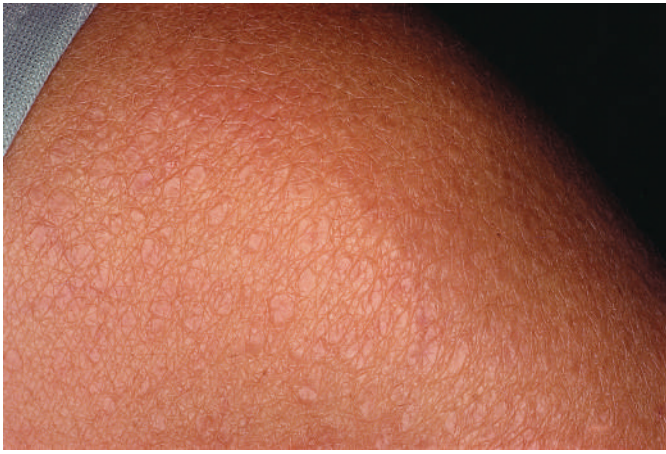[expertconsult.inkling.com](http://expertconsult.inkling.com)

**eFig. 31-1** Granuloma annulare, generalized small papules and annular plaques.

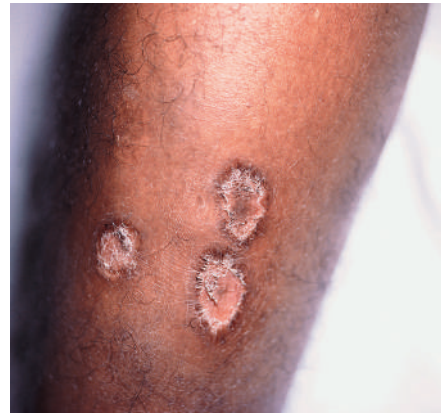**eFig. 31-2** Sarcoidosis, hypopigmented papules.

**eFig. 31-3** Sarcoidosis, hypopigmented and annular plaques.

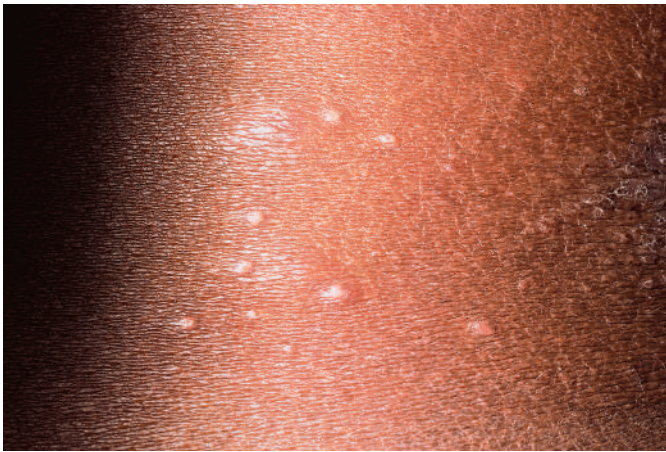




**eFig. 31-1** Granuloma annulare, generalized small papules and annular plaques.



**eFig. 31-3** Sarcoidosis, hypopigmented and annular plaques.



**eFig. 31-2** Sarcoidosis, hypopigmented papules.

# 32

## Cutaneous Lymphoid Hyperplasia, Cutaneous T-Cell Lymphoma, Other Malignant Lymphomas, and Allied Diseases

### CUTANEOUS LYMPHOID HYPERPLASIA (LYMPHOCYTOMA CUTIS, LYMPHADENOSIS BENIGNA CUTIS, PSEUDOLYMPHOMA)

The term cutaneous lymphoid hyperplasia refers to a group of benign disorders characterized by collections of lymphocytes, macrophages, and dendritic cells (DCs) in the skin. These processes can be caused by known stimuli (e.g., medications, injected foreign substances, infections, arthropod bites) or may be idiopathic. The disorders may have a purely benign histologic appearance or may resemble cutaneous lymphoma. If there is a histologic resemblance to lymphoma, the term pseudolymphoma is sometimes used. By standard techniques, most cases of cutaneous lymphoid hyperplasia will be found to lack clonality. Cases of monoclonal B-cell and T-cell cutaneous lymphoid hyperplasia do occur. Thus, a finding of monoclonality does not equate to the diagnosis of malignancy or lymphoma, and it does not predict biologic behavior.

Two clinical patterns of cutaneous lymphoid hyperplasia exist. The nodular form consists of nodular and diffuse dermal aggregates of lymphocytes, macrophages, and DCs. The clinicohistologic differential diagnosis is cutaneous B-cell lymphoma. The diffuse type is usually associated with drug exposure or photosensitivity (actinic reticuloid). Histologically, it must be distinguished from cutaneous T-cell lymphoma.

#### Cutaneous lymphoid hyperplasias—nodular B-cell pattern

The nodular pattern of cutaneous lymphoid hyperplasia is the most common pattern. It usually presents in adults and is two to three times more common in women. It favors the face (cheek, nose, or earlobe), and the majority of cases present as a solitary or localized cluster of asymptomatic, erythematous to violaceous papules or nodules. Less frequently, lesions may affect the trunk (36%) (Fig. 32-1) or extremities (25%). At times, the lesions may coalesce into a plaque or may be widespread in one region, where they present as miliary papules. Systemic symptoms are absent and, except for rare cases with regional lymphadenopathy, there are no other physical or laboratory abnormalities. It is usually idiopathic but can be caused by tattoos, *Borrelia* infections, herpes zoster scars, antigen injections, acupuncture, drug reactions, and persistent insect bite reactions.

*Borrelia*-induced cutaneous lymphoid hyperplasia is an uncommon manifestation of this infection, occurring in 0.6–1.3% of cases reported from Europe. The lack of borrelial pseudolymphoma in the United States compared with Europe may relate to the presence of different borrelial species in Europe, specifically *Borrelia afzelii*, that cause borreliosis. Lesions occur at the site of the tick bite or close to the edge of a lesion of erythema migrans. They may appear up to 10 months after

infection. Lesions may be multiple and favor the earlobes, nipple/areola, nose, and scrotal area and vary from 1 to 5 cm in diameter. Usually, there are no symptoms, but associated regional lymphadenopathy may be present. Late manifestations of *Borrelia* infection are uncommon. The diagnosis is suspected from a history of a tick bite or erythema migrans, the location (earlobe or nipple), and the histologic picture. The diagnosis is confirmed by an elevated anti-*Borrelia* antibody (present in 50% of cases) and the finding of borrelial DNA in the affected tissue. The treatment is penicillin. Some cases progress to true lymphoma.

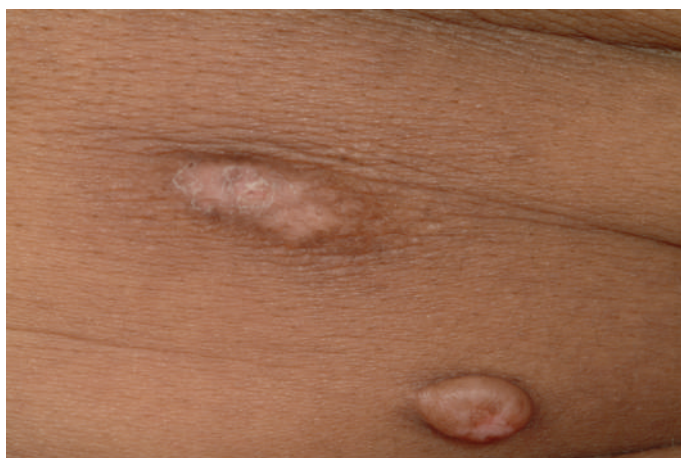
Histologic examination of nodular cutaneous lymphoid hyperplasia reveals a dense, nodular infiltrate that occupies primarily the dermis and lessens in the deeper dermis and subcutaneous fat (i.e., it is “top-heavy”). The process is usually separated from the epidermis by a clear grenz zone. The infiltrate is composed chiefly of mature small and large lymphocytes, histiocytes, plasma cells, DCs, and eosinophils. In the deeper portions, well-defined germinal centers are usually seen, with central large lymphoid cells with abundant cytoplasm and tingible body macrophages, and a peripheral cuff of small lymphocytes. A plasma cell–predominant variant has been described. Reactive hyperplasia of adnexal epithelium is common and characteristic, but it may also occasionally be seen in true lymphomas. Germinal centers are symmetric and surrounded by a mix of B and T cells. BCL-6 and CD10 expression is limited to the germinal centers, which also have an intact CD21+ network of DCs. Typically, more than 90% of the cells in the germinal center express the proliferative marker Ki-67 (MIB-1). There is no evidence of light-chain restriction by in situ hybridization. CD30+ cells may occasionally be prominent, raising concern about the development of a CD30+ lymphoproliferative disorder.

Because most lesions are asymptomatic, treatment is often not required. If the process has been induced by a medication, use of the medication should be discontinued. Infection should be treated and localized foci of infection removed. Intralesional steroidal agents are sometimes beneficial, but lesions may recur in a few months. Potent topical corticosteroids may also be tried for superficial lesions. Intralesional corticosteroids, cryosurgery, thalidomide (100 mg/day for a few months), interferon (IFN) alfa, IFN alfa-2b, laser ablation, and surgical excision can all produce good results. Low-dose radiation therapy is usually very effective and may be used on refractory facial lesions that cannot be satisfactorily removed surgically.

#### Cutaneous lymphoid hyperplasias—bandlike T-cell pattern

Cutaneous lymphoid hyperplasias may histologically show a bandlike and perivascular dermal infiltrate, at times with epidermotropism. The lesions may be idiopathic or may be caused





**Fig. 32-1** Cutaneous lymphoid hyperplasia.

by photosensitivity (formerly called actinic reticuloid; now called chronic actinic dermatitis), medications (usually anti-convulsants, but also many others), or contact dermatitis (so-called lymphomatoid contact dermatitis). Clinically, these patients have lesions that clinically resemble mycosis fungoides: widespread erythema with scaling. Thicker plaques may occur as well, and these cases are frequently caused by medications. The treatment is to stop any implicated medication. If stopping the medication is ineffective, topical and intralesional corticosteroids, psoralen plus ultraviolet A (PUVA) therapy, and, for persistent localized lesions, radiotherapy may be considered. Histologically, a T-cell-rich band of lymphocytes is present. Epidermotropism, atypia, and even clonality may suggest mycosis fungoides, but the lesions resolve when the drug or other inciting agent is withdrawn.

### Jessner lymphocytic infiltrate of the skin

The existence of this entity has recently been challenged, and the condition may best be classified as a variant of lupus erythematosus (LE). Clinically, Jessner infiltrate is a persistent papular and plaquelike eruption that is photosensitive and occurs primarily on the face. Histologically, there is a superficial and deep perivascular and periadnexal lymphocytic infiltrate. Interface dermatitis is absent. The infiltrating lymphocytes are suppressor T cells (CD8+). Features that suggest this may be distinct from other forms of cutaneous LE include the absence of an interface dermatitis, lack of mucin, and negative direct immunofluorescence (DIF). Tumid LE also lacks interface dermatitis but has ample mucin. Polymorphous light eruption (PMLE) is distinguished from Jessner infiltrate by having edematous papules and plaques that are more transient and by the presence of dermal edema. In PMLE, the infiltrating cells are also CD8+. True cases of lymphocytic infiltration of the skin may still exist. To distinguish them clearly from LE and PMLE, the lesions must contain predominantly CD8+ suppressor T cells, must lack dermal mucin and dermal edema, and must be fixed (not transient as with PMLE); patients must have negative DIF and serologic testing for LE. Both Jessner lymphocytic infiltrate and chronic cutaneous LE can respond to antimalarials.

**Böer A, et al:** Pseudoclonality in cutaneous pseudolymphomas: a pitfall in interpretation of rearrangement studies. *Br J Dermatol* 2008; 159(2):394–402.

**Safa G, et al:** Erythrodermic CD8+ pseudolymphoma during infliximab treatment in a patient with psoriasis: use of cyclosporine as a rescue therapy. *J Am Acad Dermatol* 2014; 71(4):e149–150.

**Sueki H, et al:** Drug-induced hypersensitivity syndrome/drug reaction with eosinophilia and systemic symptoms with histologic features mimicking cutaneous pseudolymphoma. *J Dermatol* 2014; 41(9):856–857.

**Tomar S, et al:** Treatment of cutaneous pseudolymphoma with interferon alfa-2b. *J Am Acad Dermatol* 2009; 60(1):172–174.

## CUTANEOUS LYMPHOMAS

Because cutaneous Hodgkin disease is very rare, the term non-Hodgkin lymphoma has little meaning when speaking of a lymphoma in the skin, because virtually all cutaneous lymphomas are “non-Hodgkin lymphomas.” Cutaneous lymphoma can be considered to be either primary or secondary. Primary cutaneous lymphomas are those that occur in the skin, and where no evidence of extracutaneous involvement is found for some period after the appearance of the cutaneous disease. Secondary cutaneous lymphoma includes cases that have simultaneous or preceding evidence of extracutaneous involvement. These cases are best classified and managed as lymph node–based lymphomas with skin involvement. This conceptual separation is not ideal, but it has been important in developing classification schemes and determining prognosis in cutaneous lymphomas.

For many years, classification of lymphomas has been based on their histologic appearance, and lesions from all organ systems were classified histomorphologically in an identical manner to lymphomas arising in lymph nodes. It had been recognized that these classification schemes have major shortcomings when applied to extranodal lymphomas. Specifically, they did not uniformly predict clinical behavior. The new World Health Organization (WHO) classification scheme recognizes distinct forms of primary cutaneous lymphoma.

Cutaneous lymphomas are classified based on their cell type. There are B-cell lymphomas and T-cell lymphomas, but B-cell lymphomas can be T cell rich. In the latter cases, atypia is restricted to the B-cell population, and immunoglobulin gene rearrangements are detected. Histologic features used in the classification system include cell size (large vs. small), nuclear morphology (cleaved or noncleaved), and immunophenotype. Because appropriate classification may be prognostically important, experienced dermatopathology consultation should be sought in cases of cutaneous lymphoma.

### Primary cutaneous T-cell lymphomas

A major insight into cutaneous lymphoma was the finding that the majority of lymphomas in the skin were of T-cell origin. This is logical, since T cells normally traffic through the skin and are important in “skin-associated lymphoid tissue.” Unfortunately, dermatologists frequently use the term cutaneous T-cell lymphoma (CTCL) synonymously with mycosis fungoides (MF). Although MF represents the large majority of primary CTCLs, up to 30% of primary CTCLs are not MF. The following discussion is divided into MF and related conditions, Sézary syndrome, lymphomatoid papulosis, and non-MF primary CTCLs.

### Mycosis fungoides

Mycosis fungoides is a malignant neoplasm of T-lymphocyte origin, almost always a memory T-helper (Th) cell. The incidence has been cited as 1 in 300,000 per year, but has been increasing. MF affects all races. In the United States, black persons are relatively more often affected than white persons. MF is twice as common in men as in women.

## Natural history

In most cases, MF is a chronic, slowly progressive disorder. It usually begins as flat patches (patch stage), which may or may not be histologically diagnostic of MF. This inability to diagnose early cases has more to do with the limits of diagnostic capabilities than a transformation from some nonneoplastic (premycotic) condition to MF, and these cases are best considered MF from the onset. Pruritus, sometimes severe, is usually present at this stage. Over time, sometimes years, the lesions become more infiltrated, and the diagnosis is usually confirmed with repeated histologic evaluation. Infiltrated plaques occur eventually (plaque stage). In some cases, tumors may eventually appear (tumor stage). Some MF patients may present with or progress to erythroderma. Most rarely, patients may present with tumors *de novo*, the so-called *d'émblée* form. With immunophenotyping, many MF cases are now recognized as non-MF T-cell lymphomas. Eventually, in some patients, noncutaneous involvement is detected. This is usually first identified in lymph nodes. Peripheral blood involvement and visceral organ involvement may also occur.

In general, MF affects elderly patients and has a long evolution. However, once tumors develop or lymph node involvement occurs, the prognosis is guarded, and MF can be fatal. In most fatal cases, the patient dies of septicemia. Early, aggressive chemotherapy in an attempt to “cure” MF is associated with excessive morbidity and mortality and is not indicated.

## Evaluation and staging

The North American Mycosis Fungoides Cooperative Group has developed a staging system. Because MF is a systemic disease from the onset (because lymphocytes naturally traffic throughout the body), concepts used for solid tumors, such as tumor burden and metastasis, cannot be readily applied. The TNMB system scores involvement in the skin (T), lymph node (N), viscera (M), and peripheral blood (B) and is in evolution. Skin involvement is divided into less than 10% (T1), more than 10% (T2), tumors (T3), and erythroderma (T4). Node involvement is normal clinically and pathologically (N0), palpable but pathologically not MF (N1), not palpable but pathologically MF (N2), or clinically and pathologically involved (N3). Viscera and blood are either not involved (M0 and B0) or involved (M1 and B1).

- Stage IA is T1,N0,M0.
- Stage IB is T2,N0,M0.
- Stage IIA is T1-2,N1,M0.
- Stage IIB is T3,N0-1,M0.
- Stage IIIA is T4,N0,M0.
- Stage IIIB is T4,N1,M0.
- Stage IVA is T1-4, N2-3,M0.
- Stage IVB is T1-4,N0-3,M1.

The “B” or blood status does not alter staging of the disease.

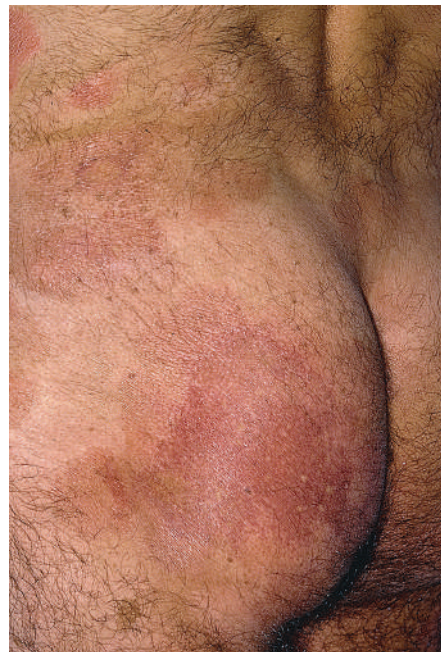A staging workup would include a complete history and physical examination, with careful palpation of lymph nodes and mapping of skin lesions; a complete blood cell count (CBC) with assays for circulating atypical cells (Sézary cells); serum chemistries, including renal and liver function tests with lactate dehydrogenase; a chest radiograph evaluation; and a skin biopsy. If palpable, lymph nodes should be examined histologically. Fine-needle aspiration is not an ideal mode of evaluation, since early lymph node involvement may be localized to certain areas of the affected nodes and often requires architectural evaluation for detection. If any abnormalities are detected through these evaluations, they should be pursued. Computed tomography (CT) can be performed to assess chest, abdominal, and pelvic lymph nodes and visceral

organs. These tests are useful in patients with stage II-IV disease, but are not indicated in patients with stage IA disease. Whether patients with stage IB disease should undergo these tests is unknown.

The value of this staging system is confirmed in large series. Stage IA patients have a life expectancy identical to that of a control population; only 8-9% progress to more advanced disease, and only 2% die of their disease. By contrast, patients with T2 disease have shorter survival than controls (median survival of 11.7-15.6 years); 24% of T2 patients progress to more advanced disease. T3 patients have a median survival of 3.2-8.4 years, and T4 patients, 1.8-3.7 years. Palpable adenopathy is associated with a median survival of only 7.7 years, whereas patients without adenopathy have survival of 21.8 years. Lymphadenopathy, tumors, and cutaneous ulceration are cardinal prognostic factors; no patient dies without having developed one of these, and patients with all three (in any order) survive a median of 1 year.

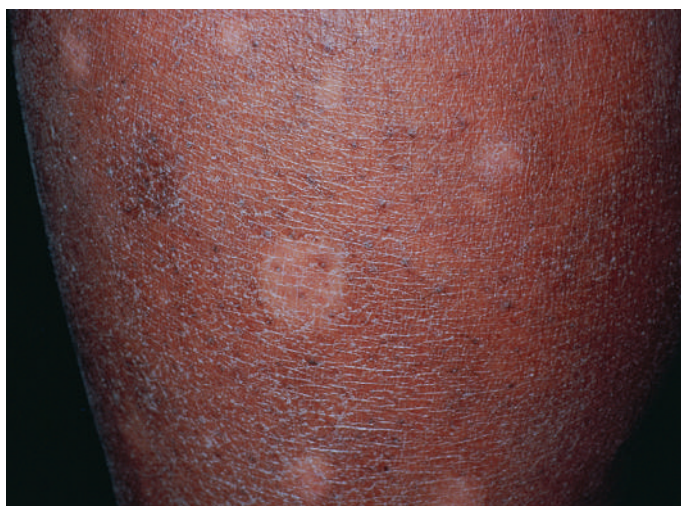## Clinical features

In the early patch/plaque stage, the lesions are macular or slightly infiltrated patches or plaques varying in size from 1 to 5 cm or more. Folliculotropic disease can resemble lichen nitidus. Except for the folliculotropic variant, lesions greater than 5 cm are virtually always present in true cases of MF. In contrast, most histologic simulators present with smaller skin lesions. The eruption may be generalized or may begin localized to one area and then spread. The lower abdomen, buttocks, upper thighs, and breasts of women are preferentially affected. The lesions may have an atrophic surface or may present as true poikiloderma with atrophy, mottled dyspigmentation, and telangiectasia. Poikiloderma vasculare atrophicum most often represents a clinical form of patch-stage MF. Likewise, large-plaque parapsoriasis and cases of small-plaque parapsoriasis with poikilodermatous change are early patch-stage lesions of MF. In contrast, typical digitate dermatosis probably never evolves into MF. “Invisible” MF is generalized skin involvement that is not visible to the naked eye but can be documented histologically. With current diagnostic methods, this can usually be confirmed. In general, the patch-stage lesions (Fig. 32-2) resemble an eczema, being round or ovoid, although annular, polycyclic, or arciform configurations can occur. Less common forms are the verrucous or

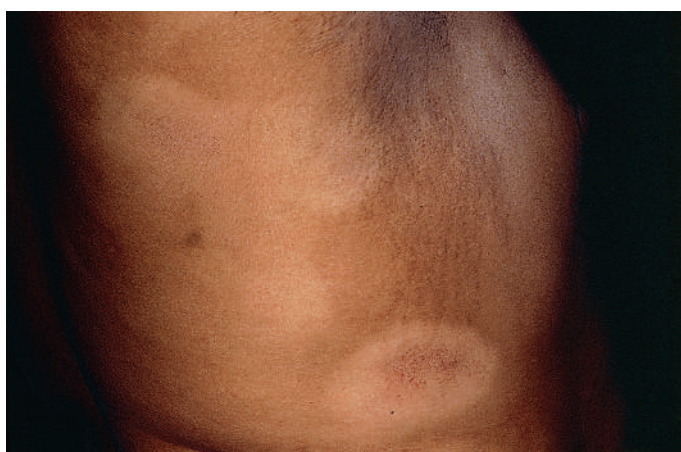

**Fig. 32-2** Mycosis fungoides, patch stage.





**Fig. 32-3** Mycosis fungoides, hypopigmented patches.

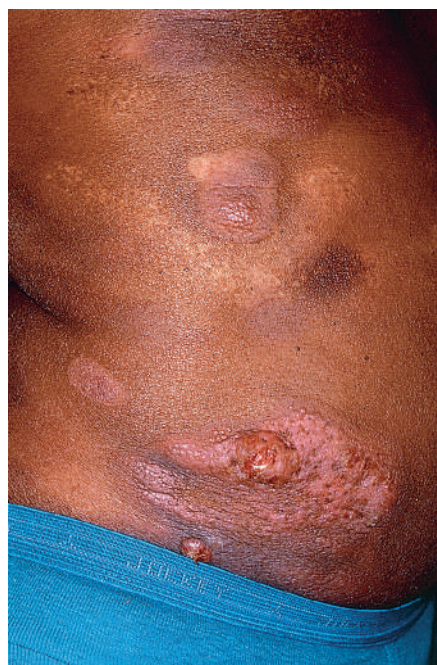

**Fig. 32-4** Mycosis fungoides, plaque stage. (Courtesy of Dr. Ellen Kim.)

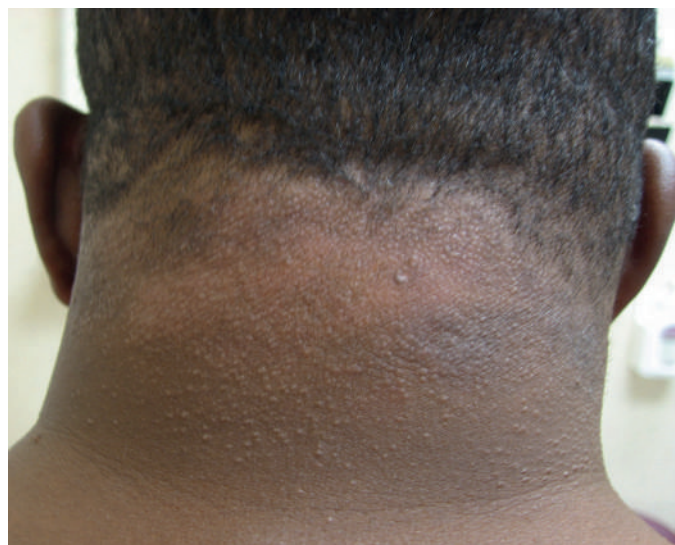hyperkeratotic form, the hypopigmented form (Fig. 32-3), lesions resembling a pigmented purpura, and the vesicular, bullous, or pustular form. The hypopigmented form seems to be more common in persons of color and is a typical presentation for adolescents and children with MF. Subtle lesions of MF may manifest clinically during anti-tumor necrosis factor (TNF) therapy.

In the plaque stage, lesions are more infiltrated and may resemble psoriasis (Fig. 32-4), a subacute dermatitis, or a granulomatous dermal process such as granuloma annulare. The palms and soles may be involved, with hyperkeratotic, psoriasisiform, and fissuring plaques. The infiltration of the plaques, at first recognized by light palpation, may be present in only a few of the lesions. It is a manifestation of diagnostic importance. Different degrees of infiltration may exist, even in the same patch, and sometimes it is more pronounced peripherally, the central part of the plaque being depressed to the level of the surrounding skin. The infiltration becomes more marked and leads to discoid patches or extensive plaques, which may be as wide as 30 cm.

Eventually, through coalescence of the various plaques, the involvement becomes widespread, but there are usually patches of apparently normal skin interspersed. When the involvement is advanced, painful superficial ulcerations may occur. During this phase, enlarged lymph nodes usually develop. They are nontender, firm, and freely movable.



**Fig. 32-5** Mycosis fungoides, early tumor stage.



**Fig. 32-6** Follicular mycosis fungoides. (Courtesy of Dr. Ellen Kim.)

The tumor stage is characterized by large, variously sized and shaped nodules on infiltrated plaques and on apparently normal skin (Fig. 32-5). These nodules tend to break down early and to form deep oval ulcers, whose bases are covered with a necrotic grayish substance and which have rolled edges. The lesions generally have a predilection for the trunk, although they may be seen anywhere on the skin or may involve the mouth and upper respiratory tract. Infrequently, tumors may be the first sign of MF.

The erythrodermic variety of MF is a generalized exfoliative process, with universal redness. The hair is scanty, nails are dystrophic, palms and soles are hyperkeratotic, and at times, generalized hyperpigmentation may occur. Erythroderma may be the presenting feature.

#### Alopecia mucinosa

The infiltrating cells of MF can demonstrate a predilection for involving the hair follicle (Fig. 32-6). This may be observed simply by folliculotropism of the cells (pilotropic or follicular



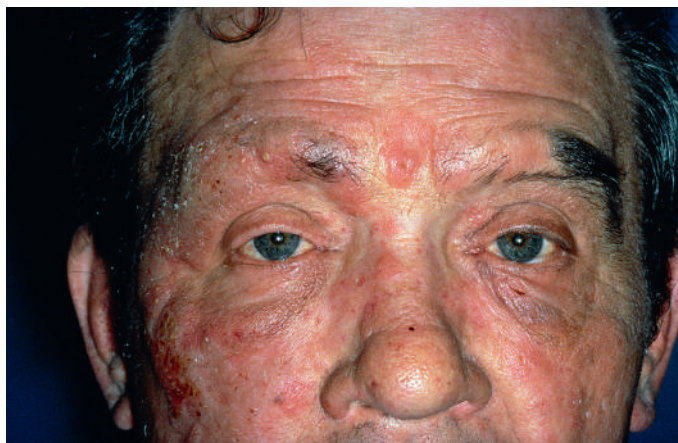

Fig. 32-7 Alopecia mucinosa.

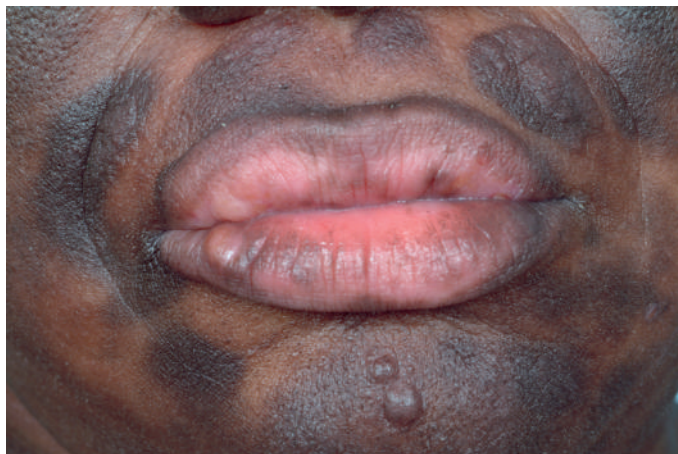

Fig. 32-8 Syringotropic mycosis fungoides.

MF) or by the appearance of follicular mucinosis (Fig. 32-7). In all cases of follicular mucinosis, the histologic specimen should be carefully examined and the diagnosis of MF considered. Among patients older than 40 who have follicular mucinosis, a large percentage will have MF or go on to develop it. However, the finding of a T-cell clone in lesions of follicular mucinosis without MF is not predictive of the development of CTCL.

Selective tropism of the CTCL cells to the sweat glands and ducts is termed syringotropic CTCL (Fig. 32-8). This is often seen in conjunction with follicular involvement. Syringolymphoid hyperplasia may be seen in these cases histologically and may mimic eccrine carcinoma. Cases previously termed “syringolymphoid hyperplasia with alopecia” are now considered to be cutaneous T-cell lymphoma. Clinically, the lesions present as discrete follicular and nonfollicular erythema, along with alopecia, milia, and follicular cysts. The initial clinical diagnosis in such cases is often discoid lupus erythematosus. The prognosis in MF with adnexal involvement is as predicted by the staging system for other MF forms. Patients with granulomatous MF have a poorer prognosis and a poorer response to skin-directed therapy.

### Systemic manifestations

Mycosis fungoides as a form of malignant lymphoma may progress to include visceral involvement. Lymph node involvement is most common; it predicts progression of MF in at least one quarter of patients and reduces survival to about 7 years.

Any other evidence of visceral involvement is a poor prognostic sign. An abnormal result on liver-spleen scan, chest radiograph or CT evaluation, abdominal or pelvic CT scans, or bone marrow biopsy is associated with a survival of about 1 year. The prognosis is worse in non-Caucasian patients with early-onset MF, especially African American women.

### Pathogenesis

Mycosis fungoides is a neoplasm of memory Th cells in most cases. Rare cases of suppressor cell (CD8+) MF have been reported. These CD8+ cases may behave indolently, like MF, or aggressively. The aggressive subset tends to present with plaques rather than patches. The events leading to the development of the malignant T cells are unknown. Some speculate that it is caused by chronic exposure to an antigen, but this has yet to be confirmed. Patients with atopic dermatitis appear to be at increased risk for development of MF, suggesting that persistent stimulation of T cells may lead to development of a malignant clone.

The inflammatory nature of the skin lesions has led to investigation of the interactions of the malignant T cells and both keratinocytes and antigen-presenting cells (APCs, including Langerhans cells) in MF. MF skin lesions have many features of skin that is immunologically “activated.” MF cells express cutaneous lymphocyte antigen (CLA), the ligand for E selectin, which is expressed on the endothelial cells of inflamed skin. This allows the malignant cells to traffic into the skin from the peripheral blood. CCR4, another homing molecule, is expressed on MF cells, and the ligand for this receptor is on basal keratinocytes. APCs are increased in MF lesions and have increased functional capacity to activate T cells. There is increased expression of major histocompatibility complex (MHC) class II antigens on the surface of the APCs. Through cytokines, infiltration of neoplastic and reactive T cells is increased. The pattern in early MF is more Th1-like, and the nonneoplastic infiltrating cells (tumor-infiltrating lymphocytes, TILs) may play a role in downregulating and controlling the neoplastic cells. There are more CD8+ cells in these early lesions, and these TILs may control the malignant clone. In fact, MF patients with more than 20% CD8+ cells in their skin survive longer than those with less than 15%. In summary, early MF is a condition in which host immunity is intact and the host immune system effectively limits proliferation of the malignant T-cell clone. In more advanced MF and in Sézary syndrome, perhaps through interleukin (IL)-4 and IL-10, a Th2 environment exists. This downregulates suppressor cell function and allows the malignant clone to proliferate. In addition, the Th2-dominant environment reduces effective Th-cell function, explaining the increased risk of infection and secondary cancer in patients with advanced CTCL. Correcting the aberrant immune response in advanced CTCL is the basis of some treatment approaches.

Common chromosomal alterations in MF include gain of 7q36 and 7q21-7q22 and loss of 5q13 and 9p21. This characteristic pattern differs from that seen in Sézary syndrome, suggesting that the two disorders are distinct. Low levels of human herpesvirus (HHV) 8 have been detected in large-plaque parapsoriasis as well as MF, but an etiologic link has not been established.

As MF advances, the number of circulating malignant T cells increases. Standard cytologic evaluation (the Sézary preparation) is expensive and not very accurate, even when enhanced by specific labeling techniques. Use of standard laboratory tests, such as the CD4/CD8 ratio test, which increases as MF progresses, and assessment of the number of CD4+, CD7- or CD4+, CD26- circulating cells, which relatively specifically identify MF cells, yield indicators of tumor burden with advanced disease but are of limited value in early disease.



## Histopathology

Perhaps more than in any other situation in dermatopathology, the ability to diagnose mycosis fungoides histologically correlates closely with the skill, training, and experience of the reviewing pathologist. When the clinician is considering a diagnosis of MF, consultation with a skilled dermatopathologist should be strongly considered if original histologic reports are nonconfirmatory or nonspecific.

In patch-stage lesions, subtle epidermotropism of lymphocytes resembles a vacuolar interface dermatitis with a lymphocyte in every vacuole. As lesions progress, there is a distinct bandlike distribution of lymphocytes with epidermotropism. At this stage, a large, dark lymphocyte is present in every vacuole. The lymphocytes within the epidermis may be numerous or few but are typically larger, darker, and more angulated than those in the dermis. Papillary dermal fibrosis is typically present. The superficial perivascular lymphoid infiltrate that surrounds the postcapillary venule is typically more prominent above the vessel than below the vessel ("bare underbelly" sign).

Plaques of MF show a more prominent, superficial bandlike lymphoid infiltrate and a deeper perivascular dermal component than patch-stage lesions. Papillary dermal fibrosis is more prominent, and the subpapillary plexus is shifted downward. Epidermotropism is much more marked and is typically associated with minimal spongiosis. This helps distinguish patch-stage MF from spongiotic dermatitis. Vesicular variants are an exception to this rule. In vesicular variants, spongiosis is prominent and results in intraepidermal and subcorneal vesiculation. Eosinophils are common in folliculotropic MF (with or without follicular mucinosis) but are uncommon in other MF forms.

In thick plaques and tumors, epidermotropism may be substantially diminished. The diagnosis of MF is confirmed by the presence of dense sheets of infiltrating lymphocytes in the dermis and subcutaneous fat. These cells may have cerebriform nuclei.

Cardinal features that should suggest a diagnosis of MF include the following:

- Solitary or small groups of lymphocytes in the basal cell layer
- Epidermotropism of lymphocytes, with disproportionately scant spongiosis
- More lymphocytes within the epidermis than would normally be seen in an inflammatory dermatosis, with little accompanying acanthosis or spongiosis
- Lymphocytes in the epidermis larger than those in the dermis
- Papillary dermal fibrosis with bundles of collagen arranged haphazardly
- Prominent folliculotropism or syringotropism of the lymphocytes, especially with intrafollicular mucin deposition (follicular mucinosis)

Features that should suggest a diagnosis of inflammatory dermatosis over MF include the following:

- Prominent upper dermal and papillary edema
- Marked epidermal spongiosis
- Accumulation of the intraepidermal inflammatory cells in flask-shaped collections, with the top open to the stratum corneum

Immunohistochemistry is of some value in assessing MF. MF cells characteristically are CD4+, but lose the CD7 and CD26 antigens (i.e., they are CD4+,CD7-,CD26-). This phenotype is very unusual for nonmalignant T cells and thus is useful in evaluating biopsy specimens and peripheral blood

lymphocytes. Loss of CD7 expression within the large, dark lymphocytes in the epidermis, with normal expression in the benign recruited lymphocytes in the infiltrate below, suggests a diagnosis of MF. DNA hybridization or a Southern blot test is frequently performed in equivocal cases to detect clonal rearrangement of the T-cell receptor (TCR). However, these data must be interpreted with caution; again, clonality does not confirm a diagnosis of malignancy. Benign processes may contain clonal TCR rearrangements. In early lesions of MF, the number of infiltrating cells may be insufficient for a clone to be detected, so a negative test does not exclude the diagnosis of MF. Testing with fresh tissue is somewhat more sensitive than with fixed tissue using current methods. Similar techniques can be used to evaluate lymph nodes in MF patients. Lymph node involvement can be detected by these molecular methods, whereas routine histologic evaluation yields normal results. Patients with more advanced disease are more likely to have clones in their lymph nodes, and the presence of clonality is predictive of shorter survival.

## Differential diagnosis

In the early patch stage, MF may be difficult to diagnose. The skin lesions usually resemble a nondescript form of eczema with some scale. Interestingly, despite the itching, scratch marks and lichenification are usually absent. MF presenting as papuloerythroderma of Ofuji is an obvious exception. The multiple morphologies of MF make the differential diagnosis vast. Plaquelike lesions may resemble subacute dermatitis or psoriasis. Tumors must be differentiated from other forms of lymphoreticular malignancy and metastases.

## Treatment

Effective therapy that reliably prolongs survival of MF patients has not yet been documented. Many forms of therapy induce remissions of variable length. The therapeutic choice depends on extent of disease, the patient's overall health and physical status, the physician's experience and preference, and the availability of various options. Topical corticosteroids, topical nitrogen mustard or 1,3-bis-(2-chloroethyl)-1-nitrosourea (carmustine, BCNU), bexarotene gel 1%, and PUVA or narrow-band UVB are generally good choices for stages IA, IB, and IIA disease. Patch-stage MF has responded to alefacept. Total-skin electron beam therapy can be used for refractory stage IIA and IIB cases. Single-agent chemotherapy or photophoresis can be used as initial management for stage III patients. Low-dose methotrexate may control the skin lesions of MF but has been associated with development of a secondary aggressive lymphoma in a few patients. Pegylated liposomal doxorubicin and combinations of IFN alfa, retinoids (bexarotene or isotretinoin), photophoresis, IFN gamma, skin-directed PUVA, sargramostim (granulocyte-macrophage colony-stimulating factor), alemtuzumab, and perhaps IL-2, IL-12, and IFN alfa may be effective in stage IV disease, as well as for patients who have failed the therapies previously cited for stages IIB and III MF. Multiagent systemic chemotherapy is used much less often with the advent of immunomodulatory treatments for MF. Chemotherapy should be considered only when all other treatment options have failed. Treatment of early-stage disease is in general restricted to skin-directed treatments. More advanced disease is treated with different modalities at different institutions. Combinations of agents are often used, and the combinations and their order of use vary among institutions. In general, therapies that also enhance the patient's immune system are favored in persons with more advanced disease. Complete remission of MF has been noted after a severe reaction to combined therapy with bexarotene, vorinostat, and high-dose fenofibrate. The reaction included fever, extensive skin necrosis, and granuloma formation.

## Topical corticosteroids

The availability of superpotent class I topical corticosteroids has led to a reassessment of their possible role in the management of early MF (patch stage, T1 and T2). Zackheim et al. reported a 63% complete remission rate for patients with T1 disease and a total response rate of 94%. In T2 patients, complete response was seen in only 25% but total response in 82%. The predominant side effect was a temporary and reversible suppression of the hypothalamic-pituitary axis in about 13% of patients. The responses were short-lived if therapy was stopped, but given the limited toxicity, this is not necessary in many patients. The adjunctive value of topical corticosteroids in T1 MF requires reappraisal because the response rates are similar to other modalities used for early MF, and the toxicity is very low.

## Topical nitrogen mustard

Anhydrous gel or ointment-based mustard products are being used more often, but aqueous mustard is still used as well. The contents of a 10-mg vial of mechlorethamine hydrochloride (Mustargen-MSD) are dissolved in 60 mL of tap water and applied to the entire skin surface, except the face, axillae, and genitalia, with a 2-inch paint brush or gauze pad. The last milliliter may be diluted to half-strength or greater dilution for application to the face, axillae, and genitalia. Daily applications are made until complete clearing occurs, which usually takes several months or longer, and may be continued indefinitely. Such treatment leads to complete responses in 80% of patients with stage IA disease, 68% in stage IB, 61% in stage IIA, 49% in stage IIB, and 60% in stage III patients. About 10% of patients obtain a durable and long-lasting remission of more than 8 years. The major side effects of topical nitrogen mustard (NH<sub>2</sub>) therapy are cutaneous intolerance, which occurs in almost 50% of patients, and allergic contact dermatitis, which occurs in 15%. Short (1 h) contact does not reduce this rate of sensitization. This can be reduced by the use of an ointment formulation, but response rates have been reported to be inferior with the ointment form. At least half of patients will relapse when therapy is stopped, but they frequently will respond again to NH<sub>2</sub>.

The duration of maintenance therapy after achieving remission varies in different centers. Some treat for an additional 6 months, and others taper treatment over 1 year or more, or continue treatment indefinitely. In many centers, topical nitrogen mustard has been a proven mainstay of therapy for patch- or plaque-stage MF without lymphadenopathy.

## Topical BCNU (carmustine)

Topical BCNU, 2 mg/mL in 150-mL aliquots, dissolved in ethanol, is dispensed to the patient. From this stock solution, the patient takes 5 mL and adds it to 60 mL of water at room temperature. This is applied once a day to the whole body, sparing the folds, genitals, hands, and feet (if they do not have lesions). If the extent of disease is limited, only the affected areas are treated. The average treatment course is 8–12 weeks. If, after 3–6 months, the patient's condition is not responding, the concentration may be doubled and the treatment repeated for 12 weeks. For small or persistent lesions, the straight stock solution may be applied daily. Patients tolerate BCNU better than nitrogen mustard, contact sensitization is uncommon, and responses are more rapid. CBC should be monitored monthly during treatment, but marrow suppression occurs in less than 10% of patients treated with the low concentrations. Telangiectasia, which may be persistent and severe, can occur after prolonged BCNU therapy or following an adverse cutaneous reaction to the medication.

## Ultraviolet therapy

Both UVB (narrow- or broad-band) and PUVA (systemic or bath) have been effective in the management of MF. About 75% of patients with patch-stage disease will have a complete clinical remission with UVB therapy. Home therapy is successful. PUVA has been used more extensively and, because of its deeper penetration, is perhaps better suited to the treatment of a disorder with a dermal component. Complete clearing is seen in 88% of patients with limited patch/plaque disease and in 52% of patients with extensive disease. Tumor-stage MF patients do not clear. Erythrodermic patients have poor tolerance for PUVA. Up to 50% of patients with a complete response to PUVA may have a remission of up to 10 years. Retinoids and IFN alfa may be added to PUVA. Retinoids may reduce the total number of PUVA treatments required. Low-dose IFN alfa plus PUVA may be used in patch-stage patients in whom topical therapy and PUVA alone are ineffective. The excimer laser may be used once or twice a week to deliver the phototherapy if the patient has a limited number of lesions. On average, 5–6 weeks of treatment is required, and remissions of up to 2 years or more can be achieved.

Extracorporeal photochemotherapy (photophoresis, ECP) is a therapeutic modality in which the circulating cells are extracted and treated with UVA outside the body; the patient ingests psoralen before the treatment. Complete responses are seen in about 20% of MF patients, and a partial response occurs in a similar percentage. In the original reports, the overall response rate for erythrodermic patients was 80%, but many of these patients failed to have at least the 50% clearing required to be considered a partial response. In one comparative trial, standard PUVA was significantly more effective than photophoresis alone, and photophoresis was judged ineffective in plaque-stage (T2) MF. ECP is now used in combination with other agents, especially IFN alfa, and appears to have better efficacy. Insulin-dependent diabetic patients respond poorly.

## Photodynamic therapy

Photodynamic therapy (PDT) with methyl-aminolevulinic acid has been used successfully for paucilesional MF. Responses were seen in 75% of patients, and patient satisfaction was high.

## Radiation

Total-skin electron beam (TSEB) therapy in doses in excess of 3000 Gy is very effective in the management of MF. Stage T1 patients have a 98% complete response; stage T2, 71%; stage T3, 36%; and stage T4, 64%. Long-term remissions occur in about 50% of T1 patients and 20% of T2 patients. Erythrodermic patients tolerate TSEB therapy poorly; other modalities should be attempted initially. Adjuvant therapy with a topical agent or PUVA can be considered if the patient relapses, as frequently occurs. The most common side effects of TSEB therapy are erythema, edema, worsening of lesions, alopecia, and nail loss. Persistent hyperpigmentation and chronically dry skin are also problems after TSEB therapy. Orthovoltage radiation may be used to control tumors or resistant thick plaques in patients whose conditions have been otherwise controlled with another modality.

## Biologic response modifiers (multimodality immunomodulatory therapy)

The appearance of circulating malignant T cells in MF may indicate failure of the host immune system to control the disease. Immunomodulatory agents are used in an attempt to enhance host immune function and gain control of the disease. It is often combined with treatments that increase malignant



cell apoptosis, so that the “tumor antigens” released will be recognized and immunologically “attacked” by the host immune system. These immunomodulatory agents both activate APCs and enhance Th1 immune function directed against the malignant T-cell clone. IFN alfa and IFN gamma have been shown to have efficacy against MF. IFN alfa is associated with a positive response in about 60% of patients and a complete response in 19%. If it is used as a single agent, toxicity is high and includes fever, chills, myalgias, neutropenia, and depression. Low-dose IFN-alfa and IFN-gamma treatments and granulocyte-macrophage colony-stimulating factor (GM-CSF) are now used in adjunctive fashion in combination with retinoid therapy, phototherapy, and other modalities. This is termed multimodality immunomodulatory therapy. IL-2 and IL-12 may be used in a similar manner in the future.

### Retinoids

Both isotretinoin and etretinate have efficacy in the treatment of MF. A clinical response is noted in about 44% of patients. Dosage of isotretinoin is about 1 mg/kg/day to start and may be increased up to 3 mg/kg/day as tolerated. Retinoids may be effective in stage IB (T2) and stage III patients, and as a palliative treatment in those with stage IVA disease. Bexarotene (Targretin), a synthetic retinoid that is bound preferentially by the retinoid X receptor (RXR), is thought to work by inducing apoptosis in the malignant T cells. It is available as a topical gel and as an oral tablet. Topical therapy is used in patients with stage IA–IIA CTCL. Patients improve about 50% with this treatment. Oral bexarotene at a dose of 300 mg/m<sup>2</sup> also has a response rate of about 50% in early-stage CTCL. This dose is complicated by hypercholesterolemia, marked hypertriglyceridemia (at times complicated by pancreatitis), central hypothyroidism, and leukopenia. It may be combined with PUVA and other forms of treatment at a lower dose.

### Systemic chemotherapy

For most forms of cancer, combinations of chemotherapeutic agents are given. In mycosis fungoides, however, multidrug chemotherapy often exacerbates the ongoing immune imbalance and may prevent the patient’s immune system from attacking the malignant T cells. For this reason, and because of the enhanced efficacy of combination immunomodulatory treatment regimens, systemic chemotherapy is now very uncommonly used for MF. Methotrexate, in doses from 5 to 125 mg/week, is effective for the management of T3 patients. In these patients, Zackheim et al. reported that 41% had a complete response, and an additional 17% a partial response, giving a total response of 58%. The median overall survival was 8.4 years, and 69% of patients were alive at 5 years. For advanced MF, higher doses of methotrexate with citrovorum-factor rescue were successful in obtaining a response, which was then maintained with lower doses of methotrexate, not requiring rescue. Similarly, vorinostat (and other histone deacetylase inhibitors), pentostatin, etoposide, fludarabine, and 2-chlorodeoxyadenosine have been used. Systemic chemotherapy beyond methotrexate, especially multiagent chemotherapy, is best managed by an oncologist. Systemic chemotherapy is only indicated in stage III and IVA patients who have failed all the available immunoenhancing treatment protocols previously noted. A number of new agents are being evaluated for the treatment of MF. Histone deacetylase inhibitors, including vorinostat, demonstrate responses in a subgroup of patients. Forodesine is a novel inhibitor of purine nucleoside phosphorylase, and pralatrexate is a novel targeted antifolate agent.

### Fusion toxin

The toxin DAB389IL-2 is the fusion of a portion of the diphtheria toxin to recombinant IL-2. This selectively binds to cells

expressing the IL-2 receptor and leads to their death. A series of MF patients who expressed the IL-2 receptor demonstrated a response rate of 37%, including a complete response in 14%. These patients had failed conventional therapies. Patients in stages I–III achieved response, but no patient with stage IV disease did so. Fever, chills, hypotension, nausea, and vomiting were common, and at high doses, a vascular leak syndrome occurred. This agent is reserved for advanced-stage patients who have failed other modalities.

**Ahn CS, et al:** Mycosis fungoides: an updated review of clinicopathologic variants. *Am J Dermatopathol* 2014; 36(12):933–951.

**Boulos S, et al:** Clinical presentation, immunopathology, and treatment of juvenile-onset mycosis fungoides: A case series of 34 patients. *J Am Acad Dermatol* 2014; 71(6):1117–1126.

**de Masson A, et al:** Syngiotropic mycosis fungoides: Clinical and histologic features, response to treatment, and outcome in 19 patients. *J Am Acad Dermatol* 2014; 71(5):926–934.

**Enke CA:** New options in diagnosis and management of mycosis fungoides and Sézary syndrome. *Oncology (Williston Park)* 2010; 24(6):507–508.

**Iwamoto M, et al:** Clinical pharmacology profile of vorinostat, a histone deacetylase inhibitor. *Cancer Chemother Pharmacol* 2013; 72(3):493–508.

**Ladizinski B, et al:** Mycosis fungoides. *Mayo Clin Proc* 2013; 88(3):e27.

**Li JY, et al:** A case-control study of clinicopathologic features, prognosis, and therapeutic responses in patients with granulomatous mycosis fungoides. *J Am Acad Dermatol* 2013; 69(3):366–374.e4.

**Pileri A, et al:** Role of bexarotene in the treatment of cutaneous T-cell lymphoma: the clinical and immunological sides. *Immunotherapy* 2013; 5(4):427–433.

**Schlaak M, et al:** Allogeneic stem cell transplantation versus conventional therapy for advanced primary cutaneous T-cell lymphoma. *Cochrane Database Syst Rev* 2013; 8:CD008908.

**Wilcox RA:** Cutaneous T-cell lymphoma: 2014 update on diagnosis, risk-stratification, and management. *Am J Hematol* 2014; 89:837–851.

## Pagetoid reticulosis

Localized epidermotropic reticulosis, pagetoid reticulosis, or Worringer-Kolopp disease is an uncommon lymphoproliferative disorder considered to be a form of mycosis fungoides. Other terms suggested for these cases have included acral mycosis fungoides or mycosis fungoides palmaris et plantaris. In large, MF clinics, such cases represent about 0.6% of all MF cases. Pagetoid reticulosis is divided into classic Worringer-Kolopp, which usually describes solitary lesions, and cases with multiple lesions (Ketrion-Goodman variant). The unique features of Worringer-Kolopp disease are clinical. The disease presents as a solitary lesion that is often located on an extremity and frequently has a keratotic rim. If there is more than a single lesion, the lesions often tend to involve both the palms and the soles. Frequently, over months to years, the lesion gradually enlarges, reaching more than 10 cm in size. In some cases, the lesions spontaneously come and go over many years. About 20% of cases occur in patients who are younger than 15 years. The long duration without progression has been a clinical hallmark of Worringer-Kolopp disease. Histologically, there is prominent epidermotropism of lymphocytes, with many lining up in the basal cell layer. This histologic pattern correlates with strong  $\alpha$ E $\beta$ 7- and  $\alpha$ 4 $\beta$ 7-integrin expression by the infiltrating cells. This integrin expression is also seen in the epidermotropic cells of classic MF and contact dermatitis. In MF, most cases are CD4+, but in the acral MF cases, they may be CD4+, CD8+, or negative for both. TCR gene rearrangements can be detected in many cases of Worringer-Kolopp disease. Therapeutically, local excision and radiation therapy have been “curative” in many patients. Topical and systemic PUVA and PDT have also proved effective. Local recurrence is possible.

## Sézary syndrome

Sézary syndrome is the leukemic phase of mycosis fungoides. The characteristic features are generalized erythroderma, superficial lymphadenopathy, and atypical cells in the circulating blood. Although patients with classic MF may progress to Sézary syndrome, patients with Sézary syndrome usually are erythrodermic from the onset. The skin shows a generalized or limited erythroderma of a typical fiery red color. Associated features can include leonine facies, eyelid edema, ectropion, diffuse alopecia, hyperkeratosis of the palms and soles, and dystrophic nails. Some patients develop lesions identical to vitiligo, especially on the lower legs. The symptoms are those of severe pruritus and burning, with episodes of chills. Prognosis is poor, with an average survival of about 5 years.

Superficial lymphadenopathy is usually found in the cervical, axillary, and inguinal areas. Leukocytosis up to 30,000 cells/mm<sup>3</sup> is usually present. In the peripheral blood, skin infiltrate, and lymph nodes, Th cells with deeply convoluted nuclei are found, the so-called Sézary cells. Chromosomal aberrations are common but differ from the typical pattern seen in MF. Resistance to Fas-ligand and TNF-related apoptosis has been demonstrated.

Histologically and on immunohistochemistry, there are no reproducible differences between cases of MF and Sézary syndrome. In a fair number of Sézary patients, the cutaneous histology may be nonspecific, showing a spongiotic dermatitis. Additional hematologic evaluation may be necessary to confirm the diagnosis in the erythrodermic patient. T-cell gene rearrangement studies are frequently used to confirm the diagnosis of Sézary syndrome. In addition, an increased CD4/CD8 ratio in the blood, with an increase in the number of CD3+/CD4+/CD7-/CD26- circulating cells, is suggestive of leukemic MF.

The erythroderma of Sézary syndrome must be distinguished from chronic lymphocytic leukemia (CLL), psoriasis, atopic dermatitis, photodermatitis, seborrheic dermatitis, contact dermatitis, drug reaction, and pityriasis rubra pilaris. This is done primarily by histopathologic and immunopathologic examination. In Sézary syndrome, the infiltrating T cells in the skin have a Th2 phenotype, and Th2 cytokines are produced by these cells. This explains the reduced delayed-type hypersensitivity, elevated IgE, and eosinophilia seen in these patients.

Sézary syndrome is difficult to treat. Low-dose methotrexate has a reasonable response rate of about 50% and an overall survival of 101 months, suggesting a survival benefit with its use. Photophoresis, used in combination with other agents, is effective in some patients, but the median survival time is only 39–60 months (see earlier). TSEB radiation has produced some complete cutaneous responses, as well as improvement in the blood burden of malignant cells. Zanolimumab has also been used in this setting.

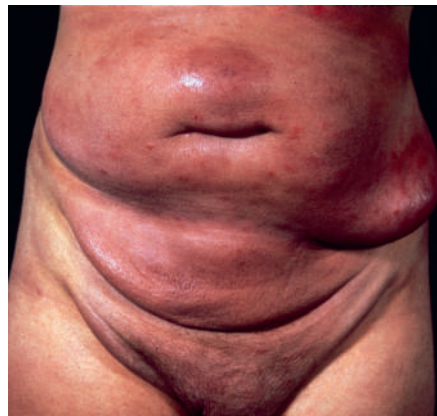**Duarte RF, et al:** Long-term outcome of allogeneic hematopoietic cell transplantation for patients with mycosis fungoides and Sézary syndrome: a European society for blood and marrow transplantation lymphoma working party extended analysis. *J Clin Oncol* 2014; 32(29):3347–3348.

**Lee AD, et al:** What is Woringer-Kolopp disease? *Skinmed* 2013; 11(1):17–20.

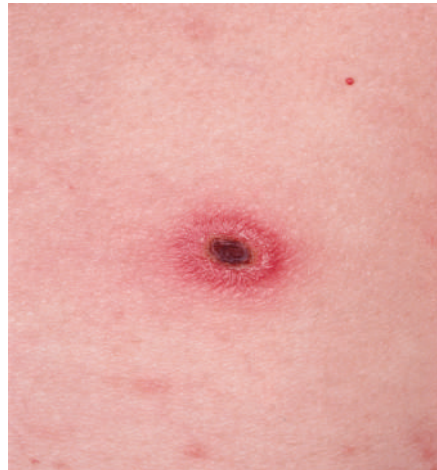
**Mendese GW, et al:** Pagetoid reticulosis in a prepubescent boy successfully treated with photodynamic therapy. *Clin Exp Dermatol* 2012; 37(7):759–761.

## Granulomatous slack skin

Granulomatous slack skin is a rare variant lymphoma that typically presents in middle-age adults and gradually



**Fig. 32-9**  
Granulomatous slack skin.



**Fig. 32-10**  
Lymphomatoid papulosis.

progresses over years. It occurs more often in men. Lesions are erythematous, atrophic, bulky, infiltrated, pendulous, and redundant plaques in the axillae and groin (Fig. 32-9). Unusual presentations may resemble Hansen's disease or acquired ichthyosis. Histologically, there is a lymphohistiocytic infiltrate extending through the dermis into the subcutaneous fat. Focal collections of huge, multinucleated cells with 20–30 nuclei arranged in a wreathlike pattern are characteristic. Elastophagocytosis is prominent and elastic tissue is absent in areas of inflammation. Lymphocytes are also found within the multinucleate giant cells and are arranged around them. Epidermotropic lymphocytes are also seen. Immunohistologically, the cells are CD4+. T-cell gene rearrangements can be detected. In most patients, the condition evolves into mycosis fungoides, but about one third of patients with granulomatous slack skin develop Hodgkin disease after years to decades.

**Hsiao PF, et al:** Granulomatous slack skin presenting as acquired ichthyosis and muscle masses. *Am J Clin Dermatol* 2009; 10(1):29–32.

## Lymphomatoid papulosis

Lymphomatoid papulosis (LyP) is an uncommon, but not rare, disorder. It occurs at any age, including childhood, but is most common in adults with a mean age of 44. In typical cases, the lesions and course are very similar to Mucha-Habermann disease (pityriasis lichenoides et varioliformis acuta), except that the lesions tend to be slightly larger and fewer in number and have a greater propensity to necrosis. Symptoms are usually minimal. The primary lesion is a red papule up to about 1 cm in diameter (Fig. 32-10). The lesions evolve to papulovesicular, papulopustular, or hemorrhagic, then necrotic papules over days to weeks. They typically heal spontaneously



within 8 weeks, somewhat longer in larger lesions. Lesions are usually generalized, although cases limited to one anatomic region have been reported.

There may be crops of lesions or a constant appearance of a few lesions. In most patients, however, the condition tends to be chronic, and lesions are present most of the time if no treatment is given. The average number of lesions present at any one time is usually 10–20, but cases with more than 100 lesions occur. Lesions heal with varioliform, hyperpigmented, or hypopigmented scars. Cases previously reported as solitary, large nodules of lymphomatoid papulosis would now be classified as CD30+ large cell lymphomas or as overlaps between LyP and lymphoma, termed borderline cases. Localized agminated LyP may be seen in areas typical for mycosis fungoides.

The diagnosis of LyP is confirmed histologically. There is a dermal infiltrate that is wedge shaped, patchy, and perivascular. In larger lesions, the infiltrate may occupy the whole dermis. It may also be bandlike. The infiltrate may involve the epidermis, with epidermotropism of inflammatory cells. As lesions evolve, epidermal necrosis and ulceration may occur. The dermal vessels may demonstrate fibrin deposition and, more rarely, a lymphocytic “vasculitis.” The dermal infiltrate is composed of lymphoid cells, eosinophils, neutrophils, and larger mononuclear cells. Atypical, large or small lymphoid cells are present and may represent up to 50% of the infiltrate. Histologically, lesions have been classified into type A, type B, and type C lesions.

Type A lesions contain atypical large cells with abundant cytoplasm and prominent nuclei, with prominent eosinophilic nucleoli. If these cells contain two nuclei, they closely resemble Reed-Sternberg cells. In type B lesions, the atypical cells are smaller, with a smaller cerebriform, hyperchromatic nucleus. These resemble the atypical cells of MF. In both types of lesion, atypical mitotic figures may be observed. Immunophenotypically, the large atypical cells mark as T cells, usually Th type. The atypical cells, especially those of the type A lesions, stain for the activation marker Ki-1 or CD30. Bcl-2 expression occurs in about 50% of cases. When clonal rearrangement studies are performed, clonal rearrangements may be found in up to 40% of LyP lesions, but this finding is not predictive of the behavior of that lesion or the case in general. Type C lesions overlap with primary cutaneous large cell lymphoma, with no clear distinction between the two. Type D, CD8+ LyP is a rare variant in which CD8+ T cells proliferate, mimicking cytotoxic lymphoma. Type E has been proposed as an angioinvasive type resembling angiodestructive lymphoma histologically, but with a self-healing course. The follicular type resembles folliculotropic MF with a relapsing course.

Lymphomatoid papulosis types A and B are associated with lymphoma. In the general literature, this number is about 5–10%, but some reports have documented rates as high as 20%, and at the University of California at San Francisco (UCSF), up to 40% of cases of LyP have an associated lymphoma. The lymphoma may occur before, concurrently with, or after the appearance of the LyP. In most cases, LyP precedes development of lymphoma, sometimes by a long period—up to 20 years. The associated lymphoma is most often mycosis fungoides (40%), a CD30+ T-cell lymphoma (30%), or Hodgkin disease (25%). The lymphoma and LyP may behave quite independently. If the lymphoma is successfully treated and cleared, the LyP typically continues. Despite this independent behavior, the lymphoma and the LyP may contain the same clonal TCR gene rearrangement. Patients with pure type B lesions are much less likely to develop lymphoma than patients with type A lesions. Lesions of LyP may occur on a background of MF and must be distinguished from CD30+ large cell transformation of MF. Papular lesions of LyP tend to occur in crops. Even

though the LyP lesions may demonstrate the same clonal rearrangements as the MF, they often continue to appear in crops, even when the MF lesions respond to therapy.

Therapy may not be necessary; no evidence shows that treatment of LyP prevents development of secondary lymphoma. When any therapy is stopped, the LyP invariably returns. Therefore, patients only need to be treated if they are moderately symptomatic and the treatment has fewer potential complications than the benefits gained. Superpotent topical corticosteroids have been beneficial in some childhood cases. Topical bexarotene may abort early lesions, and oral bexarotene may suppress lesion formation. PUVA systemically or topically may be effective, although maintenance treatment is usually required. Both narrow- and broad-band UVB may be successful. Of all the systemic agents, methotrexate gives the most dependable response, with up to 90% of LyP patients improving significantly. It is given in weekly doses similar to those used for rheumatoid arthritis, usually 7.5–15 mg/week. Higher doses may be required in some patients. Response is rapid. Some patients treated with methotrexate may have remissions of the LyP. In most, however, maintenance therapy is required.

**Cardoso J, et al:** Lymphomatoid papulosis type D: a newly described variant easily confused with cutaneous aggressive CD8-positive cytotoxic T-cell lymphoma. *Am J Dermatopathol* 2012; 34(7):762–765.

**Ganapathi KA, et al:** Early lymphoid lesions: conceptual, diagnostic, and clinical challenges. *Haematologica* 2014; 99(9):1421–32.

**Kempf W, et al:** Angioinvasive lymphomatoid papulosis: a new variant simulating aggressive lymphomas. *Am J Surg Pathol* 2013; 37(1):1–13.

**Kempf W, et al:** Follicular lymphomatoid apulosis revisited: a study of 11 cases, with new histopathological findings. *J Am Acad Dermatol* 2013; 68(5):809–816.

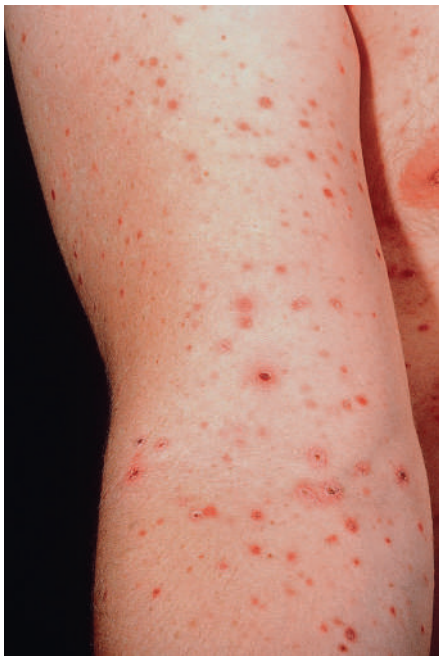## Pityriasis lichenoides

Both the acute and the chronic form of pityriasis lichenoides are lymphocytic vasculitides. The lymphoid infiltrate may contain a clonal proliferation. However, progression to cutaneous lymphoma is rare.

## Pityriasis lichenoides et varioliformis acuta (Mucha-Habermann disease)

Pityriasis lichenoides et varioliformis acuta (PLEVA) is a disorder that usually appears suddenly in children or young adults. Individual lesions are erythematous macules, papules, or papulovesicles. Lesions tend to be brownish red and evolve through stages of crusting, necrosis, and varioliform scarring. Lesions tend to appear in crops and may number from a few to more than 100 (Fig. 32-11). In general, PLEVA patients have more and smaller lesions than patients with LyP. The trunk is favored, but even the palms and soles may infrequently be involved. The patient feels otherwise well. The natural history is benign, with spontaneous involution occurring over 1–3 years. In children, diffuse cases resolved more quickly than cases that were purely central; cases with primarily peripheral lesions took almost twice as long to resolve.

Histologically, PLEVA is characterized by epidermal necrosis, together with prominent hemorrhage and a dense perivascular infiltrate in the upper and middle dermis in a wedge-shaped pattern. Lymphocytic vasculitis may be seen. T-cell gene rearrangements may be detected, but the significance of this finding is unclear at this time. Treatment of PLEVA may include oral erythromycin or tetracyclines and phototherapy (broad- or narrow-band UVB, PUVA, or PDT). Topical tacrolimus may be effective. Low-dose methotrexate,



**Fig. 32-11** Mucha-Habermann disease.

5.0–15 mg/week, may be required in severe cases. A rapid response to azithromycin has been reported. Etanercept has been reported as effective, but infliximab has been reported to cause pityriasis lichenoides.

An unusually severe form of PLEVA, febrile ulceronecrotic Mucha-Habermann disease, is characterized by the acute onset of diffuse, coalescent, large, ulceronecrotic skin lesions associated with high fever and constitutional symptoms. The condition may begin as typical PLEVA, but the ulceronecrotic lesions usually begin to appear within a few weeks. Skin necrosis may be extensive, especially in the intertriginous regions. Associated symptoms include gastrointestinal (GI) and central nervous system (CNS) symptoms, pneumonitis, myocarditis, and even death (in adult cases). The condition favors boys age 18 or younger. This severe form of PLEVA usually lasts several months with successive outbreaks, then resolves or converts to more classic PLEVA. Reported triggers include viral infections and radiocontrast injection. Treatment is systemic corticosteroids, and if response is limited, methotrexate. Dapsone may also be useful, for maintenance and as a steroid-sparing agent. Febrile ulceronecrotic Mucha-Habermann disease has been treated successfully with methotrexate as well as with infliximab and intravenous immune globulins.

### Pityriasis lichenoides chronica

Pityriasis lichenoides chronica (PLC) is a chronic form of pityriasis lichenoides related to PLEVA by its common histology. Lesions are erythematous, scaly macules and flat papules with very slow evolution. Lesions each last several months. The eventual resolution of lesions of PLC distinguishes it from guttate parapsoriasis, which it may resemble clinically. Lesions of small-plaque parapsoriasis do not spontaneously resolve. Lesions of PLC favor the lateral trunk and proximal extremities. Patients may have from 10 to hundreds of lesions, but usually fewer than 50. Resolution may leave persistent areas of hypopigmentation, which last for months to years. In many patients, the hypopigmented macules are the most prominent clinical finding. Unlike PLEVA, PLC tends to last for many years. Lesions may occur at any age. The condition often affects children, and onset at birth has been described.

Histologically, the changes in PLC are similar to PLEVA but much more subtle. A mild interface or perivascular lymphocytic infiltrate with overlying parakeratosis may be present. T-cell gene rearrangement studies may demonstrate monoclonality; however, the meaning of this finding is unclear at this time. Treatment with phototherapy (natural sunlight, UVB, UVA1, or PUVA) is most effective. Topical corticosteroids or tacrolimus may be tried. No treatment is required.

Generally, PLC is a benign disease. Rare patients have progressed to develop CTCL. The authors recommend that patients with PLC be followed regularly; changes in lesion morphology, including induration, erosion, atrophy, persistent erythema, or poikiloderma, should trigger repeat pathologic evaluation.

**Aydogan K, et al:** Narrowband UVB (311 nm, TL01) phototherapy for pityriasis lichenoides. *Photodermatol Photoimmunol Photomed* 2008; 24(3):128–133.

**Ersoy-Evans S, et al:** Narrowband ultraviolet-B phototherapy in pityriasis lichenoides chronica. *J Dermatolog Treat* 2008; 14:1–5.

**Fernández-Guarino M, et al:** Pityriasis lichenoides chronica: good response to photodynamic therapy. *Br J Dermatol* 2008; 158(1):198–200.

**Markus JR, et al:** The relevance of recognizing clinical and morphologic features of pityriasis lichenoides: clinicopathological study of 29 cases. *Dermatol Pract Concept* 2013; 3(4):7–10.

**Meziane L, et al:** Febrile ulceronecrotic Mucha-Habermann disease: treatment with infliximab and intravenous immunoglobulins and review of the literature. *Dermatology* 2012; 225(4):344–348.

**Nanda A, et al:** Febrile ulceronecrotic Mucha-Habermann disease (pityriasis lichenoides et varioliformis acuta fulminans) associated with parvovirus infection. *Am J Dermatopathol* 2013; 35(4):503–506.

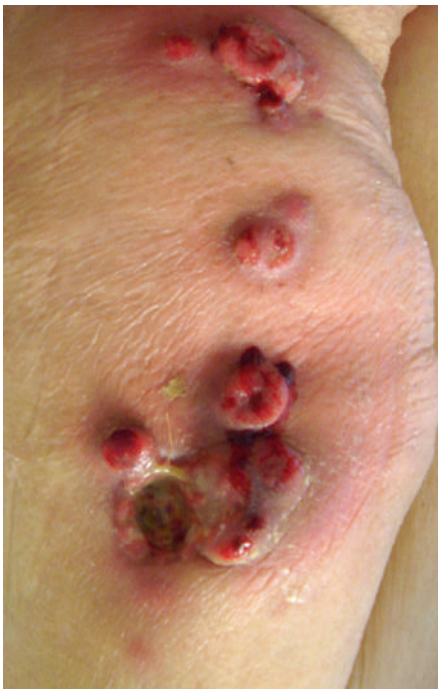**Park JM, et al:** Is narrowband ultraviolet B monotherapy effective in the treatment of pityriasis lichenoides? *Int J Dermatol* 2013; 52(8):1013–1018.

### Primary cutaneous T-cell lymphomas other than mycosis fungoides

Once a cutaneous lymphoma has been identified as being of T-cell origin and the diagnosis of mycosis fungoides and its variants has been excluded, the most important evaluation is to determine the CD30-staining pattern. CD30 is a marker found on some activated, but not resting T and B cells. It also marks the Reed-Sternberg cells of Hodgkin disease. Monoclonal antibodies Ki-1 and Ber H2 are used to identify CD30 positivity. A cutaneous lymphoma is considered to be CD30+ if there are large clusters of CD30+ cells or more than 75% of the anaplastic T cells are CD30+. Systemic CD30+ lymphoma with cutaneous involvement has a poor prognosis. Those cases that express anaplastic lymphoma kinase (ALK-1) associated with a 2:5 translocation have a somewhat better prognosis. Primary cutaneous large T-cell lymphomas that are CD30+ are typically ALK-1 negative, have a very good prognosis, and tend to run a relapsing course similar to that of lymphomatoid papulosis. Individual lesions respond to irradiation, and the relapsing course may remit with low-dose methotrexate. Large cell lymphomas of the skin have similar histologic and clinical features, so immunophenotyping is essential for prognosis. Clonal TCR gene rearrangements are present in large T-cell lymphoma. The group of T-cell lymphomas that are not large cell and CD30+ are classified in the WHO system as peripheral T-cell lymphomas.

CD56 is rapidly becoming the second most important immunophenotypic marker for cutaneous lymphomas. Four important variants of CD56+ cutaneous lymphomas have been identified: a subset of subcutaneous panniculitis-like T-cell





**Fig. 32-12** CD30+ anaplastic large cell lymphoma. (Courtesy of Dr. Misha Rosenbach.)

lymphoma, natural killer (NK)/T-cell lymphoma, blastic NK cell lymphoma, and CD8+ aggressive epidermotropic cytotoxic T-cell lymphoma.

Peripheral T-cell lymphoma is a heterogeneous grouping that includes primary cutaneous CD30+ nonanaplastic large cell lymphoma, primary cutaneous CD30– anaplastic and non-anaplastic large cell lymphoma, and primary cutaneous CD30– pleomorphic small/medium cell lymphoma.

### **CD30+ cutaneous T-cell lymphoma (primary cutaneous anaplastic large cell lymphoma)**

Clinically, the CD30+ CTCLs present as solitary or localized skin lesions that have a tendency to ulcerate (50%), spontaneously regress (25%), and relapse. They are rare in children and occur with slightly greater frequency in males. Lesions are usually firm, red to violaceous tumors up to 10 cm in diameter (Fig. 32-12). Tumors may grow in a matter of weeks. There is no favored anatomic site. Onset has been reported during glatiramer acetate treatment of multiple sclerosis.

Relapses in the skin are common, but the development of extracutaneous, bone marrow, or lymph node involvement is uncommon. Clonal populations may occasionally be demonstrated in peripheral blood, but differ from those in the skin. Lymph node involvement is associated with a poorer prognosis. The “pyogenic lymphoma” of the skin is a neutrophil-rich CD30+ lymphoma with skin lesions that clinically resemble Sweet syndrome, pyoderma gangrenosum, halogenoderma, leishmaniasis, or deep fungal infection. IL-8 overexpression by the anaplastic CD30+ cells causes the neutrophilic infiltration. The number of neutrophils present may make histologic interpretation difficult. Cases with features of both LyP and CD30+ anaplastic CTCL have been described, sometimes under the designation type C LyP. Histologically, there is a dense dermal nonepidermotropic infiltrate with atypical tumor cells whose large nuclei have one or several prominent nucleoli and abundant cytoplasm. The malignant cells can be further characterized as anaplastic, pleomorphic, and immunoblastic, but this distinction may be difficult and has yet to be determined to be of prognostic or therapeutic

value. This form of primary CTCL has an excellent prognosis, with a 5-year survival of 90%. Lesions are highly responsive to radiotherapy. Early individual lesions can even be surgically excised. Topical imiquimod has been therapeutically successful. Chemotherapy causes regression of lesions, but a rapid relapse usually occurs. Other than low-dose methotrexate, chemotherapy generally has little role in the treatment of this disease. Local hyperthermia has been used successfully, as has inhibition of the mammalian target of rapamycin.

### **Secondary cutaneous CD30+ large cell lymphoma**

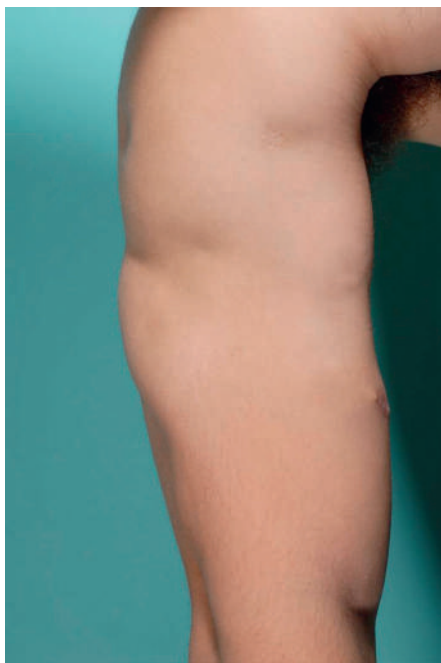
The CD30+ large cell lymphomas may arise in cases of MF, in patients with LyP, and in patients who have documented extracutaneous disease (secondary cutaneous anaplastic large cell lymphoma). Skin lesions of pyogenic lymphoma may be seen secondary to a pyogenic lymphoma of other organs. The prognosis is poor in patients who have extracutaneous disease preceding or near the time of cutaneous involvement. Among those with systemic disease, the expression of ALK-1 associated with a t(2; 5) translocation is a favorable prognostic feature. Kempf et al. reported that MUM1 expression is common in secondary anaplastic large cell lymphoma and in LyP, but uncommon in primary cutaneous anaplastic large cell lymphoma. Other authors have disputed that MUM1 is a useful marker. Patients with LyP who develop cutaneous CD30+ lymphoma and who do not have systemic lymphoma or MF typically have an excellent prognosis. The prognosis for MF patients who develop CD30+ anaplastic large cell lymphoma is poor.

### **Non–mycosis fungoides CD30– cutaneous large T-cell lymphoma**

Non-MF CD30– large CTCLs usually present as solitary or generalized plaques, nodules, or tumors of short duration. There is no preceding patch stage that distinguishes it from MF. The prognosis is poor, with 5-year survival of 15%. The malignant cells are pleomorphic, large or medium cell types or are immunoblastic. The cells may be cerebriform, and epidermotropism may be present. Some cases previously called d’emblée MF are better classified in this group. Multiagent chemotherapy is recommended.

### **Pleomorphic T-cell lymphoma (non–mycosis fungoides CD30–pleomorphic small/medium-sized cutaneous T-cell lymphoma)**

This group comprises about 3% of all primary cutaneous lymphomas. Pleomorphic small/medium-sized CTCL is distinguished from the large cell type by having less than 30% large pleomorphic cells. It is distinguished from MF by clinical features (lack of patch or plaque lesions). These primary cutaneous lymphomas usually present with one or several red-purple papules, nodules, or tumors 5 mm to 15 cm in size. Immunophenotypically, they are usually of Th-cell origin, and clonal rearrangements of the TCR gene are usually present. A CD4 phenotype, as opposed to a CD8 phenotype, is associated with a more favorable prognosis, but a CD4/CD56 phenotype has a poorer prognosis. The presence of a mixed population of suppressor cells, B cells, and histiocytes usually favors the diagnosis of reactive lymphoid hyperplasia. The overall prognosis is intermediate, with 5-year survival of 62%. The optimal therapy for this form of lymphoma has not been determined. Therapeutically, localized lesions have been treated



**Fig. 32-13**  
Subcutaneous T-cell lymphoma.

with radiation therapy or surgical excision. Chemotherapy, retinoids, IFNs, and monoclonal antibodies have been used in widespread or progressive disease.

### Lennert lymphoma (lymphoepithelioid lymphoma)

Lennert lymphoma is a rare CD4+ systemic T-cell lymphoma. Cutaneous lesions occur in less than 10% of patients and present as papules, plaques, or nodules. The skin lesions may not represent lymphoma cutis because palisaded granulomatous and nonspecific dermal infiltrates may occur. The clinicohistologic appearance may closely resemble granuloma annulare. The course is low-grade until the lymphoma transforms to a high-grade, large cell lymphoma.

### Subcutaneous (panniculitis-like) T-cell lymphoma

Clinically, patients are usually young adults who present with subcutaneous nodules (Fig. 32-13), usually on the lower extremities. The alpha/beta phenotype is generally associated with indolent disease, and gamma/delta lymphoma, which is associated with a more aggressive course, is now considered a separate provisional entity in the WHO classification. Weight loss, fever, and fatigue are common and may herald the onset of a rapidly progressive hemophagocytic syndrome.

Histologically, there is a lacelike infiltration of the lobules of adipocytes, mimicking panniculitis, especially lupus profundus. A characteristic feature is rimming of neoplastic cells around individual adipocytes with nuclear molding and atypia. Immunophenotypically, the neoplastic cells mark as T cells (CD2+, CD3+). Most cases are derived from  $\alpha/\beta$  T cells and are CD56-. Subcutaneous  $\gamma/\delta$  T-cell lymphomas are typically CD56+. Karyorrhectic debris, dermal involvement, and epidermotropism are clues to the diagnosis of  $\gamma/\delta$  T-cell lymphoma. Multiagent chemotherapy is recommended, at times with stem cell support. Denileukin diftitox (Ontak) was reported to produce a favorable response.

### Nasal/nasal-type NK/T-cell lymphoma (angiocentric lymphoma)

Natural killer/T-cell lymphoma most frequently presents in extranodal tissue and is characterized by a high incidence of nasal involvement. It is more common in Asia, where it affects primarily women with a mean age of 40. In Korea, it is reported to be the most common form of cutaneous lymphoma after mycosis fungoides. It is uncommon in the United States. Nasal NK/T-cell lymphoma presents clinically as dermal or subcutaneous papules or nodules that may ulcerate. Lesions are usually widespread and involve the lower extremities. A hydroa vacciniforme-type has been described in children in Mexico and in adults and children in Japan and Korea. Skin lesions are facial, and extremity papulovesicles ulcerate and heal with scarring. Skin lesions are exacerbated by sun exposure and are reproduced with UVA irradiation.

Histologically, the dermis and subcutaneous fat are infiltrated with intermediate-sized, atypical lymphocytes, within and around the walls of small and medium-sized vessels. Epidermotropism may be noted. The lymphoma cells express a spectrum of T- and NK-cell immunophenotypic markers, variably expressing CD2, CD3, CD4, CD8, and the NK-cell marker CD56. CD56 is not cell lineage specific, and a subset of CD56 cutaneous lymphoma cases is classified under the SPTCL category. Epstein-Barr virus is present in the NK variants and variably present in the T-cell variants. T-cell clonality is detected if the T-cell immunophenotype is present. The prognosis is poor.

**Benner MF, et al:** Bone marrow examination has limited value in the staging of patients with an anaplastic large cell lymphoma first presenting in the skin: retrospective analysis of 107 patients. *Br J Dermatol* 2008; 159(5):1148–1151.

**Booken N, et al:** Clinical spectrum of primary cutaneous CD30-positive anaplastic large cell lymphoma: an analysis of the Mannheim Cutaneous Lymphoma Registry. *J Dtsch Dermatol Ges* 2012; 10(5):331–339.

**Fujita H, et al:** Primary cutaneous anaplastic large cell lymphoma successfully treated with low-dose oral methotrexate. *Eur J Dermatol* 2008; 18(3):360–361.

**Guitart J, et al:** Cutaneous  $\gamma\delta$  T-cell lymphomas: a spectrum of presentations with overlap with other cytotoxic lymphomas. *Am J Surg Pathol* 2012; 36(11):1656–1665.

**Massone C, et al:** The morphologic spectrum of primary cutaneous anaplastic large T-cell lymphoma: a histopathologic study on 66 biopsy specimens from 47 patients with report of rare variants. *J Cutan Pathol* 2008; 35(1):46–53.

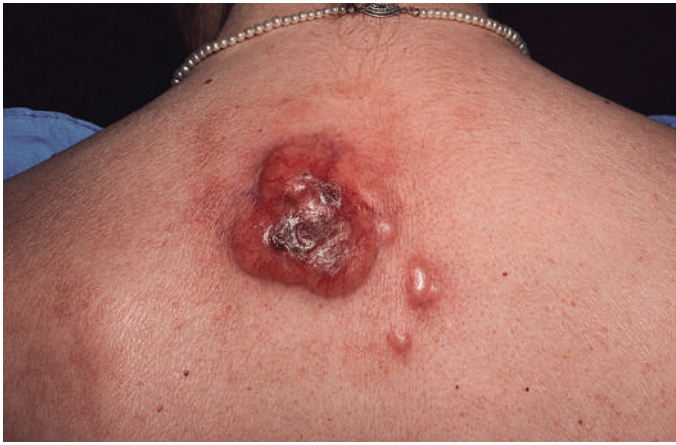**Parveen Z, et al:** Subcutaneous panniculitis-like T-cell lymphoma: redefinition of diagnostic criteria in the recent World Health Organization–European Organization for Research and Treatment of Cancer classification for cutaneous lymphomas. *Arch Pathol Lab Med* 2009; 133(2):303–308.

**Xing X, Feldman AL.** Anaplastic large cell lymphomas: ALK positive, ALK negative, and primary cutaneous. *Adv Anat Pathol* 2015; 22(1):29–49.

### Adult T-cell leukemia/lymphoma

Infection with human lymphotropic virus type 1 (HTLV-1) may lead to acute T-cell leukemia/lymphoma (ATL) in 0.01–0.02% of infected persons. This virus is endemic in Japan, Southeast Asia, the Caribbean region, Latin America, and equatorial Africa. ATL usually has an acute onset, with leukocytosis, lymphadenopathy, and HOTS (hypercalcemia, osteolytic bone lesions, T-cell leukemia, and skin lesions). Lesions resemble mycosis fungoides, except that patches are uncommon, and plaques and nodules predominate. Histologically, the skin lesions contain lichenoid infiltrates of medium-sized lymphocytes with convoluted nuclei. Epidermotropism and





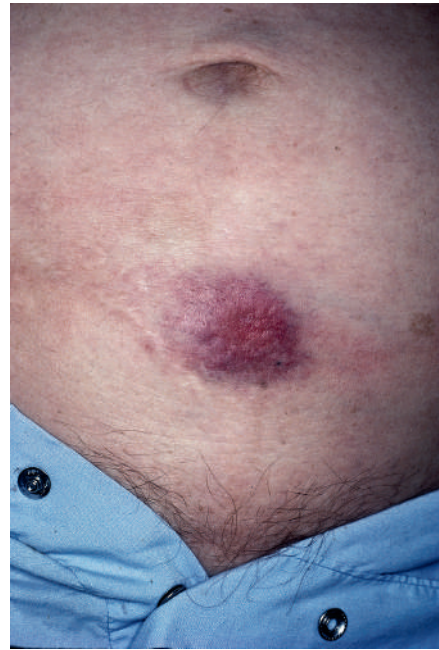**Fig. 32-14** Lymphoma, B-cell.

involvement around and within adnexa occur. Granuloma formation may occur in the dermis. ATL cells are usually CD4+/CD7- and show T-cell gene rearrangements.

## CUTANEOUS B-CELL LYMPHOMA

Primary cutaneous B-cell lymphomas (Fig. 32-14) occur less often than cutaneous T-cell lymphomas; 25% of cases of primary cutaneous non-Hodgkin lymphomas are B cell in origin). Although the morphologic appearance of the malignant lymphocytes composing these primary cutaneous lymphomas is identical to lymphomas based in lymph nodes, they have a distinctly different clinical behavior and immunophenotypic profiles. This renders the classification systems based on lymph node histology of limited benefit in the diagnosis of primary cutaneous B-cell lymphomas. More simplified schemes have thus been proposed that apply to primary cutaneous lymphomas only. Most entities classified by the European Organization for Research and Treatment of Cancer (EORTC) have now been accepted in the WHO classification, but some remain provisional entities.

The great majority of primary cutaneous B-cell lymphomas are composed of cells with the morphologic characteristics of the B cells normally found in the marginal zone or germinal centers of lymph nodes. Classification schemes used primarily for lymph node-based lymphomas divide these lymphomas into multiple types based on histomorphology. Secondary cutaneous involvement can occur with all forms of B-cell lymphoma based primarily in lymph node or other sites. The clinical features are similar to those of primary cutaneous lymphoma, with violaceous papules or nodules (Fig. 32-15). Typically, the histologic structure of secondary lesions in the skin is similar to that of the lymphoma at the site of origin, usually the lymph nodes. The pattern in the skin, however, may not be sufficient to classify the lymphoma, making lymph node biopsy necessary in most patients. In secondary cutaneous B-cell lymphomas, the prognosis is generally poor. It is therefore critical to evaluate any patient suspected of having primary cutaneous B-cell lymphoma to exclude involvement at another site. Radiation is typically used for indolent forms of cutaneous B-cell lymphoma, but excision, rituximab, intralesional corticosteroids, and systemic chemotherapy have also been used in select cases. Higher-grade lymphomas, such as leg-type lymphoma, primary cutaneous follicle center lymphoma occurring on the leg, and precursor B-cell lymphoblastic lymphoma, are typically treated with systemic chemotherapy regimens, including combinations of anthracycline-containing chemotherapies and rituximab.



**Fig. 32-15** Secondary cutaneous B-cell lymphoma.

## Primary cutaneous marginal-zone lymphoma (PCMZL, MALT-type lymphoma, including primary cutaneous immunocytoma)

These lymphomas present as solitary or multiple dermal or subcutaneous nodules or tumors, primarily on the upper part of the body, trunk, or extremities. Widespread lesions suggest secondary skin involvement by systemic lymphoma. Women are affected by PCMZL more than men. Immunocytomas are associated with European *Borrelia* and occur as tense, shiny, pink to red nodules on the legs of older patients.

Histologically, the infiltrate may be nodular or diffuse. The neoplastic cells are medium-sized gray cells with predominantly cleaved nuclei that proliferate within the space surrounding and between benign germinal centers. Plasma cells are typically present and may be numerous. Light-chain restriction is easiest to identify in the plasma cell population by means of in situ hybridization. Immunophenotypically, the cells are CD20+, CD79+, and BCL-2+. Clonal immunoglobulin gene rearrangements can usually be demonstrated, and light-chain restriction can typically be demonstrated in plasma cells at the periphery of the lymphoid aggregates. The prognosis is excellent, with 5-year survival close to 100%. Local radiation therapy, or excision if lesions are few, is recommended. In some *Borrelia*-endemic areas in Europe, immunocytomas are common. They present on the legs of older men and are characterized by sheets of plasmacytoid B cells with Dutcher bodies. Treatment is similar to other forms of PCMZL.

## Primary cutaneous follicle center cell lymphoma (PCFCCL, diffuse and follicular types)

Clinically, most patients with PCFCCL present with single or multiple papules, plaques, or nodules, with surrounding erythema, in one anatomic region. About two thirds of cases present on the trunk, about 20% on the head and neck (vast majority on scalp), and about 15% on the leg. PCFCCLs are more common in men than women. Males outnumber females 4:1 in trunk lesions, whereas women disproportionately have head and leg lesions. Untreated, the lesions gradually increase in size and number, but extracutaneous involvement is

uncommon. The prognosis is excellent; 5-year survival with treatment approaches 100%. Secondary cutaneous involvement of systemic follicular lymphoma has a poor prognosis.

Histologically, the neoplasm is composed of centroblasts (uncleaved nuclei with peripheral nucleolus) and centrocytes (cleaved nuclei with peripheral nucleolus). The diffuse form is more common than the follicular form. In the diffuse form, the neoplastic cells retain the normal BCL-6+ phenotype of a follicle center cell, but typically lose expression of CD10. The follicular growth pattern is composed of irregularly shaped, asymmetric follicles that crowd together like pieces of a jigsaw puzzle. The cells typically stain for both BCL-6 and CD10, and these stains demonstrate neoplastic cells that have “wandered” beyond the confines of the follicle center. Elongated “carrot-shaped” nuclei are often present within the follicular centers, and CD21 staining shows defects in the net of DCs in the follicle center.

In early lesions, the neoplastic cells are smaller, and a substantial portion of normal T cells surround and mix with the neoplastic B cells. Over time, the neoplastic B cells become a more predominant portion of the infiltrate, the neoplastic cells are larger, and tumor-infiltrating T cells diminish. Immunophenotypically, the neoplastic cells stain with B-cell markers (CD20), and clonal rearrangement of the immunoglobulin gene can be demonstrated by polymerase chain reaction (PCR). The absence of expression of BCL-2, lack of adenopathy, and lack of involvement of the bone marrow help to exclude nodal follicle center lymphoma. Nodal follicular lymphoma usually expresses BCL-2, and there is a t(14:18) translocation in more than 80% of cases. The translocation and BCL-2 expression are usually lacking in primary cutaneous follicular lymphoma.

Radiation therapy totaling 30–40 Gy and including all erythematous skin and a 2-cm margin of normal skin is very effective for lesions of the head and trunk. A combination of intralesional IFN alfa, 5-MU every 4 weeks, and topical bexarotene gel 1% twice has also been used. Anthracycline-based chemotherapy or rituximab may be used for relapses, as well as for more aggressive lesions of the leg. In Europe, a few cases of PCFCL are associated with *Borrelia* infection and may arise in lesions of acrodermatitis chronica atropicans.

### Diffuse large B-cell lymphoma (primary cutaneous large B-cell lymphoma)

Clinically, lesions present as solitary or localized red or purple papules, nodules, or plaques. In general, solitary or localized lesions are typical of primary disease, and widespread lesions suggest secondary cutaneous involvement of primary nodal lymphoma. Lesions on the head and neck have an excellent prognosis. Lesions on the leg have a poorer prognosis, with a 5-year survival of about 50%, and are considered in some classifications as a separate entity (Fig. 32-16).

The diffuse large B-cell lymphoma is composed of large lymphocytes. Tumors consisting of sheets of centroblasts and immunoblasts (noncleaved nuclei with peripheral or central nucleoli, respectively) should be stained for MUM1, a marker for leg-type lymphoma. If the tumor cells express MUM1, the prognosis is worse. Immunophenotypically, cells usually express CD20 and monotypic immunoglobulin, and leg-type lymphoma expresses BCL-2. Secondary cutaneous involvement with nodal large B-cell lymphoma is also associated with a poor prognosis.

Richter transformation of chronic lymphocytic leukemia (CLL) into a high-grade lymphoma occurs in 3–10% of CLL patients. Its onset is often heralded by fever, night sweats, and weight loss. The lymphoma usually arises in the lymph nodes

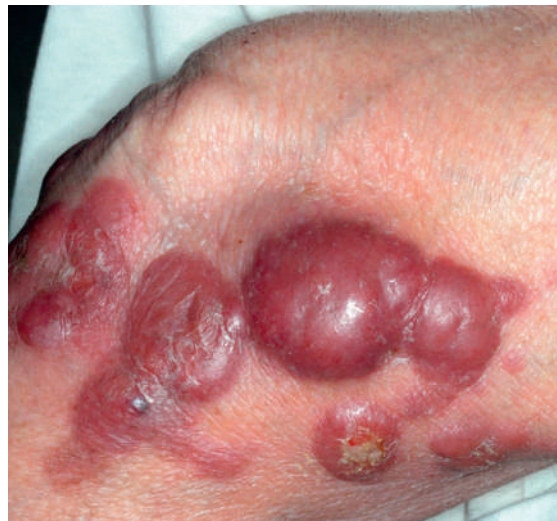

Fig. 32-16 B-cell lymphoma of the leg. (Courtesy of Dr. Misha Rosenbach.)

or bone marrow, but can also present in the skin or internal organs.

### Intravascular large B-cell lymphoma (malignant “angioendotheliomatosis,” angiotropic large cell lymphoma)

Clinically, these patients present with variable cutaneous morphologies, often subtle and nonspecific. Some intravascular large B-cell lymphomas resemble classic lymphoma with violaceous papules or nodules. Others more closely resemble intravascular thrombotic disorders, with livedo reticularis-like lesions or telangiectatic patches. Sclerotic plaques may also occur. Even normal skin can show the characteristic changes on biopsy. Patients often present with fever of unknown origin. CNS symptoms are prominent, with progressive dementia or multiple cerebrovascular ischemic events that may precede skin findings by many months.

Histologically, the features are characteristic and diagnostic. Dermal and subcutaneous vessels are dilated and filled with large neoplastic cells. Focal extravascular accumulations may be seen. The neoplastic cells are CD20+ and CD79a+ and monotypic for immunoglobulin. Clonal Ig gene rearrangements may be detected. Despite the large number of intravascular cells in the skin and other affected organs, the peripheral blood smears and bone marrow may be normal histologically. The prognosis is very poor, and multiagent chemotherapy is recommended. Rare cases of intravascular lymphoma may be of T-cell origin, but the behavior is similar to that of the B-cell variant.

**Ahearn IM, et al:** Primary cutaneous follicle-center lymphoma. *Dermatol Online J* 2014; 20(12).

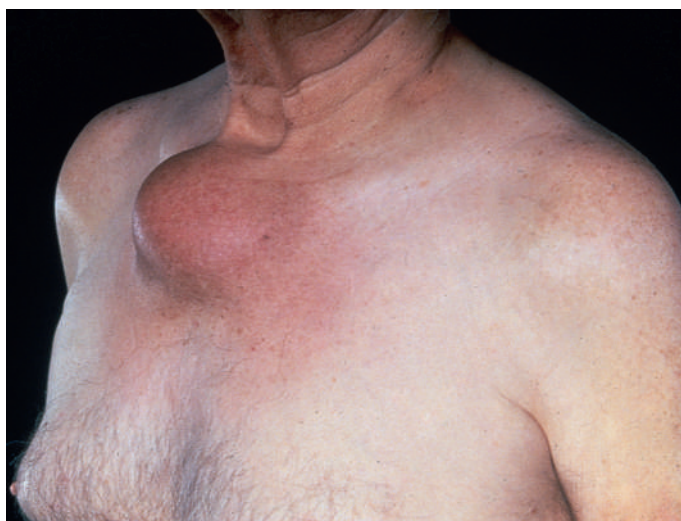**Grange F, et al:** Primary cutaneous diffuse large B-cell lymphoma, leg type: clinicopathologic features and prognostic analysis in 60 cases. *Arch Dermatol* 2007; 143(9):1144–1150.

**Servitje O, et al:** Primary cutaneous marginal zone B-cell lymphoma: response to treatment and disease-free survival in a series of 137 patients. *J Am Acad Dermatol* 2013; 69(3):357–365.

**Suárez AL, et al:** Primary cutaneous B-cell lymphomas. Part I. Clinical features, diagnosis, and classification. *J Am Acad Dermatol* 2013; 69(3):329.e1–329.e13.

**Suárez AL, et al:** Primary cutaneous B-cell lymphomas. Part II. Therapy and future directions. *J Am Acad Dermatol* 2013; 69(3):343.e1–343.e11.





**Fig. 32-17** Plasmacytoma extending from the sternum.

**Wilcox RA:** Cutaneous B-cell lymphomas: 2015 update on diagnosis, risk-stratification, and management. *Am J Hematol* 2015; 90(1):73–76.

### Plasmacytoma (multiple myeloma)

True cutaneous plasmacytomas are seen most often in the setting of myeloma, although they are rare, occurring in only 2% of myeloma patients. These cases are called secondary cutaneous plasmacytoma. Plasmacytomas may also occur by direct extension from an underlying bone lesion (Fig. 32-17). They may appear at sites of trauma, such as biopsies or intravenous catheters (inflammatory oncotaxis). Most often, secondary cutaneous plasmacytomas occur in the patient with advanced myeloma, and the prognosis is poor. Less often, the skin lesions may be the initial clinical finding, leading to the diagnosis of myeloma. Many cutaneous lesions formerly classified as primary cutaneous plasmacytomas are now classified as plasma cell-rich primary cutaneous marginal-zone lymphoma.

Anetoderma may show plasmacytoma on biopsy. A rare manifestation of a solitary plasmacytoma of bone is an overlying erythematous skin patch that may be 10 cm or more in diameter. The chest is the most common location. Lymphadenopathy is present, and some of the patients have or develop POEMS syndrome (polyneuropathy, organomegaly, endocrinopathy, monoclonal protein, skin changes). This syndrome has been called adenopathy and extensive skin patch overlying a plasmacytoma (AESOP).

Histologically, plasmacytomas are nodular and diffuse collections of plasma cells with varying degrees of pleomorphism and atypia. The degree of atypia may predict prognosis. The cells are monotypic for Ig production and produce the same light chain as the myeloma. The immunoglobulin produced is most often IgG or IgA, and rarely IgD or IgE. CD79 is positive, but CD19 and CD20 are negative.

In addition to plasmacytomas, patients with myeloma may develop a vast array of cutaneous complications, including normolipemic plane xanthomas, amyloidosis, vasculitis, and calcinosis cutis. An unusual but characteristic skin finding in myeloma is multiple follicular spicules of the nose, forehead, cheeks, and chin. They are yellowish and firm to palpation and can be removed without bleeding. Numerous small ulcerations may occur on the trunk. Both the spicules and the ulcers contain an eosinophilic material composed of the abnormal

monoclonal protein produced by the malignant cells. The spicules are not made of keratin. Clinically similar cutaneous spicules composed of keratin can be seen in vitamin A deficiency, chronic renal failure, acquired immunodeficiency syndrome (AIDS), Crohn's disease, and other malignant diseases.

The appropriate treatment of plasmacytomas is determined by the presence or absence of associated systemic disease. Solitary or paucilesional primary cutaneous plasmacytomas have been treated successfully with local surgery and radiation therapy. Systemic chemotherapy may be required if these modalities fail. The treatment for secondary plasmacytomas and for patients with numerous primary cutaneous plasmacytomas is chemotherapy.

### Cutaneous and systemic plasmacytosis

Cutaneous plasmacytosis and systemic plasmacytosis occur primarily in Asians, slightly favoring men. They typically occur between ages 20 and 55. These conditions are characterized by polyclonal proliferations of plasma cells and hyperglobulinemia and were originally considered variants of Castleman's disease. Cutaneous plasmacytosis affects only the skin, but patients may have lymphadenopathy and systemic symptoms of fever and malaise. Systemic plasmacytosis usually involves two or more organ systems, in addition to the skin, lung, bone marrow, and liver. Dyspnea may result from interstitial pneumonia. Infrequently, cases of systemic plasmacytosis may progress to lymphoma. The course is chronic and benign, and response to various cytostatic and immunosuppressive treatments has been poor. PUVA and topical tacrolimus have been reported to be effective for skin lesions. The skin lesions in cutaneous and systemic plasmacytosis are identical, consisting of multiple brown-red plaques, mostly of the central upper trunk but also the face. The lesions, 1–3 cm in diameter, are often considered simply as postinflammatory hyperpigmentation until they are palpated. Histologically, they show a dense perivascular infiltrate of mature plasma cells, which stain for both  $\kappa$  and  $\lambda$  light chains (polyclonality). The disease may be a manifestation of IgG4-related disease, a clinical entity characterized by elevated levels of serum IgG4 and tissue infiltration of IgG4+ plasma cells in various organ systems. Elevated IL-6 has been reported in some patients.

**Honda R, et al:** Cutaneous plasmacytosis: report of 6 cases with or without systemic involvement. *J Am Acad Dermatol* 2013; 68(6):978–985.

**Yamaguchi H, et al:** Cutaneous plasmacytosis as a skin manifestation of IgG4-related disease. *Eur J Dermatol* 2013; 23(4):560–562.

### IgG4-related skin disease

IgG4-related skin disease presents with mass-forming lymphoplasmacytic cutaneous infiltrates, often with eosinophils. IgG4 is elevated in serum, and many IgG4+ cells can be identified in the affected tissue. These findings are not specific for the disease, however, and clinicopathologic correlation is essential. Erythematous and itchy plaques and nodules typically involve the head and neck, particularly the periauricular region, cheeks, and jawline. Systemic infiltrates may involve the lymph nodes, lacrimal and salivary glands, or parenchymal organs such as the kidney and pancreas. Retroperitoneal fibrosis may occur. Accumulated data suggest no association with systemic malignancy. Randomized controlled trials (RCTs) are lacking, but the associated autoimmune pancreatitis typically responds to oral corticosteroids, and both rituximab and dapsone have been reported as effective in individual patients.

**Hirano K, et al:** Incidence of malignancies in patients with IgG4-related disease. *Intern Med* 2014; 53(3):171–176.

**Lehman JS, et al:** Increased immunoglobulin (Ig) G4-positive plasma cell density and IgG4/IgG ratio are not specific for IgG4-related disease in the skin. *Am J Clin Pathol* 2014; 141(2):234–238.

**Sato Y, et al:** Clinicopathologic analysis of IgG4-related skin disease. *Mod Pathol* 2013; 26(4):523–532.

## HODGKIN DISEASE

The vast majority of reports of cutaneous Hodgkin disease actually represent type A lymphomatoid papulosis. These two diseases have a considerable number of overlapping features. The type A cells of LyP have similar morphology and share immunophenotypic markers with Reed-Sternberg cells. LyP can be seen in patients with Hodgkin disease. Primary cutaneous Hodgkin disease without nodal involvement is thus difficult to prove and is extremely rare, if it exists.

Most cases of Hodgkin disease of the skin usually originate in the lymph nodes, from which extension to the skin is either retrograde through the lymphatics or direct. Lesions present as papules or nodules, with or without ulceration. Lesions resembling scrofuloderma may occur. Miliary dissemination to the skin can occur in advanced disease.

Nonspecific cutaneous findings are common in patients with Hodgkin disease. Generalized, severe pruritus may precede other findings of Hodgkin disease by many months or may occur in patients with a known diagnosis. Secondary prurigo nodules and pigmentation may occur as a result of scratching. An evaluation for underlying lymphoma should be considered in any patient with severe itching, no primary skin lesions, and no other cause identified for the pruritus. Acquired ichthyosis, exfoliative dermatitis, and generalized and severe herpes zoster are other cutaneous findings in patients with Hodgkin disease.

**Introcaso CE, et al:** Cutaneous Hodgkin disease. *J Am Acad Dermatol* 2008; 58(2):295–298.

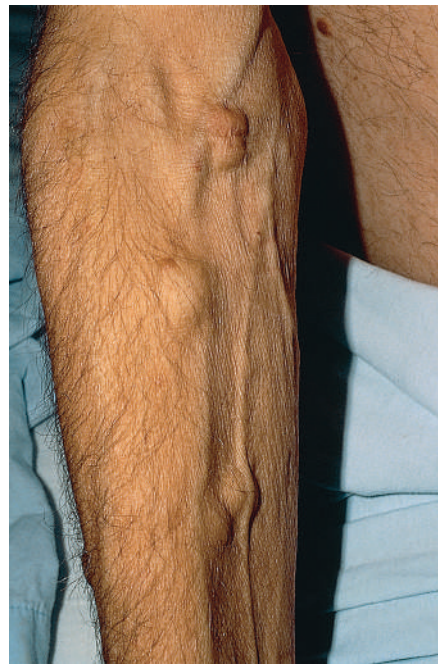
## MALIGNANT HISTIOCYTOSIS (HISTIOCYTIC MEDULLARY RETICULOSIS)

Most cases considered to be malignant histiocytosis in the past are now considered to be other forms of lymphoma or lymphomas with large components of reactive histiocytes. Very rare cases of true malignancies of histiocytes may still occur and can have cutaneous lesions, most characteristically erythematous nodules. Often, the bone marrow examination in these patients is initially normal, but cases are rapidly progressive and fatal, and the bone marrow becomes involved.

## LEUKEMIA CUTIS

### Clinical features

Cutaneous eruptions seen in patients with leukemia may be divided into specific lesions (leukemia cutis) and nonspecific lesions (reactive and infectious processes). Overall, about 30% of biopsies from patients with leukemia will show leukemia cutis. All forms of leukemia can be associated with cutaneous findings, but skin disease is more common in certain forms of leukemia. Myeloid leukemia with monocytic differentiation involves the skin more often than other types of myeloid leukemia. CD68 and lysozyme immunostains can be helpful in distinguishing this form of leukemia. Dermatologic manifesta-



**Fig. 32-18** Leukemia cutis.

tions are frequently seen in patients with acute myelogenous leukemia (AML) and myelodysplastic syndrome (MDS). AML includes types M1–M5. In AML and MDS patients, only about 25% of skin biopsies will show leukemia cutis, the remainder showing complications of the leukemia. These include infections, graft-versus-host disease, drug reactions, or the reactive conditions associated with leukemia sometimes referred to as leukemids. By contrast, in patients with acute lymphocytic leukemia (ALL), chronic myelogenous leukemia (CML), and chronic lymphocytic leukemia (CLL), about 50% of biopsies will show leukemia cutis. Lesion presentation may be subtle and may include macular erythema, hyperpigmentation, or morbilliform rash.

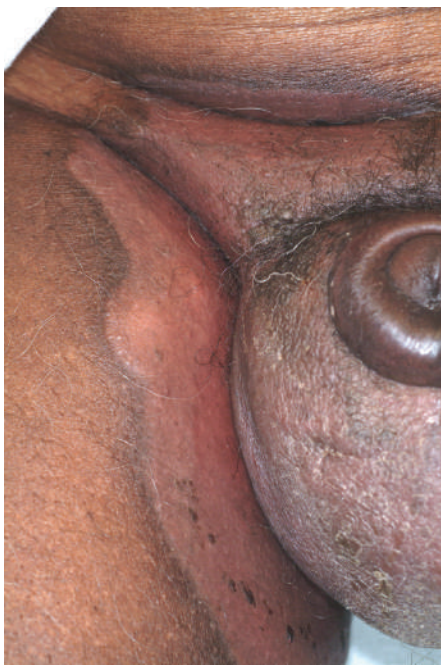### Specific eruptions

The most common morphology of leukemic infiltrations of the skin in all forms of leukemia is multiple papules or nodules (60% of cases) or infiltrated plaques (26%). These lesions are usually flesh colored, erythematous, or violaceous (plum colored) (Figs. 32-18 and 32-19). They are rubbery on palpation, and ulceration is uncommon. Extensive involvement of the face may lead to a leonine facies.

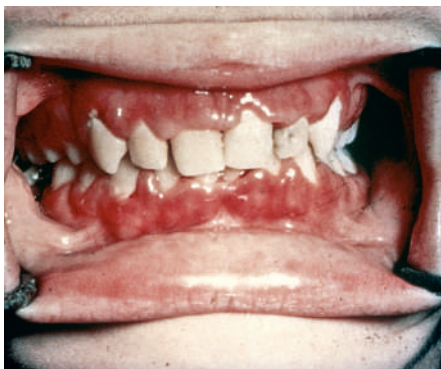Less common manifestations of leukemia cutis are subcutaneous nodules resembling erythema nodosum or panniculitis, arciform lesions (in juvenile CML), ecchymoses, palpable purpura, erythroderma, ulcerations (which may resemble pyoderma gangrenosum or venous stasis ulceration), and urticaria-like, urticaria pigmentosa-like (in ALL), and guttate psoriasis-like lesions. Rare manifestations are a lesion resembling Sister Mary Joseph nodule and cutaneous sarcoidal lesions. Myelogenous leukemia may be complicated by lesions resembling stasis dermatitis or chilblains. Gingival infiltration causing hypertrophy is common in, and relatively unique to, patients with acute myelomonocytic leukemia (Fig. 32-20).

Leukemia cutis most often occurs concomitant with or after the diagnosis of leukemia. The skin may also be a site of relapse of leukemia after chemotherapy, especially in patients who present with leukemia cutis. Infrequently, leukemia cutis may be identified while the bone marrow and peripheral blood are normal. These patients are classified as “aleukemic leukemia cutis” because they have normal bone marrow





**Fig. 32-19** Leukemia cutis.



**Fig. 32-20** Gingival involvement in leukemia.

evaluations and no circulating blasts. These cases are often misdiagnosed as cutaneous lymphomas and undertreated. They eventually relapse, with full-blown leukemia. The key to the diagnosis is a Leder stain, which will identify the atypical cells as myeloid. Systemic involvement occurs within 3 weeks to 20 months (average 6 months). Leukemia cutis is a poor prognostic finding in leukemia patients, with 90% having extramedullary involvement and 40% with meningeal infiltration.

The term congenital leukemia applies to cases appearing within the first 4–6 weeks of life. Leukemia cutis occurs in 25–30% of such cases, the vast majority being congenital myelogenous leukemia. The typical morphology is multiple, red or plum-colored nodules. In about 10% of patients with congenital leukemia cutis (or 3% of all cases of congenital leukemia), the skin involvement occurs while the bone marrow and peripheral blood are normal. Systemic involvement is virtually always identified in 5–16 weeks. Unlike in other forms of leukemia, cutaneous infiltration does not worsen prognosis in congenital leukemia. Congenital leukemia cutis has been complicated by disseminated linear calcinosis cutis. Early-onset aleukemic leukemia cutis can occasionally undergo spontaneous regression. One report involved a child with mastocytosis who also developed a leukemia clone with a t(5; 17)(q35; q12), nucleophosmin (NPM)–retinoic acid receptor- $\alpha$  (RARA) fusion gene.

## Granulocytic sarcoma (chloroma)

Granulocytic sarcomas are rare tumors of immature granulocytes. They occur in about 3% of patients with myelogenous leukemia. Granulocytic sarcoma is seen in four settings: in patients with known AML; in patients with CML or MDS as a sign of an impending blast crisis; in undiagnosed patients as the first sign of AML; or after BMT as the initial sign of relapse. Most lesions occur in the soft tissues, periosteum, or bone. Skin lesions represent 20–50% of reported cases. They may be solitary or multiple and appear as red, mahogany, or violaceous firm nodules with a predilection for the face, scalp, or trunk.

The name “chloroma” comes from the green color of fresh lesions, which can be enhanced by rubbing with alcohol; this is caused by the presence of myeloperoxidase. This appearance is variable, so the preferred term is now granulocytic sarcoma.

The diagnosis is not difficult if the diagnosis of leukemia has been established. Such patients are treated with appropriate chemotherapy. However, if the skin lesion is the initial manifestation of leukemia, and the blood and bone marrow are normal, the lesion may be misdiagnosed as a large cell lymphoma. The treatment of such patients is controversial, but most go on to develop AML within months, so chemotherapy is often given.

## Blastic plasmacytoid dendritic cell neoplasm (formerly blastic NK-cell lymphoma, CD4, CD56+ hematodermic neoplasm)

The majority of patients are men, with a mean age of about 60 years. All patients present with multiple, rapidly expanding plaques and/or nodules on noncontiguous sites. Lesions are characteristically purple in color. The course is aggressive in most patients, with rapid cutaneous relapse after chemotherapy and systemic involvement. Histologically, the cells infiltrate the dermis or subcutaneous fat, and the neoplastic cells tend to form in single file within dermal collagen. There is usually a grenz zone below the epidermis. The lymphoma cells are small/medium to large, blastic lymphocytes. Angiocentricity may be noted but is not prominent. Immunophenotyping is usually CD3–, CD4+/CD56+. MIB-1 shows a proliferation activity greater than 50%, and T-cell gene rearrangements are negative. A response to pralatrexate has been reported, but in general, results with radiation therapy and chemotherapy have been poor. Bone marrow transplantation (BMT) may play an important role in therapy.

## Hairy cell leukemia

Skin involvement is rare in hairy cell leukemia. Violaceous papules and nodules, which are the characteristic morphology of other forms of leukemia cutis, are extremely rare in hairy cell leukemia. Rather, a diffuse erythematous, nonpruritic eruption occurs, often in the setting of a systemic mycobacterial infection or a drug reaction. This may progress to erythroderma or a severe blistering eruption. Stopping the medication usually leads to resolution of the eruption. This is especially common in patients treated with 2-chlorodeoxyadenosine and allopurinol; the former treatment alone does not lead to these severe skin reactions, suggesting that the allopurinol is the cause. Patients with hairy cell leukemia also develop lesions of pustular vasculitis of the dorsal hands, a neutrophilic dermatitis closely related to bullous Sweet syndrome. This is sometimes termed a “vasculitis” in the oncology literature.

## Nonspecific conditions associated with leukemia (leukemids)

Leukemia and its treatment are associated with a series of conditions that may also be seen in patients without leukemia, but that are seen frequently enough in leukemic patients to be recognized as a complication of leukemia or its treatment.

When a dermatologist or dermatopathologist is consulted to evaluate a patient with leukemia and skin lesions, the differential diagnosis usually includes four groups of conditions: drug reactions, leukemia cutis, an infectious complication, and a reactive condition. Drug reactions include all forms of reactions but are usually erythema multiforme, morbilliform reactions, or acral erythema. Infections may present in many ways but are usually purpuric papules, pustules, or plaques, if they are caused by bacteria or fungi. Ulceration is typical. Herpes simplex and herpes zoster should be considered in all erosive, ulcerative, or vesicular lesions. The reactive conditions include a group of neutrophilic dermatoses with considerable clinical overlap (e.g., Sweet syndrome, pyoderma gangrenosum, neutrophilic hidradenitis, leukocytoclastic vasculitis). Transient acantholytic dermatosis and eosinophilic reactions resembling insect bites may occur, most often in patients with CLL, in whom a pruritic and unremitting exfoliative erythroderma is a unique feature. A granulomatous rosacea-like leukemid and cutaneous reactive angiomatosis have also been described in patients with leukemia.

Evaluation of these patients must be complete, and extensive diagnostic tests and empiric treatment are often pursued until the diagnosis is established. In the acute setting, a clinical diagnosis is made based on morphology. Possible infectious complications are covered by appropriate antibiotics, especially if the patient is febrile or the diagnosis of a herpesvirus infection is made. A skin biopsy is often diagnostic. For herpes infections, a PCR or direct fluorescent antibody test should be done because the results are virus specific and rapid, so appropriate treatment can be given quickly. Once the diagnostic tests return, the therapy is tailored to the appropriate condition. Except for herpes infections, a skin biopsy is often required. If infection is considered, a portion of the biopsy should be sent for culture.

**Blattner C, et al:** Initial presentation of acute myelogenous leukemia in the infiltrate underlying an actinic keratosis. *Indian Dermatol Online J* 2014; 5(4):508–509.

**Campbell SM, et al:** CD4+ CD56+ hematodermic neoplasm and plasmacytoid dendritic cell tumor: case report and review of the literature. *Cutis* 2012; 89(6):278–283.

**Cho-Vega JH, et al:** Leukemia cutis. *Am J Clin Pathol* 2008; 129(1):130–142.

**Cibull TL, et al:** Myeloid leukemia cutis: a histologic and immunohistochemical review. *J Cutan Pathol* 2008; 35(2):180–185.

**Mathew RA, et al:** Cutaneous manifestations in CMML: indication of disease acceleration or transformation to AML and review of the literature. *Leuk Res* 2012; 36(1):72–80.

## CUTANEOUS MYELOFIBROSIS

Myelofibrosis is a chronic myeloproliferative disorder characterized by a clonal proliferation of defective multipotential stem cells in the bone marrow. Overproduction and premature death of atypical megakaryocytes in the bone marrow produce excess amounts of platelet-derived growth factor (PDGF), a potent stimulus for fibroblast proliferation and collagen production. Extramedullary hematopoiesis (EMH) is a hallmark of myelofibrosis. Myelofibrosis may coexist with signs of mastocytosis. Blast cells and committed stem cells

escape the marrow in large numbers, enter the circulation, and form tumors of the same atypical clone in other organs, especially the spleen, liver, and lymph nodes. EMH in the skin of neonates is usually caused by intrauterine viral infections. In adults, cutaneous EMH has rarely been reported, characteristically associated with myelofibrosis. Skin lesions are dermal and subcutaneous nodules. Histologically, the cutaneous lesions are composed of dermal and subcutaneous infiltrates of mature and immature myeloid cells, erythroid precursors (in only half of cases), and megakaryocytic cells (which may predominate). There is marked production of collagen fibers in the cutaneous lesions by the mechanism previously described. Myelofibrosis must be distinguished from CML, since both have elevated white blood cell counts with immature myeloid forms, defective platelet production, and marrow fibrosis. Both may terminate in blast crisis, and myelofibrosis may rarely convert to CML. CML is associated with the Philadelphia chromosome, whereas chromosomal abnormalities occur in 40% of myelofibrosis cases on various chromosomes.

**Miyata T, et al:** Cutaneous extramedullary hematopoiesis in a patient with idiopathic myelofibrosis. *J Dermatol* 2008; 35(7):456–461.

## HYPEREOSINOPHILIC SYNDROME

Idiopathic hypereosinophilic syndrome (HES) is defined as eosinophilia with more than 1500 eosinophils/mm<sup>3</sup> for more than 6 months, with some evidence of parenchymal organ involvement; there must also be no apparent underlying disease to explain the hypereosinophilia and usually no evidence of vasculitis. About 90% of patients reported have been men, mostly between ages 20 and 50. Childhood cases are rare. Presenting symptoms include fever (12%), cough (24%), fatigue, malaise, muscle pains, and skin eruptions. Two pathogenic variants of HES have been defined: m-HES (myeloproliferative HES) and l-HES (lymphocytic HES). Patients with m-HES are overwhelmingly males, and anemia, thrombocytopenia, elevated serum B<sub>12</sub> levels, mucosal ulcerations, splenomegaly, and endomyocardial fibrosis are the clinical features. Isolated Loeffler's endocarditis has been reported as a presenting sign. Eosinophil clonality and interstitial deletion on 4q12 result in fusions of *FIP1qL1* and *PDGFRa* genes, forming an F/P fusion protein displaying constitutive activity, are pathogenically related to m-HES cases. Increased mast cells and elevated tryptase levels with myeloid precursors in peripheral blood and myelofibrosis may be found, suggesting that mast cells may be pathogenically related to this form of HES. Leukemia may develop in patients with m-HES patients. The l-HES variant has been associated with circulating T-cell clones of CD4+ phenotype, which secrete Th2 cytokines, especially IL-5. Women and men are equally affected by l-HES, and cutaneous manifestations are observed in virtually all patients. Skin manifestations include urticaria, angioedema, pruritus, eczema, and erythroderma. Splinter hemorrhages and necrotic skin lesions are seen in some HES patients as well. Endomyocardial fibrosis is uncommon, but pulmonary and digestive symptoms are common. Some cases of l-HES are clinically identical to Gleich syndrome or episodic angioedema and hypereosinophilia. Over time, some patients with l-HES will develop lymphoma.

Treatment is determined by classifying cases appropriately as m-HES or l-HES. Patients with m-HES may be treated with corticosteroids, hydroxyurea, IFN alfa, and chemotherapeutic agents. Imatinib mesylate (Gleevec, 100 mg/day or less) can be highly effective for m-HES patients with the F/P mutation because it inhibits the phosphorylation of the F/P protein and leads to apoptosis of cells producing this protein. Imatinib has



rapidly become first-choice treatment for this subset of patients. Response may be dramatic, with eosinophil levels improving, and skin and GI manifestations clearing in days. For I-HES patients, systemic glucocorticoids, and perhaps IFN alfa with glucocorticoids, can be used and are usually effective. Monoclonal anti-IL-5 antibody, cyclosporine, anti-IL-2R $\alpha$ , infliximab, and CTLA-4-Ig may be treatment options. If lymphoma supervenes, intense chemotherapy and allogeneic stem cell transplantation can be considered.

**Dahabreh IJ, et al:** Management of hypereosinophilic syndrome: a prospective study in the era of molecular genetics. *Medicine (Baltimore)* 2007; 86(6):344–354.

**Lefèvre G, et al [French Eosinophil Network]:** The lymphoid variant of hypereosinophilic syndrome: study of 21 patients with CD3-CD4+ aberrant T-cell phenotype. *Medicine (Baltimore)* 2014; 93(17):255–266.

**Plötz SG, et al:** Clinical overview of cutaneous features in hypereosinophilic syndrome. *Curr Allergy Asthma Rep* 2012; 12(2):85–98.

**Taverna JA, et al:** Infliximab as a therapy for idiopathic hypereosinophilic syndrome. *Arch Dermatol* 2007; 143(9):1110–1112.

## ANGIOIMMUNOBLASTIC T-CELL LYMPHOMA (ANGIOIMMUNOBLASTIC LYMPHADENOPATHY WITH DYSPROTEINEMIA)

Angioimmunoblastic lymphoma is an uncommon lymphoproliferative disorder. Patients are middle-aged or elderly and present with fever (72%), weight loss (58%), hepatomegaly (60%), polyclonal hyperglobulinemia (65%), and generalized adenopathy (87%). Pruritus occurs in 44% and a rash in 46%. The skin eruption is usually morbilliform in character, resembling an exanthem or a drug reaction. Petechial, purpuric, nodular, ulcerative, and erythrodermic eruptions have also been reported and may mimic infection. In about 30% of cases, the eruption is associated with the ingestion of a medication. The eruptions usually resolve with oral corticosteroids, misleading the clinician into believing that the eruption was benign. Reversible myelofibrosis has been described. Recent evidence suggests that the neoplastic cells are derived from germinal center Th cells because they express genes unique to this population, including programmed death-1 (*PD-1*) and *CXCL13*.

Histopathologically, there is a patchy and perivascular dermal infiltrate of various types of lymphoid cells, plasma cells, histiocytes (enough rarely to give a “granulomatous” appearance), and eosinophils. The lymphoid cells are usually Th cells (CD4+). Some portion of the lymphoid cells is atypical in most cases, suggesting the diagnosis. Blood vessels are increased and the endothelial cells are prominent, often cuboidal. Unfortunately, these changes may not be adequate to confirm the diagnosis. However, clonal T-cell gene rearrangement is found in three quarters of these skin lesions and is the same as the clone in the lymph node. Immunophenotyping of the skin lesions does not give a consistent pattern. At times, the skin lesions will show leukocytoclastic vasculitis on biopsy. Lymph node biopsy is usually required to confirm the diagnosis and exclude progression to lymphoma.

Angioimmunoblastic lymphadenopathy with dysproteinemia (AILD) appears to develop in a stepwise manner. Initially, there is an immune response to an unknown antigen. This immune reaction persists, leading to oligoclonal T-cell proliferation. Monoclonal evolution may occur, eventuating in lymphoma (angioimmunoblastic lymphoma, AILD-L). These are usually T-cell lymphomas, but B-cell lymphomas can also occur. In the case of AILD-L, skin lesions may contain the neoplastic cells (secondary lymphoma cutis). In up to 50% of cases, multiple unrelated neoplastic cell clones have been

identified. Clones identified in the skin may be different from clones found in lymph node. Trisomy 3 or 5 or an extra X chromosome may be found. AILD is an aggressive disease, with mortality of 48–72% in various series (average survival 11–60 months). The cause of death is usually infection. Epstein-Barr virus and HHV-6 and HHV-8 have been implicated in AILD.

Treatment of AILD has included systemic corticosteroids, methotrexate plus prednisone, combination chemotherapy, fludarabine, 2-chlorodeoxyadenosine, IFN alfa, and cyclosporine. Early treatment with systemic steroids during an oligoclonal or prelymphomatous stage may induce a long-lasting remission. Asymptomatic patients may not be treated initially but must be watched very closely. More aggressive chemotherapy achieves better remission. Nonetheless, recurrence rates are high, and average survival is 1–3 years.

**Balaraman B, et al:** Evaluation of cutaneous angioimmunoblastic T-cell lymphoma. *J Am Acad Dermatol* 2011; 65(4):855–862.

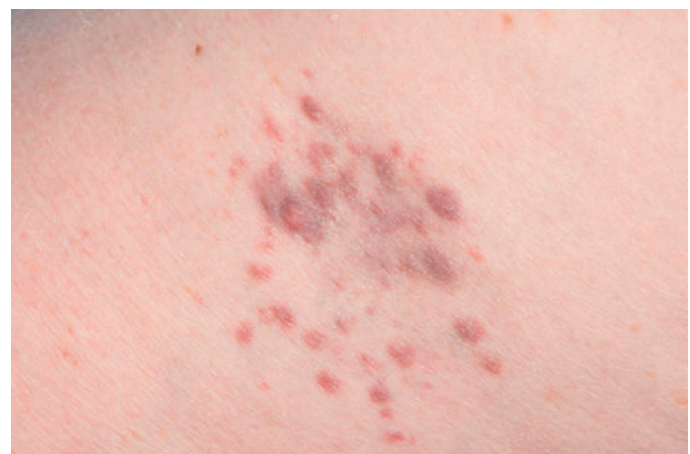**Chaoui D, et al:** Bortezomib, lenalidomide, and dexamethasone (VRD) combination as salvage therapy in refractory angioimmunoblastic T cell lymphoma. *Br J Haematol* 2014; 164(5):750–752.

**Federico M, et al:** Clinicopathologic characteristics of angioimmunoblastic T-cell lymphoma: analysis of the International Peripheral T-cell Lymphoma Project. *J Clin Oncol* 2013; 31(2):240–246.

**Shah ZH, et al:** Monoclonality and oligoclonality of T cell receptor beta gene in angioimmunoblastic T cell lymphoma. *J Clin Pathol* 2009; 62(2):177–181.

## SINUS HISTIOCYTOSIS WITH MASSIVE LYMPHADENOPATHY (ROSAI-DORFMAN DISEASE)

Sinus histiocytosis with massive lymphadenopathy (SHML), or Rosai-Dorfman disease, usually appears in patients in the first or second decade of life as a febrile illness accompanied by massive cervical (and often other) lymphadenopathy, polyclonal hyperglobulinemia, leukocytosis, anemia, and elevated erythrocyte sedimentation rate. Males and black persons are especially susceptible. Extranodal involvement occurs in 40% of cases, with skin being the most common site. About 10% of patients with SHML have skin lesions, and 3% have disease detectable only in the skin. The terms cutaneous sinus histiocytosis and cutaneous Rosai-Dorfman disease have been applied to these patients. Skin lesions consist of isolated or disseminated, yellow-brown papules, pustules, or nodules (Fig. 32-21) or macular erythema. Large annular lesions, resembling granuloma annulare, may occur. Most patients with cutaneous Rosai-Dorfman disease are older (40–60).



**Fig. 32-21** Rosai-Dorfman disease. (Courtesy of Dr. Ellen Kim.)

Histologically, there is a superficial and deep perivascular infiltrate of lymphocytes and plasma cells. Nodular and diffuse infiltration of the dermis by large, foamy histiocytes is present. An important diagnostic feature is the finding of intact lymphocytes (and less often plasma cells) in the cytoplasm of the histiocytic cells; this is called emperipolesis. Foamy histiocytes may be seen in dermal lymphatic channels. The cutaneous histology in some cases may be very nonspecific, except for the finding of emperipolesis, and only on evaluation of lymph node or other organ involvement does the diagnosis become clear. Immunohistochemistry and electron microscopy may be very useful, because the infiltrating cells are positive for CD4, factor XIIIa, and S-100 but do not contain Birbeck granules.

The cause of SHML is unknown, but numerous reports have identified HHV-6 in involved lymph nodes. The condition usually clears spontaneously, so no treatment is required. Numerous agents have been used therapeutically, with variable success, but are indicated only if the condition puts the patient at risk for death or a significant complication (usually by compressing a vital organ). Treatments have included radiation, systemic corticosteroids, and thalidomide. Single-agent and multiagent chemotherapy is met with mixed to poor response. To treat skin lesions, cryotherapy, topical corticosteroids, acitretin, and intralesional corticosteroids may be tried.

**Bunick CG, et al:** Cutaneous Rosai-Dorfman disease of the right ear responsive to radiotherapy. *J Am Acad Dermatol* 2012; 67(5):e225–e226.

**Fumerton R, et al:** Refractory cutaneous Rosai-Dorfman disease responsive to cryotherapy. *Cutis* 2011; 87(6):296–299.

**Kutlubay Z, et al:** Rosai-Dorfman disease: a case report with nodal and cutaneous involvement and review of the literature. *Am J Dermatopathol* 2014; 36(4):353–357.

**Sun NZ, et al:** Cutaneous Rosai-Dorfman disease successfully treated with low-dose methotrexate. *JAMA Dermatol* 2014; 150(7):787–788.

## POLYCYTHEMIA VERA (ERYTHREMIA)

Polycythemia vera (PCV) is characterized by an absolute increase of circulating red blood cells, with a hematocrit level of 55–80%. Leukocyte and platelet counts are also increased. The skin changes are characteristic. The skin tends to be red, especially on the face, neck, and acral areas. The mucous membranes are engorged and bluish. The phrase “red as a rose in summer and indigo blue in winter” has been ascribed to Osler in describing PCV. Telangiectases, bleeding gums, and epistaxis are frequently encountered. Cyanosis, purpura, petechiae, hemosiderosis, rosacea, and koilonychia may also be present.

In 50% of patients with PCV, aquagenic pruritus occurs. In about two-thirds, this is of limited severity and does not require treatment. The pruritus is typically triggered after a bath or shower, and the feeling induced may be itching, burning, or stinging. It usually lasts 30–60 min and is independent of the

water temperature. Pruritus unassociated with water exposure may also occur. There is a concurrent elevation of blood and skin histamine. Pruritus is present in about 20% of patients at presentation and develops in the remaining 30% over the course of their disease. Patients with pruritus have lower mean corpuscular volumes and higher leukocyte counts. Some have suggested that iron deficiency plays a role in PCV-associated pruritus, so a ferritin level and a trial of iron therapy may be indicated. Platelet counts are no different between PCV patients who itch and those who do not.

The treatment of PCV-associated pruritus may be difficult. Initial therapy would include first- or second-generation H1 antihistamines. Hydroxyzine was reported as the most effective antihistamine by a group of PCV patients. H2 blockers can be added. Narrow-band UVB therapy has been reported to be effective in 80% of patients. Topical therapy is of limited benefit, but paroxetine (Paxil), 20–60 mg/day, may be dramatically effective. Phlebotomy may be useful in patients with elevated hematocrit, and imatinib mesylate appears effective in many patients.

**Jones CM, et al:** Phase II open label trial of imatinib in polycythemia rubra vera. *Int J Hematol* 2008; 88(5):489–494.

**Pecci A, et al:** Cutaneous involvement by post-polycythemia vera myelofibrosis. *Am J Hematol* 2014; 89(4):448.



Bonus images for this chapter can be found online at

[expertconsult.inkling.com](http://expertconsult.inkling.com)

**eFig. 32-1** Jessner's lymphocytic infiltrate.

**eFig. 32-2** Reactive lymphoid hyperplasia.

**eFig. 32-3** Mycosis fungoides, patch stage with small and large patches.

**eFig. 32-4** Mycosis fungoides, path/plaque stage.

**eFig. 32-5** Mycosis fungoides, plaque stage.

**eFig. 32-6** Mycosis fungoides, tumor stage. (Courtesy of Dr. Ellen Kim.)

**eFig. 32-7** Mycosis fungoides, tumor stage.

**eFig. 32-8** Erythrodermic mycosis fungoides.

**eFig. 32-9** Syringotropic mycosis fungoides.

**eFig. 32-10** Large cell anaplastic lymphoma.

**eFig. 32-11** Sézary syndrome.

**eFig. 32-12** Pagetoid reticulosis.

**eFig. 32-13** Lymphomatoid papulosis. (Courtesy of Dr. Misha Rosenbach.)

**eFig. 32-14** Mucha-Habermann disease.

**eFig. 32-15** Lymphoma, B-cell.

**eFig. 32-16** Intravascular lymphoma.

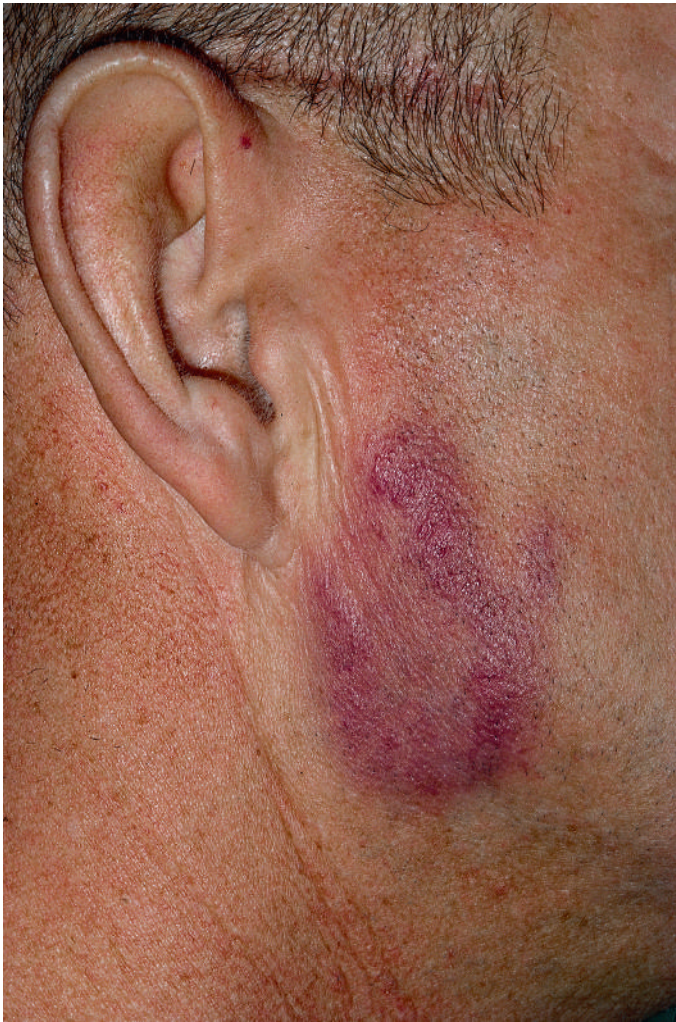**eFig. 32-17** Plasmacytoma in myeloma.

**eFig. 32-18** Malignant histiocytosis.

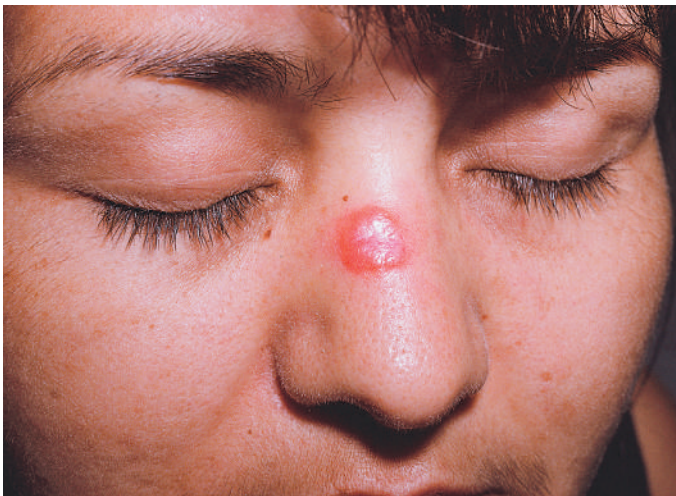**eFig. 32-19** Leukemia cutis.

**eFig. 32-20** Rosai-Dorfman disease. (Courtesy of Dr. Ellen Kim.)

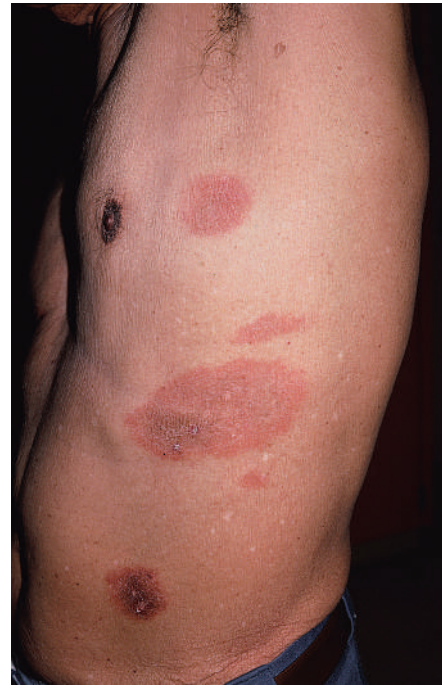



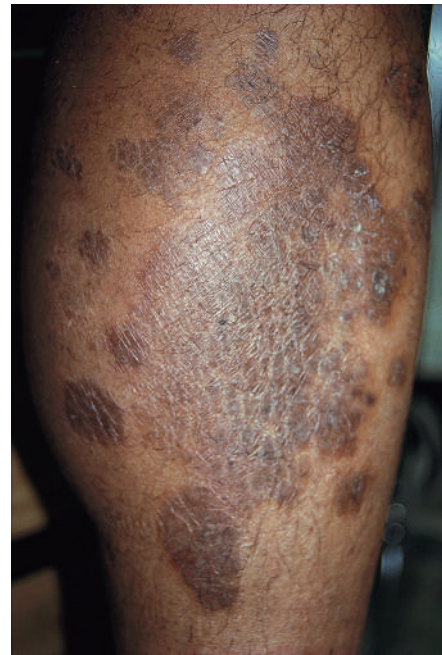
**eFig. 32-1** Jessner's lymphocytic infiltrate.



**eFig. 32-2** Reactive lymphoid hyperplasia.

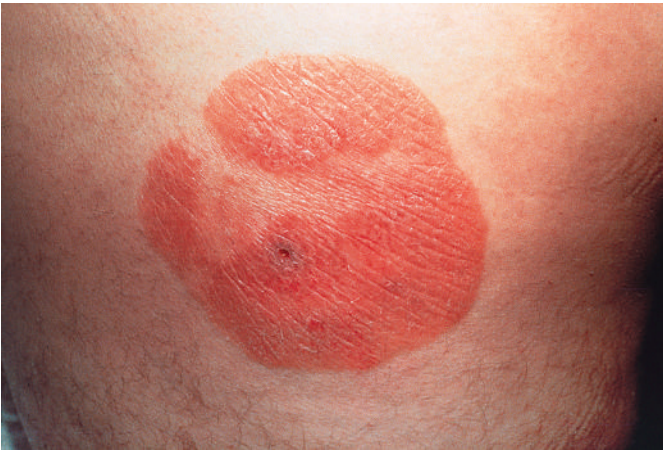

**eFig. 32-3** Mycosis fungoides, patch stage with small and large patches.

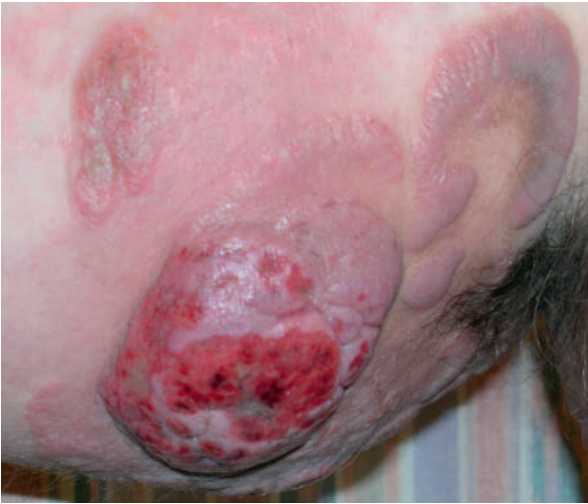

**eFig. 32-4** Mycosis fungoides, path/plaque stage.

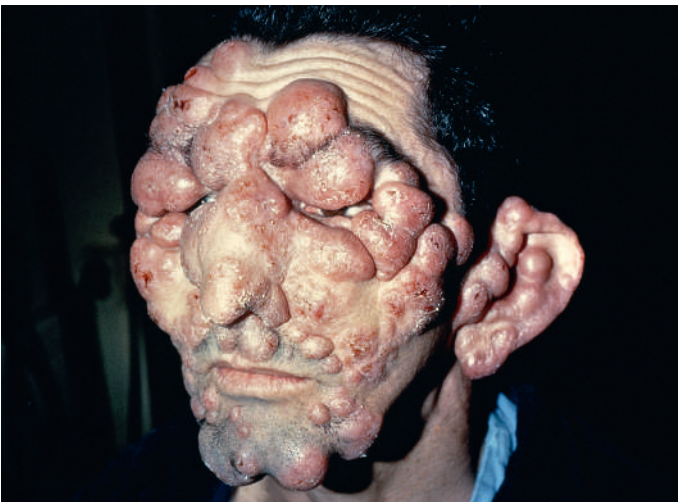



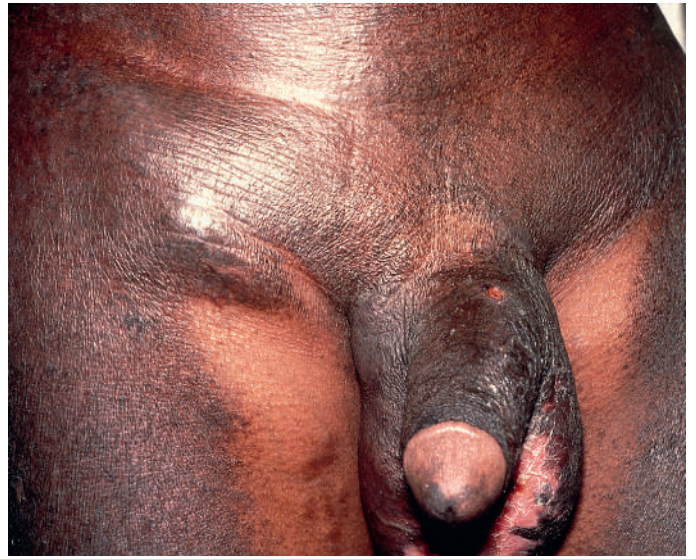
**eFig. 32-5** Mycosis fungoides, plaque stage.



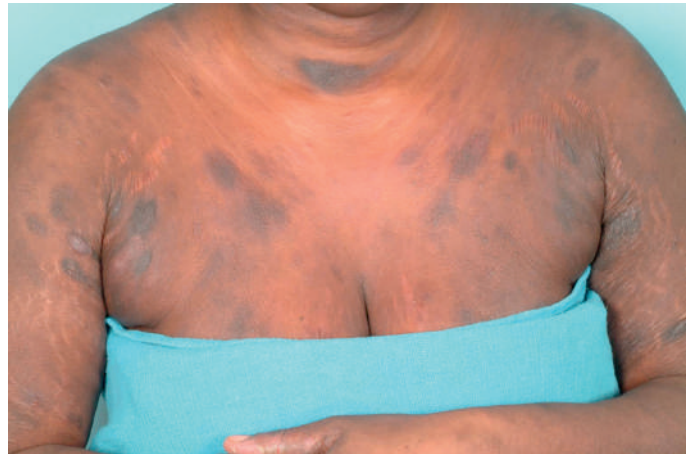**eFig. 32-6** Mycosis fungoides, tumor stage. (Courtesy of Dr. Ellen Kim.)



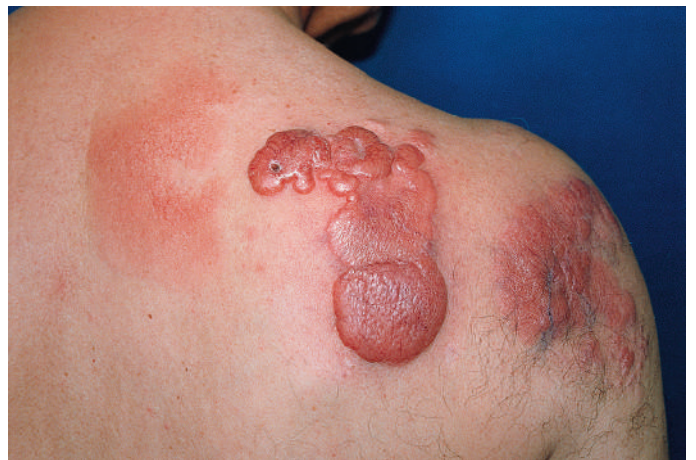**eFig. 32-7** Mycosis fungoides, tumor stage.



**eFig. 32-8** Erythrodermic mycosis fungoides.

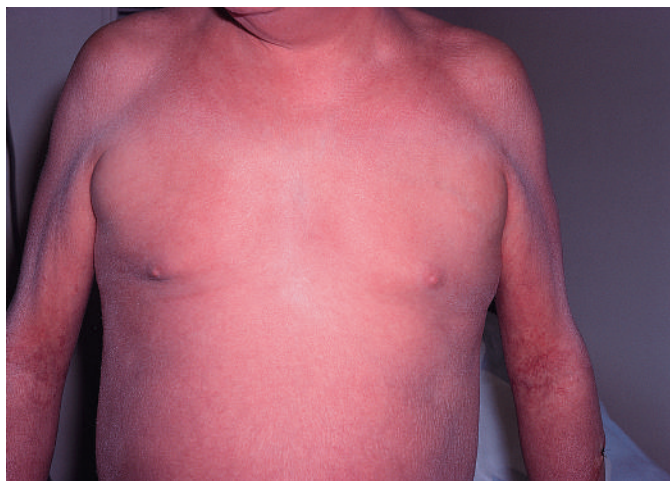

**eFig. 32-9** Syringotropic mycosis fungoides.

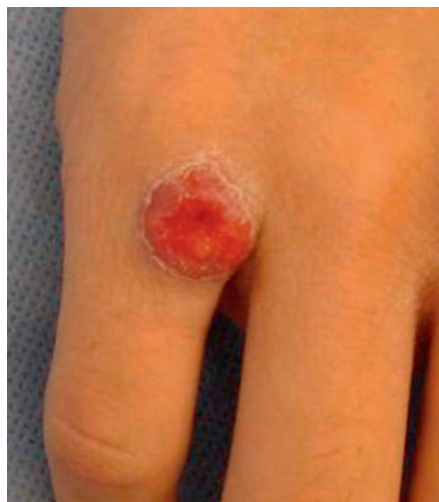

**eFig. 32-10** Large cell anaplastic lymphoma.

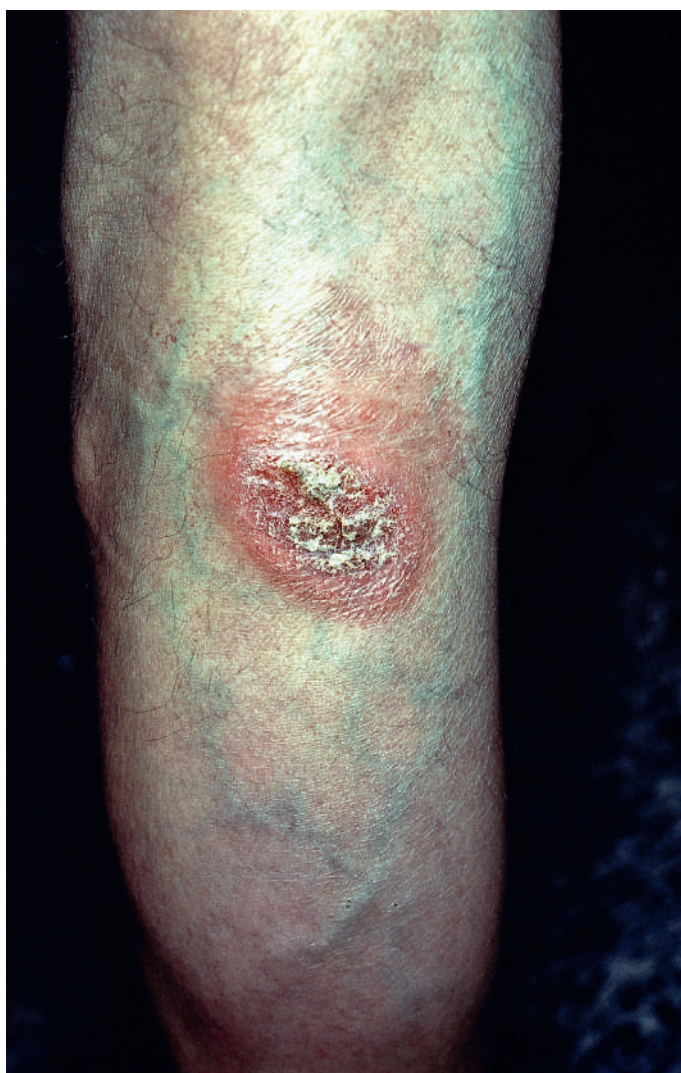



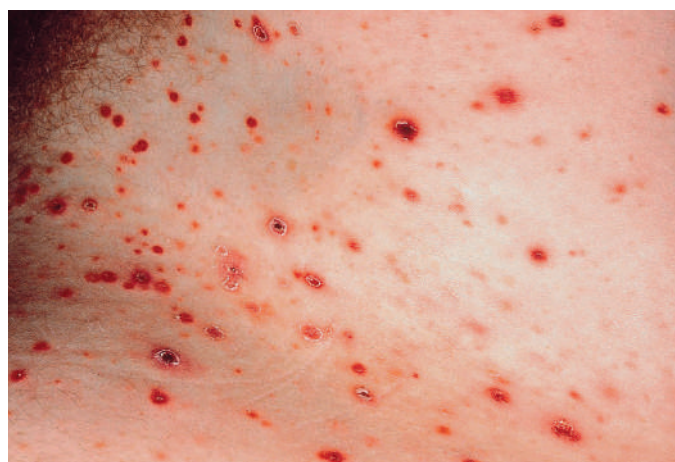eFig. 32-11 Sézary syndrome.



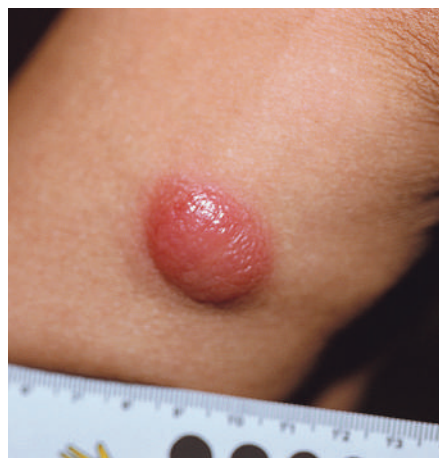eFig. 32-13  
Lymphomatoid  
papulosis. (Courtesy  
of Dr. Misha  
Rosenbach.)



eFig. 32-12 Pagetoid reticulosis.

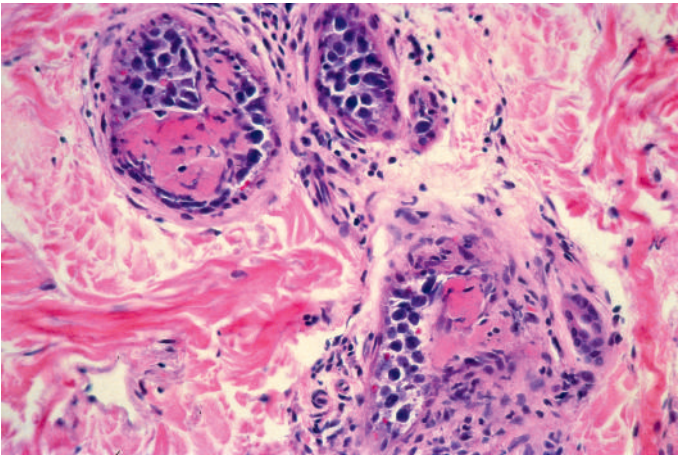


eFig. 32-14 Mucha-Habermann disease.

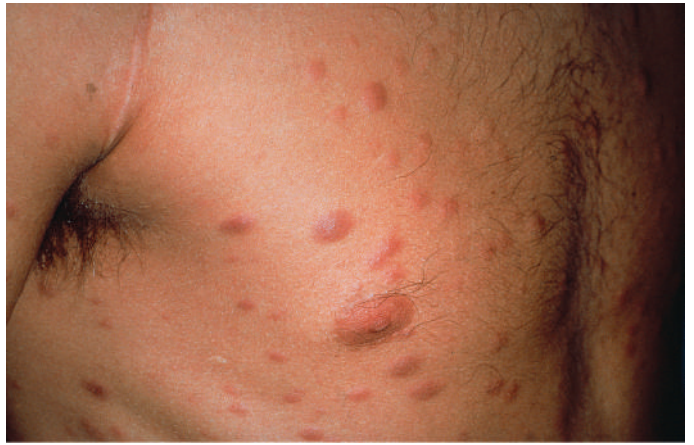

eFig. 32-15  
Lymphoma, B-cell.

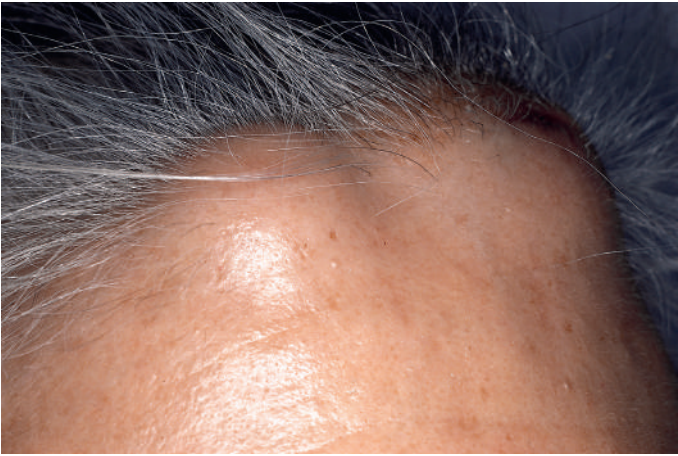




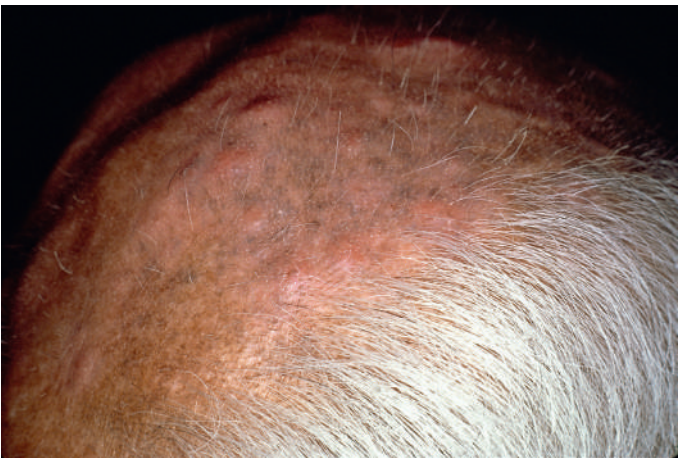
**eFig. 32-16** Intravascular lymphoma.



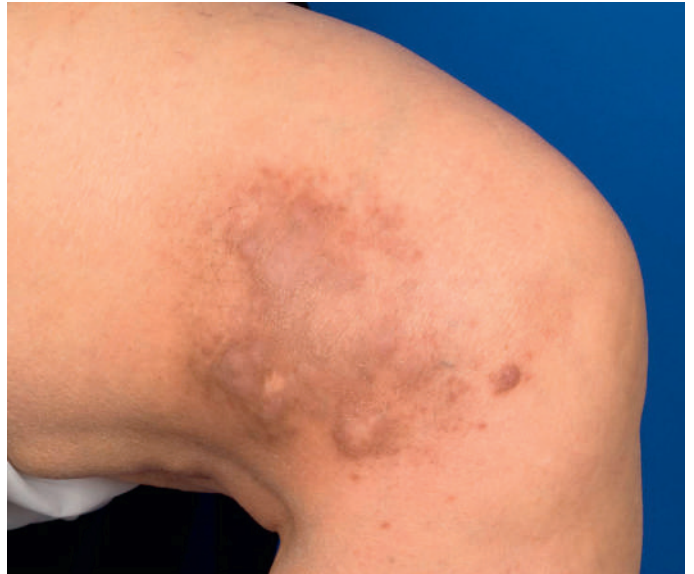**eFig. 32-19** Leukemia cutis.



**eFig. 32-17** Plasmacytoma in myeloma.



**eFig. 32-18** Malignant histiocytosis.



**eFig. 32-20** Rosai-Dorfman disease. (Courtesy of Dr. Ellen Kim.)



## Diseases of the Skin Appendages

### DISEASES OF THE HAIR

Normal human hairs can be classified according to cyclic phases of growth. Anagen hairs are growing hairs; catagen hairs are those undergoing transition from the growing to the resting stage; and telogen hairs are resting hairs, which remain in the follicles for variable periods before they fall out (teloptosis). The lag period between loss of the telogen hair and growth of a new anagen hair has been called kenogen.

Anagen hairs grow for about 3 years (1000 days), with a range between 2 and 6 years. The follicular matrix cells grow, divide, and become keratinized to form growing hairs. Catagen hairs are in a transitional phase, lasting 1 or 2 weeks, in which all growth activity ceases, with the eventual formation of the telogen “club” hair. Many apoptotic cells are present in the outer root sheath of the catagen hair as it involutes. Telogen club hairs are resting hairs, which continue in this state for 3–5 months (~100 days) before they are released.

Of human hairs plucked from a normal scalp, 85–90% are anagen hairs, and 10–15% are telogen hairs. Catagen hairs normally constitute less than 1% of scalp hairs. The scalp normally contains an estimated 100,000 hairs, and the average number of hairs shed daily is 100–150. The hair growth rate of terminal hairs is about 0.37 mm/day. Contrary to popular belief, neither shaving nor menstruation has any effect on hair growth rate. The average uncut scalp hair length is estimated to be 25–100 cm, although exceptional hairs may be as long as 170 cm (70 inches).

Lanugo hair is the fine hair present on the body of the fetus. This is replaced by the vellus and terminal hairs. Vellus hairs are fine and usually light colored and have a narrow hair shaft thinner than the width of the inner root sheath. Terminal hairs are coarse, thick, and dark, except in blond-haired persons. Hair occurs on all skin surfaces except the palms, soles, labia minora, lips, nails, glans, and prepuce. Terminal hairs are typically present on a man’s face, chest, and abdomen, but vellus hairs usually predominate on these sites in women.

Causes of alopecia are generally divided into the broad categories of cicatricial and noncicatricial alopecia. The evaluation should take into account the patient’s age and ethnicity. Examination of hair shafts can establish a diagnosis of trichodystrophy. Hair counts, hair pull, and hair pluck (trichogram) can establish the degree of hair shedding, the type of hair that is shed, and the anagen/telogen ratio. Biopsies can also determine the anagen/telogen ratio and provide information regarding the potential for regrowth, as well as providing a diagnosis. Biopsies are particularly valuable in the evaluation of cicatricial alopecia. Often, a correct diagnosis hinges on a synthesis of clinical, histologic, serologic, and immunofluorescent data.

### Noncicatricial alopecia

#### Alopecia areata

##### *Clinical features*

Alopecia areata (in French, pelade) is characterized by rapid and complete loss of hair in one or more round or oval patches, typically 1–5 cm in diameter, usually on the scalp, bearded area, eyebrows, eyelashes, and less frequently, on other hairy areas of the body. A few resting hairs may be found within the patches. Early in the course, there may be sparing of gray hair, and white hairs are rarely affected. Sudden whitening of hair may represent widespread alopecia areata in a patient with salt-and-pepper hair. In about 10% of alopecia areata patients, especially in long-standing cases with extensive involvement, the nails develop uniform pits that may form transverse or longitudinal lines. Trachyonychia, onychomadesis, and red or spotted lunulae occur, but less often. Dermoscopic examination typically demonstrates diffuse, round, or polycyclic perifollicular yellow dots.

Complete loss of scalp hair is referred to as alopecia totalis, and complete loss of all hair as alopecia universalis. Loss may occur confluent along the temporal and occipital scalp (ophiasis) (Fig. 33-1) or on the entire scalp except for this area (sisaipho). Rarely, alopecia areata may present in a diffuse pattern that may mimic pattern alopecia. Clues to the correct diagnosis include a history of periodic regrowth, nail pitting, and the presence of tapered fractures or “exclamation point” hairs (Fig. 33-2). Alopecia areata generally presents as an anagen effluvium, with an inflammatory insult to the hair matrix resulting in tapering of the hair shaft and fracture of anagen hairs. As the hair miniaturizes or converts from anagen to telogen, the remaining lower portion of the hair rises above the level of the scalp, producing the exclamation point hair.

Alopecia areata is associated with a higher incidence than usual of atopic dermatitis, Down syndrome, lichen planus, and autoimmune diseases, such as systemic lupus erythematosus (SLE), thyroiditis, diabetes mellitus, myasthenia gravis, and vitiligo. However, most cases of alopecia areata occur without associated disease, and routine screening for these disorders is of little value unless prompted by signs or symptoms.

Migratory poliosis of the scalp may represent a forme fruste of alopecia areata. Patients with this disorder present with migrating circular patches of white hair, but never lose hair. The histology resembles alopecia areata.

##### *Etiologic factors*

Oligoclonal and autoreactive T lymphocytes are present in the perifollicular inflammatory infiltrate, and many patients respond

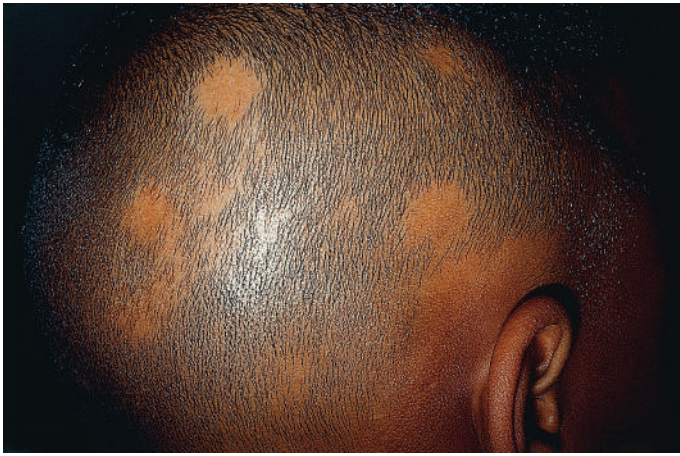

Fig. 33-1 Alopecia areata.

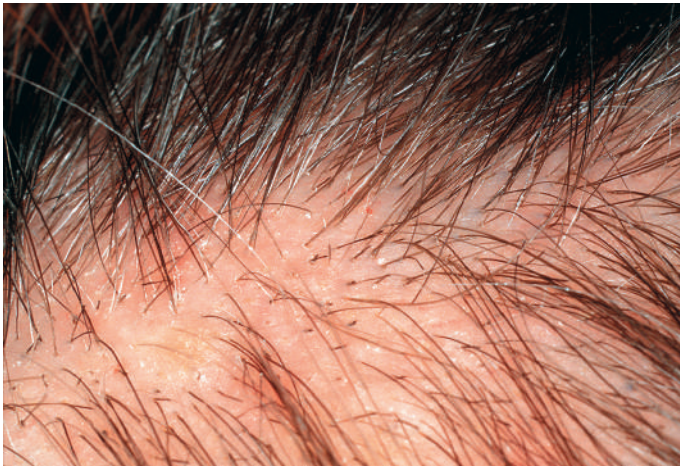


Fig. 33-2 Exclamation point hairs of alopecia areata.

to immunomodulating drugs. Affected alopecia areata scalp skin grafted on to nude mice with severe combined immunodeficiency demonstrates loss of infiltrating lymphocytes and hair growth. In this model, injecting T lymphocytes with scalp homogenate can reproduce the alopecia. Follicular melanocytes substitute for scalp homogenates to produce alopecia areata in this model, providing evidence that follicular melanocytes are the targets for activated T cells in this disease. This hypothesis is also supported by the observations that white hair is rarely affected and regrowing hair is often depigmented.

The early phase of hair loss appears to be mediated by type 1 cytokines, including interleukin (IL)-2, interferon (IFN)- $\gamma$ , and tumor necrosis factor (TNF)- $\alpha$ . The hair bulb normally represents an area of relative immune privilege during anagen, as evidenced by a very low level of expression of major histocompatibility complex (MHC) class Ia antigens. This immune privilege may prevent antigen recognition by autoreactive CD8+ T cells. Alopecia areata may be related to collapse of this immune privilege.

Overall, almost 25% of patients have a positive family history; there are reports of twins with alopecia areata. Patients with "early onset, severe, familial clustering alopecia areata" have a unique and highly significant association with the human leukocyte antigens (HLAs) DR4, DR11, and DQ7. The "later onset, milder severity, better prognostic" subsets of patients have a lower frequency of familial disease and do not share these HLAs. Familial alopecia areata associated with hereditary thrombocytopenia related to mutations in genes on

chromosome 17 has been described. R620W (c.1858C>T, a variant of the protein tyrosine phosphatase nonreceptor 22 gene, *PTPN22*) is associated with a variety of autoimmune disorders, including alopecia areata. It is associated with early onset of disease, widespread hair loss, and a positive family history.

### Histology

In early alopecia areata, there is a lymphoid infiltrate in the peribulbar area of anagen or early catagen follicles. Eosinophils may be present in the infiltrate, and lymphocyte-mediated damage to the bulb produces melanin pigment incontinence in the surrounding stroma. The presence of many catagen hairs and pigment casts within the follicular canal can cause histologic confusion with trichotillomania. The follicles eventually miniaturize, appearing as small, dystrophic anagen hairs high in the dermis, often with a persistent lymphocytic peribulbar infiltrate. Fibrous tract remnants beneath the miniaturized bulbs of alopecia areata may contain lymphoid cells, eosinophils, and melanin pigment. With time, the lymphocytes disappear, but focal eosinophils and pigment remain. Finally, only focal melanin pigment remains in the fibrous tract remnants. Every histologic feature of alopecia areata may be seen in syphilis. The presence of plasma cells is suggestive of syphilis, but plasma cells are also lacking in about one third of syphilis biopsies. Plasma cells may be present in biopsies from any form of inflammatory alopecia if the biopsy is taken from the occipital scalp, because this site readily recruits plasma cells.

### Differential diagnosis

The sharply circumscribed patch of alopecia with exclamation point hairs at the periphery and the absence of scarring are indicative of alopecia areata. Tinea capitis, androgenetic alopecia, early lupus erythematosus (LE), syphilis, congenital triangular alopecia, alopecia neoplastica, and trichotillomania should be kept in mind when alopecia areata is considered. In endemic areas of Southwest Asia, *Pheidole* ants shear hair shafts during the night, resulting in overnight loss of clumps of hair. The resulting round patches of hair loss closely mimic alopecia areata.

### Treatment

The natural course of the hair loss is highly variable. Some patches will regrow in a few weeks without any treatment. In a series of 63 consecutive responders to a follow-up questionnaire, hair had spontaneously regrown in all but four after 1 year and in all but one after 2 years. The great majority had recovered in 3 months after their only office visit. Therefore, anecdotal reports of success must be interpreted carefully in the light of the high rate of spontaneous recovery.

Intralesional injections of corticosteroid suspensions are the treatment of choice for localized, cosmetically conspicuous patches, such as those occurring in the frontal hairline or involving an eyebrow. Injections of triamcinolone, 2–10 mg/mL, are typically given intradermally or in the superficial subcutaneous tissue. Large volumes and higher concentrations of triamcinolone present a greater risk of atrophy. Injection under significant pressure or with a small-bore syringe increases the likelihood of retinal artery embolization. High-strength topical corticosteroids may be used as a safer first-line therapy but are less reliable than injections. Several investigators have reported the use of pulsed oral corticosteroids in rapidly progressing or widespread disease. However, long-term treatment is frequently needed to maintain growth, and the attendant risks should be carefully weighed against the benefits. In a study of 66 patients age 9–60 years, monthly methylprednisolone was administered at a dose of 500 mg/day for 3 days, or 5 mg/kg



twice daily over 3 days in children. More than 60% of patients with widespread patchy alopecia responded. Half the patients with alopecia totalis had a good response, whereas a quarter of those with universal alopecia responded. Patients with ophiasis alopecia areata did not respond. Predictors of response include disease duration of 6 months or less, younger than 10 years at disease onset, and multifocal disease.

Induction of contact sensitivity to squaric acid dibutyl ester, dinitrochlorobenzene (DNCB), and diphencyprone can be useful in refractory cases. Topical or oral methoxsalen (psoralen) and ultraviolet A (PUVA) therapy is an option for refractory or widespread lesions. Short-contact topical anthralin 1% cream (applied for 15–20 min and then shampooed off) can be of benefit. Topical minoxidil may be combined with other treatments or used as a single agent. Psoriatic doses of methotrexate and sulfasalazine in doses up to 1.5 g three times daily may be beneficial. Cyclosporine has been used alone or combined with other modalities, including PUVA. Biologics have produced mixed, and largely disappointing, results, and alopecia areata has developed during biologic therapy for other conditions. The 308-nm xenon chloride excimer laser (300–2300 mJ/cm<sup>2</sup>/session) has been reported to produce regrowth after 11 and 12 sessions over 9–11 weeks. Periocular pigmentation is associated with use of travoprost for eyelash disease. Therapeutic results are mixed. Botanicals, including peony glucosides and glycyrrhizin, demonstrate some promise. In a mouse model, a fusion protein of parathyroid hormone and a bacterial collagen-binding domain produced hair regrowth.

Alopecia areata can cause tremendous psychological stress. Education about the disease process, cosmetically acceptable alternatives (especially information about wigs), and research into innovative therapies should all be made available to the patient. In addition to the information conveyed by the dermatologist, an excellent resource is the National Alopecia Areata Foundation ([www.naaf.org](http://www.naaf.org), [info@naaf.org](mailto:info@naaf.org)).

### Prognosis

The tendency is for spontaneous recovery in alopecia areata patients who are postpubertal at onset. At first, the regrowing hairs are downy and light in color; later, they are replaced by stronger and darker hair with full growth. Predictors of a poor prognosis are the presence of atopic dermatitis, childhood onset, widespread involvement, ophiasis, duration of longer than 5 years, and onychodystrophy. Acute diffuse and total alopecia is a newly defined subtype of alopecia areata that occurs in young adults and has a good prognosis.

**Açikgöz G, et al:** Pulse methylprednisolone therapy for the treatment of extensive alopecia areata. *J Dermatolog Treat* 2014; 25(2):164–166.

**Falfo-Aizpurua L, et al:** Emerging treatments in alopecia. *Expert Opin Emerg Drugs* 2014; 19:545.

**Friedland R, et al:** Pulse corticosteroid therapy for alopecia areata in children: a retrospective study. *Dermatology* 2013; 227(1):37–44.

**Gensure RC:** Clinical response to combined therapy of cyclosporine and prednisone. *J Investig Dermatol Symp Proc* 2013; 16(1):S58.

**Gorcey L, et al:** Alopecia universalis successfully treated with adalimumab. *JAMA Dermatol* 2014; 150:1341.

**Hordinsky MK:** Overview of alopecia areata. *J Investig Dermatol Symp Proc* 2013; 16(1):S13–S15.

**Hordinsky M, Donati A:** Alopecia areata: an evidence-based treatment update. *Am J Clin Dermatol* 2014; 15:231.

**Islam N, et al:** The autoimmune basis of alopecia areata: A comprehensive review. *Autoimmun Rev* 2015; 14:81.

**Norris DA:** Summary of the preceding three alopecia areata research summits: what's past is prologue. *J Investig Dermatol Symp Proc* 2013; 16(1):S5–S9.

**Park KY, et al:** Combination therapy with cyclosporine and psoralen plus ultraviolet A in the patients with severe alopecia areata: a retrospective study with a self-controlled design. *Ann Dermatol* 2013; 25(1):12–16.

**Sardesai VR, et al:** A study to evaluate the efficacy of various topical treatment modalities for alopecia areata. *Int J Trichology* 2012; 4(4):265–270.

**Shapiro J:** Current treatment of alopecia areata. *J Investig Dermatol Symp Proc* 2013; 16(1):S42–S44.

**Strick RA:** DNCB use in treating extensive alopecia areata. *J Investig Dermatol Symp Proc* 2013; 16(1):S45.

**Tauber M, et al:** Alopecia areata occurring during anti-TNF therapy: a national multicenter prospective study. *J Am Acad Dermatol* 2014; 70:1146.

**Yang CC, et al:** Early intervention with high-dose steroid pulse therapy prolongs disease-free interval of severe alopecia areata: a retrospective study. *Ann Dermatol* 2013; 25(4):471–474.

**Yang D, et al:** Total glucosides of paeony capsule plus compound glycyrrhizin tablets for the treatment of severe alopecia areata in children: a randomized controlled trial. *Evid Based Complement Alternat Med* 2013; 2013:378219.

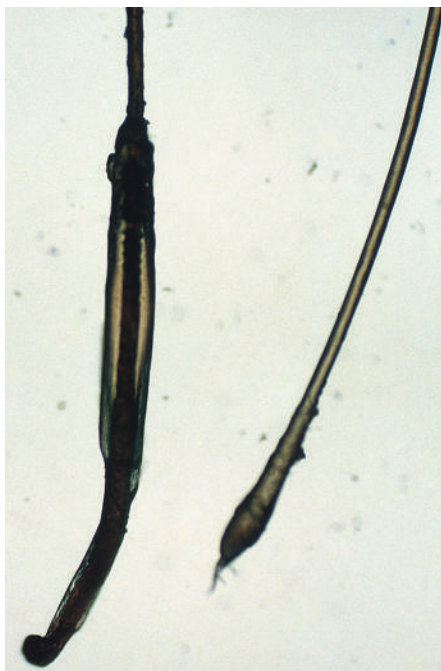### Telogen effluvium

Telogen effluvium presents with excessive shedding of normal telogen club hairs. This excessive shedding of telogen hairs most often occurs 3–5 months after the premature conversion of many anagen hairs to telogen hairs induced by surgery, parturition, fever, drugs, dieting, or traction. Local patches of early telogen conversion may be induced by papulosquamous diseases affecting the scalp. Alternatively, follicles may remain in prolonged anagen rather than normally cycling into telogen. This occurs during pregnancy. On delivery, many follicles are then released simultaneously into telogen, and shedding occurs 3–5 months later. Prolongation of telogen also occurs during pregnancy and results in an initial wave of hair loss soon after delivery or heralding early termination of a pregnancy. Shortening of the anagen phase occurs in pattern (androgenetic) alopecia and in chronic telogen effluvium. A greater proportion of hairs in telogen at any one time results in a chronic increase in telogen shed. Administration of topical minoxidil may produce a telogen effluvium by premature termination of telogen necessary to initiate anagen in responding follicles. This causes early telogen release and a brief telogen effluvium.

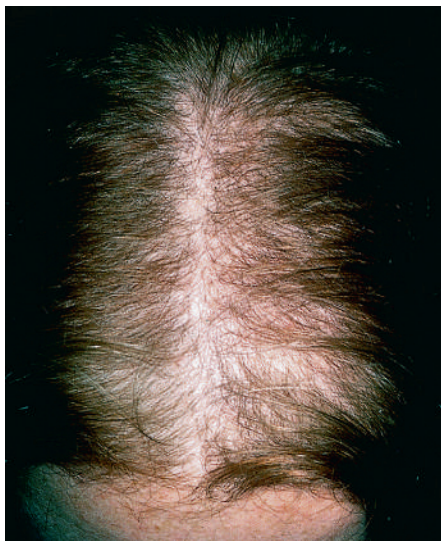Whatever the cause of the telogen loss, the hair is lost “at the root.” Each hair will have a visible depigmented club-shaped bulb and will lack a sheath (Fig. 33-3).

Telogen shed may be estimated by the pull test: grasping 40 hairs firmly between thumb and forefinger, followed by a slow pull that causes minimal discomfort to the patient. A count of more than 4–6 club hairs is abnormal, but the result is influenced by recent shampooing (2–3 hairs being abnormal in a freshly shampooed scalp), combing, and the phase of telogen effluvium (whether resolving or entering a chronic phase). The clip test may also be useful; 25–30 hairs are cut just above the scalp surface and mounted. Indeterminate and telogen hairs are short and of small diameter. Many hairs of this type may be present in telogen effluvium or pattern alopecia. Trichogram evaluation (50 hairs plucked with Kelly clamp with rubber drains over teeth) can also provide information on the anagen/telogen ratio.

Age, gender, race, and genetic factors influence the normal average daily hair loss in an individual. Again, a full head of hair numbers about 100,000; of these, approximately 100–150 are lost daily. In telogen effluvium, estimates of loss vary from 150 to more than 400. Patients may be instructed to collect and count the hair daily; however, they should make sure they collect all small hairs and those that come out in washing and in the bed, as well as those present on the comb or brush. When the pull test is positive, hair shed counts are not needed. An alternative is to collect all hairs lost during a 1-minute combing session. For this technique, developed by Dr. Jeffrey



**Fig. 33-3** Anagen and telogen hair. Anagen hair has a pigmented bulb and is surrounded by a gelatinous root sheath; telogen hair has a nonpigmented bulb and lacks a root sheath.



**Fig. 33-4** Telogen effluvium secondary to "crash" dieting.

Miller, the patient combs for 1 minute before shampooing on 3 consecutive days. The patient is instructed to comb from the vertex to the anterior hairline. The normal range of lost hairs with this technique is 10–15. Loss of more than 50 is common in telogen effluvium. Serial 1-minute hair counts can be performed to monitor progress.

Telogen effluvium may be related to protein or other nutrient deprivation (Fig. 33-4). Assessment of dietary habits and determination of iron saturation and ferritin are the simplest ways to determine nutritional status. Iron replacement is advisable if saturation or ferritin is low, but in one study, iron replacement alone did not result in resolution of telogen effluvium. Iron may merely serve as a marker for overall nutritional status. Patients with evidence of deficiency should be given supplements to correct the identified deficiency and encouraged to eat a varied diet. Sources of blood loss, such as menstrual bleeding and gastrointestinal (GI) blood loss, should be investigated. Hypothyroidism, allergic contact dermatitis to hair dyes, and renal dialysis with secondary hypervitaminosis A may also be associated with telogen effluvium. Drug-induced telogen effluvium has been noted with the use of aminosalicyclic acid, amphetamines, bromocriptine, captopril, carbamazepine, cimetidine, coumarin, danazol, enalapril, etretinate, levodopa, lithium carbonate, metoprolol, metyrapone, pramipexole, propranolol, pyridostigmine, and trimethadione. Postnatal telogen effluvium of infants may occur between birth and the first 4 months of age. Usually, regrowth occurs by 6 months of age. Telogen counts by Kligman in six infants varied from 64% to 87%. He also found a tendency for the alopecia to occur in the male-pattern distribution. Idiopathic chronic telogen effluvium has been described by Whiting in a group of 355 patients (346 women and 9 men) with diffuse generalized thinning of scalp hair. Most were 30–60 years old, and their hair loss started abruptly, with increased shedding and thinning. There was a fluctuating course and diffuse thinning of the hair all over the scalp, accompanied by bitemporal recession. This chronic form is related to shortening of the anagen phase and may respond to 5% minoxidil solution.

Trichodynia is a common symptom in patients with telogen effluvium, as it is in pattern hair loss. Trichodynia may also coexist with signs of depression, obsessive personality disorder, or anxiety.

If a 4-mm punch biopsy is performed, 25–50 hairs are normally present for inspection in transverse (horizontal) sections. If more than 12–15% of terminal follicles are in telogen, this indicates a significant shift from anagen to telogen. Pattern (androgenetic) alopecia demonstrates miniaturization, variable hair shaft diameter, and an increased proportion of telogen hairs. Traction alopecia and trichotillomania result in an increased number of catagen and telogen hairs. Pigment casts, empty anagen follicles, trichomalacia, and catagen hairs help distinguish these entities from simple telogen effluvium.

No specific therapy is required for most patients with telogen effluvium. In the majority of cases, the hair loss will stop spontaneously within a few months, and the hair will regrow. Drug-induced telogen effluvium responds to discontinuation of the offending agent. The prognosis is good if a specific event can be pinpointed as a probable cause. Pulosquamous scalp disorders may precipitate telogen hair loss and should be addressed. Iron and thyroid status should be determined if the course is prolonged or if history or physical examination suggests an abnormality. Patients should be encouraged to eat a balanced diet. In a mouse model, sonic stress can produce catagen. This model may be useful in the study of agents for the treatment of telogen effluvium.

**Bittencourt C, et al:** Chronic telogen effluvium and female pattern hair loss are separate and distinct forms of alopecia: a histomorphometric and immunohistochemical analysis. *Clin Exp Dermatol* 2014; 39:868.

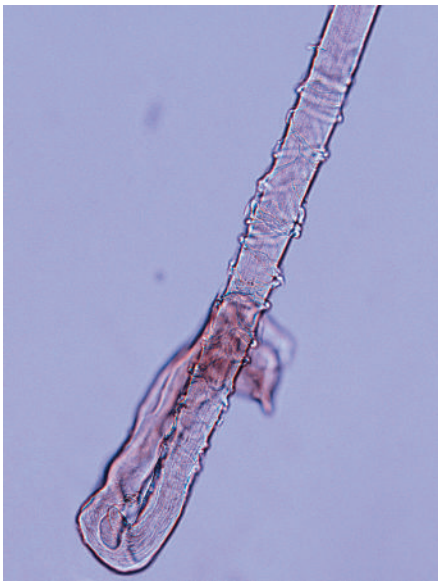**Karashima T, et al:** Oral zinc therapy for zinc deficiency-related telogen effluvium. *Dermatol Ther* 2012; 25(2):210–213.

**Mubki T, et al:** Evaluation and diagnosis of the hair loss patient. Part I. History and clinical examination. *J Am Acad Dermatol* 2014; 71:415.e1.

## Anagen effluvium

Anagen effluvium usually results from hair shaft fracture. It is frequently seen following the administration of cancer chemotherapeutic agents, such as the antimetabolites, alkylating agents, and mitotic inhibitors. These agents result in temporary shutdown of the hair matrix with resultant tapering of the shaft (Pohl-Pinkus constrictions). Trichograms reveal tapered fractures. Only anagen hairs are affected. The 10% of scalp hairs in telogen have no matrix and are unaffected. The loss tends to be diffuse but not complete. Severe loss is frequently seen with doxorubicin, the nitrosureas, and cyclophosphamide. When high doses are given, loss of anagen hairs becomes most apparent clinically in 1–2 months. Hair loss after chemotherapy is usually, but not always, reversible. Permanent alopecia





**Fig. 33-5** Loose anagen hair with “rumpled sock” cuticle.

after chemotherapy resembles pattern alopecia histologically. A pressure cuff applied around the scalp during chemotherapy and scalp hypothermia have been reported to prevent such anagen arrest; because the scalp may be a site of metastasis, however, it may be better not to spare the scalp from the effects of chemotherapy. Topical minoxidil has been shown to shorten the period of baldness by an average of 50 days.

In addition to the cytotoxic chemotherapeutic agents, various agents, such as isoniazid (INH), thallium, and boron, may induce anagen effluvium. Anagen effluvium with tapered fractures also occurs in alopecia areata and syphilis. In these diseases, an inflammatory insult to the hair bulb results in tapered fractures.

Anagen loss may also occur at the root. Loose anagen syndrome, described by Price in 1989, is a disorder in which anagen hairs may be pulled from the scalp with little effort. It occurs mostly in blond girls and usually improves with age. The syndrome appears to be related to a defect in the hair cuticle. Instead of anchoring the hair firmly, the cuticle simply folds back like a rumpled sock (Fig. 33-5), allowing the hair shaft to be extracted. Woolly hair can be associated with loose anagen hair syndrome. A keratin mutation, E337K in K6HF, was identified in three of nine families studied. Colobomas have also been associated with loose anagen hair.

Anagen hairs may be easily extracted from active areas of LE and lichen planopilaris. They usually lack the root sheath that normally surrounds a plucked anagen hair. Anagen effluvium has also been described in lesions of pemphigus.

**Kanwar AJ, et al:** Anagen effluvium. *Indian J Dermatol Venereol Leprol* 2013; 79(5):604–612.

**Miteva M, et al:** Permanent alopecia after systemic chemotherapy: a clinicopathological study of 10 cases. *Am J Dermatopathol* 2011; 33(4):345–350.

**Queretani R, et al:** Patients with profuse hair shedding may reveal anagen hair dystrophy: a diagnostic clue of alopecia areata incognita. *J Eur Acad Dermatol Venereol* 2011; 25(7):808–810.

## Pattern alopecia (androgenetic alopecia)

### Male-pattern baldness

Male-pattern alopecia (common baldness) shows itself during the teens, twenties, or early thirties with gradual loss of hair, chiefly from the vertex and frontotemporal regions. The process may begin at any time after puberty, and the presence

of “whisker” or kinky hair may be the first sign of impending male-pattern alopecia. The anterior hairline recedes on each side, in the *Geheimratswinkeln* (“professor angles”), so that the forehead becomes high. Eventually, the entire top of the scalp may become devoid of hair. Several patterns of this type of hair loss occur, but most common is the biparietal recession with loss of hair on the vertex. The rate of hair loss varies among individuals. Sudden hair loss may occur in the twenties and then proceed relentlessly, though very slowly, for a number of years. The follicles produce finer and lighter hairs with each hair cycle until terminal hairs are eventually replaced by vellus hairs. During evolution of the process, hair shafts vary significantly in diameter. The parietal and occipital areas are usually spared permanently from this process of progressive miniaturization.

Early-onset male-pattern alopecia is related to the androgen receptor gene. There is no doubt that inherited factors and the effect of androgens such as dihydrotestosterone on the hair follicle are important. Arguments for polygenic inheritance include the high prevalence, gaussian curve of distribution in the population, increased risk with number of affected relatives, increased risk in relatives of severely affected women compared with mildly affected women, and greater import of an affected mother than an affected father. The possibility that the early onset (before age 30) and later onset (after 50) forms may be inherited separately by single genes is also hypothesized.

Male-pattern alopecia is dependent on adequate androgen stimulation and appears to be related to the androgen receptor gene. Eunuchs do not develop baldness if they are castrated before or during adolescence. If they are given androgen therapy, baldness may develop. The  $5\alpha$ -reduction of testosterone is increased in the scalp of balding individuals, yielding increased dihydrotestosterone. Androgen-inducible transforming growth factor (TGF)- $\beta$ 1 derived from dermal papilla cells appears to mediate hair growth suppression. In congenital  $5\alpha$ -reductase deficiency, the type 2 isoenzyme is lacking, and baldness does not occur. Pattern alopecia does occur in males with X-linked ichthyosis, indicating that steroid sulfatase is not critical for the production of alopecia.

Progressive shortening of the anagen phase of hair growth is noted as the hair shaft diameter decreases, so hairs not only are narrowing, but also are becoming shorter. A higher proportion of telogen hairs in the affected area results in greater telogen shed. There may also be an increase in the duration of the lag phase between telogen and anagen (the kenogen lag phase).

Histologically, a decrease in anagen and increase in telogen follicles is present. Follicular miniaturization and variability in shaft diameter are noted. These features are particularly evident in transverse sections. Below the level of the miniaturized or telogen follicle, a vascular or fibromucinous fibrous tract remnant is present. These tracts appear numerous in cross section. Many mast cells may be noted in the fibrous tract remnant, but inflammatory cells are absent. Sebaceous glands may be enlarged, and hair thinning may be associated with solar elastosis. Sparse lymphoid inflammation with spongiosis may be noted at the level of the follicular infundibulum. This may represent associated seborrheic folliculitis. A sparse lymphoid infiltrate may also be noted at the level of the hair bulge.

Miniaturized human hair follicles grafted on to immunodeficient mice can quickly regenerate and grow as well as or better than terminal follicles from the same individual. This suggests that even advanced pattern alopecia may be reversible. Partial reversal of pattern alopecia has been noted after chemotherapy or treatment of psoriasis with methotrexate. Unfortunately, available pharmacologic interventions produce little effect in advanced pattern alopecia.

Men with spinal and bulbar muscular atrophy (Kennedy disease), an X-linked neurodegenerative disease caused by an expansion of a polymorphic tandem CAG repeat within the androgen receptor gene, have a decreased incidence of pattern alopecia.

Minoxidil, an oral hypotensive drug that causes hypertrichosis when given systemically, is available as topical solutions (Rogaine). Minoxidil promotes the survival of dermal papilla cells, prolongs anagen phase, and results in enlargement of shaft diameter. Clinically, apparent success is best in early cases (<10 years) of limited extent (bald area <10 cm in diameter on vertex) in whom pretreatment hair density is greater than 20 hairs/cm<sup>2</sup>. Minoxidil is available without a prescription as a solution or foam. Those who respond must continue to use minoxidil indefinitely to maintain a response.

Finasteride, a type 2 5 $\alpha$ -reductase inhibitor, given as a 1-mg tablet daily, is effective in preventing further hair loss and in increasing the hair counts to the point of cosmetically appreciable results in men age 18–41 with mild to moderate hair loss at the vertex, in the anterior midscalp, and in the frontal region. Finasteride has been shown to stop hair loss in up to 90% of men for at least 5 years. Approximately 65% of men demonstrate hair regrowth. As with minoxidil, continued use of finasteride is required to sustain benefits. Hair patterning on the temples is not improved. Hair growth will be evident only after 6 months or more of therapy. If no effect is seen after 12 months, further treatment is unlikely to be of benefit. In one study, regimens that included finasteride were more effective than minoxidil alone, and therapeutic efficacy was enhanced by combining the two drugs. Short-term side effects related to finasteride are infrequent; however, the need to take this medication indefinitely suggests that study of long-term side-effect profiles is critical. A prostate cancer prevention trial with a different dosage form of the same drug showed a decrease in the incidence of cancer. However, those cancers that did occur in the treatment group had a higher average Gleason score, possibly because only lower-grade cancers were prevented.

Dutasteride blocks both type 1 and type 2 5 $\alpha$ -reductase and is effective in the treatment of male-pattern hair loss. Other treatments that show some promise in preliminary studies include fluridil (topical antiandrogen that suppresses human androgen receptor), topical adenosine, and hormone-enriched topical cell culture medium. Hair transplantation using micrografts of hair follicles from the occipital area to the anterior scalp may satisfactorily recreate hairlines and give excellent cosmetic results.

### **Female-pattern alopecia (androgenetic alopecia in women)**

Women generally have diffuse hair loss throughout the apical scalp with the part wider anteriorly. There is typically sparing of the frontal hairline, although a subset of women exhibits a “male” pattern of temporal recession. Although maintenance of the frontal hairline is the rule in women, a progressive decrease in hair density from the vertex to the front of the scalp does occur. The same basic changes—reduced hair density and diameter and diminished anagen and increased telogen hair—occur in women as in men. Sebaceous gland hyperplasia may be present but is less common than in men. Transverse histologic sections demonstrate variability in the size of hair follicles (anisotrichosis).

The cause is now believed to be a genetic predisposition with an excessive response to androgens. Both women and men with pattern alopecia have higher levels of 5 $\alpha$ -reductase and androgen receptor in frontal hair follicles than in occipital follicles. Evidence also suggests a hierarchy of androgen sensitivity within follicular units. Follicular miniaturization

relates to unrepaired DNA damage and a reduced proliferation rate of matrix keratinocytes. Smoking may be an independent risk factor. Most women with pattern alopecia have normal menses and fertility. If other evidence of androgen excess is present, such as hirsutism, menstrual irregularities, or acne, or if the onset is sudden, evaluation as outlined for hirsutism (see later) should be performed. Topical minoxidil, and oral antiandrogens, such as spironolactone and cyproterone acetate, have been used to treat androgenetic alopecia in women. In one study, cyproterone acetate was more effective than minoxidil when there were other signs of hyperandrogenism, hyperseborrhea, and menstrual abnormalities, and when the body mass index was high. When these other factors were absent, minoxidil was the more effective treatment.

Treatment with finasteride is of limited benefit for most women, although the subset with temporal recession may show some benefit. Finasteride treatment is contraindicated in women who may become pregnant. Hair transplantation, wigs, or interwoven hair may give satisfactory cosmetic results. In a pilot study, topical melatonin appeared to prolong anagen phase and may prove to be of some benefit. In some women, telogen effluvium may produce worsening of preexisting pattern alopecia. Reversible causes of telogen effluvium, such as seborrheic dermatitis, nutrient deficiency, and thyroid disease, should be addressed.

**Caruso D, et al:** Patients treated for male pattern hair with finasteride show, after discontinuation of the drug, altered levels of neuroactive steroids in cerebrospinal fluid and plasma. *J Steroid Biochem Mol Biol* 2015; 146:74.

**Famenini S, Goh C:** Evidence for supplemental treatments in androgenetic alopecia. *J Drugs Dermatol* 2014; 13:809.

**Gubelin Harcha W, et al:** A randomized, active- and placebo-controlled study of the efficacy and safety of different doses of dutasteride versus placebo and finasteride in the treatment of male subjects with androgenetic alopecia. *J Am Acad Dermatol* 2014; 70:489.

**Krausz A, et al:** Cutaneous hyperandrogenism: role of antiandrogen therapy in acne, hirsutism, and androgenetic alopecia. *J Drugs Dermatol* 2013; 12(11):1297–1300.

**Shamsaldeen OS, et al:** Topical agents for hair growth promotion: what is out there? *Skin Ther Lett* 2013; 18(4):5–7.

**Yeo IK, et al:** An epidemiological study of androgenic alopecia in 3114 Korean patients. *Clin Exp Dermatol* 2014; 39(1):25–29.

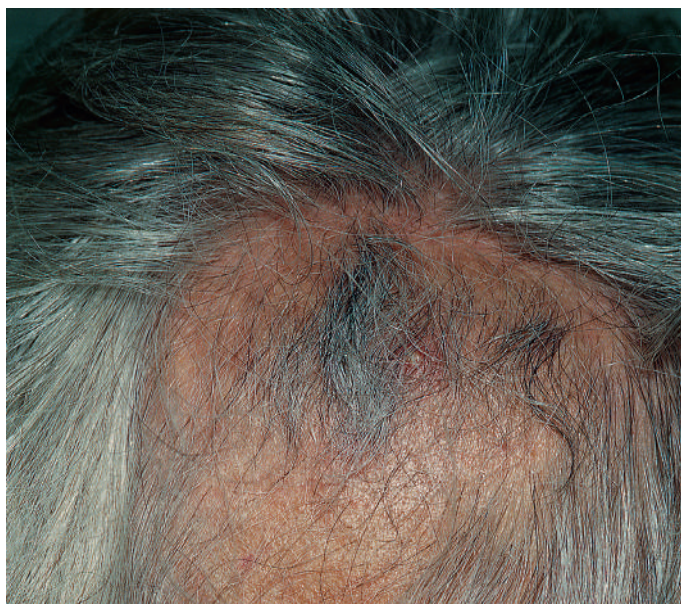
### **Trichotillomania (trichotillosis)**

Trichotillomania is the compulsive practice of plucking hair from the scalp, brows, or eyelashes. Typical areas are irregular patches of alopecia that contain hairs of varying length. The scalp has a rough texture, resulting from the short remnants of broken-off hairs. Trichotillomania is seen mostly in girls younger than 10, although boys and all adults may engage in the practice as well. Some patients relate exquisite pain localized to a follicle (Fig. 33-6) that can only be relieved by plucking the hair.

When speaking with a patient with characteristic areas of alopecia, rather than asking “if,” one should ask “how” removal of the hair is done. If this fails to uncover a history of hair pulling, shaving a 3-cm<sup>2</sup> area in the involved part of the scalp will result in hairs too short for plucking, and normal regrowth in the “skin window” within 3 weeks. Finally, a biopsy, especially if cut horizontally, may demonstrate empty anagen follicles, catagen hairs, pigment casts within the infundibulum, trichomalacia, and hemorrhage. Alopecia areata shares many of these histologic features, and care must be taken to search for the presence of peribulbar lymphocytes or inflammatory cells within the fibrous tract remnants.

Trichotillomania is usually a manifestation of an obsessive-compulsive disorder but may also be associated with depression or anxiety. It may be associated with compulsive





**Fig. 33-6** Trichotillomania.

swallowing of the plucked hairs (trichophagia) and may result in formation of a gastric bezoar (Rapunzel syndrome). Behavior modification, psychotherapy, and appropriate psychopharmacologic medication (e.g., clomipramine, olanzapine) may be helpful. *N*-acetylcysteine was effective in a study in adults, but a separate study showed disappointing results in children. Valproic acid, quetiapine, and naltrexone have been reported as effective in some patients. Bimatoprost has been used when eyelashes are involved.

**Bloch MH, et al:** *N*-acetylcysteine in the treatment of pediatric trichotillomania: a randomized, double-blind, placebo-controlled add-on trial. *J Am Acad Child Adolesc Psychiatry* 2013; 52(3):231–240.

**Falkenstein MJ, et al:** Predictors of relapse following treatment of trichotillomania. *J Obsessive Compuls Relat Disord* 2014; 3:345.

**Grant JE, et al:** The opiate antagonist, naltrexone, in the treatment of trichotillomania: results of a double-blind, placebo-controlled study. *J Clin Psychopharmacol* 2014; 34(1):134–138.

**Harrison JP, et al:** Pediatric trichotillomania. *Curr Psychiatry Rep* 2012; 14(3):188–196.

**Peabody T, et al:** Clinical management of trichotillomania with bimatoprost. *Optom Vis Sci* 2013; 90(6):e167–e171.

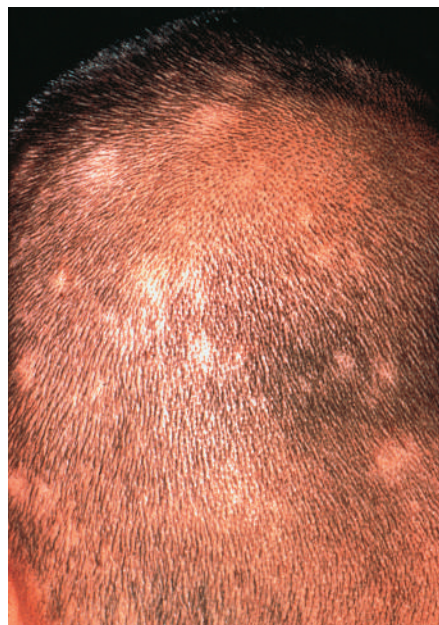
**Rothbart R, et al:** Pharmacotherapy for trichotillomania. *Cochrane Database Syst Rev* 2013; 11:CD007662.

**Rothbart R, Stein DJ:** Pharmacotherapy of trichotillomania (hair pulling disorder): an updated systematic review. *Expert Opin Pharmacother* 2014; 15:2709.

## Other forms of noncicatricial alopecia

Alopecia syphilitica may have a typical moth-eaten appearance on the occipital scalp (Fig. 33-7), may show a generalized thinning of the hair, or may resemble alopecia areata. Other areas, such as the eyebrows, eyelashes, and body hair, may be involved. The alopecia may be the first sign of syphilis.

Follicular mucinosis (alopecia mucinosa) most often occurs on the scalp or beard area and manifests as a boggy, red plaque or hypopigmented patch with hair loss. Comedolike lesions may exude mucin when expressed. Biopsy demonstrates deposition of mucin in the outer root sheath and sebaceous glands. The mucin stains as hyaluronic acid, rather than epithelial sialomucin. Primary cases (unassociated with underlying disease) usually occur as localized lesions of the



**Fig. 33-7** Syphilitic alopecia. (Courtesy of Brooke Army Medical Center Teaching File.)

head or neck. Young people are primarily affected and may demonstrate clonality even in lesions that do not progress clinically. The secondary type is associated with mycosis fungoides–type cutaneous T-cell lymphoma or a chronic inflammatory skin disease. Lesions associated with mycosis fungoides are generally widespread and chronic and occur in older patients.

Vascular or neurologic alopecia, most often of the lower extremities, may be seen in diabetes mellitus or atherosclerosis. In meralgia paresthetica, there may be alopecia of the anesthetic area of the outer thigh.

Endocrinologic alopecia may occur in various endocrinologic disorders. In hypothyroidism, the hair becomes coarse, dry, brittle, and sparse. The proportion of telogen hairs has been shown to be three to seven times higher than the normal 10%. In hyperthyroidism, the hair becomes extremely fine and sparse. Oral contraceptives (OCs) have been implicated in some cases of androgenetic alopecia. It develops in predisposed women who are usually taking androgenic progestogens. It is advisable to discontinue the androgen-dominant pill and substitute an estrogen-dominant OC. Some women develop telogen effluvium 2–4 months after discontinuing anovulatory agents, which is analogous to postpartum alopecia.

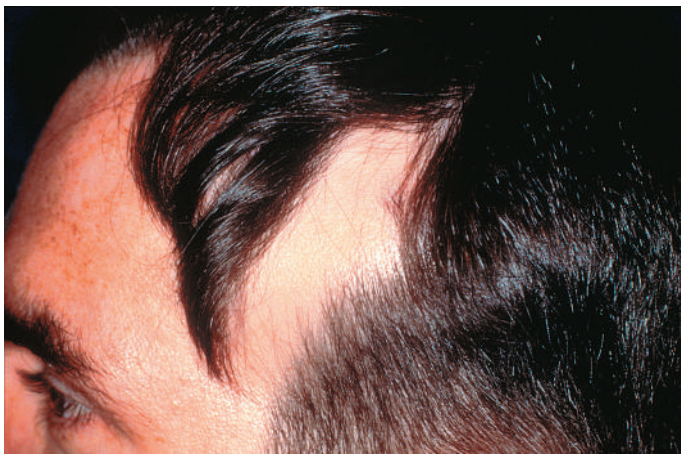Congenital alopecia occurs as total or partial loss of hair, or a lack of initial growth, accompanied usually by other ectodermal defects of the nails, teeth, and bone. The hair is light and sparse and grows slowly. Congenital triangular alopecia (Fig. 33-8) and aplasia cutis congenita are examples of congenital localized absence of hair. Hidrotic ectodermal dysplasia is a diffuse abnormality of hair associated with dental and nail changes.

Lipedematous alopecia consists of thickening of the scalp that gives the impression of thick cotton batting. The hair may be normal or shortened and sparse. Biopsy shows an increase in thickness of the subcutaneous fat and variable lymphoid inflammation. This disease appears to affect black persons primarily.

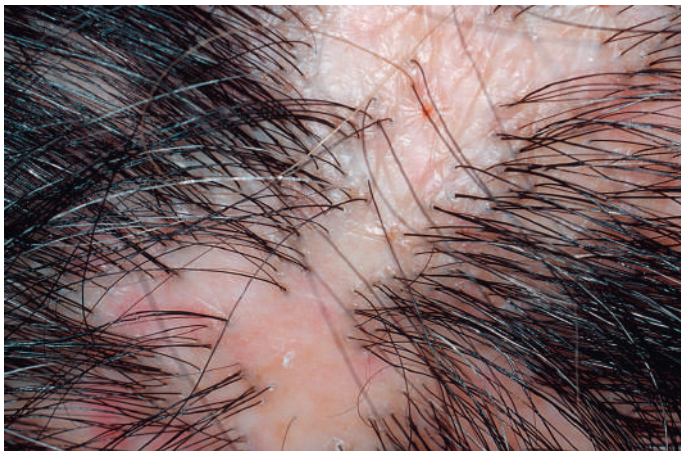
**Gibson LE, et al:** Follicular mucinosis in childhood. *J Am Acad Dermatol* 2013; 69(6):1054–1055.

**Yasar S, et al:** Clinical and pathological features of 31 cases of lipedematous scalp and lipedematous alopecia. *Eur J Dermatol* 2011; 21(4):520–528.





**Fig. 33-8** Triangular alopecia. (Courtesy of Brooke Army Medical Center Teaching File.)



**Fig. 33-9** Loss of follicular ostia in scarring alopecia.

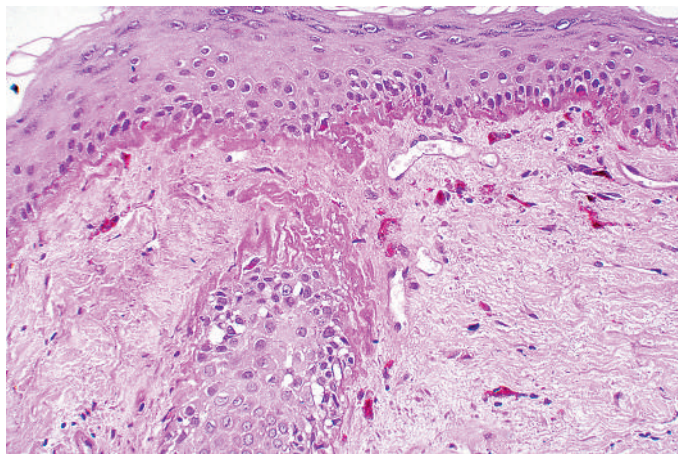
### Cicatricial alopecia

Cicatricial alopecia appears as areas of hair loss with absence of follicular ostia (Fig. 33-9). Acute lesions may appear as erythematous plaques, perifollicular papules, keratotic follicular spines, or pustules. Deep inflammatory lesions may be boggy or may resemble noncicatricial areata clinically. The inflammatory nature of the lesion may only be evident on biopsy.

Discoid lupus erythematosus (DLE), lichen planopilaris, sarcoidosis, and folliculitis decalvans are the most common inflammatory causes of cicatricial alopecia. Chronic bacterial and fungal infections may produce inflammatory alopecia that mimics primary scarring alopecia. For example, fungal folliculitis may mimic LE.

Biopsy can confirm the diagnosis and provide prognostic information regarding the potential for new growth. A 4-mm punch biopsy will provide the pathologist with an adequate specimen. Smaller specimens are of limited value. The punch should be placed parallel to the direction of hair growth to avoid transecting follicles, and the punch should be advanced to the deep subcutaneous fat. The biopsy site will typically bleed profusely, but a 4-mm-wide strip of gel foam advanced into the defect will generally provide rapid hemostasis. Sutures are rarely necessary, and because the scar from a sutured biopsy site generally stretches back to the original dimensions of the biopsy, suturing provides little benefit to the patient.

The biopsy should be taken from a well-established lesion that is still active, rather than from the advancing edge.



**Fig. 33-10** Basement membrane thickening in lupus erythematosus (periodic acid-Schiff [PAS] stain).

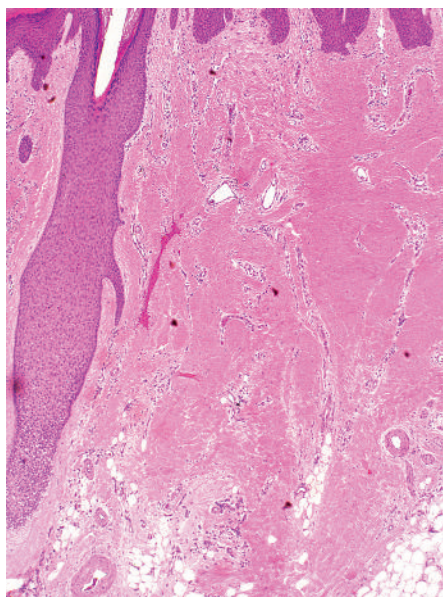
Dermoscopy may be helpful in selecting the biopsy site. The pathologist may prefer vertical or transverse (horizontal) sectioning of the specimen. Each has advantages. Every follicular unit in the specimen will be demonstrated in transverse sections. Vertical sections are superior for demonstrating changes in the surface epidermis, dermoepidermal junction (DEJ), superficial dermis, and subcutaneous fat. In general, the features of androgenetic (pattern) alopecia, telogen effluvium, and trichotillomania are better demonstrated in transverse (horizontal) sections through the specimen. Alopecia areata and syphilitic alopecia are well demonstrated in transverse sections if serial step sections are obtained to demonstrate deeper planes of section, or if the block is cut horizontally in a bread-loaf fashion before embedding. They are equally well demonstrated with serial vertical sections through the block. LE and lichen planopilaris are more easily demonstrated in serial vertical sections.

The diagnostic yield can be enhanced by pairing vertical and transverse sections. If two biopsies are done, one specimen can be bisected vertically for direct immunofluorescence (DIF) and hematoxylin and eosin (H&E) processing. It is most easily split by laying it on its side and bisecting it with a No. 15 blade pushed cleanly through the specimen in a single downward motion. Sawing at the specimen will not produce a satisfactory result. One-half the bisected specimen is placed in formalin and the other half in immunofluorescent media. The second specimen can be bisected for transverse sections in the clinic or left for the laboratory to bisect after processing. If to be bisected in the clinic, it should be placed on its side. The 15 blade should be pushed downward through the specimen in a single motion at the level of the middermis. All pieces for vertical and transverse sections may be placed in a single bottle to be embedded in a single cassette. If a single biopsy specimen is submitted for H&E sections, it can be bisected vertically, then one-half bisected transversely 1 mm above the fat (Tyler technique). This provides the advantages of both vertical and transverse sections with a single specimen.

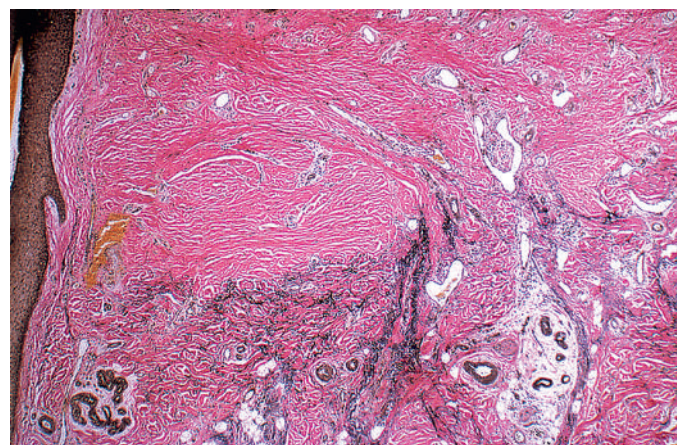
In LE, the biopsy must be from a lesion of several months' duration in order to demonstrate hyperkeratosis, follicular plugging, basement membrane zone thickening (Fig. 33-10), and dermal mucin. Only biopsies from established lesions of lupus will demonstrate reliable immunofluorescence.

When biopsies of the most active area of alopecia have failed to yield a definite diagnosis, a biopsy from a scarred area may provide additional information. Scars show loss of elastic tissue with the Verhoeff-van Gieson stain. The pattern of elastic tissue loss is the "footprint" of the preceding inflammatory process (Figs. 33-11 and 33-12), and remains the gold





**Fig. 33-11** Scarring alopecia (hematoxylin-eosin [H&E] stain).



**Fig. 33-12** Scarring alopecia (elastic stain). Normal elastic fibers (black) indicate the nonscarring portions of the dermis.

standard for evaluation of scarring alopecia, although polarized microscopy and immunofluorescence of H&E-stained sections can also be useful. Lichen planopilaris and folliculitis decalvans both affect the infundibulum. Both result in wedge-shaped superficial dermal scars. DLE results in scarring of both the follicular units and the intervening dermis. Morphea does not produce a scar, but rather hyalinization of collagen bundles with preservation of the elastic fibers. In idiopathic pseudopelade, the fibrous tract remnants are widened, but the elastic tissue sheath at the periphery of the fibrous tract is preserved.

Most patients with cicatricial alopecia experience gradual progression of the alopecia, and the prolonged course of the disease may lead to inappropriate therapeutic complacency. The progressive destruction of hairs will result in ever-expanding areas of permanent alopecia. Therefore, cicatricial alopecia must be treated aggressively and early to avoid permanent disfigurement. Surgical revision of the hairless plaque is an option for stable end-stage alopecia, but unless the underlying disease is controlled, surgery may only lead to a flare of the underlying disease with progression of hair loss. Therapy may be forestalled by the inability to establish a definite diagnosis. To help guide therapy for patients who defy diagnosis, work groups of the North American Hair Research Society have proposed a classification scheme based on the type and pattern of inflammation. Some forms of destructive alopecia are lymphocyte mediated; others are suppurative processes. The type of infiltrate and the portion of the pilosebaceous unit affected can be used to guide therapy. This classification system may also allow patients to enroll in clinical trials, even in the absence of a definite diagnosis.

**Fung MA, et al:** Elastin staining patterns in primary cicatricial alopecia. *J Am Acad Dermatol* 2013; 69(5):776–782.

**Horenstein MG, et al:** Follicular density and ratios in scarring and nonscarring alopecia. *Am J Dermatopathol* 2013; 35(8):818–826.

## Lymphoid-mediated disorders

### *Lupus erythematosus*

Chronic cutaneous (discoid) lupus of the scalp (DLE) is a common cause of cicatricial alopecia. In active disease, anagen hairs may be easily extracted from the involved area. Usually, erythema, atrophy, follicular plugging, and mottled hyperpigmentation and hypopigmentation are present. Patients with

chronic cutaneous lupus of the scalp may have accompanying SLE or skin lesions of DLE on other parts of the body. The external ear canal and concha should always be examined because they are common sites for discoid lesions. Occasionally, alopecia occurs in a plaque of tumid lupus. Lupus panniculitis may occasionally result in alopecia in the absence of surface skin changes. SLE is often associated with discoid lesions of the scalp. Patients with SLE may also have short miniaturized “lupus hairs” on the anterior scalp.

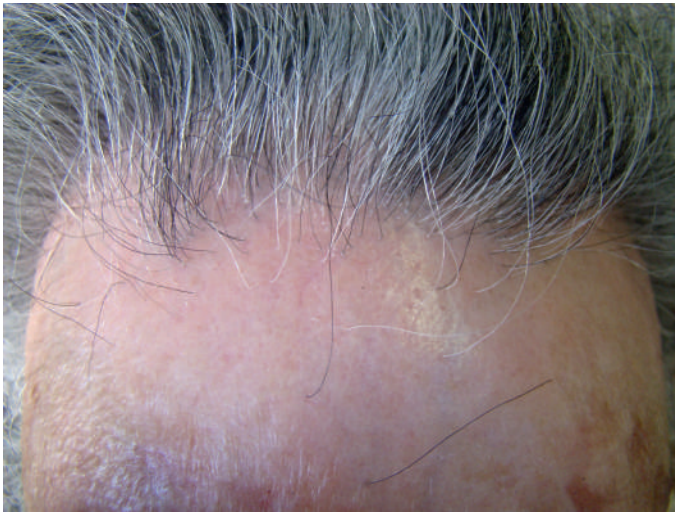Biopsy of early lesions of DLE is often nondiagnostic. Patchy lymphoid inflammation and perifollicular mucinous fibrosis may be the only histologic findings. Focal vacuolar interface dermatitis may or may not be noted. Active established lesions, present for several months, have a higher diagnostic yield. Active established lesions usually demonstrate hyperkeratosis, follicular plugging, vacuolar interface dermatitis, basement membrane zone thickening, pigment incontinence, and dermal mucin. Perivascular and periadnexal lymphoid infiltrates are patchy and involve the eccrine coil and fibrous tract remnants. Fibrous tract involvement creates dense vertical columns of lymphocytes. The underlying subcutaneous tissue may demonstrate nodular lymphoplasmacytic infiltrates and fibrin or hyaline rings around necrotic fat. Hypertrophic lesions of chronic cutaneous LE often demonstrate lichenoid dermatitis. DIF typically demonstrates continuous granular deposition of IgG, IgA, IgM, and C3 at the DEJ (“full house” pattern). This pattern is particularly helpful in distinguishing lichenoid hypertrophic LE from lichen planopilaris. Burnt-out lesions of DLE demonstrate loss of elastic fibers throughout the dermis, which differs from the focal peri-infundibular wedge-shaped scars of lichen planopilaris. In SLE, follicular atrophy may be associated with pronounced dermal mucinosis.

Chronic cutaneous lupus may respond to intralesional or potent topical corticosteroids, but systemic therapy is frequently required. Antimalarials, retinoids, dapsone, thalidomide, sulfasalazine, mycophenolate mofetil, and methotrexate have been used successfully. Topical tazarotene and topical calcineurin inhibitors are generally disappointing.

### *Lichen planopilaris*

Lichen planopilaris presents with perifollicular erythema and progressive scarring. Small follicular papules may be noted, or the lesion may resemble the ivory-white irregular patches of pseudopelade. In some patients, typical polygonal flat-topped papules are present on the wrists and ankles, and lacy white lesions are noted on the oral and genital mucosa. Widespread follicular papules may be present on the trunk or





**Fig. 33-13** Frontal fibrosing alopecia. (Courtesy of Dr. Don Adler.)

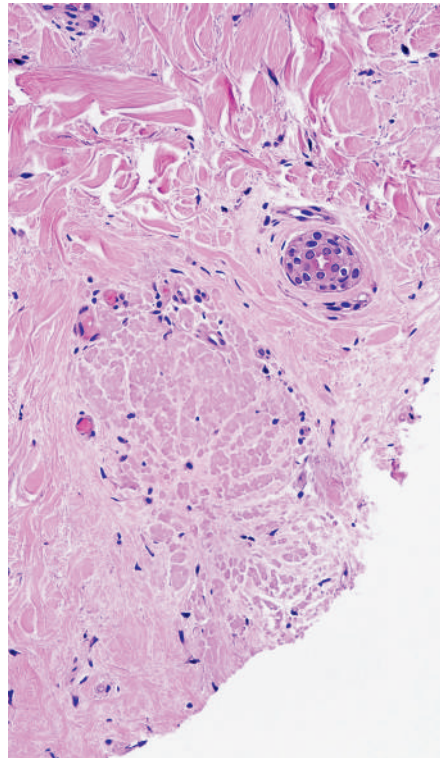
extremities. In most patients, however, only the scalp is involved. Frontal fibrosing alopecia appears to be a variant of lichen planopilaris. Most patients are older women with band-like frontotemporal alopecia (Fig. 33-13), often with “genitalized” kinky hairs. Graham Little-Piccardi-Lasseur syndrome includes cicatricial alopecia on the scalp, keratosis pilaris in the skin of the trunk and extremities, and noncicatricial hair loss in the pubis and axillae. It has been described in association with complete androgen insensitivity syndrome, a condition that also presents with noncicatricial alopecia in the axillary and pubic hair.

Diagnostic biopsies demonstrate lichenoid interface dermatitis of the follicular unit and sometimes the intervening epidermis. The entire fibrous tract may be filled with cytoid bodies (Fig. 33-14). The changes usually occur focally and may be best visualized with serial vertical sections. Perifollicular mucinous fibrosis is common, and focal perifollicular lymphoid infiltrates tend to involve the infundibulum (infiltrates of LE tend to involve isthmus). DIF may be negative or may reveal cytoid bodies and shaggy linear fibrin at the DEJ.

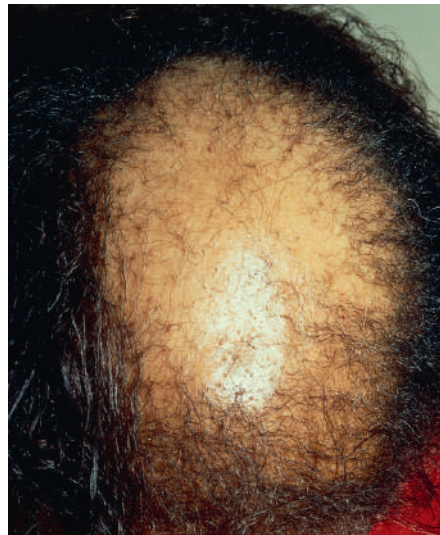Lichen planopilaris responds to oral and intralesional corticosteroids. Topical corticosteroids may be adequate in a few patients, but resulting scalp atrophy with prominence of capillary plexus may be misinterpreted as erythema signifying active disease. As in lupus, topical tazarotene and topical macrolactams are generally disappointing. Oral retinoids and excimer laser can be effective, but antimalarials are usually not effective in preventing disease progression. Similarly, the peroxisome proliferator activated receptor- $\gamma$  agonist pioglitazone is ineffective at halting progression in the majority of patients. In the authors’ experience, mycophenolate mofetil is generally reliable for patients with refractory disease. Biologics have been suggested as therapy, but onset of lichen planopilaris has been noted during etanercept therapy. Dutasteride is often effective as first line therapy in the setting of frontal fibrosing alopecia.

### **Central centrifugal cicatricial alopecia**

Central centrifugal cicatricial alopecia (CCCA) is seen most often in African American women, is slowly progressive, usually begins in the crown, and advances to the surrounding areas (Fig. 33-15). The term is often used as a broad category that includes “hot comb alopecia,” idiopathic pseudopelade, and central elliptical alopecia. Some patients will demonstrate crops of crusts at the periphery of the patches, a feature of folliculitis decalvans. Treatment of CCCA is difficult and often



**Fig. 33-14** Lichen planopilaris. Note cytoid bodies completely filling the fibrous tract remnant.



**Fig. 33-15** Central centrifugal cicatricial alopecia.

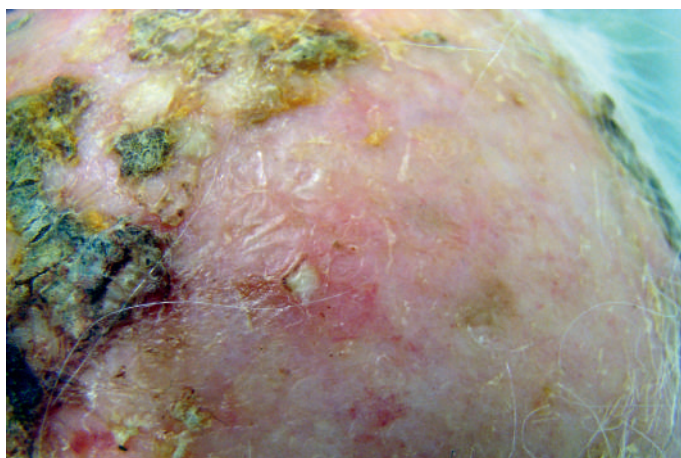
unsatisfactory. Discontinuation of chemical and heat processing and reduction of traction are recommended. Patients with overlapping features of folliculitis decalvans may respond to long-term antibiotic therapy and topical corticosteroids. In such overlapping cases, the histology shows a lymphocytic infiltrate during the chronic stage, but periodic crops of pustules demonstrate a neutrophilic folliculitis.

## **Neutrophil-mediated disorders**

### **Folliculitis decalvans**

Folliculitis decalvans presents with crops of pustules that result in cicatricial alopecia. Successive crops of pustules, crusts, or erosions lead to expansion of the alopecic patches. Staphylococci are sometimes cultured from the lesions, and some authors have suggested that folliculitis decalvans merely





**Fig. 33-16** Erosive pustular dermatitis.

represents a chronic staphylococcal infection. It is more likely that follicular destruction is the result of an abnormal suppurative immune response. Staphylococci and other organisms probably play a role in inciting the response. Erlotinib-induced folliculitis decalvans has been reported. The lesions often respond to long-term treatment with a tetracycline. The improvement may reflect the antineutrophil effects of the drug or its antimicrobial effects. Many patients also respond to other forms of antistaphylococcal therapy, but the lesions generally recur after the antibiotic is discontinued. In contrast, long-term tetracycline treatment generally results in a continued response. Some sustained responses have been noted after combination therapy with rifampin and clindamycin. Rifampin alone may promote the emergence of bacterial resistance. Selenium sulfide shampoo and topical corticosteroids may be useful as adjunctive therapy. Oral retinoids, oral and topical fusidic acid, oral zinc sulfate, photodynamic therapy (PDT) and topical tacrolimus have been reported as successful, and anti-TNF biologics have been used for refractory disease.

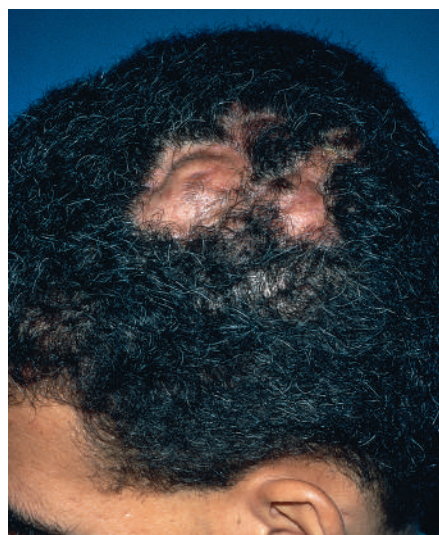A variant of folliculitis decalvans occurs in African American patients who present with pseudofolliculitis of the beard, acne keloidalis nuchae, and scarring alopecia in the vertex and parietal scalp. The scalp demonstrates ingrown hairs, crops of pustules or crusts, and permanent scarring alopecia. Although pseudofolliculitis barbae is generally accepted to be the result of ingrown hairs, the pathogenesis of acne keloidalis nuchae remains in question. Histologically, ingrown hairs are common in advanced lesions. Early lesions may not demonstrate the hair. Some patients merely develop small papules on the nape of the neck, whereas others develop pustules, crusts, and progressive alopecia. This latter group overlaps with folliculitis decalvans, and patients generally respond to treatment with a topical corticosteroid and an oral tetracycline.

### **Acne necrotica**

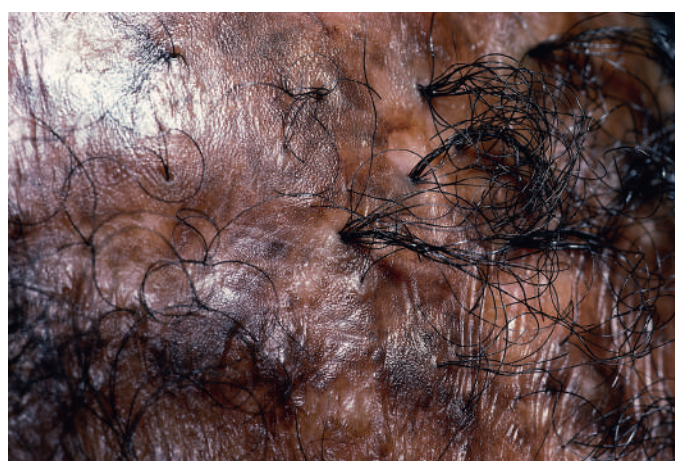Acne necrotica presents with discrete excoriated follicular papules in the scalp. Biopsy demonstrates an inflammatory crust and suppurative folliculitis. Usually, there is no associated scarring alopecia, but occasional cases overlap with folliculitis decalvans.

### **Erosive pustular dermatitis of the scalp**

Pustular dermatitis often presents as expanding eroded patches on the scalp with moist granulation tissue (Fig. 33-16). The lesions often follow trauma or a surgical procedure and tend to be chronic and progressive. They respond best to class I topical corticosteroids. PDT has also been used effectively.



**Fig. 33-17** Dissecting cellulitis.



**Fig. 33-18** Tufted doll's hairs, cicatricial alopecia.

### **Dissecting cellulitis (*perifolliculitis capitis abscessens et suffodiens of Hoffman*)**

Dissecting cellulitis often coexists with acne conglobata and hidradenitis suppurativa. It may also occur with folliculitis decalvans. The lesions are deep, boggy, and suppurative (Fig. 33-17). They may respond to tetracyclines, retinoids, and intralesional corticosteroids.

### **Tufted folliculitis**

Tufted folliculitis presents with doll's hair-like bundling of follicular units. It is seen in a wide range of scarring conditions, including chronic staphylococcal infection, chronic LE, lichen planopilaris, Graham Little syndrome, folliculitis decalvans (Fig. 33-18), acne keloidalis nuchae, immunobullous disorders, and dissecting cellulitis. Compound hairs (two or more hairs sharing a common infundibulum) occur physiologically on the occipital scalp and legs and should not be confused with tufted folliculitis.

### **Other forms of permanent alopecia**

#### **Pseudopelade of Brocq**

Also known as alopecia cicatrizzata, this pseudopelade is a rare form of cicatricial alopecia in which destruction of the hair follicles produces multiple round, oval, or irregularly shaped,



hairless, cicatricial patches of varying sizes. They are usually coin sized and are white or slightly pink in color, with a smooth, shiny, marblelike or ivory, atrophic, “onion skin” surface. Interspersed in the patches may be a few spared follicles with hairs growing from them. A clinical inflammatory stage is completely absent. No pustules, crusts, or broken-off hairs are present. The onset, as a rule, is insidious, with one or two lesions appearing on the vertex. The condition affects females three times more often than males and has a prolonged course. In advanced cases, large irregular patches are formed by coalescence of some of the many small macules, a pattern referred to as “footprints in the snow.” The alopecia is permanent and the disease slowly progressive. Most cases of pseudopelade demonstrate scarring in a wedge-shaped pattern in the superficial dermis and represent an end stage of lichen planopilaris. A distinct subset called idiopathic pseudopelade accounts for most patients with CCCA. In these patients, the dermis is contracted into a thin band of dense collagenous tissue. Elastic fibers are intact and quite thick as a result of elastic recoil related to dermal contraction. Fibrous tract remnants are wide and hyalinized with an intact elastic sheath. Lymphoid and neutrophilic inflammation is absent, but loss of the inner and outer root sheaths with subsequent hair fiber granuloma formation is noted. Sebaceous glands are decreased or absent, as they are in most forms of permanent alopecia. DIF is negative.

### Traction alopecia

Traction alopecia occurs from prolonged tension on the hair, either from wearing the hair tightly braided or in a ponytail, pulling the hair to straighten it, rolling curlers too tightly, or from the habit of twisting the hairs with the fingers. Traction alopecia most often involves the periphery of the scalp, especially the temples and above the ears, but a fringe of hair is characteristically present at the frontal and temporal hairline (Fig. 33-19).

### Sarcoidosis

Sarcoidosis of the scalp presents with diffuse or patchy hair loss. The involved scalp is often indurated, and a raised peripheral border may be present. The lesions are often red-brown in color and may have an “apple jelly” appearance on diascopy. Biopsy reveals noncaseating granulomas. Treatment is the same as for other forms of sarcoidosis.



Fig. 33-19 Traction alopecia.

### Pressure alopecia

Pressure alopecia occurs in adults after prolonged pressure on the scalp during general anesthesia, with the head fixed in one position. It may also occur in chronically ill persons after prolonged bed rest in one position (Fig. 33-20), which causes persistent pressure on one part of the scalp. It probably arises because of pressure-induced ischemia.

### Tumor alopecia

Tumor alopecia refers to hair loss in the immediate vicinity of either benign or malignant tumors of the scalp. Syringomas, nerve sheath myxomas, and steatocystoma multiplex are benign tumors that may be limited to the scalp and may cause alopecia. Alopecia neoplastica is the designation given to hair loss from metastatic tumors, most often from breast or renal carcinoma (Fig. 33-21).

### Keratosis pilaris atrophicans

Keratosis pilaris atrophicans includes many forms of keratosis pilaris with cicatricial alopecia. Variants include keratosis pilaris atrophicans faciei, atrophoderma vermiculatum, keratosis follicularis spinulosa decalvans, and ichthyosis follicularis.

Keratosis pilaris atrophicans faciei (ulerythema ophryogenes, keratosis pilaris rubra atrophicans faciei, folliculitis

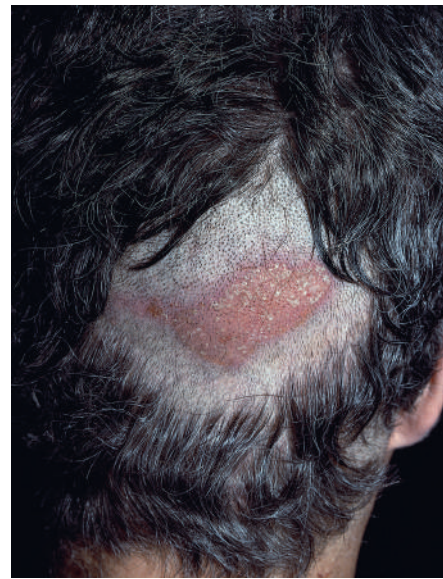

Fig. 33-20 Pressure alopecia with scalp demonstrating pressure-induced geometric pressure necrosis.

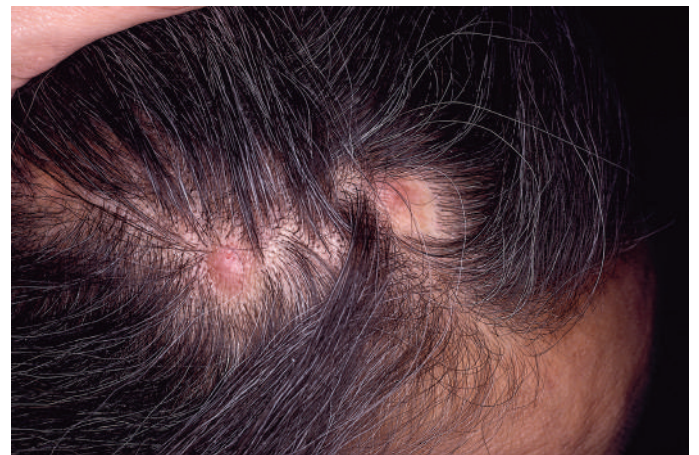

Fig. 33-21 Alopecia neoplastica.



rubra, lichen pilare, xerodermie pileaire symétrique de la face) begins in infancy as follicular papules with perifollicular erythema. Initially, the lesions are restricted to the lateral eyebrows. With time, they spread to involve the cheeks and forehead. There may be associated keratosis pilaris on the extremities and buttocks. The condition may also be associated with an atopic diathesis, ectodermal dysplasia, or Noonan syndrome.

Atrophoderma vermiculatum (acne vermoulanti, honeycomb atrophy, folliculitis ulerythematososa reticulata, ulerythema acneiforme, folliculitis ulerythematosus reticulata, atrophoderma reticulata symmetrica faciei, atrophoderma reticulatum) presents with erythematous follicular papules on the cheeks in childhood. With time, the lesions develop into pitlike depressions (reticulate atrophy). Autosomal dominant inheritance has been described. This condition generally spares the scalp and eyebrows.

Keratosis follicularis spinulosa decalvans is a rare X-linked disorder described by Siemens in 1926. The gene has been mapped to Xp21.2-p22.2. It begins in infancy with keratosis pilaris localized on the face, then evolves to more diffuse involvement. Progressive cicatricial alopecia occurs on the scalp, eyebrows, and sometimes eyelashes. The alopecia starts during childhood, and active disease may remit during the early teenage years. Corneal and conjunctival inflammation, corneal dystrophy, and blepharitis occur, and photophobia is usually a prominent finding.

Ichthyosis follicularis also demonstrates extensive spiny follicular hyperkeratosis, permanent alopecia, and photophobia. Palmar plantar keratosis, nail deformities, atopy, and recurrent cheilitis have been described.

### ***Atrichia with papular lesions***

Atrichia with papular lesions is a rare autosomal recessive disorder with early onset of atrichia, followed by a papular eruption appearing within the first years of life. The condition has been linked to chromosome 8p21, and mutations have been detected in what is now referred to as the hairless gene. It is discussed in more detail in Chapter 27.

**Bastida J, et al:** Treatment of folliculitis decalvans with tacrolimus ointment. *Int J Dermatol* 2012; 51(2):216–220.

**Callender VD, et al:** Hair breakage as a presenting sign of early or occult central centrifugal cicatricial alopecia: clinicopathologic findings in 9 patients. *Arch Dermatol* 2012; 148(9):1047–1052.

**Donovan JC, et al:** Transversely sectioned biopsies in the diagnosis of end-stage traction alopecia. *Dermatol Online J* 2013; 19(4):11.

**Elston CA, et al:** Elastic staining versus fluorescent and polarized microscopy in the diagnosis of alopecia. *J Am Acad Dermatol* 2013; 69(2):288–293.

**Elston D:** The “Tyler technique” for alopecia biopsies. *J Cutan Pathol* 2012; 39(2):306.

**Keith DJ, et al:** Erlotinib-induced folliculitis decalvans. *Clin Exp Dermatol* 2013; 38(8):924–925.

**Loganathan E, et al:** Complications of hair restoration surgery: a retrospective analysis. *Int J Trichology* 2014; 6:168.

**Loh SH, et al:** Pressure alopecia: clinical findings and prognosis. *J Am Acad Dermatol* 2015; 72:188.

**MacDonald A, et al:** Frontal fibrosing alopecia: a review of 60 cases. *J Am Acad Dermatol* 2012; 67(5):955–961.

**Mihaljević N, et al:** Successful use of infliximab in a patient with recalcitrant folliculitis decalvans. *J Dtsch Dermatol Ges* 2012; 10(8):589–590.

**Miteva M, et al:** Dermoscopy guided scalp biopsy in cicatricial alopecia. *J Eur Acad Dermatol Venereol* 2013; 27(10):1299–1303.

**Navarini AA, et al:** Low-dose excimer 308-nm laser for treatment of lichen planopilaris. *Arch Dermatol* 2011; 147(11):1325–1326.

**Rác Z, et al:** Treatment of frontal fibrosing alopecia and lichen planopilaris: a systematic review. *J Eur Acad Dermatol Venereol* 2013; 27(12):1461–1470.

**Rodney LJ, et al:** Hair and scalp disorders in ethnic populations. *J Drugs Dermatol* 2013; 12(4):420–427.

**Shao H, et al:** Follicular unit transplantation for the treatment of secondary cicatricial alopecia. *Can J Plast Surg* 2014; 22:249.

**Spring P, et al:** Lichen planopilaris treated by the peroxisome proliferator activated receptor- $\gamma$  agonist pioglitazone: lack of lasting improvement or cure in the majority of patients. *J Am Acad Dermatol* 2013; 69(5):830–832.

**Ye Y, et al:** Non-scarring patchy alopecia in patients with systemic lupus erythematosus differs from that of alopecia areata. *Lupus* 2013; 22(14):1439–1445.

## HAIR COLOR

Melanin in the hair follicles is produced in the cytoplasm of the melanocytes. Organelles involved include the endoplasmic reticulum, ribosomes, and Golgi apparatus. Melanocytes producing hair pigment are associated with the hair matrix, and melanogenesis occurs only during anagen. This cyclic melanin synthesis distinguishes follicular melanogenesis from the continuous melanogenesis of the epidermis. With age, cyclic melanocytic activity in the follicular unit declines. By age 40, most individuals show evidence of graying. Graying results primarily from a reduction in tyrosinase activity within hair bulb melanocytes. Defective migration of melanocytes from a diminishing reservoir in the outer root sheath may play a role. Physiologic graying may also be related to reactive oxygen species-mediated damage to nuclear and mitochondrial DNA in bulbar melanocytes. The melanocortin 1 receptor gene (*MCR1*) is closely related to red hair, freckling, and sun sensitivity.

The pigment in black and dark-brown hair is composed of eumelanin, whereas in blond and red hair, it is pheomelanin. In black hair, the melanocytes contain the densest melanosomes. Brown hair differs only by its smaller melanosomes. Light-brown hair consists of a mixture of the melanosomes of dark hair and the incomplete melanosomes of blond hair. Many of the melanosomes in blond hair develop only on the matrix fibers and not in the spaces between the fibers.

Red hair shows incomplete melanin deposits on the matrix fibers, to produce a blotchy-appearing melanosome. Pheomelanin is distinguished by its relatively high content of sulfur, which results from the addition of cysteine to dopaquinone along the biosynthetic pathway of melanin synthesis.

In gray hair (canities), melanogenic activity is decreased as a result of fewer melanocytes and melanosomes, as well as a gradual loss of tyrosinase activity. Graying of the scalp hair is genetically determined and may start at any age. Usually, it begins at the temples and progresses with time. The beard usually follows, with the body hair graying last. Premature whitening of scalp hair is usually caused by vitiligo, sometimes without recognized, or actually without, lesions of glabrous skin.

Early graying (before age 20 in white or before age 30 in black persons) is usually familial; however, it may occur in progeria and in Rothmund-Thomson, Böök (PHC), and Werner syndromes, as well as after radiation exposure.

In poliosis, gray or white hair occurs in circumscribed patches. This may occur in Waardenburg syndrome and piebaldism, Tietz syndrome, Alezzandrini syndrome, neurofibromatosis, and tuberous sclerosis. Poliosis is also found in association with regressing melanoma, vitiligo, and Vogt-Koyanagi syndrome and may be seen in alopecia areata when the new hairs grow. Migratory poliosis without hair loss may represent a forme fruste of alopecia areata.

Green hair has been traced to copper in the water of a swimming pool. This occurs only in blond or light hair and may be treated with topical EDTA, penicillamine-containing

shampoos, or 1.5% aqueous 1-hydroxyethyl diphosphonic acid. Tars and chrysoarobin stain light-colored hair brown.

Changes in hair color occur in various disorders. The hair is blond in phenylketonuria and homocystinuria. Light hair is also seen in oasthouse urine disease (familial methionine malabsorption syndrome), Menkes steely (kinky) hair syndrome, and albinism. In Griscelli and Chédiak-Higashi syndromes, the hair has a silvery sheen. In kwashiorkor, hair assumes a red-blond color and may demonstrate periodic banding (flag sign, segmental heterochromia). Alternating light and dark bands may also occur in iron deficiency anemia and with courses of sunitinib. In vitamin B<sub>12</sub> deficiency and with IFN therapy, whitening may occur. The disorder has been called canities segmentata sideropenica and responds completely to iron supplementation. Triparanol is associated with hypopigmented hair. By changing vellus to terminal hairs, minoxidil causes darkening of hair. Another hypotensive agent, diazoxide, gives the hair a reddish tint. Chloroquine therapy may cause hair whitening, usually in redheads and blonds, but not in brunettes. Pigmentation of the eyelashes and irides has been described with latanoprost. Xanthotrichia (yellow hair) has been noted with selenium sulfide and dihydroxyacetone.

Many black patients with acquired immunodeficiency syndrome (AIDS) have experienced softening, straightening, lightening, and thinning of their hair. Patients with human immunodeficiency virus 1 (HIV-1) infection may also experience elongated eyelashes and telogen effluvium.

**Liu F, et al:** Colorful DNA polymorphisms in humans. *Semin Cell Dev Biol* 2013; 24(6/7):562–575.

**Praetorius C, et al:** A Polymorphism in IRF4 affects human pigmentation through a tyrosinase-dependent MITF/TFAP2A pathway. *Cell* 2013; 155(5):1022–1033.

## HAIR STRUCTURE DEFECTS

Examination of hairs for structural defects is greatly facilitated by a method devised by Shelley: putting a piece of double-stick tape on a microscope slide and aligning 5-cm segments of hair in parallel on it. Dermoscopy can be useful in assessing hair morphology. Microscopic mounts of hairs are best examined under a dissecting microscope or polarized light. Gold coating and scanning electron microscopy (SEM) can also be done on hairs so mounted. Hairs from multiple body sites may need to be sampled. This has been documented in Netherton syndrome, where scalp hair can be normal while eyebrow hair demonstrates the characteristic hair shaft defect.

### Hair casts (pseudonits)

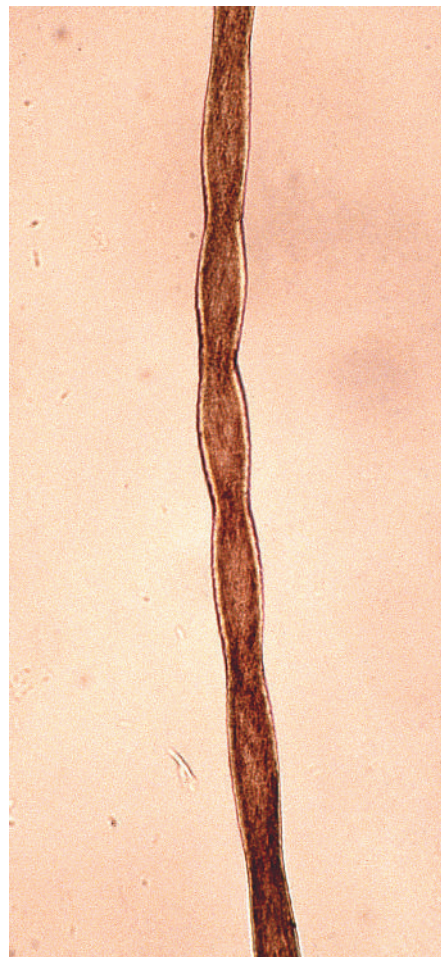Hair casts represent remnants of the inner root sheath. They often occur in great numbers and may mimic nits in the scalp. Whereas nits are firmly cemented to the hair shaft, however, hair casts slide freely along the shaft. Taeb et al. reviewed 36 published cases and distinguished two groups: girls age 2–8 years with diffuse involvement and no scalp disease, and children and adults with psoriasis, lichen planus, seborrheic dermatitis, traction, or trichotillomania. Keipert made a similar distinction, separating a large group of cases with some keratinizing disorder of the scalp and dark, oddly shaped masses of keratin adherent to or surrounding the hairs, which he called “parakeratotic” hair casts; and lighter-colored tubular casts 2–4 mm long, which he called “peripilar” hair casts. Taeb et al. found 0.025% tretinoin lotion to be effective. False hair casts may occur as a result of hair spray or deodorant concretions. Immunoglobulin casts and cutaneous spicules have been noted in multiple myeloma.

## Pili torti

Also known as “twisted hairs,” pili torti is a malformation of hair characterized by twisting of the hair shaft on its own axis (Fig. 33-22). The hair shaft is segmentally thickened, and light and dark segments are seen. Scalp hair, eyebrows, and eyelashes may be affected. The hairs are brittle and easily broken.

In the classic type, unassociated with other disorders, onset is usually in early childhood; by puberty, it has usually improved. Clinically, pili torti may be associated with patchy alopecia and short, broken hairs. It usually follows a dominant inheritance pattern, although recessive and sporadic cases have been reported. Acquired cases have been described in young women with anorexia nervosa. Pili torti may be seen with associated abnormalities. The Björnstad syndrome consists of congenital deafness of the cochlear type, with pili torti. Both autosomal dominant and autosomal recessive inheritance patterns have been described. *BCS1L* mutations cause the Björnstad syndrome. The gene encodes an adenosine triphosphatase (ATPase) necessary for the assembly of complex III in mitochondria. *BCS1L* mutations also cause lethal conditions, including the complex III deficiency and the GRACILE syndrome, with severe multisystem and neurologic manifestations.

Pili torti also may occur in citrullinemia (argininosuccinate synthetase deficiency), Menkes steely (kinky) hair syndrome, Bazex follicular atrophoderma syndrome, ectodermal dysplasias, Crandall syndrome (pili torti, nerve deafness, hypogonadism), Netherton syndrome (along with bamboo hair), with isotretinoin and etretinate therapy, in anorexia nervosa, and in trichothiodystrophy.



**Fig. 33-22** Pili torti.



Laron syndrome is an autosomal recessive disease with primary insulinlike growth factor 1 deficiency and primary growth hormone insensitivity. Affected children have sparse hair and frontal recession. Pili torti et canaliculi, tapered hair, and trichorrhexis nodosa have been noted.

### Menkes steely (kinky) hair syndrome

Pili torti and often monilethrix and trichorrhexis nodosa are all common in the hairs in this sex-linked recessively inherited disorder. It has also been called steely hair disease because the hair resembles steel wool. The characteristic ivory color of the hair appears between 1 and 5 months of age. Drowsiness, lethargy, convulsive seizures, severe neurologic deterioration, and periodic hypothermia ensue, with death at an early age. Hairs become wiry, sparse, fragile, and twisted about their long axis. Osteoporosis, and dental and ocular abnormalities are common. The skin is pale and the face pudgy, and the upper lip has an exaggerated "Cupid's bow" configuration. The occipital horn syndrome, primarily a connective tissue disorder, is a milder variant of Menkes syndrome. Patients have a deficiency of serum copper and copper-dependent enzymes, resulting from mutations in the *ATP7A* gene. The gene encodes a trans-Golgi membrane-bound copper transporting P-type ATPase. Loss of this protein activity blocks the export of dietary copper from the GI tract and causes the copper deficiency. Low serum copper and ceruloplasmin levels are characteristic, but are not seen in all patients; levels are particularly variable in the first weeks of life. Other tests helpful for screening include the ratio of catechols, such as dihydroxyphenylalanine, to dihydroxyphenylglycol. High levels of the catechols dopa, dihydroxyphenylacetic acid, and dopamine and low levels of dihydroxyphenylglycol are characteristic. Studies of copper egress in cultured fibroblasts have also been used.

Early detection allows for genetic counseling and institution of copper histidine treatment, which has shown promising results in some infants. Pamidronate treatment is associated with an increase in bone mineral density in children with Menkes disease. In zebra fish, antisense morpholino oligonucleotides directed against the splice-site junctions of two mutant calamity alleles were able to correct the molecular defect. Also, L-threo-dihydroxyphenylserine can correct neurochemical abnormalities in a mouse model. This is a promising area for research.

### Trichorrhexis nodosa

The affected hair shafts fracture easily and may have small white nodes arranged at irregular intervals. These nodes are the sites of fraying of the hair cortex. The splitting into strands produces a microscopic appearance suggestive of a pair of brooms stuck together end to end by their bristles. The hairs soon break at these nodes (Fig. 33-23). The number of these nodes along one hair shaft varies from one to several, depending on its length. These fractured hairs are found mostly on the scalp, often in just a small area or areas, but other sites, such as the pubic area, axillae, and chest, may be involved.

Several categories or types of trichorrhexis nodosa have been described. Proximal trichorrhexis nodosa involves the proximal shafts of the hairs of black patients who traumatize their hair with styling or chemicals. The involved hairs break a few centimeters from the skin surface, resulting in patches of short hair. It appears to occur in genetically predisposed patients. Distal trichorrhexis nodosa affects primarily Asians and white patients; it occurs several inches from the scalp and



Fig. 33-23 Trichorrhexis nodosa.

is associated with trichoptilosis, or longitudinal splitting, known as "split ends." Acquired localized trichorrhexis nodosa is a common type in which the defect occurs in a localized area a few centimeters across. Diseases that accompany localized trichorrhexis nodosa in which pruritus is a prominent symptom (perhaps caused by scratching and rubbing) include circumscribed neurodermatitis, contact dermatitis, and atopic dermatitis.

The occurrence of trichorrhexis nodosa in some patients with argininosuccinic aciduria has suggested an etiologic connection. Trichorrhexis nodosa has been described in Menkes steely hair syndrome, Netherton syndrome, hypothyroidism, ectodermal dysplasia, the syndrome of intractable infant diarrhea, biotinidase deficiency, and trichothiodystrophy. Trichoschisis, a clean transverse fracture across the hair shaft, is more often present in trichothiodystrophy. The curly hair that may result from isotretinoin therapy has been attributed to extensive trichorrhexis nodosa. Because trauma may induce this hair shaft abnormality, the specificity of this finding in the previous conditions may simply be fortuitous. Treatment is directed toward the avoidance of trauma to the hair.

### Trichorrhexis invaginata

Also known as "bamboo hair," trichorrhexis invaginata is caused by intussusception of the hair shaft at the zone where keratinization begins. The invagination is caused by softness of the cortex in the keratogenous zone. The softness may be caused by inadequate conversion of -SH to S-S proteins in the cortex. The patient with bamboo hair will have nodose ball-and-socket deformities, with the socket forming the proximal and the ball part forming the distal portion of the node along the hair shaft. This type of hair is associated with Netherton syndrome. Occasionally, only the proximal half of the abnormality is seen; this has been called "golf tee hairs."

Trichorrhexis invaginata associated with congenital ichthyosiform erythroderma or ichthyosis linearis circumflexa constitutes Netherton syndrome. Atopic manifestations and high IgE levels are typically present. The bamboo hairs may be present not only on the scalp but also on the eyebrows, eyelashes, and rarely in other hairy areas. Hair sparsity is noted all over the body. The bamboo hairs may become normal within a few years. Other reported findings include pili torti, trichorrhexis nodosa, moniliform hairs, urticaria, angioedema, growth retardation, recurrent infections, multiple epithelial neoplasms, and mental retardation. An autosomal recessive mode of inheritance has been suggested, although reported

cases involving women far outnumber men. Pathogenic mutations have been identified in serine protease inhibitor Kazal-type 5 (*SPINK5*) on chromosome 5q32, a gene encoding lymphoepithelial Kazal-type-related inhibitor (LEKTI), a serine protease inhibitor involved in skin barrier formation and immunity. PUVA therapy has been reported to help the circumflex linear ichthyosis, and etretinate has both exacerbated and improved skin findings.

Menne et al. reported the bamboo hair defect in very thin, probably vellus, hairs in a 7-year-old boy with short, thin, brittle scalp hairs and no eyebrows. They termed this a “cane-stick deformity.”

### Pili annulati (ringed hair, spangled hair)

Pili annulati is an unusual disease in which the hair seems banded by alternating segments of light and dark color when seen in reflected light. The light bands are caused by clusters of abnormal air-filled cavities, which scatter light, and reduplicated lamina densa in the region of the root bulb. Hair growth is normal in patients with pili annulati, although it is rarely associated with trichorrhexis nodosa-like breaks of the hair shaft. There are no other associated abnormalities of skin or other organ systems. It is inherited by autosomal dominant mode, begins in infancy, and requires no treatment, since the spangled appearance of the hair is not unattractive. The condition has been reported to disappear following recovery from alopecia totalis.

### Pili pseudoannulati

This anomaly of human hair mimics pili annulati. The two differ in that the light bands in pili annulati are caused by internal effects, whereas the bright segments in pili pseudoannulati are caused by reflection and refraction of light by flattened, twisted surfaces of hair. The pseudo type is a variant of normal hair.

### Monilethrix

Monilethrix, also known as “beaded hairs,” is a rare hereditary disease. It is characterized by dryness, fragility, and sparseness of the scalp hair (Fig. 33-24), with fusiform or spindle-shaped swellings of the hair shaft separated by narrow atrophic segments. The hair tends to break at the delicate internodes. There is an occasional rupture at the node and longitudinal fissuring of the shaft, which also involves the nodes.

The disease is often associated with keratosis pilaris of the extensor surfaces, temples, and back of the neck. Hair on regions other than the scalp may be affected. Leukonychia may occur. Inheritance of monilethrix is an autosomal dominant trait. It has been described in association with Menkes syndrome. Mutations in the gene for desmoglein 4 are seen in monilethrix and in localized autosomal recessive hypotrichosis, a disorder that shares clinical features with monilethrix but lacks the characteristic hair shaft changes. Several cases of monilethrix have been linked to the type II keratin gene cluster on chromosome 12q13. Causative heterozygous mutations of a highly conserved glutamic acid residue of the type II hair keratins hHb6 and hHb1 occur. Both hHb1 and hHb6 are largely coexpressed in cortical trichocytes of the hair shaft, confirming that monilethrix is a disease of the hair cortex. The hair may improve during pregnancy, but after delivery, the hair returns to its original state. Improvement may also occur with age, and there may be seasonal

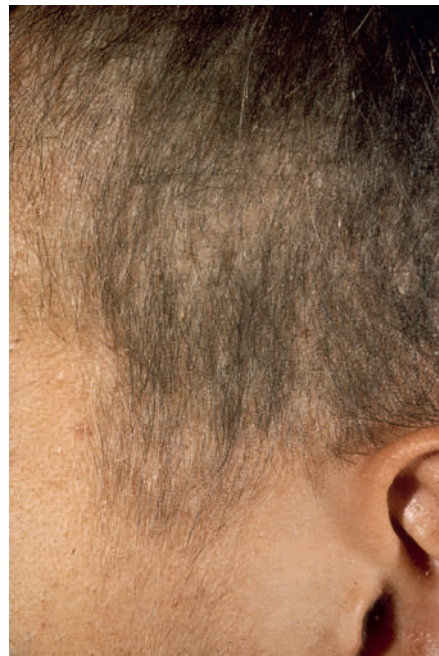

Fig. 33-24 Monilethrix.

improvement during the summer. Improvement with acitretin has been reported.

### Intermittent hair follicle dystrophy

Birnbaum et al. reported a disorder of the hair follicle leading to increased fragility of the shaft, with no identifiable biochemical disturbance. The prevalence of this disorder is unknown.

### Bubble hair deformity

Bubble hairs appear as areas of hair with altered texture. Fragility has been reported. The hairs may be curved or straight and stiff. Small, bubble-like defects are found within the hair shafts on light microscopy and electron microscopy. The condition is produced by overheating of wet hair with a malfunctioning hair dryer, analogous to the popping of popcorn. All damp hair will develop bubbles of gas when exposed to high heat.

- Bindurani S, et al:** Monilethrix with variable expressivity. *Int J Trichology* 2013; 5(1):53–55.
- Calvieri S, Rossi A:** Alopecia in genetic diseases. *G Ital Dermatol Venereol* 2014; 149:1.
- Donsante A, et al:** L-threo-dihydroxyphenylserine corrects neurochemical abnormalities in a Menkes disease mouse model. *Ann Neurol* 2013; 73(2):259–265.
- Leitner C, et al:** Pitfalls and pearls in the diagnosis of monilethrix. *Pediatr Dermatol* 2013; 30(5):633–635.
- Lünnemann L, et al:** Hair-shaft abnormality in a 7-year-old girl: trichorrhexis nodosa dueto biotinidase deficiency. *JAMA Dermatol* 2013; 149(3):357–363.
- Ozuguz P, et al:** Generalized hair casts due to traction. *Pediatr Dermatol* 2013; 30(5):614–615.
- Shao L, Newell B:** Light microscopic hair abnormalities in children: retrospective review of 119 cases in a 10-year period. *Pediatr Dev Pathol* 2014; 17:36.
- Tümer Z:** An overview and update of *ATP7A* mutations leading to Menkes disease and occipital horn syndrome. *Hum Mutat* 2013; 34(3):417–429.
- Werner K, et al:** Pili annulati associated with hair fragility: cause or coincidence? *Cutis* 2013; 91(1):36–38.



## Uncombable hair syndrome

First reported in 1973 by Dupré et al. as *cheveux incoiffables* (“undressable hairs”) and by Stroud and Mehergan as “spun-glass hair,” the microscopic abnormality of a triangular cross-sectional appearance with a longitudinal groove gives the disease its other name, *pili triangulati et canaliculi*.

Clinically, the defect is noted in the first few years of life as dry, blond, shiny hair that stands straight out from the scalp and cannot be combed (Fig. 33-25). On light microscopy, it may appear quite normal when viewed lengthwise, but on horizontal sectioning and on SEM, it shows the longitudinal grooves that make it abnormally rigid. These depressions are sometimes seen in unaffected persons, and thus 50% of hairs need to be affected for the condition to be clinically detectable.

Autosomal dominant, autosomal recessive, and sporadic forms have been described. Uncombable hair has been associated with angel-shaped phalangopiphyseal dysplasia. It has also been seen in combination with retinal dystrophy, juvenile cataract, and brachydactyly. It has also been reported in a patient who acquired the abnormality at age 39 after an episode of diffuse alopecia treated with spironolactone. Although there are usually no associated ectodermal defects, isolated cases have been reported in which uncombable hair is one component of several clustered findings. Until more experience is available in the literature, grouping these cases into new syndromes is premature.

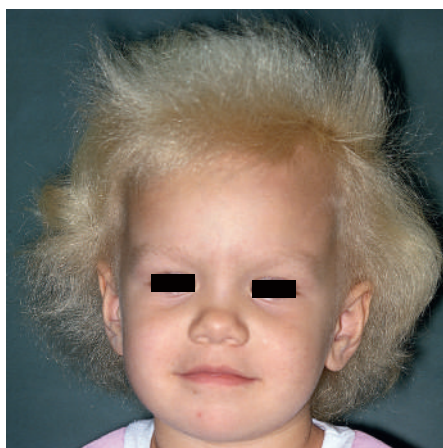
Some patients have responded clinically to biotin, 0.3 mg orally three times daily. Some cases improve spontaneously in late childhood.

**Calderon P, et al:** Uncombable hair syndrome. *J Am Acad Dermatol* 2009; 61(3):512–515.

## Kinking hair

Acquired progressive kinking of the hair, first described and named by Wise and Sulzberger in 1932, involves a structural abnormality of kinking and twisting of the hair shaft at irregular intervals. The main recognized variant of this disorder begins in men in their late teens or early twenties on the frontotemporal or vertex regions, then progresses to both the parietal and the frontal area. Usually straight, light-brown hair becomes curly, frizzy, and lusterless.

When this occurs in the androgen-dependent areas of young men, it is a precursor of male-pattern hair loss; usually these men have a strong family history of androgenetic alopecia. Treatment with topical minoxidil has not prevented development of hair thinning. “Whisker” hairs, the short dark hairs



**Fig. 33-25**  
Uncombable hair syndrome.

that grow anterior to the ears in young people who eventually develop androgenic alopecia, is believed to be a variant of acquired kinking of the hair.

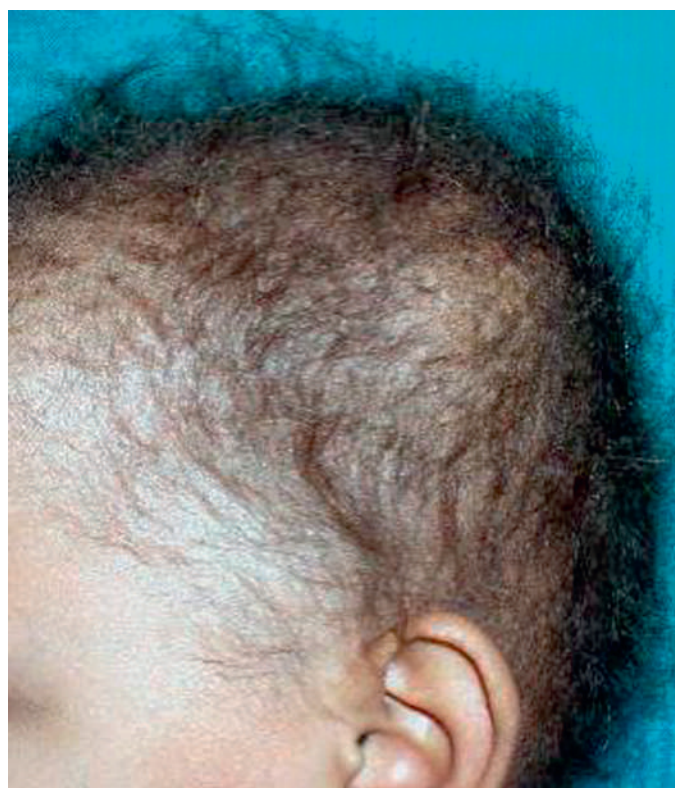Acquired hair kinking has been described in other clinical situations. Some reports detail prepubertal patients or women, as well as men, in whom kinking develops in non-androgen-dependent areas such as the eyebrows or lashes. In these reports, alopecia has not developed, and the curly, frizzy hair may remain present or may revert to its previous condition.

Widespread kinking of the hair may be induced by drugs, notably retinoids, and it may also occur in patients with AIDS.

## Woolly hair

Woolly hair is present at birth and is usually most severe during childhood (Fig. 33-26), when it is often impossible to brush the hair. In adult life, there is a variable amelioration in the condition. A clear distinction exists between the appearance of the affected and nonaffected members of a family. Both autosomal dominant and autosomal recessive inheritance have been described. Woolly hair nevus has partial scalp involvement by woolly hair, which has a greatly reduced diameter. Naxos’ disease is an autosomal recessive syndrome with arrhythmogenic right ventricular cardiomyopathy, diffuse nonepidermolytic palmoplantar keratoderma, and woolly hair. Hair abnormalities are a reliable marker for subsequent heart disease. The disease is caused by a mutation in the gene encoding plakoglobin. Carvajal syndrome is a familial cardiocutaneous syndrome consisting of woolly hair, palmoplantar keratoderma, and heart disease. It is caused by a recessive deletion mutation in desmoplakin.

Woolly hairs tend to unite into tight locks, whereas the hairs of black persons remain individual. The hair may not grow beyond a length of 12 cm, but may attain a normal appearance in adult life. In the familial group, the eyebrows and hairs on



**Fig. 33-26** Woolly hair. (Courtesy of Dr. Shyam Verma.)

the arms, legs, and pubic and axillary regions may be short and pale. There are no associated cutaneous or systemic diseases. A Dutch kindred has been described with premature loss of curly brittle hair, premature loss of carious teeth, nail dystrophy, and acral keratoderma. It has been designated the curly hair–acral keratoderma–caries syndrome.

The microscopic findings of woolly hair include a decreased diameter, an ovoid shape on cross section, a pili torti–like twisting about a longitudinal axis, trichorrhexis nodosa, and pili annulati.

### Plica neuropathica (felted hair)

Plica neuropathica is a curling, looping, intertwisting, and felting or matting of the hair in localized areas of the scalp. Predisposing factors include kinky hairs, changes in hair care, and a neurotic mental state. Plica polonica is a former name for this condition.

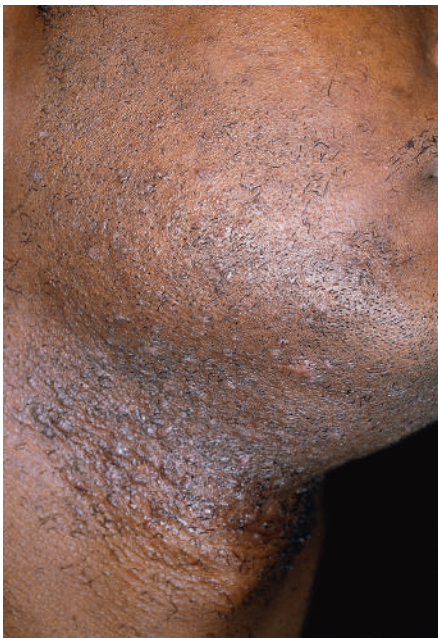**MacDonald A, et al:** Acquired progressive kinking of hair affecting the scalp and eyelashes in an adult woman. *Clin Exp Dermatol* 2011; 36(8):882–884.

**Song KH, et al:** Acquired progressive kinking of the hair in a Korean female adolescent. *J Dermatol* 2013; 40(1):80–81.

**Urbina F:** Eyelash involvement in acquired progressive kinking of the hair. *Clin Exp Dermatol* 2012; 37(5):562.

### Pseudofolliculitis barbae

Pseudofolliculitis barbae (“razor bumps”) consists of hairs that, after appearing at the surface, curve back and pierce the skin as ingrowing hairs. This results in inflammatory papules and pustules, which may scar (Fig. 33-27). In severe cases, large deforming keloids may result in the beard area. Pseudofolliculitis of the beard is seen in more than 50% of black men, who must sometimes give up shaving to alleviate the disorder. A single nucleotide polymorphism, giving rise to a disruptive Ala12Thr substitution in the 1A  $\alpha$ -helical segment of the companion layer–specific keratin K6hf, appears to be partially responsible for the phenotype. White persons are infrequently affected; however, it is more common in renal transplant recipients. Tenderness responds to midstrength topical corticoste-



**Fig. 33-27**  
Pseudofolliculitis  
barbae.

roids. The use of clippers or chemical depilatories, glycolic acid lotion, and adjunctive antibiotic therapy may be helpful. Benzoyl peroxide 5%/clindamycin 1% gel has been shown to be effective in double-blind evaluation. Laser hair removal with the long-pulse neodymium:yttrium-aluminum-garnet (Nd:YAG) laser is suitable for a wide range of skin types, and topical eflornithine can prolong responses. The diode laser and PDT have also been used.

**Alexis A, et al:** Folliculitis keloidalis nuchae and pseudofolliculitis barbae: are prevention and effective treatment within reach? *Dermatol Clin* 2014; 32:183.

**Diernaes JE, et al:** Successful treatment of recalcitrant folliculitis barbae and pseudofolliculitis barbae with photodynamic therapy. *Photodiagnosis Photodyn Ther* 2013; 10(4):651–653.

**Emer JJ:** Best practices and evidenced-based use of the 800 nm diode laser for the treatment of pseudofolliculitis barbae in skin of color. *J Drugs Dermatol* 2011; 10(12 Suppl):s20–s22.

**Xia Y, et al:** Topical eflornithine hydrochloride improves the effectiveness of standard laser hair removal for treating pseudofolliculitis barbae: a randomized, double-blinded, placebo-controlled trial. *J Am Acad Dermatol* 2012; 67(4):694–699.

### Pili multigemini

This rare malformation is characterized by the presence of bifurcated or multiple divided hair matrices and papillae, giving rise to the formation of multiple hair shafts within the individual follicles (Fig. 33-28). Pili multigemini sometimes follows lines of Blaschko. Mehregan et al. reported a patient with cleidocranial dysostosis and extensive pili multigemini over the heavily bearded chin and cheek areas. There is no treatment.

### Pili bifurcati

In this disorder, bifurcation is found in short segments along the shafts of several hairs. Each branch of the bifurcation is covered with its own cuticle. It has been seen in association with the trisomy 8 mosaic syndrome. Pili bifurcati differs from pili multigemini, in which a single follicular matrix produces two different-sized hair shafts with separate cuticles that do not fuse again. Trichoptilosis is characterized by split distal ends that are never surrounded by a complete cuticle.

**Lester L, et al:** The prevalence of pili multigemini. *Br J Dermatol* 2007; 156(6):1362–1363.

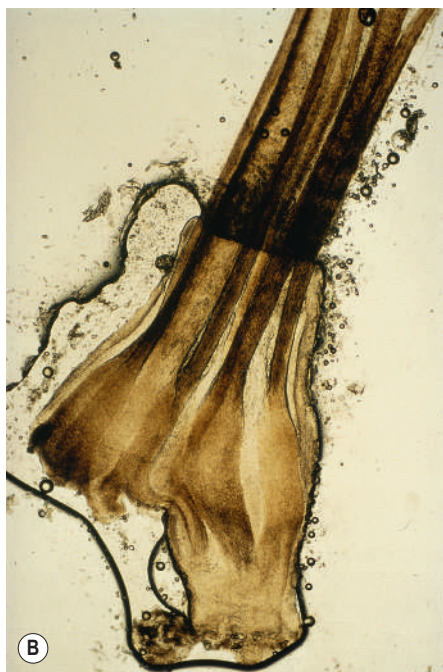
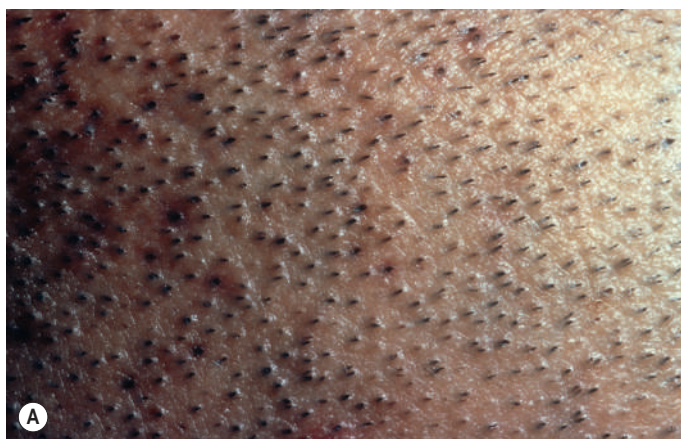### Trichostasis spinulosa

Trichostasis spinulosa is a common disorder of the hair follicles that clinically gives the impression of blackheads (Fig. 33-29), but the follicles are filled with funnel-shaped, horny plugs within which are bundles of vellus hairs (Fig. 33-30). The hairs are round at their proximal ends and shredded distally. The disease occurs primarily on the nose and forehead, but may also occur on the trunk and may be accompanied by pruritus. Dermoscopy or microscopy can be used to establish the diagnosis. The condition may be more common in patients in renal failure.

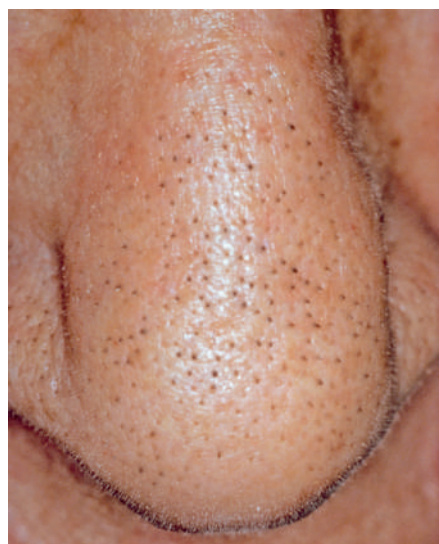Trichostasis spinulosa results from retention of telogen hairs, which are derived from a single hair matrix. It is primarily caused by a hyperkeratosis of the follicular infundibulum, which leads to a partial obstruction of the follicular orifice and thus does not permit shedding of small telogen hairs.

The plugs may be removed with hydroactive adhesive (Biore) pads. Keratolytics are also effective after using a wax






**Fig. 33-28** A, Pili multigemini of beard. B, Multiple hair shafts in single follicle.



**Fig. 33-29** Trichostasis spinulosa.



**Fig. 33-30** Trichostasis spinulosa.

depilatory. The pulsed diode and alexandrite lasers have been used successfully, and application of 0.05% tretinoin solution, applied daily for 2 or 3 months, may also produce satisfactory results.

**Badawi A, et al:** Treatment of trichostasis spinulosa with 0.5-millisecond pulsed 755-nm alexandrite laser. *Lasers Med Sci* 2011; 26(6):825–829.

**Deshmukh SD, et al:** Trichostasis spinulosa presenting as itchy papules in a young lady. *Int J Trichology* 2011; 3(1):44–45.

**Gündüz O, et al:** Trichostasis spinulosa confirmed by standard skin surface biopsy. *Int J Trichology* 2012; 4(4):273–274.

### Trichodysplasia spinulosa (viral-associated trichodysplasia)

Trichodysplasia spinulosa is seen in immunosuppressed patients and is associated with a polyomavirus. The condition is characterized by follicular distention with keratotic spines, especially on the face. Electron microscopy, immunohistochemistry, and viral load measurements indicate an etiologic role for the virus.

**Kazem S, et al:** The trichodysplasia spinulosa-associated polyomavirus: virological background and clinical implications. *APMIS* 2013; 121(8):770–782.

## HYPERTRICHOSIS

Hypertrichosis is an overgrowth of hair not localized to the androgen-dependent areas of the skin. Several forms exist. Many cases are induced by medications, including minoxidil, cyclosporine, and efalizumab. The excessive hair growth can be managed with bleaching, trimming, shaving, plucking, waxing, chemical depilatories, and electrosurgical epilation. Treatment with long-pulse Nd:YAG, diode, ruby, and long- and short-pulse alexandrite lasers as well as with intense pulsed light sources can be effective. Skin type must be considered when choosing a laser system. The greatest experience in dark skin types has been with the long-pulse Nd:YAG laser.



## Localized acquired hypertrichosis

Eyelash trichomegaly can occur with erlotinib, latanoprost, and intentionally with bimatoprost. Dermal tumors, such as melanocytic nevi, smooth muscle hamartomas, meningiomas, and Becker nevi, may have excessive terminal hair growth. Repeated irritation, trauma, occlusion under a cast, eczematous states, topical steroid use, linear melorheostotic scleroderma, lymphedema associated with filariasis, the Crow-Fukase (POEMS) syndrome, and pretibial myxedema may be other situations with a localized increase in hair growth. Porphyrias generally show a localized hypertrichosis over the malar area, such as in porphyria cutanea tarda or variegate porphyria. In the Gunther variety of erythropoietic porphyria, however, the hypertrichosis may be generalized or more diffuse.

## Localized congenital hypertrichosis

Hypertrichosis cubiti (hairy elbows) consists of long vellus hair on the extensor surfaces of the distal third of the upper arm and the proximal third of the forearm bilaterally. It is a progressive, excessive growth of lanugo hairs that often begins in infancy; the hairs may reach a length of 10 cm. Later, they become coarser, but regression has been observed during adolescence. There appear to be familial cases and a sporadic form. Short stature and some developmental abnormalities are present in some patients; however, endocrine studies or other evaluations are not necessary. The condition appears to be of cosmetic significance only.

Other causes of localized congenital hypertrichosis include congenital nevocytic nevi, anterior cervical hypertrichosis, and simple nevoid hypertrichosis. Localized hypertrichosis may be a sign of underlying spinal dysraphism when it occurs over the sacral midline, or a sign of an underlying neoplasm.

## Generalized congenital hypertrichosis (congenital hypertrichosis lanuginosa)

This rare type of excessive and generalized hairiness is a fully penetrant, X-linked dominant trait. The entire body is covered with fine vellus hairs 2–10 cm long (Fig. 33-31). The scalp hair appears to be normal. Except for the palms and soles, all other areas are covered. Congenital hypertrichosis lanuginosa may be associated with dental anomalies and gingival fibromatosis. This type of hairiness has attracted considerable attention over the centuries. Hair removal by laser may be quite useful.

Other cases of congenital generalized hypertrichosis may be secondary to drug ingestion by the mother. The fetal hydantoin syndrome is characterized by hypertrichosis, depressed nasal bridge, large lips, a wide mouth, and a short, webbed neck. The fetal alcohol syndrome includes hypertrichosis, a small face, capillary hemangiomas, and physical and mental retardation. A case of generalized hypertrichosis and multiple congenital defects was reported in a baby born to a mother who used minoxidil throughout pregnancy. Fetal valproate syndrome is characterized by generalized hypertrichosis sparing the palms and soles, coarse facies, gum hypertrophy, hypotonia, club feet and hands, and abnormal dermatoglyphics.

## Generalized or patterned acquired hypertrichosis

These cases include those caused by acquired hypertrichosis lanuginosa, those associated with various syndromes, and those secondary to drug intake. Acquired hypertrichosis lanuginosa is an ominous sign of internal malignancy (Fig. 33-32).

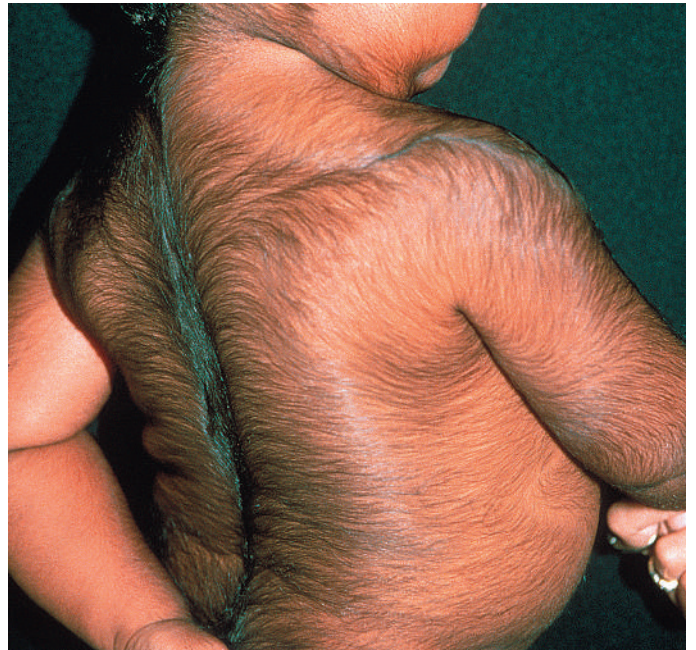

Fig. 33-31 Hypertrichosis lanuginosa. (Courtesy of Brooke Army Medical Center Teaching File.)

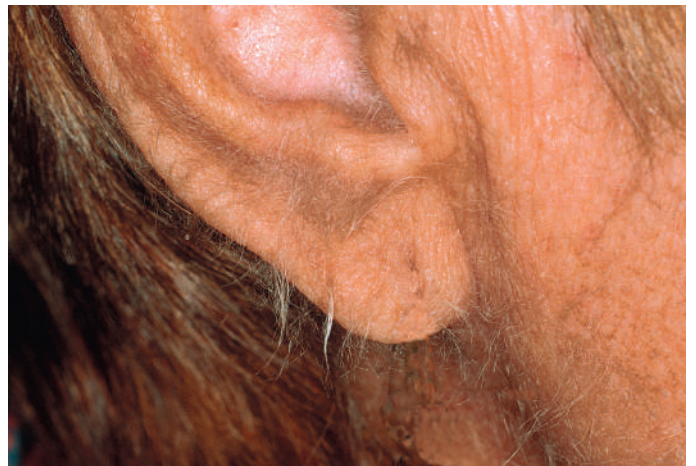

Fig. 33-32 Hypertrichosis lanuginosa associated with an internal malignancy (malignant down).

Syndromes associated with increased hair growth include lipoatrophic diabetes, stiff skin syndrome, Down syndrome, Rubenstein-Taybi syndrome, Laband syndrome, Cornelia de Lange syndrome, Hurler syndrome, leprechaunism, Winchester syndrome, Schynzel-Giedier syndrome, presymptomatic Leigh syndrome (neurometabolic mitochondrial disorder), and hypertrichosis with acromegalic features. Drugs associated with hypertrichosis include minoxidil, cyclosporine, diphenylhydantoin, diazoxide, streptomycin, penicillamine, corticosteroids, danazol, psoralens, hexachlorobenzene, PUVA, topical bimatoprost, topical corticosteroids, and topical androgens.

**Baertling F, et al:** Hypertrichosis in presymptomatic mitochondrial disease. *J Inherit Metab Dis* 2013; 36(6):1081–1082.

**Berry RS, et al:** Congenital dermatofibrosarcoma with associated hypertrichosis. *J Cutan Pathol* 2013; 40(12):990–992.

**Goel N, et al:** Familial congenital generalized hypertrichosis. *Indian J Dermatol Venereol Leprol* 2013; 79(6):849.

**Ma HJ, et al:** Acquired localized hypertrichosis induced by internal fixation and plaster cast application. *Ann Dermatol* 2013; 25(3):365–367.



## HIRSUTISM

### Clinical features

Hirsutism is an excess of terminal hair growth in women in a pattern more typical of men. Androgen-dependent growth areas affected include the upper lip, cheeks, chin, central chest, breasts, lower abdomen, and groin (Fig. 33-33). This altered growth pattern of the hair may be associated with other signs of virilization, which include temporal balding, masculine habitus, deepening of the voice, clitoral hypertrophy, and amenorrhea. Acne is an additional sign of hyperandrogenism.

### Pathogenesis

When virilization accompanies hirsutism, especially when progression is rapid, a neoplastic cause is likely. In the absence of virilization, a neoplastic cause is extremely unlikely. Most medically significant hirsutism is related to the polycystic ovarian syndrome (PCOS, hyperinsulinemic hyperandrogenism with anovulation). In a study of 873 patients with medically significant hirsutism, PCOS was present in 82%. Idiopathic hirsutism was present in 4.7%, and 6.75% of the patients had elevated androgen levels and hirsutism with normal ovulation.

Ethnic variation should be considered when evaluating hirsutism. Women of Southwest Asian, Eastern European, and southern European heritage usually have facial, abdominal, and thigh hair; whereas Asian and Indian women generally have little terminal hair growth in these areas.

In women, androgen biosynthesis occurs in the adrenal gland and ovary. Testosterone and the androgen precursor androstenedione are secreted by the ovary. The adrenal contributions are preandrogens: dehydroepiandrosterone (DHEA), DHEA sulfate, and androstenedione. These require peripheral conversion in the skin and liver to testosterone. Testosterone is converted to dihydrotestosterone, the androgen that promotes androgen-dependent hair growth, in the hair follicle by 5 $\alpha$ -reductase. Receptor molecules in the end organ are necessary for binding and hormone action at that level. Because testosterone is normally bound to carrier molecules in the plasma at a 99% level, and it is the unbound testosterone that is active, the levels of free testosterone correlate with clinical evidence of androgen excess.

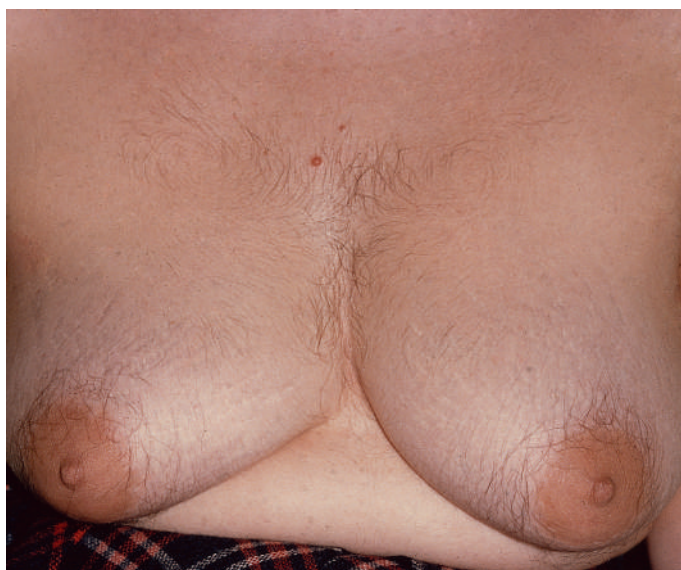

Fig. 33-33 Hirsutism.

Hirsutism may result from excessive secretion of androgens from either the ovary or the adrenal gland. The excessive secretion may be from functional excesses or rarely from neoplastic processes. Ovarian causes include PCOS (Stein-Leventhal syndrome) and a variety of ovarian tumors, both benign and malignant. PCOS is defined by anovulation (fewer than nine periods a year or periods longer than 40 days apart) with clinical evidence of hyperandrogenism. Ovarian cysts are not required for the diagnosis, and laboratory and imaging studies are not required to establish the diagnosis, according to the U.S. National Institutes of Health (NIH) consensus criteria. Rotterdam criteria for diagnosing PCOS require the presence of two of the following criteria: androgen excess, ovulatory dysfunction, or polycystic ovaries. The pathogenesis of PCOS may relate to insulin resistance, with resultant elevated insulin levels leading to ovarian overproduction of androgens. Prevalence rates of PCOS for black and white women in the United States are 8.0% and 4.8%, respectively.

Ovarian tumors include unilateral benign microadenomas, arrhenoblastomas. Leydig cell tumors, hilar cell tumors, granular/theca cell tumors, and luteomas are rare causes of hirsutism. In tumor-associated hirsutism, the onset is usually rapid, occurs with other signs of virilization, and begins between ages 20 and 40.

Adrenal causes include congenital adrenal hyperplasia (CAH) and adrenal tumors, such as adrenal adenomas and carcinomas. The adrenogenital syndrome or CAH is an autosomal dominant disorder that may result from deficiency of the enzyme 21-hydroxylase (most common form), 11 $\beta$ -hydroxylase, or 3 $\beta$ -hydroxy steroid dehydrogenase. Onset is generally in childhood, with ambiguous genitalia, precocious growth, and virilism. Nonclassic (adult-onset) CAH may present with hirsutism.

Pituitary causes include Cushing's disease, acromegaly, and prolactin-secreting adenomas. Patients with prolactin-secreting microadenomas have a 20% incidence of hirsutism and acne. Prolactin elevations may be seen in patients with PCOS. Other settings where prolactin levels may be elevated and that may lead to hirsutism include hypothyroidism, phenothiazine intake, and hepatorenal failure.

Other causes of hirsutism include the exogenous intake of androgens. End-organ hypersensitivity may be a mechanism in patients with a normal evaluation. Drugs such as minoxidil, diazoxide, corticosteroids, and phenytoin, which have been reported to cause hirsutism, generally cause hypertrichosis—a generalized increase in hair that is not limited to the androgen-sensitive areas.

### Evaluation

Most hirsutism is related to ethnic heritage or PCOS. 21-Hydroxylase-deficient nonclassic adrenal hyperplasia, the hyperandrogenic insulin-resistant acanthosis nigricans syndromes, and androgen-secreting tumors are relatively uncommon causes. A careful history and physical examination are essential. The history should focus on onset and progression, virilization, menstrual and pregnancy history, and family/racial background. Physical examination may reveal signs of Cushing's disease, hypothyroidism, or acromegaly. Other signs to be evaluated are the distribution of muscle mass and body fat, clitoral dimensions, voice depth, and galactorrhea.

Laboratory evaluation is controversial. In the authors' opinion, testing is of value only when it affects management. If this is accepted, there is no mandatory hormonal testing for stable hirsutism in patients who have no signs of virilization.

A diagnosis of PCOS can be made clinically and does not require laboratory confirmation. Determination of serum lipids and testing for glucose intolerance may be the most important laboratory evaluations in patients with PCOS because these have the greatest impact on management and long-term prognosis. When the history and physical examination suggest the possibility of a neoplasm, laboratory evaluation should include a total testosterone level. A DHEA sulfate level is usually performed if an adrenal cause is suspected. A 24-hour urine cortisol test is the gold standard for the diagnosis of Cushing's disease. Measurement of thyroid-stimulating hormone (TSH), growth hormone, and somatomedin C levels are indicated if the history and physical examination suggest hypothyroidism or acromegaly.

Dexamethasone suppression tests are recommended by some authorities, but the results often do not affect management. A baseline 17-hydroxyprogesterone (17-HP) and adrenocorticotropic hormone (ACTH) stimulation test can screen for late-onset CAH, but steroid replacement has not been proved to result in better outcomes than empiric treatment with antiandrogens. Baseline 17-HP may be normal in some women with nonclassic 21-hydroxylase deficiency, and ACTH stimulation may result in overdiagnosis of the syndrome. An exaggerated 17-HP response to ACTH stimulation is common in PCOS at a pharmacologic dose (250 µg) but not at a physiologic dose (1 µg) of ACTH. An ovarian origin of hirsutism can be identified by a buserelin test in 30% of patients with hirsutism and by dexamethasone in 22% of patients, but data proving that buserelin challenge results in better outcomes are lacking. A prolactin level will screen for prolactin-secreting tumors but will also lead to further expensive testing in many patients ultimately diagnosed with PCOS. A prolactin level should be obtained in any patient with galactorrhea but is of limited value as a routine screening test for patients with hirsutism alone.

If signs of acromegaly, Cushing's disease, or virilization are present clinically, referral to an endocrinologist is recommended. The presence of major menstrual irregularities is also an indication for referral to an endocrinologist or gynecologist. Although 90% of women with hirsutism have an elevated testosterone level, increases greater than 200 ng/dL and rapid onset or progressive virilization suggest serious underlying disease. A major elevation in the DHEA sulfate level (>7000 ng/mL) suggests an adrenal neoplasm, and imaging of the adrenal gland is recommended. Many patients with late-onset CAH will have normal screening DHEA sulfate. Patients with prolactin levels above 20 ng/mL should likewise be referred for further evaluation with magnetic resonance imaging (MRI) or computed tomography (CT). Polymorphisms in the gene coding for sex hormone-binding globulin have been identified in some families with hirsutism, but such testing does not affect management.

## Treatment

Various forms of mechanical, chemical, and laser epilation can be performed for hirsutism, as for hypertrichosis. Spironolactone with various OCs, cyproterone acetate plus ethinyl estradiol, gonadotropin-releasing hormone agonists (e.g., leuprolide, nafarelin), flutamide, finasteride, and topical eflornithine have been used successfully alone and in various combinations to treat hirsutism. The optimal combination and dosage remain to be determined, but in one study, 20 µg of ethinyl estradiol was as effective as 30 µg when used in association with drospirenone. The Endocrine Society clinical practice guideline recommends hormonal OCs as the first-line management for menstrual abnormalities and hirsutism in

patients with PCOS. The guideline notes that hormonal OCs and metformin are the best treatment options in adolescents with PCOS, that thiazolidinediones have an unfavorable risk-benefit ratio compared with other treatments, and that statins require further study.

Finasteride at doses of 2.5–5 mg/day has been shown to decrease hair number and diameter in women with hirsutism. The combination of spironolactone, 100 mg/day, plus finasteride, 5 mg/day, has been shown to be superior to spironolactone, 100 mg/day, alone. An analysis of the current literature suggested that spironolactone alone, 100 mg/day, is superior to finasteride alone, 5 mg/day, and to low-dose cyproterone acetate alone, 12.5 mg/day for the first 10 days of a cycle, in the treatment of hirsutism. Spironolactone is typically used at a dose of 100 mg twice daily, so further studies are needed comparing this higher dose with other modes of therapy. In a prospective, randomized study of Diane 35 (cyproterone acetate [CPA], 2 mg, and ethinyl estradiol, 35 µg), Diane 35 plus spironolactone, and spironolactone alone, all treatments were well tolerated. Combination therapy resulted in superior measured endocrine responses, but the authors concluded that spironolactone alone was the most cost-effective treatment. The choice of an OC is also controversial. Third-generation OCs result in a significant increase in sex hormone-binding globulin and a decrease in free testosterone, but both second-generation and third-generation OCs are clinically effective in treating hirsutism. When flutamide is used, initial treatment with 250 mg/day is followed by a long maintenance treatment period using 125 mg/day.

Metformin therapy has been shown to control menstrual cycles and improve fertility in women with PCOS. It causes a decline in testosterone and insulin levels. Oligomenorrheic women with an increased luteinizing hormone to follicle-stimulating hormone (LH/FSH) ratio and lower testosterone levels respond best. Spironolactone, 50 mg/day, was superior to metformin, 1000 mg/day, in the treatment of hirsutism and menstrual cycle frequency in a study of 82 adolescent and young women with PCOS. Doses of 200 mg/day are typically used to treat hirsutism. At this dose, menstrual irregularities induced by the drug are common, and it may be best used in combination with an OC. Good correlation has been noted between an increase in ovulation frequency with clomiphene citrate and the chance of pregnancy in women with PCOS. Other options include acarbose, gonadotrophins, and laparoscopic ovarian drilling. Infertility is best managed by a specialist in this field. Empiric treatment with an antiandrogen may be as effective as steroid replacement for the management of hirsutism in patients with nonclassic CAH.

**Bates GW Jr, et al:** Polycystic ovarian syndrome management options. *Obstet Gynecol Clin North Am* 2012; 39(4):495–506.

**Buzney E, Sheu J, et al:** Polycystic ovary syndrome: a review for dermatologists. Part II. Treatment. *J Am Acad Dermatol* 2014; 71:859.e1.

**Codner E, et al:** Metformin for the treatment of hyperandrogenism in adolescents with type 1 diabetes mellitus. *Horm Res Paediatr* 2013; 80(5):343–349.

**Jayasena CN, Franks S:** The management of patients with polycystic ovary syndrome. *Nat Rev Endocrinol* 2014; 10:624.

**Legro RS, et al:** Diagnosis and treatment of polycystic ovary syndrome: an Endocrine Society clinical practice guideline. *J Clin Endocrinol Metab* 2013; 98(12):4565–4592.

**Loriaux DL:** An approach to the patient with hirsutism. *J Clin Endocrinol Metab* 2012; 97(9):2957–2968.

**Pasquali R, et al:** Therapy in endocrine disease: treatment of hirsutism in the polycystic ovary syndrome. *Eur J Endocrinol* 2013; 170(2):R75–R90.

**Pignatelli D:** Non-classic adrenal hyperplasia due to the deficiency of 21-hydroxylase and its relation to polycystic ovarian syndrome. *Front Horm Res* 2013;40:158–170.



**Roe AH, et al:** Using the Androgen Excess-PCOS Society criteria to diagnose polycystic ovary syndrome and the risk of metabolic syndrome in adolescents. *J Pediatr* 2013; 162(5):937–941.

**Romualdi D, et al:** Clinical efficacy and metabolic impact of two different dosages of ethinyl-estradiol in association with drospirenone in normal-weight women with polycystic ovary syndrome: a randomized study. *J Endocrinol Invest* 2013; 36(8):636–641.

**Sangeeta S:** Metformin and pioglitazone in polycystic ovarian syndrome: a comparative study. *J Obstet Gynaecol India* 2012; 62(5):551–556.

**Setji TL, Brown AJ:** Polycystic ovary syndrome: update on diagnosis and treatment. *Am J Med* 2014; 127:912.

**Somani N, Turvy D:** Hirsutism: an evidence-based treatment update. *Am J Clin Dermatol* 2014; 15:247.

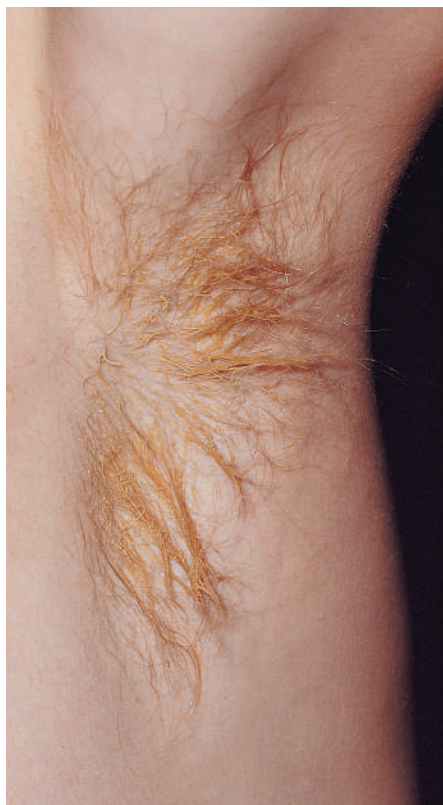**Unluhizarci K, et al:** Hirsutism: from diagnosis to use of antiandrogens. *Front Horm Res* 2013; 40:103–114.

## TRICHOMYCOSIS AXILLARIS

Discrete nodules 1–2 mm in size and attached firmly to the hair shafts of the axillary or pubic areas characterize trichomycosis. The color of the nodules may be yellow (Fig. 33-34), red, or black. Hyperhidrosis of the affected regions is usually present. A yellowish discoloration of the axillae is sometimes noted. Large numbers of *Corynebacterium* are present in the concretions. Trichomycosis axillaris may coexist with erythrasma and pitted keratolysis. Treatment with a topical antibiotic preparation (e.g., clindamycin or erythromycin) or naftifine, which has antibacterial properties, combined with any modality that will decrease the hyperhidrosis, is effective, but shaving is faster.

**Ma DL, Vano-Galvan S:** Images in clinical medicine. Trichomycosis axillaris. *N Engl J Med* 2013; 369(18):1735.

**Rho NK, et al:** A corynebacterial triad: prevalence of erythrasma and trichomycosis axillaris in soldiers with pitted keratolysis. *J Am Acad Dermatol* 2008; 58(2 Suppl):S57–S58.



**Fig. 33-34**  
Trichomycosis axillaris. (Courtesy of Dr. Anthony Slagel.)

## ASSOCIATED HAIR FOLLICLE DISEASES

### Tinea amiantacea (pityriasis amiantacea)

Thick, asbestos-like (amiantaceous), shiny scales on the scalp characterize pityriasis amiantacea. The silvery-white or dull-gray crusting may be localized or, less often, generalized over the entire scalp. The proximal parts of the hairs are matted together by the laminated crusts. There are no structural changes in the hair, but in some patches where the crusting is thick, there may be some purulent exudate under the crust and temporary alopecia such as occurs after some cases of furunculosis of the scalp.

The cause is most often severe or untreated seborrheic dermatitis or psoriasis, although it may occur paradoxically during tumor necrosis factor- $\alpha$  inhibitor therapy. In a prospective study of 85 patients, psoriasis was documented in 35% and processes suggesting seborrheic dermatitis or atopic dermatitis occurred in another 35%. Tinea capitis was the eventual diagnosis in 13%. *Staphylococcus* was found in 96.5% of patients, compared with 15% of controls. The patient should shampoo daily or every other day with selenium sulfide suspension or a tar- or steroid-containing shampoo for 2 weeks. Prior application of peanut oil or a keratolytic a few hours before shampooing facilitates removal of the scales and crusts. With such debridement, followed by topical steroid solution in Caucasians or steroid ointment in African Americans, the secondary bacterial infection usually resolves without the need for oral antistaphylococcal therapy.

**Abdel-Hamid IA, et al:** Pityriasis amiantacea: a clinical and etiopathologic study of 85 patients. *Int J Dermatol* 2003; 42:260.

**Ettler J, et al:** Pityriasis amiantacea: a distinctive presentation of psoriasis associated with tumour necrosis factor- $\alpha$  inhibitor therapy. *Clin Exp Dermatol* 2012; 37:639.

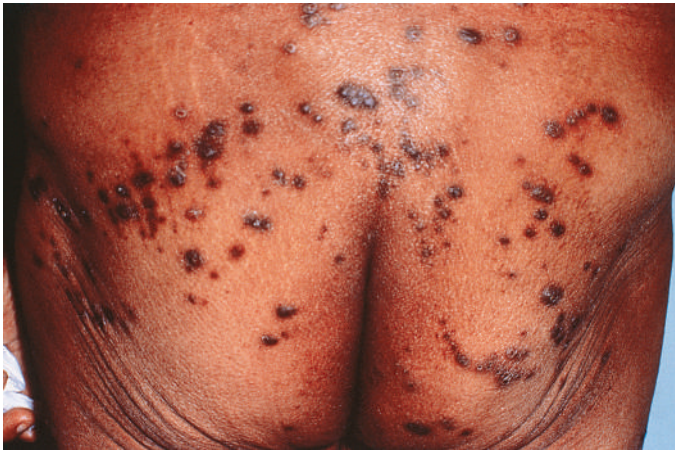
### Folliculitis nares perforans

Perforating folliculitis of the nose is characterized by small pustules near the tip of the inside of the nose. The lesion becomes crusted, and when the crust is removed, the bulbous end of the affected vibrissa is found to be embedded in the inspissated material. The affected hairs are typical of those occurring inside the nostril. *Staphylococcus aureus* may at times be cultured from the pustules. The hair should be removed and antibiotic ointment such as mupirocin applied.

**White SW, et al:** Pseudofolliculitis vibrissae. *Arch Dermatol* 1981; 117:368.

### Acquired perforating dermatosis

Perforating folliculitis, Kyrle's disease, and acquired perforating collagenosis are designations that have been supplanted by the more inclusive term acquired perforating dermatosis. The condition is not uncommon and is most often associated with renal failure or diabetes, or both. Between 4% and 10% of dialysis patients develop umbilicated dome-shaped papules on the legs, or less often on the trunk, neck, arms, or scalp, with variable itchiness (Fig. 33-35). Early lesions may be pustular; late lesions resemble prurigo nodularis both clinically and histologically. A central hyperkeratotic cone projects into the dermis, so that when it is removed, a pitlike depression remains. Usually the papules are discrete, but they may coalesce to form circinate plaques. Coalescing verrucous plaques are frequently seen, especially on the lower extremities. Koebner phenomenon may also be observed, in which



**Fig. 33-35** Acquired perforating disease in uremia. (Courtesy of Dr. Curt Samlaska.)

case plaques or elevated verrucous streaks are formed, primarily in the antecubital and popliteal spaces. Atrophic scars are seen on involution of these lesions.

Histologically, the epidermis becomes edematous, the granular layer disappears, and parakeratosis develops. Eventually, the epidermis becomes atrophic, with disruption of the sites over the papillae. Through these sites, necrobiotic connective tissue, degenerating inflammatory cells, and collagen bundles are extruded into a cup-shaped epidermal depression.

Acquired perforating dermatosis is thought to be a response to trauma, usually scratching or rubbing in response to the pruritus of the associated renal failure or dry skin. Other predisposing conditions reported include HIV infection, sclerosing cholangitis or other liver diseases, hypothyroidism, hyperparathyroidism, Hodgkin disease, healed areas of herpes zoster, and reactions to laser hair removal or indinavir and several biologic agents (e.g., gefitinib, infliximab, etanercept, bevacizumab, sorafenib, and natalizumab).

Ultraviolet treatment, either PUVA or UVB, helps the pruritus of renal disease and improves the perforating disorder. Hydration of the skin with a soaking tub bath in plain water, followed immediately (without drying) by triamcinolone ointment just before bedtime, is also useful. Topical retinoic acid (0.1% cream), tacalcitol, allopurinol, doxycycline, amitriptyline, photodynamic therapy, isotretinoin, and etretinate have been effective in flattening lesions. HIV-infected patients may respond well to thalidomide. The disease may remit promptly after renal transplantation.

**Akoglu G, et al:** Clinicopathological features of 25 patients with acquired perforating dermatosis. *Eur J Dermatol* 2013; 23:864.

**Escribano-Stable JC, et al:** Tacalcitol in the treatment of acquired perforating collagenosis. *Case Rep Dermatol* 2014; 6:69.

**Kim SW, et al:** A clinicopathologic study of thirty cases of acquired perforating dermatosis in Korea. *Ann Dermatol* 2014; 26:162.

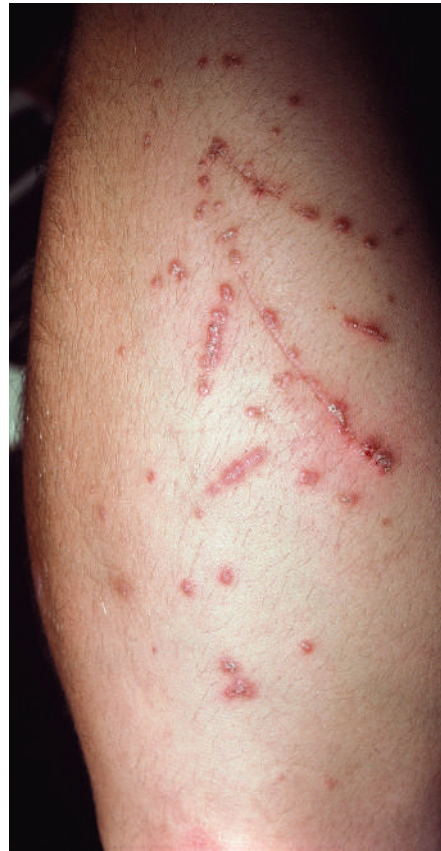**Pique-Duran E, et al:** Acquired perforating dermatosis associated with natalizumab. *J Am Acad Dermatol* 2013; 68:e185.

**Sezer E, et al:** Acquired perforating dermatosis successfully treated with photodynamic therapy. *Photodermatol Photoimmunol Photomed* 2012; 28:50.

**Yong A, et al:** Effective treatment of uremic pruritus and acquired perforating dermatosis with amitriptyline. *Australas J Dermatol* 2013; doi: 10.1111/ajd.12026 (Epub ahead of print.)

### Reactive perforating collagenosis

Reactive perforating collagenosis is an inherited condition characterized by pinhead-sized, skin-colored papules that grow to a diameter of 4–6 mm and develop a central area of



**Fig. 33-36** Reactive perforating collagenosis.

umbilication in which keratinous material is lodged (Fig. 33-36). The discrete papules may be numerous and may involve sites of frequent trauma, such as the backs of the hands, forearms, elbows, and knees. The lesion reaches a maximum size of about 6 mm in 4 weeks and then regresses spontaneously in 6–8 weeks. This is believed to be caused by a peculiar reaction of the skin to superficial trauma. Koebnerization is often observed. Young children are most frequently affected. Most reports support an autosomal recessive mode of inheritance; in one family, however, it appeared to be inherited by autosomal dominance. No specific treatment is indicated because the lesions involute spontaneously. Tretinoin 0.1% cream may be effective.

**Bansal M, et al:** Reactive perforating collagenosis in two siblings. *BMJ Case Rep.* 2013 Sep 26; pii: bcr2013009023.

**Pai VV, et al:** Familial reactive perforating collagenosis. *Indian J Dermatol.* 2014; 59:287.

### Traumatic anserine folliculosis

Traumatic anserine folliculosis is a curious gooseflesh-like follicular hyperkeratosis that may result from persistent pressure and lateral friction of one skin surface on another. Such friction is often caused by habitual pressure on the elbows, chin, jaw, or neck, often while watching television. Two thirds of patients who develop this are atopic.

**Padiiha-Gonalves A:** Traumatic anserine folliculosis. *J Dermatol* 1979; 6:365.

### Erythromelanosus follicularis faciei et colli

Erythromelanosus follicularis faciei et colli is an erythematous pigmented disease involving the follicles. A reddish brown,



sharply demarcated, symmetric discoloration involves the preauricular and maxillary regions. At times, the pigmentation may be blotchy. In addition, follicular papules and erythema are present. Under diascopic pressure, the reddish brown area, containing telangiectases, becomes pale, and the light-brown pigmentation becomes more apparent. Pityriasis-form scaling and slight itching may occur. Keratosis pilaris on the arms and shoulders is frequently found. It preferentially affects Asian and Indian patients.

Histologically, a slight hyperkeratosis occurs, with epidermal hyperpigmentation and dilation of the upper dermal vessels. The hair follicles may be enlarged in the infundibular area, and the sebaceous glands may be hypertrophic. A lymphocytic infiltration surrounds the adnexa. Successful treatment with topical tacalcitol or a dual-wavelength laser system has been reported.

**Kim WJ, et al:** Topical tacalcitol ointment can be a good therapeutic choice in erythromelanosis follicularis faciei et colli. *J Am Acad Dermatol* 2012; 67:320.

**Li YH, et al:** Treatment of erythromelanosis follicularis faciei et colli using a dual-wavelength laser system. *Dermatol Surg* 2010; 36:1344.

### Disseminate and recurrent infundibulofolliculitis

Hitch and Lund described a disseminate follicular eruption on the torso of a black man that involved all the pilosebaceous structures. The lesions were irregularly shaped papules pierced by a hair. They likened the eruption to cutis anserina viewed through a magnifying glass. The eruption is mildly pruritic at times and is chronic, with recurrent exacerbations. The papules are uniform and 1 or 2 mm in diameter. They involve all the follicles in the affected areas, which are usually the upper trunk and neck, although the entire trunk and proximal extremities may be involved. Rarely, pustules may occur.

Histologically, the infundibular portion of the follicles is chiefly affected, and the lesions are inflammatory rather than hyperkeratotic. Edema, lymphocytic and neutrophilic infiltration, and slight fibroblastic infiltration surround the affected follicles. Treatment with topical steroids, isotretinoin, or PUVA may be effective.

**Aroni K, et al:** Disseminate and recurrent infundibulofolliculitis: response to isotretinoin. *J Drugs Dermatol* 2004; 3:434.

**Hinds GA, et al:** A case of disseminate and recurrent infundibulofolliculitis responsive to treatment with topical steroids. *Dermatol Online J* 2008; 14:11.

### Lichen spinulosus

Lichen spinulosus (keratosis spinulosa) is primarily a disease of children and is characterized by minute, filiform horny spines, which protrude from follicular openings independent of any papules. The spines are discrete and grouped. The lesions appear in crops and are symmetrically distributed. There is a predilection for the neck, buttocks, abdominal wall, popliteal spaces, and extensor surfaces of the arms. Minimal or no itching is present. Occasional cases of a generalized form in adults with HIV infection or alcoholism have been reported.

Histologic evaluation shows simple inflammatory changes and follicular hyperkeratosis. The lesions may respond to keratolytics and emollients, such as salicylic acid, lactic acid, or urea gels or ointments. Tretinoin or tacalcitol creams are other alternatives. The lesions tend to involute at puberty.

**Kim SH, et al:** Successful treatment of lichen spinulosus with topical tacalcitol cream. *Pediatr Dermatol* 2010; 27:546.

**Venkatesh A, et al:** Generalized lichen spinulosus in a 4-year-old boy without systemic disease. *Arch Dermatol* 2012; 148:865.

## DISORDERS OF THE SWEAT GLANDS

### Hyperhidrosis

Hyperhidrosis, or excessive sweating, may be localized to one or several areas or may be more generalized. True generalized hyperhidrosis is rare; even hyperhidrosis caused by systemic diseases is usually accentuated in certain regions.

### Palmoplantar hyperhidrosis (emotional hyperhidrosis)

Palmoplantar hyperhidrosis is usually localized to the palms, soles, and/or axillae and may worsen during warm temperatures. Patients with palm and sole hyperhidrosis often have axillary hyperhidrosis, but only 25% of patients with axillary hyperhidrosis have palmoplantar hyperhidrosis. The hands may be cold and may show a dusky hue. The soggy keratin of the hyperhidrotic soles is frequently affected by pitted keratolysis and has a foul odor. Sweating may be constant or intermittent; in the latter case, anxiety, stress, or fear may trigger it. This type of sweating can be autosomal dominant inherited. Its onset is in childhood for the palmar and plantar type and adolescence for axillary disease. It tends to improve with age. Sweating typically ceases during sleep.

### Gustatory hyperhidrosis

Certain individuals regularly experience excessive sweating of the forehead, scalp, upper lip, perioral region, or sternum a few moments after eating spicy foods, tomato sauce, chocolate, coffee, tea, or hot soups. Gustatory sweating may be idiopathic or caused by hyperactivity of the sympathetic nerves (Pancoast tumor or postoperatively), sensory neuropathy (diabetes mellitus or subsequent to zoster), parotitis or parotid abscess, and surgery or injury of the parotid gland (auriculotemporal syndrome of von Frey). Frey syndrome occurs in one third or more of patients after parotid surgery. Fortunately, only 10% of affected patients require treatment.

### Other localized forms of hyperhidrosis

Localized sweating can occur over lesions of blue rubber bleb nevus syndrome, glomus tumors, and hemangiomas (sudoriferous hemangioma), and in POEMS syndrome, Gopalan (burning feet) syndrome, complex regional pain syndrome resulting from spinal cord tumors (especially when unilateral palmar hyperhidrosis is the complaint), and pachydermoperiostosis.

### Generalized hyperhidrosis

Febrile diseases, vigorous exercise, or a hot, humid environment (e.g., tropical milieu) may induce generalized hyperhidrosis. Hyperthyroidism, acromegaly, diabetes mellitus, pheochromocytoma, hypoglycemia, salicylism, substance abuse, lymphoma, carcinoid syndrome, pregnancy, and menopause may also produce generalized hyperhidrosis. Additional causes of hyperhidrosis include concussion, Parkinson's disease, other disturbances of the sympathetic nervous system, and metastatic tumors producing a complete transection of the spinal cord. Drugs such as anticholinesterases, antidepressants of the selective serotonin reuptake inhibitor or tricyclic types, anti-glaucoma agents, bladder stimulants, opioids, and sialogogs may cause hyperhidrosis.

## Treatment

Therapy of generalized hyperhidrosis focuses on treating the underlying systemic disease. Virtually all cases of hyperhidrosis seen by dermatologists are of the palmoplantar or axillary types, and the treatments discussed below relate primarily to these conditions. Hoorens et al. provide an excellent review with an excellent step-by-step approach to therapy.

### Topical medication

Topical aluminum chloride or aluminum chlorhydroxide are the agents most often used for hyperhidrosis. For the axillae, application of a 10–35% solution nightly to a very dry axilla (blown dry with hair dryer) is usually very effective. To limit irritation, lower concentrations should be tried first. Also, it should be washed off in 6–8 h. Occlusion is usually not required. In palmar hyperhidrosis, the application of aluminum chloride nightly in up to a 50% concentration, alone or occluded with plastic gloves, has produced good results for some patients. After topical treatment is effective when performed nightly, the frequency may be reduced to once or twice a week with continued benefit.

### Iontophoresis

Iontophoresis with plain tap water is an alternative for patients for whom topical treatments fail. It is frequently effective, using either a Drionic device or a Fischer unit. Treatments generally require 20–30 min sessions each day or twice a day. Once response has occurred, treatments may be used intermittently (even to once every 2 weeks) for maintenance. Use of glycopyrrolate 0.01%, botulinum toxin, and aluminum chloride 2% in the iontophoresis medium may hasten the response. The dry-type iontophoresis requires more study before it can be recommended.

### Botulinum toxin

Injection of botulinum A toxin into 4-cm<sup>2</sup> areas on the palms, soles, or axillae dramatically reduces sweating at the treated areas to at least 25% and often to less than 10% of baseline rates. Dosages vary according to the type of botulinum toxin used and the site of treatment. Grunfeld et al. offer a complete review of injection techniques and tips. (Also see Chapter 39 for a discussion of this treatment.) Complications are rare but include some grip weakness when higher doses are used in the palms. This problem, the expense, and the painful injections limit its use especially in the palms and soles. The hyperhidrosis continues for an average of 7 months, with some patients continuing to have substantial benefit at 16 months after one injection. Repeated injections generally do not lose efficacy and result in similar response and complication rates. This form of treatment should be offered to all patients who fail topical treatments before surgical modalities are considered. Frey syndrome remits for 1–1.5 years in almost every patient treated. This treatment may be considered for other rare forms of localized hyperhidrosis. Myobloc (botulinum toxin B) is also effective, but with more limited duration of response.

### Internal medication

The use of anticholinergic agents such as propantheline bromide, oxybutynin (available in extended-release formulation, which may result in lower efficacy), and glycopyrrolate may be helpful. The dosage of each is regulated by the patient's tolerance and response. Often, sweating is suppressed just as anticholinergic side effects reach intolerable levels, and this approach has to be abandoned. Side effects of acetylcholine-blocking agents may also cause or aggravate such conditions as glaucoma and convulsions. The effects on sweating gener-

ally last 4–6 h, and many patients prefer to use the medication to ensure dryness for special occasions only, rather than as continuous treatment. Other agents reported to reduce localized hyperhidrosis include diltiazem and clonidine.

### Surgical treatment

Axillary hyperhidrosis may be effectively controlled by excision of the most actively sweating portion of the axillary skin, followed by undercutting and subcutaneous resection of the sweat glands for 1–2 cm on each side of the elliptical excision. This procedure is virtually always effective. Alternatively, liposuction or surgical ultrasonic aspiration removal may be used. The most important preoperative consideration is the accurate mapping of the most active sweating areas of the axillae. The responsible eccrine glands are not necessarily located in the same areas as the axillary hair and are often in a reasonably limited area. Mapping may be performed with cobalt chloride or starch iodide. In a comparative trial the effectiveness of botulinum toxin injections were superior to suction-curettage surgery.

Upper thoracic sympathectomy has been found to be effective in excessive palmar sweating when all other measures have failed. Sympathetic denervation of the upper extremities is performed through endoscopy by reversibly clipping or electrocautery of portions of the third through fifth rib levels. The levels interrupted depend on the type of hyperhidrosis being treated and a risk benefit discussion with the patient. Acute surgical complications occur in less than 2% of patients but include chronic pain, infection, pneumothorax, hemothorax, bleeding, pneumonia, and even death. Sweating of the hands can be stopped or improved; however, since compensatory and gustatory hyperhidrosis occurs in many patients, satisfaction is compromised. This may be severe and as debilitating as the original problem. Topical glycopyrrolate may help alleviate compensatory hyperhidrosis, but it does not decrease with time. Horner syndrome may rarely result. Microwave technology and Nd:YAG laser treatments are newer, less well studied methods that may be useful in the future.

- 
- Cerfolio RJ, et al:** The Society of Thoracic Surgeons Expert Consensus for the Surgical Treatment of Hyperhidrosis. *Ann Thorac Surg* 2011; 91:1642.
- Chai HY, et al:** Efficacy of iontophoresis with glycopyrronium bromide for treatment of primary palmar hyperhidrosis. *J Eur Acad Dermatol Venereol* 2012; 26:1167.
- Cheshire WP, et al:** Disorders of sweating. *Semin Neurol* 2003; 23:399.
- Cheshire WP, et al:** Drug-induced hyperhidrosis and hypohidrosis. *Drug Saf* 2008; 31:109.
- Doft MA, et al:** Treatment of hyperhidrosis with botulinum toxin. *Aesthet Surg J* 2012; 32:238.
- Grunfeld A, et al:** Botulinum toxin for hyperhidrosis. *Am J Clin Dermatol* 2009; 10:87.
- Hoorens I, et al:** Primary focal hyperhidrosis: current treatment options and a step-by-step approach. *J EADV* 2012; 26:1.
- Ibrahim O, et al:** The comparative effectiveness of suction-curettage and onabotulinumtoxin-A injections for the treatment of primary focal axillary hyperhidrosis. *J Am Acad Dermatol* 2013; 69:88.
- Jacob C:** Treatment of Hyperhidrosis with microwave technology. *Semin Cutan Med Surg* 2013; 32:2.
- Kotlus BS:** Treatment of refractory axillary hyperhidrosis with a 1320-nm Nd. *J Cosmet Laser Ther* 2011; 13:193.
- Lakraj AA, et al:** Hyperhidrosis. *Toxins* 2013; 5:821.
- Letada PR, et al:** Treatment of focal axillary hyperhidrosis using a long-pulsed Nd. *J Drugs Dermatol* 2012; 11:59.
- Montaser-Kouhsari L, et al:** Comparison of intradermal injection with iontophoresis of abobotulinum toxin A for the treatment of primary axillary hyperhidrosis. *J Dermatolog Treat* 2014; 25:337.
- Paller AS, et al:** Oral glycopyrrolate as a second-line treatment for primary pediatric hyperhidrosis. *J Am Acad Dermatol* 2012; 67:918.
- Reisfeld R, et al:** Evidence-based review of the nonsurgical management of hyperhidrosis. *Thorac Surg Clin* 2008; 18:157.



- Seo SH, et al:** Tumescence superficial liposuction with curettage for treatment of axillary hyperhidrosis. *J Eur Acad Dermatol Venereol* 2008; 22:30.
- Vergilis-Kalner IJ:** Same-patient prospective comparison of Botox versus Dysport for the treatment of primary axillary hyperhidrosis and review of literature. *J Drugs Dermatol* 2011; 10:1013.
- Wallis T, et al:** Long-term efficiency of endoscopic thoracic sympathectomy. *Interact Cardiovasc Thorac Surg* 2009; 8:54.
- Wolina U, et al:** Tumescence suction curettage versus minimal skin resection with subcutaneous curettage of sweat glands in axillary hyperhidrosis. *Dermatol Surg* 2008; 34:709.
- Wolosker N, et al:** A randomized placebo-controlled trial of oxybutynin for the initial treatment of palmar and axillary hyperhidrosis. *Journal of Vascular Surgery* 2012; 55:1695.

## Anhidrosis and hypohidrosis

Anhidrosis is the absence of sweating. Hypohidrosis, or reduced sweating, is part of the spectrum of these disorders. Dysfunction in any step in the normal physiologic process of sweating can lead to decreased or absent sweating. It may be localized or generalized. Generalized anhidrosis occurs in anhidrotic ectodermal dysplasia, miliaria profunda (tropical asthenia), Sjögren syndrome, Fabry syndrome, hereditary sensory neuropathy (type IV) with anhidrosis, and in some patients with diabetic neuropathy, thyroid dysfunction, and multiple myeloma. The many drugs that may cause hypohidrosis include anticholinergics, tricyclic antidepressants, anti-epileptics, antihistamines, antihypertensives, antipsychotics, antiemetics, antivertigo drugs, bladder antispasmodics, gastric antisecretory drugs, muscle relaxants, neuromuscular paralytics, and opioids. Anhidrosis may follow infections, may be part of a neurodegenerative disorder, may occur as a symptom related to toxin exposure, may be a paraneoplastic phenomenon, or may be secondary to autoimmune inflammation. Atopic dermatitis is frequently associated with reduced sweating and pruritus when sweating is triggered. Patients with psoriasis may have similar symptoms, but less frequently. There remains an idiopathic category; this variant may respond to oral steroid treatment. Remission is possible but not universal. Immunosuppressants have been ineffective.

Anhidrosis with pruritus is a rare syndrome of young adults. Severe itching occurs whenever the person is stimulated to sweat. No sweat is delivered to the skin surface, but when the body temperature is raised by about 0.5°C, fine papules appear at each eccrine orifice. The associated pruritus is so severe that the patient feels completely incapacitated and distracted. Cooling immediately resolves the symptoms. This may represent one form of tropical asthenia or a mild form of the autonomic neuropathies described later. The natural history is unknown, but spontaneous resolution may occur after several years. These patients are frequently misdiagnosed as having cholinergic urticaria.

Segmental anhidrosis may be associated with tonic pupils (Holmes-Adie syndrome); this is called Ross syndrome. Patients have heat intolerance and segmental areas of anhidrosis on the trunk, arms, or legs. Loss of deep tendon reflexes in the arms, trunk, and legs is consistently seen. Compensatory segmental hyperhidrosis of functionally intact areas may occur. A selective degeneration of the cholinergic sudomotor neurons is the hypothesized abnormality.

Autonomic neuropathies associated with antibodies to nicotinic acetylcholine receptors may cause a variety of symptoms related to dysfunction of systems controlled by autonomic nerves. There is a spectrum of abnormalities ranging from severe autonomic failure characterized by orthostatic hypotension, GI dysmotility, anhidrosis, bladder dysfunction, and sicca syndrome to isolated anhidrosis and heat intolerance. In

this condition, a biopsy may reveal an inflammatory infiltrate surrounding the eccrine glands, and some patients respond to pulse steroids or immunosuppressants. It may also spontaneously resolve.

Anhidrosis localized to skin lesions occurs regularly over plaques of tuberculoid leprosy. This is also true of segmental vitiligo (but not the generalized type), in the hypopigmented streaks of incontinentia pigmenti, in lesions of syringolymphoid hyperplasia with alopecia and anhidrosis, and on the face and neck of patients with the rare Bazex syndrome, consisting of follicular atrophoderma, basal cell carcinomas, and hypotrichosis, an X-linked dominant disorder.

- Cheshire WP, et al:** Drug-induced hyperhidrosis and hypohidrosis. *Drug Saf* 2008; 31:109.
- Nolano M, et al:** Ross syndrome. *Brain* 2006; 129:2119.
- Ohshima Y, et al:** Treatment of patients with acquired idiopathic generalized anhidrosis. *Br J Dermatol* 2013; 168:426.
- Palm F, et al:** Successful treatment of acquired idiopathic generalized anhidrosis. *Neurology* 2007; 68:532.
- Sandroni P, et al:** Other autonomic neuropathies associated with ganglionic antibodies. *Auton Neurosci* 2009; 146:13.
- Vernino S, et al:** Autonomic ganglia, acetylcholine receptor antibodies, and autoimmune ganglionopathy. *Auton Neurosci* 2009; 146:3.
- Vijayashree R, et al:** Syringolymphoid hyperplasia with alopecia and anhidrosis in a 12-year-old boy. *Int J Dermatol* 2011; 50:1552.
- Xavier MHSB, et al:** Anhidrosis as the first sign of Ross syndrome. *Arq Neuropsiquiatr* 2009; 67:505.
- Yilmazer S, et al:** Generalized anhidrosis. *Neurosciences* 2013; 18:178.

## Bromhidrosis

Also known as fetid sweat, osmidrosis, and malodorous sweating, bromhidrosis is chiefly encountered in the axillae. Bacterial decomposition of apocrine sweat, producing fatty acids with distinctive offensive odors, is considered to be the cause. Often, patients who complain of offensive axillary sweat actually have no offensive odor; the complaint represents a delusion, paranoia, phobia, or a lesion of the central nervous system. Intranasal foreign body and chronic mycotic infection in the sinuses are additional causes. True bromhidrosis is usually not recognized by the patient.

Fish odor syndrome (trimethylaminuria) should be considered in patients presenting with complaints of offensive odor. It is caused by excretion of trimethylamine, which has a rotten-fish odor, in the eccrine sweat, urine, saliva, and other secretions. This chemical is produced from carnitine and choline in the diet and is normally metabolized in the liver. An autosomal dominant defect in the ability to metabolize trimethylamine because of a defect in flavin-containing monooxygenase 3 is the cause of this syndrome. Dietary reduction of foods high in carnitine and choline is beneficial.

Antibacterial soaps and many commercial deodorants are quite effective in controlling axillary malodor. Frequent bathing, changing of underclothes, shaving of the axillae, and topical application of aluminum chloride (Drysol) are all helpful measures. Surgical removal of the glands either by excision or tumescence liposuction is possible, as in axillary hyperhidrosis, but this is rarely indicated. Botulinum toxin A injections in the axilla have controlled body odor in this site as well in the pubic area.

Plantar bromhidrosis is produced by bacterial action on eccrine sweat-macerated stratum corneum. Hyperhidrosis is the main associated factor, and pitted keratolysis is often present. Careful washing with an antibacterial soap and use of dusting powders on the feet are helpful in eliminating bromhidrosis. Use of topical antibiotics, such as clindamycin, may be beneficial. Previously described measures to control

plantar hyperhidrosis should be instituted. Botulinum toxin A is likely to be effective.

**He J, et al:** Excision of apocrine glands and axillary superficial fascia as a single entity for the treatment of axillary bromhidrosis. *J Eur Acad Dermatol Venereol* 2012; 26:704.

**Li H, et al:** A refined surgical treatment modality for bromhidrosis. *Dermatol Surg* 2009; 35:1258.

**Ulman CA, et al:** Fish odor syndrome. *Dermatol Online J* 2014; 20:1260.

**Yang H, et al:** Modified tumescent liposuction-curettage through mini incisions for the treatment of secondary axillary bromhidrosis with subcutaneous scarring. *Plast Reconstr Surg* 2012; 130:916e.

## Chromhidrosis

Chromhidrosis, or colored sweat, is an exceedingly rare functional disorder of the apocrine sweat glands, frequently localized to the face or axilla. It has been less often noted on the abdomen, chest, breasts, thighs, groin, genitalia, and lower eyelids. The colored sweat may be yellow (most common), blue, green, or black. The colored secretion appears in response to adrenergic stimuli, which cause myoepithelial contractions. Colored apocrine sweat fluoresces and is caused by lipofuscin. Treatment with botulinum toxin A or topical capsaicin has been reported to be effective.

Eccrine chromhidrosis is caused by the coloring of the clear eccrine sweat by dyes, pigments, or metals on the skin surface. Examples are the blue-green sweat seen in copper workers and the "red sweat" seen in flight attendants from the red dye in the labels on life vests. Brownish staining of the axillae and undershirt may occur in ochronosis. Yellow sweat has been reported to be secondary to long-term intake of bisacodyl. Bile secretion in eccrine sweat occurs in patients with liver failure and marked hyperbilirubinemia. Small, round, brown or deep-green macules occur on the palms and soles.

**Beer K, et al:** Axillary chromhidrosis. *J Cosmetic Dermatol* 2010; 9:318.

**Krishnam AS, et al:** An interesting case of bisacodyl (dulcolax)-induced chromhidrosis. *Indian J Dermatol Venereol Leprol* 2012; 78:756.

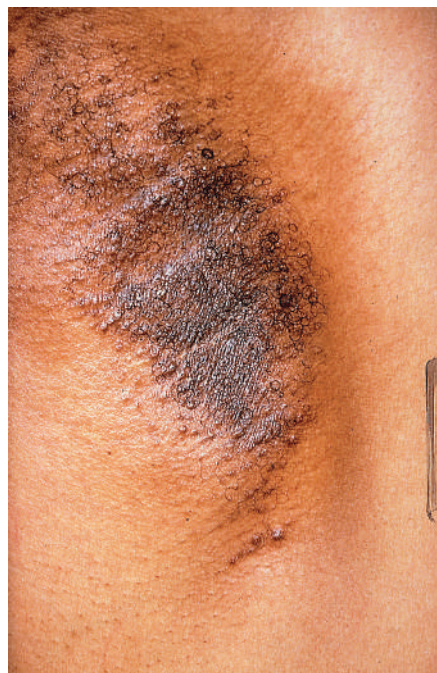**Polat M, et al:** Apocrine chromhidrosis. *Clin Exp Dermatol* 2009; 39:e373.

**Triwongwanat D, et al:** Green pigmentation on the palms and soles. *JAMA Dermatol* 2013; 149:1339.

## Fox-Fordyce disease

Fox-Fordyce disease is rare, occurring mostly in women during adolescence or soon afterward. It may occasionally be familial in nature. It is characterized by conical, flesh-colored or grayish, intensely pruritic, discrete follicular papules in areas where apocrine glands occur (Fig. 33-37). The axillae and areolae are the primary sites of involvement, but the umbilicus, pubes, labia majora, and perineum may be affected. Apocrine sweating does not occur in affected areas, and hair density may be decreased. In some cases, there is no itching. About 90% of cases occur in women between ages 13 and 35, but the disease also may present postmenopausally, after laser hair removal, or in males. Pregnancy invariably leads to improvement.

Histologically, Fox-Fordyce disease is characterized by obstruction of the follicular ostia by orthokeratotic cells. An inflammatory infiltrate of lymphocytes surrounds the upper third of the hair follicles and upper dermal vessels. An associated spongiosis of the infundibulum occurs at the entrance of the apocrine duct into the hair follicle. In one case, detached apoeccrine cells obstructed the duct. Foam cells have been noted as a histologic marker, because many of these findings are either nonspecific or difficult to demonstrate. Localized axillary xanthomatosis has been postulated to be either a variant of Fox-Fordyce disease or a type of verruciform xanthoma.



**Fig. 33-37** Fox-Fordyce disease.

No form of therapy is universally effective for patients with Fox-Fordyce disease. OCs, topical tretinoin or adapalene, topical pimecrolimus or weak corticosteroid creams, intralesional steroids, topical clindamycin solution, benzoyl peroxide, isotretinoin, fractional CO<sub>2</sub> laser, and UV phototherapy have all been effective in small numbers of patients. Excision or liposuction-assisted curettage may be successful in axillary sites.

**Al-Qarqaz F, et al:** Fox-Fordyce disease treatment with fractional CO<sub>2</sub> laser. *Int J Dermatol* 2013; 52:1572.

**Bormate AB Jr, et al:** Perifollicular xanthomatosis as a hallmark of axillary Fox-Fordyce disease. *Arch Dermatol* 2008; 144:1020.

**Jelou J, et al:** Fox-Fordyce-like disease following laser hair removal appearing on all treated areas. *Lasers Med Sci* 2013; 28:1205.

**Kassuga LE, et al:** Fox-Fordyce disease. *An Bras Dermatol* 2012; 87:329.

**Milcic D, et al:** Clinical effects of topical pimecrolimus in a patient with Fox-Fordyce disease. *Australas J Dermatol* 2012; 53:e34.

**Pock L, et al:** Pimecrolimus is effective in Fox-Fordyce disease. *Int J Dermatol* 2006; 45:1134.

**Tetzlaff MT, et al:** Fox-Fordyce disease following axillary laser hair removal. *Arch Dermatol* 2011; 147:573.

## Granulosis rubra nasi

Granulosis rubra nasi is a rare familial disease of children, occurring on the nose, cheeks, and chin. It is characterized by diffuse redness, persistent hyperhidrosis, and small, dark-red papules that disappear on diascopic pressure. The tip of the nose is red or violet. A few small pustules may occur. Hyperhidrosis precedes the erythema. The tip of the nose is cold and is not infiltrated. The disease usually disappears spontaneously at puberty, leaving no trace. The cause is unknown. Histologically, blood vessels are dilated, and an inflammatory infiltrate is seen around the sweat ducts. Treatment is with local preparations for relief of the inflammation, with involu- tion expected at puberty. Botulinum toxin A has been effective in one case.

**Grazziotin TC, et al:** Treatment of granulosis rubra nasi with botulinum toxin type A. *Dermatol Surg* 2009; 35:1298.

**Sargunam C, et al:** Granulosis rubra nasi. *Indian Dermatol Online J* 2013; 4:208.



## Hidradenitis

Hidradenitis is a term used to describe diseases in which the histologic abnormality is primarily an inflammatory infiltrate around the eccrine glands. This group includes neutrophilic eccrine hidradenitis and idiopathic plantar hidradenitis (recurrent palmoplantar hidradenitis). Hidradenitis suppurative is discussed in Chapter 13.

### Neutrophilic eccrine hidradenitis

Ninety percent of patients with neutrophilic eccrine hidradenitis (NEH) have a malignancy. NEH has been described primarily in patients with acute myelogenous leukemia (AML); however, other leukemias, lymphomas, and infrequently solid tumors may be present. It usually begins about 10 days after the start of chemotherapy. Although the majority of patients have been treated with cytarabine, NEH has not been uniformly linked to any chemotherapeutic agent and may occur in untreated patients. Patients with AML in remission have been reported to develop NEH, with associated sclerodermoid changes that herald a relapse of the leukemia. Granulocyte colony-stimulating factor, imatinib mesylate, zidovudine, decitabine, acetaminophen, and various antibiotics have also been implicated as triggers for this neutrophilic dermatosis.

The lesions are typically erythematous and edematous papules and plaques of the extremities, trunk, face (periorbital), and palms (in decreasing frequency). Pigmentation, purpura, or pustules may be present within the papules and plaques. Fever and neutropenia are often present. Histologically, there is a dense neutrophilic infiltrate around and infiltrating eccrine glands. Necrosis of sweat glands may be present, with or without the inflammatory infiltrate. Syringo-squamous metaplasia may occur. This finding can also occur in fibrosing alopecia, in burn scars, adjacent to various non-melanoma skin cancers and ischemic and surgical ulcers, in alopecia mucinosa, and in ports of radiation therapy.

The lesions may recur with repeated courses of chemotherapy, but many do not. Resolution over 1–4 weeks (average 10 days) usually occurs. Nonsteroidal anti-inflammatory drugs or oral corticosteroids may hasten the healing. Prophylactic administration of dapsone prevented recurrence in one patient.

Infections may also precipitate neutrophilic hidradenitis as a recurrent, pruritic, papular eruption. *Serratia*, *Enterobacter cloacae*, *Nocardia*, and *Staphylococcus aureus* have been implicated, and appropriate antibiotics for bacterial agents are curative. The diagnosis is confirmed by histologic evaluation and culture of affected tissue (surface cultures may not be adequate). Additionally, many HIV-infected patients have developed neutrophilic eccrine hidradenitis. An idiopathic generalized variant has occurred in four healthy Asian children ages 6 to 16 months. Spontaneous resolution is reported.

### Recurrent palmoplantar hidradenitis

Recurrent palmoplantar hidradenitis is primarily a disorder of healthy children and young adults. Lesions are primarily painful, subcutaneous nodules on the plantar surface, resembling erythema nodosum. Rarely, palmar lesions also occur. In some children, *Pseudomonas* infection may be the cause (pseudomonal hot foot syndrome; see Chapter 14, *P. aeruginosa* folliculitis). Children may present refusing to walk because of plantar pain. The condition is typically recurrent and may be triggered by exposure to wet shoes or cold, damp weather. The use of oral and topical steroidal preparations may be beneficial.

**Abbas O, et al:** Question: Can you identify this condition? Palmoplantar eccrine hidradenitis. *Can Fam Physician* 2010; 56:666.

**Andreu-Barasoain M, et al:** Generalized idiopathic neutrophilic eccrine hidradenitis in a 7-month-old child. *J Am Acad Dermatol* 2012 Oct; e133.

**Bhanu P, et al:** Neutrophilic eccrine hidradenitis. *Indian J Pharmacol* 2013; 45:91.

**Ng ES, et al:** Neutrophilic eccrine hidradenitis associated with decitabine. *Leukemia Res* 2010; 34:e130.

**Rouanet I, et al:** Neutrophilic eccrine hidradenitis in an HIV-1-infected patient. *AIDS* 2012; 26:775.

**Turan H, et al:** Neutrophilic eccrine hidradenitis induced by cetuximab. *Cutan Ocul Toxicol* 2012; 31:148.

## DISEASES OF THE NAILS

Several general references are available that review a wide spectrum of nail changes.

**André J, et al:** Nail pathology. *Clin Dermatol* 2013; 31:526.

**Baran R, et al:** Nail therapies. Boca Raton: CRC Press, 2012.

**Baran R, et al:** Diseases of the nails and their management. Hoboken: Wiley, 2012.

**Chu DH, et al:** Diagnosis and management of nail disorders in children. *Pediatr Clin North Am* 2014; 61:293.

**Flint WW, et al:** Nail and skin disorders of the foot. *Med Clin North Am* 2014; 98:213.

**Haneke E:** Nail surgery. *Clin Dermatol* 2013; 31:516.

**Inamadar AC, et al:** Nails: diagnostic clue to genodermatoses. *Indian J Dermatol Venereol Leprol* 2012; 78:271.

**Tosti A, et al:** Color atlas of nails. New York: Springer, 2010.

**Zaiac MN, et al:** Nail abnormalities associated with systemic pathologies. *Clin Dermatol* 2013; 31:627.

### Nail-associated dermatoses

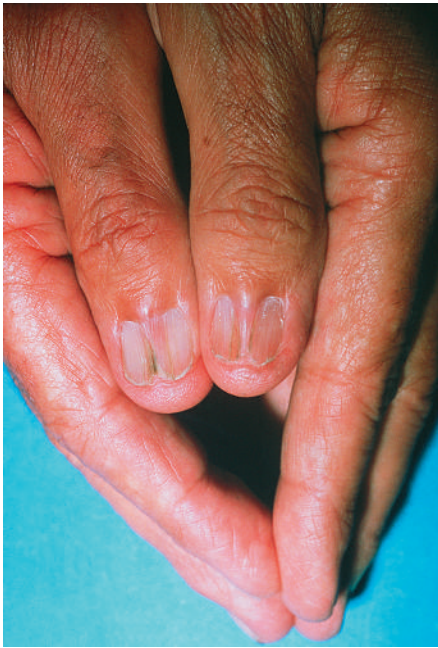Numerous dermatoses are associated with characteristic, sometimes specific, nail changes. Many are considered in other chapters.

#### Lichen planus of nails

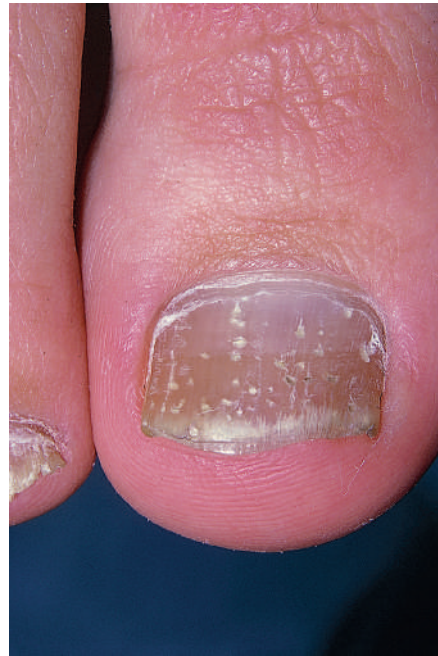The reported incidence of nail involvement in lichen planus varies from less than 1% to 10%. Lichen planus of the nails occurs without skin changes, but 25% with nail disease will have lichen planus at other locations. Although it may occur at any age, most frequently it begins during the fifth or sixth decade of life. The nail plate may be greatly thinned, and at times, distinct papules of lichen planus may involve the nail bed. Twenty-nail dystrophy (trachyonychia) may be the sole manifestation of lichen planus. Other nail changes are irregular longitudinal grooving and ridging of the nail plate, thinning of the nail plate, pterygium formation (Fig. 33-38), shedding of the nail plate with atrophy of the nail bed, subungual keratosis, or even onychopapilloma, erythronychia (red streaks), subungual hyperpigmentation, and nail degloving. This last sign involves partial or total shedding of the nail or the entire nail apparatus. The surrounding skin may also slough. This may be caused by trauma, ischemia and gangrene, or severe dermatologic disease such as toxic epidermal necrolysis or lichen planus.

The histologic changes of lichen planus may be evident in any individual nail constituent or a combination of them. The constituent most frequently involved is the matrix.

Treatment with intralesional injection of corticosteroids may be effective. Digital nerve blocks should be considered before infiltration of the matrix or nail bed. Topical corticosteroids under polyethylene occlusive dressings are usually inadequate; however, when applied with tazarotene it may be successful. Oral prednisone (0.5–1 mg/kg for 3 weeks) or oral retinoids in combination with topical corticosteroids applied



**Fig. 33-38** Pterygium caused by lichen planus. (Courtesy of Dr. Lawrence Lieblich.)



**Fig. 33-39** Pitting caused by psoriasis.

to the involved sites has been successful in some patients. Tosti et al. reported that children with typical lichen planus of the nails responded to 0.5–1 mg/kg/month of intramuscular triamcinolone acetonide given for 3–6 months, until the proximal half of the nail was normalized. Disease recurred in only two patients during the follow-up period. Although twenty-nail dystrophy was not treated, patients spontaneously improved; those with idiopathic atrophy of the nails were unchanged. (See Chapter 12 for additional therapeutic considerations.)

**Baran R, et al:** Nail degloving, a polyetiologic condition with 3 main patterns. *J Am Acad Dermatol* 2008; 58:232.

**Brauns B, et al:** Intralesional steroid injection alleviates nail lichen planus. *Int J Dermatol* 2011; 50: 626-627.

**Goettmann S, et al:** Nail lichen planus. *J Eur Acad Dermatol Venerol* 2012; 26:1304.

**Jellinek NJ:** Longitudinal erythronychia. *J Am Acad Dermatol* 2011; 64:167e1.

**Nakamura R, et al:** Dermatoscopy of nail lichen planus. *Int J Dermatol* 2013; 52:684-687.

**Piraccini BM, et al:** Nail lichen planus. *Eur J Dermatol* 2010; 20:489.

**Richert B, et al:** Nail bed lichen planus associated with onychopapilloma. *Br J Dermatol* 2007; 156:107.

**Tosti A, et al:** Nail lichen planus in children: clinical features, response to treatment and long term follow-up. *Arch Dermatol* 2001; 137:1027.

## Psoriatic nails

Nail involvement in psoriasis is common, with the reported incidence varying from 10% to 78%. Older patients, those with active exacerbations of disease, and those with psoriatic arthritis are more likely to express nail abnormalities. The nail plate may have pits (Fig. 33-39), or much less often, furrows or transverse depressions (Beau's lines), crumbling nail plate, or leukonychia, with a rough or smooth surface. Splinter hemorrhages are found in the nail bed, with reddish discoloration of a part or all of the nail bed, and horny masses. In the hyponychia, subungual hyperkeratosis, oil spots, and a yellowish green discoloration may occur in the area of onycholysis. Onychomycosis may be closely simulated. The severity of nail disease may correlate with the severity of skin and joint disease. Pustular psoriasis may produce onycholysis, with lakes of pus in the nail bed or in the perionychial areas. Rarely,

anonychia may result. Other papulosquamous diseases may affect the nails similar to psoriasis, with the exception of nail pitting. Reiter's disease, pityriasis rubra pilaris, Sézary syndrome, and acrokeratosis paraneoplastica produce hypertrophic nails with subungual hyperkeratosis.

Psoriatic nail disease may be a solitary finding or may be part of a widespread skin and nail involvement. The treatment options selected depend on the degree of cutaneous and nail involvement (see Chapter 10 for additional information and therapeutic options). Successful systemic treatment of psoriasis will usually also improve or clear the nail changes. Methotrexate, PUVA, cyclosporine, biologics, or acitretin may be effective. All local therapies have limitations. Intralesional injection of triamcinolone acetonide suspension, 3–5 mg/mL, with a 30-gauge needle is frequently helpful. Digital nerve block facilitates adequate injection. Topical 5-fluorouracil (5-FU) applied to the proximal nailfold has been reported to be effective. It is best to avoid the free edge of the nail when applying 5-FU because it may cause distal onycholysis. Topical cyclosporine and topical tazarotene 0.1% gel may also be helpful. Topical calcipotriol improves about 50% of patients with localized pustular psoriasis of the nails and may be used as a maintenance treatment after successful intervention with systemic retinoids.

**Demirsoy EO, et al:** Effectiveness of systemic treatment agents on psoriatic nails. *J Drugs Dermatol* 2013; 12:1039.

**de Vries AC, et al:** Interventions for nail psoriasis. *Cochrane Database Syst Rev* 2013; 1:CD007633.

**Diluvio L, et al:** Childhood nail psoriasis. *Pediatr Dermatol* 2007; 24:332.

**Kyriakou A, et al:** Biologic agents in nail psoriasis. *Expert Opin Bio Ther* 2013; 13:1707.

**Oram Y, et al:** Treatment of nail psoriasis. *Dermatol Res Pract* 2013; 2013:180496.

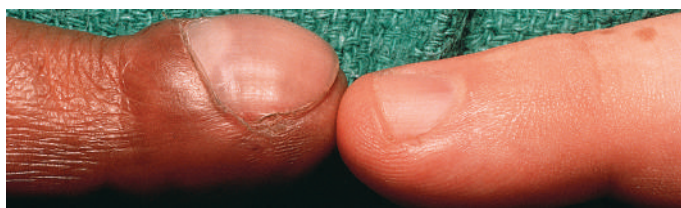**Sandre MK, et al:** Psoriatic arthritis and nail changes. *Semin Arthritis Rheum* 2014 May 6. Pii: S0049-00172(14)00072-9.

**Schons KR, et al:** Nail psoriasis. *An Bras Dermatol* 2014; 89:312.

## Darier's disease

Longitudinal, subungual, red or white streaks, associated with distal wedge-shaped subungual keratoses, are the nail signs diagnostic for Darier-White disease. Keratotic papules on





**Fig. 33-40** Clubbing. (Courtesy of Dr. Lawrence Lieblich.)

the dorsal portion of the nailfold may clinically resemble acrokeratosis verruciformis, but histologically, they have features of Darier's disease. Other nail findings include splinter hemorrhages and leukonychia. All these findings are less pronounced on the toenails.

**Bae-Harboe YS, et al:** JAAD Grand Rounds quiz: Nail dystrophy and multiple hyperkeratotic papules on the face and neck. *J Am Acad Dermatol* 2013; 69:847.

## Clubbing

Clubbing is divided into two types: idiopathic and acquired, or secondary. The changes occur not only in the nails but also in the terminal phalanges. The nails bulge and are curved in a convex arc in both transverse and longitudinal directions. The eponychium is thickened. The angle formed by the dorsal surface of the distal phalanx and the nail plate (Lovibond's angle) is approximately 160 degrees; with clubbing, however, this angle is obliterated and becomes 180 degrees or greater (Fig. 33-40). There is no diamond-shaped window when the dorsal surfaces of the corresponding finger of each hand are opposed (Schamroth's sign). The soft tissues of the terminal phalanx are bulbous and are mobile when pressure is applied over the matrix. Thickening of the nail bed is present and can be assessed reliably by a plain radiograph of the index finger.

Idiopathic clubbing is either the isolated dominantly inherited type or the pachydermoperiostosis type with its associated findings. In the hereditary isolated type, mutations of the human *HPGD* gene encoding NAD(+)-dependent 15-hydroxyprostaglandin dehydrogenase and the prostaglandin transporter *SLCO2A1* have been identified. Secondary (acquired) clubbing is usually a consequence of pulmonary, cardiac, thyroid, hepatic, or GI disease. About 36% of HIV-infected patients have clubbed nails. Typically, there is periostitis, with periosteal new bone formation in the phalanges, metacarpals, and distal ulna and radius. This is called hypertrophic osteoarthropathy and is responsible for the painful clubbing. It typically occurs in men with bronchogenic carcinoma. Unilateral or asymmetric clubbing may also occur in Takayasu arteritis and sarcoidosis.

**Anoop TM, et al:** Differential clubbing and cyanosis. *N Engl J Med* 2011; 364: 666.

**Bergmann C, et al:** Primary hypertrophic osteoarthropathy with digital clubbing and palmoplantar hyperhidrosis caused by 14-PGHD/*HPGD* loss-of-function mutations. *Exp Dermatol* 2011; 20:529.

**Busch J, et al:** Mutations in the prostaglandin transporter *SLCO2A1* cause primary hypertrophic osteoarthropathy with digital clubbing. *J Invest Dermatol* 2012; 132:2473.

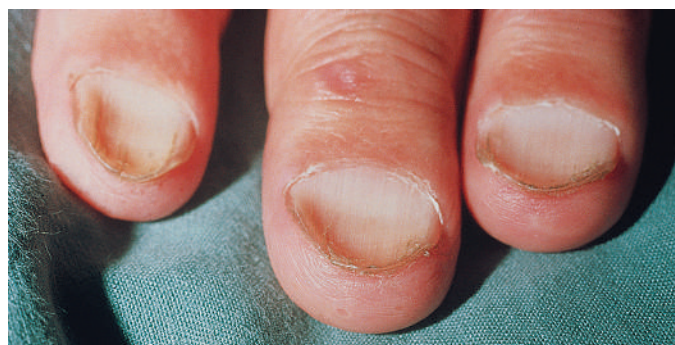**Dever LL, et al:** Digital clubbing in HIV-infected patients. *AIDS Patient Care STDS* 2009; 23:19.

**Gibb C, et al:** Clubbing. *Br J Hosp Med* 2013; 74:C170.

**Pallarés-Sanmartín A, et al:** Validity and reliability of the Schamroth sign for the diagnosis of digital clubbing. *JAMA* 2010; 304:159.

**Spicknall KE, et al:** Clubbing. *J Am Acad Dermatol* 2005; 52:1020.

**Tariq M, et al:** Mutation in the *HPGD* gene encoding NAD+dependent 15-hydroxyprostaglandin dehydrogenase underlies isolated congenital nail clubbing. *J Med Genet* 2009; 46:14.



**Fig. 33-41** Koilonychia.

## Shell nail syndrome

Cornelius described a shell nail in association with bronchiectasis. The nail resembles a clubbed nail, but the nail bed is atrophic instead of being a bulbous proliferation of the soft tissue.

**Cornelius CE:** Shell nail syndrome. *Arch Dermatol* 1969; 100:118.

## Koilonychia (spoon nails)

Spoon nails are thin and concave, with the edges everted so that if a drop of water were placed on the nail, it would not run off (Fig. 33-41). Koilonychia may result from faulty iron metabolism and is one of the signs of Plummer-Vinson syndrome, as well as of hemochromatosis. Spoon nails have been observed in coronary disease, syphilis, polycythemia, and acanthosis nigricans. Familial forms are also known to occur. Other associations include psoriasis, lichen planus, Raynaud syndrome, scleroderma, acromegaly, hypothyroidism and hyperthyroidism, monilethrix, palmar hyperkeratosis, and steatocystoma multiplex. A significant number of cases are idiopathic. Manual trauma in combination with cold exposure may result in seasonal disease. Sherpas are Tibetan people living in the Nepalese Himalayas, who often serve as porters on mountain-climbing expeditions. Chronic cold exposure, in combination with hypoxemia, may contribute to the high frequency with which koilonychia is observed among them and people living in the Leh Ladakh region of India.

**Sattur AP, et al:** Koilonychia. *N Engl J Med* 2010; 362:e59.

**Yanamandra U, et al:** Ladakhi koilonychias. *BMJ Case Rep* 2014 Jan 16; Pii: bcr2013202567.

## Congenital onychodysplasia of index fingers

Congenital onychodysplasia of the index fingers is defined by the presence of the condition at birth, index finger involvement (unilateral or bilateral), variable distortion of the nail or lunula, and polyonychia, micronychia, anonychia, hemionychogryphosis, or malalignment. It may also involve adjacent fingers, such as the middle fingers and thumbs. An underlying bone dysplasia may be present beneath the involved nail. Cases have occurred in an autosomal dominant pattern; other proposed causes include in utero ischemia or exposure to teratogens.

**Hussein TP, et al:** Malformations of the index nails. *Clin Exp Dermatol* 2009; 34:890.

**Park SW, et al:** Treatment of congenital onychodysplasia of the index finger with specialized nail device. *Clin Exp Dermatol* 2013; 38: 791.

## Trachyonychia

The nails may become opalescent, thin, dull, fragile, and finely ridged longitudinally (and as a result, distally notched). When this involves all 20 nails, it is referred to as twenty-nail dystrophy. This latter presentation may be seen at any age from 1½ years to adulthood, although it is most frequently diagnosed in children. It can be idiopathic or may be caused by alopecia areata, psoriasis, lichen planus, atopy, ichthyosis vulgaris, or other inflammatory dermatoses. Familial forms exist. In some cases, spongiosis may be found on nail biopsy. Trachyonychia has also been reported associated with autoimmune processes such as selective IgA deficiency, vitiligo, sarcoidosis, and graft-versus-host disease. Unilateral involvement may occur in complex regional pain syndrome. Thus it is caused by a heterogeneous group of inflammatory conditions. Tazarotene alone or in association with topical corticosteroids may improve the condition. Childhood cases may resolve spontaneously; in one study, 50% cleared within 6 years.

**Blanco FP, et al:** Trachyonychia. *J Drugs Dermatol* 2006; 5:469.

**Gordon KA, et al:** Trachyonychia. *Indian J Dermatol Venereol Leprol* 2011; 77:640.

**Sakata S, et al:** Follow up of 12 patients with trachyonychia. *Australas J Dermatol* 2006; 47:166.

## Onychauxis

In onychauxis, the nails are thickened but without deformity (simple hypertrophy). Simple thickening of the nails may be the result of trauma, acromegaly, Darier's disease, psoriasis, or pityriasis rubra pilaris. Some cases are hereditary. Treatment involves periodic partial or total debridement of the thickened nail plate by mechanical or chemical (40% urea paste) means. Matricectomy and nail ablation are options, as they are in onychogryphosis, congenital nail dystrophies, and chronic painful nails, such as recalcitrant ingrown toenails or splits within the medial or lateral third of the nail.

**Baran R, et al:** Matricectomy and nail ablation. *Hand Clin* 2002; 18:696.

**Singh G, et al:** Nail changes and disorders among the elderly. *Indian J Dermatol Venereol Leprol* 2005; 71:386.

## Onychogryphosis

Hypertrophy may produce nails resembling claws or a ram's horn. Onychogryphosis may be caused by trauma or peripheral vascular disorders but is most often caused by neglect (failure to cut the nails for very long periods). It is most often seen in elderly persons. Some recommend avulsion of the nail plate with surgical destruction of the matrix with phenol or the CO<sub>2</sub> laser, if the blood supply is good.

**Nath AK, et al:** Congenital onychogryphosis. *Dermatol Online J* 2011; 17:9.

## Onychophosis

A common finding in the elderly population, onychophosis is a localized or diffuse hyperkeratotic tissue that develops on the lateral or proximal nailfolds, within the space between the nailfolds and the nail plate. It may involve the subungual area, as a direct result of repeated minor trauma, and most frequently affects the first and fifth toes. The use of comfortable shoes should be encouraged. The areas involved should be debrided and treated with keratolytics. Emollients are also helpful.

**Singh G, et al:** Nail changes and disorders among the elderly. *Indian J Dermatol Venereol Leprol* 2005; 71:386.

## Anonychia

Absence of nails, a rare anomaly, may be the result of a congenital ectodermal defect, ichthyosis, severe infection, prenatal phenytoin exposure, severe allergic contact dermatitis, self-inflicted trauma, Raynaud phenomenon, lichen planus, epidermolysis bullosa, or severe exfoliative diseases. Permanent anonychia has been reported as a sequel of Stevens-Johnson syndrome. It may also be found in association with congenital developmental abnormalities, such as microcephaly, and wide-spaced teeth (autosomal recessive inheritance), autosomal dominant Cooks syndrome (brachydactyly-anonychia), which has been associated with duplications of the noncoding elements of Sox9, DOOR syndrome (deafness, onychosteodystrophy, mental retardation), and the glossopalatine syndrome (abnormal mouth, tongue being attached to temporomandibular joint).

Anonychia may also present as an autosomal recessive disorder with anonychia as the solitary finding. It has been found to be caused by a mutation in the gene for R-spondin 4. R-spondins are secreted proteins that activate the Wnt/β-catenin signaling pathway. R-spondin 4 is exclusively expressed in the mesenchyme underlying the digit tip epithelium in embryonic mice.

**Babu S, et al:** Anonychia due to prenatal phenytoin exposure. *J Assoc Phys India* 2012; 60:64.

**Ishii Y, et al:** Mutations in R-spondin 4 underlie inherited anonychia. *J Invest Dermatol* 2008; 128:867.

**Kurth I, et al:** Duplications of noncoding elements 5' of SOX9 are associated with brachydactyly-anonychia. *Nat Genet* 2009; 41:862.

**Wasif N, et al:** A novel nonsense mutation in *RSP04* gene underlies autosomal recessive congenital anonychia in a Pakistani family. *Pediatr Dermatol* 2013; 30:139.

## Onychoatrophy

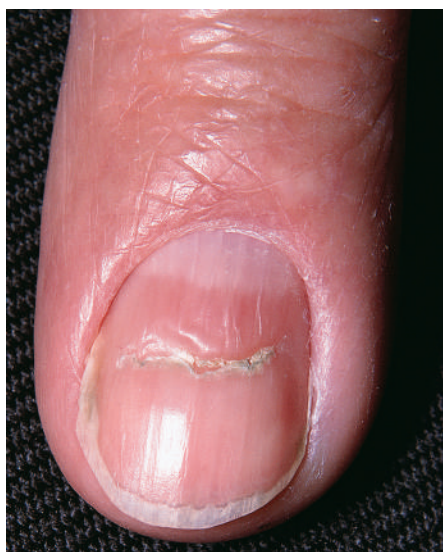Faulty underdevelopment of the nail may be congenital or acquired. The nail is thinned and small. Vascular disturbances, epidermolysis bullosa, lichen planus, Darier's disease, multicentric reticulohistiocytosis, and Hansen's disease may cause onychoatrophy. Onychoatrophy is also seen in congenital syndromes such as Apert, Goltz, Turner, Ellis-van Creveld, nail-patella, dyskeratosis congenita, cartilage-hair hypoplasia, progeria, hypohidrotic ectodermal dysplasia, incontinentia pigmenti, popliteal web, trisomy 13, trisomy 18, and as a side effect of etretinate therapy.

**Al Hawsawi K, et al:** Anonychia congenita totalis. *Int J Dermatol* 2002; 41:397.

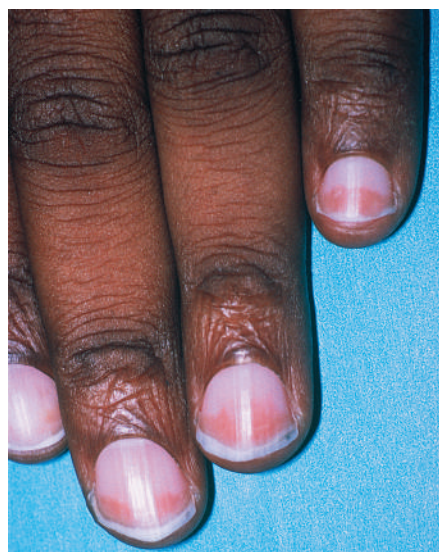## Onychomadesis

Onychomadesis is a periodic idiopathic shedding of the nail beginning at its proximal end. The temporary arrest of the function of the nail matrix may cause onychomadesis. Neurologic disorders, peritoneal dialysis, cutaneous T-cell lymphoma, Kawasaki's disease, pemphigus vulgaris, drug allergy, hand, foot, and mouth disease, varicella infection, Cronkite-Canada syndrome, and keratosis punctata palmaris et plantaris have been reported causes. It may appear as a periodic finding in runners. Immobilization from casting for fractures may cause onychomadesis. Medications such as antineoplastic agents, valproic acid, azithromycin, and retinoids may cause





**Fig. 33-42** Beau's lines.



**Fig. 33-43** Half and half nails.

onychomadesis as well. It may be an idiopathic finding in adults and neonates.

**Bettoli V, et al:** Onychomadesis following hand, foot, and mouth disease. *Int J Dermatol* 2013; 52:728.

**Kocak AY, et al:** Onychomadesis in two sisters induced by *Varicella* infection. *Pediatr Dermatol* 2013; 30:e108.

**Parmar B, et al:** Neonatal onychomadesis. *Pediatr Dermatol* 2010; 27:115.

**Piraccini BM, et al:** Twenty nail onychomadesis. *J Am Acad Dermatol* 2010; 63:172.

### Beau's lines

Beau's lines are transverse furrows that begin in the matrix and progress distally as the nail grows (Fig. 33-42). They are ascribed to the temporary arrest of function of the nail matrix. Although usually found to be bilateral, unilateral Beau's lines may occur. Various systemic and local traumatic factors may cause the lines. They may result from almost any systemic illness or major injury, such as a broken hip. Some specific associations are childbirth, measles, paronychia, acute febrile illnesses, high-altitude exposure, and drug reaction. When the process is intermittent, the nail plate may resemble corduroy. Shelley "shoreline" nails appear to be a severe expression of essentially the same transient growth arrest. Beau's lines have been reported in all 20 nails of a newborn.

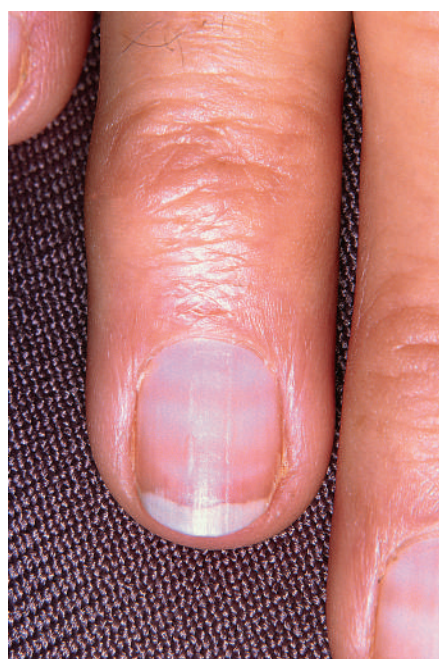**Park J, et al:** Images in clinical medicine. Multiple Beau's lines. *N Engl J Med* 2010; 362: e63.

**Ryu H, et al:** Beau's lines of the fingernails. *Am J Med Sci* 2014 Mar 24. (Epub ahead of print.)

### Half and half nails

Half and half nails show the proximal portion of the nail white and the distal half red, pink, or brown, with a sharp line of demarcation between the two halves (Fig. 33-43). About 76% of hemodialysis patients and 56% of renal transplant patients have at least one type of nail abnormality. Half and half nails are the most common, affecting 20% of hemodialysis patients. Absence of lunula, splinter hemorrhage, and half and half nails were significantly more common in hemodialysis patients, whereas leukonychia was significantly more common in transplant patients.

**lorizzo M, et al:** Half and half nails. *Cutis* 2011; 88:138.



**Fig. 33-44** Muehrcke's lines.

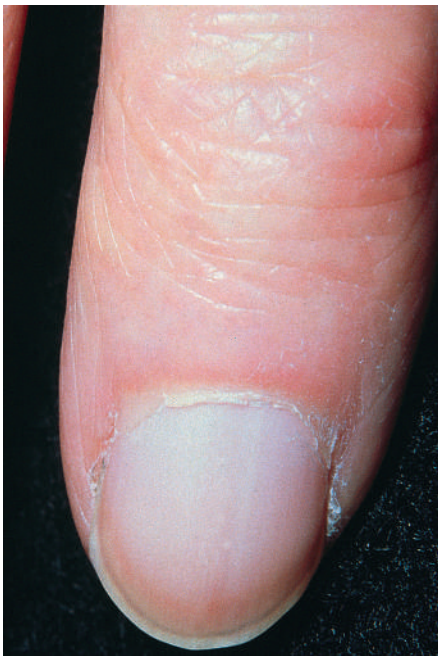**Salem A, et al:** Nail changes in chronic renal failure patients under haemodialysis. *J Eur Acad Dermatol Venereol* 2008; 22:1326.

### Muehrcke's lines

Muehrcke described narrow, white transverse bands occurring in pairs as a sign of chronic hypoalbuminemia. The lines may resolve when serum albumin is raised to or near normal (Fig. 33-44). Unlike Mees' lines, the disturbance appears to be in the nail bed, not in the nail plate. Similar lines have been reported in patients with normal albumin levels who are receiving chemotherapy. In a case of unilateral Muehrcke's lines associated with trauma, it was suggested that edema effects this change by inducing microscopic separation of the normally tightly adherent nail from its bed.

**Short N, et al:** Muehrcke's lines. *Am J Med* 2010; 123:991.

**Stanifer J, et al:** Muehrcke's lines as a diagnostic clue to increased catabolism and a severe system disease state. *Am J Med Sci* 2011; 342:331.



**Fig. 33-45** Terry nails.

### Mees' lines

Mees described single or multiple white transverse bands in 1919 as a sign of inorganic arsenic poisoning. They have also been reported in thallium poisoning, septicemia, dissecting aortic aneurysm, parasitic infections, chemotherapy, and both acute and chronic renal failure.

**Chauhan S, et al:** Mees' lines. *Lancet* 2008; 372:1410.

**Lu CI, et al:** Short-term thallium intoxication. *Arch Dermatol* 2007; 143:93.

### Terry nails

In Terry nails, the distal 1–2 mm of the nail shows a normal pink color (Fig. 33-45), whereas the entire nail plate or proximal end has a white appearance as a result of telangiectases in the nail bed. These changes have been noted in 25% of hospitalized patients, most often those with cirrhosis, chronic congestive heart failure, and adult-onset diabetes, and in very elderly patients.

**Albuquerque A, et al:** Hepatobiliary and pancreatic: Terry's nails and liver disease. *J Gastroenterol Hepatol* 2012; 27:1539.

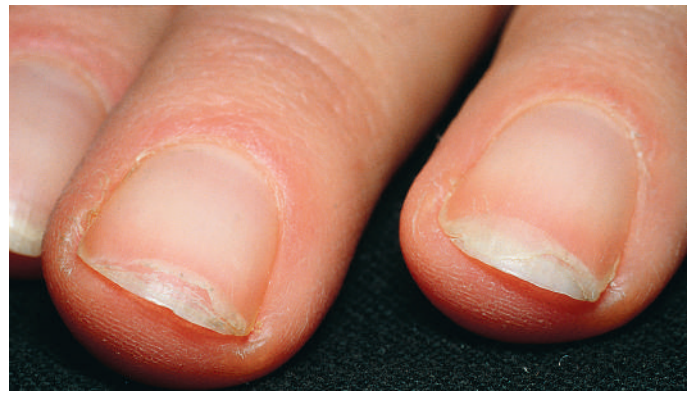**Baran B, et al:** Terry's nail: an overlooked physical finding in cirrhosis. *Hepatobiliary Pancreat Dis Int* 2013; 12:109.

**Nia AM, et al:** Terry's nails: A window to systemic diseases. *Am J Med* 2011; 124:602.

### Onychorrhexis (brittle nails)

Brittleness with breakage of the nails may result from frequent soap and water exposure, nail polish remover, hypothyroidism, anorexia or bulimia, or after oral retinoid therapy. It affects up to 20% of the population, women twice as often as men. *Fragilitas unguium* (nail fragility) is part of this process. In a series of 35 patients treated with biotin, 63% showed clinical improvement. The nail plate thickness in patients treated with biotin increases by 25%. Daily application of white petrolatum after soaking in water is also helpful.

**Gequelim GC, et al:** Perception of brittle nails in dermatologic patients. *An Bras Dermatol* 2013; 88:1022.



**Fig. 33-46** Onychoschizia.

**Nanda S, et al:** Utility of gel nails in improving the appearance of cosmetically disfigured nails. *J Cutan Aesthet Surg* 2014; 7:26.

**Uyttendaele H, et al:** Brittle nails: pathogenesis and treatment. *J Drugs Dermatol* 2003; 2:48.

**Van de Kerkhof PC:** Brittle nail syndrome. *J Am Acad Dermatol* 2005; 53:644.

### Onychoschizia

Splitting of the distal nail plate into layers at the free edge is a very common problem among women and represents a dyshesion of the layers of keratin, possibly as a result of dehydration (Fig. 33-46). Longitudinal splits may also occur. Patients with biotinidase deficiency may manifest onychoschizia, along with total or partial alopecia and an eczematous or desquamating periorificial eruption. Hypotonia, seizures, and developmental delay in children and depression in adults are the most common systemic abnormalities. Lack of treatment may result in loss of hearing and vision.

Nail polish should be discontinued; nail buffing can be substituted. Use of gel nails is well accepted and effective. Frequent application of emollients may be helpful. Biotin has also been shown to be effective in doses up to 2.5 mg/day, or two to four times that much in deficient patients.

**Gequelim GC, et al:** Perception of brittle nails in dermatologic patients. *An Bras Dermatol* 2013; 88:1022.

**Nanda S, et al:** Utility of gel nails in improving the appearance of cosmetically disfigured nails. *J Cutan Aesthet Surg* 2014; 7:26.

### Stippled nails

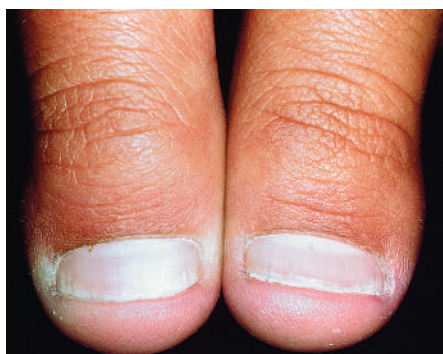Small, pinpoint depressions in an otherwise normal nail characterize this type of nail change. This may be an early change seen in psoriasis. Stippled nails are also seen with some cases of alopecia areata, in early lichen planus, psoriatic or rheumatoid arthritis, chronic eczematous dermatitis, perforating granuloma annulare, and in some individuals with no apparent disease. The deeper, broader pits are more specific for psoriasis. The pitting in alopecia areata tends to be shallower and more regular, suggesting a "Scotch plaid" (tartan) pattern.

**Tosti A, et al:** Prevalence of nail abnormalities in children with alopecia areata. *Pediatr Dermatol* 1994; 11:12.

### Racquet nails (nail en raquette)

In racquet nails, the end of the thumb is widened and flattened, the nail plate is flattened as well, and the distal phalanx is abnormally short (Fig. 33-47). Racquet nails occur on one or both thumbs and are usually inherited as an autosomal





**Fig. 33-47** Racquet nails.

dominant trait. Acquired cases have been documented in hyperparathyroidism and Erasmus syndrome (systemic sclerosis following silica exposure).

**Baran R, et al:** Acquired racquet nails. *J Eur Acad Dermatol Venerol* 2013 May 20. Doi: 10.1111/jdv.12187. (Epub ahead of print.)

**Vetrichevvel TP, et al:** Acquired racquet nails in Erasmus syndrome. *Int J Dermatol* 2010; 49:932.

### Chevron nail (herringbone nail)

This entity is a rare, transient fingernail ridge pattern of children. The ridges arise from the proximal nailfold and converge in a V-shaped pattern toward a midpoint distally.

**Delano S, et al:** Chevron nails: a normal variant in the pediatric population. *Pediatr Dermatol* 2014; 31:e24.

### Hapalonychia

Softened nails result from a defect in the matrix that makes the nails thin and soft so that they can be easily bent. This type of nail change is attributed to malnutrition and debility. It may be associated with myxedema, rheumatoid arthritis, anorexia, bulimia, Hansen's disease, Raynaud phenomenon, oral retinoid therapy, or radiodermatitis.

**Baran R, et al:** Baran and Dawber's Diseases of the Nails and Their Management. Oxford: Blackwell Scientific, 2008.

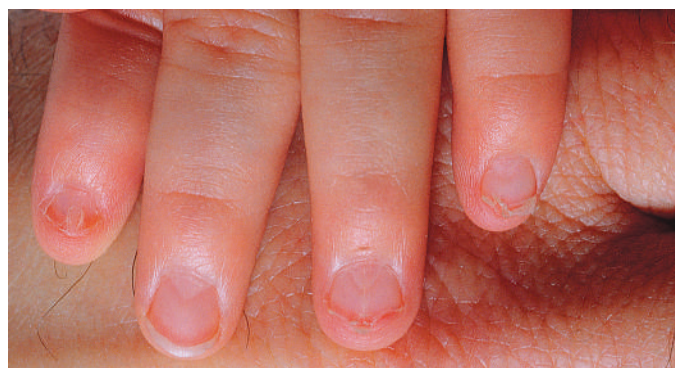### Platonychia

The nail is abnormally flat and broad. It may be seen as part of an autosomal dominant condition in which multiple nail abnormalities are present in many members of a large family.

**Hamm H, et al:** Isolated congenital nail dysplasia: a new autosomal dominant condition. *Arch Dermatol* 2000; 136:1239.

### Nail-patella syndrome (hereditary osteo-onychodysplasia, Fong syndrome)

Nail-patella syndrome comprises numerous anomalies and is characterized by the absence or hypoplasia of the patella and congenital nail dystrophy. Triangular lunulae are characteristic (Fig. 33-48). Other bone features are thickened scapulae, hyperextensible joints, radial head abnormalities, and posterior iliac horns. The skin changes may also include webbing of the elbows. Eye changes such as cataracts, glaucoma, and heterochromia of the iris may also be present. Hyperpigmentation of the pupillary margin of the iris ("Lester iris") is a characteristic finding in about half the cases. Patients with nail-patella syndrome may exhibit glomerulonephritis with



**Fig. 33-48** Nail-patella syndrome. (Courtesy of Dr. Marshall Guill.)

urinary findings of albuminuria, hematuria, and casts of all kinds, especially hyaline casts. They may be predisposed to developing hemolytic-uremic syndrome, edema, and hypertension. About 60% of patients have renal abnormalities, and 20% develop renal failure. It is an autosomal dominant trait; mutations of the human *LMX1B* gene result in this syndrome.

**Alvarez-Martin N, et al:** Nail-patella syndrome. *Nefrologia* 2013; 33:585.

**Fernandes GC, et al:** Nail-patella syndrome. *J Clin Rheumatol* 2011; 17:402.

**Richert B, et al:** Nail disorders in children. *Am J Clin Dermatol* 2011; 12:101.

**Granata A, et al:** Nail-patella syndrome and renal involvement. *Clin Nephrol* 2008; 69:377.

### Onychophagia

Nail biting is a common compulsive behavior that may greatly shorten the nail bed, sometimes damages the matrix, and at times leads to longitudinal melanonychia or pterygium formation. It is a difficult habit to cure. If there is strong motivation, habit reversal training with awareness training, competing response training, and social support may help. Psychopharmacologic intervention with medications, such as serotonin reuptake inhibitors, and hypnosis are other options.

**Anolik RB, et al:** Onychophagia-induced longitudinal melanonychia. *Pediatr Dermatol* 2012; 29:488.

**Durdu M, et al:** Clinical and cytologic features of antibiotic-resistant acute paonychia. *J Am Acad Dermatol* 2014; 70:120.

**Ghanizadeh A, et al:** Habit reversal versus object manipulation training for treating nail biting. *Iran J Psychiatry* 2013; 8:61.

**Pacan P, et al:** Onychophagia and onychotillomania. *Acta Derm Venerol* 2014; 94:67.

### Onychotillomania

Onychotillomania is a compulsive neurosis in which the patient picks constantly at the nails or tries to tear them off. This obsessive-compulsive disorder may be treated by habit reversal training, hypnosis, or psychopharmacologic agents.

**Pacan P, et al:** Onychophagia and onychotillomania. *Acta Derm Venerol* 2014; 94:67.

**Reese JM, et al:** Onychotillomania. *J Cutan Pathol* 2013; 40:419.

**Snorrason I, et al:** Nail picking disorder (onychotillomania). *J Anxiety Disord* 2014; 28:211.

### Onycholysis

Onycholysis is a spontaneous separation of the nail plate, usually beginning at the free margin and progressing proximally. Rarely, the lateral borders may be involved, with spread

confined to these. Less often, separation may begin proximal to the free edge, in an oval area 2–6 mm broad, with a yellowish brown hue (“oil spot”). This is a lesion of psoriasis; distal onycholysis is also often caused by psoriasis. The nail itself is smooth and firm with no inflammatory reaction. Underneath the nail, a discoloration may occur from the accumulation of bacteria, most frequently *Pseudomonas*, or yeast, usually *Candida*. Color changes, such as green (a result of pyocyanin from *Pseudomonas*), black, or blue may be seen. One or more nails may be affected.

Onycholysis is noted most often in women, probably secondary to traumatically induced separation. It is common in patients with hand dermatitis. Keratinization of the distal nail bed, chronic exposure to irritants, untreated dermatitis, and secondary infection with *Candida albicans* are potential reasons for the failure of the nail to reattach itself.

The many systemic causes include hyper/hypothyroidism, pregnancy, porphyria, pellagra, and syphilis. Onycholysis has also been associated with atopic dermatitis, eczema, lichen planus, congenital abnormalities of the nails, trauma induced by clawing, pinching, stabbing (manicuring), and foreign body implantation. It may be caused by mycotic, pyogenic, or viral (herpes) infections. Women should be checked for vaginal candidiasis, because that anatomic location may be the source of the infection opportunistically invading and aggravating onycholysis. Chemical causes may include the use of solvents, nail polish base coat, nail hardeners containing formalin derivatives, artificial fingernails, and allergic or irritant contact dermatitis from their use. Rarely, photo-onycholysis may occur during or soon after therapy with tetracycline derivatives, psoralens, fluoroquinolones, or chloramphenicol and subsequent exposure to sunlight. Chemotherapeutic agents and systemic retinoids may induce onycholysis. On rare occasions, it may be a sign of subungual exostoses, squamous cell carcinoma, or metastasis. Autosomal dominant hereditary forms are also known.

Trauma and chemical irritants should be completely avoided and the nail bed kept completely dry. The affected portion of the nail should be kept clipped away. Drying by exposing the nail bed in this way will rid the area of *Pseudomonas* and assist greatly in eliminating *Candida*. The combination of drying and topical corticosteroids to minimize inflammation will often allow for reattachment of the nail and improvement or cure. Usually, this process takes 3–6 months or more.

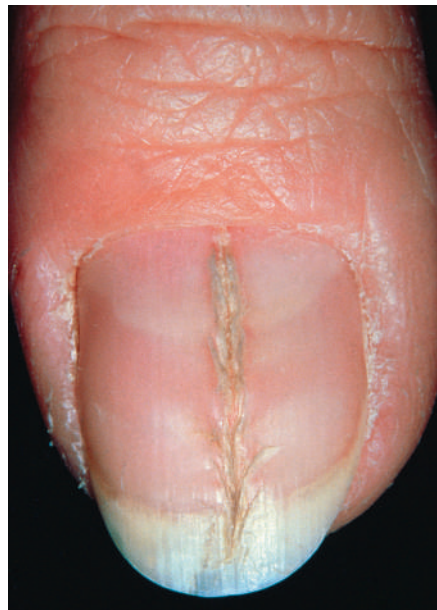**Chandran NS, et al:** Drug-induced photo-onycholysis. *Intern Med J* 2013; 43:1349.

**Daniel CR 3rd, et al:** Simple onycholysis. *Cutis* 2011; 87:226.

**Piraccini BM, et al:** Drug-induced nail diseases. *Dermatol Clin* 2006; 24:387.

### Median nail dystrophy (dystrophia unguis mediana canaliformis, solenonychia)

Median nail dystrophy consists of longitudinal splitting or canal formation in the midline of the nail. The split, which often resembles a fir tree, occurs at the cuticle and proceeds outward as the nail grows (Fig. 33-49). Trauma has been suspected of being the chief cause. Repeated typing with the nail tip on a personal digital assistant (PDA) has been reported to cause a median nail dystrophy. Some cases will resolve with avoidance of trauma or occlusive therapy with tacrolimus ointment; however, many will persist for years despite scrupulous care. The deformity may result from a papilloma or glomus tumor in the nail matrix, producing a structure resembling a tube (solenos) distal to it. Familial cases and an onset with isotretinoin or retonavir therapy are other associations.



**Fig. 33-49** Median nail dystrophy.

**Borges-Costa J, et al:** Median nail dystrophy associated with ritonavir. *Int J Dermatol* 2013; 52:1581.

**Kim BY, et al:** Treatment of median canaliform nail dystrophy with topical 0.1% tacrolimus ointment. *J Dermatol* 2010; 37:573.

**Olszewska M, et al:** The PDA nail. *Am J Clin Dermatol* 2009; 10:193.

### Pterygium unguis

Pterygium unguis forms as a result of scarring between the proximal nailfold and matrix. The classic causative example is lichen planus. It has been reported to result from sarcoidosis, parakeratosis of Mibelli, peripheral circulatory disturbances, and Hansen's disease. Onychomatricoma may infrequently simulate pterygium, but histologic examination will confirm the nature of this benign tumor.

**Kim DS, et al:** Pterygium unguis formation in parakeratosis of Mibelli. *Br J Dermatol* 2007; 156:1384.

**Perrin C, et al:** Onychomatricoma with dorsal pterygium. *J Am Acad Dermatol* 2008; 59:990.

### Pterygium inversum unguis

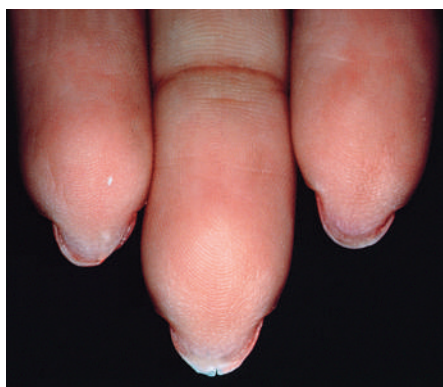Pterygium inversum unguis is characterized by adherence of the distal portion of the nail bed to the ventral surface of the nail plate (Fig. 33-50). The condition may be present at birth or acquired and may cause pain with manipulation of small objects, typing, and close manicuring of the nail. It results from the extension of the zone of the nail bed that normally contributes to the formation of the nail plate. This eventually leads to a more ventral and distal extension of the hyponychium. The most common forms of pterygium inversum unguis are the acquired secondary types caused by systemic connective tissue diseases, particularly progressive systemic sclerosis and SLE.

**Baek JH, et al:** A case of acquired idiopathic pterygium inversum unguis. *Ann Dermatol* 2014; 26:374.

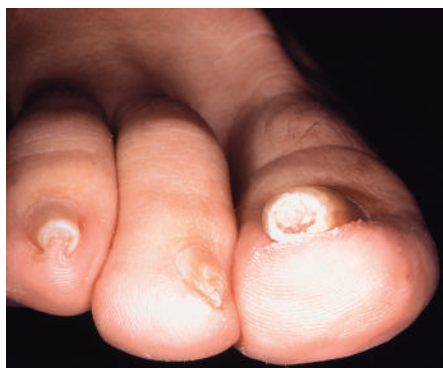**Balma A, et al:** Acquired idiopathic pterygium inversum unguis. *Clini Pediatr* 2010;49:394.

**Vadmal M, et al:** Pterygium inversum unguis associated with stroke. *J Am Acad Dermatol* 2005; 53:501.





**Fig. 33-50** Pterygium inversum unguis.



**Fig. 33-51** Pincer nails.

## Hangnail

Hangnail is an overextension of the eponychium (cuticle), which becomes split and peels away from the proximal or lateral nailfold. These lesions are painful and annoying; persistent cuticle biting frequently develops. Trimming these away with scissors is the best solution. The use of emollient creams to keep the cuticle soft is also recommended.

**Lee HJ, et al:** Minor cutaneous features of atopic dermatitis in South Korea. *Int J Dermatol* 2000; 39:337.

## Pincer nails

Pincer nails, trumpet nails, or omega (from the shape of the Greek letter) nails are alternative terms for a common toenail disorder in which the lateral edges of the nail slowly approach one another, compressing the nail bed and underlying dermis (Fig. 33-51). It may less often occur in the fingernails and, surprisingly, is usually asymptomatic. Infrequently, pain, recurrent or chronic infections, or even underlying osteomyelitis may complicate this condition. It may be an autosomal dominant inherited condition, may be acquired after trauma, or associated with Kawasaki's disease, renal disease, LE, or use of  $\beta$ -adrenergic blockers or pamidronate.

Some treatment success has been obtained using commercial plastic braces after flattening of the nail. Urea ointment under occlusion, various surgical approaches, and chemical matrixectomy with phenol and surgical nail bed repair have also been reported to be effective.

**Chi SG, et al:** Trichloroacetic acid matrixectomy and aluminum splint fixation for the treatment of pincer nails. *Dermatol Surg* 2010; 36:1493.

**Failla V, et al:** Pincer nails associated with pamidronate. *Clin Exp Dermatol* 2010; 36:305.

**Kosaka M, et al:** Pincer nails treated using zigzag nail bed flap method. *Dermatol Surg* 2010; 36:506.

**Okada K, et al:** Novel treatment using thioglycolic acid for pincer nails. *J Dermatol* 2012; 39:996.

**Pang HN, et al:** Pincer nails complicated by distal phalangeal osteomyelitis. *J Plast Reconstr Aesthet Surg* 2009; 62:254.

## Onychocryptosis (unguis incarnatus, ingrown nail)

Ingrown toenail is one of the most frequent nail complaints. It occurs chiefly on the great toes, where there is an excessive lateral nail growth into the nailfold, leading to this painful, inflammatory condition. The lateral margin of the nail acts as a foreign body and may cause exuberant granulation tissue. *Unguis incarnatus* may be caused by wearing improperly fitting shoes and by improper trimming of the nail at the lateral edges so that the anterior portion cuts into the flesh as it grows distally. Drugs such as isotretinoin, lamivudine, and indinavir may induce periungual granulation tissue, mimicking onychocryptosis.

In mild cases, soaking the foot in warm soapy water and insertion of a cotton pad, dental floss, or a flexible plastic tube beneath the distal corner of the offending nail may make surgery unnecessary. When surgical intervention is necessary, simple removal of the lateral portion of the nail plate can produce significant relief. Another simple procedure involves removal of the overhanging lateral nailfold so that the nail does not cut into it. When healed, the nail edge resembles that of the thumb, and an excellent functional result occurs. The nail is not altered, since it is not touched.

Partial or complete nail avulsion with ablation of the nail matrix will prevent recurrence. Ablation can be accomplished surgically, with phenol, 10% sodium hydroxide, or with a CO<sub>2</sub> laser. When phenol is used, the proximal nailfold should be incised and reflected to avoid burning it. As an alternative, the nailfold can be left in place and injected with a corticosteroid to reduce the subsequent inflammation. Liquid nitrogen spray to the area of tissue and nail involved for a freeze time of 20–30 s has been successful in some patients. This may be painful, however, and is reserved for patients who are not candidates for other surgical approaches.

## Retronychia

Retronychia is an unusual event associated with ingrowing of the nail plate into the proximal nailfold. This then induces a chronic paronychia. The cause in the few cases reported has been trauma, usually of the great toe. An incomplete shedding of the nail plate results in the new, growing nail pushing the old, partially detached nail plate up and backward into the proximal nailfold. Avulsion is curative.

**Baumgartner M, et al:** Retronychia. *Dermatol Surg* 2010; 36:1610.

**Dahdah MJ, et al:** Retronychia. *J Am Acad Dermatol* 2008; 58:1051.

**Haricharan RN, et al:** Nail-fold excision for the treatment of ingrown toenail in children. *J Pediatr* 2013; 162:398.

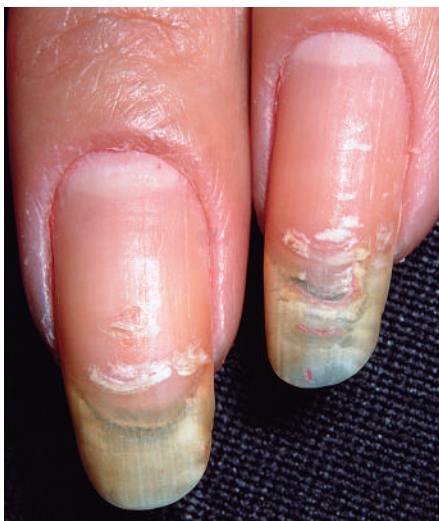**Park DH, et al:** The management of ingrowing toenails. *BMJ* 2012; 344:e2089.

**Perez CI, et al:** Operative technique with rapid recovery for ingrown nails with granulation tissue formation in childhood. *Dermatol Surg* 2013; 39:393.

**Piraccini BM, et al:** Retronychia in children, adolescents, and young adults. *J Am Acad Dermatol* 2014; 70:388.

**Richert B:** Surgical management of ingrown toenails. *Dermatol Ther* 2012; 25:498.

**Rounding C, et al:** Surgical treatments for ingrowing nails. *Cochrane Database Syst Rev* 2005; (2):CD001541.



**Fig. 33-52** Leukonychia punctata.

## NAIL DISCOLORATIONS

**Mendiratta V, et al:** Nail dyschromias. *Indian J Dermatol Venereol Leprol* 2011; 77:652.

**Ruben BS:** Pigmented lesions of the nail unit. *Semin Cutan Med Surg* 2010; 29:148.

## Leukonychia or white nails

Five forms of white nail are recognized: leukonychia punctata, leukonychia striata, longitudinal leukonychia, leukonychia partialis, and leukonychia totalis. The punctate variety is common in normal persons with otherwise normal nails (Fig. 33-52). Leukonychia striata, or transverse white parallel line, may be hereditary, of traumatic origin, or associated with systemic diseases such as HIV or Kawasaki's, or with drugs such as those used in chemotherapy. Longitudinal white lines are seen in Hailey-Hailey disease and with onychopapillomas. Partial leukonychia may occur with tuberculosis, nephritis, complex regional pain syndrome, Hodgkin disease, chilblains, metastatic carcinoma, or Hansen's disease, or it may be idiopathic.

Leukonychia totalis may be hereditary, of a simple autosomal dominant type. Mutations in the *PLCD1* gene are responsible. It may also be associated with electron beam therapy, typhoid fever, Hansen's disease, cirrhosis, ulcerative colitis, HIV, nail biting, use of emetine or vorinostat, complex regional pain syndrome, cytostatic agents, and trichinosis. Leukonychia may result from abnormal keratinization, with persistence of keratohyalin granules in the nail plate. A syndrome comprising leukonychia totalis, multiple sebaceous cysts, and renal calculi in several generations has been reported. Other reports have linked total leukonychia with deafness or with koilonychia; however, it is most often inherited as an isolated finding.

**Criscione V, et al:** Onychopapilloma presenting as longitudinal leukonychia. *J Am Acad Dermatol* 2010 Sep; 63(3):541-542.

**Eros N, et al:** Transient leukonychia after total skin electron beam irradiation. *JEADV* 2011; 25:110-122.

**Kiuru M, et al:** Hereditary leukonychia, or porcelain nails, resulting from mutations in *PLCD1*. *Am J Hum Genet* 2011; 88:839.

**Mir H, et al:** Mutations in the gene phospholipase C, delta-1 (*PLCD1*) underlying hereditary leukonychia. *Eur J Dermatol* 2012 Nov-Dec; 22(6):736-739.

## Longitudinal erythronychia

Longitudinal red bands in the nail plate that commence in the matrix and extend to the point of separation of the nail plate and nail bed may occur on multiple nails with inflammatory conditions, such as lichen planus, graft-vs-host disease, amyloidosis, acrokeratosis verruciformis of Hopf, or Darier's disease, or as an isolated finding. When only a localized single or bifid streak is present on a single digit, this may signal a benign or malignant tumor of the matrix. The fingernails of middle-age persons are most often affected, with the thumbnail usually involved. There may be a benign lesion such as a glomangioma, a distal keratosis, as with Darier's disease, human papillomavirus (HPV) infection, or an onychopapilloma; however, malignancies such as squamous cell carcinoma or amelanotic melanoma may be present. Excision of this distal keratosis, however, usually does not result in cure or diagnostic findings; biopsy of the affected matrix is necessary. When the presentation is polydactylous, biopsy is rarely done. In solitary monodactylous, single or bifid bands in men over 50 a biopsy should be seriously considered. If observation is the decision, as in longitudinal melanonychia, if the band broadens over time, excisional biopsy is indicated, because this may be secondary to an amelanotic melanoma or squamous cell carcinoma. In patients with painful lesions excision will result in cure and diagnosis.

**Cohen PR:** Longitudinal erythronychia. *Am J Clin Dermatol* 2011; 12:217.

**Jellinek NJ:** Longitudinal erythronychia. *J Am Acad Dermatol* 2011; 64:167.e1.

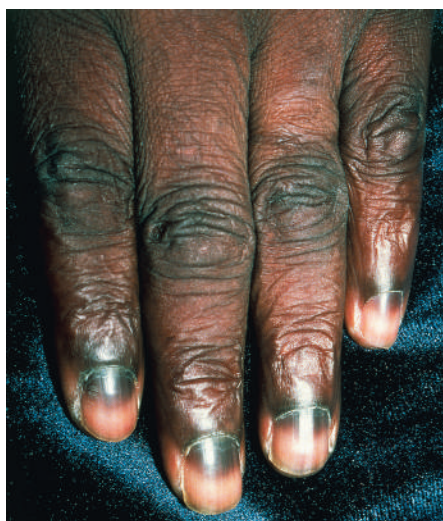**Perrin C:** Tumors of the nail unit. *Am J Dermatopathol* 2013; 35:621.

## Melanonychia

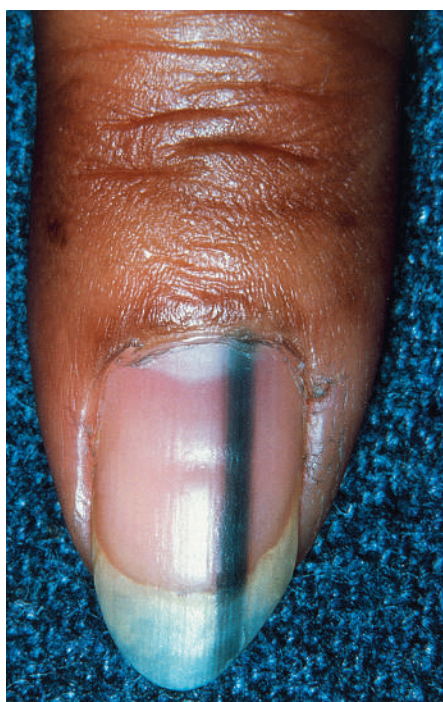Black or brown pigmentation of the normal nail plate is termed melanonychia. The entire nail may be involved or multiple longitudinal or transverse bands on several nails may occur. In such cases the following conditions may be responsible; it is when there is a solitary acquired longitudinal band that concern for malignancy is paramount. The nail pigment may be present as a normal finding on many digits in black patients. Longitudinal black or brown banding of the nails has been reported to occur in 77-96% of black persons and 11% of Asians. Other causes include trauma, systemic disease, or medication; or as a postinflammatory event from such localized events as lichen planus or fixed drug reaction. Pigmentation of the nails may occur with acanthosis nigricans, Addison's disease, Peutz-Jeghers syndrome, or vitamin B<sub>12</sub> deficiency; after adrenalectomy for Cushing syndrome; as a part of Laugier-Hunziker syndrome (pigmentation of nails associated with buccal and lip hyperpigmentation); with PUVA or ionizing radiation treatment; and as drug-induced melanocyte activation with such medications as chemotherapy, antimalarials, minocycline, antivirals (zidovudine [Fig. 33-53] or lamivudine), or metals (gold, arsenic, thallium, mercury). Drugs may induce both transverse and longitudinal bands, with multidrug chemotherapy causing most transverse bands. Friction may cause longitudinal pigmented bands in the toenails, and subungual hemorrhage or black nail caused by *Proteus mirabilis* or a variety of fungi may enter into the differential diagnosis of a dark nail.

When only one nail is affected by melanonychia striata—a single, longitudinal, brown or black band (Fig. 33-54)—a tumor of the nail matrix is the most important consideration. The location in the matrix can be inferred from the location of the pigment in the nail plate when viewed end-on. Dorsal nail plate pigmentation results from a proximal matrix lesion. Ventral nail-plate pigmentation is the result of a lesion in the distal matrix.





**Fig. 33-53** Zidovudine-induced hyperpigmentation of the nail.



**Fig. 33-54** Longitudinal melanonychia.

Tosti et al. studied 100 white adult patients with a single band of longitudinal melanonychia of unknown cause. Biopsies revealed melanocytic hyperplasia in 65, nevi in 22, melanocytic activation in 8, and melanoma in 5. Whereas the authors were unable to ascertain any clear clinical criteria that would exclude melanoma, they recommended a biopsy in any adult with the appearance of a longitudinal band of pigment in only one nail without a clear relation to a definite cause. Other reasons to biopsy include a band that has a triangular shape (wider at proximal than distal part), a blurred lateral border of the band, a lack of homogeneity of the pigmentations (bands or lines of different color), a band over 6 mm in width, or pigmentation of the periungual skin (Hutchinson's sign). The latter is not pathognomonic, however, because Bowen's disease may produce this appearance, and pigmentation of the nail matrix and proximal nail bed may reflect through the nailfold (pseudo-Hutchinson's sign). Finally, dermoscopic features that suggest melanoma are a brown coloration of the background and the presence of irregular coloration, spacing,

or thickness of longitudinal lines or disruption of their parallelism. Retracting the proximal nailfold to expose the origin of the streak at the matrix allows selection of the best biopsy site. The recommended biopsy includes the whole lesion; this may be accomplished by the tangential matrix excision, which may leave minimal scarring in some patients, or more certainly, this is accomplished by longitudinal excision.

Recommendations for prepubertal children, however, are different. Longitudinal melanonychia that appears in children is usually benign in nature, and it is recommended that since an ungual melanocytic band can appear at an age when other nevi appear, the majority can be followed. If the lesion is alarming in its appearance, however, especially if widening or darkening, sampling the whole lesion by tangential matrix or longitudinal excision is necessary.

**Chu DH, et al:** Diagnosis and management of nail disorders in children. *Pediatr Clin North Am* 2014; 61:293.

**Collins SC, et al:** Midline/paramedian longitudinal matrix excision with flap reconstruction. *J Am Acad Dermatol* 2010; 62:627.

**Finch J, et al:** Fungal melanonychia. *J Am Acad Dermatol* 2012; 66:830.

**Inokuma D, et al:** Bowen's disease of the nail matrix presenting as melanonychia. *Acta Derm Venereol* 2009; 89: 638.

**Kluger N, et al:** Toenails melanonychia induced by hydroxyurea. *La Presse Medicale* 2012; 41:444.

**Mannava KA, et al:** Longitudinal melanonychia. *Hand Surg* 2013; 18:133.

**Mendiratta V, et al:** Nail dyschromias. *Indian J Dermatol Venereol Leprol* 2011; 77:652.

**Perrin C:** Tumors of the nail unit. *Am J Dermatopathol* 2013; 35:621.

**Richert B, et al:** Tangential excision of pigmented nail matrix lesions responsible for longitudinal melanonychia. *J Am Acad Dermatol* 2013; 69:96.

**Saito T, et al:** Subungual Bowen disease revealed by longitudinal melanonychia. *J Am Acad Dermatol* 2012; 67:e240.

**Santos MdA, et al:** Melanonychia striata. *N Engl J Med* 2011; 364:11.

**Tosti A, et al:** Dealing with melanonychia. *Semin Cutan Med Surg* 2009; 28:49.

## Green nails

When onycholysis is present, a green discoloration may occur in the onycholytic area as a result of an infection with *Pseudomonas aeruginosa* (see Chapter 14). The color change may also occur as transverse green stripes. The stripes are ascribed to intermittent episodes of infection. Green nails may also result from copper in tap water.

**Hengge UR, et al:** Green nails. *N Engl J Med* 2009; 360:1125.

## Staining of nail plate

Nicotine, dyes (including hair dyes and nail polish), potassium permanganate, mercury compounds, hydroquinone, elemental iron, mepacrine, photographic developer, anthralin, chrysarobin, glutaraldehyde, or resorcin may cause nail plate staining. This is only a partial list; Mendiratta and Jain provide a complete listing. A helpful diagnostic maneuver to distinguish nail plate staining from exogenous sources and nail plate pigmentation from melanin or endogenous chemicals is to scrape the surface of the nail plate several times firmly with a glass slide or scalpel blade. Exogenous stains frequently scrape off completely if the agent has not penetrated the entire nail plate. If the stain follows the curvature of the lunulae, it is probably endogenous; if it follows the curvature of the proximal and lateral nailfolds, it is exogenous.

**Mendiratta V, et al:** Nail dyschromias. *Indian J Dermatol Venereol Leprol* 2011; 77:652.

## Red lunulae

Dusky erythema confined to the lunulae has been reported in association with alopecia areata. About 20% of patients with SLE have been reported to have this abnormality. Red lunulae may also be seen in patients taking oral prednisone for severe rheumatoid arthritis or dermatomyositis, as well as in cardiac failure, cirrhosis, lymphogranuloma venereum, psoriasis, vitiligo, chronic urticaria, lichen sclerosus et atrophicus, CO<sub>2</sub> poisoning, chronic obstructive pulmonary disease, twenty-nail dystrophy, and reticulosarcoma. The cause may be vascular congestion.

**Cohen PR:** Red lunulae: case report and literature review. *J Am Acad Dermatol* 1992; 26:292.

**Tunc SE, et al:** Nail changes in connective tissue diseases. *J Eur Acad Dermatol Venereol* 2007; 21:497.

## Spotted lunulae

This distinctive change occurs with alopecia areata.

**Cohen PR:** The lunula. *J Am Acad Dermatol* 1996; 34:943.

## Purpura of nail beds

Purpura beneath the nails usually results from trauma. Causes of toe involvement include physical pressure on the toes, such as that seen in surfing caused by a windsurfer trying to maintain balance, or exogenous pressure exerted from poorly fitting shoes. Nail bed purpura may simulate a melanoma if the patient does not communicate the acuteness at onset.

**Pierson JC, et al:** Pen push purpura. *Cutis* 1993; 51:422.

## Blue nails

A blue discoloration of the lunulae is seen in argyria and cases of hepatolenticular degeneration (Wilson's disease). The blue color in the latter is probably related to the changes in copper metabolism by the patient. It has also been reported in hemoglobin M disease and hereditary acrolabial telangiectases. Lunular blue color, as well as blue discoloration of the whole nail bed, occurs with some therapeutic agents, especially 5-FU, minocycline, imipramine, mepacrine and other antimalarials, hydroxyurea, phenolphthalein, and azidothymidine. Blue discoloration may also result from subungual hematoma, blue nevi, and melanotic whitlow. Blue nails are a normal variant finding in black people.

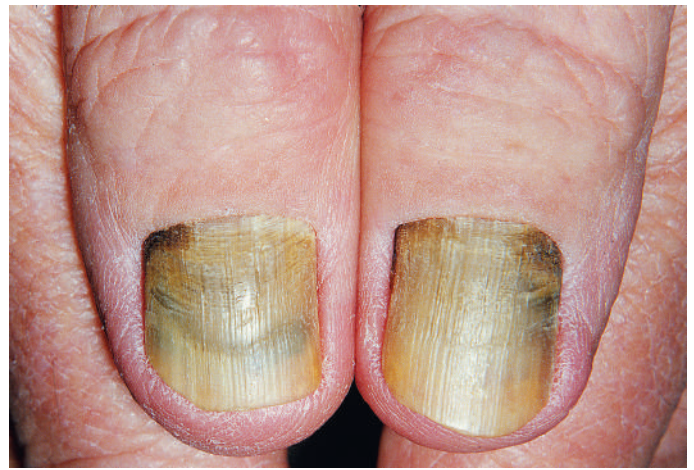**Dalle S, et al:** A blue-gray subungual discoloration. *Arch Dermatol* 2007; 143:937.

**Kalouche H, et al:** Blue lunulae. *Australas J Dermatol* 2007; 48:182.

**Kim Y, et al:** A case of generalized argyria after ingestion of colloidal silver solution. *Am J Ind Med* 2009; 52:246.

## Yellow nail syndrome

The yellow nail syndrome is characterized by marked thickening and yellow to yellowish green discoloration of the nails often associated with systemic disease, most often lymphedema and compromised respiration. The nails are typically overcurved both transversely and longitudinally, grow very slowly (<0.2 mm/week), are often subject to onycholysis, and lose both lunulae and cuticles (Fig. 33-55). Lymphedema, pleural effusions, chronic pulmonary infections, and chronic sinusitis most frequently precede the nail changes. Other less frequently associated conditions include autoimmune dis-



**Fig. 33-55** Yellow nail syndrome.

orders, immunodeficiency states, use of gold or D-penicillamine, and malignancies. In the latter cases, treatment of the underlying lymphoma or solid tissue tumor has resulted in improvement of the nail findings. Individual clinical responses have been seen with oral zinc or 800 IU/day of D- $\alpha$ -tocopherol alone or in combination with itraconazole. Although 30–50% of patients experience spontaneous improvement in the condition of their nails, fluconazole taken in combination with vitamin E cured or improved all 13 patients treated by Baran et al.

**Al Hawsawi K, et al:** Yellow nail syndrome. *Pediatr Dermatol*. 2010; 27:675.

**Baran R, et al:** Combination of fluconazole and alpha-tocopherol in the treatment of yellow nail syndrome. *J Drugs Dermatol* 2009; 8:276.

**Piraccini BM, et al:** Yellow nail syndrome: clinical experience in a series of 21 patients. *J Dtsch Dermatol Ges*. 2014; 12:131.

**Polat AK, et al:** Yellow nail syndrome: treatment of lymphedema using low pressure compression. *Lymphat Res Biol*. 2012; 10:30.

**Zaiac MN, et al:** Nail abnormalities associated with systemic pathologies. *Clin Dermatol*. 2013; 31:627.

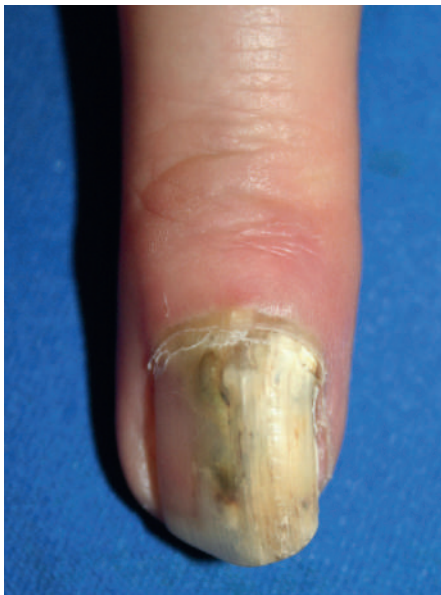## NEOPLASMS OF THE NAIL BED

Various benign and malignant neoplasms may occur in or overlying the nail matrix and in the nail bed. Signs heralding such neoplasms are paronychia, ingrown nail, onycholysis, pyogenic granuloma, nail plate dystrophy, longitudinal erythronychia, bleeding, and discolorations. Symptoms of pain, itching, and throbbing may also occur with various neoplasms.

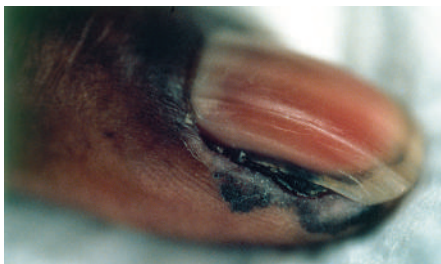
Benign tumors of the nails include verruca, pyogenic granuloma, fibromas, nevus cell nevi, myxoid cysts, angiofibromas (Koenen tumors), onychopapillomas, and epidermoid cysts. Pyogenic granuloma-like lesions may occur during treatment with isotretinoin, lamivudine, indinavir, or the epidermal growth factor receptor inhibitor family of drugs. Glomangioma is readily recognized by exquisite tenderness in the nail bed. Enchondroma of the distal phalanx often presents as a paronychia. Subungual exostoses may also present as an inflammatory process, but more often resemble a verruca at the start. Most of these are on the great toe, and radiographic evaluation will aid in the diagnosis of these last two entities. Onychopapillomas are benign tumors of the nail bed that usually present as longitudinal erythronychia. Tender swelling of the distal finger with nail distortion and radiographic evidence of solitary lytic changes can be caused by intraosseous epidermoid cysts.

Onychomatricoma is a benign tumor of the nail matrix. It presents as a yellow, thickened plate growing out from under





**Fig. 33-56**  
Onychomatricoma.  
(Courtesy of Dr. Adam  
Rubin.)



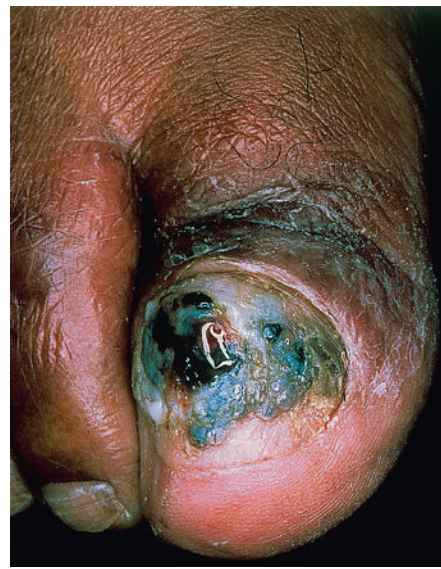**Fig. 33-57** Bowen's  
disease.

the proximal nailfold and then extending distally in a longitudinal band (Fig. 33-56). There is an increased transverse curvature of the nail, and splinter hemorrhages often are seen in the proximal nail. Infrequently, it can appear as a cutaneous horn emanating from the proximal nailfold, with dorsal pterygium formation. Biopsy at the matrix origin will permit diagnosis.

Bowen's disease and squamous cell carcinoma of the nail bed are uncommon. Radiographs may reveal lytic changes in the distal phalanx. Metastases are rare. Mohs surgery is the treatment of choice. When these lesions occur on more than one digit, they are proved to be secondary to HPV infection. Bowen's disease may be pigmental (Fig. 33-57). When keratoacanthoma occurs, there is often lysis of underlying bone, which fills in after excision of the tumor. Basal cell carcinoma may occur but is uncommon in this location.

Subungual melanoma is frequently diagnosed late in the course of growth (Fig. 33-58), since it simulates onychomycosis or subungual hematoma, with which it is confused. Amelanotic melanoma may occur and may be mistaken for granuloma pyogenicum. Although melanoma is rare among Japanese, periungual and subungual melanoma is more frequently found in Japanese than in other ethnic populations. Melanoma in this location is discussed in Chapter 30 and in the melanonychia section of this chapter.

Onycholemmal carcinoma is a slowly growing, malignant tumor of the nail bed epithelium. It is composed of small cysts filled with eosinophilic amorphous keratin. The cyst wall is lined with atypical keratinocytes. No granular layer is seen.



**Fig. 33-58** Subungual  
melanoma.

Also, solid nests and strands of atypical keratinocytes fill the dermis and may invade the bone. Mohs excision or even disarticulation of the digit may be necessary.

Evaluation of these masses may be carried out by plain x-ray films, looking for bone lysis or other changes. MRI by both T1-weighted spin-echo images and turbo spin-echo T2-weighted images may offer excellent diagnostic information about these tumors as well. Histologic examination remains the diagnostic gold standard.

**Chanprapaph K, et al:** Epidermal growth factor receptor inhibitors. *Dermatol Res Pract* 2014; 2014:734249.

**Chaser BE, et al:** Onycholemmal carcinoma. *J Am Acad Dermatol* 2013; 68:290.

**Choi JH, et al:** Subungual keratoacanthoma. *Skeletal Radiol* 2007; 36:769.

**Cloetingh D, et al:** JAAD grand rounds quiz. Onychomatricoma. *J Am Acad Dermatol* 2014; 70:395.

**Cohen PR:** Longitudinal erythronychia. *Am J Clin Dermatol* 2011; 12:231.

**DaCamra MP, et al:** Subungual exostosis of the toes: *Clin Orthop Relat Res* 2014; 472:1251.

**Koc O, et al:** Subungual glomus tumour. *Australas Radiol* 2007; 51 Spec No:B107.

**Lecerf P, et al:** A retrospective study of squamous cell carcinoma of the nail unit diagnosed in a Belgian general hospital over a 15-year period. *J Am Acad Dermatol* 2013; 69:253.

**Martin DE, et al:** Subungual malignant melanoma. *J Hand Surg Am* 2011; 36:704.

**Miteva M, et al:** Onychopapilloma presenting as longitudinal melanonychia. *J Am Acad Dermatol* 2012; 66:e242.

**Perrin C:** Tumors of the nail unit. Part I. *Am J Dermatopathol* 2013; 35:621.

**Perrin C:** Tumors of the nail unit. Part II. *Am J Dermatopathol* 2013; 35:693.

**Saito T, et al:** Subungual Bowen disease revealed by longitudinal melanonychia. *J Am Acad Dermatol* 2012; 67:e240.

**Samlaska CP, et al:** Intraosseous epidermoid cysts. *J Am Acad Dermatol* 1992; 27:454.

**Song M, et al:** Surgical treatment of subungual glomus tumor. *Dermatol Surg* 2009; 35:786.

**Turowski CB, et al:** Human papillomavirus-associated squamous cell carcinoma of the nail bed in African-American patients. *Int J Dermatol* 2009; 48:117.



Bonus images for this chapter can be found online at [expertconsult.inkling.com](http://expertconsult.inkling.com)

**eFig. 33-1** Alopecia areata.

**eFig. 33-2** Ophiasis. (Courtesy of Dr. Shyam Verma.)

**eFig. 33-3** Loose anagen syndrome.

**eFig. 33-4** Male-pattern hair loss.

**eFig. 33-5** Trichobezoar being extracted from the stomach of a patient with compulsive trichophagia. (Courtesy of Wilford Hall Air Force Medical Center Teaching File.)

**eFig. 33-6** Lichen planopilaris.

**eFig. 33-7** Dissecting cellulitis.

**eFig. 33-8** Menkes steely (kinky) hair syndrome.

**eFig. 33-9** Trichostasis spinulosa. (Courtesy of Dr. Richard Vinson.)

**eFig. 33-10** Sacral hair tuft. (Courtesy of Brooke Army Medical Center Teaching File.)

**eFig. 33-11** Hirsutism.

**eFig. 33-12** Trichomycosis axillaris. (Courtesy of Dr. Anthony Slagel.)

**eFig. 33-13** Tinea amiantacea.

**eFig. 33-14** Acquired perforating disease in uremia. (Courtesy of Dr. Curt Samlaska.)

**eFig. 33-15** Disseminated infundibulofolliculitis.

**eFig. 33-16** Axillary hyperhidrosis.

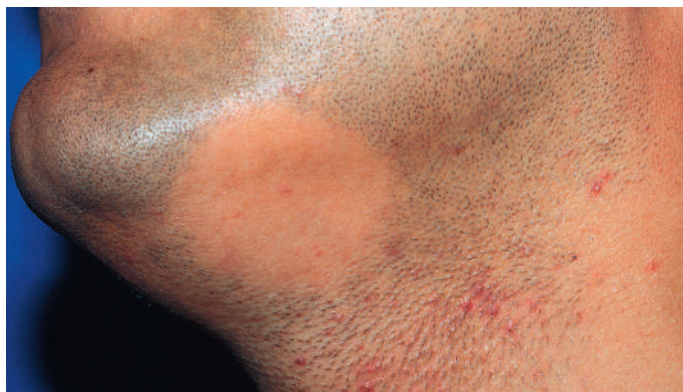**eFig. 33-17** Fox-Fordyce disease.

**eFig. 33-18** Pitting caused by psoriasis.

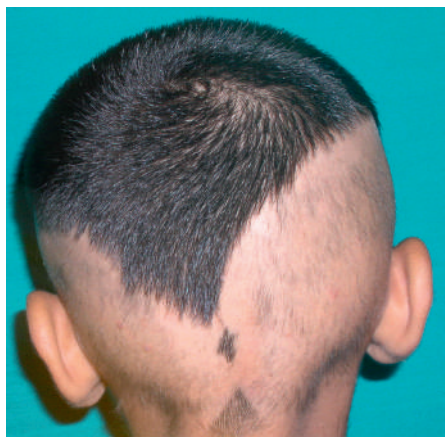**eFig. 33-19** Congenital onychodystrophy of the index finger. (Courtesy of Dr. James Fitzpatrick.)

**eFig. 33-20** Onychophagia.

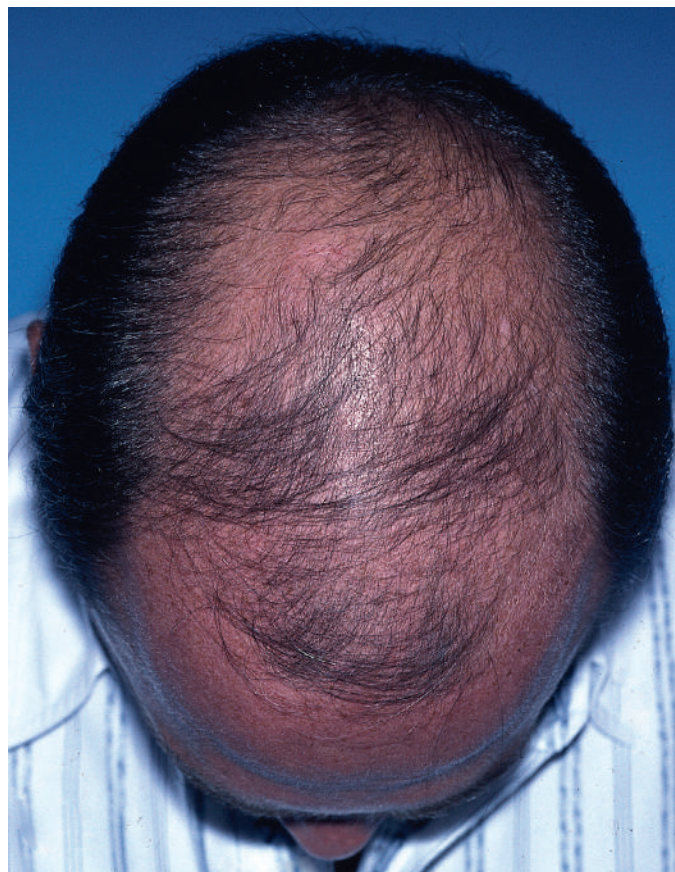




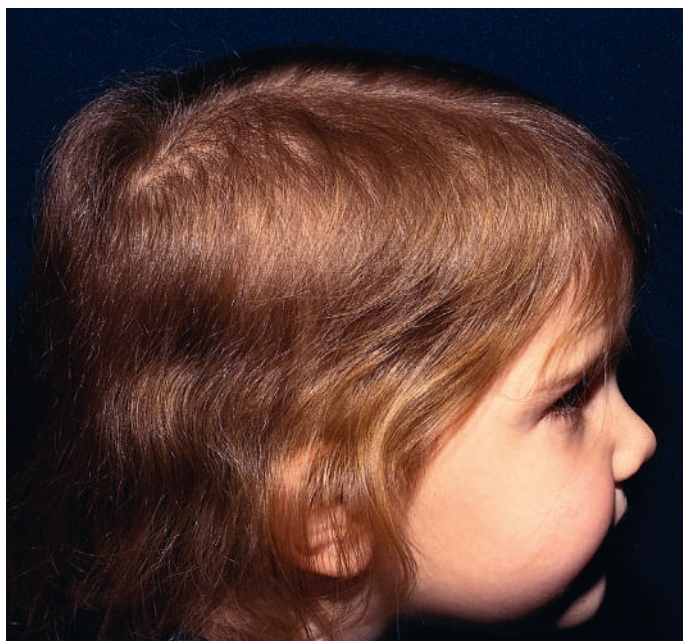**eFig. 33-1** Alopecia areata.



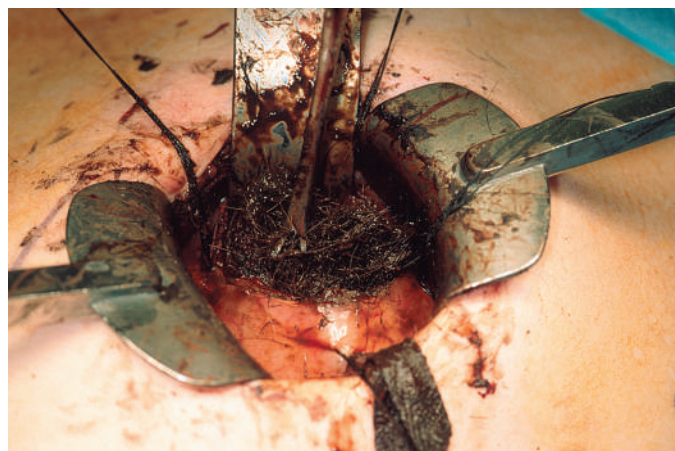**eFig. 33-2** Ophiasis.  
(Courtesy of Dr. Shyam Verma.)



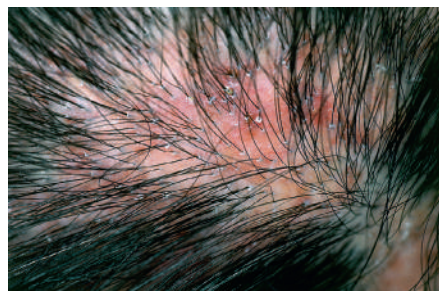
**eFig. 33-4** Male-pattern hair loss.



**eFig. 33-3** Loose anagen syndrome.

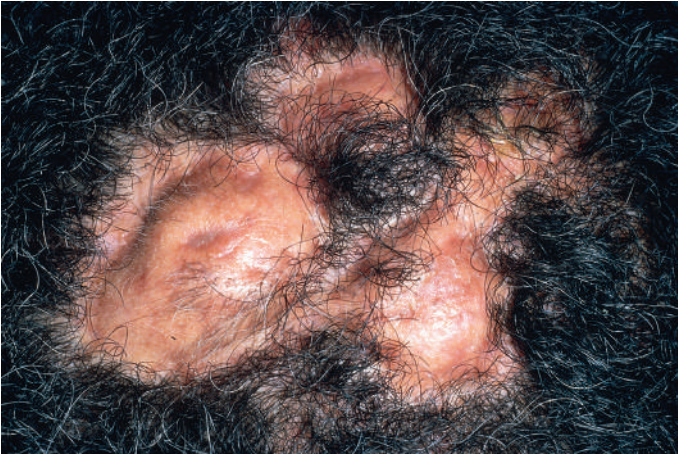

**eFig. 33-5** Trichobezoar being extracted from the stomach of a patient with compulsive trichophagia. (Courtesy of Wilford Hall Air Force Medical Center Teaching File.)

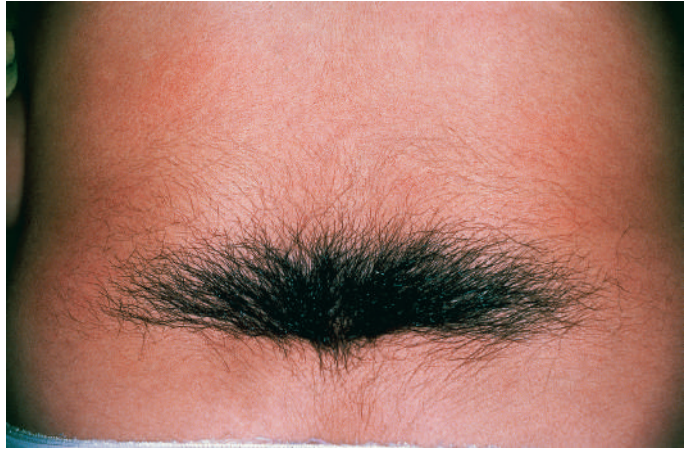

**eFig. 33-6** Lichen planopilaris.

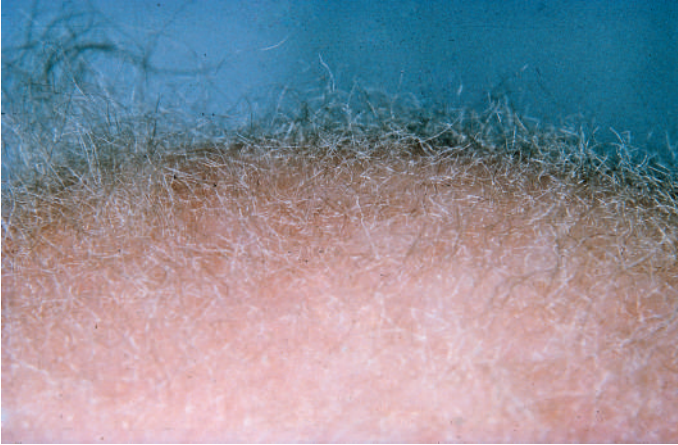



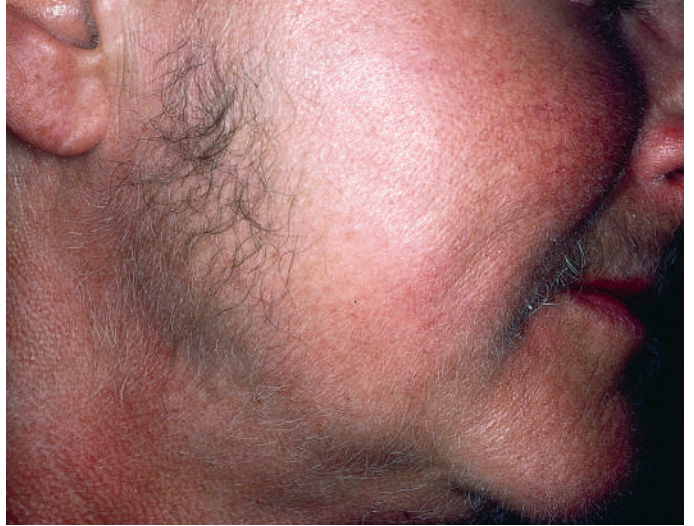**eFig. 33-7** Dissecting cellulitis.




**eFig. 33-10** Sacral hair tuft. (Courtesy of Brooke Army Medical Center Teaching File.)



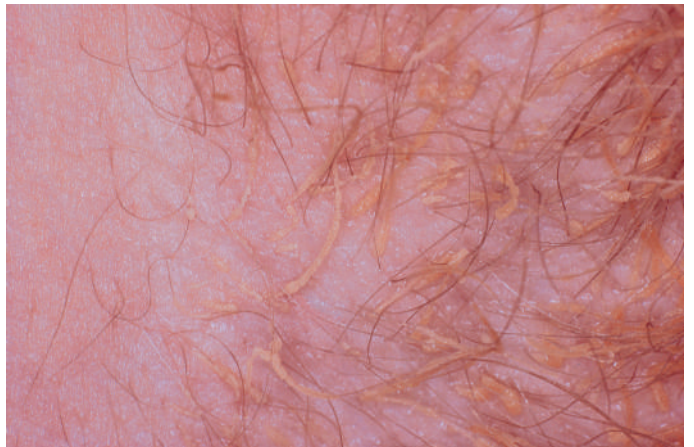**eFig. 33-8** Menkes steely (kinky) hair syndrome.



**eFig. 33-11** Hirsutism.

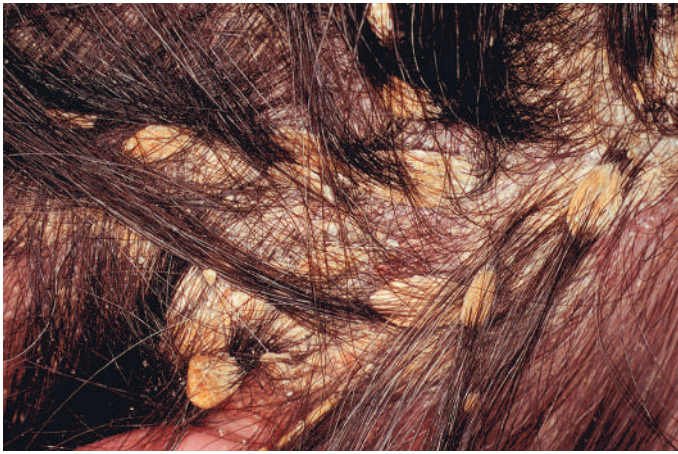

**eFig. 33-9** Trichostasis spinulosa. (Courtesy of Dr. Richard Vinson.)

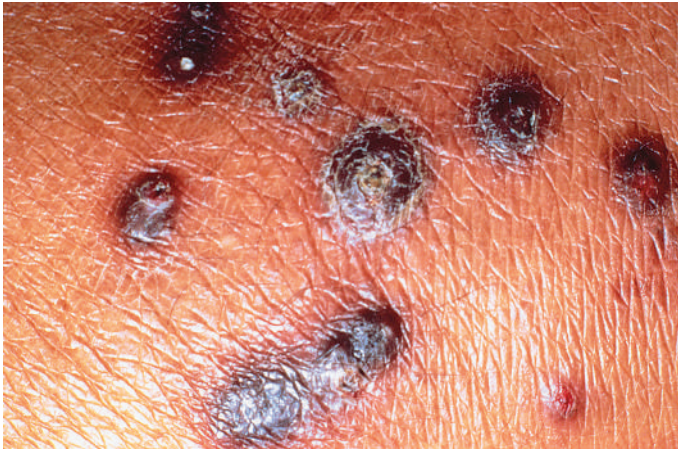


**eFig. 33-12** Trichomycosis axillaris. (Courtesy of Dr. Anthony Slagel.)

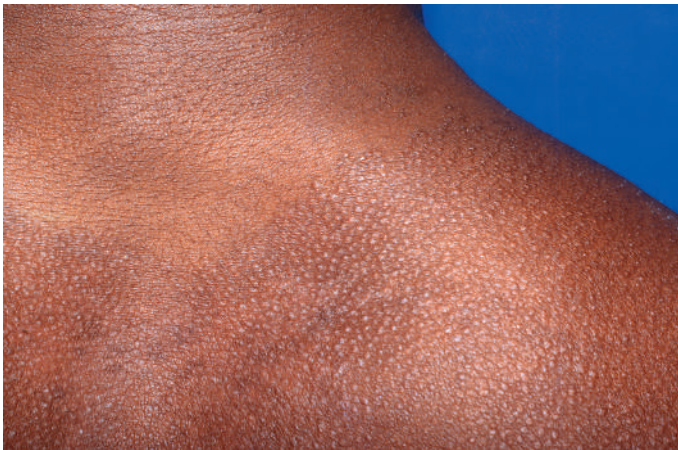



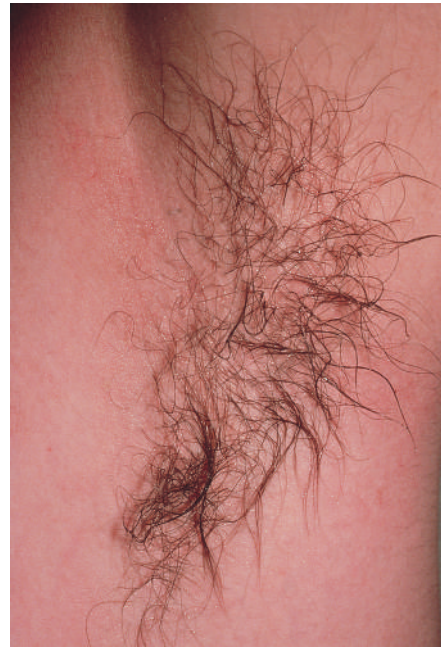**eFig. 33-13** Tinea amiantacea.



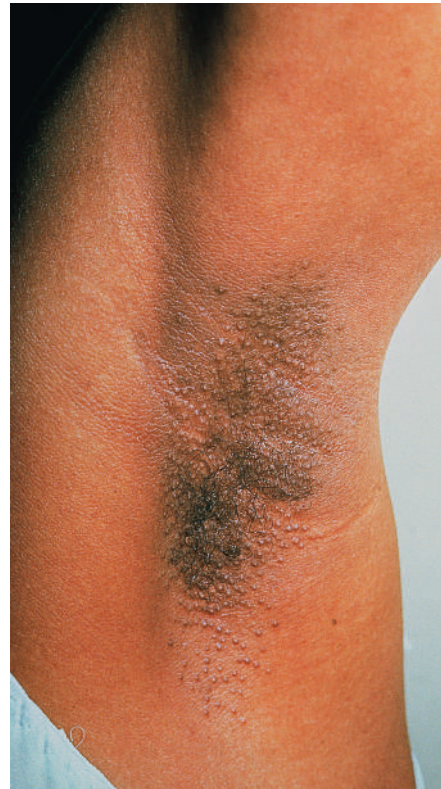**eFig. 33-14** Acquired perforating disease in uremia. (Courtesy of Dr. Curt Samlaska.)



**eFig. 33-15** Disseminated infundibulofolliculitis.

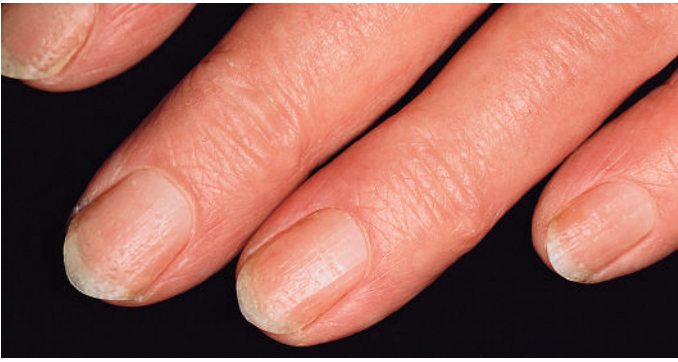

**eFig. 33-16** Axillary hyperhidrosis.

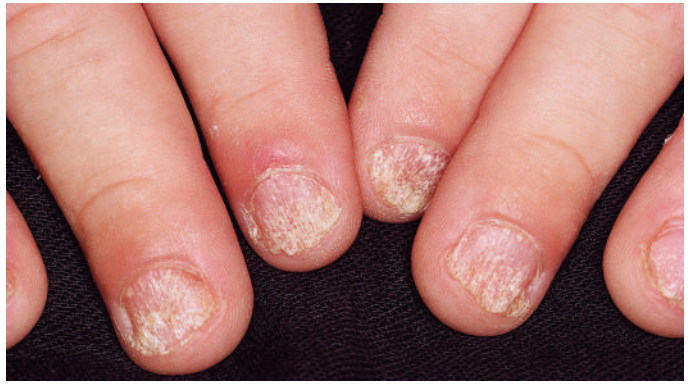

**eFig. 33-17** Fox-Fordyce disease.

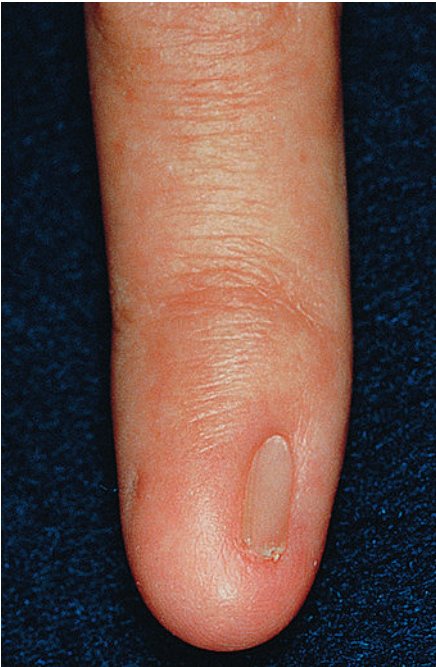



**eFig. 33-18** Pitting caused by psoriasis.



**eFig. 33-20** Onychophagia.



**eFig. 33-19** Congenital onychodystrophy of the index finger. (Courtesy of Dr. James Fitzpatrick.)



## Disorders of the Mucous Membranes

Lesions on the mucous membranes may be more difficult to diagnose than lesions on the skin, and not merely because they are less easily and less often seen. There is less contrast of color and greater likelihood of alterations in the original appearance because of secondary factors, such as maceration from moisture, abrasion from food and teeth, and infection. Vesicles and bullae rapidly rupture to form grayish erosions, and the epithelium covering papules becomes a soggy, lactescent membrane, easily rubbed off to form an erosion. Grouping and distribution are less distinctive in the mouth than on the skin, and in some cases, it is necessary to establish the diagnosis by observing the character of any associated cutaneous lesions or by noting subsequent developments.

**Pramod JR:** Textbook of Oral Medicine, 3rd ed. New Delhi: Jaypee Brothers Medical Publishers, 2014.

**Scully C:** Oral and Maxillofacial Medicine, 3rd ed. New York: Churchill Livingstone, 2013.

**Sollecito TP, Stoppler ET (eds):** Clinical approaches to oral mucosal disorders. Dent Clin North Am 2013; 57(4):561–711.

### CHEILITIS

#### Cheilitis exfoliativa

The term cheilitis exfoliativa has been used to designate a primarily desquamative, mildly inflammatory condition of the lips, of unknown cause, and also a clinically similar reaction secondary to other disease states. The former is a persistently recurring lesion that produces scaling and sometimes crusting; it most often affects the upper lip. The recurrent exfoliation leaves a temporarily erythematous and tender surface.

In the latter form, the lips are chronically inflamed and covered with crusts that from time to time tend to desquamate, leaving a glazed surface on which new crusts form. Fissures may be present, and there may be burning, tenderness, and some pain. The lower lip is more often involved, with the inflammation limited to the vermilion part. The cheilitis may be secondary to seborrheic dermatitis, atopic dermatitis (AD), psoriasis, retinoid therapy, pyorrhea, long-term actinic exposure, or the habit of lip licking (Fig. 34-1). Infrequently, the initial or only manifestation of AD may be a chronic cheilitis. Irritating or allergenic substances in lipsticks, dentifrices, and mouthwashes may be causative factors. Dyes in lipsticks may photosensitize. Candidiasis may be present. Cheilitis may be part of Plummer-Vinson or Sjögren syndrome. Cheilitis is seen in patients with acquired immunodeficiency syndrome (AIDS), and it is a known common complication of protease inhibitor therapy. These and other, uncommon causes of cheilitis are discussed in more detail within the specific entities.

The only uniformly effective treatment of cheilitis exfoliativa is the elimination of causes when they can be found. Topical tacrolimus ointment, pimecrolimus cream, or low-strength corticosteroid ointments and creams are usually helpful. If the underlying etiology is determined, specific therapy may be

instituted. When there are fissures, petrolatum or zinc oxide ointment may be useful.

**Almazrooa SA, et al:** Characterization and management of exfoliative cheilitis. Oral Surg Oral Med Oral Pathol Oral Radiol Endod 2013; 116(6):e485–e489.

**Mani SA, et al:** Exfoliative cheilitis. J Can Dent Assoc 2007; 73:629.

#### Allergic contact cheilitis

The vermilion border of the lips is much more likely to develop allergic contact sensitivity reactions than is the oral mucosa. Allergic cheilitis is characterized by dryness, fissuring, edema, crusting, and angular cheilitis. Over 90% of patients are women and over half of the reactions are caused by lipsticks. While patch testing with standard allergens will reveal a relevant positive in approximately 25–30% of patients, about 1 in 5 will only react to their own product. It may result from use of topical medications, dentifrices and other dental preparations, antichap agents, lipsticks, and sunscreen-containing lip balms; from contact with cosmetics, nail polish, rubber, and metals; or from eating foods such as mangoes. Fragrance and nickel are the most commonly identified individual sensitizers.

Treatment includes discontinuation of exposure to the offending agent and administration of topical tacrolimus, pimecrolimus, or corticosteroid preparations.

**Alrowaishdi F, et al:** Allergic contact cheilitis caused by carnauba wax in a lip balm. Contact Dermatitis 2013; 69:311–322.

**Bakula A, et al:** Contact allergy in the mouth. Acta Clin Croat 2011; 50(4):553–561.

**Budimir V, et al:** Allergic contact cheilitis and perioral dermatitis caused by propolis. Acta Dermatovenerol Croat 2012; 20(3):187–190.

**Collet E, et al:** Cheilitis, perioral dermatitis and contact allergy. Eur J Dermatol 2013; 23(3):303–307.

**Sarre ME, et al:** Allergic contact cheilitis caused by polysilicone-15 (Parsol SLX) in a lip care balm. Contact Dermatitis 2014; 70(2):119–121.

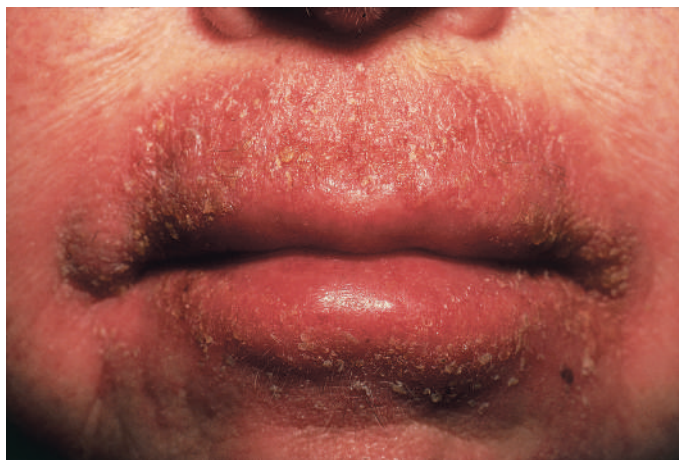**Schena D, et al:** Contact allergy in chronic eczematous lip dermatitis. Eur J Dermatol 2008; 18:688.

**Tan S, et al:** Allergic contact dermatitis to *Myroxylon pereirae* (balsam of Peru) in papaw ointment causing cheilitis. Australas J Dermatol 2011; 52(3):222–223.

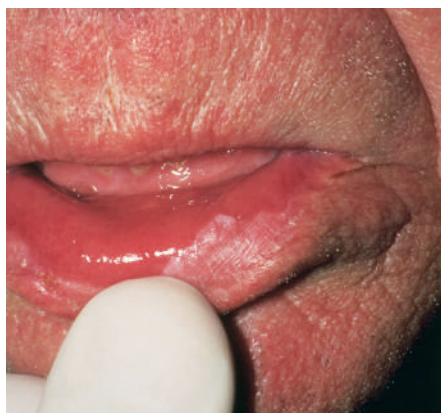**Zug KA, et al:** Patch-testing North American lip dermatitis patients. Dermatitis 2008; 19:202.

#### Actinic cheilitis

Actinic cheilitis is an inflammatory reaction of the lips to chronic excessive sunlight exposure over many years. The lower lip, which is usually the only one involved, becomes scaly, fissured, atrophic, and at times eroded and swollen; leukoplakia and squamous cell carcinoma (SCC) may develop (Fig. 34-2). Painful erosions may occur; actual ulceration is very rare unless carcinoma has developed. Hereditary polymorphous light eruption can resemble chronic actinic cheilitis, but it has no malignant potential.



**Fig. 34-1** Cheilitis secondary to lip licking.



**Fig. 34-2** Actinic cheilitis.

Avoiding sun exposure and the use of sunscreen containing lip pomades suffice to minimize further damage. A biopsy should be performed on any suspicious, thickened areas that persist; preferably, a shave technique should be used to avoid scarring.

Cryosurgical treatment may be effective, particularly for localized lesions. In cases with diffuse involvement, application of topical 5-fluorouracil (5-FU), imiquimod, ingenol, or photodynamic therapy (PDT) may be curative. Treatment with a thulium fractionated or ablative erbium laser, dermabrasion, or electrodesiccation may be required for severe disease and provides excellent results. Long-term follow-up is necessary; residual dysplasia is present with each treatment. Should treatment fail, vermilionectomy of the lower lip may be necessary. Excision of the exposed vermilion mucous membrane with advancement of the labial mucosa to the skin edge of the outer lip is effective, but this is performed less frequently since the advent of laser therapy. Refer to Chapter 29 for more information on actinic cheilitis.

**Castineiras I, et al:** Actinic cheilitis. *J Dermatolog Treat* 2010; 21:49.

**Cavalcante AS, et al:** Actinic cheilitis. *J Oral Maxillofac Surg* 2008; 66:498.

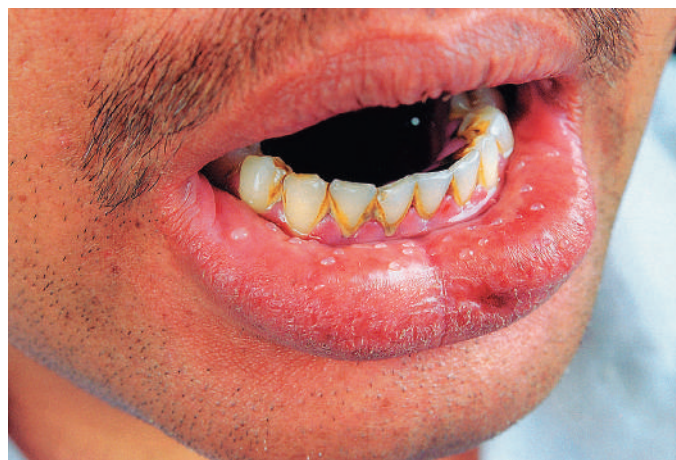**Cohen JL:** Erbium laser resurfacing for actinic cheilitis. *J Drugs Dermatol* 2013; 12(11):1290–1292.

**Dufresne RG Jr, et al:** Dermabrasion for actinic cheilitis. *Dermatol Surg* 2008; 34:848.

**Fai D, et al:** Methyl-aminolevulinate photodynamic therapy for the treatment of actinic keratoses and non-melanoma skin cancers. *G Ital Dermatol Venereol* 2009; 144(3):281–285.

**Ghasri P, et al:** Treatment of actinic cheilitis using a 1,927-nm thulium fractional laser. *Dermatol Surg* 2012; 38: 504–507.

**Ribeiro CF, et al:** Photodynamic therapy in actinic cheilitis. *An Bras Dermatol* 2012; 87(3):418–423.



**Fig. 34-3** Cheilitis glandularis. (Courtesy of Dr. Shyam Verma.)

**Sotiriou E, et al:** Sequential use of photodynamic therapy and imiquimod 5% cream for the treatment of actinic cheilitis. *Br J Dermatol* 2011; 165(4):888–892.

**Vieira RA, et al:** Actinic cheilitis and squamous cell carcinoma of the lip. *An Bras Dermatol* 2012; 87(1):105–114.

### Cheilitis glandularis

Cheilitis glandularis is characterized by swelling and eversion of the lower lip, patulous openings of the ducts of the mucous glands, cysts, and at times, abscess formation. There is general enlargement of the lips (Fig. 34-3). Mucus exudes freely to form a gluey film that dries over the lips and causes them to stick together during the night. When the lip is palpated between the thumb and index finger, the enlarged mucous glands feel like pebbles beneath the surface. The lower lip is the site of predilection. Middle-age men are most often affected. Cheilitis glandularis is a chronic inflammatory reaction that is caused by an exuberant response to chronic irritation, or to atopic, factitious, or actinic damage.

On biopsy, there is a moderate histiocytic, lymphocytic, and plasmacytic infiltration in and around the glands. Cheilitis glandularis has been reported to eventuate in SCC, but these cases may be attributed to chronic sun exposure, which frequently precedes cheilitis glandularis.

Treatment depends on the nature of the antecedent irritation; in most cases, treatment as described for actinic cheilitis is appropriate. Surgical debulking may be necessary. Intralesional triamcinolone may be beneficial in some patients, as may the combination of minocycline and tacrolimus ointment.

**Nico MM, et al:** Cheilitis glandularis. *J Am Acad Dermatol* 2010; 62:233.

**Reiter S, et al:** Cheilitis glandularis. *Oral Diseases* 2011; 17:335–339.

### Angular cheilitis

Angular cheilitis is synonymous with perleche. Fissures radiate downward and outward from the labial commissures. It is an intertriginous dermatitis caused by excessive wetness or dryness. It is often complicated by secondary infection with *Candida albicans* or *Staphylococcus aureus*.

The disease usually occurs in elderly people who wear dentures, but it may develop simply from an overhanging of the upper lip and cheek, and recession and atrophy of the alveolar ridges in old age. Measuring the facial dimensions with a ruler and tongue blade will help with objective assessment of the importance of decreased vertical facial dimension in the development of perleche. If the distance from the base of the nose



to the lower edge of the mandible is greater than or equal to 6 mm less than the distance from the center of the pupil to the parting line of the lips, the vertical dimension is decreased. In these circumstances, drooling is usually a factor. In children, angular cheilitis occurs frequently in thumb suckers, gum chewers, and lollipop eaters. Other inciting factors include riboflavin deficiency, anorexia nervosa, Down syndrome, intraoral candidiasis, especially in patients with diabetes, AIDS, chronic mucocutaneous candidiasis, Sjögren syndrome, orthodontic treatment, drug-induced xerostomia, and AD.

Opening the “bite” by improving denture fit, capping teeth, replacing lost teeth, or increasing denture height, combined with topical use of nystatin and iodochlorhydroxyquin in hydrocortisone ointment, is usually effective when the condition is associated with anatomically predisposing factors. Stubborn cases typically respond to a slightly stronger corticosteroid, such as desonide, in combination with a topical anticandidal agent. Injection of collagen or insertion of Soft-form implants to obliterate the angular creases may be beneficial. Therapy for underlying diseases should be maximized. If *S. aureus* is present, mupirocin ointment may be needed. Excision of the region, followed by a rotating flap graft, is another therapeutic option, but surgery should be reserved for resistant cases.

**Adedigba MA, et al:** Patterns of oral manifestations of HIV/AIDS among 225 Nigerian patients. *Oral Dis* 2008; 14:341.

**Lu DP:** Prosthodontic management of angular cheilitis and persistent drooling. *Compend Contin Educ Dent* 2007; 28:572.

**Park KK, et al:** Angular cheilitis. Part 1. *Cutis* 2011; 87(6):289–295.

**Park KK, et al:** Angular cheilitis. Part 2. *Cutis* 2011; 88(1):27–32.

**Sharifzadeh A, et al:** Oral microflora and their relation to risk factors in HIV+ patients with oropharyngeal candidiasis. *J Mycol Med* 2013; 23(2):105–112.

**Sharon V, et al:** Oral candidiasis and angular cheilitis. *Dermatol Ther* 2010; 23:230.

### Plasma cell cheilitis

This is also referred to as plasma cell orificial mucositis or, when the gingival is the site of involvement, plasma cell gingivitis. It is characterized by a sharply outlined, infiltrated, dark red plaque with a lacquer-like glazing of the surface of the involved area. This lesion has the same microscopic features as Zoon balanitis plasmacellularis. There is plasma cell infiltration in a bandlike pattern. Plasma cell cheilitis is not a response that is specific for any stimulus but rather represents a reaction pattern to any one of a variety of stimuli. Successful therapies include application of topical tacrolimus ointment or clobetasol propionate ointment twice daily.

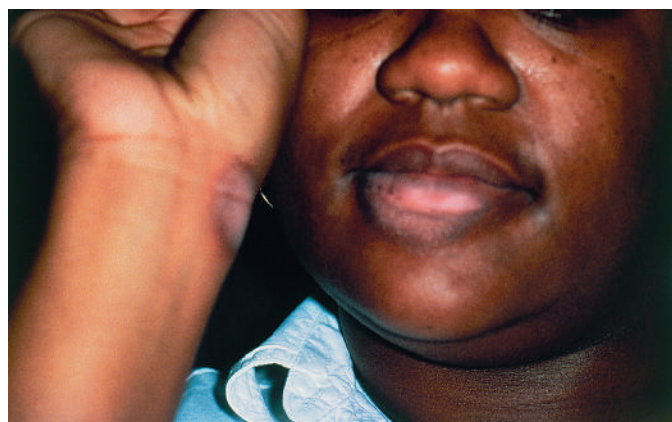### Plasmoacanthoma

Plasma cell cheilitis and plasmoacanthoma have been reported in the same patient and are believed to represent a spectrum of the same disease. Plasmoacanthoma is a verrucous tumor with a plasma cell infiltrate involving the oral mucosa, particularly along the angles. Other locations may occur, such as the perianal, periumbilical, or inguinal areas and toe webs. *C. albicans* has been found within the tissue, suggesting that it may be implicated as a cause of this disease. Excision, destruction, anticandidal preparations, and intralesional steroids are all options for treatment.

**Da Cunha Filho RR, et al:** “Angular” plasma cell cheilitis. *Dermatol Online J* 2014; 20(3). pii: doj\_21759.

**Jin Sp, et al:** Plasma cell cheilitis, successfully treated with topical 0.03% tacrolimus ointment. *J Dermatolog Treat* 2010; 21(3):1302.

**Senol M, et al:** Intertriginous plasmacytosis with plasmoacanthoma. *Int J Dermatol* 2008; 47:265.



**Fig. 34-4** Fixed drug eruption.

### Drug-induced ulcer of the lip

Painful or tender, well-defined ulcerations without induration on the lower lip may heal after withdrawal of oral medications. The causative drugs may be phenylbutazone, chlorpromazine, phenobarbital, methyl dopa, or thiazide diuretics. Solar exposure appears to be a predisposing causative influence; in some cases, this reaction may represent a fixed drug photoeruption. On rare occasions, fixed drug eruptions may also involve the lip, usually caused by naproxen, one of the oxicams, or trimethoprim-sulfamethoxazole (Fig. 34-4).

**Abdollahi M, et al:** A review of drug-induced oral reactions. *J Contemp Dent Pract* 2003; 4(1):10–31.

**Pemberton MN, et al:** Fixed drug eruption to oxybutynin. *Oral Surg Oral Med Oral Pathol Oral Radiol Endod* 2008; 106:e19.

### Other forms of cheilitis

Several diseases discussed elsewhere may affect the lips, including lichen planus, lupus erythematosus, erythema multiforme, AD, and psoriasis. A high percentage of patients with Down syndrome have cheilitis of one or both lips. Lip biting may be a factor.

## ORAL AND CUTANEOUS CROHN'S DISEASE

Crohn's disease is a chronic granulomatous disease of any part or parts of the bowel. Patients with Crohn's disease may develop inflammatory hyperplasia of the oral mucosa, with metallic dysgeusia and gingival bleeding. Reported typical changes include diffuse oral swelling, focal mucosal hypertrophy and fissuring (cobblestoning), persistent ulceration, polypoid lesions, indurated fissuring of the lower lip, angular cheilitis, granulomatous cheilitis, or pyostomatitis vegetans. Oral involvement occurs in 10–20% of patients with Crohn's disease, and 90% have granulomas on biopsy. Males with early-onset disease are most often affected. Concomitant involvement of the anal and esophageal mucosa is common.

Many cases of Crohn's disease with other cutaneous manifestations have been reported, notably pyoderma gangrenosum (more closely associated with ulcerative colitis) and erythema nodosum, polyarteritis nodosa, pellagra, pernicious anemia, an acrodermatitis-like eruption, urticaria, and necrotizing vasculitis. Direct extension to perianal skin may occur.

Metastatic Crohn's disease denotes noncaseating granulomatous skin lesions in patients with Crohn's disease. In the absence of bowel involvement, the diagnosis cannot be made. The morphologic appearances seen include genital swelling or

condyloma-like lesions, leg ulceration, pyogenic granuloma-like lesions of the retroauricular skin, and erythematous nodules, plaques, or ulcers in other locations.

Treatment of the gastrointestinal (GI) manifestations with sulfasalazine, metronidazole, systemic corticosteroids, infliximab, or immunosuppressive medications such as cyclosporine, azathioprine, mycophenolate mofetil, and methotrexate can improve the cutaneous findings. Several delivery systems use only the active ingredient of sulfasalazine, mesalamine, including Asacol, Pentasa, Rowasa, and olsalazine, and may be useful in treating the skin involvement of Crohn's disease. A mouthwash containing triamcinolone acetonide, tetracycline, and lidocaine may provide symptomatic and objective improvement. Cutaneous ulcerated granulomas and erythematous plaques caused by Crohn's disease may respond to high-potency topical corticosteroids or tacrolimus ointment. Curettage and zinc by mouth have resulted in healing in several reported patients. Dietary manipulation is another measure that can be helpful in select individuals. The course is often prolonged over several years.

**Alawai F, et al:** An update on granulomatous diseases of the oral tissues. *Dent Clin North Am* 2013; 57(4):657–671.

**Alemanno G, et al:** Rare cutaneous manifestations associated with Crohn's disease. *Int J Colorectal Dis* 2014; 29(6):765–767.

**Kurtzman DJ, et al:** Metastatic Crohn's disease. *J Am Acad Dermatol* 2014; May 30. pii: S0190-9622(14)01281-X.

**Macaigne G, et al:** Crohn's disease revealed by a cheilitis granulomatosa with favorable evolution by perfusions of infliximab. *Clin Res Hepatol Gastroenterol* 2011; 35(2):147–149.

**Marzano AV, et al:** Cutaneous manifestations in patients with inflammatory bowel diseases. *Inflamm Bowel Dis* 2014; 20(1):213–227.

**Mignogna MD, et al:** Oral Crohn's disease. *Am J Gastroenterol* 2008; 103:2954.

**Pazheri F, et al:** Pyostomatitis vegetans as an oral manifestation of Crohn's disease in a pediatric patient. *Inflamm Bowel Dis* 2010; 16(12):2007.

**Shah NP, et al:** Treatment of a Crohn's disease-related facial lesion with topical tacrolimus. *Oral Surg Oral Med Oral Pathol Oral Radiol* 2014; 118:e71–73.

**Thrash B, et al:** Cutaneous manifestations of gastrointestinal disease. *J Am Acad Dermatol* 2013; 68(2):211.

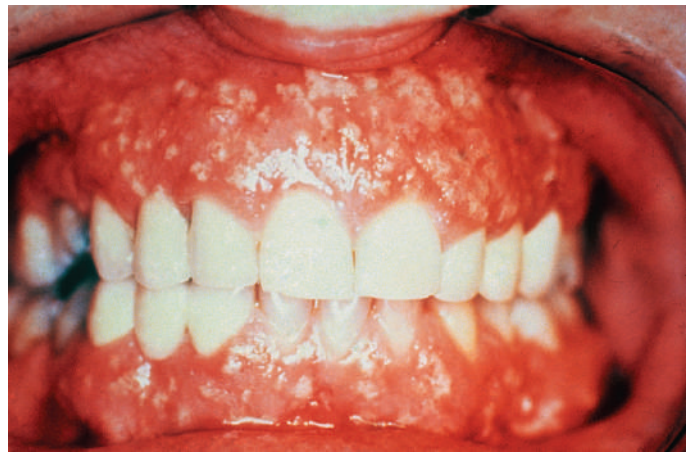**Yuksel I, et al:** Mucocutaneous manifestations of inflammatory bowel disease. *Inflamm Bowel Dis* 2009; 15:546.

## PYOSTOMATITIS VEGETANS

Pyostomatitis vegetans, an inflammatory stomatitis, is most often seen in association with ulcerative colitis but may also occur in other inflammatory bowel diseases, such as Crohn's disease. Edema and erythema with deep folding of the buccal mucosa characterize pyostomatitis vegetans, together with pustules, small vegetating projections, erosions, ulcers, and fibrinopurulent exudates (Fig. 34-5). Eroded pustules fuse into shallow ulcers, resulting in characteristic "snail-track" ulcers. It has also been associated with sclerosing cholangitis. Several cases have been reported with no underlying systemic disorder.

Histologically, there are dense aggregates of neutrophils and eosinophils. At times, crusted erythematous papulopustules that coalesce into asymmetric annular plaques may occur with or after the oral lesions. These associated skin lesions favor the axillae, groin, and scalp and are termed pyodermitis vegetans. Topical corticosteroids or tacrolimus ointment may be effective; systemic corticosteroids or infliximab, however, are usually necessary.

**Marcello MS, et al:** Pyostomatitis vegetans and its relation to inflammatory bowel disease, pyoderma gangrenosum, pyodermitis vegetans, and pemphigus. *J Oral Pathol Med* 2012; 41:584–588.



**Fig. 34-5** Pyostomatitis vegetans. (Courtesy of Dr. Charles Casima.)

**Matias Fde A, et al:** Pyodermitis-pyostomatitis vegetans. *An Bras Dermatol* 2011; 86(4 Suppl):S137–S140.

**Shah S, et al:** Pyostomatitis vegetans. *N Engl J Med* 2013; 368:20.

**Wang H, et al:** A case of pyodermitis-pyostomatitis vegetans. *Am J Med Sci* 2013; 345(2):168–171.

## CHEILITIS GRANULOMATOSA

Cheilitis granulomatosa is characterized by a sudden onset and progressive course, terminating in chronic enlargement of the lips. Usually, the upper lip becomes swollen first; several months may elapse before the lower lip becomes swollen. Usually, only enlargement is present, without ulceration, fissuring, or scaling. The swelling remains permanently. It may be a part of the Melkersson-Rosenthal syndrome when associated with facial paralysis and plicated tongue.

The cause is unknown. Histologically, cheilitis granulomatosa is characterized by an inflammatory reaction of lymphocytes, histiocytes, and plasma cells and by tuberculoid granulomas consisting of epithelioid and Langerhans giant cells. At times, intralymphatic granulomas are found and may account for the clinical swelling. In the differential diagnosis, solid edema, angioedema, cheilitis glandularis, sarcoidosis, oral Crohn's disease, infectious granulomas, contact allergy, reaction to silicone fillers, and Ascher syndrome must be considered. This cheilitis may be the presenting sign in a patient who will develop Crohn's disease or sarcoidosis at a later time.

Treatment with intralesional injections of corticosteroids is usually successful but temporary. Combining this modality with oral anti-inflammatory agents for long-term control, such as doxycycline, dapsone, colchicine, sulfasalazine, hydroxychloroquine, anti-tumor necrosis factor (TNF) agents, or topical tacrolimus ointment, is an excellent strategy. In the firmly established case, surgical repair of the involved lip through a mucosal approach and, in some cases, concomitant intralesional corticosteroid treatment provide the best results.

**Alvarez-Garrido H, et al:** Crohn's disease and cheilitis granulomatosa. *J Am Acad Dermatol* 2011; 65(1):239–241.

**Arias-Santiago S, et al:** Persistent swollen lip. *Lancet* 2013; 381:2280.

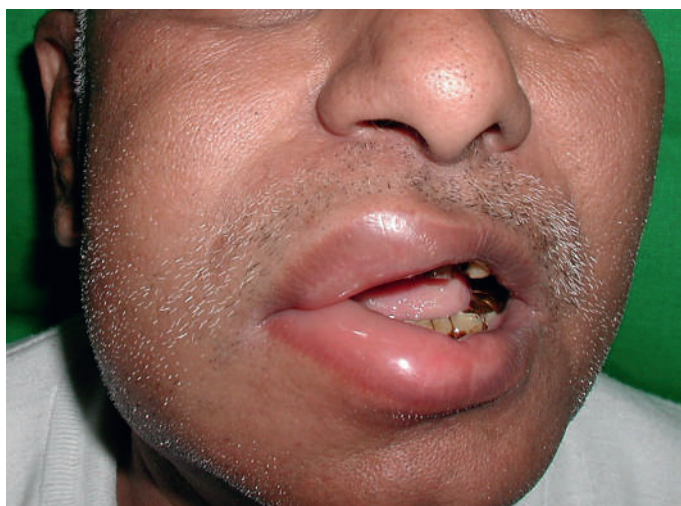**Chiu CS, et al:** Cheilitis granulomatosa associated with allergic contact dermatitis to betel quid. *Contact Dermatitis* 2008; 58:246.

**Crutchlow WA, et al:** Cheilitis granulomatosa. *Head Neck Pathol* 2014; 8(2):209–213.

**Gonzalez-Garcia C, et al:** Intralymphatic granulomas as a pathogenic factor in cheilitis granulomatosa/Melkersson-Rosenthal syndrome. *Am J Dermatopathol* 2011; 33(6):594–598.

**Lynde CB, et al:** Cheilitis granulomatosa treated with intralesional corticosteroids and anti-inflammatory agents. *J Am Acad Dermatol* 2011; 65(3):e101–e102.





**Fig. 34-6** Melkersson-Rosenthal syndrome. (Courtesy of Dr. Shyam Verma.)

## MELKERSSON-ROSENTHAL SYNDROME

Melkersson in 1928 and Rosenthal in 1930 described a triad consisting of recurring facial paralysis or paresis, soft nonpitting edema of the lips, and scrotal tongue. Attacks usually start during adolescence, with permanent or transitory paralysis of one or both facial nerves, repeated migraines, and recurring edema of the upper lip, cheeks, and occasionally the lower lip and circumoral tissues. Swelling of the skin and mucous membranes of the face and mouth is the dominant finding and most important diagnostic feature (Fig. 34-6). In order of frequency, the swelling occurs first on the upper lip, then the lower lip, and then other regions. Chronic eyelid swelling may occur.

Extrafacial swellings appear on the dorsal aspect of the hands and feet and in the lumbar region. The pharynx and respiratory tract may be involved, with thickening of the mucous membrane. The relapsing condition produces an overgrowth of connective tissue, edema, and atrophy of the muscle fibers, with permanent deformities of the lips, cheeks, and tongue.

The cause of Melkersson-Rosenthal syndrome is unknown. The association at times with megacolon, otosclerosis, and craniopharyngioma supports the theory of a neurotrophic origin. It may be familial.

Histopathologic evaluation shows a tuberculoid type of granuloma with lymphedema and a banal perivascular infiltrate. Intralymphatic granulomas may account for the swelling. In the differential diagnosis, a number of diseases characterized by edema of the lips must be considered. Ascher syndrome consists of swelling of the lips with edema of the eyelids (blepharochalasis) and is inherited. Melkersson-Rosenthal syndrome must also be differentiated from the acute swellings produced by angioedema, trauma, and infections of all types. Lymphangioma, hemangioma, neurofibroma, and sarcoidosis are some of the clinical considerations.

Melkersson-Rosenthal syndrome is frequently seen in an incomplete form, and other granulomatous diseases may present as swellings of the lips or orofacial tissues. It is worthwhile calling these, as a group, "orofacial granulomatosis" so that various underlying disease states or etiologic factors will not be missed when evaluating such patients. Oral Crohn's disease, patients who will develop typical Crohn's or sarcoidosis in the future, cheilitis granulomatosa, sarcoidosis, granulomatous infiltrates associated with tooth infections, and patients with food or contact allergic reactions should all be considered.

Intralesional injections of corticosteroids may be beneficial therapy. Again, combining this with oral anti-inflammatory agents for long-term control, such as doxycycline, dapsone, colchicine, sulfasalazine, hydroxychloroquine, anti-TNF agents, or topical tacrolimus ointment, is an excellent strategy. Clofazimine and thalidomide are reported to be useful, but availability and side effects limit their use. Surgery alone may be used, or surgery combined with intralesional corticosteroid injections and oral medications may be more successful than any of the three alone. Compression therapy is another adjuvant intervention that may add improvement without side effects. Decompression of the facial nerve may be indicated in patients with recurrent attacks of facial palsy. Odontogenic infection has been reported to initiate this condition, and antibiotic therapy for this may lead to remission.

**Belliveau MJ, et al:** Melkersson-Rosenthal syndrome presenting with isolated bilateral eyelid swelling. *Can J Ophthalmol* 2011; 46(3):286-287.

**Feng S, et al:** Melkersson-Rosenthal syndrome. *Acta Otolaryngol* 2014 June; 1-5

**Gonzalez-Garcia C, et al:** Intralymphatic granulomas as a pathogenic factor in cheilitis granulomatosa/Melkersson-Rosenthal syndrome. *Am J Dermatopathol* 2011; 33(6):594-598.

**Li Z et al:** Compression therapy. *Eur J Dermatol* 2011; 21(6):1003-1004.

**Liu R, et al:** Melkersson-Rosenthal syndrome. *J Clin Neurosci* 2013; 20(7):993-995.

## FORDYCE'S DISEASE (FORDYCE SPOTS)

Fordyce spots are ectopically located sebaceous glands, clinically characterized by minute, orange or yellowish, pinhead-sized macules or papules in the mucosa of the lips, cheeks, and less often the gums. Similar lesions may occur on the areolae, glans penis, and labia minora. Prominent lip involvement may result in a lipstick-like mark left on the rim of a glass mug after consuming a hot beverage (Meffert's sign). Involvement of the labial mucosa with pseudoxanthoma elasticum may simulate Fordyce spots. Because the anomaly is asymptomatic and inconsequential, treatment should be undertaken only if there is a significant cosmetic problem. The carbon dioxide (CO<sub>2</sub>) laser, electrodesiccation and curettage, bichloroacetic acid, PDT, and isotretinoin are therapeutic options.

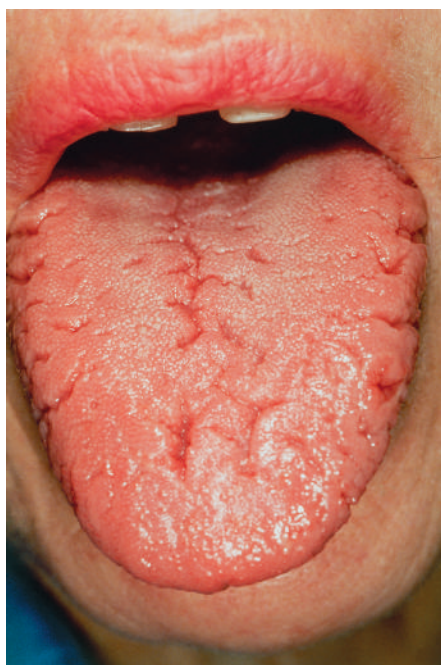**Chen PL, et al:** Fordyce spots of the lip responding to electrodesiccation and curettage. *Dermatol Surg* 2008; 34:960.

**Errichetti E, et al:** Areolar sebaceous hyperplasia associated with oral and genital Fordyce spots. *J Dermatol* 2013; 40(8):670.

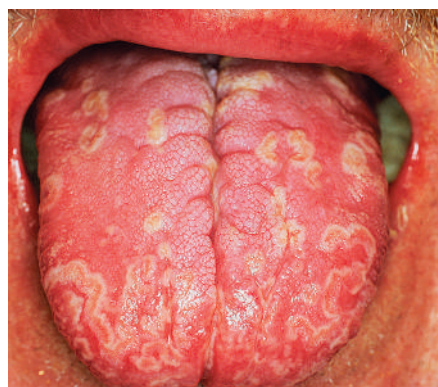## STOMATITIS NICOTINA

Also known as smoker's keratosis and smoker's patches, stomatitis nicotina is characterized by distinct, umbilicated papules on the palate. The ostia of the mucous ducts appear as red pinpoint surrounded by milky-white, slightly umbilicated, asymptomatic papules. The intervening mucosa becomes white and thick and tends to desquamate in places, leaving raw, beefy-red areas. Ulceration and the formation of aphthous ulcers may occur. Stomatitis nicotina is attributed to heavy smoking in middle-age men, although it has also been reported in nonsmokers who habitually drink hot beverages. Heat may be the causative event. Indeed, the most severe cases are associated with the type of tobacco use that produces intense heat—pipe and reverse smoking. Treatment consists of abstaining from the use of tobacco or the ingestion of hot liquids.

**Al-Attas SA, et al:** Prevalence of potentially malignant oral mucosal lesions among tobacco users in Jeddah, Saudi Arabia. *Asian Pac J Cancer Prev* 2014; 15(2):757-762.



**Fig. 34-7** Fissured tongue.



**Fig. 34-8** Annulus migrans.

**Vellappally S, et al:** Smoking related system and oral diseases. *Acta Medica* 2007; 50(3):161–166.

## TORUS PALATINUS

Torus palatinus is a bony protuberance in the midline of the hard palate, marking the point of junction of the two halves of the palate. It is asymptomatic. Exostoses also frequently occur in the floor of the mouth, involving the inner surface of the mandible.

**Bennett WM:** Torus palatinus. *N Engl J Med* 2013; 368(15):1434.

**Cantin M, et al:** A proposed explanation for the development of the torus palatinus. *Clin Anat* 2011; 24:789–790.

**Garcia-Garcia AS, et al:** Current status of the torus palatines and torus mandibularis. *Med Oral Patol Oral Cir Bucal* 2010; 15(2):e353–e360.

## FISSURED TONGUE

Also known as furrowed tongue, scrotal tongue, or lingua plicata, fissured tongue is a congenital and sometimes familial condition in which the tongue is generally larger than normal, and plicate superficial or deep grooves are usually arranged so that there is a longitudinal furrow along the median raphe, reminiscent of scrotal rugae (Fig. 34-7).

Fissured tongue is seen in Melkersson-Rosenthal syndrome and in many patients with Down syndrome. Individual case reports have been seen in association with pachyonychia congenita, pemphigus vegetans, and Cowden syndrome. Geographic tongue occurs together with fissured tongue in 50% of patients, and both are more often present in psoriasis patients than nonpsoriatic patients.

The condition gives rise to no difficulty, and treatment is not necessary, except that the deep furrows should be kept clean by use of mouthwashes. Herpetic geometric glossitis may mimic fissured tongue, but it is painful, affects predominantly immunocompromised individuals, and is centered on the back of the dorsal tongue.

**Byrd JA, et al:** Glossitis and other tongue disorders. *Dermatol Clin* 2003; 21:123.

**Madani FM, et al:** Normal variations of oral anatomy and common oral soft tissue lesions. *Med Clin North Am* 2014; 98:1281–1298.

**Pereira CM, et al:** Herpetic geometric glossitis. *Indian J Pathol Microbiol* 2010; 53(1):133–134.

## GEOGRAPHIC TONGUE

Geographic tongue is also known as lingua geographica, transitory benign plaques of the tongue, glossitis areata exfoliativa, and benign migratory glossitis. In some patients, it is a manifestation of atopy, and in others, of psoriasis. In most, however, it is an isolated finding.

The dorsal surface of the tongue is the site usually affected. Geographic tongue begins with a small depression on the lateral border or the tip of the tongue, smoother and redder than the rest of the surface. This spreads peripherally, with the formation of sharply circumscribed, ringed or gyrate, red patches, each with a narrow, yellowish white border, making the tongue resemble a map. The appearance changes from day to day; patches may disappear in one place and manifest in another. The disease is characterized by periods of exacerbation and quiescence. The lesion may remain unchanged in the same site for long periods. The condition is frequently unrecognized because it produces no symptoms except for the occasional complaint of glossodynia.

There are two clinical variants of geographic tongue. In one type, discrete, annular “bald” patches of glistening, erythematous mucosa with absent or atrophic filiform papillae are noted. Another type shows prominent circinate or annular, white raised lines that vary in width up to 2 mm. The clinical appearance and histopathologic findings of the tongue lesions in pustular psoriasis, reactive arthritis (Reiter syndrome), and geographic tongue are identical; when the tongue lesions occur with psoriasis or reactive arthritis, the name annulus migrans has been suggested for this entity (Fig. 34-8). It has been reported as being acquired in patients with AIDS or as a result of lithium therapy.

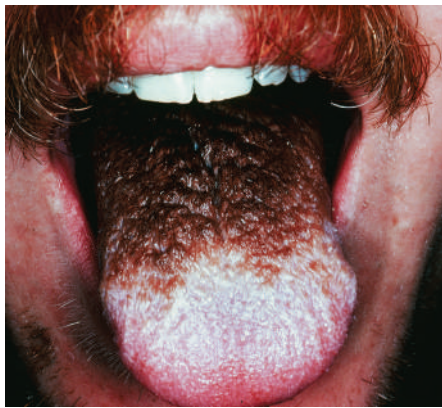Histologically, the main features are marked transepidermal neutrophil migration with the formation of spongiform pustules in the epidermis and an upper dermal mononuclear infiltrate. Although treatment is not usually necessary, a 0.1% solution of tretinoin solution (Retin-A) applied topically has produced clearing within 4–6 days.

**Byrd JA, et al:** Glossitis and other tongue disorders. *Dermatol Clin* 2003; 21:123.

**Gupta T, et al:** Medical image. A benign glossal lesion. *NZ Med J* 2014; 127(1394):88–90.

**Shekhar MG:** Geographic tongue in monozygotic twins. *J Clin Diagn Res* 2014; 8(4):ZD01–ZD02.





**Fig. 34-9** Black hairy tongue.

## BLACK HAIRY TONGUE

Black or brown hairy tongue occurs on the dorsum of the tongue anterior to the circumvallate papillae, where black, yellowish, or brown patches form, consisting of hairlike intertwining filaments several millimeters long (Fig. 34-9). The “hairs” result from a benign hyperplasia of the filiform papillae of the anterior two thirds of the tongue, resulting in retention of long, conical filaments of orthokeratotic and parakeratotic cells. It occurs much more frequently in men than in women.

Black hairy tongue may be associated with several conditions that may be predisposing factors in its causation: smoking, use of oral antibiotics, xerostomia, psychotropic drugs, and presence of *Candida* on the surface of the tongue.

This lesion may be differentiated both clinically and histologically from oral hairy leukoplakia, which is seen in human immunodeficiency virus (HIV)-infected patients. Hairy leukoplakia is usually seen on the lateral surface of the tongue, at first in corrugated patches, then with time, as solid white plaques that are adherent. Microscopic examination reveals acanthosis, parakeratosis, irregular projections of keratin, and vacuolated keratinocytes with Epstein-Barr virus (EBV) present within them.

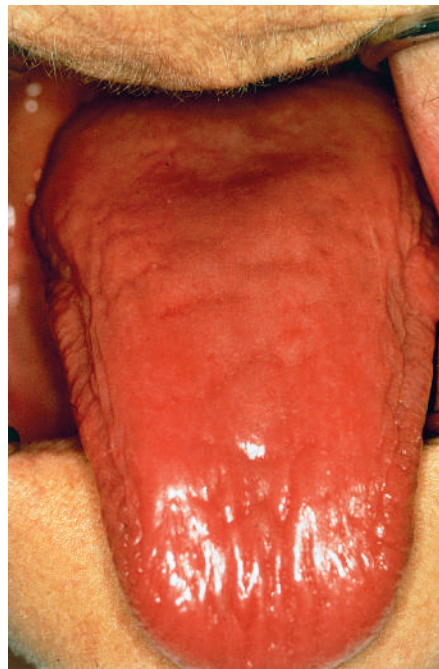A toothbrush may be used to scrub off the projections, either alone, with 1–2% hydrogen peroxide, or after application of Retin-A gel, 40% aqueous solution of urea, or papain (meat tenderizer). Such predisposing local factors as smoking, antibiotics, and oxidizing agents should be eliminated, if possible, and scrupulous oral hygiene maintained.

**Korber A, et al:** Black hairy tongue in an infant. *CMAJ* 2012; 184(10):68.

**Thompson DF, et al:** Drug-induced black hairy tongue. *Pharmacotherapy* 2010; 30(6):585–593.

## SMOOTH TONGUE

Also known as bald tongue or atrophic glossitis, the smooth glossy tongue is often painful and results from atrophy of the filiform and eventually the fungiform papillae (Fig. 34-10). When present with vitamin B<sub>12</sub> deficiency, it has been termed Moeller or Hunter glossitis. It begins with the tip and lateral surfaces of the tongue becoming intensely red, well-defined irregular patches in which the filiform papillae are absent or thinned and the fungiform papillae are swollen. The disease is chronic, and the patches are painful and sensitive, so eating may be difficult and taste impaired. With time, the entire tongue becomes smooth, and a leukoplakia may result. Treatment of pernicious anemia with vitamin B<sub>12</sub> therapy will result



**Fig. 34-10** Smooth tongue in Plummer-Vinson syndrome.

in improvements in the appearance and sensitivity of the tongue.

Atrophic glossitis is also a distinctive sign of pellagra; it results from a deficiency of niacin or its precursor, tryptophan. The sides and tip of the tongue are erythematous and edematous, with imprints of the teeth. Eventually, the entire tongue assumes a beefy-red appearance. Small ulcers appear, and all the mucous membranes of the mouth may be involved. Later, the papillae become atrophied to produce a smooth, glazed tongue, as seen in pernicious anemia. Burning or pain in the ulcers may be present. Increased salivary flow early in the disease may lead to drooling and angular cheilitis. In malabsorption syndrome, riboflavin deficiency, anorexia nervosa, alcoholism, and sprue, similar changes may be noted. Vitamin B complex is curative.

Patients with iron deficiency anemia, alone or with esophageal webs (Plummer-Vinson syndrome), and those with folic acid deficiency, syphilis, amyloidosis, celiac disease, Sjögren syndrome, or Riley-Day syndrome, may all manifest smooth tongue. Candidiasis may result in tongue pain and a partial or total atrophic appearance, along with a red or magenta color, on the dorsum of the tongue. In such patients, anticandidal therapy results in rapid improvement.

**Byrd JA, et al:** Glossitis and other tongue disorders. *Dermatol Clin* 2003; 21:123.

**Cunha SF, et al:** Papillary atrophy of the tongue and nutritional status of hospitalized alcoholics. *An Bras Dermatol* 2012; 87(1):84–89.

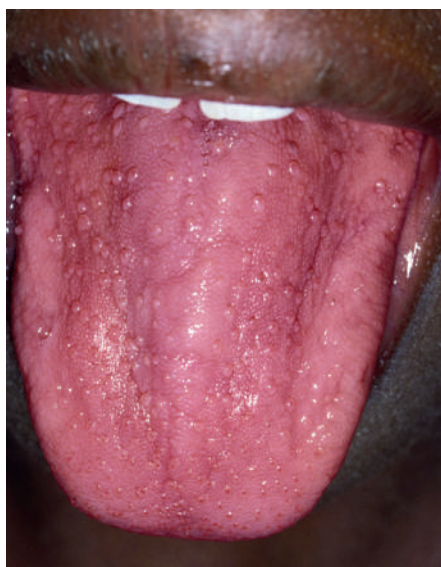**Demir N, et al:** Dermatological findings of vitamin B<sub>12</sub> deficiency and resolving time of these symptoms. *Cutan Ocul Toxicol* 2014; 33(1):70–73.

**Lee HJ, et al:** A smooth, shiny tongue. *N Engl J Med* 2009; 360:e8.

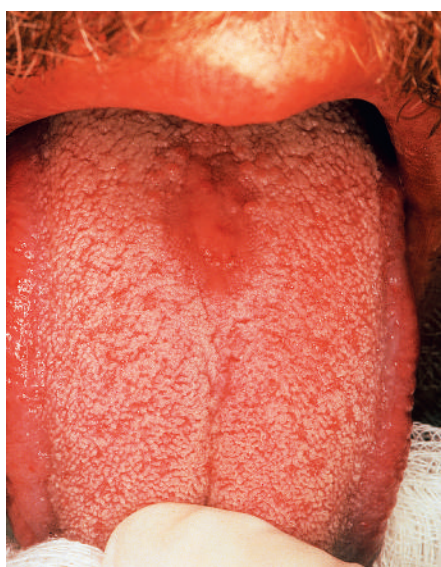**Wu YC, et al:** Oral manifestations and blood profile in patients with iron deficiency anemia. *J Formos Med Assoc* 2014; 113(2):83–87.

## ERUPTIVE LINGUAL PAPILLITIS

Lacour and Perrin first described this acute, self-limiting inflammatory stomatitis in 1997. It affects children of both genders equally, with a mean age at onset of 3½ years. It has a seasonal distribution, with the majority of cases occurring in the spring. Fever (40%), difficulties in feeding (100%), and intense salivation (60%) are common symptoms. The tongue



**Fig. 34-11** Eruptive lingual papillitis.



**Fig. 34-12** Median rhomboid glossitis.

examination reveals inflammatory hypertrophy of the fungiform papillae on the tip and dorsolateral sites (Fig. 34-11). Additional signs include submandibular or cervical adenopathy (40%) and angular cheilitis (10%). Associated skin eruptions have not been described. Spontaneous involution occurs in a mean of 7 days (range 2–15 days). Recurrence is noted in 13%. Eruptive lingual papillitis is thought to result from a viral infection, and the 50% transmission among family members further supports this theory.

**Mondal A, et al:** Eruptive lingual papillitis. *Indian Pediatr* 2014; 51(3):243.

**Roux O, et al:** Eruptive lingual papillitis with household transmission. *Br J Dermatol* 2004; 150:299.

### MEDIAN RHOMBOID GLOSSITIS

Median rhomboid glossitis is characterized by a shiny, oval or diamond-shaped elevation, invariably situated on the dorsum in the midline immediately in front of the circumvallate papillae (Fig. 34-12). The surface is abnormally red and smooth. In some cases, a few pale-yellow papules surmount the elevation. On palpation, the lesion feels slightly firm, but it usually

causes no symptoms. It persists indefinitely, with minimal or no increase in size. There is no relationship to cancer.

Median rhomboid glossitis may result from abnormal fusion of the posterior portion of the tongue, but it is almost always chronically infected with *Candida*. If there is palatal inflammation above the inflamed part of the tongue, AIDS should be suspected and an HIV test obtained. Histologically, the changes are those of a simple, chronic inflammation with fibrosis, and usually with fungal hyphae in the parakeratin layer. Treatment with clotrimazole troches or oral antifungals, such as itraconazole, may lead to improvement.

**Basak P, et al:** A smooth patch on the tongue. *N Engl J Med* 2010; 363(20):1949.

**Noonan V, et al:** Median rhomboid glossitis. *J Mass Dent Soc* 2011; 59(4):41.

### EOSINOPHILIC ULCER OF THE ORAL MUCOSA

Eosinophilic ulcer occurs most frequently on the tongue but may occur anywhere in the oral mucosa. It is characterized by an ulcer with indurated and elevated borders that is usually covered by a pseudomembrane. It develops rapidly, most often on the posterior aspect of the tongue, and spontaneously resolves in a few weeks. A traumatic cause has been postulated for this benign, self-limited disorder. The histopathologic findings show a predominantly eosinophilic infiltrate with some histiocytes and neutrophils.

In some multifocal, recurrent cases, CD30+ cells have been reported. These patients may have the oral counterpart of primary cutaneous CD30+ lymphoproliferative disease, or may simply be a simulator of this disorder. In one positive case, EBV staining was positive; the lesion resolved in 4 weeks. HIV-infected patients may develop ulcerations of the oral mucosa, resulting from a variety of infectious agents, such as herpes simplex virus (HSV), candidiasis, and histoplasmosis. However, 5 of the 16 patients reported had no evidence of infection and simply showed eosinophilic infiltrates below the ulcer.

**Abdel-Naser MB, et al:** Oral eosinophilic ulcer, an Epstein-Barr virus-associated CD30+ lymphoproliferation? *Dermatology* 2011; 222(2):113–118.

**Damevska K, et al:** Eosinophilic ulcer of the oral mucosa. *Am J Dermatopathol* 2014; 36(7):594–596.

### CAVIAR TONGUE

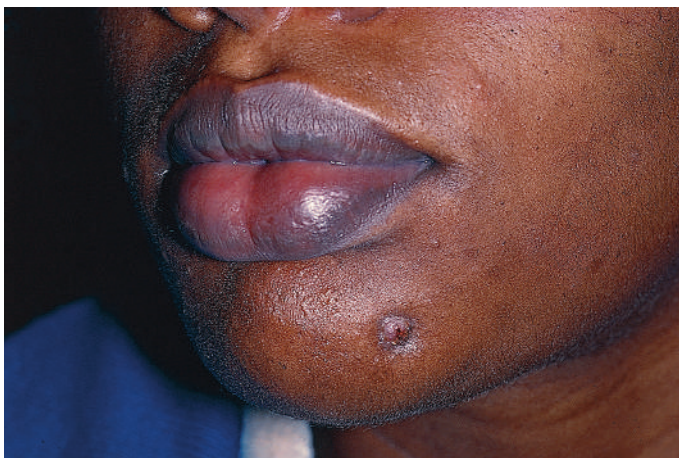William Bean gave the picturesque name caviar tongue to the purplish venous ectasias so commonly found on the undersurface of the tongue after age 50. They are attributed to elastic tissue deterioration with aging and may be associated with Fordyce angiokeratomas of the scrotum. Phleboliths or thrombophlebitis may occasionally complicate this condition.

**Viswanath V, et al:** Caviar tongue. *Indian J Dermatol Venereol Leprol* 2011; 77(1):78–79.

### CUTANEOUS SINUS OF DENTAL ORIGIN (DENTAL SINUS)

In dental (or odontogenous) sinus, chronic periapical infection around a tooth produces a burrowing, practically asymptomatic, occasionally palpable, cordlike sinus tract that eventually appears beneath the surface of the gum, palate, or periorificial skin. It forms a fistulous opening with an inflamed red nodule at the orifice. It may appear anywhere from the inner ocular





**Fig. 34-13** Odontogenic sinus.

canthus to the neck, but is most often seen on the chin or along the jawline (Fig. 34-13). Bilateral involvement has been reported. Dental radiography is diagnostic. Pyogenic granuloma, actinomycosis, SCC, osteomyelitis of the mandible, congenital fistulas, the deep mycoses, bisphosphonate-related osteonecrosis of the jaw, and foreign body reactions must be considered in the differential diagnosis. Treatment requires the removal of the offending tooth or root canal therapy of the periapical abscess.

**Bodner L, et al:** Cutaneous sinus tract of dental origin in children. *Pediatr Dermatol* 2012; 29(4):421–425.

**Gupta, et al:** A clinical predicament—diagnosis and differential diagnosis of cutaneous facial sinus tracts of dental origin. *OOOOE* 2011; 112(6):e132–e136.

**Mardones F, et al:** Cutaneous facial sinus tract of dental origin. *Pediatr Dermatol* 2010; 27(4):410–411.

**Truong SV, et al:** Bisphosphonate-related osteonecrosis of the jaw presenting as a cutaneous dental sinus track. *J Am Acad Dermatol* 2010; 62:672.

## NEOPLASMS

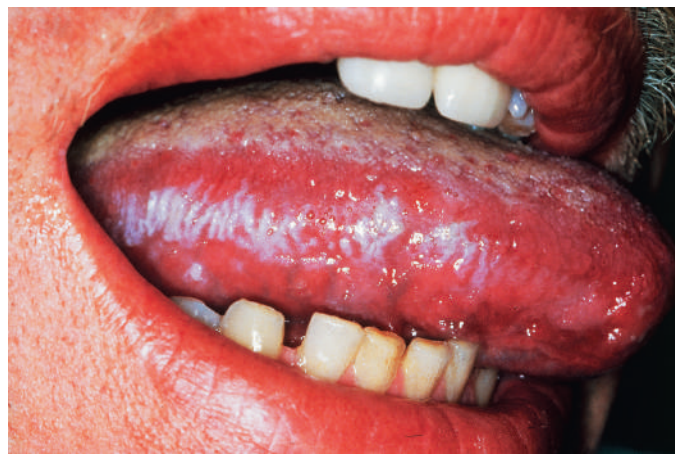Many tumors may involve the oral cavity. Most are discussed elsewhere in this book, and several are uncommon entities that affect specialized oral structures, such as the many subtypes of benign and malignant proliferations that occur in the major and minor salivary glands. These are not covered further here, and only a few select neoplasms are presented.

### Leukoplakia

#### Clinical features

Leukoplakia presents as a whitish thickening of the epithelium of the mucous membranes, occurring as lactescent superficial patches of various shapes and sizes that may coalesce to form diffuse sheets. The surface is generally glistening and opalescent, often reticulated, and may even be somewhat pigmented. The white pellicle is adherent to the underlying mucosa, and attempts to remove it forcibly cause bleeding. At times, it is a thick, rough, elevated plaque. The lips, gums, cheeks, and edges of the tongue are the most common sites, but the lesion may arise on the anus and genitalia. Leukoplakia is found chiefly in men over age 40.

Biopsy of these white lesions may reveal orthokeratosis or parakeratosis with minimal inflammation, or there may be



**Fig. 34-14** Oral hairy leukoplakia of HIV.

evidence of varying degrees of dysplasia. A benign form is usually a response to chronic irritation and has very little chance of conversion into the precancerous dysplastic form. Premalignant leukoplakia, with atypical cells histologically, is present in only about 10–20% of leukoplakia. Unfortunately, it is not possible to predict clinically which lesions will be worrisome histologically, except that if ulceration, red areas, or erosions are scattered throughout, the lesion is most likely precancerous. Therefore, biopsy is indicated.

When the lesion occurs on the lip, leukoplakia is closely related to chronic actinic cheilitis, which consists of a circumscribed or diffuse keratosis, almost invariably on the lower lip. It is preceded by an abnormal dryness of the lip and may be caused by smoking (especially pipe smoking) or chronic sun exposure. This type of leukoplakia is distinguished from SCC of the lip by the absence of infiltration, from lichen planus and psoriasis of the lips and mouth by the absence of lesions elsewhere, and from lupus erythematosus by the absence of telangiectases. Biopsy is necessary, however, to differentiate these conditions fully.

Intraoral leukoplakia appears to progress to SCC in no more than 1% of lesions per year. In time, an extensive, thick, white pellicle may cover the tongue or oral mucosa. In old lesions, the epithelium may be desquamated, and there may be fissures or ulcerations. Such changes are associated with more or less hyperemia and tenderness, and with a tendency to bleed after slight trauma. If transformation to carcinoma occurs, it generally follows a lag time of 1–20 years, although immunosuppressed transplant patients may have a rapid course of transformation.

Oral hairy leukoplakia is a term used to describe white, corrugated plaques that occur primarily on the sides of the tongue of patients with AIDS (Fig. 34-14). This is a virally induced lesion, discussed in Chapter 19, which has a characteristic histology.

Leukoplakia of the vulva usually occurs in obese women after menopause as grayish white, thickened, pruritic patches that may become fissured and edematous from constant rubbing and scratching. Secondary infection with edema, tenderness, and pain may occur. It is differentiated from lichen planus by the absence of discrete, rectangular, or annular flat papules of violaceous hue in the mucosa outside the thickened patches, about the anus, on the buccal mucosa, or on the skin. Leukoplakia of the vulva is most frequently confused with lichen sclerosus et atrophicus and other vulval atrophies. On the penis, although leukoplakia may occur, a similar precancerous process called erythroplasia (of Queyrat) is usually seen instead.

## Etiology

Numerous factors are involved in the cause of leukoplakia. It may develop as a result of tobacco smoking; use of smokeless tobacco; areca, qat, or betel nut chewing; reverse smoking; alcohol; poorly fitting dentures; sharp and chipped teeth; or improper oral hygiene. Extensive involvement of the lips and oral cavity with leukoplakia may exist for years with no indication of carcinoma. On the other hand, small, inflamed patches may be the site of a rapidly growing tumor, which, with relatively insignificant local infiltration, may involve the cervical lymphatics. Carcinoma in leukoplakia usually begins as a localized induration, often around a fissure, or as a warty excrescence or a small ulcer. There is a 6–10% transformation rate of intraoral leukoplakia into SCC. Predictors of a higher risk of SCC development include older age; female gender; nonsmokers; large size; presence on the lateral or ventral tongue, floor of the mouth, or retromolar/soft palate complex; erythroleukoplakia; and a nonhomogeneous morphology.

The degree of epithelial atypia may be considered in staging the risk of developing malignancy. Aneuploid leukoplakia has a high rate of transformation into aggressive SCC, and the cancers derived from it are more likely to be lethal.

## Treatment

It must be remembered that cancer develops frequently on histologically dysplastic leukoplakia, and thus its complete removal should be the goal in each case—first by conservative measures, then by surgery or destruction, if necessary. The use of tobacco should be stopped and proper dental care obtained. Fulguration, simple excision, cryotherapy, PDT, and CO<sub>2</sub> laser ablation are effective methods of treatment. Medical therapies that have been the subject of randomized clinical trials may lead to temporary resolution of the lesions, but relapses and adverse effects are common, and there is no evidence that they prevent the transformation to malignancy.

### Leukoplakia with tylosis and esophageal carcinoma

Leukoplakia associated with tylosis and esophageal carcinoma is extremely rare but may occur.

### Epidermization of the lip

Relatively smooth leukokeratosis of the lower vermilion, blending evenly into the skin surface distally and having a steep, sharp, irregular proximal margin, may easily be mistaken clinically for precancerous leukoplakia. Histologically, it shows only hyperkeratosis, without parakeratosis or cellular atypia. A shallow shave excision suffices to cure it and to rule out precancerous leukoplakia; no fulguration is required.

### Erythroplakia

The term erythroplakia is applied to leukoplakia that has lost (or has not developed) the thick keratin layer that makes leukoplakia white; it is the usual pattern in mucocutaneous junctions. A focal red patch with no apparent cause should be suspected of being precancerous when found on the floor of the mouth, soft palate, or buccal mucosa or under the tongue (Fig. 34-15). Histologically, there is cellular atypia, pleomorphism, hyperchromatism, and increased mitotic figures. Carcinoma in situ or invasive carcinoma is found in 90% of lesions.

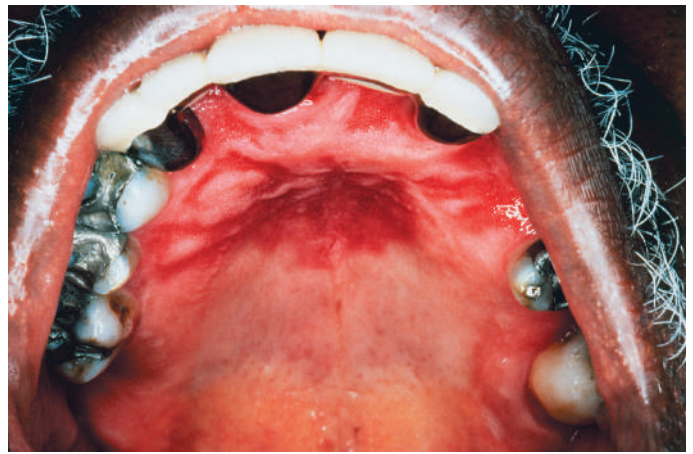

Fig. 34-15 Erythroplakia.

### Oral florid papillomatosis

Oral florid papillomatosis is a confluent papillomatosis covering the mucous membranes of the oral cavity. The distinctive picture is that of a white mass resembling a cauliflower, covering the tongue and extending on to the other portions of the mucous membranes, including the oropharynx, larynx, and trachea. Usually, there is no lymphadenopathy.

The course of the disease is progressive. Many lesions eventually in SCC, whereas others continue for many years, with the patient dying of some intercurrent disease. Oral florid papillomatosis should be regarded as a verrucous carcinoma, which has been defined as a distinctive, slowly growing, fungating tumor representing a well-differentiated SCC in which metastases occur very late or not at all. The histologic features are those of papillomatosis, acanthosis, and varying degrees of dysplasia of the epithelium, without disruption of the basement membrane. It is reasonable to expect the eventual development of epidermoid carcinoma in most patients. Esophageal involvement and keratotic papules of the extremities may occur. In the differential diagnosis, leukoplakia, proliferative verrucous leukoplakia, candidiasis, acanthosis nigricans, and condyloma acuminatum should be considered. The recommended treatment is surgical excision; however, it is often followed by recurrence and spread.

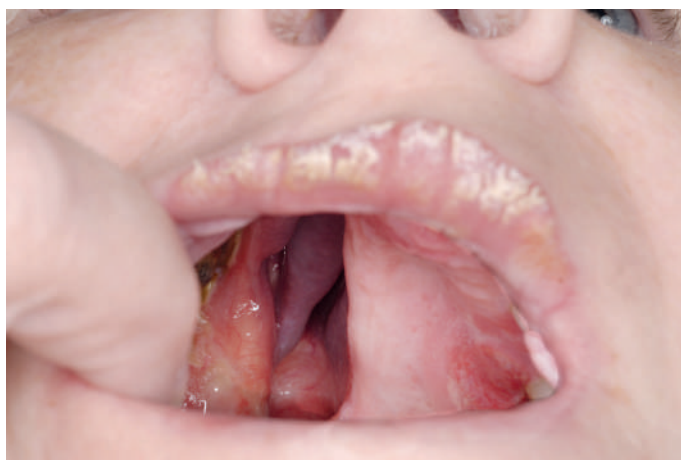### Proliferative verrucous leukoplakia

Proliferative verrucous leukoplakia is a slowly progressive condition that begins as multifocal sites of hyperplasia of the oral mucous membranes and proceeds to thicken and enlarge until SCC results (Fig. 34-16). Women outnumber men 4:1. Initially flat, usually white patches are present, but the lesions relentlessly become warty, exophytic masses. About 70% of patients develop SCC, most frequently of the palate and gingiva, with 40% of the total patients dying of it. There has been an irregular association with human papillomavirus (HPV)-16 infection, and risk factors for SCC of the oral cavity are usually not present. Treatment is difficult because of the multifocal nature of the lesions. Aggressive early surgical therapy is best. Many patients develop recurrence after only a short interval.

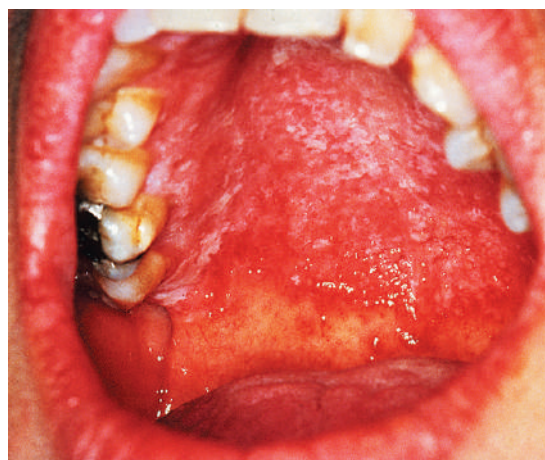### Squamous cell carcinoma

Squamous cell carcinoma is the most common oral malignancy and constitutes 2–3% of all new cancers. With almost 30,000

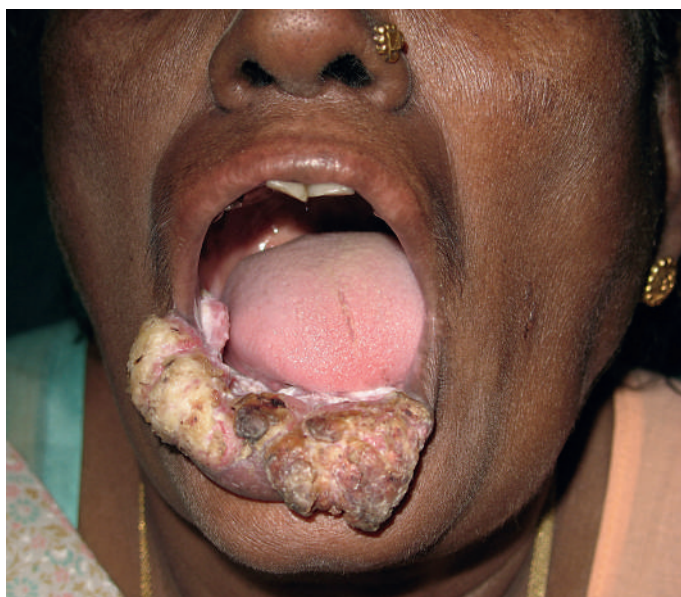



**Fig. 34-16** Proliferative verrucous leukoplakia; three sites of squamous cell carcinoma: lip and twice in palate.



**Fig. 34-18** Acquired dyskeratotic leukoplakia.



**Fig. 34-17** Oral squamous cell carcinoma. (Courtesy of Dr. Shyam Verma.)

yearly cases in the United States, SCC is the tenth most common malignancy. It occurs primarily in older men. The most frequent sites are the lower lip, tongue, soft palate, and floor of the mouth (Fig. 34-17). SCC of the lip develops from actinic damage, with 95% of the cases involving the lower lip. Intraoral lesions frequently develop from leukoplakia or erythroplakia, at sites of frequent irritation, or from long-standing mucosal inflammatory disease such as ulcerative lichen planus. About 20% of oral squamous cell cancers have an associated focus of leukoplakia; these tend to be diagnosed at a less advanced stage than those where no associated leukoplakia exists. Tobacco smoking, use of smokeless tobacco; areca, qat, or betel nut chewing; and reverse smoking are risk factors for the development of intraoral SCC. Alcohol has not been shown to be an independent risk factor. Many are positive for HPV-16 or HPV-18. The risk factors may also complicate xeroderma pigmentosa (tip of tongue), dyskeratosis congenita, dystrophic epidermolysis bullosa, erosive lichen planus, and oral submucous fibrosis. Unfortunately, the survival rate has remained at 50% for many years because disease is often discovered late, after it has metastasized to the cervical lymph nodes. Exfoliative cytology is a practical and accurate

aid to oral cancer screening. Surgical excision is the treatment of choice; the role of sentinel lymph node dissection and adjuvant chemotherapy and/or radiation are all controversial issues undergoing active study.

**Bagan JV, et al:** Malignant transformation of proliferative verrucous leukoplakia to oral squamous cell carcinoma. *Oral Oncol* 2011; 47:732–735.

**Brown JS, et al:** Systemic review of the current evidence in the use of postoperative radiotherapy for oral squamous cell carcinoma. *Br J Oral Maxillofac Surg* 2012; 59:481–489.

**Gillenwater AM, et al:** Proliferative verrucous leukoplakia: recognition and differentiation from conventional leukoplakia and mimics. *Head Neck* 2014; 36:1662–1668.

**Gouvea AF, et al:** High incidence of DNA ploidy abnormalities and increased Mcm2 expression may predict malignant change in oral proliferative verrucous leukoplakia. *Histopathology* 2013; 62(4):551–562.

**Govers TM, et al:** Sentinel node biopsy for squamous cell carcinoma of the oral cavity and oropharynx. *Oral Oncol* 2013; 49:726–732.

**Johnson NW, et al:** Squamous cell carcinoma and precursor lesions of the oral cavity. *Periodontology* 2000 2011; 57:19–37.

**Liu W, et al:** Oral cancer development in patients with leukoplakia. *PLoS One* 2012; 7(4):e34773.

**Lu YG, et al:** Treatment of oral florid papillomatosis with systemic administration of photodynamic therapy. *Photomed Laser Surg* 2010; 28(6):831–833.

**Kumar A, et al:** How should we manage oral leukoplakia? *Br J Oral Maxillofac Surg* 2013; 51:377–383.

**Mathew A, et al:** Prevalence and relationship of human papilloma virus type 16 and type 18 with oral squamous cell carcinoma and oral leukoplakia in fresh scrapings. *Indian J Med Sci* 2011; 65(5):212–221.

**Monroe MM, et al:** Management of the clinical node-negative neck in early-stage oral cavity squamous cell carcinoma. *Otolaryngol Clin North Am* 2012; 45:1181–1193.

**Parashar P, et al:** Proliferative verrucous leukoplakia. *J Evid Based Dent Pract* 2014; (Suppl):147–153.e1.

**Shaw RJ, et al:** Contemporary clinical management of oral squamous cell carcinoma. *Periodontology* 2000 2011; 57:89–101.

### Acquired dyskeratotic leukoplakia

James and Lupton reported a patient with acquired dyskeratotic leukoplakia that manifested as distinctive white plaques on the palate, gingivae, and lips (Fig. 34-18). There were similar lesions of the genitalia. Histologically, there was a unique finding of clusters of dyskeratotic cells in the prickle cell layer in all affected sites. Aggressive laser treatment was

followed by recurrence. Use of etretinate afforded some improvement, but the condition continued unabated more than 20 years.

**James WD, et al:** Acquired dyskeratotic leukoplakia. *Acta Dermatol* 1988; 124:117.

**Kim JH, et al:** Acquired dyskeratotic leukoplakia of the lip and conjunctiva. *Int J Dermatol* 2013; Dec 10. doi: 10.1111/ijd.12031. [Epub ahead of print.]

### White sponge nevus

The mouth, vagina, or rectum may be the site of this spongy, white overgrowth of the mucous membrane, with acanthosis, vacuolated prickle cells, and acidophilic condensations in the cytoplasm of keratinocytes, which electron microscopy has shown to be aggregated tonofilaments. The buccal mucosa is the most common site of involvement. There are no extramucosal lesions. Progression of the disorder generally stops at puberty. The disease is inherited as an autosomal dominant disorder. A mutation in the mucosal keratin pair K4 and K13 has been identified as the inherited defect. HPV-16 DNA has been present in some patients, the significance of which remains to be determined. Antibiotics, particularly tetracycline, may give significant improvement. A 0.25% aqueous preparation of tetracycline as a mouth rinse, 5 mL swished in the mouth for 1 min twice daily, has been successful.

**Benoit S, et al:** White sponge nevus. *Klin Padiatr* 2014; 226(6-7):375–376.

**Shimizu A, et al:** White sponge nevus caused by a missense mutation in the keratin 4 gene. *Eur J Dermatol* 2012; 22(4):571–572.

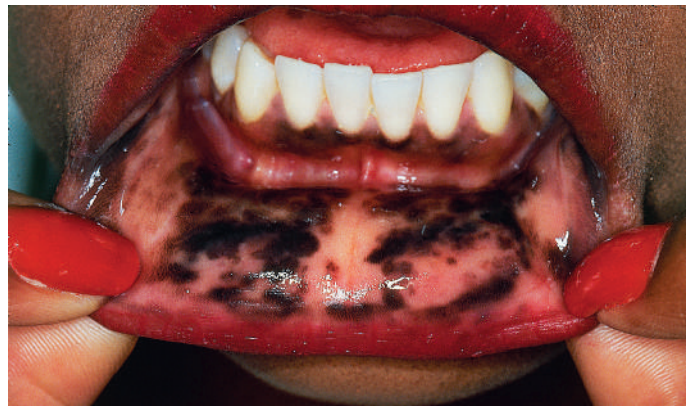**Songu M, et al:** White sponge nevus. *Pediatr Dermatol* 2012; 29(4):495–497.

### Melanocytic oral lesions

A wide variety of melanocytic lesions appear on the mucous membranes. Nevi of the oral mucosa in general are extremely uncommon. Among the melanocytic nevi of the cellular type, the intramucosal type occurs most frequently, with the compound nevus next and the junction nevus occurring only rarely. Ephelis, lentigo, blue nevus, and labial melanotic macules are other types of focal hyperpigmentation. Ephelides darken on sun exposure and are usually limited to the lower lip. The blue nevus has dendritic cells in the submucosa. Lentiginos show acanthosis of rete ridges on biopsy. Oral melanotic macules are solitary, sharply demarcated, flat, pigmented lesions that occur chiefly in young women, do not change on sun exposure, and show only acanthosis and basal-layer melanin on biopsy.

Oral melanoacanthoma is a simultaneous proliferation of keratinocytes and melanocytes. It is most frequently observed in young black patients (average age 23) on the buccal mucosa. It seems to be a reactive process, usually following trauma and resolving spontaneously in 40% of patients.

Melanoma occurs infrequently, mostly in older patients. It is recognized by being larger than the usual benign pigmented lesion and more irregular in shape, with a tendency to ulcerate and bleed. A peripheral areola of erythema and satellite pigmented spots may be present. There is a striking predilection for palatal (or less often gingival) involvement. The overall prognosis is poor (<5% survival at 5 years) because the lesions are usually deeply invasive by the time they are discovered. Whereas oral nevi are uncommon, biopsy of solitary pigmented oral lesions is indicated when the clinical diagnosis is uncertain. Biopsy of a pigmented tumor will occasionally reveal an SCC.



**Fig. 34-19** Oral melanosis.

**Alawi F:** Pigmented lesions of the oral cavity. *Dent Clin North Am* 2013; 57(4):699–710.

**Cardoso LB, et al:** Oral compound nevus. *Dermatol Online J* 2014; 20(2). pii.doi\_21542.

**Gondak RO, et al:** Oral pigmented lesions. *Med Oral Patol Oral Cir Bucal* 2012; 17(6):e919–e924.

**Gupta AA, et al:** Oral melanoacanthoma. *J Oral Maxillofac Pathol* 2012; 16(3):441–443.

**Mihajlovic M, et al:** Primary mucosal melanomas. *Int J Clin Exp Pathol* 2012; 5(8):739–753.

**Ojha J, et al:** Intraoral cellular blue nevus. *Cutis* 2007; 80:189.

**Shen ZY, et al:** Oral melanotic macule and primary oral malignant melanoma. *OOOOE* 2011; 112(1):e21–e25.

**Warszawik-Hendzel O, et al:** Melanoma of the oral cavity. *J Dermatol Case Rep* 2014; 8:60–66.

### Melanosis

Pigmentation of the oral cavity tends to occur most frequently in black persons. In other races, the darker the skin, the more mucosal pigmentation may be expected. Oral melanosis may occur with Albright syndrome, Peutz-Jeghers syndrome, Carney complex, Laugier-Hunziker disease, and Addison's disease, or rarely, as an idiopathic process with no associated disease.

James et al. reported a patient with inflammatory acquired oral hyperpigmentation that first occurred at age 30 with numerous distinct pigmented macules, similar to those seen in Peutz-Jeghers syndrome. However, the condition progressed rapidly to a diffuse oral hyperpigmentation (Fig. 34-19). This appeared to be caused by an undefined inflammation, and slow partial resolution occurred after several years of observation.

The differential diagnosis of oral hyperpigmentation should include the amalgam tattoo, a focal, brownish blue macule arising from fragments of dental silver or amalgam implanting into the gums (Fig. 34-20). Heavy-metal poisoning may also induce such lesions. Bismuth, lead, and cisplatin may produce a pigmented line along the gums near their margin. A multitude of drugs will cause pigmentation; the most common include amodiaquine, chloroquine, imatinib, oral contraceptives, phenothiazines, phenolphthalein, quinacrine, quinidine, thallium, nicotine (tobacco), and zidovudine.

**Alawi F:** Pigmented lesions of the oral cavity. *Dent Clin North Am* 2013; 57(4):699–710.

**James WD, et al:** Inflammatory acquired oral hyperpigmentation. *J Am Acad Dermatol* 1987; 16:220.

**Meleti M, et al:** Oral pigmented lesions of the oral mucosa and perioral tissues. *Oral Surg Oral Med Oral Pathol Oral Radiol Endod* 2008; 105:606.

**Yu YH, et al:** Oral and maxillofacial pathology case of the month. *Tex Dent J* 2012; 129(8):764–765.



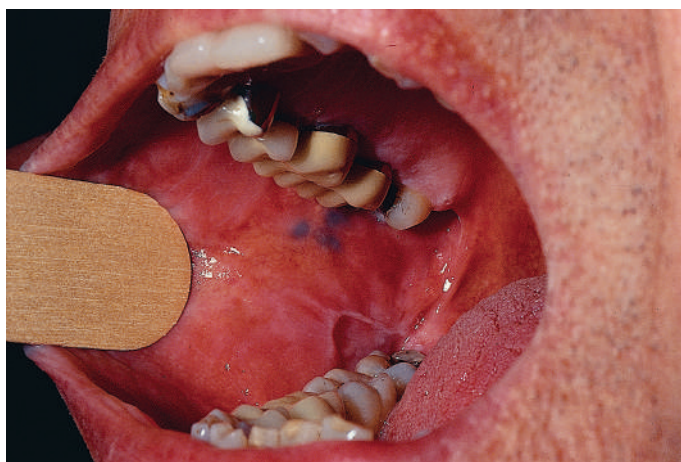


Fig. 34-20 Amalgam tattoo.

### Osseous choristoma of the tongue

Osseous choristoma of the tongue presents as a nodule on the dorsum of the tongue containing mature lamellar bone without osteoblastic or osteoclastic activity. This does not recur after simple excision.

**Goswamy M, et al:** Osseous choristoma of the periodontium. *J Indian Soc Periodontol* 2012; 16(1):120–122.

**Naik VR, et al:** Choristoma of the base of the tongue. *Indian J Pathol Microbiol* 2009; 52:86.

### Peripheral ameloblastoma

This is a neoplasm of the gingivae, which appears most often on the lower jaw. The mean age at onset is the early fifties and men outnumber women. Peripheral ameloblastoma presents as a growing, pink to red, sessile or pedunculated mass. Excision is followed by recurrence in 19% of the cases, but the lesion is benign. It can simulate basal cell carcinoma histologically.

**Bertossi D, et al:** Peripheral ameloblastoma of the upper gingiva. *J Clin Exp Dent* 2014; 6(2):e180–e184.

### TRUMPETER'S WART

Trumpeter's wart is a firm, fibrous, hyperkeratotic, pseudoepitheliomatous nodule on the upper lip of a trumpet player. A similar callus may grow on the lower lip of trombone players.

**Gambichler T, et al:** Skin conditions in instrumental musicians. *Contact Dermatitis* 2008; 58:217.

### EPULIS

The term epulis means any benign lesion situated on the gingiva. The majority of these are reactive processes that display varying degrees of fibrosis, inflammation, and vascular proliferation on biopsy. Giant cell epulis (peripheral giant cell granuloma) is a solitary, bluish red, 10–20 mm tumor occurring on the gingiva between or around deciduous bicuspids and incisors. Lesions may be induced by dental implants. Similar lesions may occur in the autosomal dominant inherited syndrome, cherubism. Histologically, epulides resemble giant cell tumor of the tendon sheath.

**Banthia R, et al:** Peripheral giant cell granuloma. *Gen Dent* 2013; 61(1):e12–e14.

**Roginsky VV, et al:** Familial cherubism. *Int J Oral Maxillofac Surg* 2009; 38(3):218–223.

**Yee J:** Congenital epulis in a newborn. *Minn Med* 2014; 97(5):39.

### Pyogenic granuloma

Pyogenic granuloma is an exuberant overgrowth of granulation tissue, frequently occurring in the oral cavity, most often involving the gingiva. It may also occur on the buccal mucosa, lips, tongue, or palate. It is a red to reddish purple, soft, nodular mass that bleeds easily and grows rapidly, but is usually not painful. When it develops during pregnancy, it is called pregnancy tumor or granuloma gravidarum. Surgical excision, pulsed dye, erbium:yttrium-aluminum-garnet (Er:YAG) or neodymium:YAG laser, and cryosurgery offer effective methods of treatment.

**Cardoso JA, et al:** Oral granuloma gravidarum. *J Appl Oral Sci* 2013; 21(3): 215–228.

**Kaya A, et al:** Oral pyogenic granuloma associated with a dental implant treated with an Er:YAG laser. *J Oral Implantol* 2013; Dec 18. [Epub ahead of print.]

**Kocaman G, et al:** The use of surgical Nd:YAG laser in an oral pyogenic granuloma. *J Cosmet Laser Ther* 2014; 16(4):197–200.

### GRANULOMA FISSURATUM

Granuloma fissuratum is a circumscribed, firm, whitish, fissured, fibrous granuloma occurring in the labioalveolar fold. The lesion is discoid, smooth, and slightly raised, about 1 cm in diameter. The growth is folded like a bent coin, so that the fissure in the bend is continuous on both sides with the labioalveolar sulcus. Symptoms are slight. It is an inflammatory fibrous hyperplasia that usually results from chronic irritation caused by poorly fitting dentures. In the dental literature, it is called epulis fissuratum, particularly when there is a deep cleft traversing the lesion. Treatment is by surgical extirpation, CO<sub>2</sub> laser ablation, or electrodesiccation after biopsy.

**Mohan RP, et al:** Epulis fissuratum. *BMJ Case Rep* 2013; Jul 17. pii: bcr20132000054.

### ANGINA BULLOSA HAEMORRHAGICA

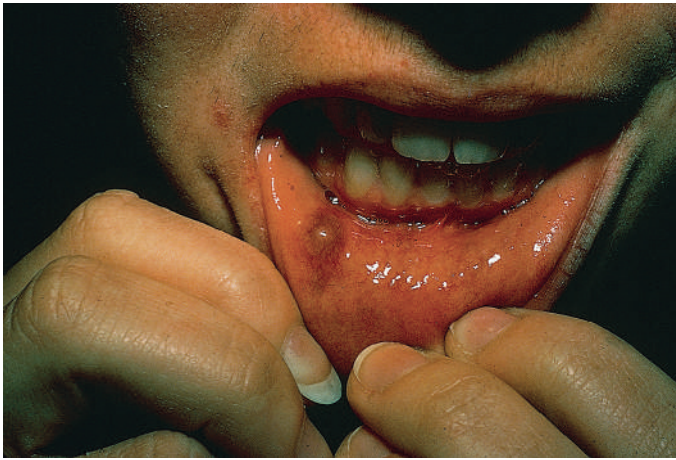The sudden appearance of one or more blood blisters of the oral mucosa characterizes angina bullosa haemorrhagica. There is no associated skin or systemic disease. The blisters may be recurrent, occur most often in the soft palate, and usually present in middle-age or elderly patients. No treatment is necessary.

**Singh D, et al:** Angina bullosa haemorrhagica. *BMJ Case Rep* 2013; Feb 8.

**Yayli S, et al:** Angina bullosa haemorrhagica. *J Dtsch Dermatol Ges* 2012; 6:436–437.

### MUCOCELE

The term mucoccele refers to a lesion resulting from trauma or obstruction of the minor salivary ducts. The most common type is the mucous extravasation phenomenon, which is usually seen inside the lower lip because it is caused by trauma from biting (Fig. 34-21). The inside of the upper lip and buccal mucosa are infrequently involved. It presents as a soft, rounded, translucent projection and usually has a bluish tint.



**Fig. 34-21** Mucocele.

The lesion varies from 2 to 10 mm in diameter. It is painless, fluctuant, and tense. Incision, or sometimes merely compression, releases sticky, straw-colored fluid (or bluish fluid if hemorrhage has occurred into it). Usually, the lesions are solitary; however, multiple superficial mucoceles have been reported to occur with graft-versus-host disease and lichenoid inflammation. In these patients, topical corticosteroids may help prevent recurrences.

The cause of mucocele is rupture of the mucous duct, with extravasation of sialomucin into the submucosa to produce cystic spaces with inflammation. Granulation tissue formation is followed by fibrosis. Excisional biopsy will document the diagnosis and eliminate the problem. Cryotherapy and laser ablation have also been reported to be successful.

There are mucous retention cysts in which true obstruction of the duct leads to an epithelial-lined cavity. These are seen more in the posterior portions of the oral mucosa. A ranula (from *Rana*, the frog genus) is a mucocele of the floor of the mouth.

Two other cysts may be present in the mouth. The parotid duct cyst occurs in musicians who use wind instruments; it develops opposite the upper second molar on the buccal mucosa. The dermoid cyst may occur on the floor of the mouth, especially in the sublingual area.

**More CB, et al:** Oral mucocele. *J Oral Maxillofac Pathol* 2014; 18(Suppl 1):S72–S77.

**Valerio RA, et al:** Mucocele and fibroma. *Braz Dent J* 2013; 24(5):537–541.

**Vieira EM, et al:** Unusual dermoid cyst in oral cavity. *Case Rep Pathol* 2014; 2014:389752.

### ACUTE NECROTIZING ULCERATIVE GINGIVOSTOMATITIS (TRENCH MOUTH, VINCENT'S DISEASE)

Acute necrotizing ulcerative gingivitis (ANUG) is characterized by a rapid onset of characteristic punched-out ulcerations appearing on the interdental papillae and marginal gingivae. A dirty-white pseudomembrane may cover the ulcerations. The lesions may spread rapidly and involve the buccal mucosa, lips, and tongue, as well as the tonsils, pharynx, and entire respiratory tract. The slightest pressure causes pain and bleeding. There is a characteristic foul, fetid odor that is always present. ANUG may lead to loss of attachment of the gingiva and alveolar bone (necrotizing ulcerative periodontitis).

Trench mouth begins in a nidus of necrotic tissue, which provides an anaerobic environment for the infection by fusospirochetal organisms (*Bacteroides fusiformis*) in association with *Borrelia vincentii* and other organisms. Poor dental hygiene,

smoking, poor nutrition, ingestion of methylenedioxymethamphetamine (ecstasy), and immunosuppression are predisposing factors. It may be seen as a component of the oral infections and inflammatory lesions that occur in immunocompromised HIV-infected patients.

Acute herpetic gingivostomatitis, or primary HSV infection, may be confused with ANUG. Young children are susceptible to this severe febrile stomatitis with lymphadenitis. It is not primarily gingival in location and does not cause necrosis of the interdental papillae. Noma is a form of fusospirillary gangrenous stomatitis occurring in children with low resistance and poor nutrition. The onset is often triggered by measles. At the onset, there is ulceration of the buccal mucosa; this rapidly assumes a gangrenous character and extends to involve the skin and bones, with resultant necrosis. It may end in the patient's death.

Treatment consists of thorough dental hygienic measures under the supervision of a dentist. Penicillin with debridement is the treatment of choice. Use of a 3% hydrogen peroxide mouthwash is also helpful.

**Atout RN, et al:** Managing patients with necrotizing ulcerative gingivitis. *J Can Dent Assoc* 2013; 79:d46.

**Feller L, et al:** Necrotizing periodontal diseases in HIV-seropositive subjects. *J Int Acad Periodontol* 2008; 10:10.

**Sangani I, et al:** Necrotizing ulcerative gingivitis and the orthodontic patient. *J Orthod* 2013; 40(1):77–80.

**Tonna JE, et al:** A case and review of noma. *PLoS Negl Trop Dis* 2010; 4(12):e869.

### ACATALASEMIA

Acatlasemia (Takahara's disease) is a rare disease in which the enzyme catalase is deficient in the liver, muscles, bone marrow, erythrocytes, and skin. There are several forms. The absence of catalase leads to progressive gangrene of the mouth, with recurrent ulcerations resulting from increased susceptibility to infection by anaerobic organisms.

Almost 60% of patients with acatalasemia develop alveolar ulcerations, beginning in childhood. The mild type of the disease is characterized by rapidly recurring ulcers. In the moderate type, alveolar gangrene develops, with atrophy and recession of the alveolar bone, so that the teeth fall out spontaneously. In the severe type, widespread destruction of the jaw occurs. After puberty, all lesions heal, even in individuals who have the severe type.

There is no gross difference in appearance between the blood of an acatalasemic patient and that of a normal individual, but when hydrogen peroxide is added to a sample of blood, acatalasemic blood immediately turns blackish brown, and the peroxide does not foam. Normal blood remains bright and causes the peroxide to foam exuberantly because of the presence of erythrocyte catalase.

Acatlasia is a rare peroxisomal disorder and is inherited as an autosomal recessive trait. Treatment consists of extraction of the diseased teeth and the use of antibiotics to control the harmful effects of the causative bacteria.

**Goth L, et al:** Inherited catalase deficiency. *Mutat Res* 2013; 753(2):147–154.

**Wang Q, et al:** Long-term follow-up evaluation of an acatalasemia boy with severe periodontitis. *Clin Chim Acta* 2014 Jun 10; 433:93–95.

### CYCLIC NEUTROPENIA

Cyclic, or periodic, neutropenia is characterized by a decrease of circulating neutrophils and dermatologic manifestations. At regular intervals (21 days), neutropenia and mouth ulcerations develop, usually accompanied by fever, malaise, and



arthralgia. Ulcerations of the lips, tongue, palate, gums, and buccal mucosa may be extensive. The ulcers are irregularly outlined and are covered by a grayish white necrotic slough. The anterior teeth may show a grayish brown discoloration. Premature alveolar bone loss and periodontitis occur. In addition, opportunistic cutaneous infections, such as abscesses, furuncles, noma, pyomyositis, and cellulitis, may develop during the neutropenic stage. Urticaria and erythema multiforme have been reported.

There is a cyclic depression of neutrophils occurring at intervals of 12–30 days (average 21 days) and lasting 5–8 days. The neutrophils in the peripheral blood regularly fall to low levels or completely disappear. Some cases have been associated with agammaglobulinemia. The cause of cyclic neutropenia is a germline mutation of the gene encoding neutrophil elastase (*ELANE*). This is thought to produce apoptosis of bone marrow progenitor cells. Both autosomal dominant disease and sporadic cases have this abnormality. Severe congenital neutropenia is caused by a mutation in the same gene but at a different site. The latter condition predisposes to the development of myelodysplasia and acute myelogenous leukemia, whereas cyclic neutropenia does not.

The differential diagnosis includes other periodic fever syndromes, such as the periodic fever, aphthous stomatitis, pharyngitis, and adenopathy (PFAPA) syndrome; Mediterranean fever; Hibernian fever and hyperimmunoglobulin D syndrome; TNF receptor-associated periodic syndrome (TRAPS); and pyogenic sterile arthritis, pyoderma gangrenosum, and acne (PAPA) syndrome. All share a predisposition to the development of aphthouslike oral ulcerations. PFAPA syndrome is defined clinically and is characterized by 4 days of high fevers (>40°C) that recur at regular intervals every 2–8 weeks, separated by well-being between episodes. Associated with fevers are aphthous stomatitis (70%), pharyngitis (72%), and cervical adenitis (88%). The disease is not familial, begins before 5 years of age, and responds to small doses of prednisone for 1–2 days. Tonsillectomy has been reported to cure it. *SPAG7* is a candidate gene for PFAPA. The autoinflammatory syndromes are discussed in detail in Chapter 7.

Use of recombinant human granulocyte colony-stimulating factor (G-CSF) has been successful in the treatment of cyclic neutropenia patients. If the potential side effects limit use of this therapy, cyclosporine has been reported to be effective as well. Administering antibiotics during infections seems to expedite recovery. Careful attention to oral hygiene, including plaque control, helps improve mouth lesions and reduces the risk of infections. Death may occur from pneumonia, sepsis, gangrenous pyoderma, or granulocytopenia.

**Bens S et al:** *SPAG7* is a candidate gene for the periodic fever, aphthous stomatitis, pharyngitis and adenopathy (PFAPA) syndrome. *Genes Immun* 2014; 15(3):190–194.

**Cush JJ:** Autoinflammatory syndromes. *Dermatol Clin* 2013; 31(3):471–480.

**Horwitz MS, et al:** *ELANE* mutations in cyclic and severe congenital neutropenia. *Hematol Oncol Clin North Am* 2013; 27:19–41.

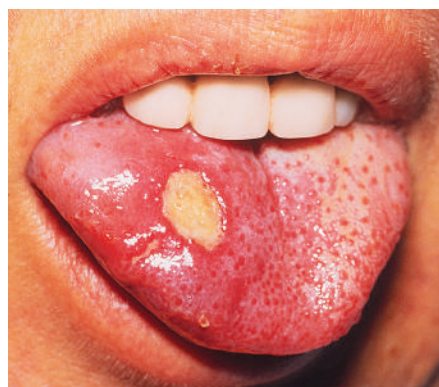**Marshall GS:** Prolonged and recurrent fevers in children. *J Infect* 2014; 68(Suppl 1):S83–S93.

**Mays JW, et al:** Oral manifestations of systemic autoimmune and inflammatory diseases. *J Evid Based Dent Pract* 2012; 12(3 Suppl):265–282.

**Tripathi SV, et al:** Autoinflammatory diseases in dermatology. *Dermatol Clin* 2013; 31(3):387–404.

## RECURRENT INTRAORAL HERPES SIMPLEX INFECTION

Recurrent intraoral infection with HSV is characterized by numerous small, discrete vesicles occurring in one or a few



**Fig. 34-22** Chronic herpes in patient receiving cancer chemotherapy.

clusters. The site of involvement is a key feature in suspecting the diagnosis. The keratinized or masticatory mucosa—the palate, gingiva, and tongue—is affected. The grouped vesicles rupture rapidly to form punctate erosions with a red base. Smears from the base prepared with Wright stain will show giant multinucleated epithelial cells. Immunofluorescent tests and viral cultures are also confirmatory.

The differential diagnosis of this uncommon manifestation of HSV includes oral herpes zoster, herpangina, and oral aphthosis. The latter two involve nonattached mucosa, whereas recurrent HSV involves mucosa fixed to bone. Differentiation from zoster is made on clinical grounds or by culture and immunofluorescent testing.

Chronic progressive ulcerative and nodular intraoral herpes are seen occasionally in HIV-infected patients or those with leukemia or neutropenia (Fig. 34-22). The presentation may mimic mucosal toxicity to chemotherapy. Solitary painful erosions of the tongue or attached mucosa should be tested for HSV in such patients. Additionally, herpetic geometric glossitis may occur, with linear longitudinal, cross-hatched, or branching fissures of the dorsal tongue, usually along the central area. This condition may be quite painful and may limit oral intake. Although the glossitis usually affects only immunocompromised patients, at least one immunocompetent patient has been affected.

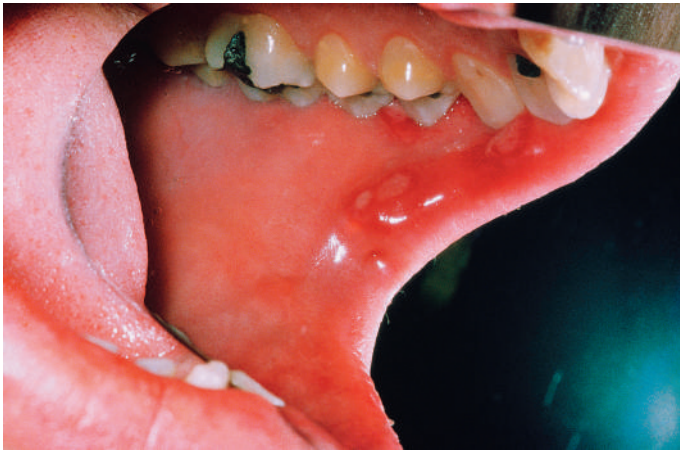
**Mirowski GW, et al:** Herpetic geometric glossitis in an immunocompetent patient with pneumonia. *J Am Acad Dermatol* 2009; 61:139.

**Westley S, et al:** Recurrent intra-oral herpes simplex 1 infection. *Dent Update* 2011; 38(6):368–370, 372–274.

## RECURRENT APHTHOUS STOMATITIS (CANKER SORES, APHTHOSIS)

### Clinical features

Aphthous stomatitis is a painful, recurrent disease of the oral mucous membrane. It begins as small, red, discrete, or grouped papules, which in a few hours become necrotizing ulcerations. They are small, round, shallow, white ulcers (aphthae), generally surrounded by a ring of hyperemia (Fig. 34-23). As a rule, they are tender; they may become so painful that they interfere with speech and mastication. They are mostly about 5 mm in diameter but may vary in size from 3 to 10 mm. When larger, they are called major aphthae. A third subcategory, herpeticiform aphthae, consists of small, 1–3 mm lesions grouped into a coalescing larger plaque, which may take 1–4 weeks to resolve. Usually, one to five lesions occur per attack; however, they may occur in any number. They are located in decreasing frequency on the buccal and labial mucosa, edges of the tongue, buccal and lingual sulci, and soft palate. There is a



**Fig. 34-23** Aphthous stomatitis.

marked predilection for the nonkeratinized mucosa (any not bound to underlying periosteum). This fact, and because they are rarely confluent, even when they occur as small crops of 1-mm or 2-mm lesions (herpetiform aphthae), help to distinguish them from the uncommon, recurrent intraoral HSV infection. Aphthae may also occur on the vagina, vulva, penis, anus, and even the conjunctiva. When they involve the oral and genital mucosa and number three or more, the term complex aphthosis is applied.

The lesions tend to involute in 1–2 weeks, but recurrences are common. These recurrences may be induced by trauma (e.g., self-biting, toothbrush injury, dental procedures), spicy foods, citrus, fresh pineapple, walnuts, allergy, emotional stress, or hormonal changes in women, as in menstruation, pregnancy, menarche, and menopause. A familial predisposition has also been described as familial epidemic aphthosis.

Recurrent aphthous stomatitis is the most common lesion of the oral mucosa, affecting 10–20% of the population. It typically starts in the second or third decade, and patients may experience recurrent bouts of lesions several times yearly for many decades. When present in neonates or young children, autoinflammatory syndromes should be considered. In PFAPA syndrome, the high fevers and associated findings occur with striking periodicity every 4 weeks, last 4–6 days, and resolve only to recur the following month. The children are otherwise well. One or two doses of prednisone (2 mg/kg) abort the attack, and tonsillectomy may cure it. Aphthous oral ulcerations may also be seen in the autoinflammatory syndromes, such as familial Mediterranean fever, TRAPS, hyperimmunoglobulinemia D and periodic fever, PAPA syndrome, and deficiency of the interleukin-1 receptor antagonist (DIRA) syndrome.

Ulcerations such as these may also be the presenting sign in Behçet syndrome, HIV infection, malabsorption syndromes, gluten-sensitive enteropathy, pernicious anemia, cyclic neutropenia, neutropenia, ulcerative colitis, and Crohn's disease. History, physical examination, complete blood count, and long-term follow-up documenting the recurrent course, in the absence of other symptoms, will secure the diagnosis. Some patients have aphthosis associated with low folate, vitamin B<sub>12</sub>, or iron levels, so testing should include this evaluation.

### Etiologic factors

Although individual patients often suspect that one of the factors just mentioned is responsible for precipitating recur-

rence of the lesions, investigators favor infectious or immunologic causation. The true cause is unknown.

Histologically, the lesion consists of a lymphocytic inflammatory infiltration with occasional plasma cells and eosinophils, which suggests delayed hypersensitivity.

### Diagnosis

Aphthous stomatitis must be differentiated from mucous patches of early syphilis, candidiasis, Vincent angina, the avitaminoses (particularly pellagra and scurvy), erythema multiforme, pemphigus, cicatricial pemphigoid, lichen planus, primary HSV infection of the mouth, recurrent labial herpes, and recurrent intraoral HSV infection.

### Treatment

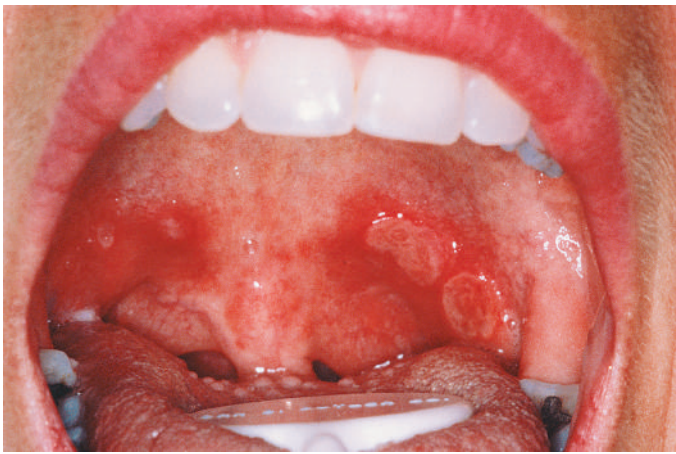No permanent cure is available for aphthosis. Several topical agents will lessen the pain. A mixture of equal parts of elixir of Benadryl and Maalox, held in the mouth for 5 min before meals, is soothing. Kaolin may also be added to the mixture. Lidocaine (Xylocaine Viscous) 2% solution, keeping 1 teaspoonful in the mouth for several minutes, is also helpful in allaying pain. Another useful topical anesthetic is dyclonine hydrochloride (Dyclone) 0.5% applied to the lesions. A large number of reasonably effective over-the-counter remedies are also available. Triggers, such as spicy foods, citrus, walnuts, pineapple, and other irritating substances, should be avoided.

Other measures may be used to shorten the course and induce healing of lesions. Chlorhexidine mouthwashes are used twice daily with any of the other treatments described. A mixture of equal parts of fluocinonide ointment and Orabase, applied to the ulcers three or four times daily, is effective in aiding the healing of existing ulcers; however, it does not prevent new ulcers. Some patients object to the thick, sticky texture of Orabase and prefer fluocinonide gel. Clobetasol ointment can also be very effective. Intralesional corticosteroids and short, 3-day or 4-day courses of oral corticosteroids may help, particularly for indolent or large lesions. Nonsteroidal alternatives include 5 mL of an oral suspension containing 250 mg of tetracycline; this is held in the mouth for 2 min and then swallowed. This is done four times daily for 1 week. Amlexanox 5% oral paste (Aphthasol) is a useful topical therapy both to induce healing and to relieve pain. Sucralfate suspension, alone or compounded with a topical corticosteroid, may be useful, as described in peptic ulcer disease and the ulcerations of Behçet's disease.

To try to prevent new lesions, known triggers for the individual patient should be avoided as much as possible. Colchicine at 0.6 mg/day for 1 week, then increasing to 1.2 or even 1.8 mg/day, is recommended. If this is ineffective or GI or other side effects limit dosage, dapsone may be added to colchicine or substituted for it. It is given in steadily increasing doses of 25 mg for 3 days, then 50 mg for 3 days, then 75 mg for 3 days, then 100 mg for 7 days. If the blood count is normal, no side effects are present, and the disease is not controlled, further increases to 125 or even 150 mg may be given. Thalidomide is another effective alternative, but caution regarding teratogenicity and neurotoxicity is necessary if this is considered. One method is thalidomide, 300 mg/day to start, 200 mg/day after 10 days, and 100 mg/day after 2 months. Relapses are treated with 100 mg/day for 12 days.

Several investigators have reported finding low folate, iron, or B<sub>12</sub> levels in about 20% of aphthosis patients investigated, but others do not see this with such high frequency. Still, it is worth investigating, since correction of the abnormality clears





**Fig. 34-24** Major aphthae.

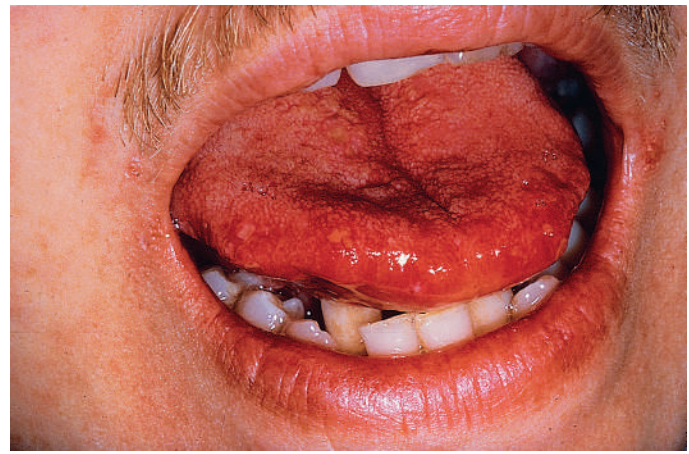or improves the condition in most patients who have an abnormality. Two studies document improvement with cyanocobalamin, even in those without abnormality.

- Belenguer-Guallar I, et al:** Treatment of recurrent aphthous stomatitis. *J Clin Exp Dent* 2014; 6(2):e168–e174.
- Brocklehurst P, et al:** Systemic interventions for recurrent aphthous stomatitis. *Cochrane Library* 2012, 9.
- Chattopadhyay A, et al:** Recurrent aphthous stomatitis. *Otolaryngol Clin North Am* 2011; 44(1):79–88.
- Chaven M, et al:** Recurrent aphthous stomatitis. *J Oral Pathol Med* 2012; 41:577–583.
- Femiano F, et al:** Guidelines for diagnosis and management of aphthous stomatitis. *Pediatr Infect Dis J* 2007; 26:728.
- Glucan E, et al:** Cyanocobalamin may be beneficial in the treatment of recurrent aphthous stomatitis even when vitamin B<sub>12</sub> levels are normal. *Am J Med Sci* 2008; 336:379.
- Hello M, et al:** Use of thalidomide for severe recurrent aphthous stomatitis. *Medicine (Baltimore)* 2010; 89:176.
- Krol P, et al:** PFAPA syndrome. *Clin Exp Rheumatol* 2013; 31(6):980–987.
- Lynde CB, et al:** Successful treatment of complex aphthosis with colchicine and dapsone. *Arch Dermatol* 2009; 145:273.
- Mays JW, et al:** Oral manifestations of systemic autoimmune and inflammatory diseases. *J Evid Based Dent Pract* 2012; 12(3 Suppl):265–282.
- Scully C, et al:** Oral mucosal disease: recurrent aphthous stomatitis. *Br J Oral Maxillofac Surg* 2008; 46:198.

## MAJOR APHTHOUS ULCER (PERIADENTIS MUCOSA NECROTICA RECURRENS)

In Sutton's disease, a major aphthous ulcer begins as a small, shotlike nodule on the inner lip, buccal mucosa, or tongue that breaks down into a painful, sharply circumscribed ulcer with a deeply punched-out and depressed crater. It may at times begin in the faucial pillars or oropharynx (Fig. 34-24). It may persist for 2–12 weeks before healing with a soft, pliable scar. There are seldom more than one to three lesions present at one time. However, remissions tend to be short, and new lesions may appear before old ones have healed. The term major aphthous ulcers has supplanted the unwieldy Latin name for this disease.

The cause is unknown, but evidence favors an immunologic or infectious etiology. These painful lesions are frequently present in immunocompromised HIV-infected patients who may experience similar lesions in the esophagus, rectum, anus, and genitals. Treatment is difficult, and the general measures discussed under recurrent aphthae should be employed. Intralesional or systemic corticosteroids in short courses may be effective and are often given. If recurrences are such that



**Fig. 34-25** Behçet's disease.

systemic steroids are prescribed for more than two or three short courses per year, alternative oral medications, such as colchicine, dapsone, or thalidomide, may be tried.

- Boldo A:** Major recurrent aphthous ulceration. *Conn Med* 2008; 72:271.
- Picciani BL, et al:** Regression of major recurrent aphthous ulcerations using a combination of intralesional corticosteroids and levamisole. *Clinics* 2010; 65(6):650–652.
- Shetty C, et al:** Current role of thalidomide in HIV-positive patients with recurrent aphthous ulcerations. *Gen Dent* 2007; 55:537.

## BEHÇET SYNDROME (OCULO-ORAL-GENITAL SYNDROME)

### Clinical features

Behçet syndrome consists of recurrent oral aphthous ulcerations that recur at least three times in one 12-month period in the presence of any two of the following: recurrent genital ulceration, retinal vasculitis or anterior or posterior uveitis, cutaneous lesions (erythema nodosum; pseudofolliculitis or papulopustular lesions; or acneiform nodules in postadolescent patients who are not receiving corticosteroid treatment), or a positive pathergy test.

Oral lesions occur on the lips, tongue (Fig. 34-25), buccal mucosa, soft and hard palate, tonsils, and even in the pharynx and nasal cavity. The lesions are single or multiple, 2–10 mm or larger in diameter, and sharply circumscribed, with a dirty-grayish base and a surrounding bright-red halo. Other patients show deep ulcerations that leave scars resembling those caused by Sutton major aphthous ulcers. The lesions are so painful that eating may be difficult. A foul mouth odor is in most cases very noticeable.

Genital lesions occur in men on the scrotum and penis or in the urethra and in women on the vulva, cervix, or vagina; lesions may be found in both genders on the genitocrural fold, anus, or perineum or in the rectum. These ulcerations are similar to those seen in the mouth. In addition, macules, papules, and folliculitis may develop on the scrotum. Lesions in women may lead to deep destruction of the vulva. Swellings of the regional nodes and fever may accompany oral and genital attacks.

The ocular lesions start with intense periorbital pain and photophobia. Retinal vasculitis is the most classic eye sign and the major cause of blindness. Conjunctivitis may be an early accompaniment of uveitis, and hypopyon may be a late one. Iridocyclitis is frequently seen. Both eyes are eventually involved. Untreated disease leads to blindness from optic atrophy, glaucoma, or cataracts.

Neurologic manifestations are mostly in the central nervous system and resemble most closely those of multiple sclerosis. Remissions and exacerbations are the rule. Thrombophlebitis occurs with some frequency. Thrombosis of the superior vena cava may also occur. Arthralgia is most often present in the form of polyarthritis.

Unfortunately, the international criteria include nonspecific common cutaneous lesions (pseudofolliculitis, papulopustular or acneiform lesions). Demonstration of either leukocytoclastic vasculitis or a neutrophilic vascular reaction on histologic examination of a lesion would make the cutaneous criteria more specific.

There is a relatively high prevalence of Behçet's disease in the Far East and Mediterranean countries, whereas in the United States and Western Europe, it is much less common. In large series of patients from areas of high prevalence, men with an age of onset in the thirties predominate. They tend to have a worse prognosis than women. Mangelsdorf et al. reported on 25 patients in a U.S. university dermatology referral practice; 22 were young women with a high frequency of mucocutaneous lesions and a low prevalence of ocular involvement. This may reflect referral bias or could indicate that the disease is less severe and female predominant in the United States.

On histologic examination, the early lesions show a leukocytoclastic vasculitis. There is perivascular infiltration, which is chiefly lymphocytic in older lesions, with endothelial proliferation that obliterates the lumen. The cause of Behçet's disease has been postulated to have an infectious, immunologic, and/or genetic basis, but the evidence is still inconclusive for any of these.

## Diagnosis

Usually, the disease starts with a single oral ulceration, which is followed by others. It may take years before additional lesions develop. Again, the diagnosis requires two classic signs in addition to oral ulcerations. In women, anal and genital lesions predominate, often with subsequent involvement of the eyes.

Behçet's disease must be differentiated from herpetic or aphthous stomatitis, pemphigus, oral cancer, and Stevens-Johnson syndrome (erythema multiforme). A skin puncture or pathergy test may be used to investigate patients further; however, it is not reliable in that it may be negative in otherwise well-documented cases. It is done by injecting 0.1 mL of normal saline solution into the skin or by simply pricking the skin with a sterile needle. A pustule appears at the site within 24 h. If results are negative, the test should be repeated at two to five points before results are accepted. Pathergy has been observed in patients with Behçet's disease, pyoderma gangrenosum, Sweet syndrome, and bowel-associated dermatosis-arthritis syndrome.

## Treatment

Usually, the ulcerations heal spontaneously. Chlorhexidine mouthwashes twice daily and toothpastes and restricted use

of the toothbrush should be prescribed when there are oral lesions. For treating the symptoms and healing of the aphthae, local treatments as described for aphthae may be used. Sucralfate suspension has been studied in Behçet oral and genital ulcers and was found to decrease pain and healing time. On the whole, the therapeutic problem of aphthosis is not the healing of the individual lesions but the prevention of new attacks. For that purpose, several options exist, none of which is optimal. Colchicine, 0.6 mg twice daily, may be started for 2 weeks. In the absence of response and GI side effects, the dose may be increased to three times daily. Although this may not totally alleviate the mucocutaneous lesions, it may decrease their recurrence rate by 50% or more. Dapsone may be substituted or added to this for improvement of response. The usual therapeutic final dose is 100 mg/day. Thalidomide has been found to be effective in many patients. One dosing method is thalidomide, 200 mg twice daily for 5 days, and 100 mg twice daily for 15–60 days. It has no effect on iridocyclitis. Again, long-term treatment will usually be complicated by neurotoxicity, and the teratogenicity of thalidomide is well known.

Methodretate, in a weekly oral dose of 7.5–20 mg, should be reserved for severe refractory cases, as should more aggressive systemic treatments such as systemic corticosteroids, azathioprine, chlorambucil, cyclosporine, interferon alfa, TNF antagonists, and cyclophosphamide.

The long-term outlook is for intermittent recurrent flares that may be lifelong. Blindness, neurologic impairment, and vascular thromboses are potential serious complications of Behçet syndrome.

**Alpsoy E, et al:** Mucocutaneous lesions of Behçet's disease. *Yonsei Med J* 2007; 48:573.

**Ambrose NL, et al:** Differential diagnosis and management of Behçet syndrome. *Nat Rev* 2013; 9:79–89.

**Arida A, et al:** Anti-TNF agents for Behçet's disease. *Semin Arthritis Rheum* 2011; 41(1):61–70.

**Hatemi G, et al:** Behçet's syndrome. *Rheum Dis Clin North Am* 2013; 39(2):245–261.

**Mat C, et al:** Behçet's syndrome. *Clin Dermatol* 2013; 31(4):352–361.

**Mazzocoli G, et al:** Behçet syndrome. *Clin Exp Med* 2014 Dec 2.

**Oh SH, et al:** Comparison of the clinical features of recurrent aphthous stomatitis and Behçet's disease. *Clin Exp Dermatol* 2009; 34:e208.

**Saleh Z, et al:** Update on the therapy of Behçet disease. *Ther Adv Chronic Dis* 2014; 5(3):112–134.



Bonus images for this chapter can be found online at

[expertconsult.inkling.com](http://expertconsult.inkling.com)

**eFig. 34-1** Melkersson-Rosenthal syndrome. (Courtesy of Dr. Curt Samlaska.)

**eFig. 34-2** Odontogenic sinus.

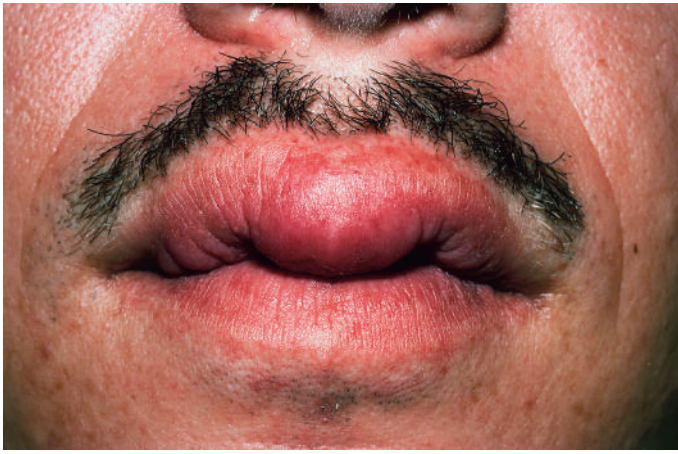**eFig. 34-3** Oral squamous cell carcinoma.

**eFig. 34-4** Benign oral leukoplakia.

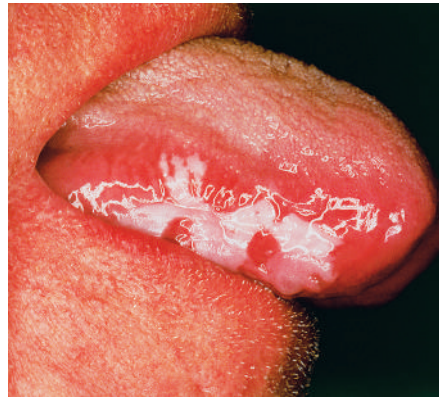**eFig. 34-5** Torus palatinus.

**eFig. 34-6** Behçet's disease.

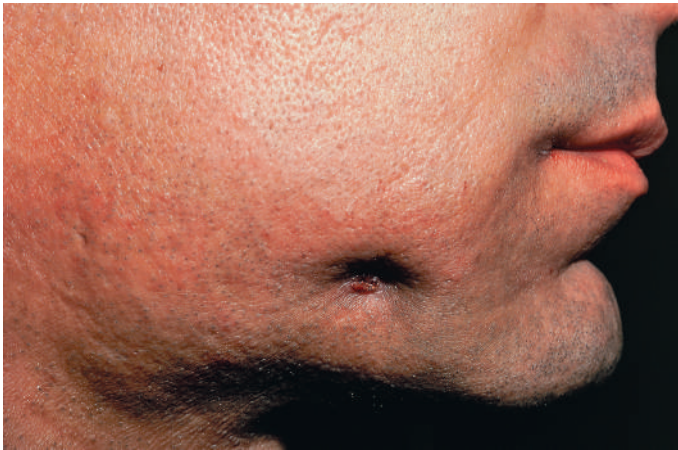



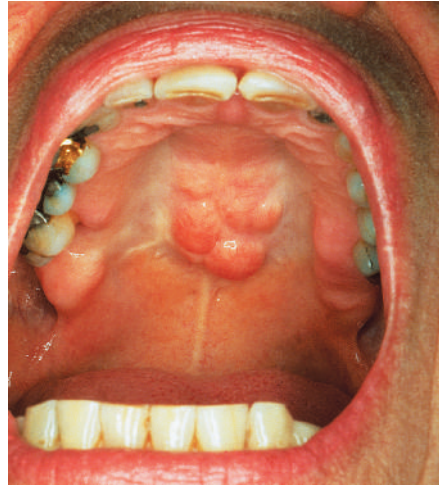
**eFig. 34-1** Melkersson-Rosenthal syndrome. (Courtesy of Dr. Curt Samlaska.)



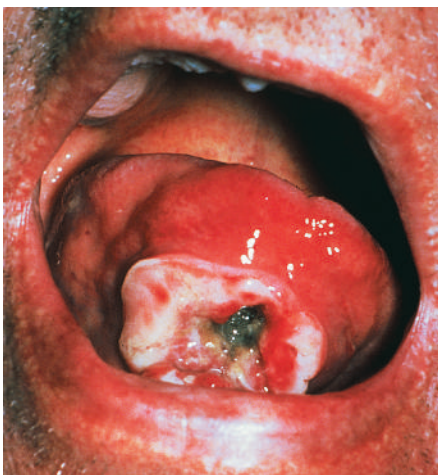**eFig. 34-4** Benign oral leukoplakia.



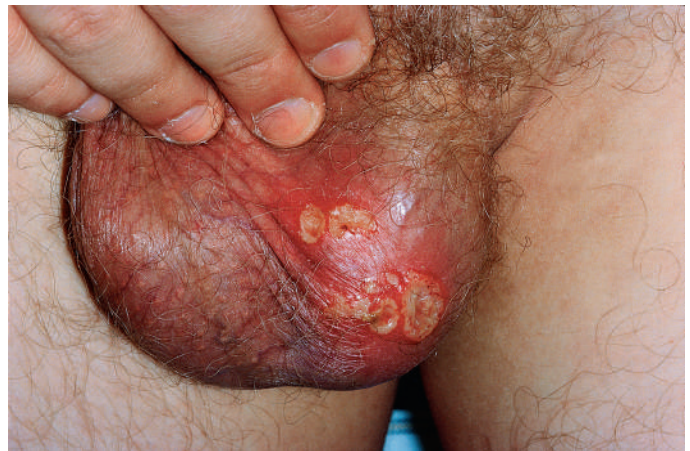**eFig. 34-2** Odontogenic sinus.



**eFig. 34-5** Torus palatinus.



**eFig. 34-3** Oral squamous cell carcinoma.



**eFig. 34-6** Behçet's disease.



## Cutaneous Vascular Diseases

# 35

### RAYNAUD PHENOMENON AND RAYNAUD DISEASE

Raynaud phenomenon is characterized by episodic, recurrent vasospasm of the fingers and toes resulting in white, blue, and red discoloration provoked by cold or stress. When it occurs in the presence of an associated disease, usually collagen vascular disease and often systemic sclerosis/scleroderma, it is called secondary Raynaud phenomenon. Raynaud disease (or primary Raynaud disease) occurs in the absence of associated illness. Although no significant structural changes occur in primary Raynaud disease, in secondary Raynaud phenomenon, especially when associated with connective tissue disease, sustained and recurrent vasospasm may lead to vessel wall damage.

In a series of 165 patients with Raynaud phenomenon, 51 had primary Raynaud disease. A defined connective tissue disease was present in about one third of the remaining patients, but 54 had undefined connective tissue disease (35 with positive antinuclear antibody [ANA] titer). In another study of 142 patients with idiopathic Raynaud phenomenon followed for more than 10 years, 14% progressed to a definite connective tissue disease. The initial presence of ANAs, thickening of fingers, older age at onset, and female gender were predictors of connective tissue disease. In a larger study of 3035 patients with primary Raynaud phenomenon, age of onset after 40 and progressively worsening Raynaud attacks were predictive of eventual diagnosis of a connective tissue disease (and reclassification as secondary Raynaud phenomenon), a development that occurred in 37.2% of patients after a mean of 4.8 years of follow-up. Sequential nailfold capillary microscopy and autoantibody determinations can predict development of systemic sclerosis in those with Raynaud phenomenon. The absence of nailfold capillaroscopic findings, conversely, predicts the presence of primary Raynaud disease (no associated systemic illness). Laser Doppler perfusion imaging may enhance the evaluation of vascular damage from Raynaud disease. Technetium digital blood flow scintigraphy and skin temperature measurement of the fingers and toes by digital thermography may aid in the early diagnosis of Raynaud phenomenon of either the primary or secondary type.

Many of the studies on pathogenesis and therapy in Raynaud phenomenon are conducted on patients with systemic sclerosis/scleroderma, so it may not be possible to translate these findings to patients with primary Raynaud disease. Apparently, however, cold exposure is a major trigger of vasospasm in all Raynaud patients. The exaggerated sympathetic response to cold may be caused by both excessive vasoconstrictor tone and a weak systemic vasodilation process, centrally mediated at least in part. The abnormal sympathetic response may also explain why some patients say that "stress" triggers Raynaud attacks. High homocysteine levels have been detected in patients with both primary and secondary Raynaud phenomenon. Patients with systemic sclerosis and Raynaud

disease have elevated levels of endothelin 1 (ET-1), which correlates with both nailfold capillaroscopic findings and more advanced disease.

### Secondary Raynaud phenomenon

Raynaud phenomenon is produced by an intermittent constriction of the small digital arteries and arterioles. The digits have sequential pallor, cyanosis, and rubor. The involved parts are affected by ischemic paroxysms, which cause them to become pale, cold to the touch, and numb. The phenomenon is more frequently observed in cold weather. When exposed to cold, the digits become white (ischemic), then blue (cyanotic), and finally red (hyperemic). Over time, the parts may fail to regain their normal circulation between attacks and become persistently cyanotic and painful. If this phenomenon persists over a long period, punctate superficial necrosis of the fingertips develops; later, even gangrene may occur.

Secondary Raynaud phenomenon occurs most frequently in young to middle-age women. It occurs with scleroderma, dermatomyositis, lupus erythematosus (LE, particularly those with anti-Sm and anti-RNP antibodies), mixed connective tissue disease, Sjögren syndrome, rheumatoid arthritis, and paroxysmal hemoglobinuria. Scleroderma was the underlying diagnosis in more than half of patients in one series. Occlusive arterial diseases, such as embolism, thromboangiitis obliterans, arteriosclerosis obliterans, and large-vessel vasculitis (Takayasu arteritis), may be present. In addition, various diseases of the nervous system, including cervical rib, scalenus anticus syndrome, and complex regional pain syndrome (reflex sympathetic dystrophy), may produce the disorder. Physical trauma, such as hand-transmitted vibration, as occurs with pneumatic hammer operation, can induce a syndrome identical to Raynaud and has been termed "vibration white finger" or "hand-arm vibration syndrome." Pianists and typists may also develop this phenomenon. Raynaud phenomenon is a well-recognized complication following cold injury, especially frostbite. Pharmacologic agents, such as bleomycin, cisplatin-based chemotherapy, ergot,  $\beta$ -adrenergic blockers (including eye drops), cyclosporine, interferon (IFN)- $\alpha$  and IFN- $\beta$ , vinyl polychloride exposure, and cocaine, may also be the cause. The clumping of red blood cells is believed to be responsible for the induction of Raynaud phenomenon, with high titers of circulating cold agglutinins. It may occur in cryoglobulinemia and polycythemia vera. Patients with cancer may develop Raynaud as a paraneoplastic phenomenon. Endocrine disorders, such as acromegaly, pheochromocytoma, carcinoid, and hypothyroidism, may present with or be associated with Raynaud phenomenon. Raynaud of the nipple is a variant of Raynaud disease that is difficult to diagnose. It presents with severe pain during lactation and must be distinguished from nipple candidiasis and eczema. Patients report the onset of symptoms during pregnancy and, when asked,



will say that the symptoms are triggered by cold and accompanied by biphasic or triphasic color changes of the nipple. Nifedipine can be highly effective in this condition and is safe for use during lactation; minimal drug is found in the breast milk.

Simple tests and physical examination will generally distinguish Raynaud disease from secondary Raynaud phenomenon. Sclerodactyly, digital pitted scars, puffy fingers with telangiectasias, positive ANA, subcutaneous calcifications, basilar lung fibrosis, and changes on nailfold capillary microscopy (avascular “skip” areas with irregularly dilated capillary loops) are signs of connective tissue disease.

### Raynaud disease (primary Raynaud disease)

Raynaud disease is a primary disorder of cold sensitivity primarily seen in young women. The intermittent attacks of pallor, cyanosis, hyperemia, and numbness of the fingers are identical to those in secondary Raynaud phenomenon (Fig. 35-1). The disease is usually bilateral, and gangrene occurs in less than 1% of cases.

The diagnosis requires the absence of the diseases enumerated under secondary Raynaud phenomenon. An international panel proposed the following consensus criteria for differentiation of Raynaud disease from secondary Raynaud phenomenon: normal capillaroscopy; absence of physical findings suggestive of secondary causes, such as sclerodactyly, calcinosis, and ulcerations; no history of existing connective tissue disease; and negative or low-titer ANA (e.g., 1:40). Although some suggest that Raynaud disease should be present for 2 years before being classified as a primary process, it may take as long as 11 years for some systemic disorders to manifest. Overall, fewer than half of patients presenting with Raynaud symptoms will prove to have a connective tissue disease. The prognosis is good for patients with primary Raynaud disease.

### Treatment

Treatments have often been studied but only in patients with secondary Raynaud phenomenon and digital ulceration associated with connective tissue disease, so not all treatments can be assumed to be effective in primary Raynaud disease or Raynaud secondary to other causes. If an underlying cause is found, treatment of the associated condition will often lead to improvement of Raynaud phenomenon. In both primary and secondary Raynaud, exposure to cold should be avoided. This includes avoidance of exposure to cold not only of the extremities but also of other parts of the body, since vasospasm may be induced by reduction of core body temperature, and Raynaud attack of atypical sites, such as the tongue, may

occur. Warm gloves should be worn whenever possible. Trauma to the fingertips should be avoided. Smoking is absolutely contraindicated. A Raynaud attack may be broken at times by swinging the affected arm in a wide circle from the shoulder—the “windmill” maneuver. The use of standard nitroglycerin paste has had minimal efficacy and can produce systemic side effects. A new form of topical nitroglycerin, MQX-503, significantly improved skin blood flow without serious adverse events in a recent randomized controlled trial (RCT). Alternative treatments, including ginkgo and other herbal medications, have limited efficacy compared with the standard treatments and cannot be recommended for patients with significantly symptomatic disease.

Calcium channel blockers are the first-line therapy used in Raynaud disease because of their efficacy and low side effect profile. Prolonged-release amlodipine or nifedipine is usually recommended. Some studies indicate that up to two thirds of treated patients will respond favorably. However, a Cochrane review of RCTs of calcium channel blockers for primary Raynaud disease concluded their benefit was minimal, translating to 1.72 fewer attacks per week compared with placebo. Sildenafil and other phosphodiesterase-5 inhibitors are moderately effective in reducing Raynaud severity score, as well as the frequency and duration of Raynaud episodes, and may improve digital ulcer healing. These have become the second-line agents of choice. The angiotensin receptor antagonist losartan reduced the frequency and severity of attacks to a greater extent than nifedipine in an RCT. Conversely, angiotensin-converting enzyme (ACE) inhibitors failed to show benefit in an RCT and are therefore not recommended. Data on selective serotonin reuptake inhibitors (fluoxetine or ketanserin) are mixed, but SSRIs may be useful in refractory cases or when other agents are not tolerated. Intravenous biweekly *N*-acetylcysteine was effective in reducing the number of attacks in an observational study, relatively free of side effects. The use of statins, specifically atorvastatin, in patients with Raynaud caused by systemic sclerosis/scleroderma was associated with a reduction in Raynaud-associated symptoms, possibly through the vasoprotective actions of statins. Statin administration was associated with reduced circulating markers of vascular injury, which are usually elevated in scleroderma patients. Bosentan, an endothelin receptor (ETA and ETB) antagonist, significantly reduces the frequency of Raynaud attacks and reduces new digital ulcers. Iloprost, a prostaglandin analog, has substantial efficacy in scleroderma-associated Raynaud disease and digital ulceration, but it is only slightly better than nifedipine and significantly more expensive. Oral prostaglandins appear to lack similar efficacy, except perhaps at high doses.

In cases refractory to these medical treatments, surgical modalities can be considered. If single digits are involved, botulinum toxin injections in the palm around each involved neurovascular bundle may lead to dramatic and at times immediate pain reduction. Ulcerations of the affected digits heal after the injections. The duration of response is often months to years, and injections can be repeated with similar efficacy. Fat grafting or fat transfer to the hand has also been reported effective in a pilot study. Local digital sympathectomy can be effective and avoids amputation of chronically ulcerated digits. Cervical sympathectomy and endoscopic thoracic sympathectomy may give initial relief, but Raynaud symptoms often recur after 12 to 18 months. However, despite the return of symptoms, digital ulceration is greatly reduced. Compensatory hyperhidrosis is a common complication of thoracic sympathectomy.

**Bank J, et al:** Fat grafting to the hand in patients with Raynaud phenomenon: a novel therapeutic modality. *Plast Reconstr Surg* 2014; 133(5):1109–1118.

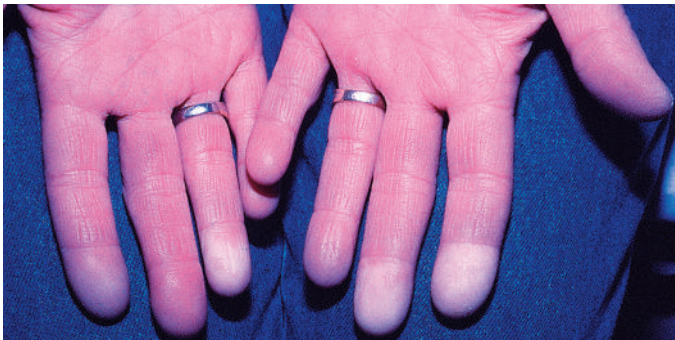

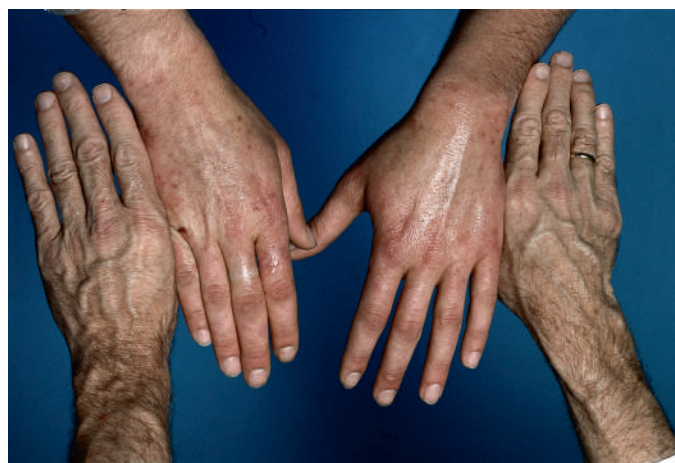Fig. 35-1 Raynaud disease.

- Barrett ME, et al:** Raynaud phenomenon of the nipple in breastfeeding mothers: an underdiagnosed cause of nipple pain. *JAMA Dermatol* 2013; 149(3):300–306.
- Blagojevic J, Matucci-Cerinic M:** Are statins useful for treating vascular involvement in systemic sclerosis? *Nat Clin Pract Rheumatol* 2009; 5:70.
- Bovenzi M:** A longitudinal study of vibration white finger, cold response of digital arteries, and measure of daily vibration exposure. *Int Arch Occup Environ Health* 2009; 83(3):259–272.
- Caglayan E, et al:** Vardenafil for the treatment of Raynaud phenomenon: a randomized, double-blind, placebo-controlled crossover study. *Arch Intern Med* 2012; 172(15):1182–1184.
- Cohen JC, et al:** Raynaud's phenomenon of the tongue. *J Rheumatol* 2013; 40(3):336.
- Coveliers HM, et al:** Thoracic sympathectomy for digital ischemia: a summary of evidence. *J Vasc Surg* 2011; 54:273.
- Cutolo M, et al:** Long-term treatment with endothelin receptor antagonist bosentan and iloprost improves fingertip blood perfusion in systemic sclerosis. *J Rheumatol* 2014; 41(5):881–886.
- De Angelis R, et al:** Raynaud's phenomenon: clinical spectrum of 118 patients. *Clin Rheumatol* 2003; 22:279.
- Ennis H, et al:** Calcium channel blockers for primary Raynaud's phenomenon. *Cochrane Database Syst Rev* 2014; 1:CD002069.
- Funauchi M, et al:** Effects of bosentan on the skin lesions: an observational study from a single center in Japan. *Rheumatol Int* 2009; 29:769.
- Gargh K, et al:** A retrospective clinical analysis of pharmacological modalities used for symptomatic relief of Raynaud's phenomenon in children treated in a UK paediatric rheumatology centre. *Rheumatology (Oxford)* 2010; 49(1):193–194.
- Gliddon AE, et al:** Prevention of vascular damage in scleroderma and autoimmune Raynaud's phenomenon: a multi-center, randomized, double-blind, placebo-controlled trial of the angiotensin-converting enzyme inhibitor quinapril. *Arthritis Rheum* 2007; 56:3837.
- Goundry B, et al:** Diagnosis and management of Raynaud's phenomenon. *BMJ* 2012; 344:e289.
- Herrick AL:** Modified-release sildenafil reduces Raynaud's phenomenon attack frequency in limited cutaneous systemic sclerosis. *Arthritis Rheum* 2011; 63:775–782.
- Hummers LK, et al:** A multi-centre, blinded, randomised, placebo-controlled, laboratory-based study of MQX-503, a novel topical gel formulation of nitroglycerine, in patients with Raynaud phenomenon. *Ann Rheum Dis* 2013; 72(12):1962–1967.
- Jenkins SN, et al:** A pilot study evaluating the efficacy of botulinum toxin A in the treatment of Raynaud phenomenon. *J Am Acad Dermatol* 2013; 69(5):834–835.
- Koenig M, et al:** Autoantibodies and microvascular damage are independent predictive factors for the progression of Raynaud's phenomenon to systemic sclerosis. *Arthritis Rheum* 2008; 58:3902.
- Kowal-Bielecka O, et al:** EULAR recommendations for the treatment of systemic sclerosis: a report from the EULAR Scleroderma Trials and Research group (EUSTAR). *Ann Rheum Dis* 2009; 68:620–628.
- Kuwana M, et al:** Long-term beneficial effects of statins on vascular manifestations in patients with systemic sclerosis. *Mod Rheumatol* 2009; 19:530.
- Kwon SR, et al:** Diagnosis of Raynaud's phenomenon by (99m) Tc-hydroxymethylene diphosphonate digital blood flow scintigraphy after one-hand chilling. *J Rheumatol* 2009; 36:1663.
- Lambova SN, Muller-Ladner U:** The role of capillaroscopy in differentiation of primary and secondary Raynaud's phenomenon in rheumatic diseases: a review of the literature and two case reports. *Rheumatol Int* 2009; 29:1263.
- Lazzerini PE, et al:** Homocysteine and Raynaud's phenomenon: a review. *Autoimmun Rev* 2010; 9(3):181–187.
- Lim MJ, et al:** Digital thermography of the fingers and toes in Raynaud's phenomenon. *J Korean Med Sci* 2014; 29(4):502–506.
- Maverakis E, et al:** International consensus criteria for the diagnosis of Raynaud's phenomenon. *J Autoimmun* 2014; 48/49:60–65.
- Mohokum M, et al:** The association of Raynaud's syndrome with cisplatin-based chemotherapy: a meta-analysis. *Eur J Intern Med* 2012; 23(7):594–598.
- Mondelli M, et al:** Sympathetic skin response in primary Raynaud's phenomenon. *Clin Auton Res* 2009; 19:355.
- Nagy Z, et al:** Nailfold digital capillaroscopy in 447 patients with connective tissue disease and Raynaud's disease. *J Eur Acad Dermatol Venereol* 2004; 18:62.
- Neumeister MW, et al:** Botox therapy for ischemic digits. *Plast Reconstr Surg* 2009; 124:191.
- Pavlov-Dolijanovic S, et al:** Late appearance and exacerbation of primary Raynaud's phenomenon attacks can predict future development of connective tissue disease: a retrospective chart review of 3,035 patients. *Rheumatol Int* 2013; 33(4):921–926.
- Pope J, et al:** Iloprost and cisaprost for Raynaud's phenomenon in progressive systemic sclerosis. *Cochrane Database Syst Rev* 2000; (2):CD000953.
- Prete M, et al:** Raynaud's phenomenon: from molecular pathogenesis to therapy. *Autoimmun Rev* 2014; 13(6):655–667.
- Rosato E, et al:** Laser Doppler perfusion imaging is useful in the study of Raynaud's phenomenon and improves the capillaroscopic diagnosis. *J Rheumatol* 2009; 36:2257.
- Salem KM, et al:** Analysis of rewarming curves in Raynaud's phenomenon of various aetiologies. *J Hand Surg Eur* 2009; 34:621.
- Schiopu E, et al:** Randomized placebo-controlled crossover trial of tadalafil in Raynaud's phenomenon secondary to systemic sclerosis. *J Rheumatol* 2009; 36:2264.
- Stewart M, Morling JR:** Oral vasodilators for primary Raynaud's phenomenon. *Cochrane Database Syst Rev* 2012; 7:CD006687.
- Sunderkotter C, et al:** Comparison of patients with and without digital ulcers in systemic sclerosis: detection of possible risk factors. *Br J Dermatol* 2009; 160:835.

## ERYTHROMELALGIA

Also called erythermalgia and acromelalgia, erythromelalgia has a population-based incidence of 1.3 per 100,000 per year: 2.0 per 100,000 in women and 0.6 per 100,000 in men. Erythromelalgia is characterized by paroxysmal vasodilation of the feet, with burning, localized pain, redness, and high skin temperature. Infrequently, the hands (Fig. 35-2), face, and ears may be involved. The burning paroxysms may last from a few minutes to several days and are usually triggered by an increase in environmental temperature or by exercise. The average patient has 1–2 attacks per week, but in some patients, the attacks are much more frequent. Cooling and limb elevation can reduce the symptoms, but often relief can only be obtained by immersing the burning feet in ice water. More than 20% of patients will have evidence of cold injury, and more than 1% will have gangrene or undergo amputation. Quality of life is severely impacted by the condition.

Erythromelalgia can be considered primary, secondary, or familial. For treatment purposes, secondary cases of erythromelalgia should be carefully divided into those associated



**Fig. 35-2** Erythromelalgia of the hands; normal hands lateral to the patient's hands.



with myeloproliferative diseases, often with elevated platelet counts, and other disorders. Myeloproliferative diseases associated with erythromelalgia include polycythemia vera, thrombotic thrombocytopenic purpura (TTP), and various forms of thrombocytopenia. Administration of romiplostim, a thrombopoiesis-stimulating protein, has resulted in erythromelalgia. Low-dose aspirin is effective therapy for erythromelalgia associated with platelet abnormalities. If this fails, other methods to reduce the platelet count, such as administration of hydroxyurea, should be considered.

Acquired erythromelalgia has been reported secondary to topical exposure to isopropyl alcohol and after mushroom poisoning with *Clitocybe acromelalga* and *Clitocybe amoenolens*. Medications that have induced erythromelalgia include calcium channel blockers (both nifedipine and verapamil), ergot derivatives such as bromocriptine and pergolide, and cyclosporine. There may be a long period of treatment (years) with these agents before the appearance of the erythromelalgia. Stopping the medication usually leads to improvement of symptoms within weeks.

In the vast majority of cases seen by dermatologists, erythromelalgia is probably a neurologic disorder. It can be seen in various neurologic conditions or diseases associated with neurologic sequelae, such as peripheral neuropathy, myelitis, multiple sclerosis, autoimmune small-fiber axonopathy, or diabetes mellitus. Erythromelalgia is sometimes associated with Raynaud phenomenon; both are disorders of abnormal neurovascular function. In many patients, no associated neurologic disease may be detected by routine neurologic examination, but careful neurologic testing will reveal evidence of a small-fiber neuropathy in the majority of such cases.

Inherited, familial, or hereditary erythromelalgia usually has its onset in childhood or adolescence (early or late onset). Familial cases have an autosomal dominant inheritance pattern. Familial erythromelalgia is now known to be an "inherited neuronal ion channelopathy." The mutation is in the gene *SCN9A*, which encodes a peripheral sodium channel  $Na_v1.7$ . This is a mainly peripheral sodium channel with robust expression in dorsal root ganglion neurons and sympathetic ganglion neurons, especially those with nociceptive function. This sodium channel acts as a "threshold" channel and sets the gain in nociceptors. Many mutations in the affected gene have been mapped. Gene mutations causing erythromelalgia occur in areas that affect the structure of the actual channel by substituting amino acids in this critical location. The mutations causing erythromelalgia are gain-of-function mutations that lead to a hyperpolarizing shift of activation, allowing  $Na_v1.7$  to open at lower potentials, enhancing excitability. Furthermore, high temperatures have been shown in vitro to cause a significant depolarizing shift in the mutant channels.

The amount of gain of function correlates with age of onset of the disease; more significant mutations have earlier onset. The nature of the mutation also affects the binding of medications to the channel, so various mutations may have different responses to the same medication, depending on whether that mutation allows the drug to bind to the channel. Other gain-of-function mutations in *SCN9A* cause "paroxysmal extreme pain disorder" (formerly called familial rectal pain syndrome). This disorder has prominent autonomic manifestations that include skin flushing, sometimes with only half the face turning red (harlequin color change), syncope with bradycardia, and severe burning pain, most often rectal, ocular, or mandibular. One mutation in  $Na_v1.7$  produced a clinical syndrome with features of both erythromelalgia and paroxysmal extreme pain disorder. Autosomal recessive nonsense mutations that cause loss of function of the  $Na_v1.7$  channel result in the inability to sense pain. These patients are otherwise neurologically normal.

Interestingly, the association of secondary erythromelalgia with autoimmune conditions has led to the supposition that autoantibodies to the  $Na_v1.7$  sodium channel may be present. Immunomodulatory therapy such as intravenous immune globulin (IVIG) has been used successfully in some patients with autoimmune disease and erythromelalgia. When severe, erythromelalgia is a life-altering disease, and aggressive management is warranted. Patients may benefit from referral to special clinics for pain management or pain rehabilitation. At times, simple measures such as immersion in cool water may stop pain crises. Biofeedback can be of benefit. In general, no more than 50% of patients with erythromelalgia of the neuropathic type will respond to any one medication, so the treatment must be tailored to each patient, and often combinations of agents are used. Topical amitriptyline 1% and ketamine 0.5% in a gel are safe topical options and are especially reasonable for affected thin-skinned areas, such as the face or ears, where penetration would be optimal. Oral amitriptyline, sertraline, nortriptyline, pregabalin, and venlafaxine have shown benefit in some patients. Mexiletine, which has a normalizing effect on pathologic gating properties of the  $Na_v1.7$  sodium channel mutation, has been reported effective in some patients, as have carbamazepine and the combination of carbamazepine and gabapentin. Neurosurgical intervention has been used in the most severely affected, carefully selected patients who have failed medical management.

### Red ear syndrome

Red ear syndrome describes a rarely reported disorder characterized by relapsing attacks of redness and burning affecting both ears, usually only one ear at a time. The attacks are more common in the winter and are precipitated by touching, movements, and exposure to warmth. Associated conditions include neural disorders of the trigeminal and glossopharyngeal nerves, migraines, and LE. It is unclear if red ear syndrome is a disease sui generis or is actually erythromelalgia of the ears. Treatment with oral and topical tricyclic antidepressants has been beneficial. Red ear syndrome must be distinguished from the springtime variant of polymorphous light eruption seen in young males with cold exposure, relapsing polychondritis (the lobe is also involved in red ear syndrome), cellulitis, and borreliosis lymphocytoma.

**Alhadad A, et al:** Erythromelalgia: incidence and clinical experience in a single centre in Sweden. *Vasa* 2012; 41(1):43–8.

**Catterall WA, et al:** Inherited neuronal ion channelopathies: new windows on complex neurological diseases. *J Neurosci* 2008; 28:11768.

**Cerci FB, et al:** Intractable erythromelalgia of the lower extremities successfully treated with lumbar sympathetic block. *J Am Acad Dermatol* 2013; 69(5):e270–e272.

**Chen MC, et al:** Erythema associated with pain and warmth on face and ears: a variant of erythromelalgia or red ear syndrome? *J Headache Pain* 2014; 15(1):18.

**Cheng X, et al:** Mutation I136V alters electrophysiological properties of the  $Na_v1.7$  channel in a family with onset of erythromelalgia in the second decade. *Mol Pain* 2008; 4:1.

**Cohen JS:** Transdermal therapy for erythromelalgia. *Arch Dermatol* 2006; 142:1508.

**Cook-Norris RH, et al:** Pediatric erythromelalgia: a retrospective review of 32 cases evaluated at Mayo Clinic over a 37-year period. *J Am Acad Dermatol* 2012; 66(3):416–423.

**Cregg R, et al:** Mexiletine as a treatment for primary erythromelalgia: normalization of biophysical properties of mutant L858F  $Na_v1.7$  sodium channels. *Br J Pharmacol* 2014; 171(19):4455–4463.

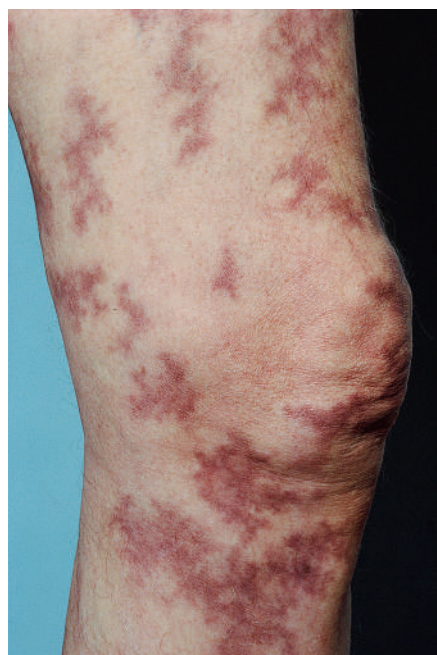**Davis MD, et al:** Erythromelalgia: vasculopathy, neuropathy, or both? A prospective study of vascular and neurophysiologic studies in erythromelalgia. *Arch Dermatol* 2003; 139:1337.

- Davis MD, et al:** Thermoregulatory sweat testing in patients with erythromelalgia. *Arch Dermatol* 2006; 142:1583.
- Drenth JP, et al:** Primary erythromelalgia as a sodium channelopathy: screening for *SCN9A* mutations: exclusion of a causal role of *SCN10A* and *SCN11A*. *Arch Dermatol* 2008; 144:320.
- Durosaro O, et al:** Intervention for erythromelalgia, a chronic pain syndrome: comprehensive pain rehabilitation center, Mayo Clinic. *Arch Dermatol* 2008; 144:1578.
- Eberhardt M, et al:** Inherited pain: sodium channel  $Na_v1.7$  A1632T mutation causes erythromelalgia due to a shift of fast inactivation. *J Biol Chem* 2014; 289(4):1971–1980.
- Eismann R, et al:** Red ear syndrome: case report and review of the literature. *Dermatology* 2011; 223(3):196–199.
- Estacion M, et al:**  $Na_v1.7$  gain-of-function mutations as a continuum: A1632E displays physiological changes associated with erythromelalgia and paroxysmal extreme pain disorder mutations and produces symptoms of both disorders. *J Neurosci* 2008; 28:11079.
- Firmin D, et al:** Treatment of familial erythromelalgia with venlafaxine. *J Eur Acad Dermatol Venereol* 2007; 21:836.
- Fisher TZ, et al:** A novel  $Na_v1.7$  mutation producing carbamazepine-responsive erythromelalgia. *Ann Neurol* 2009; 65:733.
- Genebriera J, et al:** Results of computer-assisted sensory evaluation in 41 patients with erythromelalgia. *Clin Exp Dermatol* 2012; 37(4):350–354.
- Han C, et al:** Early- and late-onset inherited erythromelalgia: genotype-phenotype correlation. *Brain* 2009; 132:1711.
- Han JH, et al:** Paraneoplastic erythromelalgia associated with breast carcinoma. *Int J Dermatol* 2012; 51(7):878–880.
- Iqbal J, et al:** Experience with oral mexiletine in primary erythromelalgia in children. *Ann Saudi Med* 2009; 29:316.
- Kalava K, et al:** Response of primary erythromelalgia to pregabalin therapy. *J Clin Rheumatol* 2013; 19(5):284–285.
- Kalgaard OM, et al:** Prostacyclin reduces symptoms and sympathetic dysfunction in erythromelalgia in a double-blind randomized pilot study. *Acta Derm Venereol* 2003; 83:442.
- Kluger N, et al:** Romiplostim-induced erythromelalgia in a patient with idiopathic thrombocytopenic purpura. *Br J Dermatol* 2009; 161:482.
- Lambru G, et al:** The red ear syndrome. *J Headache Pain* 2013; 14:83.
- Lin KH, et al:** Effectiveness of botulinum toxin A in treatment of refractory erythromelalgia. *J Chin Med Assoc* 2013; 76(5):296–298.
- Misery L, et al:** Severe neurological complications of hereditary erythromelalgia. *J Eur Acad Dermatol Venereol* 2007; 21:1446.
- Moody S, et al:** Secondary erythromelalgia successfully treated with intravenous immunoglobulin. *J Child Neurol* 2012; 27(7):922–923.
- Nanayakkara PWB, et al:** Verapamil-induced erythromelalgia. *Neth J Med* 2007; 65:349.
- Natkunaratnam J, et al:** Treatment with carbamazepine and gabapentin of a patient with primary erythromelalgia (erythromelalgia) identified to have a mutation in the *SCN9A* gene, encoding a voltage-gated sodium channel. *Clin Exp Dermatol* 2009; 34(8):e640–e642.
- Paticoff J, et al:** Defining a treatable cause of erythromelalgia: acute adolescent autoimmune small-fiber axonopathy. *Anesth Analg* 2007; 104:438.
- Pipili C, Cholongitas E:** Erythromelalgia in a diabetic patient managed with gabapentin. *Diabetes Res Clin Pract* 2008; 79:e15.
- Poterucha TJ, et al:** Topical amitriptyline combined with ketamine for the treatment of erythromelalgia: a retrospective study of 36 patients at Mayo Clinic. *J Drugs Dermatol* 2013; 12(3):308–310.
- Raieli V, et al:** Prevalence of red ear syndrome in juvenile primary headaches. *Cephalalgia* 2011; 31(5):597–602.
- Reed KB, Davis MDP:** Incidence of erythromelalgia: a population-based study in Olmsted County, Minnesota. *J Eur Acad Dermatol Venereol* 2009; 23:13.
- Ryan S, et al:** Red ear syndrome: a review of all published cases (1996–2010). *Cephalalgia* 2013; 33(3):190–201.
- Saviuc PF, et al:** Erythromelalgia and mushroom poisoning. *J Toxicol Clin Toxicol* 2001; 39:403.
- Young FB:** When adaptive processes go awry: gain-of-function in *SCN9A*. *Clin Genet* 2008; 73:34.

## LIVEDO RETICULARIS, LIVEDO RACEMOSA

Livedo reticularis is the term used to describe a netlike, mottled or reticulated, pink or reddish blue discoloration of the skin, mostly on the extremities, especially the legs. It is more prominent with exposure to cold and may vanish with warming. It is usually seen on the lower extremities in young children and women. The pathogenic basis is reduced blood flow and lowered oxygen tension in the venous plexus of the skin. *Cutis marmorata* is another name for livedoid physiologic mottling of skin exposed to cold. For clinical purposes, it is best to separate livedo reticularis (a benign condition in most cases) from fixed livedo reticularis, better known as livedo racemosa. Livedo racemosa forms irregular networks and broken circular segments that are fixed and do not vary appreciably with temperature changes (Fig. 35-3). The lesions are usually asymptomatic. If necrosis or purpura occurs over the livedoid areas, the terms necrotizing livedo and “retiform purpura,” respectively, may be used. Livedo racemosa and livedo with purpura or necrosis are almost always associated with significant systemic disease that requires treatment. Unfortunately, the literature does not always accurately separate these entities, and patients may present with variable livedo (resembling livedo reticularis) and later develop more fixed lesions. In addition, some patients who have more variable livedo may have serious underlying disease that may require evaluation and treatment. These patients may not be easily identifiable initially on physical examination features alone. In this section, the term livedo will be used to describe this cutaneous finding and its association with other conditions. When livedo reticularis is seen, the clinician should consider the following categories of diseases as possibly causal: physiologic, hypercoagulable states (including myelodysplasias, cancer, and antiphospholipid and Sneddon syndromes), vasculitis (especially medium and large vessel), emboli, medications, and neurologic disorders.

Drugs may cause livedo. Amantadine (Symmetrel) can cause livedo reticularis. Quinidine and quinine may be associated with a photosensitivity that is livedoid in appearance, but on biopsy an interface dermatitis will be present. Minocycline can cause livedo, and this is a marker for the development



**Fig. 35-3** Livedo racemosa.



of an antineutrophil cytoplasmic antibody (ANCA)-positive vasculitis in these patients. The medication must be stopped immediately. Other medications associated with livedo include gemcitabine, heparin (perhaps associated with heparin-induced antiplatelet antibodies), IFN- $\beta$ , and bismuth.

Neurologic disorders can create livedo reticularis by altering innervation and, consequently, blood flow in the skin. Brain injury, multiple sclerosis, diabetes mellitus, poliomyelitis, and Parkinson's disease are some examples.

Many of the syndromes with fixed livedo (livedo racemosa) have important systemic implications. These conditions can be either primary thrombotic processes or vascular inflammatory processes. If the vessels of the skin are affected, are the vessels in other organs, specifically the central nervous system (CNS) and kidneys, at risk? Sneddon syndrome usually occurs in young to middle-age women. These patients present with livedo and then develop cerebrovascular infarcts. The prognosis is poor. Frequently, patients have antiphospholipid antibodies (up to 85%) and may have enough features to be diagnosed with systemic lupus erythematosus (SLE). They would be accurately diagnosed as having antiphospholipid antibody syndrome. Other connective tissue diseases, such as dermatomyositis, rheumatoid arthritis, and systemic sclerosis, may have antiphospholipid antibodies and thus feature livedo. For this reason, patients with SLE and livedo are likely to have more severe disease manifestations, such as renal disease, vasculitis, and antiphospholipid antibodies, even in the absence of full-blown Sneddon syndrome. Headache may be the presenting symptom in these patients, and the misdiagnosis of migraine may initially be entertained. Not all patients with Sneddon syndrome can be diagnosed as having antiphospholipid antibody syndrome, however, and their optimal evaluation and management is unclear. Other significant disorders with livedo as a skin manifestation include thrombotic processes (hypercoagulable states, type I cryoglobulinemia), microangiopathic hemolytic anemias (TTP, hemolytic uremic syndrome, disseminated intravascular coagulation), medium- and large-vessel vasculitides, and septicemia. Moyamoya disease is a rare, chronic cerebrovascular occlusive condition characterized by progressive stenosis of the arteries in the circle of Willis. Patients present with ischemic strokes or cerebral hemorrhages. Both idiopathic moyamoya disease and disease connected with factor V Leiden mutation have been associated with livedo reticularis. Divry-van Bogaert syndrome, with livedo racemosa, seizures, and significant CNS disease, may be related to moyamoya or Sneddon syndrome.

Oxalosis may lead to livedo reticularis from deposition of oxalate crystals in and around blood vessel walls. The characteristic crystals are seen on biopsy. Calciphylaxis, with calcium deposits in vessels and tissue, may cause livedo. Other possible causes of livedo include cryofibrinogenemia, Graves' disease (associated with anticardiolipin antibodies), atrial myxoma, tuberculosis (perhaps as a complication of vascular inflammation: vascular-based tuberculid), and syphilis.

**Asherson RA, et al:** Unusual manifestations of the antiphospholipid syndrome. *Clin Rev Allergy Immunol* 2003; 25:61.

**Dean SM:** Livedo reticularis and related disorders. *Curr Treat Options Cardiovasc Med* 2011; 13(2):179-191.

**Gibbs MB, et al:** Livedo reticularis: an update. *J Am Acad Dermatol* 2005; 52:1009.

**Lenert P, et al:** ANA(+) ANCA(+) systemic vasculitis associated with the use of minocycline: case-based review. *Clin Rheumatol* 2013; 32(7):1099-1106.

**Sangle SR, et al:** The prevalence of abnormal pulse wave velocity, pulse contour analysis and ankle-brachial index in patients with livedo reticularis: a controlled study. *Rheumatology (Oxford)* 2013; 52(11):1992-1998.

**Sladden MJ, et al:** Livedo reticularis induced by amantadine. *Br J Dermatol* 2003; 149:656.

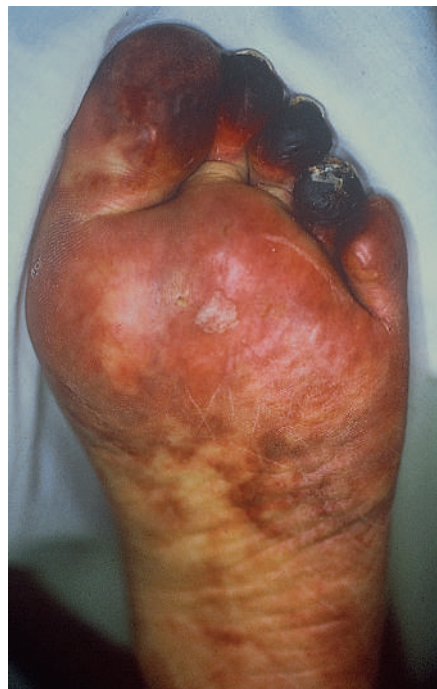**Tebbe B:** Clinical course and prognosis of cutaneous lupus erythematosus. *Clin Dermatol* 2004; 22:121.

**Tektonidou MG, et al:** Antiphospholipid syndrome nephropathy in patients with systemic lupus erythematosus and antiphospholipid antibodies: prevalence, clinical associations, and long-term outcome. *Arthritis Rheum* 2004; 50:2569.

**Tietjen GE, et al:** Livedo reticularis and migraine: a marker for stroke risk? *Headache* 2002; 42:352.

## Cholesterol emboli

Cholesterol emboli resulting from severe atherosclerotic disease, usually of the abdominal aorta, may cause unilateral or bilateral livedo of the lower extremities. The livedo may not be present with the patient supine and may only be present when the legs are dependent. Patients frequently have concomitant cyanosis (blue toes), purpura, nodules, ulceration, or gangrene (Fig. 35-4). Pain often accompanies the skin lesions. Acute renal failure occurs in up to 75%, and about one third of patients will have characteristic skin lesions. An eosinophilia on complete blood count (CBC) is present in 80% of cases. Older men with severe atherosclerotic disease are at greatest risk. They are often receiving anticoagulant therapy, and many have recently undergone vascular surgery or instrumentation. Slightly more than 1% of left-sided heart catheterizations are complicated by cholesterol emboli. The differential diagnosis includes vasculitis, septic staphylococcal emboli resulting from endocarditis or an infected aneurysm, and polyarteritis nodosa. Cholesterol emboli can involve all organs except the lungs; therefore, disease burden can range from mild to overwhelming. Mortality can be significant, as high as 90% among those with multisystem involvement, in whom renal failure, bowel infarction, and other devastating complications can occur. Livedo reticularis of recent onset in an elderly person warrants consideration of this diagnosis. Deep biopsy with serial sections may demonstrate the characteristic cholesterol clefts within thrombi. Frozen-section evaluation with polarized microscopy is particularly sensitive. Retinal emboli occur in up to 25% of patients, so funduscopic examination can also aid in diagnosis. Low-dose corticosteroids may



**Fig. 35-4** Cholesterol emboli.

be useful for treatment of cholesterol emboli-associated renal insufficiency.

**Fukamoto Y, et al:** The incidence and risk factors of cholesterol embolization syndrome, a complication of cardiac catheterization: a prospective study. *J Am Coll Cardiol* 2003; 42:211.

**Jucgla A, et al:** Cholesterol embolism: still an unrecognized entity with a high mortality. *J Am Acad Derm* 2006; 55:786–793.

**Masuda J, et al:** Use of corticosteroids in the treatment of cholesterol crystal embolism after cardiac catheterization: a report of four Japanese cases. *Intern Med* 2013; 52(9):993–998.

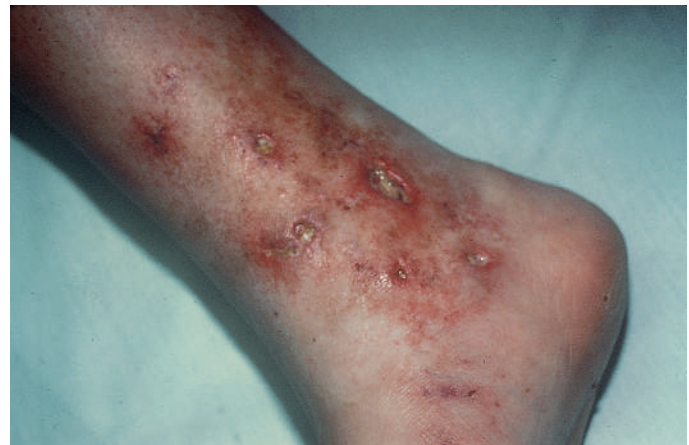## Evaluation of the patient with possible cutaneous vascular disorders

In the evaluation of patients who present with livedo, purpura, or ulceration, a broad differential diagnosis must be entertained. The diseases considered should include primary pathology of the cutaneous vasculature. In general, these vascular disorders of the skin are divided into two main groups: vasculitis and vasculopathy. Vasculitis includes disorders in which the primary damage in the blood vessels results from inflammatory cells infiltrating and damaging vessel walls. As a consequence of inflammation within vessels, the clotting cascade is triggered, and subsequent thrombosis may be seen in and adjacent to involved vessels. In vasculopathy, the primary process is thrombosis. This is usually caused by a hypercoagulable state. Once thrombosis occurs, inflammatory cells enter the vessel and vessel wall in an attempt to reestablish local circulation. Thus, late in a primary thrombotic process, vascular inflammation is seen and can be misinterpreted as “vasculitis.” Emboli can result in a similar histologic picture, because late embolic lesions may also be inflammatory and histologically misleading. All these processes—vasculitis, vasculopathy, and emboli—alter cutaneous blood flow and can be accompanied by livedo. If vessels lose competence, they leak, creating purpura. If vasculitis, vasculopathy, or embolus is severe enough or affect a large enough vessel, the viability of the overlying skin is compromised, and necrosis and ulceration may occur.

Because these entities resemble one another both clinically and histologically, accurate diagnosis is difficult for even the most skilled dermatologist. Careful sampling of early lesions, with large and deep biopsies, if necessary, may be required to find the “primary” vascular pathology. Since vasculitis can be a focal process, step sections may be required to find the diagnostic features. In addition, the diagnosis proposed must be interpreted in the context of other elements of the patient’s medical condition, such as medications, infections, underlying diseases, and involvement of other organ systems besides the skin.

## LIVEDOID VASCULOPATHY

Synonyms for livedoid vasculopathy include livedoid vasculitis, atrophie blanche, segmental hyalinizing vasculitis, livedo reticularis with summer/winter ulceration, and painful purpuric ulcers with reticular pattern of the lower extremities (PURPLE). It is a hyalinizing, thrombo-occlusive vascular disease characterized by clotting of medium-sized arterioles. The disorder is chronic, recurrent, and painful. Clinically, purpuric macules and papules cluster around the lower legs, ankles, and dorsal feet. These lesions may develop a hemorrhagic crust, then break down to form irregular, superficial ulcers bordered by violaceous erythema (Fig. 35-5). Over many months, the ulcers heal with porcelain-white, atrophic scars with peripheral telangiectasias, termed atrophie blanche.



**Fig. 35-5** Livedoid vasculopathy.

Other cutaneous findings, such as livedo reticularis, may also be present. About two thirds to three quarters of patients are female; mean age of onset is 45 years. The condition is bilateral in 80% of patients, and ulceration occurs in 70%.

This clinical presentation must be distinguished from other disorders that can cause purpura and ulcers. The differential diagnosis is broad because many conditions can cause livedo reticularis with ulceration of the lower extremities. Atrophie blanche-like lesions are a fairly common end result of ulceration and are therefore not specific for livedoid vasculopathy.

Conditions that mimic livedoid vasculopathy and must be excluded include, most importantly, the vasculitides—cutaneous small-vessel vasculitis, cryoglobulinemic vasculitis, ANCA-associated vasculitis, and polyarteritis nodosa. Vasculitis involving medium-sized cutaneous vessels can present with ulceration and atrophic, stellate scarring. The presence of other systemic manifestations typical for these conditions should help differentiate them from livedoid vasculopathy. Venous insufficiency, arterial insufficiency, and traumatic ulceration may heal with atrophie blanche and therefore mimic livedoid vasculopathy. Features such as lower extremity edema, hemosiderosis, and venous varicosities may suggest the presence of venous insufficiency, whereas absent pulses, cool extremities, diminished hair growth, and severe pain are typical of arterial insufficiency. A history of trauma should be obtained. A history of characteristic ulcers should be used to distinguish livedoid vasculopathy from other disorders that can lead to atrophic scarring. Ultimately, however, biopsy should be used to confirm the diagnosis and exclude other causes of ulceration, especially vasculitis.

Biopsy of an affected area must be sufficiently deep to sample medium-sized vessels in the deep dermis or subcutis. Typical findings include hyalinized, thickened dermal blood vessels with fibrin deposition and focal thrombosis. Perivascular hemorrhage and mild perivascular lymphocytic infiltrate can be seen. Notably, no leukocytoclasia or true vasculitis is seen. Results of direct immunofluorescence (DIF) studies are nonspecific. Biopsies of older lesions of atrophie blanche may be most notable for epidermal atrophy and flattening of the rete ridges, as well as recanalization of occluded vessels. In about 15% of patients, an initial biopsy does not reveal diagnostic histology, and a second is required. After two biopsies, diagnostic pathology is found in 98% of patients.

Livedoid vasculopathy is a vaso-occlusive condition, a hypercoagulable state with spontaneous thrombosis leading to local hypoxia and skin ulceration. A variety of risk factors for thromboembolism have been identified in association with livedoid vasculopathy. These include genetic and acquired



disorders predisposing to thrombosis such as factor V Leiden mutation; protein C or S deficiency; hyperhomocysteinemia, which results in increased clotting; increased plasminogen activator inhibitor (PAI)-1, an important inhibitor of the fibrinolytic system; methylenetetrahydrofolate reductase gene mutation; increased platelet aggregation; low tissue-type plasminogen activator (tPA) levels; enhanced fibrin formation; high levels of lipoprotein A; antithrombin III deficiency; antiphospholipid antibodies; physiologic decrease in levels of protein C and S, as in pregnancy; and other underlying hypercoagulable states (e.g., connective tissue diseases, malignancies).

A review of 45 patients with livedoid vasculopathy included 29 with hypercoagulable workup, 12 of whom (41%) had abnormalities, some multiple. In addition, a number of patients were noted to have connective tissue disease, solid-organ carcinoma, or hematologic malignancy. Livedoid vasculopathy was associated with a comorbid disease or procoagulant state in 58% (26/45). This likely represents an underestimate because exhaustive coagulation screening was not performed in most patients. In a prospective study of 34 patients, 52% (18 patients) screened had laboratory evidence of a coagulopathy, of whom 32% (11) responded to anticoagulant therapy. Some patients diagnosed with "idiopathic" livedoid vasculopathy, in whom no associated abnormality is found, actually have underlying hypercoagulable states discernible only after subsequent, more thorough, workup. As testing for coagulation abnormalities evolves, a greater percentage of livedoid vasculopathy cases will likely be associated with underlying disorders.

Livedoid vasculopathy has been associated with deep venous thrombosis, pulmonary embolism, and cerebrovascular accident (stroke), among other systemic thromboembolic events. Limited data exist to guide management, but in general, treatment of livedoid vasculopathy should be directed at treating the underlying hypercoagulable state, if any. In patients with coagulopathy or personal or family history of thromboembolism, more aggressive therapy may be warranted. A therapeutic ladder for treatment of livedoid vasculopathy begins with local wound care and compression for edema, along with basic measures to decrease risk of thromboembolism (e.g., smoking cessation), followed by the addition of relatively low-risk pharmacologic interventions (e.g., pentoxifylline or aspirin), before moving on to anticoagulants (e.g., warfarin, low-molecular-weight heparin, rivaroxaban), and other agents with a less favorable risk profile, if needed. Exceptions to this order might include the introduction of hydroxychloroquine for connective tissue disease, folic acid and vitamin B complex for methylenetetrahydrofolate reductase mutation, danazol or stanozolol for cryofibrinogenemia, and warfarin for antiphospholipid antibody syndrome or a history of systemic thromboembolism. Controlled trials are needed to define better the role of these agents in the treatment of livedoid vasculopathy as well as the possible role of therapy in preventing systemic thromboembolic complications. Systemic immunosuppression is usually not beneficial for livedoid vasculopathy, because its pathogenesis is thrombo-occlusive, not inflammatory. A dramatic response to high-dose corticosteroids, for example, suggests an alternate diagnosis.

**Alavi A, et al:** Livedoid vasculopathy: an in-depth analysis using a modified Delphi approach. *J Am Acad Dermatol* 2013; 69(6):1033–1042.e1

**Anavekar ND, Kelly R:** Heterozygous prothrombin gene mutation associated with livedoid vasculopathy. *Australas J Dermatol* 2007; 48:120.

**Callen JP:** Livedoid vasculopathy: what it is and how the patient should be evaluated and treated. *Arch Dermatol* 2006; 142:1481.

**Criado PR, et al:** Livedoid vasculopathy: an intriguing cutaneous disease. *An Bras Dermatol* 2011; 86(5):961–977.

**Davis MD, Wysokinski WE:** Ulcerations caused by livedoid vasculopathy associated with a prothrombotic state: response to warfarin. *J Am Acad Dermatol* 2008; 58:512.

**Deng A, et al:** Livedoid vasculopathy associated with plasminogen activator inhibitor-1 promoter homozygosity (4G/4G) treated successfully with tissue plasminogen activator. *Arch Dermatol* 2006; 142:1466.

**Di Giacomo TB, et al:** Frequency of thrombophilia determinant factors in patients with livedoid vasculopathy and treatment with anticoagulant drugs—a prospective study. *J Eur Acad Dermatol Venereol* 2010; 24(11):1340–1346.

**Frances C, Barette S:** Difficult management of livedoid vasculopathy. *Arch Dermatol* 2004; 140:1011.

**Gotlib J, et al:** Heterozygous prothrombin G20210A gene mutation in a patient with livedoid vasculitis. *Arch Dermatol* 2003; 139:1081.

**Hairston BR, et al:** Treatment of livedoid vasculopathy with low-molecular-weight heparin: report of 2 cases. *Arch Dermatol* 2003; 139:987.

**Hairston BR, et al:** Livedoid vasculopathy: further evidence for procoagulant pathogenesis. *Arch Dermatol* 2006; 142(11):1413–1418.

**Irani-Hakime NA, et al:** Livedoid vasculopathy associated with combined prothrombin G20210A and factor V (Leiden) heterozygosity and MTHFR C677T homozygosity. *J Thromb Thrombolysis* 2008; 26:31.

**Kerk N, et al:** Rivaroxaban prevents painful cutaneous infarctions in livedoid vasculopathy. *Br J Dermatol* 2013; 168(4):898–899.

**Meiss F, et al:** Livedoid vasculopathy: the role of hyperhomocysteinemia and its simple therapeutic consequences. *Eur J Dermatol* 2006; 16:159.

**Mimouni D, et al:** Cutaneous polyarteritis nodosa in patients presenting with atrophie blanche. *Br J Dermatol* 2003; 148:789.

**Monshi B, et al:** Efficacy of intravenous immunoglobulins in livedoid vasculopathy: long-term follow-up of 11 patients. *J Am Acad Dermatol* 2014; 71(4):738–744.

**Rampf J, et al:** Methylenetetrahydrofolate-reductase polymorphism associated homocysteinemia in a patient with livedo vasculopathy: therapy with vitamin substitution and low-molecular-weight heparin. *Br J Dermatol* 2006; 155(4):850–852.

**Vasconcelos R, et al:** Livedoid vasculopathy secondary to high levels of lipoprotein(a). *Br J Dermatol* 2011 May; 5:1111–1113.

**Yong AA, et al:** Livedoid vasculopathy and its association with factor V Leiden mutation. *Singapore Med J* 2012 Dec; 53:e258–e260.

**Zeni P, et al:** Successful use of rituximab in a patient with recalcitrant livedoid vasculopathy. *Ann Rheum Dis* 2008; 67:1055.

## CALCIPHYLAXIS

Calciophylaxis (calcific uremic arteriolopathy) is an increasingly reported and frequently fatal syndrome that occurs most often in the setting of chronic renal failure but may also occur with normal renal function (nonuremic calciophylaxis). In calciophylaxis, progressive calcification of the media of arterioles leads to vessel injury, intimal fibrosis, and thrombosis, followed by ischemic necrosis of the skin and soft tissue. About 1–4% of patients on hemodialysis and 4% of patients on peritoneal dialysis develop calciophylaxis. About half of patients are diabetic, and more than half have a body mass index (BMI) greater than 30; every gain in BMI of 1 point over 30 increases the risk for calciophylaxis by 10%. Women outnumber men 3:1 to 4:1. Other identified risk factors include liver disease, hypoalbuminemia, protein C deficiency, and exposure to warfarin or systemic glucocorticoids.

The pathogenesis of calciophylaxis remains poorly understood. Precipitation of calcium phosphate in vessel walls is generally thought to be mediated by elevated serum calcium, phosphate, and parathyroid hormone (PTH) levels, as are seen in chronic renal failure. Indeed, PTH levels are often elevated in affected patients, and the disease can be seen in the setting of primary hyperparathyroidism as well as the secondary hyperparathyroidism of chronic renal failure. Calcium-phosphate product is greater than 70 in about 20% of

calciphylaxis patients. However, a case control-study showed no statistical difference in serum calcium, phosphate, PTH, or calcium-phosphate product in patients with calciphylaxis compared with other dialysis patients. Calcium ingestion, as in the form of calcium-containing phosphate binders, did increase risk.

Calciphylaxis may be best thought of as a disease resulting from exposure of a susceptible host with dysfunctional calcium homeostasis to a particular “challenging” agent or precipitating factor, such as metal salts, fluctuation in renal function, or vascular inflammation. For calcification to occur, vascular smooth muscle cells must transform into osteoblast-like cells. Skin lesions in calciphylaxis exhibit significant upregulation of bone morphogenic protein 2 (BMP-2) and increased expression of inactive uncarboxylated matrix Gla protein (Glu-MGP), osteopontin, fibronectin, laminin, and collagen I, indicating extensive remodeling of the subcutaneous extracellular matrix.

Calciphylaxis begins as fixed livedo reticularis (livedo racemosa), which is frequently firm or hard to the touch. Areas within the livedo become increasingly violaceous and eventually purpuric, bullous, and necrotic (Fig. 35-6). Affected tissue has reduced oxygenation. Lesions affect the legs below the knees in 90% of patients. More proximal lesions and those of the fatty areas of the thighs, buttocks, and abdomen occur in about two-thirds. Severe pain is a cardinal feature of calciphylaxis, often requiring narcotic analgesia for control. Ischemic myopathy may occur in severe cases, and muscle pain may precede the appearance of the skin lesions. Penile calciphylaxis is a particularly painful variant. The glans penis develops a deep necrotic ischemic ulceration. Penectomy is often required for pain management. Calciphylaxis of the temporal artery may resemble temporal arteritis.

Necrotic skin lesions are resistant to healing, and infection of open wounds with septicemia is the most common cause of death. The mortality of calciphylaxis patients is about 50% at 1 year and 80% at 2 years; for patients with both proximal and distal disease, the 1-year mortality is 90%. Mortality doubles in those with ulcerative lesions.

Skin biopsy is generally recommended to confirm the diagnosis of calciphylaxis. It should be adjacent to the necrotic area where there is erythema or early purpura, and it should be deep and large enough to identify diagnostic features. This may require an incisional rather than a simple punch biopsy. Vascular calcification is common in all patients with chronic renal failure, so this alone cannot confirm the diagnosis. In addition, there should be evidence of tissue damage (necrosis), extravascular calcification, and thrombosis in the arterioles of the dermis and subcutaneous tissue. Because the

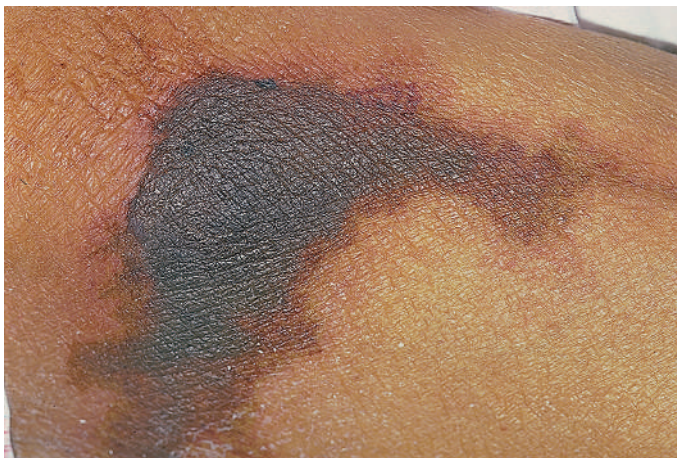

Fig. 35-6 Calciphylaxis.

sensitivity of biopsy may be poor, and the clinical presentation often strongly suggests the diagnosis, the true importance of skin biopsy in calciphylaxis is uncertain. Plain x-ray films of affected areas may reveal a characteristic netlike pattern of calcification.

Much of the treatment for calciphylaxis is directed at altering abnormal calcium metabolism. Because of its high mortality rate, patients are frequently treated with multiple agents at once, making the efficacy of any single agent particularly difficult to determine. Low-calcium dialysate, non-calcium carbonate phosphate binders, cinacalcet, bisphosphonates, and intravenous sodium thiosulfate have all been used with some success. Combination therapy is increasingly favored, and retrospective data appear to support its use. Potential exacerbating or triggering agents, such as vitamin D, calcium, warfarin, and iron, should be stopped. Pain control is essential. Once ulcerations are present, gentle debridement is associated with healing and increased survival. Intralesional sodium thiosulfate, if tolerated, may play a role in localized calciphylaxis. Hyperbaric oxygen therapy may be a useful adjunctive therapy for ulcer healing. Parathyroidectomy is best reserved for patients refractory to the previous regimens who have continued marked PTH elevation.

**Baldwin C, et al:** Multi-intervention management of calciphylaxis: a report of 7 cases. *Am J Kidney Dis* 2011; 58(6):988–991.

**Bhat S, et al:** Complete resolution of calciphylaxis after kidney transplantation. *Am J Kidney Dis* 2013; 62(1):132–134.

**Hanafusa T, et al:** Intractable wounds caused by calcific uremic arteriopathy treated with bisphosphonates. *J Am Acad Dermatol* 2007; 57:1021.

**Hayashi M:** Calciphylaxis: diagnosis and clinical features. *Clin Exp Nephrol* 2013; 17(4):498–503.

**Hayashi M, et al:** A case-control study of calciphylaxis in Japanese end-stage renal disease patients. *Japanese Calciphylaxis Study Group. Nephrol Dial Transplant* 2012; 27(4):1580–1584.

**Kalajian AH, et al:** Calciphylaxis with normal renal and parathyroid function: not as rare as previously believed. *Arch Dermatol* 2009; 145:451.

**Kramann R, et al:** Novel insights into osteogenesis and matrix remodelling associated with calcific uremic arteriopathy. *Nephrol Dial Transplant* 2013; 28(4):856–868.

**Kyritsis I, et al:** Combination of sodium thiosulphate cinacalcet, and paricalcitol in the treatment of calciphylaxis with hyperparathyroidism. *Int J Artif Organs* 2008; 31:742.

**Nigwekar SU, et al:** Sodium thiosulfate therapy for calcific uremic arteriopathy. *Clin J Am Soc Nephrol* 2013; 8(7):1162–1170.

**Ning MS, et al:** Sodium thiosulfate in the treatment of non-uremic calciphylaxis. *J Dermatol* 2013; 40(8):649–652.

**O’Neil B, Southwick AW:** Three cases of penile calciphylaxis: diagnosis, treatment strategies, and the role of sodium thiosulfate. *Urology* 2012; 80(1):5–8.

**Saifan C, et al:** Warfarin-induced calciphylaxis: a case report and review of literature. *Int J Gen Med* 2013 Aug 9; 6:665–669.

**Salmhofer H, et al:** Multi-modal treatment of calciphylaxis with sodium thiosulfate, cinacalcet and sevelamer including long-term data. *Kidney Blood Press Res* 2013; 37(4/5):346–359.

**Schliep S, et al:** Successful treatment of calciphylaxis with pamidronate. *Eur J Dermatol* 2008; 18:554.

**Shmidt E, et al:** Net-like pattern of calcification on plain soft-tissue radiographs in patients with calciphylaxis. *J Am Acad Dermatol* 2012; 67(6):1296–1301.

**Strazzula L, et al:** Intralesional sodium thiosulfate for the treatment of calciphylaxis. *JAMA Dermatol* 2013; 149(8):946–949.

**Wanat KA, et al:** Severe nonuremic calciphylaxis due to hyperphosphatemia resolving with multimodality treatment including phosphate binders. *JAMA Dermatol* 2014; 150(6):671–673.

**Vedvyas C, et al:** Calciphylaxis: a systematic review of existing and emerging therapies. *J Am Acad Dermatol* 2012; 67(6):e253–e260.

**Weentig RH, et al:** Calciphylaxis: natural history, risk factor analysis, and outcome. *J Am Acad Dermatol* 2007; 56:569.

**Zacharias JM, et al:** Calcium use increases risk of calciphylaxis: a case-control study. *Perit Dial Int* 1999; 19(3):248–252.



## MARSHALL-WHITE SYNDROME AND BIER SPOTS

Bier spots are pale, irregularly shaped macules about 10 mm in size, usually found on the upper and lower extremities of young adults. The spots are a type of vascular mottling that can be elicited by placing the limbs in a dependent position; they resolve when the limbs are raised and disappear when the surrounding skin is blanched. They likely represent areas of localized vasoconstriction surrounded by relative vasodilation. Although primarily idiopathic, asymptomatic, and transient, there are case reports of Bier spots in association with such disorders as cryoglobulinemia and scleroderma renal crisis and with pregnancy. Awareness of the condition can prevent misdiagnosis of a pigmentary disorder.

**Fan YM, et al:** Bier spots: six case reports. *J Am Acad Dermatol* 2009; 61(3):e11–e12.

**Heller M:** Diffuse Bier spots. *Dermatol Online J* 2005; 11(4):2.

## PURPURA

Purpura is the term used to describe extravasation of blood into the skin or mucous membranes. It presents as distinctive, brownish red or purplish macules a few millimeters to many centimeters in diameter. Several terms are used to describe various clinical manifestations of purpura.

Petechiae are superficial, pinhead-sized (<3 mm), round, hemorrhagic macules, bright red at first, then brownish or rust-colored. They are most often seen in dependent areas, occur in crops, regress over days, and usually imply a disorder of platelets rather than of coagulation factors, which typically give rise to ecchymoses or hematomas rather than petechiae.

Ecchymoses are commonly known as bruises. These extravasations signify a deeper, more extensive interstitial hemorrhage that forms a flat, irregularly shaped, blue-purple patch. Such patches gradually turn yellow and finally fade away.

Vibices (singular, vibex) are linear purpuric lesions.

Hematoma designates a pool-like collection of extravasated blood in a dead space in tissue that, if of sufficient size, produces swelling that fluctuates on palpation. Hematomas are usually walled off by tissue planes.

## Pathogenesis

Purpura may result from hypercoagulable and hypocoagulable states, vascular dysfunction, idiopathic thrombocytopenic purpura, TTP, disseminated intravascular coagulation (DIC), drug-induced thrombocytopenia, bone marrow failure, congenital or inherited platelet function defects, acquired platelet function defects (aspirin, renal or hepatic disease, gammopathy), and thrombocytosis secondary to myeloproliferable diseases. Most of these disorders produce findings of nonpalpable purpura. Ecchymosis predominates in procoagulant defects, such as hemophilia, pharmacologic anticoagulation, vitamin K deficiency, and advanced hepatic disease resulting in impaired synthesis of clotting factors. There is often a component of trauma. Increased ecchymosis can be the result of poor dermal support of blood vessels, most often localized to the area of trauma, and may result from actinic (senile) purpura, topical or systemic corticosteroid therapy, scurvy, systemic amyloidosis, Ehlers-Danlos syndrome, or pseudoxanthoma elasticum.

Prothrombotic disorders form characteristic “retiform” purpura or purpura associated with livedo reticularis. These include disorders in which fibrin, cryoglobulin, or other mate-

rial occludes vessels. Representative causes include monoclonal cryoglobulinemia, cryofibrinogenemia, DIC, purpura fulminans, protein C or S deficiency, warfarin-induced necrosis, heparin necrosis, cholesterol emboli, oxalate crystal occlusion, and antiphospholipid syndrome.

## Evaluation

A history and physical examination are often sufficient to evaluate for purpura. A family history of bleeding or thrombotic disorders, duration of symptoms, use of drugs and medications that might affect platelet function and coagulation, and review of medical conditions that may result in altered coagulation should be documented. Physical examination should stress the size, type, and distribution of purpura; a search for telangiectasias; a joint examination; and an evaluation of skin elasticity, unusual scars, and unusual body habitus. Correlation of purpura morphology with pathogenesis allows for a more focused approach.

A CBC and differential can be used to assess for microangiopathic anemia, screen for myeloproliferative disorders, and assess the number and morphology of platelets. A bleeding time is the preferred method of assessing platelet function. The partial thromboplastin time (PTT) and prothrombin time (PT) are tests to evaluate abnormal coagulation states.

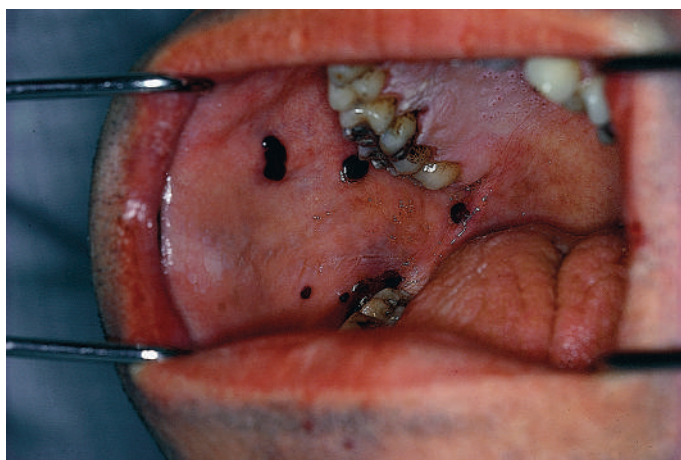
## THROMBOCYTOPENIC PURPURA

Thrombocytopenic purpura may be classified into two large categories: states resulting from accelerated platelet destruction and states resulting from deficient platelet production. Accelerated platelet destruction may be immunologic or non-immunologic. The former may be caused by antibodies (auto-immune or drug-induced thrombocytopenia), isoantibodies (congenital or posttransfusion), immune complex disease, or other immunologic processes, such as erythroblastosis fetalis, neonatal lupus, scleroderma, other connective tissue diseases, or acquired immunodeficiency syndrome (AIDS). The group of thrombocytopenias with accelerated platelet destruction also includes TTP and DIC. Deficient platelet production may be related to diseases such as aplastic anemia and leukemia.

## Immune thrombocytopenic purpura (immune thrombocytopenia)

Immune thrombocytopenic purpura (ITP) was also known as “idiopathic” thrombocytopenic purpura or Werlhof’s disease. It is an autoimmune disease characterized by an isolated thrombocytopenia (platelet count <100,000). The causative antibodies are directed at molecules on the platelet surface, leading to their premature sequestration and destruction, primarily in the spleen. ITP is called primary in the absence of another cause, or secondary if there is a causal association, such as “secondary ITP (SLE-associated).” Bleeding symptoms are minimal or absent in a large proportion of cases. Cutaneous manifestations can include an acute or gradual onset of petechiae or ecchymoses on the skin and mucous membranes, especially in the mouth. Epistaxis, conjunctival hemorrhages, hemorrhagic bullae in the mouth (Fig. 35-7), and gingival bleeding may occur. Melena and hematemesis are also present, as well as menorrhagia, which may be the first sign of the disease in young women. Chronic leg ulcers occasionally develop.

Bleeding can occur when the platelet count is less than 50,000/mm<sup>3</sup>. Posttraumatic hemorrhage, spontaneous



**Fig. 35-7** Oral hemorrhagic bullae as presenting complaint in immune thrombocytopenic purpura.

hemorrhage, and petechiae may appear. The risk of serious hemorrhage is greatly increased at levels below  $10,000/\text{mm}^3$ . The most serious complication is intracranial hemorrhage. ITP may be fatal, but most mortality in adults results from treatment complications. Bleeding time is usually prolonged and coagulation time normal, whereas clot retraction time is abnormal and capillary fragility increased. Increased numbers of megakaryocytes are found in the bone marrow.

The age of onset determines the clinical manifestations and course. In children, onset is often acute and follows a viral illness in 50–60% of patients. Parvovirus B19 is frequently complicated by thrombocytopenia, which may be ITP or simply a consequence of reduced bone marrow production of platelets. The average lag between purpura and the preceding infection is usually 2 weeks (range 1–4). Most of these cases resolve spontaneously. Since children are at much less risk of developing serious hemorrhagic complications, a more conservative management approach may be taken. A few patients will develop chronic thrombocytopenia, and deaths, usually from cerebral hemorrhage, have been reported. In a series of 332 children with ITP, 58 (17%) had episodes of major hemorrhage. One death resulted from sepsis. In another series of 427 cases, 323 (72%) had mild to benign disease. About 85% of children who undergo splenectomy experience remission. More than half of the remaining patients spontaneously remit within 15 years.

The chronic form of ITP occurs most often in adults, is persistent, and has a female/male ratio of 2:1 to 4:1. Secondary ITP is more common in adults. Human immunodeficiency virus (HIV) infection, hepatitis C, and autoimmune disease are the most common associated disorders. Treatment of associated disease may lead to improvement of the thrombocytopenia. Breast cancer has been associated with ITP, with a parallel course in one third of cases. Other malignancies have also been associated with ITP. *Helicobacter pylori* infection as a cause of ITP is controversial, but testing for *H. pylori* antibodies and treatment for infection carry limited toxicity and thus could be considered.

In elderly patients, ITP is more difficult to manage. Patients more frequently have major bleeding complications, more complications from immunosuppressive agents, especially corticosteroids, and more complications from splenectomy. Corticosteroids have a particularly low response rate in elderly ITP patients. Danazol has demonstrated reasonable safety and efficacy in the elderly population.

The differential diagnosis of ITP includes drug-induced thrombocytopenia, myelodysplasia, TTP, and congenital/

hereditary thrombocytopenia. The goal of treatment for ITP is to raise the platelet count above 20,000 to 30,000 and to stop all bleeding symptoms. Platelet transfusions are indicated if there is significant bleeding or if the platelet count is dangerously low. If the platelet count is greater than 20,000–30,000, the patient may be closely monitored. The treatment of ITP has changed with the availability of new approaches. Initial treatment is a short course of high-dose corticosteroids, either for 1–2 weeks or as monthly pulses. IVIG or anti-(Rh)D, also known as IV Rh immune globulin (IG), may be given with this treatment. Platelet survival is increased if transfused immediately after immunoglobulin infusion. If the patient relapses or has persistent symptoms, systemic corticosteroids are given with rituximab, anti-(Rh)D, IVIG, or a thrombopoietin agonist such as eltrombopag or romiplostim. Splenectomy can be considered a second-line treatment, although age over 60 makes this treatment less desirable. Danazol can be added as a second-line agent, especially in the elderly patient. When second-line treatments have failed in patients with chronic and persistent or worsening disease, immunosuppression with mycophenolate mofetil (MMF), azathioprine, cyclosporine, vincristine, lymphoma-type chemotherapeutic regimens, and even autologous transplantation could be considered.

**Aktepe OC, et al:** Human parvovirus B19 associated with idiopathic thrombocytopenic purpura. *Pediatr Hematol Oncol* 2004; 21:421.

**Aledort LM, et al:** Prospective screening of 205 patients with ITP, including diagnosis, serological markers, and the relationship between platelet counts, endogenous thrombopoietin, and circulating antithrombopoietin antibodies. *Am J Hematol* 2004; 76:205.

**Cines DB, Blanchette VS:** Immune thrombocytopenic purpura. *N Engl J Med* 2002; 346(13):995–1008.

**Daou S, et al:** Idiopathic thrombocytopenic purpura in elderly patients: a study of 47 cases from a single reference center. *Eur J Intern Med* 2008; 19:447.

**George JN:** Definition, diagnosis and treatment of immune thrombocytopenic purpura. *Haematologica* 2009; 94:759.

**Kuter DJ, et al:** Efficacy of romiplostim in patients with chronic immune thrombocytopenic purpura: a double-blind randomised controlled trial. *Lancet* 2008; 371:395.

**Noonavath RN, et al:** *Helicobacter pylori* eradication in patients with chronic immune thrombocytopenic purpura. *World J Gastroenterol* 2014; 20(22):6918–6923.

**Rodeghiero F, et al:** Standardization of terminology, definitions and outcome criteria in immune thrombocytopenic purpura of adults and children: report from an international working group. *Blood* 2009; 113:2386.

**Rodeghiero F, Ruggeri M:** Chronic immune thrombocytopenic purpura: new agents. *Hamostaseologie* 2009; 29(1):76–79.

**Vesely SK, et al:** Management of adult patients with persistent idiopathic thrombocytopenic purpura following splenectomy: a systematic review. *Ann Intern Med* 2004; 140:112.

## Drug-induced thrombocytopenia

Thrombocytopenic purpura resulting from drug-induced antiplatelet antibodies may be caused by agents such as heparin, sulfonamides (antibiotics and hydrochlorothiazide), digoxin, quinine, quinidine, chlorothiazide, penicillin, cephalosporins, minocycline, acetaminophen, nonsteroidal anti-inflammatory drugs (NSAIDs), statins, fluconazole, protease inhibitors, H2 blockers, antiplatelet agents, rifampin, and lidocaine.

Heparin-induced thrombocytopenia (HIT) is associated with life-threatening arterial and venous thrombosis and, to a lesser extent, hemorrhagic complications. The platelet count usually begins to fall 4–14 days after starting heparin, more frequently in a patient with prior exposure to the medication. Platelet counts drop to about 50% of their pre-HIT level, usually with a nadir of about 50,000, and rarely 10,000. HIT is mediated by an antibody to the platelet factor 4 (PF4)-heparin



complex. The antibody cross-links FcγRII receptors on the platelet surface, resulting in platelet activation, aggregation, and simultaneous activation of blood-coagulation pathways. Tests for HIT antibodies include immunoassays such as enzyme-linked immunoassay (ELISA) and functional tests.

Treatment for drug-induced thrombocytopenia consists of removal of the offending agent. All forms of heparin, including heparin flushes, should be discontinued. Because the HIT antibody continues to activate platelets after heparin cessation, patients with HIT have a persistently high risk of thrombosis and an ongoing need for anticoagulation. A nonheparin anticoagulant (e.g., argatroban, bivalirudin, fondaparinux) should be begun immediately unless there is a strong contraindication to anticoagulation, such as active bleeding or high bleeding risk. Warfarin can cause microthrombosis in these patients, so it should be avoided until after the patient is stably anticoagulated with another agent and the platelet count has recovered to 150,000 or higher. The total duration of anticoagulation should be at least 2–3 months in the absence of a thrombotic event and 3–6 months if thrombosis has occurred.

**Chong BH, Isaacs A:** Heparin-induced thrombocytopenia: what clinicians need to know. *Thromb Haemost* 2009; 101:279.

**Goldfarb MJ, Blostein MD:** Fondaparinux in acute heparin-induced thrombocytopenia: a case series. *J Thromb Haemost* 2011; 9:2501.

**Grossjohann B, et al:** Ceftriaxone causes drug-induced immune thrombocytopenia and hemolytic anemia: characterization of targets on platelets and red blood cells. *Transfusion* 2004; 44:1033.

**Linkins LA, et al:** Treatment and prevention of heparin-induced thrombocytopenia. In *Antithrombotic Therapy and Prevention of Thrombosis*, 9th edn: American College of Chest Physicians Evidence-Based Clinical Practice Guidelines. *Chest* 2012; 141:e495S.

**Reese JA, et al:** Identifying drugs that cause acute thrombocytopenia: an analysis using 3 distinct methods. *Blood* 2010; 116(12):2127–2133.

**Shantsila E, et al:** Heparin-induced thrombocytopenia: a contemporary clinical approach to diagnosis and management. *Chest* 2009; 135:1652.

**Wirth SM, et al:** Evaluation of a clinical scoring scale to direct early appropriate therapy in heparin-induced thrombocytopenia. *J Oncol Pharm Pract* 2010; 16(3):161–166.

## THROMBOTIC MICROANGIOPATHY

The diagnosis of a thrombotic microangiopathy is made in the presence of a microangiopathic hemolytic anemia and thrombocytopenia, in the absence of another plausible explanation. Thrombotic thrombocytopenic purpura and hemolytic uremic syndrome are the two major diseases in this group. Certain drugs, such as cyclosporine, quinine, ticlopidine, clopidogrel, mitomycin C, docetaxel, trastuzumab, and bleomycin, have been associated with a thrombotic microangiopathy.

### Thrombotic thrombocytopenic purpura

Classically, TTP consists of the pentad of microangiopathic hemolytic anemia, thrombocytopenic purpura, neurologic abnormalities, fever, and renal disease. However, only the minority of patients (20–30%) present classically; many patients do not have renal disease, and CNS findings are not required for the diagnosis. The diagnosis of TTP requires only a Coombs-negative microangiopathic hemolytic anemia and thrombocytopenia with platelet aggregation in the microvasculature. Most patients will develop neurologic findings. Fever is present in 75%. Multiple ecchymoses and retiform purpura may be found on the skin. The presence of schistocytes on a blood smear is the morphologic hallmark of the disease, and a schistocyte count greater than 1% in the absence of other

known causes of thrombotic microangiopathy strongly suggests a diagnosis of TTP. Tests may show a decreased hematocrit and decreased platelets, an elevated lactate dehydrogenase level, and elevated indirect bilirubin. A delay in diagnosis may lead to a mortality rate as high as 90%. For this reason, the presence of microangiopathic hemolytic anemia and thrombocytopenia in the absence of an obvious cause (e.g., DIC) is justification enough to begin empiric therapy. Biopsies demonstrate hemorrhage and fibrin occlusion of vessels. Inflammation is absent. Studies of plasma samples from patients with active TTP show the presence of unusually large von Willebrand factor (vWF) multimers. The underlying cause of TTP is a congenital or acquired deficiency of the vWF-cleaving protease, ADAMTS13. vWF is secreted by the endothelial cell in long multimers, which should be cleaved into monomers by ADAMTS13 and released into the circulation. Instead, multimers circulate and extend from the surface of the endothelial cells in the microvasculature. Platelets adhere to these multimers and the surface of the endothelial cell, leading to microvascular thrombosis.

The two forms of TTP are idiopathic and congenital (Upshaw-Schulman syndrome). Congenital TTP is less common (<10% of cases) and usually presents in infancy or childhood with jaundice and thrombocytopenia. Some patients with a congenital deficiency of ADAMTS13 do not present until adulthood or may even remain asymptomatic. The course is frequently relapsing TTP at regular intervals. Idiopathic TTP is a rare disease, about 10 cases per 1 million population per year. Women represent 70% of cases, and those of African descent have a ninefold greater risk of developing idiopathic TTP. Idiopathic TTP is caused by an autoantibody directed against ADAMTS13 that can be detected in up to 85% of cases. Neurologic symptoms are the most frequent presentation, ranging from confusion to seizures to coma.

Plasma exchange with fresh frozen plasma is the treatment of choice for TTP. Before it was instituted, 80% of these patients died; now, 80% survive. Plasma exchange clears the vWF multimers, reduces the autoantibody, and replenishes the inhibited ADAMTS13. If plasma exchange is not immediately available, simple plasma infusion can be performed until it can be instituted. Plasma exchange is usually continued daily until clinical symptoms improve and the platelet count is above 150,000, generally about 5–10 total exchanges. In conjunction with plasma exchange, glucocorticoids may be given, although their success is variable. Platelet transfusions should be avoided except in the setting of life-threatening (i.e., CNS) bleeding. Cyclosporine, cyclophosphamide, and rituximab have been used in refractory cases, with promising results. Splenectomy can also be considered. Congenital TTP is usually much easier to treat, with only small amounts of normal plasma infusion required to provide the missing ADAMTS13 and stop the clotting.

### Hemolytic uremic syndrome

Hemolytic uremic syndrome (HUS) has many similarities to TTP but is now considered a distinct entity, both clinically and pathogenically. HUS is usually a disease of childhood. Patients have a microangiopathic hemolytic anemia, often following a diarrheal illness caused by Shiga toxin (Stx)-producing *Escherichia coli*. The annual incidence is 6.1 cases per 100,000 population. It is the most common cause of acute renal injury requiring transplantation in children age 1–5. *Streptococcus pneumoniae* infection can also precipitate HUS. Cases of HUS not following such infections are called “atypical HUS.”

Fever is usually absent in HUS patients. Renal insufficiency occurs in all patients and is the hallmark of HUS. Neurologic

disease can occur but affects less than half of patients. Skin involvement is unusual but may take the form of retiform purpura and petechiae.

The pathogenic mechanism of typical HUS is endothelial damage caused by the bacterial toxin and subsequent complement activation on the endothelial surface. The affected vessels are thickened, endothelial cells are detached, and the vascular lumen is narrowed and occluded by platelet thrombi. The renal vessels are at particular risk, since the subendothelial membrane is exposed and vulnerable to complement-mediated damage. In atypical and familial HUS, similar complement activation via the alternative pathway (through C3b) occurs on endothelial surfaces, leading to endothelial damage and intravascular thrombosis.

In atypical and familial HUS, mutations in the alternative complement cascade have been identified. Complement factor H (CFH) mutations are most common, and many patients are heterozygotes. The abnormal CFH complexes with the normal CFH, inactivating it. CFH is the major downregulator of the alternative complement cascade as it degrades C3b. Loss of CFH activity allows for unopposed C3b activity and complement activation. Other mutations are in complement factor I (CFI), which cleaves C3b and C4b. Mutations in membrane cofactor protein (MCP), a cofactor for CFI, in C3 itself, in complement factor B (component of C3b), and in thrombomodulin can also cause atypical HUS. The type of mutation determines the clinical course of atypical HUS, with CFH, CFI, CFB, and thrombomodulin mutations having rates of death or end-stage renal disease of more than 50%. HUS recurs in more than three quarters of patients with CFH and CFI mutations. Some patients are compound heterozygotes with mutations in two of the genes previously noted. About 6% of patients have an autoantibody to CFH and have "autoimmune HUS."

Although atypical or familial HUS is a disorder caused by a genetic deficiency in most cases, onset may not occur until middle age. About 67% of atypical HUS occurs during childhood, with almost all patients with anti-CFH antibodies diagnosed before age 16. Oral contraceptive (OC) use may trigger HUS in 8% of patients with CFH and 20% of patients with CFI mutations.

The treatment of HUS is primarily supportive, including management of renal failure. Plasma exchange may be used but unfortunately does not have the same degree of benefit in HUS as in TTP. Eculizumab, a humanized monoclonal antibody to C5, is effective for the treatment of complement-mediated HUS caused by CFH and CFI mutations and is the first treatment approved by the U.S. Food and Drug Administration (FDA) for atypical HUS. Some data suggest eculizumab may also be beneficial for Stx-associated HUS, but this remains controversial. The cost of the medication, about \$400,000 (U.S.) per year, may be prohibitive.

Corticosteroids, azathioprine, vincristine, MMF, and rituximab may be used in atypical HUS. The role of kidney transplantation in atypical HUS is unclear because of the high rate of recurrence and loss of the graft. The likelihood for a successful outcome after transplantation depends on mutation type.

**Ardissino G, et al:** Skin involvement in atypical hemolytic uremic syndrome. *Am J Kidney Dis* 2014; 63(4):652–655.

**Beloncle F, et al:** Splenectomy and/or cyclophosphamide as salvage therapies in thrombotic thrombocytopenic purpura: the French TMA Reference Center experience. *Transfusion* 2012; 52:2436.

**Benhamou Y, et al:** Development and validation of a predictive model for death in acquired severe ADAMTS13 deficiency-associated idiopathic thrombotic thrombocytopenic purpura: the French TMA Reference Center experience. *Haematologica* 2012; 97:1181.

**Bouw MC, et al:** Thrombotic thrombocytopenic purpura in childhood. *Pediatr Blood Cancer* 2009; 53:537.

**Burns ER, et al:** Morphologic diagnosis of thrombotic thrombocytopenic purpura. *Am J Hematol* 2004; 75:18.

**Cataland SR, Wu HM:** How I treat: the clinical differentiation and initial treatment of adult patients with atypical hemolytic uremic syndrome. *Blood* 2014; 123(16):2478–2484.

**Delmas Y, et al:** Outbreak of *Escherichia coli* O104:H4 haemolytic uraemic syndrome in France: outcome with eculizumab. *Nephrol Dial Transplant* 2014; 29(3):565–572.

**Feys HB, et al:** ADAMTS13 in health and disease. *Acta Haematol* 2009; 121:183.

**Froissart A, et al:** Efficacy and safety of first-line rituximab in severe, acquired thrombotic thrombocytopenic purpura with a suboptimal response to plasma exchange: experience of the French Thrombotic Microangiopathies Reference Center. *Crit Care Med* 2012; 40:104.

**George JN:** How I treat patients with thrombotic thrombocytopenic purpura. 2010. *Blood* 2010; 116:4060.

**Kielstein JT, et al:** Best supportive care and therapeutic plasma exchange with or without eculizumab in Shiga-toxin-producing *E. coli* O104:H4 induced haemolytic-uraemic syndrome: an analysis of the German STEC-HUS registry. *Nephrol Dial Transplant* 2012; 27:3807.

**Legendre CM, et al:** Terminal complement inhibitor eculizumab in atypical hemolytic-uremic syndrome. *N Engl J Med* 2013; 368(23):2169–2181.

**Lotta LA, et al:** ADAMTS13 mutations and polymorphisms in congenital thrombotic thrombocytopenic purpura. *Hum Mutat* 2009; Oct 21. [Epub.]

**Marques MB:** Thrombotic thrombocytopenic purpura and heparin-induced thrombocytopenia: two unique causes of life-threatening thrombocytopenia. *Clin Lab Med* 2009; 29:321.

**Menne J, et al:** Validation of treatment strategies for enterohaemorrhagic *Escherichia coli* O104:H4 induced haemolytic uraemic syndrome: case-control study. *BMJ* 2012; 345:e4565.

**Nayer A, Asif A:** Atypical hemolytic-uremic syndrome: a clinical review. *Am J Ther* 2014; Mar 27. [Epub ahead of print.]

**Siau K, Varughese M:** Thrombotic microangiopathy following docetaxel and trastuzumab chemotherapy: a case report. *Med Oncol* 2010; 27(4):1057–1059.

**Scully M, et al:** Guidelines on the diagnosis and management of thrombotic thrombocytopenic purpura and other thrombotic microangiopathies. *Br J Haematol* 2012; 158:323.

**Tsai HM:** Thrombotic thrombocytopenic purpura and the atypical hemolytic-uremic syndrome: an update. *Hematol Oncol Clin North Am* 2013; 27(3):565–584.

**Van Goor H, et al:** Adamalysins in biology and disease. *J Pathol* 2009; 219:277.

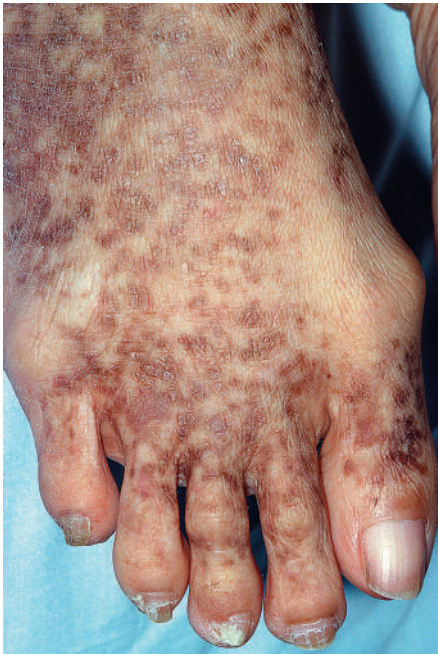**Yilmaz M, et al:** Cyclosporin A therapy on idiopathic thrombotic thrombocytopenic purpura in the relapse setting: two case reports and a review of the literature. *Transfusion* 2013; 53:1586.

## NONTHROMBOCYTOPENIC PURPURA (DYSPROTEINEMIC PURPURA)

### Cryoglobulinemia and cryofibrinogenemia

The term cryoglobulinemia refers to the presence in the serum of proteins that precipitate at temperatures below 37°C and redissolve on rewarming. These tend to be chronic conditions, unless the underlying disease process is treated. Abnormal serum proteins behaving as cryoglobulins and cryofibrinogens may be IgG, IgM, or both. Type I cryoglobulinemia results from monoclonal immunoglobulins, usually IgM and less frequently IgG, IgA, or light chains caused by an underlying lymphoproliferative disorder, usually multiple myeloma or macroglobulinemia. Type II cryoglobulinemia results from monoclonal IgM (rarely IgG and IgA) immunoglobulins, which have rheumatoid factor (RF)-like activity and form complexes to the constant, fragment crystallizable (Fc) region of polyclonal IgG. This can occur in many connective tissue diseases and may also be caused by the B-cell proliferation seen in hepatitis C virus (HCV) infection. Type III cryoglobulinemia (mixed cryoglobulinemia), in which the cryoglobulins





**Fig. 35-8**  
Cryoglobulinemia.

are polyclonal and of various classes, is associated with HCV infection in more than 90% of cases. Together, types II and III cryoglobulinemia constitute 80% of cases.

Purpura is most likely to occur on exposed surfaces after cold exposure. It may be of sudden onset and may clear rapidly once the patient is kept warm. Marked brown hyperpigmentation of the dorsal feet, at times in a livedoid pattern, may suggest this diagnosis. Cryoglobulinemia can be the cause of chronic leg ulcers (Fig. 35-8). An unusual clinical presentation of type I cryoglobulinemia in association with multiple myeloma is follicular hyperkeratosis of the central face, especially the nose.

Systemic complications in type I cryoglobulinemia relate primarily to hyperviscosity and thrombosis. Manifestations of type II and III disease are multisystem and similar to those of other types of small-vessel to medium-vessel vasculitis, including arthralgias and myalgias, glomerulonephritis, interstitial pulmonary infiltrates, and neuropathy.

In monoclonal disease, the biopsy reveals amorphous, jelly-like, eosinophilic material in the vessel lumen. In types II and III cryoglobulinemia, a skin biopsy reveals classic leukocytoclastic vasculitis and less often, features of polyarteritis nodosa.

Asymptomatic disease need not be treated. With symptomatic disease, the aim of therapy is to treat, eliminate, or control the underlying condition and to suppress the associated immune response. For type I cryoglobulinemia, this means addressing the associated myeloproliferative disorder. Thalidomide was beneficial in one patient with a type I cryoglobulin, retiform purpura and clonal plasma cell expansion. For cryoglobulinemia associated with HCV or connective tissue disease, options include systemic corticosteroids, colchicine, immunosuppressants such as cyclophosphamide or azathioprine, and IVIG. Plasmapheresis is indicated for severe or refractory disease. Simple plasma exchange can be helpful, but cryofiltration apheresis is the best method to remove cryoproteins in the treatment of cryoprecipitate-induced diseases. Reduction of the HCV viral load is the long-term solution in HCV-associated cases and can result in disappearance of the cryoglobulins. Improved treatment options for HCV are increasingly available. Mixed cryoglobulinemia with renal, neurologic, and cardiac disease refractory to other treatments may respond to rituximab.

Compared with cryoglobulinemia, cryofibrinogenemia is less often symptomatic and generally more readily treatable. Patients most often present with purpura, skin necrosis, and arthralgias; ulceration and gangrene can result. The precipitating cryofibrinogen is a cold-insoluble complex of fibrin, fibrinogen, and fibrin split products with albumin, cold-insoluble globulin, factor VIII, and plasma proteins. Associated collagen vascular disorders, infections, and malignancies are significantly more common in patients with both cryofibrinogenemia and cryoglobulins than in those with isolated cryofibrinogenemia. Cryofibrinogen has been associated with calciphylaxis in the setting of renal disease and livedoid vasculopathy when accompanied by other prothrombotic risks. Familial primary cryofibrinogenemia manifests as painful purpura, with slow-healing ulcerations and edema of both feet during the winter months. Therapy beyond cold avoidance is with aspirin, corticosteroids, or stanazol for moderate disease. Immunosuppressive and antithrombotic therapies are given for severe disease. Response rates are high, but relapses are common.

**Batiste D, et al:** Sustained exacerbation of cryoglobulinemia-related vasculitis following treatment of hepatitis C with peginterferon alfa. *Eur J Gastroenterol Hepatol* 2004; 16:701.

**Bryce AH, et al:** Natural history and therapy of 66 patients with mixed cryoglobulinemia. *Am J Hematol* 2006; 81(7):511–518.

**Cavallo R, et al:** Rituximab in cryoglobulinemic peripheral neuropathy. *J Neurol* 2009; 256:1076.

**Da Silva Fucuta Pereira P, et al:** Long-term efficacy of rituximab in hepatitis C virus-associated cryoglobulinemia. *Rheumatol Int* 2010; 30(11):1515–1518.

**De Rosa FG et al:** Observations on cryoglobulin testing. I. The association of cryoglobulins containing rheumatoid factors with manifestation of cryoglobulinemic vasculitis. *J Rheumatol* 2009; 36:1953.

**De Rosa FG, et al:** Observations on cryoglobulin testing. II. The association of oligoclonal mixed cryoglobulinemia with cirrhosis in patients infected with hepatitis C virus. *J Rheumatol* 2009; 36:1956.

**Ferri C, et al:** Mixed cryoglobulinemia: demographic, clinical, and serologic features and survival in 231 patients. *Semin Arthritis Rheum* 2004; 33:355.

**Harati A, et al:** Skin disorders in association with monoclonal gammopathies. *Eur J Med Res* 2005; 10:93.

**Iannuzzella F, et al:** Management of hepatitis C virus-related mixed cryoglobulinemia. *Am J Med* 2010; 123(5):400–408.

**Mazzaro C, et al:** Efficacy and safety of peginterferon alfa-2b plus ribavirin for HCV-positive mixed cryoglobulinemia: a multicentre open-label study. *Clin Exp Rheumatol* 2011; 29(6):933–941.

**Michaud M, Pourrat J:** Cryofibrinogenemia. *J Clin Rheumatol* 2013; 19(3):142–148.

**Ramos-Casals M, et al:** The cryoglobulinemias. *Lancet* 2012; 379(9813):348–360.

**Rayhill SC, et al:** Positive serum cryoglobulin is associated with worse outcome after liver transplantation for chronic hepatitis C. *Transplantation* 2005; 80:448.

**Requena L, et al:** Follicular spicules of the nose: a peculiar cutaneous manifestation of multiple myeloma with cryoglobulinemia. *J Am Acad Dermatol* 1995; 32:834.

**Resnik KS:** Intravascular eosinophilic deposits—when common knowledge is insufficient to render a diagnosis. *Am J Dermatopathol* 2009; 31:211.

**Rongioletti F, et al:** The histological and pathogenetic spectrum of cutaneous disease in monoclonal gammopathies. *J Cutan Pathol* 2008; 35:705.

**Saadoun D, et al:** Cryofibrinogenemia: new insights into clinical and pathogenic features. *Am J Med* 2009; 122(12):1128.

**Sampson A, Callen JP:** Thalidomide for type 1 cryoglobulinemic vasculopathy. *Arch Dermatol* 2006; 142:972.

**Sinha D, et al:** Cryofiltration in the treatment of cryoglobulinemia and HLA antibody-incompatible transplantation. *Ther Apher Dial* 2012; 16(1):91–96.

**Tallarita T, et al:** Successful combination of rituximab and plasma exchange in the treatment of cryoglobulinemic vasculitis with skin ulcers: a case report. *Cases J* 2009; 2:7859.

**Terrier B, et al:** The spectrum of type I cryoglobulinemia vasculitis: new insights based on 64 cases. *Medicine (Baltimore)* 2013; 92:61.

**Yang CH, et al:** Long-term plasmapheresis in conjunction with thalidomide and dexamethasone for the treatment of cutaneous ulcers and neovascular glaucoma in recalcitrant type I cryoglobulinemia. *JAMA Dermatol* 2014; 150(4):426–428.

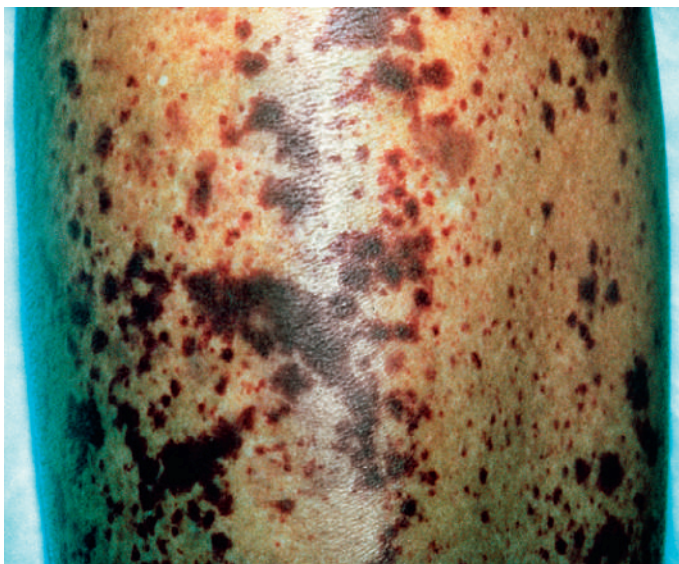
## Waldenström hyperglobulinemic purpura (purpura hyperglobulinemica)

Waldenström hyperglobulinemic purpura presents with episodic showers of petechiae that may burn or sting, occurring mainly on the lower extremities. The dorsa of the feet are intensely involved, and the petechiae diminish on the ascending parts of the feet (Fig. 35-9). A diffuse “peppery” distribution is typically noted, resembling Schamberg’s disease. The petechiae may be induced or aggravated by prolonged standing or walking or by wearing constrictive garters or stockings.

Serum protein electrophoresis demonstrates a broad-based peak (polyclonal hypergammaglobulinemia). The bulk of the protein increase is IgG, although occasionally, increased amounts of IgA are also found. IgM is usually normal or decreased. RF in varying amounts is present in almost all patients. Antithyroglobulins, increased erythrocyte sedimentation rate (ESR), leukopenia, antinuclear factors, and proteinuria may be found. Almost 80% of patients with hypergammaglobulinemic purpura of Waldenström have antibodies to Ro/SSA.

Hyperglobulinemic purpura occurs most frequently in women between ages 18 and 40 and is often seen with Sjögren syndrome and rheumatoid arthritis. Adverse fetal outcomes in these women may be associated with the presence of SSA or SSB autoantibodies. Hyperglobulinemic purpura may also be a primary, chronic, benign illness. When it is associated with hepatitis C, it has a predilection for men and has manifestations that usually last longer than those associated with Sjögren syndrome.

In about one third of patients, leukocytoclastic vasculitis is present. These patients have a higher prevalence of articular involvement, peripheral neuropathy, Raynaud phenomenon, renal involvement, ANA, RF, and anti-Ro/SSA antibodies. The course of the disease is essentially benign but chronic.



**Fig. 35-9** Waldenström hyperglobulinemic purpura.

Rare deaths are related to associated cryoglobulin disease. Hyperglobulinemic purpura may be a manifestation or harbinger of connective tissue or hematopoietic diseases, and rarely, progression to myeloma has been reported.

Patients often improve with support stockings. Corticosteroids should be reserved for severe disease. Indomethacin and hydroxychloroquine may be of value in the treatment of milder disease, especially in patients who have connective tissue disease or are SSA/B (Ro/La) positive. Aspirin and colchicine have been used with some success.

**Al-Mayouf SM, et al:** Hypergammaglobulinaemic purpura associated with IgG subclass imbalance and recurrent infection. *Clin Rheumatol* 2000; 19:499.

**Jolly EC, et al:** “Benign” hypergammaglobulinemic purpura is not benign in pregnancy. *Clin Rheumatol* 2009; 28:S11.

**Lewin JM, et al:** Hypergammaglobulinemic purpura of Waldenström. *Dermatol Online J* 2012; 18(12):2.

**Malaviya AN, et al:** Hypergammaglobulinemic purpura of Waldenström: report of 3 cases with a short review. *Clin Exp Rheumatol* 2000; 18:518.

**Nikam BP, et al:** Primary benign hypergammaglobulinemic purpura of Waldenström masquerading as disseminated Schamberg’s purpura. *Indian J Dermatol Venereol Leprol* 2011; 77(2):205–208.

**Ramos-Casals M, et al:** Cutaneous vasculitis in primary Sjögren syndrome: classification and clinical significance of 52 patients. *Medicine (Baltimore)* 2004; 83:96.

## Waldenström macroglobulinemia

Waldenström macroglobulinemia (WM) is a lymphoplasma-cytic lymphoma of B lymphocytes characterized by elevated levels of circulating IgM. Disease manifestations relate to hyperviscosity and vascular complications resulting from the circulating paraprotein as well as from neoplastic lymphoplasma-cytic infiltration of important structures such as the bone marrow, lymph nodes, spleen, and other organs. Lymphadenopathy, hepatosplenomegaly, and anemia are characteristic.

Immunoglobulin M is responsible for some of the skin manifestations of the disorder. Elderly men are predominantly affected, and there is a strong familial predisposition. The cutaneous manifestations of WM can be divided into two categories: nonspecific and specific. Nonspecific manifestations are related to the hyperviscosity syndrome created by the circulating IgM and include purpura of the skin and mucous membranes. The purpura may be surmounted by tense giant bullae. Bleeding of the gums and epistaxis can occur. The IgM may behave as a cryoglobulin, resulting in purpura, livedo, cutaneous ulcerations, and vasculitis. Urticaria (some patients satisfy the diagnostic criteria for Schnitzler syndrome or progress from that disorder), disseminated xanthoma, and amyloid deposition can be seen. Specific skin lesions are of two types: specific skin deposits of aggregates of IgM (cutaneous macroglobulinosis) and cutaneous infiltrates with neoplastic lymphoid cells. The specific skin lesions usually occur once the diagnosis of WM is already known, but infrequently the skin lesions are the first clue to the diagnosis. The specific IgM deposits present clinically as subepidermal blisters (clinically and histologically resembling bullous amyloidosis) or translucent 1–3 mm papules. They are found most often on the lower extremity, even on the sole. Slight hyperkeratosis may be seen over the papules.

Histologically, the papules are composed of dermal nodular, homogeneous, and fissured pink deposits that tend to involve newly formed vessels. They are periodic acid-Schiff (PAS) positive but negative for Congo red. DIF identifies the dermal globules as being composed of IgM and is a useful diagnostic approach. When WM results in cutaneous lymphoid aggregates, the presentation is very nonspecific. Small, red-brown



to violaceous macules, papules, nodules, or plaques may be present, usually on the face. Rosacea is often initially entertained as a diagnosis. Widespread skin involvement with a “deck-chair sign” (sparing the abdominal skinfolds) has been reported.

The natural history of WM is that of an indolent myelodysplasia. Treatment is directed at reducing the volume of neoplastic cells and should be managed by an oncologist. Most asymptomatic patients are followed or treated only when clinical disease occurs. Chlorambucil, cyclophosphamide, fludarabine, systemic corticosteroids, and rituximab or bortezomib, used alone or in combination, are initial therapeutic options. Plasmapheresis can be effective in controlling acute symptoms of hyperviscosity syndrome. Rituximab is not used as a monotherapy in WM patients with hyperviscosity because they may experience a flare of their disease. Soluble CD27 can be used as a marker of disease response to therapy.

**Ansell SM, et al:** Diagnosis and management of Waldenström macroglobulinemia: Mayo stratification of macroglobulinemia and risk-adapted therapy (mSMART) guidelines. *Mayo Clin Proc* 2010; 85:824.

**Autier J, et al:** Cutaneous Waldenström’s macroglobulinemia with “deck-chair” sign treated with cyclophosphamide. *J Am Acad Dermatol* 2005; 52:45.

**Camp BJ, Magro CM:** Cutaneous macroglobulinosis: a case series. *J Cutan Pathol* 2012; 39(10):962–970.

**Chan I, et al:** Cutaneous Waldenström’s macroglobulinaemia. *Clin Exp Dermatol* 2003; 28:491.

**Ciccarelli BT, et al:** Soluble CD27 is a faithful marker of disease burden and is unaffected by the rituximab-induced IgM flare, as well as by plasmapheresis, in patients with Waldenström’s macroglobulinemia. *Clin Lymphoma Myeloma* 2009; 9:56.

**Dimopoulos MA, et al:** Rituximab-based treatments in Waldenström’s macroglobulinemia. *Clin Lymphoma Myeloma* 2009; 9(1):59–61.

**Dimopoulos MA, et al:** Primary therapy of Waldenström macroglobulinemia (WM) with weekly bortezomib, low-dose dexamethasone, and rituximab (BDR): long-term results of a Phase 2 study of the European Myeloma Network (EMN). *Blood* 2013; 122:3276.

**Harnalikar M, et al:** Keratotic vascular papules over the feet: a case of Waldenström’s macroglobulinaemia-associated cutaneous macroglobulinosis. *Clin Exp Dermatol* 2010; 35(3):278–281.

**Libow LF, et al:** Cutaneous Waldenström’s macroglobulinemia: report of a case and overview of the spectrum of cutaneous disease. *J Am Acad Dermatol* 2001; 45(6 Suppl):S202.

**Oberschmid B, et al:** M protein deposition in the skin: a rare manifestation of Waldenström macroglobulinemia. *Int J Hematol* 2011; 93(3):403–405.

**Rajkumar SV, et al:** Monoclonal gammopathy of undetermined significance, Waldenström macroglobulinemia, AL amyloidosis, and related plasma cell disorders: diagnosis and treatment. *Mayo Clin Proc* 2006; 81:693.

**Rongioletti F, et al:** The histological and pathogenetic spectrum of cutaneous disease in monoclonal gammopathies. *J Cutan Pathol* 2008; 35:705.

**Tedeschi A, et al:** Fludarabine plus cyclophosphamide and rituximab in Waldenström macroglobulinemia: an effective but myelosuppressive regimen to be offered to patients with advanced disease. *Cancer* 2012; 118(2):434–443.

**Wolgast GM, et al:** Firm papules on lower extremities of 52-year-old male. *Am J Dermatopathol* 2005; 27:313.

## PURPURA SECONDARY TO CLOTTING DISORDERS

Hereditary disorders of blood coagulation usually result from a deficiency or qualitative abnormality of a single coagulation factor, as in hemophilia or von Willebrand’s disease. Acquired disorders usually result from multiple coagulation factor deficiencies, as in liver disease, biliary tract obstruction, malabsorption, or drug ingestion. Acquired clotting disorders may also involve platelet abnormalities, as in DIC. Hemorrhagic

manifestations are common and may be severe, especially in hereditary forms. Ecchymoses and subcutaneous hematomas are common, especially on the legs. Severe hemorrhage may follow trauma, and hemarthrosis is frequent. Other hemorrhagic manifestations include respiratory obstruction resulting from hemorrhage into the tongue, throat, or neck; epistaxis; gastrointestinal (GI) and genitourinary tract bleeding; and rarely CNS hemorrhage.

**Carpenter SL, et al:** Evaluating for suspected child abuse: conditions that predispose to bleeding. Section on Hematology/Oncology and Committee on Child Abuse and Neglect of the American Academy of Pediatrics: *Pediatrics* 2013; 131(4):e1357–e1373.

**Kruse-Jarres R, et al:** Identification and basic management of bleeding disorders in adults. *J Am Board Fam Med* 2014; 27(4):549–564.

## DRUG-INDUCED AND FOOD-INDUCED PURPURA

Drug-induced purpura may be related to platelet destruction, vessel fragility, interference with platelet function, or vasculitis. Drug-induced thrombocytopenic purpura is discussed earlier in this chapter. Purpurogenic drugs include aspirin and other NSAIDs, allopurinol, thiazides, gold, sulfonamides, cephalosporins, hydralazine, phenytoin, quinidine, ticlopidine, and penicillin. Combinations of diphenhydramine and pyridylidone can induce purpuric mottling and areas of necrosis. Cocaine-induced thrombosis with infarctive skin lesions is associated with skin popping.

Topical EMLA cream can induce purpura within 30 min of application, a result of a toxic effect on the capillary endothelium. Agave ingestion can induce purpura and vasculitis-like lesions because of a direct toxic effect on the endothelium. Purpura has been associated with the use of acetaminophen in patients with infectious mononucleosis. Small-vessel vasculitis, including urticarial vasculitis, has been caused by the ingestion of tartrazine dye. Pseudoephedrine can induce a pigmented purpura-like reaction. Patch testing reproduces the eruption. Purpuric contact dermatitis is rare and usually caused by rubber chemical or textile dyes.

**Aster RH:** Can drugs cause autoimmune thrombocytopenic purpura? *Semin Hematol* 2000; 37:229.

**Barabash-Neila R, et al:** *Agave americana* causing irritant contact dermatitis with a purpuric component. *Actas Dermosifiliogr* 2011; 102(1):74–76.

**D’Addario SF, et al:** Minocycline-induced immune thrombocytopenia presenting as Schamberg’s disease. *J Drugs Dermatol* 2003; 2:320.

**Diaz-Jara M, et al:** Pigmented purpuric dermatosis due to pseudoephedrine. *Contact Dermatitis* 2002; 46:300.

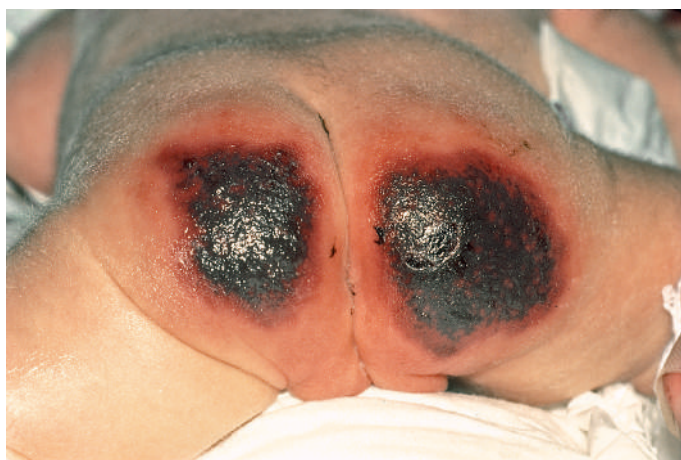**Roldán-Marín R, de-la-Barreda Becerril F:** Petechial and purpuric eruption induced by lidocaine/prilocaine cream: a rare side effect. *J Drugs Dermatol* 2009; 8(3):287–288.

**Verma GK, et al:** Purpuric contact dermatitis from footwear. *Contact Dermatitis* 2007; 56:362.

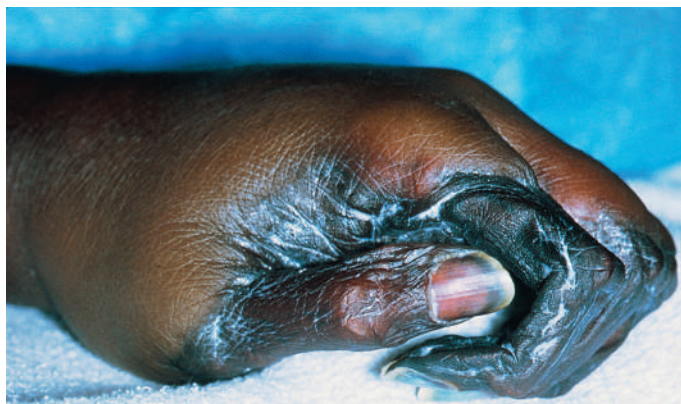## PURPURA FULMINANS

Purpura fulminans is a rapidly progressive and fatal syndrome of intravascular thrombosis, circulatory collapse, and cutaneous infarction. Also known as purpura gangrenosa, there are three forms of the disease, as follows:

1. Infectious (associated with bacterial or viral infection and DIC)
2. Neonatal/hereditary (deficiency of protein C or S, or antithrombin III)
3. Idiopathic (generally following a febrile illness, leading to acquired protein S deficiency)



**Fig. 35-10** Neonatal purpura fulminans secondary to homozygous protein C deficiency.

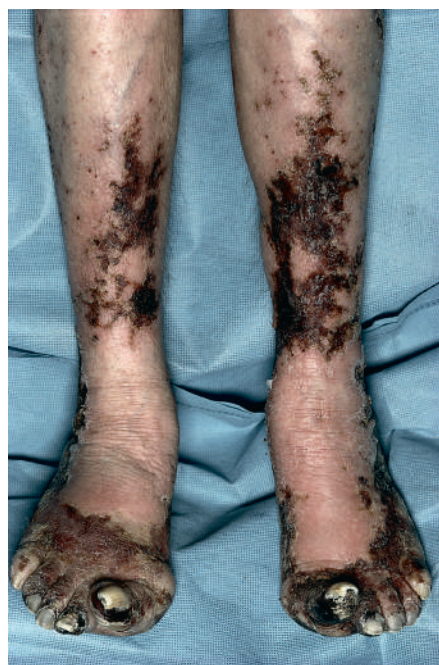

**Fig. 35-11** Purpura fulminans.

The most common form is that associated with an infectious illness, usually bacterial septicemia (most often meningococemia) but sometimes a viral infection (varicella). Asplenic patients, who are at risk for pneumococcal or meningococcal sepsis, are predisposed to purpura fulminans. Neonates with homozygous protein C or protein S deficiencies may have purpura fulminans (Fig. 35-10). Some patients develop transient deficiencies of proteins C and S in response to infection. A number of reported cases of purpura fulminans have been associated with infections and factor V Leiden mutation, with normal protein C and protein S levels. Meningococemia, streptococcal sepsis, *Capnocytophaga* sepsis (from a dog bite), staphylococcal septicemia, and urosepsis are the most common causes. Rickettsial disease and malaria may present as purpura fulminans. Active human herpesvirus 6 (HHV-6) replication with acquired protein S deficiency and purpura fulminans has been described.

Purpura fulminans presents as the sudden appearance of large ecchymotic areas, especially prominent over the extremities, progressing to acral hemorrhagic skin necrosis. (Fig. 35-11). The term “symmetrical peripheral gangrene” is used to describe cases when acral gangrene is present. Fever, shock, and DIC usually accompany the skin lesions, which on biopsy show noninflammatory necrosis with platelet-fibrin thrombi occluding the blood vessels.

Other disease, such as the fibrinolysis syndrome, may have purpura fulminans as part of the symptom complex. An acquired form has been reported secondary to alcohol and acetaminophen ingestion, as well as from diclofenac or propylthiouracil. When purpura fulminans occurs in the setting



**Fig. 35-12**  
Catastrophic antiphospholipid antibody syndrome.

of SLE, the catastrophic antiphospholipid antibody syndrome (CAPS) must be considered (Fig. 35-12). Purpura fulminans has been reported as a presenting feature of Churg-Strauss syndrome and other ANCA-positive vasculitides.

Management is usually supportive, with treatment of the underlying disease process (e.g., antibiotics for septicemia) and replacement therapy using fresh frozen plasma. Protein C and antithrombin replacement is useful in treating patients shown to have deficiencies. Plasmapheresis has been used in nonbacterial cases. Heparin anticoagulation can be used. Despite these measures, amputation (often multiple extremities) and death continue to occur in patients with severe disease. The use of pressors to maintain blood pressure during the septic episode may contribute to reduced peripheral circulation and peripheral tissue damage. Fasciotomy during the initial management of these patients may reduce the depth of soft tissue involvement and the extent of amputation.

**Akman A, et al:** Unusual location of purpura fulminans associated with acquired protein C deficiency and administration of propylthiouracil. *Clin Exp Dermatol* 2009; 34:e463.

**Boccaro O, et al:** Nonbacterial purpura fulminans and severe autoimmune acquired protein S deficiency associated with human herpesvirus-6 active replication. *Br J Dermatol* 2009; 161:181.

**Choudhary S, et al:** Antiphospholipid antibody syndrome presenting with purpura fulminans. *Int J Dermatol* 2013; 52(8):1026–1027.

**Cooper JS, et al:** Hyperbaric oxygen: a useful adjunct for purpura fulminans—case report and review of the literature. *Undersea Hyperb Med* 2014; 41(1):51–57.

**Culpeper KS, et al:** Purpura fulminans. *Lancet* 2003; 361:384.

**Davis MD, et al:** Presentation and outcome of purpura fulminans associated with peripheral gangrene in 12 patients at Mayo Clinic. *J Am Acad Dermatol* 2007; 57:944.

**Ghosh SK, et al:** Symmetrical peripheral gangrene: a prospective study of 14 consecutive cases in a tertiary-care hospital in eastern India. *J Eur Acad Dermatol Venereol* 2010; 24(2):214–218.

**Ghosh SK, et al:** Purpura fulminans: a cutaneous marker of disseminated intravascular coagulation. *West J Emerg Med* 2009; 10:41.

**Kato Y, et al:** Purpura fulminans: an unusual manifestation of severe falciparum malaria. *Intensive Care Med* 2007; 33:1168.

**Lerolle N, et al:** Assessment of the interplay between blood and skin vascular abnormalities in adult purpura fulminans. *Am J Respir Crit Care Med* 2013; 188(6):684–692.



**Price VE, et al:** Diagnosis and management of neonatal purpura fulminans. *Semin Fetal Neonatal Med* 2011; 16(6):318–322.

**Regnault V, et al:** Anti-protein S antibodies following a varicella infection: detection, characterization and influence on thrombin generation. *J Thromb Haemost* 2005; 3:1243.

**Staquet P, et al:** Detection of *Neisseria meningitidis* DNA from skin lesion biopsy using real-time PCR: usefulness in the aetiological diagnosis of purpura fulminans. *Intensive Care Med* 2007; 33:1168.

**Talwar A, et al:** Spectrum of purpura fulminans: report of three classical prototypes and review of management strategies. *Indian J Dermatol Venereol Leprol* 2012; 78(2):228.

**Thornsberry LA, et al:** The skin and hypercoagulable states. *J Am Acad Dermatol* 2013; 69(3):450–462.

**Watt SG, et al:** Purpura fulminans in paroxysmal nocturnal haemoglobinuria. *Br J Haematol* 2007; 137:271.

**Zenz W, et al:** Use of recombinant tissue plasminogen activator in children with meningococcal purpura fulminans: a retrospective study. *Crit Care Med* 2004; 32:1777.

## DISSEMINATED INTRAVASCULAR COAGULATION

Up to two thirds of patients with DIC have skin lesions, which may be the initial manifestation of the syndrome. Minute, widespread petechiae; ecchymoses; ischemic necrosis of the skin; and hemorrhagic bullae are the usual findings. Purpura fulminans may supervene and progress to symmetric peripheral gangrene. DIC may be initiated by a variety of disorders, including septicemic hypotension, hypoxemia, acidosis, malignancies, chemotherapy, obstetric crises, antiphospholipid antibody syndrome, SLE, arthropod envenomation, and leukemia. Long-term treatment with granulocyte colony-stimulating factor (G-CSF) has also been reported to precipitate DIC. Children with kaposiform hemangioendotheliomas are at risk for consumptive coagulopathy (Kasabach-Merritt syndrome).

The disease results from widespread intravascular coagulation in which certain coagulation factors are consumed faster than they can be replaced. Laboratory findings include decreased platelets, decreased fibrinogen (only in severe cases; normal in 57% of cases), elevated PT/PTT (50–60% of cases), increased fibrin degradation products, and elevated D-dimers. Control of the underlying disease is the paramount consideration, and often, antibiotics or surgical drainage of loculated infection may lead to spontaneous resolution of DIC. Bleeding is treated with platelet transfusion in the presence of thrombocytopenia and fresh frozen plasma to correct coagulation factor abnormalities. Heparin is considered when thrombosis in the form of venous, arterial, or widespread microvascular thrombosis (purpura fulminans) is present. Protein C concentrate may benefit patients with severe sepsis and DIC.

**Levi M, Meijers JC:** DIC: which laboratory tests are most useful. *Blood Rev* 2011; 25(1):33–37.

**Levi M, et al:** Guidelines for the diagnosis and management of disseminated intravascular coagulation. British Committee for Standards in Haematology. *Br J Haematol* 2009; 145:24.

**Wada H, et al:** Expert consensus for the treatment of disseminated intravascular coagulation in Japan. *Thromb Res* 2010; 125(1):6–11.

## CONGENITAL FIBRINOGEN DISORDERS

Deficiencies of fibrinogen are classified as reductions in quantity (afibrinogenemia or hypofibrinogenemia) or in quality (dysfibrinogenemia). Afibrinogenemia occurs at a rate of about 1 case per 1 million population. It may present at birth with umbilical cord bleeding, Epistaxis, menorrhagia, hemarthrosis (much less than in hemophilia and with far fewer

musculoskeletal sequelae), trauma, and surgery-related bleeding can occur. The severity of the bleeding tendency is highly variable from patient to patient, and some have no bleeding problems. Pregnancy complications include recurrent miscarriage and peripartum hemorrhage. Ironically, because of the loss of the antithrombotic effect of fibrinogen, thrombotic events are increased in afibrinogenemia. Arterial and venous thrombosis can occur. Patients with hypofibrinogenemia are seen more often; in general, they are less symptomatic and only occasionally require treatment. Hypofibrinogenemia may be associated with pregnancy losses and rarely with liver disease due to accumulation of abnormal fibrinogen in the endoplasmic reticulum of hepatocytes. Dysfibrinogenemia is asymptomatic in 55% of patients, 25% exhibit bleeding tendencies, and 20% tend to develop thrombosis. This group represents only 0.8% of patients with deep venous thrombosis, so screening for this condition is not cost-effective unless there is a family history. Mutations in the fibrinogen gene cluster cause all three of these fibrinogen disorders.

**Acharya SS, Dimichele DM:** Rare inherited disorders of fibrinogen. *Haemophilia* 2008; 14(6):1151–1158.

**Bornikova L, et al:** Fibrinogen replacement therapy for congenital fibrinogen deficiency. *J Thromb Haemost* 2011; 9(9):1687–1704.

**De Moerloose P, et al:** Congenital fibrinogen disorders: an update. *Semin Thromb Hemost* 2013; 39(6):585–595.

**Vu D, Neerman-Arbez M:** Molecular mechanisms accounting for fibrinogen deficiency: from large deletions to intracellular retention of misfolded proteins. *J Thromb Haemost* 2007; 5:125.

## BLUEBERRY MUFFIN BABY

Originally coined to describe the characteristic appearance of the purpuric lesions observed in newborns with congenital rubella, the term “blueberry muffin baby” is associated with many disorders that produce extramedullary erythropoiesis. The eruption consists of generalized, dark-blue to magenta, nonblanchable, indurated, round to oval, hemispheric papules ranging from 1 to 7 mm. Lesions favor the head, neck, and trunk. Etiologic factors include congenital infections (toxoplasmosis, rubella, cytomegalovirus, herpes simplex, parvovirus B19), hemolytic disease of the newborn (Rh incompatibility, blood group incompatibility), hereditary spherocytosis, twin transfusion syndrome, recombinant erythropoietin administration, neuroblastoma, rhabdomyosarcoma, extraosseal Ewing sarcoma, Langerhans cell histiocytosis, and congenital leukemia. Patients with multiple vascular disorders, such as hemangiopericytoma, hemangioma, blue rubber bleb nevus, and glomangioma, may be mistaken for a blueberry muffin baby. Evaluation should include a peripheral blood cell count, hemoglobin level, serologies for congenital TORCH infections, viral cultures, and a Coombs test. A skin biopsy may also be helpful in determining the cause.

**Brisman S, et al:** Blueberry muffin rash as the presenting sign of Aicardi-Goutieres syndrome. *Pediatr Dermatol* 2009; 26:432.

**Gaffin JM, Gallagher PG:** Picture of the month. Blueberry muffin baby (extramedullary hematopoiesis) due to congenital cytomegalovirus infection. *Arch Pediatr Adolesc Med* 2007; 161:1102.

**Holland KE, et al:** Neonatal violaceous skin lesions: expanding the differential of the “blueberry muffin baby.” *Adv Dermatol* 2005; 21:153.

**Krenova Z, et al:** Extraosseal Ewing sarcoma as a rare cause of the blueberry muffin baby syndrome: a case report and the review of the literature. *Am J Dermatopathol* 2011; 33(7):733–735.

**Lasek-Duriez A, et al:** Blueberry muffin baby and Langerhans' congenital cell histiocytosis. *Ann Dermatol Venereol* 2014; 141(2):130–133.

**Pandey V, et al:** Late-onset blueberry muffin lesions following recombinant erythropoietin administration in a premature infant. *J Pediatr Hematol Oncol* 2012; 34(7):534–535.

## MISCELLANEOUS PURPURIC MANIFESTATIONS

### Deep venous thrombosis

Deep venous thrombosis (DVT) is a common medical condition that can result in immediate (pulmonary embolism) or long-term (venous insufficiency, postphlebotic syndrome) consequences. Risk factors include female gender, obesity, immobilization, low atmospheric pressure, winter season, and the presence of cancer. In 35% of cancer-associated cases, the thrombosis is the first sign of the cancer. The use of erythropoiesis-stimulating agents doubles the risk of venous thromboembolism (VTE) for cancer patients. Hereditary mutations that result in a hypercoagulable state also increase the risk for VTE. The left leg is more often affected than the right. The mean age is 52 years. Significant superficial vein thrombosis is considered a risk factor for DVT. The risk of pulmonary embolism from DVT is the major concern.

On examination, a palpable cord, calf tenderness, unilateral edema, warmth, redness, and venous dilation may suggest the diagnosis. Pretest probability of DVT can be calculated with a simple tool such as the Wells score, and selective use of D-dimer can help exclude DVT. Ultrasound is used to confirm the diagnosis. Preventive strategies include exercise, weight control, and pharmacologic prophylaxis for high-risk patients, (e.g., postoperative, after stroke). Symptomatic proximal DVT is treated with at least 3 months of therapeutic anticoagulation to reduce the risk of pulmonary embolism.

**Bates SM, et al:** Clinical practice. Treatment of deep-vein thrombosis. *N Engl J Med* 2004; 351:268.

**Canonico M, Scarabin PY:** Hormone therapy and risk of venous thromboembolism among postmenopausal women. *Climacteric* 2009; 12:76.

**Dennis M, et al:** Effectiveness of intermittent pneumatic compression in reduction of risk of deep vein thrombosis in patients who have had a stroke (CLOTS 3): a multicentre randomised controlled trial. *Lancet* 2013; 382(9891):516–524.

**Doggen CJ:** High coagulant factors and venous thrombosis. *Blood* 2009; 114:2854.

**Fanikos J, et al:** Long-term complications of medical patients with hospital-acquired venous thromboembolism. *Thromb Haemost* 2009; 102:688.

**Keaton C, et al:** Antithrombotic therapy for VTE disease. In *Antithrombotic Therapy and Prevention of Thrombosis*, 9th edn: American College of Chest Physicians Evidence-Based Clinical Practice Guidelines. *Chest* 2012; 141(2 Suppl):e419S.

**Linkins LA, et al:** Selective D-dimer testing for diagnosis of a first suspected episode of deep venous thrombosis: a randomized trial. *Ann Intern Med* 2013; 158(2):93–100.

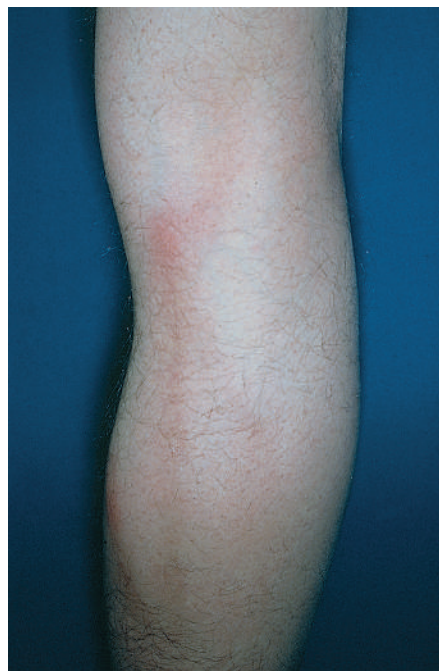**Lyman GH, Khorana AA:** Cancer, clots and consensus: new understanding of an old problem. *J Clin Oncol* 2009; 27:4821.

**Millar JA:** Selection of medical patients for prophylaxis of venous thromboembolism based on analysis of the benefit-hazard ratio. *Intern Med J* 2009; 39:606.

**Raskob GE, et al:** Apixaban versus enoxaparin for thromboprophylaxis after hip or knee replacement: pooled analysis of major venous thromboembolism and bleeding in 8464 patients from the ADVANCE-2 and ADVANCE-3 trials. *J Bone Joint Surg B* 2012; 94(2):257–264.

**Schulman S, et al:** Treatment of acute venous thromboembolism with dabigatran or warfarin and pooled analysis. *Circulation* 2014; 129(7):764–772.

**Shrier I, et al:** Effect of early physical activity on long-term outcome after venous thrombosis. *Clin J Sport Med* 2009; 19:487.



**Fig. 35-13** Superficial thrombophlebitis.

**Spyropoulos AC, et al:** Rates of venous thromboembolism occurrence in medical patients among the insured population. *Thromb Haemost* 2009; 102:951.

**Van der Velde EF, et al:** Comparing the diagnostic performance of 2 clinical decision rules to rule out deep vein thrombosis in primary care patients. *Ann Fam Med* 2011; 9(1):31.

### Superficial thrombophlebitis

Superficial venous thrombosis is an inflammatory thrombotic condition that classically presents with painful induration and erythema, often in a cordlike, linear or branching configuration (Fig. 35-13). Patients may also exhibit indurated subcutaneous nodules and overlying purpura or brown discoloration indicative of postinflammatory hyperpigmentation.

Primary hypercoagulable states that may be associated with superficial thrombophlebitis include deficiencies of antithrombin III, heparin cofactor II, protein C, protein S, and factor XII; disorders of tPA; abnormal plasminogen; dysfibrinogenemia; and lupus anticoagulant. Secondary hypercoagulable states include varicosities, malignancy (Trousseau syndrome), pregnancy, OC use, infusion of prothrombin complex concentrates, Behçet's disease, thromboangiitis obliterans, acute thrombophlebitis of superficial veins of the breast (Mondor's disease), septic thrombophlebitis, psittacosis, secondary syphilis, intravenous (IV) catheters, IV drugs (sugar solutions, protein hydrolysates, calcium, potassium, hypertonic concentrates, diazepam, nitrogen mustard, acridinylanilide, dacarbazine, and carmustine), and street drugs (cocaine, bulking agents such as paregoric, quinine, dextrose, sucrose, and lactose).

In the evaluation of superficial thrombophlebitis, the physician should consider the possibility of underlying deep venous disease. Superficial femoral vein involvement should alert the physician to underlying deep venous disease requiring anticoagulation. Lesser saphenous vein thrombophlebitis is also frequently associated with underlying DVT. Elliptical biopsies across the palpable cord may be required to exclude other considerations, such as sarcoidal granulomas, cutaneous polyarteritis nodosa, Kaposi sarcoma, and vasculotropic metastasis.



Treatment is directed at the underlying cause. Leg elevation and local heat will help to promote the dissolution of clots, which may take up to 8–12 weeks to resolve. Heparin therapy may reduce the incidence of thromboembolic complications in high-risk individuals.

### Mondor's disease

Mondor's disease occurs three times more frequently in women than in men. Most patients are between 30 and 60 years of age. The sudden appearance of a cordlike thrombosed vein along the anterolateral chest wall is characteristic (Fig. 35-14). It is at first red and tender and subsequently changes into a painless, tough, fibrous band. There are no systemic symptoms. Both sides of the chest have the same rate of involvement. Mondor's disease may be associated with strenuous exercise, pregnancy, IV drug abuse, jellyfish stings, breast cancer, and breast surgery. The condition represents a localized thrombophlebitis of the veins of the thoracoepigastric area. The veins involved are the lateral thoracic, thoracoepigastric, and superior epigastric. In the end stage, a thick-walled vein remains that has a hard, ropelike appearance and occasionally may result in a furrowing of the breast. Infrequently, a vein coursing up the inside of the upper arm and across or into the axilla may be thrombosed, leading to the "axillary web syndrome." Similar stringlike phlebitis findings have been described in the penis, antecubital fossa, groin, and abdomen. Treatment is symptomatic, with hot, moist dressings and analgesics or NSAIDs. The disease process runs its course in 3 weeks to 6 months.

**Alvarez-Garrido H, et al:** Mondor's disease. *Clin Exp Dermatol* 2009; 34(7):753–756.

**De Godoy JM, et al:** The association of Mondor's disease with protein S deficiency: case report and review of literature. *J Thromb Thrombolysis* 2002; 13:187.

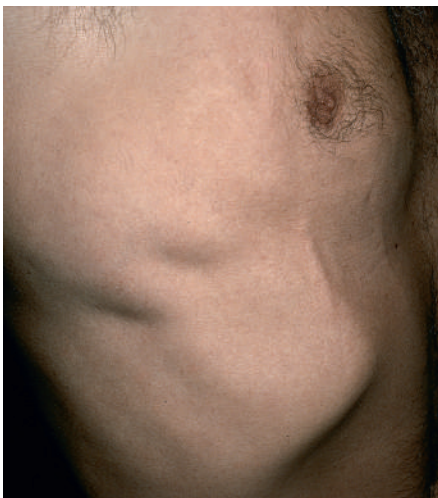**Di Nisio M, et al:** Treatment for superficial thrombophlebitis of the leg. *Cochrane Database Syst Rev* 2013; 4:CD004982.

**Quéré I, et al:** Superficial venous thrombosis and compression ultrasound imaging. *J Vasc Surg* 2012; 56(4):1032–1038.

**Samlaska CS, James WD:** Superficial thrombophlebitis. I. Primary hypercoagulable states. *J Am Acad Dermatol* 1990; 22:975.

**Samlaska CS, James WD:** Superficial thrombophlebitis. II. Secondary hypercoagulable states. *J Am Acad Dermatol* 1990; 23:1.

**Shoham Y, et al:** Axillary web syndrome: a variant of Mondor's disease, following excision of an accessory breast. *Harefuah* 2011; 150(12):893–894, 937, 936.



**Fig. 35-14** Mondor's disease.

### Postcardiotomy syndrome

Between 2 and 3 weeks after pericardiotomy, fever, pleuritis, pericarditis, or arthritis may appear together with petechiae on the skin and palate. Postcardiotomy syndrome may be confused with infectious mononucleosis and bacterial endocarditis.

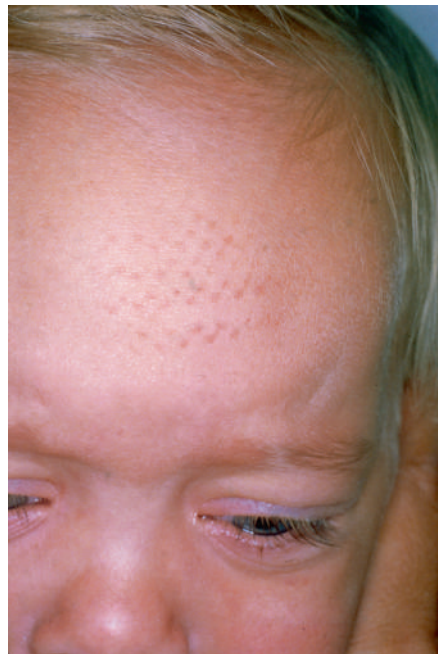### Orthostatic purpura (stasis purpura)

Prolonged standing or even sitting with the legs lowered (as in a bus, airplane, or train) may produce edema and a purpuric eruption on the lower extremities. Elevation of the legs and the use of elastic stockings are helpful preventive strategies.

### Obstructive or traumatic purpura

Purpura may be evoked by mechanical obstruction to the circulation, with resulting stress on the small vessels. This may be encountered in cardiac decompensation or after convulsions, vomiting episodes, Valsalva maneuver, pertussis, or sexual climax. Nonpalpable purpura has been reported in association with the use of a mucus-clearing device, which requires the patient to exhale forcefully through a flutter valve (flutter valve purpura). Local obstruction of the blood flow with purpura may result from compression of the veins by tumors or a gravid uterus or by occlusions from thrombosis.

Purpuric lesions in children lead to suspicion of the battered child (Fig. 35-15). Bruises and ecchymoses on the genital area, buttocks, left ear or cheek, or hands suggest an abused child. Linear lesions on accessible areas raise suspicion of factitial disease. Ecchymoses of bizarre shapes may also correspond to trauma inflicted during religious rituals or cultural practices, such as coin rubbing and cupping performed as remedies for common diseases. "Passion purpura" on the palate may result from fellatio. On the neck or upper arms, it results from biting and sucking and is better known as a "hickey." Facial, cheek, and periorbital purpura can be postictal and may be mistaken



**Fig. 35-15** Child abuse; purpura of the face from the sole of a shoe.

for spousal abuse. Bathtub suction-induced purpura occurs on the lower back location in a U-shaped distribution. It may be mistaken for abuse.

**Baselga E, et al:** Purpura in infants and children. *J Am Acad Dermatol* 1997; 37:673.

**Ely SF, et al:** Asphyxial deaths and petechiae: a review. *J Forensic Sci* 2000; 45:1274.

**Jaffe FA:** Petechial hemorrhages: a review of pathogenesis. *Am J Forensic Med Pathol* 1994; 15:203.

**Kemp AM, et al:** Bruising in children who are assessed for suspected physical abuse. *Arch Dis Child* 2014; 99(2):108–113.

**Knoell KA, et al:** Flutter valve purpura. *J Am Acad Dermatol* 1998; 9:292.

**Landers MC, et al:** Bathtub suction-induced purpura. *Pediatr Dermatol* 2004; 21:146.

**Reis JJ, et al:** Postictal hemifacial purpura. *Seizure* 1998; 7:337.

## Paroxysmal nocturnal hemoglobinuria

Paroxysmal nocturnal hemoglobinuria (PNH) is an acquired intravascular hemolytic anemia that usually occurs in young adults, median age 40 years. It is an acquired clonal disorder resulting from a somatic mutation in a multipotent hematopoietic stem cell that produces all the bone marrow-derived cell lines (neutrophils, lymphocytes, platelets, and erythrocytes). The clinical manifestations of PNH are intravascular hemolysis, smooth muscle dystonia caused by depletion of tissue nitric oxide (abdominal pain, esophageal spasm, fatigue, erectile dysfunction), and life-threatening venous thrombosis. Some cases occur after recovery from aplastic anemia. Widespread cutaneous thrombosis can occur, with initial erythematous cutaneous plaques progressing to hemorrhagic bullae. Vascular thrombi are found on biopsy. The cause of PNH is a mutation in an X-linked gene, phosphatidylinositol glycan class A (*PIGA*). The gene product is the first step in the biosynthesis of all glycosyl-phosphatidylinositol (GPI) anchors on the surface of hematopoietic cells. Erythrocytes in PNH lack two GPI-anchored proteins, CD55 and CD59, which function is to prevent complement activation on the erythrocyte surface. CD55 accelerates the rate of breakdown of membrane-bound C3 convertase, and CD59 reduces the number of membrane attack complexes that are formed. Without these proteins, amplification of the complement system is uncontrolled, leading to intravascular destruction of red blood cells (RBCs). The diagnosis of PNH can be made by detecting the loss of CD55 and CD59 through monoclonal antibody tests. The FLAER (fluorescent aerolysin) flow cytometry test is now often used to diagnose PNH. Hematopoietic stem cell transplantation may be curative, after either ablative or nonablative conditioning regimens. Eculizumab, a humanized monoclonal antibody against C5, inhibits terminal complement activation. It stabilizes hemoglobin levels and reduces transfusion requirements in PNH patients.

**Brodsky RA:** Narrative review. Paroxysmal nocturnal hemoglobinuria: the physiology of complement-related hemolytic anemia. *Ann Intern Med* 2008; 148:587.

**Kelly RJ, et al:** Long-term treatment with eculizumab in paroxysmal nocturnal hemoglobinuria: sustained efficacy and improved survival. *Blood* 2011; 117(25):6786–6792.

**Parker CJ:** Bone marrow failure syndromes: paroxysmal nocturnal hemoglobinuria. *Hematol Oncol Clin North Am* 2009; 23:333.

**Parker C:** Eculizumab for paroxysmal nocturnal haemoglobinuria. *Lancet* 2009; 373(9665):759–767.

**Santarone S, et al:** Hematopoietic stem cell transplantation for paroxysmal nocturnal hemoglobinuria: long-term results of a retrospective study on behalf of the Gruppo Italiano Trapianto Midollo Osseo (GITMO). *Haematologica* 2010; 95(6):983–988.

**White JM, et al:** Haemorrhagic bullae in a case of paroxysmal nocturnal hemoglobinuria. *Clin Exp Dermatol* 2003; 28:504.

## Paroxysmal hand hematoma (Achenbach syndrome)

Spontaneous focal hemorrhage into the palm or the volar surface of a finger may result in transitory localized pain, followed by rapid swelling and localized bluish discoloration. The lesion resolves spontaneously within a few days. Spontaneous hemorrhage from an arteriole appears to be responsible. The acute nature, purpuric findings, and rapid resolution are distinguishing features of Achenbach syndrome.

**Robertson A, et al:** Paroxysmal finger haematomas (Achenbach's syndrome) with angiographic abnormalities. *J Hand Surg B* 2002; 27:391.

**Thies K, et al:** Achenbach's syndrome revisited. *Vasa* 2012; 41(5):366–370.

## Easy bruising syndromes

Young women who bruise easily despite normal coagulation profiles and normal platelet counts may have antiplatelet antibodies. Otherwise, specific platelet function defects should be suspected. Bernard-Soulier syndrome is a rare inherited disorder characterized by giant platelets, thrombocytopenia, and a prolonged bleeding time. It is caused by genetic defects of the glycoprotein Ib-IX complex that constitutes the vWF receptor. Sebastian syndrome consists of giant platelets, leukocyte inclusions, and thrombocytopenia. Fechtner syndrome is a rare type of familial thrombocytopenia associated with large platelets, leukocyte inclusions, and features of Alport syndrome. The May-Hegglin anomaly consists of easy bruising with giant platelets and Döhle-like cytoplasmic inclusions in granulocytes. The inclusions appear as electron-dense long rods and needles oriented along the long axis of the spindle. All four of these syndromes are caused by abnormalities in the *MYH9* gene. Glanzmann thrombasthenia, with dysfunctioning  $\alpha$ IIb $\beta$ 3 receptor, is a platelet storage pool defect causing similar clinical findings.

**Andrews RK, Berndt MC:** Bernard-Soulier syndrome: an update. *Semin Thromb Hemost* 2013; 39(6):656–662.

**Balderramo DC, et al:** Sebastian syndrome: report of the first case in a South American family. *Haematologica* 2003; 88:ECR17.

**Balduini CL, Savoia A:** Genetics of familial forms of thrombocytopenia. *Hum Genet* 2012; 131(12):1821–1832.

**Hussein BA, et al:** May-Hegglin anomaly and pregnancy: a systematic review. *Blood Coagul Fibrinolysis* 2013; 24(5):554–561.

**Landi D, et al:** Report of a young girl with *MYH9* mutation and review of the literature. *J Pediatr Hematol Oncol* 2012; 34(7):538–540.

**Matzdorff AC, et al:** Perioperative management of a patient with Fechtner syndrome. *Ann Hematol* 2001; 80:436.

**Nurden AT, et al:** Genetic testing in the diagnostic evaluation of inherited platelet disorders. *Semin Thromb Hemost* 2009; 35:204.

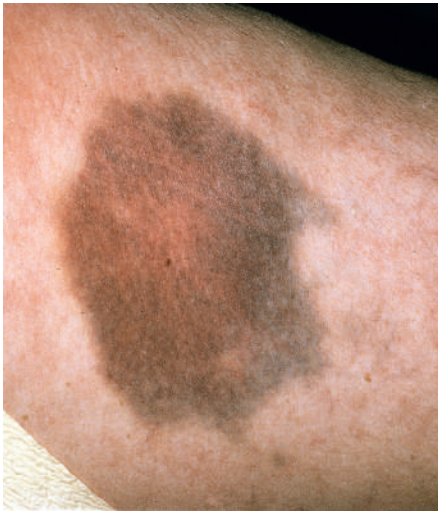**Nurden P, Nurden AT:** Congenital disorders associated with platelet dysfunctions. *Thromb Haemost* 2008; 99:253.

**Savoia A, et al:** Clinical and genetic aspects of Bernard-Soulier syndrome: searching for genotype/phenotype correlations. *Haematologica* 2011; 96(3):417–423.

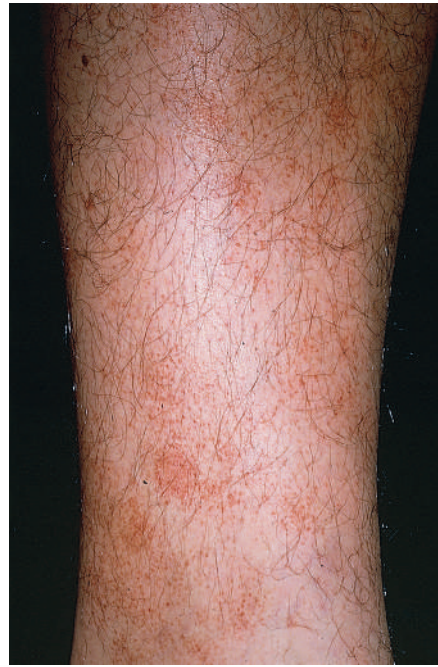## Painful bruising syndrome (autoerythrocyte sensitization, Gardner-Diamond syndrome, psychogenic purpura)

Painful bruising syndrome is a distinctive localized purpuric reaction occurring primarily in young to middle-age women, usually who manifest personality disorders. They may have depression, anxiety, or hysterical or masochistic character





**Fig. 35-16** Gardner-Diamond syndrome.



**Fig. 35-17** Schamberg's disease.

traits or may be unable to deal with hostile feelings. A recurrent type of eruption, psychogenic purpura is characterized by extremely painful and tender, poorly defined ecchymoses on the extremities (Fig. 35-16) and sometimes on the face or trunk. The lesions evolve in a few hours and resolve within 5–8 days. New lesions may appear in crops. Emotional upsets are generally associated with the appearance of these painful purpuric lesions. Some patients will report a premonition as to when they will develop new lesions a few hours before by the tingling and burning sensation at the site of a future lesion. Extracutaneous somatic symptoms are common, such as headache, paresthesias, transient paresis, syncope, diplopia, abdominal distress, diarrhea, nausea and vomiting, and arthralgia.

Gardner and Diamond reported that intracutaneous injections of erythrocyte stroma evoked typical lesions. Since then, many have reported similar reactions to autologous whole blood, packed or washed RBCs, or fractions of erythrocyte stroma. These are difficult to assess because similar reactions have been reported to substances as diverse as hemoglobin, phosphatidyl serine, histamine, histidine, trypsin, purified protein derivative (PPD), autologous serum, and platelets. Blinded controlled testing, trying to avoid factitious trauma, has given mixed responses. Abnormalities in tPA-dependent fibrinolysis, thrombocytosis, and anticardiolipin antibodies have also been implicated. Most now believe this syndrome is psychosomatic and artifactual. The most effective treatment is to address the underlying psychological dysfunction. Improvement of the underlying psychopathology usually leads to disappearance of the cutaneous manifestations.

**Hagemeier L, et al:** Gardner-Diamond syndrome: a rare differential diagnosis of child abuse. *Br J Dermatol* 2011; 164(3):672–673.

**Jafferany M:** Auto-erythrocyte sensitization syndrome (Gardner-Diamond syndrome) in a 15-year-old adolescent girl. *Int J Dermatol* 2013; 52(10):1284–1285.

**Sarkar S, et al:** Psychogenic purpura. *Indian J Psychiatry* 2013; 55(2):192–194.

**Yucel B, et al:** Dissociative identity disorder presenting with psychogenic purpura. *Psychosomatics* 2000; 41:279.

### PIGMENTARY PURPURIC ERUPTIONS (PROGRESSIVE PIGMENTARY DERMATOSIS, PROGRESSIVE PIGMENTING PURPURA, PURPURA PIGMENTOSA CRONICA)

The pigmented purpuric eruptions (PPEs) are a group of common dermatoses (capillaritis) of unknown pathogenesis.

The most common variant of progressive pigmentary dermatosis is Schamberg's disease. The typical lesions are thumbprint-sized and composed of aggregates of pinhead-sized petechiae resembling grains of cayenne pepper on a background of golden-brown hemosiderin staining. The lesions usually begin on the lower legs, with slow proximal extension (Fig. 35-17). These lesions seldom itch. The favored sites are on the lower shins and ankles, but lesions may be more widespread and occasionally affect the upper extremities or trunk.

Majocchi's disease is also known as purpura annularis telangiectodes. The early lesions are 1–3 cm annular patches composed of dark-red telangiectases with petechiae and hemosiderin staining. Central involution and peripheral extension produce ringed, semicircular, targetlike, or concentric rings. The eruption begins symmetrically on the lower extremities, spreads up the legs, and may extend on to the trunk and arms. Involution of individual patches is slow and, because new lesions continue to form, may continue indefinitely. The lesions are asymptomatic.

Gougerot-Blum syndrome (pigmented purpuric lichenoid dermatitis) is characterized by minute, rust-colored to violaceous, lichenoid papules that tend to fuse into plaques of various hues between red, violaceous, and brown (purpura with lichenoid dermatitis). Favorite locations are the legs, thighs, and lower trunk. The chief difference between this and Schamberg's disease is the deeper color and the presence of induration, both of which relate to the presence of a lichenoid band of lymphoid inflammation. Similar lesions have also occurred during IFN therapy for hepatitis C.

Ducas and Kapetanakis pigmented purpura is scaly and eczematous. The eczematous patches also demonstrate petechiae and hemosiderin staining. Pruritus is common, and the lesions are often more extensive than the other PPEs. It is distinguished histologically by the presence of spongiosis. Purpuric pityriasis rosea may resemble Ducas and Kapetanakis purpura.

Lichen aureus is characterized by the sudden appearance of one or several, golden or rust-colored, closely packed macules or lichenoid papules. The macules may be grouped into a patch and may occur on any part of the body, but the vast majority of lesions occur on the feet or lower leg. The patches are usually solitary and asymptomatic but may occasionally

be painful. Adults predominate, but children may also be affected.

Rare variants of the pigmented purpuric dermatoses are the linear or zosteriform type and the transitory type. These tend to be more transient than the other variants. A single case of evolution to linear morphea has been reported.

Histologically, all forms of PPE demonstrate superficial perivascular lymphocytic (and at times granulomatous) infiltrate associated with extravasation of RBCs and, in later lesions, hemosiderin deposition. The degree of hemosiderin deposition may be variable and is insufficient to confirm the diagnosis histologically. The infiltrating cells are primarily CD4+ lymphocytes. There may be a lichenoid band of lymphoid inflammatory cells (Gougerot-Blum type) or spongiosis (Ducas and Kapetanakis type). An iron stain (Perl, Prussian blue, ferricyanide) is sometimes used to demonstrate the hemosiderin deposition.

Cutaneous T-cell lymphoma (CTCL) may begin with clinical lesions that resemble pigmented purpura. In addition, lesions of pigmented purpuric dermatosis may demonstrate clonality. Patients with more widespread lesions above the knee are much more likely to have clonal infiltrates and eventually meet histologic criteria for the diagnosis of CTCL.

In most cases of pigmented purpuric dermatosis, the etiology is unknown. Patients with stasis dermatitis and venous insufficiency may develop lesions that bear a superficial clinical resemblance to Schamberg's disease. Their lesions are more diffuse and do not form well-circumscribed macules. Oral medications can induce PPEs that closely resemble Ducas and Kapetanakis purpura, including acetaminophen, aspirin, glipizide, IFN alfa, and medroxyprogesterone injections. Stopping the medication will lead to resolution of the eruption. Pigmented purpuric contact dermatitis may simulate a PPE. Inciting allergens include nickel sulfate, fragrance mix, and Disperse Blue dyes. Patch testing on the back may be negative, but a positive response may be seen when the causative allergen is applied to a lesion. As with pigmenting drug eruptions, pigmented purpuric contact dermatitis should be suspected when the lesions are more widespread (sites other than the legs) and especially if they have an eczematous character.

Anecdotal reports of benefit from topical corticosteroids make a therapeutic trial for 4–6 weeks reasonable. Oral rutoside, 50 mg twice daily, and ascorbic acid, 500 mg twice daily, may be beneficial. Psoralen plus ultraviolet A (PUVA) and narrow-band UVB have demonstrated efficacy and should be considered when the other modalities fail. Immunosuppressive therapy with cyclosporine and methotrexate has also been effective but is usually not warranted given the lack of significant symptoms. If immunosuppression is considered, CTCL must be excluded, and patch testing and drug withdrawal should be undertaken.

**Engin B, et al:** Patch test results in patients with progressive pigmented purpuric dermatosis. *J Eur Acad Dermatol Venereol* 2009; 23:209.

**Georgala S, et al:** Persistent pigmented purpuric eruption associated with mycosis fungoides: a case report and review of the literature. *J Eur Acad Dermatol Venereol* 2001; 15:62.

**Gupta G, et al:** Capillaritis associated with interferon-alfa treatment of chronic hepatitis C infection. *J Am Acad Dermatol* 2000; 43(5 Pt 2):937.

**Hoesly FJ, et al:** Purpura annularis telangiectodes of Majocchi: case report and review of the literature. *Int J Dermatol* 2009; 48:1129.

**Kaplan R, et al:** A case of isotretinoin-induced purpura annularis telangiectodes of Majocchi and review of substance-induced pigmented purpuric dermatosis. *JAMA Dermatol* 2014; 150(2):182–184.

**Komericki P, et al:** Pigmented purpuric contact dermatitis from Disperse Blue 106 and 124 dyes. *J Am Acad Dermatol* 2001; 45:456.

**Mackenzie AI, Biswas A:** Granulomatous pigmented purpuric dermatosis: report of a case with atypical clinical presentation including dermoscopic findings. *Am J Dermatopathol* 2014; Apr 2. [Epub ahead of print.]

## PURPURIC AGAVE DERMATITIS

*Agave americana* is a large, thick, long-leaved, subtropical plant with a striking blue-gray color. It is often used in ornamental beddings in the southwestern United States. The plant grows up to 2 m (6½ feet) in diameter and may overgrow the surrounding landscape. These plants are deep rooted and difficult to remove, and some individuals attempt removal using a chainsaw. A striking purpuric dermatosis occurs in a pattern corresponding to the splatter of the plant's sap. Histologically, there is vascular damage at the level of the capillary and post-capillary venule, with a sparse infiltrate of neutrophils and karyorrhectic debris, suggesting low-grade leukocytoclastic vasculitis. Papulovesicular lesions have also been described. The plant's sap contains calcium oxalate crystals, as well as various acrid oils and saponins. The causative component is unknown.

**Barabash-Neila R, et al:** *Agave americana* causing irritant contact dermatitis with a purpuric component. *Actas Dermosifiliogr* 2011; 102(1):74–76.

**Genillier-Foin N, Avenel-Audran M:** Purpuric contact dermatitis from *Agave Americana*. *Ann Dermatol Venereol* 2007; 134(5 Pt 1):477–478.

## VASCULITIS

Vasculitis is a clinicopathologically defined process characterized by inflammation and necrosis of blood vessels. Because the clinical morphology correlates with the size of the affected blood vessel(s), these disorders are classified by the vessel(s) affected. Diseases may involve vessels of overlapping size. In general, small-vessel disease (affecting postcapillary venules) causes urticarial lesions and palpable purpura; small-artery disease manifests with subcutaneous nodules; medium-sized arteries with necrosis of major organs, livedo, purpura, and mononeuritis multiplex; and large-vessel disease with symptoms of claudication and necrosis.

## Classification

Numerous vasculitis classification schemes have been proposed, most recently the 2012 Revised International Chapel Hill Consensus Conference Nomenclature of Vasculitides; all have limitations. It is important to remember that infectious and thrombotic conditions, which “classically” show thrombosis of vessels histologically, at times may also show true leukocytoclastic vasculitis. Therefore, infectious, embolic, and thrombotic causes of vessel damage must always be considered before unequivocally diagnosing a case as an “inflammatory” vasculitis. Leukocytoclastic vasculitis is also frequently seen adjacent to suppurative folliculitis and at the base of chronic ulcers. The discovery of the association of some forms of small-vessel and medium-vessel vasculitides with positive ANCA has made their diagnosis and classification much easier (**Box 35-1**).

**Carlson JA, Chen KR:** Cutaneous vasculitis update: small vessel neutrophilic vasculitis syndromes. *Am J Dermatopathol* 2006; 28:486.

**Grzeszkiewicz TM, Fiorentino DF:** Update on cutaneous vasculitis. *Semin Cutan Med Surg* 2006; 25:221.



**Box 35-1** Classification of vasculitis

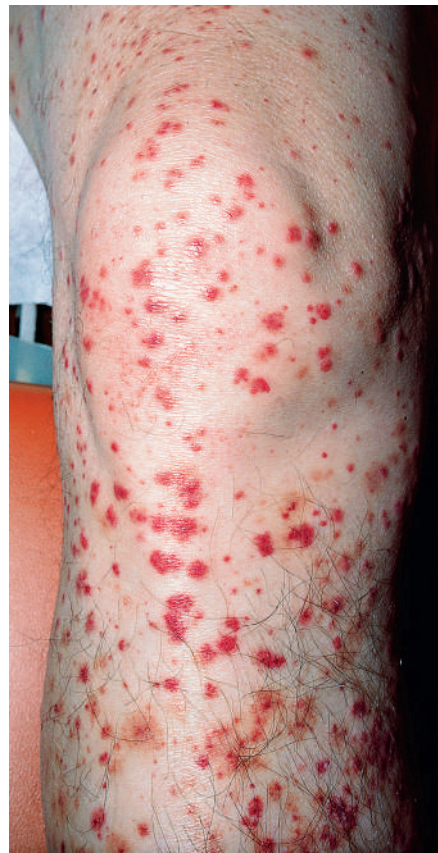- I. Cutaneous small-vessel (postcapillary venule)**
  - A. Idiopathic cutaneous small-vessel vasculitis
  - B. Henoch-Schönlein purpura
  - C. Acute hemorrhagic edema of infancy
  - D. Urticarial vasculitis
  - E. Cryoglobulinemic vasculitis
  - F. Erythema elevatum diutinum
  - G. Granuloma faciale
  - H. Other diseases with leukocytoclastic vasculitis: drug-induced vasculitis, malignancy (lymphoreticular more common than solid tumor), connective tissue diseases, hyperglobulinemic purpura, inflammatory bowel disease, bowel-associated dermatitis–arthritis syndrome (bowel bypass), HIV infection, and neutrophilic dermatoses (Behçet; Sweet; erythema nodosum leprosum; septic vasculitis; autoinflammatory conditions—familial Mediterranean fever, and serum sickness)
- II. Medium-vessel**
  - A. Polyarteritis nodosa
    1. Benign cutaneous forms
    2. Systemic form
- III. Mixed size (medium and small) vessel disease**
  - A. Connective tissue disease associated (usually rheumatoid vasculitis)
  - B. Septic vasculitis
  - C. ANCA associated
    1. Microscopic polyangiitis
    2. Wegener's granulomatosis
    3. Allergic granulomatosis (Churg-Strauss)
    4. Occasional drug-induced (most are postcapillary venule only)
- IV. Large-vessel vasculitis**
  - A. Giant cell arteritis
  - B. Takayasu arteritis

Jennette JC, et al: 2012 Revised International Chapel Hill Consensus Conference Nomenclature of Vasculitides. *Arthritis Rheum* 2013; 65(1):1–11.

Sunderkotter C, Sindrilaru A: Clinical classification of vasculitis. *Eur J Dermatol* 2006; 16:114.

**SMALL-VESSEL VASCULITIS****Cutaneous small-vessel vasculitis (cutaneous leukocytoclastic vasculitis)**

The vast majority of cases of cutaneous leukocytoclastic vasculitis (LCV) follow an acute infection or exposure to a new medication. Palpable purpura is the hallmark of this disease, with lesions ranging from pinpoint to several centimeters in diameter (Fig. 35-18). Annular, vesicular, bullous, or pustular lesions may develop. Small ulcerations may develop, but when ulceration is prominent, one must suspect either a vasculitis of larger vessels (small to medium arterioles) or the presence of both a vasculitis and a hypercoagulable state. Lesions of LCV predominate on the ankles and lower legs, affecting mainly dependent areas or areas under local pressure. Edema, especially of the ankles, is usually noted. In the hospitalized or bedridden patient, the buttocks and posterior thighs are dependent areas and may be the initial or primary site of involvement. Mild pruritus, fever, and malaise may



**Fig. 35-18**  
Leukocytoclastic vasculitis, palpable purpura.

occur. Arthralgias or less often frank arthritis may be seen. Other systemic involvement is rare and should lead to consideration of another diagnosis. Although in general, systemic involvement is not found or is minimal, serious systemic disease can accompany cutaneous LCV and should be sought in every patient.

The lesions usually resolve in 3–4 weeks, with residual postinflammatory hyperpigmentation. Ten percent of cutaneous LCV patients may have recurrences. A persistent underlying cause must be sought in chronic or recurrent cases.

**Histology**

There is angiocentric segmental inflammation of the postcapillary venule, with expansion of the vessel wall, fibrin deposition, and infiltration by neutrophils that show fragmentation of their nuclei (karyorrhexis or leukocytoclasia). Endothelial cell swelling is common, and fibrinoid necrosis of the vessel walls is seen. Vascular thrombosis may be present. The presence of tissue eosinophilia favors a medication as the cause. Immunofluorescence and ultrastructural studies have shown the presence of immunoglobulins, complement components, and fibrin deposits within postcapillary venule walls, if the biopsy is taken within the first 24 hours. Later, fibrin is prominent, but immunoglobulin deposits may have been destroyed. An important exception is Henoch-Schönlein purpura, which usually demonstrates prominent IgA deposits even in more advanced lesions.

**Pathogenesis**

Cutaneous small-vessel vasculitis is thought to be caused by circulating immune complexes. These complexes lodge in vessel walls and activate complement. Various inflammatory mediators are produced, contributing to endothelial injury.

## Etiology

In most series, the majority of cutaneous LCV cases are idiopathic. Of the remaining 50% of cases, most are either drug induced or postinfectious. Drugs in virtually every class have been reported as causing LCV, and the time from start of the medication to onset of the eruption may be hours to years, making any ingested agent a possible cause. A host of infectious agents, such as  $\beta$ -hemolytic *Streptococcus* group A, *Mycoplasma*, and rarely *Mycobacterium tuberculosis*, may cause palpable purpura. Cutaneous LCV can occur in association with a connective tissue disease or as its presenting sign. Patients with lymphoproliferative neoplasms, as well as solid tumors (lung, colon, genitourinary, and breast cancer), may experience cutaneous small-vessel vasculitis at some time during the course of their disease. A recurrence of the LCV may mark the return of a treated malignancy. Cutaneous LCV may also be the initial manifestation of mixed small-vessel and medium-vessel vasculitis.

## Clinical evaluation

The clinical evaluation is critical in separating cases of benign cutaneous vasculitis (usually following an infection or induced by a medication) from those cases associated with more serious underlying disease or that have significant systemic involvement. It may not be possible on initial physical examination to make this distinction. The history should focus on possible infectious disorders, prior associated diseases, drugs ingested, and a thorough review of systems. Screening laboratory tests may help to elucidate the underlying cause or extent of organ involvement. When the history suggests a recent drug and the patient is clinically well, nothing more than a urinalysis may be required. A CBC, basic metabolic panel, urinalysis, strep throat culture or ASO titer, hepatitis B and C serologies, and ANA and RF are a reasonable initial screen for patients with no obvious cause for their vasculitis. Serum protein electrophoresis, serum complements, ANCA, and cryoglobulins may be required in some cases. A skin biopsy should be performed to confirm the diagnosis of LCV. DIF should be performed to identify IgA vasculitis (Henoch-Schönlein purpura).

## Treatment

The initial treatment of most cases of LCV in patients who are clinically well and have a normal urinalysis should focus on symptom management and should not be aggressive, since the majority of cases are acute and self-limited, affect only the skin, and do not threaten progressive deterioration of internal organs. Rest and elevation of the legs will likely be helpful. Analgesics and avoidance of trauma and cold are prudent general measures. An identified antigen or drug should be eliminated and any identified infectious, connective tissue, or neoplastic disease treated.

A variety of systemic treatments may be required for severe, intractable, or recurrent disease, especially if significant organ involvement is present. For disease limited to the skin, NSAIDs can be considered for arthralgias. Colchicine, 0.6 mg two or three times daily, or dapsone, 50–200 mg/day, may be useful for chronic vasculitis. Low doses of colchicine and dapsone may be combined if either medication alone is unsuccessful or effective doses of either drug cannot be tolerated. Although one controlled trial (the only such trial for cutaneous small-vessel vasculitis) suggested colchicine was ineffective for LCV, some of the patients did respond and flared when the drug was stopped. Oral antihistamines, by blocking the vasodilation induced by histamine, may reduce immune complex trapping and improve LCV. Systemic corticosteroids, in doses

ranging from 60 to 80 mg/day, are recommended for patients with serious systemic manifestations or necrotic lesions. Usually, a brief course leads to resolution, and chronic treatment is rarely required. Unfortunately, systemic corticosteroids are not good long-term options for patients with chronic LCV. For those with chronic or refractory disease in whom colchicine or dapsone is ineffective, immunosuppressive agents, such as MMF, 2–3 g/day; methotrexate, 5–25 mg/week; or azathioprine, 50–200 mg/day (2–3.5 mg/kg/day), may be considered. Azathioprine dosing is based on thiopurine methyltransferase (TPMT) levels. In more difficult cases, cyclophosphamide, monthly IV pulses of steroids or cyclophosphamide, or cyclosporine, 3–5 mg/kg/day, may be effective. The tumor necrosis factor (TNF) blockers, especially infliximab and to a lesser degree etanercept, may be effective in cutaneous small-vessel vasculitis. However, these agents may also cause vasculitis. Rituximab has been effective in refractory cases.

**Arora A, et al:** Incidence of leukocytoclastic vasculitis, 1996 to 2010: a population-based study in Olmsted County, Minnesota. *Mayo Clin Proc* 2014; 89(11):1515–1524.

**Bahrami S, et al:** Tissue eosinophilia as an indicator of drug-induced cutaneous small-vessel vasculitis. *Arch Dermatol* 2006; 142:155.

**Barile-Fabris L, et al:** Vasculitis in systemic lupus erythematosus. *Curr Rheumatol Rep* 2014; 16(9):440.

**Carlson JA, et al:** Cutaneous vasculitis: diagnosis and management. *Clin Dermatol* 2006; 24(5):414–429.

**Fain O, et al:** Vasculitides associated with malignancies: analysis of sixty patients. *Arthritis Rheum* 2007; 57:1473.

**Goeser MR, et al:** A practical approach to the diagnosis, evaluation, and management of cutaneous small-vessel vasculitis. *Am J Clin Dermatol* 2014; 15(4):299–306.

**Haeblerle MT, et al:** Treatment of severe cutaneous small-vessel vasculitis with mycophenolate mofetil. *Arch Dermatol* 2012; 148(8):887–888.

**Khetan P, et al:** An aetiological and clinicopathological study on cutaneous vasculitis. *Indian J Med Res* 2012; 135:107–113.

**Loricera J, et al:** The spectrum of paraneoplastic cutaneous vasculitis in a defined population: incidence and clinical features. *Medicine (Baltimore)* 2013; 92(6):331–343.

**Loricera J, et al:** Single-organ cutaneous small-vessel vasculitis according to the 2012 Revised International Chapel Hill Consensus Conference Nomenclature of Vasculitides: a study of 60 patients from a series of 766 cutaneous vasculitis cases. *Rheumatology (Oxford)* 2014; Jul 26. [Epub ahead of print.]

**Mang R, et al:** Therapy for severe necrotizing vasculitis with infliximab. *J Am Acad Dermatol* 2004; 51:321.

**Marzano AV, et al:** Skin involvement in cutaneous and systemic vasculitis. *Autoimmun Rev* 2013; 12(4):467–476.

**Podjasek JO, et al:** Cutaneous small-vessel vasculitis associated with solid organ malignancies: the Mayo Clinic experience, 1996 to 2009. *J Am Acad Dermatol* 2012; 66(2):e55–e65.

**Podjasek JO, et al:** Histopathologic findings in cutaneous small-vessel vasculitis associated with solid-organ malignancy. *Br J Dermatol* 2014; Jun 24. [Epub ahead of print.]

**Sais G, et al:** Colchicine in the treatment of cutaneous leukocytoclastic vasculitis: results of a prospective, randomized controlled trial. *Arch Dermatol* 1995; 131:1399.

**Sokumbi O, et al:** Vasculitis associated with tumor necrosis factor- $\alpha$  inhibitors. *Mayo Clin Proc* 2012; 87(8):739–745.

## Cutaneous vasculitis and connective tissue disease

Patients with various connective tissue diseases (SLE, Sjögren's syndrome, rheumatoid arthritis [RA], dermatomyositis) may develop cutaneous vasculitic lesions. Vasculitis in the patient with connective tissue disease may be associated with significant internal organ involvement, especially of the peripheral and central nervous systems and the kidneys (glomerulonephritis). Ischemic digital infarcts are seen in addition to



palpable purpura. Ulceration of vasculitic lesions can occur and may be particularly difficult to manage in patients with RA. The prevalence of vasculitis in patients with RA has decreased with improved treatment of RA, but this complication remains a significant source of morbidity and mortality for affected patients. Treatment is the same as for cutaneous LCV, along with management of the underlying connective tissue disease.

**Barile-Fabris L, et al:** Vasculitis in systemic lupus erythematosus. *Curr Rheumatol Rep* 2014; 16(9):440.

**Makol A, et al:** Vasculitis associated with rheumatoid arthritis: a case-control study. *Rheumatology (Oxford)* 2014; 53(5):890–899.

## Subtypes of small-vessel vasculitis

### IgA vasculitis (Henoch-Schönlein purpura)

The term IgA vasculitis (IgAV) replaces the Henoch-Schönlein purpura eponym in the most recent vasculitis consensus criteria. IgAV is characterized by purpura, arthralgias, and abdominal and renal disease. Typically, mottled purpura appears on the extensor extremities, becomes hemorrhagic within 1 day, and starts to fade in about 5 days (Fig. 35-19). New crops may appear over a few weeks. Urticarial lesions, vesicles, necrotic purpura, and hemangioma-like lesions may also be present at some stages. There is a male predominance of cases. The disease occurs primarily in children (~75% of cases), with a peak age between 4 and 8 years; however, adults may also be affected. A viral infection or streptococcal pharyngitis is the usual triggering event. *Helicobacter pylori* infection has been implicated in some childhood and adult cases. Medication exposure can also trigger IgAV.

In about 40% of cases, the cutaneous manifestations are preceded by mild fever, headache, joint symptoms, and abdominal pain for up to 2 weeks. Once the vasculitis is fully established, skin lesions occur in all patients. GI symptoms are also common, occurring in about 65% of patients. Abdominal pain and GI bleeding may occur at any time during the disease; severe abdominal pain may even suggest—or portend—an acute surgical abdomen. Paralytic ileus may occur. Vomiting, rebound tenderness, and distention are other manifestations. GI radiographs may show “spiking” or a marbled “cobblestone” appearance. Arthralgia progressing to arthritis produces periarticular swelling around the knees and ankles; about 63% of patients have joint symptoms. Renal involvement manifests as microscopic or even gross hematuria and may occur in 40% or more of patients; usually it is mild.

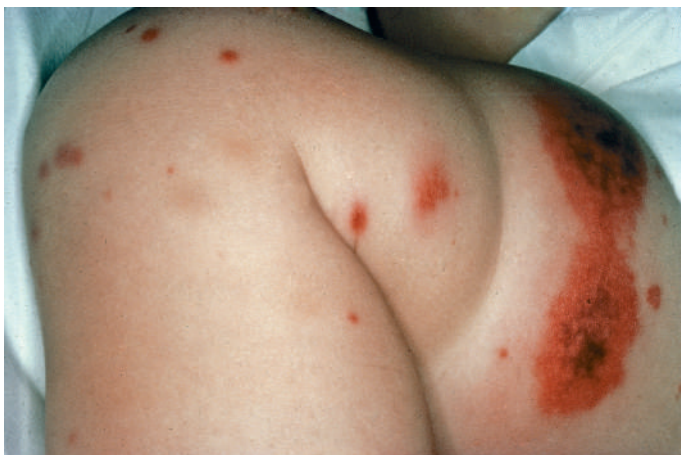

Fig. 35-19 Henoch-Schönlein purpura.

Pulmonary hemorrhage may occur and can be fatal. The long-term prognosis is generally favorable but is largely dictated by the severity of renal involvement. Children with gross hematuria usually do well; however, progressive glomerular disease and renal failure may develop in a small percentage, so careful follow-up is necessary for those with hematuria. Renal insufficiency is more common in adults, so the rate of long-term sequelae is higher in this population. Purpura above the waist may be a marker of renal involvement. Overall, persistent, usually mild nephropathy occurs in only 8% of patients. Relapses in disease activity, however, are common for months after initial diagnosis. IgA, C3, and fibrin depositions have been demonstrated in biopsies of both involved and uninvolved skin by immunofluorescence techniques. Abnormal IgA deposits in vessel walls are the defining pathophysiologic feature of IgAV (thus the name change) and may result from abnormal IgA1 glycosylation, leading to IgG-IgA1 immune complex deposition and resulting inflammation. In patients with abdominal pain suggestive of IgAV but with no skin lesions, histamine (as used as a control by allergists) can be injected into the skin and the area biopsied 4 h later. This “histamine trap test” may identify IgA in vessels and confirm the diagnosis. The presence of IgM in lesional skin may be an indication of renal involvement.

In adult patients with IgAV and upper GI symptoms (gastritis), a search for *H. pylori* infection should be undertaken. If an association with *H. pylori* can be confirmed, treatment of the GI infection may lead to resolution. IgAV in adults can be associated with an underlying malignancy. Males represent 90% or more of malignancy-associated IgAV cases. Solid tumors are seen in more than half of patients, especially non-small cell lung cancer, prostate cancer, and renal cancer. About 40% have a hematologic malignancy. About half of patients present within 1 month of diagnosis of the malignancy.

Treatment is primarily supportive. The usual duration of illness is 6–16 weeks, and no therapy appears to shorten that duration significantly. Between 5% and 30% of patients will have persistent or recurrent disease. Close follow-up, including urinalysis and blood pressure monitoring, should be continued for at least 6 months. Dapsone, 50–200 mg/day, or colchicine, 0.6 mg/day to 1.2 mg twice daily, can be used initially if treatment is required and skin lesions are the primary concern. For abdominal pain, an H2 blocker and corticosteroids (prednisone at 1 mg/kg/day) can be effective. Corticosteroids are more effective for abdominal pain than analgesia. The value of systemic corticosteroids in the treatment of renal disease is controversial, but steroids may be used preventively or to treat active nephritis. Data from randomized trials unfortunately have not shown significant benefit to this or other therapies in decreasing the risk of long-term renal sequelae. IVIG can be used in refractory skin disease and persistent abdominal pain and to arrest rapidly progressive glomerulonephritis. Cyclophosphamide is also used and may be effective for renal disease. NSAIDs are best avoided because they may cause renal or GI complications.

**Anil M, et al:** Henoch-Schönlein purpura in children from western Turkey: a retrospective analysis of 430 cases. *Turk J Pediatr* 51;2009:429–436.

**Blanco R, et al:** Henoch-Schönlein purpura as clinical presentation of a myelodysplastic syndrome. *Clin Rheumatol* 1997; 16:626.

**Bogdanovic R:** Henoch-Schönlein purpura nephritis in children: risk factors, prevention and treatment. *Acta Paediatr* 2009; 98(12):1882–1889.

**Calvo-Río V, et al:** Henoch-Schönlein purpura in northern Spain: clinical spectrum of the disease in 417 patients from a single center. *Medicine (Baltimore)* 2014; 93(2):106–113.

**Chartapisak W, et al:** Prevention and treatment of renal disease in Henoch-Schönlein purpura: a systematic review. *Arch Dis Child* 2009; 94(2):132–137.

**Chen O, et al:** Henoch-Schönlein purpura in children: clinical analysis of 120 cases. *Afr Health Sci* 2013; 13(1):94–99.

**Hoshino C:** Adult-onset Schönlein-Henoch purpura associated with *Helicobacter pylori* infection. *Intern Med* 2009; 48:847.

**Jauhola O, et al:** Renal manifestations of Henoch-Schönlein purpura in a 6-month prospective study of 223 children. *Arch Dis Child* 2010; 95(11):877–882.

**Jauhola O, et al:** Cyclosporine A vs. methylprednisolone for Henoch-Schönlein nephritis: a randomized trial. *Pediatr Nephrol* 2011; 26:2159–2166; erratum: *Pediatr Nephrol* 2011; 26(12):2263–2264.

**McCarthy HJ, Tizard EJ:** Clinical practice: diagnosis and management of Henoch-Schönlein purpura. *Eur J Pediatr* 2010; 169(6):643–650.

**Pertuiset E, et al:** Adult Henoch-Schönlein purpura associated with malignancy. *Semin Arthritis Rheum* 2000; 29(6):360–367.

**Podjasek JO, et al:** Henoch-Schönlein purpura associated with solid-organ malignancies: three case reports and a literature review. *Acta Derm Venereol* 2012; 92(4):388–392.

**Poterucha TJ, et al:** A retrospective comparison of skin and renal direct immunofluorescence findings in patients with glomerulonephritis in adult Henoch-Schönlein purpura. *J Cutan Pathol* 2014; 41(7):582–587.

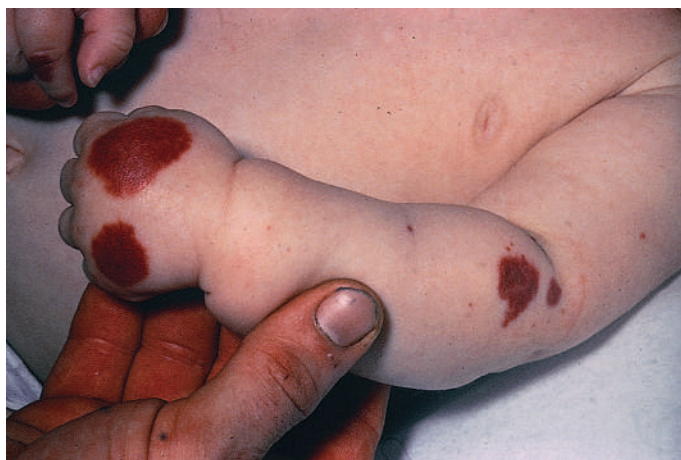**Rigante D, et al:** Is there a crossroad between infections, genetics, and Henoch-Schönlein purpura? *Autoimmun Rev* 2013; 12(10):1016–1021.

**Takeuchi S, et al:** IgM in lesional skin of adults with Henoch-Schönlein purpura is an indication of renal involvement. *J Am Acad Dermatol* 2010; 63(6):1026–1029.

**Xiong LJ, et al:** Is *Helicobacter pylori* infection associated with Henoch-Schönlein purpura in Chinese children? A meta-analysis. *World J Pediatr* 2012; 8:301–308.

## Acute hemorrhagic edema of infancy

Also known as Finkelstein disease, Seidlmayer syndrome, medallion-like purpura, infantile postinfectious irislike purpura and edema, and purpura en cocarde avec oedème, acute hemorrhagic edema (AHE) of infancy affects children younger than 2 years with a recent history of upper respiratory illness (75%), a course of antibiotics, or both. The children are often nontoxic in appearance. There is abrupt onset of large purpuric lesions involving the face, ears, and extremities (Fig. 35-20). Cockade, annular, or targetoid morphologies may be present. Scrotal purpura may also occur. Early in the course, there may first be acral edema, with subsequent proximal spread. The edema is nontender and may be asymmetric. A low-grade fever is common, and involvement of internal organ systems (joint pains, GI symptoms, renal involvement) is rare. Routine laboratory tests are unremarkable. Spontaneous recovery without sequelae occurs within 12–20 days. The differential diagnosis includes IgAV (Henoch-Schönlein purpura), meningococemia, erythema multiforme, urticaria, and Kawasaki disease.



**Fig. 35-20** Acute hemorrhagic edema.

Some similarities exist between IgAV and AHE (postinfectious, seasonal, male predilection), but AHE is different in that it favors younger children (<2 years), resolves more quickly, lacks IgA on DIF in most cases, and is rarely associated with systemic symptoms. In one family, a child younger than 4 years developed AHE while the sibling age 16 developed IgAV after the same pharyngitis. From a clinical point of view, the most urgent need is to exclude septicemia, especially meningococemia. Topical and systemic corticosteroids, as well as antihistamines and dapsone, have been reported as beneficial for relief of symptoms and rare complications of AHE of infancy.

**Fiore E, et al:** Acute hemorrhagic edema of young children (cockade purpura and edema): a case series and systematic review. *J Am Acad Dermatol* 2008; 59(4):684–695.

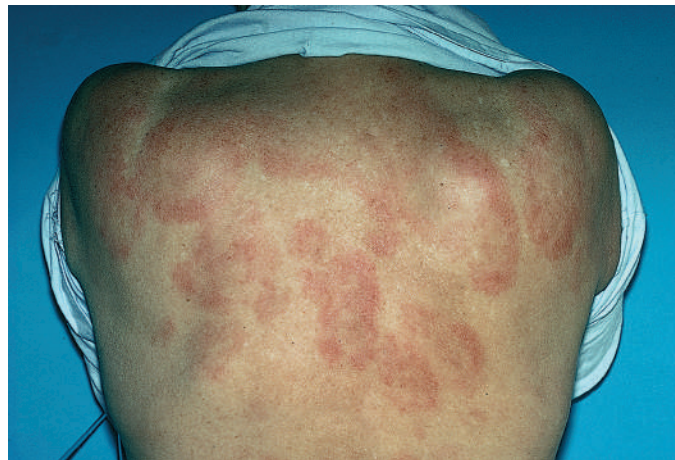**Freitas P, Bygum A:** Visual impairment caused by periorbital edema in an infant with acute hemorrhagic edema of infancy. *Pediatr Dermatol* 2013; 30(6):e132–e135.

**Savino F, et al:** Acute hemorrhagic edema of infancy: a troubling cutaneous presentation with a self-limiting course. *Pediatr Dermatol* 2013; 30(6):e149–e152.

## Urticarial vasculitis

A significant percentage of patients (reportedly as high as 5–10%, but probably less) with fixed urticarial lesions will have vasculitis histologically. This is termed “urticarial” vasculitis (Fig. 35-21). This urticarial morphology is maintained throughout the course of the illness. Microscopic hemorrhage into the urticarial plaques may occur, resulting in a bruise-like appearance as the lesions fade. Determination of the serum complement levels (CH50, C3, C4, and anti-C1q precipitins) is critical in the evaluation of urticarial vasculitis. Patients with normal complement levels usually have an LCV, which is idiopathic, limited to the skin, self-resolving, and best considered a subset of cutaneous small-vessel vasculitis. Hypocomplementemic urticarial vasculitis is a distinctive syndrome seen virtually always in women. Clinical features include arthritis (50%), arthralgias, angioedema, eye symptoms, asthma and obstructive pulmonary disease (20%), and GI symptoms (20%). Glomerulonephritis may be present. A rare subset of patients with hypocomplementemic urticarial vasculitis has Jaccoud arthropathy and serious valvular heart disease.

Underlying diseases associated with all forms of urticarial vasculitis include gammopathies (IgG and IgM gammopathy), SLE, Sjögren syndrome, serum sickness, and viral infections, especially hepatitis C. Patients with hypocomplementemic



**Fig. 35-21** Urticarial vasculitis.



urticarial vasculitis can have anti-C1q antibodies directed against the collagenlike region of that molecule, a feature used to define the disease. Patients with SLE may also have these autoantibodies. Many patients with hypocomplementemic urticarial vasculitis will have positive ANAs, and up to one-quarter will have positive anti-dsDNA antibodies. The vast majority (96%) will have a positive "lupus band test." Over time, more than 50% will meet the criteria for the diagnosis of SLE. For this reason, some consider hypocomplementemic urticarial vasculitis a form of SLE. Patients with HCV infection may develop hypocomplementemic or normocomplementemic urticarial vasculitis without a detectable cryoglobulin.

The following three clinical features distinguish the skin lesions of urticarial vasculitis from true urticaria:

1. The lesions are often burning or painful, rather than pruritic.
2. The lesions last longer than 24 h and are fixed, rather than transient and migrating.
3. On resolution, there is postinflammatory purpura or hyperpigmentation.

More difficult is the distinction of urticarial vasculitis from neutrophilic urticaria, because patients with the latter condition can have painful, more persistent lesions. Histologic evaluation is critical.

Histologically, patients with hypocomplementemic urticarial vasculitis will show both LCV and diffuse interstitial neutrophils. Eosinophils are more likely to be seen in patients with neutrophilic urticaria or normocomplementemic urticarial vasculitis. Sweet syndrome shows a more intense dermal infiltrate with marked upper dermal edema. Sweet syndrome and vasculitis share the presence of karyorrhexis. Whereas virtually all biopsies of idiopathic urticaria demonstrate neutrophils, karyorrhexis is usually distinctly absent. In neutrophilic urticaria, neutrophils will be found in the dermis and in the vessel walls (moving from the vascular compartment into the skin). Finding neutrophils in the vessel walls alone without fibrinoid necrosis of vessel walls and leukocytoclasia is insufficient to make the diagnosis of urticarial vasculitis. Most patients with urticarial lesions with neutrophilic infiltrates and normal complements have neutrophilic urticaria rather than urticarial vasculitis.

Other neutrophilic disorders in the differential diagnosis of urticarial vasculitis include mixed cryoglobulinemia, Schnitzler syndrome, the autoinflammatory syndromes (*CIAS1/NALP3* mutations), and neutrophilic dermatosis associated with connective tissue disease. Mixed cryoglobulinemia will be seen most frequently in the context of HCV infection and may present with urticarial, purpuric, or even necrotic/ulcerative lesions. Vasculitis should be seen on biopsy. The other three conditions all can have cutaneous lesions that are urticarial and clinically similar. They tend to have less dermal edema than is typical of either urticaria or Sweet syndrome. Histologically, these conditions lack vasculitis but show tissue neutrophilia with leukocytoclasia. Schnitzler syndrome is diagnosed by the finding of an IgM monoclonal gammopathy. The autoinflammatory syndromes are diagnosed by their characteristic features and genetic testing. In some patients with adult-onset Still's disease or SLE, transient macules and papules coalescing into plaques may be seen. This condition has been termed "neutrophilic urticarial dermatosis," but its pathogenesis remains unknown. In patients with such neutrophilic urticarial lesions, ferritin measurement and a workup for SLE are appropriate.

The treatment of hypocomplementemic urticarial vasculitis is directed at the symptomatology and severity of the disease. Indomethacin has been particularly effective. Antihistamines, dapsone, and colchicine may be tried. The addition of pentoxi-

fylline to dapsone may be effective. Antimalarials can be beneficial, as would be expected in this autoimmune connective tissue disease. Immunosuppressive therapy with prednisone and steroid-sparing agents such as MMF, azathioprine, rituximab, and canakinumab can be considered in refractory and severe cases.

**Amano H, et al:** Hypocomplementemic urticarial vasculitis with Jaccoud's arthropathy and valvular heart disease: case report and review of the literature. *Lupus* 2008; 17:837.

**Breda L, et al:** Hypocomplementemic urticarial vasculitis (HUVS) with precocious emphysema responsive to azathioprine. *J Clin Immunol* 2013; 33(5):891–895.

**Buck A, et al:** Hypocomplementemic urticarial vasculitis syndrome: a case report and literature review. *J Clin Aesthet Dermatol* 2012; 5(1):36–46.

**Chang S, Carr W:** Urticarial vasculitis. *Allergy Asthma Proc* 2007; 28:97.

**Hauser B, et al:** A case of hypocomplementaemic urticarial vasculitis with cardiac valve involvement successfully treated with cyclophosphamide and high-dose glucocorticoids. *Int J Rheum Dis* 2014; Apr 5. (Epub ahead of print.)

**Jara LJ, et al:** Hypocomplementemic urticarial vasculitis syndrome. *Curr Rheumatol Rep* 2009; 11(6):410–415.

**Kallenberg CG:** Anti-C1q autoantibodies. *Autoimmun Rev* 2008; 7(8):612–615.

**Kieffer C, et al:** Neutrophilic urticarial dermatosis. *Medicine* 2009; 88:23.

**Krause K, et al:** Efficacy and safety of canakinumab in urticarial vasculitis: an open-label study. *J Allergy Clin Immunol* 2013; 132(3):751–754.e5.

**Loricera J, et al:** Urticarial vasculitis in northern Spain: clinical study of 21 cases. *Medicine (Baltimore)* 2014; 93(1):53–60.

**Pasini A, et al:** Renal involvement in hypocomplementaemic urticarial vasculitis syndrome: a report of three paediatric cases. *Rheumatology (Oxford)* 2014; 53(8):1409–1413.

**Pinto-Almeida T, et al:** Cutaneous lesions and finger clubbing uncovering hypocomplementemic urticarial vasculitis and hepatitis C with mixed cryoglobulinemia. *An Bras Dermatol* 2013; 88(6):973–976.

**Saadoun D, et al:** Anti-C1q antibodies in hepatitis C virus infection. *Clin Exp Immunol* 2006; 145:308.

**Saeb-Lima M, et al:** Autoimmunity-related neutrophilic dermatosis: a newly described entity that is not exclusive of systemic lupus erythematosus. *Am J Dermatopathol* 2013; 35(6):655–660.

**Shaw D, et al:** Hypocomplementaemic urticarial vasculitis associated with non-Hodgkin lymphoma and treatment with intravenous immunoglobulin. *Br J Dermatol* 2007; 157:392.

**Swaminath A, et al:** Refractory urticarial vasculitis as a complication of ulcerative colitis successfully treated with rituximab. *J Clin Rheumatol* 2011; 17(5):281–283.

## Cryoglobulinemic vasculitis

About 15% of patients with a circulating cryoprecipitable protein are symptomatic and have cryoglobulinemic vasculitis. They typically have mixed (type II or III) cryoglobulinemia. Mixed cryoglobulinemia follows a benign course in half the cases, but in about one-third, hepatic or renal failure occurs. About 15% of patients develop malignancy, usually B-cell lymphoma, and less frequently, hepatocellular or thyroid cancer. By far the most common cause of cryoglobulinemic vasculitis is HCV infection, but lymphoproliferative disorders and autoimmune diseases can also be associated. Cryoglobulinemic vasculitis usually presents with macular or palpable purpura, typically confined to the lower extremities. Lesions may be limited or severe. Two thirds of patients show confluent areas of hemosiderosis of the feet and lower legs, characteristic of prior episodes of purpura. Although only 30% of patients report an exacerbation with cold exposure, up to 50% will have Raynaud phenomenon and cold-induced acrocyanosis of the ears. Other morphologies include

ecchymoses, livedo reticularis, urticaria, and ulcerations. Neuropathy and other neurologic complications occur in 40% of patients. Arthralgias, xerostomia, and xerophthalmia are frequent complaints. Renal disease occurs in about 25% of patients; widespread systemic vasculitis occurs in about 10%. These complications can be significant and life threatening, as can therapy-related infections. Laboratory evaluation will reveal a cryoglobulin, hypocomplementemia (90%), and a positive RF (70%). ANCA are rarely positive. A skin biopsy will show LCV.

The treatment of cryoglobulinemic vasculitis is the treatment of the underlying disease, if possible. With HCV infection, this may be IFN alfa plus ribavirin, or any of a number of newer agents available for this condition. Cryoglobulinemic vasculitis associated with HCV may also flare with IFN treatment. Colchicine, dapsone, IVIG, infliximab, and rituximab (anti-CD20 monoclonal antibody) can be attempted. In severe cases, plasmapheresis may be beneficial.

**Bryce AH, et al:** Natural history and therapy of 66 patients with mixed cryoglobulinemia. *Am J Hematol* 2006; 81(7):511–518.

**Chandesris MO, et al:** Infliximab in the treatment of refractory vasculitis secondary to hepatitis C-associated mixed cryoglobulinaemia. *Rheumatology* 2004; 43:532.

**Dammacco F, Sansonno D:** Therapy for hepatitis C virus-related cryoglobulinemic vasculitis. *N Engl J Med* 2013; 369(11):1035–1045.

**Damoiseaux J:** The diagnosis and classification of the cryoglobulinemic syndrome. *Autoimmun Rev* 2014; 13(4/5):359–362.

**De Blasi T, et al:** Cryoglobulinemia-related vasculitis during effective anti-HCV treatment with PEG-interferon alfa-2b. *Infection* 2008; 36:285.

**Farri C, et al:** Mixed cryoglobulinemia: demographic, clinical, and serologic features and survival in 231 patients. *Semin Arthritis Rheum* 2004; 33:355.

**Iannuzzella F, et al:** Management of hepatitis C virus-related mixed cryoglobulinemia. *Am J Med* 2010; 123(5):400–408.

**Kawakami T, et al:** Remission of hepatitis B virus-related cryoglobulinemic vasculitis with entecavir. *Ann Intern Med* 2008; 149:911.

**Mazzaro C, et al:** Efficacy and safety of peginterferon alfa-2b plus ribavirin for HCV-positive mixed cryoglobulinemia: a multicentre open-label study. *Clin Exp Rheumatol* 2011; 29(6):933–941.

**Ramos-Casals M, et al:** The cryoglobulinaemias. *Lancet* 2012; 379(9813):348–360.

**Retamozo S, et al:** Life-threatening cryoglobulinemic patients with hepatitis C: clinical description and outcome of 279 patients. *Medicine (Baltimore)* 2013; Aug 22. [Epub ahead of print.]

**Tallarita T, et al:** Successful combination of rituximab and plasma exchange in the treatment of cryoglobulinemic vasculitis with skin ulcers: a case report. *Cases J* 2009; 2:7859.

**Viganò M, et al:** HBV-associated cryoglobulinemic vasculitis: remission after antiviral therapy with entecavir. *Kidney Blood Press Res* 2014; 39(1):65–73.

**Zaja F, et al:** Efficacy and safety of rituximab in type II mixed cryoglobulinemia. *Blood* 2003; 101(10):3827–3834.

## Macular lymphocytic arteritis (lymphocytic thrombophilic arteritis)

Macular lymphocytic arteritis is a rarely reported condition that affects predominantly non-Caucasian females. It presents with multiple, poorly defined brown macules on the lower legs resembling postinflammatory hyperpigmentation. Histologically, a vessel in the subcutaneous fat is infiltrated with lymphocytes, but usually without destruction of the vessel. Neutrophils are absent. Recent reports suggest this condition may actually represent an indolent form of cutaneous polyarteritis nodosa with potential for ulceration.

## Golfer's and exercise-related "vasculitis"

This syndrome occurs mostly in hot weather and affects primarily older men (>50). Golfing or exercise with prolonged walking is the trigger. The syndrome is characterized by asymptomatic or pruritic, burning, or stinging, purpuric, macular or slightly raised papules and plaques, predominantly just above the sock line near the ankles. Mild ankle swelling may be present. The lesions resolve in under 3 days in most patients. Histologically, true LCV is not seen, but erythrocytes and neutrophils are present in the affected tissue. About half the patients are taking antithrombotic agents. This syndrome probably represents a form of purpura caused by anticoagulation and prolonged erect posture rather than a true vasculitis.

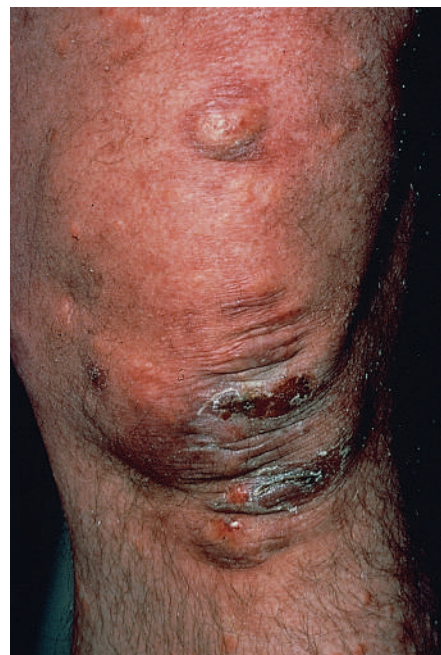**Kelly RI, et al:** Golfer's vasculitis. *Australas J Dermatol* 2005; 46:11.

**Llomas-Velasco M, et al:** Macular lymphocytic arteritis: first clinical presentation with ulcers. *J Cutan Pathol* 2013; 40(4):424–427.

**Macareno RS, et al:** Cutaneous lymphocytic thrombophilic (macular) arteritis: a distinct entity or an indolent (reparative) stage of cutaneous polyarteritis nodosa? Report of 2 cases of cutaneous arteritis and review of the literature. *Am J Dermatopathol* 2013; 35(2):213–219.

## Erythema elevatum diutinum

A rare condition, erythema elevatum diutinum (EED) is considered to be a chronic fibrosing leukocytoclastic vasculitis. Classically, multiple orange to yellow papules and plaques develop over the joints (Fig. 35-22), particularly the elbows, knees, hands, and feet. Lesions may also involve the buttocks and areas over the Achilles tendon. Petechiae and purpura can be associated with early lesions. More rarely, large plaques with nodules at the periphery may affect the trunk and extremities. Scattered nodules on the trunk with no acral lesions constitute another rare variant. With time, the papules take on a doughy to firm consistency and develop a red or purple color. In HIV infection, skin-colored or red nodules affect the soles, producing lesions resembling keloids, Kaposi sarcoma, or bacillary angiomatosis. Pruritus, arthralgias, and pain have been reported; however, most patients are



**Fig. 35-22** Erythema elevatum diutinum.



asymptomatic. Some patients with EED will develop Sweet syndrome or pyoderma gangrenosum-like ulcerations, which in one patient presented as a phagedenic penile ulceration. Systemic complications are rare, but an unusual and potentially rapidly destructive keratitis can lead to blindness. EED has been associated with HIV infection, SLE, Sjögren syndrome, lymphoma, breast cancer, lymphoepithelioma-like carcinoma, dermatitis herpetiformis, and celiac disease. IgA monoclonal gammopathy may be detected. Chronic and recurrent streptococcal infections cause exacerbations of the disease in some patients. These may all represent conditions with persistent circulating immune complexes that might trigger a chronic vasculitis. Pathogenically, ANCA (60% IgA and 33% IgG) are found in EED. ANCA-positive vasculitides, such as granulomatosis with polyangiitis and microscopic polyangiitis, have rarely been reported to have EED-like lesions.

Histologically, early lesions are an LCV, but with prominent interstitial neutrophils. Well-formed lesions are composed of nodular and diffuse mixed infiltrates of neutrophils and nuclear dust, eosinophils, histiocytes, and plasma cells that often extend into the subcutaneous fat. The prominence of eosinophils; the chronicity of the process, which results in an onion skin-like perivascular fibrosis; and the admixture of plasma cells and many lymphocytes are the hallmarks of EED. Erythrocyte extravasation may lead to extracellular cholesterol crystals in long-standing cases.

Dapsone is the treatment of choice for EED. Patients with celiac disease may respond to a gluten-free diet. Tetracycline and nicotinamide, sulfapyridine, colchicine, antimalarials, intralesional or systemic corticosteroids, topical dapsone, and surgical excision have all been reported as effective in a limited number of cases. Intermittent plasma exchange has been used successfully in patients with IgA paraproteinemia. The interstitial keratitis also responds to dapsone. Unfortunately, the late nodular lesions may not resolve with dapsone treatment.

**Barzegar M, et al:** An atypical presentation of erythema elevatum diutinum involving palms and soles. *Int J Dermatol* 2009; 48:73.

**Ben-Zvi GT, et al:** An atypical distribution of erythema elevatum diutinum. *Clin Exp Dermatol* 2014; 39(2):269–270.

**Caucanas M, et al:** Associated pyoderma gangrenosum, erythema elevatum diutinum, and Sweet's syndrome: the concept of neutrophilic disease. *Int J Dermatol* 2013; 52(10):1185–1188.

**Chan Y, et al:** Erythema elevatum diutinum in systemic lupus erythematosus. *Rheumatol Int* 2011; 31(2):259–262.

**Chandrasekaran SS, et al:** Erythema elevatum diutinum in association with dermatitis herpetiformis. *Indian Dermatol Online J* 2014; 5(1):48–50.

**Crichlow SM, et al:** Is IgA antineutrophil cytoplasmic antibody a marker for patients with erythema elevatum diutinum? A further three cases demonstrating this association. *Br J Dermatol* 2011; 164(3):675–677.

**El Fekih N, et al:** Erythema elevatum diutinum: an "idiopathic" case. *Dermatol Online J* 2011; 17(7):7.

**Frieling GW, et al:** Novel use of topical dapsone 5% gel for erythema elevatum diutinum: safer and effective. *J Drugs Dermatol* 2013; 12(4):481–484.

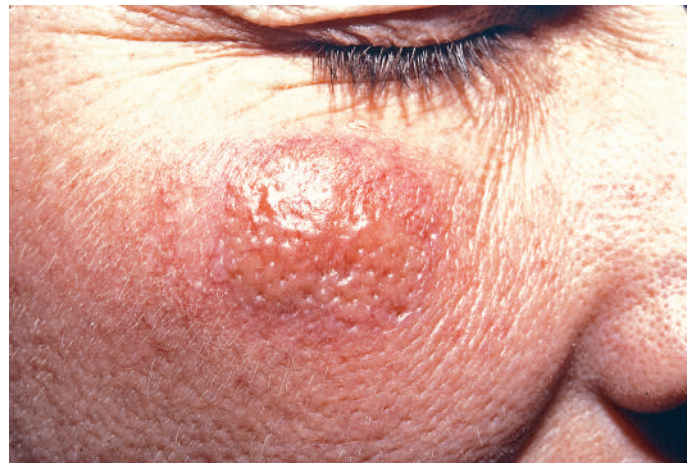**Jiao T, et al:** A case of erythema elevatum diutinum associated with peripheral ulcerative keratitis. *Australas J Dermatol* 2012; 53(1):78–80.

**Kawakami T, et al:** Acceleration of pulmonary interstitial fibrosis in a patient with myeloperoxidase-antineutrophil cytoplasmic antibody-positive erythema elevatum diutinum. *J Am Acad Dermatol* 2011; 65(3):674–675.

**Kwon JL, et al:** Erythema elevatum diutinum in association with celiac disease. *Int J Dermatol* 2009; 48(7):787–789.

**Lekhanont K, et al:** Progressive keratolysis with pseudopterygium associated with erythema elevatum diutinum. *Ophthalmology* 2011; 118(5):927–933.

**Liu TC, et al:** Erythema elevatum diutinum as a paraneoplastic syndrome in a patient with pulmonary lymphoepithelioma-like carcinoma. *Lung Cancer* 2009; 63:151.



**Fig. 35-23** Granuloma faciale.

**Marie I, et al:** Erythema elevatum diutinum associated with dermatomyositis. *J Am Acad Dermatol* 2011; 64(5):1000–1001.

**Shimizu S, et al:** Erythema elevatum diutinum with primary Sjögren syndrome associated with IgA antineutrophil cytoplasmic antibody. *Br J Dermatol* 2008; 159:733.

**Smitha P, et al:** A case of extensive erosive and bullous erythema elevatum diutinum in a patient diagnosed with human immunodeficiency virus (HIV). *Int J Dermatol* 2011; 50(8):989–991.

**Wahl CE, et al:** Erythema elevatum diutinum. *Am J Dermatopathol* 2005; 27:397.

**Zacaron LH, et al:** Clinical and surgical therapeutic approach in erythema elevatum diutinum: case report. *An Bras Dermatol* 2013; 88(6 Suppl 1):15–18.

## Granuloma faciale

Characterized by brownish red, infiltrated papules, plaques (Fig. 35-23), and nodules, granuloma faciale involves the facial areas, particularly the nose. Healthy, middle-age (mean 53 years) white men (male/female ratio 5:1) are most often affected. Childhood cases have been reported. Extrafacial disease occurs in up to 20% of patients, usually affecting the upper trunk and extremities. The pathology of granuloma faciale is similar to that of EED, with focal LCV, diffuse dermal neutrophilia with leukocytoclasia, tissue eosinophilia, and perivascular fibrosis. Some histologic features, including an abnormal content of IgG4 plasma cells, may be similar to those of IgG4-related sclerosing diseases. A variety of treatment options are available. Intralesional corticosteroids are the recommended first approach. Cryotherapy in combination with intralesional corticosteroids has been shown to be very effective. Topical corticosteroids or tacrolimus may also be useful. Although controlled clinical trials are lacking, dapsone, colchicine, or antimalarials could be considered if the patient remains unresponsive. Pulsed dye or carbon dioxide (CO<sub>2</sub>) laser therapy has been effective in multiple cases, making it a reasonable consideration as first-line treatment.

**Bakkour W, Madan V:** Rhinophyma-like granuloma faciale successfully treated with carbon dioxide laser. *Br J Dermatol* 2014; 170(2):474–475.

**Cesinaro AM, et al:** Granuloma faciale: a cutaneous lesion sharing features with IgG4-associated sclerosing diseases. *Am J Surg Pathol* 2013; 37(1):66–73.

**Dowlati B, et al:** Granuloma faciale: successful treatment of nine cases with a combination of cryotherapy and intralesional corticosteroid injection. *Int J Dermatol* 1997; 36:548.

**Erceg A, et al:** The efficacy of pulsed dye laser treatment for inflammatory skin diseases: a systematic review. *J Am Acad Dermatol* 2013; 69(4):609–615.

**Gupta L, et al:** Granuloma faciale with extrafacial involvement and response to tacrolimus. *J Cutan Aesthet Surg* 2012; 5(2):150–152.

**Marcovall J, et al:** Granuloma faciale: a clinicopathological study of 11 cases. *J Am Acad Dermatol* 2004; 51:269.

## POLYARTERITIS NODOSA

Polyarteritis nodosa (PAN) is characterized by necrotizing vasculitis affecting primarily the small to medium-sized arteries. There are two major forms, the benign cutaneous and the systemic, although even long-standing benign cutaneous PAN can evolve into systemic disease. In 1990, the American College of Rheumatology selected the following 10 features of systemic PAN, at least three of which should be present for diagnosis:

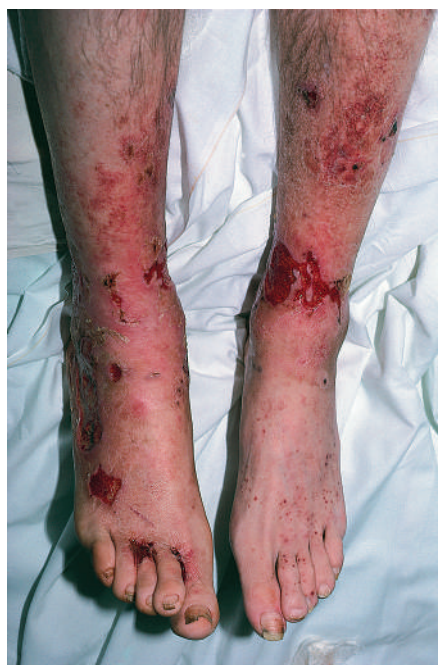1. Livedo racemosa
2. Polymorphonuclear arteritis
3. Leg pain/myopathy/weakness
4. Mononeuropathy/polyneuropathy
5. Positive hepatitis B virus (HBV) serology
6. Weight loss >4 kg
7. Testicular pain/tenderness
8. Diastolic blood pressure >90 mm Hg
9. Elevated BUN/creatinine
10. Arteriographic abnormality

Systemic PAN shares some clinical features with microscopic polyangiitis (MPA), but the strong association of MPA with ANCA positivity, the involvement of renal glomeruli and pulmonary capillaries, and the presence of vasculitis in arterioles, venules, and capillaries help distinguish MPA from PAN.

The mean age of presentation is 45–50 years, and PAN is two to four times more common in men than women. A cutaneous vasculitis identical to PAN has been seen in IV drug abusers (see later) and in association with SLE, inflammatory bowel disease, hairy cell leukemia, familial Mediterranean fever, and Cogan syndrome (nonsyphilitic interstitial keratitis and vestibuloauditory symptoms). Reported infectious associations include hepatitis B, hepatitis C, antecedent streptococcal infection, and many others. Vascular-based tuberculids (erythema induratum, nodular tuberculid) may have histology identical to PAN. The proportion of PAN cases associated with HBV was previously higher but is currently about 5–7% of cases overall and decreasing with HBV immunization. The identification of associated hepatitis virus infection has therapeutic and prognostic implications.

The skin is involved in up to 50% of patients with the systemic form of PAN, with wide-ranging findings. The most striking and diagnostic lesions (15% of patients) are 5–10 mm subcutaneous nodules occurring singly or in groups, distributed along the course of the blood vessels, above which the skin is normal or slightly erythematous (macular arteritis). These nodules are often painful and may pulsate and over time ulcerate (Fig. 35-24). Common sites are the lower extremities, especially below the knee. Ecchymoses and peripheral gangrene of the fingers and toes may also be present. Livedo reticularis in combination with subcutaneous nodules strongly suggests the diagnosis of PAN. Palpable purpura with histologic features of cutaneous LCV may be seen in 20% of PAN patients. Urticaria is present in 6%. HBV-associated PAN is associated with cutaneous findings in only 30% of patients.

Classic systemic PAN may involve the vessels throughout the entire body. It has a particular predilection for the skin, peripheral nerves, GI tract, and kidneys. Hypertension (from renal involvement in 80%), tachycardia, fever, edema, and



**Fig. 35-24** Polyarteritis nodosa with multiple leg ulcerations.

weight loss (>70%) are cardinal signs of the disease. Arthralgia/arthritis (up to 75%), myocardial and intestinal infarctions, and peripheral neuritis (75%) are also seen. Mononeuritis multiplex, most often manifested as footdrop, is a hallmark of PAN. Involvement of the meningeal, vertebral, and carotid arteries may lead to hemiplegia and convulsions. The lungs and spleen are rarely involved. Aneurysms develop, which may result in multiorgan infarcts. A Five Factor Score (FFS) has been validated, with 1 point each for proteinuria (>1 g/d), renal insufficiency (serum creatinine >1.58 mg/dL), GI tract involvement, CNS involvement, and cardiomyopathy. The 5-year survival for patients with FFS of 0, 1, and more than 2 are 88%, 75%, and 54%, respectively. Among survivors, relapses remain common. Before the use of systemic immunosuppressives, the mortality for systemic PAN exceeded 90%.

A leukocytosis of as high as 40,000/mm<sup>3</sup> may occur, with neutrophilia up to 80%; thrombocytosis, progressive normocytic anemia, and elevated ESR and C-reactive protein (CRP) may also be found. Hepatitis B and C studies should be performed. Urinary abnormalities, such as proteinuria, hematuria, and RBC casts, are present in 70% of patients. ANCA positivity in PAN is rare (if present, most often p-ANCA), whereas the more specific proteinase-3 and myeloperoxidase antibodies are negative.

The histology is that of an inflammatory necrotizing and obliterative panarteritis that affects the small and medium-sized arteries. Focal vasculitis forms nodular swellings that become necrotic, producing aneurysms and rupture of the vessels. Hemorrhage, hematoma, and ecchymosis may result. Obliteration of the lumen may occur, with ischemic necrosis of surrounding tissue. Characteristically, the arteries are affected at their branching points. Biopsy samples of skin nodules or ulcers must be sufficiently deep to include affected vessels in the deep dermis or subcutis.

The mainstay of diagnosis is the presence of these histologic features and the constellation of clinical findings. The preferable site for biopsy is an accessible area such as skin, muscle, or testis. If these are not involved, angiography may detect aneurysmal dilations as small as 1 cm wide in the renal, hepatic, or other visceral vessels; the angiographic appearance of these aneurysms is characteristic, if not pathognomonic.



## Treatment

Untreated classic PAN can be fatal, usually from renal failure or cardiovascular or GI complications. Death generally occurs early in the course of the disease, within weeks to months, highlighting the importance of early diagnosis and treatment. Patients with HBV- or HCV-associated PAN should receive appropriate antiviral treatments as part of their initial therapy. For PAN not associated with HBV or HCV, treatment with corticosteroids and cytotoxic agents has increased 5-year survival to more than 75%. Corticosteroids, in the range of 1 mg/kg/day of oral prednisone, are given initially. Once the disease remits, the dose should be reduced. After an average of 3–6 months, if the patient remains in remission, the corticosteroids are slowly tapered to discontinuation.

Cyclophosphamide is recommended for those with serious systemic involvement or steroid-refractory disease. It is given with corticosteroids or sometimes alone. Initially, 2 mg/kg/day as a single dose is recommended. Twice this amount may be required for severely ill patients. The oral cyclophosphamide dose is then adjusted to maintain the white blood cell (WBC) count between 3000 and 3500 cells/mm<sup>3</sup> and neutrophil count above 1500 cells/mm<sup>3</sup>. When the disease has been quiescent for at least 1 year, the cyclophosphamide may be tapered and stopped. On average, 18–24 months of therapy are required. Pulsed IV cyclophosphamide is associated with a lower incidence of toxicity, especially the long-term risk of malignancy. Plasma exchange may be used for acute crises or treatment failures with corticosteroids and cyclophosphamide. Ulcerations in PAN can be very painful because of the associated neuropathy and should be managed as nonhealing leg ulcers.

### Cutaneous polyarteritis nodosa

About 10% of patients present with PAN localized to the skin and have limited systemic involvement. Neuropathy occurs in 20%. Subcutaneous nodules (80%), livedo (70%), and ulceration (44%) are the characteristic cutaneous features that should lead to suspicion of cutaneous PAN. Atrophic blanche-like lesions on the ankles may be the sole manifestation. Plaques on the trunk and proximal extremities, expanding slowly and centrifugally, are another manifestation. At the periphery of the plaques is a ring of 1–2 cm subcutaneous nodules. Cutaneous PAN has a better prognosis and requires less aggressive therapy. Patients rarely develop the systemic renal, GI, and cardiovascular complications of systemic PAN. This form of PAN is the most common childhood pattern of PAN. Whether there are two clear subsets of patients, with cutaneous or systemic PAN, or whether they exist on a spectrum, is controversial. Patients with “cutaneous” PAN must be followed carefully and regularly evaluated to exclude the development of systemic involvement, which may appear as long as two decades after the initial diagnosis.

The diagnosis of cutaneous PAN is made by biopsy of a subcutaneous nodule. An excisional biopsy is recommended because the vasculitis is focal. The affected arteriole is at the junction of the dermis and subcutaneous tissue or in the subcutaneous fat. Adjacent to the affected vessel, there is an inflammatory panniculitis, and inadequate evaluation of the biopsy or too small a sample may lead to the erroneous diagnosis of a panniculitis. Also distal to the affected arteriole, thrombosis usually occurs. If the biopsy is inadequate in depth or size, this bland thrombosis without inflammation is seen, and the erroneous diagnosis of a “vasculopathy” will be made. Cutaneous PAN has been associated with HBV surface antigenemia, HCV infection, Crohn’s disease, Takayasu arteritis,

relapsing polyarthritides, streptococcal infections, tuberculosis, and medications (minocycline). Typically, the only laboratory abnormality is an elevated ESR or CRP. In some cases, a p-ANCA may be present. Most patients respond well to aspirin, NSAIDs, prednisone, pentoxifylline, sulfapyridine, colchicine, dapsone, methotrexate, or MMF alone or in some combination. In childhood cutaneous PAN, since streptococcal infection is common, penicillin treatment may be used. In refractory cases, IVIG may be given.

- Asano Y, et al:** High-dose intravenous immunoglobulin infusion in polyarteritis nodosa: report on one case and review of the literature. *Clin Rheumatol* 2006; 25:396.
- Beckum KM, et al:** Polyarteritis nodosa in childhood: recognition of early dermatologic signs may prevent morbidity. *Pediatr Dermatol* 2014; 31(1):e6–e9.
- Chan PT, et al:** Inflammatory plaque with peripheral nodules: a new specific finding of cutaneous polyarteritis nodosa. *J Am Acad Dermatol* 2009; 60:320.
- De Menthon M, Mahr A:** Treating polyarteritis nodosa: current state of the art. *Clin Exp Rheumatol* 2011; 29(1 Suppl 64):S110–S116.
- Falcini F, et al:** Clinical overview and outcome in a cohort of children with polyarteritis nodosa. *Clin Exp Rheumatol* 2014; 32(2 Suppl 82):S134–S137.
- Fernanda F, et al:** Mycophenolate mofetil treatment in two children with severe polyarteritis nodosa refractory to immunosuppressant drugs. *Rheumatol Int* 2012; 32(7):2215–2219.
- Fortin PR, et al:** Prognostic factors in systemic necrotizing vasculitis of the polyarteritis nodosa group: a review of 45 cases. *J Rheumatol* 1995; 22:78.
- Guillevin L, et al:** Prognostic factors in polyarteritis nodosa and Churg-Strauss syndrome: a prospective study in 342 patients. *Medicine (Baltimore)* 1996; 75:17.
- Hernández-Rodríguez J, et al:** Diagnosis and classification of polyarteritis nodosa. *J Autoimmun* 2014; 48/49:84–89.
- Kawakami T, Soma Y:** Use of mizoribine in two patients with recalcitrant cutaneous polyarteritis nodosa. *J Am Acad Dermatol* 2011; 64(6):1213–1214.
- Kermani TA, et al:** Polyarteritis nodosa-like vasculitis in association with minocycline use: a single-center case series. *Semin Arthritis Rheum* 2012; 42(2):213–221.
- Kluger N, et al:** Ulcerative cutaneous polyarteritis nodosa treated with mycophenolate mofetil and pentoxifylline. *J Dermatolog Treat* 2011; 22(3):175–177.
- Mimouni D, et al:** Cutaneous polyarteritis nodosa in patients presenting with atrophic blanche. *Br J Dermatol* 2003; 148:789.
- Rogalski C, Sticherling M:** Panarteritis cutanea benigna—an entity limited to the skin or cutaneous presentation of a systemic necrotizing vasculitis? Report of seven cases and review of the literature. *Int J Dermatol* 2007; 46:817.
- Saadoun D, et al:** Hepatitis C virus-associated polyarteritis nodosa. *Arthritis Care Res (Hoboken)* 2011; 63(3):427–435.
- Samson M, et al:** Long-term follow-up of a randomized trial on 118 patients with polyarteritis nodosa or microscopic polyangiitis without poor-prognosis factors. French Vasculitis Study Group (FVSG). *Autoimmun Rev* 2014; 13(2):197–205.
- Segelmark M, Selga D:** The challenge of managing patients with polyarteritis nodosa. *Curr Opin Rheumatol* 2007; 19:33.

### ANCA-POSITIVE VASCULITIDES

Antineutrophil cytoplasmic antibodies (ANCA) are an important laboratory finding used in the diagnosis and prognosis of systemic vasculitis. ANCA occur in three patterns: cytoplasmic (c-ANCA), perinuclear (p-ANCA), and atypical ANCA. The initial screening is performed using indirect immunofluorescence, then confirmed using ELISA for characterization of target antigens. c-ANCA is associated with antibodies directed against proteinase 3 (PR3). Antibodies against myeloperoxidase (MPO) result in the p-ANCA pattern, but antibodies against other antigens may also give this pattern. Only ANCA against PR3 or MPO are associated with primary vasculitic

syndromes; atypical ANCA are directed against neither. Most laboratories now perform specific tests to determine whether positive ANCA are reactive against MPO or PR3. Anti-PR3 antibodies are relatively specific for granulomatosis with polyangiitis (Wegener's granulomatosis) and microscopic polyangiitis. Antibodies against MPO are less specific and can be found in microscopic polyangiitis, eosinophilic granulomatosis with polyangiitis (Churg-Strauss syndrome), and drug-induced vasculitis. Usually, either anti-MPO or anti-PR3 antibodies are found, but not both. If both patterns are found, drug-induced vasculitis should be suspected.

The ANCA-associated vasculitides—microscopic polyangiitis (MPA), granulomatosis with polyangiitis (GPA), and eosinophilic granulomatosis with polyangiitis (EGPA)—have overlapping features, characteristically demonstrating pulmonary hemorrhage and/or necrotizing glomerulonephritis (pulmonary-renal syndrome). Conversely, 60% of patients with the pulmonary-renal syndrome will have ANCA-associated vasculitis. With ANCA testing, these diseases can be diagnosed with 85% sensitivity and 98% specificity. However, although ANCA are usually negative in Takayasu arteritis, giant cell arteritis, Kawasaki disease, and Behçet's disease, positive ANCA can be found in cryoglobulinemia and other forms of skin-limited vasculitis, SLE, RA, inflammatory bowel disease, and certain infectious diseases. ANCA are most useful, therefore, when confirmed by ELISA testing in the setting of vasculitis with systemic features or in situations where the clinical findings suggest ANCA-associated vasculitis. ANCA testing, when used appropriately, is highly sensitive and specific, but it does not replace these clinical features, other relevant laboratory tests, or histologic confirmation of the presence of vasculitis.

### Microscopic polyangiitis

With the advent of ANCA serologies and clarification of the features of MPA, this diagnosis is becoming increasingly more common. There is a north-south gradient in incidence, with southern European countries having three to four times as many cases. Most patients with MPA have systemic symptoms, such as fever, weight loss, myalgias, and arthralgias, which can present with an acute flulike illness or evolve for months to years before a more explosive phase of the disease. These cases have been termed "slowly progressive MPA." Most patients with MPA will have or develop segmental necrotizing and crescentic glomerulonephritis (80–90%), with pulmonary involvement in 25–65%. Pulmonary capillaritis, which can be complicated by hemorrhage, occurs in 12–29% of MPA patients. The skin is involved in 44%. Purpuric papules and macules are most common, and livedo reticularis, retiform purpura, cutaneous ulcers, and digital ischemia are also seen. Urticarial lesions occur in 1% of cases. Patients with MPA may present with skin lesions as their initial clinical findings. Livedo is seen in two thirds of such patients. Biopsies of macules, papules, petechiae, or sites adjacent to ecchymoses may reveal a necrotizing LCV in the reticular dermis.

Vasculitic neuropathy is common (58%), and eye disease may occur. Eosinophilia and asthma are not seen. ANCA are positive in 70% of cases, p-ANCA more frequently than c-ANCA. MPA is differentiated from PAN by the presence of glomerulonephritis, pulmonary symptoms, and the absence of hypertension and microaneurysms. ANCA are rarely positive in PAN.

Microscopic polyangiitis is managed similar to other forms of ANCA-associated vasculitis, with systemic corticosteroids and often cytotoxic agents from disease onset. Glucocorticoid monotherapy is associated with lower remission rates. In

generalized but non-organ-threatening disease, methotrexate may be added to prednisone, 1 mg/kg/day or equivalent, as initial therapy. For more severe disease, cyclophosphamide is usually given instead with glucocorticoids in the early induction phase of treatment as monthly pulses (vs. daily treatment) for 6–12 months. This regimen has a lower relapse rate compared with the combination of methotrexate and corticosteroids, Rituximab in combination with glucocorticoids is another option for induction of remission shown not to be inferior to combination cyclophosphamide and prednisone for MPA and GPA. Other, less toxic immunosuppressives, such as methotrexate, azathioprine, and MMF, may be used in milder cases or as maintenance therapy. IVIG and anti-TNF agents (infliximab) may be considered in refractory cases. Relapses are frequent. The 5-year survival is about 75%, and 7-year survival is 62%.

**Bosch X, et al:** Treatment of antineutrophil cytoplasmic antibody-associated vasculitis: a systematic review. *JAMA* 2007; 298:655.

**Cohen Tervaert JW, Damoiseaux J:** Antineutrophil cytoplasmic autoantibodies: how are they detected and what is their use for diagnosis, classification and follow-up?. *Clin Rev Allergy Immunol* 2012; 43(3):211–219.

**Finkelman JD, et al:** Antiproteinase 3 antineutrophil cytoplasmic antibodies and disease activity in Wegener granulomatosis. *Ann Intern Med* 2007; 147(9):611–619.

**Guilleven L, et al:** Microscopic polyangiitis: clinical and laboratory findings in eighty-five patients. *Arthritis Rheum* 1999; 42:421.

**Iatrou C, et al:** Mycophenolate mofetil as maintenance therapy in patients with vasculitis and renal involvement. *Clin Nephrol* 2009; 72(1):31–37.

**Kallenberg CG:** The diagnosis and classification of microscopic polyangiitis. *J Autoimmun* 2014; 48/49:90–93.

**Kluger N, et al:** Comparison of cutaneous manifestations in systemic polyarteritis nodosa and microscopic polyangiitis. *Br J Dermatol* 2008; 159:615.

**Niyama S, et al:** Dermatological manifestations associated with microscopic polyangiitis. *Rheumatol Int* 2008; 28:593.

**Sinico RA, Radice A:** Antineutrophil cytoplasmic antibodies (ANCA) testing: detection methods and clinical application. *Clin Exp Rheumatol* 2014; 32(2 Suppl 82):S112–S117.

**Stone JH, et al:** Rituximab versus cyclophosphamide for ANCA-associated vasculitis. *N Engl J Med* 2010; 363(3):221–232.

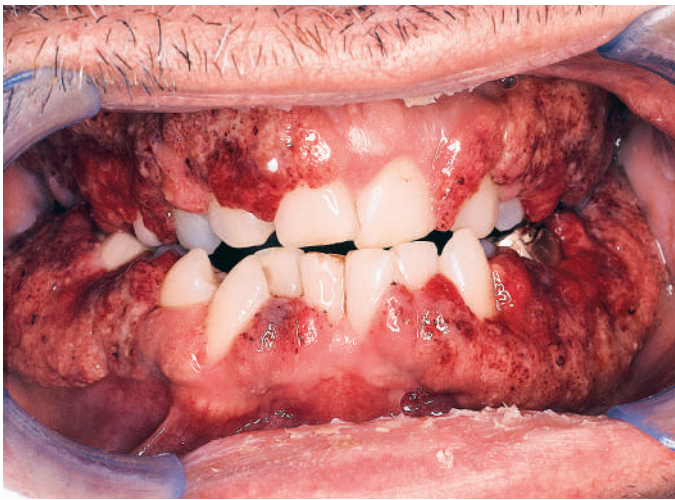
**Terrier B, et al:** Antimyeloperoxidase antibodies are a useful marker of disease activity in antineutrophil cytoplasmic antibody-associated vasculitides. *Ann Rheum Dis* 2009; 68(10):1564–1571.

**Wilke L, et al:** Microscopic polyangiitis: a large single-center series. *J Clin Rheumatol* 2014; 20(4):179–182.

### Granulomatosis with polyangiitis (Wegener's granulomatosis)

Granulomatosis with polyangiitis (GPA) is a syndrome consisting of necrotizing granulomas of the upper and lower respiratory tract, generalized necrotizing angiitis affecting small and medium-sized blood vessels, and focal necrotizing glomerulitis. By far the most common initial manifestation, present in 90% of patients, is the occurrence of rhinorrhea, severe sinusitis, and nasal mucosal ulcerations, with one or several nodules in the nose, larynx, trachea, or bronchi. Failure to respond to conventional treatment for sinusitis may prompt suspicion of the diagnosis. Fever, weight loss, and malaise occur in these patients, who are usually 40–50 years of age and more often male than female (1.3:1). Obstruction in the nose may also block the sinuses. The nodules in the nose frequently ulcerate and bleed. The parenchymal involvement of the lungs produces cough, dyspnea, and chest pain; 71% of patients have pulmonary infiltrates radiographically. Granulomas may occur in the ear and mouth, where the alveolar ridge becomes necrotic, and ulceration of the tongue and perforated ulcers of





**Fig. 35-25** Wegener's granulomatosis, strawberry gingiva.

the palate develop. The combination of nasal and palatal involvement may lead to saddle-nose deformity. The “strawberry gums” appearance of hypertrophic gingivitis is characteristic, and biopsy of these lesions may be diagnostic (Fig. 35-25).

Cutaneous findings occur in 45% of GPA patients. Nodules may appear in crops, especially along the extensor surfaces of the extremities. The firm, slightly tender, flesh-colored or violaceous nodules may later ulcerate. These may be mistaken for ulcerating rheumatoid nodules. The necrotizing angitis of the skin may present as a palpable purpura, petechial or hemorrhagic pustular eruption, subcutaneous nodules, or ulcers. Livedo reticularis is rare in GPA. Patients may present with pyoderma gangrenosum-like lesions, and several patients have been reported presenting with features of temporal arteritis. The condition previously described as “malignant pyoderma” is now thought to represent GPA.

Limited forms of GPA involving the upper respiratory tract without renal involvement may also occur and have a better prognosis. Cutaneous findings can be associated with limited disease. Focal crescentic necrotizing glomerulonephritis occurs in 85% of GPA patients. It may be fulminant from the outset or may become more severe as the disease progresses. Renal failure was the most frequent cause of death before cyclophosphamide treatment. Other organs frequently involved include the joints (arthralgia in two-thirds); eyes (conjunctivitis, episcleritis, and proptosis) in 58%; and the CNS and heart in 22% and 12% of patients, respectively.

Histologically, the cutaneous lesions may demonstrate an LCV, with or without granulomatous inflammation. Granulomatous vasculitis may be seen. Palisaded granulomas with multinucleated giant cells and a central core of neutrophils and debris are a characteristic finding. Often, if the lesions are ulcerated, they are nonspecific histologically. Biopsy of another affected organ, such as the kidney, lung, or upper respiratory tract, may be required to confirm the diagnosis. The early detection of GPA has improved with the availability of ANCA testing, because almost 100% of patients with active generalized GPA are ANCA positive by either indirect immunofluorescence or ELISA. Almost 90% are c-ANCA (anti-PR3) positive, with the remainder p-ANCA (anti-MPO) positive and very few ANCA negative.

Untreated GPA has a mean survival time of 5 months and a 90% mortality over 2 years. Cyclophosphamide therapy has dramatically changed the prognosis; however, therapy-related adverse events now account for more deaths in the first year after diagnosis than the vasculitis itself. Treatment

recommendations are cyclophosphamide, 2 mg/kg/day, and prednisone, 1 mg/kg/day, followed by slow tapering of the prednisone to not less than 15 mg/day during the first 3 months of therapy. Complete remission is achieved in up to 93% of patients and lasts an average of 4 years. Rituximab combined with high-dose glucocorticoids is an alternative to cyclophosphamide for induction therapy and was approved by the FDA in 2011. In more limited disease, patients may respond to methotrexate alone or in combination with prednisone. After initial induction therapy and remission, methotrexate, azathioprine, leflunomide, MMF, or rituximab may be used instead of cyclophosphamide. Treatment should be continued for at least 1 year. Trimethoprim-sulfamethoxazole (TMP-SMX) may decrease the relapse rate and can be considered for long-term treatment of patients with limited upper respiratory tract involvement in remission, in combination with conventional immunosuppressive protocols. The benefit of long-term TMP-SMX results from its reduction of nasal carriage of *Staphylococcus aureus*, a possible trigger of GPA. In refractory cases, plasma exchange, IVIG, and anti-TNF therapy (infliximab) may be used. Tacrolimus, 0.1 mg/kg/day, was successful in treating a pyoderma gangrenosum-like ulceration in a patient with GPA.

**Falk RJ, et al:** Granulomatosis with polyangiitis (Wegener's): an alternative name for Wegener's granulomatosis. American College of Rheumatology, American Society of Nephrology, European League Against Rheumatism. *Arthritis Rheum* 2011; 63(4):863–864.

**Hiemstra TF, et al:** Mycophenolate mofetil vs azathioprine for remission maintenance in antineutrophil cytoplasmic antibody-associated vasculitis: a randomized controlled trial. *JAMA* 2010; 304(21):2381–2388.

**Kallenberg CG:** Key advances in the clinical approach to ANCA-associated vasculitis. *Nat Rev Rheumatol* 2014; Jul 1. doi: 10.1038/nrrheum.2014.104. [Epub ahead of print.]

**Little MA, et al:** Early mortality in systemic vasculitis: relative contribution of adverse events and active vasculitis. *Ann Rheum Dis* 2010; 69(6):1036–1043.

**Manchanda Y, et al:** Strawberry gingiva: a distinctive sign in Wegener's granulomatosis. *J Am Acad Dermatol* 2003; 49:335.

**Mukhtyar C, et al:** EULAR recommendations for the management of primary small and medium vessel vasculitis. *Ann Rheum Dis* 2009; 68:310–317.

**Ong Tone S, et al:** Polyangiitis overlap syndrome with granulomatosis with polyangiitis (Wegener's) and giant cell arteritis. *Can J Ophthalmol* 2013; 48(1):e6–e8.

**Specks U, et al:** Efficacy of remission-induction regimens for ANCA-associated vasculitis. *N Engl J Med* 2013; 369(5):417–427.

**Tashtoush B, et al:** Large pyoderma gangrenosum-like ulcers: a rare presentation of granulomatosis with polyangiitis. *Case Rep Rheumatol* 2014; 2014:850364.

**Walsh M, et al:** Effects of duration of glucocorticoid therapy on relapse rate in antineutrophil cytoplasmic antibody-associated vasculitis: a meta-analysis. *Arthritis Care Res (Hoboken)* 2010; 62(8):1166–1173.

**Wenzel J, et al:** Successful treatment of recalcitrant Wegener's granulomatosis of the skin with tacrolimus (Prograf). *Br J Dermatol* 2004; 151:927.

### Eosinophilic granulomatosis with polyangiitis (Churg-Strauss syndrome)

Eosinophilic granulomatosis with polyangiitis (EGPA) occurs in three phases. The initial phase, often lasting many years, consists of allergic rhinitis, nasal polyps, and asthma. The average age of onset of the asthma is 35 years in EGPA (unlike allergic asthma, which often presents in childhood). After 2–12 years, a debilitated asthmatic patient begins to experience attacks of fever and eosinophilia (20–90%), with pneumonia and gastroenteritis caused by eosinophilic infiltration (second phase). After a few more months or years, but on average 3

years after the initial symptoms, a diffuse small-vessel and medium-vessel vasculitis with granulomatous inflammation involves the lungs, heart, liver, spleen, kidneys, intestines, and pancreas. Mononeuritis multiplex is common. Triggers of this third phase have included vaccination, desensitization, leukotriene inhibitors, azithromycin, inhaled fluticasone, and rapid discontinuation of corticosteroids. Renal involvement is less common than in GPA or MPA. A fatal outcome is likely in most untreated patients; congestive heart failure resulting from granulomatous inflammation of the myocardium is the most frequent cause of death. Increased rates of arterial and venous thrombosis are seen in EGPA, perhaps related to the dense infiltrates of eosinophils.

Cutaneous lesions are present in two thirds of EGPA patients. Palpable purpura is seen in almost 50%. Subcutaneous nodules on the extensor surfaces of the extremities and on the scalp are seen in 30%. Firm, nontender papules may be present on the fingertips; these may resemble the lesions seen with septic emboli or atrial myxoma but show vasculitis on biopsy. Urticaria, solar urticaria, and livedo reticularis can occur in EGPA. Plaques with the histologic features of eosinophilic cellulitis (Wells syndrome) can be seen.

Laboratory studies are significant for a peripheral eosinophilia, which correlates with disease severity. ANCAs are frequently positive (55–70%), most often p-ANCA (anti-MPO) and less frequently c-ANCA (anti-PR3), and tend to correlate with disease severity.

Histologically, a small-vessel vasculitis is present that involves not only superficial venules, but also larger and deeper vessels. The tissue is often diffusely infiltrated with eosinophils, and granulomas may be present. Palisaded granulomas differ from those in Wegener's granulomatosis in that they generally lack multinucleated giant cells, and the core contains eosinophils. In some patients, flame figures, similar to those in Wells syndrome, are noted in the dermis.

Corticosteroids alone may be used in patients with EPGA and FFS of 0 (see [Polyarteritis nodosa](#)). Cyclophosphamide alone or in combination with corticosteroids should be used in patients with neuropathy, refractory glomerulonephritis, myocardial disease, severe GI disease, and CNS involvement. When treatment is stratified in this way, survival is good, about 90% at 7 years. However, 40% of patients experience one or more relapses, usually with steroid taper. Azathioprine, as well as methotrexate and leflunomide, is used as a steroid-sparing agent, especially to maintain a remission. IFN alfa, MMF, and the anti-TNF agents infliximab and etanercept have also been used successfully in patients with EPGA (Churg-Strauss syndrome).

**Abe R, et al:** Disseminated subcutaneous nodules alone as manifestations of Churg-Strauss syndrome. *Int J Dermatol* 2008; 47:532.

**Black JG, et al:** Montelukast-associated Churg-Strauss vasculitis: another associated report. *Ann Allergy Asthma Immunol* 2009; 102:351.

**Comarmond C, et al:** Eosinophilic granulomatosis with polyangiitis (Churg-Strauss): clinical characteristics and long-term follow-up of the 383 patients enrolled in the French Vasculitis Study Group cohort. *Arthritis Rheum* 2013; 65(1):270–281.

**Davis MDP, et al:** Cutaneous manifestations of Churg-Strauss syndrome. *J Am Acad Dermatol* 1997; 37:199.

**Grau RG:** Churg-Strauss syndrome: 2005–2008 update. *Curr Rheumatol Rep* 2008; 10(6):453–458.

**Ishibashi M, et al:** Spectrum of cutaneous vasculitis in eosinophilic granulomatosis with polyangiitis (Churg-Strauss): a case series. *Am J Dermatopathol* 2014; Jul 30. [Epub ahead of print.]

**Jaworsky C:** Leukotriene receptor antagonists and Churg-Strauss syndrome: an association with relevance to dermatopathology? *J Cutan Pathol* 2008; 35:611.

**Kim MY, et al:** Clinical features and prognostic factors of Churg-Strauss syndrome. *Korean J Intern Med* 2014; 29(1):85–95.

**Marmursztejn J, et al:** Churg-Strauss syndrome cardiac involvement evaluated by cardiac magnetic resonance imaging and positron-emission tomography: a prospective study on 20 patients. *Rheumatology (Oxford)* 2013; 52(4):642–650.

**Metzler C, et al:** A Phase II study of interferon-alpha for the treatment of refractory Churg-Strauss syndrome. *Clin Exp Rheumatol* 2008; 26(3 Suppl 49):S35–S40.

**Mouthon L, et al:** Diagnosis and classification of eosinophilic granulomatosis with polyangiitis (formerly named Churg-Strauss syndrome). *J Autoimmun* 2014; 48/49:99–103.

**Nepal M, Padma H:** Fluticasone-associated cutaneous allergic granulomatous vasculitis: an underrecognized but important cause of drug-induced cutaneous Churg-Strauss syndrome. *South Med J* 2008; 101:761.

**Ratzinger G, et al:** Wells syndrome and its relationship to Churg-Strauss syndrome. *Int J Dermatol* 2013; 52(8):949–954.

**Samson M, et al:** Long-term outcomes of 118 patients with eosinophilic granulomatosis with polyangiitis (Churg-Strauss syndrome) enrolled in two prospective trials. French Vasculitis Study Group. *J Autoimmun* 2013; 43:60–69.

**Sokolowska BM, et al:** ANCA-positive and ANCA-negative phenotypes of eosinophilic granulomatosis with polyangiitis (EGPA): outcome and long-term follow-up of 50 patients from a single Polish center. *Clin Exp Rheumatol* 2014; 32(3 Suppl 82):S41–S47.

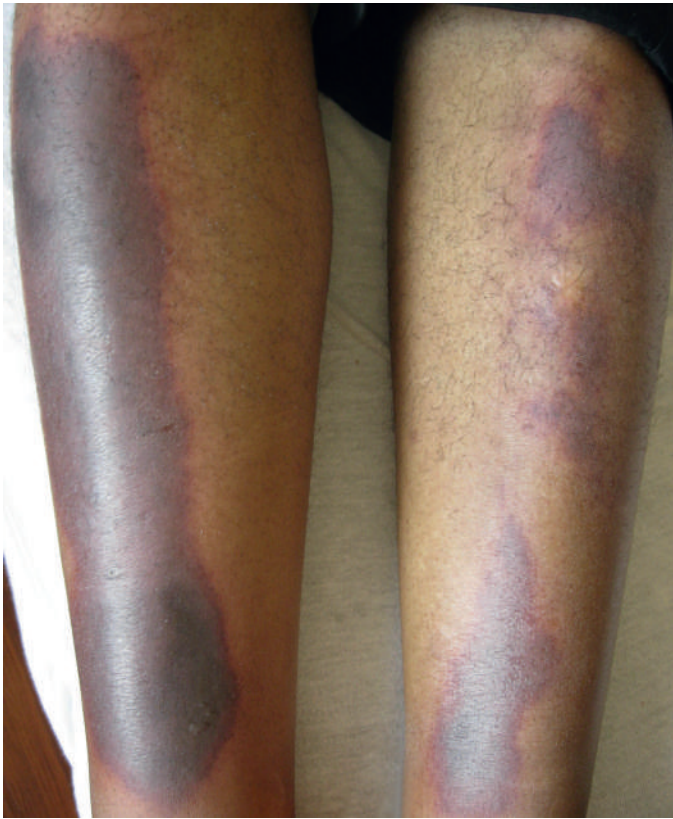**Thiel J, et al:** Rituximab in the treatment of refractory or relapsing eosinophilic granulomatosis with polyangiitis (Churg-Strauss syndrome). *Arthritis Res Ther* 2013; 15(5):R133.

## COCAINE-ASSOCIATED VASCULITIS AND LEVAMISOLE-INDUCED VASCULOPATHY/VASCULITIS

There are numerous reports of various forms of cutaneous vasculitis associated with the intravenous or intranasal use of cocaine. Skin lesions have included typical LCV, as well as larger-vessel vasculitis resembling PAN. Localized nasal lesions with vasculitis resembling GPA (Wegener's granulomatosis) have been observed in patients using inhaled cocaine. This has been termed "cocaine-induced pseudovasculitis" or "cocaine-induced midline destructive lesions" to try to distinguish it from true GPA. In addition, patients using cocaine may develop more widespread cutaneous and systemic vasculitis affecting the kidneys, lungs, and testes. The cutaneous lesions resemble LCV, but ecchymotic lesions ([Fig. 35-26](#)) and skin necrosis are more prominent in these patients than in the typical LCV patient. Purpura and necrosis of the earlobe and nose are especially common and characteristic; retiform purpura on the thighs and other areas is frequently seen. Agranulocytosis, not a typical feature of ANCA-positive vasculitis, also occurs. These patients have an elevated c-ANCA, similar to those with true GPA. However, the c-ANCA in patients with cocaine-induced vasculitis reacts with human neutrophil elastase (HNE-ANCA). Patients with GPA and MPA are negative for HNE-ANCA.

Street cocaine is often contaminated with pharmaceutical agents. Levamisole has been found in the cocaine seized by law enforcement in up to 70% of U.S. cases and 100% in Italy. Levamisole is associated with ecchymotic purpura and necrosis, with a predilection for the ears. It also causes agranulocytosis and c-ANCA positivity. It is therefore unclear whether the vasculitic lesions seen in recreational cocaine users are caused by the cocaine or by the levamisole excipient (levamisole-induced vasculopathy/vasculitis), or both. In every patient presenting with a cutaneous or systemic vasculitis, a detailed history of recreational drug use must be obtained, and toxicology screening should be considered in any patient with vasculitis having the features just outlined, especially agranulocytosis or cutaneous necrosis, or failing to





**Fig. 35-26** Cocaine-associated vasculitis.

respond to appropriate therapy. Because its half-life is only 5.6 hours, confirming the presence of levamisole in the urine can be difficult. In affected patients, stopping of the drug may lead to a gradual improvement of the vasculitis, although initial immunosuppressive therapy may be required. Treatment to eradicate nasal *S. aureus* should be considered if there are prominent nasal findings.

**Barbano G, et al:** Disseminated autoimmune disease during levamisole treatment of nephrotic syndrome. *Pediatr Nephrol* 1999; 13:602.

**Buchanan JA, et al:** Prevalence of levamisole in urine toxicology screens positive for cocaine in an inner-city hospital. *JAMA* 2011; 305(16):1657–1658.

**Chung C, et al:** Characteristic purpura of the ears, vasculitis, and neutropenia: a potential public health epidemic associated with levamisole-adulterated cocaine. *J Am Acad Dermatol* 2011; 65(4):722–725.

**Crowe DR, et al:** Clinical, histopathologic, and immunofluorescence findings in levamisole/cocaine-induced thrombotic vasculitis. *Int J Dermatol* 2014; 53(5):635–637.

**Gaertner EM, Switlyk SA:** Dermatologic complications from levamisole-contaminated cocaine: a case report and review of the literature. *Cutis* 2014; 93(2):102–106.

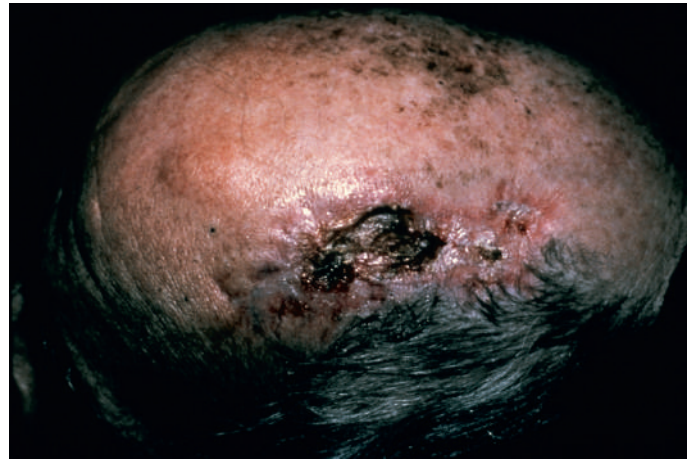**Jiménez-Gallo D, et al:** Pyoderma gangrenosum and Wegener granulomatosis–like syndrome induced by cocaine. *Clin Exp Dermatol* 2013; 38(8):878–882.

**Magro CM, Wang X:** Cocaine-associated retiform purpura: a C5b-9-mediated microangiopathy syndrome associated with enhanced apoptosis and high levels of intercellular adhesion molecule-1 expression. *Am J Dermatopathol* 2013; 35(7):722–730.

**Menni S, et al:** Ear lobe bilateral necrosis by levamisole-induced occlusive vasculitis in a pediatric patient. *Pediatr Dermatol* 1997; 14:477.

**Neynaber S, et al:** PR3-ANCA-positive necrotizing multi-organ vasculitis following cocaine abuse. *Acta Derm Venereol* 2008; 88:594.

**Pendergraft WF 3rd, Niles JL:** Trojan horses: drug culprits associated with antineutrophil cytoplasmic autoantibody (ANCA) vasculitis. *Curr Opin Rheumatol* 2014; 26(1):42–49.



**Fig. 35-27** Giant cell arteritis with scalp necrosis.

**Perez, et al:** Asculitis mimics: cocaine-induced midline destructive lesions. *Am J Med Sci* 2013; 346(5):430–431.

**Rachapalli SM, Kiely PD:** Cocaine-induced midline destructive lesions mimicking ENT-limited Wegener's granulomatosis. *Scand J Rheumatol* 2008; 37:477.

**Rongioletti F, et al:** Purpura of the ears: a distinctive vasculopathy with circulating autoantibodies complicating long-term treatment with levamisole in children. *Br J Dermatol* 1999; 140:948.

**Sánchez-Cruz A, et al:** Cocaine induced vasculitis: have we found a culprit? *Case Rep Rheumatol* 2012; 2012:982361.

**Strazzula L, et al:** Levamisole toxicity mimicking autoimmune disease. *J Am Acad Dermatol* 2013; 69(6):954–959.

**Waller JM, et al:** Cocaine-associated retiform purpura and neutropenia: is levamisole the culprit? *J Am Acad Dermatol* 2010; 63(3):530–535.

## GIANT CELL ARTERITIS/TEMPORAL ARTERITIS

Giant cell arteritis (GCA) is a systemic disease of people over age 50 (mean age >70), favoring women (2:1). It is uncommon in African Americans and favors whites. Its best-known location is the temporal artery, and it is also known as temporal arteritis, cranial arteritis, and Horton's disease. GCA is characterized by a necrotizing arteritis with granulomas and giant cells, which produce unilateral headache and exquisite tenderness in the scalp over the temporal or occipital arteries in 50–75% of patients. Temporal headaches are characteristically constant, severe, and boring. Ear and parotid pain and mastication-induced jaw claudication may occur. Fever, anemia, and a high ESR (>50) are usually present. Proximal, symmetric, and severe morning and even day-long limb girdle stiffness, soreness, and pain occur in 50% of patients (associated polymyalgia rheumatica). GCA is rarely fatal. Blindness may develop and is the most feared complication of the disease. Many patients who develop visual loss have premonitory symptoms, allowing for diagnosis and intervention, which may prevent permanent visual loss. However, failure to begin treatment within the first 48 hours of the onset of visual symptoms still may lead to permanent damage.

The cutaneous manifestations of GCA may be only inflammatory. The affected artery becomes evident as a hard, pulsating, tender, tortuous bulge under red or cyanotic skin. Another manifestation is necrosis of the scalp (Fig. 35-27). Lesions may begin as ecchymoses. Later, they may become vesicular or bullous and are followed by gangrene. Urticaria, purpura, alopecia, tender nodules, pruriginous nodules, and livedo reticularis may be seen. Lingual artery involvement may cause an accompanying red, sore, or gangrenous tongue. Nasal septal

perforation may develop. Actinic granuloma may be associated. Actinic damage of the arterial elastic tissue of the temporal artery may occur because of its superficial location. The elderly Caucasian is at greatest risk, and when lesions are biopsied, at times only the external half of the artery that received solar radiation is involved. Some posit that temporal arteritis may be an actinically induced disease.

Polymyalgia rheumatica (PMR) has a significant clinical association with GCA. Prompt treatment may forestall serious disease. About 10% of central retinal artery occlusions are caused by GCA. ESR is elevated in more than 90% of patients. Temporal artery biopsy is generally diagnostic, provided at least a 2-cm segment is provided. Even arteries that are normal on palpation may show diagnostic findings. Magnetic resonance angiography and color Doppler and duplex ultrasonography are noninvasive diagnostic methods that may aid in confirming the clinical suspicion and identifying the best site to biopsy, or may even obviate the need for biopsy. Importantly, therapy should never be postponed waiting for a biopsy. Not all patients with arteritis of the temporal artery have GCA, because temporal arteritis may be a manifestation of a systemic vasculitis such as PAN, GPA, or microscopic polyarteritis. Conversely, GCA patients may have involvement of the aorta and its proximal branches, similar to Takayasu arteritis, and are at risk of aneurysm and dissection; it is not clear whether such patients with extracranial large-vessel vasculitis require more aggressive treatment or monitoring. Pathogenically, the presence of TNF polymorphisms in patients with PMR and temporal arteritis suggests a genetic predisposition.

Treatment begins with prednisone, 60 mg/day, and continues for 1 month or until all reversible clinical and laboratory parameters (e.g., ESR) return to normal. GCA is quite steroid responsive, and tapering to a prednisone dose of 7.5–10 mg/day is usually possible. Daily therapy seems to be important and is usually necessary for a minimum of 1–2 years. Most patients achieve complete remission, which is often maintained after therapy is withdrawn. Cyclophosphamide, methotrexate, azathioprine, and anti-TNF agents may be used in refractory cases, but the data are mixed, and relapses occur when treatment is stopped. Corticosteroid therapy is usually required.

**Ball EL, et al:** Role of ultrasonography in the diagnosis of temporal arteritis. *Br J Surg* 2010; 97(12):1765–1771.

**Borchers AT, Gershwin ME:** Giant cell arteritis: a review of classification, pathophysiology, geoeidemiology and treatment. *Autoimmun Rev* 2012; 11(6/7):A544–A554.

**Brodmann M, et al:** Tongue necrosis as first symptom of giant cell arteritis (GCA). *Clin Rheumatol* 2009; 28(Suppl 1):S47–S49.

**Goicochea M, et al:** Tongue necrosis in temporal arteritis. *Headache* 2007; 47(8):1213–1215.

**Hoffman GS, et al:** Infliximab for maintenance of glucocorticosteroid-induced remission of giant cell arteritis: a randomized trial. *Ann Intern Med* 2007; 146(9):621–630.

**Karahaliou M, et al:** Colour duplex sonography of temporal arteries before decision for biopsy: a prospective study in 55 patients with suspected giant cell arteritis. *Arthritis Res Ther* 2006; 8(4):R116.

**Maksimowicz-McKinnon K, et al:** Takayasu arteritis and giant cell arteritis: a spectrum within the same disease? *Medicine (Baltimore)* 2009; 88(4):221–226.

**Martinez-Taboada VM, et al:** A double-blind placebo-controlled trial of etanercept in patients with giant cell arteritis and corticosteroid side effects. *Ann Rheum Dis* 2008; 67(5):625–630.

**Salvarani C, et al:** Polymyalgia rheumatica and giant-cell arteritis. *Lancet* 2008; 372(9634):234–245.

**Tomasson G, et al:** Risk for cardiovascular disease early and late after a diagnosis of giant-cell arteritis: a cohort study. *Ann Intern Med* 2014; 160(2):73–80.

**Tsianakas A, et al:** Scalp necrosis in giant cell arteritis: case report and review of the relevance of this cutaneous sign of large-vessel vasculitis. *J Am Acad Dermatol* 2009; 61:701.

**Waldman CW, et al:** Giant cell arteritis. *Med Clin North Am* 2013; 97(2):329–335.

## Takayasu arteritis

Known also as aortic arch syndrome and pulseless disease, Takayasu arteritis (TA) is a thrombo-obliterative process of the great vessels stemming from the aortic arch, occurring generally in young women (female/male ratio 9:1) in the second or third decade of life. It is more common in Japan, Southeast Asia, India, and South America. Radial and carotid pulses are typically obliterated. Most skin changes are caused by the disturbed circulation. There may be loss of hair and atrophy of the skin and its appendages, with underlying muscle atrophy. Occasional patients with cutaneous necrotizing or granulomatous vasculitis of small vessels have been reported. Erythematous nodules with or without livedo, simulating erythema nodosum or erythema induratum, may rarely occur. Sweet syndrome has also been reported in association with TA. Pyoderma gangrenosum-like ulcerations are well described in Japan; the lesions precede the diagnosis of TA by an average of 3 years. These lesions are more often generalized and in three quarters of cases occur on the upper extremities.

Treatment of TA with prednisone is recommended, 1 mg/kg/day tapered over 8–12 weeks to 20 mg/day or less. Methotrexate may be used for its steroid-sparing effects. The possible effectiveness of biologic therapies, such as the interleukin-6 receptor antagonist tocilizumab, is being actively investigated. With active medical and surgical intervention, the aggressive course of TA can be modified. The pyoderma gangrenosum-like lesions are also treated with systemic corticosteroids, but azathioprine, cyclophosphamide, MMF, cyclosporine, and tacrolimus have also been effective.

**Arnaud L, et al:** Pathogenesis of Takayasu's arteritis: a 2011 update. *Autoimmun Rev* 2011; 11(1):61–67.

**Ma EH, et al:** Sweet's syndrome with postinflammatory elastolysis and Takayasu arteritis in a child: a case report and literature review. *Pediatr Dermatol* 2012; 29(5):645–650.

**Minagawa A, et al:** Takayasu's arteritis with pyoderma gangrenosum and necrotizing vasculitis. *Clin Exp Dermatol* 2010; 35(3):329–330.

**Pascual-Lopez M, et al:** Takayasu's disease with cutaneous involvement. *Dermatology* 2004; 208:10.

**Rocha LK, et al:** Cutaneous manifestations and comorbidities in 60 cases of Takayasu arteritis. *J Rheumatol* 2013; 40(5):734–738.

**Unizony S, et al:** New treatment strategies in large-vessel vasculitis. *Curr Opin Rheumatol* 2013; 25(1):3–9.

## MALIGNANT ATROPHIC PAPULOSIS

Papulosis atrophicans maligna, also known as Degos' disease, is a potentially fatal obliterative arteritis syndrome. Some affected patients, perhaps as many as 70%, have a long benign course with skin lesions only, whereas in others, death occurs within a few years. Degos' disease occurs two to three times more frequently in men than in women, often presenting between ages 20 and 40. Familial kindreds are well reported. In patients with the more aggressive variant, survival averages 2–3 years after the disease has developed.

Skin lesions are usually the first sign of the disease. Clinically, Degos' disease is characterized by the presence of pale, round, edematous papules occurring mostly on the trunk. Similar lesions may occur on the bulbar conjunctiva and oral mucosa. Palms, soles, and face are spared, but the penis may be involved. Over days to weeks, the lesions become umbilicated, with an enlarging central depression. The center becomes distinctively porcelain white, while the periphery



becomes livid red and telangiectatic. Central atrophy occurs eventually. The eruption proceeds by crops in which only a few new lesions appear at any one time. One patient was reported to develop panniculitis. Lesions characteristic of Degos' disease may be seen in patients with LE, dermatomyositis, scleroderma, and GPA.

Systemically, ischemic infarcts involve the intestines, producing acute abdominal symptoms, which include epigastric pain, fever, and hematemesis. Death usually results from fulminant peritonitis caused by multiple perforations of the intestine. Less frequently, death occurs from cerebral infarctions.

Wedge-shaped necroses initiated by the occlusion of arterioles and small arteries account for the clinical lesions. Proliferation of the intima and thrombosis constitute the typical histologic picture. The thrombosing process is usually pauc-inflammatory, although neutrophils or lymphocytes may be found associated with the thrombosis. The overlying dermis, which is infarcted, contains abundant mucin, especially early in the lesion's evolution. Adnexae are typically necrotic, and the depressed central portion may be noted histologically.

The etiology of malignant atrophic papulosis is unknown, but based on the infarctive nature of the lesions and the universal presence of arteriolar thrombosis, a hyperthrombotic state or endothelial abnormality is suggested. Although most patients have not had abnormalities identified, abnormal platelet aggregation and abnormal coagulation have been identified in some cases. Antiphospholipid antibodies and anticardiolipin antibodies have been discovered in some patients, as has factor V Leiden mutation in one. Parvovirus B19 infection was associated with a fatal case in an adult. Prominent C5b-9 deposits and elevated IFN- $\alpha$  expression have also been described in vessels of the skin, GI tract, and brain, suggesting that complement-mediated vascular injury may play a role.

There is no proven therapy for Degos' disease. Administration of immunosuppressives has been mostly unsuccessful and may even worsen the disease. IVIG has been of therapeutic benefit in one patient, but failed in another. Terminal complement inhibition using the C5 protein inhibitor eculizumab has been attempted. While under investigation, eculizumab apparently has not consistently succeeded in preventing or forestalling systemic manifestations of the disease. Ingestion of low-dose acetylsalicylic acid alone or in combination with dipyridamole (Persantine) has been effective in some patients. Heparin, as described by Degos, has been helpful, and should be considered if antiplatelet therapy is ineffective. Nicotine patches, 5 mg/day, were effective in one patient. Subcutaneous treprostinil was used successfully in a case of eculizumab-resistant Degos' disease. In severe crises, fibrinolytic therapy should be considered. The prognosis is guarded in patients with systemic involvement.

**Chung HY, et al:** Degos' disease: a rare condition simulating rheumatic diseases. *Clin Rheumatol* 2009; 28:861.

**De Breucker S, et al:** Inefficacy of intravenous immunoglobulins and infliximab in Degos' disease. *Acta Clin Belg* 2008; 63:99.

**Dyrsen ME, et al:** Parvovirus B19-associated catastrophic endothelialitis with a Degos-like presentation. *J Cutan Pathol* 2008; 35:20.

**Flühler C, et al:** Malignant form of atrophic papulosis with lethal abdominal involvement. *J Eur Acad Dermatol Venereol* 2014; Jul 1. [Epub ahead of print.]

**Hohwy T, et al:** A fatal case of malignant atrophic papulosis (Degos' disease) in a man with factor V Leiden mutation and lupus anticoagulant. *Acta Derm Venereol* 2006; 86:245.

**Kanekura T, et al:** A case of malignant atrophic papulosis successfully treated with nicotine patches. *Br J Dermatol* 2003; 149:660.

**Magro CM, et al:** Degos disease: a C5b-9/interferon- $\alpha$ -mediated endotheliopathy syndrome. *Am J Clin Pathol* 2011; 135(4):599-610.

**Magro CM, et al:** The effects of eculizumab on the pathology of malignant atrophic papulosis. *Orphanet J Rare Dis* 2013 26; 8:185.

**Meephansan J, et al:** Possible involvement of SDF-1/CXCL12 in the pathogenesis of Degos disease. *J Am Acad Dermatol* 2013; 68(1):138-143.

**Passarini B, et al:** Lack of recurrence of malignant atrophic papulosis of Degos in multivisceral transplant: insights into possible pathogenesis? *J Am Acad Dermatol* 2011; 65(2):e49-e50.

**Scheinfeld N:** Pairing and comparing nine diseases with Degos disease (malignant atrophic papulosis): an attempt to illustrate our understanding and direct future inquiry. *Dermatol Online J* 2009; 15(1):10.

**Shapiro LS, et al:** Effective treatment of malignant atrophic papulosis (Köhlmeier-Degos disease) with treprostinil: early experience. *Orphanet J Rare Dis* 2013; 8:52.

**Theodoridis A, et al:** Malignant atrophic papulosis (Köhlmeier-Degos disease): a review. *Orphanet J Rare Dis* 2013; 8:10.

**Theodoridis A, et al:** Malignant and benign forms of atrophic papulosis (Köhlmeier-Degos disease): systemic involvement determines the prognosis. *Br J Dermatol* 2014; 170(1):110-115.

**Zhu KJ, et al:** The use of intravenous immunoglobulin in cutaneous and recurrent perforating intestinal Degos disease (malignant atrophic papulosis). *Br J Dermatol* 2007; 157:206.

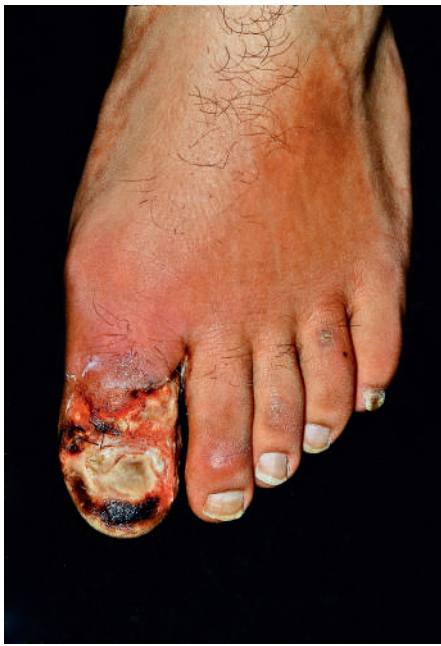## THROMBOANGIITIS OBLITERANS (BUERGER'S DISEASE)

Thromboangiitis obliterans (TAO) is a nonatherosclerotic segmental occlusive disease affecting the arteries of multiple extremities. It is most often seen in men between ages 20 and 40 who smoke heavily. Smoking and rarely the use of smokeless tobacco are intimately tied to Buerger's disease. The various diagnostic criteria proposed usually include age under 45 (or 50); history of tobacco use; distal extremity involvement (infrapopliteal segmental arterial occlusion with sparing of proximal vasculature); frequent distal upper extremity involvement (Raynaud or digital ulcers); consistent angiographic findings; superficial thrombophlebitis; exclusion of autoimmune disease, diabetes mellitus, and hypercoagulable or embolic states.

The vasomotor changes in early cases may be transient or persistent; they produce blanching, cyanosis, burning, and tingling. Superficial thrombophlebitis in the leg and foot occurs in 38% of patients, and 44% may have Raynaud phenomenon. The color of the affected area may change when it is raised or lowered below heart level—red when dependent and white when elevated. Pain is a constant symptom, coming at first only after exercise and subsiding with rest. Instep and foot claudication is the classic complaint. Ultimately, the dorsalis pedis and posterior tibial pulses disappear, followed by others. In TAO, skin supplied by affected arterioles tends to break down, with central necrosis and ulceration and eventual gangrene (Fig. 35-28). GI involvement has been reported. Exposure to cold may cause exacerbations, and more cases are identified in the winter than in any other season.

Arteriography should be done to investigate for central atherosclerotic disease, which may be operable, rather than the inoperable distal damage of Buerger's disease. A characteristic tapering and occlusion of the major arteries with "corkscrew" collateral arteries is found in Buerger's disease on angiography. A vasculo-occlusive syndrome similar to Buerger's disease has been reported in cannabis smokers, but venous thrombophlebitis does not occur. The pathogenic mechanism of the vascular occlusion in Buerger's disease is unknown. In one report, G20210A prothrombin mutations, the majority homozygotic, were found, but these findings have not been reproduced.

The most important therapeutic step is the complete cessation of smoking. Even one or two cigarettes/day, smokeless



**Fig. 35-28** Buerger's disease.

tobacco, or nicotine replacement may keep the disease active. IV iloprost (prostaglandin analog) may help the patient with critical limb ischemia get through an acute episode. Oral iloprost is ineffective. Phosphodiesterase type 5 inhibitors have been used successfully. Sympathectomy can provide temporary relief. Implantation of a spinal cord stimulator may be tried. Autologous transplantation of bone marrow mononuclear cells into the calf muscle has benefited patients with TAO and other forms of limb ischemia. G-CSF-mobilized peripheral blood mononuclear cells have had similar efficacy. Endovascular recanalization may be useful in preventing the need for amputation. In patients who stop smoking and do not have gangrene, major amputation is rare. In continued smokers, at least 43% will require amputation.

- Abeles AM, et al:** Thromboangiitis obliterans successfully treated with phosphodiesterase type 5 inhibitors. *Vascular* 2013; 22(4):313–316.
- Bozkurt AK, et al:** A stable prostacyclin analogue (iloprost) in the treatment of Buerger's disease: a prospective analysis of 150 patients. *Ann Thorac Cardiovasc Surg* 2013; 19(2):120–125.
- De Vriese AS, et al:** Autologous transplantation of bone marrow mononuclear cells for limb ischemia in a Caucasian population with atherosclerosis obliterans. *J Intern Med* 2008; 263:395.
- Espinoza LR:** Buerger's disease: thromboangiitis obliterans 100 years after the initial description. *Am J Med Sci* 2009; 337:285.
- Fazeli B, Ravari H:** A disease-specific activity score for thromboangiitis obliterans. *Vascular* 2014; 22(5):336–340.
- Graziani L, et al:** Clinical outcome after extended endovascular recanalization in Buerger's disease in 20 consecutive cases. *Ann Vasc Surg* 2012; 26(3):387–395.
- Hida N, Ohta T:** Current status of patients with Buerger disease in Japan. *Ann Vasc Dis* 2013; 6(3):617–623.
- Jouanjus E, et al:** Cannabis use: signal of increasing risk of serious cardiovascular disorders. *J Am Heart Assoc* 2014; 3(2):e000638.
- Kothari R, et al:** Thoracoscopic dorsal sympathectomy for upper limb Buerger's disease. *JLS* 2014; 18(2):273–276.
- Malecki R, et al:** Thromboangiitis obliterans in the 21st century—a new face of disease. *Atherosclerosis* 2009; 206:328.
- Manfredini R, et al:** Thromboangiitis obliterans (Buerger's disease) in a female mild smoker treated with spinal cord stimulation. *Am J Med Sci* 2004; 327:365.
- Spanos K, et al:** Effectiveness of intravenous ilomedin infusion and smoking cessation in the treatment of acutely symptomatic Buerger disease. *Angiology* 2013; Dec 22. [Epub ahead of print.]
- Vijayakumar A, et al:** Thromboangiitis obliterans (Buerger's disease): current practices. *Int J Inflamm* 2013; 2013:156905.

**Yuan L, et al:** Clinical results of percutaneous transluminal angioplasty for thromboangiitis obliterans in arteries above the knee. *Atherosclerosis* 2014; 235(1):110–115.

## ARTERIOSCLEROSIS OBLITERANS

Arteriosclerosis obliterans is an occlusive arterial disease most prominently affecting the abdominal aorta, as well as the small and medium-sized arteries of the lower extremities. The symptoms are caused by ischemia of the tissues. Intermittent claudication is manifested by pain, cramping, numbness, and fatigue in the muscles on exercise. These symptoms are relieved by rest. There may be “rest pain” at night when in bed. Also, sensitivity to cold, muscular weakness, stiffness of the joints, and paresthesia may be present. Sexual impotence is common, and there is increased frequency of coronary artery disease.

Reduced or absent pulses (dorsalis pedis, posterior tibial, or popliteal arteries) may be found on physical examination, confirming the diagnosis. The feet, especially the toes, may be red and cold. Striking pallor of the feet with elevation and redness with dependency are compatible findings. Decreased to absent hair growth may be observed on the legs. Ulceration and gangrene may supervene. If present, necrosis usually begins on the toes and is quite painful. Arteriography may be indicated as a preliminary to corrective surgery (arterial grafts). Occasionally, subclavian atherosclerosis may give rise to these signs in the distal upper extremity, producing painful nails and loss of digital skin. Diabetes mellitus, smoking, and hyperlipidemia are risk factors for the development of atherosclerosis.

Claudication and diminished blood pressure in the affected extremity are findings that may lead to earlier diagnosis and thus to curative surgical intervention. Usually, bypass of the affected artery or sympathectomy, or both, are the preferred treatment for arteriosclerosis obliterans. Balloon angioplasty or stent placement may also be effective. Oral beraprost, a prostaglandin I<sub>2</sub> analog, appears to improve symptoms of intermittent claudication in these patients. When critical limb ischemia is present, injection of stem cells into the calf muscle may be beneficial.

**Arai T:** Long-term effects of beraprost sodium on arteriosclerosis obliterans: a single-center retrospective study of Japanese patients. *Adv Ther* 2013; 30(5):528–540.

**Masaki H, et al:** Collective therapy and therapeutic strategy for critical limb ischemia. *Ann Vasc Dis* 2013; 6(1):27–32.

**Matsumoto K, et al:** Insulin resistance and arteriosclerosis obliterans in patients with NIDDM. *Diabetes Care* 1997; 20:1738.

## DIFFUSE DERMAL ANGIOMATOSIS

Diffuse dermal angiomas (DDA) is a disorder that preferentially affects women. The most common location is the breast, especially the dependent portion. Affected women tend to have large, pendulous breasts and are usually older than 45. Patients may have had a reduction mammoplasty (often decades earlier), and the disease tends to localize adjacent to the scar from that procedure. The clinical lesions may be reticulated groups of telangiectasias, ischemic (retiform) purpura, ulceration, or some combination. The erythematous/telangiectatic plaques are slightly palpable but not usually indurated. The nipple and areola are spared. The affected patients often have multiple risk factors for a hypercoagulable state or premature atherosclerosis, including a personal history of atherosclerotic cardiovascular disease, obesity, smoking, diabetes mellitus, hypertension, mutations in the thrombolytic



pathway (analogous to those seen in livedoid vasculopathy), and a strong family history for premature atherosclerotic disease-related cardiovascular events. The areas involved are similar to those affected by other prothrombotic disorders (e.g., warfarin necrosis, heparin necrosis)—skin with overly abundant adipose tissue. The breast is most often affected, but the abdomen and medial thighs are also sites of predilection. Usually, only one site is affected, but if the breast is involved, the process can be bilateral. Surgical procedures on the affected area may lead to ulceration that is painful and slow to heal. Because a surgical procedure triggered the ulceration, a mistaken diagnosis of pyoderma gangrenosum may be entertained.

Histologically, a diffuse dermal proliferation of endothelial cells and bland blood vessels occupies much of the dermis. Atypical cells and atypical vascular shapes (as seen in angiosarcoma and Kaposi sarcoma) are not seen. The dermal cells stain for markers of endothelial cells, CD31 and CD34. The pathogenesis is thought to be chronic local ischemia, which may lead to vascular proliferation (angiomatosis) or, if acute and severe, retiform purpura and ulceration. The fatty areas are poorly oxygenated (worse in obese patient), and the pendulous nature of the breasts may stretch or tether the vessels, further compromising the circulation. Inherited and acquired hypercoagulable risk factors (e.g., smoking, atherosclerosis) contribute to the pathogenesis.

The treatment of DDA involves reversing the contributing factors. This includes smoking cessation, weight reduction, and antithrombotic medications such as low-dose aspirin, 81 mg/day, and pentoxifylline, 400 mg twice daily. Reduction mammoplasty may lead to resolution. Atherosclerosis of the arteries serving the affected area may be found, and vascular surgery to enhance circulation may lead to improvement. More than one patient has been successfully treated with isotretinoin. Isotretinoin has fibrinolytic and antiangiogenic effects, which may explain its efficacy.

**Adams BJ, et al:** A cause of unbearably painful breast, diffuse dermal angiomatosis. *Gland Surg* 2012 Aug 1; 1(2).

**Kirkland CR, et al:** Atherosclerosis-induced diffuse dermal angiomatosis with fatal outcome. *Arch Dermatol* 2010; 146(6):684–685.

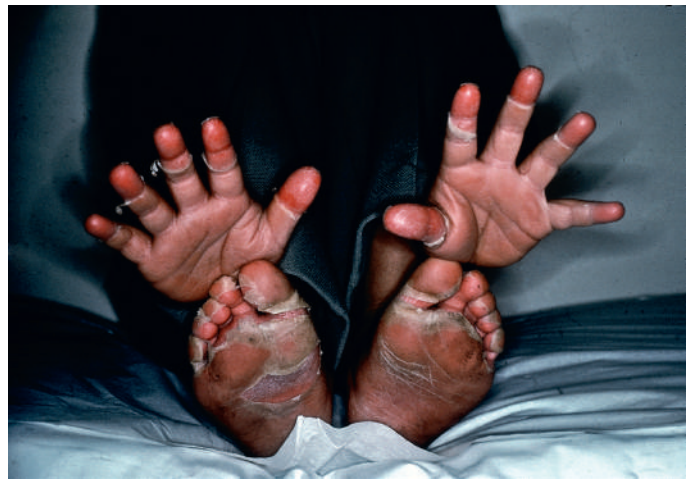**Morimoto K, et al:** Diffuse dermal angiomatosis. *Eur J Vasc Endovasc Surg* 2011; 42(3):381–383.

**Sanz-Motilva V, et al:** Diffuse dermal angiomatosis of the breast: clinical and histopathological features. *Int J Dermatol* 2014; 53(4):445–449.

**Steele KT, et al:** Diffuse dermal angiomatosis associated with calciphylaxis in a patient with end-stage renal disease. *J Cutan Pathol* 2013; 40(9):829–832.

## MUCOCUTANEOUS LYMPH NODE SYNDROME (KAWASAKI DISEASE)

The typical presentation is an irritable, ill-appearing, febrile infant or child younger than 5 years old. Clinical findings in mucocutaneous lymph node syndrome include a skin eruption; stomatitis (injected pharynx, strawberry tongue) and fissuring cheilitis; edema of the hands and feet; nonexudative conjunctival injection; and cervical lymphadenitis. The presence of four of these five cardinal features, plus fever for 5 days or longer, represent diagnostic criteria established by the American Heart Association. The skin eruption is polymorphous and may be macular, morbilliform, urticarial, scarlatiniform, erythema multiforme-like, pustular, or erythema marginatum-like. An early finding (within first week) is the appearance of an erythematous, desquamating perianal eruption in about two thirds of patients. Periorbital edema has been reported. From 15% to 20% of children with Kawasaki disease



**Fig. 35-29** Desquamation in Kawasaki disease.

(KD) and fever will not have one or more of the other cardinal features. These cases are termed “incomplete KD.” These patients are still at risk for cardiac disease.

Numerous cutaneous and systemic complications have been reported as accompanying or following KD. Pincer nail deformities may appear and resolve spontaneously. Intestinal pseudo-obstruction may occur. Facial nerve paralysis has been described, and a severe peripheral vasculitis with vasospasm, digital ischemia, and gangrene can occur. Numerous children have developed guttate or plaque psoriasis 10–20 days after KD onset. The presumed mechanism is the triggering of psoriasis by the superantigens associated with the acute illness.

The acute illness evolves over 10–20 days. One or 2 weeks after the acute illness, the fingers and toes desquamate, starting around the nails (Fig. 35-29). Coronary artery aneurysms occur in 20–25% of untreated children and 3–5% of treated children. This is the most common cause of acquired cardiac disease in young children. The cardiac involvement can also include decreased left ventricular function, arrhythmias, mitral regurgitation, and pericardial effusion. These complications can be immediate and are the major cause of morbidity and mortality. Over time, those with aneurysms can develop coronary artery stenosis, and as a result, acute cardiac events can occur in young adulthood.

## Pathogenesis

A viral or infectious pathogenesis for KD is appealing for the following reasons:

1. Cases were rare before 1950.
2. KD affects children older than 3 months but younger than 8 years.
3. Seasonal peaks occur in the winter and spring.
4. Focal epidemics have been reported.
5. Oligoclonal IgA immune responses are found, suggesting a respiratory portal of entry of an infectious agent.

There are increased superantigens in the stool of children with KD, and a KD-like illness has been described with group A meningococcal septicemia. An infectious pathogenesis, therefore, remains the most plausible etiologic hypothesis; it is less clear whether this is caused by a single unknown agent or whether it represents an immunologic response to a variety of infectious triggers.

It has long been suspected that there is a genetic basis for KD. The disease is 10–20 times more common in persons from Northeast Asia (Japan and Korea), where rates of up to 1 per

150 children are reported. When these Asians move to the United States, they still have this high rate of increased susceptibility. The risk of a sibling developing KD is increased tenfold. Children of parents who had KD in childhood have a twofold increased risk of developing KD. A genome-wide search of almost 1000 KD cases and family members found strong linkage to five genes, three of which form a single functional network. The central gene of this network is *CAMK2D*, which encodes a serine/threonine kinase expressed in cardiomyocytes and vascular endothelial cells. These genes are known to be involved in cardiac and inflammatory pathways. Their transcripts are also greatly suppressed during KD. Other genetic polymorphisms are associated with increased KD susceptibility, including the genes encoding inositol 1,4,5-trisphosphate 3-kinase C (*ITPKC*) and the immunoglobulin G receptor gene (*FCGR2A*).

Kawasaki disease is a systemic vasculitis of medium-sized arteries, of which the coronary arteries are most profoundly and characteristically affected. Coronary artery disease occurs after day 10 of the illness (subacute phase), in combination with thrombocytopenia (up to 1 million cells). This combination of an altered endovascular surface and too many platelets, plus abnormal blood flow in the coronary aneurysms, leads to thrombosis and occlusion of the vessels and subsequent cardiac events.

## Treatment

The cornerstone of therapy for KD patients is IVIG, given in a single dose of 2 g/kg infused over 10–12 h. Response to treatment is best if given during the first 5–6 days of the illness; however, children with persistent fever beyond this period may benefit from later treatment. Aspirin is used to reduce inflammation and platelet aggregation. The dose is 80–100 mg/kg/day in four divided doses. Once the child has been afebrile for 3–7 days, the aspirin dose is decreased to a single daily dose of 3–5 mg/kg. If the child remains febrile 36 hours after initial treatment (which may occur in 10–20% of patients), a second 2-g/kg dose of IVIG should be given. Such patients are at significantly higher risk of coronary artery aneurysms. A single dose of infliximab, 5 mg/kg, has been reported to be effective in refractory cases, but response, as with other treatments, is not universal. If there is no response to the second IVIG dose, systemic corticosteroid therapy is usually given. Angioplasty, thrombolytic therapy, or coronary artery bypass surgery may be required for patients with coronary disease. Overall, the rate of long-term adverse cardiovascular events appears to be low, although adult patients with a history of KD may be at increased risk of early atherosclerotic disease.

- Bayers S, et al:** Kawasaki disease. Part I. Diagnosis, clinical features, and pathogenesis. *J Am Acad Dermatol* 2013; 69(4):501.e1–e11
- Bayers S, et al:** Kawasaki disease. Part II. Complications and treatment. *J Am Acad Dermatol* 2013; 69(4):513.e1–e8
- Burgner D, et al:** A genome-wide association study identifies novel and functionally related susceptibility loci for Kawasaki disease. *PLoS Genet* 2009; 5:e1000319.
- Burns JC, Newburger JW:** Genetics insights into the pathogenesis of Kawasaki disease. *Circ Cardiovasc Genet* 2012; 5(3):277–278.
- Falcini F, et al:** Discrimination between incomplete and atypical Kawasaki syndrome versus other febrile diseases in childhood: results from an international registry-based study. *Clin Exp Rheumatol* 2012; 30:799–804.
- Galeotti C, et al:** Kawasaki disease: aetiopathogenesis and therapeutic utility of intravenous immunoglobulin. *Autoimmun Rev* 2010; 9(6):441–448.
- Holve TJ, et al:** Long-term cardiovascular outcomes in survivors of Kawasaki disease. *Pediatrics* 2014; 133(2):e305–e311.

- Kobayashi T, et al:** Efficacy of intravenous immunoglobulin combined with prednisolone following resistance to initial intravenous immunoglobulin treatment of acute Kawasaki disease. *J Pediatr* 2013; 163(2):521–526.e1.
- Manhiot C, et al:** Complete and incomplete Kawasaki disease: two sides of the same coin. *Eur J Pediatr* 2012; 171(4):657–662.
- Onouchi Y, et al:** ITPKC functional polymorphism associated with Kawasaki disease susceptibility and formation of coronary artery aneurysms. *Nat Genet* 2008; 40(1):35–42.
- Salguero JS, et al:** Refractory Kawasaki disease with coronary aneurysms treated with infliximab. *An Pediatr (Barc)* 2010; 73(5):268–271.
- Succimari R:** Kawasaki disease. *Pediatr Clin North Am* 2012; 59(2):425–445.
- Son MB, et al:** Treatment of Kawasaki disease: analysis of 27 US pediatric hospitals from 2001 to 2006. *Pediatrics* 2009; 124(1):1–8.
- Tobayama H, et al:** Analysis of arterial function in adults with a history of Kawasaki disease. *J Cardiol* 2013; 61(5):330–335.
- Uehara R, Belay ED:** Epidemiology of Kawasaki disease in Asia, Europe, and the United States. *J Epidemiol* 2012; 22(2):79–85.
- Ulloa-Gutierrez R, et al:** Pustular rash in Kawasaki syndrome. *Pediatr Infect Dis J* 2007; 26(12):1163–1165.

## TELANGIECTASIA

Telangiectasias are fine, linear vessels coursing on the surface of the skin. They may occur in normal skin at any age, in both genders, and anywhere on the skin and mucous membranes. Fine telangiectasias may be seen on the alae nasi of most adults. They are prominent in areas of chronic actinic damage. In addition, persons long exposed to wind, cold, or heat are subject to telangiectasias. Calcium channel blockers may lead to generalized or photodistributed telangiectatic lesions and contribute to the appearance of photoaging. Telangiectasias may also be found on the legs as a result of heredity, varicosities, pregnancy, and OC use.

Telangiectasias can be found in conditions such as radio-dermatitis, xeroderma pigmentosum, lupus erythematosus, scleroderma and the CREST syndrome, rosacea, pregnancy, cirrhosis of the liver, AIDS, poikiloderma, basal cell carcinoma, necrobiosis lipoidica diabetorum, lichen sclerosus et atrophicus, sarcoid, lupus vulgaris, keloid, adenoma sebaceum, kaposiform hemangioendothelioma, angioma serpiginosum, angiokeratoma corporis diffusum, hereditary benign telangiectasia, Cockayne syndrome, ataxia-telangiectasia, and Bloom syndrome.

Altered capillary patterns on the finger nailfolds (cuticular telangiectasias) are indicative of collagen vascular disease, such as LE, scleroderma, or dermatomyositis. These may infrequently be present in RA. These disorders are reviewed in Chapter 8.

- Bakkour W, et al:** Photodistributed telangiectasia induced by calcium channel blockers: case report and review of the literature. *Photodermatol Photoimmunol Photomed* 2013; 29(5):272–275.
- Beaubien ER, et al:** Kaposiform hemangioendothelioma. *J Am Acad Dermatol* 1998; 38:799.
- Cooper SM, Wojnaraowska F:** Photo-damage in Northern European renal transplant recipients is associated with the use of calcium channel blockers. *Clin Exp Dermatol* 2003; 28:588.
- Huh J, et al:** Localized facial telangiectasias following frostbite injury. *Cutis* 1996; 57:97.
- Kanekura T, et al:** Lichen sclerosus et atrophicus with prominent telangiectasia. *J Dermatol* 1994; 21:447.

## Generalized essential telangiectasia

Generalized essential telangiectasia (GET) is characterized by the appearance of telangiectasias over a large segment of the body without preceding or coexisting skin lesions. Lesions



tend to appear first on the legs and progress caudad (Fig. 35-30). Women are more often affected, with the condition starting between age 20 and 50. Characteristic features include the following:

1. Widespread cutaneous distribution
2. Progression or permanence of the lesions
3. Accentuation in dependent areas and by dependent positioning
4. Absence of coexisting epidermal or dermal changes, such as atrophy, purpura, depigmentation, or follicular involvement

The telangiectasias may be distributed over the entire body or localized to some large area, such as the legs, arms, and trunk. They may be discrete or confluent. Distribution along the course of the cutaneous nerves may occur. Systemic symptoms are absent, although conjunctival telangiectasias can also be seen. GET is generally not believed to be associated with an increased risk of epistaxis, but GI bleeding has been reported. Families with this disorder, inherited as an autosomal dominant trait, have been reported. The cause of essential telangiectasia is unknown. Treatment is with vascular lasers, if required.

Cutaneous collagenous vasculopathy, a condition favoring middle-age men, is clinically similar to GET but histologically distinct. Histologically, both disorders exhibit greatly dilated subepidermal vessels. However, in cutaneous collagenous vasculopathy, these blood vessels have thickened vascular walls and perivascular hyaline, whereas in GET, they do not.

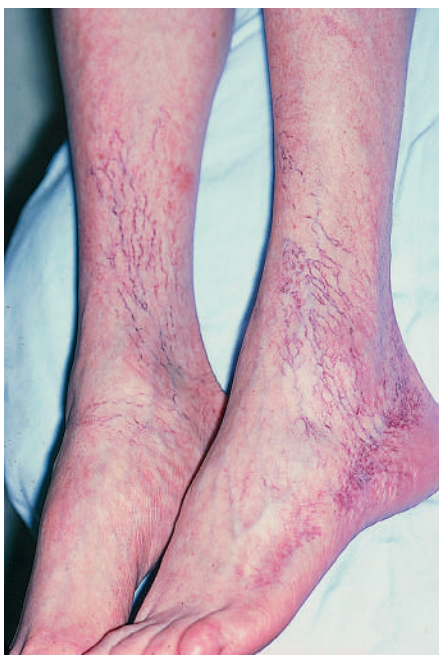**Burdick LM, et al:** Cutaneous collagenous vasculopathy: a rare cutaneous microangiopathy. *J Cutan Pathol* 2012; 39(8):741–746.

**Gambichler T, et al:** Generalized essential telangiectasia successfully treated with high-energy, long-pulse, frequency-doubled Nd:YAG laser. *Dermatol Surg* 2001; 27:355.

**Gordon Spratt EA, et al:** Generalized essential telangiectasia. *Dermatol Online J* 2012; 18(12):13.

**Perez A, et al:** Cutaneous collagenous vasculopathy with generalized telangiectasia in two female patients. *J Am Acad Dermatol* 2010; 63:882–885.

**Thieu KP, Haynes HA:** Generalized essential telangiectasia with predilection for surgical scar. *J Am Acad Dermatol* 2009; 60(4):710–711.



**Fig. 35-30** Generalized essential telangiectasia.

## Unilateral nevoid telangiectasia

In unilateral nevoid telangiectasia (UNT), fine, threadlike telangiectases develop in a unilateral, sometimes dermatomal distribution (or following lines of Blaschko). Spider angiomas may also be present. The most common distribution is unilateral or bilateral involvement of the third and fourth cervical dermatomes. The condition is rare in men; in affected women, it starts in adulthood. The familial form (very rare) favors males, is autosomal dominant, and appears postnatally. UNT is associated with conditions that have increased levels of estrogen or vascular endothelial growth factor (VEGF): puberty, pregnancy, OC use, HCV infection, and cirrhosis, as well as with neurologic disorders such as hypoesthesia of the affected area. Treatment with pulse dye laser can be effective.

**Akman-Karakaş A, et al:** Unilateral nevoid telangiectasia accompanied by neurological disorders. *J Eur Acad Dermatol Venereol* 2011; 25(11):1356–1359.

**Kawakami T, et al:** Unilateral nevoid telangiectasia on the lower extremity of a pediatric patient. *J Am Acad Dermatol* 2010; 62(3):528–530.

**Oliveira A, et al:** Unilateral nevoid telangiectasia: report of two cases. *Int J Dermatol* 2014; 53(1):e32–e33.

**Sharma VK, Khandpur S:** Unilateral nevoid telangiectasia—response to pulsed dye laser. *Int J Dermatol* 2006; 45:960.

**Smith J, et al:** Unilateral nevoid telangiectasia syndrome (UNTS) associated with chronic hepatitis C virus and positive immunoreactivity for VEGF. *Dermatol Online J* 2014; 20(6).

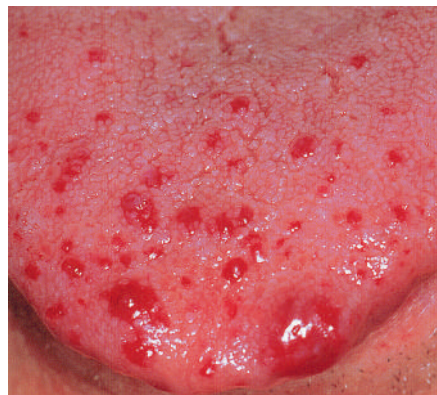**Tanglertsampan C, et al:** Unilateral nevoid telangiectasia: case report and proposal for new classification system. *Int J Dermatol* 2013; 52(5):608–610.

**Wenson SF, et al:** Unilateral nevoid telangiectasia syndrome: a case report and review of the literature. *Dermatol Online J* 2011; 17(5):2.

## HEREDITARY HEMORRHAGIC TELANGIECTASIA (OSLER'S DISEASE)

Also known as Osler-Weber-Rendu disease, hereditary hemorrhagic telangiectasia (HHT) is characterized by small tufts of dilated capillaries scattered over the mucous membranes and the skin. These slightly elevated lesions develop mostly on the lips, tongue, palate, nasal mucosa, ears, palms, fingertips, nailbeds, and soles. They may closely simulate the mat telangiectases of the CREST variant of scleroderma, without the other features of CREST syndrome. Diagnostic criteria have been proposed and include the following:

1. Epistaxis—spontaneous, recurrent nosebleeds
2. Telangiectases—multiple at characteristic sites (lips, oral cavity, fingers, nose) (Fig. 35-31)



**Fig. 35-31** Hereditary hemorrhagic telangiectasia.

3. Visceral lesions—GI bleeding; pulmonary, hepatic, cerebral, or spinal arteriovenous malformation (AVM)
4. Family history—one affected first-degree relative

The presence of three of the four criteria indicates a definite diagnosis, and two of four indicates a possible diagnosis. There are at least three variants: HHT1 and HHT2, and a third associated with juvenile polyposis.

Frequent nosebleeds and melena are experienced because of the telangiectasias in the nose and GI tract. Epistaxis is the most frequent and persistent sign. Worsening epistaxis may herald high-output cardiac failure from AVMs. Pregnancy can also exacerbate HHT. GI bleeding is the presenting sign in up to 25% of patients; however, 40–50% develop GI bleeding sometime during the course of their disease. Chronic persistent anemia requiring iron and blood transfusions is characteristic of severe cases. The spleen may be enlarged. Pulmonary and CNS AVMs may appear later in life. Liver failure can result from diffuse intrahepatic shunting—hepatic artery to vein, bypassing the liver parenchyma. Retinal arteriovenous aneurysms occur only rarely. Other sites of bleeding may be the kidney, spleen, bladder, liver, meninges, and brain. The risk of cerebral hemorrhage from cerebral AVMs, cerebral abscesses, and pulmonary hemorrhage from pulmonary AVMs is probably high enough that asymptomatic patients should be screened for the presence of cerebral and pulmonary AVMs. Because of the risk of cerebral abscess, some have advocated antibiotic prophylaxis for dental and contaminated skin procedures.

The telangiectasias tend to increase in number in middle age; however, the first appearance on the undersurface of the tongue and floor of the mouth is at puberty. Pulmonary or intracranial arteriovenous fistulas and bleeding in these areas may be a cause of death.

Osler's disease (HHT) is inherited as an autosomal dominant trait. The vascular abnormalities found in HHT consist of direct arteriovenous connections without an intervening capillary bed. Affected patients have mutations that affect transforming growth factor (TGF)- $\beta$  signaling. Multiple gene mutations are known; mutations in endoglin (*ENG*) and ALK-1 (*ACVRL1*) together make up 85% of cases. These encode a homodimeric integral membrane glycoprotein, which is a TGF- $\beta$  receptor. HHT1 is associated with *ENG* mutations, and HHT2 with *ACVRL1* mutations. HHT1 patients have a higher prevalence of pulmonary AVMs, while HHT2 patients tend to have a milder phenotype and later age of onset, but increased liver manifestations. Patients with HHT and juvenile polyposis have mutations in the *MADH4* gene, a downstream effector of TGF- $\beta$  signaling. TGF- $\beta$  is a potent stimulator of VEGF production. VEGF leads to disorganized and tortuous vessels, as seen in HHT. VEGF levels are increased in patients with HHT.

Treatment is directed at controlling the specific complications and identifying and treating AVMs before they become symptomatic. The tendency to epistaxis has been reduced by estrogen therapy, and some recommend estrogen preparations or tamoxifen. Dermoplasty of the bleeding nasal septum may be performed by replacing the mucous membrane with skin from the thigh or buttock. Repeated laser treatments of the nasal and GI mucosa are often required. Topical tranexamic acid has been used to control epistaxis. Bleeding episodes are treated supportively with iron and RBC transfusions. Interventional radiology with selective embolization can treat pulmonary and CNS AVMs, avoiding invasive surgeries. In patients with liver failure or high-output heart failure due to liver AVMs, liver transplantation may be required. Blocking VEGF with thalidomide (or more effectively with lenalidomide) can reduce GI bleeding and transfusion dependence.

Bevacizumab, a monoclonal inhibitor of VEGF delivered intravenously, has dramatically improved some severely ill HHT patients, reducing the size and flow of their hepatic AVMs, reversing heart and liver failure, and reducing transfusion requirements. It has also been used successfully as a submucosal injection and topical spray for epistaxis.

- Al-Saleh S, et al:** Utility of contrast echocardiography for pulmonary arteriovenous malformation screening in pediatric hereditary hemorrhagic telangiectasia. *J Pediatr* 2012; 160(6):1039–1043.e1.
- Bose P, et al:** Bevacizumab in hereditary hemorrhagic telangiectasia. *N Engl J Med* 2009; 360:2143.
- Bowcock SJ, Patrick HE:** Lenalidomide to control gastrointestinal bleeding in hereditary haemorrhagic telangiectasia: potential implications for angiodysplasias? *Br J Haematol* 2009; 146:220.
- Dupuis-Girod S, et al:** Bevacizumab in patients with hereditary hemorrhagic telangiectasia and severe hepatic vascular malformations and high cardiac output. *JAMA* 2012; 307:948.
- Faughnan ME, et al:** International guidelines for the diagnosis and management of hereditary haemorrhagic telangiectasia. *J Med Genet* 2011; 48:73.
- Fernandez-Fernandez FJ:** Hereditary haemorrhagic telangiectasia: from symptomatic management to pathogenesis based treatment. *Eur J Hum Genet* 2010; 18(4):404.
- Franchini M, et al:** Novel treatments for epistaxis in hereditary hemorrhagic telangiectasia: a systematic review of the clinical experience with thalidomide. *J Thromb Thrombolysis* 2013; 36(3):355–357.
- Fuchizaki U, et al:** Hereditary haemorrhagic telangiectasia (Rendu-Osler-Weber disease). *Lancet* 2003; 362:1490.
- Gallione CJ, et al:** A combined syndrome of juvenile polyposis and hereditary haemorrhagic telangiectasia associated with mutations in *MADH4* (*SMAD4*). *Lancet* 2004; 363:852.
- Giordano P, et al:** Hereditary hemorrhagic telangiectasia: arteriovenous malformations in children. *J Pediatr* 2013; 163(1):179–186.e1–e3.
- Govani FS, Shovlin CL:** Hereditary haemorrhagic telangiectasia: a clinical and scientific review. *Eur J Hum Genet* 2009; 17:860.
- Grève E, et al:** High diagnostic and clinical impact of small-bowel capsule endoscopy in patients with hereditary hemorrhagic telangiectasia with overt digestive bleeding and/or severe anemia. *Gastrointest Endosc* 2010; 71(4):760–767.
- Haneen S, et al:** Mutation analysis of “Endoglin” and “Activin receptor-like kinase” genes in German patients with hereditary hemorrhagic telangiectasia and the value of rapid genotyping using an allele-specific PCR-technique. *BMC Med Genet* 2009; 10:53.
- Karnezis TT, Davidson TM:** Efficacy of intranasal bevacizumab (Avastin) treatment in patients with hereditary hemorrhagic telangiectasia-associated epistaxis. *Laryngoscope* 2011; 121:636.
- Khalid SK, et al:** Worsening of nose bleeding heralds high cardiac output state in hereditary hemorrhagic telangiectasia. *Am J Med* 2009; 122:779.e1.
- Lacombe P, et al:** Diffuse pulmonary arteriovenous malformations in hereditary hemorrhagic telangiectasia: long-term results of embolization according to the extent of lung involvement. *Chest* 2009; 135(4):1031–1037.
- McDonald J, et al:** Hereditary hemorrhagic telangiectasia: an overview of diagnosis, management, and pathogenesis. *Genet Med* 2011; 13(7):607–616.
- Mei-Zahav M, et al:** Symptomatic children with hereditary hemorrhagic telangiectasia: a pediatric center experience. *Arch Pediatr Adolesc Med* 2006; 160:596.
- Mitchell A, et al:** Bevacizumab reverses need for liver transplantation in hereditary hemorrhagic telangiectasia. *Liver Transpl* 2008; 14:210.
- Shovlin CL, et al:** Ischaemic strokes in patients with pulmonary arteriovenous malformations and hereditary hemorrhagic telangiectasia: associations with iron deficiency and platelets. *PLoS One* 2014; 9(2):e88812.
- Van Gent MW, et al:** Real prevalence of pulmonary right-to-left shunt according to genotype in patients with hereditary hemorrhagic telangiectasia: a transthoracic contrast echocardiography study. *Chest* 2010; 138:833.
- Yaniv E, et al:** Anti-estrogen therapy for hereditary hemorrhagic telangiectasia: a long-term clinical trial. *Rhinology* 2011; 49:214.



## LEG ULCERS

Leg ulcers are a common medical condition, affecting 3–5% of the population over age 65. The cause of chronic leg ulceration is venous insufficiency alone in 45–60% of cases, arterial insufficiency in 10–20%, diabetes mellitus in 15–25%, or combinations thereof in 10–15%. Smoking and obesity increase the risk for ulcer development and persistence, independent of the underlying cause. Defining the cause of the leg ulceration is important for treatment.

The wound-healing response is complex, involving intricate interactions between different cell types, structural proteins, growth factors, and proteinases. Normal wound repair consists of three phases—*inflammation, proliferation, and remodeling*—which occur in a predictable sequence.

## VENOUS DISEASES OF THE EXTREMITIES

### Stasis dermatitis

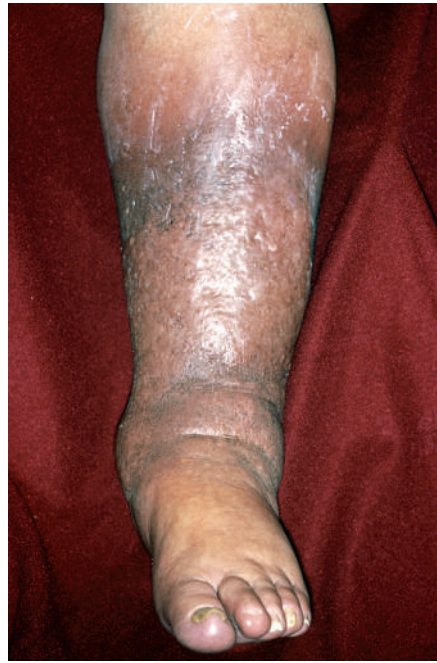Stasis dermatitis presents as erythema and a yellowish or light-brown pigmentation of the lower third of the lower legs, especially in the area just superior to the medial malleolus. An associated eczematous dermatitis may occur. The dermatitis may be weepy or dry, scaling or lichenified; it is almost invariably hyperpigmented by melanin and hemosiderin. Varicose veins are usually present, although they need not be numerous or conspicuous. Stasis dermatitis is a cutaneous marker for venous insufficiency. The approach to management should be twofold: relief of symptoms and treatment of the underlying venous insufficiency. Patients with pruritus and an eczematous component should be treated with emollients and topical corticosteroids. The daily use of elevation and support stockings is strongly recommended.

### Venous insufficiency and obesity-associated mucinosis

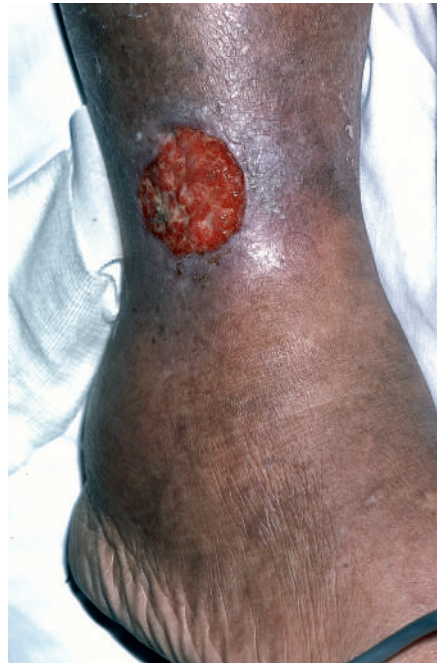Localized areas of mucin deposition can be observed directly over the perforators on the lower extremity. These present as blushed, red-blue, partially compressible, agminated papules. On biopsy, deposits of dermal mucin against a background of the changes of venous insufficiency are seen. In the setting of morbid obesity and lower extremity edema, pretibial translucent papules can appear and merge into plaques. The plaques are composed of dermal mucin (hyaluronic acid). The diagnosis of “pretibial myxedema” is usually made, but thyroid functions are normal. With weight loss, the lesions improve, suggesting that they were caused by the lower extremity edema and venous insufficiency of obesity.

### Venous insufficiency ulceration

Stasis dermatitis and venous ulceration result from increased pressure in the venous system of the lower leg. The most common cause is insufficiency of the valves in the deep venous system and lower perforating veins of the lower leg. With each contraction of the calf, blood should be pumped to the heart via this “muscle pump.” Intact valves in the lower leg are required to prevent this “pumped” blood from refluxing out through the perforators into the superficial system. Increased flow through the superficial system results in enlargement of the superficial venous plexus and the appearance of “varicose veins.” Increased pressure on the iliac veins from pregnancy



**Fig. 35-32** Stasis dermatitis, venous insufficiency.



**Fig. 35-33** Venous leg ulcer.

or obesity, or simple inactivity may also result in the appearance of “venous insufficiency.” The valvular insufficiency results in disorder in the venous and capillary circulation of the leg. Valve insufficiency may occur from prior thrombophlebitis or congenital “weakness.” Prolonged standing without walking or contracting the calf muscles, sitting for long periods, anemia, zinc deficiency, and a defective fibrinolytic system may accelerate the process. If a history of thrombophlebitis is present, an evaluation for a hypercoagulable state, such as a deficiency of factor V Leiden, should be considered.

Edema and fibrosis develop in the skin over the medial aspect of the ankle and lower third of the shin (Fig. 35-32). Following minor trauma, a macular hemorrhage appears. This is the premonitory sign of an impending ulceration. Venous ulcers usually occur on the lower medial aspect of the leg. They may appear on the background of stasis dermatitis with lipodermatosclerosis (Fig. 35-33). Venous ulcerations can be

painful, but not as painful as pyoderma gangrenosum or arterial or embolic ulcerations. The ulcer tends to be round or oblong and has a characteristic yellow, fibrinous base. Multiple lesions may occur.

In most cases, the diagnosis of a venous ulceration can be made on clinical grounds. If there is no clear history or physical findings of venous insufficiency, venous rheography can be performed. An ABI (ankle:brachial index, or ratio of blood pressure in the leg to the arm) should be performed, especially in cases where peripheral pulses are diminished and hair on the lower legs is lost. This will identify coexistent arterial disease. More extensive vascular studies may be necessary to identify the presence and extent of arterial disease or focal venous valvular incompetence or congenital absence. In leg ulcers of the lower medial leg, even if cutaneous findings of venous insufficiency are absent, venous insufficiency will still be the most common cause of the ulcer. Lesions in atypical locations, those that do not respond appropriately to therapy, and those in which venous rheography is normal may require a biopsy to exclude other causes, including a cutaneous neoplasm. Additional workup may also be required to identify other, less common causes of leg ulcers, such as cholesterol emboli, atherosclerotic disease, diabetes mellitus, sickle cell disease, vasculitis, infection, and pyoderma gangrenosum.

Despite extensive research and the marketing of many new products and devices for the treatment of leg ulcers, little has changed in their management over the last decades. Treatment is primarily to improve venous return and reduce edema. Compression therapy is the mainstay of treatment. This involves, preferably, the use of inelastic/short-stretch bandages or multilayer compression dressings such as Unna boots, versus elastic/long-stretch bandages such as Coban or ACE wraps, which are significantly less effective at reducing venous hypertension and edema. Elevation of the leg above the heart, for as much of the time as possible (at least 2 h twice daily), is also beneficial. Elastic support of the legs must be continued after the ulcer heals. Other causes of edema, such as cardiac failure, must be addressed. The avoidance of long, cramped sitting (in airplanes or vehicles) or prolonged standing is advisable. Diuretics are overused and not proven to be of benefit. If there is a central cause of fluid retention (cirrhosis, heart failure, renal failure), diuretics may be beneficial, but otherwise they should be avoided. Avoidance of trauma is important. Pentoxifylline, 400–800 mg three times daily, in addition to compression, is beneficial in healing refractory venous ulcerations. A cooperative patient and a patient physician are necessary in the long-term management of venous disease. Topical anti-infectives are usually not necessary (except metronidazole gel to prevent anaerobic overgrowth). There is a high risk of allergic contact dermatitis from other topical antibiotics. Oral antibiotics should only be used to treat associated invasive infection. A rim of erythema usually surrounds an ulcer. Expanding erythema, an enlarging ulcer, or increasing pain or tenderness may be signs of infection. Surface cultures and Gram stains may demonstrate colonizing, but not pathogenic, bacteria. Biopsy for histology and tissue homogenate culture is the most effective way to demonstrate a true invasive pathogen.

Many treatment options have been developed for chronic ulcers. Unfortunately, conclusive comparative studies between the various treatment alternatives are lacking. All are to be used in combination with compression treatment, which by itself leads to healing in 73% of cases without other interventions. Occlusive and semipermeable biosynthetic wound dressings can be very effective when combined with compression. They can speed healing, reduce pain, make dressing changes infrequent, and help debridement. If a hard eschar is present over the ulcer when first seen, a dressing will assist

in its removal. Early in the treatment of an ulcer, a highly inflammatory and exudative phase occurs. This will often wash off the semipermeable dressing and may require the use of fenestrated dressings and even the application of absorbent padding over the dressing for the first few weeks. The patient will interpret this increased wound exudate, which is normal and indicates the conversion of a nonhealing to a healing wound, as an infection, and should be appropriately educated before such dressings are applied. Dressings containing dilute acetic acid or silver may help reduce bacterial overgrowth in the wound but fail to decrease the time to healing. However, metronidazole gel 0.75% instilled into the wound will help to reduce the amount of wound exudate and remove unpleasant odor by eliminating anaerobic bacteria. The smell of a chronic leg ulcer may reduce the patient's quality of life. Topical growth factors applied to the wound bed, such as platelet derived growth factor and epidermal growth factor, can promote wound healing but are limited by high cost. Granulation tissue formation is enhanced, so they may be useful in wounds that are unable to develop a granulation tissue base despite local care and conservative debridement. Weekly debridement of the anesthetic, dead fibrinous tissue can be useful in stimulating granulation tissue at the base of slow-to-heal venous ulcerations. Injection of granulocyte-macrophage colony-stimulating factor (GM-CSF) into the ulcer base may also stimulate refractory ulcers to heal, but is very expensive. Grafts and skin substitutes can be considered for refractory ulcers that have failed conservative therapy. Bilayer artificial skin grafts, in conjunction with compression, increases venous ulcer healing compared with compression plus dressing alone.

In more than 90% of patients, only simple but persistently applied measures are required. Enhanced compliance, longer elevation, and removal of leg edema are the first steps in attempting to heal refractory leg ulcers. If these are not optimized, expensive dressing and medications will not lead to healing. The role of vascular surgery or venous ablation in the healing of leg ulcers is controversial. Vascular surgery does not impact wound healing significantly compared with compression alone, but it appears to diminish rates of recurrence.

Risk factors that predict failure to heal within 24 weeks of limb compression therapy include a large wound area, history of venous ligation or stripping, history of hip or knee replacement, ABI less than 0.80, fibrin on 50% or more of the wound surface, and presence of the ulcer for an extended time. For every 6 months of duration, the ulcer healing time doubles.

## ARTERIAL INSUFFICIENCY (ISCHEMIC) ULCER

Ischemic ulcers are mostly located on the lateral surface of the ankle or the distal digits. The initial red, painful plaque breaks down into a painful superficial ulcer with a surrounding zone of purpuric erythema. Granulation tissue is minimal, little or no infection is present, and a membranous inactive eschar forms over the ulcer. Patients at risk are those with long-standing hypertension, smokers, diabetic patients, and those with hyperlipidemia. The presence of an arterial ulceration identifies patients at increased risk for limb loss.

Signs and symptoms indicating that arterial disease is the cause of the ulceration include thinning of the skin, absence of hair, decreased or absent pulses, pallor on elevation, coolness of the extremity, dependent rubor, claudication on exercise, and pain on elevation (especially at night) relieved with dependency. In progressive disease, the diagnosis of thromboangiitis obliterans, or Buerger's disease, should be considered. Patients with arterial insufficiency are also at risk



for cholesterol emboli, another arterial cause of lower leg ulceration. Eosinophilia, palpable peripheral pulses, sudden onset, and associated renal insufficiency are clues to the diagnosis of cholesterol emboli.

The diagnosis of arterial insufficiency can usually be confirmed by physical examination and careful palpation of the leg pulses. For more accurate evaluation, the blood pressure in the arm and leg is taken, which should be almost identical. The ratio of the popliteal to brachial pressure is called the ABI; if less than 0.75, arterial insufficiency exists, and if less than 0.5, the insufficiency is substantial.

Surgical intervention may be required to heal the ulceration. If the blood supply cannot be improved, little can be done, except to prevent infection by the measures described for venous ulcers. The area should be protected from injury and cold, and smoking and tight socks should be avoided. Hyperbaric oxygen may be of some use but is limited by availability and cost. A recent Cochrane review highlighted the dearth of high-quality studies but suggested hyperbaric oxygen improves ulcer healing in the short term but not the long term.

## NEUROPATHIC ULCERS

Foot ulcers in diabetic patients are usually related to sensory neuropathy. Offloading the ulcer is the primary principle of management. Necrotic tissue should be debrided back to bleeding, viable tissue. Because the foot is typically insensate, this can be done in the office without the need for anesthetic. Associated osteomyelitis is best treated by removal of the infected bone. Consultation with or referral to a podiatrist or orthopedic surgeon may be indicated. Various shoes and padded boots can be used to offload different areas of the foot. An orthotics consultation is usually indicated. Clinical infection should be treated, but simple colonization typically does not require treatment. After the ulcer heals, a shoe of appropriate depth and width will help to prevent recurrence. Frequent foot inspections for the presence of "hot spots," as well as debridement of dystrophic nails, are important facets of prevention of leg ulcers in diabetic patients.

**Alavi A, et al:** Diabetic foot ulcers. Part II. Management. *J Am Acad Dermatol* 2014; 70(1):21.e1–e24; quiz 45–46.

**Chiesa R, et al:** Chronic venous disorders: correlation between visible signs, symptoms, and presence of functional disease. *J Vasc Surg* 2007; 46:322.

**Cianfarani F, et al:** Granulocyte/macrophage colony-stimulating factor treatment of human chronic ulcers promotes angiogenesis associated with de novo vascular endothelial growth factor transcription in the ulcer bed. *Br J Dermatol* 2006; 154(1):34–41.

**Darvall KA, et al:** Higher prevalence of thrombophilia in patients with varicose veins and venous ulcers than controls. *J Vasc Surg* 2009; 49:1235.

**Eliassen A, et al:** Marjolin's ulcer in a patient with chronic venous stasis. *Ann Vasc Surg* 2013; 27(8):1182.e5–e8.

**Gohel MS, et al:** Long-term results of compression therapy alone versus compression plus surgery in chronic venous ulceration (ESCHAR): randomised controlled trial. *BMJ* 2007; 335:7610.

**Jones JE, et al:** Skin grafting for venous leg ulcers. *Cochrane Database Syst Rev* 2013; 1:CD001737.

**Kranke P, et al:** Hyperbaric oxygen therapy for chronic wounds. *Cochrane Database Syst Rev* 2012; 4:CD004123.

**Margolis DJ, et al:** Risk factors associated with failure of a venous leg ulcer to heal. *Arch Dermatol* 1999; 135:920.

**McAree BJ, Berridge DC:** Investigation of the patient with a venous ulcer. *Phlebology* 2010; 25(Suppl 1):20–27.

**Meissner MH:** Venous ulcer care: which dressings are cost effective? *Phlebology* 2014; 29(1 Suppl):174–180.

**Michaels JA, et al:** Randomized controlled trial and cost-effectiveness analysis of silver-donating antimicrobial dressings for venous leg ulcers (VULCAN) trial. *Br J Surg* 2009; 96:1147.

**Mosti G:** Compression in leg ulcer treatment: inelastic compression. *Phlebology* 2014; 29(1 Suppl):146–152.

**Pugashetti R, et al:** Dermal mucinosis as a sign of venous insufficiency. *J Cutan Pathol* 2010; 37(2):292–296.

**Rico T, et al:** Vascular endothelial growth factor delivery via gene therapy for diabetic wounds: first steps. *J Invest Dermatol* 2009; 129:2084.

**Rongioletti F, et al:** Obesity-associated lymphoedematous mucinosis. *J Cutan Pathol* 2009; 36:1089.

**Samson RH, et al:** Stockings and the prevention of recurrent venous ulcers. *Dermatol Surg* 1996; 22:373.

**Serra R, et al:** A genetic study of chronic venous insufficiency. *Ann Vasc Surg* 2012; 26:636.

**Tokuda Y, et al:** Chronic obesity lymphoedematous mucinosis: three cases of pretibial mucinosis in obese patients with pitting oedema. *Br J Dermatol* 2006; 154:157.

**Van Gent WB, et al:** Conservative versus surgical treatment of venous leg ulcers: a prospective, randomized, multicenter trial. *J Vasc Surg* 2006; 44(3):563–571.

**Vlajinac HD, et al:** Body mass index and primary chronic venous disease: a cross-sectional study. *Eur J Vasc Endovasc Surg* 2013; 45:293.

**Wong IK, et al:** Randomized controlled trial comparing treatment outcome of two compression bandaging systems and standard care without compression in patients with venous leg ulcers. *J Vasc Surg* 2012; 55(5):1376–1385.

## LYMPHEDEMA

Lymphedema is the swelling of soft tissues in which an excess amount of lymph has accumulated. Chronic lymphedema is characterized by long-standing, nonpitting edema. [Box 35-2](#) provides a working classification of lymphedema.

The most prevalent worldwide cause of lymphedema is filariasis. In the United States, the most common cause is postsurgical. If lymphedema is long-standing, a verrucous appearance to the affected extremity develops (elephantiasis verrucosa nostra).

Lymphedema of the lower extremity must be distinguished from "lipedema." This syndrome is characterized by bilateral, symmetric lower extremity enlargement caused by subcutaneous fat deposition. The buttocks to the ankles are affected in women, starting at puberty with gradual progression. The feet are spared in lipedema but usually involved in lower extremity lymphedema. Lipedema does not respond to compression therapy. The skinfold at the base of the second toe is too thick to pinch in lymphedema but normal in lipedema (Stemmer's sign). Verrucous changes do not occur in lipedema but do occur in lymphedema. Women with lipedema will have tenderness to pressure on the affected area. There is frequently a family history of lipedema. Magnetic resonance imaging (MRI) will separate the two entities if the diagnosis cannot be confirmed on a clinical basis.

## Types

Lymphedema is classified by clinical type ([Box 35-2](#)). Primary types include congenital and early-onset and late-onset lymphedema. Other primary types of lymphedema are associated with characteristic features or syndromes. Some cutaneous disorders are associated with, or a complication of, primary lymphedema. Secondary lymphedema can occur from numerous causes, including neoplasia and its treatment, infections, and physical factors.

## Lymphedema praecox

Lymphedema praecox accounts for the majority of primary lymphedema cases; it usually develops in females between

**Box 35-2** Classification of lymphedema**Primary lymphedema**

- Congenital lymphedema (Milroy's disease)
- Lymphedema praecox
- Lymphedema tarda

**Syndromes associated with primary lymphedema**

- Yellow nail syndrome
- Turner syndrome
- Noonan syndrome
- Pes cavus
- Phakomatosis pigmentovascularis
- Distichiasis-lymphedema
- Emberger syndrome
- WILD syndrome
- Hypotrichosis-telangiectasia-lymphedema syndrome

**Cutaneous disorders sometimes associated with primary lymphedema**

- Yellow nails
- Hemangiomas
- Xanthomatosis and chylous lymphedema
- Congenital absence of nails

**Secondary lymphedema**

- Postmastectomy lymphedema
- Melphalan isolated limb perfusion
- Malignant occlusion with obstruction
- Extrinsic pressure
- Factitial lymphedema
- Postradiation therapy
- Following recurrent lymphangitis/cellulitis
- Lymphedema of upper limb in recurrent eczema
- Granulomatous disease
- Rosaceous lymphedema
- Primary amyloidosis

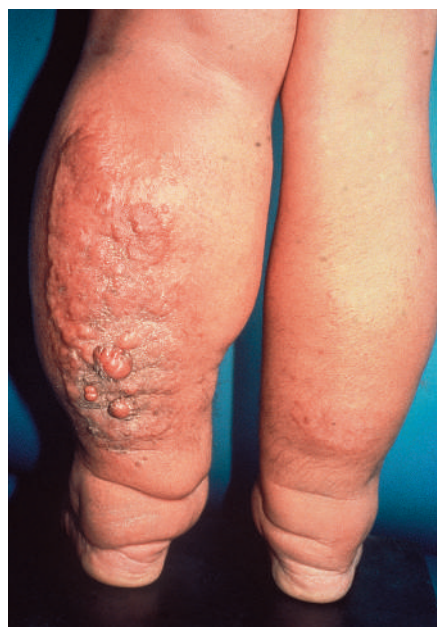**Complications of lymphedema**

- Cellulitis of lymphedema
- Elephantiasis nostra verrucosa
- Ulceration
- Lymphangiosarcoma

ages 9 and 25. Swelling appears around the ankle and then extends upward to involve the entire leg; the condition is unilateral in 70% and affects the left leg more often than the right. With the passage of time, the leg becomes painful, with a dull, heavy sensation. Once this stage has been reached, the swollen limb remains swollen, since fibrosis has occurred. These changes are caused by a defect in the lymphatic system. Lymphangiography demonstrates hypoplastic lymphatics in 87% of patients, aplasia in approximately 5%, and hyperplasia with varicose dilation of the lymphatic vessels in 8%. Because the condition typically occurs in women around menarche, estrogen may play a pathogenic role.

**Nonne-Milroy-Meige syndrome (hereditary lymphedema)**

Milroy hereditary edema of the lower legs is characterized by a unilateral or bilateral lymphedema present at, or soon after, birth and is inherited as an autosomal dominant trait. The edema is painless, pits on pressure, is not associated with any



**Fig. 35-34** Milroy's disease. (Courtesy of Dr. Lawrence Lieblich.)

other disorder, and persists throughout life (Fig. 35-34). It may involve the genitalia and produce lymphangiectasias superficially. Chylous discharge can occur. The face and arm may also be involved. Most frequently, the lymphedema is bilateral, and females are predominantly affected.

Treatment of this particular type of edema is extremely difficult, since the disease is an anomaly of the lymph-draining vessels. Decongestive physiotherapy can be considered. In some cases, surgical procedures to remove affected tissue can be performed. This condition may be linked to a mutation in *FLT4*, the gene for VEGFR3, which is expressed in lymphatic endothelial cells and is necessary for normal lymphatic function.

**Lymphedema-distichiasis syndrome**

The association of distichiasis (double row of eyelashes) and late-onset lymphedema is a form of hereditary lymphedema called lymphedema-distichiasis syndrome, or Meige syndrome. It is an autosomal dominant syndrome with the appearance of bilateral lymphedema, beginning between ages 8 and 10 in affected boys, and between 13 and 30 in affected girls. Lymphatic vessels are increased (not hypoplastic or absent, as in other forms of congenital lymphedema) in the affected legs, but lymphatic valves are aplastic. Associated findings are varicose veins in 50% by age 64; congenital ptosis (31%); and congenital heart disease (6.8%), cleft palate (4%), scoliosis, and renal abnormalities. There may be phenotypic heterogeneity in this syndrome, because different mutations may lead to slightly different phenotypes, especially in regard to the ancillary features associated with the syndrome. This syndrome is caused by a gene mutation in the *FOXC2* transcription factor. This factor is expressed in developing eyelids, lymphatics, lymphatic valves, and other tissues with abnormalities in this syndrome.

**Emberger syndrome**

Emberger syndrome is primary lymphedema associated with myelodysplasia. This genetic syndrome presents with lymphedema of one or both lower limbs and often the genitalia between infancy and puberty. Myelodysplastic syndrome and



acute myeloid leukemia developing in adolescence or childhood are preceded by pancytopenia with a high incidence of monosomy 7 in the bone marrow. Associated features include mild skeletal abnormalities, deafness, and multiple warts. This syndrome is associated with gene mutations in GATA2, a hematopoietic transcription factor.

### **WILD syndrome (warts, immunodeficiency, lymphedema, anogenital dysplasia)**

Lymphedema appears in early childhood and may progress to involve all four extremities and the genitalia. Widespread flat warts appear during childhood, resembling the numerous flat warts seen in epidermodysplasia verruciformis. The anogenital region develops numerous warts and anogenital dysplasia. Helper T cells are reduced.

### **Hypotrichosis-telangiectasia-lymphedema syndrome**

Lymphedema appears in childhood. Vascular dilations and telangiectasias appear on the palms and soles. Both autosomal recessive and autosomal dominant patterns of inheritance occur, but both forms are caused by mutations in the gene for SOX18.

### **Primary lymphedema associated with yellow nails and pleural effusion (yellow nail syndrome)**

Lymphedema is confined mostly to the ankles and occurs in about 60% of patients with yellow nail syndrome. The nails show a distinct yellowish discoloration and thickening. Recurrent pleural effusion or bronchiectasis may be a feature.

### **Secondary lymphedema**

In some malignant diseases, involvement of the axillary or pelvic lymph nodes will produce blockage and lymphedema. Malignant disease of the breast, uterus, prostate, skin, bones, or other tissues may cause such changes. Hodgkin disease and especially Kaposi sarcoma may be accompanied by significant lymphedema well beyond the amount expected from the degree of skin involvement. Such patients require chemotherapy; lymphedema is the hallmark of lymphatic involvement. Chronic lymphedema is seen in more than one in five women after mastectomy and removal of the axillary nodes; it may occur after varying time periods.

### **Postmastectomy lymphangiosarcoma (Stewart-Treves syndrome)**

This type of vascular malignancy usually arises in chronic postmastectomy lymphedema. The lesions are bluish or reddish nodules arising on the arm. Similarly, primary or secondary lymphedema of the lower extremity may be complicated by angiosarcoma. Angiosarcoma arising in a lymphedematous extremity often presents with multiple lesions. Metastasis and death frequently result. Early, aggressive surgical treatment with amputation may be lifesaving. The treatment of breast cancer with lumpectomy and local radiation therapy may be complicated by angiosarcoma of the breast with minimal or no associated lymphedema. This is called "cutaneous postradiation angiosarcoma of the breast." This form of angiosarcoma also frequently results in metastasis and death.

### **Obesity-related lymphedema**

Morbid obesity may impair lymphatic return, resulting in lymphedema. It is also an independent risk factor for developing lymphedema after surgery or cancer therapy. A recently-described entity called "massive localized lymphedema" occurs in morbidly obese patients, presenting with a painless mass, usually on the medial thigh, characterized by typical cutaneous clinical and histologic changes of chronic lymphedema.

### **Postinflammatory lymphedema**

The lymphedematous extremity may be caused and worsened by repeated bacterial cellulitis or lymphangitis. These recurrent infectious episodes, when they complicate filariasis, cause the elephantiasis. Streptococcal cellulitis after venectomy in patients who have undergone coronary bypass surgery is a well-documented cause. However, almost any chronic or recurrent infection can cause lymphatic damage. Chronic antibiotic therapy can halt the progression by preventing the attacks of bacterial cellulitis.

### **Bullous lymphedema**

Frequently misdiagnosed as an immunobullous disease, bullous lymphedema usually occurs with poorly controlled edema related to heart failure and fluid overload. Compression results in healing.

### **Factitial lymphedema**

Also known as hysterical edema, lymphedema can be produced by wrapping an elastic bandage, cord, or shirt around an extremity, and/or holding the extremity in a dependent and immobile state. Self-inflicted causes of lymphedema are usually difficult to prove and may occur in settings of known causes of lymphedema, such as postphlebotic syndrome or surgical injury to the brachial plexus. Factitial lymphedema caused by blunt trauma localized to the dorsum of the hand or forearm is referred to as Secretan syndrome or l'oedème bleu, respectively. It often is unilateral, and significant purpura may occur. Effective care of such patients requires psychiatric intervention. Occupational causes must be excluded.

### **Podoconiosis**

Podoconiosis, or mossy foot, is a noninfectious form of lymphedema. It is restricted to tropical regions in Central Africa, Central America, and North India. It occurs in persons walking barefoot in soil of volcanic origin. This soil has high concentrations of aluminum, silicon, beryllium, zirconium, magnesium, and iron. Colloid-sized particles of the dust penetrate the sole, are ingested by macrophages, and migrate to lymph nodes. Lymphatic drainage is impaired by fibrosis of lymphatic channels induced by microscopic deposits of the substances. Males and females are equally affected, and in endemic areas, up to 5% of the population can develop the disease. Moving into an endemic area from a nonendemic area can lead to the condition appearing over the next 5 years. Podoconiosis begins in childhood or adolescence with mild swelling of the feet. Burning of the feet occurs at night. The dorsal surface of the foot itches, is rubbed, and becomes lichenified. Increased skin markings result, and finally, marked hyperkeratosis caused by repeated infections. This closely resembles elephantiasis verrucosa cutis. The condition is usually asymmetric. Podoconiosis is prevented by wearing shoes. Elevation, compression, and local wound care all aid in treating this condition. Extensive surgery, as done for filariasis, has had disappointing results.

## Occupational hand edema

Occupational persistent hand edema in divers can occur, related to the constrictive action of the divers' suits and pricks from sea urchin spines.

### Evaluation

The diagnosis of lymphedema is usually based on a classic presentation; in the early stages, however, the disease may require further investigation. Considerations include isotopic lymphoscintigraphy, fluorescence microlymphography, MRI, computed tomography, and ultrasonography. These imaging modalities have replaced lymphangiography, a more invasive technique that can cause further damage to remaining lymphatics.

### Treatment

Most patients with lymphedema are treated conservatively by means of various forms of compression therapy, complex physical therapy, pneumatic pumps, and compressive garments. Chronic antibiotic treatment may be beneficial in patients with repeated episodes of erysipelas or cellulitis. In diabetic patients with insensate feet, the frequency of infection can be reduced by wearing properly fitting shoes. Volume-reducing surgery and lymphatic microsurgery are rarely performed, although a few centers consistently report favorable results. It is best to refer these patients to a center versed in the treatment of these complicated conditions, to optimize patient compliance and customize therapy to the patient's lifestyle.

**Allen PJ, et al:** Lower extremity lymphedema caused by acquired immune deficient syndrome-related Kaposi's sarcoma. *J Vasc Surg* 1995; 22:178.

**Ameen M, et al:** Clinicopathological case 2: lymphoedema-distichiasis syndrome. *Clin Exp Dermatol* 2003; 28:463.

**Angelini G, et al:** Occupational traumatic lymphedema of the hands. *Dermatol Clin* 1990; 8:205.

**Asch S, et al:** Massive localized lymphedema: an emerging dermatologic complication of obesity. *J Am Acad Dermatol* 2008;59(5 Suppl):S109.

**Badger C, et al:** Physical therapies for reducing and controlling lymphoedema of the limbs. *Cochrane Database Syst Rev* 2004; 4:CD003141.

**Campisi C, Boccardo F:** Microsurgical techniques for lymphedema treatment: derivative lymphatic-venous microsurgery. *World J Surg* 2004; 28:609.

**Cerri A, et al:** Lymphangiosarcoma of the pubic region: a rare complication arising in congenital non-hereditary lymphedema. *Eur J Dermatol* 1998; 8:511.

**Connell F, et al:** A new classification system for primary lymphatic dysplasias based on phenotype. *Clin Genet* 2010;77(5):438–452.

**DiSipio T, et al:** Incidence of unilateral arm lymphoedema after breast cancer: a systematic review and meta-analysis. *Lancet Oncol* 2013; 14:500.

**Dornia C, et al:** Yellow nail syndrome: dystrophic nails, peripheral lymphedema and chronic cough. *Can Respir J* 2011; 18(4):e68–e69.

**Downes M, et al:** Vascular defects in a mouse model of hypotrichosis-lymphedema-telangiectasia syndrome indicate a role for SOX18 in blood vessel maturation. *Hum Mol Genet* 2009; 18:2839.

**Durr HR, et al:** Stewart-Treves syndrome as a rare complication of hereditary lymphedema. *Vasa* 2004; 33:42.

**Fonder MA, et al:** Lipedema, a frequently unrecognized problem. *J Am Acad Dermatol* 2007; 57:S1.

**Fredman R, Tenenhaus M:** Elephantiasis nostras verrucosa. *Eplasty* 2012; 12:ic14

**Harel L, et al:** Lymphedema praecox seen as isolated unilateral arm involvement. *J Pediatr* 1997; 130:492.

**Helyer LK, et al:** Obesity is a risk factor for developing postoperative lymphedema in breast cancer patients. *Breast J* 2010; 16(1):48–54.

**Joseph A, et al:** The efficacies of affected-limb care with penicillin diethylcarbazine, the combination of both drugs or antibiotic ointment, in the prevention of acute adenolymphangitis during bancroftian filariasis. *Ann Trop Med Parasitol* 2004; 98:685.

**Karkkainen MJ, et al:** Missense mutations interfere with VEGFR-3 signalling in primary lymphoedema. *Nat Genet* 2000; 25(2):153–159.

**Kerchner K, et al:** Lower extremity lymphedema update: pathophysiology, diagnosis, and treatment guidelines. *J Am Acad Dermatol* 2008; 59:324.

**Kreuter A, et al:** A human papillomavirus-associated disease with disseminated warts, depressed cell-mediated immunity, primary lymphedema, and anogenital dysplasia: WILD syndrome. *Competence Network HIV/AIDS. Arch Dermatol* 2008; 144(3):366–372.

**Makrilakis K, et al:** Successful octreotide treatment of chylous pleural effusion and lymphedema in the yellow nail syndrome. *Ann Intern Med* 2004; 141:246.

**Maldonado F, Ryu JH:** Yellow nail syndrome. *Curr Opin Pulm Med* 2009; 15:371.

**Mayrovitz HN:** The standard of care for lymphedema: current concepts and physiological considerations. *Lymphat Res Biol* 2009; 7(2):101–108.

**Mellor RH, et al:** Lymphatic dysfunction, not aplasia, underlies Milroy disease. *Microcirculation* 2010; 17(4):281–296.

**Mendola A, et al:** Mutations in the VEGFR3 signaling pathway explain 36% of familial lymphedema. *The Lymphedema Research Group. Mol Syndromol* 2013; 4(6):257–266.

**Miller TA, et al:** Staged skin and subcutaneous excision for lymphedema: a favorable report of long-term results. *Plast Reconstr Surg* 1998; 102:1486.

**Moorjani N, et al:** Pleural effusion in yellow nail syndrome: treatment with bilateral pleuro-peritoneal shunts. *Respiration* 2004; 71:298.

**Nenoff P, et al:** Podoconiosis—non-filarial geochemical elephantiasis—a neglected tropical disease. *J Dtsch Dermatol Ges* 2010; 8:7.

**Nikitenko LL, et al:** Adrenomedullin haploinsufficiency predisposes to secondary lymphedema. *J Invest Dermatol* 2013; 133(7):1768–1776.

**Ostergaard P, et al:** Mutations in GATA2 cause primary lymphedema associated with a predisposition to acute myeloid leukemia (Emberger syndrome). *Nat Genet* 2011; 43(10):929.

**Pereira de Godoy JM, et al:** Intensive treatment of leg lymphedema. *Indian J Dermatol* 2010; 55(2):144–147.

**Ridner SH, et al:** Symptom burden and infection occurrence among individuals with extremity lymphedema. *Lymphology* 2012; 45:113–123.

**Rockson SG:** Diagnosis and management of lymphatic vascular disease. *J Am Coll Cardiol* 2008; 52:799.

**Ruocco V, et al:** Lymphedema: an immunologically vulnerable site for development of neoplasms. *J Am Acad Dermatol* 2002; 47:124.

**Sharma A, Schwartz RA:** Stewart-Treves syndrome: pathogenesis and management. *J Am Acad Dermatol* 2012; 67(6):1342–1348.

**Tosti A, et al:** Systemic itraconazole in the yellow nail syndrome. *Br J Dermatol* 2002; 146:1064.

**Warren AG, et al:** Lymphedema: a comprehensive review. *Ann Plast Surg* 2007; 59(4):464–472.



Bonus images for this chapter can be found online at [expertconsult.inkling.com](http://expertconsult.inkling.com)

**eFig. 35-1** Raynaud phenomenon with fingertip necrosis.

**eFig. 35-2** Photo-induced livedo reticularis secondary to quinidine administration.

**eFig. 35-3** Hematoma.

**eFig. 35-4** Purpura secondary to vomiting.

**eFig. 35-5** Pigmented purpuric dermatosis.

**eFig. 35-6** Leukocytoclastic vasculitis; concentration of lesions along dividing line between dorsal foot and sole (Wallace line).

**eFig. 35-7** Henoch-Schönlein purpura.

**eFig. 35-8** Acute hemorrhagic edema.

**eFig. 35-9** Erythema elevatum diutinum.

**eFig. 35-10** Hereditary hemorrhagic telangiectasia.

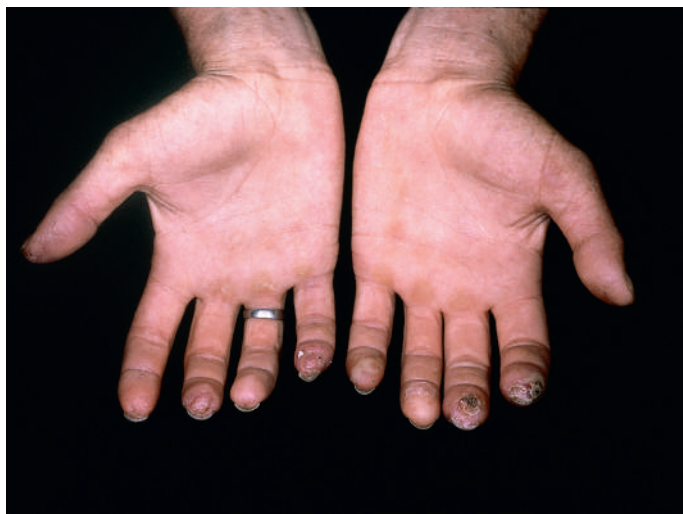**eFig. 35-11** Hereditary hemorrhagic telangiectasia.

**eFig. 35-12** Stasis dermatitis, venous insufficiency.

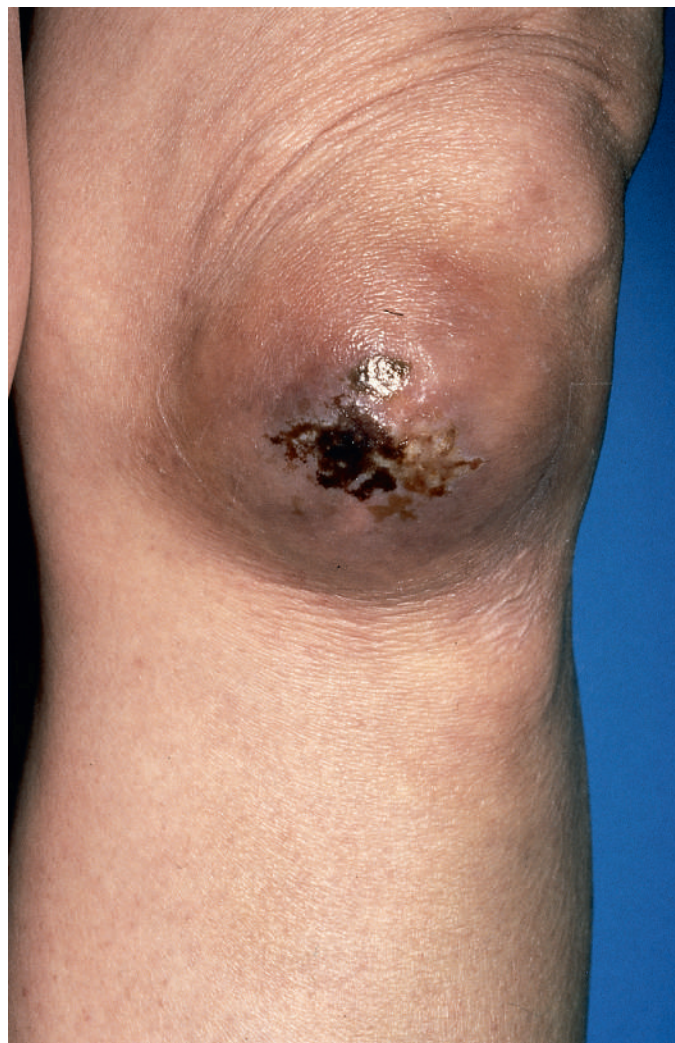**eFig. 35-13** Elephantiasis verrucosa nostra.

**eFig. 35-14** Distichiasis. (Courtesy of Dr. Curt Samlaska.)

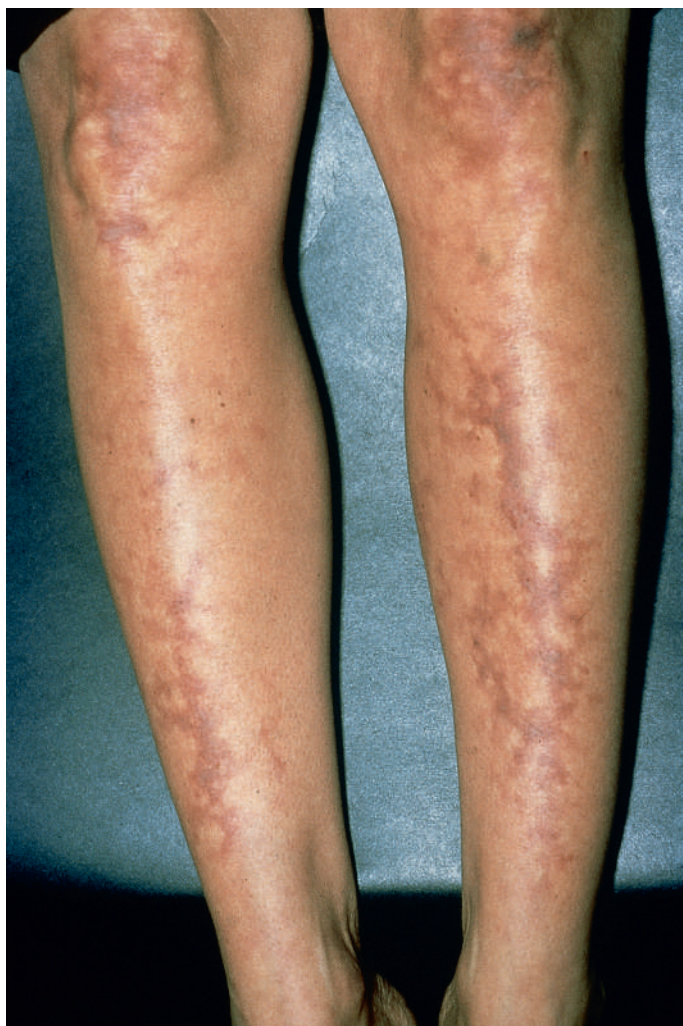



**eFig. 35-1** Raynaud phenomenon with fingertip necrosis.

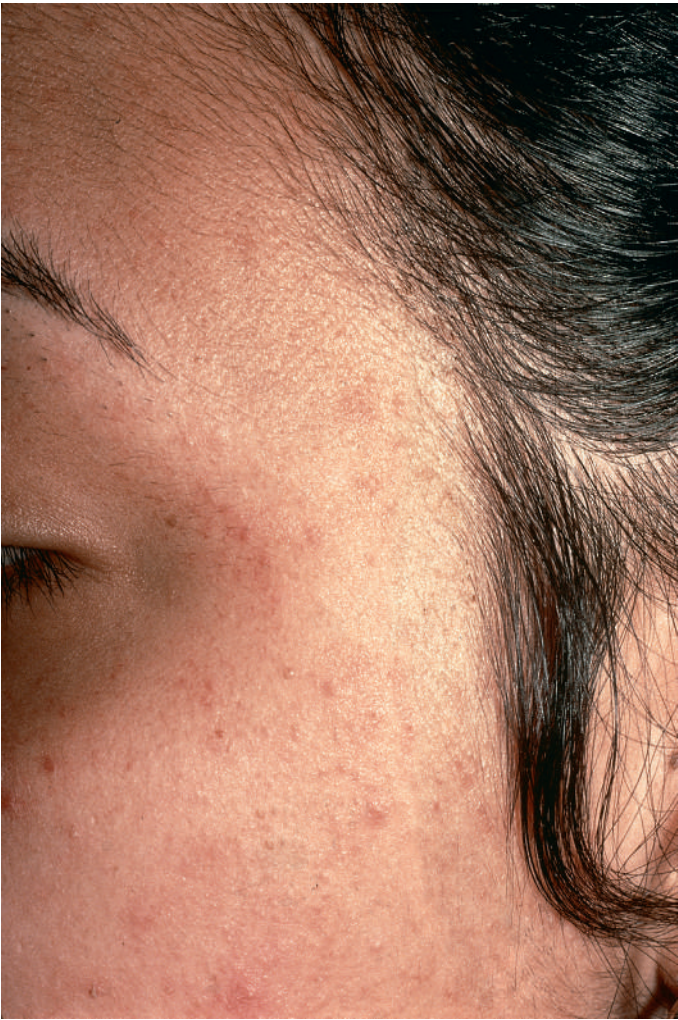

**eFig. 35-3** Hematoma.

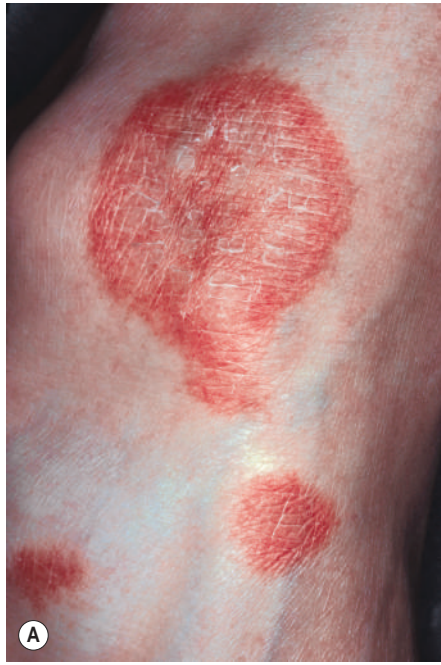


**eFig. 35-2** Photo-induced livedo reticularis secondary to quinidine administration.

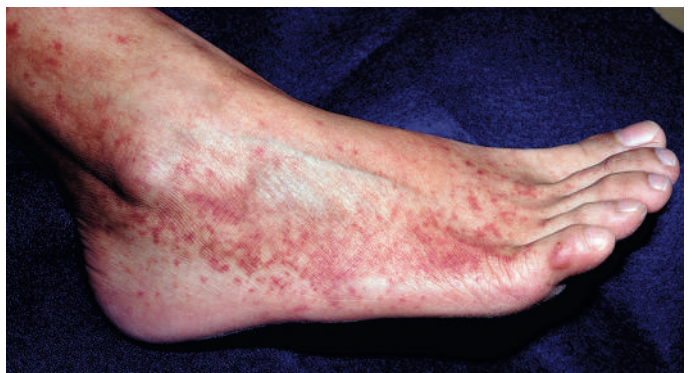
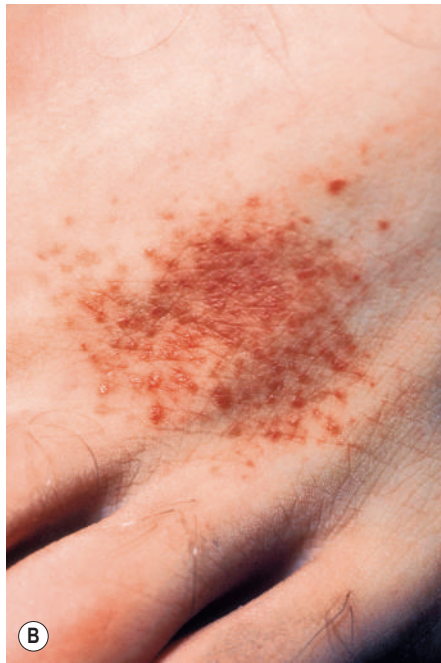


**eFig. 35-4** Purpura secondary to vomiting.

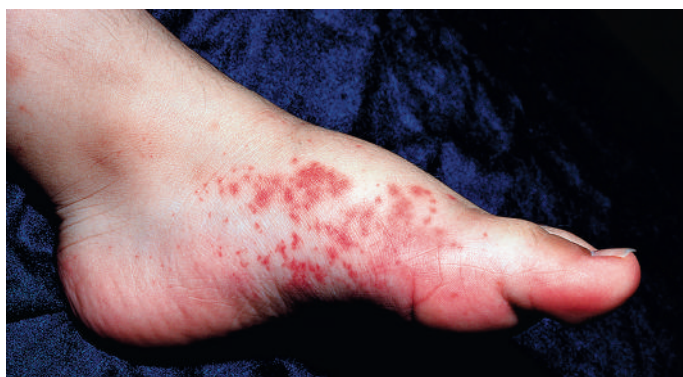

**eFig. 35-5** Pigmented purpuric dermatosis.

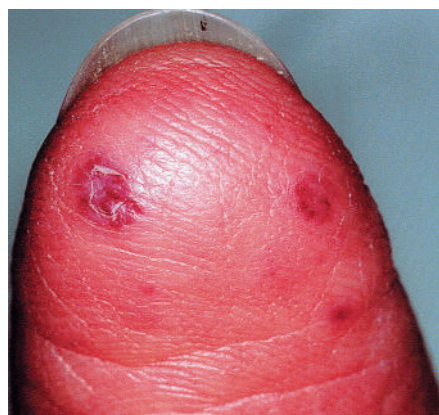

**eFig. 35-6** Leukocytoclastic vasculitis; concentration of lesions along dividing line between dorsal foot and sole (Wallace line).

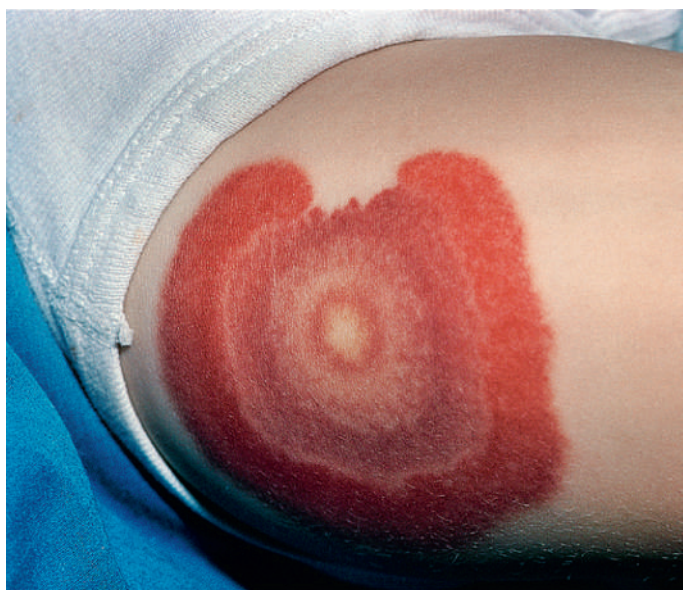



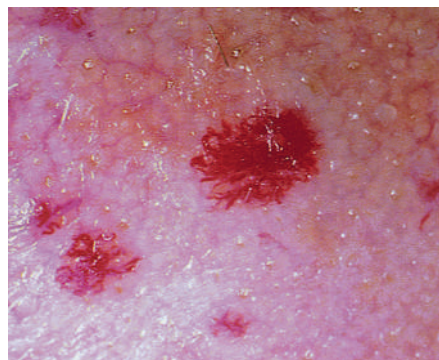
eFig. 35-7 Henoch-Schönlein purpura.



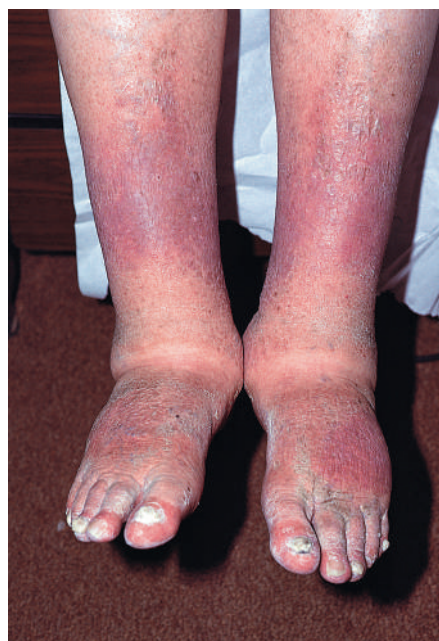eFig. 35-10 Hereditary hemorrhagic telangiectasia.



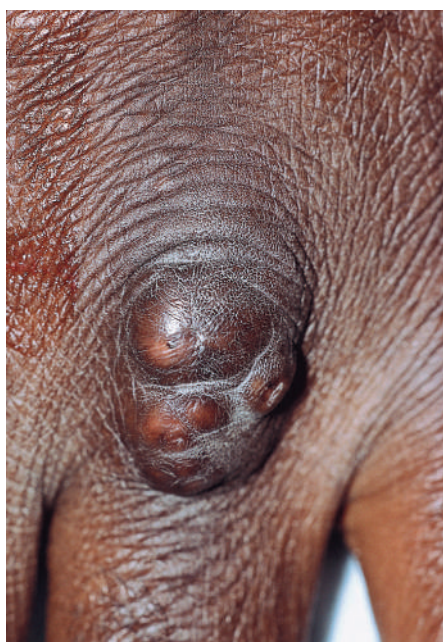eFig. 35-8 Acute hemorrhagic edema.



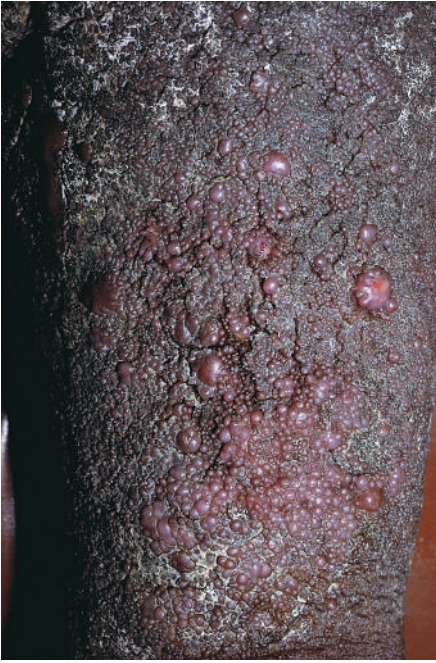eFig. 35-11 Hereditary hemorrhagic telangiectasia.



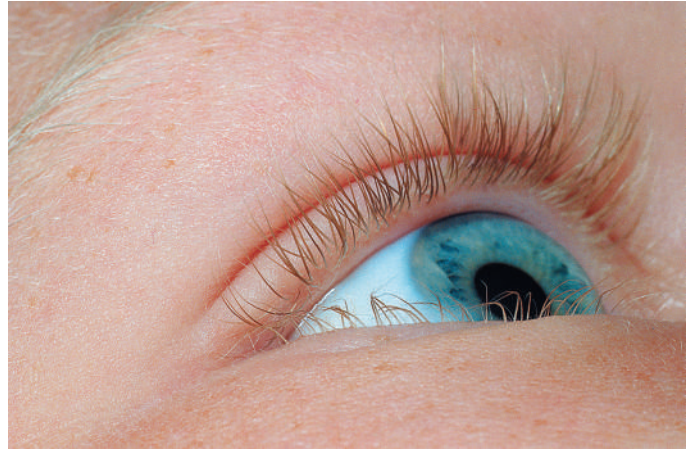eFig. 35-12 Stasis dermatitis, venous insufficiency.



eFig. 35-9 Erythema elevatum diutinum.



**eFig. 35-13**  
Elephantiasis  
verrucosa nostra.



**eFig. 35-14** Distichiasis. (Courtesy of Dr. Curt Samlaska.)



# 36

## Disturbances of Pigmentation

The visible pigmentation of the skin or hair is a combination of the amount of melanin, type of melanin (eumelanin vs. pheomelanin), degree of vascularity, presence of carotene, and thickness of the stratum corneum. Other materials can be deposited abnormally in the skin, leading to pigmentation. Eumelanin is the primary pigment producing brown coloration of the skin. Pheomelanin is yellow or red and is also produced solely in melanocytes. Melanin is formed from tyrosine, through the action of tyrosinase, in the melanosomes of melanocytes. A multitude of genes are expressed only in melanosomes and apparently are important in melanin production and delivery. Melanosomes are lysosome-related organelles. Melanosome formation and the end result, pigmentation, require both the adequate manufacture of melanin and the appropriate transport of melanosomes within the melanocyte. The melanosomes are transferred from a melanocyte to a group of 36 keratinocytes called the epidermal melanin unit, to which they provide melanin. The variations in skin color between persons and races are related to the degree of melanization of melanosomes, their number, and their distribution in the epidermal melanin unit. Disorders of loss or reduction of pigmentation may be related to loss of melanocytes or the inability of melanocytes to produce melanin or transport melanosomes correctly. Wood's light examination is often performed to evaluate lesions of hyperpigmentation or hypopigmentation. Hyperpigmented lesions that enhance with Wood's light usually have increased epidermal melanocyte number or activity. If the lesions do not enhance, the melanin is located in the dermis. Wood's light will greatly enhance depigmented lesions (complete loss of pigment) but does not enhance lesions with partial pigment loss (hypopigmentation).

**Yaar M, et al:** Cutaneous pigmentation in health and disease: novel and well-established players. *J Invest Dermatol* 2013; 133:11.

### PIGMENTARY DEMARCATION LINES

Pigmentary demarcation boundaries of the skin can be classified into groups based on their anatomic location, orientation, and degree of pigmentation (hyperpigmentation or hypopigmentation):

1. Group A: lines along the outer upper arms with variable extension across the chest
2. Group B: lines along the posteromedial aspect of the lower limb (Fig. 36-1)
3. Group C: paired median or paramedian lines on the chest, with midline abdominal extension
4. Group D: medial, over the spine
5. Group E: bilaterally symmetric, obliquely oriented, hypopigmented macules on the chest
6. Groups F, G, and H: facial pigmentary demarcation lines

More than 70% of black patients have one or more lines, which are much less common in white patients. Group B lines often appear for the first time during pregnancy.

The term "acquired, idiopathic, patterned facial pigmentation" (AIPFP) has been used to encompass pigmentary demarcation lines of the face as well as idiopathic periorbital and perioral pigmentation. These are patterned, bilateral, and homogeneous and have various shades of brown with a variable gray undertone. Periorbital and perioral hyperpigmentation occur in the late teens and early twenties. Other forms of facial hyperpigmentation occur later (average age >30). Periorbital pigmentation usually is demarcated by a band of normal skin beneath the upper eyebrow superiorly and the orbital rim inferiorly. It may extend outward onto the lateral cheek or over the root of the nose. One third of patients with perioral pigmentation have a family history. These patterns of facial pigmentation may represent variations of embryologic pigmentation.

Pigmentary demarcation lines must be distinguished from the much rarer condition, acquired dermal melanocytosis (ADM). This primarily affects Asian and Hispanic women (male/female ratio 1:17). The face is the most common location, and it includes the entities bilateral and unilateral nevus of Ota-like macules (Hori and Sun nevus, respectively). ADM can first appear during pregnancy or therapeutic use of estrogen/progesterone. Lesions present as blue-gray patches, with superimposed brown macules. Infrequently, the trunk or extremities may be affected. Lesions do not enhance with Wood's light. They may be localized (after trauma) or may be more diffuse. Ultraviolet (UV) light and psoralen plus UVA (PUVA) therapy are possible precipitants. Biopsy shows melanocytes in the dermis, similar to the findings in mongolian spot, nevus of Ota, and nevus of Ito. The lesions appear to represent activation of melanin production by residual dermal melanocytes because biopsies in "normal" skin adjacent to the pigmented lesions show dermal melanocytosis.

**Cho E, et al:** Type B pigmentary demarcation lines of pregnancy involving the anterior thighs and knees. *Ann Dermatol* 2012; 24:348.

**Chuah SY, et al:** Acquired dermal melanocytosis of the nose. *J Eur Acad Dermatol Venereol* 2014; Mar 11. [Epub ahead of print.]

**Fauconneau A, et al:** Acquired dermal melanocytosis of the back in a Caucasian woman. *Am J Dermatopathol* 2012; 34:562.

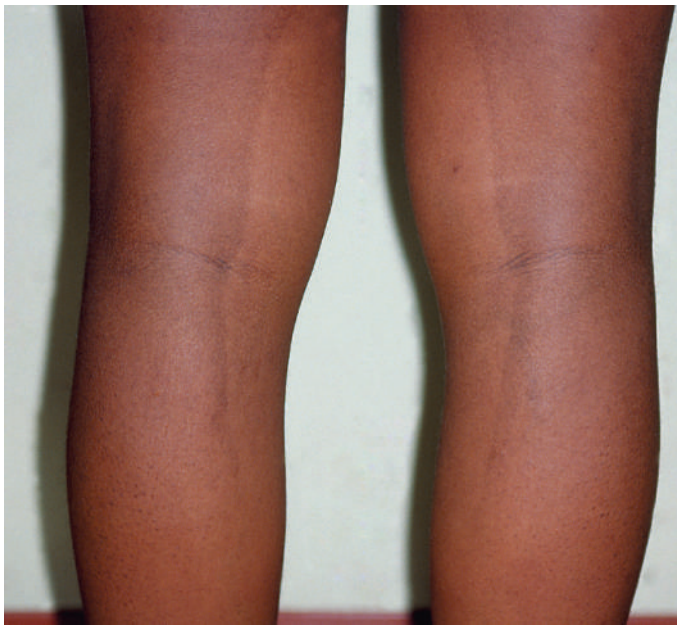**Mintz S, Velez I:** Pigmentary demarcation lines (Futcher lines): an orofacial case. *Quintessence Int* 2010; 41:873.

**Nagase K, et al:** Acquired dermal melanocytosis induced by psoralen plus ultraviolet A therapy. *Acta Derm Venereol* 2012; 92:691.

**Peck JW, Cusack CA:** Futcher lines: a case report in pregnancy and literature review. *Cutis* 2013; 92:100.

**Permatasari F, et al:** Late-onset acquired dermal melanocytosis on the hand of a Chinese woman. *Indian J Dermatol Venereol Leprol* 2013; 79:269.

**Purnak S, et al:** Pigmentary demarcation lines of pregnancy in two Caucasian women. *J Eur Acad Dermatol Venereol* 2014. [Epub ahead of print.]



**Fig. 36-1** Pigmentary demarcation lines.

**Sarma N, et al:** Acquired, idiopathic, patterned facial pigmentation (AIPFP) including periorbital pigmentation and pigmentary demarcation lines on face follows the lines of Blaschko on face. *Indian J Dermatol* 2014; 59:41.

**Zhang R, Zhu W:** Coexistence of pigmentary demarcation lines types C and E in one subject. *Int J Dermatol* 2011; 50:863.

## ABNORMAL PIGMENTATION

### Hemosiderin hyperpigmentation

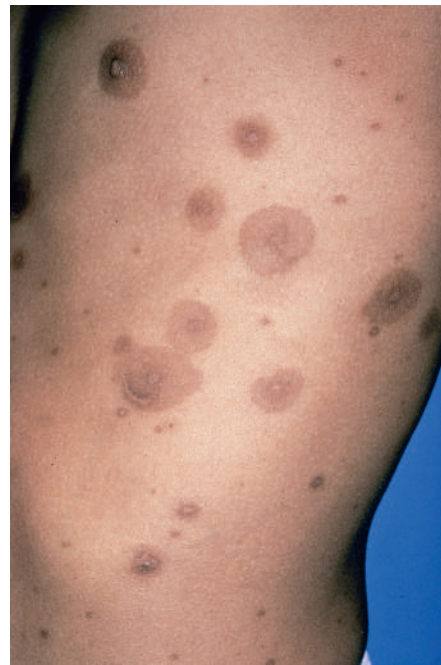
Pigmentation resulting from deposits of hemosiderin occurs in purpura, hemochromatosis, hemorrhagic diseases, and stasis dermatitis. Clinically, hemosiderin hyperpigmentation is distinguished from postinflammatory dermal melanosis by a golden-brown hue, unlike the brown or gray-blue pigmentation of epidermal or dermal melanin, respectively. At times, a biopsy is required to distinguish melanin-induced from hemosiderin-induced hyperpigmentation. Some medications, including minocycline, deposit in the skin and complex with both iron and melanin, making uniquely colored (usually blue-gray) deposits. Extravasation of iron into the soft tissue from a poorly functioning venous catheter can cause local hemosiderosis of a limb. Multiple transfusions (>20) can result in cutaneous iron deposits in about 20% of patients. Drinking tea while ingesting an iron-containing solution can result in iron staining of the tongue and teeth, simulating black hairy tongue.

### Postinflammatory hyperpigmentation (postinflammatory pigmentary alteration)

Any natural or iatrogenic inflammatory condition can result in hyperpigmentation or hypopigmentation. Postinflammatory dyspigmentation is more common in persons with Fitzpatrick skin types IV, V, and VI, especially types IV and V. It is more likely to occur after laser treatment when performed in premenstrual women. It affects both genders equally.

Hyperpigmentation may result from the following two mechanisms:

1. Increased epidermal pigmentation via increased melanocyte activity



**Fig. 36-2** Postinflammatory hyperpigmentation from varicella.

2. Dermal melanosis from melanin dropout from the epidermis into the dermis

Wood's light examination will distinguish these two patterns of postinflammatory hyperpigmentation. Lesions of hyperpigmentation tend to be tan to brown (Fig. 36-2) and may have a gray hue, caused by dermal melanin.

Hypopigmented lesions are prominently lighter than the surrounding area. Histologically, there is melanin in the upper dermis and around upper dermal vessels, located primarily in macrophages (melanophages). The pattern of the dermal melanosis does not predict whether the lesion will be lighter or darker as a result of the prior inflammatory process—thus the tendency of pathologists to provide a diagnosis of “postinflammatory pigmentary alteration” (PIPA) in such cases.

Postinflammatory dyspigmentation is addressed initially by treating the underlying skin disease, if possible. The resolution of pityriasis alba with mild topical corticosteroids and moisturizers is an example of resolution of postinflammatory hypopigmentation by treating the cause. This should be the sole approach in hypopigmented lesions after inflammation. For hyperpigmented lesions, hydroquinone may be used in cases that enhance with Wood's light. Tretinoin application may enhance the effect of hydroquinone. Laser treatments and chemical peels must be done with extreme caution, because results are unpredictable and increased pigmentation may result.

**Al Mohizea S:** The effect of menstrual cycle on laser-induced hyperpigmentation. *J Drugs Dermatol* 2013; 12:1335.

**Cardinali G, et al:** Mechanisms underlying post-inflammatory hyperpigmentation: lessons from solar lentigo. *Ann Dermatol Venereol* 2012; 139:S148.

**Grimes PE:** Management of hyperpigmentation in darker racial ethnic groups. *Semin Cutan Med Surg* 2009; 28:77.

**Jung KE, et al:** Presence of iron in segmented heterochromia of the scalp hair without iron-deficiency anaemia. *Clin Exp Dermatol* 2012; 37:786.

**Kasuya Y, et al:** Glossal pigmentation caused by the simultaneous uptake of iron and tea. *Eur J Dermatol* 2014; 24:493.

**Lobo C, et al:** Retrospective epidemiological study of Latin American patients with transfusional hemosiderosis: the first Latin America epidemiological study in iron overload—the RELATH study. *Hematology* 2011; 16:265.



**Oram Y, Akkaya AD:** Refractory postinflammatory hyperpigmentation treated with fractional CO<sub>2</sub> laser. *J Clin Aesthet Dermatol* 2014; 7:42.

**Thompson J, et al:** Severe hemosiderin pigmentation after intravenous iron infusion. *Intern Med J.* 2014; 44:706.

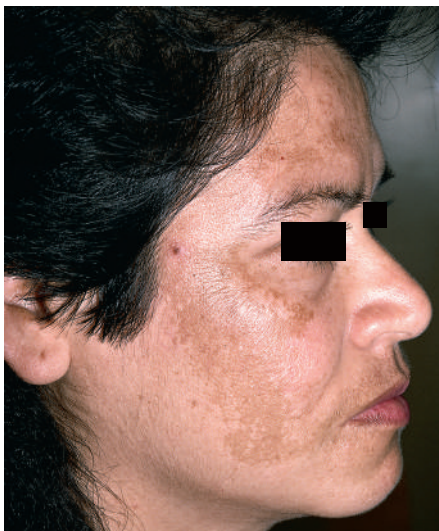
## MELASMA (CHLOASMA)

Melasma is a common disorder, with two predisposing factors: sun exposure and sex hormones. It tends to affect darker-complexioned individuals, especially East, West, and South-east Asians, Hispanics, and black persons who live in areas of intense sun exposure and who have Fitzpatrick skin types IV and V. Subtle melasma, as identified by UV light examination, may be seen in up to 30% of middle-age Asian females. Men are also affected, especially those from Central America, who may have prevalence rates as high as 35%. Guatemalan men seem to be at greater risk than Mexican men, and speaking a native tongue is also a risk factor, suggesting a genetic component associated with indigenous heritage.

The pathogenesis of melasma is not known. However, many observations strongly suggest that sun exposure is the primary trigger. Melasma affects the face, a sun-exposed area, and worsens in the summer. Melasma patients have a lower minimal erythema dose (MED) to UV light, and pigment more easily with UV exposure. An association exists between the number of melanocytic nevi and the development of melasma. The prevalence of melasma increases with age in both men and women. Solar elastosis is more marked in areas of melasma than unaffected facial skin. Melasma-affected skin has reduced WIF-1 (Wnt antagonist) expression and resultant increased Wnt expression; Wnt stimulates melanogenesis.

After sun exposure, the second most important trigger for melasma is female hormones. Melasma is more common and severe in women than men. It occurs frequently during pregnancy, with oral contraceptive (OC) use, or with hormone replacement therapy (HRT) at menopause. Discontinuing OC use or HRT rarely clears the pigmentation, which still may last for many years. In contrast, melasma of pregnancy usually clears within a few months of delivery. Melasma may be seen in other endocrinologic disorders, as well as with phenytoin and finasteride therapy.

Melasma is characterized by brown patches, typically on the malar prominences and forehead. The forearms may also be affected. There are three clinical patterns of facial melasma: centrofacial, malar, and mandibular. The centrofacial and malar patterns constitute the majority (Fig. 36-3), but most



**Fig. 36-3** Melasma of the cheek.

patients have multiple types, so this classification is not very useful therapeutically. The pigmented patches are usually sharply demarcated. Although melasma has classically been classified as epidermal or dermal, based on the presence or absence of Wood's light enhancement, respectively, most cases show both epidermal and dermal melanin. Dermal melanophages are a normal finding in sun-exposed Asian skin. Independent of Wood's light findings, a therapeutic trial of some form of hypopigmenting agent should be recommended if the patient requests it.

Therapeutically, a sunblock with broad-spectrum UVA (even visible light) coverage should be used daily; it will modestly improve the melasma, but more importantly, will enhance the efficacy of bleaching creams. Bleaching creams with hydroquinone are the gold standard and are moderately efficacious, containing 2% (available over the counter) to 4% hydroquinone. Tretinoin cream may be added to increase efficacy. Tretinoin alone may reduce melasma, but it is not as effective as hydroquinone. The combination of hydroquinone and tretinoin, administered with a topical corticosteroid, has been called "Kligman's formula" and is the most effective topical regimen available to treat melasma. Twice-weekly application of the triple combination can be effective for maintenance. Overuse can lead to fixed erythema and telangiectasias, acneiform eruptions, and hypertrichosis. When 4% hydroquinone is ineffective, higher concentrations may be recommended. Satellite pigmentation and local ochronosis are potential complications from use of these higher-concentration preparations. Methimazole, azelaic acid, kojic acid, vitamin C, and arbutin are other therapies with minimal to moderate efficacy. Many of these agents are added to cosmetic products for skin lightening and may be combined, because they act on different steps of melanogenesis. All these topical agents are generally less effective than 4% hydroquinone but may be used in the patient intolerant of hydroquinone. Oral tranexamic acid may play a role as a systemic agent in treating refractory melasma.

Various surgical procedures, such as peels and light-based treatments, have been proposed as effective for melasma, but results are mixed. Peels with glycolic acid, salicylic acid, trichloroacetic acid (TCA), and tretinoin 1% have not reproducibly enhanced the efficacy of 4% hydroquinone and can cause hyperpigmentation if irritation ensues. The use of light-based modalities for the treatment of melasma should be approached with caution. These therapies may be complicated by hyperpigmentation, irritation, hypopigmentation, and even scarring, if not used appropriately. Intense pulse light (IPL) can improve melasma, but there is a high relapse rate. Pulse dye laser may enhance combination topical treatment, and improvement may continue after therapy is discontinued. Q-switched neodymium:yttrium-aluminum-garnet (Nd:YAG) laser therapy can lead to increased pigmentation.

**Adalatkah H, et al:** Melasma and its association with different types of nevi in women: a case-controlled study. *BMC Dermatol* 2008; 8:3.

**Castanedo-Cazares JP, et al:** Near-visible light and UV photoprotection in the treatment of melasma: a double-blind randomized trial. *Photodermatol Photoimmunol Photomed* 2014; 30:35.

**Famenini S, et al:** Finasteride-associated melasma in a Caucasian male. *J Drugs Dermatol* 2014; 13:484.

**Fisk WA, et al:** The use of botanically derived agents for hyperpigmentation: a systematic review. *J Am Acad Dermatol* 2014; 70:352.

**Grimes PE:** Management of hyperpigmentation in darker racial ethnic groups. *Semin Cutan Med Surg* 2009; 28:77.

**Handel AC, et al:** Risk factors for facial melasma in women: a case-control study. *Br J Dermatol* 2014; 171:588.

**Hernandez-Barrera R, et al:** Solar elastosis and presence of mast cells as key features in the pathogenesis of melasma. *Clin Exp Dermatol* 2008; 33:305.

- Hexsel D, et al:** Epidemiology of melasma in Brazilian patients: a multicenter study. *Int J Dermatol* 2014; 53:440.
- Hexsel D, et al:** Objective assessment of erythema and pigmentation of melasma lesions and surrounding areas on long-term management regimens with triple combination. *J Drugs Dermatol* 2014; 13:444.
- Jutley GS, et al:** Systematic review of randomized controlled trials on interventions for melasma: an abridged Cochrane review. *J Am Acad Dermatol* 2014; 70:369.
- Kandhari R, Khunger N:** Skin lightening agents: use or abuse? A retrospective analysis of the topical preparations used by melasma patients of darker skin types. *Indian J Dermatol Venereol Leprol* 2013; 79:701.
- Kim MJ, et al:** Punctate leucoderma after melasma treatment using 1064-nm Q-switched Nd:YAG laser with low pulse energy. *J Eur Acad Dermatol Venereol* 2009; 23:960.
- Kim NH, et al:** Cadherin 11, a miR-675 target, induces N-cadherin expression and epithelial-mesenchymal transition in melasma. *J Invest Dermatol* 2014; 134:2967.
- Li YH, et al:** Efficacy and safety of intense pulsed light in treatment of melasma in Chinese patients. *Dermatol Surg* 2008; 34:693.
- Li Y, et al:** Treatment of melasma with oral administration of compound tranexamic acid: a preliminary clinical trial. *J Eur Acad Dermatol Venereol* 2014; 28:388.
- Makino ET, et al:** Clinical efficacy and safety of a multimodality skin brightener composition compared with 4% hydroquinone. *J Drugs Dermatol* 2013; 12:s21.
- Malek J, et al:** Successful treatment of hydroquinone-resistant melasma using topical methimazole. *Dermatol Ther* 2013; 26:69.
- Passeron T:** Long-lasting effect of vascular targeted therapy of melasma. *J Am Acad Dermatol* 2013; 69:e141.
- Pichardo R, et al:** Prevalence of melasma and its association with quality of life among adult male migrant Latino workers. *Int J Dermatol* 2009; 48:22.
- Rendon MI:** Utilizing combination therapy to optimize melasma outcomes. *J Drugs Dermatol* 2004; 3:S27.
- Rivas S, Pandya AG:** Treatment of melasma with topical agents, peels and lasers: an evidence-based review. *Am J Clin Dermatol* 2013; 14:359.
- Sardana K, Garg VK:** Lasers are not effective for melasma in darkly pigmented skin. *J Cutan Aesthet Surg* 2014; 7:57.
- Sardana K, et al:** Which therapy works for melasma in pigmented skin: lasers, peels or triple combination creams. *Indian J Dermatol Venereol Leprol* 2013; 79:420.
- Tse TW, et al:** Tranexamic acid: an important adjuvant in the treatment of melasma. *J Cosmet Dermatol* 2012; 12:57.

## RETICULATE PIGMENT DISORDERS OF THE SKIN

This group of disorders is linked by similar clinical features: reticulate pigmentation of various skin sites and characteristic histology – adenoid pigmented proliferations of the rete ridges of the interfollicular and infundibular follicular epidermis, at times with focal acantholysis. Patients may have overlapping features of several different syndromes, making specific classification of an individual patient or family difficult.

### Dyschromatosis symmetrica hereditaria (reticulate acropigmentation of Dohi)

Originally described and still reported primarily in the Japanese, acropigmentation of Dohi has been found to affect individuals from Europe, India, and the Caribbean region. It is also referred to as dyschromatosis symmetrica hereditaria (DSH) or symmetric dyschromatosis of the extremities. It is inherited most often as an autosomal dominant trait, although autosomal recessive kindreds have been reported. Patients develop progressive hyperpigmented and hypopigmented macules, often mixed in a reticulate pattern, concentrated on the dorsal extremities, especially the dorsal hands and feet. The lesions vary in size from pinpoint to pea sized. Frecklelike macules

can present on the face. Long hair on the forearms, hypo/hyperpigmented hair, acral hypertrophy, and dental abnormalities also have been reported. Lesions appear in infancy or early childhood and usually stop spreading before adolescence. The pigmentary lesions last for life. The autosomal dominant form of DSH is caused by a mutation in the *DSRAD* (*ADAR1*) gene, which encodes a double-stranded RNA-specific adenosine deaminase, an RNA-editing enzyme.

- Kantaputra PN, et al:** Dyschromatosis symmetrica hereditaria with long hair on the forearms, hypo/hyperpigmented hair, and dental anomalies: report of a novel *ADAR1* mutation. *Am J Med Genet A* 2012; 158:2258.
- Liu Y, et al:** Two novel frameshift mutations of the *DSRAD* gene in Chinese pedigrees with dyschromatosis symmetrica hereditaria. *Int J Dermatol* 2012; 51:920.
- Mohana D, et al:** Reticulate acropigmentation of Dohi: a case report with insight into genodermatoses with mottled pigmentation. *Indian J Dermatol* 2012; 57:42.
- Murata T, et al:** Dyschromatosis symmetrica hereditaria with acra hypertrophy. *Eur J Dermatol* 2011; 21:649.
- Obieta MP:** Familial reticulate acropigmentation of Doji: a case report. *Dermatol Online J* 2006; 12:16.
- Shi BJ, et al:** First report of the coexistence of dyschromatosis symmetrica hereditaria and psoriasis: one novel TCT to A mutation in the double-RNA-specific adenosine deaminase gene. *J Eur Acad Dermatol Venereol* 2012; 26:657.
- Zhu CY, et al:** A novel insertion mutation in the *ADAR1* gene of a Chinese family with dyschromatosis symmetrica hereditaria. *Genet Mol Res* 2013; 12:2858.

### Dowling-Degos disease (reticular pigmented anomaly of flexures)

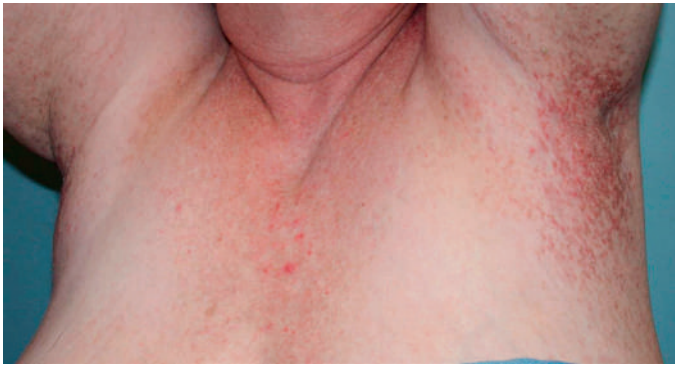Reticular pigmented anomaly of the flexures is a rare autosomal dominant pigmentary disorder; it is now more often called Dowling-Degos disease (DDD). Pigmentation usually appears at puberty or in early adolescence but may present later in adulthood. The skin lesions primarily affect the intertriginous areas, such as the axillae, neck, genitalia, and inframammary/sternal areas. In some cases, the dorsal hands are involved. The pigmentation is reticular; at the periphery, discrete, brownish black macules surround the partly confluent, central pigmented area. In more mildly affected patients, the pigmentation is dappled. The pigmentation progresses very gradually. There are frequently acneiform, pitted scars, sometimes pigmented, around the mouth. Comedonal and cystic lesions have been described on the flexures and in the axillae. Hidradenitis suppurativa-like lesions in the groin and axilla may occur. A follicular variant of DDD has been reported. Patients may complain that the condition is worse during hot weather. Squamous cell carcinoma of the buttocks or perianal area has been described.

Histologically, in addition to the typical lentiginous adenoid proliferations of the rete ridges, small horn cysts may be present, so that the pattern resembles that of a reticulated seborrheic keratosis. Comedones may be present. Classic autosomal dominant Dowling-Degos disease is caused by mutations in the keratin 5 gene (*KRT5*). Similar mutations occur in Galli-Galli disease, suggesting that the two conditions represent variants of the same disorder rather than separate diseases. In DDD patients who lack mutation in *KRT5*, mutations have been found in *POGLUT1* and *POFUT1*, both of which are essential regulators of Notch activity. Cases of DDD associated with these gene mutations can have widespread cutaneous lesions.

### Galli-Galli disease

Galli-Galli disease is now recognized as an acantholytic variant of Dowling-Degos disease, also caused by mutations in the





**Fig. 36-4** Galli-Galli disease.

keratin 5 gene. The skin lesions are 1–2 mm, slightly keratotic, red to dark-brown papules, which are focally confluent in a reticulate pattern (Fig. 36-4). The skin lesions favor skinfolds, although other skin sites may also be involved. The neck, axillae, upper extremities, dorsal hands, trunk, groin, and even the scrotum and lower extremities may be affected. Histologically, there is prominent digitate downgrowth of the rete ridges, identical to that seen in DDD. The characteristic histologic feature is a suprabasilar cleft and suprapapillary thinning of the epidermis. There is no dyskeratosis, as seen in Grover's disease. Ablative laser treatment led to axillary symptom resolution in one patient.

**Arnold AW, et al:** Type 1 segmental Galli-Galli disease resulting from a previously unreported keratin 5 mutation. *J Invest Dermatol* 2012; 132:2100.

**Basmanav FB, et al:** Mutations on *POGLUT1*, encoding protein O-glucosyltransferase 1, cause autosomal-dominant Dowling-Degos disease. *Am J Hum Genet* 2014; 94:135.

**Gomes J, et al:** Galli-Galli disease: a rare acantholytic variant of Dowling-Degos disease. *Case Rep Med* 2011; 2011:703257.

**Guo L, et al:** A novel heterozygous nonsense mutation of keratin 5 in a Chinese family with Dowling-Degos disease. *J Eur Acad Dermatol Venereol* 2012; 26:908.

**Hanneken S, et al:** Systematic mutation screening of *KRT5* supports the hypothesis that Galli-Galli disease is a variant of Dowling-Degos disease. *Br J Dermatol* 2010; 163:197.

**Horner ME, et al:** Dowling-Degos disease involving the vulva and back: case report and review of the literature. *Dermatol Online J* 2011; 17:1.

**Kang HS, et al:** A case of Dowling-Degos disease on the vulva. *Ann Dermatol* 2011; 23:205.

**Li M, et al:** Mutations in *POFUT1*, encoding protein O-fucosyltransferase 1, cause generalized Dowling-Degos disease. *Am J Human Genet* 2013; 92:895.

**Muller CS, et al:** The spectrum of reticulate pigment disorders of the skin revisited. *Eur J Dermatol* 2012; 22:596.

**Pickup TL, Mutasim DF:** Dowling-Degos disease presenting as hypopigmented macules. *J Am Acad Dermatol* 2011; 64:1224.

**Reisenauer AK, et al:** Heterozygous frameshift mutation in keratin 5 in a family with Galli-Galli disease. *Br J Dermatol* 2014; 170:1362.

**Schmieder A, et al:** Galli-Galli disease is an acantholytic variant of Dowling-Degos disease: additional genetic information in a German family. *J Am Acad Dermatol* 2012; 66:e250.

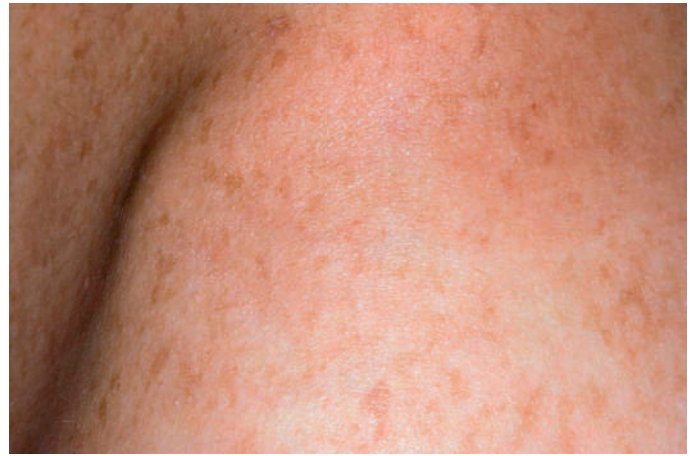**Singh S, et al:** Follicular Dowling-Degos disease: a rare variant of an evolving dermatosis. *Indian J Dermatol Venereol Leprol* 2013; 79:802.

**Taskapan O, et al:** Dowling-Degos disease with diffuse penile pigmentation. *J Eur Acad Dermatol Venereol* 2014; 28:1405.

**Voth H, et al:** Efficacy of ablative laser treatment in Galli-Galli disease. *Arch Dermatol* 2011; 147:317.

### Reticulate acropigmentation of Kitamura

Reticulate acropigmentation of Kitamura (RPK) is a rare autosomal dominant disease that initially was recognized in Japan but now has been seen in many countries, usually in persons



**Fig. 36-5** Dermatopathia pigmentosa reticularis.

of color. The characteristic presentation is pigmented, angulated, irregular, frecklelike lesions with atrophy, arranged in a reticulate pattern on the dorsal feet and hands. Lesions start in the first to second decade of life, gradually progress, and slowly darken over time. The axillae and groin may be affected, as can the skin of the trunk and more proximal extremities. Linear irregular breaks in the dermatoglyphics of the palms are characteristic and help to distinguish this disorder from the other "reticulate flexural anomalies." Patients with mixed features of DDD and RPK have been reported. RPK is caused by a loss-of-function mutation in *ADAM10*, the gene product of which is involved in ectodomain shedding of adhesion molecules.

**Koguchi H, et al:** Characteristic findings of handprint and dermoscopy in reticulate acropigmentation of Kitamura. *Clin Exp Dermatol* 2014; 39:58.

**Kono M, et al:** Whole-exome sequencing identifies *ADAM10* mutations as a cause of reticulate acropigmentation of Kitamura, a clinical entity distinct from Dowling-Degos disease. *Hum Mol Genet* 2013; 22:3524.

### DERMATOPATHIA PIGMENTOSA RETICULARIS

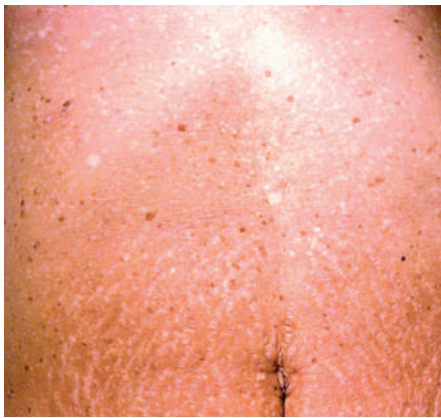
Dermatopathia pigmentosa reticularis (DPR) is an extremely rare dominant ectodermal dysplasia characterized by the triad of generalized reticulate hyperpigmentation (Fig. 36-5), noncicatricial alopecia, and onychodystrophy. Additional associations include loss of dermatoglyphics, hypo/hyperhidrosis, pigmented lesions of the oral mucosa, palmoplantar hyperkeratosis, and nonscarring blisters on the dorsa of the hands and feet. Wiry scalp hair and digital fibromatosis have also been reported. Dental anomalies are not a feature of DPR. Some members of families affected by Naegeli-Franceschetti-Jadassohn syndrome (NFJS) have clinical features identical to DPR. Both NFJS and DPR are caused by mutations in the keratin 14 gene.

**Goh BK, et al:** A case of dermatopathia pigmentosa reticularis with wiry scalp hair and digital fibromatosis resulting from a recurrent *KRT14* mutation. *Clin Exp Dermatol* 2009; 34:340.

**Lugassy J, et al:** Naegeli-Franceschetti-Jadassohn syndrome and dermatopathia pigmentosa reticularis: two allelic ectodermal dysplasias caused by dominant mutations in *KRT14*. *Am J Hum Genet* 2006; 79:724.

**Shanker V, Gupta M:** Dermatopathia pigmentosa reticularis: a rare reticulate pigmentary disorder. *Indian Dermatol Online J* 2013; 4:40.

**Van Steensel MA, Lemmink HH:** A missense mutation in *KRT14* causing a dermatopathia pigmentosa reticularis/Naegeli-Franceschetti-Jadassohn phenotype. *J Eur Acad Dermatol Venereol* 2010; 24:1116.



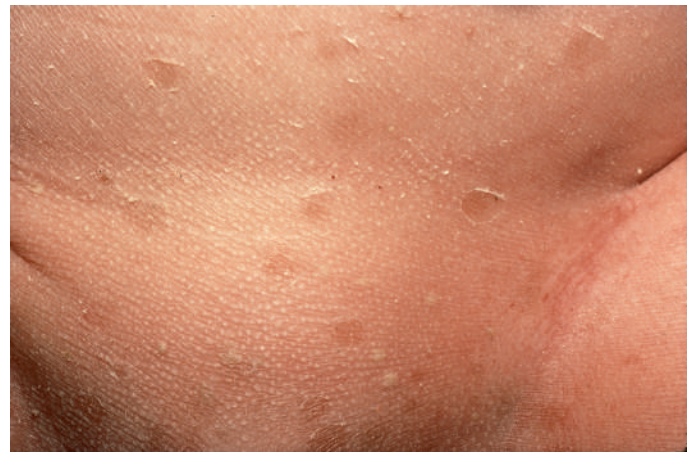
**Fig. 36-6**  
Dyschromatosis  
universalis hereditaria.

### Dyschromatosis universalis hereditaria, familial progressive hyperpigmentation and hypopigmentation

Dyschromatosis universalis hereditaria (DUH) is a rare autosomal dominant genodermatosis characterized by asymptomatic hyperpigmented and hypopigmented macules in a generalized distribution (Fig. 36-6) on the trunk and limbs and sometimes the face. Lesions are irregular in size and shape and appear in infancy or childhood, often in the first few months of life. The palms, soles, and mucous membranes are usually spared. Most DUH patients do not show other symptoms and are otherwise well. Infrequently reported associations include ocular and auditory abnormalities, photosensitivity, developmental delay, and short stature. Histologically, there are normal numbers of melanocytes in both the lighter and the darker skin, but more melanized, mature melanosomes in the darker areas and empty, immature melanosomes in the hypopigmented areas. A mutation in the *ABCB6* gene (mitochondrial porphyrin transporter localized to outer membrane of mitochondria) has been identified in numerous cases of autosomal dominant DUH (DUH-1). The wild-type protein localizes to the dendrites of melanocytes and is probably involved in melanosome transport. The mutant protein remains in the Golgi complex, which could disrupt melanosome transport.

A much rarer variant of DUH is DUH-2, which is inherited as an autosomal recessive genodermatosis, with a putative gene location on chromosome 12. Familial progressive hyperpigmentation (FPH) is an autosomal dominant genodermatosis characterized by hyperpigmented patches presenting in early infancy and progressing with age. Hypopigmented lesions are absent, distinguishing it from DUH-2, which FPH otherwise closely resembles. Familial progressive hyperpigmentation and hypopigmentation (FPHH) is an autosomal dominant disorder characterized by diffuse, partly blotchy hyperpigmentation, hyperpigmented macules, café au lait macules, and larger hypopigmented ash-leaf macules on the face, neck, trunk, and limbs present at birth or early in infancy. Lesions increase in size and number with age. FPHH and FPH have also been associated with mutations in the same region of chromosome 12 as DUH-2, mapping to the gene *KITLG* (also known as steel factor or mast cell growth factor/stem cell factor), which codes for the ligand of c-KIT. The mutations in FPHH and FPH are gain-of-function mutations.

**Amyere M, et al:** *KITLG* mutations cause familial progressive hyper- and hypopigmentation. *J Invest Dermatol* 2011; 133:1234.



**Fig. 36-7** Transient neonatal pustulosis.

**Cui YX, et al:** Novel mutations of *ABCB6* associated with autosomal dominant dyschromatosis universalis hereditaria. *PLoS One* 2013; 8:e79808.

**Kumir S, et al:** Dyschromatosis universalis hereditaria: a rare entity. *Dermatol Online J* 2011; 17:6.

**Liu H, et al:** Genome-wide linkage, exome sequencing and functional analyses identify *ABCB6* as the pathogenic gene of dyschromatosis universalis hereditaria. *PLoS One* 2014; 9:e87250.

**Nogita T, et al:** Removal of facial and labial lentiginos in dyschromatosis universalis hereditaria with a Q-switched alexandrite laser. *J Am Acad Dermatol* 2011; 65:e61.

**Reddy SG, Worobec SM:** Dyschromatosis universalis hereditaria in an African American male. *Dermatol Online J* 2011; 17:3.

**Udayashankar C, Nath AK:** Dyschromatosis universalis hereditaria: a case report. *Dermatol Online J* 2011; 17:2.

**Zhang C, et al:** Mutations in *ABCB6* cause dyschromatosis universalis hereditaria. *J Invest Dermatol* 2013; 133:2221.

### TRANSIENT NEONATAL PUSTULAR MELANOSIS

Also called transient neonatal pustulosis, this disorder is present at birth. Newborns present with 1–3 mm, flaccid, superficial fragile pustules (Fig. 36-7). Some of the pustules may have already resolved in utero, leaving pigmented macules. Lesions affect the chin, neck, forehead, back, and buttocks, but can occur anywhere. Delayed appearance into the second or third week of life is rarely reported, as are numerous lesions and lesions up to 1 cm in diameter. In dark-skinned infants, pigmented macules may persist for weeks or months after the pustules have healed. Transient neonatal pustular melanosis is observed in 4.4% of black and 0.6% of white newborns and may be more common after vaginal than cesarean delivery.

Histologically, there are intracorneal or subcorneal aggregates, predominantly of neutrophils, although eosinophils may also be found. Dermal inflammation is composed of a mix of neutrophils and eosinophils. The differential diagnosis includes erythema toxicum neonatorum, neonatal acne, and acropustulosis of infancy.

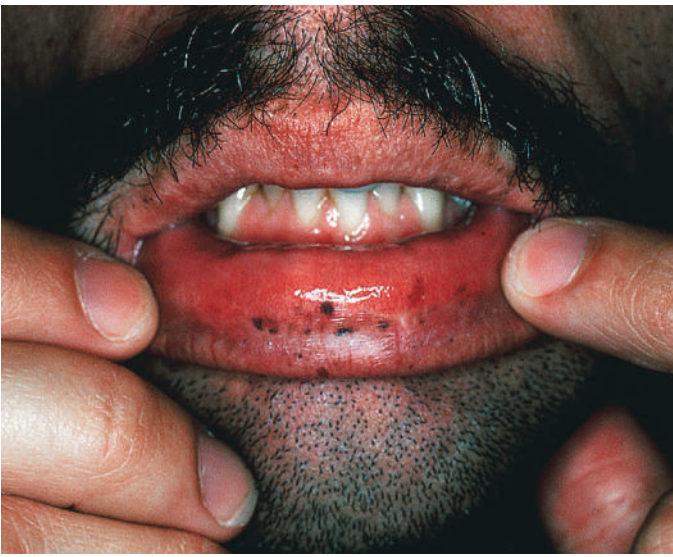**Brazzelli V, et al:** An unusual case of transient neonatal pustular melanosis: a diagnostic puzzle. *Eur J Pediatr* 2014; 173:1655.

**Chia PS, et al:** An infant with transient neonatal pustular melanosis presenting as pustules. *Pediatr Neonatal* 2010; 51:356.

**Ekiz O, et al:** Skin findings in newborns and their relationship with maternal factors: observational research. *Ann Dermatol* 2013; 25:1.

**Paloni G, Cutrone M:** Giant transient pustular melanosis in an infant. *Arch Dis Child Fetal Neonatal Ed* 2013; 98:F492.





**Fig. 36-8** Peutz-Jeghers syndrome, macular pigmentation of lower lip.

### PEUTZ-JEGHERS SYNDROME

Peutz-Jeghers syndrome (PJS) is characterized by hyperpigmented macules on the lips and oral mucosa, polyposis of the gastrointestinal (GI) tract, and greatly increased cancer risk. The dark-brown or black macules appear typically on the lips, especially the lower lip, in infancy or early childhood (Fig. 36-8). Similar lesions may appear on the buccal mucosa, tongue, gingiva, and the perianal mucosa; macules may also occur around the mouth, on the central face, and on the backs of the hands, especially the fingers, toes, and tops of the feet. More than two thirds of patients have lesions on the hands and feet, and 95% have perioral lesions. Skin lesions grow in size and number until puberty, after which they begin to regress. Buccal pigmented macules tend to persist. Similar pigmentation may be seen in the bowel.

The diagnosis of PJS is made with any of four major criteria: (1) two or more histologically confirmed PJS polyps; (2) any number of PJS polyps and a family history of PJS; (3) characteristic mucocutaneous pigmentation and a family history of PJS; or (4) any number of PJS polyps and characteristic mucocutaneous pigmentation. In 94% of patients who fulfill these criteria, a mutation in the *STK11* gene will be found. Almost half of patients are “new” mutations, with no family history of PJS.

The associated polyps, which are histologically characteristic, involve the small intestine by preference (64%), but hamartomatous polyps may also occur in the stomach (49%), colon (49%), and rectum (32%). The polyposis of the small intestine may cause repeated bouts of abdominal pain and vomiting. Bleeding is common; intussusception is frequent (47%). Boys with PJS often have evidence of estrogen excess with gynecostia and advanced bone age.

Patients with PJS have a 10-fold to 18-fold greater lifetime cancer risk (81–94%) than the general population. The greatest risk is for GI malignancy, which is increased 130-fold in PJS patients. These cancers occur in the colon (39% of patients), stomach (29%), and small intestine (13%). Cancers begin to appear about age 30 years. Cancers also occur in extraintestinal sites, especially the breast, genitourinary (GU) tract, and pancreas (100-fold increase in PJS patients). The prevalence of cancers by anatomic site is pancreas (26%), breast (54%, can be bilateral), and ovary (21%). Sertoli-Leydig cell stromal tumors occur in 9% of PJS males, and sex cord tumors with annular

tubules can occur in female PJS patients. Given the high risk of cancer in PJS patients, standard screening protocols have been recommended. Since 40% of patients develop significant GI and potentially GU complications by age 6 years, GI screening may need to begin as early as age 4 or 5, with testicular examination in males with PJS. The syndrome is transmitted as a simple mendelian dominant trait, caused in the majority of patients by a germline mutation of the *STK11/LKB1* tumor suppressor gene on chromosome 19p13. The gene product is a serine-threonine kinase involved in signal transduction in the mTOR pathway. Patients have one inactive copy of this gene. Patients with truncation of the gene rather than a missense mutation are more severely affected, suggesting a phenotype/genotype correlation. In Chinese PJS patients, mutations in *OR4C45*, *ZAN*, pre-microRNAs, and other genes have been identified, suggesting that multiple different genes can cause this syndrome.

Laugier-Hunziker syndrome, Carney syndrome, and Cronkhite-Canada syndrome should be considered in the differential diagnosis of PJS. Laugier-Hunziker syndrome presents with mucosal pigmentation and pigmented nail streaks. Cronkhite-Canada syndrome consists of melanotic macules on the fingers and GI polyposis, as well as generalized, uniform darkening of the skin, extensive alopecia, and onychodystrophy. The polyps that occur are usually benign adenomas and may involve the entire GI tract. A protein-losing enteropathy may develop and is associated with the degree of intestinal polyposis. Onset is typically after age 30 in this sporadically occurring, generally benign condition. Hypogeusia is the dominant initial symptom, followed by diarrhea and ectodermal changes. About 75% of all cases have been reported from Japan. Zinc therapy may improve the hypogeusia and other symptoms. Carney syndrome patients may also develop Sertoli cell tumors and gynecomastia, which in combination with their mucocutaneous pigmentation, may lead to an erroneous diagnosis of PJS.

**Banno K, et al:** Hereditary gynecological tumors associated with Peutz-Jeghers syndrome (review). *Oncol Lett* 2013; 6:1184.

**Borun P, et al:** High resolution melting analysis as a rapid and efficient method of screening for small mutations in the *STK11* gene in patients with Peutz-Jeghers syndrome. *BMC Med Genet* 2013; 14:58.

**Campos-Munoz L, et al:** Dermoscopy of Peutz-Jeghers syndrome. *J Eur Acad Dermatol Venereol* 2009; 23:730.

**Goldstein SA, Hoffenberg EJ:** Peutz-Jegher syndrome in childhood: need for updated recommendations? *J Pediatr Gastroenterol Nutr* 2013; 56:191.

**Ham S, et al:** Overexpression of aromatase associated with loss of heterozygosity of the *STK11* gene accounts for prepubertal gynecomastia in boys with Peutz-Jeghers syndrome. *J Clin Endocrinol Metab* 2013; 98:E1979.

**Heymann WR:** Peutz-Jeghers syndrome. *J Am Acad Dermatol* 2007; 57:513.

**Jelsig AM, et al:** Hamartomatous polyposis syndromes: a review. *Orphanet J Rare Dis* 2014; 9:101.

**Korsse SE, et al:** Pancreatic cancer risk in Peutz-Jeghers syndrome patients: a large cohort study and implications for surveillance. *J Med Genet* 2013; 50:59.

**Resta N, et al:** Cancer risk associated with *STK11/LKB1* germline mutations in Peutz-Jeghers syndrome patients: results of an Italian multicenter study. *Dig Liv Dis* 2013; 45:606.

**Richey JD, et al:** Carney syndrome in a patient previously considered to have Peutz-Jeghers syndrome. *J Am Acad Dermatol* 2014; 70:e44.

**Shah KR, et al:** Cutaneous manifestations of gastrointestinal disease. Part I. *J Am Acad Dermatol* 2013; 68:189.e1.

**Tsai HL, et al:** Rectal carcinoma in a young female patient with Peutz-Jeghers syndrome: a case report. *Med Princ Pract* 2014; 23:89.

**Wang HH, et al:** Exome sequencing revealed novel germline mutations in Chinese Peutz-Jeghers syndrome patients. *Dig Dis Sci* 2014; 59:64.

**Wangler MF, et al:** Unusually early presentation of small-bowel adenocarcinoma in a patient with Peutz-Jeghers syndrome. *J Pediatr Hematol Oncol* 2013; 35:323.

## METALLIC DISCOLORATIONS

Pigmentation may develop from the deposit of fine metallic particles in the skin. The metal may be carried to the skin by the bloodstream or may permeate into it from surface applications. Discolorations from medications containing silver and gold are discussed in Chapter 6.

### Arsenic

Acute arsenic poisoning is associated with flushing on day 1 of exposure and facial edema on days 2–5. A morbilliform eruption appears on days 4–6. Hepatic dysfunction occurs simultaneously with the appearance of an eruption of discrete red-brown, erythematous papules in the intertriginous areas (areas of friction) of the lower abdomen, buttocks, and lateral upper chest. It regresses after 2–3 weeks, at times accompanied by acral desquamation. Three months after exposure, Mees' lines, total leukonychia, Beau's lines, and onychodystrophy may be seen. Periungual pigmentation occurs in up to half of acutely poisoned patients at 3 months.

Arsenic is an elemental metal that is ubiquitous, existing in nature as metalloids, alloys, and a variety of chemical compounds. These various forms of arsenic may be deposited into water, soil, and vegetation, producing serious health risks. Certain regions of Pakistan, India (West Bengal and Eastern India), Mongolia, China, Cambodia, and Vietnam have high levels of arsenic in their drinking water, exposing millions of people to levels of arsenic that result in health consequences. Numerous cases of arsenic-induced skin lesions have occurred. In areas of exposure, even young children can demonstrate cutaneous stigmata. Skin lesions usually occur only when arsenic concentrations in drinking water are 50 µg/L or more.

Two characteristic forms of skin disease occur. Cutaneous hyperpigmentation is the most common and earliest side effect. The hyperpigmentation is usually diffuse, most prominent on the trunk. Patchy hyperpigmentation may be accentuated in the inguinal folds, on the areolae, and on palmar creases. This can simulate Addison's disease. Areas of hypopigmentation may be scattered in the hyperpigmented areas, giving a "raindrop" appearance. Focal melanotic macules may also be present. The pigmentation may resolve or persist indefinitely. Punctate keratoses on the palms and soles are characteristic. Diffuse palmoplantar keratoderma may rarely occur. Blackfoot disease—arsenic-induced peripheral vascular disease that can lead to vasospasm and peripheral gangrene—and a severe peripheral neuropathy can also occur with chronic arsenic ingestion.

Risk factors for development of clinically evident arsenic-induced disease include concentration of arsenic contamination in exposure source (usually water) and malnutrition with low body mass index (BMI). There is significant variation in prevalence of skin disease from arsenic exposure among different racial groups and individuals. Evidence indicates that polymorphisms in arsenic-metabolizing (methylation) pathways, specifically converting monomethylarsonic acid to dimethylarsinic acid, may explain these risk differences. Arsenic exposure is also associated with a significant reduction in circulating helper T cells, perhaps contributing to increased cancer risk. One study identified polymorphisms in the *XPD* gene as a risk factor for arsenic-induced skin lesions. Histologically, the arsenical keratosis on the palms and soles shows hyperkeratosis, parakeratosis, acanthosis, and papillomatosis. Approximately 6–7% of hyperkeratotic skin lesions will demonstrate basilar atypia, and about 1% will show cancer. Arsenic exposure leads to the development of nonmelanoma skin

cancers. Bowen's disease represents the majority of arsenic-induced skin cancers and may appear on sun-exposed or sun-protected skin. Basal cell carcinomas are frequent, are usually multiple, are most common on the trunk, and can be in sun-protected sites. Squamous cell carcinoma may also occur. Acitretin may improve "arsenical" keratoses. Arsenic exposure results in increased risk for lung, liver, and renal carcinoma.

**Agusa T, et al:** Exposure, metabolism, and health effects of arsenic in residents from arsenic-contaminated groundwater areas of Vietnam and Cambodia: a review. *Rev Environ Health* 2010; 25:193.

**Elmariah SB, et al:** Invasive squamous-cell carcinoma and arsenical keratoses. *Dermatol Online J* 2008; 14:24.

**Fatmi Z, et al:** Burden of skin lesions of arsenicosis at higher exposure through groundwater of Taluka Gambat district Khairpur, Pakistan: a cross-sectional survey. *Environ Geochem Health* 2013; 35:341.

**Li X, et al:** Arsenic methylation capacity and its correlation with skin lesions induced by contaminated drinking water consumption in residents of chronic arsenicosis area. *Environ Toxicol* 2011; 26:118.

**Liao WT, et al:** Differential effects of arsenic on cutaneous and systemic immunity: focusing on CD4+ cell apoptosis in patients with arsenic-induced Bowen's disease. *Carcinogenesis* 2009; 30:1064.

**Lin GF, et al:** Association of XPD/ERCC2 G23591A and A35931C polymorphisms with skin lesion prevalence in a multiethnic, arseniasis-hyperendemic village exposed to indoor combustion of high arsenic coal. *Arch Toxicol* 2010; 84:17.

**Maiti S, et al:** Antioxidant and metabolic impairment result in DNA damage in arsenic-exposed individuals with severe dermatological manifestations in Eastern India. *Environ Toxicol* 2012; 27:342.

**Majumdar KK, Guha Mazumder DN:** Effect of drinking arsenic-contaminated water in children. *Indian J Public Health* 2012; 56:223.

**Park JY, et al:** Metallic discoloration on the right shin caused by titanium alloy prostheses in a patient with right total knee replacement. *Ann Dermatol* 2013; 25:356.

**Pilsner JR, et al:** Folate deficiency, hyperhomocysteinemia, low urinary creatinine, and hypomethylation of leukocyte DNA are risk factors for arsenic-induced skin lesions. *Environ Health Perspect* 2009; 117:254.

**Schuhmacher-Woiz U, et al:** Oral exposure to inorganic arsenic: evaluation of its carcinogenic and non-carcinogenic effects. *Crit Rev Toxicol* 2009; 39:271.

**Sengupta SR, et al:** Pathogenesis, clinical features and pathology of chronic arsenicosis. *Indian J Dermatol Venereol Leprol* 2008; 74:559.

**Watson K, Creamer D:** Arsenic-induced keratoses and Bowen's disease. *Clin Exp Dermatol* 2004; 29:46.

**Xia Y, et al:** Well water arsenic exposure, arsenic-induced skin lesions and self-reported morbidity in Inner Mongolia. *Int J Environ Res Public Health* 2009; 6:1010.

### Lead

Chronic lead poisoning can produce a "lead hue," with lividity and pallor, and a deposit of lead in the gums may occur: the "lead line."

### Iron

In the past, soluble iron compounds were used in the treatment of allergic contact and other dermatitides. In eroded areas, iron was sometimes deposited in the skin, like a tattoo. The use of Monsel solution can produce similar tattooing, so aluminum chloride is now preferred. If Monsel is used, to minimize tattooing, it is best applied with a cotton-tipped applicator barely moistened with the solution, then rolled across a wound that has just been blotted dry.

### Hemochromatosis

Hemochromatosis is a disorder caused by mutations in at least five different genes involved in iron absorption. It is very common in the white European population, in whom most



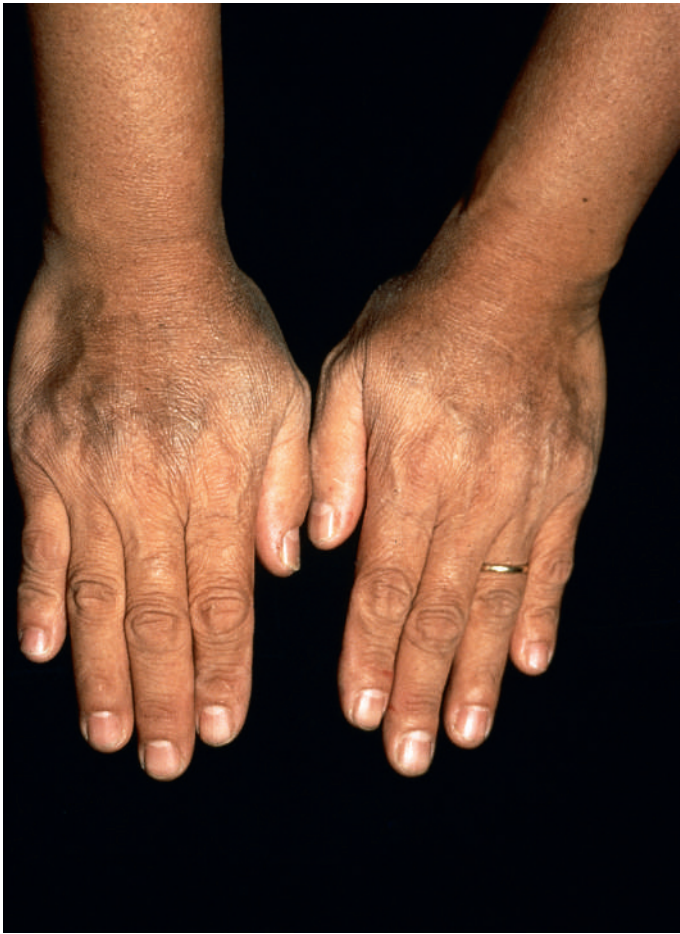

Fig. 36-9 Hemochromatosis.

mutations are at two genetic loci, C282Y and H63D in the *HFE* gene. Only a minority of persons with the most common genetic defects causing hemochromatosis will develop disease, perhaps 25% of men and 6% of women. Men are affected more frequently and at an earlier age, usually 30–50. With widespread genetic testing, the age of diagnosis has been decreased, and the number of asymptomatic affected females has dramatically increased. The characteristic cutaneous manifestation is gray to brown mucocutaneous hyperpigmentation. This is enhanced in sun-exposed areas of the forearms, dorsal hands (Fig. 36-9), and face, as well as in the inguinal area. The mucous membranes are pigmented in up to 20% of patients. The percentage of affected males with pigmentation is about 30%, and in women, fewer than 10% of diagnosed patients have skin changes. Other skin changes can include koilonychia and localized ichthyosis. Alopecia is common, and pruritus can occur. Porphyria cutanea tarda may result from inhibition of uroporphyrinogen decarboxylase in the liver by iron overload. In patients with chronic venous insufficiency, the risk of lower leg ulceration is increased sixfold in those also carrying the C282Y mutation, leading some to suggest that this test should be ordered in at-risk patients at the initial stages of venous insufficiency. Biopsy of affected hyperpigmented skin shows dermal iron deposition, but the visible pigmentation is actually increased epidermal melanin in the basal cell layer.

The most seriously affected organ is the liver. Hepatomegaly and elevated liver function tests (LFTs) are signs of hepatic iron overload. Cirrhosis and hepatocellular carcinoma may develop, but are now less common with early diagnosis and treatment. The endocrine system is also affected, with hypogonadism the primary complaint. The association of

diabetes mellitus (DM) with hemochromatosis has been questioned. Few patients diagnosed in the 21st century have associated DM, and those who do have a positive family history of diabetes independent of the hemochromatosis, suggesting that development of DM in patients with hemochromatosis is caused by other genetic and environmental factors, and not iron overload. Arthropathy is seen in about 50% of women and 40% of men. Cardiac abnormalities include heart failure and arrhythmias. Consuming alcohol and smoking, as well as coexistent hepatitis C virus (HCV) infection, make it more likely that persons with genetic predisposition will develop clinical disease.

Laboratory evaluation should be pursued in persons with appropriate clinical findings suggesting the diagnosis of hemochromatosis. Levels of plasma iron and the serum iron-binding protein are elevated. The transferrin saturation (TS = serum iron/total iron-binding capacity) is a useful screening measure. A score of 45 or less is normal, except in premenopausal women, in whom greater than 35 may be considered abnormal. High serum ferritin levels are also present. Genotyping is now performed in persons with TS greater than 45 and elevated ferritin level, and confirms the diagnosis. Liver biopsy is reserved for persons with elevated LFTs, ferritin greater than 1000  $\mu\text{g/L}$ , or age over 40.

Four different genes cause autosomal recessive hemochromatosis, and one causes autosomal dominant disease. The most common autosomal recessive form is caused by a mutation in the *HFE* gene, most frequently C282Y (80%), and less often H63D. The incidence of homozygosity for C282Y is 5 in 1000 persons of northern European descent, making it 10 times more common than cystic fibrosis. Compound heterozygotes (C282Y/H63D) also develop disease. Two autosomal recessive forms of juvenile hereditary hemochromatosis are described, caused by mutations in the Hemojuvelin and the Hpcidin gene. Mutations in the transferrin receptor 2 gene lead to a form of autosomal recessive adult-onset hemochromatosis. Ferroportin mutation leads to an adult-onset form of autosomal-dominant hemochromatosis.

All forms of hemochromatosis are treated with phlebotomy until satisfactory iron levels are attained. Vitamin C supplementation must be avoided, because it can worsen the disease. Raw seafood should be avoided because *Vibrio vulnificus* infection may occur. Phlebotomy can prevent cirrhosis. Once cirrhosis is present, phlebotomy does not prevent development of hepatocellular carcinoma, which occurs in 30% of patients.

**Bardou-Jacquet E, Brissot P:** Diagnostic evaluation of hereditary hemochromatosis (HFE and non-HFE). *Hematol Oncol Clin North Am* 2014; 28:625.

**Barton JC:** Hemochromatosis and iron overload: from bench to clinic. *Am J Med Sci* 2013; 346:403.

**Kew MC:** Hepatic iron overload and hepatocellular carcinoma. *Liver Cancer* 2014; 3:31.

**Zamboni P, et al:** Hemochromatosis C282Y gene mutation increases the risk of venous leg ulceration. *J Vasc Surg* 2005; 42:309.

## Titanium

A titanium-containing ointment caused yellowish papules on the penis in a patient. Titanium screws used for orthopedic procedures, if close to the skin, can cause cutaneous blue-black hyperpigmentation. In cases of degeneration of artificial knee joints, periprosthetic black pigment can be seen, resulting from titanium deposition. Rarely, this pigment may migrate to the skin, resulting in dermal blue-gray patches over the shin. Melanin stains are positive, but polarizing foreign material can be seen, and x-ray spectrophotometry reveals titanium in the tissue.



**Fig. 36-10** Idiopathic guttate hypomelanosis.

**Akimoto M, et al:** Metallosis of the skin mimicking malignant skin tumor. *Br J Dermatol* 2003; 149:653.

**Dupre A, et al:** Titanium pigmentation. *Arch Dermatol* 1985; 121:656.

### IDIOPATHIC GUTTATE HYPOMELANOSIS (LEUKOPATHIA SYMMETRICA PROGRESSIVA)

Idiopathic guttate hypomelanosis is a common acquired disorder that affects women more frequently than men. It usually occurs after age 40, and its prevalence increases with age, exceeding 90% in Koreans over age 60. The lesions occur chiefly on the shins (Fig. 36-10) and forearms, suggesting that sun exposure plays a role. Widespread lesions have occurred in patients receiving UV phototherapy. Individual lesions are small (average 2–5 mm), hypopigmented macules. They usually number 10–30, but numerous lesions may occur. A few lesions can occur on the face. The lesions are irregularly shaped and sharply defined, similar to depigmented ephelides. Histologically, there is epidermal atrophy and reduced numbers of hypoactive melanocytes. Skin injury with cryotherapy, phenol, and carbon dioxide (CO<sub>2</sub>) laser can improve the appearance of the lesions. Topical calcineurin inhibitors, by their stimulation of melanocyte migration and activity, can be therapeutic.

**Asawanonda P, et al:** Pimecrolimus for idiopathic guttate hypomelanosis. *J Drugs Dermatol* 2010; 9:238.

**Friedland R, et al:** Idiopathic guttate hypomelanosis–like lesions in patients with mycosis fungoides: a new adverse effect of phototherapy. *J Eur Acad Dermatol Venereol* 2010; 24:1026.

**Kakepis M, et al:** Idiopathic guttate hypomelanosis: an electron microscopy study. *J Eur Acad Dermatol Venereol* 2014; Aug 4. [Epub ahead of print.]

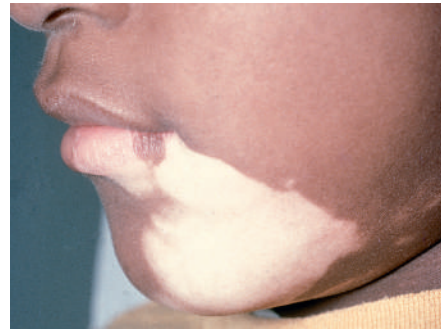**Kim SK, et al:** Comprehensive understanding of idiopathic guttate hypomelanosis: clinical and histopathological correlation. *Int J Dermatol* 2010; 49:162.

**Rerknimitr P, et al:** Topical tacrolimus significantly promotes repigmentation in idiopathic guttate hypomelanosis: a double-blind, randomized, placebo-controlled study. *J Eur Acad Dermatol Venereol* 2013; 27:460.

**Shilpashree P, et al:** Therapeutic wounding: 88% phenol in idiopathic guttate hypomelanosis. *Indian Dermatol Online J* 2014; 5:14.

**Shin MK, et al:** Clinical features of idiopathic guttate hypomelanosis in 646 subjects and association with other aspects of photoaging. *Int J Dermatol* 2011; 50: 798.

**Shin J, et al:** The effect of fractional carbon dioxide lasers on idiopathic guttate hypomelanosis: a preliminary study. *J Eur Acad Dermatol Venereol* 2013; 27:e243.



**Fig. 36-11** Localized vitiligo.

## VITILIGO

Vitiligo usually begins in childhood or young adulthood, with a peak onset between ages 10 and 30. About half of cases begin before age 20. The prevalence ranges from 0.5% to 1% in most countries, but more than 8% in some regions of India. Although females are disproportionately represented among patients seeking care, it is not known whether they are actually more frequently affected or simply more likely to seek medical care. Vitiligo does begin at a younger age in females. Vitiligo has developed in recipients of bone marrow transplant or lymphocyte infusions from patients with vitiligo.

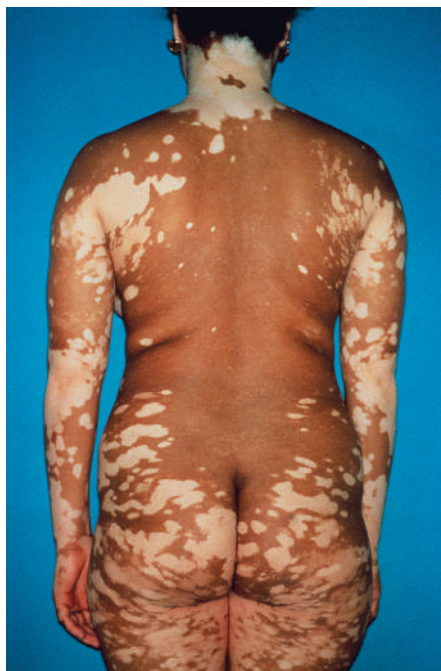### Clinical features

Vitiligo is an acquired pigmentary anomaly of the skin manifested by depigmented white patches surrounded by a normal or a hyperpigmented border. There may be intermediate tan zones or lesions halfway between the normal skin color and depigmentation, so-called trichrome vitiligo. Blue-gray hyperpigmented macules representing melanin incontinence may be present focally. The hairs in the vitiliginous areas usually become white as well. Rarely, the patches may have a red, inflammatory border. The patches are of various sizes and configurations, but the margins are usually smooth and convex, except in segmental vitiligo, which has a much more irregular contour.

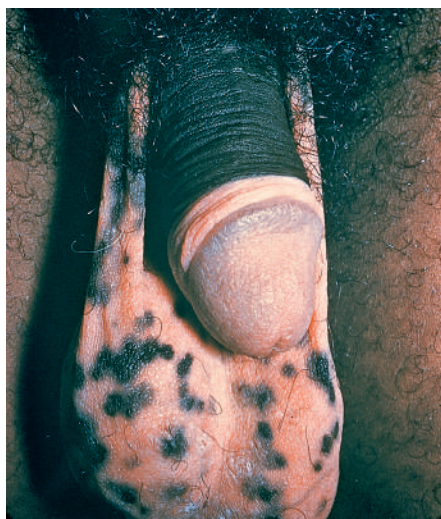Six types of vitiligo have been described, according to the extent and distribution of the involved areas: localized (Fig. 36-11) or focal (single or a few macules in one anatomic area, often the trigeminal area, especially in children); segmental; generalized (common symmetric); universal (Fig. 36-12); acrofacial; and mucosal. The generalized pattern is most common. Involvement is symmetric. The most commonly affected sites are the face, upper part of the chest, dorsal aspects of the hands, axillae, and groin. The skin around orifices tends to be affected: the eyes, nose, mouth, ears, nipples, umbilicus, penis, vulva, and anus. Lesions appear at areas of trauma, so vitiligo favors the elbows and knees. Universal vitiligo applies to cases where the entire body surface is depigmented. The acrofacial type affects the distal fingers and facial orifices (lips and tips). Focal vitiligo may affect one nondermatomal site, such as the glans penis (Fig. 36-13), or asymmetrically affect a single region. Focal vitiligo is to be distinguished from the segmental form of vitiligo, which resists treatment, has an earlier onset, and is less often associated with other autoimmune phenomena. Segmental vitiligo represents 5% of adult and 20% of childhood cases and often has a dermatomal or quasidermatomal distribution.

In patients with vitiligo, local loss of pigment may occur around melanocytic nevi and melanomas, the so-called halo phenomenon. Vitiligo-like leukoderma occurs in about 1% of melanoma patients. In those with previously diagnosed





**Fig. 36-12** Vitiligo, generalized.



**Fig. 36-13** Penile vitiligo.

melanoma, this suggests metastatic disease. Paradoxically, however, because the reaction indicates an autoimmune response against melanocytes, patients who develop it have a better prognosis than patients without leukoderma. Lesions of vitiligo are hypersensitive to UV light and burn readily when exposed to the sun. With repeated sun exposure, lesions of vitiligo can tolerate additional UV exposure (photoadaptation), allowing for increasing doses of therapeutic UV phototherapy.

Ocular abnormalities are increased in patients with vitiligo, including iritis and retinal pigmentary abnormalities. Patients have no visual complaints. Eight percent of patients with idiopathic uveitis have vitiligo or poliosis. The conditions most frequently associated with vitiligo are other “autoimmune” diseases. Autoimmune thyroid disease is the most common autoimmune association and should be screened for in every vitiligo patient. Other autoimmune conditions include type 1 DM, pernicious anemia, Addison’s disease, and alopecia areata. Additional screening should be directed by signs and symptoms. Vitiligo occurs in 13% of patients with the autoimmune polyendocrinopathy-candidiasis-ectodermal dystrophy (APECED) syndrome, caused by mutations in the

autoimmune regulator gene (*AIRE*). Polymorphisms in *AIRE* are found more often in vitiligo patients than controls.

Although familial aggregation of vitiligo is seen – up to 30% of vitiligo patients have an affected relative – it is not inherited as an autosomal dominant or recessive trait, but rather seems to have a multifactorial genetic basis. In addition to the autoimmune pathogenic hypothesis, which is most likely, oxidant/antioxidant and neural theories have been proposed. The psychological effect of vitiligo should not be underestimated. Patients are frequently anxious or depressed because of the appearance of their skin and the way it affects their social interactions. This is true for both children and adults. Determining how the vitiligo psychosocially impacts the patient (if it does) should be documented in the record and could be used as a metric to guide therapy. It is important to treat children who may not be having a psychological complication, since when they become young adults, they frequently develop quality-of-life impairment because of their vitiligo. Referring the patient to a mental health professional or the National Vitiligo Foundation ([www.nvfi.org](http://www.nvfi.org)) may be helpful in this situation.

### Histopathology

There is complete absence of melanocytes. Usually, there is no inflammatory infiltrate, but lichenoid or spongiotic inflammation may be detected at the edge of vitiligo lesions. This explains the scaling or hyperpigmentation sometimes observed around lesions of vitiligo.

### Differential diagnosis

Vitiligo must be differentiated from morphea and lichen sclerosus, both of which are hypopigmented but associated with a change in the skin *texture*. Pityriasis alba has a fine scale, is slightly papular, and is poorly defined. Tinea versicolor favors the center back and chest and has a fine scale; yeast and hyphal forms are demonstrable with potassium hydroxide (KOH) examination. The tertiary stage of pinta might easily lead to diagnostic confusion, but a travel history and serologic testing will help elucidate the diagnosis. Patients with severe chronic actinic dermatitis may develop vitiligo-like depigmentation. Chemical leukoderma may closely resemble vitiligo (see later section).

### Treatment

Vitiligo can be a frustrating condition to treat. Spontaneous repigmentation occurs in no more than 15–25% of cases. Response is typically slow, taking weeks to months to see results. Segmental vitiligo is the least responsive form. Treatment of vitiligo can be approached in two steps: (1) stopping progression and (2) repigmenting the depigmented areas. Many treatments may stop the progression, but fewer lead to durable repigmentation. For rapidly progressive, generalized vitiligo, a short course of systemic corticosteroids can be considered. Because early treatment may result in better response, the duration and stability of the vitiligo should be factored into any treatment decision. Specifically, if one hopes to recruit melanocytes from hair follicles in the affected area, if the hair is still pigmented in the vitiligo-affected skin, the likelihood of response may be higher. Some forms of treatment, such as phototherapy, may actually worsen the appearance of the vitiligo initially by pigmenting surrounding normal skin, accentuating the depigmented areas. This is particularly true in persons of lower Fitzpatrick phototypes (I and II). The

anatomic location of the lesion predicts the likelihood of response and the rate of response, independent of the modality used for therapy. Facial vitiligo has an excellent prognosis, with many patients achieving cosmetically significant improvement. The dorsal hands and feet, by contrast, respond to most forms of treatment only about 10–20% of the time. Truncal vitiligo demonstrates an intermediate response.

The major problem for the vitiligo patient is appearance. For vitiligo in persons of low Fitzpatrick phototypes (I and II) and for long-term, stable vitiligo, nontreatment is an option. These patients are treated with sun protection, supplemented with cosmetic camouflage as required. The newer self-tanning creams are useful for light-skinned and olive-complexioned patients with acral lesions. Phototherapy may more dramatically increase the risk of skin cancer in those with lower Fitzpatrick phototypes, suggesting that alternative approaches should be considered. In addition, mucosal vitiligo (of the lips) and periungual and dorsal hand vitiligo currently have essentially no reproducibly effective form of medical therapy. Camouflage is therefore an important therapeutic modality for the vitiligo patient. Dihydroxyacetone is a brown dye that stains the skin. In lower concentrations, it can be used in persons with lower phototype, since it is a golden or tan color (self-tanning products). In high concentrations, it is dark brown and can be used in patients with type V and VI phototypes to camouflage their lesions. Dihydroxyacetone is a stain, so it does not rub off, but rather needs to be reapplied because it is sloughed off from the epidermis (every 5–10 days). Numerous cosmetic products are available and can be amazingly effective in making the vitiliginous skin blend completely into the normal surrounding skin. However, it is technically difficult for patients to match their skin color without instruction. In the beginning, vitiligo patients using these products will benefit by consulting an aesthetician trained in medical camouflage. Once applied, the products tend to rub off. Application of Cavilon “No Sting Barrier Film” as a spray over the camouflage cosmetic may prevent the product from rubbing off during daily activities.

Topical treatment is appropriate for limited skin areas (<10–20% body surface area [BSA]). Occlusion of all forms of topical therapy may enhance efficacy. Topical potent to superpotent corticosteroids are used for a 2-month trial. Up to 80% of patients with facial vitiligo will achieve more than 90% repigmentation. This usually occurs diffusely, not perifollicularly, as occurs on the trunk. On the trunk, only 40% of patients achieve greater than 90% repigmentation. Treatment should be limited to 4–6 months, and the patient must be monitored for acne, atrophy, and telangiectasias. Although rarely studied, monthly intralesional triamcinolone acetonide, 3 mg/mL, has achieved 80–90% repigmentation in a limited number of patients. The response is reported to be durable and remains after the injections are stopped.

Topical pimecrolimus cream and tacrolimus ointment 0.1% have been particularly efficacious in treating facial vitiligo. In some series, these have been as effective as superpotent topical corticosteroids and avoid the steroid-induced complications of atrophy and acne. Patients who initiate treatment in the summer have a higher rate of response. Continual application may be required; patients who discontinue treatment may develop new lesions. With topical therapies, new areas of vitiligo appear in untreated areas, suggesting there is no systemic effect. Topical pimecrolimus may enhance the efficacy of narrow-band (NB) UVB in repigmenting facial, but not other, vitiligo. Topical calcipotriene and other vitamin D analogs have had variable results. Alone, these agents lack efficacy. When they are used in combination with other treatments, some studies have demonstrated additive benefit and others no benefit. Therefore, these agents cannot be recommended.

Use of NB-UVB two to three times weekly has become the preferred form of phototherapy to treat vitiligo. It avoids the need for prolonged eye protection and the occasional psoralen-induced nausea associated with PUVA. About half of patients will achieve more than 75% repigmentation of the face, trunk, proximal arms, and legs. Hand and foot lesions repigment in less than 25% of patients. Children may have slightly higher response rates than adults. In patients with greater than 20% BSA involvement, only about 5% will show complete repigmentation with phototherapy. Long courses of treatment may be required. PUVA therapy can also be used to treat vitiligo but is less effective than NB-UVB. Repigmentation from phototherapy may begin after 15–25 treatments; however, significant improvement may take as many as 100–200 treatments (6–24 months). On average, maximum improvement is seen after about 9 months of therapy. If follicular repigmentation has not appeared after 3 months, phototherapy should be discontinued. Home phototherapy is a good option in UV-responsive vitiligo patients. Known photosensitivity, porphyria, and systemic lupus erythematosus are contraindications to phototherapy. Excimer laser phototherapy can be as effective as or more effective than NB-UVB, and the response is more rapid. It can be used on limited areas, avoiding whole-body UV exposure. Whereas 25% of treated patches repigment completely, treatment-resistant areas (elbows, knees, wrists, dorsal hands and feet) have only a 2% rate of at least 75% repigmentation. The addition of topical corticosteroid to excimer laser treatment will enhance efficacy. Afamelanotide, a synthetic melanocyte-stimulating hormone analog delivered by monthly implant, may enhance the efficacy of NB-UVB treatment. Oral khellin or L-phenylalanine and antioxidants greatly enhance the response to phototherapy for some investigators, but the results are not reproducible.

Topical application of 8-methoxypsoralen at a concentration of 0.01–0.1%, followed by UVA exposure, may lead to repigmentation. Topical PUVA is used for focal or limited lesions. Inadvertent burns with blistering are frequent complications during treatment in the United States, even when the patient is treated by professionals. For this reason, topical PUVA therapy has been difficult for patients to perform at home. Topical PUVA, however, is widely used in India with success, suggesting that, in the right hands, this treatment can be effective.

In certain situations, use of systemic immunosuppressives may be appropriate in the treatment of vitiligo. This is usually in the setting of rapidly progressive disease, with the goal of reducing the total amount of pigment loss. Systemic corticosteroids are usually used and are tapered over several months. Twice-weekly dexamethasone, at a dose of 10 mg, is one such regimen. Once the disease is arrested, the patient can be converted to phototherapy. The long-term use of systemic immunosuppressives is not recommended. These initially may control the disease, but with chronic use, unacceptable toxicity often develops.

Surgical treatments can be applied to limited lesions if the previous methods do not prove beneficial, but these are time-consuming. Surgery is recommended primarily in patients with treatment-resistant vitiligo, specifically segmental vitiligo, which does not reactivate with injury. Patients must have stable disease (no new lesions or expansion of lesions for 1 year). Surgical procedures are not effective in patients who exhibit Koebner phenomenon or have active vitiligo. Given its expense, surgical treatment should be reserved for exposed skin sites covering less than 2–3% of BSA. Minigrafting, transplantation of autologous epidermal cell suspension, and ultrathin epidermal grafts have all been used. UV phototherapy is often given after the surgical procedure. In some patients with refractory head and neck lesions of vitiligo, skin injury with various lasers combined with sunlight may lead to repigmentation.



## Total depigmentation

If more than 50–80% of BSA is affected by vitiligo, the patient can consider depigmentation. This form of treatment should be considered permanent, and the goal is total depigmentation. Limited areas, such as those exposed daily, may be treated, but satellite and distant depigmentation may occur, so the action of the medication cannot be limited to the applied area. Monobenzone (monobenzyl ether of hydroquinone) 20% is applied twice daily for 3–6 months to residual pigmented areas. Up to 10 months may be required to complete the treatment. About one in six patients treated experiences acute dermatitis, usually confined to the still-pigmented areas, but this rarely limits treatment. Once a uniform depigmented appearance is achieved, the patient is very satisfied. Topical 4-methoxyphenol 20% cream (mequinol, monomethylether of hydroquinone) can also be used for depigmentation. The Q-switched laser selectively destroys melanocytes and can also achieve depigmentation. Laser can be combined with a topical depigmenting agent for added efficacy.

### CHEMICAL LEUKODERMA (OCCUPATIONAL VITILIGO)

Chemical leukoderma is an acquired, depigmented dermatosis caused by repeated exposure to chemicals. It is frequently misdiagnosed as vitiligo. Patients with vitiligo or a family history of vitiligo are at much greater risk of developing chemical leukoderma. The diagnostic criteria follow:

1. Acquired, vitiligo-like depigmented lesions
2. History of repeated exposure to a specific chemical compound
3. Patterned, vitiligo-like macules conforming to site of exposure
4. Confetti macules

The majority of cases are caused by exposure to aromatic or aliphatic derivatives of phenols and catechols, including parateritary butylphenol (adhesive in shoes), amyphenol, butylcatechol, and alkyl phenols. However, sulfhydryls, mercurials, arsenics, cinnamic aldehyde, *p*-phenylenediamine, chloroquine, and azelaic acid have also been implicated. Some of these compounds have a structure similar to tyrosine and may be converted by tyrosine-related protein-1 to compounds toxic to the melanocyte. This process is considered to be different from depigmentation following allergic contact dermatitis. The clinical pattern may be similar to idiopathic vitiligo, but lesions tend to be concentrated in areas of repeated contact with the substance. The first recognized cases of occupational vitiligo occurred in individuals who worked in rubber garments or wore gloves that contained monobenzyl ether of hydroquinone. Phenolic antiseptic detergents used in hospitals and in industrial cleaners have caused chemical leukoderma in janitorial and housekeeping employees. Adhesives and glues containing incriminated chemicals may be found in shoes, wristbands, adhesive tape, and rubber products used in brassieres, girdles, panties, or condoms. Self-sticking bindis (cosmetic used by many Indian women on forehead) have been reported to induce leukoderma from the adhesive material. Also, electrocardiograph electrodes may cause similar round, hypopigmented spots at the site of contact. Radiation therapy and imiquimod application for genital wart treatment can also cause cutaneous depigmentation resembling vitiligo.

The most common location for chemical leukoderma is the face (40% of cases), followed by the hands and feet. The scalp

is rarely affected. Hair dye (at rim of scalp but not on scalp), deodorant (axilla), detergent, adhesives (face, bindis), rubber sandals (feet), black socks and shoes (feet), and rubber condoms (penis) are the exposures associated with lesions in various anatomic regions. Pruritus occurs in more than 20% of patients (rare complaint in vitiligo patients). The clinical lesions are sharply marginated macules and patches, often with “confetti” or pea-sized macules seen at the periphery. This clinical pattern is atypical for idiopathic vitiligo and should suggest the diagnosis of chemical leukoderma. More than 25% of patients have lesions outside the area of contact with the implicated chemical. In about 10% of patients, new vitiliginous lesions will continue to develop, even after exposure to the chemical is stopped. Treatment is avoidance and measures used for idiopathic vitiligo. Chemical leukoderma in a person without vitiligo has a good prognosis, with repigmentation in up to 75% of cases. If a person with vitiligo develops a chemical leukoderma, repigmentation occurs in only 20% of patients. Histologically, the vitiliginous areas of a chemical leukoderma show an absence of melanocytes identical to lesions of true vitiligo.

**Alajlan A, et al:** Transfer of vitiligo after allogeneic bone marrow transplantation. *J Am Acad Dermatol* 2002; 46:606.

**Alikhan A, et al:** Vitiligo: a comprehensive overview. Part I. Introduction, epidemiology, quality of life, diagnosis, differential diagnosis, associations, histopathology, etiology, and workup. *J Am Acad Dermatol* 2011; 65:473.

**Anbar TS, et al:** Beyond vitiligo guidelines: combined stratified/personalized approaches for the vitiligo patient. *Exp Dermatol* 2014; 23:219.

**Anbar TS, et al:** Most individuals with either segmental or non-segmental vitiligo display evidence of bilateral cochlear dysfunction. *Br J Dermatol* 2014; Jul 17. [Epub ahead of print.]

**Ashique KT, Srinivas CR:** Resizing blister roof grafts for vitiligo surgery. *J Am Acad Dermatol* 2014; 71:e39.

**Attili VR, Attili SK:** Lichenoid inflammation in vitiligo—a clinical and histopathologic review of 210 cases. *Int J Dermatol* 2008; 47:663.

**Au WY, et al:** Generalized vitiligo after lymphocyte infusion for relapsed leukaemia. *Br J Dermatol* 2001; 145:1015.

**Austin M:** Fighting and living with vitiligo. *J Am Acad Dermatol* 2004; 51:S7.

**Aziz Jalali M, et al:** Treatment of segmental vitiligo with normal-hair follicle autograft. *Med J Islam Repub Iran* 2013; 27:210.

**Basak PY, et al:** The role of helper and regulatory T cells in the pathogenesis of vitiligo. *J Am Acad Dermatol* 2009; 60:256.

**Bisen N, et al:** Target-like pigmentation after minipunch grafting in stable vitiligo. *Indian J Dermatol* 2014; 59:355.

**Colucci R, et al:** High prevalence of circulation autoantibodies against thyroid hormones in vitiligo and correlation with clinical and historical parameters of patients. *Br J Dermatol* 2014; 171:786.

**Felsten LM, et al:** Vitiligo: a comprehensive overview. Part II. Treatment options and approach to treatment. *J Am Acad Dermatol* 2011; 65:493.

**Ghosh S, Mukhopadhyay S:** Chemical leukoderma: a clinico-aetiological study of 864 cases in the perspective of a developing country. *Br J Dermatol* 2009; 160:40.

**Grimes PE, et al:** The efficacy of afamelanotide and narrowband UV-B phototherapy for repigmentation of vitiligo. *JAMA Dermatol* 2013; 149:68.

**Hartmann A, et al:** Occlusive treatment enhances efficacy of tacrolimus 0.1% ointment in adult patients with vitiligo: results of a placebo-controlled 12-month prospective study. *Acta Derm Venereol* 2008; 88:474.

**Hélou J, et al:** Fractional laser for vitiligo treated by 10,600 nm ablative fractional carbon dioxide laser followed by sun exposure. *Lasers Surg Med* 2014; 46:443.

**Hexsel CL, et al:** A clinical trial and molecular study of photoadaptation in vitiligo. *Br J Dermatol* 2009; 160:534.

**Hsu S:** Camouflaging vitiligo with dihydroxyacetone. *Dermatol Online J* 2008; 14:23.

**Krüger C, Schallreuter KU:** A review of the worldwide prevalence of vitiligo in children/adolescents and adults. *Int J Dermatol* 2012; 51:1206.

**Li W, et al:** Indication of vitiligo after imiquimod treatment of condylomata acuminata. *BMC Infect Dis* 2014; 14:329.

**Linthorst Homan MW, et al:** Impact of childhood vitiligo on adult life. *Br J Dermatol* 2008; 159:915.

**Martin-Garcia RF, et al:** Chloroquine-induced, vitiligo-like depigmentation. *J Am Acad Dermatol* 2003; 48:981.

**Nicolaidou E, et al:** Narrowband ultraviolet B phototherapy and 308-nm excimer laser in the treatment of vitiligo: a review. *J Am Acad Dermatol* 2009; 60:470.

**Pacific A, Leone G:** Photo(chemo)therapy for vitiligo. *Photodermatol Photoimmunol Photomed* 2011; 27:261.

**Park KK, et al:** A review of monochromatic excimer light in vitiligo. *Br J Dermatol* 2012; 167:468.

**Passeron T, et al:** Topical tacrolimus and the 308-nm excimer laser: a synergistic combination for the treatment of vitiligo. *Arch Dermatol* 2004; 140:1065.

**Patel NS, et al:** Advanced treatment modalities for vitiligo. *Dermatol Surg* 2012; 38:381.

**Pavithran K, et al:** Report of a case of radiation-induced new-onset vitiligo with collective review of cases in the literature of radiation-related vitiligo. *Case Rep Med* 2013; 2013:345473.

**Radakovic-Fijan S, et al:** Oral dexamethasone pulse treatment for vitiligo. *J Am Acad Dermatol* 2001; 44:814.

**Sassi F, et al:** Randomized controlled trial comparing the effectiveness of 308-nm excimer laser alone or in combination with topical hydrocortisone 17-butyrate cream in the treatment of vitiligo of the face and neck. *Br J Dermatol* 2008; 159:1186.

**Sawicki J, et al:** Vitiligo and associated autoimmune disease: retrospective review of 300 patients. *J Cutan Med Surg* 2012; 16:261.

**Shan X, et al:** Narrow-band ultraviolet B home phototherapy in vitiligo. *Indian J Dermatol Venereol Leprol* 2014; 80:336.

**Silverberg NB:** Recent advances in childhood vitiligo. *Clin Dermatol* 2014; 32:524.

**Silverberg NB, et al:** Tacrolimus ointment promotes repigmentation of vitiligo in children: a review of 57 cases. *J Am Acad Dermatol* 2004; 51:760.

**Spritz RA:** Six decades of vitiligo genetics: genome-wide studies provide insights into autoimmune pathogenesis. *J Invest Dermatol* 2012; 132:268.

**Suga Y, et al:** Medical pearl: DHA application for camouflaging segmental vitiligo and piebald lesions. *J Am Acad Dermatol* 2002; 47:436.

**Vrijman C, et al:** The prevalence of thyroid disease in patients with vitiligo: a systematic review. *Br J Dermatol* 2012; 167:1224.

**Wang E, et al:** Intralesional corticosteroid injections for vitiligo: a new therapeutic option. *J Am Acad Dermatol* 2014; 71:391.

**Wong R, Lin AN:** Efficacy of topical calcineurin inhibitors in vitiligo. *Int J Dermatol* 2013; 52:491.

**Yang Y, et al:** Clinical analysis of thyroglobulin antibody and thyroid peroxidase antibody and their association with vitiligo. *Indian J Dermatol* 2014; 59:357.

**Yazdani Abyaneh M, et al:** Narrowband ultraviolet B phototherapy in combination with other therapies for vitiligo: mechanisms and efficacies. *J Eur Acad Dermatol Venereol* 2014; 28:1610.

## VOGT-KOYANAGI-HARADA SYNDROME

Vogt-Koyanagi-Harada syndrome (VKHS) is a rare multisystem disease which affects the eyes, skin, auditory system, and central nervous system (CNS). It affects primarily pigmented races and is rare in white persons. It is twice as common in females and affects all ages. The disease occurs in four phases. First is the prodromal phase or meningoencephalitic phase, with fever, malaise, headache, nausea, and vomiting. The CNS involvement can include meningismus, headaches, mental status changes, cerebrospinal fluid pleocytosis, tinnitus, and dysacusis. Recovery is usually complete. The second, uveitic phase is characterized by anterior and/or posterior uveitis and inflammation of many other parts of the eye. The third, convalescent phase begins 3 weeks to 3 months after the uveitis appears, usually as it begins to improve. This stage is charac-

terized by noncicatricial alopecia, vitiligo-like depigmentation, and poliosis of scalp, eyebrows, eyelashes, and hairs of the axillae. The vitiligo-like lesions occur in only 20–60% of patients with VKHS. The skin of the back or buttocks seems to be the initial or only anatomic area involved. The skin lesions must begin after the ocular symptoms to be considered diagnostic. The fourth phase is one of recurrent attacks of uveitis. Most ocular complications result from this stage of the disease, including permanent decreased visual acuity, cataracts, and glaucoma.

Vogt-Koyanagi-Harada syndrome is a cell-mediated autoimmune disease, with the autoantigen(s) thought to be expressed solely in melanin-containing cells. The target antigens may be the tyrosinase family proteins; immunization of mice with several of these proteins can induce a syndrome similar to VKHS. Supporting this hypothesis are the rare observations that vitiligo, interferon therapy for hepatitis C, and melanoma can all be associated with the appearance of VKHS. Aggressive immunosuppressive therapy with systemic corticosteroids and immunomodulatory medications (cyclosporine, azathioprine, mycophenolate, tacrolimus, infliximab) may preserve ocular function and prevent ocular complications. Th17 CD4+ cells stimulated by high levels of interleukin (IL)-23 and secreting IL-17 are present in VKHS patients with active uveitis. At least 10 patients with psoriasis and VKHS have been reported. They present at an older age than VKHS patients without psoriasis, and they often have HLA genotypes that have been associated with both VKHS and psoriasis (DR4, Cw6).

**Abu El-Asrar AM, et al:** The outcomes of mycophenolate mofetil therapy combined with systemic corticosteroids in acute uveitis associated with Vogt-Koyanagi-Harada disease. *Acta Ophthalmol* 2012; 90:e603.

**Abu El-Asrar AM, et al:** Prognostic factors for clinical outcomes in patients with Vogt-Koyanagi-Harada disease treated with high-dose corticosteroids. *Acta Ophthalmol* 2013; 91:e486.

**Aisenbrey S, et al:** Vogt-Koyanagi-Harada syndrome associated with cutaneous malignant melanoma: an 11-year follow-up. *Graefes Arch Clin Exp Ophthalmol* 2003; 241:996.

**Bilgiç Ö, et al:** Vogt-Koyanagi-Harada disease in an adolescent boy. *Pediatr Dermatol* 2014; 31:99.

**Chi W, et al:** IL-23 promotes CD4+ T cells to produce IL-17 in Vogt-Koyanagi-Harada disease. *J Allergy Clin Immunol* 2007; 119:1218.

**Chuang CT, et al:** Reversible alopecia in Vogt-Koyanagi-Harada disease and sympathetic ophthalmia. *J Ophthalmic Inflamm Infect* 2013; 3:41.

**Greco A, et al:** Vogt-Koyanagi-Harada syndrome. *Autoimmun Rev* 2013; 12:1033.

**Hernandez C, et al:** Vogt-Koyanagi-Harada syndrome in a 6-year-old Hispanic boy. *Pediatr Dermatol* 2012; 29:191.

**Latronico ME, et al:** Bilateral dexamethasone intravitreal implant in a young patient with Vogt-Koyanagi-Harada disease and refractory uveitis. *Clin Rheumatol* 2014; Apr 25. [Epub ahead of print.]

**Liu X, et al:** Inhibitory effect of cyclosporin A and corticosteroids on the production of IFN-gamma and IL-17 by T cells in Vogt-Koyanagi-Harada syndrome. *Clin Immunol* 2009; 131:333.

**Niccoli L, et al:** Efficacy of infliximab therapy in two patients with refractory Vogt-Koyanagi-Harada disease. *Br J Ophthalmol* 2009; 93:1553.

**Sakata VM, et al:** Diagnosis and classification of Vogt-Koyanagi-Harada disease. *Autoimmun Rev* 2014; 13:550.

**Shimizu A, et al:** Alopecia in a patient with Vogt-Koyanagi-Harada disease. *J Dermatol* 2014; 41:184.

**Sylvestre DL, et al:** Vogt-Koyanagi-Harada disease associated with interferon alfa-2b/ribavirin combination therapy. *J Viral Hep* 2003; 10:467.

**Takahashi H, et al:** Psoriasis vulgaris associated with Vogt-Koyanagi-Harada syndrome. *J Dermatol* 2013; 40:933.

**Tsuruta D, et al:** Inflammatory vitiligo in Vogt-Koyanagi-Harada disease. *J Am Acad Dermatol* 2001; 44:129.

**Xiang Q, et al:** *TRAF5* and *TRAF3IP2* gene polymorphisms are associated with Behçet's disease and Vogt-Koyanagi-Harada syndrome: a case-control study. *PLoS One* 2014; 9:e84214.



## ALEZZANDRINI SYNDROME

Alezzandrini syndrome is an extremely rare condition (<10 reported cases) characterized by a unilateral degenerative retinal pigment epithelia degeneration, ipsilateral vitiligo on the face, ipsilateral poliosis, and ipsilateral sensorineural deafness.

**Andrade A, Pithon M:** Alezzandrini syndrome: report of a sixth clinical case. *Dermatology* 2011; 222:8.

**Gupta M, et al:** Alezzandrini syndrome. *BMJ Case Rep* 2011.

## LEUKODERMA

Postinflammatory leukoderma may result from many inflammatory dermatoses, such as pityriasis rosea, psoriasis, herpes zoster, secondary syphilis, and morphea. Sarcoidosis, tinea versicolor, mycosis fungoides, scleroderma, and pityriasis lichenoides chronica may all present with hypopigmented lesions (only rarely are these actually depigmented), as may Hansen's disease. Burns, scars, postdermabrasion, and intralesional steroid injections with depigmentation are other examples of leukoderma. IL-17 and tumor necrosis factor (TNF)- $\alpha$  synergistically suppress pigmentation related signaling and melanin production, partly through induction of  $\beta$ -defensin 3, an antagonist for melanocortin 1 (MC1R), and may represent the mechanism by which psoriasis and other inflammatory dermatoses are complicated by hypopigmentation.

Melanosomes are members of the lysosome-related organelle (LRO) family. Congenital disorders of hypopigmentation can be caused by four groups of genetic defects: (1) mutations in genes controlling melanoblast migration (Waardenburg syndrome); (2) mutations in genes controlling enzymes involved in melanin synthesis (oculocutaneous albinism); (3) mutations in genes of melanosome structural proteins (genes controlling melanosome cell membrane or scaffolding on which melanins are deposited within melanosome—Chédiak-Higashi and Hermansky-Pudlak syndromes); or (4) mutations in genes controlling melanosome-trafficking proteins (surface proteins on melanosome that direct melanosome movement from Golgi complex to melanocyte periphery—Griscelli syndrome). Clinically, this group of disorders can be characterized as generalized (systemic) or localized. Within each of these subgroups are those conditions with associated comorbidities and those without comorbidities (Box 36-1).

### Box 36-1 Classification of hypopigmentation disorders

#### I. Systemic hypopigmentation (generalized hypopigmentation)

- A. Without comorbidities
  - i. Oculocutaneous albinism types 1–4
  - ii. Griscelli syndrome type 3
- B. With comorbidities
  - i. Bleeding: Hermansky-Pudlak syndrome
  - ii. Infection: Chédiak-Higashi syndrome, Griscelli syndrome, Hermansky-Pudlak syndrome type 2

#### II. Localized hypopigmentation

- A. Without comorbidities
  - i. Nevus depigmentosus
  - ii. Piebaldism
- B. With comorbidities
  - i. Deafness: Waardenburg syndrome
  - ii. Megacolon and neural disorders: Hirschsprung disease type 2
  - iii. Neural disorders: hypomelanosis of Ito

**Wang CQ, et al:** IL-17 and TNF synergistically modulate cytokine expression while suppressing melanogenesis: potential relevance to psoriasis. *J Invest Dermatol* 2013; 133:2741.

**Yamaguchi Y, Hearing VJ:** Melanocytes and their diseases. *Cold Spring Harb Perspect Med* 2014; 4:a017046.

## OCULOCUTANEOUS ALBINISM

Oculocutaneous albinism (OCA) is an autosomal recessively inherited trait with reduction or absence of melanin in skin, hair, and eyes. Eye problems are frequently present, including moderate to severe impairment of visual acuity, nystagmus, strabismus, and photophobia. The cutaneous phenotype of the various forms of albinism is broad, but the ocular phenotype is reasonably constant in most forms.

The most serious sequelae of albinism are gross visual disturbances and increased risk for development of skin cancer. A number of syndromes associated with albinism can also cause premature mortality from impaired functioning of other involved organs and systems.

### Disorders of melanin synthesis

The seven genetic forms of nonsyndromal OCA are all caused by disruption of melanin synthesis and are all autosomal recessive disorders. Their prevalence varies widely around the world but is estimated at about 1 in 17,000. This means that about 1 in 70 persons carries a gene for OCA. Given the phenotypic overlap of the various forms of OCA, genetic testing is recommended to establish the diagnosis. Since both parents are obligate carriers and two thirds of healthy siblings are at risk for being carriers, genetic counseling is recommended. Carriers are asymptomatic. All persons with OCA and their parents should be educated regarding aggressive sun protection with sunscreens, appropriate clothing, and sun avoidance. Vitamin D supplementation may be required. As adults, patients should be examined for skin lesions suspicious for melanoma and nonmelanoma skin cancer.

#### Oculocutaneous albinism 1

OCA1 results from mutations in the tyrosinase gene and accounts for approximately 40% of OCA worldwide. It is the most severe form of albinism and is the most common type of albinism in Japanese, non-Hispanic Caucasians, and a mixed-race European population, with a prevalence of about 1 in 40,000. Affected patients are homozygous for the mutant gene or are compound heterozygotes for different mutations in the tyrosinase gene (*TYR*). OCA1 is divided into two forms: OCA1A and OCA1B. At birth, these are indistinguishable. OCA1A is the most severe form, with complete absence of tyrosinase activity and of melanin in the skin and eyes. Visual acuity is decreased to 20/400. The hair, eyelashes, and eyebrows are white, and the skin is white and does not tan. Irises are light blue to pink and fully translucent. Amelanotic nevi may be present. In OCA1B, tyrosinase activity is greatly reduced but not absent. Affected patients may show an increase in skin, hair, and eye color beginning at age 1–3 years, and they can tan. Iris color may also darken over time. OCA1B was originally called “yellow mutant” albinism. Temperature-sensitive OCA (OCA1-TS) is considered a variant of OCA1B; it results from mutations in *TYR* that produce an enzyme with limited activity below 37°C (98°F) and no activity above this temperature. Affected patients have white hair, skin, and eyes at birth. At puberty, dark hair develops in cooler acral areas: legs, arms, and chest. Visual acuity is not as severely affected in OCA1B.

### Oculocutaneous albinism 2

OCA2 has a prevalence of 1 in 36,000 in white Europeans, but as much as 1 in 4000 in some parts of Africa. It is the most common form of OCA, accounting for approximately 50% of OCA worldwide. OCA2 was formerly called “tyrosinase-positive” albinism, or “brown OCA.” Inheritance is autosomal recessive and results from mutations in the OCA2 gene, formerly known as the P-gene. The OCA2 gene encodes an integral melanosomal protein that is important for normal biogenesis of melanosomes and normal processing and transport of melanosomal proteins such as tyrosinase and tyrosinase-related protein 1 (TYRP1). The cutaneous phenotype of OCA2 patients is broad, ranging from near-normal pigmentation to virtually no pigment. Newborns have pigmented hair. Nevi and ephelides are common. Pink irises are usually not seen. Visual defects are not as severe as in OCA1. Pigmentation increases with age, and visual acuity improves from infancy to adolescence. Prader-Willi and Angelman syndromes are caused by deletions in the chromosomal region contiguous to and sometimes including the OCA2 gene. About 1% of patients with these syndromes also have OCA2.

### Oculocutaneous albinism 3

OCA3 is caused by mutations in the *TYRP1* gene. *TYRP1* is involved in the maintenance of melanosome structure and affects melanocyte proliferation and cell death. It also is an essential cofactor for tyrosinase activity. This form of OCA has been most frequently found in African patients and was called “rufous” or red OCA. Patients have red hair and reddish brown skin. Visual abnormalities may not be detectable.

### Oculocutaneous albinism 4

OCA4 is caused by mutations in the *MATP* (also known as *SLC45A2*) gene encoding a membrane-associated protein, predicted to span the membrane 12 times and to function as a transporter. Patients are hypopigmented to a variable degree and are phenotypically identical to patients with OCA2. Visual acuity is decreased, and nystagmus is found in many but not all patients. This has also been reported in a Turkish patient, as well as German, Japanese, and Korean OCA patients.

### Oculocutaneous albinism 5

OCA5 has been mapped to the 4q24. It has been described in a Pakistani family with golden hair, white skin, nystagmus, photophobia, and impaired visual acuity.

### Oculocutaneous albinism 6

OCA6 is caused by mutations in *SLC24A5*, the gene product of which is a solute carrier protein important in melanosomal architecture, linking closely the structure of the melanosome to melanin synthesis. This form of OCA is found in diverse ethnicities, and the phenotype is heterogeneous with hair color from white to blond to dark brown. Most mutations occur in position 111 of the gene, with a Thr111 mutation in European or American OCA6 and Ala111 in African or Asian OCA6.

### Oculocutaneous albinism 7

OCA7 is caused by mutation in the C10 or FII gene, the gene product of which is a member of the leucine-rich repeat proteins.

## Disorders of melanosome formation and trafficking

These multisystem syndromes are associated with albinism and are caused by genes that function in intracellular organelle formation and movement in a variety of specialized cell types,

such as melanocytes, neurons, immune cells, monocytes, platelets, and type II epithelial cells in lungs. The silver hair associated with some of these syndromes may demonstrate pigment clumping, allowing the diagnosis to be suspected.

### Chédiak-Higashi syndrome

Chédiak-Higashi syndrome (CHS) is a progressively degenerative, fatal disease characterized by partial oculocutaneous albinism (decreased skin, eye, and hair pigment), giant intracellular granules, pigment clumping in hair shafts, and a bleeding diathesis caused by absent or reduced platelet-dense bodies. It presents in childhood, usually with infections of the skin, gut, and lungs. Common pathogens are *Staphylococcus aureus*, streptococcus, gram-negative organisms, *Candida*, and *Aspergillus*. Immunoglobulins, antibody production, and phagocytosis are normal, but neutropenia is common and leukocytes display impaired migration. Natural killer cells are decreased in function, and cytotoxic T-lymphocyte (CTL) cytotoxicity is impaired. The hair of these patients is blond and sparse. The ocular albinism is accompanied by nystagmus and photophobia. In darker-skinned races, affected patients are lighter-skinned than their parents and siblings and may have speckled hyperpigmentation and hypopigmentation.

Chédiak-Higashi syndrome results from mutations in the *LYST* or *CHS1* gene, the exact biologic function of which is unknown. The gene must be important in lysosome and lysosome-related organelle trafficking or size regulation. Melanosomes are giant, and platelets, eosinophils, basophils, and monocytes have giant intracellular granules that are azurophilic.

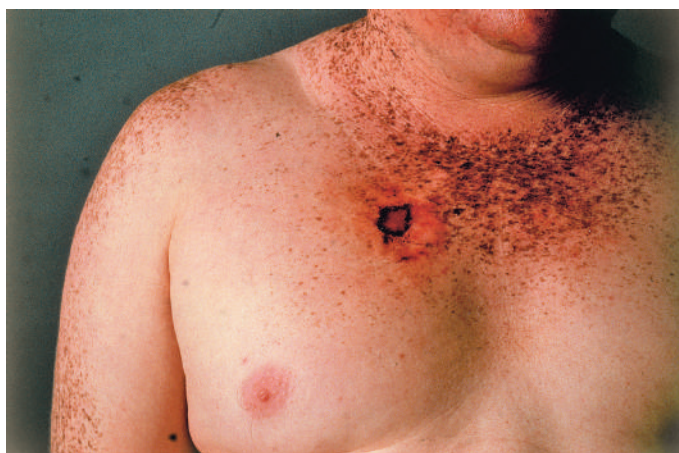About 85% of CHS patients develop hemophagocytic lymphohistiocytosis (HLH), referred to as the “accelerated phase.” This occurs during infancy or childhood and can be fatal. It is caused by the unfettered proliferation of lymphocytes creating a lymphomalike condition with fever, anemia, neutropenia, hepatosplenomegaly, and lymphadenopathy. The likelihood of developing HLH is related to the degree of deficiency of CTL cytotoxicity, independent of genotype. Hematopoietic stem cell transplantation (HSCT) before the onset of this phase may be lifesaving, and it also prevents the infections. Unfortunately, even with HSCT, if CHS patients survive into adulthood, they develop progressive neurologic involvement, including dementia, spinocerebellar impairment, parkinsonism, and spastic paraparesis.

### Hermansky-Pudlak syndrome

Hermansky-Pudlak syndrome (HPS) is an autosomal recessive disorder consisting of oculocutaneous albinism, a hemorrhagic diathesis secondary to the absence of dense bodies in platelets. There is progressive accumulation of a ceroidlike material in the reticuloendothelial system and visceral organs. It is hypothesized but not confirmed that this ceroid material can lead to interstitial lung disease (HPS-ILD) and inflammatory bowel disease (HPS-IBD). The hypopigmentation is caused by impaired melanosome trafficking. Patients with this disorder have a history of easy bruisability, epistaxis, gingival bleeding, hemoptysis, and bleeding after various surgical procedures and childbirth. Major bleeding occurs in 40% of HPS patients.

Currently, nine human genes (for HPS1, *AP3B1* gene, and for HPS 3–9) have been identified, which, when independently mutated, lead to a clinical picture consistent with HPS. All these genes form protein complexes that regulate vesicle trafficking in the endolysosomal system (LROs). These proteins complex together to form various lysosomal-trafficking protein complexes: AP-3, BLOC-1, BLOC-2, and BLOC-3. Although many of the HPS subtypes share the clinical signs and symptoms previously noted, a few subtypes either lack some of





**Fig. 36-14** Hermansky-Pudlak syndrome; freckling of V of neck and basal cell carcinoma in Puerto Rican man.

these or have additional unique features that serve to distinguish them from the other HPS subtypes. Mutations in any gene that produces a protein that contributes to a specific BLOC tend to create a similar clinical phenotype. For example, in mice and men, HPS1 and HPS4 (BLOC-3 proteins) and HPS 3, 5, and 6 (BLOC-2 proteins) have relatively similar phenotypes. The most common subtype is HPS1, which, together with HPS4, accounts for 50% of the known worldwide cases of HPS. One in 21 Puerto Ricans has a mutation (usually 16-base pair [bp] duplication) in the HPS1 gene. HPS accounts for 80% of albinos in Puerto Rico, and 1 in 1800 Puerto Ricans in the northwest region of the country has HPS. HPS1 and HPS4 are clinically similar because together they form the BLOC-3 complex (Fig. 36-14). These are the two most severe forms of HPS. Skin pigmentation can vary from total lack of pigment to lighter hair and skin coloring than in other members of the family. Ocular changes similar to those of OCA can occur, including iris transillumination, hypopigmented retina, visual impairment, horizontal nystagmus, and strabismus. Atypical nevi, acanthosis nigricans-like lesions in the axillae and neck, and trichomegaly also occur. Solar damage, as evidenced by solar lentigines, actinic keratoses, and nonmelanoma skin cancers, occurs in 80% of patients with the 16-bp duplication in HPS1. Interstitial pulmonary fibrosis, IBD, renal failure, and cardiomyopathy are late complications and can cause premature mortality between ages 20 and 50. About 60% of patients with HPS have pulmonary symptoms, starting at a mean age of 35 years. Pirfenidone, an antifibrotic agent, can slow the progression of pulmonary fibrosis in HPS1 patients with significant residual lung function (initial forced ventilatory capacity >50%). Lung transplantation can be considered.

Hermansky-Pudlak syndrome type 2 is caused by a mutation in the gene (*AP3B1*) coding for the 3 $\beta$ A subunit of AP3, a molecule necessary for normal protein trafficking to the lysosome. HPS2 is notable for immunodeficiency and persistent neutropenia, with recurrent bacterial infections of the upper respiratory system and middle ear, possibly caused by the lack of antigen presentation by the CD1b molecule, since CD1b fails to gain access to the lysosome. Initially, patients may be misdiagnosed as having CHS resulting from pigment dilution and recurrent infections. However, the large intracellular granules of CHS are absent. Mild pulmonary fibrosis and a mild hearing defect can be associated with HPS2.

Patients with HPS3, HPS5, and HPS6 have mild clinical findings, without reported pulmonary or GI involvement. These types are caused by mutations in three proteins that make up BLOC2. HPS7 and HPS8 are very rare and present with a phenotype of oculocutaneous albinism and a bleeding

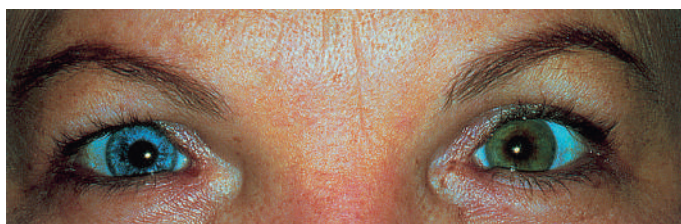
tendency caused by platelet dysfunction. The HPS7 gene (*DTNBP1*) encodes dysbindin; the HPS8 gene is *BLOC1S3*, both BLOC-1 subunits.

## Disorders of melanocyte transport

### Griscelli syndrome

The myosin-5a/RAB27A/melanophilin tripartite protein complex is required to capture mature melanosomes in the peripheral actin network for subsequent transfer to keratinocytes. Mutation in each of these genes causes one type of Griscelli syndrome (GS), with a distinct clinical phenotype with features unique to each type. All types of GS are rare, autosomal recessive inherited, and characterized by mild skin and hair hypopigmentation. GS patients do not have a bleeding tendency, distinguishing them clinically from HPS. GS1 is caused by mutations in the *MYO5A* gene encoding the actin-associated myosin Va motor protein. Patients have primary neurologic dysfunction but no immunologic disease. They have silver hair. GS1 and Elejalde syndrome are thought to be the same disease. GS2 is caused by mutation in the *RAB27A* gene. Patients have silver hair, infections, and hemophagocytic lymphohistiocytosis (HLH), usually triggered by viruses. Leukocytes infiltrating the brain can cause secondary neurologic disease, but patients have no primary neural defects. GS3 is caused by mutations in melanophilin (*MLPH*) and results only in cutaneous hypopigmentation.

- Bachmann C, et al:** Neonatal and maternal risk in Hermansky-Pudlak syndrome: peripartum management-brief report and review of the literature. *Arch Gynecol Obstet* 2014; 289:1193.
- Bhambhani V, et al:** Chédiak-Higashi syndrome presenting as young-onset levodopa-responsive parkinsonism. *Mov Disord* 2013; 28:127.
- Çağdaş D, et al:** Griscelli syndrome types 1 and 3: analysis of four new cases and long-term evaluation of previously diagnosed patients. *Eur J Pediatr* 2012; 171:1527.
- Cullinane AR, et al:** The BEACH is hot: a LYST of emerging roles for BEACH-domain containing proteins in human disease. *Traffic* 2013; 14:749.
- Dotta L, et al:** Clinical, laboratory and molecular signs of immunodeficiency in patients with partial oculo-cutaneous albinism. *Orphanet J Rare Dis* 2013; 8:168.
- Durmaz A, et al:** Molecular analysis and clinical findings of Griscelli syndrome patients. *J Pediatr Hematol Oncol* 2012; 34:541.
- Jessen B, et al:** Subtle differences in CTL cytotoxicity determine susceptibility to hemophagocytic lymphohistiocytosis in mice and humans with Chédiak-Higashi syndrome. *Blood* 2011; 118:4620.
- Jessen B, et al:** The risk of hemophagocytic lymphohistiocytosis in Hermansky-Pudlak syndrome type 2. *Blood* 2013; 121:2943.
- Kamaraj B, Purohit R:** Mutational analysis of oculocutaneous albinism: a compact review. *Biomed Res Int* 2014; 2014:905472.
- Kaur S, et al:** A rare pigmentary disorder in two non-identical siblings: Griscelli syndrome-type 3. *Dermatol Online J* 2014; 20.
- Mahalingashetti PB, et al:** Griscelli syndrome: hemophagocytic lymphohistiocytosis with silvery hair. *J Lab Physicians* 2012; 4:129.
- Masliyah-Planchon J, et al:** Molecular determinants of platelet delta storage pool deficiencies: an update. *Br J Haematol* 2012; 160:5.
- Meeths M, et al:** Clinical presentation of Griscelli syndrome type 2 and spectrum of *RAB27A* mutations. *Pediatr Blood Cancer* 2010; 54:563.
- Montoliu L, et al:** Increasing the complexity: new genes and new types of albinism. *Pigment Cell Melanoma Res* 2013; 27:11.
- Nagai K, et al:** Clinical characteristics and outcomes of Chédiak-Higashi syndrome: a nationwide survey of Japan. *Pediatr Blood Cancer* 2013; 60:1582.
- Sánchez-Guiu, et al:** Hermansky-Pudlak syndrome: overview of clinical and molecular features and case report of a new HPS-1 variant. *Hamostaseologie* 2014; 34:301.
- Seward SL Jr, Gahl WA:** Hermansky-Pudlak syndrome: health care throughout life. *Pediatr* 2013; 132:153.



**Fig. 36-15** Waardenburg syndrome with heterochromia iridis.

**Singh A, et al:** An Indian boy with Griscelli syndrome type 2: case report and review of the literature. *Indian J Dermatol* 2014; 59:394.

**Wei AH, Li W:** Hermansky-Pudlak syndrome: pigmentary and non-pigmentary defects and their pathogenesis. *Pigment Cell Melanoma Res* 2012; 26:176.

**Wei AH, Li W:** Hypopigmentation in Hermansky-Pudlak syndrome. *J Dermatol* 2013; 40:325.

**Westbroek W, et al:** Cellular and clinical report of new Griscelli syndrome type III cases. *Pigment Cell Melanoma Res* 2011; 25:47.

**Wong L, Yano S:** Silvery-gray hair in a newborn. *JAMA* 2012; 308:617.

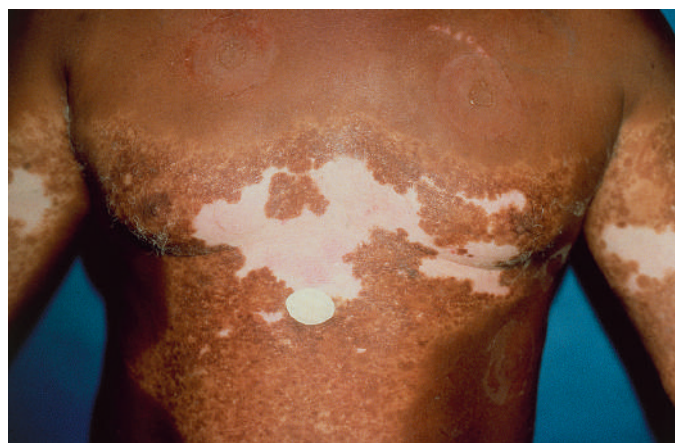## Disorders of melanoblast migration and survival

These disorders cause “spotting,” with patches of white hair and unpigmented skin.

### Waardenburg syndrome

Four types of Waardenburg syndrome (WS) exist, with overlapping phenotypic features; three are autosomal dominant, and type IV is autosomal recessive. Six genes are associated with WS. Types I and III are caused by mutations in the *PAX3* gene, encoding a transcription factor. Most cases of WS type II are caused by mutations in the *MITF* gene; however, some, more mildly affected patients with mutations in *SOX10*, *EDN3*, *EDNRB*, and *SNA12* may present as WS type II. WS type IV is caused either by a heterozygous mutation in the *SOX10* gene or by homozygous mutations in the endothelin-3 (*EDN3*) or the endothelin B receptor (*EDNR3*) gene. These mutations impair the ability of melanoblasts to reach their final target sites (inner ear, eye, skin) during embryogenesis.

Patients with WS have features of piebaldism, with a white forelock, hypopigmentation, and premature graying, caused by absence of melanocytes in affected areas. Other characteristic findings include synophrys (eyebrows growing together), lateral displacement of the medial canthus (dystopia canthorum), congenital deafness, and ocular changes, including heterochromia iridis (Fig. 36-15). Types I and III are both characterized by dystopia canthorum; in WS type I, white forelock and depigmented skin patches are more frequent; while in WS type III, musculoskeletal anomalies (flexion contractures, muscle hypoplasia of the upper limbs, and camptodactyly) occur. In WS type II, no dystopia canthorum is observed, but hearing loss and heterochromia iridis are more frequently found. WS type IV is identical to type I, except for its association with Hirschsprung disease (congenital megacolon), since the migration of neural crest cells into the Auerbach plexus requires *EDN3/EDNRB* and *SOX10*. *SOX10* mutations are associated with neurologic defects, and there is a poor phenotype/genotype correlation in *SOX10*-associated WS. Developmental delay occurs in the many of these patients, suggesting that other genes required for neural development may influence *SOX10* mutation-associated phenotype. This association between WS type IV caused by *SOX10* and neurologic disease has been termed PCWH (peripheral demyelinating neuropathy, central demyelinating leukodystrophy, Waardenburg syndrome, Hirschsprung disease).



**Fig. 36-16** Piebaldism, vitiligo-like depigmentation.

### Piebaldism

Piebaldism is a rare, autosomal dominant syndrome with variable phenotype, presenting at birth. The characteristic clinical features are a white forelock and patchy absence of skin pigment (Fig. 36-16). The depigmented lesions are static and characteristically occur on the anterior and posterior trunk, midupper arm to wrist, mid thigh to midcalf, and shins. A characteristic feature of piebaldism is the presence of hyperpigmented macules within the areas lacking pigmentation and also on normally pigmented skin. The depigmented lesions may repigment spontaneously, or especially after injury. The white forelock is a triangular or diamond-shaped midline white macule on the frontal scalp or forehead, and it is the only manifestation in 80–90% of patients. The medial portions of the eyebrows and eyelashes may be white. Histologically, melanocytes are completely absent in the white macules.

Piebaldism is caused by mutations in the *KIT* gene. The phenotypic differences between families are caused by different locations of mutations in the gene. A mild phenotype occurs in cases associated with haploinsufficiency or a truncated mutation in the TK domain. Severe phenotypes are associated with dominant-negative inhibition caused by a missense mutation in the TK domain. The white lesions may respond to camouflage cosmetics or surgical corrections (see [Vitiligo](#)). Rarely, Hirschsprung disease and neurofibromatosis type I have been associated with piebaldism.

**Agarwal S, Ojha A:** Piebaldism: a brief report and review of the literature. *Indian Dermatol Online J* 2012; 3:144.

**Horner ME, et al:** The spectrum of oculocutaneous disease. Part I. Infectious, inflammatory, and genetic causes of oculocutaneous disease. *J Am Acad Dermatol* 2014; 70:795.e1.

**Jelena B, et al:** Phenotypic variability in Waardenburg syndrome resulting from a 22q12.23-q13.1 microdeletion involving *SOX10*. *Am J Med Genet* 2014; 164:1512.

**Oiso N, et al:** Piebaldism. *J Dermatol* 2013; 40:330.

**Pingault V, et al:** Review and update of mutations causing Waardenburg syndrome. *Hum Mutat* 2010; 31:391.

**Steiman R, et al:** Poliosis circumscripta: overview and underlying causes. *J Am Acad Dermatol* 2013; 69:625.



Bonus images for this chapter can be found online at  
[expertconsult.inkling.com](http://expertconsult.inkling.com)

**eFig. 36-1** Dermatopathia pigmentosa reticularis.

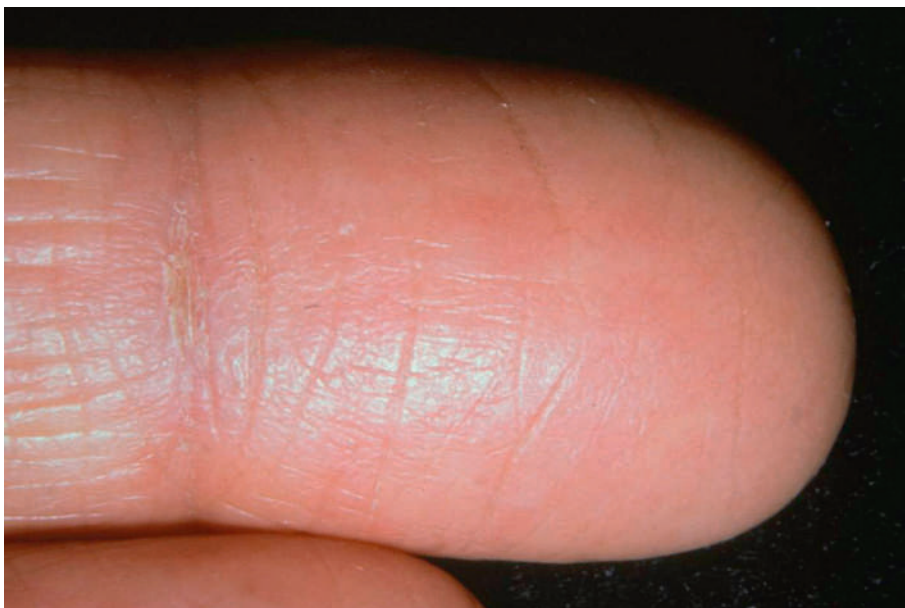**eFig. 36-2** Vitiligo, characteristic periorificial location.

**eFig. 36-3** Lead line.

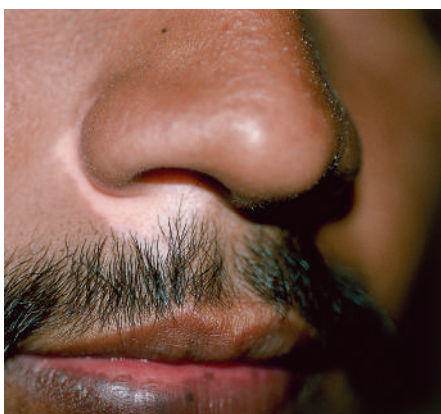**eFig. 36-4** Idiopathic guttate hypomelanosis.

**eFig. 36-5** Piebaldism, white forelock.

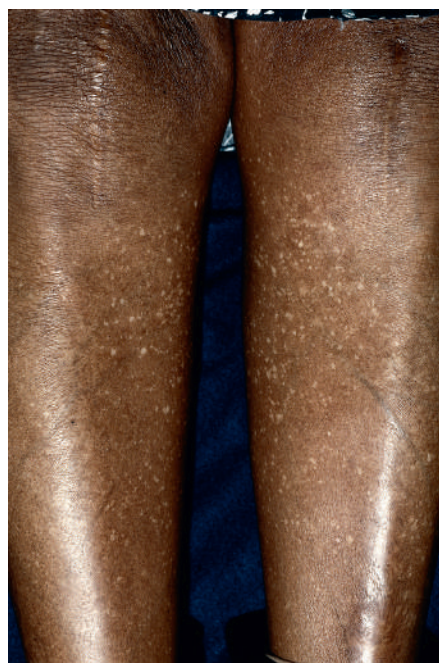



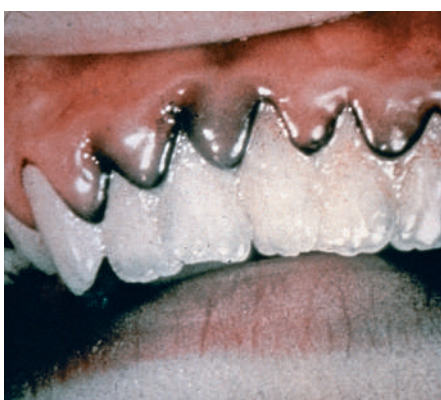**eFig. 36-1** Dermatopathia pigmentosa reticularis, adermatoglyphia.



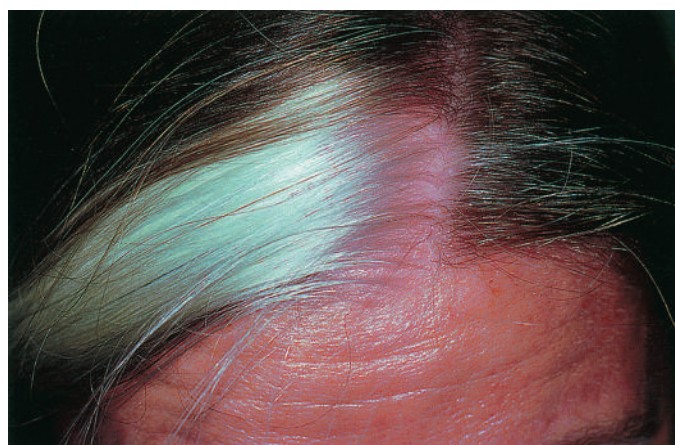**eFig. 36-2** Vitiligo, characteristic periorificial location.



**eFig. 36-4** Idiopathic guttate hypomelanosis.



**eFig. 36-3** Lead line.



**eFig. 36-5** Piebaldism, white forelock.

Dermatology has always been a surgically oriented specialty. Although procedures such as curettage, biopsy, destruction, and excision have been key components of the field, the practice has evolved to include a greater number and extent of surgical procedures. This progression can be attributed to a variety of factors. Dermatologists have a greater understanding of cutaneous pathology, which places them in a unique role to manage complex surgical procedures that arise in the skin. In addition, outpatient dermatologic surgery has been shown to be cost-effective, safe, and efficacious, delivering a greater degree of patient convenience, particularly compared with other fields. The American Board of Dermatology therefore mandates surgical exposure and experience for all residents in dermatology residency programs. Furthermore, with the Accreditation Council for Graduate Medical Education (ACGME) accreditation of Procedural Dermatology fellowships, dermatologic surgery has become recognized as a mainstream medical option for patients. This chapter and Chapters 38 and 39 provide a survey of procedures, indications, and appropriate management within the spectrum of the dermatologic surgery field.

**Hanke CW, et al:** Current status of surgery in dermatology. *J Am Acad Dermatol* 2013; 69(6):972–1001.

**Starling J 3rd, et al:** Determining the safety of office-based surgery: what 10 years of Florida data and 6 years of Alabama data reveal. *Dermatol Surg* 2012; 38(2):171–177.

## PREPARATION FOR SURGERY

A thorough and complete preoperative evaluation is required before performing any surgical procedure. A detailed medical history must be obtained, including information on drug allergies, current medications (including herbal or natural supplements), presence of a pacemaker or implantable cardioverter/defibrillator, recently implanted prosthetic devices, history of prior wound infection or perioperative bleeding, and history of endocarditis or cardiac valvular or congenital malformation.

### Anticoagulants

Much has been written regarding the role of antiplatelets and anticoagulants and surgical bleeding. Dermatologists are frequently presented with the dilemma of whether to discontinue blood thinners in the setting of surgery. Data and multiple reviews have shown that continuous treatment with blood thinners perioperatively in patients undergoing Mohs and cutaneous surgery is not associated with an increase in surgical complications leading to significant morbidity. In contrast, discontinuation of these medications may increase the risk of catastrophic cerebral and cardiovascular complications. Kovich and Otley reported a series of thrombotic complications in a group of patients who had discontinued aspirin or

warfarin before surgery; these included cerebrovascular accident (stroke), transient ischemic attack, myocardial infarction, pulmonary embolus, and death. Multiple authors believe that the potential adverse effects of discontinuing essential medical blood thinners far outweigh the potential side effects of surgical bleeding (e.g., managing a postoperative hematoma). In fact, despite some surgeons' claims to the contrary, studies have demonstrated that blinded surgeons are unable to identify intraoperatively which patients are taking anticoagulation medication based on the subjective amount of surgical oozing. As such, it is recommended that patients be maintained on all medically necessary blood thinners during cutaneous surgery. In contrast, patients taking aspirin for primary prevention may discontinue use 2 weeks before any surgical procedure.

Herbal supplements are becoming increasingly popular with patients who are looking for a "natural" option to traditional medication. Patients may not readily volunteer that they are taking these supplements, either because they do not characterize supplements as medication or because they are concerned that physicians will not be accepting of alternative treatments. Therefore, physicians should ask patients specifically if they are taking any supplements. Ginkgo, garlic, ginseng, ginger, and vitamin E may increase the risk of perioperative bleeding. These herbal supplements are not medically necessary, so patients should discontinue them for several weeks before undergoing dermatologic surgery.

**Bordeaux JS, et al:** Prospective evaluation of dermatologic surgery complications including patients on multiple antiplatelet and anticoagulant medications. *J Am Acad Dermatol* 2011; 65:576–583.

**Bunick CG, Aasi SZ:** Hemorrhagic complications in dermatologic surgery. *Dermatol Ther* 2011; 24:537–550.

**Callahan S, et al:** The management of antithrombotic medication in skin surgery. *Dermatol Surg* 2012; 38:1417–1426.

**Dinehart SM, Henry L:** Dietary supplements: altered coagulation and effects on bruising. *Dermatol Surg* 2005; 31:819–826.

**Gill JF, et al:** Tobacco smoking and dermatologic surgery. *J Am Acad Dermatol* 2013; 68(1):167–172.

**Hurst EA, et al:** Bleeding complications in dermatologic surgery. *Semin Cutan Med Surg* 2007; 26:40–46.

**Kovich O, Otley CC:** Thrombotic complications related to discontinuation of warfarin and aspirin therapy preoperatively for cutaneous operation. *J Am Acad Dermatol* 2003; 48:233–237.

**Lewis KG, Dufresne RG Jr:** A meta-analysis of complications attributed to anticoagulation among patients following cutaneous surgery. *Dermatol Surg* 2008; 34:160–164.

**Otley CC:** Perioperative evaluation and management in dermatologic surgery (review). *J Am Acad Dermatol* 2006; 54:119–127.

**West SW, et al:** Cutaneous surgeons cannot predict blood-thinner status by intraoperative visual inspection. *Plast Reconstr Surg* 2002; 110:98–103.

### Antibiotic prophylaxis

Dermatologists performing cutaneous surgery are often faced with the decision of whether to prescribe prophylactic



antibiotics. The main issues surrounding antibiotic prophylaxis are prevention of surgical site infections and reduction of the risk of endocarditis or contamination of prosthetic devices in high-risk patients. Despite the trend in medicine toward evidence-based approaches, many dermatologists overlook this when approaching antibiotic prophylaxis. Although reducing infection is one objective in the use of antibiotics, dermatologists must consider the risks of such treatment, including adverse drug reactions, serious drug reactions, drug interactions, development of resistant strains of bacteria, and increased cost.

## Surgical site infection

Determining the indications for antibiotic prophylaxis for surgical site infections requires an understanding of the various types of wound that the dermatologist may encounter. Wounds can be categorized into the following four groups:

1. Clean wounds (class I) are created on normal skin using clean or sterile technique. Examples include excision of neoplasms, noninflamed cysts, biopsies, and most cases of Mohs surgery. The majority of dermatologic surgery falls into this category. The infection rate of these wounds is less than 5%. Of note, this incidence is based on general surgery cases, which are often of longer duration and a greater extent than most dermatologic procedures. This explains the lower actual infection rate in dermatologic surgery, which is in the 1-3% range.
2. Clean-contaminated wounds (class II) are created on contaminated skin or any mucosal or moist intertriginous surface, such as the oral cavity, upper respiratory tract, axilla, or perineum. The infection rate of these wounds is 10%.
3. Contaminated wounds (class III) involve visibly inflamed skin with/without nonpurulent discharge and have an infection rate of 20-30%. Examples included inflamed cysts or traumatic wounds.
4. Infected wounds (class IV) have contaminated foreign bodies, purulent discharge, or devitalized tissue. Examples included necrotic tumors, ruptured cysts, or active hidradenitis suppurativa. These wounds have an infection rate of 40%.

Clean (class I) wounds, which constitute the vast majority of dermatologic surgery procedures, do not require antibiotic prophylaxis.

Although antibiotic prophylaxis in clean-contaminated (class II) wounds is not a clear issue, most cases do not require routine antibiotics. It is preferable to treat infections should they arise (because these are not a common occurrence, even in class II wounds), rather than expose all patients to antibiotics and the increased rate of drug-related adverse events. Some exceptions to this that have been advocated include surgical cases that violate mucosal membranes (oral, nasal, anogenital) and patients with heavily colonized skin (atopic dermatitis, infected skin), as well as those in whom a wound infection would result in significant morbidity. However, dermatologic surgeons do not universally agree on these exceptions, and the role for antibiotic prophylaxis is still debated.

In contaminated (class III) and infected (class IV) wounds, antibiotics serve a therapeutic, rather than a prophylactic, role and should be used routinely in these cases.

## Antibiotic selection and timing

To achieve optimal prophylaxis, antibiotics should be in the bloodstream, and thus at the surgical site, at the time of

**Table 37-1** Antibiotic prophylaxis for heavily colonized or high-risk patients

Surgical site	Antibiotic	Regimen (single dose 1 hour preoperatively)
Skin	Cephalexin	1 g orally
	Dicloxacillin	1 g orally
	Clindamycin	300 mg orally
	Vancomycin	500 mg intravenously
Oral and respiratory mucosa	Cephalexin	1 g orally
	Amoxicillin	1 g orally
	Clindamycin	300 mg orally
Gastrointestinal and genitourinary mucosa	Cephalexin	1 g orally
	Trimethoprim-sulfamethoxazole	1 double-strength tablet orally
	Ciprofloxacin	500 mg orally

incision. Antibiotics given at the conclusion of the procedure are not as effective in preventing infection, because they are not incorporated into the coagulum of the wound. Once the surgical wound is closed, the risk of infection decreases significantly. Most dermatologic procedures are of short duration, so a single preoperative dose of antibiotics 1 hour before the start of the case is sufficient. In rare cases with an extended dermatologic procedure, a second dose of antibiotics can be administered 6 hours postoperatively.

The choice of antibiotic is based on the most likely causative organism at the surgical site (Table 37-1). *Staphylococcus aureus* is the most common wound infection in cutaneous surgery. Other pathogens to consider in some situations include *Streptococcus viridans* (oral mucosa) and *Escherichia coli* (perineal and genital location).

First-generation cephalosporins are an ideal initial choice for the treatment of wound infection because of their coverage of staphylococcal organisms, common gram-negative organisms such as *E. coli*, and certain *Proteus* species. Cephalosporins are rapidly absorbed when taken orally and have good tissue penetration. Their estimated cross-reactivity in penicillin-allergic patients is 5-10%.

Isoxazolyl penicillins, such as dicloxacillin and nafcillin, can also be used because they provide coverage for most strains of streptococci and  $\beta$ -lactamase-producing bacterial strains, such as *S. aureus*. Aminopenicillins, such as ampicillin and amoxicillin, have better gram-negative, enterococcal, and group A streptococcal coverage. However, aminopenicillins are not effective against  $\beta$ -lactamase-producing bacteria and thus are used more often in procedures involving oral mucosa.

Clindamycin, macrolides (e.g., erythromycin, azithromycin), trimethoprim-sulfamethoxazole (TMP-SMX), and ciprofloxacin can all be considered in patients with a penicillin or cephalosporin allergy, with the specific choice based on the site of surgery and thus the presumed causative organism. Vancomycin is generally limited to those cases where methicillin-resistant *Staphylococcus aureus* (MRSA) is suspected, because it requires intravenous administration and adjustment in patients with impaired renal function.

## Treatment of wound infection

Postoperative surgical site infection is quite uncommon in dermatologic surgery procedures, with an incidence of 1-3%. Infections typically present 4-7 days after surgery with

increased erythema, tenderness, warmth, and purulent drainage. Sutures can be removed to allow for drainage of exudate. In cases where infection leads to dehiscence, the wound can be packed or allowed to heal by second intention. Scar revision can be performed at a later date should that be necessary. A culture should be performed before initiating empiric antibiotics to determine sensitivities.

*Staphylococcus aureus* is the most common pathogen, and cephalexin or dicloxacillin is an appropriate first-line treatment. Patients with a penicillin allergy can be treated with clindamycin. Although this antibiotic has been associated with colitis, the short courses of clindamycin typically used with surgical site infection generally do not present a problem. In communities or institutions with a high incidence of MRSA, antibiotic choice can be modified based on community sensitivities (e.g., doxycycline, TMP-SMX). Ciprofloxacin can be used for infections with a higher likelihood of gram-negative or *Pseudomonas* organisms (e.g., ear). Antibiotic choice should be modified based on culture results.

## Endocarditis prophylaxis

The American Heart Association (AHA) updated its recommendations on infective endocarditis (IE) prophylaxis in 2007. The overall conclusions were that bacteremia from daily activities is much more likely to cause IE than bacteremia associated with dental procedures, and that far fewer patients are now recommended to have antibiotic prophylaxis. Antibiotic prophylaxis has been limited to patients with the conditions listed in **Box 37-1**. All other cardiac conditions, including mitral valve prolapse and other forms of congenital heart disease, no longer require prophylaxis for any procedure.

Antibiotic prophylaxis is reasonable when procedures involve manipulation of gingival tissue, perforation of oral mucosa, or incision or biopsy of the respiratory mucosa, or when performed on infected skin, but only in patients with underlying cardiac conditions associated with the highest risk of adverse outcome, as outlined in **Box 37-1**. Antibiotic prophylaxis solely to prevent IE is not recommended for gastrointestinal or genitourinary procedures. The AHA reaffirmed its 1997 statement regarding medical procedures, including incision or biopsy of surgically scrubbed skin, that do not require antibiotic prophylaxis. Antibiotic prophylactic regimens for those select high-risk patients should be a single dose of antibiotic administered 1 hour before the procedure (**Table 37-2**).

There are no formal guidelines regarding the use of antibiotics in patients with orthopedic prosthetic devices undergoing dermatologic surgery. However, guidelines for dental procedures in patients with joint replacement can be extrapolated to certain procedures. Patients with joint replacement probably do not need prophylactic antibiotics for clean wounds. If mucosa is invaded, prophylaxis may be appropriate and reasonable in the small number of patients who might be at high risk of joint infection. Consultation with orthopedic surgery is appropriate in determining whether antibiotic prophylaxis is necessary.

**American Dental Association, American Academy of Orthopedic Surgeons:** Antibiotic prophylaxis for dental patients with total joint replacements. *J Am Dent Assoc* 2003; 134(7):895–899.

**Bae-Harboe YS, Liang CA:** Perioperative antibiotic use of dermatologic surgeons in 2012. *Dermatol Surg* 2013; 39(11):1592–1601.

**Hurst EA, et al:** Infectious complications and antibiotic use in dermatologic surgery. *Semin Cutan Med Surg* 2007; 26:47–53.

**Lilly E, Schmults CD:** A comparison of high- and low-cost infection-control practices in dermatologic surgery. *Arch Dermatol* 2012; 148(7):859–861.

**Maragh SL, et al:** Antibiotic prophylaxis in dermatologic surgery: updated guidelines. *Dermatol Surg* 2005; 31:83–91.

### Box 37-1 Cardiac conditions associated with highest endocarditis risk

Prosthetic cardiac valve or prosthetic material used for cardiac valve repair

Previous infectious endocarditis  
Congenital heart disease (CHD)\*

- Unrepaired cyanotic CHD, including palliative shunts and conduits
- Completely repaired congenital heart defect with prosthetic material or device, during the first 6 months after the procedure
- Repaired CHD with residual defects at the site or adjacent to the site of a prosthetic patch or prosthetic device (which inhibit endothelialization)

Cardiac transplantation recipients who develop cardiac valvulopathy

Modified from Wilson W, et al: Prevention of infective endocarditis. *Circulation* 2007; 116:1736–1754.

\*Except for conditions listed above, antibiotic prophylaxis is not recommended for any other form of CHD.

**Table 37-2** Endocarditis prophylaxis regimen (single dose 1 hour preoperatively)

Situation	Agent	Adults	Children
Able to take oral medication	Amoxicillin	2 g	50 mg/kg
Unable to take oral medication	Ampicillin	2 g IM/IV	50 mg/kg IM/IV
	Cefazolin or ceftriaxone	1 g IM/IV	50 mg/kg IM/IV
Allergic to penicillins or ampicillin and able to take oral medication	Cephalexin*	2 g	50 mg/kg
	Clindamycin	600 mg	20 mg/kg
	Azithromycin or clarithromycin	500 mg	15 mg/kg
Allergic to penicillins or ampicillin and unable to take oral medication	Cefazolin or ceftriaxone*	1 g IM/IV	50 mg/mg IM/IV
	Clindamycin	600 mg IM/IV	20 mg IM/IV

Modified from Wilson W, et al: Prevention of infective endocarditis. *Circulation* 2007; 116:1736–1754.

\*Cephalosporins should not be used in patients with a history of anaphylaxis, angioedema, or urticaria with penicillins or ampicillin. IM, Intramuscularly; IV, intravenously.



**Maragh SL, Brown MD:** Prospective evaluation of surgical site infection rate among patients with Mohs micrographic surgery without the use of prophylactic antibiotics. *J Am Acad Dermatol* 2008; 59(2):275–278.

**Rogers HD:** Prospective study of wound infections in Mohs micrographic surgery using clean surgical technique in the absence of prophylactic antibiotics. *J Am Acad Dermatol* 2010; 63(5):842–851.

**Wilson W, et al:** Prevention of infective endocarditis: guidelines from the American Heart Association—a guideline from the American Heart Association Rheumatic Fever, Endocarditis, and Kawasaki Disease Committee, Council on Cardiovascular Disease in the Young, and the Council on Clinical Cardiology, Council on Cardiovascular Surgery and Anesthesia, and the Quality of Care and Outcomes Research Interdisciplinary Working Group. *Circulation* 2007; 116:1736–1754.

**Wright TI, et al:** Antibiotic prophylaxis in dermatologic surgery: advisory statement 2008. *J Am Acad Dermatol* 2008; 59(3):464–473.

## Preoperative antisepsis

Many surgical preparations are available for preoperative antisepsis. Alcohol is frequently used for minor clean procedures, such as biopsies. However, since it has only weak antimicrobial activity, alcohol is not recommended for more extensive procedures.

Chlorhexidine has a broad spectrum against gram-positive and gram-negative organisms, a rapid onset of activity, and sustained residual activity even after being wiped off, and it is nonstaining. Chlorhexidine has been reported to cause both ototoxicity and keratitis from direct tympanic or ocular contact. However, this is mainly in patients under general anesthesia who cannot respond to immediate irritation associated with ocular contact, a problem that is avoided in most dermatologic procedures performed under local anesthesia.

Betadine (povidone-iodine) and all iodine-containing preparations have an excellent bactericidal activity within several minutes of application. However, these agents are often irritating to the skin, leave a residual color, can be absorbed in premature infants, and must dry before the procedure if they are to act as an effective antimicrobial agent.

Hexachlorophene is not bactericidal against many gram-negative organisms. It has the potential for neurotoxicity in children and teratogenicity in pregnancy. Hydrogen peroxide has no significant antiseptic properties, and thus it is not suitable for sterile skin preparation.

If hair must be removed before surgery, this should be done in a manner that does not leave open skin (cuts or scratches), which can serve as a conduit for infection. Preoperative shaving has been associated with a higher rate of bacterial infection secondary to cutting of the skin surface.

**Dumville JC, et al:** Preoperative skin antiseptics for preventing surgical wound infections after clean surgery. *Cochrane Database Syst Rev* 2013; 3:CD003949.

**Kamel C, et al:** Preoperative skin antiseptic preparations for preventing surgical site infections: a systematic review. *Infect Control Hosp Epidemiol* 2012; 33(6):608–617.

**Noorani A, et al:** Systematic review and meta-analysis of preoperative antisepsis with chlorhexidine versus povidone-iodine in clean-contaminated surgery. *Br J Surg* 2010; 97(11):1614–1620.

## Anesthesia

Anesthetics work by blocking sodium influx into neurons and preventing depolarization and blockage of action potential. Small, unmyelinated C fibers, which carry pain and temperature sensation, are more easily blocked than larger, myelinated A fibers, which carry pressure sensation and motor function.

This difference translates clinically, with patients under local anesthesia not experiencing pain from the sharp incision, but still maintaining the sensation of pressure during the procedure.

All local anesthetics have a similar structure, consisting of three parts: an aromatic hydrophobic ring, intermediate chain, and amine end. The aromatic hydrophobic portion is lipophilic and facilitates diffusion through nerve cell membranes, correlating to the potency of the anesthesia. The hydrophilic amine end contributes to the aqueous solubility of the anesthetic and is involved in binding of the molecule to the sodium channel. The intermediate chain consists of either an amide or an ester. Amides are metabolized by hepatic microsomal enzymes, and esters are metabolized in plasma by pseudocholinesterase and excreted by the kidney.

The choice of anesthetic is based on a variety of factors, including patient allergy, renal or hepatic impairment, and type of procedure being performed. The “workhorse” anesthetic of dermatologic surgery is lidocaine, because of its rapid onset of action and intermediate duration of action. Longer-acting anesthetics, such as bupivacaine, have a delayed onset of action, but can be used in special procedures or in combination with lidocaine to maximize duration of anesthesia.

All local anesthetics, with the exception of cocaine and prilocaine, cause vasodilation from relaxation of smooth muscle. As a result, patients experience increased surgical bleeding and shorter duration of action as the anesthesia is cleared from the surgical site because of vasodilation. Epinephrine, which causes vasoconstriction, is often added to local anesthetics to decrease bleeding, increase duration of anesthesia, and reduce systemic side effects caused by systemic absorption. Concentrations of 1:100,000 to 1:400,000 are typically used, with lower concentrations having fewer side effects while still maintaining clinical efficacy. The vasoconstrictive effect of epinephrine takes 15 min for onset, so the surgeon must allow adequate time before starting the procedure. Epinephrine is a strong  $\alpha$ - and  $\beta$ -adrenergic receptor agonist and has an absolute contraindication in hyperthyroidism and pheochromocytoma. Large amounts of epinephrine must be used cautiously in patients with severe hypertension or narrow-angle glaucoma, as well as in pregnancy. Patients taking  $\beta$ -blockers, monoamine oxidase inhibitors, tricyclic antidepressants, and phenothiazines are more sensitive to epinephrine. Although the subject of much controversy, epinephrine is safe to use in well-vascularized areas, such as the ear, nose, and genitals. Reports of necrosis are likely the result of excessive volume being placed, which can cause a physical tamponade of vessels, rather than being a direct result of epinephrine.

Sodium bicarbonate (8.4%) can be added (1:10 ratio) to reduce the pain and burning associated with the lower pH of lidocaine with epinephrine. However, sodium bicarbonate can reduce epinephrine activity with time, thus requiring freshly mixed preparations on a regular basis.

## Side effects

The most common side effect of local anesthetic is injection site pain. Buffering with sodium bicarbonate, using a small-gauge needle (e.g., 30 gauge), using ice or vibratory distraction at the injection site, injecting slowly into the subcutaneous tissue (rather than the dermis), warming the anesthesia, minimizing the number of injections, and placing subsequent injections in an already-anesthetized location can minimize the pain associated with local anesthesia. Vasovagal reactions are common during anesthesia administration. Patients should lie flat during the injection to reduce this occurrence. Cold compresses and placing the patient in a Trendelenburg position can help if symptoms occur.

Maximum dosage of anesthesia has traditionally been accepted as 5 mg/kg of 1% plain lidocaine and 7 mg/kg of 1% lidocaine with epinephrine. These numbers have been based on traditional industry-based studies, not found in the medical literature. Experience with tumescent liposuction has taught that dosages up to 55 mg/kg are well tolerated and safe in certain clinical situations. Bupivacaine has a greater risk of cardiac toxicity than lidocaine because of its longer duration of action.

Most true allergic reactions to local anesthetics have been reported with esters. The metabolite *p*-aminobenzoic acid (PABA) is responsible for ester allergies. There is no cross-reactivity between ester and amide classes of anesthetics, so allergy to one type does not preclude the use of the other. True systemic amide allergy is extremely rare. Thorough questioning of patients who report allergy often reveals a vasovagal reaction or epinephrine sensitivity. If local anesthetic use is precluded, intradermal injection with diphenhydramine can be used. Drowsiness can be a side effect when large doses of this agent are used. Bacteriostatic saline, with the benzyl alcohol preservative acting as the anesthetic agent, is often sufficient to provide the brief anesthesia needed to perform small procedures.

Topical anesthetics can be effectively used for many laser procedures, as well as decreasing pain associated with pin-pricks of local anesthesia. These products require an extended time of application and/or occlusion to penetrate the stratum corneum and work effectively. The level of anesthesia obtained with these agents is often inconsistent. Topical anesthetics are more effective on mucosa because of the absence of the corneal barrier. There are numerous lidocaine-containing products in a variety of preparations. Eutectic mixture of 2.5% lidocaine and 2.5% prilocaine has also been used extensively. Prilocaine-induced methemoglobinemia has been reported in children from the increased systemic absorption of prilocaine from certain topical products.

Direct application of ice can reduce injection site pain. Ethyl chloride spray rapidly chills the skin and can be used for

minor curettage procedures or needle insertion. Refrigerated forced air or water-chilled sapphire crystals can help reduce pain associated with laser procedures. Ophthalmic solutions of proparacaine 0.5% or tetracaine 0.5% can provide rapid anesthesia and are useful when placing corneal shields.

**Alam M, et al:** Safety of peak serum lidocaine concentration after Mohs micrographic surgery: a prospective cohort study. *J Am Acad Dermatol* 2010; 63(1):87–92.

**Koay J, Orengo I:** Application of local anesthetics in dermatologic surgery. *Dermatol Surg* 2002; 28:143–148.

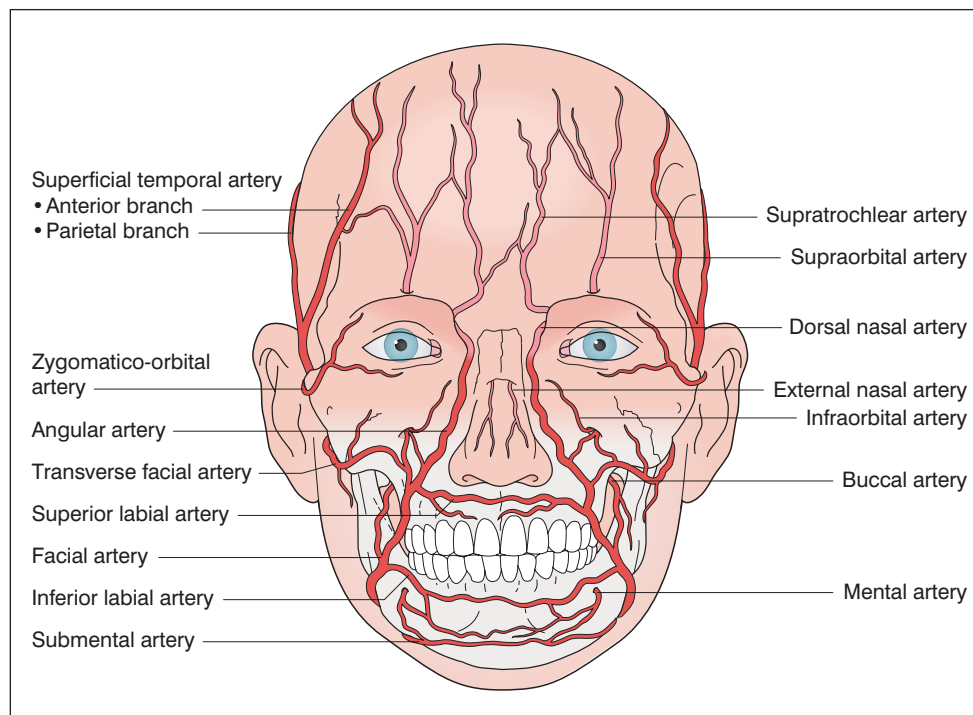
**Morganroth PA, et al:** A randomized, double-blind comparison of the total dose of 1.0% lidocaine with 1:100,000 epinephrine versus 0.5% lidocaine with 1:200,000 epinephrine required for effective local anesthesia during Mohs micrographic surgery for skin cancers. *J Am Acad Dermatol* 2009; 60(3):444–452.

**Sobanko JF, et al:** Topical anesthetics for dermatologic procedures: a review. *Dermatol Surg* 2012; 38(5):709–721.

## Anatomy

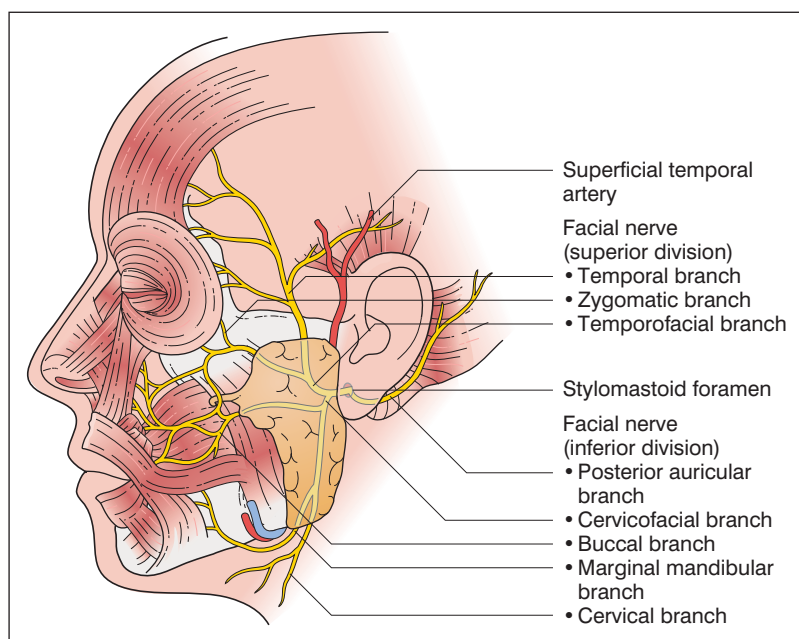
A thorough understanding of anatomy is critical when performing dermatologic surgery. The vascular supply, sensory and motor innervation, and muscles of facial expression all play a role in the successful surgical outcome (Figs. 37-1 to 37-3 and Box 37-2).

Several key danger zones are worthy of mention. The temporal branch of the facial nerve is at greatest risk for injury when it runs superficial to the deep temporalis fascia as it crosses the zygomatic arch. Care must be taken to undermine bluntly in a plane above the SMAS (superficial muscular aponeurotic system). Injury to the temporal nerve results in brow ptosis and inability to raise the eyebrow. The danger zone for the marginal mandibular nerve lies where it crosses over the body of mandible, just anterior to the masseter muscle. Injury to the marginal mandibular nerve causes asymmetric ipsilateral lip elevation and inability to show the lower teeth. The spinal accessory nerve is at risk in a region of the neck delineated by the clavicle inferiorly, sternocleidomastoid muscle

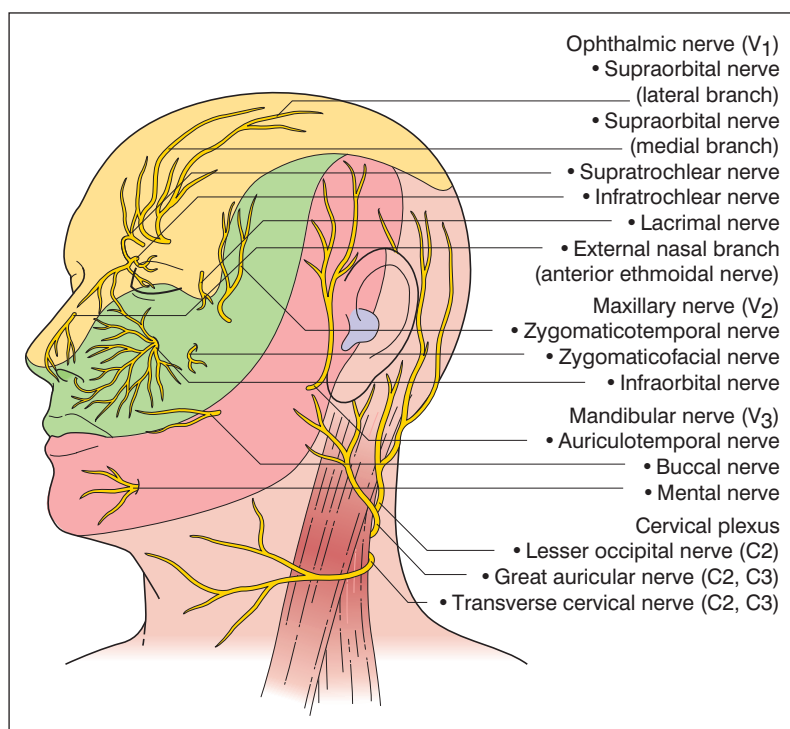


**Fig. 37-1** Arterial supply of the face. Light pink designates arteries derived from the internal carotid artery; dark pink, from the external carotid artery.





**Fig. 37-2** Facial (motor) nerve.



**Fig. 37-3** Trigeminal (cranial nerve V) and cervical plexus cutaneous sensory nerves. The concha and external auditory canal are variably innervated by branches of the vagus, glossopharyngeal, and facial nerves.

anteriorly, and trapezius muscle laterally and posteriorly. Damage to the nerve causes a winged scapula, inability to shrug the shoulder, difficulty abducting the shoulder, shoulder drop, and chronic shoulder pain.

## Equipment

The choice of instruments and suture depends on the procedure being performed. Most simple, in-office biopsies are performed in a “clean” rather than sterile manner and require minimal instrumentation. More complex excisional and reconstructive surgery is generally performed with sterile technique and employs a surgical tray with a wider range of instruments (Box 37-3).

For procedures requiring sutures, absorbable material is used for deeper, layered closures, whereas surface sutures are generally nonabsorbable or fast-absorbing (Table 37-3). The large number of suture choices relates to both the type of procedure performed and the anatomic location treated. Choices include absorbable and nonabsorbable, synthetic and nonsynthetic, monofilament and braided. The surgeon must consider a variety of other characteristics when choosing which suture to use. Memory is the ability of the suture to return to its original shape after deformation, which results in poor handling and decreased knot security. Plasticity is the ability of the suture to retain its new shape after it has been stretched. Elasticity is the ability of a suture to return to its original length and shape after stretching, an important factor to consider in relation to the resulting edema associated with surgery. The

**Box 37-2** Innervation of muscles of facial expression via cranial nerve VII (facial nerve)**Temporal branch**

Frontalis muscle (m.)  
 Corrugator supercilii m.  
 Orbicularis oculi m. (upper portion)  
 Auricular m. (anterior and superior; also known as temporoparietalis m.)

**Posterior auricular branch**

Occipitalis m.  
 Auricular m. (posterior)

**Zygomatic branch**

Orbicularis oculi m. (lower portion)  
 Nasalis m. (alar portion)  
 Procerus m.  
 Upper lip muscles

- Levator anguli oris m.
- Zygomaticus major m.

**Buccal branch**

Buccinator m. (muscle of mastication)  
 Depressor septi nasi m.  
 Nasalis m. (transverse portion)  
 Upper lip muscles

- Zygomaticus major and minor muscles
- Levator labii superioris m.
- Orbicularis oris m.
- Levator anguli oris m.

Lower lip muscles (orbicularis oris m.)

**Marginal mandibular branch**

Lower lip muscles

- Orbicularis oris m.
- Depressor anguli oris m.
- Depressor labii inferioris m.
- Mentalis m.

Risorius m.  
 Platysma m. (upper portion)

**Cervical branch**

Platysma m.

**Box 37-3** Cutaneous surgical instruments and supplies

- Scalpel handle (flat No. 3)
- Blade (No. 15)
- Needle holder (appropriate size)
- Sharp curved iris scissors, tissue-cutting scissors
- Blunt undermining scissors
- Skin hook (dull-tipped, two to four prongs)
- Hemostats
- Forceps (1 × 2 teeth, with suture platform)
- Skin preparatory scrub in sterile basin
- Sterile towels
- Sterile gauze and cotton-tipped swabs
- Hyfrecator cover
- Suture
- Suture scissors
- Blade remover

**Table 37-3** Examples of common skin suture material

Material	Type
<b>Absorbable</b>	
Gut (chromic, plain)	twisted
Polyglycolic acid (Dexon)	braided
Polyglactin 910 (Vicryl)	braided
Polydioxanone (PDS)	monofilament
Polytrimethylene carbonate (Maxon)	monofilament
Poliglecaprone 25 (Monocryl)	monofilament
Glycomer 631 (Biosyn)	monofilament
<b>Nonabsorbable</b>	
Silk	braided
Nylon (Ethilon, Dermalon)	monofilament
Nylon (Surgilon, Nurolon)	braided
Polypropylene (Prolene, Surgipro)	monofilament
Polyester (Ethibond, Mersilene, Dacron)	braided
Polybutester (Novafil)	monofilament

coefficient of friction is the ease with which the suture slides through tissue and is directly related to knot security. Capillarity is the ability of the suture to wick away fluid, with braided sutures having an increased tendency to trap fluid and bacteria. All have appropriate applications.

In general, for procedures requiring buried suture, a synthetic braided suture is a common choice. The 50% tensile strength for this class of suture is about 3 months, and this suture is less palpable under the skin. For these reasons, synthetic braided sutures are often used across all anatomic locations. For procedures on the trunk and extremities (i.e., areas under tension), a monofilament absorbable suture may be considered, because the tensile strength may last longer than with synthetic braided suture, and reports indicate decreased incidence of “spitting” suture. The thicker skin in the trunk and extremities may hide the palpability of monofilament absorbable suture, making it more acceptable to patients. Epidermal approximation in more delicate areas is more appropriately closed with smaller, 5-0 or 6-0 sutures, whereas 4-0 or 3-0 sutures are used in more high-tension areas (e.g., trunk, extremities). Absorbable sutures (e.g., gut) may be considered in sensitive areas where suture removal may be painful or difficult (e.g., eyelids) or in children. Facial sutures are often taken out in 4-7 days to decrease the risk of forming track marks from epithelialization of the suture puncture site, whereas sutures on the scalp, neck, and body are often left in for about 2 weeks. Running subcuticular sutures can be left in for 3 weeks to add tensile strength to wounds without the risk of suture marks. Surgical staples can be used on locations such as the scalp to accommodate the higher tension and avoid pulling hair into the wound. Staples can be applied more quickly than traditional suturing and can provide good wound eversion to facilitate healing.

Cyanoacrylates are liquid tissue adhesives that rapidly polymerize when applied to the skin. These adhesives are easy to apply, avoid suture marks, minimize postoperative wound care, and eliminate the need to return to the clinic for suture removal. *N*-butyl-2-cyanoacrylate (Indermil; Synture, Norwalk, CT) and octylcyanoacrylate (Dermabond; Ethicon, Bridgewater, NJ) are the more frequently used adhesives. The longer length of the side chain of octylcyanoacrylate has been



shown to be stronger and more flexible when applied. Studies report various results compared with traditional sutures. As such, care must be taken in choosing the right clinical situations to use these products.

**Coulthard P, et al:** Tissue adhesives for closure of surgical incisions. *Cochrane Database Syst Rev* 2010; (5):CD004287.

**Regan T, Lawrence N:** Comparison of poliglecaprone-25 and polyglactin-910 in cutaneous surgery. *Dermatol Surg* 2013; 39(9):1340–1344.

**Snizek PJ, et al:** A randomized controlled trial of high-viscosity 2-octyl cyanoacrylate tissue adhesive versus sutures in repairing facial wounds following Mohs micrographic surgery. *Dermatol Surg* 2007; 33(8):966–971.

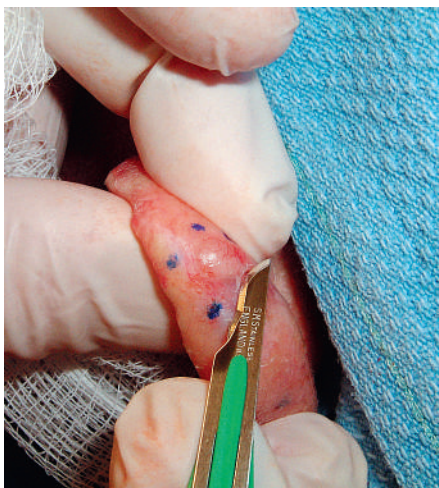**Tajirian AL, Goldberg DJ:** A review of sutures and other skin closure materials. *J Cosmet Laser Ther* 2010; 12(6):296–302.

**Tierney EP, et al:** Rapid absorbing gut suture versus 2-octylethylcyanoacrylate tissue adhesive in the epidermal closure of linear repairs. *J Cosmet Laser Ther* 2010; 12(6):296–302.

## BIOPSIES

When performing a skin biopsy, the clinician should consider the lesion characteristics, reason for biopsy (diagnostic vs. cosmetic), and site. Shave biopsies can range from a superficial scissor snip of an epidermal growth to deep shave excisions of papillary dermal processes. Punch biopsies are most often used for dermal lesions, sampling deeper than shave biopsies, but requiring sutures. Excisional biopsies remove an entire clinical lesion and are the biopsy of choice for pigmented lesions suspicious for melanoma. Incisional biopsies remove a portion of a clinical lesion and are often performed on larger plaques or patches when an excisional biopsy is not cosmetically acceptable or feasible. A wedge biopsy is a deep incisional biopsy that can sample pathologic tissue and adjacent normal tissue; it is especially useful for pathologic diagnosis of certain inflammatory conditions (e.g., panniculitis, fasciitis).

Shave biopsies are best suited for pedunculated, papular, or otherwise exophytic lesions (see Video 37-1). Using a deep or rolled shave, samples can also be obtained of macular or indurated lesions, provided the necessary histologic changes reside in the epidermis or papillary dermis. Infiltration of local anesthesia distends and elevates the lesion, increases skin turgor, affords greater resistance to the blade, and facilitates undercutting the lesion. Using either a No. 15 blade scalpel or a razor blade, which can be flexed to achieve the desired depth, a horizontal incision is made and the lesion removed with sweeping strokes (Fig. 37-4). Hemostasis is typically attained with topical application of 35% aluminum chloride solution.



**Fig. 37-4** Shave biopsy. Lesion is pinched up with thumb and finger and biopsy performed with sweeping strokes.

Sharp scissor biopsy is best suited for pedunculated lesions. Iris or Gradle scissors are used to snip the base of the lesion. In many cases, this can be done without anesthesia. Chemical hemostasis, electrocautery, or simple pressure can be used to control bleeding.

The dermatologic punch is frequently used for both excisional and incisional biopsies (Fig. 37-5; also see Video 37-2). When performing a punch biopsy, the skin should be stretched perpendicular to the relaxed skin tension lines. The elliptical wound resulting from the release of the tension can be suture-closed in a linear fashion, without redundancy or puckering associated with circular wounds. The punch is placed on the skin perpendicular to the surface. While the surgeon applies gentle pressure, it is rotated back and forth and advanced to the hub. The specimen is carefully grasped to avoid crush artifact, and the base is cut. Sutures are typically placed to achieve hemostasis, but punch sites that are allowed to heal by second intention have been shown to heal with a similar cosmetic outcome.

A variation of the punch biopsy can be used to remove larger subcutaneous nodules. Narrow-hole extrusion is a surgical technique that uses a punch biopsy to make a small cutaneous portal through which larger benign growths (e.g., lipoma) can be extruded (Fig. 37-6; also see Video 37-3). This technique allows the evacuation of large subcutaneous growths with a relatively small surface incision.

## Suture technique

Proper suture placement is essential to obtain the desired final result. Sutures are used to close any dead space, reduce bleeding, provide tensile strength and minimize tension to facilitate wound healing, and achieve epidermal wound approximation to maximize cosmetic outcome. Instrumented knots are the most common sutures used in dermatologic surgery. Various suturing techniques can be employed, based on factors such as size, anatomic location, and thickness of the surgical wound.

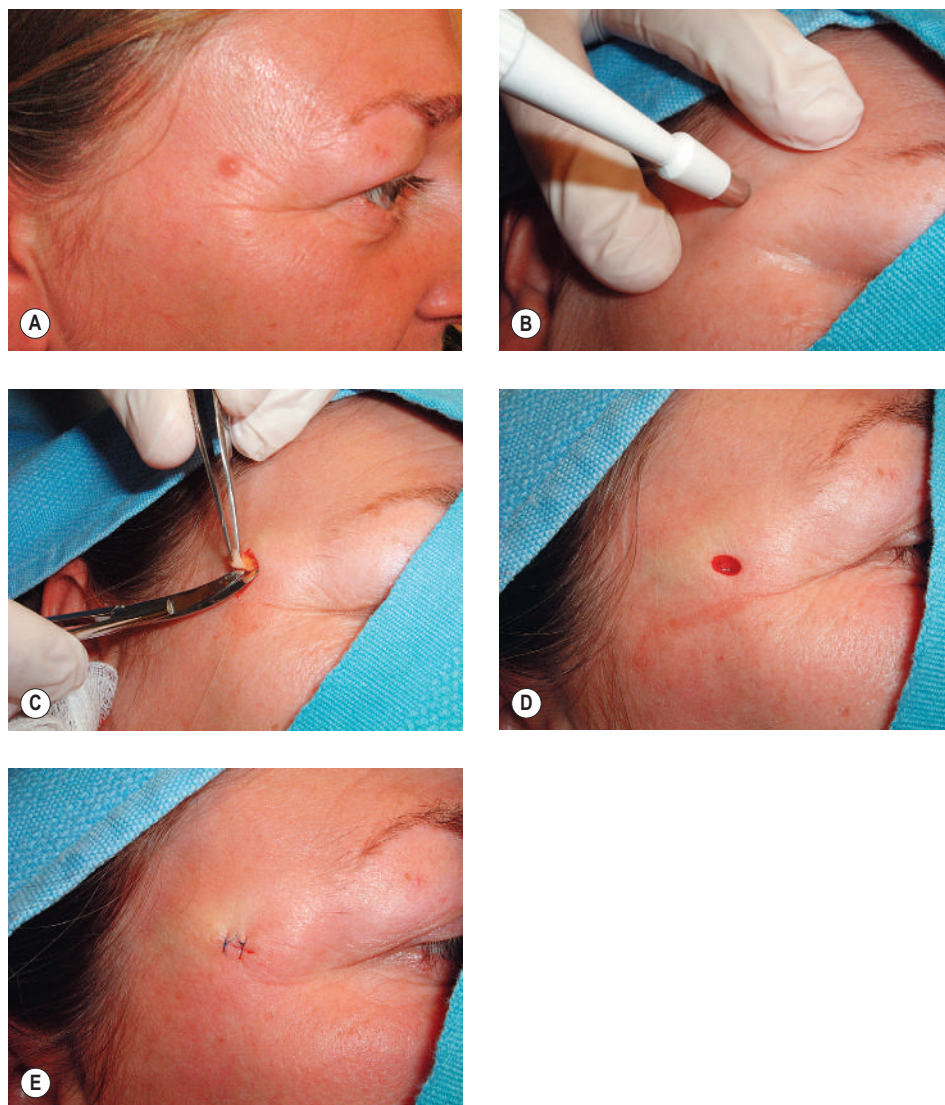
Buried subcutaneous sutures are used for larger or deeper wounds to reduce the risk of wound dehiscence. Proper placement is key to achieving eversion of the wound edges and decreasing tension (Fig. 37-7). The stitch is in the dermis and fat, with the knot cut short and buried to reduce tissue reaction and “spitting” sutures.

Simple epidermal interrupted sutures are one of the most versatile stitches used in dermatology. These are best used for closure of small punch biopsies or for larger, layered excision or flap repairs. Interrupted sutures are especially useful in high-tension wounds; a single suture can be removed, and the surgeon can assess the wound for any dehiscence. For wound edges with a step-off from the opposing epidermal edges, the surgeon places the suture more superficially at the higher side and deeper on the lower side to even the edges (Fig. 37-8).

The vertical mattress suture is useful for reducing tension, closing dead space, and achieving wound eversion (Fig. 37-9). It can function as both the buried and the superficial suture. Because it tends to leave track marks and strangulate the skin, the vertical mattress suture must be used strategically and removed sooner than traditional sutures.

The horizontal mattress suture reduces tension and can be used as a retention suture when attempting to close larger wounds (Fig. 37-10). It can cause strangulation and necrosis of poorly vascularized tissue and should be used with caution when closing flaps.

Running sutures can be used for epidermal closure in wounds under minimal tension and with closely approximated wound edges. Placement is much faster than with simple interrupted sutures because knots are only used at each



**Fig. 37-5** Punch biopsy. A, Lesion to be removed. B, Skin stretched perpendicular to relaxed skin tension lines and punch inserted with twisting motion. C, Specimen is carefully grasped and removed. D, Resultant elliptical defect. E, Sutures in place.

end of the wound. The running locked suture is a variant of the simple running suture and involves passing the needle through the previous loop (Fig. 37-11). This technique creates pressure along the wound edge and can be used in highly vascularized regions for additional hemostasis.

Running subcuticular sutures typically use a nonabsorbable suture and are used for trunk and extremity closures where sutures are left for 2–3 weeks. Since the suture is buried, it can be left in place for a longer period without developing cross-hatch marks (Fig. 37-12). A single loop coming out in the middle of larger wounds can help facilitate removal of the suture. Alternatively, absorbable suture can be used and can eliminate the need for removal.

**Christenson LJ, et al:** Primary closure vs second-intention treatment of skin punch biopsy sites: a randomized trial. *Arch Dermatol* 2005; 141(9):1093–1099.

**Kronic AL, et al:** Running combined simple and vertical mattress suture: a rapid skin-everting stitch. *Dermatol Surg* 2005; 31(10):1325–1329.

**Lee KK, et al:** Surgical revision. *Dermatol Clin* 2005; 23(1):141–150; vii.

**Moy RL, et al:** A review of sutures and suturing techniques. *J Dermatol Surg Oncol* 1992; 18(9):785–795.

## CRYOSURGERY

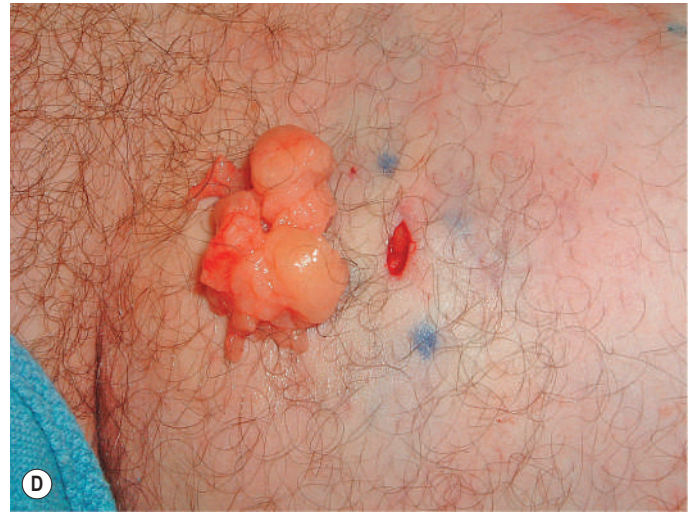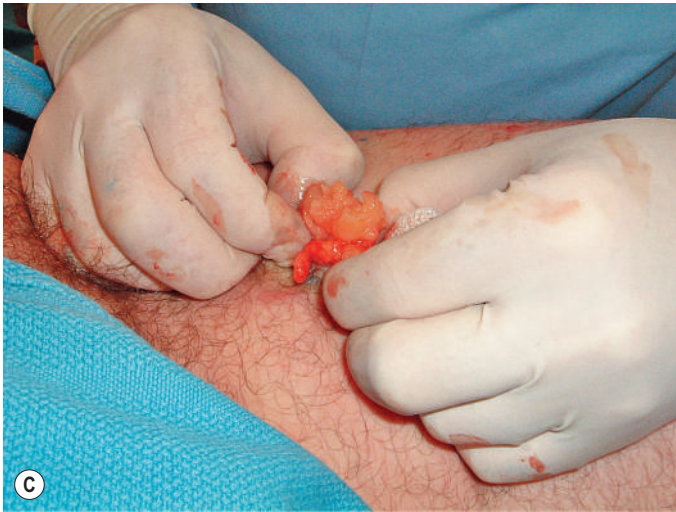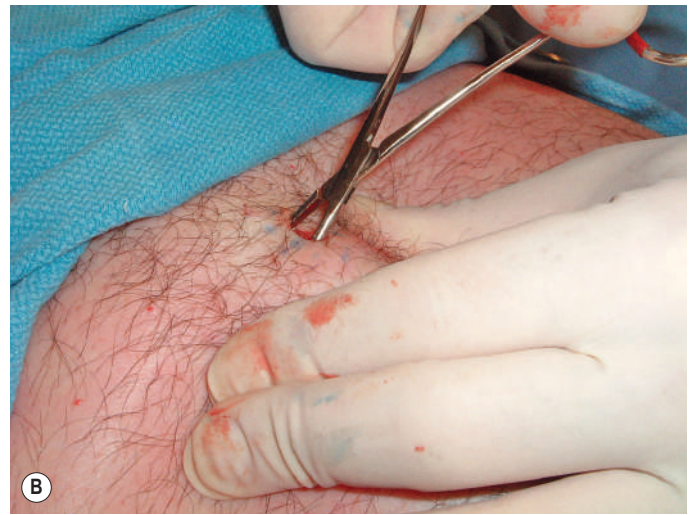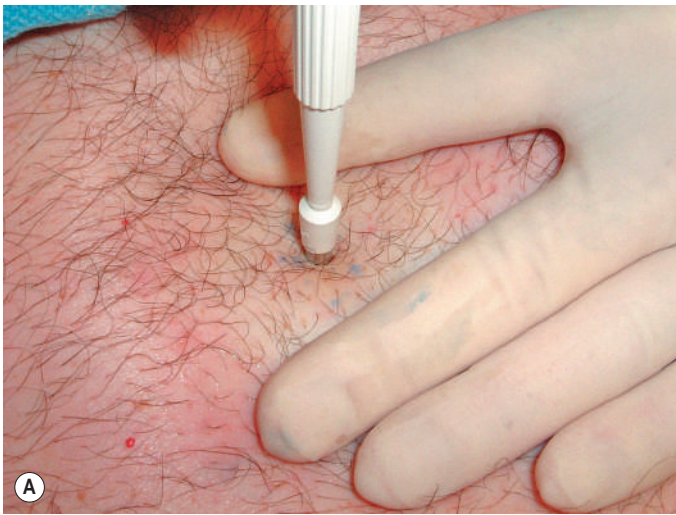
Cryosurgery is used for the treatment of numerous benign, premalignant, and malignant skin lesions. Most dermatolo-

gists employ cryosurgery extensively because it is easy to use, cost-effective, and versatile. Postoperative wound care is relatively simple, and complications are uncommon. Although a number of cryogenes have been used (e.g., ethyl chloride, CO<sub>2</sub>, NO), liquid nitrogen, with a boiling point of  $-195.6^{\circ}\text{C}$ , is most widely utilized.

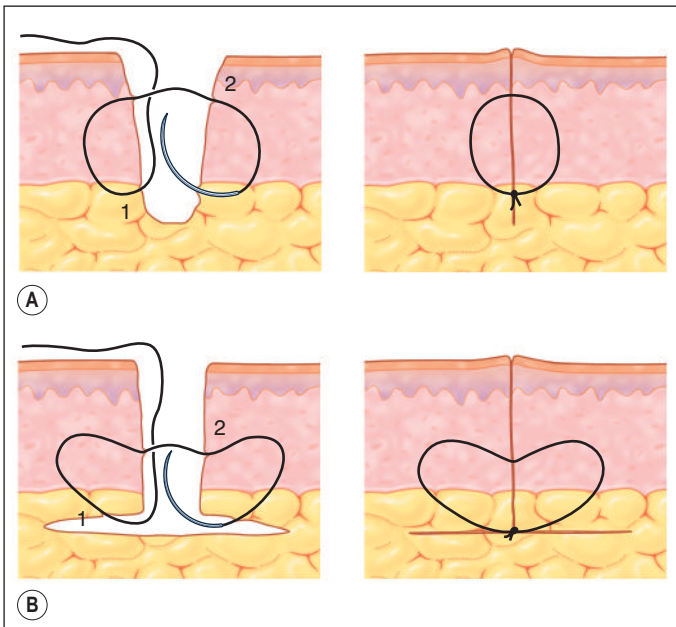
The mechanism of injury in cryosurgery is the result of multiple factors, including mechanical damage to cells resulting from intracellular and extracellular ice crystal formation, exposure to high electrolyte concentrations in surrounding nonfrozen or thawing fluid, recrystallization patterns during thaw, and ischemia caused by vascular stasis and damage. Rapid freezing causes intracellular ice crystals that are more destructive than the extracellular crystals formed during slow freezing. Tissue damage is maximized with a slow thaw time, which causes increased solute gradients and greater cell destruction. Multiple freeze-thaw cycles can further increase damage to the target lesion.

There are several techniques for cryosurgery. The simplest is the use of a cotton-tipped applicator. Varying the amount of pressure applied and duration of contact of the applicator to the skin can control the depth of freeze. Additionally, the volume of liquid nitrogen can be increased or decreased by adding or removing cotton from the applicator tip. Viruses have been shown to survive in liquid nitrogen, so cotton-tipped applicators should never be reintroduced to the storage container. Rather, a small amount of liquid nitrogen

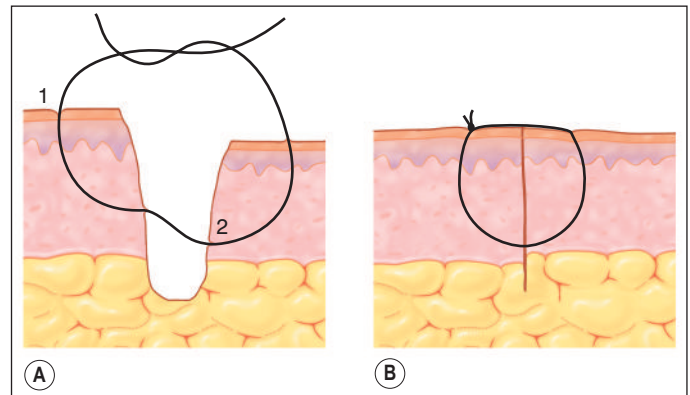




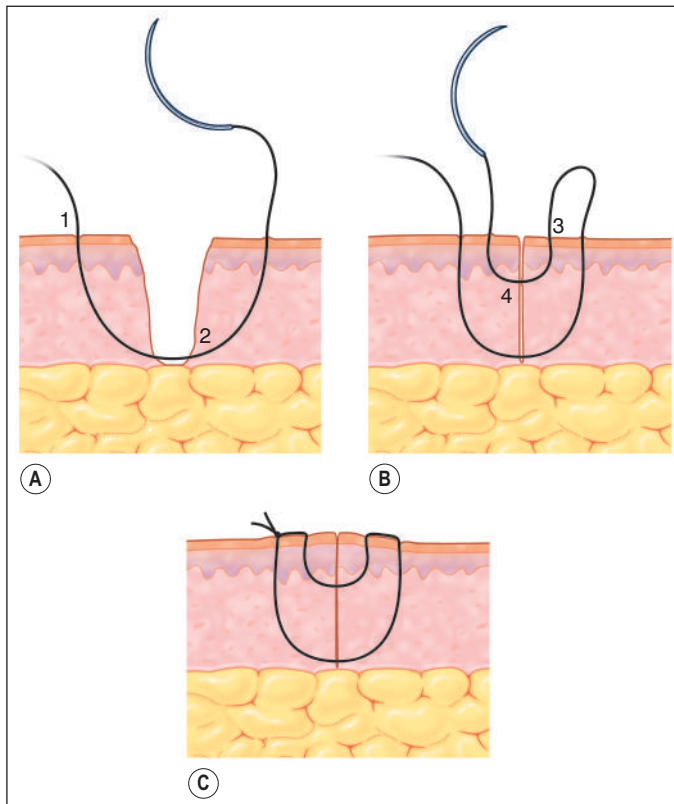
**Fig. 37-6** Narrow-hole extrusion of lipoma. A, The 4-mm punch is in center of lipoma. B, Hemostat used to loosen lipoma. C, Extrusion of lipoma through narrow hole. D, Entire lipoma removed.



**Fig. 37-7** Buried dermal sutures. Numbers indicate entry points of the needle. A, Conventional buried suture placement results in mild wound eversion. B, Buried vertical mattress suture placement results in moderate to significant wound eversion.



**Fig. 37-8** Step-off correction. A, To correct a step-off deformity, place a simple interrupted suture superficially on the higher wound edge (1) and deeply on the lower wound edge (2). Numbers indicate entry points of the needle. B, Tying this suture results in even wound edges.

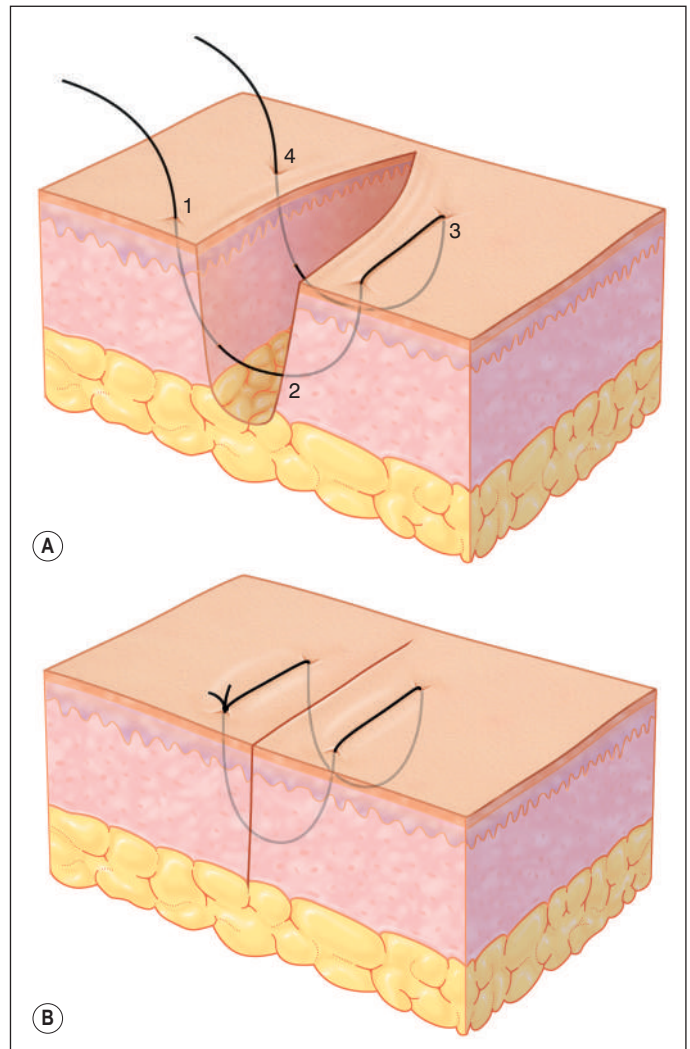


**Fig. 37-9** Placement of vertical mattress stitch. A, The needle is placed 5–10 mm from the wound edge, and a deeply seated simple interrupted suture is placed (1) (2). Numbers indicate entry points of the needle. B, The needle is redirected back across the wound more superficially, penetrating the skin edge 2–4 mm from the wound on both sides (3). C, Final appearance of this suture after tying.

should be transferred to an individual container and discarded after use.

Spray application is one of the most common methods of cryosurgery. This technique uses a handheld liquid nitrogen spray unit with an adjustable nozzle to vary the size of the stream delivered. An insulating cone or a disposable otoscope speculum can be used to focus the delivery of liquid nitrogen, resulting in a deeper freeze and finer control with less damage to uninvolved skin (Fig. 37-13).

Basal cell carcinomas (BCCs) can be treated with cryosurgery. However, alternative surgical options are more routinely performed for the treatment of BCCs given the cure rates obtained, tolerance of the procedure, and aesthetic outcomes achieved. Freezing to reach a target temperature of approximately  $-50^{\circ}\text{C}$ , as measured by a thermocouple, is appropriate for management of these tumors. This translates to a thaw time of approximately 60 sec, with a freeze margin of approximately 5 mm (Fig. 37-14). It is important to recognize that the pain associated with such treatment requires local anesthesia. Kokoszka and Scheinfeld found a recurrence rate of less than 10% for primary small, noninfiltrating (superficial and nodular) BCC treated with cryosurgery. Some have suggested that initially treating the tumor with curettage, followed by cryosurgery, can lead to cure rates consistent with curettage and electrodesiccation. However, Kuijpers et al. suggested that standard excision provides higher cure rates than curettage and cryosurgery and recommend that excision be used as the preferred treatment for BCC, because of the higher cure rate, better cosmetic outcome, and faster healing.

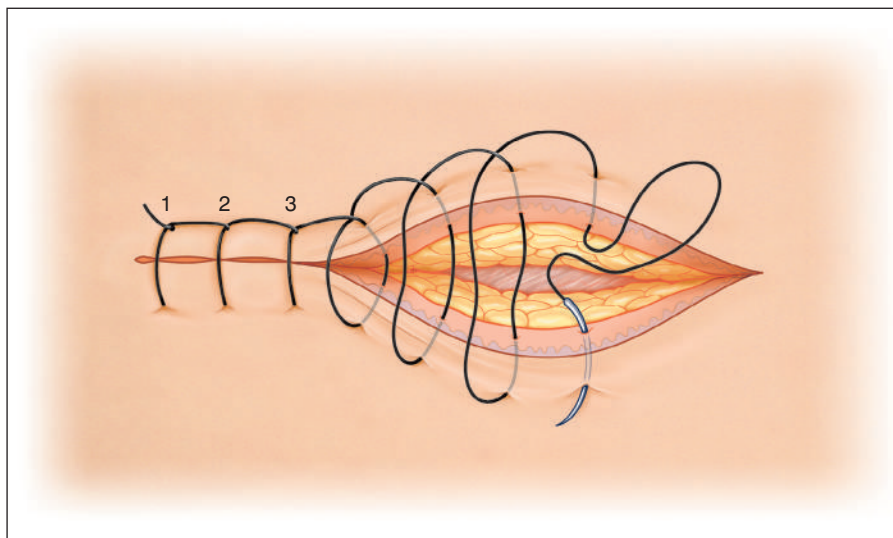


**Fig. 37-10** Horizontal mattress suture. A, To place this suture, begin with a widely spaced, simple interrupted suture (1) (2). Numbers indicate entry points of the needle. Move laterally down the wound 3–5 mm, and place another interrupted suture in the opposite direction as the first (3) (4). B, Appearance of this suture when tied.

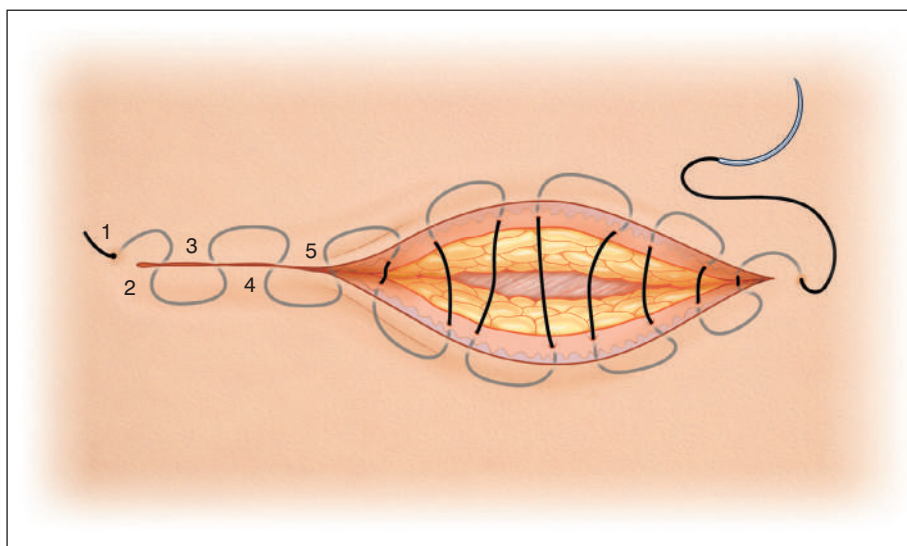
Side effects of cryosurgery are similar to those of other ablative procedures (e.g., curettage and electrodesiccation) and include blistering, crusting, pain, a 3- to 4-week healing period, and scarring. Because melanocytes are more susceptible to thermal damage than keratinocytes, hypopigmentation can often be seen, especially in individuals with darker skin tones. Although more frequently seen with longer freeze-thaw times, pigment alterations can be observed even with very brief treatment cycles. A self-limited hyperplastic or pseudoepitheliomatous healing response may occur approximately 2–4 weeks after freezing. Nerve injury can occur during cryosurgery. Anatomic locations with superficial nerves (e.g., lateral aspects of fingers, ulnar groove of elbow, preauricular and postauricular skin) are especially susceptible to this complication. Techniques to limit this risk include tenting the skin up and away from the nerve, ballooning the skin with lidocaine, or sliding the skin back and forth over the underlying fascia during treatment to limit exposure to the underlying nerve. Alopecia can occur when treating hair-bearing areas. Both atrophic and hypertrophic scars can be seen after cryosurgery.

**Kokoszka A, Scheinfeld N:** Evidence-based review of the use of cryosurgery in treatment of basal cell carcinoma. *Dermatol Surg* 2003; 29:566.

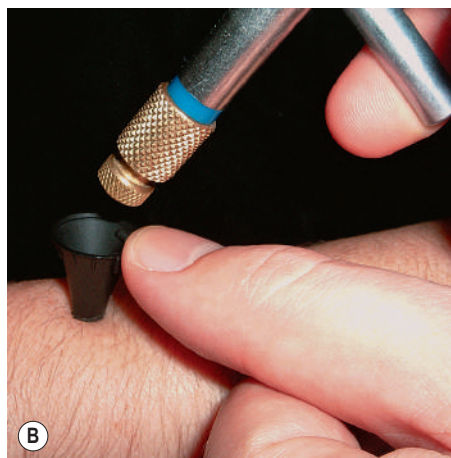
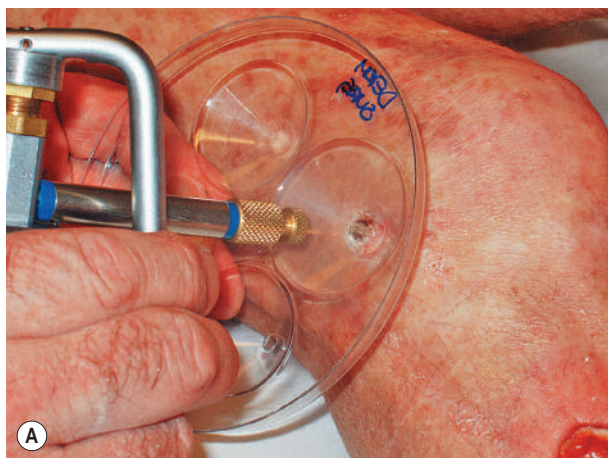




**Fig. 37-11** Running block suture. A running simple suture is placed, passing the needle through the loop created by the last suture. This locking suture facilitates hemostasis. Numbers indicate entry points of the needle.



**Fig. 37-12** Running subcuticular suture. Multiple horizontally placed dermal sutures are placed in succession on alternating wound edges. This results in epidermal and dermal closure without visible suture marks. Numbers indicate entry points of the needle.



**Fig. 37-13** A, Cryoplate with multiple-sized openings. B, Disposable otoscope speculum with tip cut off.

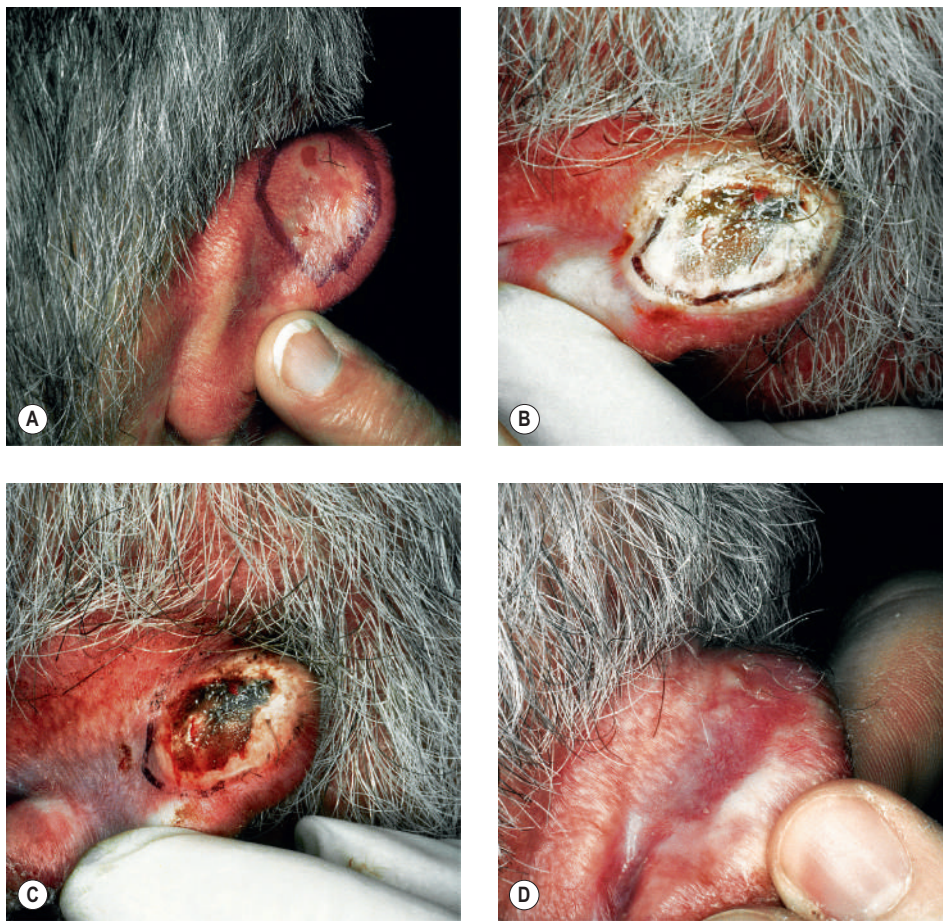
**Kuijpers DI, et al:** Surgical excision versus curettage plus cryosurgery in the treatment of basal cell carcinoma. *Dermatol Surg* 2007; 33:579–587.

**Lindemalm-Lundstam B, Dalenbäck J:** Prospective follow-up after curettage-cryosurgery for scalp and face skin cancers. *Br J Dermatol* 2009; 161:568–576.

**Nordin P:** Curettage-cryosurgery for non-melanoma skin cancer of the external ear: excellent 5-year results. *Br J Dermatol* 1999; 140:291.

## CURETTAGE

The curette has long been a standard tool in the dermatologist's surgical management of neoplasm. This round, semisharp knife is available in sizes from 0.5 to 10 mm, allowing for the removal of a variety of lesions. Since it is not as sharp as a scalpel, the curette does not easily cut through normal skin. Therefore, it is best suited for use on soft or friable lesions,



**Fig. 37-14** Cryosurgery. A, Basal cell carcinoma on the posterior helix. B, Cryosurgery to neoplasm. C, One week later, with necrosis and sloughing of treatment area. D, Final result several months later.

such as warts, seborrheic and actinic keratoses, the papules of molluscum contagiosum, and select BCCs and squamous cell carcinomas (SCCs). The proper selection of lesion, location, and size of the curette, combined with the surgeon's technique, all play a role in both the therapeutic and the cosmetic outcome.

The skin should be stabilized with the nondominant hand while the curette is held like a pencil. Curettage should be performed in a centripetal manner (from the outside in) to avoid stripping sun-damaged skin and creating a larger wound. To ensure complete destruction, curettage should be performed in multiple directions to produce symmetric wound margins. A large curette can be used for initial debulking, followed by a smaller curette to remove any residual foci or extensions. Curettage is complete when the "gritty," firm sensation of normal dermis is felt, and slight punctate dermal bleeding occurs.

Curettage combined with electrodesiccation (C&E) is widely used for the treatment of BCC and SCC (Fig. 37-15). Silverman et al. reviewed the cure rates of primary BCC treated with C&E over a 27-year period at New York University, stratifying low-, middle-, and high-risk anatomic locations and the risk of recurrence after C&E of primary BCC. Low-risk anatomic sites (neck, trunk, and four extremities) had a 5-year recurrence rate of 3.3%. Middle-risk sites (scalp, forehead, pre-/postauricular, and malar areas) had an overall recurrence rate of 12.9%, but this was reduced to 5% when limited to noninfiltrative carcinomas of less than 1 cm. High-risk sites (nose, paranasal, nasolabial groove, ear, chin, mandibular, perioral, and periocular areas) had an overall recurrence rate of 17.5%, but a more acceptable 5% recurrence rate was achieved when treatment was limited to lesions of less than 6 mm.

In addition to size and anatomic location, the histologic subtype is an important factor in the effectiveness of C&E. Infiltrative and micronodular BCCs are not appropriate for C&E, whereas it can be considered a therapeutic option in superficial and nodular subtypes. Blixt et al. demonstrated that tumors with high-risk histologic subtypes (e.g., infiltrating, micronodular, desmoplastic) had overall recurrence rates of 27% when treated with C&E alone. SCC in situ may be appropriately treated with C&E, although in most circumstances, invasive SCC would not typically be amenable to this modality.

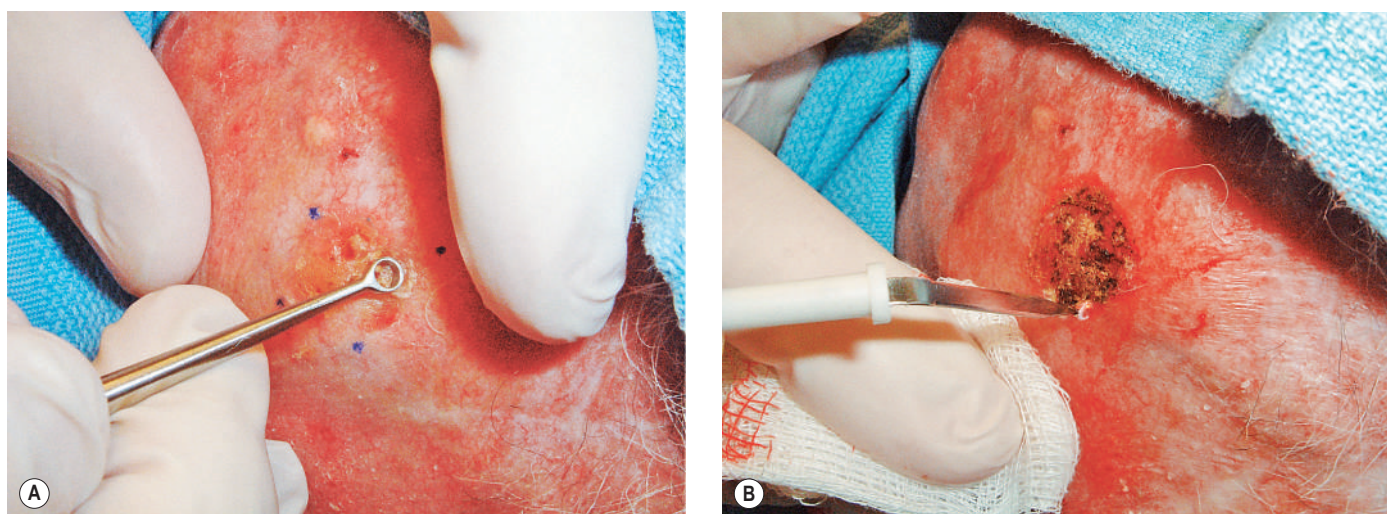
There is little agreement regarding the requisite number of cycles of C&E. In fact, treating all lesions identically with a particular number of cycles may lead to overtreatment of some lesions and undertreatment of others. In general, accepted therapy employs three cycles to treat most malignant lesions. However, smaller superficial malignancies may be treated with fewer cycles; the rationale is to improve cosmetic outcome while still achieving acceptable cure rates. Nonetheless, the success of C&E relies on the surgeon's ability to identify by feel and appearance the tissue to be ablated. Finally, C&E should be replaced by excision if curettage extends into subcutaneous tissue. As such, lesions previously biopsied using a punch that has extended into the subcutaneous fat may be less amenable to C&E.

**Barlow JO, et al:** Treatment of basal cell carcinoma with curettage alone. *J Am Acad Dermatol* 2006; 54(6):1039–1045.

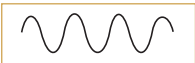



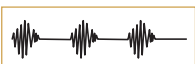


**Blixt E, et al:** Recurrence rates of aggressive histologic types of basal cell carcinoma after treatment with electrodesiccation and curettage alone. *Dermatol Surg* 2013; 39(5):719–725.

**Goldman G:** The current status of curettage and electrodesiccation. *Dermatol Clin* 2002; 20:569.





**Fig. 37-15** Curettage and electrodesiccation. A, Curettage of squamous cell carcinoma in situ. B, Electrodesiccation immediately after curettage.

60Hz Alternating current		Unaltered sine wave	
<b>Spark gap circuit</b>			
Modality	Electrode configuration		Waveform
Electrodesiccation	Monoterminal	Markedly damped	
Electrofulguration	Monoterminal	Markedly damped	
Electrocoagulation	Biterminal	Moderately damped	
<b>Electronic circuit</b>			
Modality	Electrode configuration		Waveform
Electrocoagulation	Biterminal	Partially rectified	
Electrosection, with coagulation	Biterminal	Fully rectified	
Electrosection, pure cutting	Biterminal	Fully rectified, filtered	

**Fig. 37-16** Electrosurgery waveforms.

**Rodriguez-Vigil T, et al:** Recurrence rates of primary basal cell carcinoma in facial risk areas treated with curettage and electrodesiccation. *J Am Acad Dermatol* 2007; 56:91-95.

**Silverman MK, et al:** Recurrence rates of treated basal cell carcinomas. Part 2. Curettage-electrodesiccation. *J Dermatol Surg Oncol* 1991; 17:720.

## ELECTROSURGERY

Electrosurgery comprises a variety of surgical techniques, applications, and apparatuses. In general, the tissue effect is created by heat delivered to or generated in the tissue as a result of an electric current. Various forms of electrosurgery are routinely used by dermatologists for applications such as destruction, hemostasis, excisions, and cosmetic procedures.

An understanding of the different modalities and their applications can improve surgical outcome (Fig. 37-16).

## Electrocautery

Electrocautery is most often performed today with battery-powered, handheld, disposable units. Direct current is passed through a metal treatment tip. Resistance to the flow of current causes heat to be generated, which can be adjusted by the intensity of the current. Hemostasis is achieved by direct heating of the tissue; no electric current passes through the patient. Therefore, this device may be considered in patients with implantable cardiac devices sensitive to electric current.

## Electrodesiccation and electrofulguration

Electrodesiccation (desiccate, “dry up”) and electrofulguration (*fulgur*, “lightning”) represent the most common uses of electrosurgery in dermatology. In electrodesiccation, the electrode tip is in contact with the tissue; with electrofulguration, a 1–2 mm separation between the tip and the tissue produces a spark. Electrodesiccation causes a deeper wound, whereas electrofulguration is more superficial.

A highly damped (decreasing amplitude) waveform of high voltage and low amperage is produced by a spark-gap generator. This is a monoterminal current, so a grounding electrode on the patient is not required. Electrodesiccation/fulguration produces superficial destruction, because the carbonization on the treated surface limits damage to deeper tissue.

This type of electrosurgery has numerous applications in the daily practice of dermatology. Superficial, small dermal tumors, such as syringomas or seborrheic keratoses, may be treated with electrodesiccation. Insertion of the fine, epilating needle into the tumor is followed by the application of low current until a surface bubbling occurs. The small amount of char is then removed with a curette, resulting in a smooth surface appearance. In addition, skin tags, warts, and fine telangiectases may all be effectively removed by this technique. Electrodesiccation or fulguration is typically employed in treatment of many BCCs and SCCs (see [Curettage](#)). It is also useful in excisional surgery to obtain hemostasis. The field must be dry, because the destruction by this current is superficial and will not be transmitted through blood.

## Electrocoagulation

Electrocoagulation employs moderately damped current with a lower voltage and higher amperage. The patient is incorporated into a biterminal circuit. Electrocoagulation causes greater tissue damage and deeper penetration than electrodesiccation or electrofulguration.

## Electrosection

Electrosection employs an undamped, low-voltage, high-amperage current in a biterminal manner. This technique has the advantage of cutting with simultaneous hemostasis. As such, it is used for bloodless excisional surgery of protuberant masses and growths, such as rhinophyma. There is vaporization of tissue with minimal heat spread. Extra care must be taken with this technique; maintaining an appropriate depth can be difficult, given the ease with which the device can cut through skin. When the device is properly used, fine surgical excisions can be produced, with minimal trauma to surrounding tissue and excellent hemostasis. Various handpiece attachments, including scalpels, needles, wire loops, and balls, can further adapt the instrument to the specific procedure.

Special care must be taken when using electrosurgery in a patient with a pacemaker or implantable cardioverter-defibrillator, especially if the procedure is performed within a few centimeters of the device. Although modern devices are better shielded and less likely to respond to external electrical interference, it is always prudent to deliver current in short bursts. The physician should also consider the use of electrocautery (heat only, no electrical transmission) or a bipolar device (current transmitted between two tips) when treating these patients. Yu et al. reviewed the use of electrosurgery in patients with cardiac devices.

**Howe N, Cherpelis B:** Obtaining rapid and effective hemostasis. Part II. Electrosurgery in patients with implantable cardiac devices. *J Am Acad Dermatol* 2013; 69(5):677.

**Matzke TJ, et al:** Pacemakers and implantable cardiac defibrillators in dermatologic surgery. *Dermatol Surg* 2006; 32:1155–1162.

**Rex J, et al:** Surgical management of rhinophyma: report of eight patients treated with electrosection. *Dermatol Surg* 2002; 28:347.

**Taheri A, et al:** Electrosurgery. Part 1. Basics and principles. *J Am Acad Dermatol* 2014; 70(4):591–604.

**Taheri A, et al:** Electrosurgery. Part 2. Technology, applications, and safety of electrosurgical devices. *J Am Acad Dermatol* 2014; 70(4):607–618.

**Voutsalath MA, et al:** Electrosurgery and implantable electronic devices: review and implications for office-based procedures. *Dermatol Surg* 2011; 37(7):889–899.

**Yu SS, et al:** Cardiac devices and electromagnetic interference revisited: new radiofrequency technologies and implications for dermatologic surgery. *Dermatol Surg* 2005; 31:932.

## EXCISIONAL TECHNIQUE

The fusiform or elliptical excision is the workhorse procedure used to treat invasive skin cancers, as well as benign skin lesions needing extirpation ([Fig. 37-17](#); also see Videos 37-4 and 37-5). The basic principle of the fusiform ellipse is excision of a specimen oriented with its longest axis along skin tension lines and its width not exceeding one third of its length. The ellipse can be curved in a crescentic or “lazy S” pattern to align the final scar better with skin tension lines. If the procedure is performed with the correct dimensions (usually a length/width ratio of 3:1) and a 30-degree angle at each pole, standing cutaneous cones at the two extremes of the excision are generally avoided. Standing cutaneous cones represent excess tissue bunching at the poles of a skin closure and should be “sewn out” or excised by triangulation or M-plasty, if needed. Undermining, using sharp or blunt dissection of the skin from underlying subcutaneous tissue, reduces wound tension and helps with wound edge eversion.

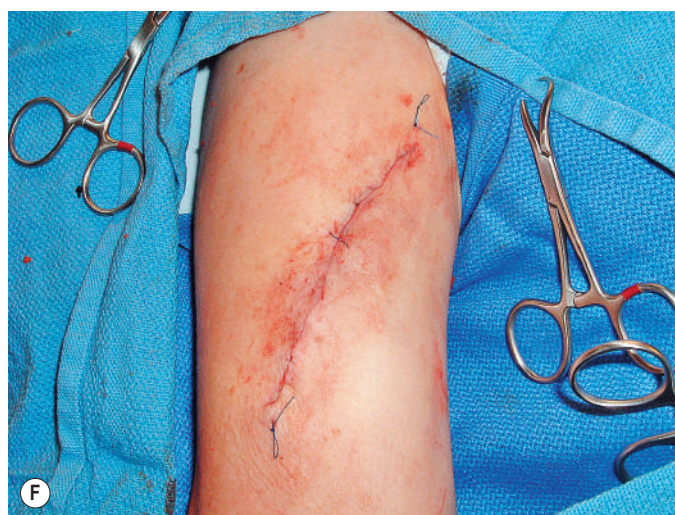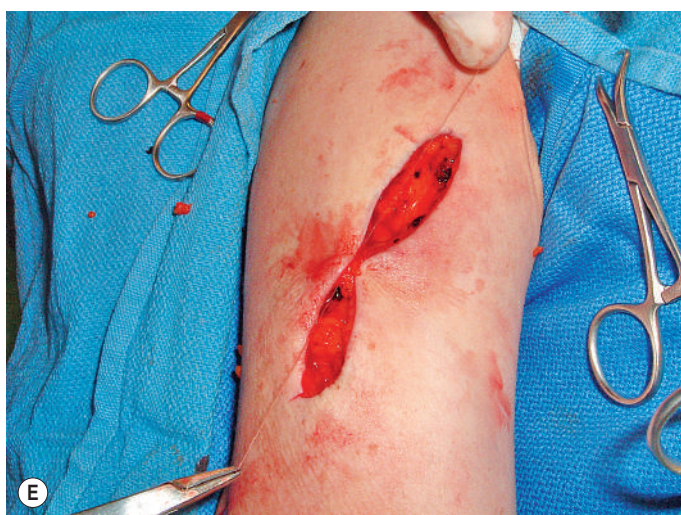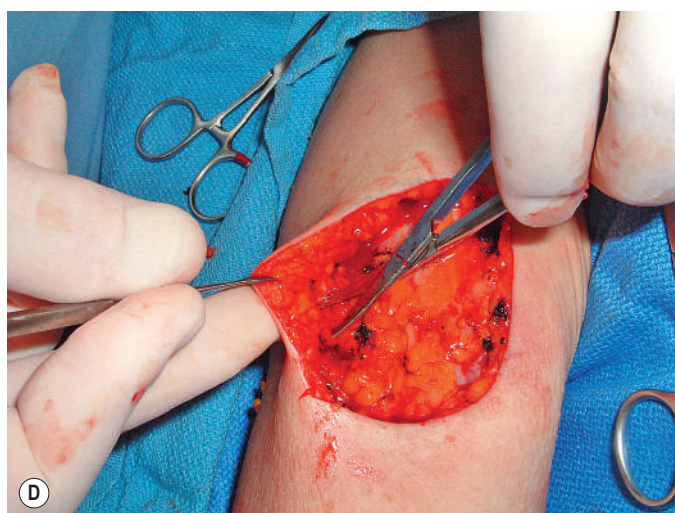
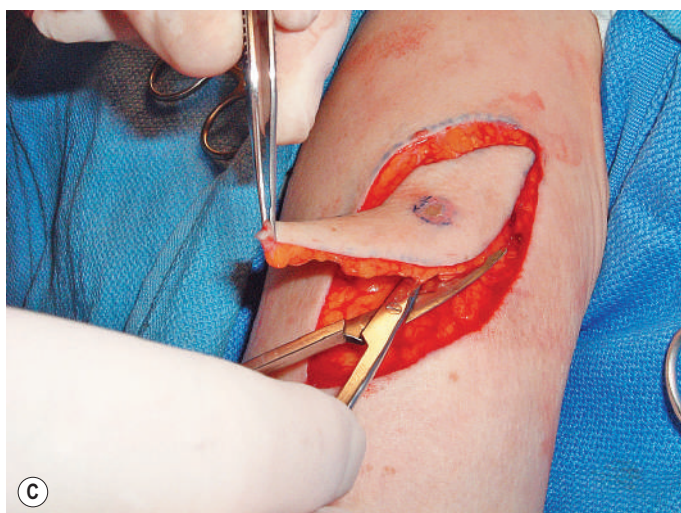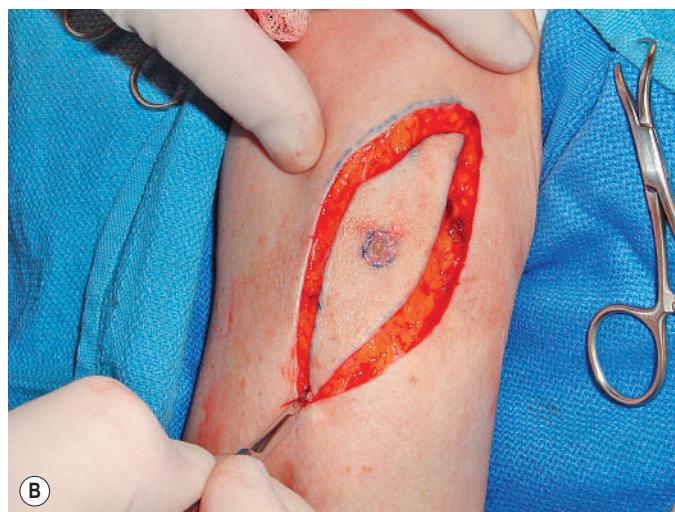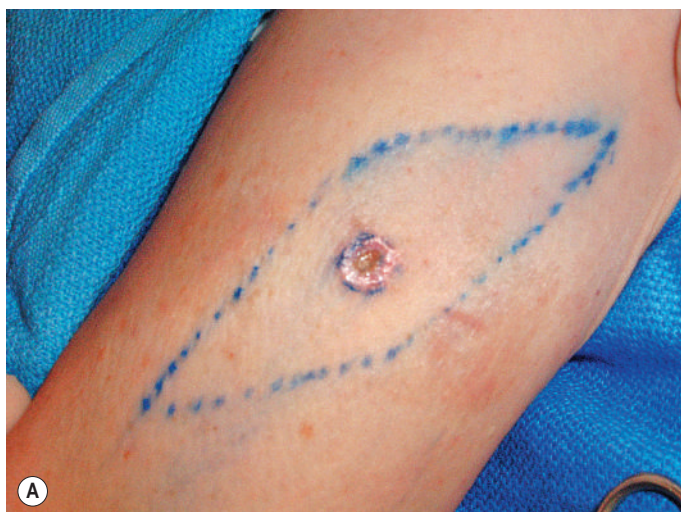## SKIN FLAPS AND GRAFTS

Choosing whether to close a wound by linear closure, local skin flap, or skin graft or to allow it to heal by second intention can be complex. Important considerations include patient concerns and ability to perform required wound care, local tissue movement, adjacent anatomic structural preservation and function, and cosmesis.

## Healing by second intention

Wound healing by second intention yields excellent results in select clinical settings. Because contraction occurs in wound healing, wounds adjacent to a free margin may result in a pull and distortion. This may affect surrounding anatomic structures (e.g., pull on a nasal rim or eyelid). The wounds may heal with hypertrophic or pigmentary changes. In some areas and situations, however, allowing a wound to heal by second intention is appropriate. These include superficial wounds in concave areas (e.g., medial canthus, conchal bowl, junction between nose and cheek), partial-thickness wounds involving the mucosa of the lip, or certain clinical situations, such as elderly or frail patients with decreased cosmetic concerns ([Fig. 37-18](#)). Wound care is straightforward, and postoperative restrictions are minimal.





**Fig. 37-17** Elliptical excision. A, Ellipse is designed along relaxed skin tension lines with a 3:1 length/width ratio. B, Incision made into subcutaneous tissue. C, Removal using tissue scissors in even plane. D, Blunt undermining of skin edges using skin hook. E, Buried interrupted tension-bearing absorbable sutures placed. F, Epidermal approximation using nonabsorbable running subcuticular sutures, with interruption in center of wound for easier removal.



## Flaps

Local skin flaps are geometric segments of tissue contiguous with a skin defect that are advanced, rotated, or transposed to close a wound. Advantages of flaps include better approximation of skin texture and color, hiding incision lines, redirecting tension vectors, and covering exposed cartilage and bone. Flap survival is based on the preservation of the random blood supply along the pedicle. Consideration of both the primary movement of the flap (actual movement of flap into defect)

and secondary movement (movement of surrounding tissue in reaction to flap movement) is critical when designing the repair (Fig. 37-19).

### Advancement flap

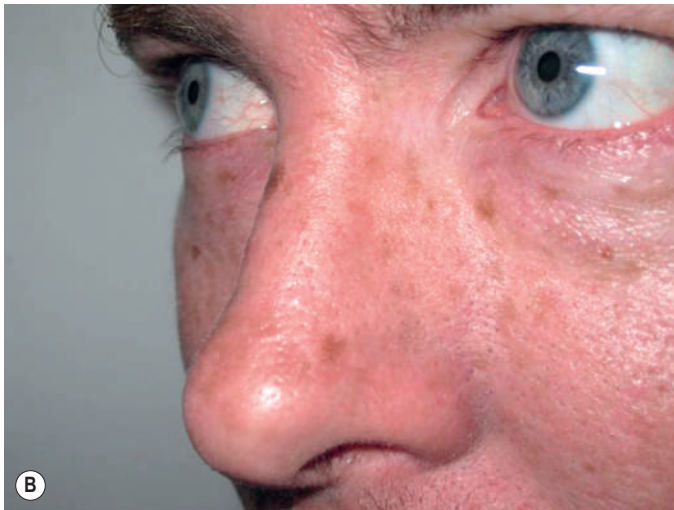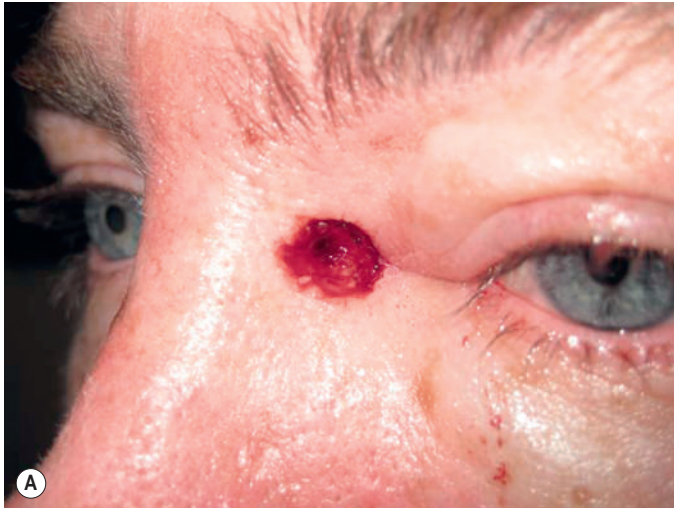
An advancement flap moves almost entirely in one linear direction (Fig. 37-20). The classic advancement flap involves the creation of a rectangular pedicle, which slides into position over the primary surgical defect. The key suture advances the flap and closes the primary defect. Tissue redundancies at the base of the flap can be removed by triangulation. Survival of the distal tip of the flap depends on blood supply from the base, and thus a maximum length/width ratio of 3:1 should be designed.

If insufficient movement is obtained with a single advancement flap, a bilateral advancement (O-H) can be employed, such that each flap advances to cover half the defect. This repair can be used in eyebrow or helical rim repairs. Single arm advancement flaps (O-L) and bilateral single arm advancement flaps (O-T) are similar to classic advancement flaps, except that only a single incision is made and the standing cone is removed by triangulation. These flaps have the advantage of a larger pedicle providing blood supply and allow a linear portion of the flap to be hidden in an existing rhytid for better cosmetic outcome. Common sites for single arm advancement flaps include the nasal side wall, helical rim, upper lip, forehead, and eyebrow.

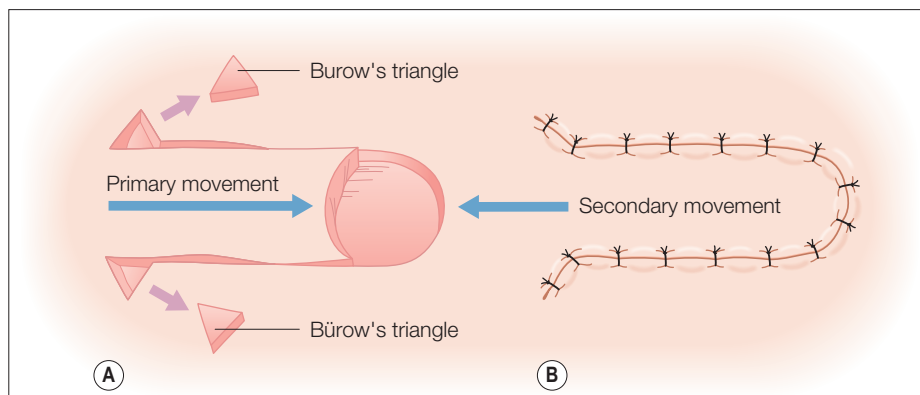
The island pedicle flap is a specific variant of an advancement flap (Fig. 37-21). This flap depends on a subcutaneous vascular pedicle for its blood supply and has all the epidermal connections severed by incisions. Care must be taken in designing island pedicle flaps because the incision lines surrounding the flap can result in a patchlike appearance in the final outcome. The best cosmetic results are achieved when at least one of the incision lines can be hidden in an existing rhytid or anatomic boundary.

### Rotation flap

The rotation flap can conceptually be considered a variation of the advancement flap, in that it slides into position in much the same way, although in an arcuate manner. Tension vectors from this pulling action are directed along the arc of rotation in reverse fashion (Fig. 37-22). Rotation flaps are often used to close large defects when there is insufficient tissue laxity (Fig. 37-23). The flap has the advantage of good survival secondary to the large pedicle and the ability to recruit skin from a great distance. A back cut can be used to reduce pivotal restraint and provide greater tissue movement, but this may compromise the vascular pedicle. Variations include bilateral rotation flap (O-Z) (Fig. 37-24) or dorsal nasal rotation flap (Fig. 37-25).

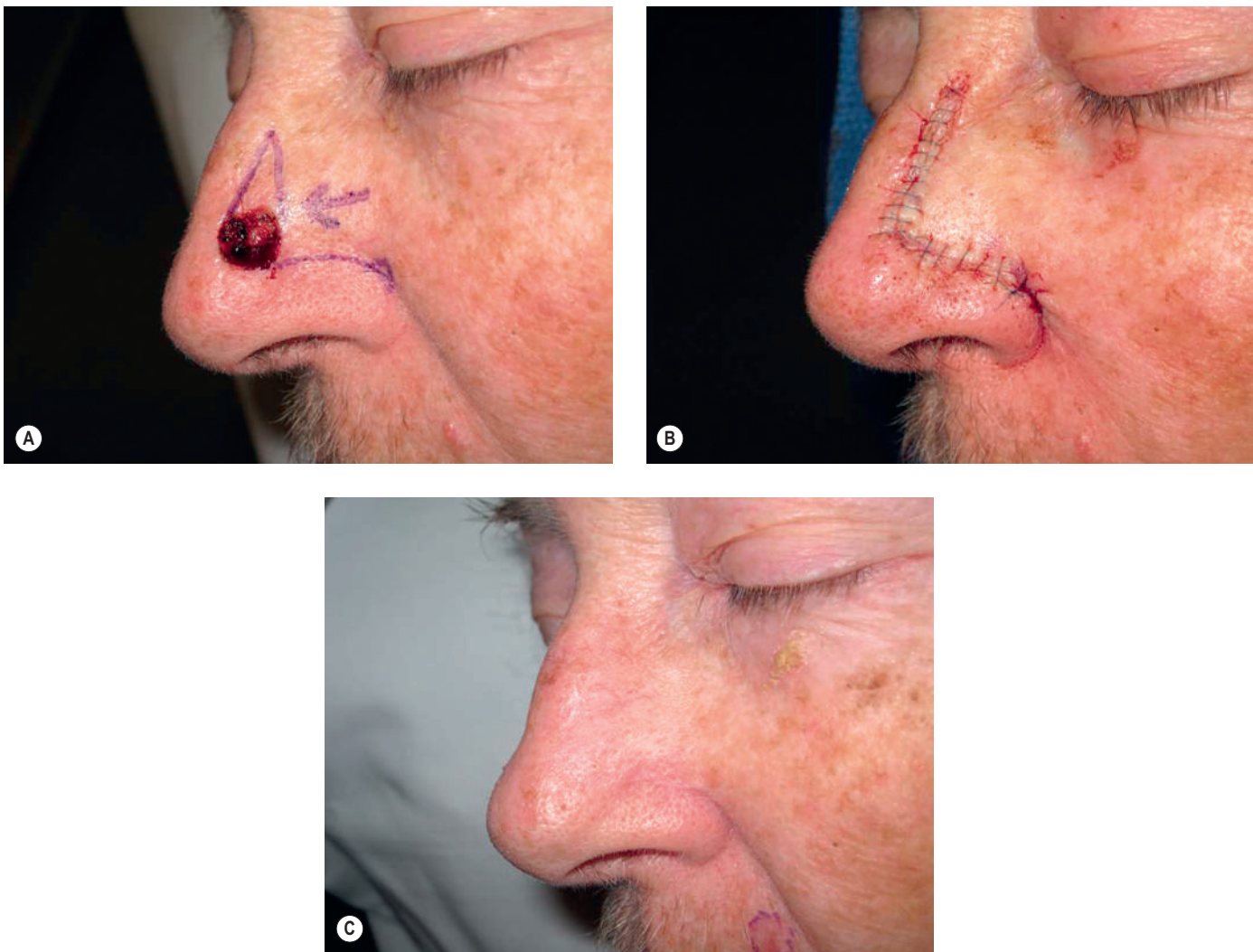


**Fig. 37-18** Healing by second intention. A, Mohs defect. B, Final result, 1 year later.



**Fig. 37-19** Advancement flap movement.





**Fig. 37-20** Single arm advancement flap. A, Advancement flap designed on nasal side wall. B, Final wound closure. C, Three months postoperatively.

## Transposition flaps

In the case of the transposition flap, the flap is elevated, transposed over intervening tissue, and sutured into the primary defect. The tension vector is redirected across the closure of the secondary defect (i.e., area originally occupied by flap). This is especially helpful for defects that are adjacent to anatomic free margins. The key suture closes the secondary defect, and the flap is then lifted and transposed into position over the primary defect. The prototype of this flap is the rhombic flap (Fig. 37-26). Other examples include bilobed flaps (Fig. 37-27), nasolabial/melolabial flaps, banner flap, Z-plasty, and Webster's 30-degree flap (Fig. 37-28; also see Video 37-6).

Choice of a particular type of flap involves multiple factors, including location of defect, availability of tissue movement, surrounding structures, effects of tissue movement, and blood supply. Full discussion of flaps is beyond the scope of this chapter and is available in multiple referenced texts. The successful design and execution of flap repairs can be complex and requires appropriate and extensive training.

## Z-plasty

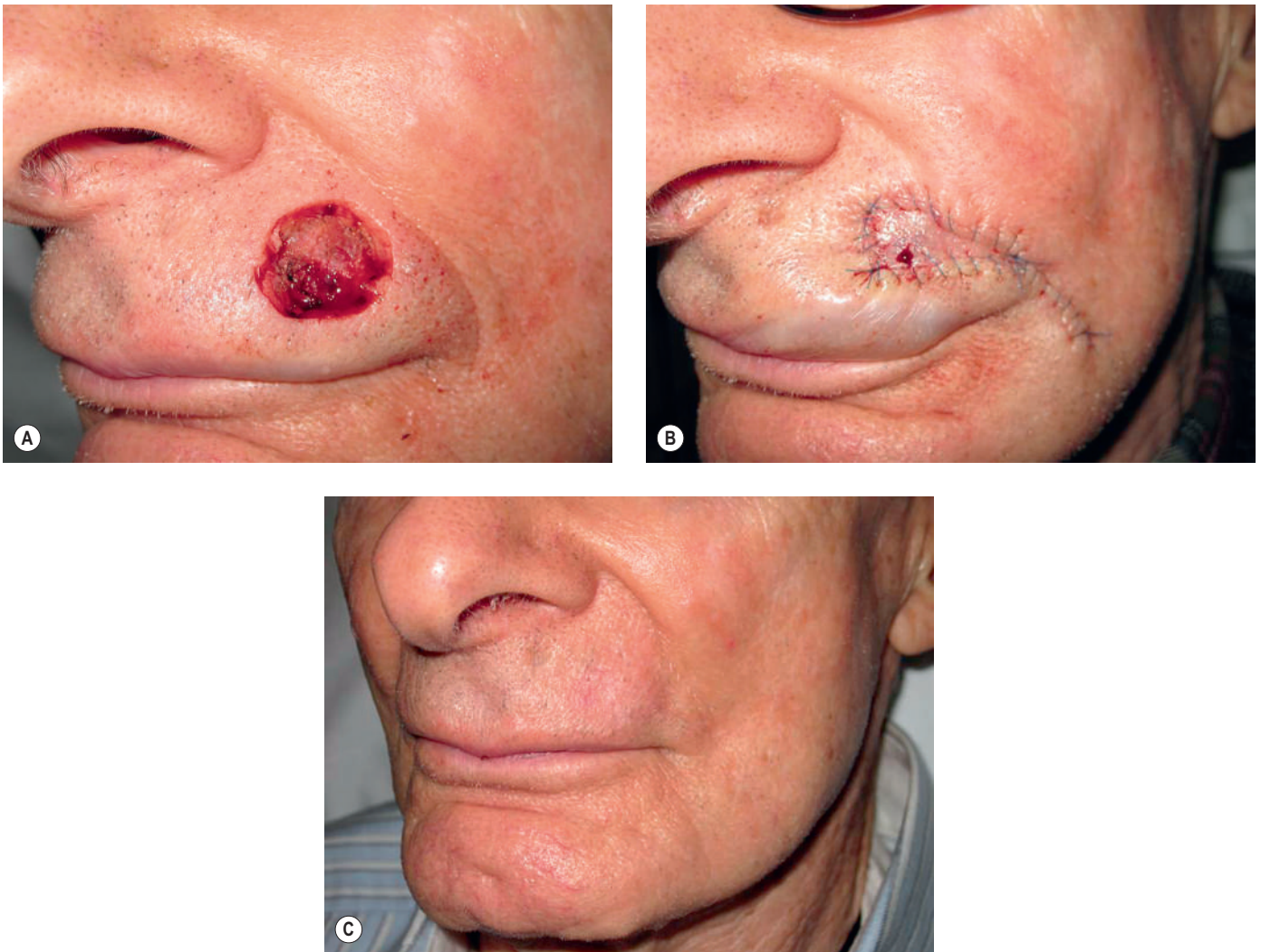
The Z-plasty is useful for any reconstructive surgeon, especially as part of scar revision. When used properly, the Z-plasty alters the direction of the scar, lengthens the contracted scar,

and changes a linear scar into geometric, broken lines. Z-plasty can thus redirect a scar into the relaxed skin tension lines or can reduce anatomic distortion resulting from scar contracture by lengthening the scar.

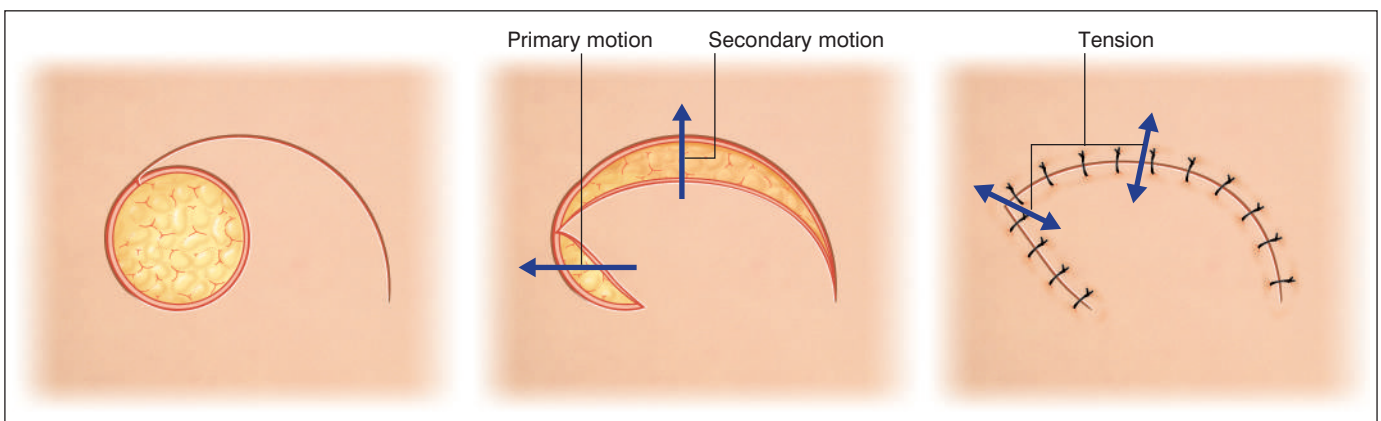
In the classic Z-plasty, the scar is the central diagonal, and two symmetric limbs are taken from the end of the scar, resulting in a "z" appearance. The length and angle of these peripheral arms determine the degree of wound lengthening and redirection. In a classic 60-degree Z-plasty, the scar is redirected 90 degrees and the wound lengthened by 75% (Fig. 37-29). Smaller angles result in a less dramatic gain in length. Once the limbs are incised, the two triangular flaps are "flip-flopped" into position and sutured into place. One disadvantage of Z-plasty is the increase in incisions, which often are more difficult to camouflage.

## Skin grafts

Skin grafts are employed when primary closure or flap closure is not an available option. By definition, a graft is completely excised from the donor site and is devitalized (i.e., no intrinsic blood supply). Success is predicated on the reattachment of vascular supply to the graft from the defect. Grafts offer the advantage of fewer incision lines compared with local flaps. However, the lack of color and texture match resulting

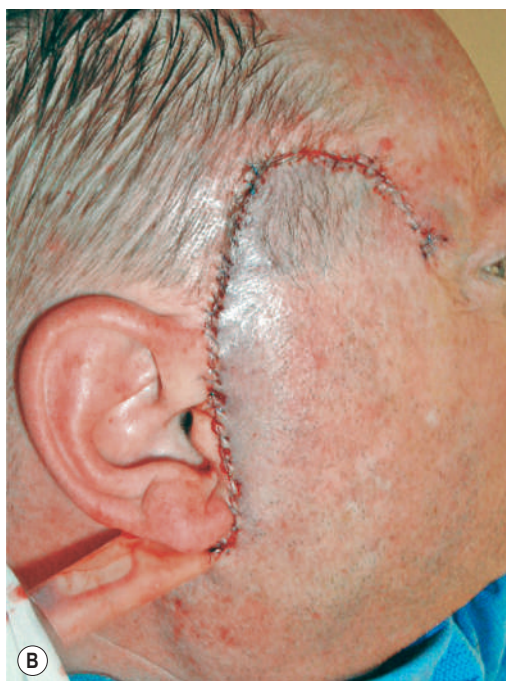
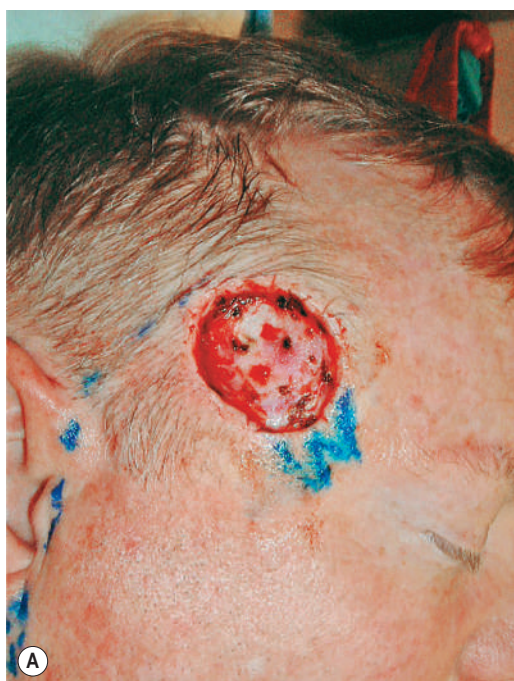
**Fig. 37-21** Island pedicle flap. A, Mohs defect. B, Final wound closure. C, One year postoperatively.

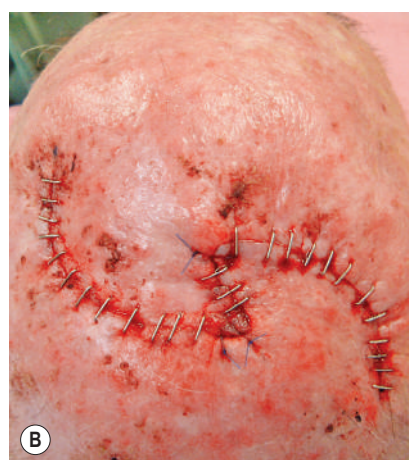
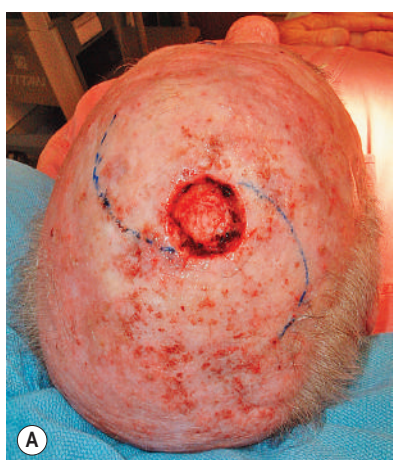
**Fig. 37-22** Rotation flap movement.

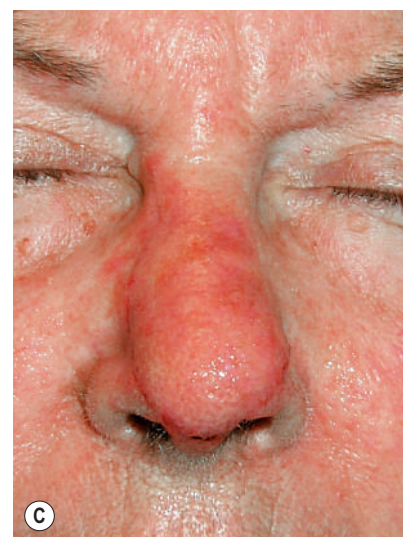
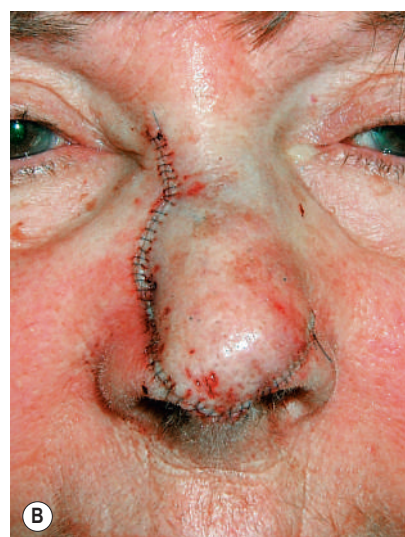
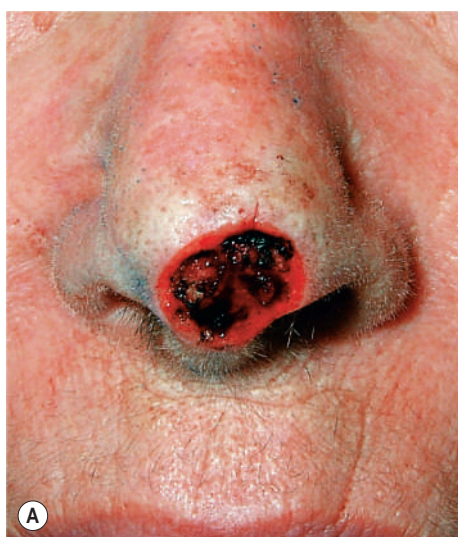

**Fig. 37-23** Rotation flap. A, Rotation flap designed with M-plasty. Redundant skin from cheek is borrowed to repair defect. B, Final closure.

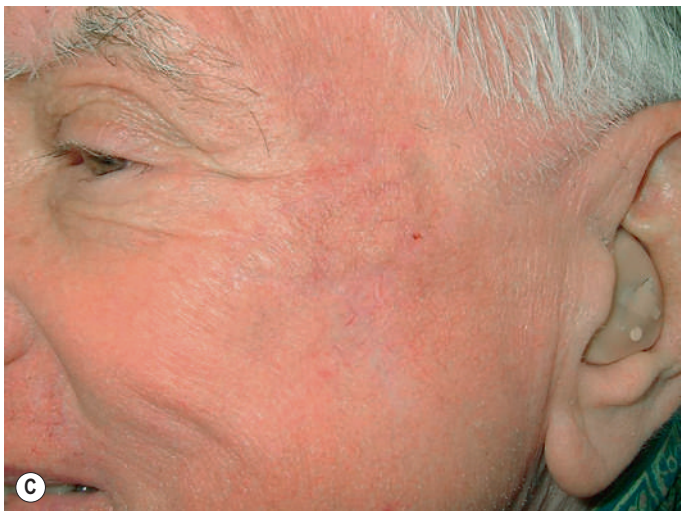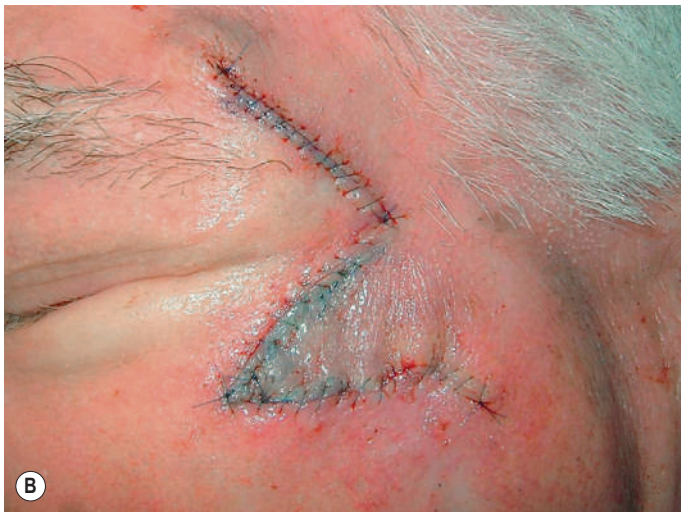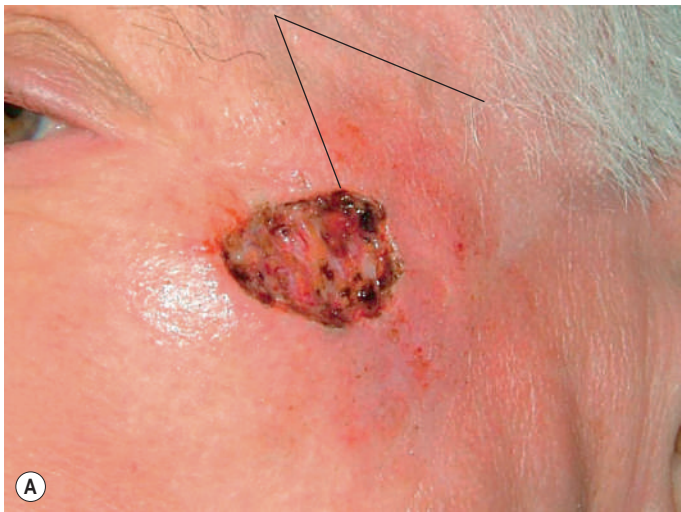


**Fig. 37-24** O-Z rotation flap. A, Flap designed. B, Final wound closure.



**Fig. 37-25** Dorsal nasal rotation flap. A, Mohs defect. B, Final wound closure. C, Eight weeks postoperatively.

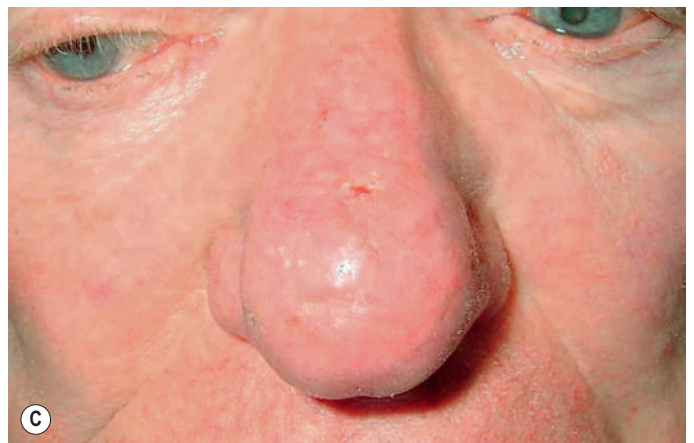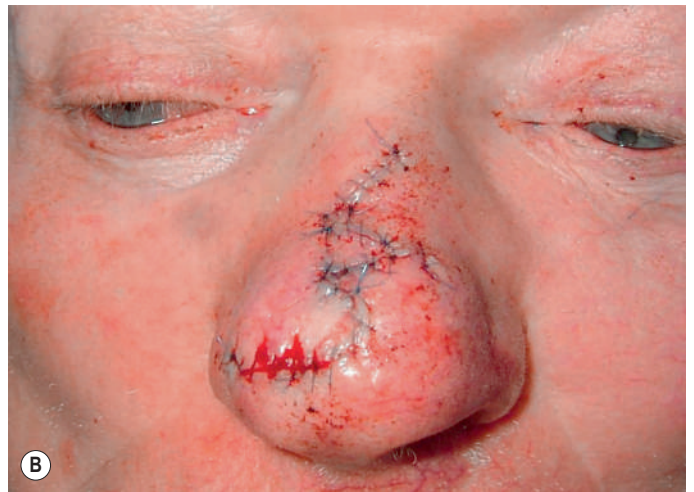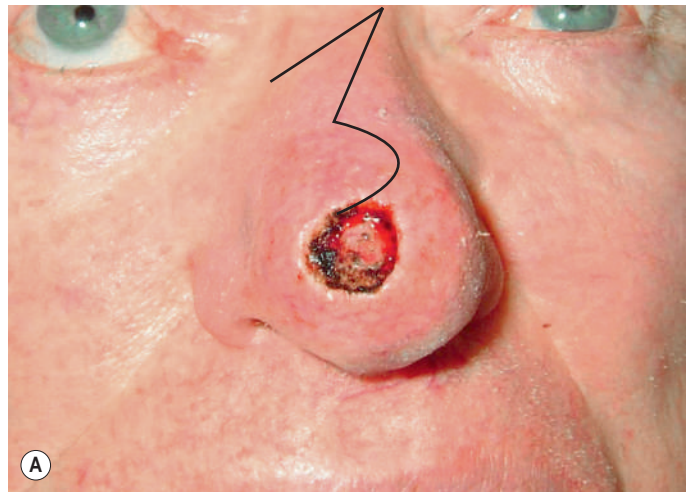




**Fig. 37-26** Transposition flap. A, Mohs defect. B, Final wound closure. C, Follow-up at 3 months.

from the remote donor location of grafts is a potential disadvantage.

Grafts can be categorized as full, split, or composite; when to use each depends on the depth of the defect, vascular supply, and concern about skin cancer recurrence. Full-thickness skin grafts have a full dermis and are the most common grafts used in dermatologic surgery. The graft is



**Fig. 37-27** Bilobed flap. A, Mohs defect. B, Final wound closure. C, Follow-up at 6 weeks.

defatted, trimmed to fit the defect, anchored in place with peripheral and basting sutures, and secured with a tie-over dressing. Common donor sites include preauricular cheek, postauricular crease, conchal bowl, upper eyelid, upper inner arm, and clavicle. Full-thickness grafts can produce an excellent cosmetic result if executed properly (Fig. 37-30). However, the increased skin thickness results in an increased metabolic demand and a higher rate of necrosis and failure.

Imbibition occurs during the first 24–48 h after graft placement. The graft is sustained by passive diffusion of nutrients

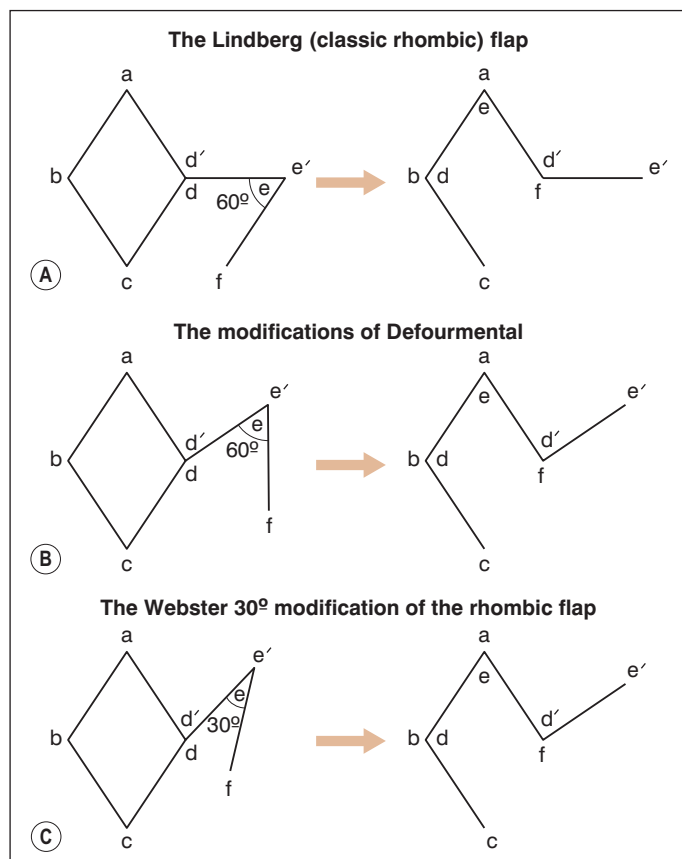


from the wound bed during this stage. It becomes edematous, and the fibrin network attaches the graft to the bed. Inosculation is the next stage, with revascularization resulting from linkage of dermal vessels in the graft to the wound bed. Neovascularization occurs from capillary ingrowth to the graft from the recipient base and side walls. Full circulation can be restored in 7 days and depends on graft thickness and vascularity of the wound bed.

Split-thickness skin grafts have only a partial dermis and are useful for covering large areas or improving surveillance in

tumors with a high risk of recurrence (see Video 37-7). Small grafts can be harvested freehand with No. 15 blade or with a handheld Weck blade, using various guards to determine graft thickness (Fig. 37-31). Larger grafts can be obtained using a power dermatome (Fig. 37-32). Grafts can be meshed to provide coverage for larger defects. Compared with full-thickness skin grafts, split-thickness grafts have a higher rate of survival and shorter healing time, do not require repair of the donor site, and are a good choice for areas that are poorly vascularized because of lower metabolic demand. However, split-thickness grafts have a higher degree of contraction, lack skin appendages, and provide a poorer cosmetic match than full-thickness grafts.

Composite grafts usually consist of skin and underlying structure (e.g., cartilage) and are predominantly used to repair such wounds as full-thickness alar rim defects. These grafts have an increased nutrient requirement and thus are more likely to fail. Free cartilage grafts can be used for reconstruction of the ear and nasal ala or tip.



**Fig. 37-28** Variations of transposition flap.

**Adams DC, Ramsey ML:** Grafts in dermatologic surgery: review and update on full- and split-thickness skin grafts, free cartilage grafts, and composite grafts. *Dermatol Surg* 2005; 31:1055–1067.

**Cook JL:** Reconstructive utility of the bilobed flap: lessons from flap successes and failures. *Dermatol Surg* 2005; 31(8 Pt 2):1024–1033.

**Donaldson MR, Coldiron BM:** Scars after second intention healing. *Facial Plast Surg* 2012; 28(5):497–503.

**Goldman GD:** Rotation flaps. *Dermatol Surg* 2005; 31:1006–1013.

**Jacobs MA, et al:** Clinical outcome of cutaneous flaps versus full-thickness skin grafts after Mohs surgery on the nose. *Dermatol Surg* 2010; 36(1):23–30.

**Krishnan R, et al:** Advancement flaps: a basic theme with many variations. *Dermatol Surg* 2005; 31:986–994.

**Leonard AL, Hanke CW:** Second intention healing for intermediate and large postsurgical defects of the lip. *J Am Acad Dermatol* 2007; 57:832–835.

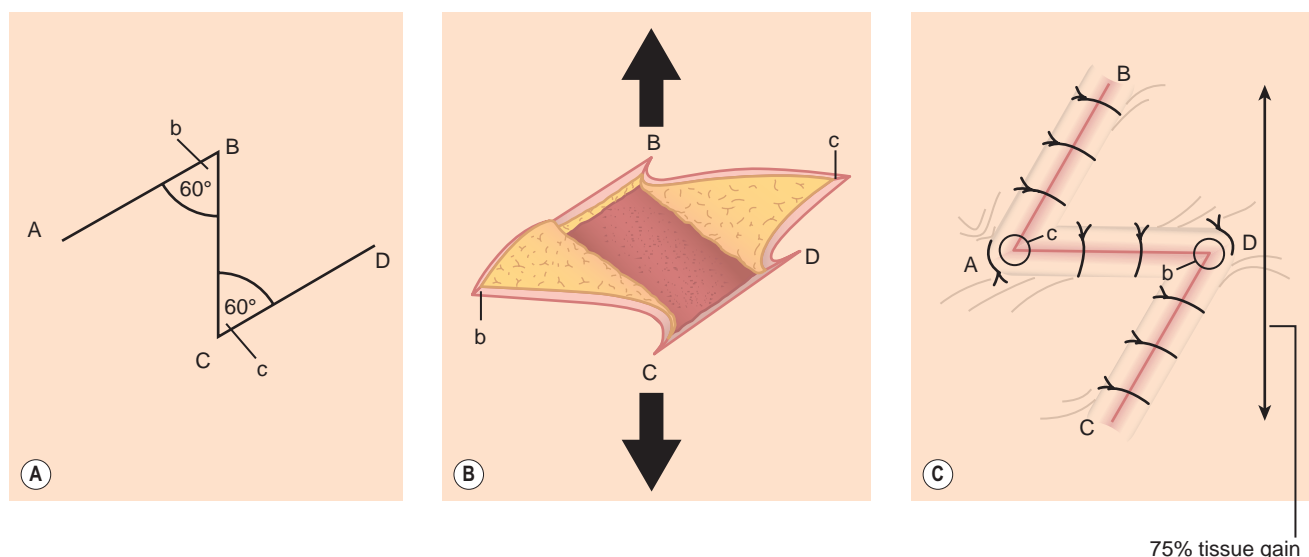
**Neuhaus IM, Yu SS:** Second-intention healing of nasal alar defects. *Dermatol Surg* 2012; 38(4):697–702.

**Rohrer TE, Bhatia A:** Transposition flaps in cutaneous surgery. *Dermatol Surg* 2005; 31:1014–1023.

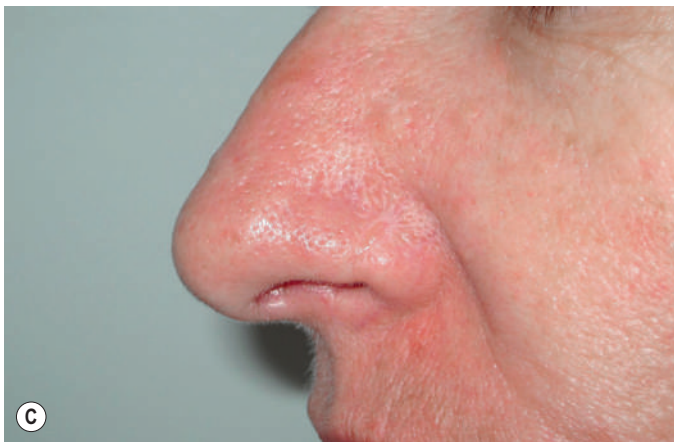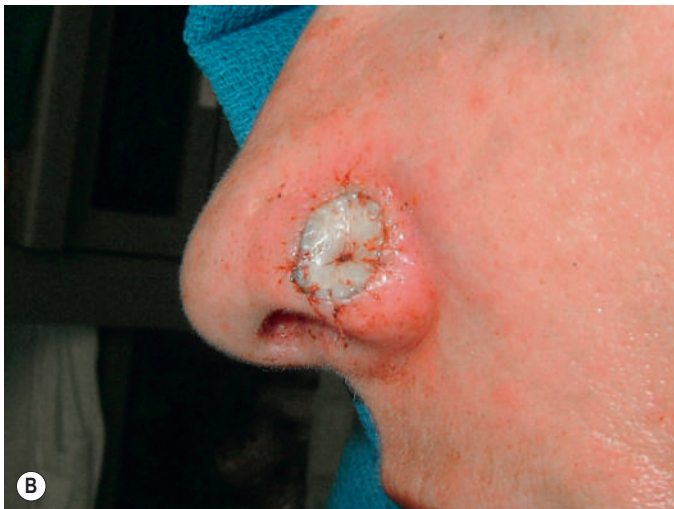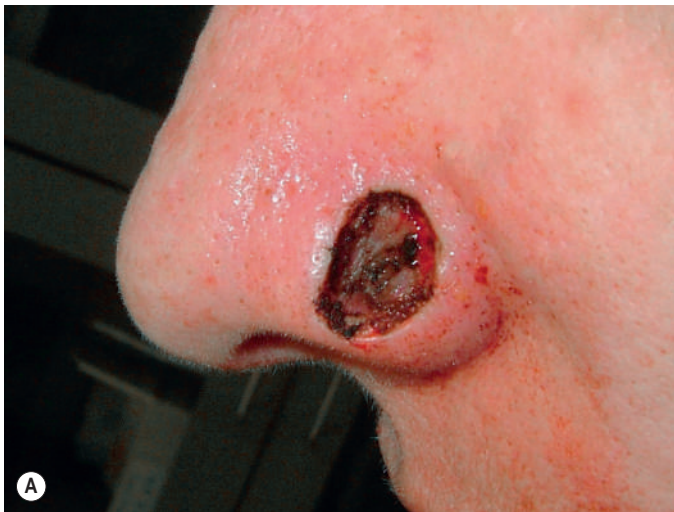**Tan E, et al:** The nasal sidewall rotation flap: a workhorse flap for small defects of the distal nose. *Dermatol Surg* 2010; 36(10):1563–1567.

**Van der Eerden PA, et al:** Secondary intention healing after excision of nonmelanoma skin cancer of the head and neck: statistical evaluation of prognostic values of wound characteristics and final cosmetic results. *Plast Reconstr Surg* 2008; 122(6):1747–1755.

**Zhang AY, Meine JG:** Flaps and grafts reconstruction. *Dermatol Clin* 2011; 29(2):217–230, viii.



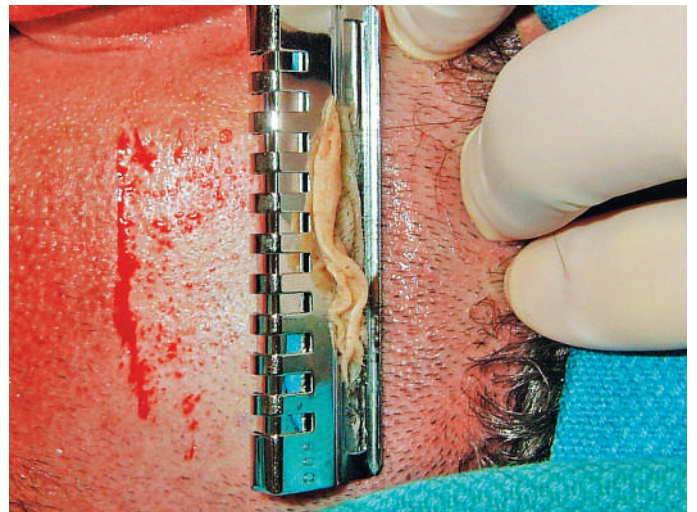
**Fig. 37-29** Single Z-plasty, 60 degrees. A, Central scar is the common diagonal. B, Two triangular flaps are lifted and transposed. C, Result is approximately 75% increased tissue length.



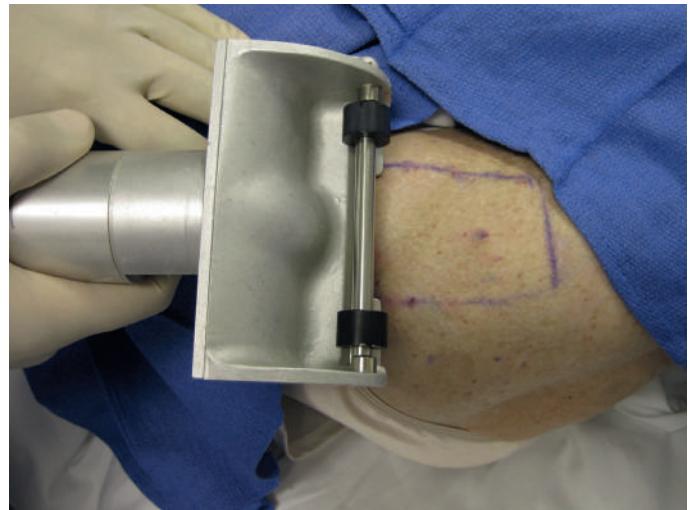
**Fig. 37-30** Full-thickness skin graft. A, Mohs surgery defect. B, Final wound closure. C, Follow-up at 3 years.

## MOHS MICROGRAPHIC SURGERY

Frederic Mohs initially developed this technique at the University of Wisconsin in the 1930s as a means for margin control during surgical excision of skin cancer. The original technique used zinc chloride paste to fix tissue *in vivo*, followed by surgical excision. Drs. Tromovitch and Stegman in San Francisco modified Mohs technique in the 1970s to a fresh frozen tissue variant that continues to be used today. The basic



**Fig. 37-31** Harvesting of split-thickness skin graft. Mastoid process is an excellent source. Hair will regrow at donor site and hide the wound. Hairs remaining in the graft are above the level of the bulb and will not persist once the graft takes.

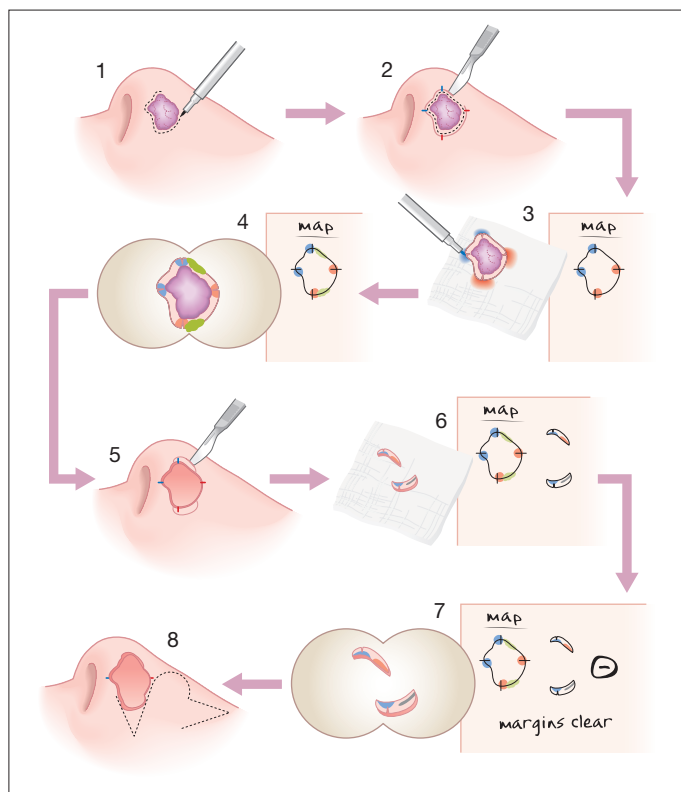


**Fig. 37-32** Harvesting of split-thickness skin graft with powered dermatome.

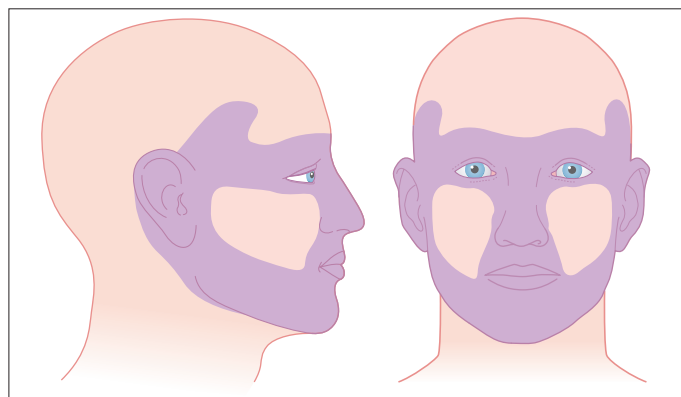
surgical principles in Mohs micrographic surgery are similar to those used in standard excision, although unique challenges are encountered with Mohs surgery. A complete understanding of pathology, anatomy, cutaneous oncology, advanced surgical reconstruction, and management of surgical complications is critical to a successful patient outcome. Any dermatologist performing Mohs micrographic surgery should be well trained in this technique and all the accompanying challenges of surgical and postoperative care.

Mohs micrographic surgical excision is a tissue-sparing technique that employs frozen-section control of 100% of the surgical margin (see Video 37-8). This evaluation of the entire surgical margin using horizontal sections (not vertical, as used in standard sectioning) combined with precise mapping allows for the highest cure rate of cutaneous neoplasms (Fig. 37-33). In addition, the sparing of normal adjacent tissue can improve cosmesis and decrease the risk of functional defects in a sensitive anatomic location. Any tumor that has a contiguous growth pattern is a candidate for Mohs micrographic surgical excision. Immunohistochemical stains can be used in specific cases to help identify residual tumor.





**Fig. 37-33** Mohs micrographic surgery process.



**Fig. 37-34** H-zone of the face.

Multiple indications exist for Mohs micrographic surgical excision (Fig. 37-34 and Box 37-4). In an effort to help identify which patients and tumors are appropriate for treatment with Mohs surgery, a joint task force has established guidelines for appropriate-use criteria. These guidelines should be followed to prevent overuse of Mohs surgery for inappropriate clinical situations. A smartphone “app” is available for reference when evaluating patients in the clinic. Mohs surgery provides cure rates of 99% for primary BCCs and 95% for recurrent BCCs. SCCs on the skin and lip treated with Mohs surgery have a 5-year recurrence rate of 3.1% (vs. 10.9% for other modalities). SCC on the ear treated with Mohs surgery has a 5-year recurrence rate of 5.3% (vs. 18.7% for other modalities). Locally recurrent SCC also has reduced recurrence when treated with Mohs surgery compared with other modalities (10% vs. 23.3%). Other tumors that can be successfully treated by Mohs surgery include dermatofibrosarcoma protuberans, atypical fibroxanthoma, and microcystic adnexal carcinoma. Mohs micrographic surgical excision of melanoma continues to be debated. Several studies have demonstrated comparable

#### Box 37-4 Indications for Mohs surgery

- Recurrent or incompletely excised nonmelanoma skin cancer
- Tumors with aggressive histologic subtypes (infiltrative, morpheaform, micronodular, perivascular, or perineural involvement)
- Tumors with poorly defined clinical margins
- High-risk location >0.4 cm (H-zone of the face, eyes, ears, nose)
- Large tumors (>1.0 cm on face; >2.0 cm on trunk or extremities)
- Cosmetically and functionally important areas, including genital, anal, perianal, hand, foot, and nail units
- Tumors arising in immunosuppressed patients
- Tumors arising in previously irradiated skin or scar
- Genetic conditions with increased risk of neoplasms (basal cell nevus syndrome or xeroderma pigmentosa)

local recurrence, metastasis, and disease-specific survival rates in head and neck melanomas treated with Mohs micrographic surgery when compared with standard excision. In contrast, Walling et al. showed that staged excision for melanoma resulted in lower recurrence rates and similar-sized defects compared with Mohs surgery.

**Alam M, et al:** Adverse events associated with Mohs micrographic surgery: multicenter prospective cohort study of 20,821 cases at 23 centers. *JAMA Dermatol* 2013; 149(12):1378–1385.

**Bae JM, et al:** Mohs micrographic surgery for extramammary Paget disease: a pooled analysis of individual patient data. *J Am Acad Dermatol* 2013; 68(4):632–637.

**Chang KH, et al:** The operative management of melanoma: where does Mohs surgery fit in? *Dermatol Surg* 2011; 37(8):1069–1079.

**Chin-Lenn L, et al:** Comparison of outcomes for malignant melanoma of the face treated using Mohs micrographic surgery and wide local excision. *Dermatol Surg* 2013; 39(11):1637–1645.

**Connolly SM, et al:** Ad Hoc Task Force. AAD/ACMS/ASDSA/ASMS 2012 appropriate use criteria for Mohs micrographic surgery: a report of the American Academy of Dermatology, American College of Mohs Surgery, American Society for Dermatologic Surgery, and the American Society for Mohs Surgery. *J Am Acad Dermatol* 2012; 67(4):531–550.

**El Tal AK, et al:** Immunostaining in Mohs micrographic surgery: a review. *Dermatol Surg* 2010; 36(3):275–290.

**Faroozan M, et al:** Efficacy of Mohs micrographic surgery for the treatment of dermatofibrosarcoma protuberans: systematic review. *Arch Dermatol* 2012; 148(9):1055–1063.

**Leibovitch I, et al:** Cutaneous squamous cell carcinoma treated with Mohs micrographic surgery in Australia. I. Experience over 10 years. *J Am Acad Dermatol* 2005; 53(2):253–260.

**Leibovitch I, et al:** Basal cell carcinoma treated with Mohs surgery in Australia. II. Outcome at 5-year follow-up. *J Am Acad Dermatol* 2005; 53(3):452–457.

**Pugliano-Mauro M, Goldman G:** Mohs surgery is effective for high-risk cutaneous squamous cell carcinoma. *Dermatol Surg* 2010; 36(10):1544–1553.

**Rowe DE, et al:** Long-term recurrence rates in previously untreated (primary) basal cell carcinoma: implications for patient follow-up. *J Dermatol Surg Oncol* 1989; 15:315.

**Rowe DE, et al:** Mohs surgery is the treatment of choice for recurrent (previously treated) basal cell carcinoma. *J Dermatol Surg Oncol* 1989; 15:424.

**Rowe DE, et al:** Prognostic factors for local recurrence, metastasis, and survival rates in squamous cell carcinoma of the skin, ear, and lip: implications for treatment modality selection. *J Am Acad Dermatol* 1992; 26:976.

**Thomas CJ, et al:** Mohs micrographic surgery in the treatment of rare aggressive cutaneous tumors: the Geisinger experience. *Dermatol Surg* 2007; 33(3):333–339.

**Walling HW, et al:** Staged excision versus Mohs micrographic surgery for lentigo maligna and lentigo maligna melanoma. *J Am Acad Dermatol* 2007; 57(4):659–664.

## PHOTODYNAMIC THERAPY

Photodynamic therapy (PDT) involves the activation of a photosensitizer by visible light in the presence of oxygen, resulting in the creation of reactive oxygen species, which selectively destroy the target tissue. The first requirement for PDT is delivery of either a systemic or a topical photosensitizing drug. Systemic photosensitizing molecules are large, lipophilic molecules that require intravenous administration to reach the target site. One of the major disadvantages of these systemic drugs is the prolonged period of phototoxicity. Examples include porfimer sodium and hematoporphyrin derivative. The benzoporphyrin derivative monoacid ring A (verteporfin) has a shorter period of photosensitivity (<72 h) than other systemic agents.

Topical agents offer the advantage of limiting photosensitivity to the application site and have become widely used in dermatology. Delta-aminolevulinic acid (ALA) is the most common photosensitizing agent used in dermatology. It is applied and left on the skin for a sufficient period to allow for accumulation within the target cells. ALA is subsequently converted to the photosensitizer protoporphyrin IX (PpIX), which can then be stimulated through the controlled use of a light source. Tumor cells are thought to be selectively targeted by increased penetration of ALA through the abnormal epidermis overlying the tumor cells. In addition, the iron-deficient, rapidly proliferating tumor cells have an increased production of PpIX compared with normal epidermal cells, resulting in selective photosensitivity and damage to the target site. Methyl aminolevulinate (mALA) is also used as a topical photosensitizing agent. Gentle scraping or curettage before application is performed to increase penetration. Once absorbed, mALA is converted to ALA within the target tissue.

The second requirement of PDT is an appropriate light source to activate the photosensitizer. The light source must match the absorption peak of the photosensitizer. Lasers, intense pulsed-light devices, or an incoherent light source can be used. Red light uses the 630-nm peak of PpIX as its target and has deeper penetration, which is appropriate for dermal processes. Blue light targets the 417-nm peak and has a more superficial penetration, making it an appropriate choice for the treatment of epidermal lesions such as actinic keratoses.

Following absorption of light, the photosensitizer is converted from a stable ground state to an excited triplet state. The excited-triplet-state electrons interact with tissue oxygen, creating singlet oxygen. Singlet oxygen causes oxidative damage to cellular membranes (mitochondria and other cellular organelles) and direct cell death, the key mechanism of action in topical PDT. This entire process occurs over microseconds. In comparison, PDT using systemic photosensitizers predominantly causes destruction of target sites through vascular injury that leads to tissue ischemia.

### Actinic keratosis

Numerous studies have demonstrated the efficacy of PDT in the treatment of actinic keratoses, with overall clearance rates ranging from 50% to 70% for a single treatment and up to 90% with additional treatment sessions. Facial lesions tend to respond better than acral or extremity lesions. Initial studies used an extended application of topical ALA for 14–18 h, followed by activation with a variety of light sources (e.g., blue light, red light, pulsed dye laser, intense pulsed light). This protocol resulted in an effective treatment for actinic keratoses on the scalp and face. However, recent studies and clinical practice show that short incubation periods of 1–3 h with ALA

are an effective protocol for the treatment of actinic keratoses, vastly improving the convenience of this therapy.

Methyl ALA may offer several advantages over  $\delta$ -ALA, including improved skin penetration from mALA's increased lipophilic quality, greater selectivity for neoplastic cells, and possibly less pain and discomfort associated with treatment. However, there are no comparative studies for ALA and mALA PDT in the treatment of actinic keratosis. Pariser et al. showed that mALA applied for 3 h, followed by noncoherent red light, resulted in an almost 90% response rate in actinic keratosis. Given the absence of stratum corneum on the lips and the increased penetration of topical ALA, PDT has been used effectively for actinic cheilitis. This may be an option in patients with recalcitrant disease.

### Basal cell carcinoma

Studies suggest that topical PDT for the treatment of BCC can have initial clearing and excellent cosmetic results, with cure rates ranging from 64% to 97%. However, despite the initial success, BCCs treated with PDT often have a higher recurrence rate on long-term follow-up. In addition, comparative studies of PDT and traditional surgical treatments (e.g., excision or Mohs surgery) are limited or lacking.

Superficial BCC tends to have better response rates than nodular BCC, likely caused by the limited penetration of both the ALA and the activating light into the deeper portion of the dermis for nodular tumors. Pretreatment with curettage for thicker lesions may help to facilitate penetration of ALA and may result in improved cure rates. Infiltrative tumors have an even higher recurrence rate, suggesting that PDT should not be considered a first-line treatment for this histologic subset of BCC.

Arits et al. compared PDT, topical 5-fluorouracil (5-FU), and imiquimod for the treatment of superficial basal cells. Although all modalities were effective, imiquimod was demonstrated to have higher success rate. Both PDT and 5-FU had similar cure rates over 1-year follow-up. However, individual patient factors must be considered when choosing a treatment option.

Subsets of patients with numerous and extensive BCCs (e.g., basal cell nevus syndrome) may be unique cases in whom PDT can be considered for nodular or more extensive tumors, because of the tissue-sparing and chemopreventive advantages over traditional surgical treatments.

### Squamous cell carcinoma in situ

In situ SCC is quite responsive to PDT. Multiple studies demonstrate an initial cure rate of 54–100%, with variable long-term efficacy. Red light should be used instead of blue light because it penetrates more deeply and thus more effectively treats adnexal extensions. Truchuelo et al. demonstrated a 76% clearance of Bowen's disease after two mALA PDT sessions. Calzavara-Pinton et al. used mALA PDT for SCC in situ and reported cure rates of 87.8% at 3 months and 70.7% at 24 months. These patients had good cosmetic outcomes and tolerated the procedure well. In contrast, patients with invasive SCC fared much more poorly with mALA PDT, with a 45.2% cure rate at 3 months falling to 25.8% at 24 months.

Few reports detail the use of PDT for invasive cutaneous SCC. Given the limited success in treating these tumors and the potential for metastatic spread, PDT is not recommended as standard therapy for invasive SCC.

**Arits AH, et al:** Photodynamic therapy versus topical imiquimod versus topical fluorouracil for treatment of superficial basal-cell carcinoma: a



single blind, non-inferiority, randomised controlled trial. *Lancet Oncol* 2013; 14(7):647–654.

**Babilas P, et al:** Photodynamic therapy in dermatology: state-of-the-art. *Photodermatol Photoimmunol Photomed* 2010; 26(3):118–132.

**Basset-Seguín N, et al:** Consensus recommendations for the treatment of basal cell carcinomas in Gorlin syndrome with topical methylaminolaevulinate-photodynamic therapy. *J Eur Acad Dermatol Venereol* 2014; 28(5):626–632.

**Braathén LR, et al:** Guidelines on the use of photodynamic therapy for nonmelanoma skin cancer: an international consensus. *J Am Acad Dermatol* 2007; 56(1):125–143.

**Calzavara-Pinton PG, et al:** Methylaminolaevulinate-based photodynamic therapy of Bowen's disease and squamous cell carcinoma. *Br J Dermatol* 2008; 159(1):137–144.

**Christensen E, et al:** High and sustained efficacy after two sessions of topical 5-aminolaevulinic acid photodynamic therapy for basal cell carcinoma: a prospective, clinical and histological 10-year follow-up study. *Br J Dermatol* 2012; 166(6):1342–1348.

**Dirschka T, et al:** Long-term (6 and 12 months) follow-up of two prospective, randomized, controlled Phase III trials of photodynamic therapy with BF-200 ALA and methyl aminolaevulinate for the treatment of actinic keratosis. *Br J Dermatol* 2013; 168(4):825–836.

**Hadley J, et al:** Results of an investigator-initiated single-blind split-face comparison of photodynamic therapy and 5% imiquimod cream for the treatment of actinic keratoses. *Dermatol Surg* 2012; 38(5):722–727.

**Morton CA, et al:** European guidelines for topical photodynamic therapy. Part 1. Treatment delivery and current indications: actinic keratoses, Bowen's disease, basal cell carcinoma. *J Eur Acad Dermatol Venereol* 2013; 27(5):536–544.

**Mosterd K, et al:** Fractionated 5-aminolaevulinic acid-photodynamic therapy vs. surgical excision in the treatment of nodular basal cell carcinoma: results of a randomized controlled trial. *Br J Dermatol* 2008; 159:864–870.

**Pariser DM, et al:** Photodynamic therapy with topical methyl aminolevulinate for actinic keratosis: results of a prospective randomized multicenter trial. *J Am Acad Dermatol* 2003; 48:227.

**Piacquadio DJ, et al:** Photodynamic therapy with aminolevulinic acid topical solution and visible blue light in the treatment of multiple actinic keratoses of the face and scalp. *Arch Dermatol* 2004; 140:41.

**Rhodes LE, et al:** Five-year follow-up of a randomized, prospective trial of topical methyl aminolevulinate photodynamic therapy vs surgery for nodular basal cell carcinoma. *Arch Dermatol* 2007; 143(9):1131–1136.

**Rozeboom MH, et al:** Overall treatment success after treatment of primary superficial basal cell carcinoma: a systematic review and meta-analysis of randomized and nonrandomized trials. *Br J Dermatol* 2012; 167(4):733–756.

**Serra-Guillen C, et al:** A randomized comparative study of tolerance and satisfaction in the treatment of actinic keratosis of the face and scalp between 5% imiquimod cream and photodynamic therapy with methyl aminolaevulinate. *Br J Dermatol* 2011; 164(2):429–433.

**Serra-Guillén C, et al:** A randomized pilot comparative study of topical methyl aminolevulinate photodynamic therapy versus imiquimod 5% versus sequential application of both therapies in immunocompetent patients with actinic keratosis: clinical and histologic outcomes. *J Am Acad Dermatol* 2012; 66(4):e131–e137.

**Scola N, et al:** A randomized, half-side comparative study of aminolaevulinate photodynamic therapy vs. CO<sub>2</sub> laser ablation in immunocompetent patients with multiple actinic keratoses. *Br J Dermatol* 2012; 167(6):1366–1373.

**Tierney E, et al:** Photodynamic therapy for the treatment of cutaneous neoplasia, inflammatory disorders, and photoaging. *Dermatol Surg* 2009; 35(5):725–746.

**Truchuelo M, et al:** Effectiveness of photodynamic therapy in Bowen's disease: an observational and descriptive study in 51 lesions. *J Eur Acad Dermatol Venereol* 2012; 26(7):868–874.

**Zaiac M, Clement A:** Treatment of actinic cheilitis by photodynamic therapy with 5-aminolevulinic acid and blue light activation. *J Drugs Dermatol* 2011; 10(11):1240–1245.

conditions. The use of ionizing radiation in dermatologic therapy of benign conditions has decreased greatly, because of highly effective medical therapies and the potential genetic and somatic hazards of radiation. However, XRT for malignant skin conditions remains an important primary and adjuvant therapeutic modality. When used in the proper clinical situation, XRT can provide effective treatment while sparing normal tissue and eliminating the need for surgical reconstruction.

Radiation is an appropriate primary treatment for skin cancer in patients who refuse surgery or who are not optimal surgical candidates. In contrast, patients who are relatively young are less ideal candidates for XRT because of the increased risk of developing additional primary tumors within the radiation field, as well as the long-term cosmetic complications associated with this therapy. Tumors located on the eyelids, nose, ears, and lips can be treated with excellent cosmetic outcomes with XRT, whereas lesions on the extremities are frequently treated by excision because of the larger surgical area that can be easily achieved. Treatment of primary BCC with XRT can produce cure rates greater than 90%, although primary SCC may have slightly lower cure rates. It is important to stress that Mohs micrographic surgical excision of primary tumors can achieve cure rates of 97–99%, often with excellent long-term cosmetic outcomes. Furthermore, Mohs surgery can generally be completed in a single day, whereas XRT is routinely fractionated over weeks.

Recently, superficial XRT and electronic surface brachytherapy have been presented as alternative nonsurgical methods to treat skin cancer. These technologies differ from traditional XRT and classic forms of radionuclide-based brachytherapy. Superficial XRT is “low-energy” therapy. In contrast to other XRT types, where the goal is usually to treat tumors that extend deeply beneath the skin surface, superficial x-rays have very limited penetration and thus primarily target the skin. Electronic surface brachytherapy delivers radiation without using an isotope using a miniaturized x-ray tube. This form of treatment contains no actively radioactive isotope components, so it is subject to much less regulation and offers the advantage of less shielding requirements for patients and staff. Both superficial XRT and brachytherapy have been used for skin cancer increasingly over the past few years. In a retrospective analysis of 1715 BCCs and SCCs treated with superficial XRT, Cognetta et al. reported cumulative recurrence rates of all tumors at 2 and 5 years of 1.9% and 5.0%, respectively. Long-term outcomes for electronic brachytherapy are not yet available, but many centers have reported initial cohorts with good short-term cosmesis. At present, additional research is needed for these modalities to determine their proper role in the treatment and management of cutaneous malignancies.

Radiation therapy may also be considered if surgical margins show microscopic evidence of residual tumor after excision. XRT can be used for recurrent BCC and SCC previously treated with nonradiologic methods, although not with the same success as primary tumors. Caccialanza et al. demonstrated an 84% 5-year cure rate for recurrent BCC and SCC in a group of about 250 recurrent tumors, with almost all having an acceptable cosmetic result. Locke et al. showed that primary tumors treated with radiation had a response rate of 93%, versus 80% for recurrent neoplasms. Mohs micrographic surgical excision of recurrent nonmelanoma skin cancer (NMSC) produces higher cure rates (95%), but if cancers have recurred multiple times, consideration should be given to addition of adjuvant XRT based on negative pathologic features.

Several studies indicate that recurrence of NMSC after primary XRT may be more aggressive and invasive than recurrence after primary surgical treatment. Smith et al. demonstrated that BCCs recurring after primary XRT had deeper

## RADIATION THERAPY FOR SKIN CANCER

Radiation therapy (x-ray therapy, XRT) has a long history of use for treatment of both benign and malignant skin

subcutaneous tissue invasion and a larger percentage increase between clinical preoperative tumor area and final postoperative defect area than recurrent tumors that had initially been treated with other modalities. Therefore, salvage surgeries for post-XRT recurrences generally should be undertaken with large clinical margins.

Radiation therapy offers a valuable adjunctive treatment option for particularly aggressive perineural SCC and BCC. Detection of single-cell tumor spread may be particularly difficult after excisional surgery. In addition, perineural carcinoma may spread more rapidly along nerve sheaths than by contiguous growth. With either primary surgery or primary radiation, overall control rates are lower for tumors with perineural invasion. Given the increased risk of metastasis and recurrence in this group of tumors, adjuvant XRT should be considered as prophylactic treatment after surgical excision.

**Bhatnagar A:** Nonmelanoma skin cancer treated with electronic brachytherapy: results at 1 year. *Brachytherapy* 2013; 12(2):134–140.

**Caccialanza M, et al:** Radiotherapy of recurrent basal and squamous cell skin carcinomas: a study of 249 re-treated carcinomas in 229 patients. *Eur J Dermatol* 2001; 11:25.

**Cognetta AB, et al:** Superficial x-ray in the treatment of basal and squamous cell carcinomas: a viable option in select patients. *J Am Acad Dermatol* 2012; 67(6):1235–1241.

**Han A, Ratner D:** What is the role of adjuvant radiotherapy in the treatment of cutaneous squamous cell carcinoma with perineural invasion? *Cancer* 2007; 109(6):1053–1059.

**Jambusaria-Pahlajani A, et al:** Surgical monotherapy versus surgery plus adjuvant radiotherapy in high-risk cutaneous squamous cell carcinoma: a systematic review of outcomes. *Dermatol Surg* 2009; 35(4):574–585.

**Locke J, et al:** Radiotherapy for epithelial skin cancer. *Int J Radiat Oncol Biol Phys* 2001; 51:748.

**Silverman MK, et al:** Recurrence rates of treated basal cell carcinomas. Part 4. X-ray therapy. *J Dermatol Surg Oncol* 1992; 18:549.

**Smith SP, et al:** Use of Mohs micrographic surgery to establish quantitative proof of heightened tumor spread in basal cell carcinoma recurrent following radiotherapy. *J Dermatol Surg Oncol* 1990; 16:1012.

**Veness MJ:** The important role of radiotherapy in patients with non-melanoma skin cancer and other cutaneous entities. *J Med Imaging Radiat Oncol* 2008; 52(3):278–286.

**Wang Y, et al:** Indications and outcomes of radiation therapy for skin cancer of the head and neck. *Clin Plast Surg* 2009; 36(3):335–344.



Cutaneous laser surgery is a continually evolving area of dermatology. Development of new lasers, as well as improvements in existing lasers, continues to advance the field. As a result of this progress, laser surgery has become an extremely effective therapeutic modality for a multitude of dermatologic conditions.

### LASER PRINCIPLES

“Laser” is an acronym for light amplification by stimulated emission of radiation. The first laser, a ruby laser, was operated in 1960 by Theodore Maiman. Medical applications were quickly recognized, and Leon Goldman pioneered their dermatologic use.

Although technology has advanced through the years, several distinctive characteristics have remained in all lasers. Compared with other light sources, laser light is defined as monochromatic (i.e., a single wavelength), collimated (i.e., nondivergent), and coherent (i.e., in phase, with peaks and troughs of the light all aligned) (Fig. 38-1). Laser energy is measured in joules (J). Fluence is defined as the amount of energy delivered per unit area ( $J/cm^2$ ). Power is the rate at which energy is delivered and is measured in watts (1 watt is defined as 1 J/sec).

The wavelength is determined by the active medium of each particular laser. Active medium can consist of a gas (e.g., argon,  $CO_2$ ), liquid (e.g., dye), or a solid (e.g., ruby, yttrium-aluminum-garnet crystal) (Table 38-1). The choice of wavelength is determined by the target tissue and depth of penetration required (Fig. 38-2).

Continuous-wave lasers emit a beam of light whose output power is constant over time, resulting in a long, continuous exposure. Quasi-continuous-wave lasers shutter the continuous beam into short segments, producing interrupted emissions of constant laser emission. Pulsed lasers produce short, high-energy pulses of light. Q-switched (quality-switched) lasers are able to generate extremely high-energy pulses over very short (nanoseconds or picoseconds) pulse durations and are used primarily for treating pigmented lesions.

Light can interact with incident targets in one of several ways: reflected, transmitted, scattered, or absorbed (Fig. 38-3). Approximately 5% of laser light is reflected from the epidermis and not absorbed. Transmitted light passes unaltered through the tissue. Light is scattered by the various skin structures, molecules, and cells, thus limiting its depth of penetration and effect on tissue. When reflected, transmitted, or scattered, the light has no effect on the target tissue. When absorbed, however, the light energy is transformed into heat. In most cases of laser therapy, it is the heat generated by absorption that produces the desired therapeutic effect.

The concept of selective photothermolysis, originally promoted by Parish and Anderson, is the basis for all laser-tissue

interactions. Lasers in cutaneous surgery are selected by matching their particular wavelength with the absorption spectrum of a desired target. The target structures that absorb laser light are defined as chromophores, with the most common in the skin being water, hemoglobin, and melanin (Fig. 38-4). The goal is to deliver a wavelength that is specifically absorbed by the chromophore, inducing heat buildup and the resultant destruction of that target. In an ideal situation, this wavelength would have little or no absorption by surrounding structures. By controlling exposure times and energy delivered (fluence), the amount of heat buildup can be confined to the desired target with minimal or no collateral damage to surrounding structures from heat dissipation, a property defined as thermal relaxation. A target's thermal relaxation time (TRT) is defined as the time required for the heated target tissue to dissipate half the absorbed heat and is related to the size and shape of the target structure. Selective photothermolysis is achieved by ensuring that the laser pulse duration is equal to or less than the TRT of the target tissue. Thus, larger structures (e.g., hair follicles) have a longer TRT and are best treated with longer pulse widths. Smaller structures (e.g., melanosomes) have a shorter TRT and can be treated with much shorter pulse durations (Table 38-2).

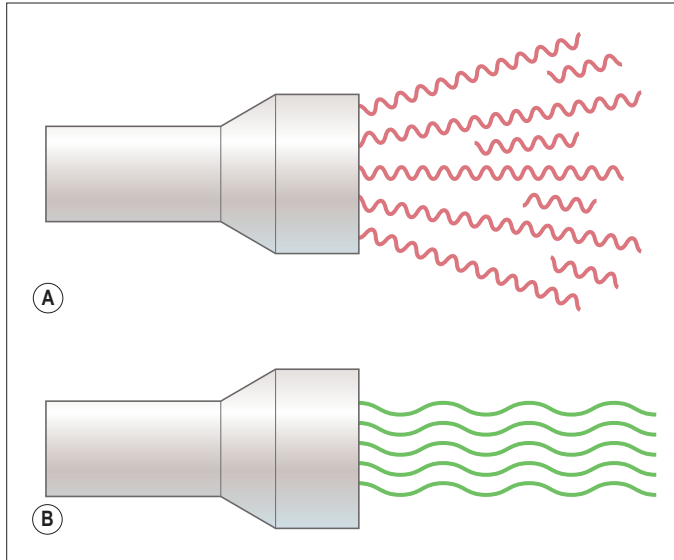
The beam diameter of the laser, or spot size, is a factor in depth of laser penetration. Small spot sizes produce significantly more scatter of the laser outside the effective beam, thus resulting in smaller effective treatment areas. In contrast, larger spot sizes produce more photons that remain within the beam diameter, resulting in higher fluences at a given depth. Therefore, with any given wavelength, a larger beam diameter results in a deeper level of penetration (Fig. 38-5).

Epidermal melanin and heat transfer from dermal structures can result in inadvertent epidermal heating and injury. By selectively cooling the overlying skin, while still maintaining sufficient dermal heat to damage the target, the laser surgeon can reduce the chances of epidermal injury. Precooling, parallel cooling, and postcooling have all been used to protect the skin. Dynamic cooling devices use a cryogen spray to cool the skin before and after laser exposure. Contact cooling with a chilled sapphire tip can be used throughout the treatment and is especially useful for parallel cooling. Forced cooled air provides less effective cooling than other methods but can be useful in reducing pain associated with laser treatment. Direct application of ice can also be used for postcooling.

The laser is a technologically advanced instrument that has been used effectively and safely for a wide variety of dermatologic conditions. However, as with any surgery or therapeutic intervention, side effects and complications can occur. Short-term side effects include purpura, edema, and crusting. More concerning, long-term adverse events include scarring (both atrophic and hypertrophic), dyspigmentation, infection, and persistent erythema. Although not a complication, lasers sometimes show a lack of efficacy even when used properly

in appropriate clinical settings. Detailed informed consent is critical before performing any laser treatment. Appropriate instruction and supervision in the use of lasers must be obtained by dermatologic surgeons to ensure optimum safety and surgical outcome. Adverse outcomes in laser-treated patients have a significant medicolegal impact, with nonphysician operators accounting for a significant proportion of these cases. Caution is required for any physician who is supervising these providers when performing laser treatment.

**Anderson RR, Parrish JA:** Selective photothermolysis: precise microsurgery by selective absorption of pulsed radiation. *Science* 1983; 220:524.



**Fig. 38-1** Laser characteristics. In contrast to the diagram in A, the B figure demonstrates laser light that is both collimated and coherent.

**Carroll L, Humphreys TR:** Laser-tissue interactions. *Clin Dermatol* 2006; 24(1):2–7.

**Dawson E, et al:** Adverse events associated with nonablative cutaneous laser, radiofrequency, and light-based devices. *Semin Cutan Med Surg* 2007; 26(1):15–21.

**Jalian HR, et al:** Common causes of injury and legal action in laser surgery. *JAMA Dermatol* 2013; 149(2):188–193.

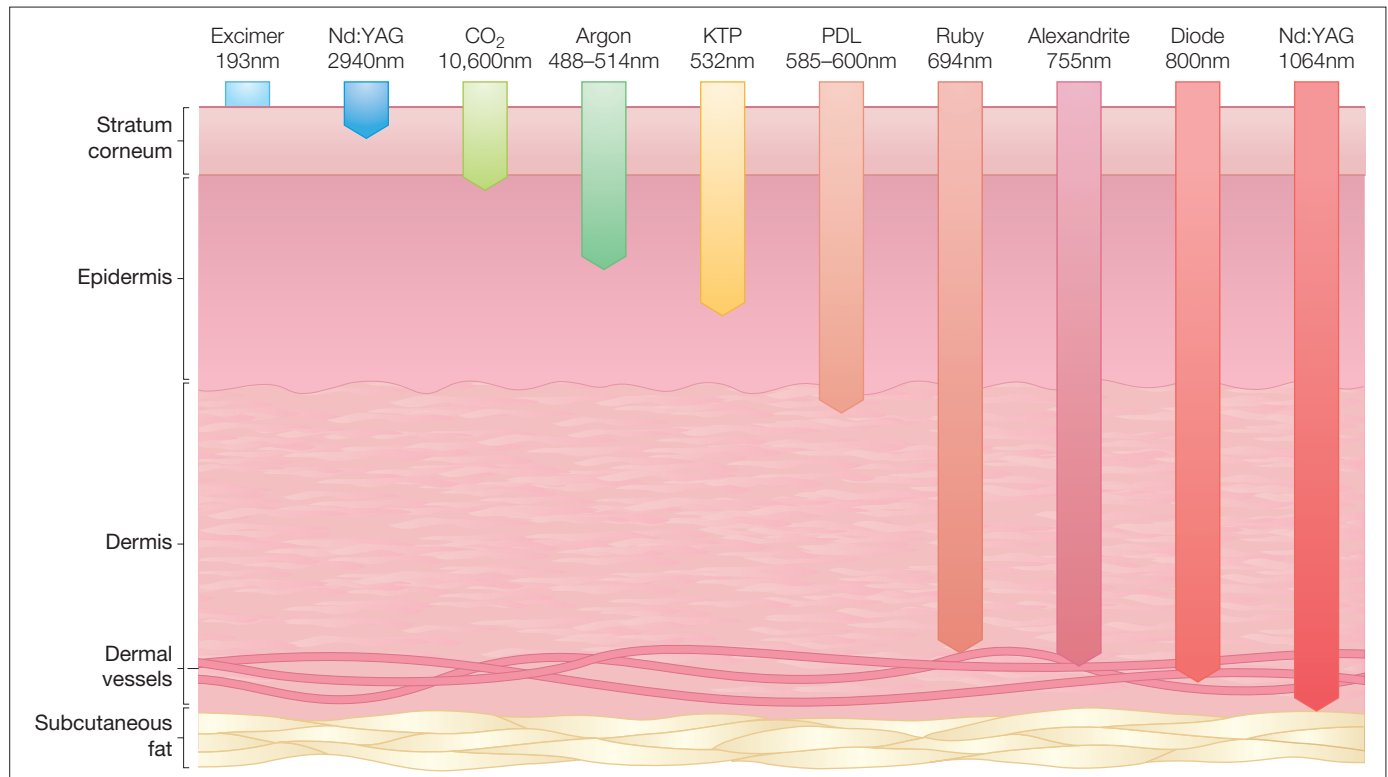
**Tanzi EL, et al:** Lasers in dermatology: four decades of progress. *J Am Acad Dermatol* 2003; 49(1):1–31.

## LASER TREATMENT OF VASCULAR LESIONS

A number of congenital and acquired vascular lesions can be effectively treated with laser. Given the variety of choices available, the laser surgeon must have a complete understanding of the inherent differences in wavelengths, pulse durations, and the vessel size of the particular lesion being targeted. Over the years, lasers have become more selective and the treatment of vascular lesions more effective.

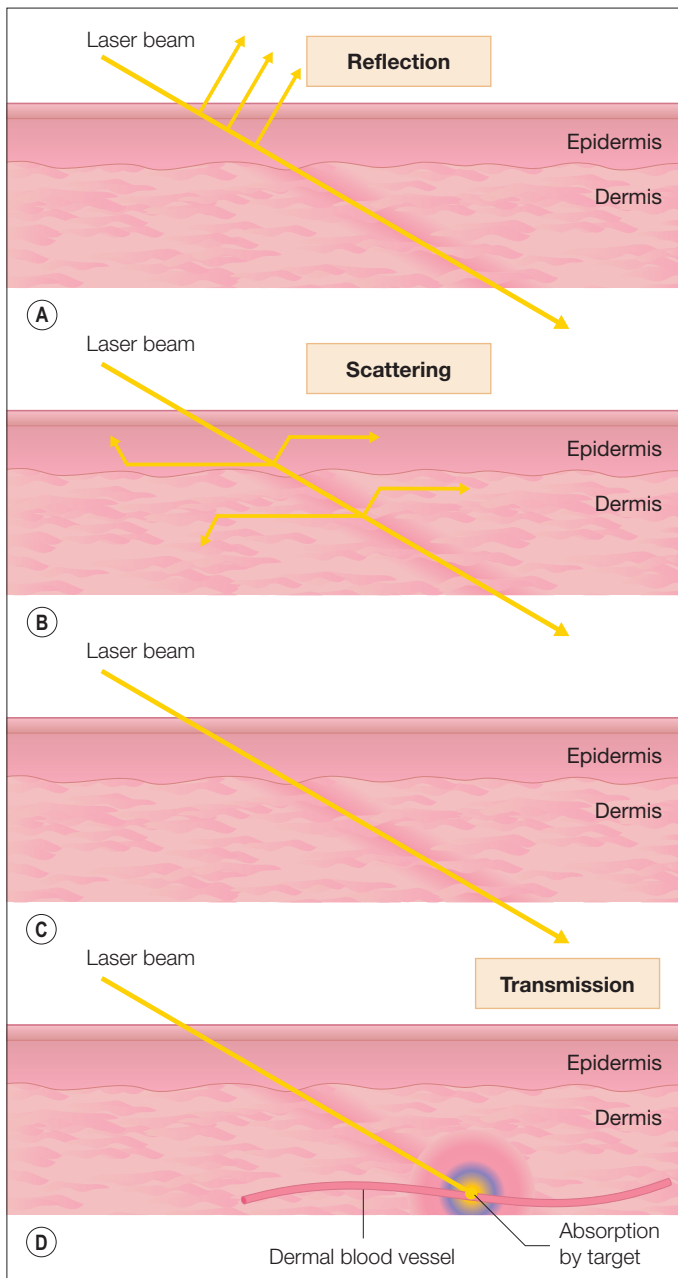
### Pulsed dye laser

The pulsed dye laser (PDL) was the first laser developed specifically to take advantage of selective photothermolysis. The laser medium is a rhodamine dye, which initially was developed to deliver a wavelength of 577 nm, coinciding with a specific hemoglobin absorption peak. Older lasers used a wavelength of 585 nm, but for various technical and clinical reasons, the wavelength has evolved in the current generation of PDL to be 595 nm. Initial pulse durations were about 500 microsecond ( $\mu$ s)/pulse. This was based on calculations that the target, hemoglobin, had a TRT of 1 millisecond (ms) or less. These parameters resulted in immediate postoperative purpura lasting up to 2 weeks.



**Fig. 38-2** Laser penetration.

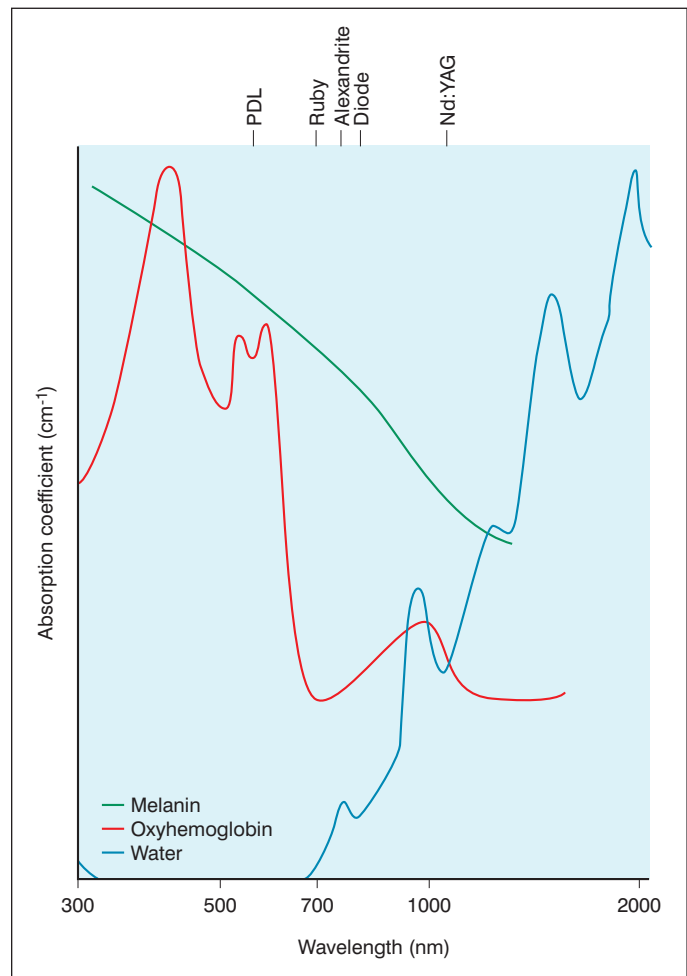




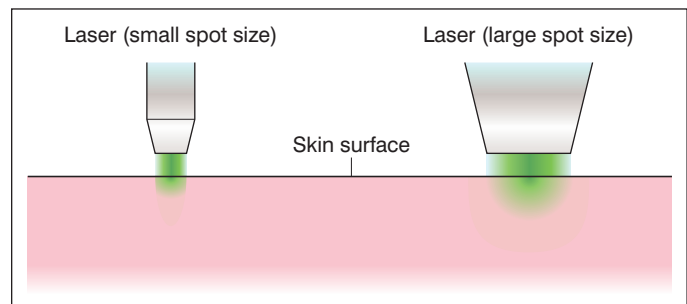
**Fig. 38-3** Laser interaction with skin.

Newer configurations of the laser allow for pulse durations from 0.45 to 40 ms, based on newer understandings of TRTs in the context of the size of the target (e.g., capillaries vs. larger vessels) and clinical effects (purpuric vs. nonpurpuric treatment). By using longer pulse durations, gentler and more uniform heating results in reduced or absent posttreatment purpura (more acceptable to patients) than the earlier PDL configurations, while still maintaining clinical efficacy.

The PDL is an extremely useful instrument for the treatment of vascular lesions. These lasers have traditionally been used for port wine stains, telangiectasias, erythematotelangiectatic rosacea, and hemangiomas. The risk of scarring and pigment change is very slight with this technology. PDL is used in a wide range of patients, including newborns. The newer, long-pulsed and longer-wavelength lasers allow for treatment of larger and deeper vessels. By combining these treatments with surface-cooling devices, the epidermis can be protected, which allows for the delivery of greater energy in a safer and less painful manner.



**Fig. 38-4** Absorption spectra. The heterogeneous absorption spectra of chromophores allow selective photothermolysis to work.



**Fig. 38-5** Effects of spot size on scattering. The larger spot size allows more photons to remain within a beam's diameter, whereas with a smaller spot size, a greater fraction of photons scatters outside the beam and is ineffective. Thus, a beam of a given wavelength penetrates to a deeper level with a larger spot size.

The PDL is the treatment of choice for port wine stains. A series of treatments every 4–6 weeks is required for maximum benefit, with gradual improvement after each session. Although most patients will show improvement, total clearance of lesions is extremely rare (Fig. 38-6). Rate of improvement is related to anatomic location, with lesions on the extremity responding less than facial lesions. Size also plays a role in the response rate of port wine stains. Smaller lesions have greater rate of improvement than larger lesions. Treatments are typically performed with short pulse durations, with resulting purpura lasting for 10–14 days. When the

**Table 38-1** Dermatologic lasers

Laser/system	Wavelength (nm)	Color	Applications
Argon	488–514	Blue-green	Vascular lesions
Intense pulsed light (IPL)	515–1200	Green-red and infrared	Vascular lesions, pigmented lesions, epilation, photodamage
Potassium titanyl phosphate (KTP)	532	Green	Vascular lesions, pigmented lesions
QS Nd:YAG (frequency doubled)	532	Green	Vascular lesions, pigmented lesions; tattoo—red
Copper vapor	578/511	Yellow-green	Vascular lesions, pigmented lesions
Flashlamp-pumped pulsed dye (PDL)	585–600	Yellow	Vascular lesions
QS ruby	694	Red	Deep and superficial pigmented lesions; tattoo—black, blue, green
Long-pulsed ruby	694	Red	Epilation
QS alexandrite	755	Infrared	Tattoo—blue, black, green
Long-pulsed alexandrite	755	Infrared	Epilation
Diode	810	Infrared	Epilation
QS Nd:YAG	1064	Infrared	Deep and superficial dermal pigment; tattoo—black, blue
Long-pulsed Nd:YAG	1064	Infrared	Epilation, vascular lesion
Er:YAG	2940	Infrared	Superficial skin resurfacing; destruction of superficial growths
Carbon dioxide	10600	Infrared	Skin resurfacing; destruction of warts, keloids, superficial cancers, and benign growths

QS, Q-switched; Nd:YAG, neodymium-doped yttrium-aluminum-garnet.

**Table 38-2** Pulse durations and targets of selective photothermolysis

Chromophore	Diameter	TRT	Typical laser pulse duration
Tattoo ink particle	0.1 $\mu\text{m}$	10 ns	10 ns
Melanosome	0.5 $\mu\text{m}$	250 ns	10–100 ns
Port wine stain vessels	30–100 $\mu\text{m}$	1–10 ms	0.4–20 ms
Terminal hair follicle	300 $\mu\text{m}$	100 ms	3–100 ms
Leg vein	1 mm	1 s	0.1 s

TRT, Thermal relaxation time; ns, nanoseconds, ms, milliseconds; s, second.

treatment is performed with proper cooling and appropriate technique, the risk of atrophic scarring and pigmentary alterations is extremely low. Redarkening of treated port wine stains after treatment with PDL has occurred over time and may necessitate repeat treatments years later.

Ulcerated hemangiomas have been successfully treated by PDL. In addition, following spontaneous resolution of infantile hemangiomas, PDL can be used for any persistent telangiectasias. PDL has a limited depth of penetration, however, and thus is not effective in the treatment of deeper components of hemangiomas, which are likely to continue to proliferate despite laser therapy. The use of PDL for superficial hemangiomas in the proliferative phase remains controversial. Some

studies have demonstrated that early treatment with PDL results in improved clearing. However, other authors have advocated that the natural course of hemangiomas is of regression, and that potential risk of ulceration and atrophy from PDL treatment is not warranted for uncomplicated lesions.

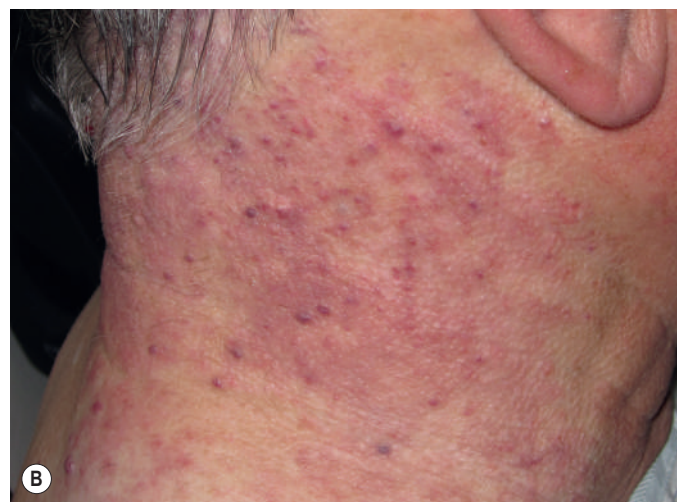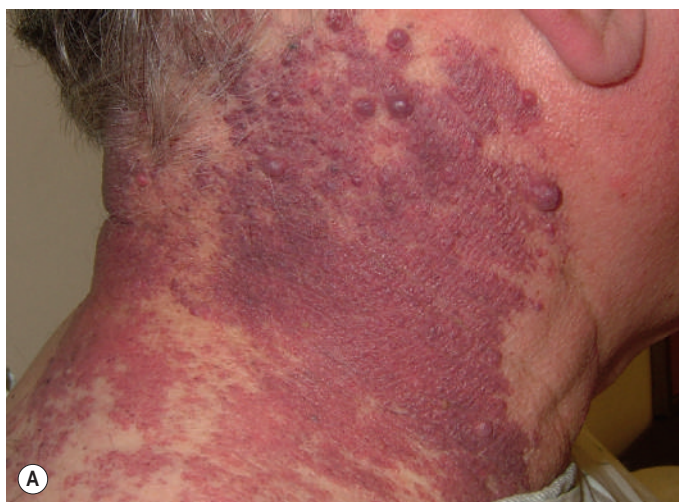Erythematotelangiectatic rosacea is a common condition characterized by persistent facial erythema, telangiectasias, and flushing. PDL has been shown to be an effective and safe treatment option (Fig. 38-7). The long-pulsed PDL has the advantage of purpura-free treatment, which is better tolerated by patients desiring cosmetic improvement.

The PDL has been effectively used for the treatment of warts, producing similar cure rates as traditional therapy. Several reports address the use of PDL for hypertrophic scars. Manuskiatti and Fitzpatrick demonstrated that PDL, intralesional corticosteroid, and 5-fluorouracil (5-FU) produced similar beneficial effects in the treatment of hypertrophic sternotomy scars. The mechanism of action in warts and hypertrophic scars is not clear but may be related to injury to vessels supporting the lesions or simply to heat-related injury. As with other treatment modalities for these two conditions, results are variable.

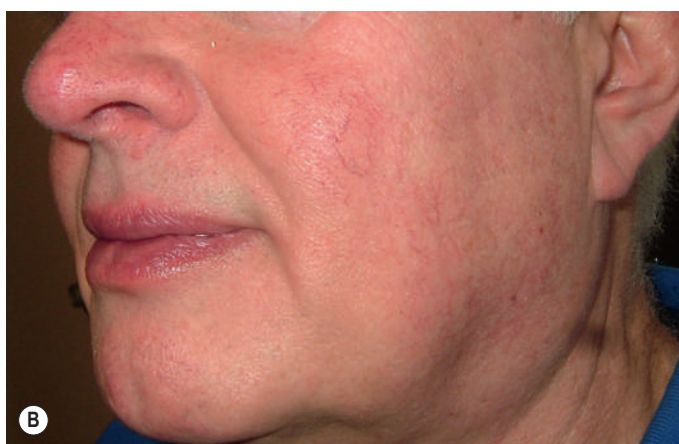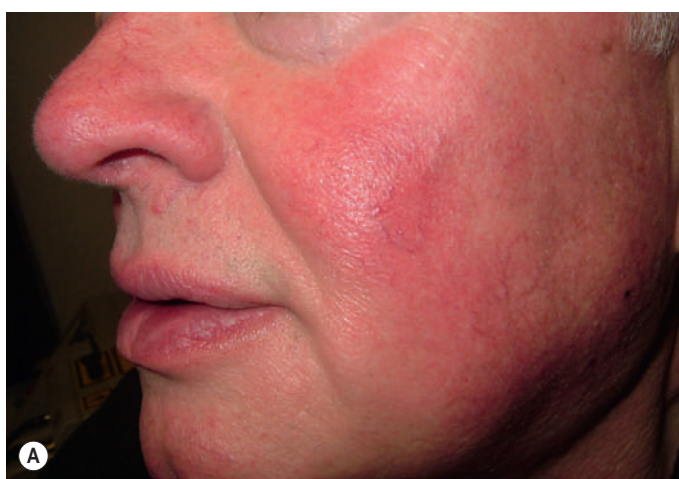### Potassium titanyl phosphate laser

The potassium titanyl phosphate (KTP) laser produces a visible green beam of 532 nm. Because there is significant hemoglobin and melanin absorption of this wavelength, the KTP laser can be used to treat both vascular and superficial pigmented lesions. The KTP laser is actually an Nd:YAG laser that emits a wavelength of 1064 nm. The beam is passed through a crystal of KTP that reduces the wavelength by 50%, producing the 532-nm wavelength.





**Fig. 38-6** Laser treatment of port wine stain. A, Before treatment. B, After eight treatments with pulsed dye laser.



**Fig. 38-7** Laser therapy for rosacea. A, Before treatment. B, After two treatments with subpurpuric pulsed dye laser.

Pulsed KTP lasers have pulse durations ranging from 1 to 100 ms. The advantage of these lasers is the strong absorption of their wavelength by hemoglobin. In addition, purpura is not present with the longer pulse widths. The 532-nm wavelength has a limited depth of penetration, making it an excellent choice for the treatment of fine facial vessels. However, it can be absorbed by epidermal pigment to a greater degree than other, longer-wavelength vascular lasers, which increases

the risk of pigmentary complications. KTP lasers can be quite compact, allowing for easy transport between various locations. With few moving parts, they are also relatively maintenance free.

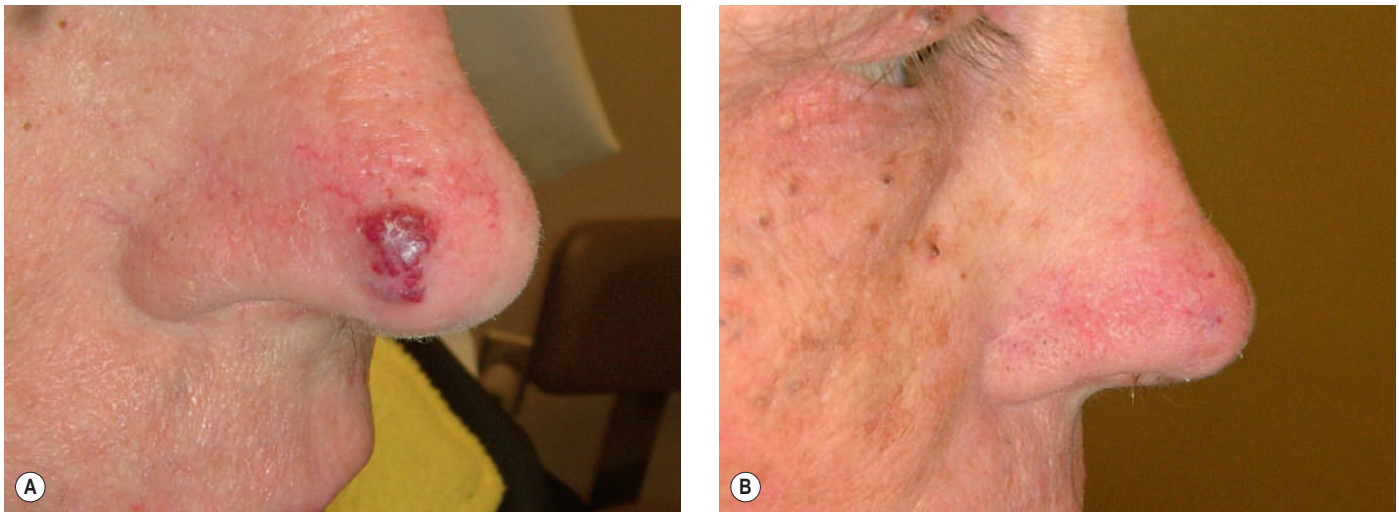
The KTP lasers are suited to treatment of individual telangiectasias of the face, cherry angiomas, and small spider angiomas. Since individual vessels must be traced out using a narrow beam diameter, the number of vessels treated in any given session is limited when using certain KTP lasers with smaller spot sizes. However, models with larger spot size and cooling can be effectively used for the treatment of erythematotelangiectatic rosacea and port wine stain.

### Long-pulsed infrared lasers

Lasers are now being used to take advantage of the broad oxyhemoglobin absorption band in the near-infrared range. Long-pulsed lasers include the alexandrite (755 nm), diode (800 nm, 940 nm), and neodymium:yttrium-aluminum-garnet (Nd:YAG; 1064 nm). These lasers are best used for larger and deeper vessels, such as large-vessel venous malformations, vascular blebs in port wine stains, blue reticular veins, venous lakes, and lower extremity spider veins (Fig. 38-8).

### Intense pulsed light

The intense pulsed light (IPL) system, although technically not a laser, uses a flashlamp that emits a noncoherent broad spectrum of light (400–1200 nm) at various pulse durations and intervals. By employing filters to eliminate the lower wavelengths, light from 560 nm and above can be used to treat various cutaneous conditions. IPL technology has the advantage of treating more than one specific chromophore at a time and is especially useful in improving both vascular and pigmentary changes typically seen in photodamaged skin (see later discussion). In addition, IPL has a relatively large beam size and rapid pulse rate, allowing for the treatment of a large area in a relatively short amount of time. IPL has been used for the treatment of facial telangiectasia and rosacea. There is generally no purpura when appropriate settings are used, but care must be taken to avoid dyspigmentation and blistering in darker skin types. As with other light sources, a series of treatment sessions spaced out every 4–6 weeks is typically required for maximum improvement with IPL systems.



**Fig. 38-8** Laser treatment of venous lake. A, Before treatment. B, After two treatments with long-pulsed Nd:YAG laser.

**Civas E, et al:** Clinical experience in the treatment of different vascular lesions using a neodymium-doped yttrium aluminum garnet laser. *Dermatol Surg* 2009; 35(12):1933–1941.

**Clark C, et al:** Treatment of superficial cutaneous vascular lesions: experience with the KTP 532 nm laser. *Lasers Med Sci* 2004; 19(1):1–5.

**Faurschou A, et al:** Pulsed dye laser vs. intense pulsed light for port-wine stains: a randomized side-by-side trial with blinded response evaluation. *Br J Dermatol* 2009; 160(2):359–364.

**Galeckas KJ:** Update on lasers and light devices for the treatment of vascular lesions. *Semin Cutan Med Surg* 2008; 27(4):276–284.

**Groot D, et al:** Algorithm for using a long-pulsed Nd:YAG laser in the treatment of deep cutaneous vascular lesions. *Dermatol Surg* 2003; 29:35.

**Huikeshoven M, et al:** Redarkening of port-wine stains 10 years after pulsed-dye-laser treatment. *N Engl J Med* 2007; 356(12):1235–1240.

**Kessels JP, et al:** Superficial hemangioma: pulsed dye laser versus wait-and-see. *Dermatol Surg* 2013; 39(3 Pt 1):414–421.

**Manuskiatti W, Fitzpatrick RE:** Treatment response of keloidal and hypertrophic sternotomy scars: comparison among intralesional corticosteroid, 5-fluorouracil, and 585-nm flashlamp-pumped pulsed-dye laser treatments. *Arch Dermatol* 2002; 138:1149.

**Neuhaas IM, et al:** Comparative efficacy of nonpurpuragenic pulsed dye laser and intense pulsed light for erythematotelangiectatic rosacea. *Dermatol Surg* 2009; 35(6):920–928.

**Nouri K, et al:** Comparison of the effects of short- and long-pulse durations when using a 585-nm pulsed dye laser in the treatment of new surgical scars. *Lasers Med Sci* 2010; 25(1):121–126.

**Reddy KK, et al:** Treatment of port-wine stains with a short pulse width 532-nm Nd:YAG laser. *J Drugs Dermatol* 2013; 12(1):66–71.

**Robson KJ, et al:** Pulsed-dye laser versus conventional therapy in the treatment of warts: a prospective randomized trial. *J Am Acad Dermatol* 2000; 43:275.

**Savas JA, et al:** Pulsed dye laser-resistant port-wine stains: mechanisms of resistance and implications for treatment. *Br J Dermatol* 2013; 168(5):941–953.

**Schellhaas U, et al:** Pulsed dye laser treatment is effective in the treatment of recalcitrant viral warts. *Dermatol Surg* 2008; 34(1):67–72.

**Schroeter CA, et al:** Effective treatment of rosacea using intense pulsed light systems. *Dermatol Surg* 2005; 31(10):1285–1289.

**Stier MF, et al:** Laser treatment of pediatric vascular lesions: port wine stains and hemangiomas. *J Am Acad Dermatol* 2008; 58(2):261–285.

**Tan SR, Tope WD:** Pulsed dye laser treatment of rosacea improves erythema, symptomatology, and quality of life. *J Am Acad Dermatol* 2004; 51(4):592–599.

**Uebelhoefer NS, et al:** A split-face comparison study of pulsed 532-nm KTP laser and 595-nm pulsed dye laser in the treatment of facial telangiectasias and diffuse telangiectatic facial erythema. *Dermatol Surg* 2007; 33(4):441–448.

**Witman PM, et al:** Complications following pulsed dye laser treatment of superficial hemangiomas. *Lasers Surg Med* 2006; 38(2):116–123.

**Table 38-3** Q-switched (QS) lasers

Laser type	Wavelength (nm)	Pulse duration (ns)
QS Nd:YAG (frequency doubled)	532	5–7
QS ruby	694	25–40
QS alexandrite	755	50–100
QS Nd:YAG	1064	5–7

Nd:YAG, Neodymium-doped yttrium-aluminum-garnet; ns, nanoseconds.

## LASER TREATMENT FOR PIGMENTED LESIONS

Highly pigment-selective Q-switched (QS) lasers are used extensively in the treatment of both epidermal and dermal pigmented lesions. In most cases, the target chromophore is the melanosome. These tiny structures have a very short TRT (250–1000 ns), and the development of Q-switching allows for production of extremely high energies and short, nanosecond (ns) pulse durations. As a result, these lasers can produce damage to the selected target while minimizing injury to surrounding tissue.

Q-switched lasers are used to treat epidermal pigmented lesions and tattoos. The delivery of tremendous amounts of energy over a very short period (nanoseconds or picoseconds) produces pressure waves. This photoacoustic effect results in shock waves that shatter the larger ink particles into smaller fragments. Repeated treatments are necessary for complete response. QS lasers include the ruby (694 nm), alexandrite (755 nm), and Nd:YAG, in both a frequency-doubled (532 nm) and standard (1064 nm) mode (Table 38-3). Because of the longer wavelength, the Nd:YAG laser penetrates much more deeply and therefore is more useful in treating more deeply seated or thicker lesions compared to shorter-wavelength QS lasers.

Less pigment-selective lasers can be used in some clinical settings. The variable-pulsed KTP laser can be used to treat epidermal pigmentation, such as lentigines, ephelides, thin seborrheic keratoses, and dermatosis papulosis nigra. Because the KTP laser has a limited depth of penetration, it is not effective in the treatment of deeper dermal lesions. Long-pulsed ruby, alexandrite, and Nd:YAG lasers can also be used to treat



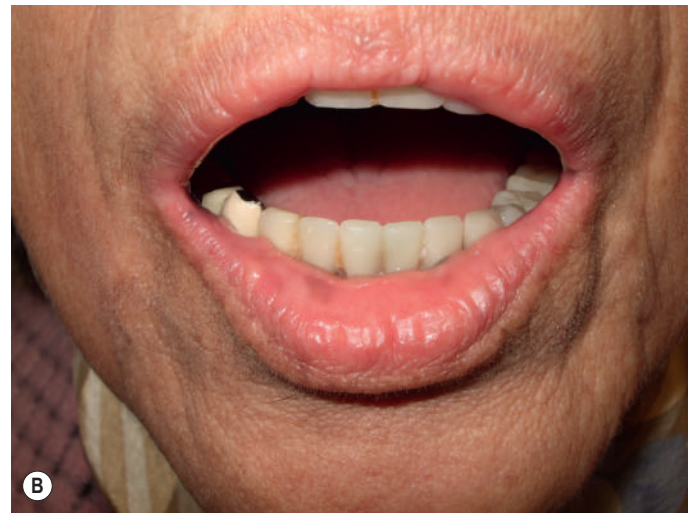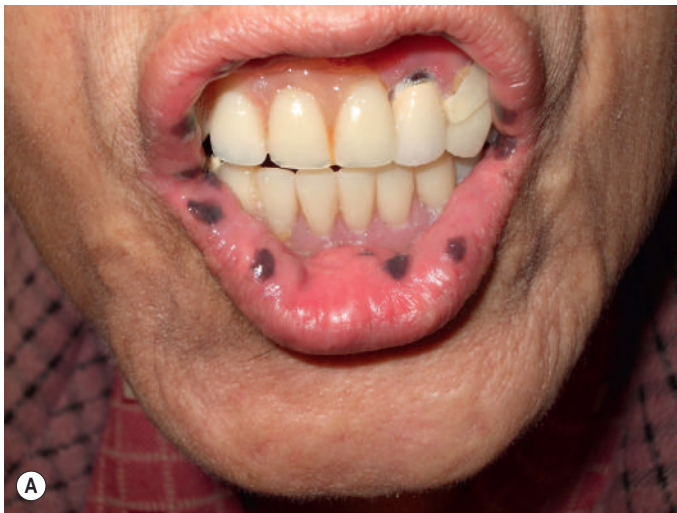pigmented lesions, but are not as effective as their QS counterparts.

Non-pigment-specific ablative lasers have been used in the treatment of pigmented lesions and tattoos. Carbon dioxide (10,600 nm) and erbium:YAG lasers (2940 nm) target water. They nonselectively remove the entire epidermis and a variable level of dermis tissue, as well as any associated pigment present.

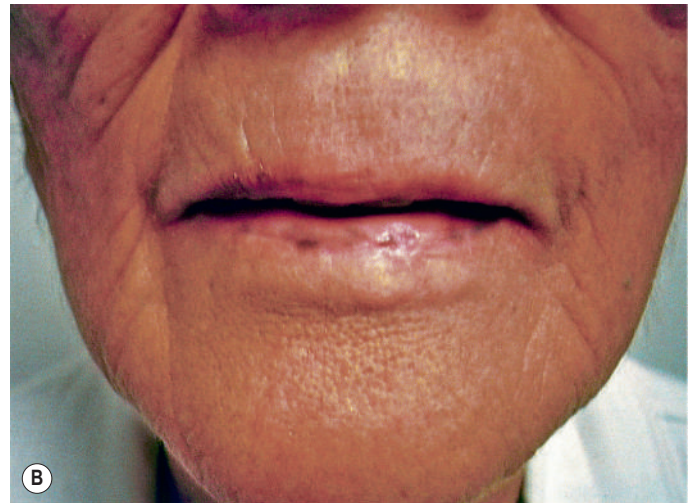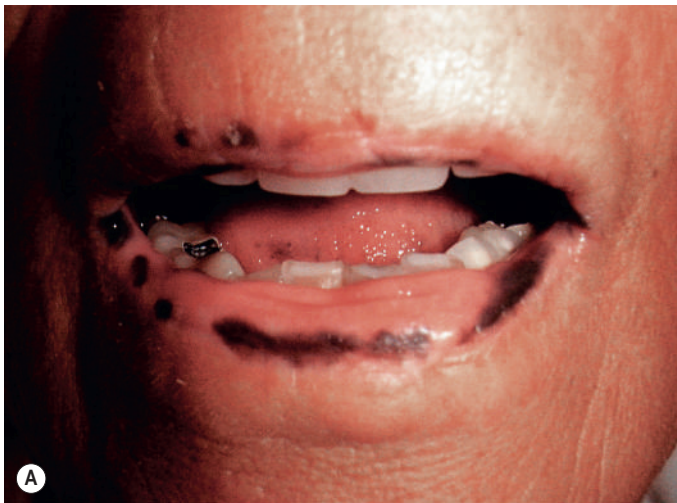### Epidermal pigmented lesions

Lentigines are hyperpigmented macules composed of an increased number of basal melanocytes. These lesions can be effectively treated with a variety of laser and light sources because of their superficial position in the skin. QS lasers can be used to treat solar lentigines and those associated with certain syndromes (e.g., Peutz-Jeghers) (Figs. 38-9 and 38-10). Variable-pulsed KTP provides effective treatment. IPL is an excellent choice for patients with widespread photodamage consisting of both vascular and pigmentary changes.

Café au lait macules and Becker's nevus can be treated with QS lasers. Unfortunately, treatment often results in variable clinical efficacy. Short-term lightening or clearing with multiple treatments is frequently seen, but recurrence is common.



**Fig. 38-9** Laser therapy for labial melanotic macules. A, Before treatment. B, After single treatment with Q-switched (QS) 532-nm laser.



**Fig. 38-10** Laser treatment of lip lentigines in patient with Peutz-Jeghers syndrome. A, Before treatment. B, After treatment with QS ruby laser.

### Dermal pigmented lesions

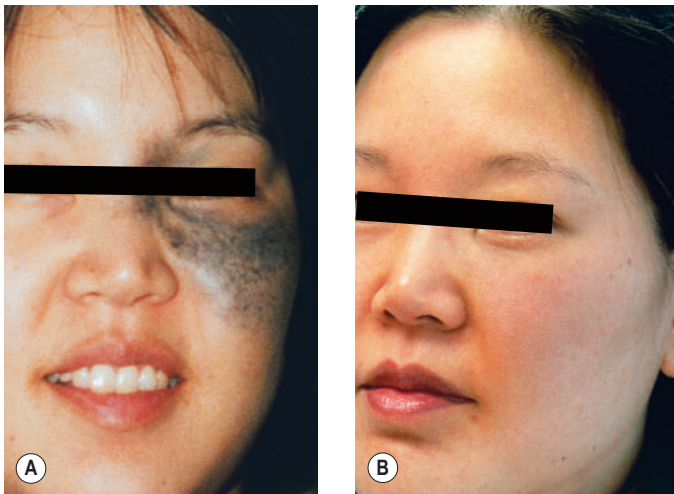
Nevus of Ota and nevus of Ito are dermal melanocytoses that can be effectively treated with QS lasers. A series of treatments can significantly improve or even clear the lesion (Fig. 38-11). These treatments are generally well tolerated and the results long-lasting.

Melasma is an acquired hypermelanosis that is often associated with sun exposure, pregnancy, and oral contraceptives. First-line treatment includes strict sun protection, discontinuing any offending systemic medication, and the use of topical agents such as hydroquinone and retinoids. Laser treatment is often ineffective, and recurrence is frequently seen in patients with initial improvement.

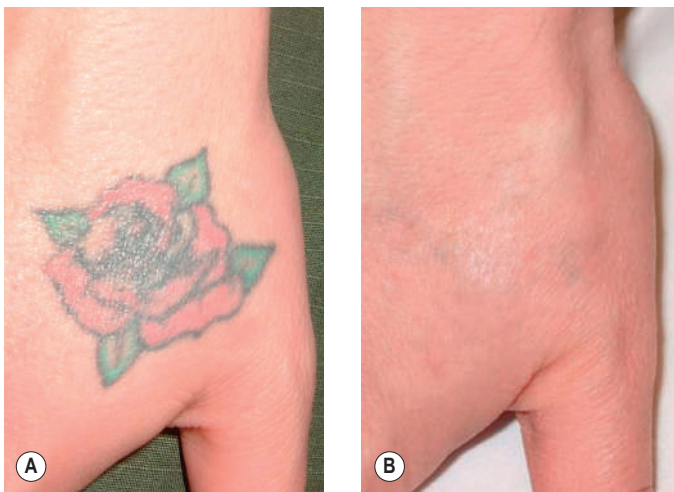Postinflammatory hyperpigmentation does not generally respond to QS laser. Recurrence or worsening is typically seen because of additional epidermal injury associated with laser treatment.

### Tattoos

Pigmentation to mark the skin for decorative purposes has been used by humans for thousands of years and remains a popular practice today. As a result of the increasing number



**Fig. 38-11** Laser therapy for patient with nevus of Ota. A, Before treatment. B, After treatment with QS ruby laser.



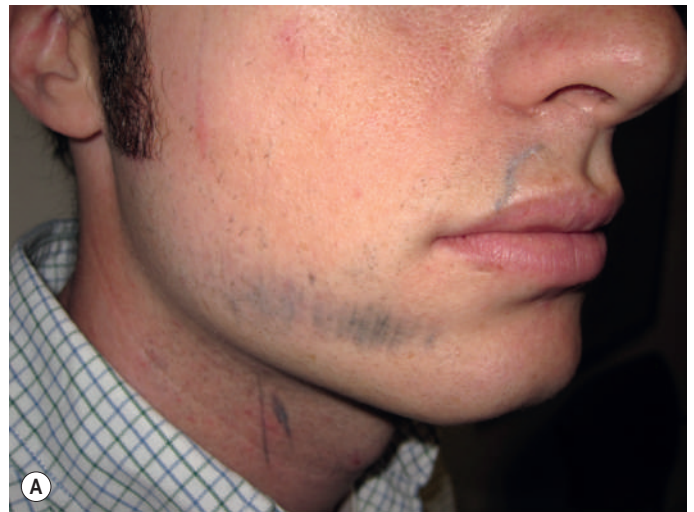**Fig. 38-12** Laser therapy for tattoo removal. A, Before treatment. B, After six treatments with QS ruby and QS Nd:YAG laser.

of people with tattoos, it should come as no surprise that many patients desire removal. Regardless of the type of tattoo—cosmetic, medical, or traumatic—effective treatment can be frequently offered.

In the past, tattoos were removed by a variety of nonselective destructive techniques, including excision, dermabrasion, cryosurgery, and ablative laser. Although effective in eliminating the ink, these techniques produced significant scarring. With the advent of newer technology that is more specific and less traumatic, these destructive modalities are not generally employed today.

Currently, QS lasers are the first-line treatment for tattoo removal. The delivery of high energy in very short pulse durations causes fragmentation of the tattoo ink particle, which is then eliminated from the body by phagocytosis of macrophages and lymphatic drainage. Repeat treatments are required to achieve maximum benefit (Fig. 38-12).

Patients frequently inquire as to the number of treatment sessions needed for maximum improvement. Unfortunately, a precise answer is difficult to provide and depends on the amount of ink in the tattoo, size of tattoo, location, and color being treated. Traumatic tattoos typically respond extremely well with a short course of treatments. Amateur tattoos typically have less ink and generally have a good response to laser



**Fig 38-13** Traumatic tattoo. A, Before laser treatment. B, After two treatments with QS Nd:YAG laser.

treatment. Traumatic tattoos from an injury typically respond very well with a limited number of treatments (Fig. 38-13). In contrast, multicolored professional tattoos have a more unpredictable response and require more treatments, sometimes 10-15 or more, to achieve maximum benefit. The choice of which laser to use depends on the specific tattoo color being targeted (Table 38-4).

### Tattoo complications

Textural changes can occur as a result of the repetitive injury associated with laser treatment (Fig. 38-14). Epidermal injury can be seen with excessive fluences and with short treatment intervals. By spacing out treatment sessions, lowering fluences, and using longer wavelengths to protect the epidermis, this can often be avoided.

Hypopigmentation is sometimes seen in patients with darker skin types (Fig. 38-15). Similar to textural changes, pigmentary changes are more common with shorter wavelengths (ruby and alexandrite), which can cause more epidermal damage. Similar precautions can be used to minimize these changes.

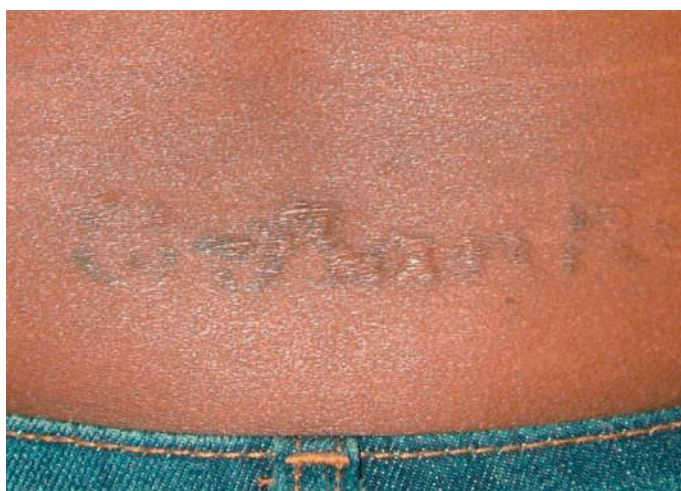Paradoxical darkening of flesh, brown, or white tattoos (with red and yellow ink less frequently) can occur immediately following treatment with QS lasers. The reduction of rust-colored ferric oxide to black-colored ferrous oxide or the white-colored titanium<sup>4+</sup> dioxide to blue titanium<sup>3+</sup> dioxide is thought to be responsible for the color change. This reaction



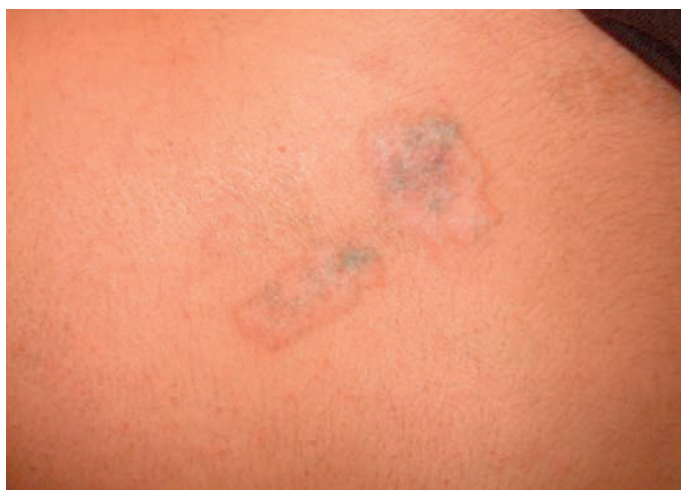**Table 38-4** Tattoo colors and pigments, with lasers used for treatment

Color/etiology	Pigment	Laser
Traumatic	Lead, asphalt, carbon, gunpowder	QS ruby; QS alexandrite; QS Nd:YAG (1064 nm)
Amateur black	India ink, carbon	QS ruby; QS alexandrite; QS Nd:YAG (1064 nm)
Professional black	Carbon, iron oxide, logwood extract	QS ruby; QS alexandrite; QS Nd:YAG (1064 nm)
Blue	Cobalt aluminate (azure blue)	QS ruby; QS alexandrite; QS Nd:YAG (1064 nm)
Green	Chromium oxide (casalis green), hydrated chromium sesquioxide (guignet green), malachite green, lead chromate, ferroferric cyanide, curcumin green, phthalocyanine dyes (copper salts with yellow coal tar dyes)	QS ruby; QS alexandrite
Red	Mercury sulfide (cinnabar), cadmium selenide (cadmium red), sienna (red ochre; ferric hydrate and ferric sulfate), azo dyes	QS Nd:YAG (532 nm)
Yellow	Cadmium sulfide (cadmium yellow), ochre, curcumin yellow	QS Nd:YAG (532 nm)
Brown	Ochre	Tan/light brown: QS Nd:YAG (532 nm) Dark brown: QS ruby; QS alexandrite; QS Nd:YAG (1064 nm)
Violet	Manganese violet	QS Nd:YAG (532 nm)
White	Titanium dioxide, zinc oxide	QS Nd:YAG (532 nm)
Flesh	Iron oxides	QS Nd:YAG (532 nm)

QS, Q-switched; Nd:YAG, neodymium-doped yttrium-aluminum-garnet.



**Fig. 38-14** Textural changes secondary to QS laser treatment.



**Fig. 38-15** Hypopigmentation secondary to QS laser treatment.

is typically seen is cosmetic tattoos used for lip liners and eyebrows. However, many brightly colored tattoos have some white mixed in with them, so caution must be taken in these circumstances (Fig. 38-16). A test treatment in a limited area should be done if paradoxical darkening is possible. The darkened tattoo can be treated with the appropriate QS wavelength, but response is unpredictable and requires numerous treatments.

Despite appropriate treatment, tattoos may not respond completely. This may result from the color, ink density, anatomic location, or age of the tattoo. Appropriate preoperative counseling is required before embarking on any treatment course.

Treatment of gunpowder traumatic tattoos can result in microexplosions and scars. Care must be taken when treating these patients.

**Bencini PL, et al:** Removal of tattoos by Q-switched laser: variables influencing outcome and sequelae in a large cohort of treated patients. *Arch Dermatol* 2012; 148(12):1364–1369.

**Brauer JA, et al:** Successful and rapid treatment of blue and green tattoo pigment with a novel picosecond laser. *Arch Dermatol* 2012; 148(7):820–823.

**Choudhary S, et al:** Lasers for tattoo removal: a review. *Lasers Med Sci* 2010; 25(5):619–627.

**Felton SJ, et al:** Our perspective of the treatment of naevus of Ota with 1,064-, 755- and 532-nm wavelength lasers. *Lasers Med Sci* 2014; 29(5):1745–1749.

**Fusade T, et al:** Treatment of gunpowder traumatic tattoo by Q-switched Nd:YAG laser: an unusual adverse effect. *Dermatol Surg* 2000; 26(11):1057–1059.

**Halachmi S, et al:** Melasma and laser treatment: an evidenced-based analysis. *Lasers Med Sci* 2014; 29(2):589–598.

**Holzer AM, et al:** Adverse effects of Q-switched laser treatment of tattoos. *Dermatol Surg* 2008; 34(1):118–122.

**Kent KM, Graber EM:** Laser tattoo removal: a review. *Dermatol Surg* 2012; 38(1):1–13.

**Liu J, et al:** A retrospective study of Q-switched alexandrite laser in treating nevus of Ota. *Dermatol Surg* 2011; 37(10):1480–1485.

**Park JM, et al:** Combined use of intense pulsed light and Q-switched ruby laser for complex dyspigmentation among Asian patients. *Lasers Surg Med* 2008; 40(2):128–133.



**Fig. 38-16** Paradoxical darkening of red tattoo after single test pulse with QS 532-nm laser. A, Before treatment. B, After treatment of darkening with QS Nd:YAG laser.

**Sadighha A, et al:** Efficacy and adverse effects of Q-switched ruby laser on solar lentigines: a prospective study of 91 patients with Fitzpatrick skin type II, III, and IV. *Dermatol Surg* 2008; 34(11):1465–1468.

**Trafeli JP, et al:** Use of a long-pulse alexandrite laser in the treatment of superficial pigmented lesions. *Dermatol Surg* 2007; 33(12):1477–1482.

**Wang HW, et al:** Analysis of 602 Chinese cases of nevus of Ota and the treatment results treated by Q-switched alexandrite laser. *Dermatol Surg* 2007; 33(4):455–460.

**Xi Z, et al:** Q-switched alexandrite laser treatment of oral labial lentigines in Chinese subjects with Peutz-Jeghers syndrome. *Dermatol Surg* 2009; 35(7):1084–1088.

**Zhou X, et al:** Efficacy and safety of Q-switched 1,064-nm neodymium-doped yttrium aluminum garnet laser treatment of melasma. *Dermatol Surg* 2011; 37(7):962–970.

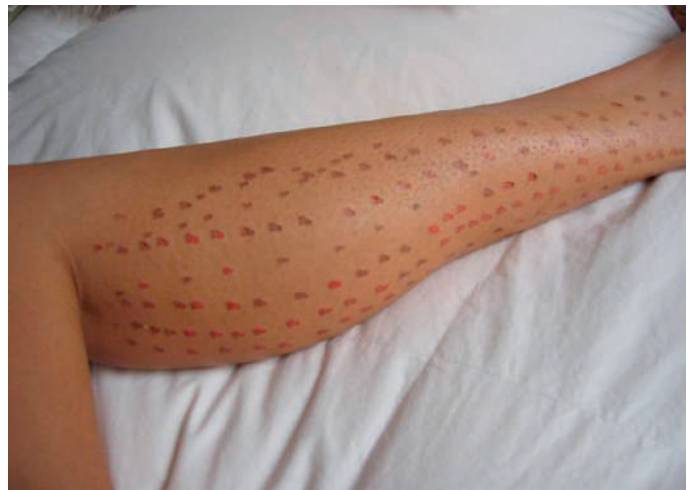## LASER HAIR REMOVAL

Laser hair removal is widely used for the permanent reduction of hair and is one of the most popular laser procedures performed. Hair removal lasers target the melanin within the follicle, and given the size of the target chromophore, longer pulse durations are required to generate enough heat to damage the bulbar stem cells. Patients with dark hair and lightly pigmented skin are the best candidates for treatment. In contrast, white, blond, and gray hairs generally respond poorly given their absence of a sufficient pigment target.

Patients must avoid waxing, electrolysis, or plucking of hairs before laser treatment, because hair is required to be present as a target. Shaving before laser treatment is acceptable and will not interfere with efficacy. Shaving is mandatory immediately before treatment to avoid epidermal injury from absorption of the laser by hairs on the surface of the skin. Only hairs in the anagen growth phase are permanently injured. Therefore, sufficient time must elapse between treatments for hair to regrow and provide an appropriate chromophore for subsequent laser treatment, generally 6–8 weeks.

Devices currently used for hair removal include the long-pulsed ruby, alexandrite, diode, and Nd:YAG lasers and IPL. Multiple treatments are required for maximum benefit. In addition, these longer-pulsed lasers can produce a significant reduction in both hair and papules/pustules in patients with pseudofolliculitis barbae, acne keloidalis nuchae, or folliculitis decalvans.

Complications are rare with proper patient selection and treatment parameters. Excessive fluences or insufficient



**Fig. 38-17** Epidermal burns secondary to laser hair removal performed by an unlicensed provider at a “medi-spa.”

cooling can result in epidermal injury (Fig. 38-17). Caution must be employed in treating patients with increased skin pigmentation caused by sun tanning, because pigmentary changes and cutaneous burns can occur. Since melanin is the target for these lasers, care must be taken in treating more darkly pigmented patients to avoid epidermal damage. In this patient population, the longer-pulsed Nd:YAG laser has allowed safe treatment with fewer complications, because of the deeper penetration and reduced melanin absorption of this wavelength. Paradoxical hypertrichosis as a result of laser hair treatment has been reported. The etiology is unclear, but the condition seems to occur more frequently in darker skin types. Rarely, atypical cutaneous infections have been reported. Interestingly, studies have shown that laser hair removal is the most common litigated laser procedure, with nonphysician providers accounting for a significant proportion of these cases.

**Alajlan A, et al:** Paradoxical hypertrichosis after laser epilation. *J Am Acad Dermatol* 2005; 53(1):85–88.

**Bouzari N, et al:** Laser hair removal: comparison of long-pulsed Nd:YAG, long-pulsed alexandrite, and long-pulsed diode lasers. *Dermatol Surg* 2004; 30(4 Pt 1):498–502.



**Davoudi SM, et al:** Comparison of long-pulsed alexandrite and Nd:YAG lasers, individually and in combination, for leg hair reduction: an assessor-blinded, randomized trial with 18 months of follow-up. *Arch Dermatol* 2008; 144(10):1323–1327.

**De Benito V, et al:** *Mycobacterium chelonae* infection after laser hair removal. *J Am Acad Dermatol* 2013; 69(5):e255–e257.

**Desai S, et al:** Paradoxical hypertrichosis after laser therapy: a review. *Dermatol Surg* 2010; 36(3):291–298.

**El Bedewi AF:** Hair removal with intense pulsed light. *Lasers Med Sci* 2004; 19(1):48–51.

**Esmat SM, et al:** The efficacy of laser-assisted hair removal in the treatment of acne keloidalis nuchae: a pilot study. *Eur J Dermatol* 2012; 22(5):645–650.

**Gan SD, Graber EM:** Laser hair removal: a review. *Dermatol Surg* 2013; 39(6):823–838.

**Haak CS, et al:** Hair removal in hirsute women with normal testosterone levels: a randomized controlled trial of long-pulsed diode laser vs. intense pulsed light. *Br J Dermatol* 2010; 163(5):1007–1013.

**Ismail SA:** Long-pulsed Nd:YAG laser vs. intense pulsed light for hair removal in dark skin: a randomized controlled trial. *Br J Dermatol* 2012; 166(2):317–321.

**Jalian HR, et al:** Increased risk of litigation associated with laser surgery by nonphysician operators. *JAMA Dermatol* 2014; 150(4):407–411.

**Klein A, et al:** Photoepilation with a diode laser vs. intense pulsed light: a randomized, intrapatient left-to-right trial. *Br J Dermatol* 2013; 168(6):1287–1293.

**McGill DJ, et al:** A randomised, split-face comparison of facial hair removal with the alexandrite laser and intense pulsed light system. *Lasers Surg Med* 2007; 39(10):767–772.

**Rao K, Sankar TK:** Long-pulsed Nd:YAG laser-assisted hair removal in Fitzpatrick skin types IV–VI. *Lasers Med Sci* 2011; 26(5):623–626.

**Schulze R, et al:** Low-fluence 1,064-nm laser hair reduction for pseudofolliculitis barbae in skin types IV, V, and VI. *Dermatol Surg* 2009; 35(1):98–107.

## ABLATIVE LASER RESURFACING

Both carbon dioxide (CO<sub>2</sub>) and erbium:YAG (Er:YAG) lasers are absorbed by water. Since water makes up 72% of the skin, these lasers effectively ablate the skin to varying depths depending on the energy delivered. Ablative lasers can be used therapeutically to treat conditions such as warts, adnexal tumors, and actinic damage. In addition to these medical indications, ablative lasers can also be employed to remove very superficial external layers and resurface the skin for cosmetic enhancement (e.g., acne scarring, photorejuvenation [see Video 38-1]). Despite all the efforts to produce nonablative resurfacing technology, ablative lasers remain unparalleled in producing meaningful and dramatic rejuvenation.

Early systems employed a continuous-wave mode of emission, which led to a greater degree of thermal damage and risk of scarring. Newer, high-energy, ultrapulsed and computerized scanning systems have allowed a greater degree of control with laser ablation, resulting in more predictable outcomes.

### Carbon dioxide lasers

The CO<sub>2</sub> laser emits an invisible infrared beam of 10,600 nm and can be used in continuous-wave or superpulsed mode. Water nonselectively absorbs laser energy, turning it instantly into steam, and producing ablative and thermal damage. Used in the superpulsed mode, the laser beam can be delivered in short bursts, allowing thermal destruction of the epidermis and papillary dermis while limiting deeper thermal damage. Delivery in this mode is more uniform and much faster when the optomechanical scanner is employed. Superpulsed CO<sub>2</sub> lasers are extremely effective for the treatment of actinic damage and photoaging. The thermal injury causes

conformational changes within the collagen, leading to clinical tightening. As such, ablative laser resurfacing produces significant improvement in wrinkling, scarring, and skin tone.

Ablative laser surgery can be performed safely and comfortably under local anesthesia in the outpatient setting. Oral anxiolytics are routinely employed before starting the procedure. Regional blocks and local infiltration of anesthesia can provide effective pain control. Metal eye shields and anesthetic eye drops (e.g., proparacaine) should be used to provide eye protection. Wet towels are placed around the treatment site to prevent fire or heat injury.

Side effects include postinflammatory pigmentary changes, especially in patients with Fitzpatrick skin types III–VI. Treatment with hydroquinone at the first sign of hyperpigmentation can effectively reduce the hyperpigmentation. Hypopigmentation is frequently seen after resurfacing and is often caused by the contrast between treated and untreated skin. To minimize the aesthetic impact, the entire face should be treated or, if this is not possible, regional subunits to avoid a clear line of demarcation. Scarring and textural changes can rarely be seen. Prolonged erythema can last 3–10 months. Bacterial, viral, and fungal infections have all been reported with resurfacing but have a relatively low incidence. Prophylactic antiviral agents are typically started on the day of the procedure, even in patients with no history of orolabial herpes simplex virus (HSV) infection. There is no role for universal antibiotic or antifungal prophylactic treatment in patients undergoing resurfacing. Rather, treatment can be started empirically if patients develop infection, then tailored based on culture results. Given the morbidity of the postoperative course and prolonged recovery associated with ablative resurfacing, patients must be properly counseled during the preoperative visit.

Used in the quasi-continuous-wave mode, the CO<sub>2</sub> laser is an excellent therapeutic choice for very large plantar and perianal warts that have failed to respond to routine office modalities. Both a cutting mode and a defocused ablative mode can be used with these systems to excise the visible verrucae effectively and to treat any residual human papillomavirus in surrounding skin.

The CO<sub>2</sub> laser is also a treatment option for refractory keloids. Other benign lesions amenable to CO<sub>2</sub> laser ablation include xanthelasma, rhinophyma, and syringomas. Various malignant and premalignant lesions are also effectively treated by laser ablation, including actinic cheilitis and superficial basal and squamous cell carcinomas.

### Erbium:yttrium-aluminum-garnet laser

The Er:YAG laser emits an invisible near-infrared beam of 2940 nm, resulting in significantly more efficient absorption by water (16 times) and a more explosive ablative effect than with the CO<sub>2</sub> laser. As such, the Er:YAG laser results in tissue ablation with less surrounding thermal damage. In addition, this wavelength is close to a collagen absorption peak, thus allowing for greater collagen ablation than the CO<sub>2</sub> laser. The decreased thermal injury and collagen ablation is an advantage for treatment of scars, photodamaged skin, rhytids, and rhinophyma (Figs. 38-18 and 38-19). Some maintain that healing may be slightly faster, with less risk of prolonged erythema and scarring. Nonetheless, the depth of injury produced (regardless of technology used) is the primary determinant for the healing process and incidence of side effects, not the laser used.

Compared with the photocoagulation effects of the CO<sub>2</sub> laser, the decreased thermal damage produced by the Er:YAG laser can result in poor hemostasis. To address this limitation, certain Er:YAG systems have a programmable coagulation



mode to limit the amount of intraoperative bleeding. In addition, the collagen-tightening effect may not be as pronounced as with the CO<sub>2</sub> laser. However, when similar clinical injuries and depth are achieved, studies have shown that the Er:YAG and CO<sub>2</sub> lasers have comparable photorejuvenating effects, as well as similar postoperative healing times and complication profiles.

### Fractional resurfacing

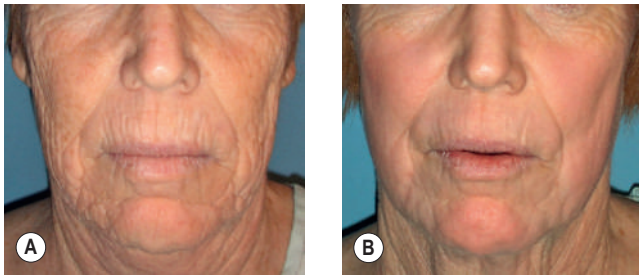
In fractional photothermolysis, an ablative laser is administered in a pixilated pattern over a grid. These lasers created small columns of thermal injury, or microthermal zones (MTZ), which are separated by areas of untreated skin. Only 15–25% of the skin surface is typically ablated during a treatment session, so this technique allows for more rapid reepithelialization, compared with the confluent patch of laser-induced injury typically created with traditional ablative resurfacing. The injury created by MTZ results in the stimulation of collagen synthesis and cutaneous remodeling, much in the same manner as traditional resurfacing, but to a proportionately lesser degree.

Fractional resurfacing has been used for the treatment of photoaging, with the advantage of more rapid healing, reduced erythema and swelling, and fewer side effects. Fractional

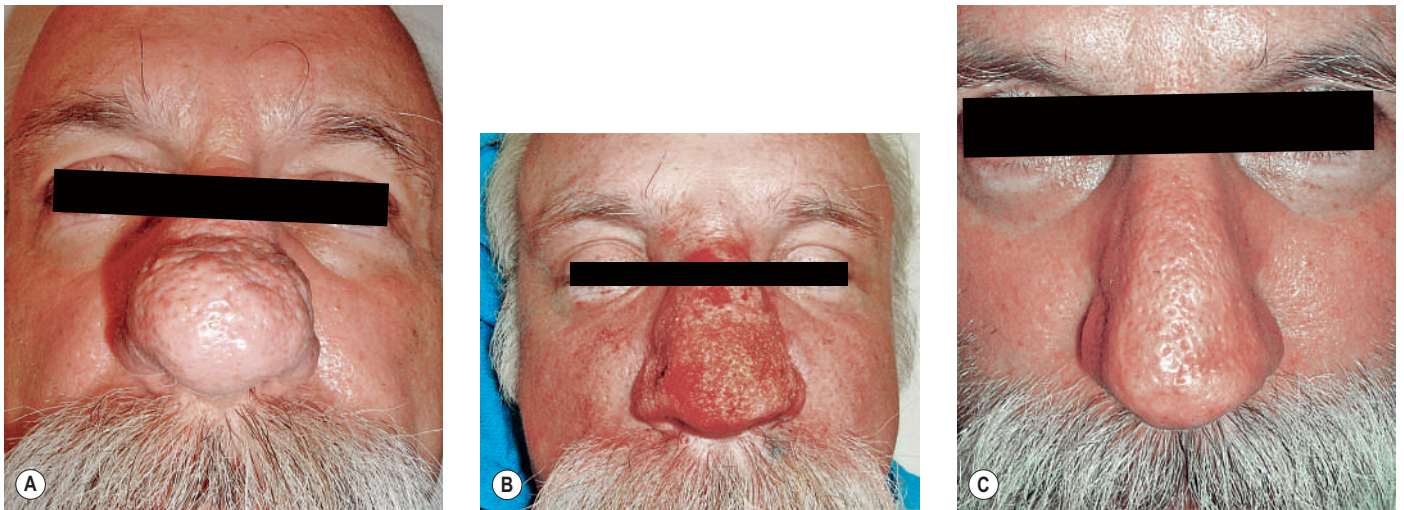
resurfacing has also been used for such indications as acne scars, residual hemangioma residuum, and pigmentary disorders. An additional advantage of this technology is the ability to treat any anatomic location, including hands, chest, neck, and arms. However, patients often need multiple treatment sessions to achieve maximum benefit, and the final result is not nearly as impressive as with traditional ablative resurfacing. In addition, the cumulative downtime required with multiple treatments may exceed that of a single ablative resurfacing treatment, thus negating the perceived benefit of fractional resurfacing.

Fractional ablative resurfacing has been used for the treatment of acne scarring. It has also been used for residual hemangioma and pigmentary disorders such as melasma.

- Brightman LA, et al:** Ablative fractional resurfacing for involuted hemangioma residuum. *Arch Dermatol* 2012; 148(11):1294–1298.
- Ei-Domyati M, et al:** Fractional versus ablative erbium:yttrium-aluminum-garnet laser resurfacing for facial rejuvenation: an objective evaluation. *J Am Acad Dermatol* 2013; 68(1):103–112.
- Graber EM, et al:** Side effects and complications of fractional laser photothermolysis: experience with 961 treatments. *Dermatol Surg* 2008; 34(3):301–305.
- Hedelund L, et al:** Fractional CO<sub>2</sub> laser resurfacing for atrophic acne scars: a randomized controlled trial with blinded response evaluation. *Lasers Surg Med* 2012; 44(6):447–452.
- Madan V, et al:** Carbon dioxide laser treatment of rhinophyma: a review of 124 patients. *Br J Dermatol* 2009; 161(4):814–818.
- Metelitsa AI, Alster TS:** Fractionated laser skin resurfacing treatment complications: a review. *Dermatol Surg* 2010; 36(3):299–306.
- Ong MW, et al:** Fractional laser resurfacing for acne scars: a review. *Br J Dermatol* 2012; 166(6):1160–1169.
- Orringer JS, et al:** Direct quantitative comparison of molecular responses in photodamaged human skin to fractionated and fully ablative carbon dioxide laser resurfacing. *Dermatol Surg* 2012; 38(10):1668–1677.
- Riggs K, et al:** Ablative laser resurfacing: high-energy pulsed carbon dioxide and erbium:yttrium-aluminum-garnet. *Clin Dermatol* 2007; 25(5):462–473.
- Tanzi EL, Alster TS:** Single-pass carbon dioxide versus multiple-pass Er:YAG laser skin resurfacing: a comparison of postoperative wound healing and side-effect rates. *Dermatol Surg* 2003; 29(1):80–84.
- Tierney EP, Hanke CW:** Fractionated carbon dioxide laser treatment of photoaging: prospective study in 45 patients and review of the literature. *Dermatol Surg* 2011; 37(9):1279–1290.
- Tierney EP, et al:** Review of fractional photothermolysis: treatment indications and efficacy. *Dermatol Surg* 2009; 35(10):1445–1461.



**Fig. 38-18** Ablative resurfacing using Er:YAG laser. A, Before treatment. B, Six months after full-face resurfacing. (Courtesy of Roy Grekin, MD.)



**Fig. 38-19** Laser therapy for rhinophyma. A, Before treatment. B, Immediately after treatment with Er:YAG laser. C, Final result 3 months later, with marked improvement in shape and appearance.



Dermatologists have been leaders in the field of cosmetic surgery. Many procedures, products, and technologies in cosmetic dermatologic surgery have been developed and researched by dermatologists. Patients are increasingly turning to dermatologists for the management of cosmetic issues. As a result, the specialty must continue to be at the forefront of cosmetic procedures and remain committed to advancing the field through innovation and scientific progress.

### SOFT TISSUE AUGMENTATION

Soft tissue augmentation has been gaining in popularity in recent years as patients seek cosmetic improvement without undergoing invasive procedures. Numerous fillers are available to correct soft tissue contour abnormalities and provide cosmetic enhancement. Although they provide numerous advantages over surgical techniques, the temporary nature of most fillers requires repeated treatment to maintain a desired outcome. Some patients find that the temporary nature of these agents is less than ideal, but one must also consider that undesired outcomes of treatment are also temporary. In the last few years, the number of available agents has increased. In Europe, there are as many as 30 different filler choices. The U.S. Food and Drug Administration (FDA) has approved fewer fillers, although several new products have recently become available.

### Bovine collagen

Bovine-derived collagen has been used for more than 20 years and is the gold standard against which all filler substances are compared. There are currently three FDA-approved brand-name products for use in soft tissue augmentation: Zyderm I, Zyderm II, and Zyplast (Allergan, Irvine, CA). The source for all three bovine types is a closed herd in the United States, and there have been no cases of bovine spongiform encephalopathy associated with these products. All are composed of 95% type I collagen and the remainder of type III collagen, suspended in buffered saline and 0.3% lidocaine. Zyderm I consists of 35 mg/mL of collagen, and Zyderm II has a higher concentration of 65 mg/mL. Zyplast is cross-linked with glutaraldehyde, making it more resistant to proteolytic degradation, which provides longer duration. All three products come preloaded into syringes and are stored at 4°C.

Bovine collagen hypersensitivity occurs in about 3% of the population, making skin testing a requirement before using these products. Additionally, 1–2% of patients with a negative skin test will subsequently develop an allergic reaction after treatment. Therefore, many dermatologists recommend a second skin test after an initial negative test. Patients

may also develop allergy after multiple treatments. Therefore, in patients with a span between treatments of more than 2 years, repeated skin testing is indicated.

Zyderm I and Zyderm II are injected into the superficial dermis, whereas Zyplast is placed deeper. A combination of threading, fanning, and serial puncture injection techniques with a 30-gauge needle can be used. Anesthesia may not be required because the product already contains lidocaine; however, regional nerve blocks may be helpful in sensitive patients or when injecting the lips. Slight overcorrection is recommended with bovine collagen because it tends to reduce in volume due to the amount of water in the product.

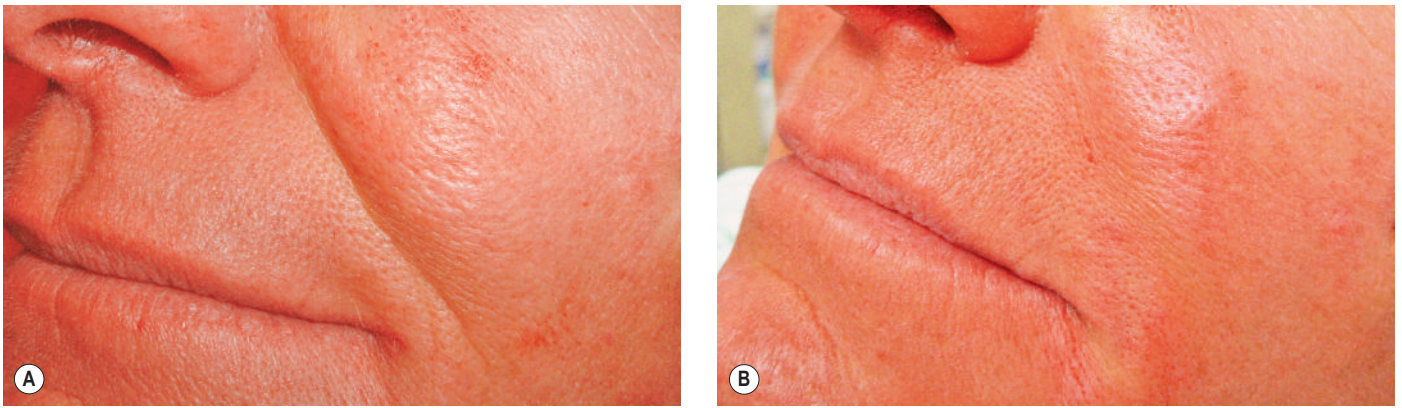
Patients can expect 2–5 months of improvement, depending on the location of placement. Dynamic rhytids (e.g., caused by muscular activity) have a shorter duration of correction, unlike more static conditions (e.g., acne scars). Zyplast may have a longer duration because of its relative protection from enzymatic degradation. However, it must be placed deeper in the dermis to avoid a beaded surface appearance and is therefore less useful for correction of superficial rhytids.

Complications with bovine collagen include delayed hypersensitivity reactions. Although rare, allergic reactions can occur in 1% of patients who have had two negative skin tests. This presents as swollen granulomas or sterile abscesses at the treatment site. Although self-limiting, these reactions can take up to 1 year to resolve. Intralesional steroid injections, antibiotics, and systemic anti-inflammatory drugs can be considered for treatment. Zyplast placed in the glabellar complex has resulted in vascular occlusion and necrosis. This may be caused by the deeper placement required with this product and the associated adverse pressure-related effects on cutaneous vasculature.

### Human collagen

One of the main shortcomings of bovine collagen is the risk of hypersensitivity reaction. Synthetic human collagen has been developed as an alternative that does not require multiple skin testing and can be administered immediately. There has been no documented cross-reaction between bovine and bioengineered human collagen, allowing patients with a documented allergy to bovine collagen to be treated safely with human collagen.

Cosmoderm 1 and 2 and Cosmoplast (Allergan) are FDA-approved bioengineered human collagen derived from neonatal foreskin. Synthetic human collagen has a very similar formulation to its bovine counterpart and is packaged in similar concentrations. Cosmoderm 1 has a concentration of 35 mg/mL and is in phosphate-buffered saline with 0.3% lidocaine. Cosmoderm 2 has a concentration of 65 mg/mL. Cosmoplast has 35 mg/mL of human-derived collagen and is



**Fig. 39-1** Hyaluronic acid filler, nasolabial fold. A, Before treatment. B, Immediately after placement of hyaluronic acid, with marked improvement and reduction of rhytids.

cross-linked with glutaraldehyde. All products have the same indications, are injected in a similar manner to their bovine counterparts, and have similar cosmetic results and longevity.

The clinical use of collagen has been declining as manufacturers have decreased production and transitioned to the manufacturing and promotion of hyaluronic acid fillers.

### Hyaluronic acid

Hyaluronic acid, a polysaccharide, is a natural component of human connective tissue. A member of the family of glycosaminoglycans, hyaluronic acid is composed of repeating disaccharide units. This molecule has the advantage of being identical across all species. As such, hypersensitivity reactions should not occur, and skin testing is not required before treatment. However, early formulations of hyaluronic acid did produce rare hypersensitivity reaction, although the incidence has declined with the introduction of a more purified product. Granulomatous foreign body reactions have been described in case reports.

Hyaluronic acid avidly binds water, and patients may experience redness, swelling, and bruising in the first few days after treatment. Most of the volume is maintained after placement, making overcorrection unnecessary when injecting. Hyaluronic acid products consist of a clear gel in a prepackaged syringe. Early products did not contain lidocaine, often necessitating the use of local anesthesia and regional blocks for patient comfort. However, many current preparations of hyaluronic acid now include lidocaine, thus eliminating the need for adjuvant anesthesia and making them significantly more comfortable for patients. Hyaluronic acid fillers can produce a more durable aesthetic improvement than collagen, often lasting from 5 to 8 months (Fig. 39-1; also see Video 39-1).

The two types of hyaluronic acid filler substances are streptococcal derived and animal (i.e., rooster comb) derived. Streptococcal-derived filler is by far the most common as manufacturers and consumers moved away from animal-derived products due to lack of longevity. There are numerous evolving proprietary formulations, including Restylane and Perlane (Medicis, Scottsdale, AZ), with the "L" designation for the lidocaine-containing formulation; Juvederm and Voluma (Allergan), with the "XC" designation for the lidocaine-containing formulation; and Belotero Balance (Merz; Greensboro, NC). All these fillers come in prepackaged syringes and do not require refrigeration.

The characteristics and viscosity of the different products are largely determined by the size and concentration of the

molecule within each preparation. Restylane contains 20 mg/mL of hyaluronic acid, with a particle size of 100,000/mL, and is injected with a 30-gauge needle. Perlane also has a concentration of 20 mg/mL, but a much larger particle size of 8000/mL, and is appropriate for deeper contour abnormalities. Juvederm is available in two formulations, Ultra and Ultra Plus ("XC" indicates lidocaine-containing product). Both have a concentration of 24 mg/mL, with Ultra Plus being about 20% thicker, making it more appropriate for deeper folds. Voluma is indicated for cheek augmentation or to correct age-related volume loss in the midface. Belotero can be used for fine superficial lines, such as perioral rhytids.

Hyaluronic acids tend to produce more swelling and bruising than collagen. Proper preoperative consultation is necessary to ensure that the patient understands this and does not have upcoming social engagements. Improper placement of hyaluronic acid too superficially can result in a blue discoloration or nodule on the skin surface, known as the Tyndall effect. An incision with a large-gauge needle or No. 11 blade and expression of the product can be performed. Hyaluronidase injections can dissolve the product if either a reaction or unevenness results, a considerable advantage over other filler substances.

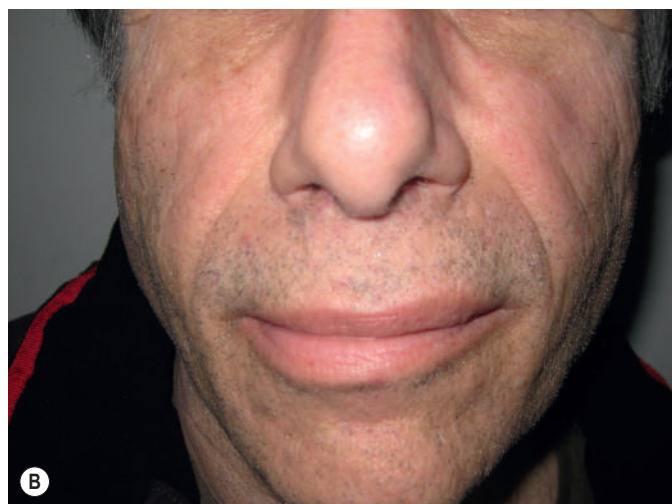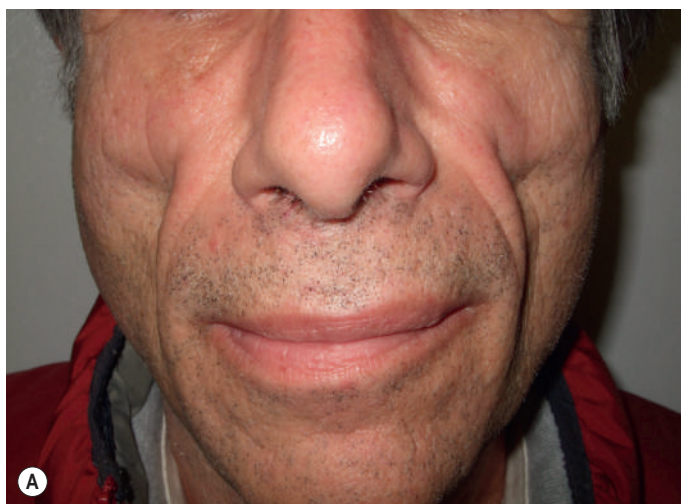### Poly-L-lactic acid

Microparticles of poly-L-lactic acid (Sculptra; Valeant, Bridgewater, NJ) are used as an injectable implant to replace diffuse volume loss, rather than the small-volume injections of other fillers. This product is currently FDA approved for correcting facial lipoatrophy in patients with human immunodeficiency virus (HIV) infection and for aesthetic treatment of lines and contour deficiencies.

Poly-L-lactic acid is a biodegradable, biocompatible, and immunologically inert product that does not require skin testing. Polylactic acid has been used as absorbable suture material (e.g., Vicryl). Polylactic acid is absorbed gradually in the skin, inducing a fibroblastic response and de novo collagen synthesis. Multiple treatment sessions at intervals of 4–6 weeks are often required to achieve the final result (Fig. 39-2). Since correction depends on the formation of new collagen, patients must be counseled that an immediate effect does not occur with this product. Results can last for up to 2 years.

Poly-L-lactic acid comes packaged as a freeze-dried powder and must be reconstituted for a minimum of 4 hours before injection to ensure adequate hydration of the particles. Lidocaine can be added to the vial to reduce injection pain. The product is injected using a 25-gauge needle at the level of the





**Fig. 39-2** Poly-L-lactic acid for HIV lipatrophy. A, Before treatment. B, After five treatments.

deep dermis and subcutaneous junction in a fanning or cross-hatch fashion. Postinjection massage for several days can help reduce nodules.

Side effects include delayed foreign body granulomas at injection sites. Intralesional 5-fluorouracil (5-FU) or triamcinolone, 10 mg/mL, may be used for the treatment of these papules.

### Calcium hydroxylapatite

Calcium hydroxylapatite (Radiesse; Merz, Greensboro, NC) consists of fine particles (25–45  $\mu\text{m}$ ) of material traditionally used to reconstruct bone. Once injected into the dermal-subcutaneous junction, the particles act as scaffolding for autologous collagen synthesis. The ensuing fibrotic reaction results in soft tissue correction that can last for 9–12 months. It is FDA approved for correction of moderate to severe folds and wrinkles, such as nasolabial folds, and for HIV facial lipatrophy.

Injections can be quite painful, and local anesthesia is generally used. Calcium hydroxylapatite is injected into the deep dermis and subcutaneous junction with a threading technique using a 27-gauge needle. It comes prepackaged in syringes and can be stored at room temperature.

Nodules are more often seen when calcium hydroxylapatite is injected into the lips, thus discouraging its use in the treatment of hypolabium. Caution must be exercised; any product that requires a fibrotic reaction to be effective can result in a granulomatous reaction and an untoward result. Since calcium is radiopaque, the product may be detected and may interfere with radiologic imaging.

### Silicone

Silicone has been used in the past for soft tissue augmentation by dermatologists. This product was never FDA approved, and issues of purity and safety limited its widespread use. In 1994, the FDA removed silicone from the market. Recently, however, the FDA approved 1000-centistoke liquid silicone (Silikon 1000; Alcon Labs, Fort Worth, TX) for the treatment of retinal detachment. It is currently being used off-label as permanent filler for HIV-associated facial lipatrophy, scars, and rhytids.

The potential for delayed and severe complications with this permanent filler, as well as legal concerns and restrictions, has

limited use of silicone. Adverse reactions associated with silicone injections include granuloma formation and migration of implant, which are compounded by the permanent nature of the product. Many of the past reported complications of silicone injection were the result of using either an impure, nonmedical-grade substance or an improper technique with large-volume injections. A multisession, microdroplet technique, placing multiple depot injection of 0.01 mL of product into the deep dermis in 1–3 mm intervals, significantly reduces the complication rate. An additional consideration is that the current FDA-approved product is more concentrated than the previous silicone products. Further study is needed to evaluate the long-term safety and efficacy of silicone oil injections for correction of soft tissue contour deficiencies.

### Polymethylmethacrylate

Artefill (Suneva Medical, San Diego), named Artecoll in Europe, is an FDA-approved suspension containing 20% polymethylmethacrylate (PMMA, commonly known as Lucite) microspheres of 30–40 microns ( $\mu$ ) in diameter, suspended in 80% bovine collagen, for soft tissue augmentation. The carrier collagen provides initial correction and is degraded over several months, leaving the PMMA microspheres. PMMA is nondegradable and serves as a permanent framework for connective tissue deposition and can produce long-term correction.

Technique is critical to successful outcomes. If injected too deeply, the implant is ineffective; superficial placement can cause prolonged erythema. Granuloma formation and hypertrophic scarring can occur and have been reported as a delayed reaction. Intralesional triamcinolone can be used for treatment of these reactions. One patient who developed a delayed foreign body granuloma 6 years after injection with PMMA was successfully treated with a 24-week course of 600 mg/day of allopurinol. Intralesional triamcinolone has also been used as a treatment for granulomas. Because the product contains bovine collagen, skin testing is required before use. Early indications suggest efficacy of triamcinolone treatment for acne scarring.

### Expanded polytetrafluoroethylene

Expanded polytetrafluoroethylene (ePTFE) is a synthetic solid material that is soft and pliable, is not degraded, and

has the advantage of being permanent. The material is placed through a small skin incision and positioned in the desired location. Areas typically treated include lip margins or the muscular portion of the vermillion for enhancement, nasolabial folds, and soft tissue depressions. Complications associated with ePTFE include extrusion, migration, shrinkage, and hardening.

### Autologous fat transplantation

Autologous lipotransfer allows for soft tissue augmentation without the risk of allergy, rejection, or infectious transmission. Unlike other filler techniques, fat transfer is truly a grafting procedure. As such, its success is predicated on the survival of the transferred adipocytes. Fat is harvested from a choice of donor sites, typically the abdomen, buttock, thigh, or knee. There is no consensus as to the advantages of harvesting with a liposuction cannula, syringe extraction with a large-bore needle, or open surgical method. The fat is then separated from anesthetic fluid and blood and injected through a large-bore needle (16–18 gauge) into the desired location. Any remaining fat can be frozen at  $-70^{\circ}\text{C}$  for use later, with varying claims regarding loss of efficacy.

The variable rate of graft survival, the recipient site reaction (bruising, swelling), and the added morbidity of a donor site are limiting factors in patient satisfaction with this technique. In some cases, partial survival results in uneven correction that may require additional treatments. Some argue that multiple smaller-volume injections spaced over two or three treatments are more effective than single, large-volume lipotransfer. If the fat survives, it can provide a very natural correction. However, local factors such as motor activity and gravitational effects will mitigate against permanent correction. This technique is not useful for the correction of superficial rhytids and mainly corrects deeper defects such as nasolabial folds, hypolabium, buccal depression, and deep scars.

**Alcalay J, et al:** Late-onset granulomatous reaction to Artecoll. *Dermatol Surg* 2003; 29:859.

**Bachmann F, et al:** The spectrum of adverse reactions after treatment with injectable fillers in the glabellar region: results from the injectable filler safety study. *Dermatol Surg* 2009; 35:1629–1635.

**Baumann LS, et al:** Comparison of smooth-gel hyaluronic acid dermal fillers with cross-linked bovine collagen: a multicenter, double-masked, randomized, within-subject study. *Juvederm vs. Zyplast Nasolabial Fold Study Group. Dermatol Surg* 2007; 33(Suppl 2):S128–S135.

**Benedetto AV, Lewis AT:** Injecting 1000 centistoke liquid silicone with ease and precision. *Dermatol Surg* 2003; 29:211.

**Butterwick KJ, et al:** Fat transplantation using fresh versus frozen fat: a side-by-side two-hand comparison pilot study. *Dermatol Surg* 2006; 32(5):640–644.

**Chen F, et al:** HIV-associated facial lipoatrophy treated with injectable silicone oil: a pilot study. *J Am Acad Dermatol* 2013; 69(3):431–437.

**Epstein RE, Spencer JM:** Correction of atrophic scars with Artefill: an open-label pilot study. *J Drugs Dermatol* 2010; 9(9):1062–1064.

**Glogau RG:** Fillers: from the past to the future. *Semin Cutan Med Surg* 2012; 31(2):78–87.

**Goldman MP:** Cosmetic use of poly-L-lactic acid: my technique for success and minimizing complications. *Dermatol Surg* 2011; 37(5):688–693.

**Lemperle G, et al:** ArteFill permanent injectable for soft tissue augmentation. I. Mechanism of action and injection techniques. *Aesthetic Plast Surg* 2010; 34(3):264–272.

**Lemperle G, et al:** ArteFill permanent injectable for soft tissue augmentation. II. Indications and applications. *Aesthetic Plast Surg* 2010; 34(3):273–286.

**Levy RM, et al:** Treatment of HIV lipoatrophy and lipoatrophy of aging with poly-L-lactic acid: a prospective 3-year follow-up study. *J Am Acad Dermatol* 2008; 59(6):923–933.

**Lorenc ZP, et al:** Review of key Belotero Balance safety and efficacy trials. *Plast Reconstr Surg* 2013; 132(4 Suppl 2):33S–40S.

**Lowe NJ, et al:** Injectable poly-L-lactic acid: 3 years of aesthetic experience. *Dermatol Surg* 2009; 35(Suppl 1):344–349.

**Mamelak AJ, et al:** Foreign body reaction to hyaluronic acid filler injection: in search of an etiology. *Dermatol Surg* 2009; 35(Suppl 2):1701–1703.

**Markey AC, Glogau RG:** Autologous fat grafting: comparison of techniques. *Dermatol Surg* 2000; 26:1135.

**Matarasso SL:** Injectable collagens: lost but not forgotten—a review of products, indications, and injection techniques. *Plast Reconstr Surg* 2007; 120(6 Suppl):17S–26S.

**Moulonguet I, et al:** Foreign body reaction to Radiesse: 2 cases. *Am J Dermatopathol* 2013; 35(3):e37–e40.

**Narins RS, et al:** A randomized, double-blind, multicenter comparison of the efficacy and tolerability of Restylane versus Zyplast for the correction of nasolabial folds. *Dermatol Surg* 2003; 29:588.

**Requena L, et al:** Adverse reactions to injectable soft tissue fillers. *J Am Acad Dermatol* 2011; 64(1):1–34; quiz 35–36.

**Reszko AE, et al:** Late-onset subcutaneous nodules after poly-L-lactic acid injection. *Dermatol Surg* 2009; 35(Suppl 1):380–384.

**Sadick NS, et al:** A multicenter, 47-month study of safety and efficacy of calcium hydroxylapatite for soft tissue augmentation of nasolabial folds and other areas of the face. *Dermatol Surg* 2007; 33(Suppl 2):S122–S126.

**Sage RJ, et al:** Granulomatous foreign body reaction to hyaluronic acid: report of a case after melolabial fold augmentation and review of management. *Dermatol Surg* 2009; 35(Suppl 2):1696–1700.

**Tzikas TL:** A 52-month summary of results using calcium hydroxylapatite for facial soft tissue augmentation. *Dermatol Surg* 2008; 34(Suppl 1):S9–S15.

### BOTULINUM TOXIN

The use of botulinum toxin (BTX) in dermatology has increased rapidly over the years, and at present, it is one of the most common cosmetic procedure performed in the United States. In 2002, the FDA approved onabotulinumtoxinA for the treatment of dynamic glabellar frown lines. Although BTX is most frequently used for relaxation of dynamic rhytids in the upper third of the face, advanced aesthetic treatment techniques for additional anatomic sites have been developed and are currently used off-label.

Produced by *Clostridium botulinum*, there are seven different serotypes of BTX: A, B, C1, D, E, F, and G. These serotypes inhibit the release of acetylcholine from the presynaptic motor neuron, resulting in chemodeneration and paralysis of the treated muscle. Over time, new nerve terminals form and create new neuromuscular junctions with the muscle fibers, which gradually restore motor function.

BTX type A (Botox Cosmetic [onabotulinumtoxinA], Allergan; Dysport [abobotulinumtoxinA], Medicis); Xeomin (incobotulinumtoxinA; Merz) is the most common serotype. Its mechanism of action is through the cleavage of SNAP-25, a presynaptic membrane protein required for fusion of neurotransmitter-containing vesicles. Effect is generally noted 2–5 days after treatment with BTX-A, but the delay can be as long as 2 weeks in some cases. Results can last 2–5 months. In addition to aesthetic indications, onabotulinumtoxinA is FDA approved for the treatment of blepharospasm, strabismus, cervical dystonia, upper limb spasticity, chronic migraine, urinary incontinence, and axillary hyperhidrosis.

Each of these BTX-A products has a similar mechanism of action, but each formulation also has unique characteristics. For dosing purposes, onabotulinumtoxinA and incobotulinumtoxinA have a similar potency (clinical equivalency ratio of 1 unit = 1 unit). AbobotulinumtoxinA has equivalency of 3:1 compared with the other formulations. Therefore, it is critical that physicians perform appropriate dosage conversions when switching among different products. AbobotulinumtoxinA appears to have greater spread once injected into the skin. IncobotulinumtoxinA is unique in that it is



formulated with no complex proteins and thus, in theory, may have a lower risk of neutralizing antibody formation (although the risks of this occurring in aesthetic use is exceedingly low with all current formulations of BTX-A). In addition, incobotulinumtoxinA has the advantage of being able to be stored refrigerated or at room temperature, whereas the other products require refrigeration.

The only other serotype that is currently available commercially is BTX type B (Myobloc [rimabotulinumtoxinB]; Solstice Neurosciences, Malvern, PA). Its mechanism of action is through the cleavage of a vesicle-associated membrane protein (VAMP), also known as synaptobrevin. This serotype has more rapid onset of effect than BTX-A. In addition, differences in potency suggest that approximately 100 units of Myobloc are equivalent to 1 unit of Botox. It currently has FDA approval for the treatment of cervical dystonia.

BTX-A is distributed in vials as a vacuum-dried powder, which is reconstituted with 1.0–5.0 mL of saline. Many physicians think that the dilution of BTX does not make a significant difference in patient outcome, and studies appear to confirm this. Others argue that higher concentrations with smaller injection volumes reduce the amount of unintended diffusion. It is more important to use the same dilution every time to ensure that the physician does not need to do “mental math,” and to reduce confusion with each new vial of BTX.

Despite package insert recommendations, experience suggests that there is little loss of potency over several weeks following reconstitution with preserved saline. The use of preserved saline for reconstitution reduces the burning and pain associated with injection from the anesthetic properties of the benzyl alcohol in preserved saline.

BTX-A is predominantly used in dermatology for treatment of dynamic rhytids on the upper third of the face. The key to successful treatment is understanding the anatomy involved in facial expression, rather than performing the procedure by rote. Having the patient frown, squint, and raise the brows before treatment helps identify the active target muscles and serves as a guide for proper placement.

## Glabellar frown lines

Currently, treatment of glabellar frown lines is the only FDA-approved cosmetic indication for BTX-A. These lines result from contraction of the corrugator supercilii muscle, which pulls the brows medially, and the procerus muscle, which pulls the brow inferiorly. In addition, by inactivating the brow depressors, unopposed action of the brow elevators (e.g., frontalis muscle) can result in a slight but noticeable brow lift.

Approximately 20–35 units of onabotulinumtoxinA (or equivalent if using different product), are typically injected into the corrugators and procerus in a five-point injection method (Fig. 39-3; also see Video 39-2). Male patients and those with larger muscle mass may require a higher number of units (30–50). By having the patient furrow the brow, one can identify the origin and insertion of the corrugator supercilii. By grasping with the thumb and index finger, the physician can isolate the muscle and ensure accurate toxin placement.

If toxin diffuses through the orbital septum into the orbit, weakening of the levator palpebrae muscle can result in upper lid ptosis. Care should be taken to inject 1 cm above the superior bony orbital rim to reduce risk of diffusion of toxin and the resulting complication. The use of  $\alpha$ -adrenergic agonist eye drops, such as apraclonidine 0.5% or phenylephrine 2.5%, can stimulate Müller’s muscles in the lid, providing some relief until the effects of the BTX-A dissipate.

## Horizontal forehead lines

Horizontal forehead lines are caused by contraction of the frontalis muscle, which produces elevation and movement of the eyebrows. Care must be taken when treating this area with BTX-A to avoid ptosis or “heaviness” of the brow. Extra caution should be used in men with low-set brows or older patients who use their frontalis to raise their eyebrows to assist with vision.

Since the lower portion of the frontalis is primarily responsible for brow elevation, injections are often limited to the upper half or two thirds of the muscle. Between 10 and 25 units of onabotulinumtoxinA (or equivalent if using different product), delivered in multiple superficial injections across the forehead, is typically used for this area (see Video 39-3).

If upper lateral fibers of the frontalis remain totally untreated, the increased resting muscle tone will raise the lateral edge of the eyebrow, creating a quizzical look (Fig. 39-4). Injecting a small amount of BTX-A in the upper lateral brow can help correct this.

## Crow’s feet

Crow’s feet are rhytids that extend radially from the lateral canthus and are produced by contraction of the lateral orbicularis oculi. Even with successful treatment with BTX-A, rhytids may still persist because of the upward motion of the cheek when the patient smiles. Proper preoperative counseling is required to prevent frustrated patients.

Superficial blebs are raised approximately 1 cm lateral to the lateral canthus (Fig. 39-5). Between 8 and 12 units of onabotulinumtoxinA (or equivalent if using different product) are placed around each orbit. Care should be taken to orient the needle away from the globe as a safety precaution, in case the patient moves unexpectedly.

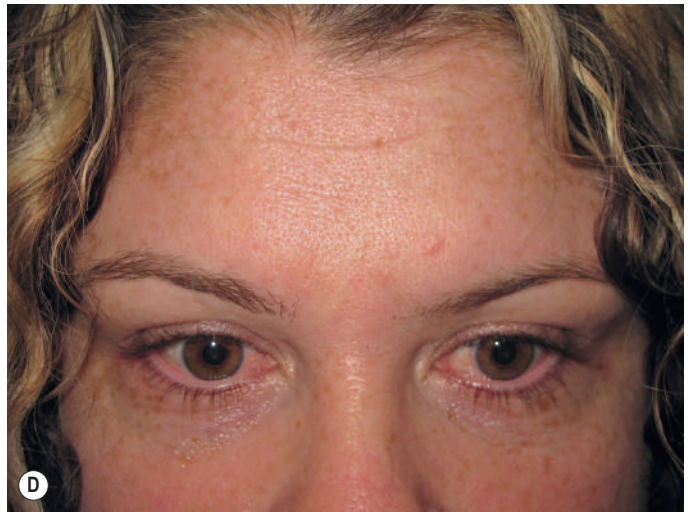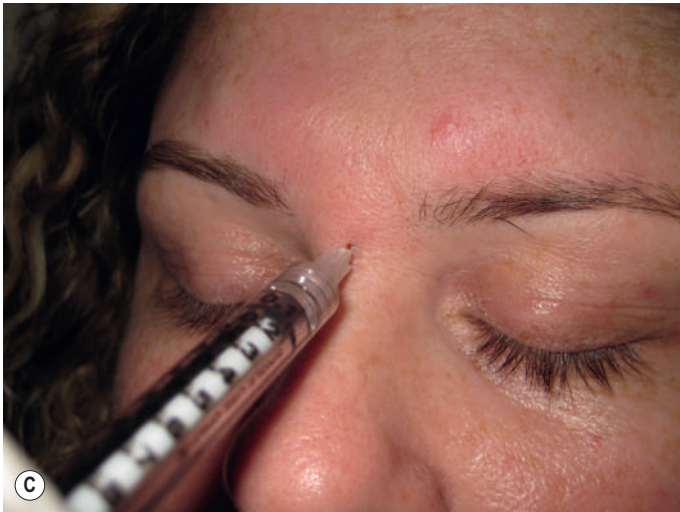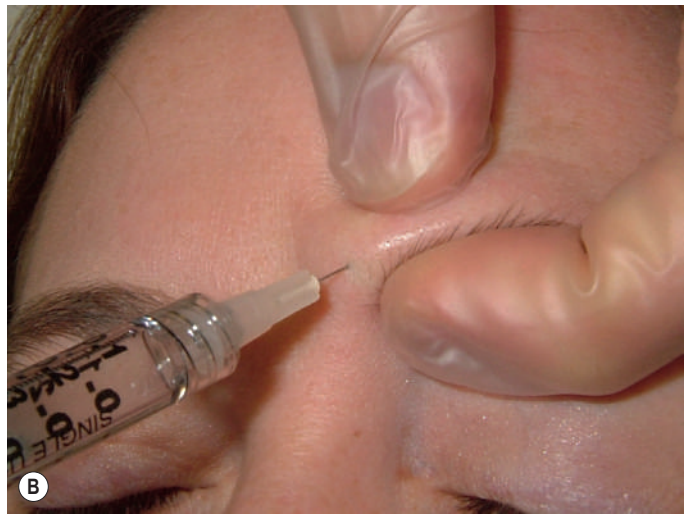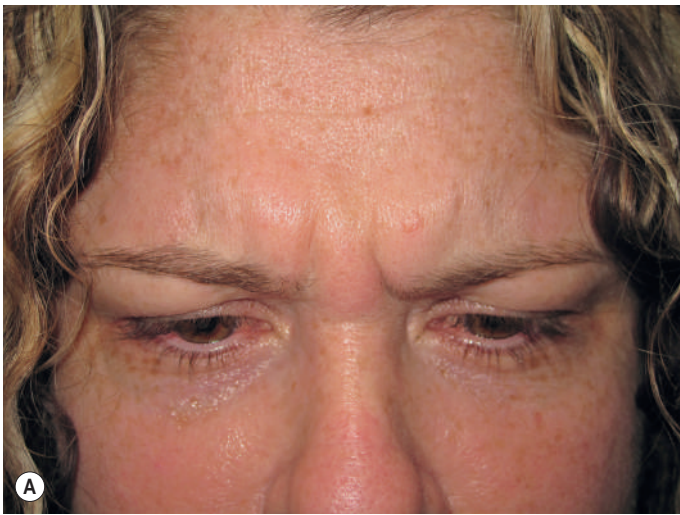Bruising is common in this location because of the thinness of the skin and the presence of numerous periorcular superficial veins. Purpura can be minimized by injecting superficially, ensuring proper illumination and stretching of the skin to help identify the veins, and limiting the total number of injections. Diffusion into the zygomaticus major and minor muscles, leading to ipsilateral lip ptosis and asymmetric smile, can occur with overzealous treatment of the inferior portion of the orbicularis oculi muscle.

## Other locations

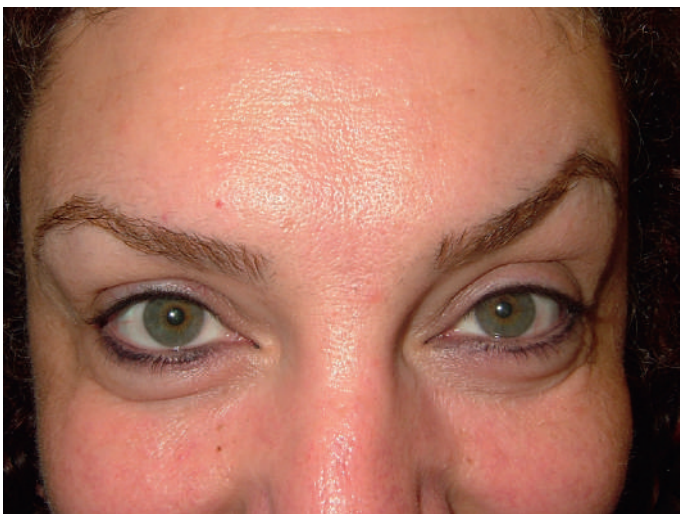Other sites that can be treated with BTX-A include platysmal bands, diagonal creases along the nasal side wall (“sniff lines” or “bunny lines”), mental crease, and depressor anguli oris muscle (for frowning of lateral corners of mouth). Care must be taken when treating the lower third of the face to avoid complications with mouth and lip control. Excessive or misplaced BTX-A in the platysmal bands can cause dysphagia, dysphonia, and neck weakness.

## Hyperhidrosis

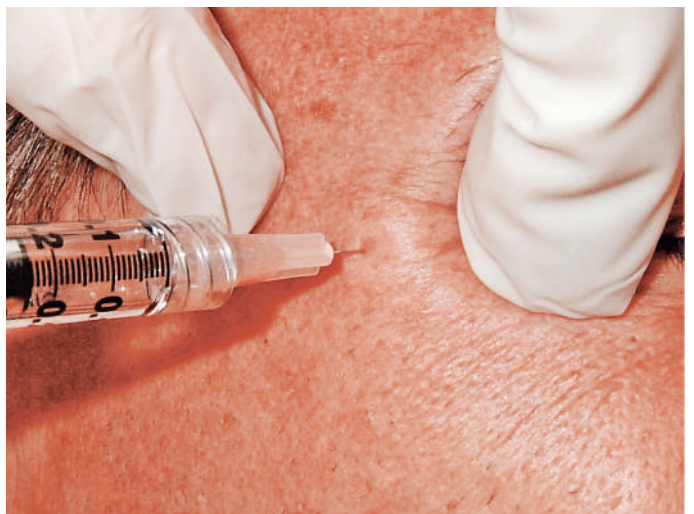In addition to cosmetic uses, onabotulinumtoxinA is FDA approved for the treatment of axillary hyperhidrosis. Before treatment, a Minor’s starch-iodine test is used to document both the severity and the location of excessive sweating (Fig. 39-6; also see Video 39-4). Effective treatment can be achieved with doses of 50 units/axilla, although some patients do require higher doses. Intradermal injections are spaced in a grid 1 cm



**Fig. 39-3** Botulinum toxin injection technique for glabellar frown furrow. A, Glabellar lines with frowning. B, As patient frowns, the muscle is grasped between thumb and index finger; the injection is placed directly into the belly of the corrugator supercilii muscle. C, Injection into the procerus muscle. D, Patient attempting to frown after botulinum toxin injection.

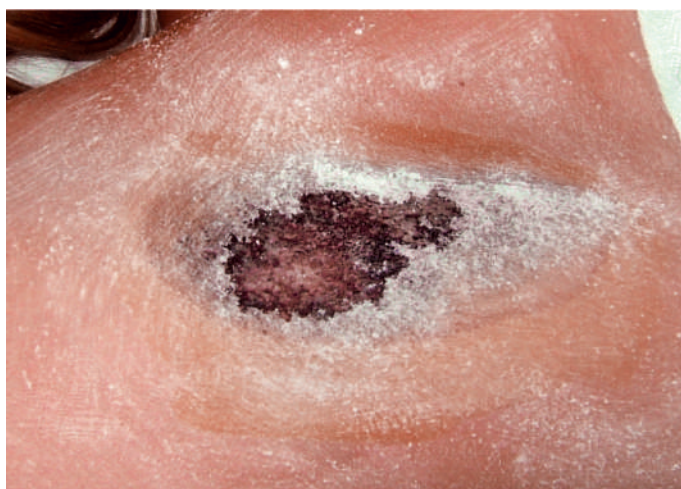


**Fig. 39-4** Botulinum toxin complication: "quizzical" brow look.

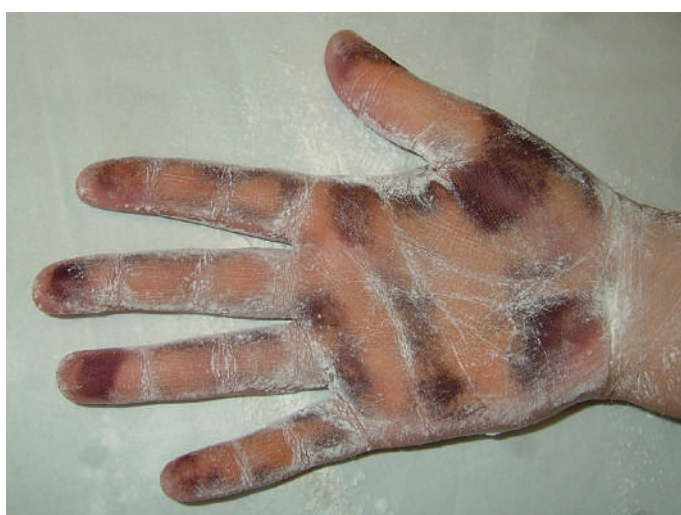

**Fig. 39-5** Botulinum toxin injection technique for crow's feet. Superficial injection is approximately 1 cm from the orbital rim.





**Fig. 39-6** Starch-iodine test; developing positive test with darkening in areas of hyperhidrosis.



**Fig. 39-7** Starch-iodine test; partial response to botulinum toxin.

▶ apart over the entire area. Anhidrosis is achieved within 1 week and typically lasts for 4–12 months (see Video 39-5). Side effects are generally limited to injection site bruising.

Treatment of palmar hyperhidrosis with BTX-A is more complicated than treating the axilla. Higher doses, typically 100–150 units/palm, are required because of the greater surface area involved and the limited diffusion of the toxin in acral skin. Pain is more significant when treating the palm and typically requires the use of wrist nerve blocks. Lastly, a slight muscle weakness of the hands, manifested by the loss of fine motor movement, is typically seen for several weeks after treatment.

Frequently, there are focal areas of activity after treatment for hyperhidrosis. However, since the sweat diffuses over the entire surface, patients often describe a false sensation of severe sweating and complain that the treatment “didn’t work.” By repeating the starch-iodine test, the focal areas of activity can be identified and directed touch-up performed (Fig. 39-7). Repeated treatments over time appear to increase the duration of efficacy for resulting injections.

**Absar MS, Onwudike M:** Efficacy of botulinum toxin type A in the treatment of focal axillary hyperhidrosis. *Dermatol Surg* 2008; 34(6):751–755.

**Alam M, et al:** Pain associated with injection of botulinum A exotoxin reconstituted using isotonic sodium chloride with and without

preservative: a double-blind, randomized controlled trial. *Arch Dermatol* 2002; 138:510.

**Allen SB, Goldenberg NA:** Pain difference associated with injection of abobotulinumtoxinA reconstituted with preserved saline and preservative-free saline: a prospective, randomized, side-by-side, double-blind study. *Dermatol Surg* 2012; 38(6):867–70.

**Baumann L, Black L:** Botulinum toxin type B (Myobloc). *Dermatol Surg* 2003; 29:496.

**Carruthers A, et al:** The convergence of medicine and neurotoxins: a focus on botulinum toxin type A and its application in aesthetic medicine: a global, evidence-based botulinum toxin consensus education initiative. Part I. Botulinum toxin in clinical and cosmetic practice. *Dermatol Surg* 2013; 39(3 Pt 2):493–509.

**Carruthers A, et al:** The convergence of medicine and neurotoxins: a focus on botulinum toxin type A and its application in aesthetic medicine: a global, evidence-based botulinum toxin consensus education initiative. Part II. Incorporating botulinum toxin into aesthetic clinical practice. *Dermatol Surg* 2013; 39(3 Pt 2):510–25.

**Carruthers A, et al:** Multicenter, randomized, Phase III study of a single dose of incobotulinumtoxinA, free from complexing proteins, in the treatment of glabellar frown lines. *Dermatol Surg* 2013; 39(4):551–558.

**Hanke CW, et al:** A randomized, placebo-controlled, double-blind Phase III trial investigating the efficacy and safety of incobotulinumtoxinA in the treatment of glabellar frown lines using a stringent composite endpoint. *Dermatol Surg* 2013; 39(6):891–899.

**Hayton MJ, et al:** A review of peripheral nerve blockade as local anaesthesia in the treatment of palmar hyperhidrosis. *Br J Dermatol* 2003; 149:447.

**Kiripolsky MG, et al:** A two-phase, retrospective analysis evaluating efficacy of and patient satisfaction with abobotulinumtoxinA used to treat dynamic facial rhytides. *Dermatol Surg* 2011; 37(10):1443–1447.

**Lecouflet M, et al:** Duration of efficacy increases with the repetition of botulinum toxin A injections in primary axillary hyperhidrosis: a study in 83 patients. *J Am Acad Dermatol* 2013; 69(6):960–964.

**Liu A, et al:** Recommendations and current practices for the reconstitution and storage of botulinum toxin type A. *J Am Acad Dermatol* 2012; 67(3):373–378.

**Lowe NJ, et al:** Botulinum toxin type A in the treatment of primary axillary hyperhidrosis: a 52-week multicenter double-blind, randomized, placebo-controlled study of efficacy and safety. North American Botox in Primary Axillary Hyperhidrosis Clinical Study Group. *J Am Acad Dermatol* 2007; 56(4):604–611.

**Pena MA, et al:** Complications with the use of botulinum toxin type A for cosmetic applications and hyperhidrosis. *Semin Cutan Med Surg* 2007; 26(1):29–33.

**Solish N, et al:** A comprehensive approach to the recognition, diagnosis, and severity-based treatment of focal hyperhidrosis: recommendations of the Canadian Hyperhidrosis Advisory Committee. *Dermatol Surg* 2007; 33(8):908–923.

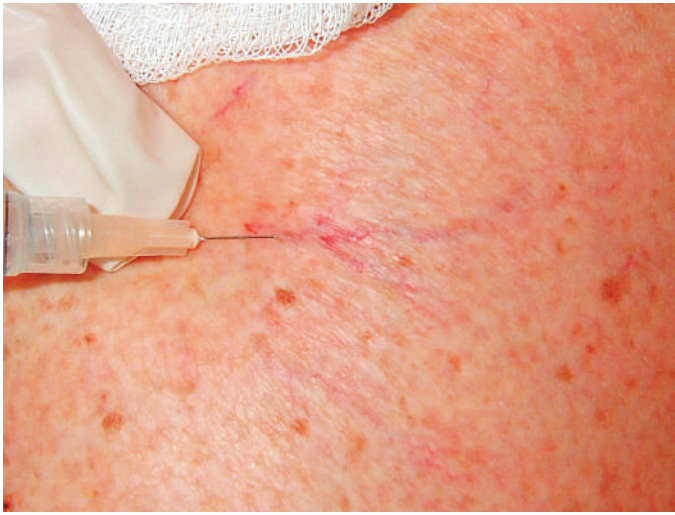## VARICOSE AND TELANGIECTATIC VEINS

### Sclerotherapy

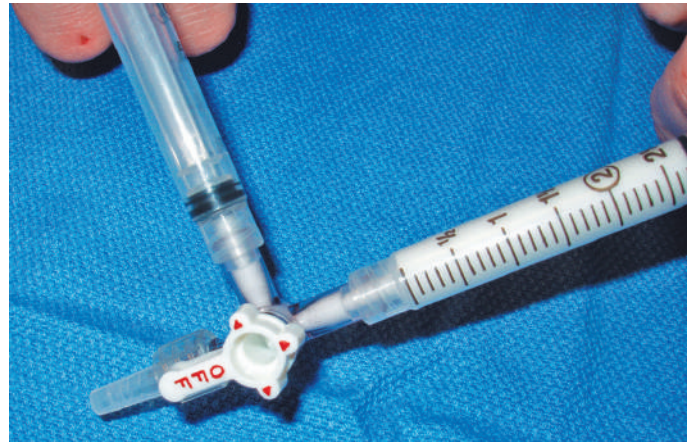
▶ Patients frequently seek treatment of telangiectasias and reticular veins in the lower extremities. Historically, the treatment of choice for telangiectatic and reticular veins has been sclerotherapy (Fig. 39-8; also see Video 39-6). However, some studies suggest that laser treatment for lower extremity telangiectasia can be as effective as sclerotherapy. In addition, laser therapy can be considered in patients who failed to respond to sclerotherapy or had significant complications from sclerotherapy. However, many believe that sclerotherapy should be first-line treatment for vessels that can be cannulated with a needle.

### Sclerosing solutions

There are three broad classes of sclerosing agent available to dermatologists: hyperosmotic agents, detergents, and chemical irritants (Table 39-1). Hyperosmotic agents cause endothelial cell damage through dehydration; detergents disrupt the



**Fig. 39-8** Sclerotherapy; injection technique using fine needle to cannulate vein.



**Fig. 39-9** Sclerosing foam. Sodium tetradecyl sulfate (STS) foam is made by mixing air with liquid using a three-way stopcock and two syringes.

**Table 39-1** Sclerotherapy agents

Agent	Class	FDA approved	Comments
Hypertonic saline	Hyperosmotic	Yes	No allergenicity; painful
Hypertonic saline (10%) plus dextrose (25%)	Hyperosmotic	No	Lower allergenicity; painful
Sodium tetradecyl sulfate	Detergent	Yes	Can be used as foam; painless except with extravascular injection
Polidocanol	Detergent	Yes	Painless; can be used as foam
Sodium morrhuate	Detergent	Yes	High risk of allergic reaction
Chromated glycerin	Chemical irritant	No	Weak agent
Polyiodinated iodine	Chemical irritant	No	Highly caustic

cellular membrane; and chemical irritants act as a corrosive and lead to endothelial injury.

Hypertonic saline is an FDA-approved agent frequently used in sclerotherapy. At concentrations of 10–30%, this agent has the advantage of a complete lack of allergenicity when used alone. The disadvantage of hypertonic saline is pain associated with injections and ulcerogenic potential. Often, anesthetic agents such as lidocaine are added to the mixture to minimize the discomfort involved, by decreasing the concentration of the saline and through the direct anesthetic effect.

Hypertonic saline (10%) mixed with dextrose (25%) is another hyperosmolar agent that has been used in vein sclerosing. This agent has the advantages of low allergenicity and decreased pain compared with higher concentrations of plain

hypertonic saline. However, this mixture is currently not FDA approved and is a relatively weak sclerosant compared to other options available.

Sodium tetradecyl sulfate (STS) or Sotradecol (AngioDynamics, Latham, NY) is a detergent sclerosant that has been FDA approved for 55 years. Typical concentrations used for superficial telangiectasias are 0.1–0.2%, and reticular veins can be treated with 0.2–0.5%. One advantage of STS is the lack of pain with injections; however, extravascular injection can be painful.

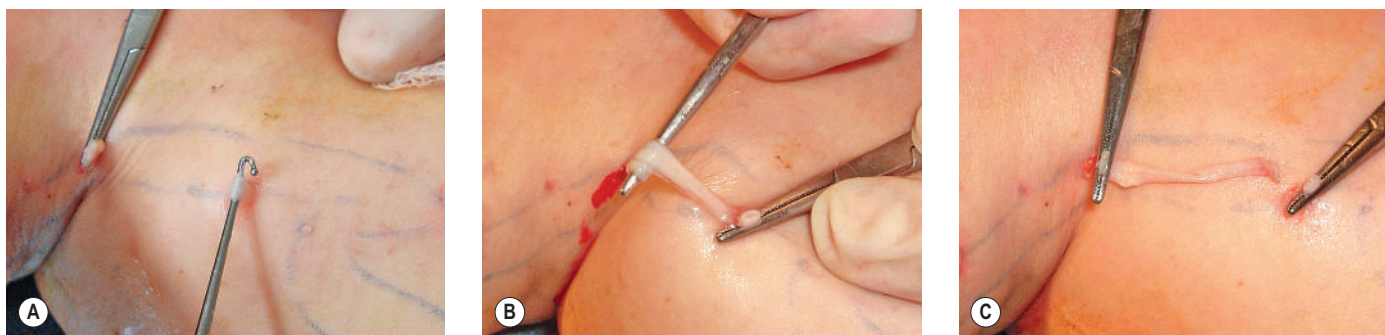Polidocanol (Asclera; Merz Aesthetics, San Mateo, CA), a detergent, is FDA approved for use in sclerotherapy and comes in 0.5% (for vessels <1 mm in diameter) and 1% concentrations (for reticular veins <3 mm). It possesses many of the same advantages as STS, including lack of pain with injection and the ability to be used as foam. Goldman demonstrated comparable efficacy and a similar adverse event profile between polidocanol and STS.

As detergents, both STS and polidocanol can be made into foam. This is typically done with a three-way stopcock and a syringe filled with air (Fig. 39-9; also see Video 39-7). Foam can increase contact between the agent and the vessel wall, can result in more effective sclerosis at a lower concentration, and allows treatment of larger-caliber vessels. Foam tends to degrade fairly quickly (1–2 min), so it should be mixed immediately before injection. The bubble size created correlates to the stability of the foam created, with microfoam (<50  $\mu$ ) being more stable than larger foam (>100  $\mu$ ). Foam technique has historically been an off-label use of polidocanol or STS but has been used widely with successful results and a high degree of safety. However, Varithena (BTG, London) is a polidocanol injectable nitrogen foam product approved by the FDA in 2013 and is indicated for the treatment of incompetent great saphenous veins, accessory saphenous veins, and visible varicosities of the great saphenous vein system above and below the knee.

Sodium morrhuate is a detergent approved by the FDA for treatment of varicose veins. However, this sclerosing agent is not generally used for the treatment of cutaneous telangiectasias because of its highly caustic nature and higher anaphylaxis potential.

Glycerin and polyiodide iodine are chemical irritants used as sclerosing agents. Although not FDA approved for sclerotherapy, these act as corrosive agents and cause a direct injury to the vessel endothelium. Leach and Goldman report a significant decrease in bruising, swelling, and postprocedural hyperpigmentation with glycerin compared with STS.





**Fig. 39-10** Ambulatory phlebectomy. A, Hook used to secure the vein. B, Vein is clamped on either side and severed. Clamp is then used to remove the vein using a rolling and pulling technique. C, Removed vein segment. The distal end can be tied off using absorbable suture, or additional segments can be removed using the same technique.

## Complications

Side effects and complications of sclerotherapy can be associated with all types of sclerosing agent. Ulceration can occur despite the meticulous technique of the dermatologist and regardless of the sclerosing agent used. Extravasation of sclerosing solution from the vein may occur, or injection into a dermal arteriole or arteriovenous anastomosis may result in cutaneous necrosis. If extravasation is suspected, injection of normal saline to dilute the sclerosing agent may prevent ulceration. Alternatively, application of 2% nitroglycerin ointment may prove beneficial. If ulceration does occur, conservative wound management should be undertaken until healed.

Hyperpigmentation along the course of treated veins has been reported to occur in 10–30% of patients. This pigmentation is caused by hemosiderin deposition and has been reported with a variety of sclerosing agents, including hypertonic saline, polidocanol, and STS. Pigmentation often improves with time, with approximately 70% improvement over a 6-month period. Treatment options include trichloroacetic acid, hydroquinone, retinoic acid cream, intense pulsed light, and laser treatments. Tafazzoli et al. report excellent results with the Q-switched ruby laser.

Telangiectatic matting is the appearance of fine telangiectatic blush at the site of previously treated veins. This has been reported in 10–15% of patients treated with sclerotherapy. Risk factors associated with this include estrogen therapy, obesity, and a family history of telangiectasia. Low injection pressures and limiting the amount of sclerosant per injection site may help reduce the incidence of telangiectatic matting. Spontaneous resolution often occurs in 3–12 months. Treatment options include intense pulsed light, pulsed dye laser, and injection of sclerosant into the matted vessels.

Arterial injection of sclerosant is the most serious complication of vein sclerosing. Although rare, it has considerable associated morbidity and necessitates timely action. Classically, the patient reports significant pain immediately after injection, accompanied by pallor and cyanosis. If arterial injection occurs, the physician should immediately apply ice and attempt to dilute the vessel with injections of normal saline. Procaine can be used to inactivate STS. Intravenous heparin and thrombolysis should be considered.

## Ambulatory phlebectomy

Ambulatory phlebectomy is an outpatient procedure used to remove varicose veins, employing skin hooks through a series of stab incisions along the course of the varicosity. Tumescence anesthesia is often used during this technique and has the

added benefit of compression of the vein and reduction of blood loss. Various hooks and clamps are used to remove the vein (Fig. 39-10). Incision sites heal with minimal scarring. Adverse effects are generally limited and consist of minor pain and bruising. Infection and nerve damage are extremely rare.

## Endovenous ablation

Endovenous ablation should be considered in patients with greater saphenous incompetence and is rapidly replacing traditional vein stripping. In patients with lower extremity telangiectasia and reticular veins, prior assessment of underlying saphenous reflux is necessary to prevent recurrence following treatment of the visible varicosities.

Radiofrequency or laser (using 810 nm or 1320 nm) can be used to heat and damage veins. Either method results in vein wall shrinkage and subsequent vessel thrombosis and occlusion. Tumescence anesthesia allows the procedure to be performed painlessly, surrounds and compresses the vein for greater contact between the catheter and vessel wall, and distends the skin away from the heat source, preventing cutaneous damage. A catheter is placed under ultrasound guidance and guided to the saphenofemoral junction. The catheter is slowly withdrawn along the length of the vein, and the thermal injury leads to vessel occlusion.

The most common complications include ecchymosis and pain. Thermal burns of the skin are infrequently seen when tumescence anesthesia is properly used. Nerve injury is uncommon, and paresthesias are often temporary. Deep vein thrombosis has been documented, but pulmonary embolism is extremely rare when the technique is performed properly.

**Brasic N, et al:** Endovenous laser ablation and sclerotherapy for treatment of varicose veins. *Semin Cutan Med Surg* 2008; 27(4):264–275.

**Goldman MP:** Treatment of varicose and telangiectatic leg veins: double-blind prospective comparative trial between Aethoxyskerol and Sotradecol. *Dermatol Surg* 2002; 28:52.

**Kern P, et al:** A double-blind, randomized study comparing pure chromated glycerin with chromated glycerin with 1% lidocaine and epinephrine for sclerotherapy of telangiectasias and reticular veins. *Dermatol Surg* 2011; 37(11):1590–1594.

**Leach BC, Goldman MP:** Comparative trial between sodium tetradecyl sulfate and glycerin in the treatment of telangiectatic leg veins. *Dermatol Surg* 2003; 29:612.

**Lupton JR, et al:** Clinical comparison of sclerotherapy versus long-pulsed Nd:YAG laser treatment for lower extremity telangiectases. *Dermatol Surg* 2002; 28:694.

**Malskat WS, et al:** Endovenous laser ablation (EVLA): a review of mechanisms, modeling outcomes, and issues for debate. *Lasers Med Sci* 2014; 29(2):393–403.

- Moul DK, et al:** Endovenous laser ablation of the great and short saphenous veins with a 1320-nm neodymium:yttrium-aluminum-garnet laser: retrospective case series of 1171 procedures. *J Am Acad Dermatol* 2014; 70(2):326–331.
- Munavalli GS, Weiss RA:** Complications of sclerotherapy. *Semin Cutan Med Surg* 2007; 26(1):22–28.
- Munia MA, et al:** Comparison of laser versus sclerotherapy in the treatment of lower extremity telangiectases: a prospective study. *Dermatol Surg* 2012; 38(4):635–639.
- Nijsten T, et al:** Minimally invasive techniques in the treatment of saphenous varicose veins. *J Am Acad Dermatol* 2009; 60(1):110–119.
- Peterson JD, et al:** Treatment of reticular and telangiectatic leg veins: double-blind, prospective comparative trial of polidocanol and hypertonic saline. *Dermatol Surg* 2012; 38(8):1322–1330.
- Ramelet AA:** Phlebectomy: technique, indications and complications. *Int Angiol* 2002; 21:46.
- Rao J, et al:** Double-blind prospective comparative trial between foamed and liquid polidocanol and sodium tetradecyl sulfate in the treatment of varicose and telangiectatic leg veins. *Dermatol Surg* 2005; 31(6):631–635.
- Sadick NS:** Choosing the appropriate sclerosing concentration for vessel diameter. *Dermatol Surg* 2010; 36(Suppl 2):976–981.
- Stücker M, et al:** Review of published information on foam sclerotherapy. *Dermatol Surg* 2010; 36(Suppl 2):983–992.
- Tafazzoli A, et al:** Q-switched ruby laser treatment for postsclerotherapy hyperpigmentation. *Dermatol Surg* 2000; 26:653.
- Uurto I, et al:** Single-center experience with foam sclerotherapy without ultrasound guidance for treatment of varicose veins. *Dermatol Surg* 2007; 33(11):1334–1339.
- Van Den Bos RR, et al:** Endovenous laser ablation-induced complications: review of the literature and new cases. *Dermatol Surg* 2009; 35(8):1206–1214.

## LIPOSUCTION

Liposuction is used for the removal of local areas of adipose and to improve body contour. It is not a treatment for obesity and should not be used as a weight loss mechanism. The most common areas treated are the abdomen and thighs, neck, jowls, knees, ankles, and breasts (Fig. 39-11). Additional conditions, such as gynecomastia, buffalo hump, lipoma, lipodystrophy, and axillary hyperhidrosis, can be treated by liposuction.

The most common technique employed by dermatologists involves infiltrating the treated area with dilute anesthesia and aspirating the fat through cannulas attached to a vacuum. The choice of cannula can determine the amount of fat aspirated, with more aggressive cannulas having a larger bore, being pointier, and having multiple, larger holes placed near the tip. Tumescent anesthesia typically consists of 0.05–0.1% lidocaine

with 1:1 million epinephrine and sodium bicarbonate. The total safe concentration of lidocaine that can be used is 55 mg/kg. The benefits of tumescent anesthesia are the ability to perform the procedure comfortably under local anesthesia, hemostasis, and hydrodissection of adipocytes, which facilitates aspiration. Laser-assisted lipolysis has not been shown to be superior to traditional tumescent liposuction.

Much discussion surrounds the safety of office-based liposuction. It is important to stress that the serious complications seen in liposuction are associated with general anesthesia, not with procedures performed with local tumescent anesthesia. Although deaths have been reported during liposuction, none has occurred when patients were treated with tumescent anesthesia alone. Office-based tumescent liposuction performed by dermatologic surgeons is safe and has a lower complication rate than hospital-based procedures.

**Coldiron BM, et al:** Office surgery incidents: what seven years of Florida data show us. *Dermatol Surg* 2008; 34(3):285–291; discussion 291–292.

**Coleman WP 3rd, et al:** Guidelines of care for liposuction. *J Am Acad Dermatol* 2001; 45:438.

**Fakhouri TM, et al:** Laser-assisted lipolysis: a review. *Dermatol Surg* 2012; 38(2):155–169.

**Habbema L:** Safety of liposuction using exclusively tumescent local anesthesia in 3,240 consecutive cases. *Dermatol Surg* 2009; 35(11):1728–1735.

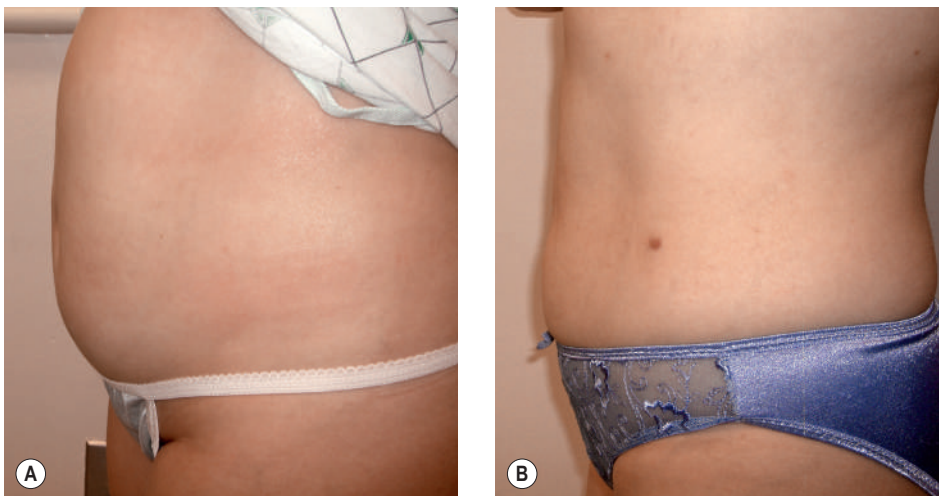
**Housman TS, et al:** The safety of liposuction: results of a national survey. *Dermatol Surg* 2002; 28:971.

**Ibrahim O, et al:** The comparative effectiveness of suction-curettage and onabotulinumtoxin-A injections for the treatment of primary focal axillary hyperhidrosis: a randomized control trial. *J Am Acad Dermatol* 2013; 69(1):88–95.

## CHEMICAL PEELS

### Superficial peel

Peels are categorized by the level of injury they cause. Superficial peels cause wounding to the epidermis and may reach the papillary dermis. These peels are well tolerated by patients who require limited “downtime” after treatment. Superficial peels are used in the treatment of photoaging, acne, actinic keratoses, solar lentigines, and pigmentary dyschromias. Given the limited nature of the injury induced by these peels, patients often need multiple treatments on a weekly or monthly basis to reach a desired result. However, patients need to be properly counseled regarding the limited benefit of superficial peels, which cannot provide the improvement in wrinkles and



**Fig. 39-11** Tumescent liposuction. A, Before treatment of abdomen. B, After treatment.



deep furrows that may be possible with deeper injury peels. Repeated superficial peels cannot produce the same results as a single, deeper peel.

Alpha-hydroxy acids (AHAs), naturally occurring agents that are typically derived from foods, include glycolic acid (sugarcane), lactic acid (sour milk), malic acid (apples), and citric acid (citrus fruits). Glycolic acid has the smallest molecular size and thus the greatest bioavailability, making it one of the most frequently used AHAs. The depth of injury is determined by the pH, concentration of the acid, amount applied, and length of treatment time. Glycolic acid, in concentrations up to 70%, is often used for melasma, acne, and photoaging. Following rapid application to the entire face, it must be neutralized with sodium bicarbonate or plain water. Glycolic acid has been used in combination with 5-FU for the treatment of actinic keratoses.

Salicylic acid, a  $\beta$ -hydroxy acid, can be used in concentrations of 20–30% for the treatment of acne and mild photoaging. It is especially useful as an adjunctive treatment for acne because of both the keratolytic and the comedolytic properties of salicylic acid. It is also used in combination with other agents as part of Jessner's solution. Salicylic acid tends to be less inflammatory than other superficial chemical peels. After application, patients experience some mild stinging and discomfort. A whitening of the skin, termed frosting, from the precipitation of salicylic acid crystals is noted within several minutes of application. Salicylic acid does not require neutralization, although cool compresses after application can soothe the skin.

Trichloroacetic acid (TCA) in concentrations of 10–25% is used extensively as a superficial peel. The depth of injury is related to the concentration and the number of applications, with repeated coats of a low-concentration TCA leading to greater penetration. The agent is applied, and erythema and a white frost are noted within 1 minute. Patients experience a burning sensation. Handheld fans and postprocedural cool compresses can reduce discomfort. TCA does not require neutralization after application.

Jessner's solution combines resorcinol, salicylic acid, and lactic acid in ethanol (Table 39-2). This superficial peel has keratolytic activity and is typically used for acne or hyperkeratotic lesions. It is self-neutralizing, and multiple applications can be performed to obtain a deeper injury.

Solid CO<sub>2</sub> (dry ice) has been used alone and in combination with TCA to obtain a deeper peel. It has been proposed as an effective treatment for acne scars and as a way to potentiate the effect of TCA to achieve a deeper peel.

### Medium-depth peel

Medium-depth chemical peeling is defined as a controlled wound through the epidermis and down to the deep papillary dermis. In contrast to the multiple treatments that are often performed with superficial peels, medium-depth peels are

generally done as a single procedure because of the more significant injury produced and more robust clinical response. These peels cause epidermal necrosis and dermal injury, which result in increased collagen production during the wound-healing process over the next several months. Medium-depth peels are indicated for the treatment of mild to moderate photodamage, rhytids, pigmentary dyschromias, actinic keratoses, solar lentiginos, and other epidermal growths.

The classic medium-depth peel is 50% TCA. However, it is generally not used currently as a single-agent peel because of its unpredictable results and increased incidence of scarring and dyspigmentation. Rather, combining 35% TCA with an initial application of another agent, such as Jessner's solution or glycolic acid, can produce a medium-depth injury without the complications associated with higher concentrations of TCA alone. As a result of the damage to the epidermis produced with the initial peel, the lower-strength TCA is able to penetrate deeper and produce a more significant and even result.

Antiviral prophylaxis should be used in any full-face medium-depth peel because of the potential risk of herpes simplex virus (HSV) activation. Acyclovir, 400 mg three times daily, or valacyclovir, 500 mg twice daily, can be started at the time of peel and continued until complete reepithelialization has occurred, typically 7–10 days. Prophylactic antibiotic therapy has no role in these full-face peels.

### Deep peel

Deep chemical peels are defined as those that cause an injury down to the midreticular dermis. These peels are indicated for patients with moderate to severe photodamage and advanced rhytids. Deep peels produce significant injury, and patients have an extended period of postoperative healing.

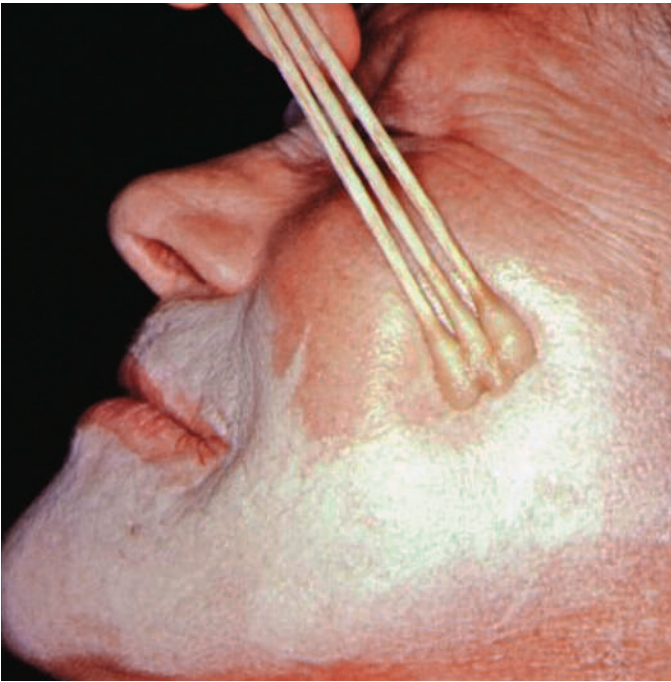Baker-Gordon formula phenol peel is the traditional deep peel (Fig. 39-12). Undiluted 88% phenol does not produce a deep or consistent injury because it causes complete coagulation of epidermal keratin proteins, thus blocking further penetration. The Baker-Gordon formula reduces the concentration of phenol to 55%; the croton oil acts as a keratolytic and potentiates the depth of penetration of the phenol (Table 39-3). Cardiac monitoring is required because phenol can produce arrhythmias. Intravenous fluids are given before and during the peel to limit the serum concentrations of phenol and any potential renal complications. In addition, the face is divided into smaller cosmetic units, which are treated individually. A 15-minute wait is required between treating each subunit, spreading the entire procedure over 1–2 hours, thus further limiting the systemic concentration of phenol. Following application, occlusive tape can be applied if a deeper wound is desired. The patients are managed conservatively in the postoperative period with petrolatum and wound care until the skin heals. In addition to the cardiac and systemic concerns associated with deep peels, other risks include

**Table 39-2** Jessner's solution

Agent	Amount
Resorcinol	14 g
Salicylic acid	14 g
85% lactic acid	14 g
95% ethanol qs ad	100 mL

**Table 39-3** Baker-Gordon formula

Agent	Amount
88% liquid phenol, USP	3 mL
Tap water	2 mL
Septisol liquid soap	8 drops
Croton oil	3 drops



**Fig. 39-12** Baker-Gordon phenol peel; white frosting after application. (Courtesy of Richard G. Glogau, MD).

hypopigmentation, textural abnormalities, and scarring. If any of the phenol solution accidentally contacts the eyes, mineral oil should be used to flush, because water can potentiate the effect of the phenol. Antiviral prophylaxis should be administered.

**Al-Waiz MM, Al-Sharqi AI:** Medium-depth chemical peels in the treatment of acne scars in dark-skinned individuals. *Dermatol Surg* 2002; 28(5):383–387.

**Bae BG, et al:** Salicylic acid peels versus Jessner's solution for acne vulgaris: a comparative study. *Dermatol Surg* 2013; 39(2):248–253.

**Garg VK, et al:** Glycolic acid peels versus salicylic-mandelic acid peels in active acne vulgaris and post-acne scarring and hyperpigmentation: a comparative study. *Dermatol Surg* 2009; 35(1):59–65.

**Kligman D, Kligman AM:** Salicylic acid peels for the treatment of photoaging. *Dermatol Surg* 1998; 24:325.

**Landau M:** Cardiac complications in deep chemical peels. *Dermatol Surg* 2007; 33(2):190–193.

**Marrero GM, Katz BE:** The new fluor-hydroxy pulse peel: a combination of 5-fluorouracil and glycolic acid. *Dermatol Surg* 1998; 24:973.

**Monheit GD:** Medium-depth chemical peels. *Dermatol Clin* 2001; 19:413.

**Sarkar R, et al:** The combination of glycolic acid peels with a topical regimen in the treatment of melasma in dark-skinned patients: a comparative study. *Dermatol Surg* 2002; 28(9):828–832.